




QUAIN'S ANATOMY.





23  
Q1  
1878  
V. 2  
Repts.

QUAIN'S

ELEMENTS OF ANATOMY

*W. Sharpey M.D.*  
EDITED BY  
*Sept 28 1880*

WILLIAM SHARPEY, M.D., LL.D., F.R.S. L. & E.,  
EMERITUS PROFESSOR OF ANATOMY AND PHYSIOLOGY IN UNIVERSITY COLLEGE, LONDON

ALLEN THOMSON, M.D., LL.D., F.R.S. L. & E.,  
PROFESSOR OF ANATOMY IN THE UNIVERSITY OF GLASGOW

AND


EDWARD ALBERT SCHÄFER  
ASSISTANT PROFESSOR OF PHYSIOLOGY IN UNIVERSITY COLLEGE, LONDON

IN TWO VOLUMES.


ILLUSTRATED BY UPWARDS OF 950 ENGRAVINGS ON WOOD.

VOL. II.

Eighth Edition.



NEW YORK  
WILLIAM WOOD AND CO., PUBLISHERS  
27 GREAT JONES STREET  
1878.



# CONTENTS.

## GENERAL ANATOMY.

|                                       | PAGE |                                             | PAGE |
|---------------------------------------|------|---------------------------------------------|------|
| <b>GENERAL CONSIDERATIONS ON THE</b>  |      | <b>Blood-Vessels, &amp;c.</b>               | 92   |
| <b>TEXTURES</b>                       |      | <b>Formation and Growth of Bone.</b>        | 94   |
| Enumeration of the Textures . . . . . | 1    | Ossification in Membrane . . . . .          | 94   |
| Organic Systems . . . . .             | 1    | Ossification in Cartilage . . . . .         | 97   |
| Structural Elements . . . . .         | 2    | Growth and Absorption of                    |      |
| Physical Properties . . . . .         | 2    | Bone . . . . .                              | 103  |
| Chemical Composition . . . . .        | 3    | <b>MUSCULAR TISSUE</b>                      | 107  |
| Vital Properties . . . . .            | 4    | Structure of Voluntary Muscles.             | 108  |
| <b>DEVELOPMENT OF THE TEXTURES</b>    | 6    | Sheath . . . . .                            | 108  |
| The Vegetable Cell . . . . .          | 7    | Fasciculi . . . . .                         | 109  |
| The Animal Cell . . . . .             | 8    | Fibres . . . . .                            | 111  |
| Nutrition and Regeneration of         |      | Blood-Vessels, &c. . . . .                  | 116  |
| the Textures . . . . .                | 16   | Involuntary Muscles . . . . .               | 118  |
| <b>THE BLOOD</b>                      | 18   | Development and Growth of                   |      |
| Physical and Organic Constitu-        |      | Muscle . . . . .                            | 120  |
| tion . . . . .                        | 18   | Composition and Properties of               |      |
| Chemical Composition . . . . .        | 25   | Muscular Tissue . . . . .                   | 121  |
| Coagulation of the Blood . . . . .    | 34   | <b>NERVOUS SYSTEM</b>                       | 125  |
| <b>THE LYMPH AND CHYLE</b>            | 37   | Structural Elements . . . . .               | 126  |
| Formation of the Corpuscles of        |      | White or Medullated Fibres . . . . .        | 126  |
| the Lymph and Chyle . . . . .         | 40   | Grey Fibres . . . . .                       | 131  |
| Formation of the Blood-Cor-           |      | Ganglia . . . . .                           | 136  |
| puscles . . . . .                     | 40   | The Cerebro-Spinal Nerves . . . . .         | 140  |
| <b>EPITHELIAL, EPIDERMIC, OR CU-</b>  |      | The Sympathetic or Ganglionic               |      |
| <b>TICULAR TISSUE</b>                 | 42   | Nerves . . . . .                            | 156  |
| Ciliated Epithelium . . . . .         | 46   | Chemical Composition . . . . .              | 159  |
| <b>PIGMENT</b>                        | 51   | Vital Properties . . . . .                  | 160  |
| <b>CONNECTIVE TISSUE</b>              | 52   | Development of Nerves . . . . .             | 161  |
| The Areolar Tissue . . . . .          | 53   | <b>BLOOD-VESSELS</b>                        | 163  |
| Adipose Tissue . . . . .              | 59   | Arteries . . . . .                          | 164  |
| Fibrous Tissue . . . . .              | 63   | Veins . . . . .                             | 172  |
| Yellow or Elastic Tissue . . . . .    | 66   | Smaller Arteries and Veins and              |      |
| Special Varieties of Connective       |      | Capillaries . . . . .                       | 175  |
| Tissue . . . . .                      | 68   | Development of Blood-Vessels . . . . .      | 180  |
| Development of the Connective         |      | <b>LYMPHATIC SYSTEM</b>                     | 183  |
| Tissue . . . . .                      | 70   | Lymphatic Glands . . . . .                  | 191  |
| <b>CARTILAGE</b>                      | 72   | <b>SEROUS MEMBRANES</b>                     | 196  |
| Hyaline Cartilage . . . . .           | 72   | <b>SYNOVIAL MEMBRANES</b>                   | 200  |
| Elastic or Yellow Cartilage . . . . . | 78   | <b>MUCOUS MEMBRANES</b>                     | 204  |
| White Fibro-Cartilage . . . . .       | 78   | <b>THE SKIN</b>                             | 211  |
| <b>BONE OR OSSEOUS TISSUE</b>         | 79   | Epidermis, Cuticle, or Scarf Skin . . . . . | 211  |
| Physical Properties . . . . .         | 80   | Corium . . . . .                            | 213  |
| Chemical Composition . . . . .        | 80   | Nails and Hairs . . . . .                   | 217  |
| Structure . . . . .                   | 81   | Glands of the Skin . . . . .                | 226  |
| Periosteum . . . . .                  | 91   | <b>SECRETING GLANDS</b>                     | 231  |
| Marrow . . . . .                      | 91   | <b>DUCTLESS OR VASCULAR GLANDS.</b>         | 238  |

## SPECIAL ANATOMY OF THE VISCERA.

|                                        | PAGE |                                    | PAGE |
|----------------------------------------|------|------------------------------------|------|
| THE THORACIC VISCERA . . . . .         | 239  | The Large Intestine . . . . .      | 371  |
| The Pericardium . . . . .              | 239  | Structure . . . . .                | 371  |
| THE HEART . . . . .                    | 242  | Special Characters and Con-        |      |
| Position of the Parts of the Heart     |      | nections of the Different          |      |
| with Relation to the Wall of           |      | Parts of the Large Intestine       | 374  |
| the Thorax . . . . .                   | 253  | The Anus and its Muscles . . . . . | 379  |
| Intimate Structure of the Heart.       | 255  | The Liver . . . . .                | 380  |
| Dimensions and Weight of the           |      | Structure . . . . .                | 386  |
| Heart . . . . .                        | 262  | The Pancreas . . . . .             | 394  |
| ORGANS OF RESPIRATION . . . . .        | 263  | The Spleen . . . . .               | 397  |
| The Trachea and Bronchi . . . . .      | 263  | Structure . . . . .                | 398  |
| Structure . . . . .                    | 266  | THE URINARY ORGANS . . . . .       | 402  |
| The Lungs and Pleuræ . . . . .         | 268  | Kidneys . . . . .                  | 402  |
| The Pleuræ . . . . .                   | 268  | Suprarenal Bodies . . . . .        | 413  |
| The Lungs . . . . .                    | 269  | The Ureters . . . . .              | 417  |
| Root of the Lung . . . . .             | 273  | The Urinary Bladder . . . . .      | 419  |
| Structure . . . . .                    | 273  | Structure . . . . .                | 423  |
| The Larynx or Organ of Voice . . . . . | 280  | The Urethra . . . . .              | 427  |
| Cartilages of the Larynx . . . . .     | 280  | REPRODUCTIVE ORGANS IN THE         |      |
| Ligaments and Joints . . . . .         | 283  | MALE . . . . .                     | 427  |
| Interior of the Larynx . . . . .       | 285  | The Prostate Gland . . . . .       | 427  |
| Muscles of the Larynx . . . . .        | 288  | The Penis . . . . .                | 430  |
| Mucous Membrane and Glands . . . . .   | 293  | Corpora Caverosa . . . . .         | 431  |
| Vessels and Nerves . . . . .           | 294  | Corpus Spongiosum . . . . .        | 435  |
| Formation and Growth of the            |      | Urethra of the Male . . . . .      | 436  |
| Larynx . . . . .                       | 294  | Testicles and Accessory Struc-     |      |
| DUCTLESS GLANDS OF THE LA-             |      | tures . . . . .                    | 440  |
| RYNX AND TRACHEA . . . . .             | 295  | Coverings of the Testis and        |      |
| The Thyroid Body . . . . .             | 295  | Cord . . . . .                     | 440  |
| The Thymus Gland . . . . .             | 297  | The Testicles . . . . .            | 445  |
| ORGANS OF DIGESTION . . . . .          | 300  | Vas Deferens . . . . .             | 450  |
| The Mouth . . . . .                    | 300  | Seminal Vessels and Ejacula-       |      |
| The Teeth . . . . .                    | 301  | tory Ducts . . . . .               | 451  |
| General Characters . . . . .           | 301  | Vessels and Nerves of the          |      |
| Structure . . . . .                    | 306  | Testis . . . . .                   | 453  |
| Formation of the Teeth . . . . .       | 313  | REPRODUCTIVE ORGANS IN THE         |      |
| Secondary Dentine . . . . .            | 314  | FEMALE . . . . .                   |      |
| The Tongue . . . . .                   | 325  | The Vulva . . . . .                | 456  |
| Mucous Membrane . . . . .              | 325  | The Female Urethra . . . . .       | 459  |
| Muscular Substance . . . . .           | 331  | The Vagina . . . . .               | 460  |
| The Palate . . . . .                   | 333  | The Uterus . . . . .               | 462  |
| The Tonsils . . . . .                  | 335  | Fallopian Tubes . . . . .          | 470  |
| The Salivary Glands . . . . .          | 335  | The Ovaries . . . . .              | 471  |
| Parotid Gland . . . . .                | 335  | Structure . . . . .                | 472  |
| Submaxillary Gland . . . . .           | 337  | THE PERITONEUM . . . . .           | 481  |
| Sublingual gland . . . . .             | 338  | MAMMARY GLANDS . . . . .           | 486  |
| Structure of the Salivary              |      | Structure . . . . .                | 486  |
| Glands . . . . .                       | 339  | THE CEREBRO-SPINAL AXIS . . . . .  | 489  |
| The Pharynx . . . . .                  | 341  | SPINAL CORD . . . . .              | 489  |
| The Oesophagus . . . . .               | 343  | External Form . . . . .            | 489  |
| THE ABDOMINAL VISCERA . . . . .        | 346  | Internal Structure . . . . .       | 494  |
| The Abdomen . . . . .                  | 346  | Minute Structure . . . . .         | 497  |
| The Peritoneum . . . . .               | 348  | THE ENCEPHALON . . . . .           | 502  |
| The Stomach . . . . .                  | 349  | The Medulla Oblongata . . . . .    | 503  |
| Structure . . . . .                    | 350  | The Pons Varolii . . . . .         | 511  |
| THE SMALL INTESTINE . . . . .          | 356  | Internal Structure . . . . .       | 511  |
| Structure . . . . .                    | 358  | The Cerebellum . . . . .           | 515  |
| Special Characters and Connec-         |      | Internal Structure . . . . .       | 518  |
| tions of the Different Parts of        |      | Minute Structure . . . . .         | 520  |
| the Small Intestine . . . . .          | 369  | The Cerebrum . . . . .             | 522  |

|                                        | PAGE |                                   | PAGE |
|----------------------------------------|------|-----------------------------------|------|
| Exterior of the Cerebrum . . .         | 522  | The Cornea . . . . .              | 592  |
| Internal or Median and Ten-            |      | The Choroid Coat . . . . .        | 598  |
| torial Surface. . . . .                | 531  | The Iris . . . . .                | 601  |
| Base of the Cerebrum . . . . .         | 533  | Retina or Nervous Tunic . . . . . | 605  |
| Internal Parts of the Cerebrum         | 537  | The Vitreous Body . . . . .       | 619  |
| Internal Structure of the Cere-        |      | The Lens . . . . .                | 622  |
| brum . . . . .                         | 553  | Aqueous Humour and its            |      |
| White Matter . . . . .                 | 553  | Chamber . . . . .                 | 626  |
| Grey Matter . . . . .                  | 556  | THE EAR . . . . .                 | 626  |
| Meynert's Terminology . . . . .        | 564  | External Ear . . . . .            | 626  |
| Origin of the Cranial Nerves . . . . . | 565  | The Pinna . . . . .               | 626  |
| Membranes of the Brain and             |      | The External Auditory             |      |
| Spinal Cord . . . . .                  | 569  | Canal . . . . .                   | 630  |
| The Dura Mater . . . . .               | 569  | The Middle Ear or Tympanum        | 630  |
| The Pia Mater . . . . .                | 571  | Small Bones of the Ear . . . . .  | 635  |
| The Arachnoid Membrane . . . . .       | 572  | Ligaments and Muscles of          |      |
| Blood-Vessels of the Brain and         |      | the Tympanum . . . . .            | 637  |
| Spinal Cord . . . . .                  | 576  | The Lining Membrane . . . . .     | 639  |
| Blood-Supply of the Brain . . . . .    | 576  | Vessels and Nerves . . . . .      | 640  |
| Size and Weight of the Enceph-         |      | The Internal Ear or Labyrinth.    | 641  |
| alon . . . . .                         | 577  | The Osseous Labyrinth . . . . .   | 641  |
| Weight of the Spinal Cord . . . . .    | 582  | The Membranous Labyrinth          | 645  |
| Specific Gravity of the En-            |      | Vestibule . . . . .               | 645  |
| cephalon . . . . .                     | 582  | Semicircular Canals . . . . .     | 646  |
| ORGANS OF THE SENSES . . . . .         | 583  | Cochlea . . . . .                 | 651  |
| THE EYE . . . . .                      | 583  | Organ of Corti . . . . .          | 657  |
| The Eyelids and Conjunctiva . . . . .  | 583  | THE NOSE . . . . .                | 664  |
| The Lachrymal Apparatus. . . . .       | 587  | Cartilages of the Nose . . . . .  | 665  |
| The Globe of the Eye . . . . .         | 588  | Nasal Fossæ . . . . .             | 667  |
| The Sclerotic Coat. . . . .            | 589  | Mucous Membrane. . . . .          | 668  |

## EMBRYOLOGY; OR, DEVELOPMENT OF THE FÆTUS AND ITS ORGANS.

|                                            |     |                                    |     |
|--------------------------------------------|-----|------------------------------------|-----|
| THE OVUM: ITS MATURATION, FE-              |     | INTRA-EMBRYONIC PHENOMENA          |     |
| CUNDATION, AND SEGMENTA-                   |     | OF DEVELOPMENT . . . . .           | 691 |
| TION: FORMATION OF THE                     |     | Axial Rudiment of the Em-          |     |
| BLASTODERM. . . . .                        | 673 | bryo: Cerebro-Spinal Axis. . . . . | 691 |
| The Mature Ovarian Ovum . . . . .          | 673 | The Notochord . . . . .            | 692 |
| Distinction of the Germ . . . . .          | 673 | Protovertebræ . . . . .            | 693 |
| Disappearance of the Germinal              |     | Pleural Cleavage of the Lateral    |     |
| Vesicle . . . . .                          | 674 | Parts of the Mesoblast . . . . .   | 693 |
| Fecundation . . . . .                      | 675 | Inflection of the Walls of the     |     |
| Segmentation of the Yolk . . . . .         | 676 | Body of the Embryo . . . . .       | 694 |
| Segmentation of the Mammal's Ovum. . . . . | 678 | The Cerebro-Spinal Nervous         |     |
| In the Bird's Ovum . . . . .               | 679 | Centre . . . . .                   | 695 |
| THE BLASTODERM: ITS STRUC-                 |     | The Nerves . . . . .               | 695 |
| TURE AND RELATION TO THE                   |     | Organs of the Senses . . . . .     | 695 |
| DEVELOPMENT OF THE EM-                     |     | Vascular System . . . . .          | 696 |
| BRYO . . . . .                             | 681 | Alimentary Canal . . . . .         | 698 |
| Position and Extent . . . . .              | 681 | Reproductive and Urinary           |     |
| Trilaminar Structure . . . . .             | 683 | Organs . . . . .                   | 699 |
| Relation of the Layers to De-              |     | The Limbs . . . . .                | 699 |
| velopment . . . . .                        | 683 | EXTRA-EMBRYONIC PHENOMENA          |     |
| Discovery of the Blastodermic              |     | OF DEVELOPMENT. . . . .            | 700 |
| Elements . . . . .                         | 685 | Fœtal Membranes . . . . .          | 700 |
| SHORT OUTLINE OF THE MORE                  |     | The Yolk-Sac . . . . .             | 700 |
| GENERAL PHENOMENA OF                       |     | The Amnion . . . . .               | 703 |
| DEVELOPMENT OF THE OVUM                    | 689 | The Allantois: Urinary Vesicle     | 704 |
| Distinction of Embryonic and               |     | The Chorion . . . . .              | 706 |
| Peripheral Phenomena . . . . .             | 689 | Villi of the Chorion . . . . .     | 709 |

|                                                                                     | PAGE |                                                                                                            | PAGE |
|-------------------------------------------------------------------------------------|------|------------------------------------------------------------------------------------------------------------|------|
| Endochorion or Vascular Layer of the Allantois . . . . .                            | 709  | DEVELOPMENT OF THE LUNGS AND TRACHEA . . . . .                                                             | 782  |
| UTEROGESTATION: PLACENTATION                                                        | 710  | Pleura . . . . .                                                                                           | 783  |
| Incapsulation of the Ovum in the Decidua . . . . .                                  | 710  | Pulmonary Vessels . . . . .                                                                                | 783  |
| Earliest Observed Human Ova                                                         | 710  | DEVELOPMENT OF THE HEART AND BLOOD-VESSELS . . . . .                                                       | 784  |
| Formation of Decidua . . . . .                                                      | 711  | Development of the Heart . . . . .                                                                         | 784  |
| Structure of the Placenta . . . . .                                                 | 718  | Origin of the Heart . . . . .                                                                              | 784  |
| Circulation of Blood in the Placenta . . . . .                                      | 719  | Division into single Auricle, Ventricle, and Arterial Bulb . . . . .                                       | 787  |
| Further Consideration of the Structure of the Placenta . . . . .                    | 721  | Division of the Cavities : Ventricles . . . . .                                                            | 787  |
| General Conclusion . . . . .                                                        | 723  | Division of the Auricles . . . . .                                                                         | 788  |
| Separation at Birth and Restoration of the Mucous Membrane of the Uterus . . . . .  | 724  | Division of the Arterial Bulb                                                                              | 789  |
| DEVELOPMENT OF PARTICULAR ORGANS AND SYSTEMS . . . . .                              | 725  | Formation of the Valves . . . . .                                                                          | 791  |
| THE SKELETON AND ORGANS OF VOLUNTARY MOTION . . . . .                               | 725  | Development of the Blood-Vessels . . . . .                                                                 | 791  |
| Vertebral Column and Trunk                                                          | 725  | The Principal Arteries : the Aorta . . . . .                                                               | 791  |
| Segmentation of the Proto-vertebrae . . . . .                                       | 728  | Aortic or Branchial Arches. Development of the Great Veins . . . . .                                       | 796  |
| Formation of Vertebral Matrices . . . . .                                           | 730  | Peculiarities of the Fœtal Organs of Circulation . . . . .                                                 | 799  |
| The Head . . . . .                                                                  | 731  | Course of the Blood in the Fœtus . . . . .                                                                 | 802  |
| The Cranium . . . . .                                                               | 732  | Changes in the Circulation at Birth . . . . .                                                              | 803  |
| The Cranial Flexures . . . . .                                                      | 733  | DEVELOPMENT OF THE GENITAL AND URINARY ORGANS . . . . .                                                    | 804  |
| Formation of the Mouth and Hypophysis Cerebri . . . . .                             | 734  | Primary Formation of the Urogenital System . . . . .                                                       | 804  |
| Subcranial, Facial, or Pharyngeal Plates or Arches . . . . .                        | 738  | Wolfian Bodies . . . . .                                                                                   | 804  |
| Relations of Cranial Nerves. Origin and Formation of the Limbs . . . . .            | 742  | First Origin of the Wolfian Bodies . . . . .                                                               | 806  |
| Development of the Muscles . . . . .                                                | 744  | Homologies of the Wolfian Body . . . . .                                                                   | 809  |
| Formation of the Joints . . . . .                                                   | 745  | The External Organs . . . . .                                                                              | 811  |
| DEVELOPMENT OF THE ORGANS OF THE NERVOUS SYSTEM . . . . .                           | 746  | Further History of the Development of the Uro-Genital Organs . . . . .                                     | 812  |
| The Spinal Marrow . . . . .                                                         | 746  | The Urinary Bladder and Urachus . . . . .                                                                  | 813  |
| The Brain or Encephalon . . . . .                                                   | 750  | Genital Cord . . . . .                                                                                     | 814  |
| General Phenomena of Development in Birds and Mammals . . . . .                     | 750  | Reproductive Organs . . . . .                                                                              | 814  |
| Farther Development of the Brain in Man and Mammals . . . . .                       | 755  | Reproductive Glands . . . . .                                                                              | 814  |
| Development of the Nerves . . . . .                                                 | 760  | The Testicle . . . . .                                                                                     | 815  |
| Development of the Eye . . . . .                                                    | 762  | The Ovary . . . . .                                                                                        | 816  |
| Development of the Nose . . . . .                                                   | 772  | The Genital Passages . . . . .                                                                             | 818  |
| DEVELOPMENT OF THE ALIMENTARY CANAL AND ORGANS ARISING FROM THE HYPOBLAST . . . . . | 774  | The Female Passages . . . . .                                                                              | 819  |
| Alimentary Canal . . . . .                                                          | 774  | The Male Passages . . . . .                                                                                | 821  |
| The Liver . . . . .                                                                 | 779  | The Descent of the Testicles . . . . .                                                                     | 823  |
| The Pancreas . . . . .                                                              | 781  | Type of Development and Abnormal Forms of the Genital Organs . . . . .                                     | 825  |
| The Spleen, Lymphatic Glands, Thymus and Thyroid Glands . . . . .                   | 782  | Table of Corresponding Parts of Genito-Urinary Organs, and their Relation to Formative Rudiments . . . . . | 826  |
| INDEX TO VOLUME II. . . . .                                                         |      |                                                                                                            | 827  |



# GENERAL ANATOMY.

## GENERAL CONSIDERATIONS ON THE TEXTURES.

**Enumeration of the Textures.**—The human body consists of solids and fluids. Only the solid parts can be reckoned as textures, properly so called; still, as some of the fluids, viz. the blood, chyle, and lymph, contain in suspension solid organised corpuscles of determinate form and organic properties, and are not mere products or secretions of a particular organ, or confined to a particular part, the corpuscles of these fluids, though not coherent textures, are to be looked upon as organised constituents of the body, and as such may not improperly be considered along with the solid tissues. In conformity with this view the textures and other organised constituents of the frame may be enumerated as follows :—

The blood, chyle, and lymph.

Epithelial tissue, including epithelium, cuticle, nails, and hairs.

Pigment.

Connective tissue, viz.

Areolar tissue.

Adipose tissue.

Fibrous tissue.

Elastic tissue.

Cartilage and its varieties.

Bone or osseous tissue.

Muscle.

Nerve.

Blood-vessels.

Lymphatic vessels and glands.

Serous and synovial membranes.

Mucous membrane.

Skin.

Secreting glands.

Vascular or ductless glands.

**Organic Systems.**—Every texture taken as a whole was viewed by Bichat as constituting a peculiar system, presenting throughout its whole extent in the body characters either the same, or modified only so far as its local connections and uses render necessary; he accordingly used the term “organic systems” to designate the textures taken in this point of view, and the term was very generally employed by succeeding writers. Of the tissues or organic systems enumerated

some are found in nearly every organ ; such is the case with the connective tissue, which serves as a binding material to hold together the other tissues which go to form an organ ; the vessels, which convey fluids for the nutrition of the other textures, and the nerves, which establish a mutual dependence among different organs, imparting to them sensibility, and governing their movements. These were named by Bichat the "general systems." Others again, as the cartilaginous and osseous, being confined to a limited number or to a particular class of organs, he named "particular systems." Lastly, there are some tissues of such limited occurrence that it has appeared more convenient to leave them out of the general enumeration altogether, and to defer the consideration of them until the particular organs in which they are found come to be treated of. Accordingly, the tissues peculiar to the crystalline lens, the teeth, and some other parts, though equally independent textures with those above enumerated, are for the reason assigned not to be described in this part of the work.

**Structural Elements.**—It is further to be observed, that the anatomical constituents of the body above enumerated are by no means to be regarded as simple structural elements ; on the contrary, many of them are complex in constitution, being made up of several more simple tissues. The blood-vessels, for instance, are composed of several coats of different structure, and some of these coats consist of more than one tissue. They are properly rather organs than textures, although they are here included with the latter in order that their general structure and properties may be considered apart from their local distribution ; but indeed it may be remarked, that the distinction between textures and organs has not in general been strictly attended to by anatomists. The same remark applies to mucous membrane and the tissue of the glands, which structures, as commonly understood, are highly complex. Were we to separate every tissue into the simplest parts which possess assignable form, we should resolve the whole into a very few constructive elements.

#### PHYSICAL PROPERTIES.

The animal tissues, like other forms of matter, are endowed with various physical properties, such as consistency, density, colour, and the like. Of these the most interesting to the physiologist is the property of imbibing fluids, and of permitting fluids to pass through their substance, which is essentially connected with some of the most important phenomena that occur in the living body, and seems indeed to be indispensable for the maintenance and manifestation of life.

All the soft tissues contain water, some of them more than four-fifths of their weight : this they lose by drying, and with it their softness and flexibility, and so shrink up into smaller bulk and become hard, brittle, and transparent ; but when the dried tissue is placed in contact with water, it greedily imbibes the fluid again, and recovers its former size, weight, and mechanical properties. The imbibed water is no doubt partly contained mechanically in the interstices of the tissue, and retained there by capillary attraction, like water in moist sandstone or other inorganic porous substances ; but the essential part of the process of imbibition by an animal tissue is not to be ascribed to mere porosity, for the fluid is not merely lodged between the fibres or laminae, or in the cavities of the texture ; a part, probably the chief part, is incorporated with the matter which

forms the tissue, and is in a state of union with it, more intimate than could well be ascribed to the mere inclusion of a fluid in the pores of another substance. Be this as it may, it is clear that the tissues, even in their inmost substance, are permeable to fluids, and this property is indeed necessary, not only to maintain their due softness, pliancy, elasticity, and other mechanical qualities, but also to allow matters to be conveyed into and out of their substance in the process of nutrition.

#### CHEMICAL COMPOSITION.

**Ultimate Constituents.**—The human body is capable of being resolved by ultimate analysis into chemical elements, or simple constituents, not differing in nature from those which compose mineral substances. Of the chemical elements known to exist in nature, the following have been discovered in the human body, though it must be remarked, that some of them occur only in exceedingly minute quantity, if indeed they be constant: oxygen, hydrogen, carbon, nitrogen, phosphorus, sulphur, chlorine, fluorine, potassium, sodium, calcium, magnesium, iron, silicon, manganese, aluminium, copper.

**Proximate Constituents.**—The ultimate elements do not directly form the textures or fluids of the body; they first combine to form certain compounds, and these appear as the more immediate constituents of the animal substance; at least the animal tissue or fluid yields these compounds, and they in their turn are decomposed into the ultimate elements. Of the immediate constituents some are found also in the mineral kingdom, as for example, water, chloride of sodium or common salt, and carbonate of lime; others, such as albumin, fibrin, and fat, are peculiar to organic bodies, and are accordingly named the proximate organic principles.

The animal proximate principles have the following leading characters. They all contain carbon, oxygen, and hydrogen, and the greater number also nitrogen; they are all decomposed by a red heat; and, excepting the fatty and acid principles, they are, for the most part, extremely prone to putrefaction, or spontaneous decomposition, at least, when in a moist state; the chief products to which their putrefaction gives rise being water, carbonic acid, ammonia, and sulphuretted, phosphuretted, and carburetted hydrogen gases. The immediate compounds obtained from the solids and fluids of the human body are the following.

I. *Azotised Substances*, or such as contain nitrogen, viz., albumin, blood-fibrin, myosin, syntonin, casein, globulin, gelatin, chondrin, salivin, kreatin, kreatinin, pepsin, mucin, horny matter or keratin, pigment, hæmoglobin, urea, uric acid, hippuric acid, inosinic acid, sarkin (or hypoxanthin), leucin, tyrosin, protagon and its components lecithin and neurin, azotised biliary compounds.

II. *Substances destitute of Nitrogen*, viz., fatty matters, glycogen (or animal starch), grape sugar, sugar of milk, inosit, lactic, formic, and oxalic acids, certain principles of the bile.

Some of the substances now enumerated require no further notice in a work devoted to anatomy. Of the rest, the greater number will be explained, as far as may be necessary for our purpose, in treating of the particular solids or fluids in which they are chiefly found.

It has been shown by Graham,\* that chemical substances may be distinguished

\* Liquid Diffusion applied to Analysis,—Phil. Trans., 1861.

into two classes—the *crystalloid* and the *colloid*—which differ in several important characters. Crystalloid bodies, of which water, most salts and acids, and sugar, may be taken as examples, have a disposition to assume a crystalline state; their solutions are usually sapid, diffuent, and free from viscosity; they readily diffuse in liquids, and pass through moist organic membranes or artificial septa of organic matter, such as parchment-paper. Colloids, on the other hand, are characterised by low diffusibility and great indisposition to permeate organic septa, so that when they are associated with crystalloids, the latter may be easily separated by diffusion through a septum into another fluid; *i.e.*, by “dialysis.” Colloids are, moreover, generally tasteless; they have little or no tendency to crystallize, and their solution, when concentrated, is always, in a certain degree, viscous or gummy. Among the colloids may be reckoned hydrated silicic acid, and various hydrated metallic peroxides, also albumin, gelatin, starch, gum, and vegetable and animal extractive matters. Several substances may exist either in the colloid or the crystalloid condition. In point of *chemical* activity the crystalloid appears to be the more energetic, and the colloidal the more inert form of matter; but the colloids possess an activity of their own, arising out of their physical properties, and especially their penetrability, by which they become a medium for liquid diffusion, like water itself. Another characteristic is their tendency to change; the solution of hydrated silicic acid, for instance, cannot be preserved; after a time it congeals. In this respect a liquid colloid might be compared to liquid water at a temperature below freezing, or to a supersaturated saline solution. This dominant tendency of the particles of a colloid to cohere, aggregate, and contract, is obvious in the gradual thickening of the liquid and its conversion into a jelly; and in the jelly itself the contraction still proceeds, causing separation of water, and division into a clot and serum. Their permeability to fluids, their ready capability of physical changes, and their comparative chemical inertness, are properties by which colloid bodies seem fitted to form organised structures, and to take part in the processes of the living economy. Graham further found that silicic acid may combine both in a dissolved and in a gelatinous state with a variety of very different fluids without undergoing alteration; and presuming that the organic colloids are invested with similar wide powers of combination, he remarks that the capacity of a mass of gelatinous silicic acid to assume alcohol, or even olein, without disintegration or alteration of form, and to yield it up again in favour of some other substituted fluid, may perhaps afford a clue to the penetration of the colloid matter of animal membrane by fatty and other bodies insoluble in water; and moreover, that the existence of *fluid* compounds of silicic acid of a like nature, suggests the possibility of the formation of a compound of colloid albumen with olein, soluble also and capable of circulating with the blood.\*

The important relation which this chemical doctrine bears to the constitution and organic processes of the animal body, has appeared to justify the introduction of the present notice of it; for further information the reader is referred to the sources already cited.

#### VITAL PROPERTIES OF THE TEXTURES.

Of the phenomena exhibited by living bodies, there are some which, in the present state of knowledge, cannot be referred to the operation of any of the forces which manifest themselves in inorganic nature; they are therefore ascribed to certain powers, endowments, or properties, which so far as known, are peculiar to living bodies, and are accordingly named “vital properties.” These vital properties are called into play by various stimuli, external and internal, physical, chemical, and mental; and the assemblage of actions thence resulting has been designated by the term “life.” The words “life” and “vitality” are

\* On the Properties of Silicic Acid and other Analogous Colloidal Substances,—Proceedings of the Royal Society, June 16th, 1864.

often also employed to signify a single principle, force, or agent, which has been regarded as the common source of all vital properties, and the common cause of all vital actions.

As ordinary physical forces, such as mechanical motion, heat, electricity, chemical action, and the like, although differing from each other in specific character and mode of operation, are nevertheless shown to be mutually convertible and equivalent, and are held to be but different modifications of one and the same common force or "energy," so it may in like manner come to be shown that vital action is similarly related to the physical forces as they are related to each other, and is also a manifestation, under conditions special to the living economy, of the same common energy.

**1. Assimilatory Property.**—Of the vital properties, there is one which is universal in its existence among organised beings, namely, the property, with which all such beings are endowed, of converting into their own substance, or "assimilating," alimentary matter. The operation of this power is seen in the continual renovation of the materials of the body by nutrition, and in the increase and extension of the organised substance, which necessarily takes place in growth and reproduction; it manifests itself, moreover, in individual textures as well as in the entire organism. It has been called the "assimilative force or property," "organising force," "plastic force," and is known also by various other names. But in reality the process of assimilation produces two different effects on the matter assimilated: first, the nutrient material, previously in a liquid or amorphous condition, acquires determinate form; and secondly, it may, and commonly does, undergo more or less change in its chemical qualities. Such being the case, it seems reasonable, in the mean time, to refer these two changes to the operation of two distinct agencies, and, with Schwann, to reserve the name of "plastic" force for that which gives to matter a definite organic form; the other, which he proposes to call "metabolic," being already generally named "vital affinity." Respecting the last-named agency, however, it has been long since remarked, that although the products of chemical changes in living bodies for the most part differ from those appearing in the inorganic world, the difference is nevertheless to be ascribed, not to a peculiar or exclusively vital affinity different from ordinary chemical affinity, but to common chemical affinity operating in circumstances or conditions which present themselves in living bodies only.

**2. Vital Contractility.**—When a muscle, or a tissue containing muscular fibres, is exposed in an animal during life, or soon after death, and scratched with the point of a knife, it contracts or shortens itself; and the property of thus visibly contracting on the application of a stimulus is named "vital contractility," or "irritability," in the restricted sense of this latter term. The property in question may be called into play by various other stimuli besides that of mechanical irritation—especially by electricity, the sudden application of heat or cold, salt, and various other chemical agents of an acrid character, and, in a large class of muscles, by the exercise of the will, or by involuntary mental stimuli.

The evidence that a tissue possesses vital contractility is derived, of course, from the fact of its contracting on the application of a stimulus.

Mechanical irritation, as scratching with a sharp point, or slightly pinching with the forceps, electricity obtained from a piece of copper and a piece of zinc, or from a larger apparatus if necessary, and the sudden application of cold, are the stimuli most commonly applied.

**3. *Vis Nervosa*.**—The stimulus which excites contraction may be applied either directly to the muscle, or to the nerves entering it, which then communicate the effect to the muscular fibre, and it is in the latter mode that the voluntary or other mental stimuli are transmitted to muscles from the brain. Moreover, a muscle may be excited to contract by irritation of a nerve not directly connected with it. The stimulus, in this case, is first conducted by the nerve irritated, to the brain or spinal cord; it is then, without participation of the will, and even without consciousness, transferred to another nerve, by which it is conveyed to the muscle, and thus at length excites muscular contraction. The property of nerves by which they convey stimuli to muscles, whether directly, as in the case of muscular nerves, or circuitously, as in the case last instanced, is named the “*vis nervosa*.”

**4. *Sensibility*.**—We become conscious of impressions made on various parts of the body, both external and internal, by the faculty of sensation; and the parts or textures, impressions on which are felt, are said to be sensible, or to possess the vital property of “*sensibility*.”

This property manifests itself in very different degrees in different parts; from the hairs and nails, which indeed are absolutely insensible, to the skin of the points of the fingers, the exquisite sensibility of which is well known. But sensibility is a property which really depends on the brain and nerves, and the different tissues owe what sensibility they possess to the sentient nerves which are distributed to them. Hence it is lost in parts severed from the body, and it may be immediately extinguished in a part, by dividing or tying the nerves so as to cut off its connection with the brain.

It thus appears that the nerves serve to conduct impressions to the brain, which give rise to sensation, and also to convey stimuli to the muscles, which excite motion; and it is probable that, in both these cases, the conductive property exercised by the nervous cords may be the same; the difference of effect depending on this, that in the one case the impression is carried upwards to the sensorial part of the brain, and in the other downwards to an irritable tissue, which it causes to contract; the stimulus in the latter case either having originated in the brain, as in the instance of voluntary motion, or having been first conducted upwards, by an afferent nerve, to the part of the cerebro-spinal centre devoted to excitation, and then transferred to an efferent or muscular nerve, along which it travels to the muscle. If this view be correct, the power by which the nerves conduct sensorial impressions and the before-mentioned “*vis nervosa*” are one and the same vital property; the difference of the effects resulting from its exercise, and, consequently, the difference in function of sensorial and motorial nerves, being due partly to the different nature of the stimuli applied, but especially to a difference in the susceptibility and mode of reaction of the organs to which the stimuli are conveyed.

## DEVELOPMENT OF THE TEXTURES.

The tissues of organised bodies, however diversified they may ultimately become, show a wonderful uniformity in their primordial condition. The results of modern researches have shown that the



different organised structures found in plants and animals originate directly or indirectly by means of elementary corpuscles, which have been named "cells." These so-called cells, remaining as separate corpuscles in the fluids, and grouped together in the solids, persisting in some cases with but little change, in others undergoing a partial or thorough transformation, produce the varieties of form and structure met with in the animal and vegetable textures. Nay, the germ from which an animal originally springs, so far at least as it has been recognised under a distinct form, appears as a cell; and the embryo, in its earliest stages, is but a cluster of cells produced apparently from that primordial one; no distinction of texture being seen till the process of transformation of the cells has begun.

No branch of knowledge can be said to be complete; but, even now that between a quarter and half a century has elapsed since the promulgation of the cell-doctrine, there is, perhaps, none which can be more justly regarded as in a state of progress than that which relates to the origin and development of the textures, and much of the current opinion on the subject is uncertain, and must be received with caution.

## THE VEGETABLE CELL.

If we view under the microscope the early embryo of one of the higher plants (fig. 1.), we see that it is built up entirely of a number of closely adherent vesicles,—these are the elementary cells. Each of those cells consists of an external membranous investment (*a*), the cell-wall, containing in its interior a finely granular transparent substance of semi-fluid consistence—the *protoplasm* (*b*),—in this is imbedded at one part a more solid looking body of rounded form (the *nucleus*, *c*), which again itself contains generally one or two distinct strongly refracting particles (*nucleoli*). On closer examination it may be observed that in many cells the protoplasm is not absolutely quiescent as at first sight appears, but on the contrary exhibits slow streaming movements of its substance, indicating a certain amount of vital activity. This is more particularly the case in the more rapidly growing parts, where also it is not uncommon to find two nuclei in a cell. This, as will be seen later on, is an indication of the commencing division of the cell into two: by the constant repetition of this process the growth of the plant is effected. In their early condition all plants are similarly composed of an agglomeration of cells, and some retain this primitive condition throughout life; in all the higher classes, however, by changes in the form and in the contents of the cells, various modifications occur, by means of which the different textures of the plant are produced. Some of these are shown in the accompanying figures

Fig. 1.

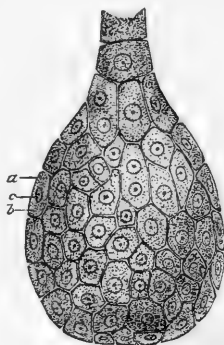


Fig. 1.—EMBRYO OF A DICOTYLEDONOUS PLANT. MODERATELY MAGNIFIED.

*a*, cell-envelope; *b*, protoplasm; *c*, nucleus.

(figs. 2. and 3): it would however lead us too far to enter into a description of them here.

Fig. 2.

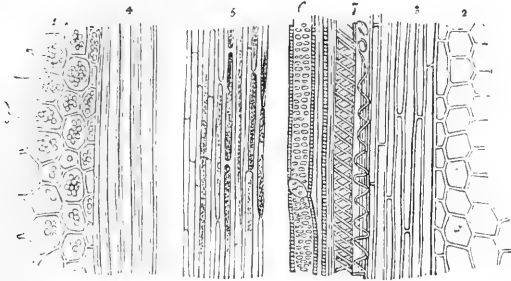


Fig. 3.

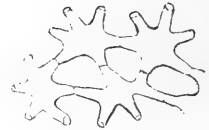

Fig. 2.—TEXTURES SEEN IN A LONGITUDINAL SECTION OF THE LEAF-STALK OF A FLOWERING PLANT.

1, 2, Polyhedral cells (from mutual pressure). 3, 4, 5, Elongated tubular and prismatic cells. 6, Pitted tissue. 7, Spiral vessels.

Fig. 3.—STELLATE VEGETABLE CELLS.

#### THE ANIMAL CELL.

Turning now our attention to the animal embryo, we find that it also is entirely made up of cells (fig. 4), rather smaller it is true than those composing the embryo plant, but, like them, consisting of a granular protoplasmic substance (*b*) enclosing a nucleus (*c*); this in its turn containing one or more nucleoli.

Fig. 4.

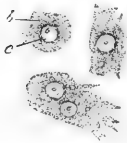

Fig. 4.—THREE CELLS FROM EARLY EMBRYO OF THE CAT. HIGHLY MAGNIFIED.

*b*, protoplasm; *c*, nucleus with nucleolus. The lowermost cell has two nuclei.

And here, at the outset, we encounter a fundamental difference between the cells composing the animal and those composing the vegetable embryo. In the former there is no membranous investment or cell-wall. In consequence of this absence of a restraining envelope the streaming movements of the protoplasm, which are observable in every cell, whether animal or vegetable, at an early stage of its existence, and in some remain persistent throughout life, are capable, as will hereafter be more fully explained, of effecting changes both in the

form and also in the position of the animal cell.\*

Before proceeding to inquire into the changes which may occur in

\* The existence of animal cells destitute of envelope, although more insisted on of late years, has been all along recognised in the study of cell-development, and was expressly pointed out by Schwann himself (*Microscopische Untersuchungen, &c.*, p. 209). It has appeared to some that another name should be used to designate bodies which thus exist in a naked non-vesicular form. Brücke proposed to call them "elementary organisms," a term too cumbersome for use. As the first "shaped" products of organisation which appear in the development of all but the lowest organised beings, they might be named "protoplasts," or, as that name has been already used in a widely different sense—"monoplasts," but after all, seeing the universal currency of the term "cell," it is probably most convenient and best to adhere to it, with the understanding that in many cases it is used in a conventional sense.

the embryo cells in order to the production of the various textures of which the animal body is composed, it will be convenient to consider the manner in which the cells themselves are produced, and the nature of the substance composing them.

**Production of Embryo Cells.**—So far as is at present known, every cell in the animal body has been derived from a previously existing cell. In the case of the cells which compose the early embryo this parent cell is, as has been previously pointed out, the ovum itself, or at least its germinative part.

The mammalian ovum differs indeed from the cells we have just been considering, both in its size, and in possessing a stout external membrane (fig. 5 *a*). Like them, however, it mainly consists of a protoplasmic substance (*b*), in which are embedded fatty granules (the *yelk*), and contains structures (the *germinal vesicle* (*c*) and *germinal spot*), which are comparable respectively to the nucleus and nucleolus.

Fig. 5.

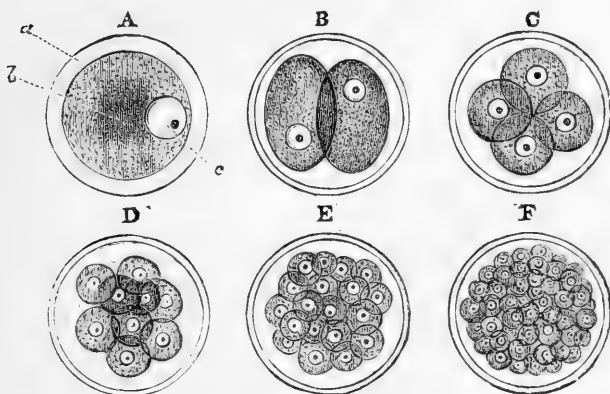


Fig. 5.—DIAGRAMMATIC FIGURES TO ILLUSTRATE THE FORMATION OF CELLS WITHIN THE MAMMALIAN OVUM BY SEGMENTATION OF THE YELK ; MAGNIFIED.

*a*, external membrane ; *b*, protoplasmic contents ; *c*, germinal vesicle containing the germinal spot.

The embryonic cells are produced from the ovum by a process of cleavage or segmentation, of which the following is an outline :—

The germinal vesicle disappears ; the contents of the ovum then shrink somewhat and separate into two equal parts (*B*) ; the first two segments divide each again into two (*C*), and the binary division thus goes on (*D*, *E*,) pretty regularly until the whole is transformed into a number of small segments, the embryonic cells, each consisting, as we have seen, of protoplasmic matter enclosing a nucleus. The latter is not always discoverable in the earlier segments, being perhaps hidden by the opaque granular mass, but it soon comes into view, and has been supposed to play an important part in the formation of the cells. At all events it may be observed, in those segments in which the nucleus is visible, that the division of this body precedes that of the protoplasmic substance. Whether the first nucleus is itself derived from the vanishing germinal vesicle and spot is unknown.

The formation of cells by segmentation may be traced with comparative ease in the ova of many invertebrata. The accompanying figure (fig. 6) represents the several stages of the process in small species of the ascaris worm. A, B, and C are from the *Ascaris nigrovenosa*, as observed by Kölliker. He found that, after the germinal vesicle had disappeared, a new nucleus with nucleolus was formed in its place: the segmentation then goes on as in the mammalian ovum, but the nuclei are visible from the first.

In many animals the segmentation process affects only a part of the contents of the ovum.

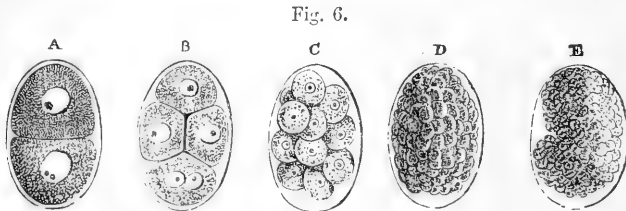


Fig. 6.—DIVISION OF THE YOLK OF ASCARIS.

A, B, C (from Kölliker), ovum of *Ascaris nigrovenosa*; D and E, that of *Ascaris acuminata* (from Bagge).

**The Protoplasm of the Cell.**—The substance of which the embryonic cells, and all others which display similar vital contractility, chiefly consist, is in reality clear and hyaline, but commonly contains minute particles imbedded in the clear substance, which give it a granular appearance (fig. 4, *b*). It is semi-fluid and viscid in consistence, and in chemical constitution closely agrees with the albuminoid bodies, consisting, in fact, principally of a substance allied to myosin, the chief constituent of muscular tissue; but in many animal cells it doubtless also includes other organic principles, especially fat, and glycogenous or amyloid matter. Protoplasm is characterised by properties which have been aptly termed “vital,” since upon their presence the life of the organism seems to depend. Chief among these properties are those of assimilation and of irritability: indeed, it is probable that the vital properties of the textures above enumerated depend, in great measure or wholly, upon the protoplasm which they contain.

**The Nucleus of the Cell.**—The nucleus (fig. 4, *c*) is a round or ovoid, clear, and apparently vesicular body, commonly situate near the centre of the cell, and containing one or two strongly refracting granules—the *nucleoli*—which are probably of a fatty nature.

From the affinity which, in common with protoplasm, it possesses for certain colouring matters, the nucleus has been supposed by some eminent histologists (and notably by Beale, who has applied the term “germinal matter” to both) to be identical in nature with that substance. Its behaviour, however, with many reagents is altogether different; and in general it may be said that it offers greater resistance to their action than the substance which surrounds it. The fact that in the division of cells the segmentation of the nucleus appears to precede that of the protoplasm, has been held to be a strong argument in favour of the possession by the nucleus of a considerable amount of vital activity, but it is impossible to say whether this process may not be effected by means of the surrounding protoplasm. At all events there are, it is believed, no recent observations which would tend to show the manifestation by the nucleus of any vital phenomena, unless when associated with protoplasm, whereas the converse fact is well established.

**Changes which occur in Cells.**—The changes which may occur in cells in relation to the production of the textures are of two principal kinds, according as the form of the cell, or the nature of the substance composing it, undergoes alteration. These changes may occur at one and the same time—indeed, this is commonly found to be the case; it will, however, be more convenient here to consider them separately.

1. *Chemical and Plastic Changes occurring in Cells.*—The protoplasm originally composing the embryonic cell may become variously altered in chemical constitution, all such changes tending to diminish the original activity of the cell and to fit it for a special function. An alteration commonly met with in older cells is the conversion of the outer portion of the protoplasm into a comparatively dense layer, which constitutes an investment for the remainder, and in this way approximates the cell more to the vegetable type. Such a transformation is met with in a high degree in the stratified epithelia, in which the cells of the uppermost layers become almost entirely transformed into dense horny scales.

Another change which is apt to occur is the deposition within the cell of various chemical principles, which are either derived directly from the plasma of the blood, in which in such cases they pre-exist, or are elaborated by the cell itself from some other constituent of that fluid. Examples of these changes are to be found in the deposit of fat and pigment, and of the peculiar constituents of certain secretions within the cells of the tissue or gland producing them.

The deposition of fat occurs ordinarily and in its most characteristic form in the corpuscles of the connective tissue, transforming them into fat cells, although it may occasionally be found in other cells, such as those of the liver and of cartilage. Pigment on the other hand may be deposited both in connective tissue cells and in epithelium, and this to such an extent as to give an intensely black appearance to the part, as in the choroid coat of the eye and in the cuticle of the negro.

Sometimes these chemical changes are accompanied by others of a *plastic* or *organizing* character, as in the fibrillation which is often found to occur in cells, and notably in those of the nervous and muscular tissues, as well as in the formation of the spontaneously moving bodies called spermatozoa in the spermatic cells. Another example of such a change is to be found in the formation of red blood corpuscles within the cells of connective tissue.

These plastic changes are equally unexplained with the other alterations of form and structure which accompany the production and metamorphoses of cells. As regards the changes in the quantity and chemical nature of the contained matter, it may be remarked that the introduction of new matter into a cell is to a great extent a phenomenon of imbibition. In addition to this, many cells, by virtue of their amœboid movements to be presently described, are enabled to take into their substance minute solid particles, both inorganic and organic. But, while an alteration in the contents of a cell may be thus brought about by imbibition and intersusception of pre-existing material, the contained substance may also be changed in its qualities by a process of conversion or elaboration taking place within the cell.

2. *Changes in Form*—The changes of form which may occur in cells are of two kinds, the one being merely passive and mechanical, the other dependent upon the growth of the cell. Instances of the former are seen in those cases where, by mutual compression, the cells

have acquired a more or less dodecahedral form (as is frequently the case in plants, see fig. 2), or where, by growth of young cells beneath them, they become flattened out and forced towards a free surface, as probably happens in the case of the stratified epithelia. Examples of the latter are observable in the ramification of the cells of the nervous and connective tissues, and in the elongation of cells to form muscular fibres.

3. *Movements of Cells.*—Many cells undergo spontaneous movements, leading to temporary changes in their form. If we watch carefully under a high power of the microscope any cell which is exhibiting these phenomena—a pale blood-corpusele, for example—we observe, in the first place, at one point of its circumference, a protrusion of a portion of its protoplasm, which is commonly at first clear and hyaline, but into which granules are soon seen to flow. After a short time this process may be retracted, and another similarly protruded at another point, and again withdrawn, and so on for a considerable time, the corpusele remaining all the while perfectly stationary. Occasionally, however, especially if the corpusele be maintained at the temperature of the body, the part protruded remains fixed, and the cell itself is drawn towards the extremity of the process. Should this occur a number of times in the same direction, a slow progressive motion of the whole cell is the result. In this way cells such as we are now considering may undergo very considerable changes of form and place within a relatively short time. Thus, under certain conditions, the pale blood-corpuseles may some of them make their way out of the blood-vessels and move freely in the surrounding tissues: hence the term “migratory cells” (*Wanderzellen*) applied to them.

The movements which we have just been describing as occurring in cells are quite similar to those which are exhibited, but in a more vigorous manner, by the common fresh-water amœba, and are hence designated “amœboid.” They are more marked in cells in the young state, such as those of the embryo, but are not altogether absent in some which persist in the fully-developed tissues, as, for example, in the connective tissue corpuseles. The contractile property of the protoplasm, to which its movements are due, would seem to be quite comparable to the contractility of muscular substance; for it is found that the substance of these protoplasmic cells contracts under the electric stimulus, whether this be directly applied, or, as observed by Kühne in the cornea, indirectly through the medium of the nerves.\*

In the cells of the *Vallisneria*, *Chara*, and various other plants, when exposed under the microscope, the green coloured grains (of chlorophyll) and other small masses and corpuseles contained in the cavity, are seen to be moved along the inside of the cell-wall in a constant and determinate direction. This phenomenon appears to be of very general occurrence in the vegetable kingdom, although the movement does not always go on with the same regularity as in the instances cited. It is obviously due to a layer of protoplasm on the inner surface of the cell-wall, which enters into a peculiar flowing or undulating motion and trails the passive chlorophyll granules along with it; but how the motion of the protoplasm itself is produced is not at all understood.

To the same class of phenomena are probably to be referred the remarkable movements observed in the pigment-cells of the frog’s skin, which were carefully investigated by Lister.† In these ramified cells the dark particles of pigment are

\* Untersuchungen über das Protoplasma und die Contractilität. 1864.

† Phil. Trans., 1858.



at one time dispersed through the whole cell and its branches, but at another time they gather into a heap in the central part, leaving the rest of the branched cell vacant, but without alteration of its figure. In the former case the skin is of a dusky hue; in the latter, pale. Like the movements of the protoplasm, the aggregation of the pigment molecules can be excited through the nerves, both mechanically and electrically.

The fact above mentioned, that these movements of cells may be excited by stimulation of the nerves, is especially worthy of note, in as much as it proves that operations effected in and by cells are more or less under the governance of the nervous system. Moreover, the well known influence of mental states over the secretions, and the effects resulting from experimental stimulation of the nerves of secreting glands, although doubtless due in part to changes in the blood-vessels, seem to show that this subjection to the nervous system extends even to the chemical and physical operations which take place in secreting cells. A curious and interesting observation in proof of this is adduced by Kölliker. He found that the light of the firefly, *lampyris*, is emitted from cells in which albuminoid matter is decomposed with production of urate of ammonia, and that the emission of light could be brought on or rendered more vivid by electrical and other stimuli operating through the nerves.

The well-known tremulous movement which so often affects minute particles of matter, is not unfrequently observed in the molecular contents of cells; but this phenomenon depends simply upon physical conditions, and is of a totally different character from the motions of the protoplasm above referred to.

**Multiplication of Cells by Division.**—The amoeboid movements of the protoplasm are directly concerned in the process of subdivision of a cell. This is more particularly to be observed in the division of a free cell—a white blood-corpuscle, for example—in which the process, as described by Klein and others, is, briefly, as follows (fig. 7):—One

Fig. 7.

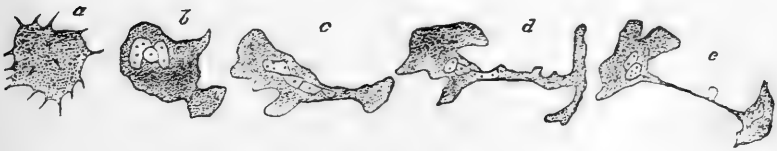

Fig. 7.—STAGES IN THE DIVISION OF A COLOURLESS CORPUSCLE OF NEWT'S BLOOD (after Klein).

of the processes of an amoeboid corpuscle, the nucleus of which has previously undergone division, remains unretracted, and into this one of the nuclei from the body of the cell may pass. The protruded part then becomes more and more withdrawn from the rest of the cell, and, finally, by the rupture of the connecting neck of protoplasm, may become entirely detached, breaking away as an independent corpuscle.

But the process is commonly of a more simple character, as is the case, for instance, with the process of cleavage, already mentioned in treating of the production of embryonic cells. The actual process of division has now been observed in the ova of many of the lower animals. It is preceded by slow heaving movements of the protoplasm; a furrow then appears upon the surface, soon to disappear

again. This is repeated two or three times, but finally the furrow becomes permanent, and, deepening into a groove, gradually constricts the mass into two. In some cases, before this process is complete, a second furrow appears at right angles to the first, and sometimes even a third, the division being thus into four or eight segments instead of into two only, as previously described in the case of the mammalian ovum.

Fig. 8.

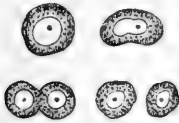


Fig. 8.—DIAGRAM OF THE DIVISION OF A CELL.

In the same manner the division of other cells may take place, the nucleus first becoming divided, and a portion of the protoplasm collecting around each half. The two cells thus produced may each undergo a similar change, and in this way cell-multiplication may be exceedingly rapid. The cells commonly become separated; in some tissues, however, cartilage, for instance, they may remain in proximity, producing thus groups of two or four newly-formed cells, which, in the case of that tissue, are at first enclosed in a common cavity of the matrix: hence the process of multiplication has here been styled "endogenous." It is, however, in all probability, essentially the same as in the less solid tissues.

The division of cells is usually into two, as above described, but, as observed by Remak in the frog larva, it may occur into as many as

five or six. Instances of the same kind are also observed in the development of pus corpuscles from connective tissue corpuscles, the cells becoming enlarged, and their nuclei multiplied previously to breaking up into pus corpuscles. Sometimes, however, a multiplication of nuclei within a cell would seem to occur without immediate separation into new cells, as, for instance, in the case of the large flattened multinucleated

Fig. 9.

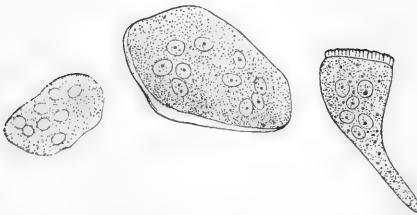


Fig. 9.—MULTINUCLEATED CELLS. 400 DIAMETERS (Kölliker).

cells (fig. 9), which are found in the medullary cavities of bone, and in other situations, and which would seem, at least in bone, to fulfil a special function.

**Of cells in their relation to each other.**—The cells which compose the early embryo have but little connection one with another, the intercellular substance being small in amount, or altogether absent. As growth proceeds, however, they come to present differences in their relations to each other.

a. They may remain isolated, as in the instance of the pale corpuscles of blood, chyle, and lymph.

b. They may be united into a continuous tissue by means of a cementing substance: the epithelium and cuticle, the nails and hairs afford instances of this.

c. Processes from neighbouring cells meet and become united, as is

frequently the case with the corpuscles of connective tissue, and as is seen in the process of development of blood-vessels and nerves.

**Intercellular substance.**—Of the matter which lies between cells—the intercellular substance—and its relation to them, it may be observed that sometimes it is in very small quantity, and seems merely to cement the cells together, as in epithelium; at other times it is more abundant, and forms a sort of matrix, or ground substance, in which the cells are embedded, as in cartilage. It is homogeneous, translucent, and firm in most cartilages, and pervaded by fibres in yellow cartilage. In connective tissue it consists of fibres, with soft interstitial matter, which is scanty in the denser varieties, but abundant in the lax tissue of the umbilical cord; in bone the intercellular substance is calcified and mostly fibrous. As to the production of the intercellular substance, there can be little doubt that in cartilage it is derived from the cells. Formed as capsules round the cells by excretion from their surface, or by conversion of their proper substance, and being blended into a uniform mass, it accumulates while the cells multiply, and while fresh material is supplied to them from the blood, which they convert into chondrinous substance. The source of the intercellular substance is not, in every instance, so apparent, but it may be presumed that the cells have some influence in its nutrition and maintenance.

From what has been said it will be obvious that cells play an important part in the growth of textures, and probably in nutrition. The former process is usually accompanied by a great multiplication of cells, the peculiar constituent of which—the protoplasm—seems to be specially endowed with the faculty of propagation by division, and of increase by appropriating and converting new matter. It is conceivable that in this way it may serve for the extension of growing tissue and the development of structural elements from the crude materials of growth. Again, in the nutrition of a mass of tissue the crude material may undergo preparation by the cells that lie in the interstices of the structure.

The existence of this protoplasmic germinative substance is very general, perhaps indeed universal, in the animal and vegetable kingdoms. But whilst in the great majority of organic beings it assumes the form of a nucleated cell (protoplast, or monoplast), as the first condition of their organised structure, in simpler modes of life and organisation it is not subject to the same limitation of form and mass. In the *mycetozoa* (*myxomycetes*), a curious tribe, heretofore mostly reckoned among the fungi, but standing as it were on the debatable ground between the animal and vegetable kingdoms, the protoplasm is extended into reticular masses, or irregularly anastomosing trains (*plasmodia*), spread over the surface of bark and other bodies to which it parasitically clings; whilst in vibrios and some other infusorial animalcules of the simplest kind, it appears as fine molecular particles; but it is most probably derived from parents in all instances, however minute and apparently insignificant these may be.

The intercellular or ground substance, possesses in a high degree the property of combining with and reducing the salts of silver when previously impregnated with them and exposed to the light. This method of staining, which was introduced by His and von Recklinghausen, has furnished us with a ready means of determining the position and form of delicate cellular elements in a tissue, since these, remaining unstained by the reagent, stand out white upon the dark ground: or in the case of an epithelioid tissue, appear as white polygonal areas bounded by fine dark lines (compare figs. 108 and 109, pp 166, 167).

## NUTRITION AND REGENERATION OF THE TEXTURES.

**Nutrition.**—The tissues and organs of the animal body, when once employed in the exercise of their functions, are subject to continual loss of material, which is restored by nutrition. This waste or consumption of matter, with which, so to speak, the use of a part is attended, takes place in different modes and degrees in different structures. In the cuticular textures the old substance simply wears away, or is thrown off at the surface, whilst fresh material is added from below. In muscular texture, on the other hand, the process is a chemical or chemico-vital one; the functional action of muscle is attended with an expenditure of moving force, and a portion of matter derived in part from the muscle itself is consumed in the production of that force; that is, it undergoes a chemical change, and being by this alteration rendered unfit to serve again is removed by absorption. The amount of matter changed in a given time, or, in other words, the rapidity of the nutritive process, is much greater in those instances where there is a production and expenditure of force, than where the tissue serves merely passive mechanical purposes. Hence, the bones, tendons, and ligaments are much less wasted in exhausting diseases than the muscles, or than the fat, which is consumed in respiration, and generates heat. Up to a certain period, the addition of new matter exceeds the amount of waste, and the whole body, as well as its several parts, augments in size and weight: this is “growth.” When maturity is attained, the supply of material merely balances the consumption; and, after this, no steady increase takes place, although the quantity of some matters in the body, especially the fat, is subject to considerable fluctuation at all periods of life.

It would be foreign to our purpose to enter on the subject of nutrition in general; we may, however, briefly consider the mode in which the renovation of substance is conceived to be carried on in the tissues.

The material of nutrition is immediately derived from the plasma of the blood, or liquor sanguinis, which is conveyed by the blood-vessels, and transudes through the coats of their capillary branches; and it is in all cases a necessary condition that this matter should be brought within reach of the spot where nutrition goes on, although, as will immediately be explained, it is not essential for this purpose that the vessels should actually pass into the tissue. In certain instances, moreover, the pale corpuscles, which exist in the blood, pass through the coats of the vessels, and may become employed as elements of nutrition and reparation.

In cuticle and epithelium, the nutritive change is effected by a continuance of the process to which these textures owe their origin. The tissues in question being devoid of vessels, nutrient matter is furnished by the vessels of the true skin, or subjacent vascular membrane, and is appropriated by young cells, derived most probably from pre-existing ones. These new cells enlarge, alter in figure, often also in chemical nature, and, after serving for a time as part of the tissue, are thrown off at its free surface.

But it cannot in all cases be so clearly shown that nutrition takes place by a continual formation and decay of the structural elements of the tissue; and it must not be forgotten, that there is another con-

ceivable mode in which the renovation of matter might be brought about, namely, by a molecular change which renews the substance, particle by particle, without affecting the form or structure ; by a process, in short, which might be termed "molecular renovation." Still, although conclusive evidence is wanting on the point, it seems probable that the crude material of nutrition first undergoes a certain elaboration or preparation through the agency of cells disseminated in the tissue ; which may serve as centres of assimilation and increase, as already explained.

*Office of the vessels.*—In the instance of cuticle and epithelium, no vessels enter the tissue, but the nutrient fluid which the subjacent vessels afford penetrates a certain way into the growing mass, and the cells continue to assimilate this fluid, and pass through their changes at a distance from, and independently of, the blood-vessels. In other non-vascular tissues, such as articular cartilage, the nutrient fluid is doubtless, in like manner, conveyed by imbibition through their mass, where it is then attracted and assimilated. The mode of nutrition of these and other non-vascular masses of tissue may be compared, indeed, to that which takes place throughout the entire organism in cellular plants, as well as in polypes and some other simple kinds of animals, in which no vessels have been detected. But even in the vascular tissues the case is not absolutely different ; in these, it is true, the vessels traverse the tissue, but they do not penetrate into its structural elements. Thus the capillary vessels of muscle pass between and around its fibres, but do not penetrate their inclosing sheaths ; still less do they penetrate the fibrillæ within the fibre ; these, indeed, are much smaller than the finest vessel. The nutrient fluid, on exuding from the vessels, has here, therefore, as well as in the non-vascular tissues, to permeate the adjoining mass by transudation, in order to reach these elements, and yield new substance at every point where renovation is going on. The vessels of a tissue have, indeed, been not unaptly compared to the artificial channels of irrigation which distribute water over a field ; just as the water penetrates and pervades the soil which lies between the intersecting streamlets, and thus reaches the growing plants, so the nutritious fluid, escaping through the coats of the blood-vessels, must permeate the intermediate mass of tissue which lies in the meshes of even the finest vascular network. The quantity of fluid supplied, and the distance it has to penetrate beyond the vessels, will vary according to the proportion which the latter bear to the mass requiring to be nourished.

We have seen that in the cuticle the decayed parts are thrown off at the free surface ; in the vascular tissues, on the other hand, the old or effete matter must be first reduced to a liquid state, then find its way into the blood-vessels, or lymphatics, along with the residual part of the nutritive plasma, and be by them carried off.

From what has been said, it is clear that the vessels are not proved to perform any other part, in the series of changes above described, beyond that of conveying matter to and from the scene of nutrition ; and that this, though a necessary condition, is not the essential part of the process. The several acts of assuming and assimilating new matter, of conferring on it organic structure and form, and of disorganising again that which is to be removed, which are so many manifestations of the metabolic and plastic properties already spoken of, are performed beyond the blood-vessels. It is plain, also, that a tissue, although devoid of vessels,

and the elements of a vascular tissue, although placed at an appreciable distance from the vessels, may still be organised and living structures, and within the dominion of the nutritive process. How far the sphere of nutrition may, in certain cases, be limited, is a question that still needs further investigation; in the cuticle, for example, and its appendages, the nails and hairs, which are placed on the surface of the body, we must suppose that the old and dry part, which is about to be thrown off or worn away, has passed out of the limits of nutritive influence; but to what distance beyond the vascular surface of the skin the province of nutrition extends, has not been determined.

**Regeneration.**—When part of a texture has been lost or removed, the loss may be repaired by regeneration of a new portion of tissue of the same kind; but the extent to which this restoration is possible is very different in different textures. Thus, in muscle, a breach of continuity may be repaired by a new growth of connective tissue; but the lost muscular substance is not restored. Regeneration occurs in nerve; in bone it takes place readily and extensively, and still more so in fibrous, areolar, and epithelial tissues. The special circumstances of the regenerative process in each tissue will be considered hereafter; but we may here state generally, that, as far as is known, the reproduction of a texture is effected in the same manner as its original formation.

In experimental inquiries respecting regeneration, we must bear in mind, that the extent to which reparation is possible, as well as the readiness with which it occurs, is much greater in many of the lower animals than in man. In newts, and some other cold-blooded vertebrata, indeed (not to mention still more wonderful instances of regeneration in animals lower in the scale), an entire organ, a limb, for example, is readily restored, complete in all its parts, and perfect in all its tissues.

In concluding what it has been deemed advisable in the foregoing pages to state respecting the development of the textures, we may remark that, besides what is due to its intrinsic importance, the study of this subject derives great interest from the aid it promises to afford in its application to pathological inquiries. Researches which have been made within the last few years, and which are still zealously carried on, tend to show that the structures which constitute morbid growths are formed by a process analogous to that by which the natural or sound tissues are developed: some of these morbid productions, indeed, are in no way to be distinguished from areolar, fibrous, cartilaginous and other natural structures, and have, doubtless, a similar mode of origin; others, again, as far as yet appears, are peculiar, but still their production is with much probability to be referred to the same general process. The prosecution of this subject, however, does not fall within the scope of the present work.

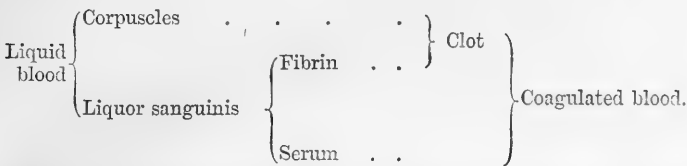
## THE BLOOD.

### PHYSICAL AND ORGANIC CONSTITUTION.

The most striking external character of the blood is its well-known colour, which is florid red in the arteries, but of a dark purple or modena tint in the veins. It is a somewhat clammy and consistent liquid, a little heavier than water, its specific gravity being 1·052 to 1·057; it has a saltish taste, a slight alkaline reaction, and a peculiar faint odour.

To the naked eye the blood appears homogeneous; but, when examined with the microscope, either while within the minute vessels, or when spread out into a thin layer upon a piece of glass, it is seen to

consist of a transparent colourless fluid, named the "lymph of the blood," "liquor sanguinis," or "plasma," and minute solid particles or corpuscles immersed in it. These corpuscles are of two kinds, the coloured and the colourless: the former are by far the more abundant, and have been long known as "the red particles," or "globules," of the blood; the "colourless," "white," or "pale corpuscles," on the other hand, being fewer in number and less conspicuous, were later in being generally recognised. When blood is drawn from the vessels, the liquor sanguinis separates into two parts;—into fibrin, which becomes solid, and a pale yellowish liquid named *serum*. The fibrin in solidifying involves the corpuscles and forms a red consistent mass, named the clot or *crassamentum* of the blood, from which the serum gradually separates. The relation between the above-mentioned constituents of the blood in the liquid and the coagulated states may be represented by the subjoined scheme:—



**Red Corpuscles.**—These are not spherical, as the name "globules," by which they have been so generally designated, would seem to imply, but flattened or disk-shaped. Those of the human blood (fig. 10 and fig. 12 A) have a nearly circular outline, like a piece of coin, and most of them also present a shallow cup-like depression or dimple on both surfaces; their usual figure is, therefore, that of biconcave disks. Their magnitude differs somewhat even in the same drop of blood, and it has been variously assigned by authors; but the prevalent size may be stated at from  $\frac{1}{3500}$ th to  $\frac{1}{3200}$ th of an inch in diameter, and about one-fourth of that in thickness.

In mammiferous animals generally, the red corpuscles are shaped as in man, except in the camel tribe, in which they have an elliptical outline. In birds, reptiles, and most fishes, they are oval disks with a central elevation on both surfaces (fig. 12, B, from the frog), the height and extent of which, as well as the proportionate length and breadth of

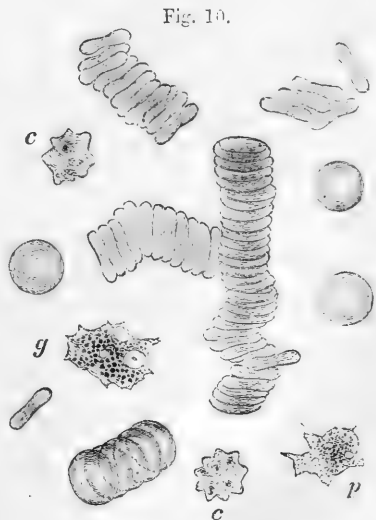


Fig. 10.—HUMAN BLOOD AS SEEN ON THE WARM STAGE. MAGNIFIED ABOUT 1200 DIAMETERS.

*c, c*, crenate red corpuscles; *p*, a finely granular, *g*, a coarsely granular pale corpuscle. Both exhibit two or three vacuoles, in *g*, a nucleus also is visible.

the oval, vary in different instances, so that in some osseous fishes the elliptical form is almost shortened into a circle. The blood-corpuses of invertebrata, although they (except in some of the red-blooded annelides) want the red colour, are also, for the most part, flattened or disk-shaped ; being in some cases circular, in others oblong, as in the larvæ of aquatic insects. Sometimes they appear granulated on the surface like a raspberry, but this is probably due to some alteration occurring in them.

The size of the corpuscles differs greatly in different kinds of animals; it is greater in birds than in mammalia, and largest of all in the naked amphibia. They are for the most part smaller in quadrupeds than in man; in the elephant, however, they are larger, being  $\frac{1}{2700}$ th of an inch, which is the largest size yet observed in the blood-corpuses of any mammiferous animal ; the goat was long supposed to have the smallest, viz., about  $\frac{1}{3400}$ th of an inch; but Gulliver found them much smaller in the Meminna and Napu musk-deer, in which animals they are less than  $\frac{1}{12000}$ th of an inch. In birds they do not vary in size so much; from Gulliver's very elaborate tables of measurement it appears that they range in length from about  $\frac{1}{2400}$ th to  $\frac{1}{1700}$ th of an inch; he states that their breadth is usually a little more than half the length, and their thickness about a third of the breadth or rather more. He found a remarkable exception in the corpuscles of the snowy owl, which measure  $\frac{1}{1350}$ th of an inch in length; and are only about a third of this in breadth. In scaly reptiles they are from  $\frac{1}{1500}$ th to  $\frac{1}{1200}$ th of an inch in length; in the naked amphibia they are much larger: thus, in the frog they are  $\frac{1}{1000}$ th of an inch long, and  $\frac{1}{1700}$ th broad; in the salamander they are larger still; but the largest yet known are found in the protean reptiles. For example, in *Proteus anguinus* they are  $\frac{1}{300}$ th of an inch in length, and  $\frac{1}{270}$ th in breadth; in the siren, which is so much allied to the proteus in other respects, they measure  $\frac{1}{200}$ th of an inch in length, and  $\frac{1}{70}$ th in breadth, whilst in *Amphiuma tridactylum* they are as much as one-third larger than in the proteus. In the skate and shark tribe the corpuscles resemble those of the frog, in other fishes they are smaller.

From what has been stated, it will be seen that the size of the blood-corpuses in animals generally is not proportionate to the size of the body; at the same time, as Gulliver remarks, "if we compare the measurements made from a great number of different species of the same order, it will be found that there is a closer connection between the size of the animal and that of its blood-corpuses than has been generally supposed;" and he has pointed out at least one example of a very natural group of quadrupeds, the ruminants, in which there is a gradation of the size of the corpuscles in relation to that of the body.

**Structure.**—The human red corpuscle is composed essentially of a soft colourless stroma (tegumentary frame of Gulliver) of the same shape and size as the corpuscle itself, throughout which is diffused a semi-fluid coloured matter which may be readily separated from the stroma by means of reagents. Some of these, such as water and acetic acid, appear to act simply by dissolving out the coloured part, leaving the stroma more or less swollen from imbibition of fluid. Others, such as ether and chloroform and the salts of the biliary acids, cause the discharge of the coloured matter into the surrounding fluid; blood so



treated, when viewed in mass by transmitted light, is seen to have lost its opaque appearance and to have acquired a transparent laky tint. Such lake-coloured blood may also be produced by various other means, such as the action of heat ( $60^{\circ}$  C.), the alternate freezing and thawing of a portion of blood, and the passage of electric shocks: the change in colour and translucency obviously depends upon the fact that the corpuscles, when deprived of their coloured part, interfere less with the transmission of light than before: such blood is often exceedingly prone to yield crystals of hæmoglobin (to be afterwards described). The action of tannin is peculiar from the fact that under certain conditions the coloured part, instead of being diffused in the fluid, becomes collected into a minute, highly refracting, globular mass which remains attached to the exterior of the stroma (W. Roberts).\*

The corpuscles alter their shape on the slightest pressure, as is beautifully seen while they move within the vessels; they are also elastic, for they readily recover their original form again. It must be remarked that the blood-corpuscles when viewed singly appear very faintly coloured, and it is only when collected in considerable quantity that they produce a strong deep red.

The human-blood corpuscles, as well as those of the lower animals, often present deviations from the natural shape, which are most probably due to causes acting after the blood has been drawn from the vessels, but in some instances depend upon abnormal conditions previously existing in the blood. Thus, it is not unusual for many of them to appear indented or jagged at the margin, when exposed under the microscope, (fig. 10, *c, c*) and the number of corpuscles so altered often appears to increase during the time of observation. This is, perhaps, the most common change; it occurs whenever the density of the plasma is increased by the addition of a neutral salt, and is one of the first effects of the passage of an electric shock. The corpuscles may become distorted in various other ways, and corrugated on the surface; not unfrequently one of their concave sides is bent out, and they acquire a cup-like figure.

Gulliver made the curious discovery that the corpuscles of the Mexican deer and some allied species present very singular forms, doubtless in consequence of exposure; the figures they assume are various, but most of them become lengthened and pointed at the ends, and then often slightly bent, not unlike caraway-seeds.

The red disks, when blood is drawn from the vessels, sink in the plasma; they have a singular tendency to run together, and to cohere by their broad surfaces, so as to form by their aggregation cylindrical columns, like piles or rouleaus of money, and the rolls or piles themselves join together into an irregular network (figs. 10 and 11). Generally the corpuscles separate on a slight impulse, and they

Fig. 11.

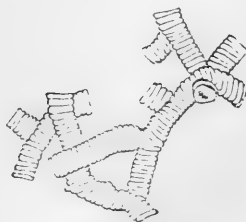


Fig. 11.—RED CORPUSCLES COLLECTED INTO ROLLS (after Henle).

\* Proceedings of the Royal Society, vol. xii. p. 481. For some interesting observations by Dr. W. Addison, F.R.S., on the curious effects produced on red blood-corpuscles by immersion in sherry-wine, see Proceedings of the Royal Society, Dec. 8, 1859.

may then unite again. The phenomenon is probably of a physical kind: it will take place in blood that has stood for some hours after it has been drawn, and also when the globules are immersed in serum in place of liquor sanguinis.\*

By processes, which need not here be detailed, Vierordt and Welcker have estimated the number of red corpuscles in a cubic millimetre of human blood. The former assigns it at upwards of 5,000,000; the latter at 5,000,000 in the male, and 4,500,000 in the female.

Fig. 12.

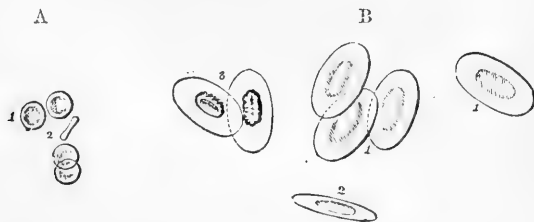


Fig. 12.—HUMAN RED CORPUSCLES (A) AND BLOOD CORPUSCLES OF THE FROG (B) PLACED SIDE BY SIDE TO SHOW RELATIVE SIZE. 500 DIAMETERS.

1, shows their broad surface; 2, one seen edgeways; 3, shows the effect of dilute acetic acid; the nucleus has become distinct (from Wagner).

Like the mammalian blood-disks the large corpuscles of the frog and salamander may be described as consisting of coloured matter and stroma. They differ from them however in the possession of a more solid particle of an oval shape which lies imbedded in the stroma. This has been long known as the “nucleus,” it is rather more than one-third the length of the corpuscle. In the natural unaltered condition the nucleus is seldom visible; this is probably owing to the extreme smoothness of its outline and the fact that it possesses very nearly the same index of refraction as the rest of the corpuscle. For it may be rendered visible, even under such circumstances, by the combined action of watery vapour and carbonic acid upon the blood; a precipitate (of paraglobulin) is thus produced upon the nucleus, and its outline comes into view; on readmission of air the precipitate is re-dissolved, and the nucleus again disappears (Stricker).

The effect of most reagents is similar to that produced on human blood. Water causes both stroma and nucleus to swell up by imbibition, the coloured part being extracted at the same time. A dilute solution of acetic acid in an indifferent fluid also removes the colouring matter, but the stroma and nucleus retain their shape, the last-mentioned body presenting a markedly granular appearance (fig. 12, 3); if strong acetic acid be employed, the nucleus often acquires a reddish tint. Alkalies, on the other hand, even when very dilute, rapidly destroy both corpuscle and nucleus. Various reagents added to newt's blood cause the coloured part of the corpuscles to become collected around the nucleus, and to be more or less withdrawn from the stroma; this is more especially the case with a two per cent. solution of boracic acid (Brücke): the coloured matter and nucleus may subsequently be altogether extruded from the body of the corpuscle.

\* For possible explanations of this phenomenon the reader is referred to memoirs by Lister (Phil. Trans., 1858), and Norris (Proc. Roy. Soc. 1869).

**Pale, white or colourless Corpuseles** (figs. 10 and 13).—These are comparatively few in number, of a rounded and slightly flattened figure, rather larger in man and mammalia than the red disks, and varying much less than the latter in size and aspect in different animals. In man (during health) the proportion of the white corpuseles to the red is about 2 or 3 to 1000. This proportion is diminished by fasting and increased after a meal, especially of albuminous food. Their number compared with the red corpuseles is said to be greater in venous than arterial blood, and much greater in the blood of the splenic and hepatic veins than in venous blood generally. They are destitute of colour and specifically lighter than the red corpuseles. In nature they are in many respects similar to the embryonic cells already described (p. 8), and they possess in a high degree the capability of undergoing amœboid movement; sending out processes (fig. 10, *g*, *p*) into which their granules enter and retracting them again, and even occasionally performing extensive locomotion. The pale corpuseles possess one, two, or, commonly, three nuclei, which are frequently obscured by the granular character of the protoplasm, but may be brought into view by dilute acids (fig. 13). Minute, round, clear spaces may often be seen in the protoplasm (fig. 10); they are entirely free from granules, although probably filled with fluid, and have been named *vacuoles*. They are also met with in the embryonic as well as in other protoplasmic cells. The colourless blood-corpuseles are commonly distinguished into two kinds, according as the protoplasm composing them is finely granular throughout (fig. 10, *p*), or contains a greater or less number of coarser granules, strongly refracting the light (*g*). Whether in the latter case the granules have been formed from fluid matter within the corpusecle, or whether they have not rather been taken in from the surrounding fluid, by the same process as an amœba takes in its food, is at present uncertain: it is however an interesting fact that the pale blood-corpuseles are peculiarly apt to take into their interior minute solid particles that have been introduced into the blood; this property has served as a means of detecting escaped white corpuseles in tissues which are wholly extravascular, the cornea for example (Cohnheim).

Albuminous granules, and molecules of a fatty nature occur in the blood in varying numbers; sometimes very scantily, or not at all, but the latter sometimes very abundantly so as to give the serum a turbid, milky appearance. These are probably derived directly from the chyle, and they are especially seen in the blood of herbivora, in sucking animals, and in pregnant women.

Granular masses occasionally occur in drawn blood, even when taken from a healthy person, but more especially in cachectic states of the system, which on minute examination are seen to be composed of excessively fine, colourless, discoid particles. The latter under favourable conditions develop into vibrating filaments which break away

Fig. 13.



Fig. 13.—PALE CORPUSCLES OF HUMAN BLOOD; MAGNIFIED ABOUT 500 DIAMETERS.

The upper two as seen in the ordinary manner of examination; the lower one after the action of dilute acetic acid, which brings into view the single or composite nucleus.

from the mass and move freely in the liquid (Osler).\* Masses of pigmentous matter are also occasionally found, especially in disease; and in the blood of the splenic vein cells enclosing red blood-corpuscles have been noticed (Ecker, Kölliker). Fine interlacing filaments are commonly to be seen in a preparation of blood under the microscope. These consist of fibrin, and are formed, after the blood has been drawn, in the manner to be presently noticed.

**Liquor Sanguinis, or Plasma.**—This is the pale clear fluid in which the corpuscles are naturally immersed. Its great character is its strong tendency to coagulate when the blood is withdrawn from the circulating current, and on this account it is difficult to procure it free from the corpuscles. Nevertheless, by filtering the slowly coagulable blood of the frog, as was first practised by J. Müller, the large corpuscles are retained by the filter, while the liquor sanguinis comes through in perfectly clear and colourless drops, which, while yet clinging to the funnel, or after they have fallen into the recipient, separate into a pellucid glassy film of fibrin, and an equally transparent diffuent serum. When human blood is drawn in inflammatory diseases, as well as in some other conditions of the system, the red particles separate from the liquor sanguinis before coagulation, and leave the upper part of the liquid clear. In this case, however, the plasma is still mixed with the pale corpuscles, which, being light, accumulate at the top. On coagulation taking place in these circumstances, the upper part of the clot remains free from redness, and forms the well-known buffy coat so apt to appear in inflammatory blood. Horse's blood ordinarily presents this condition when drawn.

The readiest way to obtain the liquor sanguinis in quantity free from red corpuscles is to allow the blood of the horse to flow from the vessels into a receiver, kept cool by means of ice: the blood corpuscles sink to the bottom, leaving the upper part of the fluid clear and colourless. This may be drawn off into another vessel and is found readily to coagulate at a slight elevation of temperature. In the case of frog's blood this artificial cooling is not always necessary; for, if it be collected with as little disturbance as possible, *e.g.*, if the heart be allowed to pump blood directly into a clean glass tube, little or no coagulation may take place, so that the corpuscles rapidly subside and leave the plasma perfectly clear and colourless.† In *post mortem* examinations the cavities of the heart are often found occupied by an almost completely colourless, gelatinous coagulum. This is due to the subsidence of the corpuscles after death.

Coagulated plasma, whether obtained from buffy blood, or exuded on inflamed surfaces, presents, under the microscope, a multitude of fine filaments confusedly interwoven, as in a piece of felt; but these are more or less obscured by the intermixture of corpuscles and fine granules, the former having all the characters of the pale corpuscles of the blood. The filaments are no doubt formed by the fibrin, as it solidifies in the coagulation of the liquor sanguinis. Sometimes, however, fibrin presents when coagulated a gelatinous appearance under the microscope without any sign of filaments.

Blood may be freed from fibrin by stirring it with a bundle of twigs, which entangle the fibrin as it concretes.

\* Centralblatt f. d. med. Wissensch. 1873. Proc. R. S., 1874.

† Schäfer. British Association Reports, 1872.

## CHEMICAL COMPOSITION OF THE BLOOD.

The blood is slightly alkaline in reaction. Carbonic acid, oxygen, and nitrogen gases may be extracted from it by exhaustion by means of the Torricellian vacuum aided by gentle warmth. Carbonic acid is yielded in largest proportion, oxygen next, and nitrogen least. The nitrogen is simply retained by absorption, *i.e.*, in the same proportion as by water at the same pressure and temperature. The oxygen is held by the coloured matter of the red corpuscles; it may be completely expelled from this combination by means of carbonic oxide gas (Bernard). The carbonic acid, which is obtained in larger proportion from serum than from blood, is in great part combined with carbonate of soda in a bicarbonate; from this combination it is set loose in vacuo if the colouring matter of the blood is present. Arterial blood yields more oxygen and less carbonic acid than venous blood.

On being evaporated, 1000 parts of blood yield on an average, about 790 of water and 210 of solid residue. This residue has nearly the same ultimate composition as flesh. A comparative examination of dried ox-blood and dried flesh (beef), by Playfair and Böeckmann gave the following mean result:—

|                    | <i>Flesh.</i> | <i>Blood.</i> |
|--------------------|---------------|---------------|
| Carbon . . . . .   | 51·86         | 51·96         |
| Hydrogen . . . . . | 7·58          | 7·25          |
| Nitrogen . . . . . | 15·03         | 15·07         |
| Oxygen . . . . .   | 21·30         | 21·30         |
| Ashes . . . . .    | 4·23          | 4·42          |

**Red Corpuscles.**—The specific gravity of the red corpuscles in a moist state is calculated at 1·088. They consist, as already stated, of an insoluble colourless stroma, and a diffused red matter, which is soluble and separable by water.

The stroma consists of various substances, chief among which are *paraglobulin*, *cholesterin*, and a phosphuretted fat which was named by O. Liebreich *protagon*, but which, as Hoppe-Seyler has shown, itself consists of two distinct substances—*lecithin* and *neurin*.

If blood be shaken up with ether, the fatty matters of the stroma are dissolved, and the colouring matter is in this way set free (Hermann).

Paraglobulin will be most conveniently described with the serum of the blood, in which it also occurs, and from which it is more readily obtainable; and, for a similar reason, the consideration of the other two substances will be deferred until the nervous system has been treated of.\*

The soluble coloured ingredient of the corpuscles has been named **hæmoglobin** (cruorin of Stokes). This substance, although crystallizable, is indiffusible, and, according to Hoppe-Seyler, contains, when pure, in 100 parts 54·2 of carbon, 21·5 of oxygen, 16·0 of nitrogen, 7·27 of hydrogen, 0·7 of sulphur, and 0·42 of iron; or  $C_{1200}$ ,  $H_{960}$ ,

\* The nucleus of the nucleated red corpuscle consists chiefly of mucin (Kühne, L. Brunton).

$N_{1.54}, Fe_2, S_6, O_{3.54}$ . It may be obtained in quantity and tolerably pure by the following method (Preyer) :

Blood (preferably from a dog) is drawn into a capsule, and the serum allowed to separate. The clot is then taken, and after being quickly minced, is thrown upon a filter, and washed with ice-cold distilled water until the washings yield but little precipitate with perchloride of mercury. By this process the serum, with the albumin it contains, is in great part removed, the cold water taking up but little of the hæmoglobin. The latter is then dissolved out by warm water, and an amount of alcohol, just insufficient to cause its precipitation, is added to the solution. On placing this in a freezing mixture, a large part of the hæmoglobin crystallizes out.

The crystals of hæmoglobin present various forms in different animals, but almost all (the hexagonal plates of the squirrel alone being excepted) belong to the rhombic system. From human blood and that of most mammals, the crystals are elongated prisms (fig. 14, 1), but tetrahedrons in the guinea-pig (2), and short rhombohedrons in the hamster (4). They are most readily obtained for microscopical examination from the blood of the rat, where they appear merely on the addition of a little water.

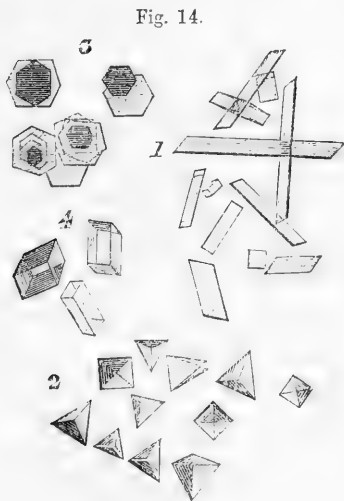


Fig. 14.—BLOOD-CRYSTALS, MAGNIFIED.

1, from human blood ; 2, from the guinea-pig ; 3, squirrel ; 4, hamster.

present in the oxidated or deoxidated condition.\*

**Products of Decomposition of Hæmoglobin.**—Hæmoglobin is an exceedingly unstable body. Even at the ordinary temperature the crystals cannot long be preserved without undergoing alteration, the substance of which they are composed readily decomposing into an exceedingly pure (ash-free) albuminoid substance, named by Preyer *globin*, and a brownish-red powder, very nearly allied to hæmoglobin in chemical composition (hence termed *methæmoglobin*), but differing from that body both in its general reactions and in the character of its spectrum. Another brownish-red substance, which contains all the iron of hæmoglobin, and was long supposed to be the true colouring

\* For an account of the examination of the colouring matter of the blood by the prism, and of the differences in its absorptive effect on light, the reader is referred to an important paper by Professor G. G. Stokes, in the Proceedings of the Royal Society for June 16, 1864, vol. xiii. p. 355, as well as to an exhaustive treatise on the whole subject of hæmoglobin, by W. Preyer (Die Blutkrystalle, Jena, 1871).

matter of blood, is produced by the action of alkalies upon hæmoglobin, and is termed *hæmatin*. When obtained pure this body is insoluble in water, and also in alcohol and ether, except in presence of an alkali. Like hæmoglobin, its alkaline solutions produce a different effect upon the spectrum according as they are oxidated or deoxidated; the absorption bands are, however, entirely different from those of hæmoglobin. The effect of acids upon hæmatin is to separate the iron and to transform the substance into *hæmatoin* (acid-hæmatin), the spectrum of which is characterised by the presence of four absorption bands. A compound of hæmatin with hydrochloric acid (*hæmin*, Teichmann) is readily obtained from hæmoglobin by warming it with a little salt and glacial acetic acid. On cooling, it crystallizes out in minute reddish-brown acicular prisms (fig. 15), the demonstration of which affords a positive proof of the presence of blood-colouring matter. They may readily be obtained from dried blood without the addition of salt, merely by warming it with concentrated acetic acid.\*

Fig. 15.



Fig. 15.—HEMIN CRYSTALS, MAGNIFIED (from Preyer).

**Inorganic Constituents of the Red Corpuscles.**—Besides the iron of the hæmoglobin, the red corpuscles contain a certain proportion of salts, chiefly of potash and lime, combined with carbonic and phosphoric acids. It is, however, impossible to obtain the corpuscles in quantity, sufficiently isolated for exact analysis.

**Proportion of Red Corpuscles.**—The red corpuscles form by far the largest part of the organic matter in the blood: their proportion may be approximately ascertained by filtering defibrinated blood mixed with solution of sulphate of soda; or by weighing the dried clot, and making allowance for the fibrin it contains. The latter method, however, will serve only to give a rough estimate, as the very uncertain amount of serum remaining in the clot and affecting its weight cannot be determined. Prevost and Dumas made too large a deduction for the solid matter supposed to belong to the retained serum, and this reduced the estimate of the dried corpuscles too much, viz. to 129 parts per 1000 of blood. Lecanu also gives it at from 120 to 130: Becquerel and Rodier at from 131 to 152. Schmidt, from three modes of calculation, which it is needless here to explain, arrived at the conclusion that the proportion of *moist* red corpuscles in 1000 parts of blood is from 480 to 520; but there are reasons for regarding this as too high an estimate. Hoppe-Seyler estimates the proportion at 326 per 1000.

Different observers agree that, as a general rule, the proportion of red particles is greater in the blood of the male sex than in that of the female. Lecanu gives the following mean result, derived from numerous analyses, exhibiting the proportion of dry crassamentum and water in the blood of the two sexes. No

\* For some interesting observations by A. Gamgee on the action of nitrites on hæmoglobin, see Philosophical Transactions, 1868, p. 589.

deduction is made for the fibrin ; but, considering its small relative quantity, any possible variation in it cannot materially affect the general conclusion.

|                     | <i>Male.</i> | <i>Female.</i> |
|---------------------|--------------|----------------|
| Crassamentum, from. | 115·8 to 148 | 68·3 to 129·9  |
| Water . . . . .     | 778 to 805   | 790 to 853     |

As regards age, Denis found the proportion of crassamentum greatest between the ages of 30 and 40. Sudden loss of blood rapidly diminishes it. In two women who had suffered from uterine hæmorrhage, the crassamentum amounted to only 70 parts in 1000. The same effect may be observed to follow ordinary venesection. In a person bled three times in one day, Lecanu found in the first drawn blood 139, and in the last only 76 parts of crassamentum in the 1000. This effect may be produced very suddenly after a bleeding. Prevost and Dumas bled a cat from the jugular vein, and found 116 parts of crassamentum in 1000, but in blood drawn five minutes afterwards, it was reduced to 93. The sudden loss of blood probably causes a rapid absorption of serous and watery fluid into the vessels, and thus diminishes the relative amount of the red particles. It is found that the blood of warm-blooded animals is richer in crassamentum than that of the cold-blooded ; and, among the former, the proportion is highest in the class of birds.

**Liquor Sanguinis, or Plasma.**—The fluid part of the blood, as already described, separates spontaneously into fibrin and serum. The fibrin may be obtained by stirring the blood as soon as possible after it is drawn, or by washing the crassamentum with water, to free it from red matter. Procured in either of these ways, the fibrin contains pale corpuscles and a small proportion of fat. From dried fibrin of healthy human blood, Nasse obtained nearly five per cent. of fat, and still more from the fibrin of buffy blood. The proportion of fibrin in the blood does not exceed  $2\frac{1}{2}$  parts in 1000 ; indeed, according to the greater number of observers, it is not more than  $2\frac{1}{2}$ . As a general rule, the quantity is somewhat greater in arterial than in venous blood, and it is increased in certain states of the body, especially in inflammatory diseases and in pregnancy.

**Origin of Fibrin.**—It is now ascertained that the fibrin is not present, as such, in a liquid form, in the plasma, but is produced at the moment of consolidation by the co-operation or combination of two previously distinct substances. About thirty years ago, A. Buchanan\* discovered that the fluid of hydrocele, which might in an unmixed state be kept for an indefinite time without coagulating, very speedily congealed and separated into clot and serum when mixed with a little blood. Ordinary blood-serum, blood-clot, especially washed clot, and buffy coat, even after being dried and long kept, when added in small proportion to the hydrocele-fluid, produced the same effect. From these facts Buchanan concluded that fibrin exists as a liquid both in hydrocele-fluid and in the liquor sanguinis, that liquid fibrin does not coagulate spontaneously, but requires for that end the influence of some “suitable reagents,” that such a reagent is naturally present in the blood, and brings about the solidification of its fibrin in the natural process of coagulation, and that it is absent from the hydrocele-fluid, but when supplied by the addition of blood, causes the fluid fibrin to solidify. On further reasoning on the facts he had observed, Dr. Buchanan was led to believe that “coagulant power”

\* Proceedings of the Glasgow Philosophical Society, 1845.



was mainly seated in the pale corpuscles,\* which abound in the washed clot and the buffy coat, and are present in the serum; and that their efficacy depended on their organisation as elementary cells. In harmony with this latter view, he found on trial that the organised tissues, such as muscle, skin, and spinal marrow, possessed the same power, though in a less degree than the pale corpuscles, in which, as primary cells, the metabolic power is more energetic.

The remarkable phenomenon described by Buchanan did not obtain the consideration it deserved, and the coagulation of hydrocele-fluid, under the conditions stated, was commonly ascribed to some catalytic action of the substance added, which induced liquid fibrin present in the fluid to solidify. In 1861, however, A. Schmidt, of Dorpat, apparently unaware of Buchanan's observations, fell upon facts of the same kind, and pursuing the investigation by an elaborate series of experiments, not only with hydrocele-fluid, but with pericardial, peritoneal, and other serous fluids and effusions, which give a like result, has satisfactorily shown that fibrin has no existence in a liquid state, but that when it appears as a coagulum in a fluid, it is actually produced then and there by the union of two constituents present in solution, and forthwith shed out as a solid matter. One of these constituents which contributes in largest measure to the product, he names *fibrinogenous substance*, the other *fibrinoplastic substance*. In the coagulation of hydrocele-fluid, the former, or *fibrinogen*, is already there, while the *fibrinoplastin* is supplied from the blood. It is not that the latter converts albumin into fibrin, for, after a certain amount of fibrin has been coagulated from the serous fluid, no further addition will generate more, although abundance of albumin remains; and again, a given quantity of fibrinoplastin will not coagulate with equal rapidity and intensity any amount of fluid containing fibrinogen. In short, the fibrinoplastic substance seems to operate not by catalysis, but by combining with the other necessary ingredient. Now Schmidt has shown that the fibrinoplastic matter presents all the chemical characters of paraglobulin, and is, in fact, nothing else than that substance. This paraglobulin is not restricted to the red corpuscles; it is found in the serum after separation of the clot, and doubtless exists also in the pale corpuscles. Nor is it confined to the blood. From chyle and lymph, and from various organs and tissues of the body, a substance may be obtained having the same reactions and the same fibrino-plastic power. Fibrinogen may be obtained from hydrocele-fluid in the same manner as paraglobulin from blood-serum (*vide infra*); it very closely resembles paraglobulin in its chemical relations, only it is less soluble in acids and alkalies, and less energetic in all its re-actions. Of course, it exists in blood-plasma, and in the process of coagulation of the blood combines with paraglobulin to form the fibrin of the clot.†

\* This idea or one similar, has been recently revived by Mantegazza, who conceives the fibrin to be derived from the pale corpuscles, or at least that their presence is necessary for coagulation to take place. Compare also Burdon Sanderson, Handbook for the Physiological Laboratory, p. 173.

† Schmidt, Alex., in Reichert & Du Bois Reymond's Archiv für Anat. u. Physiol. 1861 and 1862. For a lucid account of this subject, founded on a confirmatory repetition of Buchanan's and of Schmidt's fundamental experiments, see an article on "the Coagulation of the Blood," [by Dr. Michael Foster], in the Natural-History Review for 1864, p. 157.

**Serum.**—This is a thin and usually transparent liquid, of a pale yellowish hue; it is, however, sometimes turbid, or milky, and this turbidity may depend upon different conditions, but most commonly on excess of fatty particles. The specific gravity of serum ranges from 1·025 to 1·030, but is most commonly between 1·027 and 1·028 (Nasse), and is more constant than that of the blood. The solid contents of the serum are not more than 8 or 9 in 100 parts; the proportion of water being, for males 90·88, and for females 91·71. It is always more or less alkaline. When heated, it coagulates, in consequence of the large quantity of albumin it contains; and after separation of the albumin, a thin saline liquid remains, sometimes named “serosity.” The following ingredients are found in the serum:—

**Albumin.**—This principle is partly combined with soda as an albuminate; its quantity may be determined (after previous removal of paraglobulin) by precipitating it in the solid form by means of heat or alcohol, washing with distilled water, drying, and weighing the mass. Its proportion is about 80 in 1000 of serum, or nearly 40 in 1000 of blood. Serum-albumin differs from albumin obtained from white of egg in the fact of its not being precipitated by ether; in other respects it closely resembles that substance. Albumin is coagulated and transformed into an insoluble variety by heat.

Albumin is closely allied to paraglobulin, fibrinogen, myosin, and many other nitrogenized substances met with in the animal economy: they are therefore commonly grouped together as *albuminoid* substances, protein bodies, or proteids. Albuminoids are characterised by their low diffusibility and their readiness, when in solution, to take on the solid condition, or to coagulate. They therefore belong to the colloid substances of Graham. They are precipitated from their solutions by alcohol, mineral acids, tannic acid, corrosive sublimate, and many other metallic salts. They are all coloured yellow by nitric acid, becoming red on subsequent addition of ammonia. Acid nitrate of mercury produces a red colour, and sulphate of copper and potash a violet colour in their solutions. The albuminoids all consist of carbon, hydrogen, oxygen, and nitrogen, together with a small amount of sulphur.

By the action of the gastric juice ordinary albuminoids are transformed into an exceedingly soluble, diffusible variety termed *pepton*.

Albumin combines with both acids and alkalis forming respectively acid-albumin or syntonin, and alkali-albumin or casein.

**Paraglobulin.**—When serum is diluted with about ten times its bulk of distilled water, and subjected to a stream of carbonic acid, the liquid becomes turbid, and paraglobulin is precipitated. It may also be obtained from the diluted serum by the cautious addition of acetic acid, but the least excess of acid will re-dissolve the precipitate. Paraglobulin is a protein compound, agreeing very nearly with albumin in elementary composition, so far as this has been ascertained. Paraglobulin is nearly insoluble in pure water, but readily dissolves on a very slight addition of either an alkali or an acid. Weak acids throw it down from its solution in alkali, but when added in slight excess re-dissolve it. In like manner it is precipitated by alkalis from its solutions in acids and re-dissolved by excess. From neither of these solutions is it thrown down by heat. It is dissolved by neutral salts, and from this solution heat throws it down in an insoluble precipitate. From its slightly alkaline solution in water it is thrown down by a stream of carbonic acid, and may be re-dissolved by passing air or

oxygen through the liquid. Its precipitate is distinguished from that of other albuminoids by being always in form of fine granules or molecules. But the most important and distinctive character of paraglobulin is its fibrino-plastic property, already referred to, by which it co-operates with fibrinogen in producing solid fibrin; this property is destroyed by exposure of the solution to a boiling heat.

Paraglobulin is almost identical in chemical nature and composition with the substance which composes the crystalline lens, and which was named by Berzelius *globulin*. The latter substance, however, besides exhibiting minor differences, does not possess the fibrino-plastic power; they have therefore been separately distinguished by Kühne. Like hæmoglobin, paraglobulin is diffusible through animal membranes, not through vegetable parchment. Fibrinogen, on the other hand, is totally indiffusible. Both paraglobulin and fibrinogen may be precipitated from their solutions by the addition of common salt to saturation.

A substance similar to *myosin* has also been described as occurring in blood-serum (Heynsius).

**Fatty Compounds.**—A small amount of fat is contained in the serum, partly dissolved, and partly diffused in the liquid. It may be separated by gently agitating the serum with about a third of its bulk of ether, or by evaporating the serum and digesting the dry residue in ether, or in boiling alcohol. The turbid milky aspect which serum often exhibits, is in most cases due to a redundancy of fat, and may accordingly be removed by agitation with ether.

**Extractive Matters.**—When the serum has been freed from albuminous matter by coagulation, and from fat by ether, and is evaporated to dryness, a yellowish or brown mass remains, consisting of organic matters mixed with salts; the former belonging principally to the ill-defined class of substances denominated “extractive matters.” These have now been more carefully sifted, and have yielded several definite and recognisable bodies, generated in the natural process of decomposition of the tissues, or residual matters of nutrition formed in the blood itself, and on their way to be excreted by the kidneys. Several of the substances to be next mentioned belong to this class, and as they are obviously excrementitious and transitory ingredients, they are not allowed to gather in any notable quantity in the healthy state of the economy.

*Creatin* and *Creatinin*.—Products of the natural “wear” of the muscles, or derived from fleshy food. These compounds, which are found in muscular substances and in the urine, together with *hypoxanthin* (also named *sarkin*), obtainable from the same sources, have been stated to exist in excessively small quantities in the blood.

*Urea*.—This substance, which accumulates in the blood of animals after extirpation of the kidneys or ligature of the renal arteries, as well as in certain diseases, has been found in very minute quantity in the healthy blood of the ox and of the calf, by Marchand and Simon, and in that of man, by Lehmann, Garrod, and others. It is, however, in such excessively small quantity, that its estimation is attended with great difficulty.

*Uric Acid* has been shown to exist in healthy blood by Garrod, and in that of persons suffering from gout it is in such considerable quantity as to be readily detected. In health its proportion is extremely small.

*Hippuric Acid* is found in the blood of herbivora, and, according to some observers, in that of man. There is, however, much doubt upon this point.

*Leucin* and *Tyrosin*, which exist in almost all secretions and excretions, probably are present in minute quantity in the blood; but as yet they have only been detected in it in disease of the liver.

*Sugar* has been found in the blood of dogs, oxen, and cats, also in that of diseased and healthy persons. The quantity is very small. The form of sugar is that known as glucose or grape sugar.

*Colouring and Odoriferous Matters.*—The yellowish colour and peculiar faint odour which serum possesses are probably dependent upon the presence of certain definite principles. No one has, however, as yet succeeded in isolating them. The odour of the blood is said to be of peculiar character in each species of animal, and to be heightened by the addition of sulphuric acid. Schmidt found, however, that the blood of only three animals yielded an odour distinctive of the species.

**Salts.**—1. Having soda and potash as bases, combined with lactic, carbonic, phosphoric, sulphuric, and fatty acids. Also chlorides of sodium and potassium, the former in large proportion. Schmidt has pointed out that the potash-salts exist almost exclusively in the blood-corpuscles and the soda salts principally in the serum. In the corpuscles there are principally chloride of potassium and phosphate of potash: in the serum, chloride of sodium and phosphate of soda. The following table (giving the mean of eight experiments) exhibits the relative quantities of potassium and sodium, and of phosphoric acid and chlorine, in the blood-corpuscles and plasma.

100 parts of Inorganic Matters.

| <i>Blood-Corpuscles.</i> |      | <i>Plasma.</i> |       | <i>Blood-Corpuscles.</i> |       | <i>Plasma.</i>    |       |
|--------------------------|------|----------------|-------|--------------------------|-------|-------------------|-------|
| K.                       | Na.  | K.             | Na.   | PO <sub>5</sub> .        | Cl.   | PO <sub>5</sub> . | Cl.   |
| 40.89                    | 9.71 | 5.19           | 37.74 | 17.64                    | 21.00 | 6.08              | 40.68 |

The table shows that the chlorides are, relatively to the phosphates, in much larger quantity in the plasma than in the blood-corpuscles; and that the phosphates are, relatively to the chlorides, in much larger proportion in the blood-corpuscles than in the plasma.

2. Lactate of ammonia. 3. Salts with earthy bases, viz., lime and magnesia, with phosphoric, carbonic, and sulphuric acids.

The earthy salts are for the most part associated with the albumin, but partly with the crassamentum. As they are obtained by calcination, it has been suspected that the phosphoric and sulphuric acids may be in part formed by oxidation of the phosphorus and sulphur of the organic compounds. Nasse found in 1000 parts of blood 4 to 7 of alkaline, and 0.53 of earthy salts.

The ashes of blood yield, according to Jarisch, 8.34 per cent. of oxide of iron, or about .0948 parts in 100 of blood.

**Mean Composition of Blood.**—The following approximative statement of the mean composition of venous blood (horse) is furnished by Hoppe-Seyler:—

In 1000 parts of blood—

|                      |       |
|----------------------|-------|
| Corpuscles . . . . . | 326.2 |
| Plasma . . . . .     | 670.8 |

In 1000 parts of corpuscles—

|                  |       |
|------------------|-------|
| Water . . . . .  | 565.0 |
| Solids . . . . . | 435.0 |

In 1000 parts of plasma—

|                  |       |                                                                                                                                                                     |
|------------------|-------|---------------------------------------------------------------------------------------------------------------------------------------------------------------------|
| Water . . . . .  | 908.4 | { Fibrin . . . . . 9.2<br>Albumin . . . . . 70.5<br>Fats . . . . . 1.0<br>Extractives . . . . . 3.6<br>Soluble salts . . . . . 5.8<br>Insoluble salts . . . . . 1.5 |
| Solids . . . . . | 91.6  |                                                                                                                                                                     |

Scherer and Otte give the following as the composition of human venous blood :—

In 100 parts of blood—

|                         |       |                                                                                                                                       |
|-------------------------|-------|---------------------------------------------------------------------------------------------------------------------------------------|
| Water . . . . .         | 79.05 | { Fibrin . . . . . 0.2<br>Albuminoids (with<br>Hæmoglobin) . . . . . 19.44<br>Extractives . . . . . .48<br>Soluble salts. . . . . .83 |
| Solid matters . . . . . | 20.95 |                                                                                                                                       |

The serum of the same blood yielded in 100 parts—

|                        |       |
|------------------------|-------|
| Water . . . . .        | 90.66 |
| Albumin . . . . .      | 7.76  |
| Extractives . . . . .  | 0.51  |
| Soluble salts. . . . . | 0.94  |

**Difference between Arterial and Venous Blood.**—By arterial blood is meant that which is contained in the aorta and its branches (systemic arteries), in the pulmonary veins and in the left cavities of the heart; the venous blood is that of the veins generally, the pulmonary arteries, and right cavities of the heart. Their differences, apart from their functional effects in the living body, come under the heads of colour and composition.

1. Colour. Arterial blood, as already stated, is scarlet, venous blood dark, or purple. Venous blood assumes the scarlet colour on exposure to air, *i. e.* to oxygen. This change is greatly promoted by the saline matter of the serum, and may be accelerated by adding salts or sugar to the blood, especially by carbonate of potash, or of soda, and by nitre. Salts added to dark blood, without exposure to oxygen or air, cause it to assume a red colour, but not equal in brightness to that of arterial blood. On the other hand, the addition of a little water darkens the blood. According to Stokes, the corpuscles in the former case "lose water by exosmosis, and become thereby highly refractive, in consequence of which a more copious reflexion takes place at the common surface of the corpuscles and surrounding fluid. In the latter case they gain water by endosmosis, which makes their refractive power more nearly equal to that of the fluid in which they are contained, and the reflexion is consequently diminished."\* But the presence of serum or of saline matter is not indispensable to the brightening, for although the clot when washed free from serum scarcely if at all reddens on exposure to oxygen, yet it is found that the red matter when squeezed out of the clot and dissolved in water, still becomes brighter and clearer on exposure to oxygen, whilst the colour is darkened (and the solution becomes turbid from deposition of paraglobulin), on being shaken with carbonic acid. As in this case the colouring matter is extracted from the corpuscles and is reddened by oxygen without the presence of salts, it is plain that the difference of colour of arterial and venous blood essentially depends, not on a difference in the figure or density of the corpuscles, but on the alteration produced in the colour-

\* Proc. Royal Soc., vol. xiii. p. 362.

ing substance by oxidation and deoxidation, which alters its absorptive effect on the light.

Viewed in thin layers by transmitted light, venous blood appears green. It is, therefore, dichroitic.

2. Composition. The arterial blood, so far as is known, is uniform in nature throughout; but in passing through the capillary vessels into the veins, whilst it generally acquires the common characters of venous blood, it undergoes special changes in its passage through particular organs, so that the blood of all veins is not alike in quality. Thus the blood of the hepatic veins differs from that of the portal vein, and both are in various respects different from what might be regarded as the common venous blood, which is conveyed by the veins of the limbs, and of the muscular and cutaneous parts of the body generally. Moreover, Bernard has shown that the blood of veins returning from secreting glands differs according to the state of functional activity of the organs. Whilst their function is in abeyance the blood in their veins is dark, as usual, but when secretion is active, the blood, which then also flows much more freely and abundantly, comes through from the arteries to the veins with very little, if any, reduction of its arterial brightness; it also retains nearly the whole of its separable oxygen.

Compared with blood from a cutaneous vein, arterial blood is found to contain a very little more water (about five parts in 1000) and to have a somewhat lower specific gravity. The arterial plasma yields more fibrin and coagulates more quickly; the serum was said by Lehmann to contain less albumin and less fat, but more extractive and a little more saline matter. Arterial blood yields more oxygen gas, and less of both free and combined carbonic acid.

*Blood of the portal vein*, compared with that of the jugular vein, was stated by Lehmann to contain more water in proportion to solid matter, less fibrin and albumin, more fat, extractive matter and salts. The pale corpuscles are vastly more numerous than in venous blood generally.

*The blood of the hepatic veins*, according to Lehmann's statement, is richer in both red and pale corpuscles, possibly from loss of water, and the proportion of pale corpuscles to the red is increased. The hepatic venous blood, moreover, yields sugar, derived from glycogen formed in the liver.

The blood of the renal veins was stated by Bernard and Brown-Séguard not to coagulate in the normal state of the kidney and its function: on trial, however, we find that as regards coagulation it behaves like ordinary venous blood.

#### COAGULATION OF THE BLOOD.

In explaining the constitution of the plasma, we have been obliged so far to anticipate the account of the coagulation of the blood. The following are the phenomena which usher in and which accompany this remarkable change. Immediately after it is drawn the blood emits a sort of exhalation, the "halitus," having a faint smell; in about three or four minutes a film appears on the surface, quickly spreading from the circumference to the middle; a minute or two later the part of the blood in contact with the inside of the vessel becomes solid, then speedily the whole mass; so that in about eight or nine minutes after being drawn, the blood is completely gelatinised. At about fifteen or twenty minutes, or it may be much later, the jelly-like mass begins to shrink away from the sides of the vessel, and the serum to exude from it. The clot continues to contract, and the serum to escape for several hours, the rapidity and degree of the contraction varying exceedingly in different cases; and, if the serum be poured off, more will usually continue to drain slowly from the clot for two or three days.

The nature of the change which takes place in the coagulation of the blood has been already spoken of: it is essentially owing to the coagulation of the

liquor sanguinis, the fibrin being generated in that liquid by the concurrence of its two constituents in the way already explained, and separating in form of a solid mass, which involves the corpuscles but allows the serum to escape from it in greater or less quantity. But although the solidification of the fibrin and formation of a red clot would undoubtedly take place independently of any mechanical co-operation on the part of the corpuscles, still it must not be forgotten that the red disks are not altogether indifferent while coagulation goes on: for they run together into rolls, as already described, and the circumstance of their doing so with greater or with less promptitude materially affects the result of the coagulating process. Thus there seems good reason to believe that, as H. Nasse pointed out, one of the causes—and in inflammatory blood probably the chief cause—of the production of the buffy coat, is an exaltation of the natural tendency of the red disks to run together, whereby being more promptly and more closely aggregated into compact masses, they more speedily subside through the liquid plasma, leaving the upper part of it colourless by the time coagulation sets in; and Wharton Jones has drawn attention to what he conceives to be another influential circumstance depending likewise on the corpuscles, in inflammatory blood, namely, the more rapid and close shrinking of the network, or spongework as he terms it, into which the little rolls of corpuscles unite, and the consequent expulsion of the great part of the liquor sanguinis from its meshes before the fibrin solidifies, in which case the mass of aggregated corpuscles naturally tends to the lower part of the vessel, whilst the expressed plasma, being lighter, accumulates at the top. Of course it is not meant to deny that more tardy coagulation of the plasma would produce the same result as more speedy aggregation of the corpuscles; it is well known, indeed, that blood may be made to show a buffy coat by delaying its coagulation, but buffed inflammatory blood is not necessarily slow in coagulating.

**Circumstances affecting Coagulation.**—Various causes accelerate, retard, or entirely prevent the coagulation of the blood; of these it will here suffice to indicate the more important and best ascertained.

1. **Temperature.**—Cold delays, and at or below 40 degrees Fahr. wholly suspends coagulation; but even frozen blood, when thawed and heated again, will coagulate. Moderate elevation of temperature above that of the body promotes coagulation.

2. Coagulation is accelerated by contact of the blood with foreign matter, such as the sides of the basin or other vessel into which it is drawn. On the other hand, the maintenance of its fluidity is favoured by retention within its vessels or natural receptacles where it is in contact with the natural tissues of the body; but when the coats of the vessels or other tissues, with which the blood is contiguous, lose their vitality and are altered in their properties, they become as foreign bodies, and coagulation is promoted. The usual exposure of drawn blood to the air promotes coagulation, but according to Lister, by no means so powerfully as was formerly believed. The effect of other gases is the same. Coagulation speedily takes place when blood is subjected to the air-pump, and has therefore been said to occur readily in vacuo, but Lister finds that this is owing to the agitation caused by the bubbling of the blood from the escape of liberated gases, whereby more and more of it is successively brought into contact with the sides of the vessel.

3. Arrest of the blood's motion *within the body* is said to favour coagulation, probably by arresting those perpetual changes of material, both destructive and renovative, to which it is naturally subject in its rapid course through the system. The coagulation of the stagnant blood after death is also largely to be ascribed to the alteration then ensuing in the coats of the containing vessels. Lister found that, after

death, blood remains longer fluid in the small veins than in the heart and great vessels ; and even in these the coagulation is usually slow. Agitation of *exposed* blood accelerates coagulation by increasing its exposure to foreign contact.

4. Water, in a proportion not exceeding twice the bulk of the blood, hastens coagulation ; a larger quantity retards it. Blood also coagulates more speedily when the serum is of low specific gravity, indicative of much water in proportion to the saline ingredients.

5. Almost every substance that has been tried, except the caustic alkalis, when added to the blood *in minute proportion*, hastens its coagulation ; although many of the same substances, when mixed with it in somewhat larger quantity, have an opposite effect. The salts of the alkalies and earths, added in the proportion of two or three per cent. and upwards, retard, and, when above a certain quantity, suspend or prevent coagulation ; but, though the process be thus suspended, it speedily ensues on diluting the mixture with water. Caustic potash and soda permanently destroy the coagulability of the blood. Acids delay or prevent coagulation.

6. Certain states of the system.—Faintness occasioned by loss of blood favours coagulation ; states of excitement are said to have, though not invariably, the opposite effect. Impeded aëration of the blood in disease, or in suffocative modes of death, makes it slow to coagulate ; probably from retention of carbonic acid. In cold-blooded animals, with slow circulation and low respiration, the blood coagulates less rapidly than in the warm-blooded ; and, among the latter, the tendency of the blood to coagulate is strongest in birds, which have the greatest amount of respiration, and highest temperature.

7. Coagulation commences earlier, and is sooner completed, in arterial than in venous blood. Nasse states that women's blood begins to coagulate sooner than that of the male sex.

In general, when blood coagulates quickly, the clot is more bulky and less firm, and the serum is less effectually expressed from it ; so that causes which affect the rapidity of coagulation, will also occasion differences in the proportion of the moist clot to the exuded serum.

There is no sufficient evidence of evolution of heat or of disengagement of carbonic acid from blood during its coagulation, which some have supposed to occur.

**Theory of Coagulation.**—Although it is certain that the coagulation of the blood consists in solidification of fibrin, and although it seems tolerably well established that this is the result of the combination of two primarily separate animal principles, it is by no means clearly understood how such combination and solidification do not naturally take place within the living body, and how the several conditions already mentioned as influencing the process operate in promoting or opposing coagulation.

According to one view, which is fundamentally the same as that entertained by John Hunter and some other British physiologists, and which has been advocated by Brücke,\* the blood has a natural tendency to coagulate ; or, if we may use the language suggested by later researches, the para-globulin and fibrinogen naturally tend to combine ; within the body this tendency is held in check by some inhibitory or restraining influence exercised by the coats of the vessels and the living tissues in contact with the blood ; but when blood is withdrawn from its natural receptacles, or if these lose their vitality, its intrinsic disposition to coagulate being no longer opposed, is allowed to prevail. At the same time it is not

\* British and Foreign Medico-Chirurgical Review, vol. xix. 1857.



inconsistent with this theory to admit the positive efficacy of contact with foreign or dead matter in promoting coagulation. Lister,\* on the other hand, considers that the blood has no spontaneous tendency to coagulate, either within or without the vessels, but that the coagulation is brought about in drawn blood by contact with foreign matter. Accepting the conclusion of Schmidt, that para-globulin and fibrinogen are necessary to the evolution of fibrin, he thinks that, if these bodies unite in ordinary chemical combination, the action of foreign matter may determine their union, as spongy platinum promotes the combination of oxygen and hydrogen. He considers that the living vessels do not exert any action to prevent coagulation, but that their peculiarity, as distinguished from an ordinary solid, consists in the remarkable circumstance that their lining membrane, in a state of health, is wholly negative in its relation to coagulation, and does not cause that molecular disturbance, so to speak, which is produced in the blood by all ordinary matter. When the vessels lose their peculiar property by death, or become seriously altered by disease or injury, their contact with the blood induces coagulation like that of an extraneous body. More recently, Schmidt† has himself come to the conclusion that the union of para-globulin and fibrinogen to form fibrin is determined by the presence of a third substance, which, however, does not itself take part in the combination and which he has consequently named the fibrin-ferment. This substance he believes to be not preformed in the blood, but to become formed immediately after the withdrawal of that fluid from the body. Other substances also, according to Schmidt, possess the property of inducing the union of para-globulin and fibrinogen, amongst them being the colouring matter of the blood,‡ charcoal, spongy platinum, asbestos, animal ferments, &c.; more especially those which are able to decompose peroxide of hydrogen. Schmidt considers the action of these substances to be purely one of contact; in this respect it will be seen he has adopted Lister's view. Finally, it may be observed, that in any attempted explanation of the coagulation of the blood, it is well to bear in mind that there is a purely physical or chemical phenomenon, which, as suggested by Graham, has a certain analogy to it, namely the change from the liquid to the insoluble state so easily induced in colloidal matter by slight external causes.

#### THE LYMPH AND CHYLE.

A transparent and nearly colourless fluid, named "lymph," is conveyed into the blood by a set of vessels distinct from those of the sanguiferous system. These vessels, which are named "lymphatics," from the nature of their contents, and "absorbents," on account of their reputed office, take their rise in nearly all parts of the body, and, after a longer or shorter course, discharge themselves into the great veins of the neck; the greater number of them previously joining into a main trunk, named the thoracic duct,—a long narrow vessel which rises up in front of the vertebrae, and opens into the veins on the left side of the neck, at the angle of union of the subclavian and internal jugular; whilst the remaining lymphatics terminate in the corresponding veins of the right side. The absorbents of the small intestine carry an opaque white liquid, named "chyle," which they absorb from the food as it passes along the alimentary canal; and, on account of the milky aspect of their contents, they have been called the "lacteal vessels." But in thus distinguishing these vessels by name, it must be remembered, that they differ from the rest of the absorbents only in the nature of the matters which they convey; and that this difference holds

\* On the Coagulation of the Blood; the Croonian Lecture for 1863.—Proceedings of the Royal Society, vol. xii. p. 580.

† Pfüger's Archiv. vi. 1872.

‡ In connection with this fact, it may be interesting to mention that, if blood which has been well whipped to remove the fibrin be frozen and thawed again (a process by which the red corpuscles become broken up), it yields a further coagulum.

good only while digestion is going on ; for at other times the lacteals contain a clear fluid, not to be distinguished from lymph. The lacteals enter the commencement of the thoracic duct, and the chyle, mingling with the lymph derived from the lower part of the body, is conveyed along that canal into the blood. Both lacteals and lymphatics, in proceeding to their destination, pass into and out of certain small, solid, and vascular bodies, named lymphatic glands, which have a special structure and internal arrangement, as will be afterwards described ; so that both the chyle and lymph are sent through these glands before being mixed with the blood.

Thus much having been explained to render intelligible what follows, we may now consider the lymph and the chyle, which, as will be seen, are intimately related to the blood.

The **lymph** may be procured free from admixture of chyle, and in quantity sufficient for examination, from the larger lymphatic vessels of the horse or ass. It may also be obtained by opening the thoracic duct of an animal that has fasted for some time before being killed. It is a thin fluid, transparent and colourless, or occasionally of a pale yellow hue ; its taste is saline, its smell faint and scarcely perceptible, and its reaction alkaline. Sometimes the lymph has a decided red tint, of greater or less depth, which becomes brighter on exposure to the air. This redness is due to the presence of coloured corpuscles, like those of the blood : and it has been sometimes supposed, that such corpuscles exist naturally in the lymph, in greater or less quantity ; but they are more probably introduced into the lymphatic vessels accidentally. It can, in fact, be shown, that when an incision is made into a part, the blood very readily enters the lymphatics which are laid open, and passes along into larger trunks ; and in this way blood is conveyed into the thoracic duct, or any other large vessel, exposed as usual by incision immediately after the animal is killed. Indeed, mere rough handling of some organs, such as the liver and spleen, will rupture the fine vessels and cause the contents of the issuing lymphatics speedily to become red from admixture of blood.

The lymph, when examined with the microscope, is seen to consist of a clear liquid, with corpuscles floating in it. These "lymph-corpuscles," or lymph-globules, agree entirely in their characters with the pale corpuscles of the blood, which have been already described (page 23). It is alleged that some of the lymph corpuscles have a yellowish tint. Occasionally, smaller particles are found in the lymph ; also, but more rarely, a few oil globules of various sizes, as well as red blood-corpuscles, the presence of which has just been referred to.

The liquid part (lymph-plasma) bears a strong resemblance in its physical and chemical constitution to the plasma of the blood ; and accordingly, lymph fresh-drawn from the vessels coagulates after a few minutes' exposure, and separates after a time into clot and serum. This change is owing to the combination of the constituents of the fibrin contained in the lymph-plasma, and in this process most of the corpuscles are entangled in the coagulum. The serum, like the corresponding part of the blood, consists of water, albumin, extractive matters, fatty matters in very sparing quantity and salts. Sugar exists in small quantity in the lymph, and urea, in the proportion of from 0·01 to 0·02 per cent. ; leucin has also been found, at least in the lymphatic glands.

Human lymph has been obtained fresh from the living body in several instances, from lymphatic vessels, opened by wounds or other causes. It has been found to agree in all material points with the lymph of quadrupeds.

The **chyle** of man and mammiferous animals is an opaque, white fluid, like milk, with a faint odour and saltish taste, slightly alkaline or altogether neutral in its reaction. It has often a decided red tint, especially when taken from the thoracic duct. This colour, which is heightened by exposure to air, is doubtless generally due to the presence of blood-corpuscles, and may be explained in the same way as the occasional red colour of lymph.

Like blood and lymph, both of which fluids it greatly resembles in constitution, the chyle consists of a liquid holding small particles in suspension. These particles are, 1. *Corpuscles*, precisely like the lymph and pale blood-corpuscles already described. 2. *Molecules*, of almost immeasurably minute but remarkably uniform size. These abound in the fluid, and form an opaque white molecular matter diffused in it, which was named by Gulliver the *molecular base* of the chyle. The addition of ether instantly dissolves this matter, and renders the chyle nearly, but not quite, transparent; whence it may be inferred that the molecules are minute particles of fatty matter, and no doubt the chief cause of the opacity and whiteness of the chyle. According to the late H. Müller, they are each coated with a fine film of albuminoid matter. They exhibit the usual tremulous movement common to the molecules of many other substances. 3. *Oil-globules*; these are of various sizes, but much larger than the molecules above described, and are often found in the chyle in considerable numbers. 4. *Minute spherules* (Gulliver), from  $\frac{1}{24000}$  to  $\frac{1}{8000}$  of an inch in diameter; probably of an albuminous nature, and distinguished from the fatty molecules by their varying magnitude and their insolubility in ether.

The plasma, or liquid part of the chyle, contains fibrin, so that chyle coagulates on being drawn from the vessels, and nearly all the corpuscles, with part of the molecular base, are involved in the clot. The serum which remains resembles in composition the serum of lymph; the most notable difference between them being the larger proportion of fatty matter contained in the chyle-serum.

The following analyses of lymph and chyle exhibit the proportions of the different ingredients; but it must be explained that the amount of the corpuscles cannot be separately given, the greater part of them being included in the clot and reckoned as fibrin. No. 1 is the mean of two analyses, by Gubler and Quevenne, of human lymph taken during life from the lymphatics of the thigh; No. 2 the mean of three analyses by Gmelin of lymph from the thoracic duct of horses after privation of food; No. 3, by O. Rees, of chyle from the lacteals of an ass, after passing the mesenteric glands.

|                             | I.     | II.      | III.   |
|-----------------------------|--------|----------|--------|
| Water . . . . .             | 937.32 | 939.70   | 902.37 |
| Fibrin . . . . .            | 0.595  | 10.60    | 3.70   |
| Albumin . . . . .           | 42.775 | 38.83    | 35.16  |
| Fat . . . . .               | 6.51   | a little | 36.01  |
| Extractive matter . . . . . | 5.05   | 10.87    | 22.76  |
| Salts . . . . .             | 7.75   |          |        |
|                             | 1000.  | 1000.    | 1000.  |

The extractive matters of the chyle and lymph probably vary with the nature of the food: they generally contain sugar and urea in appreciable quantities.

The gas obtainable from lymph consists almost entirely of carbonic acid. From human lymph Hensen obtained 70 per cent. by volume, whilst in lymph from the dog, Ludwig and Hammarsten were unable to obtain more than about 40 per cent.

#### FORMATION OF THE CORPUSCLES OF THE LYMPH AND CHYLE.

The lymph-plasma appears to consist fundamentally of blood-plasma, which, having exuded from the capillary blood-vessels and yielded nutritive material to the tissues, is, with more or less admixture of waste products, returned by the lymphatics. Pale blood-corpuscles also, which have migrated from the vessels, may find their way into the beginning of the lymphatics. In this way the presence of corpuscles in the lymph even before it has passed through the lymphatic glands is accounted for. As to the further origin of the lymph and chyle corpuscles, it may, in the first place, be observed that the greatly increased proportion of these bodies in the vessels which issue from the lymphatic glands, and the vast store of corpuscles having the same characters contained in the interior recesses of these glands, are unmistakable indications that the glands are at least a principal seat of their production. They are, most probably, produced by division of parent corpuscles or cells contained in the glands, and in some measure also by further division of corpuscles thus produced, after they have made their way into the lymphatic vessels. The corpuscles found sparingly both in chyle and lymph before passing the mesenteric glands may be in part formed in the agminated and solitary follicular glands of the intestine—which, though differing much in form, yet in essential structure have much in common with the lymphatic glands—and may come partly also from the tracts of lymphoid tissue, which exist in the intestinal mucous membrane. Lymph-corpuscles are probably also produced in the spleen and in the thymus gland; they may also be formed by proliferation of connective tissue corpuscles, or even of the flattened cells of which the commencing lymphatic vessels are composed.

#### FORMATION OF THE BLOOD-CORPUSCLES.

**In the embryo of batrachians.**—In the early embryo of the frog and newt (in which, perhaps, the steps of the process are best ascertained), at the time when the circulation of the blood commences, the corpuscles in that fluid appear as rounded cells, filled with granular matter, and of larger average size than the future blood-corpuscles. The bodies in question, although spoken of as cells and presenting a regularly defined outline, have no separable envelope. They contain, concealed in the midst of the granular mass, a pellucid globular nucleus, which usually presents one or two small clear specks, situated eccentrically. The granular contents consist partly of fine molecules, exhibiting the usual molecular movements; and partly of little angular plates, or tablets, of a solid substance, probably of a fatty nature. After a few days, most of the cells have assumed an oval figure, and are somewhat reduced in size; and the granular matter is greatly diminished in quantity, so that the nucleus is conspicuous. Now, also, the blood-corpuscles, previously colourless, have acquired a yellowish or faintly red colour. In a further stage, the already oval cell is flattened, the granules entirely disappear, the colour is more decided, and, in short, the blood-corpuscle acquires its permanent characters. From this description it will be seen that the blood-cells which first appear agree in nature with the embryonic cells (described at page 8), and they are, in all probability, produced by the process of segmentation. The different parts of the embryo in its early condition, the heart, for example, are for a time entirely composed of cells of the same kind, and all have probably a common origin.

It is possible that some, at least, of the red corpuscles of batrachians, originate in a similar manner (endogenously) to that immediately to be described in the bird and in mammalia. For developing blood-vessels of the tadpole's tail have been observed to contain blood-corpuscles before the establishment of a communication with the rest of the vascular system (Stricker).

**In the bird.**—In the egg of the bird, the first appearance of blood-corpuscles, as well as of blood-vessels, is seen in the blastoderm, or germinal membrane, a structure formed by the extension of the cicatricula, in the early stages of incubation. The commencing embryo, with its simple tubular heart, is seen in the middle of this circular membrane, and blood-vessels, containing blood-corpuscles, appear over a great part of its area. These first vessels, therefore, though connected with the heart, and intended to convey nutriment to the embryo, are formed in an exterior structure; but, in a somewhat later stage, blood-vessels and corpuscles are developed in various textures and organs within the body. The formation of blood-corpuscles in the middle layer of the blastoderm has been recently carefully investigated by Klein.\* He describes the blood-vessels of the embryo chick as originating in an endogenous manner in the interior of certain of the cells of the middle layer of the blastoderm. It would appear, first, that the nuclei of these cells become multiplied, and that then the protoplasm around each takes on a reddish colour, and, a cavity becoming formed within the mother-cell by the enlargement of a vacuole, the newly-formed, nucleated, red blood-corpuscles become free within the cavity thus produced (fig. 16). In other instances the cavity becomes first formed within the cell, which is considerably enlarged, and in the protoplasmic wall of which nuclei are embedded. From this wall, blood-corpuscles, both red and white, bud forth into the interior of the vesicle. The mother-cells send out processes which connect them with one another, and into these processes their cavities are eventually extended: in this way a system of blood-vessels containing blood is produced. According to Balfour † it is the nuclei themselves which become the coloured corpuscles, whilst the nucleoli within them develop into the so-called "nuclei" of the blood-corpuscles.

It is uncertain whether any of the primary red corpuscles are formed by direct transformation of embryonic cells, as described in the embryo of Batrachians. At the same time they agree with those cells in exhibiting amoeboid movements.

**In man and mammalia.**—In the embryo of man and mammalia the primitive red blood-corpuscles are nucleated spheroidal bodies, of much larger size than the future red disks. As to their origin nothing is certainly known: they are probably transformed embryonic cells. These large nucleated red and colourless corpuscles, continuing to increase in number, constitute the earliest, and, for a time, the only corpuscles in the embryo-vessels. But their multiplication is soon arrested, and a new epoch in blood-formation begins with the development of the liver. The blood which returns to the embryo charged with fresh material of nutrition from the maternal system, has then to pass, at first entirely afterwards in great part, through the vessels of the liver; and it would seem that henceforth colourless nucleated corpuscles are produced in that organ and poured abundantly into the general mass of blood by the hepatic veins. It is probable that the liver continues its hæmopoietic or blood-forming function throughout foetal life; but, in the meanwhile, the spleen and lymphatic system

Fig. 16

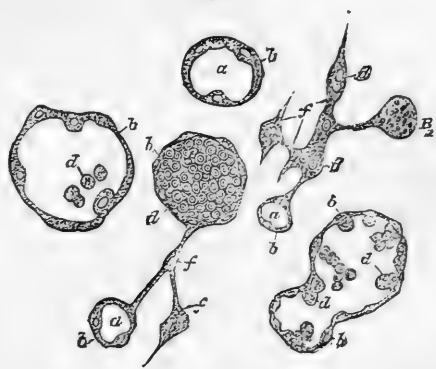

Fig. 16.—VARIOUS FORMS OF MOTHER-CELLS UNDERGOING DEVELOPMENT INTO BLOOD-VESSELS (from the middle layer of the chick's blastoderm. Klein.)

*d, d*, blood-corpuscles.

\* Wiener Sitzungsberichte, lxiii. 1871.

† Quarterly Journal of Microscopic Science. July, 1873.

have also begun to produce pale corpuscles, and in after periods supersede the liver in that office. These corpuscles, either immediately or after fissiparous multiplication, acquire colour like the first—those from the liver and spleen probably in great part before they leave these organs—and are converted into nucleated red corpuscles. The nucleated red corpuscles thus produced are gradually converted into, or at least succeeded by, smaller disk-shaped red corpuscles without nuclei, having all the characters of the blood-disks of the adult. This transition or substitution begins early, and proceeds gradually, until at length, long before the end of intrauterine life, the *nucleated* red corpuscles have altogether vanished.

The disk-shaped red corpuscles are produced, in part at least, in the interior of connective tissue cells of the developing mammal in a manner somewhat similar to that described by Klein in the cells of the middle layer of the chick's blastoderm. The cell-nuclei, however, are not involved in the process, which seems to be rather of the nature of a deposit within the cells. The blood-corpuscles which are at first spheroidal eventually take on the flattened form and become free within a cavity which is hollowed out in the interior of the cell; the latter becomes united with neighbouring cells to form the blood-vessels of the part. This endogenous mode of cell formation commonly ceases before birth.\*

Throughout life the mass of blood is subject to continual change; a portion of it is constantly expended, and its place taken by a fresh supply. It is certain that the corpuscles are not exempted from this general change, but it is not known in what manner they are consumed, nor has the process been fully traced by which new ones are continually formed to supply the place of the old. With regard to the latter question, it may be stated, that the explanation which has hitherto found most favour with physiologists is, that the corpuscles of the chyle and lymph, passing into the sanguiferous system, become the pale corpuscles of the blood; and that these last are converted into red disks. Pale corpuscles are also generated in the spleen, and, after part of them have changed into red disks, pass directly into the blood, independently of those derived from the chyle and lymph. A production of blood-corpuscles is also said to take place in certain cells of the marrow of the bones, in which transitional forms to the red corpuscles have been observed. (Neumann, Bizzozero.) As to the manner in which the pale corpuscles are transformed into the red, there is considerable difference of opinion. According to one view (adopted by Paget, Kölliker, Funke, and others), the pale corpuscles gradually become flattened, acquire coloured contents, lose their nuclei, and shrink somewhat in size, and thus acquire the characters of the red disks. Wharton Jones, on the other hand, arrived at the conclusion that, whilst in birds, reptiles, and fishes, the pale or lymph corpuscle, suffering merely some alteration of form and contents, becomes the red disk, its nucleus alone is developed into the red disk of mammalian blood. According to this view (supported by Busk, Huxley, and Gulliver), while the red corpuscle of oviparous vertebrata is the transformed pale corpuscle—its development not proceeding beyond this stage—the non-nucleated red disk of men and mammalia is, on the other hand, considered to be, not the homologue of the oval nucleated red disk of the oviparous vertebrata, but that of its nucleus. It is not within the scope of this work to enter upon a discussion of the relative merits of these opinions, and the reader is referred to physiological works for a consideration of these and other views adopted by various authors upon the point at issue.

### EPITHELIAL, EPIDERMIC, OR CUTICULAR TISSUE.

**General nature and situation.**—It is well known, that when the skin is blistered, a thin, and nearly transparent membrane, named the cuticle or epidermis, is raised from its surface. In like manner, a transparent film may be raised from the lining membrane of the mouth, similar in nature to the epidermis, although it has in this situation

\* Schäfer, Proceedings of the Royal Society. 1874.

received the name of "epithelium ;" \* and under the latter appellation, a coating of the same kind exists on nearly all free surfaces of the body. It is true that in many situations the epithelium cannot be actually raised from the adjacent surface as a coherent membrane, still its existence as a continuous coating can be demonstrated ; and, although in different parts it presents important differences, its several varieties are connected by certain common characters.

The existence of a cuticular covering composed of cells has in one form or other been demonstrated in the following situations : viz., 1. On the surface of the skin. 2. On mucous membranes; a class of membranes to be afterwards described, which line those internal cavities and passages of the body that open exteriorly, viz., the alimentary canal, the lachrymal, nasal, tympanic, respiratory, urinary, and genital passages ; as well as the various glandular recesses and ducts of glands, which open into these passages or upon the surface of the skin. 3. On the inner or free surface of serous membranes, which line the walls of closed cavities in the head, chest, abdomen, and other parts. 4. On the inner surface of the heart, blood-vessels and lymphatics.†

**Structure in general.**—This tissue has no vessels, although nerves have been demonstrated in it in various situations ; apart from these, however, it possesses a decidedly organised structure. Wherever it may exist, it is formed essentially of nucleated cells united together by cohesive matter, often in too small quantity to be apparent. The cells, where consisting of more than one layer, in whatever way they may be produced, make their appearance first in the deepest part of the structure, where they receive material for growth from the blood-vessels of the subjacent tissue ; then, usually undergoing considerable changes in size, figure, and consistency, they gradually rise to the surface, where, as shown at least in various important examples, they are thrown off and succeeded by others from beneath. In many situations the cells form several layers, in which they may be seen in different stages of progress, from their first appearance to their final desquamation. The layer or layers thus formed take the shape of the surface to which they are applied, following accurately all its eminences, depressions and inequalities. Epithelium when destroyed or cast off, is, for the most part, very readily regenerated.

**Varieties.**—In accordance with the varied purposes which the epithelium is destined to fulfil, the cells of which it is composed come to differ in different situations, in figure and size, in their position in respect of each other, their degree of mutual cohesion, and in the nature of the matter they contain, as well as in the vital endowments which they manifest ; and, founded on these modifications of its con-

\* The term "epithelia," which has passed into "epithelium," was introduced by Ruysch to designate the cuticular covering on the red part of the lips. The word "epidermis" he considered inappropriate, as the subjacent surface is not skin (*derma*) ; but, as it is beset with papillæ, he named the covering layer "epi-thelia," from  $\epsilon\pi\iota$  and  $\theta\eta\lambda\eta$ , a nipple or papilla. The use of the term has, by a not unusual license, been extended so as to signify the same kind of coating when it spreads over non-papillary surfaces. The word "endothelium," recently applied by some German writers to distinguish what has heretofore been spoken of as the epithelium lining the serous membranes, and the inner surface of blood-vessels and lymphatics, appears to me a needless innovation, and, considering the literal meaning of the word, not a happy one.—W. S.

† The flattened cells which are enumerated under 3 and 4, and which have a close affinity with the cells of the connective tissue to be afterwards described, may be conveniently distinguished by the term "epithelioid."

stituent cells, or, at any rate, those forming the superficial layer, four principal varieties of epithelium have been recognised, as follows :—

1. The cells may become flattened into plates or scales, and the variety of epithelial tissue thus constituted is termed *scaly*, or *tessellated* (*pavement epithelium* of German histologists). It might be well to employ the former term when the flattened cells overlap at their edges (as in fig. 17), the latter where the adjoining edges meet; in which case the lines of junction may be even (as in fig. 18), or more or less sinuous, as in various parts of the lymphatic system (fig. 19).

Fig. 17.

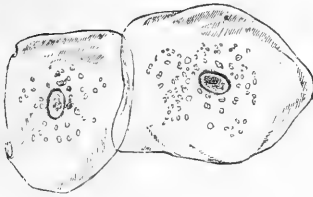


Fig. 18.

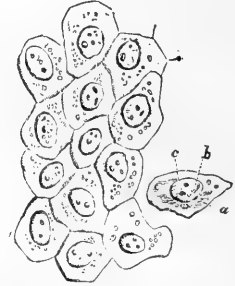


Fig. 17.—EPITHELIUM-SCALES FROM THE INSIDE OF THE MOUTH; MAGNIFIED 260 DIAMETERS (Henle).

Fig. 18.—EPITHELIOID CELLS FROM A SEROUS MEMBRANE (PERITONEUM); MAGNIFIED 410 DIAMETERS.

*a*, cell; *b*, nucleus; *c*, nucleoli (Henle).

2. In a second variety named *columnar* (cylinder-epithelium of the Germans) the cells assume a prismatic figure, and are set upright on the surface which they cover (fig. 20).

Fig. 19.

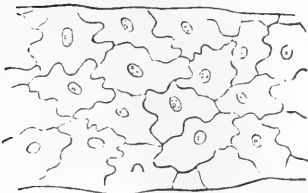


Fig. 20.

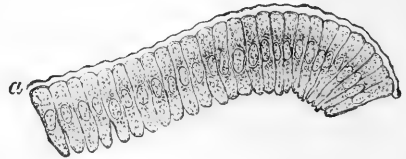


Fig. 19.—EPITHELIOID CELLS OF COMMENCING LYMPHATIC; MAGNIFIED 240 DIAMETERS (Auerbach).

Fig. 20.—COLUMNAR EPITHELIUM FROM INTESTINAL VILLUS OF A RABBIT; MAGNIFIED 300 DIAMETERS.

*a*, Thick border (from Kölliker).

3. The cells may retain their primitive roundness, or, being flattened where they touch acquire a polyhedral or cubical figure, in which no one dimension remarkably predominates: in some places, however, the cells show a tendency to lengthen into columns and in others to flatten into tables, presenting thus transitional forms between the other varieties. This variety of epithelium has been named *spheroidal* and *transitional*.

4. Lastly the cells, which in this case are mostly prismatic in form,



bear on their basal or free ends spontaneously moving filaments, named *cilia*; on which account this variety of epithelium is termed *ciliated* (fig. 21).

Fig. 21.

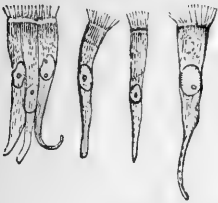


Fig. 21.—COLUMNAR CILIATED EPITHELIUM CELLS FROM THE HUMAN NASAL MEMBRANE; MAGNIFIED 300 DIAMETERS.

Fig. 22.

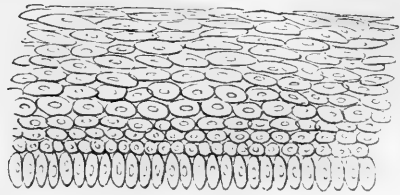


Fig. 22.—DIAGRAM OF SECTION OF STRATIFIED EPITHELIUM, IN WHICH THE UNDERMOST CELLS ARE OBLONG AND VERTICAL.

When the cells of an epithelium are arranged in several superimposed layers instead of being in a simple layer, it is termed *stratified*: in

Fig. 23.

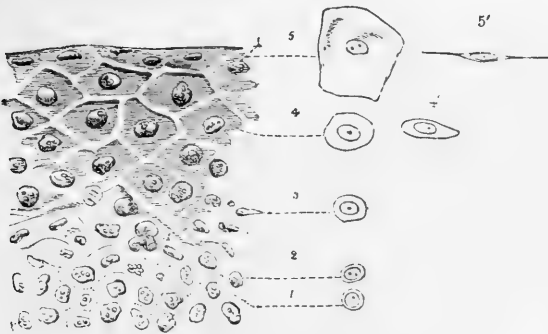


Fig. 23.—EPITHELIUM OF CONJUNCTIVA OF CALF.

1, 2, 3, 4, 5, progressive flattening of the cells as they rise to the surface. The outline figures represent single cells from different depths, viewed on their surface; and at 4' and 5', edgeways. Magnified 410 diameters (chiefly after Henle).

these cases it is commonly found that the lowermost layer is columnar in shape, and the uppermost scaly; the intermediate strata presenting transitions between these forms (figs. 22, 23).

The first three of the varieties here enumerated present local peculiarities which make it convenient to describe them with the tissues or organs with which they are associated. The ciliated epithelium, on the other hand, being of nearly uniform character as regards situation, vital properties and functional activity, can be most conveniently treated of under one general head, and will therefore be considered here.

It may first be remarked, however, that amidst these changes the nucleus of the cell undergoes little alteration, and its characters are accordingly remarkably uniform throughout (see figs.). It is round or oval, and more or less flattened; its diameter measures from  $\frac{1}{1000}$ th to  $\frac{1}{500}$ th of an inch, or more. Its substance is insoluble in acetic acid,

clear and colourless. It usually contains one or two nucleoli, distinguished by their strong dark outline; and a variable number of more faintly marked granules irregularly scattered. For the most part, the nucleus is persistent, but in some cases it disappears from the cell.

#### CILATED EPITHELIUM.

In this form of epithelium, the particles, which are generally columnar, bear at their free extremities little hair-like processes, which are agitated incessantly during life, and for some time after death, with a lashing or vibrating motion. These minute and delicate moving organs are named *cilia*. They have now been discovered to exist very extensively throughout the animal kingdom; and the movements which they produce are subservient to very varied purposes in the animal economy.

**Distribution and use.**—In the human body ciliated epithelium occurs in the following parts, viz.:—1. On the mucous membrane of the air passages and its prolongations. It commences at a little distance within the nostrils, covers the membrane of the nose (except the proper olfactory part) and of the adjoining bony sinuses, and extends up into the nasal duct and lachrymal sac. From the nose it spreads backwards a certain way on the upper surface of the soft palate, and over the upper or nasal region of the pharynx; thence along the Eustachian tube and lining membrane of the tympanum, of which it covers the greater part. The lower part of the pharynx is covered by scaly epithelium as already mentioned; but the ciliated epithelium begins again in the larynx a little above the glottis, and continues throughout the trachea and the bronchial tubes in the lungs to their smallest ramifications. 2. On the mucous lining and in the glands of the uterus, commencing at the middle of the cervix and extending along the Fallopian tubes, even to the peritoneal surface of the latter at their fimbriated extremities. 3. Lining the *vasa efferentia, coni vasculosi*, and first part of the excretory duct of the testicle. 4. To some extent on the parietes of the ventricles of the brain, and throughout the central canal of the spinal cord. 5. In the excretory ducts of certain small racemose glands of various parts (tongue, pharynx, &c.).

In other mammiferous animals, as far as examined, cilia have been found in nearly the same parts. To see them in motion, a portion of ciliated mucous membrane may be taken from the body of a recently killed quadruped. The piece of membrane is to be folded with its free or ciliated surface outwards, placed on a slip of glass, with a little weak salt water or serum of blood, and covered with thin glass. When it is now viewed with a magnifying power of 200 diameters or upwards, a very obvious agitation will be perceived on the edge of the fold; this appearance is caused by the moving cilia, with which the surface of the membrane is covered. Being set close together, and moving simultaneously or in quick succession, the cilia, when in brisk action, give rise to the appearance of a bright transparent fringe along the fold of the membrane, agitated by such a rapid and incessant motion, that the single threads which compose it cannot be perceived. The motion here meant, is that of the cilia themselves; but they also set in motion the adjoining fluid, driving it along the ciliated surface, as is indicated by the agitation of any little particles that may accidentally float in it.

The fact of the conveyance of fluids and other matters along the ciliated surface, as well as the direction in which they are impelled, may also be made manifest by immersing the membrane in fluid, and dropping on it some finely pulverised substance (such as charcoal in fine powder), which will be slowly but steadily carried along in a constant and determinate direction; and this may be seen with the naked eye, or with the aid of a lens of low power.

The ciliary motion of the human mucous membrane is beautifully seen on the surface of recently extracted nasal polypi; and single ciliated particles, with their cilia still in motion, are sometimes separated accidentally from mucous surfaces in the living body, and may be discovered in the discharged mucus; or they may even be purposely detached by gentle abrasion. But the extent and limits of the ciliated epithelium of the human body have been determined chiefly from its anatomical characters.

Cilia have now been shown to exist in almost every class of animals, from the highest to the lowest. The immediate purpose which they serve is, to impel matter, generally more or less fluid, along the surfaces on which they are attached; or, to propel through a liquid medium the ciliated bodies of minute animals, or other small objects on the surface of which cilia are present; as is the case with many infusorial animalcules, in which the cilia serve as organs of locomotion like the fins of larger aquatic animals, and as happens, too, in the ova of many vertebrate as well as invertebrate animals, where the yolk revolves in its surrounding fluid by the aid of cilia on its surface. In many of the lower tribes of aquatic animals, the cilia acquire a high degree of importance: producing the flow of water over the surface of their organs of respiration, indispensable to the exercise of that function; enabling the animals to seize their prey, or swallow their food, and performing various other offices of greater or less importance in their economy. In man, and the warm-blooded animals, their use is apparently to impel secreted fluids or other matters along the ciliated surface, as, for example, the mucus of the windpipe and nasal sinuses, which they carry towards the outlet of these cavities.

**Structure.**—The cells of the ciliated epithelium (fig. 24) contain clear oval nuclei; their protoplasm is commonly granular, but the free border of the cell from which the cilia appear to spring presents a bright appearance (fig. 21). They have most generally an elongated form,

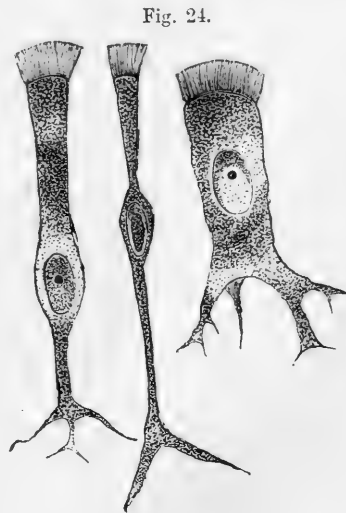


Fig. 24.—CILIATED EPITHELIUM CELLS FROM TRACHEA OF CAT; MAGNIFIED ABOUT 600 DIAMETERS (Klein).

like the particles of the columnar

epithelium, which they resemble too in arrangement, but are often of greater length and more slender and pointed at their lower end, which is commonly branched. The cilia are attached to their broad or superficial end, each columnar particle bearing a tuft of these minute hair-like processes. In some cases, the cells are spheroidal in figure, the cilia being still, of course, confined to that portion of the cell which forms part of the general surface of the epithelial layer, as shown in fig. 25, which presents such cells from

Fig. 25.

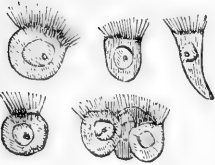


Fig. 25. — SPHEROIDAL CILIATED CELLS FROM THE MOUTH OF THE FROG; MAGNIFIED 300 DIAMETERS.

the epithelium of the frog's mouth. In man this form occurs in the ciliated epithelium of the cerebral ventricles and tympanum, where the cells form but a single stratum. The columnar ciliated epithelium also may exist as a simple layer, as in the uterus and Fallopian tubes, the finest ramifications of the bronchia, and the central canal of the spinal cord; but in various other parts—as the nose, pharynx, Eustachian tube, the trachea and its larger divisions—there is a layer of elongated cells beneath the superficial ciliated range, filling up the spaces between the pointed extremities of the latter, and beneath this is an undermost layer, formed of small rounded cells. Probably the

subjacent cells acquire cilia, and take the place of ciliated cells, which are cast off; but the mode of renovation of ciliated epithelium is not yet fully understood.

The relation of the ciliated, as well as other epithelium-cells, to the connective tissue of the subjacent membrane, has much engaged attention since the importance of the connective-tissue-corpuscles has come to be recognised; and a strong impression or belief prevails that such epithelium-cells are structurally connected by prolongations from their lower ends with these corpuscles, and genetically related to them. As a matter of observation, such anatomical connection is affirmed in reference to the columnar ciliated epithelium of the central canal of the spinal cord and the Sylvian aqueduct, (Lockhart Clarke, Gerlach).

The cilia themselves differ widely in size in different animals, and they are not equal in all parts of the same animal. In the human windpipe they measure  $\frac{1}{5000}$ th to  $\frac{1}{2500}$ th of an inch in length; but in many invertebrate animals, especially such as live in salt water, they are a great deal larger. In figure they have the aspect of slender, conical, or slightly flattened filaments; broader at the base, and usually pointed at their free extremity. Their substance is transparent, soft, and flexible. It is to all appearance homogeneous, and no fibres, granules, or other indications of definite internal structure, have been satisfactorily demonstrated in it.

**Motion of the cilia.**—The manner in which the cilia move, is best seen when they are not acting very briskly. Most generally they seem to execute a sort of fanning or lashing movement; and when a number of them perform this motion in regular succession, as is generally the case, they give rise to the appearance of a series of waves travelling along the range of cilia, like the waves caused by the wind in a field of corn. When they are in very rapid action the undulation is less obvious, and, as Henle remarks, their motion then conveys the idea of swiftly running

water. The undulating movement may be beautifully seen on the gills of a mussel. The undulations, with some exceptions, seem always to travel in the same direction on the same parts. The impulsion, also, which the cilia communicate to the fluids or other matters in contact with them, maintains a constant direction; unless in certain of the infusoria, in which the motion is often variable and arbitrary in direction, and has even been supposed to be voluntary. Thus in the wind-pipe of mammalia, the mucus is conveyed upwards towards the larynx, and, if a portion of the membrane be detached, matters will still be conveyed along the surface of the separated fragment in the same direction relatively to that surface, as before its separation.

The persistence of the ciliary motion for some time after death, and the regularity with which it goes on in parts separated from the rest of the body, sufficiently prove that, with the possible exceptions alluded to, it is not under the influence of the will of the animal nor dependent for its production on the nervous centres, and it does not appear to be influenced in any way by stimulation or sudden destruction of these centres. The time which it continues after death or separation differs in different kinds of animals, and is also materially influenced by temperature and by the nature of the fluid in contact with the surface. In warm-blooded animals the period varies from two or three hours to two days, or even more; being longer in summer than in the cold of winter. In frogs the motion may continue four or five days after the destruction of the brain; and it has been seen in the gullet of the tortoise fifteen days after decapitation, continuing seven days after the muscles had ceased to be irritable.

With the view of throwing further light on the nature of this remarkable kind of motion, experiments have been made to ascertain the effect produced on it by different physical, chemical, and medicinal agents; but, so far as these experiments have gone, it would seem that, with the exception of moderate heat and cold, alkaline solutions, chloroform vapour, and perhaps some other narcotics, these agents affect the action of the cilia only in so far as they act destructively on their tissue.

The effect of change of temperature is different in warm and in cold-blooded animals. In the former the motion is stopped by a cold of 43° F., whereas in the frog and river-mussel it goes on unimpaired at 32° F. E. H. Weber made the interesting observation that, in ciliated epithelium particles detached from the human nasal membrane, the motion which has become languid or quiescent from the cold may be revived by warmth, such as that of the breath, and this several times in succession. A moderately elevated temperature, say 100° F., does not affect the motion in cold-blooded animals; but, of course, a heat considerably higher than this and such as to alter the tissue, would put an end to it in all cases. Electric shocks, unless they cause abrasion of the ciliated surface (which is sometimes the case), produce no visible effect; and the same is true of galvanic currents. Fresh water arrests the motion in marine mollusca and in other salt-water animals; but it evidently acts by destroying both the form and substance of the cilia, which in these cases are adapted to a different medium. Most of the common acid and saline solutions, when concentrated, arrest the action of the cilia instantaneously in all animals; but dilution delays this effect, and when carried farther, prevents it altogether; and hence it is, probably, due to a chemical alteration of the tissue. Virchow has observed that a solution of either potash or soda will revive the movement of cilia after it has ceased. Narcotic substances, such as hydrocyanic acid, salts of morphia and strychnia, opium and belladonna, are said by Purkinje and Valentin to have no effect, though the

first-named agent has certainly appeared to us to arrest the motion in the river-mussel. In confirmation of an observation of Lister,\* we find that exposure for a few moments to the vapour of chloroform arrests ciliary action, and that the motion revives again if the application of the vapour is discontinued.

Bile stops the action of the cilia, while blood prolongs it in vertebrated animals; but the blood or serum of the vertebrata has quite an opposite effect on the cilia of invertebrate animals, arresting their motion almost instantaneously.

Whatever views may be entertained concerning the nature and source of the power by which the cilia act, it must be borne in mind that each ciliated cell is individually endowed with the faculty of producing motion, and that it possesses in itself whatever organic apparatus and whatever physical or vital property may be necessary for that end; for single epithelium cells are seen to exhibit the phenomenon long after they have been completely insulated.

It seems not unreasonable to consider the ciliary motion as a manifestation of that property on which the more conspicuous motions of animals are known to depend, namely, vital contractility; and this view has at least the advantage of referring the phenomenon to the operation of a vital property already recognised as a source of moving power in the animal body. But, assuming this view to be sound, so far as regards the nature of the motile property brought into play, it affords no explanation of the cause by which the contractility is excited and the cilia maintained in constant action.

It is true that nothing resembling a muscular apparatus in the ordinary sense of the term, has been shown to be connected with the cilia, nor is it necessary to suppose the existence of any such; for it must be remembered that, while the organic substance on which vital contractility depends is probably uniformly the same in composition, it does not everywhere assume the same form and texture. The anatomical characters of human voluntary muscle differ widely from those of most involuntary muscular structures, and still more from the contractile tissues of some of the lowest invertebrate animals, although the movements must in all these cases be referred to the same principle. The heart of the embryo beats while yet but a mass of cells, united, to all appearance, by amorphous matter, in which no fibres are seen; yet no one would doubt that its motions depend then on the same property as at a later period, when its structure is fully developed.

In its persistence after systemic death and in parts separated from the rest of the body, the ciliary motion agrees with the motion of certain muscular organs, as the heart, for example; and the agreement extends even to the regular or rhythmic character of the motion in these circumstances. It is true, the one endures much longer than the other; but the difference appears to be one only of degree, for similar differences are known to prevail among muscles themselves. No one, for instance, doubts that the auricle of the heart is muscular, because it beats longer after death than the ventricle; nor, because a frog's heart continues to act a much longer time than a quadruped's, is it inferred that its motion depends on a power of a different nature. And the view here taken of the nature of the ciliary motion derives strength from the consideration that the phenomenon lasts longest in cold-blooded animals, in which vital contractility also is of longest endurance. In the effects of heat and cold, as far as observed, there is also an agreement between the movement of cilia and that of muscular parts; while, on the other hand, it must be allowed that electricity does not appear to excite their activity. The effects of narcotics afford little room for inference, seeing that our knowledge of their local action on muscular irritability is by no means exact; but in one instance, at least, an agent, chloroform vapour, which stops the action of the freshly excised heart of a frog, arrests also

\* Phil. Trans. 1858, p. 690, where will be found other valuable observations on the effect of external agents on ciliary action.

the ciliary motion. Something, moreover, may depend on the facility or difficulty with which the tissues permit the narcotic fluid to penetrate, which circumstance must needs influence the rapidity and extent of its operation. Again, we see differences in the mode in which the cilia themselves are affected by the same agent; thus, fresh water instantly arrests their motion in certain cases, while it has no such effect in others.

The existence of vibrating cilia on the spores and other parts of certain cryptogamic vegetables may perhaps be considered to afford an argument on the opposite side; but it is by no means proved that the sensible motions of plants (such, at least, as are not purely physical), and those of animals, do not depend on one common vital property.

## PIGMENT.

The cells of the cuticle, and of other epithelial structures, sometimes contain a black or brown matter, which gives a dark colour to the parts over which the cells are spread. A well-marked example of such pigmented cells in the human body is afforded by the black coating which lines the choroid membrane of the eye, and covers the posterior surface of the iris. Pigment is also met with in certain cells of the investing membrane (pia mater) of the spinal cord, in the membranous labyrinth of the ear, and (with brownish yellow pigment) on the olfactory region of the nose.

The pigment, strictly so called, which is contained within the cells, consists of black or brown granules or molecules of a round or oblong shape, and almost too small for exact measurement. These molecules are densely packed together in some cells; in others they are more scattered, and then it may be seen that there is a certain amount of colourless matter included along with them. When they escape from the ruptured cells, they exhibit very strikingly the "Brownian" molecular movement; and in consequence of this movement the apparent figure of the particles is subject to change. It is worthy of remark, that when viewed singly with a very high magnifying power they look transparent and almost colourless, and it is only when they are heaped together that their blackness distinctly appears. The nucleus is colourless, but is very generally hidden from view by the black particles.

The dark colour of the negro is known to have its seat in the cuticle, and chiefly in the deeper and softer part named the rete mucosum. It is caused by dark-brown colouring matter within the cells, either diffused through their substance or in form of granules—usually more densely aggregated round the nucleus. The dark parts of the European skin owe their colour and its different shades to the presence of pigment granules in the cells in different proportions. Lastly, it cannot be

Fig. 26.

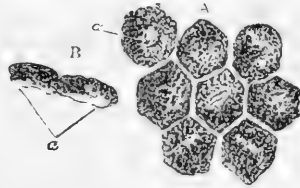


Fig. 26.—PIGMENTED EPITHELIUM CELLS FROM THE CHOROID; MAGNIFIED 370 DIAMETERS (Henle).

A, cells still cohering, seen on their surface; a, nucleus indistinctly seen. In the other cells the nucleus is concealed by the pigment granules.

B, two cells seen in profile; a, the outer or posterior part containing scarcely any pigment.

doubted, that in both the coloured and white races, the colouring matter of the skin is the same in its essential nature as that of the choroid. In Albino individuals, both negro and European, in whom the black matter of the choroid is wanting, the cuticle and the hair are colourless also.

Fig. 27.

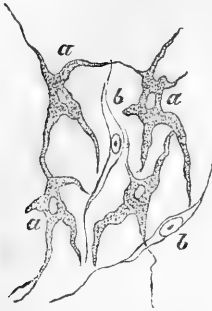


Fig. 27.—RAMIFIED CELLS, FROM THE TISSUE OF THE CHOROID COAT OF THE EYE; MAGNIFIED 350 DIAMETERS (Kölliker).

*a*, cells with pigment;  
*b*, colourless fusiform cells.

In some situations the pigment is met with in enlarged and irregularly branched corpuscles which belong to the connective tissue. Such ramified cells are very common in many animals. In the human body cells of this description are found in the dark tissue on the outer surface of the choroid coat, *lamina fusca* (fig. 27, *a a*), and on the pia mater covering the upper part of the spinal cord. The condition of the pigment in the hairs will be afterwards noticed.

When the cuticle of the negro is removed by means of a blister, it is renewed again of its original dark hue; but if the skin be destroyed to any considerable depth, as by a severe burn, the resulting scar remains long white, though it at length acquires a dark colour.

**Composition.**—Examined chemically, the black matter is found to be insoluble in cold and hot water, alcohol, ether, fixed and volatile oils, acetic and diluted mineral acids. The pigment of the bullock's eye, when purified by boiling in alcohol and ether, was found by Scherer to consist of 58.672 carbon, 5.962 hydrogen, 13.768 nitrogen, and 21.598 oxygen; its proportion of carbon is thus very large. Preceding chemists had obtained from its ashes oxide of iron, chloride of sodium, lime, and phosphate of lime.

**Uses.**—In the eye the black matter seems obviously intended to absorb redundant light, and accordingly its absence in Albinos is attended with a difficulty of bearing a light of considerable brightness. Its uses in other situations are not so apparent. The pigment of the cuticle, it has been supposed, may screen the subjacent cutis from the pungency of the sun's rays, but in many animals the pigment is not only employed to variegate the surface of the body, but attaches itself to deep-seated parts. Thus, in the frog the branches and twigs of the blood-vessels are speckled over with it, and in many fish it imparts a black colour to the peritoneum and other internal membranes.

## CONNECTIVE TISSUE.

This substance consists of fibres of two kinds, more or less amorphous matter, and peculiar corpuscles. By means of its fibres it serves in the animal body as a bond of connection of different parts; also as a covering or investment to different organs, not only protecting them outwardly, but, in many cases entering into their structure and connecting and supporting their component parts. The corpuscles, on the other hand, are destined for other than mechanical purposes; they appear to be essentially concerned in the nutrition and reparation of tissues.

Three principal modifications or varieties of connective tissue have long been recognised, consisting of the same structural elements, but in widely different proportions, and thereby exhibiting a difference in their grosser or more obvious characters and physical properties. They are



known as the *areolar* (including the fat), the *fibrous*, and the *elastic* tissues, and will be now severally treated of. Without disregarding the alliance of cartilage and bone to the connective tissues, we shall not, in imitation of some respected authorities, include them in the same group; but there remain certain forms of tissue, occurring locally, or met with as constituents of other textures, which properly belong to this head, and will be briefly considered in a separate section as subordinate varieties of connective tissue.

Cartilage and bone are included in the group of connective tissues or connective substances by several eminent German histologists, and present undoubted points of relationship with these tissues, both in their nature and the general purpose which they serve in the animal frame. Thus, yellow cartilage shows an unmistakable transition to elastic connective tissue, as fibro-cartilage does, even more decidedly, to white fibrous tissue. Moreover, the animal basis of bone agrees entirely in chemical composition, and in many points of structure, with the last-named tissue. Still, when it is considered that cartilage, in its typical form, consists of a quite different chemical substance, chondrin, and that bone is characterised by an impregnation of earthy salts, it seems more consistent with the purpose of histological description to recognise cartilage and bone as independent tissues. As to their community of origin, little stress need be laid on it as a basis of classification, seeing that the origin of blood-vessels, nerves, and muscles, may be traced up to protoplasm-cells, to all appearance similar to those that give rise to the connective tissues, and belonging to the same embryonic layer.

#### THE AREOLAR TISSUE.

**Distribution and arrangement.**—If we make a cut through the skin and proceed to raise it from the subjacent parts, we observe that it is loosely connected to them by a soft filamentous substance, of considerable tenacity and elasticity, and having, when free from fat, a white fleecy aspect; this is the substance known by the names of “cellular,” “areolar,” “filamentous,” “connective,” and “reticular” tissue; it used formerly to be commonly called “cellular membrane.” In like manner the areolar tissue is found underneath the serous and mucous membranes which are spread over various internal surfaces, and serves to attach those membranes to the parts which they line or invest; and as under the skin it is named “subcutaneous,” so in the last-mentioned situations it is called “subserous” and “submucous” areolar tissue. But on proceeding further we find this substance lying between the muscles, the blood-vessels, and other deep-seated parts, occupying, in short, the intervals between the different organs of the body where they are not otherwise insulated, and thence named “intermediate;” very generally, also, it becomes more consistent and membranous immediately around these organs, and, under the name of the “investing” areolar tissue, affords each of them a special sheath. It thus forms inclosing sheaths for the muscles, the nerves, the blood-vessels, and other parts. Whilst the areolar tissue might thus be said in some sense both to connect and to insulate entire organs, it also performs the same office in regard to the finer parts of which these organs are made up; for this end it enters between the fibres of the muscles, uniting them into bundles; it connects the several membranous layers of the hollow viscera, and binds together the lobes and lobules of many compound glands; it also accompanies the vessels and nerves within these organs, following their branches nearly to their finest divisions, and affording them support and protection. This portion

of the areolar tissue has been named the "penetrating," "constituent," or "parenchymal."

It thus appears that the areolar is one of the most general and most extensively distributed of the tissues. It is, moreover, continuous throughout the body, and from one region it may be traced without interruption into any other, however distant; a fact not without interest in practical medicine, seeing that in this way dropsical waters, air, blood, and urine, effused into the areolar tissues, and even the matter of suppuration, when not confined in an abscess, may spread far from the spot where they were first introduced or deposited.

On stretching out a portion of areolar tissue by drawing gently asunder the parts between which it lies, it presents an appearance to the naked eye of a multitude of fine, soft, and somewhat elastic threads, quite transparent and colourless, like spun glass; these are intermixed with fine transparent films, or delicate membranous laminae, and both threads and laminae cross one another irregularly and in all imaginable directions leaving open interstices or areolae between them. These meshes are, of course, more apparent when the tissue is thus stretched out; it is plain also that they are not closed cells, as the term "cellular tissue" might seem to imply, but merely interspaces, which open freely into one another: many of them are occupied by the fat, which, however, does not lie loose in the areolar spaces, but is enclosed in its own vesicles. A small quantity of colourless transparent fluid is also present in the areolar tissue, but, in health, not more than is sufficient to moisten it. This fluid is generally said to be of the nature of serum; but it is not improbable that, unless when unduly increased in quantity or altered in nature by disease, it may resemble more the liquor sanguinis, as is the case with the fluid of most of the serous membranes.

On comparing the areolar tissue of different parts, it is observed in some to be more loose and open in texture, in others more dense and close, according as free movement or firm connection between parts is to be provided for. In some situations, too, the laminae are more numerous; in others the filamentous structure predominates, or even prevails exclusively; but it does not seem necessary to designate these varieties by particular names, as is sometimes done.

**Fibres.**—When examined under the microscope, the areolar tissue is seen to be principally made up of exceedingly fine, transparent, and apparently homogeneous filaments, from about  $\frac{1}{300000}$ th to  $\frac{1}{250000}$ th of an inch in thickness, or even less (fig. 28). These are seldom single, being mostly united by means of a small and usually imperceptible quantity of a homogeneous connecting substance into bundles and filamentous laminae of various sizes, which to the naked eye, appear as simple threads and films. Though the bundles may intersect in every direction, the filaments of the same bundle run nearly parallel to each other, and no one filament is ever seen to divide into branches or to unite with another. The associated filaments take an alternate bending or waving course as they proceed along the bundle, but still maintain their general parallelism. This wavy aspect, which is very characteristic of these filaments, disappears on stretching the bundle, but returns again when it is relaxed.

The filaments just described, though transparent when seen with transmitted light under the microscope, appear white when collected in considerable quantity and seen with reflected light; and they

not only occur in the areolar tissue strictly so called, but form the chief part of the tendons, ligaments, and other white fibrous connective tissues. They were long supposed to be the only fibrous constituent existing in the areolar tissue, but it is now well known that fibres of another kind are intermixed with them; these agree in all characters and are obviously identical with the fibres of the yellow elastic tissue, and have accordingly been named the yellow or elastic fibres, to distinguish them from the white or waved filaments above described.

Fig. 28.

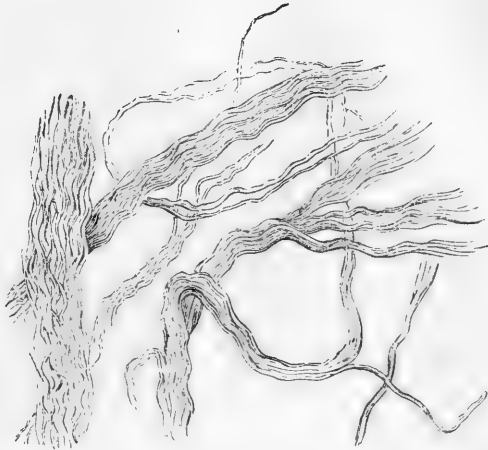

Fig. 28. — FILAMENTS OF AREOLAR TISSUE, IN LARGER AND SMALLER BUNDLES, AS SEEN UNDER A MAGNIFYING POWER OF 400 DIAMETERS.

In certain portions of the areolar tissue, as for instance in that which lies under the serous and mucous membranes of particular regions, the yellow or elastic fibres are abundant and large, so that they cannot well be overlooked; but in other parts they are few in number, and small, and are then in a great measure hidden by the white filaments; in such cases, however, they can always be rendered conspicuous under the microscope by means of acetic acid, which causes the white filaments to swell up and become indistinct, whilst the elastic fibres, not being affected by that re-agent, come then more clearly into view (fig. 29). Moreover, they resist the action of boiling alkaline solutions of potash and soda, of moderate strength, which very speedily destroy the rest of the tissue. Under the

Fig. 29.

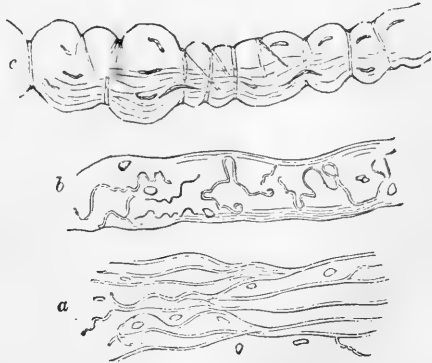


Fig. 29. — MAGNIFIED VIEW OF AREOLAR TISSUE (FROM DIFFERENT PARTS) TREATED WITH ACETIC ACID.

The white filaments are no longer seen, and the yellow or elastic fibres with the nuclei come into view. At *c*, a bundle of white fibres, which is swollen out by the effect of the acid, and presents a number of constricting bands as described in the text.

microscope the elastic fibres appear transparent and colourless, with a strong, well-defined, dark outline. They are further remarkable for their tendency to curl up, especially at their broken ends, which gives them a very peculiar aspect; and in many parts of the areolar tissue they divide into branches and join or anastomose with one another, in the same manner as in the pure elastic tissue (*a*). They differ among themselves very widely in size, some being as fine as the white filaments, others many times larger.

The elastic fibres lie, for the most part, without order, among the bundles of white filaments; but here and there we see what appears to be an elastic fibre winding round one of these bundles, and encircling it with several spiral turns. When acetic acid is applied, the fasciculus swells out between the constricting turns of the winding fibre, and presents a highly characteristic appearance (*c*). This remarkable disposition of the elastic fibres, which was pointed out by Henle, is not uncommon in certain parts of the areolar tissue; it may be always seen in that which accompanies the arteries at the base of the brain. It must be observed, however, that the encircling fibre sometimes forms not a continuous spiral, but several separate rings; moreover, the whole appearance may be explained on the supposition that the bundles in question are naturally invested with a delicate sheath, which, like the elastic tissue, resists acetic acid, but, on the swelling up of the bundle under the operation of that agent, is rent into shreds or segments, mostly annular or spiral, which cause the constrictions. Indeed, some bundles have been shown to possess such a sheath, made up of flattened

cells (Ranvier, Key and Retzius). Moreover, the union of branches of the corpuscles (to be immediately noticed) around a bundle may, in some instances, be the cause of the appearance (Kölliker).

A very different view of the structure of areolar tissue from that here stated was taken by Reichert, and adopted by Virchow, Donders, and other distinguished histologists. According to this view the apparent bundles consist of a substance in reality amorphous or homogeneous, and its seeming fibrillation is partly artificial, the result of cleavage, and partly an optical illusion, arising from creasing or folding. In point of fact, however, the bundles readily separate into fibrils after exposure to dilute solutions of chromic acid, or to lime-water, or to baryta-water, by which the uniting matter is dissolved; so that there can be no doubt of their truly fibrillar structure. At the same time it is not denied that immature fasciculi may probably occur, in which the fibrillation is incomplete.

Fig. 30.

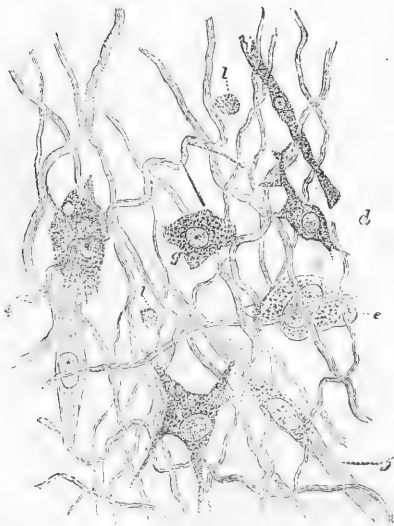


Fig. 30.—CELLS FROM SUBCUTANEOUS CONNECTIVE TISSUE OF YOUNG GUINEA-PIG. MAGNIFIED 350 DIAMETERS.

*a*, branched corpuscle; *c*, flattened corpuscle; *g*, granular corpuscle; *f*, fibrillated cell; *l*, *l*, leucocytes or migratory cells.

**Ground-substance and Corpuscles.**—The fibrils are, as before said, united into the

small bundles and laminae which are visible to the naked eye by means of a variable amount of homogeneous cementing matter or

ground-substance, which also covers the surface of the bundles. In this substance lie the cellular elements of the tissue, the *connective-tissue corpuscles* (figs. 30, 31). These bodies, which are of a protoplasmic nature, are commonly of a flattened form and not unfrequently have processes which ramify in the tissue and may anastomose with branches from neighbouring corpuscles (fig. 31). The cells have each a clear round or oval nucleus, containing one or more nucleoli: occasionally two nuclei are to be seen in a cell. Besides presenting considerable variations in size and shape the corpuscles also exhibit differences in the character of their protoplasm (see fig. 30), which in some is coarsely granular in appearance, in others finely granular, or even perfectly clear and pellucid, with a few coarse granules scattered in it here and there, whilst in others again there is a distinct appearance of striation or fibrillation within the cell; but these differences have hardly as yet been sufficiently investigated.

The cells (with their processes) occupy spaces in the ground-substance which they more or less completely fill, and which therefore closely correspond to the corpuscles themselves in size and form, and in their branching and intercommunication. These *cell-spaces* (Saftcänälchen, Recklinghausen) are brought into view by treating the tissue with a solution of nitrate of silver and subsequently exposing it to the light, by

which the ground-substance and fibrils of the tissue are stained of a uniform brown tint, whereas the protoplasm of the cells remains unstained, and the cell-spaces consequently appear white (fig. 32).\*

\* In the case of the pigment-cells of the frog's skin previously noticed (pp. 12, 13), it is probable that the clear, branched figure which remains after the shrinking of the pigmented matter, is the outline of the *cell-space*, which was previously filled by the cell-substance. (Sharpey.)

Fig. 31.



Fig. 31.—RAMIFIED CONNECTIVE-TISSUE CORPUSCLES FROM SYNOVIAL MEMBRANE. 250 DIAMETERS.

Fig. 32.

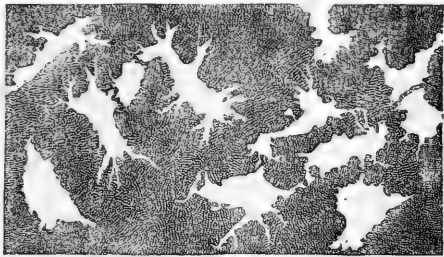


Fig. 32.—CELL-SPACES OF SUBCUTANEOUS CONNECTIVE-TISSUE, NITRATE OF SILVER PREPARATION. 340 DIAMETERS.

In some parts of the tissue, and especially on the surface of the laminae, patches of cells are here and there to be found which present an epithelioid appearance in silver preparations, the cells being much flattened, and joined edge to edge, with but a small amount of intercellular or ground substance between them, like the layer on the inner surface of a serous membrane. The cells at the margin of such a patch, however, commonly have processes at their free border, and every transition is found between these epithelioid cells and the ordinary branched and irregular cells of the tissue.

Corpuscles of a fusiform shape are not so common in the adult as was at one time supposed; the appearance being generally produced by flattened cells seen edgewise.

The connective-tissue corpuscles are for the most part considerably larger than the pale blood-corpuscles (which are also to be found in the tissue (fig. 30, *l*), having probably escaped from the vessels), and do not, like these, exhibit active movements of locomotion, the motions which have been observed in them consisting merely of slow protrusion and retraction of processes or straining movements of the protoplasm composing them.

**Vessels and Nerves.**—Numerous *blood-vessels* are seen in the areolar tissue after a minute injection. These for the most part only pass through it on their way to other more vascular textures, but a few seem to end in capillaries destined for the tissue itself, and dense clusters of vessels are distributed to the fat-lobules. Large *lymphatic* vessels proceeding to distant parts also pass along this texture, and abundant lymphatic networks may be discovered in many parts of the subcutaneous, subserous, and submucous areolar tissue, having evident relation to the function of the membranes under which they lie. A close connection subsists between the cells of the areolar tissue and the commencements of the lymphatics; for the flattened cells which form the walls of the latter vessels are in contact with, and pass into, the connective-tissue corpuscles of the tissue in which they lie. In this manner the cell-spaces of the connective tissue are brought into intimate relation with the lymphatics, and the latter vessels may, in a certain sense, be described as originating in the net-work of cell-spaces which the tissue commonly contains. Absorption readily takes place from the interstices of the texture, but that process may be effected through the agency of blood-vessels as well as of lymphatics.

Larger and smaller branches of *nerves* also traverse this tissue on their way to other parts; but it has not been shown that any remain in it, and accordingly it may be cut in a living animal apparently without giving pain, except when the instrument meets with any of these traversing branches. It is not improbable, however, that nerves end in those parts of the areolar tissue, which, like that of the scrotum, contain contractile fibres; but, if present in such cases, the nerves, like the vessels of the fat, are, after all, destined not to the areolar tissue but to another mixed with it.

**Composition and Properties.**—The areolar tissue contains a considerable quantity of water, and consequently loses much of its weight by drying. It is almost wholly resolved into gelatin by boiling in water. Acetic acid causes it, that is, the bundles of white fibrils, to swell up into a soft, transparent, jelly-like mass; but the original condition may be restored by a solution of an alkaline carbonate.

The physical properties of this texture have been sufficiently indicated in the foregoing description; also its want of sensibility. The vital contractility ascribed to certain portions of it is most probably due to the presence of muscular tissue.

**Regeneration.**—With the exception of the epithelium, no tissue is so readily regenerated as the areolar. It is formed in the healing of wounds and in the adhesion of inflamed surfaces. It is produced also in many morbid growths.

#### ADIPOSE TISSUE.

The human body in the healthy state contains a considerable amount of fatty matter of different kinds. Fat, as has been already stated, is found in the blood and chyle, and in the lymph, but much more sparingly. It exists, too, in several of the secretions, in some constituting the chief ingredient; and in one or other of its modifications it enters into the composition of certain solid textures. But by far the greater part of the fat of the body is inclosed in small cells or vesicles, which, together with their contained matter, constitute the adipose tissue.

**Distribution.**—This tissue is not confined to any one region or organ, but exists very generally throughout the body, accompanying the still more widely distributed areolar tissue in most though not in all parts in which the latter is found. Still its distribution is not uniform, and there are certain situations in which it is collected more abundantly. It forms a considerable layer underneath the skin, and, together with the subcutaneous areolar tissue in which it is lodged, constitutes in this situation what has been called the *panniculus adiposus*. It is collected in large quantity round certain internal parts, especially the kidneys. It is seen filling up the furrows on the surface of the heart, and imbedding the vessels of that organ underneath its serous covering; and in various other situations it is deposited beneath the serous membranes, or is collected between their folds, as in the mesentery and omentum, at first generally gathering along the course of the blood-vessels and at length accumulating very copiously. Collections of fat are also common round the joints, lying on the outer surface of the synovial membrane, and filling up inequalities; in many cases lodged, like the fat of the omentum, in folds of the membrane, which project into the articular cavity. Lastly, the fat exists in large quantity in the marrow of bones. On the other hand, there are some parts in which fat is never found

Fig. 33.

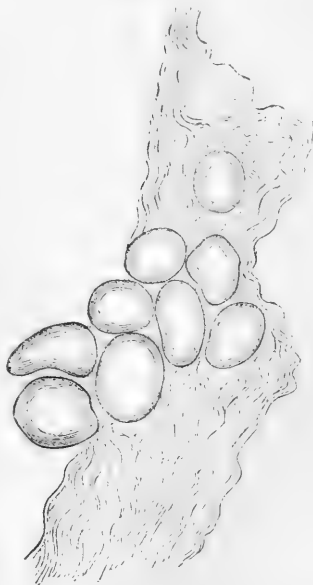

Fig. 33.—LOOSE AREOLAR TISSUE WITH FAT-CELLS; OF MAN. (Köl- liker.)

in the healthy condition of the body. Thus it does not exist in the subcutaneous areolar tissue of the eyelids and penis, nor in the lungs, nor within the cavity of the cranium.

**Structure.**—When subjected to the microscope, the adipose tissue (fig. 33) is seen to consist of small vesicles, filled with an oily matter, and for the most part lodged in the meshes of the areolar tissue. The vesicles are most commonly collected into little lobular clusters, and these again into the little lumps of fat which we see with the naked eye, and which in some parts are aggregated into round or irregular masses of considerable magnitude. Sometimes the vesicles, though grouped together, have less of a clustered arrangement; as when they collect alongside of the minute blood-vessels of thin membranous parts.

In well-nourished bodies the vesicles or fat-cells are round or oval, unless where packed closely together, in which case they acquire an angular figure, and bear a striking resemblance to the cells of vegetable tissues. The greater number of them are from  $\frac{1}{300}$ th to  $\frac{1}{600}$ th of an inch in diameter, but many exceed or fall short of this measurement. Each one consists of a very delicate envelope, inclosing the oily matter, which, completely filling the envelope, appears as a single drop.

A nucleus is commonly present (fig. 34), but is usually obscured by the fatty matter. The envelope is the remains of the original protoplasm of the embryonic cell: it is generally quite transparent and apparently homogeneous in structure. According to some authorities it consists of two parts, a delicate structureless external membrane, and a layer of finely granular protoplasm

immediately surrounding the fat.

Such is the normal condition, but in emaciated, dropsical, and old persons, the oily contents of the cells may become wholly or partially removed, in which case serous fluid may be found occupying its place, and then too the nucleus becomes apparent.

The common fat of the human body consists essentially of palmitin, stearin and olein, which are the compounds of glycerine with palmitic, stearic and oleic acids respectively. These compounds, which are considered to be glycerine-ethers, contain three equivalents of the fatty acid to each equivalent of glycerine; they have hence been termed tri-palmitin, tri-stearin, and tri-olein. The tri-olein, or liquid fat, holds the other two in solution; and the varying consistency of animal fats depends on the relative proportion of the solid and liquid ingredients. During life the oily matter contained in the cells is liquid; but the acicular crystalline spots which are sometimes seen after death indicate a partial solidification of one of its constituents.

The fat being thus contained in closed cells, it will be readily understood why, though liquid or nearly so in the living body, it does not shift its place in obedience to pressure or gravitation, as happens with the water of dropsy and other fluids effused into the interstices of the areolar tissue; such fluids, being unconfined, of course readily pass from one place to another through the open meshes.

The areolar tissue connects and surrounds the larger lumps of fat,

Fig. 34.

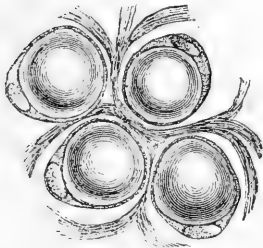


Fig. 34.—FAT CELLS FROM RABBITS' OMENTUM, SHOWING NUCLEUS AND PROTOPLASMIC ENVELOPE, WITH SUPPORTING AREOLAR TISSUE BETWEEN THE CELLS (Klein).



but forms no special envelope to the smaller clusters; and although fine fasciculi and filaments of that tissue pass irregularly over and through the clusters, yet it is probable that the vesicles are held together in these groups mainly by the fine network of capillary vessels distributed to them. In the marrow the connective tissue is very scanty; indeed, the fat-cells in some parts of the bones are said to be altogether unaccompanied by connective filaments.

The adipose tissue is copiously supplied with **blood-vessels**. The larger branches of these pass into the fat-lumps, where they run between the lobules and subdivide, till at length a little artery and vein are sent to each small lobule, dividing into a network of capillary vessels, which not only surrounds the cluster externally, but passes through between the vesicles in all directions, supporting and connecting them. The **lymphatics** of the fat are in close relation to the blood-vessels, accompanying and occasionally completely enclosing them, as they enter the lobule. No nerves have been seen to terminate in this tissue, although nerves destined for other textures may pass through it. Accordingly it has been observed that, unless when such traversing nervous twigs happen to be encountered, a puncturing instrument may be carried through the adipose tissue without occasioning pain.

**Uses and Amount.**—As to the uses of the fatty tissue, it may be observed, in the first place, that it serves the merely mechanical purpose of a light, soft, and elastic packing material to fill vacuities in the body. Being thus deposited between and around different organs, it affords them support, facilitates motion, and protects them from the injurious effects of pressure. In this way, too, it gives to the exterior of the body its smooth, rounded contour. Further, being a bad conductor of heat, the subcutaneous fat must so far serve as a means of retaining the warmth of the body, especially in warm-blooded creatures exposed to great external cold, as the whale and other cetaceous animals, in which it forms a very thick stratum.

But the most important use of the fat is in the process of nutrition. Composed chiefly of carbon and hydrogen, it is absorbed into the blood and consumed in respiration, combining with oxygen to form carbonic acid and water, and thus contributing with other hydrocarbonous matters to maintain the heat of the body; and it is supposed that when the digestive process introduces into the system more carbon and hydrogen than is required for immediate consumption, the excess of those elements is stored up in the form of fat, to become available for use when the expenditure exceeds the immediate supply. According to this view, active muscular exercise, which increases the respiration, tends to prevent the accumulation of fat by increasing the consumption of the hydrocarbonous matter introduced into the body. Again, when the direct supply of calorific matter for respiration is diminished or cut off by withholding food, or by interruption of the digestive process, nature has recourse to that which has been reserved in the form of fat; and in the wasting of the body caused by starvation, the fat is the part first consumed.

The use of the fat in nutrition is well illustrated by what occurs in the hedgehog and some other hibernating animals. In these the function of alimentation is suspended during their winter sleep; and though their respiration is reduced to the lowest amount compatible with life, and their temperature falls, there is yet a considerable amount of hydrocarbonous material provided in the shape of fat, before their hibernation commences, to be slowly consumed during that period, or perhaps to afford an immediate supply on their respiration becoming again active in spring.

It has been estimated that the mean quantity of fat in the human subject is about one-twentieth of the weight of the body, but from what has been said, it is plain that the amount must be subject to great fluctuation. The proportion

is usually largest about the middle period of life, and greatly diminishes in old age. High feeding, repose of mind and body, and much sleep, favour the production of fat. To these causes must be added individual and perhaps hereditary predisposition. There is a greater tendency to fatness in females than males; also, it is said, in eunuchs. The effect of castration in promoting the fattening of domestic animals is well known.

In infancy and childhood the fat is confined chiefly to the subcutaneous tissue. In after-life it is more equally distributed through the body, and in proportionately greater quantity about the viscera. In Hottentot females fat accumulates over the gluteal muscles, forming a considerable prominence: and, in a less degree, over the deltoid. A tendency to local accumulations of the subcutaneous fat is known to exist also in particular races of quadrupeds.

**Development.**—According to Valentin the fat first appears in the human embryo about the fourteenth week of intra-uterine life. It is deposited in the form of minute granules or droplets in certain cells of the connective tissue (fig. 35, *f, f'*): these droplets increase in size

Fig. 35.

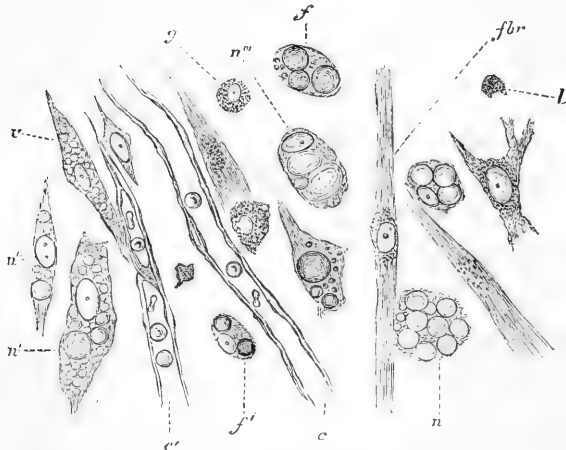


Fig. 35.—DEVELOPMENT OF FAT IN CELLS OF SUBCUTANEOUS CONNECTIVE TISSUE OF NEW-BORN RAT. ABOUT 350 DIAMETERS.

*f, f'*, cells containing fat globules; in *f'*, the nucleus is visible; *fbr*, fibrillated cell; *v*, granular corpuscle; *l*, leucocyte; *v*, vacuolated cell; *n, n', n'', n''''*, hemapoietic cells; *c*, capillary blood-vessel; *c'*, developing capillary. The fibrils of the tissue are omitted for the sake of clearness.

and eventually run together so as to form one large drop in each cell. By further deposition this comes to be considerably larger than the original cell, the protoplasm of which remains as a delicate envelope surrounding the fat-drop. By the end of the fifth month the fat-cells have largely increased in number, and have become collected into small groups. Like the other cells of the areolar tissue, the fat-cells in their early state contain a nucleus, but this, as already stated, becomes afterwards hidden from view.

The deposit of fat within the cells is preceded and accompanied by the formation of a rich network of capillary blood-vessels, which are produced by a transformation of other cells of the tissue in the manner to be afterwards described.

## FIBROUS TISSUE.

**Distribution.**—This substance is one of those which are serviceable in the body chiefly on account of their mechanical properties, being employed to connect together or to support and protect other parts. It is met with in the form of ligaments, connecting the bones together at the joints; it forms the tendons of muscles, into which their fleshy fibres are inserted, and which serve to attach these fibres to the bones. In its investing and protecting character it assumes the membranous form, and constitutes a class of membranes termed “fibrous.” Examples of these are seen in the periosteum and perichondrium which cover the bones and cartilages, in the dura mater which lines the skull and protects the brain, and the fibrous layer which strengthens the pericardium, also in the albugineous coat of the testicle, and the sclerotic coat of the eye, which inclose the tender internal parts of these organs. Fibrous membranes, named “aponeuroses” or “fasciæ,” are also employed to envelope and bind down the muscles of different regions, of which the great fascia inclosing the muscles of the thigh and leg is a well-known example. The tendons of muscles, too, may assume the expanded form of aponeuroses, as those of the broad muscles of the abdomen, which form strong fibrous layers in the walls of that cavity and add to their strength. It thus appears that the fibrous tissue presents itself under two principal forms, the *fascicular* and the *membranous*.

**Physical Properties.**—The fibrous tissue is white or yellowish white, with a shining, silvery, or nacreous aspect. It is exceedingly strong and tough, yet perfectly pliant; but it is almost devoid of extensibility. By these qualities it is admirably suited to the purposes to which it is applied in the animal frame. By its inextensible character it maintains in apposition the parts which it connects against any severing force short of that sufficient to cause actual rupture, and this is resisted by its great strength, whilst its flexibility permits of easy motion. Accordingly the ligaments and tendons do not sensibly yield to extension in the strongest muscular efforts; and though they sometimes snap asunder, it is well known that bones will break more readily than tendons of equal thickness. The fibrous membranes are proportionally strong and alike inextensible; they will gradually yield, it is true, when the extending force acts slowly and for a long time, as when tumours or fluids slowly gather beneath them; but perhaps this gradual extension is accompanied with some nutritive change affecting the properties of the tissue.

**Structure.**—The fibrous tissue is made up of fine filaments, agreeing in all respects with the white filaments of the areolar tissue already described. Like these they are collected into bundles, in which they run parallel and exhibit the same wavy character, cohering very intimately. The bundles appear to the naked eye as fine shining threads or narrow flattened bands, for they vary greatly in thickness. They either run all in one direction as in long tendons, or intersect each other in different planes as in some aponeuroses, or they take various directions and decussate irregularly with each other as in the dura mater. And when they run parallel to each other, as in tendon, they do not keep separate throughout their length, but send off slips to join neighbouring bundles and receive the like in turn; so that successive

cross sections of a tendon or ligament present different figures of the sectional areas of the bundles. A sheath of dense areolar tissue covers the tendons and ligaments on the outside, and a variable amount of the same tissue lies between the larger fasciculi; little in tendons, more in some fibrous membranes.

The surface of a tendon or of any other part consisting of this texture, appears marked across the direction of the fasciculi with alternate light and dark streaks, which give it a peculiar aspect, not

Fig. 36.

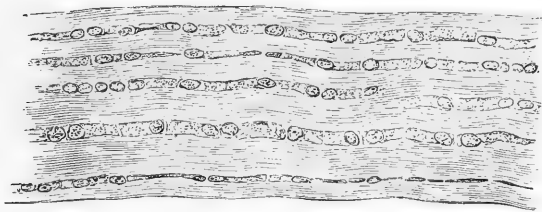


Fig. 36.—TENDON OF MOUSE'S TAIL, STAINED WITH LOGWOOD; SHOWING CHAINS OF CELLS BETWEEN THE TENDON-BUNDLES. 175 DIAMETERS.

of the mouse or rat, or a portion only of a larger one, is examined under the microscope in an indifferent fluid, and a little dilute acetic acid is cautiously added, the filaments are seen to swell up and become indistinct, and the acid discloses the existence of chains of oblong flattened cells lying between the tendon-bundles (fig. 36). These cells,

unlike that of a watered ribbon. This appearance is owing to the wavy course of the filaments, for when the light falls on them their bendings naturally give rise to alternate lights and shadows.

If a very fine tendon, such as those in the tail

Fig. 37.



Fig. 37.—EIGHT CELLS FROM THE SAME TENDON AS REPRESENTED IN FIG. 36. 425 DIAMETERS.

The nuclei, with their numerous nucleoli, were deeply coloured by the logwood.

which are represented more highly magnified in fig. 37, agree, in almost every point except in shape, with the connective-tissue corpuscles previously described: each consists of a delicate protoplasmic body, thicker at the centre than at the sides, and containing a more or less flattened, round, or oval clear nucleus, with several nucleoli. The ends of adjacent cells are in close apposition, so as to form, as before noticed, long chains of cells in the tendon, and the nucleus is generally so situated towards one end of the cell as to be in close proximity to the nucleus of an adjacent cell; they thus present the appearance of being arranged in pairs. Here and there a third nucleus, with a small amount of protoplasm, may be seen interpolated between two such cells (fig. 36). The rows of cells lie flattened against the tendon-bundles, the middle of each cell lying in the angular space between three or more bundles and a lamellar prolongation extends

from this into the interstice between each two contiguous bundles: this arrangement will be evident on study of the transverse section (fig. 38). On the flat surface of the cells lines are commonly seen running in a longitudinal direction (fig. 37): these are not to be regarded as due either to creases in the cells, or to the presence of an "elastic stripe" as conceived by Boll, but are merely the optical sections of such lamellar extensions as are directed either towards or away from the observer.\* At their edges the lamellæ gradually fade off as they pass between the tendon-bundles: the latter are not completely enclosed by the cells, as was at first supposed by Ranvier, to whom the merit of the discovery of these flattened cellular elements belongs.†

Treatment with nitrate of silver solution brings into view corresponding spaces (fig. 39), which commonly appear somewhat larger than the cells themselves, with which, however, in general form and arrangement they in the main coincide.

Fig. 38.

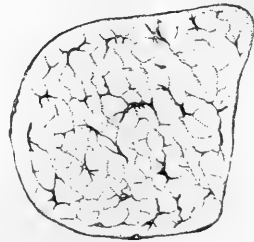


Fig. 38.—TRANSVERSE SECTION OF TENDON OF MOUSE'S TAIL STAINED WITH LOGWOOD. 175 DIAMETERS.

The flattened processes of the tendon-cells (which are stained deeply by logwood) appear in section as lines, frequently coming off at right angles from the body of the cell. The bundles of fibres are not represented; they are very irregular, and but incompletely separated by the cell-processes.

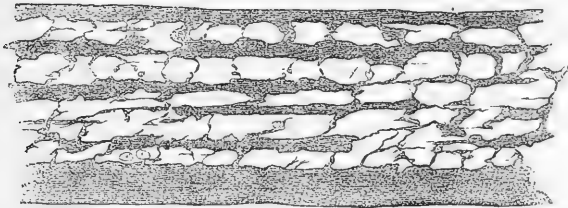


Fig. 39.—CELL SPACES OF TENDON OF MOUSE'S TAIL, BROUGHT INTO VIEW BY TREATMENT WITH NITRATE OF SILVER. 175 DIAMETERS.

The fibrous and areolar tissues thus agreeing in their ultimate structure, it is not to be wondered at that sometimes the limits between the two should be but ill-defined, and that the one should pass by inconspicuous gradations into the other. Instances of such a transition may be seen in many of the fasciæ: these at certain parts consist of dense areolar tissue, but on being traced farther are seen gradually to take on the fibrous character; and fasciæ, which in one body consist of areolar tissue, may be decidedly fibrous in another.

In chemical constitution also the fibrous tissue is similar to the areolar. It contains about two-thirds of its weight of water; it becomes transparent and hard, when dried, but readily imbibes water

\* From an article received since the above was in type, it would appear that Ranvier has also, from a further study of the subject, arrived at a similar conclusion (*Arch. de Phys.* No. 2, 1874).

† *Arch. de Physiologie*, 1869.

again and regains its original properties. It is resolved into gelatin by boiling.

**Vessels and Nerves.**—The fibrous tissue receives *blood-vessels*, but in general they are inconsiderable both in number and size compared with the mass of tissue to which they belong. In tendons and ligaments with longitudinal fasciculi, the chief branches of the vessels run parallel with and between the larger fasciculi, and, sending communicating branches across them, eventually form a very open network with large oblong meshes. Some fibrous membranes, as the periosteum and dura mater, are much more vascular; but the vessels seen in these membranes do not strictly belong to them, being destined for the bones which they cover.

*Lymphatics* are contained in great abundance, as Ludwig and Schweigger-Seidel\* have shown, in the enveloping areolar-tissue sheaths of tendons and aponeuroses, where they form plexuses with polygonal meshes. In addition to these a close net-work of lymphatic vessels with elongated meshes may be injected in the deeper parts of the tendons. A connection no doubt subsists between these lymphatics and the cell-spaces of the fibrous structures: and it has been suggested, with great probability, that those of the tendons are largely concerned in the removal of matters derived from the attached muscles, in which the existence of lymphatic plexuses has not hitherto been established.

As to *nerves*, their existence in tendons and ligaments has not been satisfactorily demonstrated by anatomical investigation. The fasciæ and the sheaths of tendons are also destitute of nerves. On the other hand, fine nerves have been traced in the interosseous membrane of the leg, and nervous filaments are even abundant in the periosteum, but the majority of them do not belong to the membrane itself, but are destined for the subjacent bone. Nerves have also been traced in the dura mater; some accompany the vessels, others appear destined for the membrane itself, and others again for the bones.

It has been proved by numerous observations and experiments, that the tendons and ligaments are, in the healthy state, quite insensible; but then it is known, on the other hand, that they occasion severe pain when inflamed, which cannot well be accounted for on the supposition that they are entirely destitute of nerves. Bichat, while he admitted their insensibility to cutting, burning, and most other kinds of stimuli which cause pain in sensible textures, ascribed to them a peculiar sensibility to twisting or to violent traction, and this opinion has been supported by other authorities of weight, but the proofs of it are not clear.

**Regeneration.**—Fibrous tissue readily heals and unites when divided, as is seen in cases of broken tendo Achillis. It is very generally produced as a uniting medium of broken bones when osseous union fails to take place; and is common as a diseased production in various kinds of tumours.

#### YELLOW OR ELASTIC TISSUE.

Whilst the fibrous tissue is remarkable for its want of extensibility, and owes its usefulness as a constituent of the frame in a great measure to that character, the substance we have now to consider possesses this

\* Die Lymphgefäße der Fascien und Sehnen. Leipzig, 1870.

property in a very high degree, and is employed wherever an extensible and highly elastic material is required in the animal structure.

Examples of this texture on a large scale are seen in the horse, ox, elephant, and other large quadrupeds, in which it forms the great elastic ligament, called *ligamentum nuchæ*, that extends from the spines of the vertebræ to the occiput, and aids in sustaining the head; in the same animals it also forms an elastic subcutaneous fascia, which is spread over the muscles of the abdomen and assists in supporting the contents of that cavity. In the human body it is met with chiefly in the following situations, viz. :—

1. Forming the *ligamenta subflava*, which extend between the arches of adjacent vertebræ; these ligaments, while they permit the bones to be drawn apart in flexion of the body, aid in restoring and maintaining their habitual approximation in the erect posture—so far, therefore, relieving the constant effort of the erector muscles. There is, moreover, an obvious advantage in having an elastic band in this situation, instead of an ordinary ligament, which would be thrown into folds when the bones are approximated.
2. Constituting the chief part of the stylohyoid, thyrohyoid, and cricothyroid ligaments, and those named the vocal cords. Also extending, in form of longitudinal bands, underneath the mucous membrane of the windpipe and its ramifications.
3. Entering, along with other textures, into the formation of the coats of the blood-vessels, especially the arteries, and conferring elasticity on these tubes.
4. Beneath the mucous membrane of the gullet and lower part of the rectum, also in the tissue which surrounds the muscular coat of the gullet externally.
5. In the tissue which lies under the serous membranes in certain parts.
6. In many of the fasciæ, where it is mixed with much areolar tissue.
7. Largely in the suspensory ligament and subcutaneous tissue of the penis.
8. In considerable quantity in the tissue of the skin.
9. In the enclosing capsule and trabecular tissue of the spleen.

The elastic tissue in its purest and most typical condition, such as is seen in the ligamentum nuchæ of quadrupeds and the ligamenta subflava of the human spine, has a yellow colour more or less decided; it is extensible and elastic in the highest degree, but is not so strong as ordinary fibrous ligament, and it breaks across the direction of its fibres when forcibly stretched. Its fibres may be easily torn separate in a longitudinal direction; they are often gathered into irregular fasciculi which run side by side, but join at short distances by slips with one another, and are further connected by areolar tissue, which is always intermixed with them in greater or less quantity. Elastic ligaments are also covered outwardly with a sheath of areolar tissue.

When the elastic fibres are mixed up with a large proportion of some other kind of tissue, their yellow colour may not appear, but they can always be recognised by their microscopic characters. When viewed under a tolerably high magnifying power, they appear quite transparent, with a remarkably well-defined dark outline (fig. 40). They run side by side, following a somewhat bending course, but with bold and wide curves, unlike the undulations of the white connective filaments. As they proceed they divide into branches, and join or anastomose together in a reticular manner. Elastic networks may be composed of fine fibres with wide meshes; in other parts the elastic fibres are larger and broader and the intervening spaces narrower, so that the tissue may even acquire a lamellar character and present the appearance of a homogeneous membrane, which may be either entire, or with gaps or perforations at short intervals, in which case

it constitutes the fenestrated membrane of Henle, found in the coats of the blood-vessels. A remarkable character which elastic fibres exhibit in many specimens, is their singular tendency to curl up at their

Fig. 40.

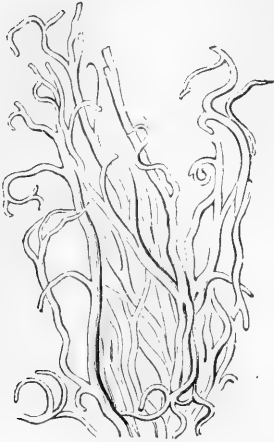

Fig. 40.—ELASTIC FIBRES FROM THE LIGAMENTA SUBFLAVA, MAGNIFIED ABOUT 200 DIAMETERS.

broken ends; and these ends are not pointed, but abruptly broken across. Their size is very various; the largest in man are nearly  $\frac{1}{4000}$ th of an inch in diameter, the smallest perhaps not more than  $\frac{1}{24000}$ th. In some varieties of the tissue the larger sized fibres prevail; this is the case with the ligamenta subflava, where their general diameter is about  $\frac{1}{7500}$ th of an inch; in other instances, as in the chordæ vocales, they are exceedingly fine. In some animals elastic fibres are met with  $\frac{1}{1300}$ th of an inch in thickness. Acetic acid produces no change on the elastic fibres, while it speedily alters the wavy areolar fibres that are usually intermixed with them in greater or less number. They also withstand boiling for a short time in solutions containing ten to fifteen per cent. of caustic potash or soda, by which the white fibres and the corpuscles of connective tissue are speedily destroyed.

**Chemical Composition.**—The elastic tissue, of course, contains water, and loses much of its weight by drying; but the proportion is said not to be so great as in most other soft tissues. By very long boiling it yields a substance in some points resembling gelatin, while a portion, equal to rather more than the half, remains undissolved.

The gelatin, no doubt, comes from the intermixed areolar tissue; but the dissolved matter is not pure gelatin, for it is precipitated by acetic acid, and by some other re-agents which do not disturb a solution of pure gelatin. The nature of the substance which remains undissolved has not been determined. Caustic potash and soda have little effect on elastic tissue in the cold, and in weak solutions even when hot, unless the application is long continued; boiling in concentrated solutions speedily dissolves it. It is soluble with the aid of heat in dilute hydrochloric acid.

**Vessels and Nerves.**—The yellow ligaments, which contain this tissue in its purest form, are but scantily supplied with vessels; and no nerves have been traced into them. We are not aware of any experiments or observations as to their sensibility, but there is no reason for supposing it to be greater than that of ordinary ligaments; nor has it been shown that structures containing this tissue possess vital contractility, unless they also contain contractile fibres of another kind.

#### SPECIAL VARIETIES OF CONNECTIVE TISSUE.

**1. Jelly-like connective tissue** or *mucous tissue*. At an early period of development connective tissue consists of a pellucid jelly and nucleated corpuscles. The soft watery jelly contains the chemical principle of mucus, or *mucin*, and, in much less proportion,



albumin, but not gelatin. In the general course of development of the tissue, fibres, both white and elastic, are formed in the soft matrix, and finally this substance in a great measure disappears. But in certain cases the course is different. The cells may disappear, only the jelly remaining, as in the vitreous humour of the eye; or the corpuscles may branch out and join together in form of a network in the jelly, with the nuclei persisting at the spots whence the threads diverge. The areolar tissue surrounding and imbedding the vessels in the umbilical cord consists of fusiform and ramified corpuscles associated with white fibrillar bundles and elastic fibres, along with much of the soft matrix, which is persistent at the time of birth and is known as the jelly of Wharton.

**2. Retiform\* connective tissue; Reticular tissue, and Cylogenous tissue (Kölliker); Adenoid tissue (His).** In this case the matrix disappears: neither white nor elastic fibres are developed, but the ramified corpuscles unite together into a reticular or fine trabecular structure (fig. 41); either retaining their nuclei as at *a*, or losing them and then forming a fine network of simple fibres without nuclei as at *b*.

That in both forms the tissue is constructed of ramified corpuscles is shown by its withstanding boiling in water, whilst it readily dissolves in hot alkaline solutions. This form of connective tissue enters into the construction of certain organs and textures, where it serves as a supporting framework

to their peculiar elements and their nourishing blood-vessels, and thus becomes a "sustentacular" tissue (*Stützgewebe*, Germ.). In this way it forms a trabecular network within the lymphatic glands, containing the lymph-corpuscles in its meshes (as at *c*). So also it is found in the solitary and agminated glands of the intestine, the tongue, and tonsils; in the thymus gland; in the spleen; and in the tissue of the intestinal mucous membrane at certain parts; in all which situations the meshes contain corpuscles of similar external character with those in the lymphatic glands. But, although thus related to glands and thence named "adenoid" tissue, it exists also as a sustaining structure in the brain and spinal cord, where, with finer branches and closer meshes, it forms an extremely delicate framework supporting the proper nervous substance, and has been called the *reticulum* (Kölliker).

\* We use the term "retiform," not because it signifies more or less than "reticular," but because the latter term is not unfrequently applied to areolar tissue.

Fig. 41.

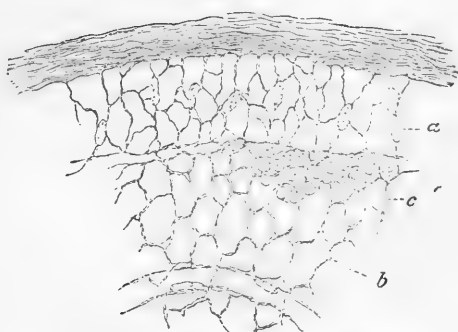


Fig. 41.—THIN SECTION FROM THE CORTICAL PART OF A LYMPHATIC GLAND, MAGNIFIED.

A network of fine trabeculae formed by retiform or adenoid tissue, from the meshes of which the lymph-corpuscles have been washed out, except at *c*, where they are left (after His, slightly altered).

3. A third variety of connective tissue is commonly met with in the form of **delicate membranes** and was formerly supposed to be quite homogeneous in structure. These membranes have, however, in almost every case, been shown to be made up of flattened cells, in close apposition, and more or less fused together by their edges, which can, however, be brought to view by staining with nitrate of silver. Examples of such are to be found in the walls of the capillaries, the hyaloid membrane of the eye and the *membrana propria* lying under the epithelium of mucous membranes at certain parts, in gland ducts and the like.

It must be noted, however, that some homogeneous membranes, as for example, the posterior elastic lamina of the cornea, are of a different nature.

#### DEVELOPMENT OF THE CONNECTIVE TISSUE.

Those parts of the early embryo in which connective tissue is subsequently to be developed, are at first composed entirely of closely agglomerated embryonic cells, to all appearance similar to those of which the remainder of the body is constituted (see p. 8). The first change of importance that occurs is the development of blood-vessels from some of these cells in the manner that has already been partly explained (p. 41), and will be further treated of when those vessels have come under consideration. Soon after the development of these primitive blood-vessels the embryonic cells become more separated, but retain for the most part a connection with one another by interjoining processes; and the interstices between the cells are now found to be filled with a clear fluid, as to which it is uncertain whether it is produced by the cells themselves, or derived directly by transudation from the blood-vessels, as Boll is inclined to believe: it is to be noted, however, that besides albumin this fluid contains mucin, which is commonly a product of cells and is not demonstrable in the liquor sanguinis. This muco-albuminous fluid subsequently acquires a firmer consistence and eventually remains as the ground substance, which in the adult tissue, although widely diffused, is nevertheless, relatively to the fibres, in very small amount. A difference is noticeable in the relations of the cells according as areolar or fibrous tissue is to become developed, they being in the former case connected together both laterally and at their ends, in the latter at their ends merely; rows or chains of cells being thus produced. Before long a delicate striation appears within the cells, in the case of the fibrous tissues in a longitudinal direction only, in that of the areolar obliquely and transversely as well: this striation (which afterwards passes into fibrillation) may be traced through the connecting processes from one cell into another. In this manner each bundle of fibrils is produced from a series of connected cells by the conversion of the whole or of a part only of their protoplasm into collagenous substance: in the latter case the remainder of the cell becomes flattened out and persists on the surface of the bundle as a connective-tissue corpuscle or tendon-cell, as the case may be. In the areolar tissue many of the smaller bundles or threads are formed from processes which grow out from the corpuscles into the surrounding ground-substance, and, interlacing and intertwining with processes from other cells,

subsequently become fibrillated. The cell-processes, however, do not, it is believed, ever form single fibrils, but always smaller or larger bundles; in this there is a marked difference between the development of the white connective tissue and that of the elastic fibres, as will immediately be seen. The bundles of white fibres probably become enlarged by a further fibrillation of the part of the cells in contact with them, the cells at the same time themselves increasing in size and probably also in number.

The above description of the development of the white connective tissue, which is principally founded upon the results of actual observation on the mammalian embryo and young animal, is substantially the same as that given by most recent observers who have investigated the subject,\* and in many respects accords with the original description of Schwann. It is right, however, to state that a very different view is held by several distinguished authorities, according to whom the cells themselves have no direct share in the formation of the fibrils, which are believed to be developed as an independent deposit in the muco-albuminous matter which lies between the cells.

With regard to the formation of the elastic fibres, little is positively known, but it would appear that they also are formed from cells, probably of a different nature from those which generate the white connective tissue. The fibres appear to be formed of the processes of the cells which grow out and branch, becoming connected with processes from other cells. The conversion into elastic substance seems to occur first at the extremities of the processes and to proceed towards the body of the cell: it would appear probable that it is the surface layer of a fibre that is first changed, for elastic fibres (presumably not fully developed) are here and there met with which appear to present a tubular structure; for a precipitate may under some circumstances be produced in their interior. What becomes of the body of the cell is not very clear: however, it would seem that in some instances, at least, the connection of the elastic fibres with cell processes is retained even in the fully-developed tissue (Thin): in the pure elastic ligaments, on the other hand, the cells are stated to disappear.

The first appearance of the elastic fibres is described by Ranvier and others as occurring in the form of rows of granules or globules which subsequently run together. Such a mode of formation would explain the appearance of an indistinct transverse striation which has sometimes been described in those fibres.

As in the case of the white connective tissue, it has been held by many authorities that the elastic fibres are also formed by a deposit (although of a different nature) in the muco-albuminous fluid between the cells.

In the formation of the special varieties of connective tissue, no fibres are developed, but either the cells disappear altogether, their place being occupied by muco-albuminous matter, as in the jelly-like connective tissue; or this matter is developed in but very small amount, in which case the cells may either become flattened out, remaining coherent at their edges, as in the homogeneous membranes, or, some of them becoming branched, and, intercommunicating by their processes, may form a reticulum within the meshes of which other cells are more or less closely packed, as in the retiform or adenoid tissue.

\* Max Schultze: Brücke (Obersteiner, and Kusnetzoff, Wiener Sitzb. lvi.); Stricker (Breslauer, Arch. f. mikr. Anat. v.): Boll, Arch. f. mikr. Anat. vii.

## CARTILAGE.

This is the well-known substance commonly called "gristle." The following are its more obvious characters. When in mass, it is opaque and of a pearly or bluish white colour, in some varieties yellow; but in thin slices it is translucent. Although it can be easily cut with a sharp knife, it is nevertheless of very firm consistence, but at the same time highly elastic, so that it readily yields to pressure or torsion, and immediately recovers its original shape when the constraining force is withdrawn. By reason of these mechanical properties, it is rather extensively used in the construction of the body. Its specific gravity is 1.15.

In the early embryo the skeleton is, in great part, cartilaginous; but the cartilage forming its different pieces, which have the outward form of the future bones, in due time undergoes ossification or gives place to bone, in the greater part of its extent at least, and hence this variety of cartilage is named "temporary."

Of the permanent cartilages a great many are in immediate connection with bone, and may be still said to form part of the skeleton. The chief of these are the articular and the costal cartilages; the former cover the ends or surfaces of bones in the joints, and afford these harder parts a thick springy coating, which breaks the force of concussion and gives ease to their motions; the costal or rib-cartilages form a considerable part of the solid framework of the thorax, and impart elasticity to its walls. Other permanent cartilages enter into the formation of the external ear, the nose, the eyelids, the Eustachian tube, the larynx, and the windpipe. They strengthen the substance of these parts without undue rigidity; maintaining their shape, keeping open the passages through them where such exist, and giving attachment to moving muscles and connecting ligaments.

Cartilages, except those of the joints, are covered externally with a fibrous membrane named the *perichondrium*.

When a very thin slice of cartilage is examined with the microscope, it is seen to consist of nucleated cells, also named cartilage-corpuscles, disseminated in a solid mass or matrix. (Fig. 42.)

The matrix is sometimes transparent, and to all appearance homogeneous; sometimes dim and very faintly granular, like ground glass: both these conditions occur in *hyaline cartilage*, which may be regarded as the most typical form of the tissue. Two varieties exist in which the matrix is pervaded to a greater or less extent by fibres. In the one named *elastic* or *yellow cartilage*, the fibres are similar to those of elastic tissue; in the other, named *fibro-cartilage*, they are of the white kind as in ordinary ligament.

## HYALINE CARTILAGE.

In hyaline cartilage the matrix, as just stated, is uniform and, in the normal state, free from fibres. The cells consist of a rounded, oval, or bluntly angular *cell-body* of translucent, but sometimes finely granular-looking substance (fig. 42, *h*), with a round *nucleus* (*n*), which is either clear or of a coarsely granular appearance, and one or more *nucleoli*. The cell-body lies in a cavity of the matrix, which, in its natural condition, it entirely fills. This cavity is bounded and inclosed

by a transparent *capsule*, which is seldom obvious to the eye, for it coheres intimately with the surrounding matrix, with which it agrees in nature, and cannot usually be distinguished without the aid of re-agents.

In thin slices of young cartilage the capsules may be freed from the matrix by means of concentrated mineral acids, and can then be shown as distinct vesicles having the cell-bodies within. The effect of acids is promoted by previous boiling of the cartilage in water. By exposure to water and some other liquids as well as to the action of electric shocks the cell-body shrinks away from the inside of the capsule, and assumes a jagged or otherwise irregular figure, and then may hide the nucleus (fig. 44). It often contains larger or smaller fatty globules (fig. 42, *g*.)

The cells are rarely dispersed singly in the matrix; they most commonly occur in groups of two or more. When disposed in pairs (as at *a*, fig. 42) the cells are generally triangular or pyramidal in form with rounded angles, and with their bases opposite one another; in the larger groups (*b*) the cells have a straight outline where they adjoin or approach one another, but at the circumference of the group their outline is rounded. Towards the surface of the cartilage the groups are generally flattened conformably with the surface, appearing narrow and almost linear when seen edgewise, as in a perpendicular section (fig. 43).

Fig. 42.

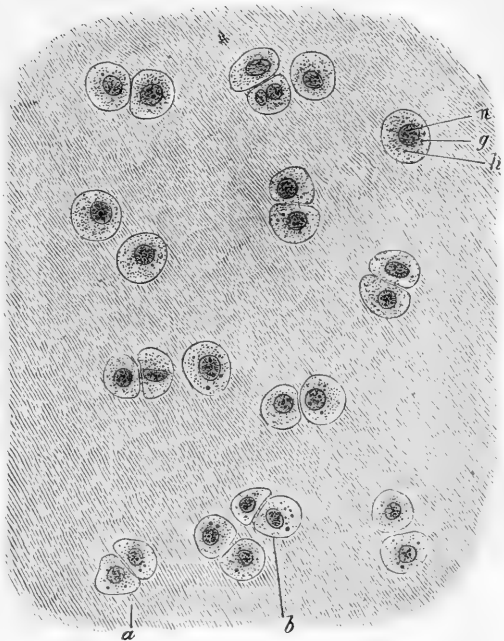


Fig. 42. — ARTICULAR CARTILAGE FROM HEAD OF METATARSAL (OSMIC ACID PREPARATION). THE CELL-BODIES ENTIRELY FILL THE SPACES IN THE MATRIX. 340 DIAMETERS.

*a*, *b*, groups of cells; *h*, protoplasm of cell, with *g*, fatty granules; *n*, nucleus.

Such is the structure of hyaline cartilage in general, but it is more or less modified in different situations.

In **articular cartilage**, the matrix in a thin section appears dim, like ground glass, and has an almost granular aspect. The cells are smaller and more uniformly dispersed, as a rule, than in rib cartilage. As is the case with cartilage generally, the groups which they form are flattened at and near to the surface, and lie parallel with it (fig. 44); deeper and nearer the bone, on the other hand, they are narrow and oblong, like short irregular strings of beads, and are

mostly directed vertically. (Fig. 43.) It is well known that articular cartilages readily break in a direction perpendicular to their surface,

Fig. 43.

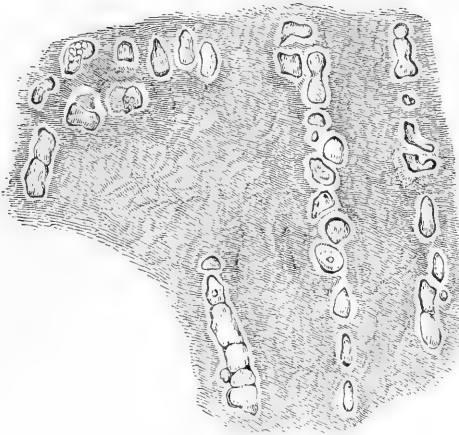


Fig. 44.

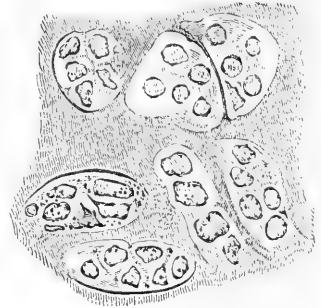


Fig. 43.—VERTICAL SECTION OF ARTICULAR CARTILAGE OF THE HEAD OF THE HUMERUS. A deep portion near the bone. Magnified 400 diameters.

Fig. 44.—A THIN LAYER PEELED OFF FROM THE SURFACE OF THE CARTILAGE OF THE HEAD OF THE HUMERUS, SHOWING FLATTENED GROUPS OF CELLS.

The shrunken cell-bodies are distinctly seen, but the limits of the capsular cavities where they adjoin one another are but faintly indicated. Magnified 400 diameters.

and the surface of the fracture appears to the naked eye to be striated in the same direction, as if they had a columnar structure; this has been

Fig. 45.

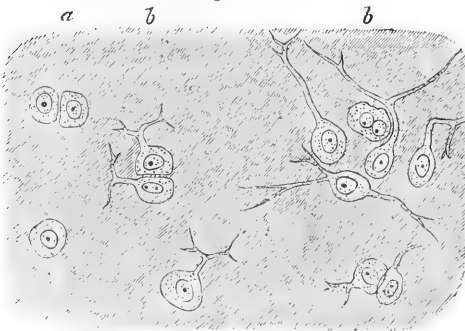


Fig. 45.—BORDER OF ARTICULAR CARTILAGE SHOWING TRANSITION OF CARTILAGE CELLS INTO CONNECTIVE-TISSUE CORPUSCLES OF SYNOVIAL MEMBRANE. FROM HEAD OF METATARSAL BONE, HUMAN. ABOUT 340 DIAMETERS.

*a*, ordinary cartilage cells; *b, b*, with branching processes.

broad patches of cells with the intermediate matrix are not to be

ascribed to the vertical arrangement of the rows of cells, or to a latent fibrous or columnar disposition of the substance of the matrix (Leidy). It was formerly held that the free surface of articular cartilage is covered with epithelium, but no such covering really exists. It is easy, no doubt, to peel off a thin film from the surface of the cartilage of the head of the humerus or femur; but this superficial layer is really part of the cartilage, and its matrix are not to be

mistaken. (See fig. 44.) Near the margin of these cartilages a layer of fine filamentous tissue is prolonged a certain way over their surface from the synovial membrane, and the cartilage-cells in the neighbourhood of this acquire processes and present transitions to the connective-tissue corpuscles of that membrane (fig. 45.) The matrix of articular cartilage rarely, or perhaps never, becomes pervaded by fibres like those so often seen in rib cartilage, nor is it prone to ossify.

In the **costal cartilages**, the corpuscles or cells, which are of large size are also collected in groups. Near the exterior of the cartilage they are flattened, and lie parallel with the surface, forming a superficial stratum from  $\frac{1}{200}$ th to  $\frac{1}{300}$ th of an inch thick. As to those situated more inwardly, we can sometimes observe, in a transverse slice, that they form oblong groups disposed in lines radiating to the circumference; but this arrangement is not constant, and they often appear quite irregular. The cells, with the exception of those lying upon the surface, commonly contain larger or smaller drops of oil; and the nucleus, being generally undiscoverable, is concealed by the fat or may itself have undergone a fatty metamorphosis. The matrix is tolerably clear, except where fibres have been developed in it, in which parts it is opaque and yellowish. Such fibrous patches are very frequent; the fibres are fine, straight, and parallel, appearing transparent when few together; they appear to withstand the action of acetic acid. It is not uncommon to find the rib-cartilages extensively ossified.

The description given of the microscopic characters of the costal cartilages will apply with little variation to the ensiform cartilage of the sternum, to the cartilages of the larynx and windpipe, except the epiglottis and cornicula laryngis, and to the cartilages of the nose. With the exception of the last, these resemble the rib-cartilages also in their tendency to ossify.

The characters of the temporary cartilages, which are hyaline, will be noticed in the account of the formation of bone.

**Vessels and nerves.**—In the healthy state, no blood-vessels penetrate the articular cartilages. Whatever nutrient fluid they require seems to be derived from the vessels of adjoining textures, especially the bone, and to be conveyed through the tissue by imbibition. Towards the circumference of the cartilage, however, underneath the synovial membrane, the synovial vessels form a narrow vascular border round it, which has been named the *circulus articuli vasculosus*.

When the tissue exists in thicker masses, as in the cartilages of the ribs, canals are here and there excavated in its substance, along which vessels are conducted to supply nourishment to the parts too distant to receive it from the vessels of the perichondrium. But these canals are few and wide apart, and the vessels do not pass beyond them to ramify in the intermediate mass, which is accordingly quite extravascular. It must be further remembered respecting these vascular canals, that many of them lead to spots where the cartilage is undergoing ossification, and convey vessels to supply the bony deposits.

No nerves have been traced into any of the cartilages, and they are known to be destitute of sensibility.

**Composition.**—Ordinary permanent hyaline cartilage contains about three fifths of its weight of water, and becomes transparent by drying. By boiling it in water for fifteen or twenty hours, it is resolved into chondrin. This is a substance said to gelatinise on cooling, although it may be doubted whether the

congelation is not in reality owing to an admixture of gelatin derived from fibrous tissue not duly separated from the cartilage. Like gelatin, chondrin is thrown down from its solutions by tannic acid, alcohol, ether, creasote, and corrosive sublimate, and not by prussiate of potash. It differs from gelatin in being precipitated by the mineral and other acids, the acetic not excepted; also by alum, sulphate of alumina, persulphate of iron, and acetate of lead; the precipitates being soluble in an excess of the respective precipitants. The temporary cartilages are resolved into a matter which has the chemical reactions of chondrin, but does not gelatinise.

The following analyses are by Hoppe Seyler :

|                                                                      | Water. | In 100 parts. |                       |
|----------------------------------------------------------------------|--------|---------------|-----------------------|
|                                                                      |        | Organic.      | Solids.<br>Inorganic. |
| Costal Cartilage . . .                                               | 67.67  | 30.13         | 2.20                  |
| Articular Cartilage . . .                                            | 73.59  | 24.87         | 1.54                  |
| The ashes from Costal Cartilage were found to contain in 100 parts : |        |               |                       |
| Sulphate of potash . . .                                             |        | 26.66         |                       |
| Sulphate of soda . . .                                               |        | 44.81         |                       |
| Chloride of sodium . . .                                             |        | 6.11          |                       |
| Phosphate of soda . . .                                              |        | 8.42          |                       |
| Phosphate of lime . . .                                              |        | 7.88          |                       |
| Phosphate of magnesia . . .                                          |        | 4.55          |                       |

Frommherz and Gugert obtained a small percentage of iron and considerable quantities of the carbonates of lime and soda.

**Development of Hyaline Cartilage.**—The parts of the embryo which are about to become cartilages are made up at first of the common embryonic cells from which the tissues generally originate. The cell-contents clear up, the nucleus becomes more visible, and the cells, mostly of polygonal outline, appear surrounded by clear lines of pellucid substance, forming as it were a network of bright meshes inclosing them, but in reality consisting of the cohering capsules of the contiguous cells, and constituting all that exists of the matrix at this time.\* Glycogen appears at an early period in the protoplasm of cartilage-cells. Rouget found it in the sheep's embryo of two months, both in ossifying cartilage and in the cartilages of the trachea.

The subsequent changes consist in enlargement and multiplication of the cells and development of the intermediate matrix.

The process is commonly described as follows, but it is necessary to mention that all the successive steps here described and represented (see fig. 46) have not been actually traced:—The cartilage-cells first divide, a species of capsule being formed round each of the young cells (B), whilst the old one inclosing them becomes blended with the intercellular matrix, and is no longer traceable (C).

The new cells, in turn, divide in the same way, so as to make a group of four, each of which is surrounded by its own capsule (D), whilst the capsules of the first descent (secondary) blend with the matrix (E) like their predecessor.

It is doubtful how the capsule is produced; whether excreted by the cell which it afterwards incloses, as held by Kölliker; or formed by conversion of a superficial layer of the protoplasm of the cell-body, as taught by Max Schultze; or a primarily independent deposit around the cells. However this may be, there is at first no matrix but what is made up of the simple capsules. In further growth there is a difference, according as the cells do or do not undergo frequent division. In the

\* Cartilages, which retain this condition throughout life, have been termed "parenchymatous." A good example of this is found in the cartilage of the mouse's ear, and in that which composes the notochord of the embryo.



latter case a cell becomes surrounded by many concentric capsules formed in succession ; that is, the first capsule is expanded, and the others formed each within its expanding predecessor, so that the cartilage comes to consist of scattered cells, each with a concentric system of capsules, which by means of re-agents may be rendered visible in the neighbourhood of the cells, but further off are inseparably blended into a uniform substance. When, on the other hand, the cells have a tendency to frequent subdivision, the new capsules are produced by

Fig. 46.

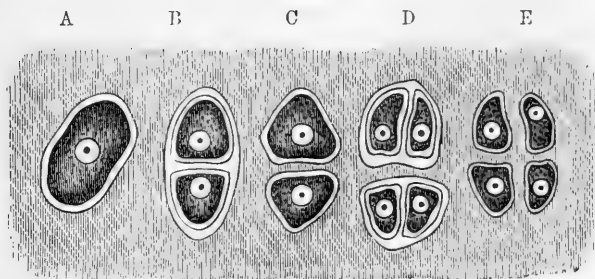


Fig. 46.—IDEAL PLAN OF THE MULTIPLICATION OF CELLS OF CARTILAGE.

A, cell in its capsule ; B, divided into two, each with a capsule ; C, primary capsule disappeared, secondary capsules coherent with matrix ; D, tertiary division ; E, secondary capsules disappeared, tertiary coherent with matrix.

the new cells, and are included in and finally blend with those which had belonged to the previous cells, as shown by fig. 46.

The matrix, although thus formed of the capsules, becomes to all appearance homogeneous ; but in sections of cartilage that have been exposed to acids and other re-agents, the contour lines of the capsules round cells and cell-groups may be more or less distinctly brought into view. But, whilst admitting that the capsules have a share in the production of the matrix, Kölliker and some other histologists incline to the opinion that part of it is an independent deposit. Heidenhain, however, found that, when thin sections of cartilage are digested for twenty-four hours in water, at from  $112^{\circ}$  to  $122^{\circ}$  F., or in diluted nitric acid with chlorate of potash for a greater or less time according to the degree of dilution, the matrix becomes parted or marked off into polygonal areas corresponding to the larger groups of cells, and these again into smaller groups or single cells, without any intervening substance ; the whole matrix thus appearing to be portioned out into segments, each appertaining to a larger or smaller group of cells, and in all probability representing the aggregated capsules belonging to them.

The vital changes which occur in cartilage take place very slowly. Its mode of nutrition has been already referred to ; it is subject to absorption, and when a portion is absorbed in disease or removed by the knife, it is not regenerated. Also, when fractured, as sometimes happens with the rib-cartilages, there is no re-union by cartilaginous matter, but the broken surfaces become connected, especially at their circumference, by fibrous or dense areolar tissue, often by a bony clasp.\* But, notwithstanding that normally it is not regenerated, hyaline cartilage occurs in perfectly characteristic form as a morbid product in certain tumours.

\* Recent observations tend to show that, in animals at least, the connective tissue which in the first instance joins the ends of a divided rib-cartilage eventually becomes itself transformed into true hyaline cartilage (Archangelsky, Barth.)

## ELASTIC OR YELLOW CARTILAGE.

The epiglottis and cornicula of the larynx, the cartilages of the ear and of the Eustachian tube, differ so much from the foregoing, both in intimate structure and outward characters, that they have been included

Fig. 47.

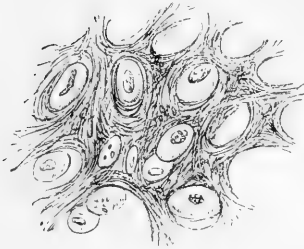


Fig. 47.—SECTION OF THE EPI-  
GLOTTIS, MAGNIFIED 350 DIAMET-  
ERS (Baly).

in a class apart, under the name of the “elastic,” “yellow,” or “spongy” cartilages. These are opaque and somewhat yellow, are more flexible and tough than the ordinary cartilages, and have little tendency to ossify. They are made up of cells and a matrix, but the latter is everywhere pervaded with fibres (fig. 47), except sometimes in a little area or narrow zone left round each of the cells. These fibres resist the action of acetic acid; they are in most parts short, straight, and confusedly intersecting each other in all directions, like the filaments in a piece of felt; in such parts the matrix has a rough indistinctly granular look. Here and there the fibres are longer and more fasciculated, but still interlace at short distances. In thin sections the cells readily drop out from the matrix, leaving empty the cavities which they occupied.

In the fœtus the matrix of elastic cartilage is at first homogeneous and hyaline, and the elastic fibres are subsequently produced in it. They appear first in those parts of the matrix which are in immediate connection with the cartilage-cells (Hertwig, Deutschmann). In the cartilage of the external ear this change occurs about the fifth month of intra-uterine life, and is said to commence in the more central parts, *i.e.*, those furthest from the perichondrium (Rabl-Rückhard.)

## WHITE FIBRO-CARTILAGE.

This is a substance consisting of a mixture of the fibrous and cartilaginous tissues, and so far partaking of the qualities of both. Like hyaline cartilage, it possesses firmness and elasticity, but these properties are united with a much greater degree of flexibility and toughness. It presents itself under various forms, which may be enumerated under the following heads.

1. *Interarticular* fibro-cartilages. These are interposed between the moving surfaces of bones, or rather of articular cartilages, in several of the joints. They serve to maintain the apposition of the opposed surfaces in their various motions, to give ease to the gliding movement, and to moderate the effects of great pressure. In the joint of the lower jaw and in that of the clavicle they have the form of round or oval plates, growing thinner towards their centre; in the knee-joint they are curved in form of a sickle, and thinned away towards their concave free edge. In all cases their surfaces are free; while they are fixed by synovial or fibrous membrane at their circumference or extremities. The synovial membrane of the joint is prolonged for a short distance upon these fibro-cartilages, from their attached margin.

2. The articular cavities of bones are sometimes deepened and extended by means of a rim or border of fibro-cartilage. A good example of one of these *circumferential* or *marginal* fibro-cartilages is seen in the hip-joint, attached round the lip of the cotyloid cavity.

3. *Connecting* fibro-cartilages are such as pass between the adjacent surfaces of bones in joints which do not admit of gliding motion, as at the symphysis of the pubes and between the bodies of the vertebræ. They have the general form of disks, and are composed of concentric rings of fibrous tissue with cartilage interposed; the former predominating at the circumference, the latter increasing towards the centre. The bony surfaces between which they pass are usually encrusted with true cartilage. The modifications which they present in particular instances are described in the special anatomy of the joints.

4. The bony grooves in which tendons of muscles glide are lined with a thin layer of fibro-cartilage. Small nodules of this tissue (*sesamoid fibro-cartilages*) may also be developed in the substance of tendons, of which there is an example in the tendon of the tibialis posticus, where it passes beneath the head of the astragalus. Lastly, fibro-cartilage is sometimes connected with muscular tissue, and gives attachment to muscular fibres, like that which is known to exist at the orifices of the heart.

Fibro-cartilage appears under the microscope to be made up of bundles of fibres, like those of ordinary ligament, with cartilage-cells intermixed; but the proportion of the two elements differs much in the different instances above enumerated. In general the fibrous tissue very greatly predominates, and in some cases, as in the interarticular laminae of the knee-joint, it constitutes almost the entire structure. In the intervertebral disks the cartilage-corpuseles are abundant towards the centre of the mass where the cartilaginous tissue prevails, and the substance is softer.

In chemical composition this texture agrees most with ligament, yielding gelatin when boiled.

Its blood-vessels are very few, and, according to Toynbee,\* are confined to the parts that are fibrous. Its vital changes are slow; it is subject to absorption, but much less readily so than bone; hence it is no uncommon thing to find the intervertebral disks entire when the adjacent bodies of the vertebræ have been destroyed by disease. It has not much tendency to ossify.

Little is known concerning the mode of development of fibro-cartilage. It is probable that the matrix is at first hyaline and that fibrous tissue is subsequently developed within it, but whether as an ingrowth from the perichondrium or not is not known with certainty.

## BONE OR OSSEOUS TISSUE.

The bones are the principal organs of support, and the passive instruments of locomotion. Connected together in the skeleton, they form a framework of hard material, which affords attachment to the soft parts, maintains them in their due position, and shelters such as are of delicate structure, giving stability to the whole fabric, and preserving its shape; and the different pieces of the skeleton, being joined

\* Phil. Trans. 1841.

moveably together, serve also as levers for executing the movements of the body.

While substantially consisting of hard matter, bones in the living body are covered with periosteum and filled with marrow; they are also pervaded by vessels for their nutrition.

**Physical Properties of Bone.**—Bone has a white colour, with a pink and slightly bluish tint in the living body. Its hardness is well known, but it also possesses a certain degree of toughness and elasticity; the last property is peculiarly well marked in the ribs. Its specific gravity is from 1·87 to 1·97.

**Chemical Composition.**—Bone consists of an earthy and an animal part, intimately combined together; the former gives hardness and rigidity, the latter tenacity, to the osseous tissue.

The earthy part may be obtained separate by calcination. When bones are burned in an open fire, they first become quite black, like a piece of burnt wood, from the charring of their animal matter; but if the fire be continued with free access of air, this matter is entirely consumed, and they are reduced to a white, brittle, chalk-like substance, still preserving their original shape, but with the loss of about a third of their weight. The earthy constituent, therefore, amounts to about two-thirds of the weight of the bone. It consists principally of phosphate of lime, with about a fifth part of carbonate of lime, and much smaller proportions of fluoride of calcium, chloride of sodium, and magnesian salts.

The animal constituent may be freed from the earthy, by steeping a bone in diluted hydrochloric acid. By this process the salts of lime are dissolved out, and a tough flexible substance remains, which, like the earthy part, retains the perfect figure of the original bone in its minutest details; so that the two are evidently combined in the most intimate manner. The animal part is often named the cartilage of bone, but improperly, for it differs entirely from cartilage in structure, as well as in physical properties and chemical nature. It is much softer and much more flexible, and by boiling it is almost wholly resolved into gelatin. It may accordingly be extracted from bones, in form of a jelly, by boiling them for a considerable time, especially under high pressure.

The earthy or saline matter of bone, as already stated, constitutes about two-thirds or 66·7 per cent., and the animal part one-third, or 33·3 per cent.; but from observations made on animals, it appears that the proportion of the several constituents may differ somewhat in different individuals of the same species under apparently similar conditions. The proportion of earthy matter appears to increase for some time after birth, and is considerably greater in adults than in infants; but, from the varying conditions of individuals as to health and nutrition in after life, there is as yet no thoroughly comparable series of experiments to determine whether any constant difference exists in old age. Moreover, it is not clearly established that the differences observed depend on the composition of the proper osseous substance; for the larger proportion of animal matter in infancy may be due to the greater vascularity of infantile bones and the difficulty of thoroughly removing the vessels from their pores. The spongy osseous tissue, carefully freed from fat and adhering membranous matter, has been found to contain rather less earth than the compact substance; and, in accordance with this result, differences, although on the whole insignificant, have been found in different bones of the skeleton, apparently depending on the relative amount of their compact and spongy tissue. (Rees, Von Bibra, Alphonse Milne-Edwards.) Here again it remains to be shown that the result is not due to differences in the

proportion of minute pores and lacunæ, which contain soft matter scarcely separable in such experiments.

Subjoined are the statements of two analyses. The one, by Berzelius, is well known; the other, which nearly agrees with it, was performed by Middleton, in the laboratory of University College.\*

|                                                         | Berzelius. | Middleton. |
|---------------------------------------------------------|------------|------------|
| Animal matter . . . . .                                 | 33·30      | — 33·43    |
| Phosphate of lime . . . . .                             | 51·04      | — 51·11    |
| Carbonate of lime . . . . .                             | 11·30      | — 10·31    |
| Fluoride of calcium . . . . .                           | 2·00       | — 1·99     |
| Magnesia, wholly or partially in the state of phosphate | 1·16       | — 1·67     |
| Soda and chloride of sodium . . . . .                   | 1·20       | — 1·68     |

In the compact substance of a femur that had been long buried, Aeby found only 16·5 per cent. of animal matter.

The phosphate of lime is peculiar, and passes in chemistry under the name of the "bone-earth phosphate." It is a tribasic phosphate. Von Bibra and A. Milne-Edwards† found the proportion of the carbonate of lime to the phosphate greater in spongy than in compact tissue, and less in infantile bones generally than in those of adults. The fluoride of calcium is found in larger quantity in fossil than in recent bones.

**Structure.**—On sawing up a bone, it will be seen that it is in some parts dense and close in texture, appearing like ivory; in others open and reticular: and anatomists accordingly distinguish two forms of osseous tissue, viz., the *compact*, and the *spongy* or *cancellated*. On closer examination, however, especially with the aid of a magnifying glass, it will be found that the bony matter is everywhere porous in a greater or less degree, and that the difference between the two varieties of tissue depends on the different amount of solid matter compared with the size and number of the open spaces in each; the cavities being very small in the compact parts of the bone, with much dense matter between them; whilst in the cancellated texture the spaces are large, and the intervening bony partitions thin and slender. There is, accordingly, no abrupt limit between the two,—they pass into one another by degrees, the cavities of the compact tissue widening out, and the reticulations of the cancellated becoming closer as they approach the parts where the transition takes place.

In all bones, the part next the surface consists of compact substance, which forms an outer shell or crust, whilst the spongy texture is contained within. In a long bone, the large round ends are made up of spongy tissue, with only a thin coating of compact substance; in the hollow shaft, on the other hand, the spongy texture is scanty, and the sides are chiefly formed of compact bone, which increases in thickness from the extremities towards the middle, at which point the girth of the bone is least, and the strain on it greatest. In tubular bones, such as those of the skull, the compact tissue forms two plates, or tables, as they are called, inclosing between them the spongy texture, which in such bones is usually named *diploe*. The short bones, like the ends of the long, are spongy throughout, save at their surface, where there is a thin crust of compact substance. In the complex or mixed bones, such as the vertebræ, the two substances have the same general relation to each other; but the relative amount of each in different parts, as well as their special arrangement in particular instances, is very various.

\* Philosophical Magazine, vol. xxv., p. 18.

† Ann. des Sc. Nat. 4me Série, vol. xiii., 1860.

On close inspection the cancellated texture is seen to be formed of slender bars or spicula of bone and thin lamellæ, which meet together and join in a reticular manner, producing an open structure which has been compared to lattice-work (*cancelli*), and hence the name usually applied to it. In this way considerable strength is attained without undue weight, and it may usually be observed that the strongest laminae run through the structure in those directions in which the bone has naturally to sustain the greatest pressure. The open spaces or areolæ of the bony network communicate freely together; in the fresh state they contain marrow or blood-vessels, and give support to these soft parts.

Fig. 48.

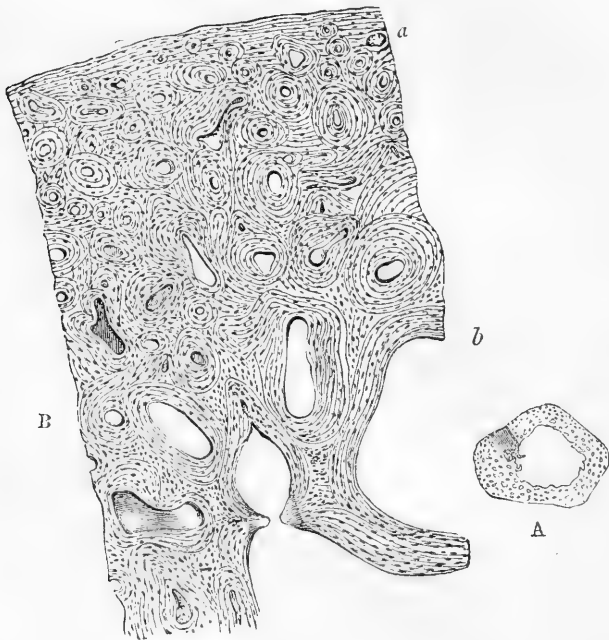

Fig. 48.—A, TRANSVERSE SECTION OF A BONE (ULNA) DEPRIVED OF ITS EARTH BY ACID.

The openings of the Haversian canals seen. Natural size. A small portion is shaded to indicate the part magnified in Fig. B.

B, PART OF THE SECTION A, MAGNIFIED 20 DIAMETERS.

The lines indicating the concentric lamellæ are seen, and among them the lacunæ appear as little dark specks.

The compact tissue is also full of holes; these, which are very small, are best seen by breaking across the shaft of a long bone near its middle and examining it with a common magnifying glass. Numerous little round apertures (fig. 48 A) may then be seen on the broken surface, which are the openings of short longitudinal passages running in the compact substance, and named the **Haversian canals**, after Clopton Havers, an English physician and writer of the seventeenth

century, who more especially called attention to them. Blood-vessels run in these canals, and the widest of them also contain marrow. They are from  $\frac{1}{1000}$ th to  $\frac{1}{200}$ th of an inch in diameter: there are some no more than  $\frac{1}{2000}$ th, but these are rare; the medium size is about  $\frac{1}{500}$ th. The widest are those nearest the medullary cavity, and they much smaller towards the circumference of the bone. They are quite short, as may be seen in a longitudinal section, and somewhat crooked or oblique at their ends, where they freely open into one another, their oblique communications connecting them both longitudinally and laterally. Those also which are next the circumference of the bone, open by minute pores on its external surface, and the innermost ones open widely into the medullary cavity; so that these short channels collectively form a sort of irregular network of tubes running through the compact tissue, in which the vessels of that tissue are lodged, and through the medium of which these vessels communicate together, not only along the length of the bone, but from its surface to the interior through the thickness of the shaft. The canals of the compact tissue in the other classes of bones have the same general characters, and for the most part run parallel to the surface.

On viewing a thin transverse section of a long bone with a microscope of moderate power, especially after the earthy part has been removed by acid (fig. 48 B), the opening of each Haversian canal appears to be surrounded by a series of concentric rings. This appearance is occasioned by the transverse sections of concentric **lamellæ** which surround the canals. The rings are not all complete, for here and there one may be seen ending between two others. In some of the sets, the rings are nearly circular, in others oval,—differences which seem mostly to depend on the direction in which the canal happens to be cut: the aperture too, may be in the centre, or more or less to one side, and in the latter case the rings are usually narrower and closer together on the side towards which the aperture deviates. Again, some of the apertures are much lengthened or angular in shape, and the lamellæ surrounding them have a corresponding disposition. Besides the lamellæ surrounding the Haversian canals, there are others disposed conformably with the circumference of the bone (fig. 48 B, *a*), and which may therefore be said to be concentric with the medullary canal; some of these are near the surface of the bone, others run between the Haversian sets, by which they are interrupted in many places. Lastly, in various parts of the section, lines are seen which indicate lamellæ, differing in direction from both of the above-mentioned orders. As to the circumferential laminae, Tomes and De Morgan state that they are by no means so common as is generally supposed; further, that they are most conspicuous in bones of full growth, in which, consequently, nutritive changes proceed slowly; and that their presence may be made the means of determining, within certain limits, the age at which a bone has arrived.

The appearance in a longitudinal section of the bone is in harmony with the account above given: the sections of the lamellæ are seen as straight and parallel lines, running in the longitudinal direction of the bone, except when the section happens to have passed directly or slantingly across a canal; for wherever this occurs there is seen, as in a transverse section, a series of rings, generally oval and much lengthened on account of the obliquity of the section.

The cancellated texture has essentially the same lamellar structure. The slender bony walls of its little cavities or areolæ are made up of superimposed lamellæ, like those of the Haversian canals (fig. 48 B, *b*), only they have fewer lamellæ in proportion to the width of the cavities which they surround; and, indeed, the relative amount of solid matter and open space constitutes, as already said, the only difference between the two forms of bony tissue; the intimate structure of the solid substance and the manner of its disposition round the cavities being essentially the same in both.

Besides the openings of Haversian canals as above described, a transverse section of the compact bone now and then presents vacuities or spaces formed by absorption of the tissue. These are named "Haversian spaces" by Tomes and De Morgan, who first showed that they occur not only in growing bone but at all periods of life. In their primitive condition these cavities are characterised by an irregular or eroded outline, and their formation by absorption is further indicated by their encroaching on the adjacent groups of concentric lamellæ, which have been, as it were, eaten away to a greater or less extent to give place to the new cavity. In another stage the spaces in question are lined by new-formed lamellæ, which may as yet be confined to the peripheral part of the vacuity, or may fill it up in a concentric series, leaving a Haversian aperture in the middle, and in fact, constituting a system of concentric Haversian lamellæ, interpolated or intruded among those previously existing. The concentric lamellæ, which thus come to occupy a greater or less extent of the area of the cavity, are of course bounded exteriorly by segments of adjoining sets of Haversian lamellæ, which have been more or less cut in upon in the excavation of the space. It has been further observed by Tomes and De Morgan, that vacuities may sometimes be seen which are being filled up at one part by the deposition of lamellæ, whilst they are extending themselves by absorption at another. The Haversian spaces are most numerous in young and growing bones; but, as already stated, they occur also after growth is completed. Their origin and changes will be better understood after the reader has perused the account of the growth and development of bone, to which head, indeed, the subject more properly belongs, although it has seemed expedient to introduce it here.

All over the section numerous little dark specks are seen among the lamellæ. These were named the "osseous corpuscles;" but as it is now known that they are in reality minute cavities existing in the bony substance, the name of **lacunæ** has since been more fittingly applied to them. To see the lacunæ properly, however, sections of unsoftened bones must be prepared and ground very thin, and a magnifying power of from 200 to 300 must be employed. Such a section, viewed with transmitted light, has the appearance represented in fig. 49. The openings of the Haversian canals are seen with their encircling lamellæ, and among these the corpuscles or lacunæ, which are mostly ranged in a corresponding order, appear as black or dark brown and nearly opaque oblong spots, with fine dark lines extending from them and causing them to look not unlike little black insects; but when the same section is seen against dark ground, with the light falling on it (as we usually view an opaque object), the little bodies and lines appear quite white, like figures drawn with chalk on a slate, and the intermediate substance, being transparent, now appears dark.



The lacunæ, as already stated, are minute recesses in the bone, and the lines extending from them are fine pores or tubes named "canaliculi," which issue from their cavity. The lacunæ present some variety of figure, but in such a section as that represented they for the most part appear irregularly fusiform, and lie nearly in the same direction as the lamellæ between which they are situated; or, to speak more correctly,

Fig. 49.

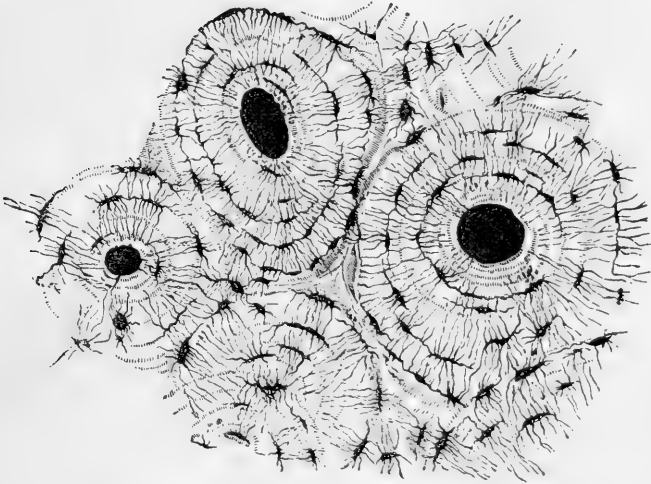


Fig. 49.—TRANSVERSE SECTION OF COMPACT TISSUE (OF HUMERUS) MAGNIFIED ABOUT 150 DIAMETERS.

Three of the Haversian canals are seen, with their concentric rings; also the corpuscles or lacunæ, with the canaliculi extending from them across the direction of the lamellæ. The Haversian apertures had become filled with débris in grinding down the section, and therefore appear black in the figure, which represents the object as viewed with transmitted light.

the little cavities are flattened and extended conformably with the lamellæ; for when the bone is cut longitudinally, their sections still appear fusiform and lengthened out in the direction of the lamellæ. The canaliculi, on the other hand, pass across the lamellæ, and they communicate with those proceeding from the next range of lacunæ, so as to connect the little cavities with each other; and thus since the canaliculi of the most central range open into the Haversian canal, a system of continuous passages is established by these minute tubes and their lacunæ, along which fluids may be conducted from the Haversian canal through its series of surrounding lamellæ; indeed, it seems probable that the chief purpose of these minute passages is to allow nutrient matter to be conveyed from the vascular Haversian canals through the mass of hard bone which lies around and between them. In like manner the canaliculi open into the great medullary canal, and into the cavities of the cancellated texture; for in the thin bony parietes of these cavities lacunæ are also contained; they exist, indeed, in all parts of the bony tissue. As first shown

by Virchow, each lacuna is occupied by a nucleated cell, or soft corpuscle, which sends branches along the canaliculi; and later observers (Rouget, Neumann,) state that they have been able to detach the proper osseous wall of the lacuna and its appertaining canaliculi after decalcification, and to obtain it separate with its included corpuscle. It can scarcely be doubted that the protoplasm of the nucleated corpuscle takes an important share in the nutritive process in bone, and very probably serves both to modify the nutritive fluid supplied from the blood and to further its distribution through the lacunar and canalicular system of the bony tissue. Virchow considers that the corpuscles of bone are homologous with those of connective tissue: to this it may be added that the enclosing lacunæ and canaliculi may be looked upon as corresponding to the cell-spaces (Saft-canälchen) of that tissue.

To return to the lamellæ. With a little pains, thin films may be peeled off in a longitudinal direction from a piece of bone that has been softened in acid. These for the most part consist of several laminae, as may be seen at the edge, where the different layers are usually torn unequally, and some extend farther than others. Examined in this way, under the microscope, the lamellæ are seen to be perforated with fine apertures placed at very short distances apart. These apertures were described by Deutsch,\* but they have not much attracted the notice of succeeding observers; they appear to be the transverse sections

Fig. 50.




Fig. 50. — THIN LAYER  
PEELED OFF FROM A SOFT-  
ENED BONE, AS IT APPEARS  
UNDER A MAGNIFYING  
POWER OF 400.

This figure, which is intended to represent the reticular structure of a lamella, gives a better idea of the object when held rather farther off than usual from the eye.

points of intersection, for they cannot be teased out from one another; but at the torn edge of the lamella they may often be seen

of the canaliculi already described, and their relative distance and position accord sufficiently with this explanation. According to this view, therefore, the canaliculi might (in a certain sense) be conceived to result from the apposition of a series of perforated plates, the apertures of each plate corresponding to those of the plates contiguous with it; in short, they might be compared to holes bored to some depth in a straight or crooked direction through the leaves of a book, in which case it is plain that the perforations of the adjoining leaves would correspond; it being understood, however, that the passages thus formed are most likely bounded by proper parietes. The apertures now referred to must be distinguished from larger holes seen in some lamellæ, which give passage to the perforating fibres to be mentioned further on.

But the lamellæ have a further structure. To see this, the thinnest part of a detached shred or film must be examined, as shown in figs. 50 and 52; it will then appear plainly that they are made up of transparent fibres, decussating with each other in the form of an exceedingly fine network. The fibres intersect obliquely, and they seem to coalesce at the

\* De Penitiori Ossium Structurâ. Wratisl. 1834, p. 17, Fig. 6.

separate for a little way, standing out like the threads of a fringe. Most generally they are straight, as represented in the figure; but they are not always so, for in some parts they assume a curvilinear direction. Acetic or hydrochloric acid causes these fibres to swell up and become indistinct, like the white fibres of connective tissue; care must therefore be taken in their examination that the remains of the decalcifying acid be removed from the tissue, by maceration in water or in solution of an alkaline carbonate. Moreover, the fibro-reticular structure is not equally distinct in all parts where its presence is recognisable; for in some places it is less decidedly marked, as if the fibrillation were incompletely developed.

In many instances the lamellæ are perforated by fibres, or rather bundles of fibres, which pass through them in a perpendicular, or oblique direction, and, as it were, bolt them together. These **perforating fibres** may be seen, with the aid of the microscope, in a thin transverse slice of a decalcified cylindrical or cranial bone, on pulling asunder the sections of the lamellæ (as in fig. 51). In this way some lamellæ will generally be observed with fibrous processes attached to them (fig. 51 *b*) of various lengths, and usually tapering and pointed at their free extremities, but sometimes truncated—probably from having come in the way of the knife. These fibres have obviously been drawn out from the adjacent lamellæ, through several of which they must have penetrated. Sometimes, indeed, indications of perforations may be recognised in the part of the section of bone from which the fibres have been pulled out (fig. 51 *c*). The processes in question are thus, so to speak,

Fig. 51.

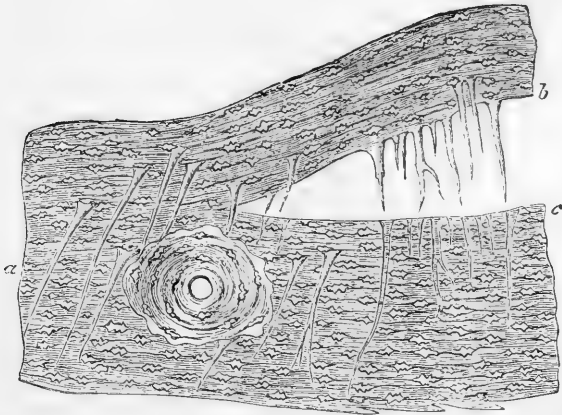


Fig. 51.—MAGNIFIED VIEW OF A PERPENDICULAR SECTION THROUGH THE EXTERNAL TABLE OF A HUMAN PARIETAL BONE, DECALCIFIED.

At *a*, perforating fibres in their natural situation; at *b*, others drawn out by separation of the lamellæ; at *c*, the holes or sockets out of which they have been drawn (H. Müller).

viewed in profile; but they may frequently also be seen on the flat surface of detached lamellæ, projecting like nails driven perpendicularly

or slantingly through a board (fig. 52, *c*); whilst the lamellæ at other parts present obvious apertures of considerable size, through which perforating fibres had passed (as at *a*).

These perforating fibres exist very generally in the bones of vertebrata. The late Henry Müller, of Würzburg, has supplied many details respecting their arrangement in man and mammalia.\* Kölliker considers them to be connected with the periosteum, and this, no doubt, is the case with some of them—some of those, for example, which penetrate the external table of the cranial bones; but in cross sections of cylindrical bones they often appear to spring, with their broad ends, from the deeper lamellæ, and taper outwards into fine points, which do not reach the periosteum; although without doubt they must, like the bony layers in which they occur, have been formed by subperiosteal ossification. They are rarely found, and when present are smaller, in the concentric systems of Haversian lamellæ; in this case they must of course have been formed from the osteoblastic tissue (similar in nature to that under the periosteum) which occupied the medullary spaces and produced the concentric laminæ. Perforating fibres exist abundantly in the *crusta petrosa* of the teeth.

Fig. 52.

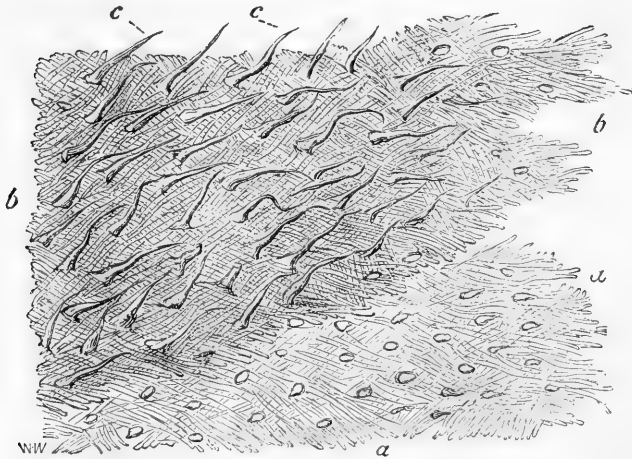


Fig. 52.—LAMELLE TORN OFF FROM A DECALCIFIED HUMAN PARIETAL BONE AT SOME DEPTH FROM THE SURFACE.

*a*, a lamella, showing reticular fibres; *b*, *b*, darker part, where several lamellæ are superposed; *c*, *c*, perforating fibres. Apertures through which perforating fibres had passed, are seen especially in the lower part, *a*, *a*, of the figure. Magnitude as seen under a power of 200, but not drawn to a scale (from a drawing by Allen Thomson).

The perforating fibres, or rather bundles of fibres, for the most part agree in character with the white fibrous tissue, but some, according to H. Müller, are of the nature of elastic tissue. H. Müller has shown that in some parts the fibres escape calcification, and thus, as they shrink in drying, leave tubes or channels in the dry bone, generally leading from the surface inwardly. In this way he explains the nature and mode of production of the "tubes" described by Tomes and De Morgan as penetrating the bone in certain situations, and conjectured by them to be modified lacunæ.† There can be no doubt of the correctness of

\* Würzburger Naturw. Zeitschr., vol. i., p. 296.

† Phil. Trans. 1853, p. 116.

Müller's explanation : at the same time it is equally certain that uncalcified fibres, though numerous at particular spots, are by no means so frequent as might be inferred from Müller's account of them, and that the perforating fibres may be said to be generally calcified. Finally, these fibres seem to have no physiological significance : they may be regarded as merely a modification of the mechanical structure of the tissue.

In a thin transverse section of hard bone, the concentric lines, or rather bands which represent the cut edges of the lamellæ, generally present, with transmitted light, a dark granular-looking, and a light, transparent, and usually narrower zone. Under a high power of the microscope the former appears thickly dotted over with fine dark points. In a decalcified section the dark part shows a multitude of short bright lines running radially across it, with dark angular particles between them. The lines are probably caused by pores and fine clefts passing through the lamella ; the appearance of dark particles seems to be produced by the cut ends of the reticulating fibres of which the lamellæ are made up. A longitudinal section of a cylindrical bone carried across the lamellæ presents a corresponding appearance, for as the fibres run more or less obliquely to the axis of the bone, they present cut ends in a longitudinal section also.

It thus appears that the animal basis of bone is made up of lamellæ composed of fine reticular fibres ; but interposed among these lamellæ, layers are here and there met with of a different character, viz. :—

1. Strata of amorphous or granular aspect, in which the lacunæ are very conspicuous and regularly arranged, and sometimes appearing as if surrounded by faintly defined areolæ. These generally incomplete layers are often bounded by a scalloped border, as if made up of confluent round or oval bodies ; this is indicated also by the occasional occurrence of oval or flattened spheroidal bodies singly or in small groups near the border of these layers, each with a cavity in the centre. In fact, if the round bodies shown in figure 53 had a central cavity, they would very well represent the objects here referred to. In some parts the granular substance is obscurely fibrous, and transitions may be observed to the well-marked reticular laminæ. The layers described appear principally to occur near the surface of the compact tissue, and at the circumference of many of the systems of concentric Haversian lamellæ.

2. Irregular layers of rounded bodies, apparently solid and without central cavity or mark, well represented in figure 53, which is after a drawing from nature by Dr. A. Thomson. These layers are met with chiefly near the surface of the shaft of long bones, lying among the circumferential laminæ, and apparently forming only part of a circuit. They can occasionally be recognised in a transverse section as short curvilinear bands of peculiar aspect, broader in the middle and thinning away at the ends, appearing here and there between the cut edges of two ordinary circumferential laminæ.

The appearances described under 1 and 2, and especially the last, as represented in fig. 53, may be accounted for by the explanation offered by Professor C. Lovén, of Stockholm, on seeing the figure and specimens ; viz. that the surface covered apparently with globular bodies, single or in botryoidal groups, is really a cast in relief from a contiguous surface of bone that has been excavated by absorption. It is known that in the growth of a bone absorption occurs at various parts, and is often followed by fresh ossific deposition ; as, for example, in the excavation and subsequent filling up of the Haversian spaces. The absorption in such cases is a healthy process, but the absorbed surface is, as in absorption from disease, eroded or scooped out into sinuous hollows, the larger of which are again carved on the inside into smaller rounded pits (foveolæ). New osseous matter deposited on such a surface fills up its hollows, and, when the new layer is detached, it exhibits a raised impression corresponding with them.\*

\* Two observations which I have had occasion to make favour this explanation. A cross section of a (large) serpent's rib shows an outer and an inner series of concentric lamellæ surrounding the medullary canal, and the inner trenches on the outer by a festooned

Fig. 53.

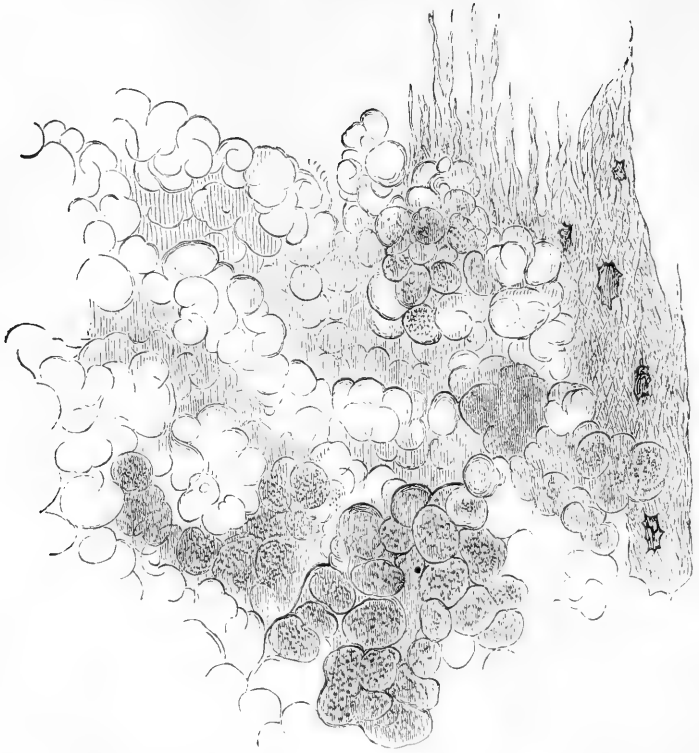


Fig. 53.—PORTION OF A NODULATED LAYER OF BONE-TISSUE FROM NEAR THE SURFACE OF THE SHAFT OF A DECALCIFIED HUMERUS.

At one side shreds of fibrous lamellæ are seen in the figure. Magnified 300 diameters.

**Ossified cartilage** is found on the articular ends of adult bones, lying underneath the natural cartilage of the joint, both in the moveable articulations and in symphyses, and is in fact the deeper part of the cartilage which has been encroached upon by the calcifying process.

border such as often bounds a series of Haversian rings. Now, in the decalcified rib, it is easy to peel off the inner from the outer layers, and the detached surface of the former shows a number of oval eminences, some with one, others with two, three, or more lacunæ in their substance; whilst what was the contiguous surface of the outer layers has excavations that correspond. Again, in the grinding tooth of the horse, the surface of the crista petrosa which is contiguous to the dentine or to the enamel, is marked over with spheroidal bodies having, in decalcified specimens, very much the appearance represented in Fig. 53, but most of them with one or more lacuna-like cavities within. They look very like distinct globules, and were described by Czernak as calcified cells containing lacunæ; but on carefully viewing the decalcified layer in profile-sections and otherwise, I am led to the conclusion that they are mamillary elevations of the surface, continuous by their (sometimes contracted) bases with the general substance. The enamel is destroyed in the decalcification, but the surface of the dentine of the cervix and root from which the mamillated layer of crista petrosa has been detached, is found to be excavated in a manner to correspond with it; an arrangement well calculated to secure their mutual connection. [w.s.]

The animal basis is here, however, of a totally different nature from that of the bone beneath ; for, when the earthy matter is extracted by means of an acid, the tissue which remains has all the characters of cartilage.

As to the mode in which the earthy matter is connected with the animal substance, we know that the combination is very intimate, but the manner in which it is effected is not fully understood ; probably there is a chemical union between the collogenuous matter and the earthy salts.

The **periosteum**, as already stated, is a fibrous membrane which covers the bones externally. It adheres to them very firmly, and invests every part of their surface, except where they are covered with cartilage or connected to other bones by fibro-cartilage. According to Kölliker it is composed of two different layers ; the outer, consisting of white fibres, and containing occasional fat-cells, is the means of supporting numerous blood-vessels destined for the bone, which ramify in the membrane, and at length send their minute branches into the Haversian canals of the compact substance, accompanied by processes of filamentous tissue derived from, or at least continuous with, the periosteum. The inner layer is made up of elastic fibres ; and frequently presents the appearance of several distinct strata of "elastic membrane." Between those, however, and the proper osseous tissue there is, in the young bone at least, a fibrous stratum containing a number of granular corpuscles (fig. 62, *c*). Fine nerves spread out in the periosteum ; they are chiefly associated with the arteries, and for the most part destined for the subjacent bone ; but some are for the membrane itself. By treating the membrane with nitrate of silver, lymphatics are discovered in it accompanying the blood-vessels, and, as in other aponeurotic structures, extensive epithelioid markings, covering a great part of the surface, are brought into view.

The chief use of this membrane is evidently to support the vessels going to the bone, and afford them a bed in which they may subdivide into fine branches, and so enter the dense tissue at numerous points. Hence, when the periosteum is stripped off at any part, there is great risk that the denuded portion of the bone will die and exfoliate. The periosteum also contributes to give firmer hold to the tendons and ligaments where they are fixed to bones ; indeed, these fibrous structures become continuous and incorporated with it at their attachment. Its relation to the growth of bone will be referred to later on.

The **marrow** (*medulla ossium*) is lodged in the interior of the bones ; it fills up the hollow shaft of long bones and occupies the cavities of the cancellated structure ; it extends also into the Haversian canals—at least into the larger ones—along with the vessels. A fine layer of a highly vascular areolar tissue lines the medullary canal, as well as the smaller cavities which contain marrow ; this has been named the medullary membrane, internal periosteum, or endosteum ; but it cannot be detached as a continuous membrane. Its vessels partly supply the contiguous osseous substance, and partly proceed to the clusters of adipose vesicles, among which there is but very little connective tissue, in consequence perhaps of their being contained and supported by bone.

The marrow differs considerably in different situations. Within the shaft of the long bones it is of the character of ordinary adipose tissue,

and contains, in 100 parts, 96 of fat, 1 of connective tissue, and 3 of water. In short bones, and in the cancellated ends of long bones, but especially in the cranial diploe, the bodies of the vertebræ, the sternum, and the ribs, it is red or reddish in colour, of more fluid consistence, and with very few fat-cells. That from the diploe consists of 75 parts of water and 25 of solid matters, which are chiefly albumin, fibrin, extractive and salts, with mere traces of fat. While, however, the fat-cells are scanty in the red-coloured marrow, it contains numerous roundish nucleated cells—the proper *marrow cells* of Kölliker. These, which in general appearance resemble the pale corpuscles of the blood, and like them exhibit amœboid movements, are supported by a fine reticulum of connective tissue. They vary somewhat in size, and many of them present a reddish colour, resembling somewhat in appearance the nucleated primitive red corpuscles of the embryo; indeed, it is stated that ordinary red-blood corpuscles are produced from them (Neumann, Bizzozero). Other cells have occasionally been noticed containing one or more red corpuscles in their interior: whether these have been developed *in situ* in a manner similar to that previously described in connective tissue corpuscles of the young animal, or have been taken into the interior of an amœboid cell, there to be transformed into pigment granules, is not certainly known. Cells containing reddish pigment granules are, however, not uncommon. In addition to these smaller cells, and larger ones which resemble connective tissue-corpuscles, there occur in the marrow, especially in the neighbourhood of the osseous substance, large multi-nucleated protoplasmic masses (myeloplagues, Robin), which, as pointed out by Kölliker, appear to be more especially concerned with the process of absorption of bone, under which they will consequently be described.

**Blood-vessels.**—The bones are well supplied with blood-vessels. A network of periosteal vessels covers their outward surface; others penetrate to the cavities of the spongy part and the medullary canal, on the sides of which they ramify; and fine vessels, deprived of their muscular coat, run through all parts of the compact tissue in the Haversian canals. The sides of these internal cavities and canals make up together a large extent of inward surface on which vessels are spread. The nutritious fluid conveyed by these vessels no doubt escapes through their coats and permeates the surrounding dense bone interposed between the vascular canals, and it seems highly probable that the system of lacunæ and communicating canaliculi, already described, is a provision for conducting the exuded fluid through the hard mass. When a bone is macerated, its vessels and membranes are destroyed, whilst the intermediate true bony matter, being of an incorruptible and persistent nature, remains; a process which, for obvious reasons, cannot be effected with the soft tissues of the body.

The vessels of bone may be recognised while it is yet fresh by the colour of the blood contained in them; but the vascularity of the tissue is rendered much more conspicuous by injecting a limb with size and vermilion, depriving the bones of their earth by means of an acid, and then drying them and putting them into oil of turpentine, by which process the osseous tissue is rendered transparent whilst the injected matter in the vessels retains its red colour and opacity. Numberless small vessels derived from the periosteum, as already mentioned, pass along the Haversian canals



in the compact substance. These are both arterial and venous, but according to Todd and Bowman, the two kinds of vessels occupy distinct passages; and the veins, which are the larger, are said to present, at irregular intervals, pouch-like dilatations. Arteries, of larger size but fewer in number, proceed to the cancellated texture. In the long bones numerous apertures may be seen at the ends, near the articular surfaces; some of these give passage to the arteries referred to, but the greater number, as well as the larger of them, are for the veins of the cancellated texture, which run separately from the arteries. Lastly, a considerable artery goes to the marrow in the central part of the bone; in the long bones this medullary artery, often, but improperly, called "the nutritious artery," passes into the medullary canal, near the middle of the shaft, by a hole running obliquely through the compact substance. The vessel, which is accompanied by one or two veins, then sends branches upwards and downwards to the marrow and medullary membrane in the central cavity and the adjoining Haversian canals; from these branches capillaries pass radially towards the periphery. The comparatively narrow arterial capillaries pass suddenly into the wide venous ones, so that the current of blood must be considerably retarded both in these and in the large thin-walled veins. The blood contained in these is said to possess a large number of pale corpuscles, as well as transitions from these to the red. The ramifications of the medullary artery anastomose with the arteries of the compact and cancellated structure; indeed, there is a free communication between the finest branches of all the vessels which proceed to the bone, and there is no strictly defined limit between the parts supplied by each. In the thigh-bone there are two medullary arteries entering at different points.

The veins of the cancellated texture are peculiar and deserve special notice. They are large and numerous, and run separately from the arteries. Their arrangement is best known in the bones of the skull, where, being lodged in the diploe or spongy texture between the outer and inner compact tables, they have received the name of the diploic veins. They run in canals formed in the cancellated structure, the sides of which are constructed of a thin lamella of bone, perforated here and there for the admission of branches from the adjoining cancelli. The veins, being thus inclosed and supported by the hard structure, have exceedingly thin coats. They issue from the bone by special apertures of large size. A similar arrangement is seen in the bodies of the vertebræ, from whence the veins come out by large openings on the posterior surface.

The **lymphatics** of the bones are but little known; still, there is evidence of their existence, for, independently of the authority of Mascagni (who, however, does not state that he injected the vessels which he took for the lymphatics of bone), we have the testimony of Cruikshank, who injected lymphatics coming out of the body of one of the dorsal vertebræ, in the substance of which he also saw them ramifying.\* The lymphatics in the periosteum have been already noticed (p. 91).

Fine **nerves** have been seen passing into the medullary canal of some of the long bones along with the artery, and following its ramifications, but their ultimate distribution is doubtful; and Kölliker describes fine

\* Anatomy of the Absorbing Vessels, 1790, p. 198.

nervous filaments as entering with the arteries of the bone to the spongy and compact tissue. As far, however, as can be judged from observations on man and experiments on the lower animals, the bones, as well as their investing periosteum, are scarcely if at all sensible in the healthy condition, although they are painfully so when inflamed.

Some hold that the same is true of the marrow, or rather the medullary membrane; others, among whom are Duverney and Bichat, affirm, on the contrary, that the medullary tissue is sensible. They state that, on sawing through the bone of a living animal, and irritating the medullary membrane by passing a probe up the cavity, or by injecting an acrid fluid, very unequivocal signs of pain will be manifested. Beclard, who affirms the same fact, points out a circumstance which may account for the result occasionally turning out differently.—namely, that when the bone happens to be sawn through above the entrance of the medullary artery, the nerves going along with that vessel are divided, and the marrow consequently rendered insensible, as happens with any other sensible part when its nerves are cut.

#### FORMATION AND GROWTH OF BONE.

The foundation of the skeleton is laid at a very early period; for, among the parts that appear soonest in the embryo, we distinguish the rudiments of the vertebræ and base of the skull, which afterwards form the great median column to which the other parts of the bony fabric are appended. But it is by their outward form and situation only, that the parts representing the future bones are then to be recognised; for at that early period they do not differ materially in substance from the other structures of the embryo, being, like these, made up of granular corpuscles or elementary cells, united together by a soft amorphous matter. Very soon, however, they become cartilaginous, and ossification in due time beginning in the cartilage and continuing to spread from one or from several points, the bone is at length completed.

But, while it is true with respect to the bones generally that their ossification commences in cartilage, it is not so in every instance. The tabular bones forming the roof of the skull may be adduced as a decided example to the contrary; in these the ossification goes on in a membranous tissue quite different in its nature from cartilage;\* and even in the long bones, in which ossification undoubtedly commences and to a certain extent proceeds in cartilage, it will be afterwards shown that there is much less of the increment of the bone really owing to that mode of ossification than was at one time generally believed. It is necessary, therefore, to distinguish two species or modes of ossification, which for the sake of brevity may be called the *intramembranous* and the *intracartilaginous*.

**Ossification in membrane.**—The tabular bones of the cranium, as already said, afford an example of this mode of ossification. The base of the skull in the embryo is cartilaginous; but in the roof, that is to say, the part comprehending the parietal, the upper and greater part of the frontal, and a certain portion of the occipital bones, we find (except where they happen to be commencing muscular fibres) only the

\* This fact was pointed out and insisted on by Nesbitt, who distinguishes the two different modes of ossification, and so far his views are quite correct.—See his *Human Osteogeny*. Lond. 1736.

integuments, the dura mater, and an intermediate membranous layer, which differs from cartilage in its intimate structure as well as in its more obvious characters, and in which the ossification proceeds.

The commencing ossification of the parietal bone, which may be selected as an example, appears to the naked eye in form of a network in which the little bars or spicula of bone run in various directions, and meet each other at short distances. By-and-by the ossified part, becoming extended, gets thicker and closer in texture, especially towards the centre, and the larger bony spicula which now appear, run out in radiating lines to the circumference. The ossification continues thus to spread and consolidate until the parietal meets the neighbouring bones, with which it is at length united by a suture.

The figure (54) represents the parietal bone of an embryo sheep about two inches and a half long, and shows the character of the ossification as it appears when the object is magnified about twelve diameters. The bone is formed in membrane as in the human foetus, but a thin plate of cartilage rises up on its inside from the base of the skull. The ossification, however, is decidedly unconnected with the cartilage, and goes on in a membrane lying outside of it.

When further examined with a higher magnifying power, the tissue or membrane in which the ossification is proceeding, appears to be made up of fibres and granular corpuscles, with a soft amor-

phous or faintly granular uniting matter, and, in point of structure, might not unaptly be compared to connective tissue in a certain stage of development. The corpuscles are large, mostly two or three times the size of blood-corpuscles; their substance is granular in character, and, especially in specimens preserved in spirit, usually hides the nucleus. They are densely packed all over the area of ossification, covering the bony spicula, and filling up their interstices; so that, to bring the growing parts into view, the corpuscles must be brushed away with a hair pencil, or removed by short immersion of the specimen in weak solution of soda.

Fig. 54.

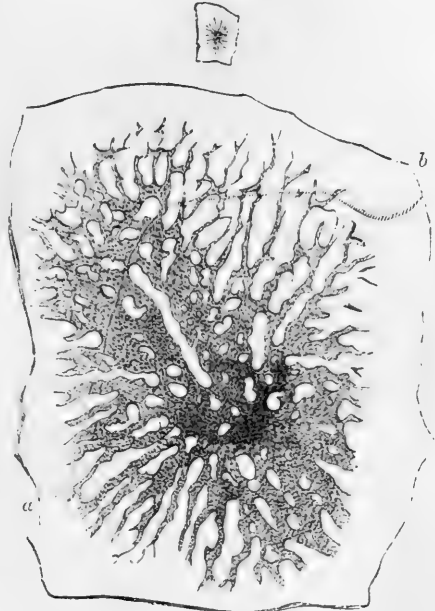


Fig. 54.—PARIETAL BONE OF AN EMBRYO SHEEP. SIZE OF THE EMBRYO, 2½ INCHES.

The small upper figure represents the bone of the natural size, the larger figure is magnified about 12 diameters. The curved line, *a*, *b*, marks the height to which the subjacent cartilaginous lamella extended. A few insulated particles of bone are seen near the circumference, an appearance which is quite common at this stage.

On observing more closely the points of the growing osseous rays at the circumference of the bone, where they shoot out into the soft tissue, it will be seen that the portion of them already calcified is granular and rather dark in appearance (fig. 55, *a, b, c*), but that this character is gradually lost as they are traced further outwards in the membrane, in which they are prolonged for a little way in form of soft and pliant bundles of transparent fibres (fig. 55, *f*). Further inwards, where the slender rods or bars of bone are already in great part hard, their calcified

Fig. 55.

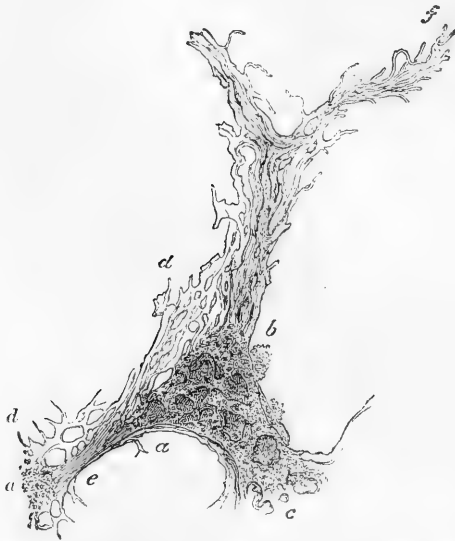

Fig. 55.—THE GROWING END OF A SPICULUM FROM THE PARIETAL BONE OF AN EMBRYO SHEEP at about the same period of advancement as in Fig. 54; magnified 150 diameters, but drawn under a power of 350 diameters.

*a, b, c,* and *a'*, parts already calcified; *d, d*, irregular network of soft and pellucid osteogenic substance, on which the calcification is encroaching; *a, c, a'*, a connecting bar or bridge still soft at *e*, but calcified at *a* and *a'*; *f*, extremity formed of bundles of soft osteogenic fibres. The structure represented was covered over and hidden by granular corpuscles, or osteoblasts, which have been removed. In the calcified part, *a, b, c*, superficial excavations are seen which are probably commencing or incomplete lacunæ, from which the corpuscles have been washed out. From a drawing by Prof. J. Marshall, F.R.S.

substance is coated over (although unequally) with transparent and as yet soft and imperfectly calcified matter, by which they grow in thickness; and this ossifying substance spreads out at their sides, and encroaches on the intervening space, in form of a bright trellis-work (fig. 55, *d*), thin towards its outer limit, and there composed of fine fasciculi, but denser and closer nearer the bone, where the trabeculæ are thick and round, and already granular from commencing earthy impregnation. The interstices of this mesh-work are in some parts occupied by one or more of the corpuscles, but at other parts they are reduced to short narrow clefts or mere pores. The appearance here described is especially well seen at those places where a cross bridge of bone is being formed between two long spicula (as at *e*); we may there distinguish the clear soft fibres or trabeculæ which have already stretched across the interval, and the darkish granular opacity indicating the earthy deposit (*a, a'*) may be perceived advancing into them and shading off gradually into their pellucid substance without a precise limit. This soft transparent matter, which becomes ossified, may, wherever it occurs, be distinguished by the name of "osteogenic substance," as proposed by H. Müller, or simply of "osteogen." It is or becomes fibrous in intimate structure, and for the most part finely reticular, like the decalcified

received advancing into them and shading off gradually into their pellucid substance without a precise limit. This soft transparent matter, which becomes ossified, may, wherever it occurs, be distinguished by the name of "osteogenic substance," as proposed by H. Müller, or simply of "osteogen." It is or becomes fibrous in intimate structure, and for the most part finely reticular, like the decalcified

bone itself, but must not be confounded with fibres which may pre-exist in the membranous tissue in which the bone is growing.

The granular corpuscles or cells everywhere cover, in a dense layer, the osteogenic substance, and lie in its meshes; most probably they yield or excrete that substance; hence the name "osteoblasts" has been assigned to them.

But some of the granular cells are involved in the ossifying matrix, and eventually inclosed in lacunæ. Single cells may accordingly be seen partially sunk in the recent osteogenic deposit, which then gradually grows over them and buries them in its substance; and the cavity in which the corpuscle is thus enclosed becomes a lacuna.

With regard to the formation of the canaliculi, some observers state that, when such a corpuscle is as yet but half sunk in the growing substance, processes may be seen passing from the imbedded side into fine clefts of the matrix, which close in around them and become the canaliculi: and that as the inclosure of the corpuscle is completed, canaliculi are in like manner formed in the rest of its circumference. It is also supposed that the canaliculi are afterwards extended by absorption, so as to anastomose with those of neighbouring lacunæ.

As the bone extends in circumference, it also increases in thickness; the vacancies between the bony spicula become narrowed or disappear, and at a more advanced period the tabular bones of the cranium are tolerably compact towards the centre, although their edges are still formed of slender radiating processes. At this time also numerous furrows are grooved on the surface of the bone in a similar radiating manner, and towards the centre these are continued into complete tubes or canals in the older and denser part, which run in the same direction. The canals, as well as the grooves, which become converted into canals, contain blood-vessels supported by processes of the investing membrane, and are lined with osteoblasts, which deposit concentric layers of bone inside these channels; and, when thus surrounded with concentric laminae, these tubular cavities are in fact Haversian canals.

It may here be observed that in earlier stages, such as that shown in fig. 54, vessels may be seen in the soft tissue, some twice or three times the size of a blood-capillary, others considerably more, but all with only a homogeneous coat with cells upon it here and there, and without a muscular layer.

**Ossification in cartilage.**—It has already been stated that, in by far the greater number of bones, the primitive soft cellular matter of which they originally consist is very quickly succeeded by cartilage, in which the ossification begins. One of the long bones taken from a very small embryo, just before ossification has commenced in it, is observed to be distinctly cartilaginous. In the tibia of a sheep, for example, at a time when the whole embryo is not more than an inch and a quarter in length, we can plainly see that the substance consists of cartilage-cells imbedded in a pellucid matrix. These cells, which can scarcely be said to be collected into groups, are much larger in the middle part of the shaft where ossification afterwards commences, and there also they are mostly placed with their long diameter across the direction of the bone: towards the ends they are much smaller and closer together, and the cartilage there is less transparent. As it enlarges, the cartilage acquires firmer consistence; it represents in figure the future bone, though of course much smaller in size, and it is surrounded with a

fibrous membrane or perichondrium, the future periosteum. Vessels ramify in this membrane, but none are seen in the cartilage until ossification is about to begin.

In a long bone the ossification commences in the middle and proceeds toward the ends, which remain long cartilaginous, as represented in fig. 56. At length separate points of ossification appear in them, and form epiphyses, which at last are joined to the body of the bone.

Fig. 56.

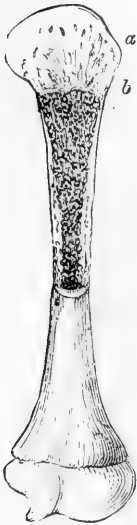

Fig. 56.—HUMERUS OF A FETUS, NATURAL SIZE.

The upper half is divided longitudinally. *a*, cartilage, *b*, bone, which terminates towards the cartilage by a slightly convex surface.

The newly formed osseous tissue is red and obviously vascular, and blood-vessels extend a little way beyond it into the adjoining part of the cartilage. In a long bone these precursory vessels are seen at either end of the ossified portion of the shaft, forming a red zone in that part of the cartilage into which the ossification is advancing. The vessels are lodged in excavations or branching canals in the cartilage, (fig. 56, *a*) which also contains granular corpuscles (osteoblasts). Other vascular canals enter the cartilage from its outer surface, and conduct vessels into it directly from the perichondrium; at least, this may be seen when the ossification approaches near to the ends of the bones.

Baly observed that in a transverse section of the ossifying cartilage, its cells appear arranged in radiating lines round the sections of the vascular canals; \* and it may also be here remarked that in many of these radiating groups the cells successively diminish in size towards the centre, that is, as they approach the canal. The canals which enter from the surface of the cartilage are probably formed by processes from the vascular subperichondrial tissue, which, excavating the canals by absorption, thus extend themselves through the mass of cartilage; and as the perichondrium affords material for the growth of the cartilage at the surface, so these vascular processes probably yield matter for the multiplication of the cells in the interior of the mass. The canals which pass into the cartilage from the ossified part are, in like manner, most probably formed by processes of the subperiosteal tissue which pierce the bone and extend through the medullary cavities within it to the cartilage, into which they penetrate for a short way beyond the advancing limit of ossification.

To examine the process more minutely, let an ossifying bone be divided lengthwise, as in fig. 56, and then from the surface of the section (as at *a*, *b*) take off a thin slice of cartilage, including a very little of the ossified part, and examine it with the microscope. Such a view, seen with a low power, is shown in fig. 57. The cartilage at a distance from the surface of the ossified part has its cells uniformly disseminated in the matrix, (as at *a*, where it appears in the figure as if granular.) but at and near to the limit where the ossification is encroaching upon it, the cells are gathered into rows or oblong groups, between which the transparent matrix appears in form of clear longitudinal lines (often obscurely striated) obliquely intersecting each other (*b*). Turning now

\* Müller's Physiology, plate I., fig. 16.

to the newly-formed bone (*c*), which from its dark opaque aspect contrasts strongly with the cartilage, and tracing it towards their mutual boundary, we see plainly the dark lines of ossification shooting up into the clear spaces of the cartilage between the groups of corpuscles. The earthy deposit, in fact, proceeds through the matrix, and affects also those parts of the cartilage-capsules which form the circumference of a group, so that the new osseous substance forms in the first instance

Fig. 57.




Fig. 58.

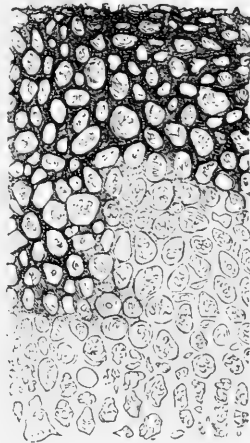


Fig. 57.—THIN LONGITUDINAL SECTION OF OSSIFYING CARTILAGE FROM THE HUMERUS OF A FETAL SHEEP.

*a*, cartilage-cells uniformly diffused; *b*, cells nearer the boundary of the ossification, collected into piles and inclosed in oblong areolæ of the clear matrix; *c*, dark lines of ossification extending into the matrix and forming the primary bony areolæ. Magnified about 70 diameters.

Fig. 58.—TRANSVERSE SECTION OF THE OSSIFYING CARTILAGE REPRESENTED IN Fig. 57.

Made a little above *c*, along the surface of ossification, and including part of the new bone, magnified 70 diameters. The circular sections of the groups of cells and of the osseous areolæ are seen; and the dark bone extending into the clear intercellular matrix.

oblong areolæ or loculi, which enclose the groups of cells. This is further illustrated by a thin transverse section, carried nearly parallel to the ossifying surface, and partly encroaching on it, so as to take off a little of the bone along with the cartilage, as represented in fig. 58.

In this view we see, at one part, the dark and nearly circular sections of the newly-formed osseous areolæ ; at another, sections of the rows of cartilage-cells with the clear matrix between and around them, and into this the dark ossification is advancing. It may frequently be observed, that here also, as in intramembranous ossification, the deposition of calcareous matter is preceded by the formation of an obscurely fibrous structure, extending between the rows of cells.

Fig. 59.

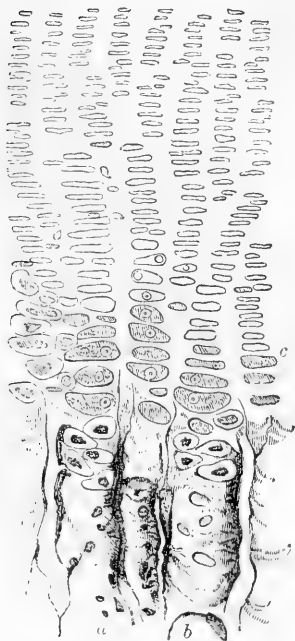


Fig. 59.—SMALL PORTION OF A SECTION SIMILAR TO THAT IN FIG. 57, MORE HIGHLY MAGNIFIED (ABOUT 140 DIAMETERS).

*a, b*, two of the new-formed osseous tubes or areolæ, with a few cartilage-cells and granular corpuscles lying in them; *c, c*, cartilage-cells near the ossifying surface, exhibiting the appearance described in the text.

place in the following manner. The *primary areolæ* of the bone above described open into one another both laterally and longitudinally by absorption of their intermediate walls, and by their confluence give rise to the larger or *secondary cavities*, the *medullary spaces* of H. Müller, which succeed them lower down. This is shown in a longitudinal section in fig. 60, and in transverse section in fig. 61, *A*, which represents a thin section made almost immediately below the

On using a higher power, as in fig. 59, it will be seen that the cells forming the groups are placed with their long diameter transversely, as if they had been flattened and piled upon one another; but in the immediate vicinity of the bone they become greatly enlarged and more rounded. As to the substance composing them, in some it is pellucid, strongly refracting the light, and nearly filling the capsule; in others faintly granular and light like ground glass, and has a well-defined outline, and in these there is a very distinct nucleus, varying much in size in different cells, but always most regularly circular, and inclosing one or more nucleoli; lastly, a good many cells may be seen, especially in the neighbourhood of the advancing blood-vessels, in which the contained mass or cell-body does not nearly fill the capsule, and then it is usually coarsely granular, with an uneven and, in some, a jagged outline.

It thus appears that the bony tissue, as it advances into the cartilage, has at first a sort of alveolar structure, made up of fusiform *areolæ* or short tubular cavities, with thin parietes, which are formed by calcification of the matrix and partial calcification of the capsules of the cartilage-cells. But this condition, which differs from that of perfect bone, is only transitory, and at a short distance below the ossifying surface we see a change taking place in the newly-formed tissue; the structure becomes more open, the original cartilage-cells disappear from its interstices, and the medullary spaces, with their lamellated parietes, as in the permanent cancellated tissue, begin to be formed. This, which is the next step of the process, takes

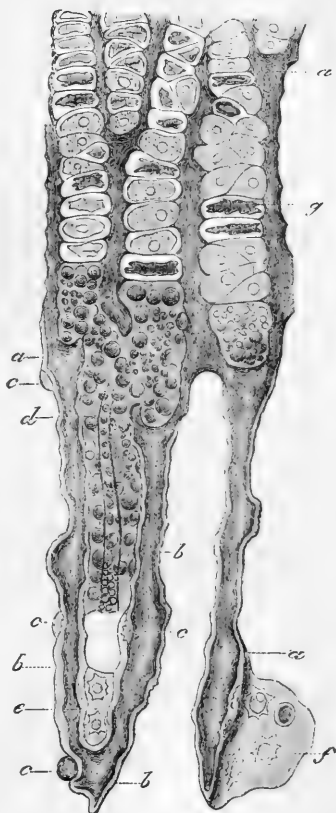


surface of ossification, and in which the primary cavities are seen to have coalesced into larger ones. A transverse section somewhat lower

Fig. 60.—THIN LONGITUDINAL SECTION OF THE GROWING END OF THE SHAFT OF THE METATARSAL BONE OF A SLINK CALF, MAGNIFIED.

The upper part of the figure shows four groups of cartilage-cells, with calcified matrix between them forming the walls of four primary areolæ filled as yet by the original cartilage-cells, except at the lower part, where these are replaced by osteoblasts. Lower down are two oblong spaces (secondary or medullary cavities); one, indicated by *d*, is nearly filled by osteoblasts and vessels, the other is vacant. The walls of these spaces are beginning to be lined with secondary osseous deposit, shown in the figure as a lighter layer, *b*, *b*, and *b*; *c*, *c*, and *c*, are corpuscles about to be imbedded in the ossifying substance and inclosed in laminae; *g*, a cartilage-cell of which the body has shrunk from the inside of the capsule (after H. Müller and Kölliker).

Fig. 60.



down, (fig. 61, B,) shows that they go on enlarging by further absorption and coalescence, and that their sides are thickened by layers of new bone; this soon begins to be deposited (fig. 60, *b*, *b*, in longitudinal and 61, A, in cross section), and goes on increasing, (fig. 61, B). In the meantime the cartilage-cells have disappeared, and the bony cavities are filled with soft matter, in which there are a few fibres and numerous granular corpuscles resembling the osteoblasts seen in the intramembranous ossification; there are also many blood-vessels. In the end, some of the enlarged cavities and open structure remain to form the cancellated tissue, but much of this structure is afterwards removed by absorption, to give place to the medullary canal of the shaft. In many of these cavities the walls of the coalesced primary areolæ may long be distinguished, like little arches, forming by their union a sort of festooned outline, within which the new bony laminae are situated.

The primary osseous matter forming the original thin walls of the areolæ, and produced by calcification of the cartilaginous matrix, is decidedly granular, and has a dark appearance; the subsequent or secondary deposit on the other hand is quite transparent, and of a uniform, homogeneous aspect. This secondary deposit begins to cover the granular bone a very short distance (about  $\frac{1}{50}$ th of an inch) below the surface of ossification, and, as already stated, increases in thickness further down. The lacunæ first appear in this deposit; there are none in the primary granular bone. The cartilage-cells do not become calcified. According to H. Müller the capsules are opened by absorption, and the granular bodies contained within them (*i.e.* the proper cell-bodies) produce by fissiparous multiplication

the granular osteoblastic cells which succeed them. On the other hand, Lovén\* has suggested, and, as it would seem, with more probability, that the osteoblastic corpuscles properly belong to the vascular processes of the subperiosteal tissue,

Fig. 61, A.

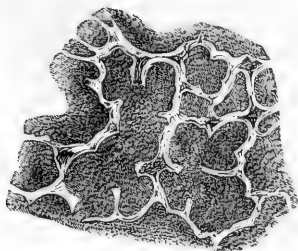


Fig. 61, B.

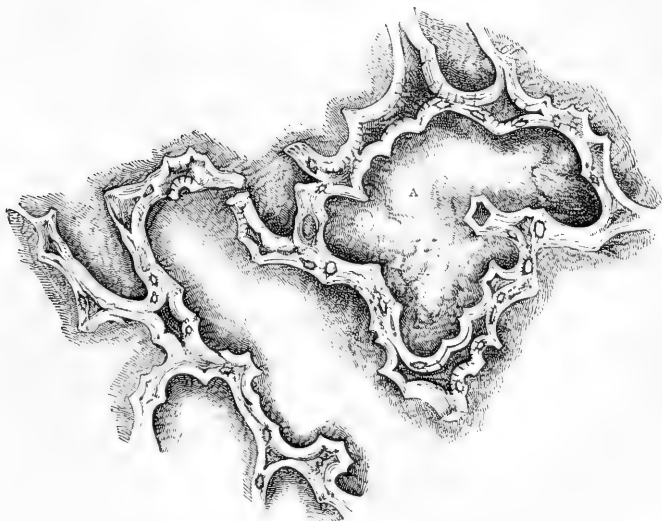


Fig. 61.—A AND B REPRESENT TWO TRANSVERSE SECTIONS OF GROWING BONE, AS IN FIG. 58, BUT MUCH MORE MAGNIFIED (ABOUT 120 DIAMETERS).

They show the lateral coalescence of the primary bony areolæ and the thickening of the sides of the enlarged cavities by new osseous deposit. The section A is made almost immediately below the surface of ossification; B, is somewhat lower, and shows the cavities still more enlarged and their sides more thickened than in A. The new osseous lining is transparent, and appears light in the figures; the dark ground within the areolæ is owing to opaque *débris*, which collected there in grinding the sections. It must be further noticed that the letter A within the larger figure, marks a place where a bony partition had been accidentally broken away, for the large space was naturally divided into two.

which, as already stated, penetrate the newly formed bone and spread throughout its cavernulated structure. The excavation and removal of the cartilage, as well as the partial absorption of the walls of the bony cavities, is no doubt effected by this tissue, and the abundant osteoblastic cells which appear in it are most

\* Studier och Undersökningar öfver Benväfnaden. Stockholm. 1863.

probably derived by descent from similar cells equally abundant beneath the periosteum. The cells or corpuscles in question, in whatever way produced, are disposed in a layer or layers upon the walls of the secondary or medullary spaces, in immediate contact with the new osteogenic deposit, which here, as in the intramembranous ossification, they probably produce (figs. 60, 62). Here too the osteogenic substance is finely reticular, and retains that character when calcified; for the secondary bony deposit is formed in layers made up of finely reticulating fibres, like the lamellæ of perfect bone shown in fig. 47. On a careful inspection, and with a certain adjustment of the light, fine striæ may be seen in many parts indicating the obliquely decussating fibres of the newly formed laminae. The structure in some measure reminds us of the secondary deposit inside the oblong cells of the wood of coniferous trees, in which the ligneous matter is arranged in fibres, or rather in fine lines, running obliquely round the wall of the cell and crossing one another in alternate layers.

The lacunæ are formed, as described in the intramembranous ossification, by some of the granular corpuscles becoming embedded in the osteogenic substance, and inclosed in a cavity formed round them by its further deposit (fig. 62*d*). Lacunæ formed from cartilage-cells exist but very scantily. Examples occur in articular cartilage, and in that of the pubic symphysis, when, as commonly happens in mature life, the part of these tissues adjoining the bone is encroached on by a species of ossification, as noticed at page 97. The ossifying process in this case is mere calcification of the cartilage, and stellate lacunæ, not intercommunicating by canaliculi, remain in the partially ossified cells. When this hard tissue is decalcified by an acid, the original cells and cartilaginous matrix become apparent.

As ossification advances towards the ends of the bone, the portion as yet cartilaginous continues to grow at the same time, and increases in every dimension. The part already osseous increases also in circumference; the medullary canal, of which for some time there is no appearance, begins to be excavated in the interior by absorption, and the sides of the shaft acquire compactness and solidity. The increase in girth is brought about by deposition of bone at the surface underneath the periosteum. It was at one time supposed that a formation of cartilage precedes the bone also in this situation; but such is not the case, for the vascular soft tissue in immediate contact with the surface of the growing bone is not cartilage, but a soft substance containing fibres and osteoblasts; in fact, the increase takes place by intramembranous ossification, and accordingly the Haversian canals of the shaft are formed in the same way as those of the tabular bones of the skull,—that is, the osseous matter is not only laid on in strata parallel to the surface of the bone, but is deposited around processes of the vascular membranous tissue which extend from the surface obliquely into the substance of the shaft (fig. 62); and the canals in which these vascular processes lie, becoming narrowed by the deposition of concentric osseous laminae, eventually remain as the Haversian canals.

Ossification having thus proceeded for some time in the shaft, at length begins in the extremities of the bone from one or more independent centres, and extends through the cartilage, leaving, however, a thick superficial layer of it unossified, which permanently covers the articular end of the bone. The epiphyses thus formed continue long separated from the shaft or diaphysis by an intervening portion of cartilage, which is at last ossified, and the bone is then consolidated.

**Growth and absorption of Bone.**—The time of final junction of the epiphyses is different in different bones; in many it does not arrive until the body has reached its full stature. Meanwhile

Fig. 62.

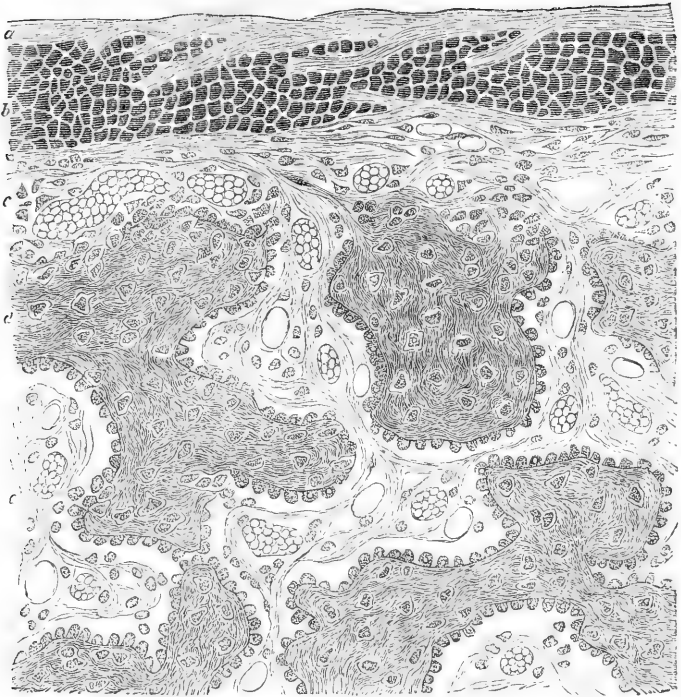


Fig. 62.—HIGHLY MAGNIFIED TRANSVERSE SECTION OF SUPERFICIAL PART OF FEMUR—  
HUMAN FŒTUS (Klein).

*a, b, c*, periosteum; *c*, internal layer, with numerous osteoblasts, passing in to form *d*, new bony growth, which is covered with osteoblasts, some of which are imbedded in it, forming bone corpuscles. Numerous blood-vessels are seen cut across, in the periosteal ingrowth, some filled with blood-corpuscles, others empty.

the bone increases in length by the ossification continuing to extend into the intervening cartilage, which goes on growing at the same time; and it appears that in the part of the shaft already ossified little or no elongation takes place by interstitial growth. This is shown by an experiment first made by Hales and afterwards by Duhamel and by John Hunter, in which, two or more holes being bored in the growing bone of a young animal at a certain measured distance from each other, they are found after a time not to be farther asunder, although the bone has in the mean while considerably increased in length.\* In like manner the shaft also increases in circumference by deposition of new bone on its external surface, while at the same time its medullary canal is enlarged by absorption from within. A ring of

\* Hales, *Veget. Statics.*, 4th edit. p. 340; Duhamel, *Mem. de l'Acad. des Sc.* 1743 et seq. Hunter (reported by Home) in *Trans. of Soc. for Imp. of Med. and Chir. Knowledge*, vol. ii.; also *Catalogue of Hunterian Museum*, vol. i., p. 249. Duhamel was led from some of his experiments to infer that an interstitial elongation took place near the ends; but there is some doubt left as to the precise circumstances of the experiments in these cases. Both Hales and Duhamel, in experimenting on the growing tibia of a chicken,

silver or platinum put round the wing bone of a growing pigeon, becomes covered with new bone from without, and the original bone included within it gets thinner, or, according to Duhamel, who first made the experiment, is entirely removed, so that the ring comes to lie within the enlarged medullary canal.

Madder given to an animal along with its food tinges those parts in which deposition of new bone is taking place. The earth of bone appears to act as a sort of mordant, uniting with and fixing the colouring matter; and, as in this way the new osseous growth can be readily distinguished from the old, advantage was taken of the fact by Duhamel, and afterwards by Hunter, in their inquiries as to the manner in which bones increase in size. By their experiments it was shown that when madder is given to a young pig for some weeks, the external part of its bones is deeply reddened, proving that the new osseous matter is laid on at the surface of that previously formed. Again, it was found that, when the madder was discontinued for some time before the animal was killed, an exterior white stratum (the last formed) appeared above the red one, whilst the internal white part, which was situated within the red, and had been formed before any madder was given, had become much thinner: showing that absorption takes place from within. In this last modification of the experiment also, as noted by Hunter, a transverse red mark is observed near the ends of the bone, beyond which they are white; the red part indicating the growth in length during the use of the madder, and the white beyond, that which has taken place subsequently,—thus showing that the increase in length is caused by the addition of new matter to the extremities. But other changes take place in the bone. The spaces in the cancellated structure, as well as the medullary canal, become enlarged by absorption; whilst in other parts the tissue becomes more compact by farther deposit on the inner surface of the vascular cavities. The sides of the shaft in particular acquire greater solidity by the narrowing of the Haversian canals, within which the osteoblasts continue to deposit fresh layers of bone; and madder administered while this process is going on, colours the interior and recently-formed laminae, so that in a cross section the Haversian apertures appear surrounded with a red ring.

Flourens,\* and more recently, Kölliker, have repeated and varied these experiments, and have represented the results in beautiful delineations. Kölliker has, in addition, carefully investigated the microscopic appearances observed in the process of absorption of bone. From the results of his researches (which were in part anticipated by those of Lovén),† it would seem that the process is essentially dependent on the presence of large multi-nucleated cells, by him termed "ostoclasts" (the myeloplaques of Robin), which excavate, in the part which is undergoing absorption, small shallow pits (*foveolæ*) in which also they lie. These pits were first noticed by Howship: they seem to occur wherever absorption is proceeding, and it is to them that the festooned appearance of the Haversian spaces is due. The ostoclasts (fig. 63) vary in size, but are always many times larger than a blood-corpuscle: in shape they are almost always flattened, with either an even or an irregular outline. Their substance is granular, and they each contain from two to ten clear round nuclei, but this number may be considerably exceeded. The ostoclasts frequently present on the side by which they are in contact with the bone a thickened striated border (fig. 63, *a*), somewhat similar to the well-known thickened base of the columnar epithelium cells of the intestine. With respect to the origin and destiny of the ostoclasts, they are regarded by Kölliker both as in the first instance derived from and as eventually breaking up into osteoblasts. Wegner,‡ on the other hand,

observed that the addition of new bone was much greater at the upper end. Humphry has found that in the femur the elongation is greater at the *lower*, and in the humerus at the *upper* end of the shaft (Med. Chir. Trans., vol. xlv.).

\* Recherches sur le Développement des Os et des Dents. Paris, 1842.

† Loc. cit., 1863.

‡ Virch. Archiv. lvi. 1873.

describes them as springing originally from the cells which compose the walls of the blood-vessels. Osteoclasts are found in connection with the roots of the milk teeth where these are undergoing absorption to make way for the permanent set :

Fig. 63.

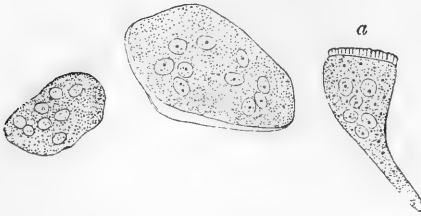


Fig. 63.—THREE OSTEOCLASTS FROM ABSORPTION SURFACES OF GROWING BONE. 400 DIAMETERS (Kölliker).

a, with thickened striated border.

and cells precisely similar occur in various situations quite apart from any hard tissue, and in such situations have long been known as "giant-cells" (Riesenzellen, Virchow). Whether in these cases also they are concerned in any way with absorption is unknown.

The changes of shape which the bones undergo in the process of growth, as well as any changes which may occur in them in adult life, are all produced in the same manner as the increase of size—that is to say, not by interstitial growth and expansion of the substance of the bone in one direction more than in another, but by a deposition of new bone by osteoblasts at some parts and a simultaneous absorption by osteoclasts at others ; whilst in other places again neither absorption nor deposition is occurring—just as a modeller corrects his work by plastering the clay on at one part whilst scraping it away at another part.\*

From the foregoing account of the development of bone, it is evident that a great portion of a long bone is formed independently of cartilage. It appears therefore reasonable to consider the pre-existence of that tissue as not being a necessary condition of the ossific process, and to regard the precursory cartilage of the foetal skeleton in the light of a temporary substitute for bone, and also as affording, as it were, a mould of definite figure and of soft but yet sufficiently consistent material in which the osseous tissue may be at first deposited and assume a suitable form. In fact the cartilage-cells are not ossified, and, as to the slender walls of the primary areolæ formed by calcification of the intercellular cartilaginous matrix, most of them are, in a long bone, swept away by absorption, in the excavation of the medullary canal ; so that they can only remain—coated, however, and obscured by secondary laminated deposit—in the cancellar structure of bones which begin to ossify in cartilage.†

The time of commencement of ossification in the different bones, as well as the number and mode of conjunction of their centres of ossification, are subjects that belong to special anatomy. It may, however, be here remarked in general, that the commencement of ossification does not in all cases follow the order in which the bones appear in their soft or cartilaginous state. The vertebræ, for instance, appear as cartilages before there is any trace of the clavicle, yet ossification begins in the latter sooner than in any other bone of the skeleton. The time when it commences in the clavicle, and consequently the date of the first ossification in the skeleton, is referred by some to the seventh week of

\* For special details of this modelling process as it is met with in the different bones of the skeleton, the reader is referred to Kölliker's memoir : *Die normale Resorption des Knochengewebes*. Leipzig, 1873.

† Nesbitt, in 1736, maintained that the cartilage is "entirely destroyed ;" he therefore considered it to be a mere temporary substitute ; but the steps of the process of intracartilaginous ossification as now traced with the aid of the microscope were unknown to him. The view stated in the text, together with most of the facts adduced in support of it, was announced by Sharpey in the fifth edition of this work in 1846, but notwithstanding the comprehensive researches of Bruch, by which he was led to the same opinion (*Denks. d. Schweiz. naturf. Gesells.* 1852), it met with little notice, and probably less assent, until the subject was treated of in a special memoir by the late H. Müller (*Zeits. für wissensch. Zool.* vol. ix., 1858), to whom the doctrine in its modern shape is now commonly ascribed.

intra-uterine life ; others assign a considerably earlier period ; but owing to the uncertainty that prevails as to the age of early embryos, the dates of commencing ossification in the earliest bones cannot be given with precision.

In regard to the number and arrangement of the osseous centres, the following general facts may be stated :—1. In the long bones there is one centre of ossification in the middle, and the ends are for the most part ossified from separate centres ; whilst a layer of cartilage remains interposed until the bone has nearly attained its full length. By this means the bone is indurated in the parts where strength is most required, whilst its longitudinal growth is facilitated. 2. The larger foramina and cavities of the skeleton are for the most part formed by the junction of two, but more generally of three or more ossific centres around the aperture or included space. The vertebral rings, the acetabulum, the occipital foramen, and the cranium itself, are illustrations of this. It is easy to conceive that in this way the ready and equable enlargement of such cavities and apertures is provided for. 3. Bones of a complex figure, like the vertebræ, have usually many centres of ossification ; but the converse is not always true. 4. We can frequently connect the number of ossific centres with the principle of uniformity of type on which the skeleton of vertebrated animals is constructed. Thus the typical form of the sternum seems to be that of a series of distinct bones, one placed between each pair of ribs in front, as the vertebræ are behind, and this is its permanent condition in many quadrupeds. In man it conforms to the general type in its mode of formation, in so far as it is ossified from several centres, and for some time consists of several pieces ; but, to suit the fabric of the human thorax, these at last coalesce one with another, and are reduced in number to three.

**Regeneration of Bone.**—In the reunion of fractured bones, osseous matter is formed between and around the broken ends, connecting them firmly together ; and when a portion of bone dies, as happens in necrosis, a growth of new bone very generally takes place to a greater or less extent, and the dead part is thrown off. The several steps of the process of restoration in these instances are so fully described in works on Surgical Pathology, that it is unnecessary to add to the length of this chapter by introducing an account of them here. Nevertheless it may be well to refer briefly to the importance of the periosteum in the process of repair, a point that was urged by Duhamel and Troja, and more recently by Syme and Ollier.\* It is well known that if a portion of periosteum be stripped off, the subjacent bone will be liable to die and exfoliate ; conversely, if a large part or the whole of a bone be removed and the periosteum at the same time be left intact, the bone will, in a great measure, be regenerated. These and many other facts connected with the subject of osseous regeneration have been very fully illustrated by the experiments of Ollier, who has shown, amongst other things, that osseous formation will even occur in connection with portions of periosteum which have been stripped away from the bone itself and intertwined amongst the muscles of the part, or even with portions that have been entirely removed from a bone and transplanted to a soft tissue—as, for instance, underneath the skin.

## MUSCULAR TISSUE.

The muscular tissue is that by means of which the active movements of the body are produced. It consists of fine fibres, which are for the most part collected into distinct organs called muscles, and in this form it is familiarly known as the flesh of animals. These fibres are also disposed round the sides of cavities and between the coats of hollow viscera, forming strata of greater or less thickness. The muscular fibres are endowed with *contractility*, a remarkable and characteristic property, by virtue of which they shrink or contract more or less rapidly under the influence of certain causes which are capable of

\* Syme, Trans. R. S. Ed. 1840. Ollier, *Traité de la Régénération des Os*. Paris, 1867.

exciting or calling into play the property in question, and which are therefore named *stimuli*. A large class of muscles, comprehending those of locomotion, respiration, expression, and some others, are excited by the stimulus of the will, or volition, acting on them through the nerves; these are therefore named "voluntary muscles," although some of them habitually, and all occasionally, act also in obedience to other stimuli. There are other muscles or muscular fibres which are entirely withdrawn from the control of the will, such as those of the heart and intestinal canal, and these are accordingly named "involuntary." These two classes of muscles differ not only in the mode in which they are excited to act, but also to a certain extent in their anatomical characters; and on this account we shall consider the structure of each class separately.

#### OF THE STRUCTURE OF VOLUNTARY MUSCLES.

The voluntary muscular fibres are for the most part gathered into distinct masses or muscles of various sizes and shapes, but most generally of an oblong form, and furnished with tendons at each extremity, by which they are fixed to the bones.

The two attached extremities of a muscle are named, in anatomical descriptions, its origin and insertion;—the former term being usually applied to the attachment which is considered to be most fixed, although the rule cannot be always applied strictly. The fleshy part is named the belly, which in some cases is interrupted in the middle or divided into two by a tendon, and then the muscle is said to be biventral or digastric; on the other hand it may be cleft at one end into two or three portions, in which case it is named bicipital or tricipital.

The muscular fibres are collected into packets or bundles, of greater or less thickness, named fasciculi or lacerti (fig. 64), and the fibres themselves are commonly described as consisting of much finer threads, visible by the aid of the microscope, which are termed muscular filaments, fibrillæ, or fibrils (fig. 65, *c*). The fibrils run parallel with each other in the fibres, and the fibres are parallel in the fasciculi; and the fasciculi extend continuously from one terminal tendon to the other, unless in those instances, like the rectus muscle of the abdomen and the digastric of the inferior maxilla, in which the fleshy part is interrupted by interposed tendinous tissue. The fasciculi also very generally run parallel, and, although in many instances they converge towards their tendinous attachment with various degrees of inclination, yet in the voluntary muscles they do not interlace with one another.

**Sheath.**—An outward investment or sheath of areolar tissue (sometimes named *perimysium*) surrounds the entire muscle, and sends partitions inwards between the fasciculi; furnishing to each of them a special sheath. The areolar tissue extends also between the fibres, but does not afford to each a continuous investment, and therefore cannot be said to form sheaths for them. Every fibre, it is true, has a tubular sheath; but this, as will be afterwards explained, is not derived from the areolar tissue. The tissue of the sheath is composed of elastic (yellow) as well as of white fibres; but the elastic element is found principally in its investing (as distinguished from its penetrating) portion. The chief uses of the areolar tissue are to connect the fibres and fasciculi together, and to conduct and support the blood-vessels and



nerves in their ramifications between these parts. The relation of these different subdivisions of a muscle to each other, as well as the shape of the fasciculi and fibres, is well shown by a transverse section (figs. 64 and 65).

Fig. 64.

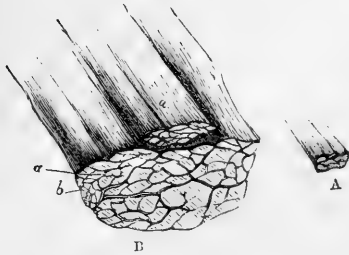


Fig. 65.

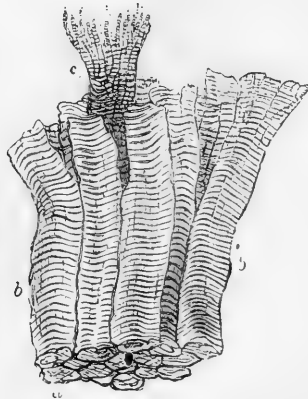


Fig. 64.—A, SMALL PORTION OF MUSCLE, NATURAL SIZE; B, THE SAME MAGNIFIED 5 DIAMETERS, CONSISTING OF LARGER AND SMALLER FASCICULI, SEEN IN A TRANSVERSE SECTION.

Fig. 65.—A FEW MUSCULAR FIBRES, BEING PART OF A SMALL FASCICULUS, MAGNIFIED, SHOWING THE TRANSVERSE STRIÆ.

*a*, end view of *b*, *b*, fibres; *c*, a fibre split into fibrils.

**Fasciculi.**—The fasciculi are of a prismatic figure, and their sections have therefore an angular outline. The number of fibres of which they consist varies, so that they differ in thickness, and a large fasciculus may be divisible into two or three orders of successively smaller bundles, but of no regularly diminishing magnitude. Some muscles have large, others only small fasciculi; and the coarse or fine texture of a muscle, as recognized by the dissector, depends on this circumstance. The length of the fasciculi is not always proportioned to the length of the muscle, but depends on the arrangement of the tendons to which their extremities are attached. When the tendons are limited to the ends of a long muscle, as in the sartorius, the fasciculi, having to pass from one extremity to the other, are of great length; but a long muscle may be made up of a series of short fasciculi attached obliquely to one or both sides of a tendon, which advances some way upon the surface or into the midst of the fleshy part, as in the instances of the rectus muscle of the thigh, and the tibialis posticus. Muscles of the kind last referred to are named “penniform,” from their resemblance to the plume of a feather, and other modifications of the arrangement, which can be readily conceived, are named “semi-penniform” and “compound penniform.” Many short fasciculi connected thus to a long tendon, produce by their combined operation a more powerful effect than a few fasciculi running nearly the whole length of the muscle;

but by the latter arrangement the extent of motion is greater, for the points of attachment are moved through a longer space.

**Fibres; their figure and measurement.**—In shape the fibres are cylindrical, or prismatic, and in the latter case often with rounded surfaces and angles. Their size is tolerably uniform, although fibres occur here and there in a muscle which differ greatly in size from the prevailing standard. Bowman gave the average diameter in the male at  $\frac{1}{352}$  and in the female at  $\frac{1}{454}$  of an inch. According to later measurements by Kölliker in different regions of the body, the prevailing size of the fibres in the muscles of the trunk and limbs is from  $\frac{1}{750}$  to  $\frac{1}{400}$  of an inch, but is less in those of the head, especially in the facial muscles, in which he found the diameter to range from  $\frac{1}{750}$  down to  $\frac{1}{400}$  of an inch.

**Cross stripes.**—When viewed by transmitted light with a sufficiently high power of the microscope, the fibres, which are then clear and pellucid in aspect, appear marked with fine parallel stripes or bands passing across them directly or somewhat obliquely with great regularity (figs. 65 and 66, A), and this not only at the surface but, as may be seen by altering the focus of the microscope, throughout its substance also.

Fig. 66.

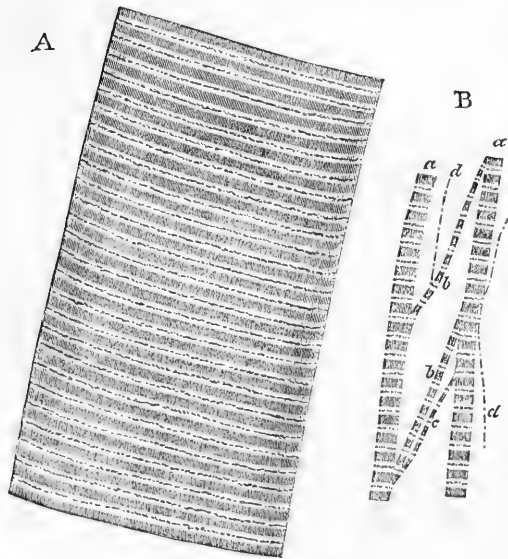


Fig. 66.—A, PORTION OF A MEDIUM-SIZED HUMAN MUSCULAR FIBRE, MAGNIFIED NEARLY 800 DIAMETERS.

B, SEPARATED BUNDLES OF FIBRILS, EQUALLY MAGNIFIED. *a, a*, larger, and *b, b*, smaller collections; *c*, still smaller; *d, d*, the smallest which could be detached.

very generally but not in all cases, a fine dark dotted line (first noticed by Busk and Huxley) passing along the middle of the light stripe, and dividing it into two (fig. 66, A). About eight or nine dark and as many light stripes may be counted in the length of  $\frac{1}{1000}$  of an inch, which would give about  $\frac{1}{17000}$  inch as the breadth of each. But whilst this may be assigned as their usual breadth, they are in different parts found to be much narrower, so that not unfrequently they are double the above number in an equal space. This closer approximation may generally be noticed in

the microscope, the fibres, which are then clear and pellucid in aspect, appear marked with fine parallel stripes or bands passing across them directly or somewhat obliquely with great regularity (figs. 65 and 66, A), and this not only at the surface but, as may be seen by altering the focus of the microscope, throughout its substance also. The stripes are commonly said to be dark, with light intervals; but it is more correct to speak of both light and dark stripes which alternately cross the fibre. The dark and light stripes are nearly of equal breadth, and there also may be seen,

thicker and apparently contracted parts of the fibre, but it is by no means confined to such parts. This cross-striped appearance, which is most beautiful and characteristic, is found in all the voluntary muscles: but it is not altogether confined to them, for it is seen in the fibres of the heart, which is a strictly involuntary organ: striped fibres are also found in the pharynx and upper part of the gullet, in the muscles of the internal ear, and those of the urethra, parts which are not under the direct control of the will.

**Structure of the fibres.**—A muscular fibre may be said to consist of a soft contractile substance inclosed in a tubular sheath.

This, the proper sheath of the fibre, is named *sarcolemma* or *myolemma*. It consists of transparent and apparently homogeneous membrane agreeing in chemical characters with elastic tissue, and, being comparatively tough, will sometimes remain entire when the included fibrils are ruptured by stretching the fibre, as represented in fig. 67.

In this way its existence may be demonstrated; and it is especially well seen in fish and other animals which have large fibres, for in these it is thicker and stronger. It may also be well shown in fresh muscular fibres from the frog, by exposing them to water under the microscope. The fluid is imbibed, and then collects between the substance of the fibre and its sheath so as to separate the membrane and make it apparent. At the same time, as

regards mammalian muscles, it must be admitted that it is not always easy to bring the sarcolemma distinctly into view.

The proper substance of the fibre presents, besides the cross-striped appearance already mentioned, also an appearance of longitudinal striation, which is the better marked where the transverse striation is less distinct. On separating the fibre with needles, especially after hardening in alcohol or solution of osmic acid, it may be broken up longitudinally into the so-called *fibrils*, which, when of a certain fineness, appear to consist of a row of dark quadrangular particles (fig. 66 B, *b*), with bright intervals, the latter being commonly traversed by a dark dotted line, *c*. These rows of quadrangular particles may, however, be further separated, and the finest of the filaments so obtainable present the appearance of lines regularly broken at short distances with a dot in each of the breaks, *d*. Each such thread may be looked upon as an ultimate fibril. It must, however, be borne in mind that the fibre is not actually *composed* of these, but that there is in addition a not inconsiderable amount of connecting substance. Under certain circumstances the fibres show a tendency to cleave across in a direction parallel to the stripes, and even to break up into transverse plates or disks, which are formed by the lateral cohesion of the particles of adjacent fibrils. To make up such a disk, therefore, every fibril contributes a particle, which separates from those of its own fibril, but coheres with its neighbour on each side, and this with perfect regularity. Indeed, Bowman conceives that the subdivision of a fibre into fibrillæ is merely a phenomenon of the same kind, only of more common occurrence, the cleavage

Fig. 67.



Fig. 67.—MUSCULAR FIBRE OF FISH. SUBSTANCE OF FIBRE RUPTURED SO AS TO EXHIBIT SARCOLEMMMA. (After Bowman.)

in the latter case taking place longitudinally instead of transversely: accordingly, he considers that the fibrillæ have no existence as such in the fibre, any more than the disks; but that both the one and the other owe their origin to the regular arrangement of the particles of the fibre (sarcous elements) longitudinally and transversely, whereby, on the application of a severing force, it cleaves in the one or in the other direction into regular segments. Kölliker, on the other hand, holds to the opinion that the fibrils pre-exist as such, and that they are of essentially the same nature from end to end of the fibre, the alternating dark and light parts being due to differences in optical characters merely: he describes them as being collected into definite bundles (which make up a fibre), termed by him "muscle-columns."

It is difficult, however, on account of the extreme delicacy of the elements composing it and the readiness with which changes occur in them, to make out, with the means at present at our command, the exact structure of the mammalian muscular fibre; and, to endeavour to attain to a satisfactory knowledge of the subject, histologists have therefore largely availed themselves of the facilities afforded by the muscular fibres of the arthropoda, and especially of the water-beetle, which are quite similar in appearance and character, but in which the elements are relatively large, these fibres, moreover, are readily obtained in a perfectly unaltered and still contractile condition.

Such muscular fibres, when examined, without the addition of any fluid, under a high power of the microscope, in what may be considered their typical condition, present, like mammalian muscle, the appearance of alternate dim and bright stripes crossing the fibre. Each dim stripe is seen to be pervaded by a series of minute rod-shaped

particles set side by side, with their axes parallel to that of the fibre (fig. 68). Crossing the fibre in the middle of each of the bright stripes a double row of dots (*c*) is apparent; and on close inspection it may be seen that each rod-shaped particle of the dim stripe is traceable at each end into one of the dots of the bright stripe: the dots consequently are merely the knobbed ends of the rod-shaped particles. In this way the whole fibre is pervaded by these minute rods (muscle-rods, *d*). The muscle-rods refract the light more strongly than the rest of the muscular substance, and hence appear somewhat darker; like that substance, they are probably of a soft and yielding nature.

Now it can be shown that a linear series of strongly refracting spheroids, like the enlarged ends of the muscle-rods, must necessarily have the effect, when viewed by transmitted light, of producing a bright band, due to diffraction, on

Fig. 68.

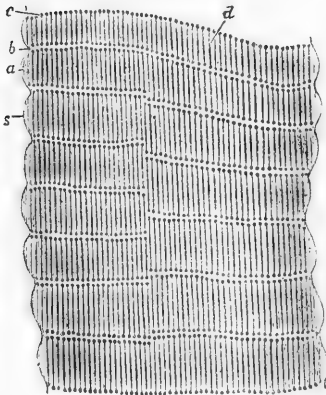


Fig. 68.—LIVING MUSCLE OF WATER-BEETLE (*DYTISCUS MARGINALIS*), HIGHLY MAGNIFIED.

*s*, sarcolemma; *a*, dim stripe; *b*, bright stripe; *c*, rows of dots in bright stripe which are seen to be the knobbed heads of *d*, muscle rods.

mitted light, of producing a bright band, due to diffraction, on

either side, just as a minute oil-globule in water appears surrounded with a bright halo when examined under the microscope. According to this view the proper substance of the muscle may be regarded as consisting of a homogeneous ground-substance, in which lie imbedded successive series of rod-shaped particles, the enlarged ends of which give the appearance of transverse lines of dots, and, by diffraction, produce a relatively bright appearance in their immediate neighbourhood, and therefore rise to the bright bands.\* In transverse section the muscle rods appear, if the muscle be perfectly fresh, as minute round dots in the homogeneous ground-substance (fig. 69).

Fig. 69.

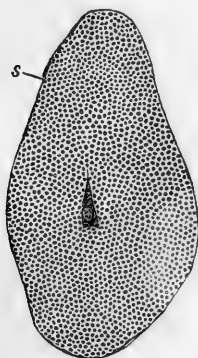


Fig. 70.

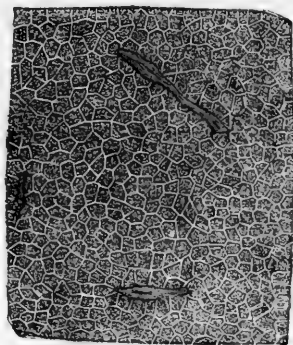


Fig. 69.—TRANSVERSE SECTION OF A SMALL MUSCULAR FIBRE OF WATER-BEEBLE. HIGHLY MAGNIFIED.

*s*, sarcolemma.

Fig. 70.—TRANSVERSE SECTION OF PORTION OF MUSCULAR FIBRE OF LOBSTER. EXAMINED IN SALT SOLUTION ( $\frac{1}{2}$  PER CENT.) AND MAGNIFIED 400 DIAMETERS (Kölliker).

The polygonal areas of Cohnheim are seen, and among them two or three irregular nuclei.

Under certain circumstances, especially on the addition of any fluid, this appearance vanishes, and the ground becomes parted off into definite polygonal areas (Cohnheim's areas) bounded by clear bright lines (fig. 70). These are regarded by Kölliker as the sections of the muscle-columns described by him; by W. Krause as the ends of minute prisms of which he conceives the muscular substance to be made up. They are not observable in the unaltered condition of the fibre.

There is every reason to believe that the ground-substance is similar in nature to ordinary protoplasm but without the granular character commonly, but not always, exhibited by the latter. Like the substance composing the plain muscular cells shortly to be described, it is doubly refracting (anisotropous), whereas the substance composing the muscle-rods is probably singly refracting (isotropous).

\* This view of the cause of the appearance is supported by the fact that in certain fibres the ends of the rods are not enlarged, and in such cases the bright transverse stripes are no longer observed. It also explains, amongst other things, why it is that, until quite lately, observers have failed in recognising the actual continuation of the rod-shaped particles into the dots. For a more extended account of the subject, as well as a notice of the recent literature, the reader is referred to a paper on "The Minute Structure of the Leg-muscles of the Water-beetle" in the Philosophical Transactions for 1873.

Since, however, the rods are enclosed in anisotropic substance their isotropic character is not apparent in the ordinary condition of the fibre, but the appearances observable in the contraction of muscle under polarized light lead to the above conclusion.

Brücke (from the appearance of dead muscular fibre in polarized light) described the dark stripes as being anisotropic, the light isotropic, and he has been followed in this by most subsequent writers on the subject. The fact has, however, been almost entirely overlooked that, as Brücke himself pointed out, in *living* muscle at rest, the whole of the muscular substance appears doubly refracting; and it is only in contraction that the alternate stripes appear singly refracting.

On theoretical grounds the doubly refracting parts of a muscular fibre have been conceived by Brücke to be made up of an aggregation of minute doubly refracting particles, termed by him *disdiaclasts*. But, while the doubly refracting property is no doubt dependent upon the ultimate molecular constitution of the substance possessing it, it is by no means proved that this is represented by particles other than the molecules of which that substance is composed.

**Changes which the muscular elements undergo in contraction.**—When a portion of the still living muscular tissue of the water-beetle is observed under the microscope, contractions may be seen passing in waves along the fibres from end to end, and with care the following changes may be made out. That part of a fibre which is undergoing contraction becomes shorter and thicker, in all probability by the contraction of the protoplasmic ground-substance; the rows of muscle-rods appear at the same time to get pressed down the one upon the other, so that the previously double row of rod-heads in the middle of each bright stripe, first becomes blended into one and then approximated to the neighbouring rows, the

heads of the muscle-rods being enlarged, and their shafts encroached upon. Now since it has been shown that the bright bands are dependent on the diffraction of the lines of rod-heads, it is easy to understand that they will, accompanying these, encroach on and eventually replace the dim stripe in which the shafts of the rods lie. So that when the portion of muscle is fully contracted (fig. 71, *c*) the closely approximated dark stripes which are observed are in reality due to the enlarged rod-heads which have more or less blended with one another; while the bright effect, which is produced by reflection of light from the surface of the disks thus formed, tends to obscure the attenuated shafts.\*

When a contracted fibre is viewed under polarized light the dark bands (which are formed in this case, as just explained, by the coalesced rod-heads) refract the light singly so that we now get dark and light bands crossing the fibre; it is possible that the alterations of doubly and singly refracting parts, which are commonly

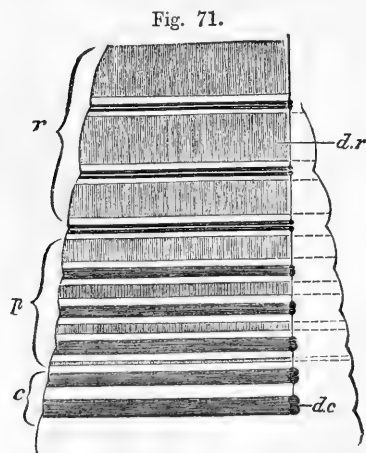


Fig. 71.—DIAGRAM OF CONTRACTION OF MUSCLE.

*r*, portion at rest; *p*, portion in which contraction is proceeding; *c*, contracted portion; *dr*, dark stripe of muscle at rest; *dc*, dark stripe of contracted muscle formed by apposition of the enlarged rod-heads.

observed in preserved specimens of muscle, may be due to the presence of a condition similar to that here described.

\* It will be seen, therefore, that in the process of contraction the relative position of the light and dark parts of the fibre becomes altered, so that the stripe which was previously dim is now bright.

**Nuclei or muscle-corpuscles.**—A number of clear oval nuclei are found in the fibres (see p. 154, fig. 105, and fig. 106 *e*). In mammalian muscles they lie upon the inner surface of the sarcolemma, but in frogs they are distributed through the substance of the fibre (fig. 72). Associated with and surrounding them is a certain amount of granular protoplasm, which is doubtless connected with the growth and nutrition of the muscle. It shades off at the margins into the ground-substance of the fibre. Both it and the ground-substance are to be regarded as the remains of the original formative protoplasm of the embryonic cells which compose the muscle (Max Schultze). In the unaltered condition the nuclei are commonly obscured, but may be made conspicuous by the addition of acetic acid.

Fig. 72.




Fig. 72.—A FROG'S MUSCULAR FIBRE TREATED WITH ACETIC ACID, MAGNIFIED 350 DIAM. (from Kölliker).

The nuclei are somewhat shrunk. Interstitial granules in longitudinal rows, here and there.

**Length and ending of the fibres.**—

The fibres composing a muscle are of limited length, not exceeding one inch and a half; and accordingly in a long fasciculus a fibre does not reach from one tendinous attachment to the other, but ends with a rounded extremity, invested with its sarcolemma, and cohering with neighbouring fibres. Unless when either is fixed to a tendon, both extremities of the fibre terminate in the way described, so that it has a long cylindrical shape.

**Branched fibres.**—Generally speaking the fibres neither divide nor anastomose; but this rule is not without exception. In the tongue of the frog the muscular fibres (fig. 73) as they approach the surface divide into numerous branches, by which they are attached to the under surface of the mucous membrane. The same thing has also been seen in the tongue of man and various other animals; and the fibres of the facial muscles of mammals have been shown by Bûsk and Huxley to divide in a similar manner where they fix themselves to the skin.

Fig. 73.

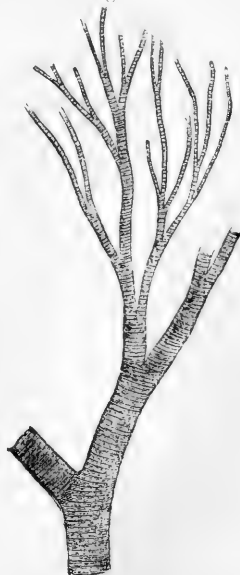


Fig. 73.—A BRANCHED MUSCULAR FIBRE FROM THE FROG'S TONGUE, MAGNIFIED 350 DIAM. (from Kölliker).

**Connection with tendons.**—As shown by Kölliker, the mode of connection differs when the muscular fibres are continuous in a direct line with those of the tendon from that which is observed when the former join the latter at a more or less acute angle. In the first case the two are directly continuous, the muscular fibre being distinguishable from that of the fibrous tissue by its striation alone (fig. 74, B). In the second case,

the muscular fibres terminate in rounded ends, which are received into corresponding depressions of the tendinous structure, to which they cling; the connective tissue of the one being continuous with that of the other (fig. 74 A).

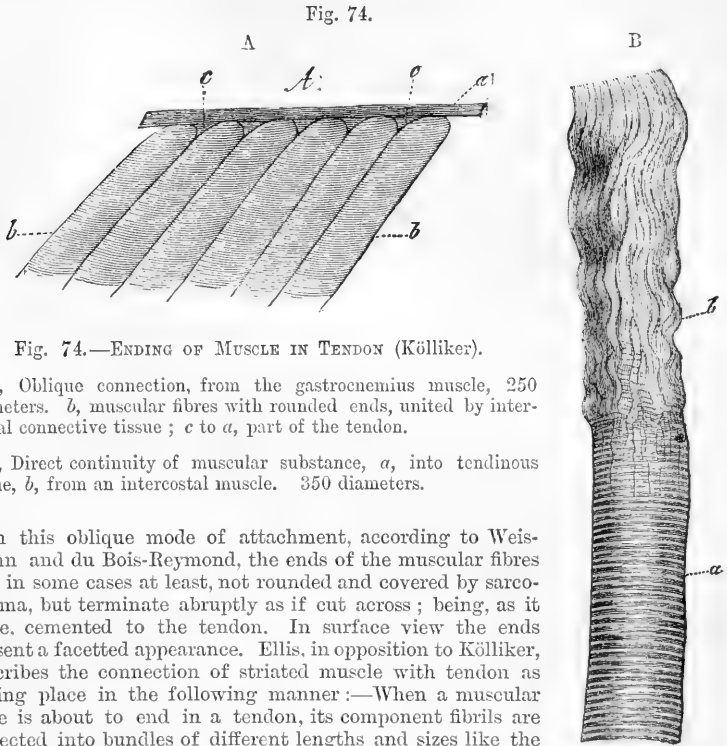


Fig. 74.—ENDING OF MUSCLE IN TENDON (Kölliker).

A, Oblique connection, from the gastrocnemius muscle, 250 diameters. *b*, muscular fibres with rounded ends, united by interstitial connective tissue; *c* to *a*, part of the tendon.

B, Direct continuity of muscular substance, *a*, into tendinous tissue, *b*, from an intercostal muscle. 350 diameters.

In this oblique mode of attachment, according to Weismann and du Bois-Reymond, the ends of the muscular fibres are, in some cases at least, not rounded and covered by sarcolemma, but terminate abruptly as if cut across; being, as it were, cemented to the tendon. In surface view the ends present a faceted appearance. Ellis, in opposition to Kölliker, describes the connection of striated muscle with tendon as taking place in the following manner:—When a muscular fibre is about to end in a tendon, its component fibrils are collected into bundles of different lengths and sizes like the roots of a tree. Around each bundle tendinous tissue is collected, forming a sheath which appears gradually to cease as it is continued backwards on the undivided fibre. The muscular fibrils of a bundle in approaching the tendon gradually cease, each having probably its own tendinous thread to fix it. He states that, where the attachment is oblique, as in the gastrocnemius and soleus, every fibre is provided with its separate tendon and is continuous with it as above described, and that the increasing thickness of the main tendon from above downwards is due to successive additions, in the form of strata, of the contributing tendons from the lower placed layers of muscular fibres.

In attaching themselves to the skin and mucous membranes, the muscular fibres divide into pointed processes or fine filaments which are continuous with those of the connective tissue (Hyde Salter).

**Blood-vessels.**—The blood-vessels of the muscular tissue are extremely abundant, so that, when they are successfully filled with coloured injection, the fleshy part of the muscle contrasts strongly with its tendons. The arteries, accompanied by their associate veins, enter the muscle at various points, and divide into branches: these pass among the fasciuli, crossing over them, and dividing more and more as they get between the finer divisions of the muscle; at length,



penetrating the smallest fasciculi, they end in capillary vessels, which run between the fibres. The vessels are supported in their progress by the subdivisions of the sheath of the muscle, to which also they supply capillaries. The capillaries destined for the proper tissue of the muscle are extremely small; they form among the fibres a fine network, with narrow oblong meshes (fig. 75), which are stretched out in the direction of the fibres: in other words, they consist of longitudinal and transverse vessels, the former running parallel with the muscular fibres, and lying in the angular intervals between them, —the latter, which are much shorter, crossing between the longitudinal ones, and passing over or under the intervening fibres.

Fig. 75.

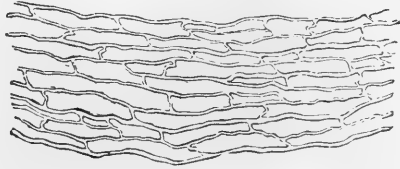


Fig. 75. — CAPILLARY VESSELS OF MUSCLE, FROM AN INJECTION BY LIEBERKÜHN, SEEN WITH A LOW MAGNIFYING POWER.

None of the capillary vessels enter the sarcolemma or proper sheath of the fibre, and the nutritious fluid which they convey must therefore reach the finer elements of the muscle by imbibition. Moreover, as the capillaries do not penetrate the fibres, but lie between them, their number in a given space, or their degree of closeness, will in some measure be regulated by the number and consequently by the size of the fibres; and accordingly in the muscles of different animals it is found that, when the fibres are small, the vessels are numerous and form a close network, and *vice versâ*: in other words, the smaller the fibres, the greater is the quantity of blood supplied to the same bulk of muscle. In conformity with this, we see that in birds and mammalia, in which the process of nutrition is active, and where the rapid change requires a copious supply of material, the muscular fibres are much smaller and the vessels more numerous than in cold-blooded animals, in which the opposite conditions prevail.

**Lymphatics.**—Of lymphatic vessels in the muscular tissue nothing certain is known. The rich supply of these vessels in the sheaths of muscles and of their tendons would seem, as pointed out by Ludwig and Schweigger-Seidel, to serve the purpose of collecting and conveying away the lymph from those organs, but how the fluid reaches the lymphatic vessels of the sheath is not certainly known: probably by the medium of the intercommunicating cell-spaces of the connective tissue which, as before remarked, penetrates between the fasciculi and fibres of the muscle.

**Nerves.**—The nerves of a voluntary muscle are of considerable size. Their branches pass between the fasciculi, and repeatedly unite with each other in form of a plexus, which is for the most part confined to a small part of the length of the muscle, or muscular division in which it lies. From one or more of such *primary* plexuses, nervous twigs proceed, and form finer plexuses composed of slender bundles, each containing not more than two or three dark-bordered nerve-fibres, whence single fibres pass off between the muscular fibres and divide into branches which are finally distributed to the tissue. The mode of final distribution will be described with the general anatomy of the nerves.

Nerves of small size accompany the branches of blood-vessels within muscles; though destined for the vessels, these nerves are said sometimes to communicate with the proper muscular plexuses.

#### INVOLUNTARY MUSCLES.

The involuntary muscular tissue differs from the voluntary kind, not only in its want of subjection to the will, but also in its external characters; for whilst in many parts it appears in the form of fibres, these, except in the heart and a few instances of less note, are unmarked

Fig. 76.



Fig. 77.

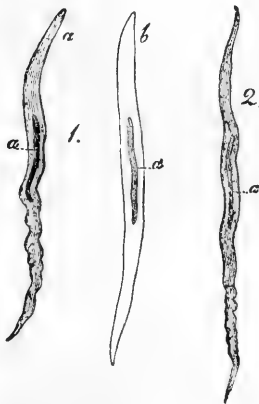


Fig. 77. — MUSCULAR FIBRE-CELLS FROM HUMAN ARTERIES, MAGNIFIED 350 DIAMETERS (Kölliker).

*a*, natural state; *b*, treated with acetic acid.

Fig. 76.—MUSCULAR FIBRE-CELL FROM THE MUSCULAR COAT OF THE SMALL INTESTINE, MAGNIFIED (Kölliker).

by the cross lines so characteristic of the striped fibres; moreover, they are in reality made up of elongated contractile cells cemented together by some kind of uniting medium.

**Plain or unstriped muscular tissue.**—This, as has just been remarked, is made up of cells, named *contractile fibre-cells*, which were first distinguished as the true elements of the tissue by Kölliker. The cells may form fibrous bundles, and strata, or may be less regularly arranged, or mixed with other tissues in greater or less proportion. They are of an elongated fusiform shape (figs. 76 and 77), usually pointed at the ends, but sometimes abruptly truncated, and are roundish or prismatic in transverse section. The cells vary greatly in length according to the part or organ in which they are found. Some occur which are cleft or forked at one end. Their substance is finely granular and commonly exhibits a faint longitudinal striation. It has a smooth soft aspect, and presents no indication of an envelope. Each has a nucleus (*a, a*), rarely more than one, which is always elongated and either oval or rod-shaped. Towards each end of the nucleus the substance of the cell

usually contains a few larger granules arranged in linear series.

The plain muscular tissue is for the most part disposed between the coats of the membranous viscera, as the stomach, intestines, and bladder, in the parietes of the air-tubes, excretory ducts of glands, and the like.

It is generally collected into larger and smaller fasciculi, which in many cases cross one another and interlace. The fasciculi are connected at their ends with tendinous tissue, and are thus inserted into the membranous and firmer parts in the neighbourhood. Small tendons are also fixed by blending with the fibrous sheaths investing contiguous muscular bundles. Ellis states that in the gullet the longitudinal muscular fasciculi are intersected wholly or partially, at intervals of from  $\frac{1}{30}$  to  $\frac{1}{10}$  of an inch, by small tendons into which they are inserted, after the fashion of the rectus abdominis, only on a miniature scale.

The plain muscular tissue is met with in the lower half of the gullet, the stomach, and the whole intestinal canal; that is, both in the muscular coat of the alimentary canal, and also as a layer in the tissue of the mucous membrane, and in the villi; in the trachea and bronchial tubes, in the bladder and ureters, and the ducts of the larger glands generally, in the uterus and its appendages, in the corpora cavernosa of both sexes, in the prostate gland, and in the ciliary muscle and iris. The middle coat of the arteries, the coats of many veins and the larger lymphatics contain plain muscular tissue. It has also been detected in certain parts of the skin, in the dartos or subcutaneous tissue of the scrotum, and in form of minute muscles attached to the hair-follicles.

**Muscular Tissue of the Heart.**—The fibres of the heart differ remarkably from those of involuntary muscular organs in general, inasmuch as they present transverse striæ. The striæ, however, are less strongly marked, and less regular, and the fibres are smaller in diameter than in the voluntary muscles. They differ also from these in being made up of distinct quadrangular cells (fig. 78) joined end to

Fig. 78.

Fig. 79.

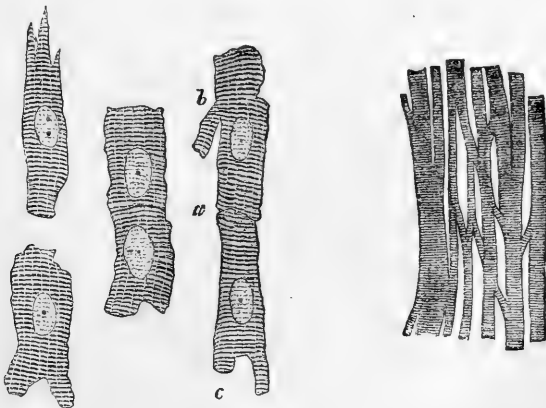


Fig. 78.—SIX MUSCULAR FIBRE-CELLS FROM THE HEART. MAGNIFIED 425 DIAMETERS.  
*a*, line of junction between two cells; *b*, *c*, branching of cells.  
 From a drawing by Mr. J. E. NEALE.

Fig. 79.—MUSCULAR FIBRES FROM THE HEART, MAGNIFIED, SHOWING THEIR CROSS STRIÆ, DIVISIONS, AND JUNCTIONS (Kölliker.)

end and often presenting a branched or forked appearance near one extremity (*c*). Each cell has commonly a single clear oval nucleus

situate near the centre; occasionally two nuclei are seen. The cell substance is faintly striated longitudinally as well as transversely: it presents no indication of an investing membrane or sarcolemma.

The muscular fibres of the heart freely divide and anastomose (fig. 79), the junctions with neighbouring fibres being effected by the medium of the cell-offsets above noticed.

#### DEVELOPMENT AND GROWTH OF MUSCLE.

**Development.**—The elements of the *plain* or *unstriated muscular tissue* are derived from embryonic nucleated cells, consisting of granular protoplasmic substance, as usual. These become lengthened out, pointed at the ends, and flattened, with elongation of the nucleus, whilst their substance becomes more uniform in aspect, and acquires its permanent condition and characteristic properties.

The *striated muscular tissue* is also developed in the embryo from cells. Schwann considered each fibre to be formed by the linear coalescence of several cells; recent researches, however, for the most part, tend to establish the view, originally promulgated by Remak, that the fibres are produced by the elongation of single cells, with differentiation of their contents and multiplication of their nuclei. Wilson Fox, who has lately investigated the process in the tadpole, the chick, and the mammalian embryo, at very early stages, finds that the first elements of the muscular fibres are rounded or oval cells, with a clear nucleus and granular contents, agreeing in all respects with the cells of which the parts of the embryo body originally consist. To form a muscular fibre, a cell elongates, often acquiring pointed ends; the nucleus generally divides into two, and by further division these are multiplied; a fine membrane, at first absent or invisible, is soon discovered, bounding the cell and enclosing its contents. In the meantime the substance becomes striated longitudinally at one part, and more transparent, the granules disappearing. The striation, which is the first indication of the proper muscular substance, extends throughout the length of the elongated cell, but at first affects only a small part of its breadth, and the remaining space is occupied by unchanged granular matter and the nucleus or nuclei which lie on one side. In due time, however, this conversion into the proper muscular substance, further shown by the appearance of cross striæ, proceeds through the whole thickness of the cell, or fibre as it may now be called; the enclosing cell-membrane becomes the sarcolemma, and the nuclei, with a small residue of the granular protoplasm still adhering to them, remain as the muscle corpuscles.\*

**Growth.**—The muscular fibres of the growing foetus, after having acquired their characteristic form and structure, continue to increase in size till the time of birth, and thenceforward up to adult age. In a full-grown foetus most of them measure twice, and some of them three or four times their size at the middle of foetal life; and in the adult they are about five times as large as at birth. This increase in bulk of the individual fibres would, of course, so far account for the concomitant enlargement of the entire muscles. But there would seem to be also a multiplication of the fibres; and Budge believes he has

\* Phil. Trans. 1866.

proved this as regards the muscles of frogs. Two modes of production of new fibres have been described—viz., firstly, from connective tissue corpuscles lying between the existing fibres, by a process analogous to the original development of the muscle (von Wittich); secondly, by the splitting up of a fibre throughout its whole length into two or more smaller ones, preceded by multiplication of its included nuclei. This second process has been described by Weismann and by Kölliker as occurring in frogs, in the winter season, and would appear to serve for the replacement of fibres destroyed by fatty degeneration, which is said to be not uncommon in these creatures. Beale, however, denies that the new and slender fibres are derived from a larger one by splitting of its substance; he believes that they are produced from cells, as in the first mode, and that the old fibre is removed.

The great increase in the muscular tissue of the uterus during gestation takes place both by elongation and thickening of the pre-existing fibre-cells of which that non-striated tissue consists, and by the development of new muscular fibre-cells from small, nucleated, granular cells lying in the tissue. In the shrinking of the uterus after parturition the fibre-cells also diminish to their previous size; many of them become filled with fat-granules (fig. 80), and many are doubtless removed by absorption.

As far as can be concluded from the observations and experiments that have hitherto been made on the subject, the striated muscular tissue is not regenerated in warm-blooded animals. It is true that, when a muscle is cut across, or a portion removed, the breach will heal, but the loss of substance is not repaired by new-formed muscular tissue. Striated muscular fibres have been found in certain tumours of the ovary and testicle, but these cases are altogether peculiar and abnormal.

Fig. 80.

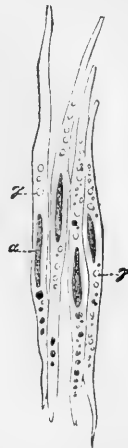


Fig. 80.—MUSCULAR FIBRE-CELLS FROM THE UTERUS, THREE WEEKS AFTER DELIVERY, TREATED WITH ACETIC ACID, MAGNIFIED 350 DIAMETERS (Kölliker).

α, nuclei; γ, fat-granules.

#### COMPOSITION AND PROPERTIES OF MUSCULAR TISSUE.

**Chemical composition.**—Muscular tissue contains nearly 80 per cent. of water, so that in being dried it loses about four-fifths of its weight. The chief and characteristic constituent of the fibre is an albuminoid body. This was at one time regarded as fibrin; but, as it was afterwards shown to be not identical with that substance, it was distinguished by the name of *syntonin*; the ground of distinction being, that syntonin is soluble in very dilute hydrochloric acid, and can be extracted from muscle by that solvent; also, that its solution is precipitated by neutral salts. More recently, the subject has been investigated by Kühne, who states that the albuminoid matter of muscle exists in the fibres in a liquid form during life, but coagulates after death, and thereby gives rise to the cadaveric rigidity which then invades the muscles. When extracted from fresh and still irritable frogs' muscles at a temperature of freezing, this substance, which

Kühne names *myosin*, is liquid; but if it be then exposed to the ordinary heat of the atmosphere it partially coagulates, and the portion then remaining liquid (the *muscle-serum*) when heated to 112° F., or less if it be strongly acid, yields a further coagulum, which Kühne considers peculiar to muscle; and finally, at 167°, ordinary coagulated albumin. The primary coagulation is hastened by the presence of blood, and possibly it may be due to the mutual reaction of two albuminoids analogous in their operation to the fibrinogen and para-globulin of the blood (ante, p. 29). The coagulum of myosin is soluble in strong solutions of neutral salts, and accordingly it may thereby be dissolved out of dead and rigid muscles; but it loses this property if previously dissolved in dilute hydrochloric acid. It then, in fact, agrees with the so-called syntonin, which Kühne regards, not as an original albuminoid of muscle, but as myosin altered by the process of extraction. It has been suggested that the ready solution of muscular fibre in dilute hydrochloric acid may be owing to the presence of pepsin in minute quantity.

Other substances also exist in muscle, but in very small proportion in comparison with the albuminoid matter. Most of them probably result from the process of wear of the original muscular substance. Amongst them are,—1. Kreatin and kreatinine, both of them nitrogenized and crystalline, the former neutral, the latter (derived from it) alkaline; both are also found in the urine. 2. Sarkin. 3. A substance termed “carnin,” hitherto only found in Liebig’s extract of beef (Weidel). 4. Non-nitrogenized substances, viz.: grape sugar; inosit—an unfermentable sugar from the tissue of the heart; glycogen, at least in embryos and young animals. 5. Various organic acids, viz., lactic, inosinic, butyric, acetic, formic, and uric. 6. Salts, in which potash predominates over soda, magnesia over lime, and phosphoric acid over chlorine,—muscle, in this respect, resembling blood-corpuscles as contrasted with serum. Lastly, a variable amount of fat may be extracted from muscle, and also gelatin; the latter no doubt from connective tissue; for it must be remembered that a piece of muscle subjected to analysis comprehends, along with the proper muscular fibres, more or less of connective tissue, blood-vessels and nerves. The account here given of the chemical constitution of muscle applies especially to the striped variety, but, so far as is known, it is essentially the same in the non-striated tissue, and recent researches point to the probability that ordinary protoplasm possesses a similar chemical constitution.

The juice expressed from a muscle after death, and especially after rigidity has set in, is acid, from the presence of lactic acid; so that the cut surface of a dead muscle reddens litmus-paper. On the other hand, a perfectly fresh section of muscle in the living body, or while it retains its irritability, is alkaline or neutral. But, while this is true of a living muscle in its usual state, it gives a decided acid reaction after it has been strongly exerted, as, for instance, after tetanic spasm excited by electricity or by strychnia poisoning. The acid is probably generated by a change in the saccharine matter of the muscle. Ultimately the tissue in all cases becomes alkaline from putrefaction and the evolution of ammonia.

**Physical properties of muscle.**—A dead muscle has little strength, and may be torn asunder by a force of no great amount. A living muscle readily yields to extension, and shrinks exactly to its original length when the extending force

ceases. Its elasticity is therefore said to be small in degree, but very perfect or complete in operation. A dead muscle, especially after cadaveric rigidity has come on, resists extension more powerfully, but does not afterwards return to its original length; hence its elasticity is said to be greater than that of the living muscle, but less perfect.

The red colour of muscle is well known, but it differs greatly in degree in different cases. It is usually paler in the involuntary muscles; but here the heart again is a striking exception. In most fish the chief muscles of the body are nearly colourless, and in the breast of wild fowl we see a difference in the depth of colour in different strata of the same muscles. The redness is no doubt partly due to blood contained in the vessels, but not entirely so, for a red colouring matter, apparently of the same nature as that of the blood, is obviously incorporated with the fibres.

Under this head must also be mentioned the manifestation of electricity by a quiescent but living muscle. When a muscle taken from a living or recently killed animal (a frog is commonly used) is brought into connection with the ends of a very delicate galvanometer, so that one extremity of the latter touches the outer surface of the muscle and the other a cross section made through its fibres, the needle will deviate so as to indicate an electric current passing along the wire from the surface of the muscle to its cross section. If both ends of the galvanometer touch points in the length of the muscle equidistant from its middle, no effect ensues, but if one point of contact be farther than the other from the middle, a current will pass along the wire from the nearer to the more distant point. The same results are obtained with a small shred or fasciculus of the muscle. The phenomenon described is called "the muscular current," and is supposed to indicate a state of electric polarity in the particles of the muscle, probably caused by chemical changes going on in its substance.

**Vital properties of muscle.**—The muscular tissue possesses a considerable degree of *sensibility*, but its characteristic vital endowment, as already said, is *irritability* or *contractility*, by which it serves as a moving agent in the animal body.

*Sensibility.*—This property is manifested by the pain which is felt when a muscle is cut, lacerated, or otherwise violently injured, or when it is seized with spasm. Here, as in other instances, the sensibility belongs, properly speaking, to the nerves which are distributed through the tissue, and accordingly, when the nerves going to a muscle are cut, it forthwith becomes insensible. It is by means of this property, which is sometimes called the "muscular sense," that we become conscious of the existing state of the muscles which are subject to the will, or rather of the position and direction of the limbs and other parts which are moved through means of the voluntary muscles, and we are thereby guided in directing our voluntary movements towards the end in view. Accordingly, when this muscular sense is lost, while the power of motion remains,—a case which, though rare, yet sometimes occurs—the person cannot direct the movements of the affected limbs without the guidance of the eye.

*Irritability or Contractility.*—The merit of distinguishing this property of the animal body from sensibility on the one hand, and from mere mechanical phenomena on the other, is due to Francis Glisson, a celebrated English physician of the seventeenth century: but irritability, according to the view which he took of it, was supposed to give rise to various other phenomena in the animal economy besides the visible contraction of muscle, and his comprehensive acceptance of the term has been adopted by many succeeding authorities, especially by writers on pathology. Haller in his use of the term irritability, restricted it to the peculiar property of muscle.

*Stimuli.*—In order to cause contraction, the muscle must be excited by a stimulus. The stimulus may be applied immediately to the muscular tissue, as when the fibres are irritated with a sharp point; or it may be applied to the nerve or nerves which belong to the muscle: in the former case, the stimulus is said to be "immediate," in the latter, "remote." The nerve does not contract, but it has the property, when stimulated, of exciting contractions in the muscular fibres to which it is distributed; and this property, named the "*vis nervosa*," is distinguished from contractility, which is confined to the muscle. Again, a

stimulus may be either directly applied to the nerve of the muscle, as when that nerve is itself mechanically irritated or galvanised; or it may be first made to act on certain other nerves, by which its influence is, so to speak, conducted in the first instance to the brain or spinal cord, and then transferred or reflected to the muscular nerve.

The stimuli to which muscles are obedient are of various kinds: those best ascertained are the following, viz.: 1. Mechanical irritation of almost any sort, under which head is to be included sudden extension of the muscular fibres. 2. Chemical stimuli, as by the application of salt or acrid substances. 3. Electrical; usually by means of a galvanic current made to pass through the muscular fibres or along the nerve. 4. Sudden heat or cold; these four may be classed together as *physical stimuli*. Next, *mental stimuli*, viz.: 1. The operation of the will, or volition. 2. Emotions, and some other involuntary states of the mind. Lastly, there still remain exciting causes of muscular motions in the economy, which, although they may probably turn out to be physical, are as yet of doubtful nature, and these until better known may perhaps without impropriety be called *organic stimuli*; to this head may be also referred, at least provisionally, some of the stimuli which excite convulsions and other involuntary motions which occur in disease.

**Duration of irritability after death.**—It is known that, if the supply of nutrient material be cut off from a muscle by arresting the flow of blood into it, its contractility will be impaired, and soon extinguished altogether, but will after a time be recovered again if the supply of blood be restored. The influence of the blood supplied to muscles in maintaining their contractility has been strikingly shown by Brown-Séquard, who has succeeded in restoring muscular contractility in the bodies both of man and animals some time after death, and after it had become to all appearance extinct, by injecting into the vessels arterial blood deprived of its fibrin, or defibrinated venous blood previously reddened by exposure to the air. In warm-blooded animals in which the nutritive process is more active, and the expenditure of force more rapid, the maintenance of irritability is more closely dependent on the supply of blood and the influence of oxygen, so that it sooner fails after these are cut off. In accordance with this statement, it is known that while the muscles of man and quadrupeds cease to be irritable within a few hours after death, and those of birds still sooner, the muscular irritability will remain in many reptiles and fishes, even for days after the extinction of sensation and volition and the final cessation of the respiration and circulation—that is, after systemic death. A difference of the same kind is observed among warm-blooded animals in different conditions; thus irritability endures longer in new-born animals than in those which have enjoyed respiration for some time and are more dependent on that function; and, in like manner, it is very lasting in hibernating animals killed during their winter sleep.

But the duration of this property differs also in different muscles of the same animal. From numerous careful observations Nysten concluded that in the human body its extinction takes place in the following order, viz.: 1, the left ventricle of the heart; 2, the intestines and stomach; 3, the urinary bladder; 4, the right ventricle; in these generally within an hour; 5, the gullet; 6, the iris; 7, the voluntary muscles, *a*, of the trunk, *b*, of the lower and *c*, of the upper extremities; 8, the left auricle, and, 9, the right auricle of the heart, which last was on this account styled by Galen the "ultimum moriens." In one case Nysten observed the right auricle to continue irritable for sixteen hours and a half after death. But it has been recently found that a voluntary muscle may give signs of a certain degree of irritability even later than this, if it be struck a smart blow with a blunt edge, such as the back of a knife, across the direction of the fibres. The contraction then produced is quite local, and confined to the parts struck. Funke states that he and the brothers Weber obtained this result in the body of a decapitated criminal twenty-four hours after death.

The time of duration is affected by the mode of death. Thus the irritability is said to be almost wholly and immediately extinguished by a fatal stroke of lightning, and to disappear very speedily in the bodies of persons stifled by noxious vapours, such as carbonic acid, and especially sulphuretted hydrogen.



In like manner certain causes acting locally on muscles accelerate the extinction of their irritability.

**Rigor mortis.**—The “cadaveric rigidity,” or stiffness of the body, which ensues shortly after death, is a phenomenon depending on the muscles, which become fixed or set in a rigid state, so as to resist flexion of the joints. The rigidity almost invariably begins in the muscles of the lower jaw and neck, then invades those of the trunk, and afterwards those of the limbs,—the arms usually before the legs. After persisting for a time, it goes off in the same order. It usually comes on within a few hours after death, rarely later than seven hours. In some cases it has been observed to begin within ten minutes (Sommer), and in others not till sixteen or eighteen hours; and the later its access, the longer is its endurance. The rigidity comes on latest, attains its greatest intensity, and lasts longest in the bodies of robust persons, cut off by a rapidly fatal disease, or suddenly perishing by a violent death: in such cases it may last six or seven days. On the other hand, it sets in speedily, is comparatively feeble, and soon goes off in cases where the body has been much weakened and emaciated by lingering or exhausting diseases; also in new-born infants, and in the muscles of animals that have been hunted to death. It seems thus to be affected by the previous state of nutrition of the muscles. Destruction of the nervous centres does not prevent the occurrence of rigidity, nor are the muscles of paralysed limbs exempted from it, provided their nutrition has not been too deeply affected. The fibres of stiffened muscles no longer show the muscular electric current.

The immediate cause of the muscular rigidity is doubtful: some conceive it to be an effect of vital contraction,—the last effort of life as it were; others, with more probability, ascribe it to a solidification of the tissue caused by chemical changes occurring after death. Kühne adduces various arguments, some of them, it must be admitted, of a cogent character, to show that the stiffening is due to post-mortem coagulation of the myosin. He thinks that the substance of the fibre is liquid during life; but it is difficult to reconcile his notion of actual fluidity of substance with some of the most obvious properties of a living muscle. At the same time, it is conceivable that liquid myosin may be present in the interstices of more consistent elements of the living fibre, and may give rise to rigidity by coagulating after death. Free lactic acid is developed in the substance of rigid muscle, and some regard it as the cause of the coagulation of the myosin, but although an acid condition very generally accompanies rigidity, the concurrence is not invariable or essential. Brown-Séguard, in opposition to the chemical theory, maintained that he could remove rigidity by injecting blood into the vessels of the muscle; but Kühne holds this to be impossible after rigor has decidedly set in. The general accession of rigidity is an unequivocal sign of death.

## NERVOUS SYSTEM.

The nervous system consists of a *central part*, or rather a series of connected *central organs*, named the *cerebro-spinal axis*, or *cerebro-spinal centre*; and of the *nerves*, which have the form of cords connected by one extremity with the cerebro-spinal centre, and extending from thence through the body to the muscles, sensible parts, and other organs placed under their control. The nerves form the medium of communication between these distant parts and the centre. One class of nervous fibres, termed *afferent* or *centripetal*, conduct impressions towards the centre,—another, the *efferent* or *centrifugal*, carry motorial stimuli from the centre to the moving organs.

Besides the cerebro-spinal centre and the nervous cords, the nervous system comprehends also certain bodies named *ganglia*, which are connected with the nerves in various situations. These bodies, though of much smaller size and less complex nature than the brain, agree, never-

theless, with that organ in their elementary structure, and to a certain extent also in their relation to the nervous fibres with which they are connected; and this correspondence becomes even more apparent in the nervous system of the lower members of the animal series.

The nerves are divided into the *cerebro-spinal*, and the *sympathetic* or *ganglionic* nerves. The former are distributed principally to the skin, the organs of the senses, and other parts endowed with manifest sensibility, and to muscles placed more or less under the control of the will. They are attached in pairs to the cerebro-spinal axis, and like the parts which they supply are, with few exceptions, remarkably symmetrical on the two sides of the body. The sympathetic or ganglionic nerves, on the other hand, are destined chiefly for the viscera and blood-vessels, of which the motions are involuntary, and the natural sensibility is obtuse. They differ also from the cerebro-spinal nerves in having generally a greyish or reddish colour, in their less symmetrical arrangement, and especially in the circumstance that the ganglia connected with them are much more numerous and more generally distributed. Branches of communication pass from the spinal and several of the cerebral nerves at a short distance from their roots, to join the sympathetic, and in these communications the two systems of nerves mutually give and receive nervous fibres; so that parts supplied by the sympathetic may be also in nervous connection with the cerebro-spinal centre.

The nervous system is made up of a substance proper and peculiar to it, with inclosing membranes, nutrient blood-vessels and supporting connective tissue. The *nervous substance* has been long distinguished into two kinds, obviously differing from each other in colour, and therefore named the *white*, and the *grey* or *cineritious*.

#### STRUCTURAL ELEMENTS.

When subjected to the microscope, the nervous substance is seen to consist of two different structural elements, viz., *fibres* and *cells*. The fibres are found universally in the nervous cords, and they also constitute the greater part of the nervous centres: the cells on the other hand are confined in a great measure to the cerebro-spinal centre and the ganglia, and do not exist generally in the nerves properly so called, although they have been found at the terminations of some of the nerves of special sense, and also interposed here and there among the fibres of particular nerves; they are contained in the grey portion of the brain, spinal cord, and ganglia, which grey substance is in fact made up of these cells intermixed in many parts with fibres, and with a variable quantity of supporting connective substance.

The fibres are of two kinds: 1, the *white, medullated, tubular, or dark bordered*, and 2, the *grey, pale, or non-medullated*. The former are by far the most abundant; the latter are found principally in the sympathetic nerve, but exist also in the cerebro-spinal nerves.

THE WHITE OR MEDULLATED FIBRES (fig. 81).—These form the white part of the brain, spinal cord, and nerves. When collected in considerable numbers and seen with reflected light, the mass which they form is white and opaque. Viewed singly, or few together, under the microscope, with transmitted light, they are transparent; and if quite fresh from a newly killed animal, and unchanged by cold or exposure, they appear as if entirely homogeneous in substance, and are

bounded on each side by a well-defined, simple and usually gently sinuous outline. Their size differs considerably even in the same nerve, but much more in different parts of the nervous system; some being as small as the  $\frac{1}{12000}$ th and others upwards of the  $\frac{1}{1500}$ th of an inch in diameter; moreover, the same fibre may change its size in different parts of its course, and it is generally smaller at its central and peripheral ends. Very speedily after death, and especially on exposure to the action of water, these seemingly homogeneous fibres become altered: and it is when so altered that they are commonly subjected to examination, as represented in fig. 81, A. In particular instances, and in

Fig. 81.

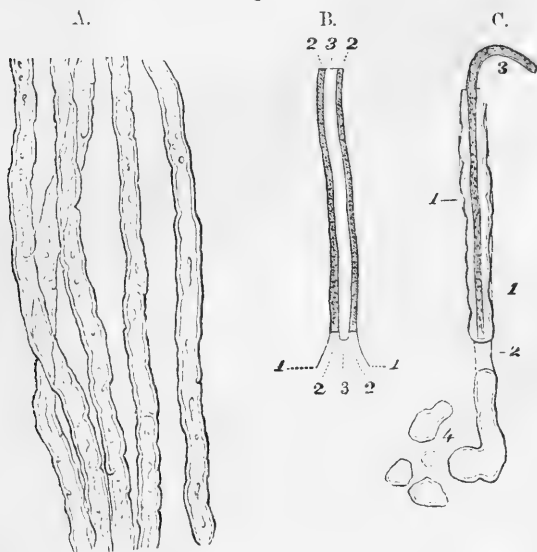


Fig. 81.—A. WHITE OR MEDULLATED NERVE-FIBRES, showing the sinuous outline and double contours (after Bidder and Volkmann).

B. DIAGRAM to show the parts of a medullated fibre, viz. 1, 1, *primitive sheath*. 2, 2, *white substance or medullary sheath*. 3, *axis or primitive band*.

C. DIAGRAM intended to represent the appearances occasionally seen in the tubular fibres. 1, 1, membrane of the tube seen at parts where the white substance has separated from it. 2, a part where the white substance is interrupted. 3, axis projecting beyond the broken end of the tube. 4, part of the contents of the tube escaped.

favourable circumstances, it may be discovered that the fibre is composed of a fine membranous tube, inclosing a peculiar soft substance, and that this contained substance itself is distinguishable into a central part placed like a sort of axis in the middle of the tube, and a peripheral portion surrounding the axis, and occupying the space between it and the tubular inclosing membrane. In the annexed ideal plan (fig. 81, B), the *membranous tube* or *primitive sheath*, is marked 1, 1: the central part, marked 3, was named *cylinder-axis* by Purkinje, who considered it to be identical with the structure previously described by Remak under the name of the *primitive band* (*fibra primitiva*); the matter surrounding it, marked 2, 2, is supposed to be the chief cause of the whiteness of

the brain and nerves, and it was accordingly named the *white substance* by Schwann, and by others, though less appropriately, the *medullary sheath*.

**White substance of Schwann or Medullary Sheath.**—It is this substance, which appears to be of a fatty nature, that undergoes the most marked change on exposure; it then seems to suffer a sort of coagulation or congelation, and when this has taken place, it very strongly refracts the light, and gives rise to the appearance of a dark border on each side of the nerve-tube (fig. 81, A and C). This border, though darker than the rest of the tube, is nevertheless translucent; it is bounded by two nearly parallel lines, so that the nerve-fibre has a double contour. The dark contours pursue a sinuous course, often with deep and irregular indentations; while straight or curved lines of the same character, occasioned no doubt by wrinkles or creases occurring in the layer of white substance, are frequently seen crossing the tube. By continued exposure, round and irregular spots appear at various points, and at length the contents of the nerve-tube acquire a confusedly curdled or granulated aspect.

The double contour appears only in fibres of a certain size; in fine fibres, which become varicose or dilated at intervals, the double line is seen only in the enlargements, and not in the narrow parts between. It often happens that the soft contents of the tube are pressed out at the ruptured extremities, as in fig. 81, C, 4, and then the round or irregular masses of the effused matter are still surrounded by a double contour, which proves that this appearance is produced independently of the membranous tube.

The fine transparent membranous tube, named the **primitive sheath**, or **sheath of Schwann**, presents an apparently homogeneous appearance, with nuclei disposed at intervals along its inner surface.

So long as this tube is accurately filled by the contained matter, its outline can seldom be distinguished; but sometimes, when the white substance separates at various points from the inside of the tube, the contour of the fibre becomes indented and irregular, and then the membrane of the tube may, in favourable circumstances, be discerned as an extremely faint line, running outside the deeply shaded border formed by the white substance, and taking no part in its irregular sinuosities (fig. 81, C, 1, 1). The membranous tube may also be distinguished at parts where the continuity of the contained matter is broken in consequence of traction, squeezing, or like injury of the fibre; in such parts the double line produced by the white substance is wanting, and the faint outline of the membranous tube may be perceived passing over the interruption (2). The primitive sheath is not found on fibres within the substance of the brain and spinal cord.

The **axis-cylinder**, *axis-band*, or *axial-fibre* is situated in, or near, the middle of the nerve-tube, where it may occasionally be seen, on a careful inspection, as a greyish stripe or band, bounded on each side by a very faint even outline, having no share in the sinuosities of the white substance (fig. 81, C).

The axis is of a more tenacious consistence than the white substance, and may accordingly be sometimes seen projecting beyond it at the end of a broken nerve-tube, either quite denuded, or covered only by the tubular membrane, the intervening white substance having escaped. In the brain and spinal cord it is especially easy to obtain this appear-

ance, from the absence of the comparatively tough membranous sheath. Although the name of axis-cylinder would seem to imply that it has actually a cylindrical figure, yet this is by no means certain; and whether naturally cylindrical or not, it certainly often appears more or less flattened when subjected to examination. In the fresh state, and under high powers of the microscope, the axis-cylinder frequently presents an appearance of longitudinal striation, indicating a fibrillar structure (see fig. 89, p. 134); indeed both at the origin and termination of a nerve it may commonly be seen to separate into excessively fine filaments or fibrils. These, the *primitive fibrille* of Max Schultze, are regarded, with the axis-cylinder, which they mainly compose, as the essential part of the nerve: at all events, it frequently happens that these form the only portion of the nerve that remains at the peripheral extremity. Minute varicosities are commonly found on them (fig. 89, *b*), probably the result of post-mortem change. These are not to be confounded as being frequently met with in the medullary sheath. Cross sections of the spinal cord, or of any nerve trunk, which have been stained with carmine and subsequently mounted in balsam or dammar varnish, exhibit the sections of the axis-cylinders as deeply stained dots in or near the centre of the medullated fibres.

**Nodes of Ranvier.**—It has been shown by Ranvier,\* that there constantly occur in peripheral medullated nerve-fibres breaks in the continuity of the white substance, which succeed one another at regular intervals along the course of the nerves; and give the fibres the appearance of being constricted at these places. The breaks or *nodes*, as they may conveniently be termed, divide the fibre into a series of segments of nearly equal length. The segmentation is readily made apparent by the action of a solution of osmic acid, which leaves the nodes (fig. 82, *R, R*) almost colourless, while the medullary sheath, or white substance of Schwann, becomes stained of an irky black colour. In such preparations also the primitive sheath of the fibre often becomes visible, and within this, between it and the white substance, a clear oval nucleus (*c*), with a

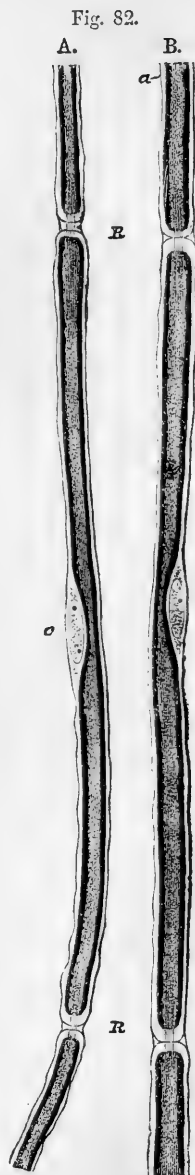

Fig. 82.—PORTIONS OF TWO NERVE-FIBRES STAINED WITH OSMIC ACID. 425 DIAMETERS.

*R, R*, Nodes of Ranvier, with axis-cylinder passing across. *a*, Primitive sheath of the nerve. *c*, Opposite the middle of the segment indicates the nucleus and protoplasm lying between the primitive sheath, and the medullary sheath here stained black. In *A* the nodes are wider, and the intersegmental substance more apparent than in *B*. (From a drawing by Mr. J. E. Neale).

\* Comptes Rendus, 1871; and Arch. de Physiologie, 1872.

certain amount of granular protoplasm. may be seen near the middle of each segment. The primitive sheath turns in at the nodes and surrounds the axis-cylinder as this passes from one segment to the other, so that the sheath is in a manner perforated by the axis-cylinder. The sheaths of successive segments are not directly continuous over the nodes, but are there separated by a certain amount of clear intersegmental substance (shown in A. fig. 82), which forms the "constricting band" of Ranvier, and is probably similar in nature to ordinary intercellular or cementing substance (see p. 15), being like that stained by nitrate of silver. The last-named reagent stains also the axis-cylinder in the neighbourhood of the node, so that the fibres after this treatment appear marked with little crosses (fig. 83); the transverse limb of the cross being due to the ring of intersegmental substance, the longitudinal to the axis-cylinder. Other staining fluids, such as the picrocarminate of ammonia, also act on the axis-cylinder at the nodes; they are probably prevented from reaching it elsewhere owing to the presence of the fatty matter in the surrounding medullary sheath.

Fig. 83.

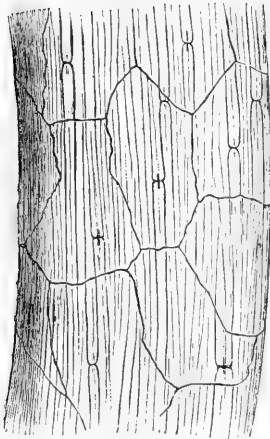


Fig. 84.

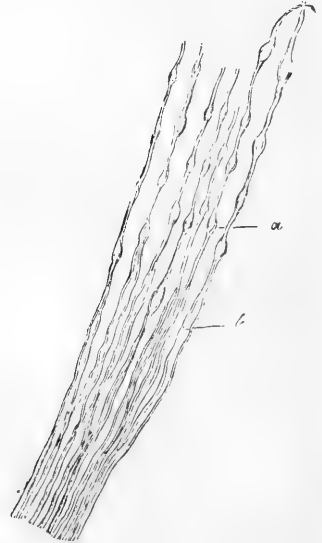


Fig. 83.—A PORTION OF A SMALL NERVE-TRUNK FROM THE THORAX OF THE MOUSE, TREATED WITH NITRATE OF SILVER (Ranvier). MAGNIFIED.

Cross markings are seen at the nodes, and the layer of flattened epithelioid cells which covers the surface is also brought into view.

Fig. 84.—FIBRES FROM THE ROOT OF A SPINAL NERVE.

At *a*, where they join the spinal cord, they are varicose; lower down at *b*, they are uniform and larger (from Valentiu).

No structure corresponding to Ranvier's nodes has, it is believed, hitherto been observed in the non-medullated fibres; they appear to be absent also in the white fibres of the brain and spinal cord.

**Varicose fibres.**—Many of the medullated nerve-fibres, when subjected to the microscope, appear dilated or swollen out at short distances

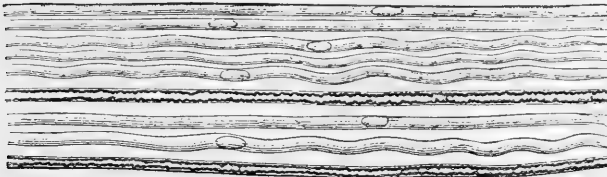
along their length, and contracted in the intervals between the dilated parts. Such fibres have been named *varicose* (fig. 84). They occur principally in the brain and spinal cord, and in the intra-cranial part of the olfactory, in the optic, and acoustic nerves; they are occasionally met with also in the other nerves, especially in young animals. These fibres, however, are naturally cylindrical like the rest, and continue so while they remain undisturbed in their place; and the varicose character is occasioned by pressure or traction during the manipulation, which causes the soft matter to accumulate at certain points, whilst it is drawn out and attenuated at others. Most probably the change takes place before the white substance has coagulated. The fibres in which it is most apt to occur are usually of small size, ranging from  $\frac{1}{12000}$ th to  $\frac{1}{36000}$ th of an inch in diameter; and when a very small fibre is thus affected, the varicosities appear like a string of globules held together by a fine transparent thread. As already remarked, the double contour caused by congelation of the white substance does not appear in the highly constricted parts. The axis takes no part in this change, indeed it may sometimes be seen running through the varicosities and undergoing no corresponding dilatation.

**Course of the fibres.**—Neither in their course along the nervous cords, nor in the white part of the nervous centres, have the medullated fibres ever been observed to unite or anastomose together, nor are they seen to divide into branches; it is therefore fair to conclude that, though bound up in numbers in the same nervous cords, they merely run side by side like the threads in a skein of silk, and that they maintain their individual distinctness throughout the trunk and branches of a nerve; but in many cases the fibres divide in approaching the peripheral termination of the nerve, as will be again noticed.

GREY, PALE, NON-MEDULLATED, OR GELATINOUS FIBRES\* (fig. 85.)  
—The white fibres, at the peripheral extremities of many nerves, lay

Fig. 85.

A.



B.



Fig. 85.—NON-MEDULLATED NERVE-FIBRES (Max Schultz).  
Magnified between 400 and 500 diameters.

A. From a branch of the olfactory nerve of the sheep; at *a, a*, two dark bordered or medullated fibres, from the fifth pair, associated with the pale olfactory fibres.

B. From the sympathetic nerve.

\* These fibres were termed "gelatinous" by Henle, from their aspect, not their chemical nature.

aside their medullary sheath and dark borders, and are prolonged into pale fibres, often minutely dividing, which seem to represent the axis-cylinder deprived of surrounding white substance, and either naked or covered with a prolongation of the primitive sheath. But, apart from these pale continuations of white fibres, there are nerve-fibres which exhibit the non-medullated character throughout their whole length. These are the pale grey fibres first pointed out by Remak, and commonly designated by his name, which are found, with or without associated white fibres, chiefly in the sympathetic but also in other nerves. The branches of the olfactory nerve of man and mammalia consist wholly of these pale fibres. They measure from  $\frac{1}{8000}$ th to  $\frac{1}{3000}$ th of an inch in diameter, appear flattened, translucent, homogeneous, or very faintly granular, and sometimes finely striated longitudinally. At short distances they bear oblong nuclei, which belong to a sheath. In structure these fibres are essentially similar to the axis-cylinder of the medullated fibre, being composed of a bundle of exquisitely fine fibrils with a certain amount of intervening substance. The nucleated sheath corresponds to the primitive sheath of the medullated fibre.

Pale fibres are also met with (in the sympathetic nerve especially) which appear as fine threads with fusiform enlargements. These enlargements are granular in substance, and possibly of the nature of nuclei, but placed in the continuity of the fibre, and not merely attached to a sheath.

**NERVE-CELLS.**—These, as already mentioned, constitute the second kind of structural elements proper to the nervous system. They are found in the grey matter of the cerebro-spinal centre and ganglions, constituting a principal part of the last-mentioned bodies, and thence often named *ganglionic corpuscles* or **ganglion-cells**; they exist also in some of the nerves of special sense at their peripheral expansions, and, here and there, in the course of certain other nerves. The nerve-cells

Fig. 86.

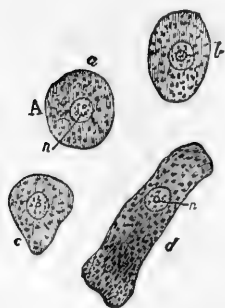


Fig. 86.—GANGLIONIC NERVE-CELLS, MAGNIFIED (from Valentin). The cell-processes are broken off.

*n.*, nucleus.

Fig. 87.

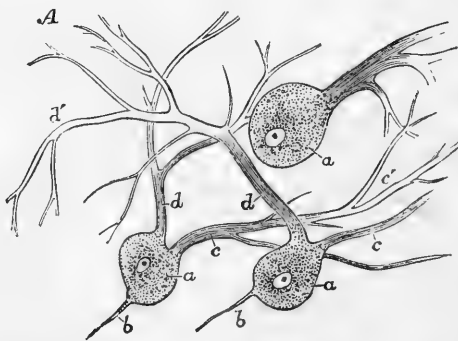


Fig. 87.—NERVE-CELLS FROM THE CORTICAL GREY MATTER OF THE CEREBELLUM. MAGNIFIED 260 DIAMETERS (Kölliker).

may have a spheroidal, oval, or pyriform shape (fig. 86); and such for the most part is their form in the ganglia; but many, and especially



those from the grey matter of the spinal cord and brain, are of an angular or irregular figure, and send out processes, often finely branched, from their circumference (figs. 87, 88, and 90); and then they are often

Fig. 88.

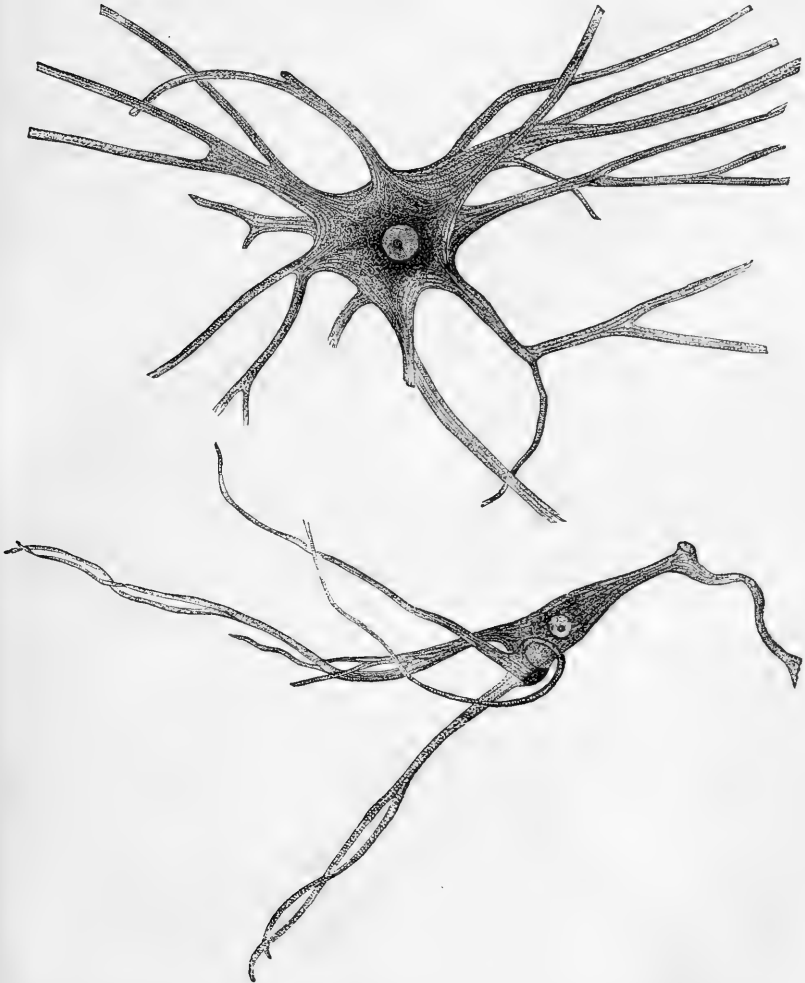


Fig. 88.—TWO NERVE-CELLS FROM ANTERIOR COLUMN OF SPINAL CORD OF OX, ISOLATED AFTER MACERATION IN VERY DILUTE CHROMIC ACID. MAGNIFIED 175 DIAMETERS.

Each cell has a well-defined, clear, round nucleus, and a bright nucleolus. The cell processes are seen to be finely fibrillated, the fibrils passing from one process into another through the body of the cell.

named, according to the number of processes they present, uni-, bi-, and multi-polar; terms obviously ill chosen, but rendered current by use. They have each, as a rule, a large, well-defined, clear, round

nucleus (fig. 88), and within this an equally distinct nucleolus, or rarely more than one. The substance of the cell is soft and translucent, but finely granular or punctuated, and slightly tinged throughout with a brownish red colour; and cells are often seen, especially those of the large ramified kind, with one, or sometimes two, much deeper coloured

Fig. 89.

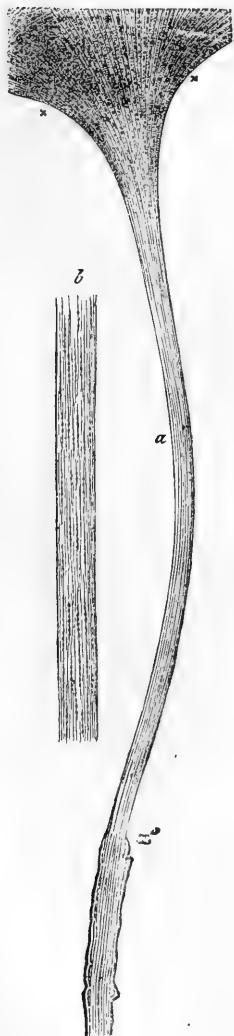


Fig. 90.



Fig. 90.—RAMIFIED NERVE-CELL FROM ANTERIOR CORNU OF SPINAL CORD (MAN).

*a*, axis-cylinder process. *b*, clump of pigment granules. Above the cell is seen part of the network of fibrils mentioned in the text (from Gerlach).

Fig. 89.

x, x, Portion of nerve-cell from spinal cord of ox, with axis-cylinder process, *a*, coming off from it and acquiring at *a'* a medullary sheath. Highly magnified.

*b*, represents an axis-cylinder, still more magnified, showing the fine varicose fibrils which it contains (from Max Schultze.)

brown patches caused by groups of pigment granules (fig. 90, *b*); the colour is deeper in adult age than in infancy.

The bodies in question are destitute of a proper envelope. The out-runners or branches are formed by prolongations of the same soft substance which forms the cell-body; they are, therefore, very readily broken, and the cells thereby mutilated, in the manipulation required for their insulation. A fibrillation similar to that in the axis-cylinders of medullated nerve-fibres is seen in these processes (figs. 88, 89); it may be observed also passing from them through the body of the cell, and from one process to another; we have, however, never succeeded in tracing any connection of these fibrils with either the nucleus or the nucleolus of the cell as has been affirmed by some.

According to Deiters, one process (and only one) of each of the cells of the grey matter of the spinal cord passes directly into the axis-cylinder of a nerve-fibre, as represented in figs. 89, 90. This process he describes as being unbranched from the commencement. The other processes divide into finer and finer branches, but what becomes of the ultimate divisions is not certainly known. The fibrils resulting from the repeated divisions join, it is said, with processes of other cells to form a close network (fig. 90) throughout the grey substance of the cord, and from this network other fibrils may, it is supposed, proceed and unite to form the axis-cylinders of issuing nerves. We may remark, however, that the presence of an undivided axis-cylinder process is by no means so constant in these cells as is commonly described.

Other cells (fig. 91, *a*) are found in the nervous substance, which are distinguished chiefly by the pellucid, colourless, and homogeneous aspect of the matter contained in them; such cells possess a nucleus like the rest; they are seldom large, and have usually a simple round or oval figure, but may also be found branched. They occur along with nerve-cells of the kind before described. Lastly, small bodies of the size of human blood-corpuscles and upwards, containing one or more bright specks like nucleoli, abound in the grey matter in certain situations (fig. 91 *b*, *c*.) These bodies, which are sometimes called "granules" resemble the nuclei of nerve-cells; and it may be a question whether they are not the nuclei of cells in which the cell-matter or protoplasm is very scanty, and accidentally detached in examination. These nucleus-like bodies are very abundant in the superficial grey matter of the cerebellum.

In the grey matter of the cerebro-spinal centre, the nerve-cells appear as if imbedded in a sort of matrix of granular substance, interposed between them in greater or less quantity, and very generally traversed by nerve-fibres. But it is very probable that the appearance of granular or molecular matter results from a confused interlacement of very fine fibrils, and especially of the fine ramifications of nerve-cells; or from

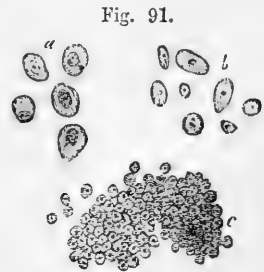


Fig. 91.—SMALL CELLS FROM THE NERVOUS CENTRES.

*a*, from the (cortical) grey matter of the brain. *b* and *c* are from the cortical substance of the cerebellum; *b* resemble detached cell-nuclei. *c* are smaller bodies, also like cell-nuclei, densely aggregated (from Hannover, magnified 340 diameters).

the crushing and breaking down of such fibres in the process of examination. In the ganglia properly so called, the cells are packed up among nerve-fibres, but each cell is also immediately surrounded by an inclosing capsule (fig. 93 *b*).

The proper nervous substance of the brain and spinal cord is described by Kölliker as being traversed in all directions and supported by a frame-

Fig. 92.

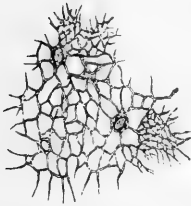


Fig. 92.—PART OF THE  
RETICULUM FROM THE  
SPINAL CORD.

Open meshes are seen generally, but at two places close lamelliform interlacements are shown. Magnified 350 diameters (Kölliker).

work of connective tissue—the “retiform” connective tissue described at page 69. This is stated to be formed of an interunion of ramified connective tissue corpuscles, or of a network of fine fibres alone, originally proceeding from such corpuscles. Kölliker names this supporting structure the *reticulum* of the nervous centres (fig. 92). Virchow proposes the term *neuroglia*. It is not merely an open mesh-work, but consists also of fine laminae formed of a close interlacement of the finest fibrils, disposed as membranous partitions and tubular compartments for separating and enclosing the nervous bundles. Besides these ramified cells others are found (Deiters) which are flattened and distinctly fibrillated, somewhat like the cells of developing connective tissue. Moreover, the granular matrix above described, in which the nerve-cells are imbedded, is considered by Boll to be derived from connective tissue cells, which

have undergone a granular rather than a fibrillar metamorphosis.\*

Such being the structural elements of the nervous substance, we have next to consider the arrangement of the cells and fibres in the ganglia and nerves which they contribute to form; the intimate structure of the encephalon and spinal cord being treated of in the part of this work which is devoted to special or descriptive anatomy.

#### OF THE GANGLIA.

The bodies so named are found in the following situations—viz. :  
1. On the posterior root of each of the spinal nerves; on one, and probably the corresponding root of the fifth nerve of the encephalon; and on the seventh pair, glosso-pharyngeal and pneumogastric nerves, involving a greater or less amount of their fibres; also on the branches of certain cerebro-spinal nerves. 2. Belonging to the sympathetic nerve. (*a*)—In a series along each side of the vertebral column, connected by nervous cords, and constituting what was once considered as the trunk of the sympathetic. (*b*)—On branches of the sympathetic; occurring numerously in the abdomen, thorax, neck, and head; generally in the midst of plexuses, or at the point of union of two or more branches. Those which are found in several of the fossæ of the cranium and face are for the most part placed at the junction of fine branches of the sympathetic with branches, usually larger, of the cerebro-spinal

\* Stieda, Studien über das centrale Nerven-system, Z. für Zool., 1868, 1870. Golgi, Contribuzione alle fina Anatomia degli Organi centrali del Sistema nervoso; Rivista Clinica, 1871. Boll, Die Histologie und Histiogenese der Nervöse Central-organe, Berlin, 1873.

nerves; but they are generally reckoned as belonging to the sympathetic system.

The ganglia differ widely from each other in figure and size: those which have been longest known to anatomists are most of them large and conspicuous objects; but by the researches of Remak and others, it has been shown that there are numerous small, or what might be almost termed microscopic ganglia, disposed along the branches of nerves distributed to the tongue, the heart, the blood-vessels, the lungs, and some other viscera; also connected with fine plexuses of nerves between the coats of the intestines.

Ganglia are invested externally with a thin, but firm and closely adherent envelope, continuous with the fibrous sheath of the nerves, and composed of connective tissue: this outward covering sends processes inwards through the interior mass, dividing it, as it were into lobules, and supporting the numerous fine vessels which pervade it. A section carried through a ganglion, in the direction of the nervous cords connected with it, discloses to the naked eye merely a collection of reddish-grey matter traversed by the white fibres of the nerves. The nervous cords on entering lay aside their investing sheath and spread out into smaller bundles, between which the grey ganglionic substance is interposed; and their fibres are gathered up again into cords, furnished with sheaths, on issuing from the ganglion. The microscope shows that this grey substance consists of nerve-cells and fibres with supporting connective tissue. The nerve-cells have mostly a round, oval, or pyriform figure. They are enclosed in capsules formed of a transparent membrane with nuclei (fig. 93, *b*, 94, 95): these capsules are apparently continuous with the primitive sheaths of the nerves (M. Schultze).

Of the relation between the nerve-fibres in a ganglion and the ganglion-cells, it may be stated that many fibres pass through without being connected with the cells, but that every nerve-cell is connected with a fibre or with fibres. According to Beale, each cell is connected with, at least, two fibres, which, on reaching the nervous bundle in which they are distributed, run in opposite directions (fig. 94). One of the fibres is straight, usually of tolerable size, and connected with the cell at one spot like a stalk—in pyriform cells at the small end. The other, usually smaller, begins or is attached at some distance

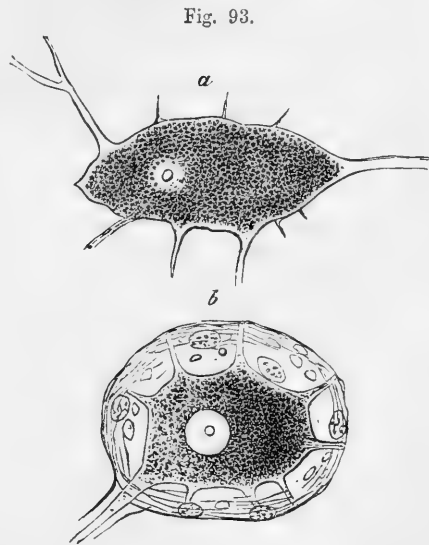


Fig. 93.—MULTI-POLAR GANGLION CELLS FROM SYMPATHETIC OF MAN (Max Schultze). Magnified.

*a*, freed from capsule; *b*, enclosed within capsule. The processes of both are broken off a short distance from the cell.

from the insertion of the first, and makes several turns on the surface of the cell, but within its capsule, which are continued as spiral coils round the straight fibre, and then the two part company, and apparently run in opposite directions in the nervous bundle in which they mingle.

The spiral fibre bears large oblong nuclei along its course. These are seen on its spiral turns upon the surface of the cell, and some, at the commencement of the fibre, seem to be beneath the surface. It may be single from the first, or begin by two or more filaments which join at some distance from the cell. Both fibres increase in size as

Fig. 94.

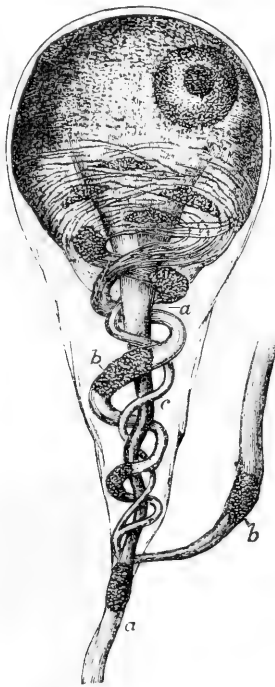

Fig. 95.

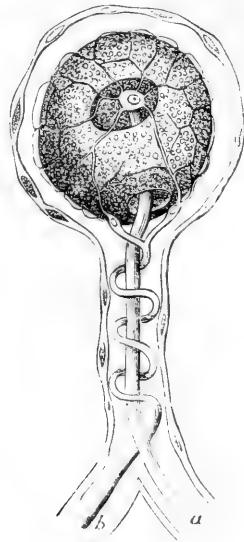


Fig. 94.—GANGLION-CELL OF A FROG, MAGNIFIED; ACCORDING TO BEALE.

Reduced and adapted from one of his figures. *a, a*, straight fibre; *b, b*, coiled fibre; *c*, smaller one joining it.

Fig. 95.—MAGNIFIED GANGLION-CELL, FROM THE SYMPATHETIC OF THE FROG, ACCORDING TO J. ARNOLD. Virch. Arch. 1865.

*a*, straight fibre; *b*, coiled fibre, arising by a superficial net connected with nucleolus of the cell; *c, c*, capsule with nuclei.

they proceed. They have at first the character of pale fibres (or axis-cylinders), then one of them—generally the straight one, but it may be the other—at a short distance from the cell acquires a medullary sheath and becomes a dark bordered fibre. At the same time it cannot be positively said that both fibres may not become dark bordered, or both continue as pale fibres. The spiral fibres may make more or fewer

coils, and Beale thinks the coils are more numerous in older cells—for in some cases the smaller fibre (answering to the spiral one elsewhere) is not coiled; the cells in such cases he considers to be young or recently formed.

Beale's observations were chiefly made on the ganglia of frogs, the cells of which have very commonly a pyriform shape like the one represented in the figure. In mammalia they are more spheroidal, and the observation of their connection with fibres is more difficult; but from examinations in mammalia, he was led to infer that the relation of the cells and fibres is essentially the same as in frogs.

Two subsequent writers, Julius Arnold, and L. G. Courvoisier, confirmed the original observation of Beale in almost every point; but whilst the last-named observer described the two fibres as connected with the substance of the cell and at its surface only—or, at least, could not obtain satisfactory evidence of their passing into the interior—Arnold, and (after him) Courvoisier describe (as had previously been done by Harless and others) the straight fibre as traceable into the nucleus, with which Arnold thinks its medullary sheath, here altogether inconsiderable, is continuous, whilst the axial part ends in the nucleolus, which he regards as the knobbed end of the axis-cylinder (fig. 95). They both describe a network of exquisitely fine fibrils, which, springing from the nucleolus as a centre, traverses the substance of the cell and comes to the surface between the cell-body and its sheath, and finally unites into the spiral fibre. According to this account, the nucleolus is, as it were, the end of the straight fibre and beginning of the spiral one, or *vice versa*; or, at least the point of organic connection between them in the cell. Courvoisier describes both fibres as acquiring a medullary sheath, the straight one first. He has found the above described structure in the ganglia of fish, birds, and mammals; but whilst in the frog the cell has never, or scarcely ever, more than one straight and very rarely more than one spiral fibre, he finds that in other vertebrates a cell may give off such twin fibres from two or more parts of its circumference.

With regard to the alleged connection of the fibres with the nucleus and nucleolus of the cell, we would remark that no such connection is observable in other nerve-cells.—those of the spinal cord for instance. And recent observers have for the most part failed to corroborate the statements of Arnold and Courvoisier. On the other hand, it is probable that the primitive fibrils of the nerves are continuous with one another through the body of the cell.

Besides such cells as have now been described, others are not unfrequently met with in which there is a different arrangement. In the spinal ganglia of the skate, torpedo, dogfish, &c., as first pointed out by R. Wagner, two fibres are connected with each ganglion-cell at opposite sides—one directed centrally towards the root of the nerve, and the other outwardly towards its branches (fig. 96).

Fig. 96.

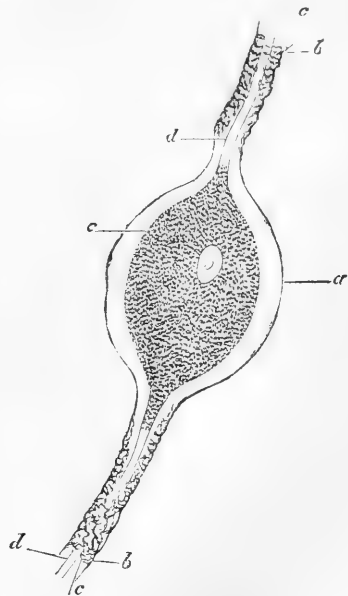


Fig. 96. — BIPOLAR GANGLION-CELL FROM SPINAL GANGLION OF PIKE. 350 DIAMETERS. (Kölliker.)

a, Capsule of cell continuous with, b, sheath of nerve. c, medullary sheath. d, axis-cylinder. e, body of cell.

In the spinal ganglia of man the cells commonly appear to possess but a single process, which runs peripherally; on the other hand, multipolar cells are occasionally found. The latter, according to Max Schultze, are also to be met with in the sympathetic ganglia (see fig. 93).

#### OF THE CEREBRO-SPINAL NERVES.

**Construction.**—These nerves are formed of the nerve-fibres already described, collected together and bound up in sheaths of connective tissue. A larger or smaller number of fibres inclosed in a tubular sheath form a slender round cord of no determinate size, usually named a *funiculus*; if a nerve be very small it may consist of but one such cord, but in larger nerves several funiculi are united together into one or more bundles, which, being wrapped up in a common membranous covering, constitute the nerve (fig. 97). Accordingly, in dissecting a nerve, we first come to an outward covering, formed of connective tissue, often so strong and dense that it might well be called fibrous. From this common sheath we trace laminae passing inwards between the larger and smaller bundles of funiculi, and finally between the funiculi themselves, connecting

Fig. 97.

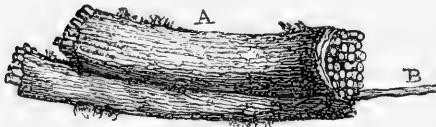


Fig. 97.—PORTION OF THE TRUNK OF A NERVE CONSISTING OF MANY SMALLER CORDS OR FUNICULI WRAPPED UP IN A COMMON SHEATH.

A, the nerve; B, a single funiculus drawn out from the rest (from Sir C. Bell).

them together as well as conducting and supporting the fine blood-vessels which are distributed to the nerve. But, besides the interposed areolar tissue which connects these smallest cords, each funiculus has a special sheath of its own, as will be immediately noticed.

The common sheath and its subdivisions consist of connective tissue, presenting the usual white and yellow constituent fibres of that texture, the latter being present in considerable proportion: frequently also a little fat is to be found. The special sheaths of the funiculi, on the other hand, appear to be formed essentially of a fine transparent membrane, which may without difficulty be stripped off, in form of a tube, from the little bundle of nerve-fibres of which the funiculus consists. When examined with a high power of the microscope, this membrane presents the aspect of a thin transparent film, which in some parts appears to be quite simple and homogeneous, but is more generally marked with extremely fine reticulated fibres. Corpuscles resembling elongated cell-nuclei may be seen upon it when acetic acid is applied, and by treatment with nitrate of silver it may be shown that the film above mentioned is not in reality simple, but is made up of two, three, or more excessively delicate lamellae, on the surface of which an epithelioid layer of extremely fine flattened cells, to which the nuclei above mentioned belong, may occasionally be observed. The fine reticulated fibres seen on the lamellae are probably of an elastic nature; in some parts they appear merely as a series of granules, as if incompletely developed (see p. 71). Moreover, small plates of elastic substance are here and there met with in the lamellae which also appear granulated near their edges (Ranvier).



The tissue here described as investing each funiculus and enclosing its proper fibres is named the *neurilemma*.\* It is covered quite externally by a layer of large thin flattened cells, the outlines of which are brought into view by the silver treatment (as in fig. 83).

The funiculi of a nerve are not all of one size, but all are sufficiently large to be readily seen with the naked eye, and easily dissected out from each other. In a nerve so dissected into its component funiculi, it is seen that these do not run along the nerve as parallel insulated cords, but join together obliquely at short distances as they proceed in their course, the cords resulting from such union dividing in their further progress to form junctions again with collateral cords; so that in fact the funiculi composing a single nervous trunk have an arrangement with respect to each other similar to that which we shall presently find to hold in a plexus formed by the branches of different nerves. It must be distinctly understood, however, that in these communications the proper nerve-fibres do not join together or coalesce. They pass off from one nervous cord to enter another, with whose fibres they become intermixed, and part of them thus intermixed may again pass off to a third funiculus, or go through a series of funiculi and undergo still further intermixture; but throughout all these successive associations (until near the termination of the nerve) the fibres remain, as far as known, individually distinct, like the threads in a rope.

The fibres of the cerebro-spinal nerves are chiefly, in some cases perhaps exclusively, of the white or medullated kind, but in most instances there are also grey fibres in greater or less number. Moreover, filaments of extreme tenuity, like the white filaments of connective tissue, occur, mixed up with well-characterised nerve-fibres within the sheaths of the funiculi. Lying alongside each other, the fibres of a funiculus form a little skein or bundle, which runs in a waving or serpentine manner within its sheath; and the alternate lights and shadows caused by the successive bendings being seen through the sheath, give rise to the appearance of alternate light and dark cross stripes on the funiculi, or even on larger cords consisting of several funiculi. On stretching the nerve, the fibres are straightened and the striped appearance is lost.

**Vessels.**—The *blood-vessels* of a nerve, supported by the sheath, divide into very fine capillaries. These, which are numerous, run parallel with the fibres, many of them within the funicular sheaths, but are connected at intervals by short transverse branches, so as in fact to form a network with long narrow meshes. *Lymphatics* are found in the uniting connective tissue or perineurium. Little is known of their mode of commencement, but it is probable that, as in other parts, they take origin in the connective tissue. Spaces which appear to be lymphatic are met with between the layers of the neurilemma.

**Branching and conjunction of Nerves.**—Nerves in their progress very commonly divide into branches, and the branches of different nerves not unfrequently join with each other. As regards the arrange-

\* Some recent writers believing that the primitive sheath of the nerve-fibre corresponds to the sarcolemma of muscle, have proposed to designate it as the neurilemma, and to use the term *perineurium* for the coarser sheathing of the nerves and nervous cords, to which the term neurilemma has been usually applied. The use of the term *perineurium* is unobjectionable, and may sometimes be convenient, but the proposed new and restricted application of the term *neurilemma* would lead to ambiguity, and is of doubtful propriety. The general external covering of the nervous trunks has been named "cellular sheath" (*vagina cellulosa*).

ment of the fibres in these cases, it is to be observed, that, in the branching of a nerve, collections of its fibres successively leave the trunk and form branches; and that, when different nerves or their branches intercommunicate, fibres pass from one nerve to become associated with those of the other in their further progress; but in neither case (unless towards their peripheral terminations) is there any such thing as a division or splitting of an elementary nerve-fibre into two, or an actual junction or coalescence of two such fibres together.

A communication between two nerves is sometimes effected by one or two connecting branches. In such comparatively simple modes of connection, which are not unusual, both nerves commonly give and receive fibres; so that, after the junction, each contains a mixture of fibres derived from two originally distinct sources. More rarely the fibres pass only from one of the nerves to the other, and the contribution is not reciprocal.

In other cases the branches of a nerve, or branches derived from two or from several different nerves, are connected in a more complicated manner, and form what is termed a plexus. In plexuses—of which the one named “brachial” or “axillary,” formed by the great nerves of the arm, and the “lumbar” and “sacral,” formed by those of the lower limb and pelvis, are appropriate examples—the nerves or their branches join and divide again and again, interchanging and intermixing their fibres so thoroughly that, by the time a branch leaves the plexus, it may contain fibres from all the nerves entering the plexus. Still, as in the more simple communications already spoken of, the fibres, so far as is known, remain individually distinct throughout.

In some instances of nervous conjunctions certain collections of fibres, after passing from one nerve to another, take a retrograde course in that second nerve, and, in place of being distributed peripherally with its branches, turn back to its root and rejoin the cerebro-spinal centre. An apparent example of such nervous arches without peripheral distribution is afforded by the optic nerves, in which various anatomists admit the existence of arched fibres that seem to pass across the commissure between these nerves from one optic tract to the other, and to return again to the brain. These, however, are perhaps to be compared with the commissural fibres of the brain itself, of which there is a great system connecting the symmetrical halves of that organ. But instances of a similar kind occurring in other nerves have been pointed out by Volkmann; as in the connection between the second and third cervical nerves of the cat, also in that of the fourth cranial nerve with the first branch of the fifth in other quadrupeds, and in the communications of the cervical nerves with the spinal accessory and the descendens noni. But certain fibres of the optic nerves take a course deviating still more from that followed generally, for they appear to be continued across the commissure from the eyeball and optic nerve of one side to the opposite nerve and eye, without being connected with the brain at all, and thus to form arches with peripheral terminations, but no central connection. In looking, however, for an explanation of this arrangement, it must be borne in mind that the retina is itself originally an outgrowth from the brain and contains nerve-cells, like those of the nervous centres, and perhaps the fibres referred to may be intended merely to bring the collections of nerve-cells of the two sides into relation independently of the brain. Julius Arnold has found an arrangement of fibres at the junctions of the nerve-plexus of the iris similar to that in the optic commissure.\*

The disposition of the fibres at the points of division and junction of the

\* Virchow's Arch. 1863.

branches of nerves still requires further investigation. For some interesting observations on the subject the reader is referred to a paper by Beale.\*

**Origins or Roots of the Nerves.**—The cerebro-spinal nerves, as already said, are connected by one extremity to the brain or to the spinal cord, and this central extremity of a nerve is, in the language of anatomy, named its origin or root. In some cases the root is single, that is, the funiculi or fibres by which the nerve arises are all attached at one spot or along one line or tract; in other nerves, on the contrary, they form two or more separate collections, which arise apart from each other and are connected with different parts of the nervous centre, and such nerves are accordingly said to have two or more origins or roots. In the latter case, moreover, the different roots of a nerve may differ not only in their anatomical characters and connections, but also in function, as is well exemplified in the spinal nerves, each of which arises by two roots, an anterior and a posterior—the former containing the motor fibres of the nerve, the latter the sensory.

The fibres of a nerve, or at least a considerable share of them, may be traced to some depth in the substance of the brain or spinal cord, and hence the term “apparent or superficial origin” has been employed to denote the place where the root of a nerve is attached to the surface, in order to distinguish it from the “real or deep origin” which is beneath the surface and concealed from view.

To trace the different nerves back to their real origin, and to determine the points where, and the modes in which their fibres are connected with the nervous centre, is a matter of great difficulty and uncertainty; and, accordingly, the statements of anatomists respecting the origin of particular nerves are in many cases conflicting and unsatisfactory. Confining ourselves here to what applies to the nerves generally, it may be stated, that their roots, or part of their roots, can usually be followed for some way beneath the surface, in form of white tracts or bands distinguishable from the surrounding substance; and very generally these tracts of origin may be traced towards deposits of grey nervous matter situated in the neighbourhood; such, for instance, as the central grey matter of the spinal cord, the grey centres of the pneumo-gastric and glosso-pharyngeal nerves, the corpora geniculata and other larger grey masses connected with the origin of the optic nerve. It would further seem probable that certain fibres of the nerve-roots take their origin in these local deposits of grey matter, whilst others become continuous with the white fibres of the spinal cord or encephalon, which are themselves connected with the larger and more general collections of grey matter situated in the interior or on the surface of the cerebro-spinal centre.

There is still much uncertainty as to the precise mode in which the nerve-fibres originating or terminating in the grey matter are related to its elements, and for the most part, indeed, individual fibres on being traced into the grey matter, become so hidden in the mass as to elude further scrutiny. Nevertheless, as a continuity between the nerve-fibres and nerve-cells in the grey matter has now been traced in individual examples by many different observers, and as such connections may be held to be general in the ganglions, it is not unfair to infer that, but for the obstacles to successful investigation, the cells in the grey matter of the cerebro-spinal centre would by this time also have been shown to be generally connected with the nerve-fibres.

\* On the Branching of Nerve-Trunks, &c., Archives of Medicine, vol. iv., p. 127.

Three modes of connection of cells with fibres are described. 1. From a cell, which may have several branched outrunners, one stout unbranched process is continued into a nerve-fibre, at first naked, and probably representing only the axis-cylinder, then acquiring a medullary sheath and dark borders, and finally a membranous tube or primitive sheath (figs. 89, 90, p. 134). 2. From one or more finely divided branches of a cell, or of more than one cell, equally fine fibrils are prolonged, which coalesce into a pale fibre, having the characters of an axis-cylinder, which then, as in the former case, may in its progress become a dark-bordered medullated fibre. 3. The extreme ramifications of a cell or cells, become connected, as in the last case, with fibrils, which join into a nerve-fibre; but the connection takes place by the intervention of small bipolar cells, which are by one pole continuous with the branches of the larger cell or cells, and by the other with fine fibrils which join into a pale fibre, or into an axis-cylinder of a dark-bordered fibre. Gerlach, and after him Waldeyer and others, have described this last mode of connection, as seen by them in the cerebellum. The statement also derives support from the observations of Lockhart Clarke, on the structure of the olfactory bulb. Along with this indirect connection through small intervening cells, Gerlach supposes that a process or processes of the large cells pass directly into nerve-fibres; and should such direct connection take place by the prolongation of an unbranched cell-process into a nerve-fibre, the arrangement would be analogous to that in the ganglia: the simple origin, representing that of the straight fibre from the ganglion-cell, whilst the ramified origin, with the intervening small cells, might be compared to that of the superficial or spiral fibre, with its interposed nuclei.

The primitive fibrils may, as already stated, be frequently observed to pass through the nerve-cells from one process into another. Wherever this is found it seems reasonable to regard the cells rather as interpolations in the course of the nerves than as actually giving origin to them; this is more especially the case in those instances in which a comparatively small, nucleated swelling on a peripheral fibre represents a nerve-cell.

The fibres of origin of a nerve, whether deeply implanted or not, on quitting the surface of the brain or spinal cord to form the apparent origin or free part of the root, are in most cases collected into funiculi, which are each invested with a sheath of neurilemma. This investment is generally regarded as a prolongation of the pia mater, and in fact its continuity with that membrane may be seen very plainly at the roots of several of the nerves, especially those of the cervical and dorsal nerves within the vertebral canal, for in that situation the neurilemma, like the pia mater itself, is much stronger than in the cranium. The funiculi, approaching each other if originally scattered, advance towards the foramen of the skull or spine which gives issue to the nerve, and pass through the dura mater, either in one bundle and by a single aperture, or in two or more fasciculi, for which there are two or more openings in the membrane. The nerve-roots in their course run beneath the arachnoid membrane, and do not perforate it on issuing from the cranio-vertebral cavity; for the loose or visceral layer of the arachnoid is prolonged on the nerve and loosely surrounds it as far as the aperture of egress in the dura mater, where, quitting the nerve, it is reflected upon the inner surface of the latter membrane, and becomes continuous with the

parietal or adherent layer of the arachnoid. The nerve, on escaping from the skull or spine, acquires its external, stout, fibrous sheath, which connects all its funiculi into a firm cord, and then, too, the nerve appears much thicker than before its exit. The dura mater accompanies the nerves through the bony foramina, and becomes continuous with their external sheath and (at the cranial foramina) with the pericranium; but the sheath does not long retain the densely fibrous character of the membrane with which it is thus connected at its commencement.

The arrangement of the membranes on the roots of certain of the cranial nerves requires to be specially noticed.

The numerous fasciculi of the olfactory nerve pass through their foramina almost immediately after springing from the olfactory bulb, and then also receive their neurilemma. The bulb itself, and the intracranial part of the nerve, which are to be regarded as being really a prolongation or lobe of the brain, are invested externally by the pia mater, but are not fasciculated. The arachnoid membrane passes over the furrow of the brain in which this part of the nerve lies, without affording it a special investment.

The optic nerve becomes subdivided internally into longitudinal fasciculi by neurilemma a little way in front of the commissure: on passing through the optic foramen it receives a sheath of dura mater, which accompanies it as far as the eyeball. The acoustic nerve becomes fasciculated, receives its neurilemma, and acquires a firm structure on entering the meatus auditorius internus in the temporal bone, towards the bottom of which it presents one or more small ganglionic swellings containing the characteristic cells. Up to this point it is destitute of neurilemma, and is of soft consistence, whence the name "portio mollis" applied to it.

The larger root of the fifth pair acquires its neurilemma and its fasciculated character sooner at its circumference than in the centre, so that, in the round bunch of cords of which it consists, those placed more outwardly are longer than those within, and, when all are pulled away, the non-fascicular part of the nerve remains in form of a small conical eminence of comparatively soft nervous substance.

Most of the nerves have ganglia connected with their roots. Thus, the spinal nerves have each a ganglion on the posterior of the two roots by which they arise; and in like manner several of the cranial, viz., the fifth, seventh, glosso-pharyngeal, and pneumo-gastric, are furnished at their roots, or at least within a short distance of their origin, with ganglia which involve a greater or less number of their fibres, as described elsewhere in the special anatomy of these nerves.

TERMINATION, OR PERIPHERAL DISTRIBUTION, OF NERVES.—It may be stated, generally, and apart from what may apply to special modes of termination, that, in approaching their final distribution, the *fibres* of nerves, medullated and non-medullated, commonly divide into branches (fig. 98); and the former, either before or after division, generally lose their medullary sheath, and consequently their dark borders, and take on the characters of pale fibres. The axis-cylinder participates in the division, and it might be said that the white fibres are represented in their further progress by the axis-cylinder and its ramifications; still, the primitive sheath or membranous tube continues some way along these pale branches after the medullary sheath has ceased, but may finally too desert them. By repeated division the fibres become smaller and smaller; but whilst some of the resulting small fibres may be simple, many are really bundles of exquisitely fine pale fibrils, straight,

sinuous, or somewhat tortuous in their course. They bear nuclei, some of which, no doubt, may appertain to the prolongation of the primitive sheath; but others, generally fusiform and granular, are interposed, as

Fig. 98.

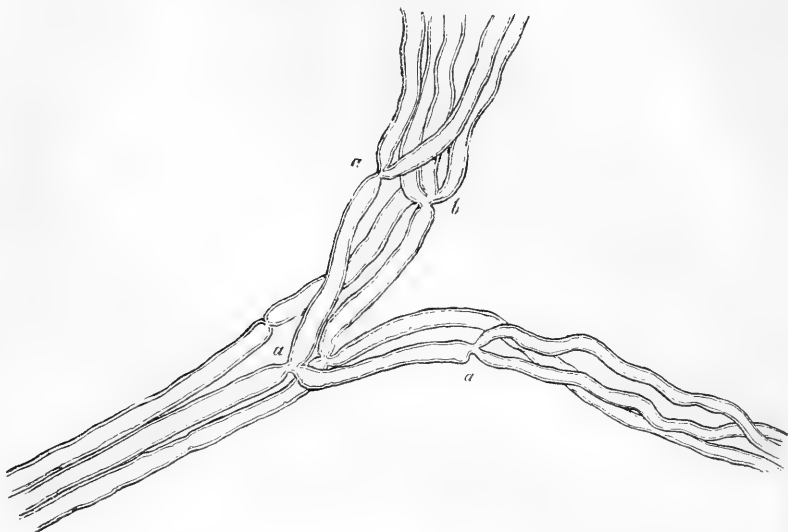


Fig. 98.—SMALL BRANCH OF A MUSCULAR NERVE OF THE FROG, NEAR ITS TERMINATION, SHOWING DIVISIONS OF THE FIBRES. MAGNIFIED 350 DIAMETERS (Kölliker).

*a*, into two; *b*, into three.

it were, in the course of the fibres, and are continuous with them at either end; nuclei, moreover, of a triangular or irregular shape, are common at the bifurcations of the fibres. These pale fibres often join into networks; but their further disposition in different parts will be treated of below. In the meantime it must be explained that the original dark-bordered fibres which thus undergo division and change, or which may proceed singly to end in a different and special manner, are commonly provided with a tolerably strong sheath with nuclei, which, as it stands well apart from the dark borders of the fibre, is very conspicuous. This is sometimes considered to be only the primitive sheath of the fibre modified in character, but it seems more probable that it is derived from the neurilemma or perineurium which incloses the fine bundles or funiculi, and, as these part into smaller collections and single fibres, undergoes a corresponding division, and finally sends sheaths along single fibres.

In further treating of the termination of nerves, it will be convenient to consider the sensory and motor nerves separately.

**Termination of sensory nerves.**—Of the sensory, or, at least, non-muscular nerves, the following modes of final distribution have been recognised.

A. By networks, or terminal plexuses. These are formed by the

branching and interjunction of the fibrils, above described as resulting from the division of the pale fibres or of the axis-cylinder of the white fibres. The meshes of the net may be at first wider, and the threads, or bundles of threads, larger, but from these, finer filaments forming closer reticulations proceed, and then sometimes the nuclei become less frequent, or disappear. Such networks are found in the skin, in various parts of the mucous membranes, in the cornea, and in various other parts: they will be most conveniently considered in the description of the organs to which they belong.

B. Sensory terminal organs. Three varieties of these are now recognised, viz., *end-bulbs*, *tactile-corpuscles*, and *Pacinian bodies*. These have so far a common structure, that in all of them there is an inward part or core (*Innenkolben*, Germ.) of soft, translucent substance; an outer membranous capsule with pertaining corpuscles; and, finally, one or sometimes more nerve-fibres, pale and without dark contours, which pass into the core and apparently end with a free, usually somewhat swollen, or knobbed extremity. Thus agreeing in their internal and probably essential structure, the terminal organs differ chiefly, or at least most obviously, in their capsule, which, simple in the end-bulbs, becomes highly complicated in the Pacinian bodies; and therefore in the further account of them it will be convenient to begin with the former, although the Pacinian bodies have been much longer known.

**End-bulbs.**—Noticed incidentally by Kölliker, but first investigated and recognised as distinct organs by W. Krause, who named them *Endkolben*. Their figure in man and apes is usually spheroidal (fig. 99), but oblong in some quadrupeds. They measure about  $\frac{1}{500}$ th of an inch in diameter, but may exceed this in length with a less breadth, when of an oval shape. They have a simple outer capsule of connective tissue, bearing nuclei, and within this a core of clear soft matter, in which specks resembling fat-granules become visible after exposure to a solution of soda. To an end-bulb there proceeds usually one, but sometimes two, or even three dark-bordered nerve-fibres; and sometimes an originally single fibre divides into two or three immediately before entering the corpuscle; or several branches of one fibre may each run into a separate end-bulb. The fibre or fibres pass into the core, lose their dark borders, and appear to end, when their ends can be traced, in a bulbous extremity or knob. The nerve-fibre, when about to enter the corpuscle, is often much coiled, and this may be the case too with its pale continuation within, which contributes greatly to obscure its actual termination. End-bulbs have been hitherto found in the conjunctiva over the sclerotic coat of the eye, and in the mucous membrane on the floor of the mouth, the lips, soft palate, and tongue, being in these last-mentioned situations lodged in papillæ,

Fig. 99.

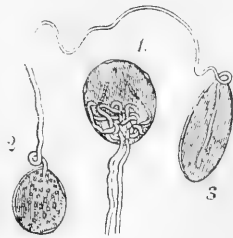


Fig. 99.—THREE NERVE-END-BULBS FROM THE HUMAN CONJUNCTIVA, TREATED WITH ACETIC ACID, MAGNIFIED 300 DIAMETERS.

1. With two nerve-fibres forming coils within. 2. With one nerve-fibre and fat-granules in the core. 3. Of an oval figure; termination of nerve distinct. Nuclei on the capsules of 1 and 2 (from Kölliker, after a drawing by Lüdden).

or at their roots (fig. 100); also, more deeply, in the skin of the glans of the penis and clitoris.\*

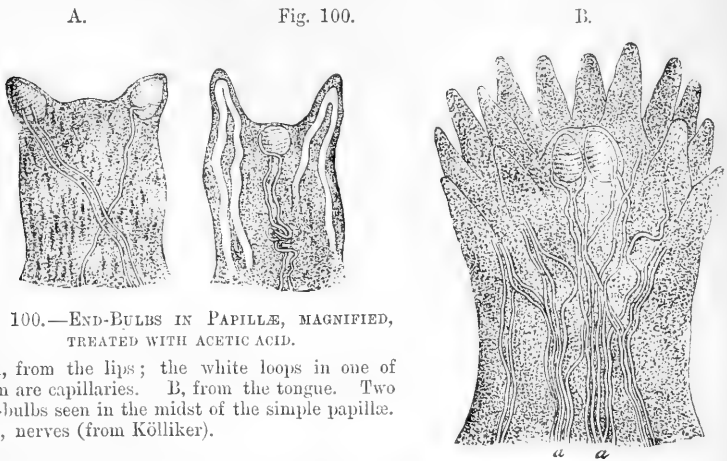


Fig. 100.—END-BULBS IN PAPILLÆ, MAGNIFIED, TREATED WITH ACETIC ACID.

A, from the lips; the white loops in one of them are capillaries. B, from the tongue. Two end-bulbs seen in the midst of the simple papillæ. *a, a*, nerves (from Kölliker).

**Tactile corpuscles or touch-bodies** (*corpuscula tactûs*) (fig. 101).

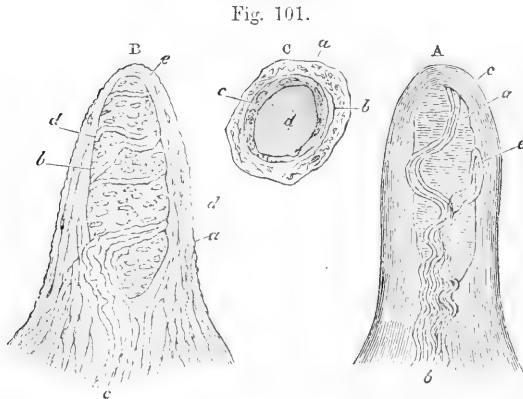


Fig. 101.—PAPILLÆ FROM THE SKIN OF THE HAND, FREED FROM THE CUTICLE AND EXHIBITING THE TACTILE CORPUSCLES. MAGNIFIED 350 DIAMETERS.

A. Simple papilla with four nerve-fibres. *a*, Tactile corpuscle; *b*, nerves. B. Papilla treated with acetic acid; *a*, connective tissue of papilla with cells and fine elastic filaments; *b*, tactile corpuscle with transverse nuclei; *c*, entering nerve with neurilemma or perineurium; *d*, nerve-fibres winding round the corpuscle. c. Papilla viewed from above so as to appear as a cross section. *a*, connective tissue of papilla; *b*, nerve-fibre; *c*, sheath of the tactile corpuscle containing nuclei; *d*, core (after Kölliker).

Discovered by R. Wagner and Meissner. These are mostly of an oval

\* W. Krause has described peculiar organs in the skin of the penis and clitoris, allied to the end-bulbs, which he proposes to call *genital nerve-corpuscles*. They are various in form, but present a mulberry-like surface. One, or two, rarely three or four, dark-bordered nerve fibres enter each of them. They have a delicate sheath of connective tissue, with many nuclei, and soft finely granular contents allied to the core of the end-bulbs.



shape, nearly  $\frac{1}{300}$  of an inch long, and  $\frac{1}{300}$  of an inch thick. Within is a core of soft, transparent, homogeneous substance, with sparsely imbedded granules; outside, a capsule of connective tissue, with oblong nuclei directed transversely to the axis (and rendered more conspicuous by acetic acid or coloration with carmine), which, with perhaps some horizontally wound fibres, give the corpuscle somewhat the appearance of a miniature fir-cone. One, two, or even more nerve-fibres, run to the corpuscle, and proceeding straight, or with serpentine windings, approach the summit, up to this point retaining their dark borders; they then pass into the core, and, so far as can be seen, end as fine pale fibres. The touch corpuscles are found in the skin of the hand and foot, and one or two other parts, where they are inclosed in certain of the cutaneous papillæ which usually include no vessels. It may be here observed that loops of nerves are sometimes seen in papillæ without touch-bodies, but probably they belong to a nerve on its way to end in the corpuscle of a neighbouring papilla.

**Pacinian bodies.**—In dissecting the nerves of the hand and foot, certain small oval bodies like little seeds, are found attached to their branches as they pass through the subcutaneous fat on their way to the skin; and it has been ascertained that each of these bodies receives a nervous fibre which terminates within it. The objects referred to were more than a century ago described and figured by Vater,\* as attached to the digital nerves, but he did not examine into their structure, and his account of them seems not to have attracted much notice. In more recent times, their existence was again pointed out by Cruveilhier and other French anatomists, as well as by Pacini of Pisa, who appears to be the first writer that has given an account of the internal structure of these curious bodies, and clearly demonstrated their essential connection with the nervous fibres. The researches of Pacini were followed up by Henle and Kölliker,† who named the corpuscles after the Italian savant; and to their memoir, as well as to more recent papers,‡ the reader is referred for details that cannot be conveniently introduced here.

The little bodies in question (fig. 102) are, as already said, attached in numbers to the branches of the nerves of the hand and foot, and here and there one or two are found on other cutaneous nerves. They have been discovered also within the abdomen on the nerves of the solar plexus, and they are nowhere more distinctly seen or more conveniently obtained for examination, than in the mesentery of the cat, between

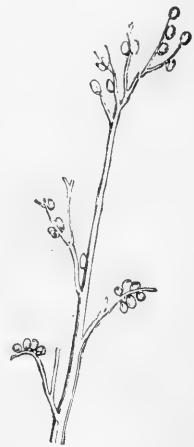

Fig. 102.—A NERVE OF THE MIDDLE FINGER, WITH PACINIAN BODIES ATTACHED. NATURAL SIZE (after Henle and Kölliker).

\* Abr. Vater, Diss. de Consensu Partium Corp. hum. ; Vitemb. 1741, (recus. in Halleri Disp. Anat. Select. tom. ii.). Ejusd. Museum Anatomicum; Helmst. 1750.

† Ueber die Pacinischen Körperchen; Zurich, 1844.

‡ Bowman, Cyclop. of Anat. W. Krause, Anat. Untersuchungen; Hannover, 1861, and Zeits. f. rat. Med. xvii. 1865. T. W. Engelmann, Zeits. f. Wiss. Zool. xiii. 1863. Michelson, Schultze's Archiv, v. 1869. Axel Key and Retzius, Schultze's Archiv, ix. 1873.

the layers of which they exist abundantly. They have been found on the pudic nerves in the glans penis and bulb of the urethra, on the intercostal nerves, sacral plexus, cutaneous nerves of the upper arm and neck, and on the infraorbital nerve. Lately they have been recognised on the periosteal nerves, and, in considerable numbers, on the nerves of the joints. They are found in individuals of all ages. The figure of these corpuscles is oval, somewhat like that of a grain of wheat,—regularly oval in the cat, but mostly curved or reniform in man, and sometimes a good deal distorted. Their mean size in the adult is from  $\frac{1}{15}$ th to  $\frac{1}{10}$ th of an inch long, and from  $\frac{1}{20}$ th to  $\frac{1}{10}$ th of an inch broad. They have a whitish, opaline aspect: in the cat's mesentery they are usually more transparent, and then a white line may be distinguished in the centre. A slender stalk or peduncle attaches the corpuscle to the branch of nerve with which it is connected. The peduncle contains a single medullated nerve-fibre ensheathed in

Fig. 103.

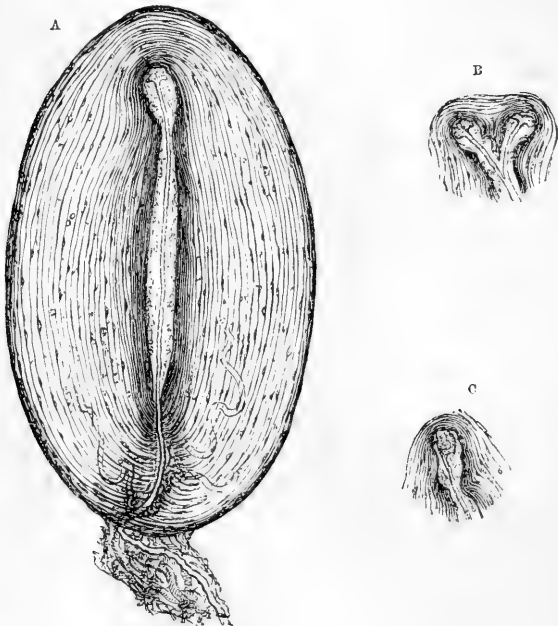


Fig. 103.—A, MAGNIFIED VIEW OF A PACINIAN BODY FROM THE MESENTERY OF A CAT (from a drawing by Professor Marshall), showing the lamellar structure, the capsules with their nuclei (the inner and closer series of capsules appearing darker in the figure) the nerve-fibre passing along the peduncle, and penetrating the capsules to reach the core in the central cavity, where it loses its strong, dark outline, and terminates by an irregular knob at the distal and here dilated end of the cavity. Connective tissue (neurilemma or perineurium) and blood-vessels are represented in the peduncle, and tortuous capillaries are seen running up among the capsules. B and C represent the termination of the nerve with the distal end of the central cavity and adjoining capsules, to illustrate varieties of arrangement. In B the fibre, as well as the core and adjoining capsules, is bifurcated.

neurilemma, with connective tissue and one or more fine blood-vessels ; it joins the corpuscle at or near one end, and conducts the nerve-fibre into it. The little body itself, examined under the microscope, is found to have a beautiful lamellar structure (fig. 103, A). It consists, in fact, of numerous concentric membranous capsules encasing each other like the coats of an onion, with a small quantity of pellucid fluid included between them. Surrounded by these capsules, and occupying a cylindrical cavity in the middle of the corpuscle, is the core, formed of transparent and homogeneous soft substance, in the midst of which the prolongation of the nerve-fibre is contained. The number of capsules is various ; from forty to sixty may be counted in large corpuscles. The series immediately following the central or median cavity, and comprehending about half of the entire number, are closer together than the more exterior ones, seeming to form a system by themselves, which gives rise to a white streak often distinguishable by the eye along the middle of the corpuscles when seen on a dark ground. Outside of all, the corpuscle has a coating of ordinary connective tissue. The capsules, at least the more superficial ones, consist each of a thin lamella of an almost homogeneous or faintly striated appearance, with a reticulum of exquisitely fine fibres, probably of an elastic nature, on the outer surface. On the inner surface of each lamella a number of clear oval nuclei are to be seen, and treatment with nitrate of silver shows these to belong to a delicate layer of flattened epithelioid cells (fig. 104), lining each successive capsule (Hoyer). It is thus seen that in intimate structure the capsules correspond very closely to the lamellæ of which the neurilemma of the nerve, before described, is composed.

The nerve fibre, the disposition of which must now be noticed, is conducted along the centre of the stalk, enters the corpuscle, and passes straight into the central cavity, at the further end of which it terminates.

The neurilemma surrounding the nerve-fibre in the peduncle accompanies it also in its passage through the series of capsules, gradually decreasing in thickness as it proceeds, and ceasing altogether when the nerve has reached the central cavity. According to Pacini, the neurilemma forms a series of concentric cylindrical layers, which successively become continuous with, or rather expand into the

Fig. 104.

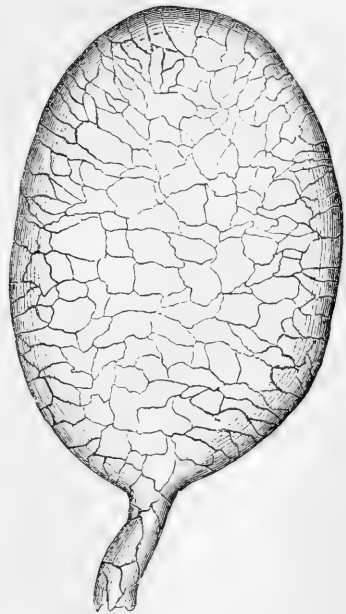


Fig. 104.—PACINIAN CORPUSCLE FROM MESENTERY OF CAT ; STAINED WITH NITRATE OF SILVER. MAGNIFIED.

The epithelioid cells of the outermost capsule are shown, and their continuity, at the peduncle, with those of the corresponding layer of the neurilemma (from a drawing by Mr. G. C. Henderson).

capsules, the innermost, of course, advancing farthest. Others suppose that the capsules are all successively perforated by a conical channel which gives passage to the nerve with its neurilemma, but at the same time has its own proper wall, round which, on the outside, the capsules are attached. We must, however, adhere to Pacini's view, having in silvered preparations observed the layers of epithelioid cells lining the capsules to be directly continuous with those of the neurilemma.

The nerve-fibre is single, as it runs along the peduncle, unless when the latter supports two corpuscles; it retains its dark double contour until it reaches the central cavity, where, diminished in size, and freed from its perineurium, it becomes somewhat flattened, and presents the appearance either of a pale, finely granular, and very faintly outlined band or stripe, little narrower than the previous part of the fibre, or of a darker and more sharply defined narrow line; differing thus in appearance according as its flat side or its edge is turned towards the eye. The pale aspect which the fibre presents in the centre of the corpuscle has with some probability been ascribed to its losing the white substance or medullary sheath on entering the cavity. Henle and Kölliker, however, think that it is more likely the result merely of a diminution in size, together with a certain degree of flattening. It sometimes happens that the fibre regains its original magnitude and double contour for a short space, and changes again before it terminates; this is especially liable to occur while it passes through a sharp flexure in a crooked central cavity. The fibre ends by a sort of knob at the further extremity of the median cavity, which is often itself somewhat dilated. The knob, often finely granular, appears to be an expansion of the axis-cylinder, and is sometimes of considerable size. It may present an irregular shape with processes branching outwards from the sides, and in such cases has been taken to represent a nerve-cell; but the characteristic nucleus of the latter is absent. The ultimate destination of the processes is unknown. The axis-cylinder presents the usual longitudinal fibrillation as it passes through the core, and the fibrils become somewhat spread out as they pass into the terminal expansion. In many cases the fibre, before terminating, divides into two branches, as represented in figure 103, B.: a division into three has been observed, but this is very rare. In case of division of the fibre, the cavity is generally, but not invariably, divided in a corresponding measure, and the inner capsules present a figure in keeping with it. It is worthy of remark, that the nerve-fibre in its course along the cavity runs almost exactly in the axis of the channel, and it maintains this position even when passing through the abrupt flexures of an irregularly shaped cavity. It sometimes happens that a fibre passes quite through one corpuscle and terminates in a second, resuming its original size and dark outline while passing from the one to the other; and it is said that a nerve-fibre may go through two Pacinian bodies without terminating in either, returning again to the parent nerve in form of a loop (Pappenheim). Other varieties occur, for an account of which the reader is referred to the several authorities already mentioned. A little artery enters the Pacinian bodies along with the nerve, and soon divides into capillary branches, which run up between the capsules. They then form loops, and return by a similar route into a vein corresponding to the artery: a single capillary usually accompanies the nerve as far as the central

capsule, and passes some way on its wall, sometimes in a spiral direction (Bowman).

There is considerable difference of opinion as to the condition of the nerve-fibre in the Pacinian body. Kölliker thinks that it retains its primitive sheath, and is not wholly deprived of its medulla; and that the surrounding core is composed of a nearly homogeneous connective tissue, in which he has seen faintly marked nuclei and faint longitudinal striation.\* Engelmann, on the other hand, considers the core to be an expansion of the medullary sheath of the nerve, and ascribes the appearances noticed by Kölliker to changes occurring in the originally homogeneous medulla, as in the case of a white nerve-fibre. The pale fibre within he considers to be simply the axis-cylinder. The core and pale fibre of the end-bulbs he regards in precisely the same way, and thinks it not improbable that the touch-corpuscles will be found to conform. He looks upon the simple capsule of the end-bulb as a development of the primitive nerve-sheath, to which, in the Pacinian bodies, is superadded a series of concentric coats of connective tissue. Engelmann, besides adducing other arguments, refers especially to the structure of the Pacinian bodies of birds, as affording material evidence in support of his view.

To us the core of the Pacinian corpuscle seems most nearly to correspond in its anatomical relations with the protoplasmic layer which Ranvier has described as existing, especially in young nerves, between the primitive sheath and the medullary sheath of the nerve-fibre, in which case the innermost capsule of the Pacinian, with its nuclei, would answer to the nucleated sheath of Schwann or primitive sheath of the nerve. For in the first place there can be little doubt that the capsules are expansions of the lamellæ of the neurilemma, with which they agree essentially in structure. In the second place, we have never been able to observe any structure resembling a primitive sheath immediately surrounding the nerve as it passes through the core. We have, however, more than once observed a nerve-fibre pass through one Pacinian to end in another, without at all being divested of its medullary sheath as it traversed the core of the first. In such cases, as well as in others, in which the medullary sheath is retained for a certain distance within the core, it is easy to see, in opposition to Engelmann's view, that the substance composing the core presents a marked contrast to the medullary sheath. Neither is it, like the latter, deeply coloured by osmic acid (Michelson) or by chloride of gold, but, on the contrary, is only moderately stained by these re-agents.

Nothing positive is known concerning the special purpose in the animal economy which these curious appendages of the nerves are destined to fulfil. In an anatomical sense a Pacinian body might be viewed as a more complex development of an end-bulb, from which it differs chiefly in the multiplied layers of the capsule. W. Krause endeavours to show that the series of concentric capsules with interposed fluid is an arrangement for converting the effect of mechanical traction into fluid pressure upon the nerve, so that tension and traction of the tissue in which the corpuscle is placed, may be felt and appreciated as ordinary pressure. Their presence in the mesentery of the cat seems, at first sight, against their importance as sentient organs, but it turns out upon trial, that the part in question is remarkably sensitive.

Other special modes of termination of sensory nerves as, for instance, in the organs of special sense, will be most conveniently considered in the description of the organs to which they belong.

**Termination of nerves in muscle:**—A. In plain or unstriped muscle.—Beale, and, after him, Klebs and others, have described the nerves proceeding to the involuntary fibres as finally distributed in networks of non-medullated fibres, with nuclei at intervals. The networks are at first coarse, and from them proceed finer bundles and

\* See also Axel Key and Retzius, *loc. cit.*

single fibrils, forming closer reticulations, and constituting the intramuscular plexus, which is disposed amongst the muscular fasciculi and fibre-cells.

Klebs states that in a single instance only he was able to trace an apparent connection of a nerve with a fibre-cell. According to Julius Arnold, on the other hand, excessively fine straight fibrils come off at right angles from the nerves between the cells, to be connected with the nucleoli of the muscular fibre-cells, through the substance of which they are said to pass.

B. In voluntary muscle.—The nerves of voluntary muscles terminate for the most part in special expansions, to which the term **motorial end-plates** has been applied.

As mentioned in the account of the muscular tissue, the nerves in the voluntary muscle form plexuses, of which the branches grow finer and the meshes closer as they advance further into the tissue. The individual fibres, while still associated in small bundles, undergo division, and at length single dark-bordered fibres pass off to the muscular fibres. These nerve-fibres on approaching or reaching a muscular fibre often divide still further. The branches retain their medullary sheath until they reach the sarcolemma, when it abruptly terminates, while the primitive sheath becomes continuous with the sarcolemma (fig. 105, *s*). The axis-cylinder as it passes into the fibre forms a clear flattened expansion (*p, p*) which lies immediately under the sarcolemma, and, according to Kühme, is always more or less cleft into lobes or branches.

Around and beneath this expansion is a layer of granular matter, with large, clear nuclei imbedded in it, each having one or more bright

Fig. 105.

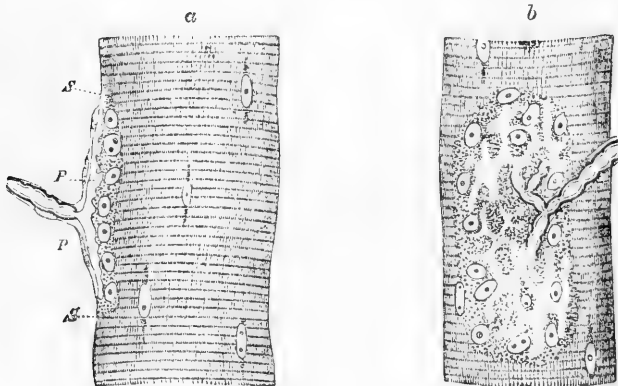


Fig. 105.—NERVE-ENDING IN MUSCULAR FIBRE OF A LIZARD. (*Lacerta viridis*.)

*a*, end-plate seen edgeways; *b*, from the surface. *s, s*, Sarcolemma; *p, p*, expansion of axis-cylinder. In *b* the expansion of the axis-cylinder appears as a clear network branching from the divisions of the medullated fibre. Highly magnified (from Kühne).

nucleoli. The sarcolemma over the seat of the end-plate, and the plate itself, are slightly raised above the general surface, so that the whole structure has been designated by Kühne as the *nerve-eminence* (Nerven-hügel). It would appear that a muscular fibre, when short, has but one

terminal organ, and receives consequently but one nerve-fibre. As, moreover, the fibres of a nerve undergo division, probably repeated division, before ending, it follows that one fibre in a nerve-root or trunk may supply several muscular fibres. Longer muscular fibres have two or more end-plates.

The motorial end-plates have now been recognised in mammalia, birds, and scaly reptiles. They were discovered by Rouget\* in lizards and warm-blooded animals; they had been previously found, but in a modified form, by Doyère and others in various invertebrata.

In amphibia (fig. 106) there is no true end-plate, but the branches resulting from the division of the medullated nerve lose their medullary sheath on penetrating the sarcolemma, and are continued as pale fibres. These give off branches which run for a short distance parallel with the axis of the fibre between the sarcolemma and the muscular substance, terminating abruptly by rounded extremities. These pale fibres present here and there slight enlargements, connected with which are granular, pear-shaped nuclei (*b*), not to be confounded with the proper nuclei of the muscle (*c*). A fine tortuous fibril is stated by Kühne to be given off from the pale fibre to each of these granular nuclei, and to terminate in it by a bulbous enlargement.

The above account may be taken as the one most in accordance with the more recent researches on the subject, and as probably, on the whole, correct. It is, however, only right to state that the existence of the end-plates has been lately called in question by Gerlach, who from the study of muscular fibres prepared with chloride of gold has arrived at the conclusion that the axis-cylinder of the nerve after passing through the sarcolemma forms a close network of minute varicose fibrils

Fig. 106.

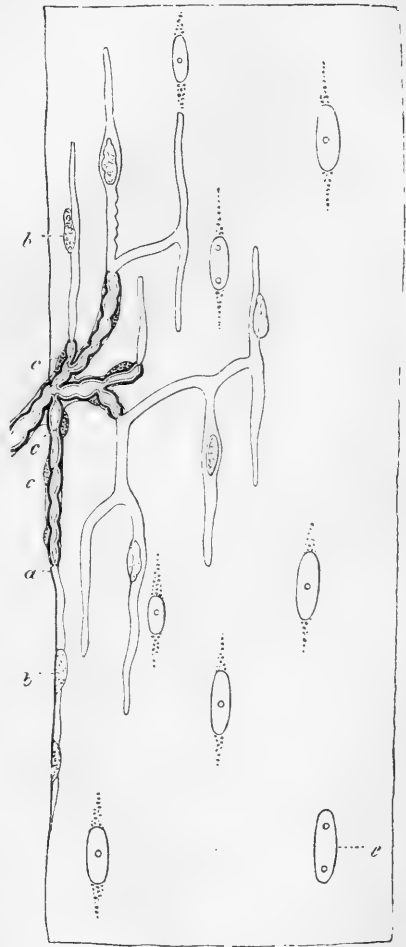


Fig. 106.—NERVE-ENDING IN MUSCLE OF FROG (Kühne).

*a*, one of the branches of the medullated fibres passing within the sarcolemma; *b*, *b*, granular pear-shaped nuclei; *c*, *c*, nuclei of primitive sheath; *e*, muscle nuclei.

a close network of minute varicose fibrils

\* Comptes Rendus, lv., 1862. See also Krause, Göttinger Nachrichten und Zeitsch. f. rat. Med. (various papers): Engelmann, Unters. ueber d. Zusammenh., &c., 1863: Kühne, Virch. Arch. (various papers), and article in Stricker's Handbook of Histology, where also a complete account of the history and literature of the subject will be found.

throughout the muscular substance, with which they are closely incorporated (Sitz. der Phys. Med. Soc. z. Erlangen, 1873). Another observer, Arndt, who admits the existence of the end-plate, describes in addition a complex system of communicating fibres which extend throughout the muscular substance, and by means of which the plate is brought into connection with the muscle corpuscles and nuclei (Schultze's *Archiv f. micr. Anatomie*, ix.).

**Differences of cerebro-spinal nerves.**—It remains to notice the differences which have been observed among the cerebro-spinal nerves in regard to the size of their fibres, and the proportionate amount of the different kinds of fibres which they respectively contain.

As already stated, both white and grey fibres exist in cerebro-spinal nerves, and those of the former kind differ greatly from each other in size. Volkmann and Bidder, who have bestowed much pains in endeavouring to arrive at an approximate estimate of the relative amount of the large and the small fibres in different nerves, give the following as the more important results of their researches.

1. The nerves of voluntary muscles have very few small fibres, usually in not larger proportion than about one to ten.

2. In the nerves of involuntary muscles, whether derived immediately from the cerebro-spinal system or from the sympathetic, the small fibres eminently preponderate, being about a hundred to one.

3. The nerves going to the integuments have always many small fibres, at least as many small as large.

4. Nerves of sentient parts of mucous membranes have from five to twenty times more small fibres than large: in mucous membranes possessing little sensibility, the nerves are made up chiefly of small fibres. The nerves which enter the cavities of the teeth consist principally of large fibres.

It is plain, however, that Volkmann and Bidder must have reckoned in with their small fibres more or fewer of the non-medullated sort, so that the proportion assigned to the small fibres in their estimate must be taken as including some grey, as well as white fibres; and this agrees with the observation previously made by Remak, that many more grey fibres are contained in the cutaneous than in the muscular nerves. The roots of the spinal nerves contain fine fibres, but according to Remak only in very small proportion: Volkmann and Bidder state that in man the anterior roots contain proportionally more large fibres than the posterior. In almost all nerves, the fibres diminish in size as they approach their termination.

The peculiarities of some of the cranial nerves, such as the olfactory and auditory, have been already alluded to and need not be further considered here.

#### OF THE SYMPATHETIC OR GANGLIONIC NERVES.

This name is commonly applied to a nerve or system of nerves present on both sides of the body, and consisting of the following parts, viz.:—1. A series of ganglia, placed along the spinal column by the side of the vertebræ, connected with each other by an intermediate nerve-cord, and extending upwards to the base of the skull and downwards as far as the coccyx. This principal chain of ganglia, with the cord connecting them, forms what is often named the trunk of the sympathetic. 2. Communicating branches, which connect these ganglia or the intermediate cord with all the spinal and several of the cranial nerves. 3. Primary branches passing off from the ganglionic chain or trunk of the nerve, and either bestowing themselves at once, and generally in form of plexuses, on the neighbouring blood-vessels, glands, and other organs, or, as is the case with the greater number, proceeding



in the first instance to other ganglia of greater or less size (sometimes named præ-vertebral) situated in the thorax, abdomen, and pelvis, and usually collected into groups or coalescing into larger ganglionic masses near the roots of the great arteries of the viscera. 4. Numerous plexuses of nerves, sent off from these visceral or præ-vertebral ganglia to the viscera, usually creeping along the branches of arteries, and containing in various parts little ganglia disseminated among them. Some of these plexuses also receive contributions from spinal or cerebral nerves, by means of branches which immediately proceed to them without previously joining the main series of ganglia.

**Structure of the sympathetic nerve-trunks.**—The nervous cords of the sympathetic consist of white fibres, and of pale or grey fibres, mixed with a greater or less amount of filamentous connective tissue, and inclosed in a common external fibro-areolar sheath. The white fibres differ greatly from each other in thickness. A few are of large size, ranging from  $\frac{1}{2000}$  to  $\frac{1}{1500}$  of an inch: but most of them are much smaller, measuring from about  $\frac{1}{3300}$  to  $\frac{1}{4500}$  of an inch in diameter, and, though having a well-defined sharp outline, for the most part fail to present the distinct double contour seen in the larger and more typical examples of the medullated fibre. The pale, non-medullated fibres, have the characters of Remak's grey fibres, already described, and often look as if made up of exquisitely fine fibrils; there are also pale fibres of much less thickness, which, at short distances, are interrupted by, or might be said to swell out into, fusiform nuclei. The fibres are in the large trunks collected into bundles or funiculi, the proper sheath of which, or *neurilemma*, agrees in structure with that met with in the cerebro-spinal nerves (*vide antea*, p. 140).

The more grey-looking branches or bundles of the sympathetic consist of a large number of the pale fibres mixed with a few of the medullated kind; the whiter cords, on the other hand, contain a proportionally large amount of medullated fibres, and fewer of the grey; and in some parts of the nerve grey fasciculi and white fasciculi, respectively constituted as above described, run alongside of each other in the same cords for a considerable space without mixing. This arrangement may be seen in some of the branches of communication with the spinal nerves, in the trunk or cord which connects together the principal chain of ganglia, and in the primary branches proceeding from thence to the viscera. In the last-mentioned case the different fasciculi get more mixed as they advance, but generally it is only after the white fasciculi have passed through one or more ganglia that they become thoroughly blended with the grey; and then, too, the nervous cords receive a large accession of grey fibres (apparently derived from the ganglia), which are mixed up with the rest, and take off more and more from their whiteness.

**Relation of the sympathetic to the cerebro-spinal nerves.**—On this important question two very different opinions have long existed, in one modification or another, amongst anatomists. 1. According to one, which is of old date, but which has been revived and ably advocated by Valentin, the sympathetic set of nerves is a mere dependency, offset, or embranchment of the cerebro-spinal system of nerves, containing no fibres but such as centre in the brain and cord, although it is held that these fibres are modified in their motor and sensory properties in passing through the ganglia in their way to and from the viscera and involuntary organs. 2. According to the other view, the sympathetic nerve (commonly

so called) not only contains fibres derived from the brain and cord, but also proper or intrinsic fibres which take their rise in the ganglia; and in its communications with the spinal and cranial nerves, not only receives from these nerves cerebro-spinal fibres, but imparts to them a share of its own proper ganglionic fibres, to be incorporated in their branches and distributed peripherally with them. Therefore, according to this latter view, the sympathetic nerve, commonly so called, though not a mere offset of the cerebro-spinal nerves, yet, receiving as it does a share of their fibres, is not wholly independent, and for a like reason the cerebro-spinal nerves (as commonly understood) cannot be considered as constituted independently of the sympathetic; in short, both the cerebro-spinal and the sympathetic are mixed nerves, that is, the branches of each system consist of two sets of fibres of different and independent origin, one connected centrally with the brain and cord, the other with the ganglia. Hence, if we look to the central connection of their fibres as the essential ground of distinction among nerves, the cerebro-spinal system of nerves might, strictly speaking, be considered as consisting of and comprehending all the fibres having their centre in the cerebro-spinal axis, whether these fibres run in the nerves usually denominated cerebral and spinal, or are distributed to the viscera in the branches of the nerve usually named the sympathetic; and, on the same ground, the sympathetic or ganglionic system, strictly and properly so called, would consist of and comprehend all the fibres connected centrally with the ganglia, wherever such fibres exist and into whatever combinations they enter, whether proceeding to the viscera or distributed peripherally with the nerves of the body generally; the nerve-fibres which emanate from the ganglia on the roots of the spinal and cerebral nerves being reckoned into the system, as well as those from ganglia, usually denominated sympathetic. While ready, however, to acquiesce in the justice of the above distinction, we do not mean to employ the terms already in use in a sense different from that which is currently received.

In endeavouring to decide between the two views above stated, it may be first observed that the existence in the sympathetic nerve of fibres connected centrally with the cerebro-spinal axis, is proved not only by tracing bundles of fibres from the roots of the spinal nerves along the communicating branches and into the sympathetic, but by the pain or uneasy sensations which arise from disease or disturbance of organs, such as the intestines, supplied exclusively, or almost exclusively, by what are considered branches of the sympathetic; by experiments on living or recently killed animals, in which artificial irritation of the roots of the spinal nerves, or of various parts of the cerebro-spinal centre, caused movements of the viscera; and by experiments on the sympathetic nerve in the neck, by which it is shown that the dilatation of the pupil and the tonicity of the cutaneous vessels of the head are dependent on fibres which pass along the sympathetic nerve but are centrally connected with the upper part of the spinal cord and medulla oblongata.

These facts, it is evident, accord with both of the above-mentioned opinions respecting the constitution of the sympathetic; but it may be further shown that this nerve contains fibres which arise from the ganglia and take a peripheral course, so that the second of the two opinions approaches nearer to the truth. In support of this assertion we may adduce the actual observation of nerve-fibres proceeding from the nerve-cells of the ganglia in a peripheral direction only; and there are also other grounds for believing that more fibres pass out of the sympathetic ganglia than can possibly be derived from the brain and cord. This seems to follow from a comparison of the aggregate size of the distributional branches issuing from these ganglia with that of all the branches which can be supposed to enter them.

The branches of communication which pass between the ganglia or gangliated cord of the sympathetic and spinal nerves, are connected with the anterior and greater branch of each of the latter nerves, a little in advance of the spinal ganglion; and at the point of connection the communicating branch in most cases divides into two portions, one central, running towards the roots of the spinal nerve and the spinal cord, the other, peripheral, taking an outward course along with the anterior branch of the spinal nerve with which it becomes incorporated and distributed. It can scarcely be doubted that the central portion,

whilst it may contain fibres sent by the sympathetic to the spinal nerves or to the spinal cord, must necessarily contain all those which proceed from the cord to the sympathetic, and that, on the other hand, the peripheral division must contain the fibres immediately proceeding from the sympathetic and distributed peripherally with the spinal nerve.

It seems on the whole reasonable to conclude that nerve-fibres take their rise in the ganglia both of the cerebro-spinal and sympathetic nerves, and are in both kinds of nerves mixed with fibres of cerebral or spinal origin; that the ganglia are nervous centres which may probably receive through afferent fibres impressions of which we are unconscious and reflect these impressional stimuli upon efferent or motor fibres: that perhaps, even, certain motorial stimuli emanate from them; the movements excited by or through the ganglia being always involuntary, and affecting chiefly the muscular parts of the viscera, the sanguiferous, and perhaps the absorbent vessels; and that, in fine, the chief purpose served in the animal economy by the ganglia and the ganglionic nerve fibres, whether existing in acknowledged branches of the sympathetic, or contained in other nerves, is to govern the involuntary, and, for the most part, imperceptible movements of the vascular system, as well as the secretory and nutritive processes, in so far at least as these are not dependent on the brain and spinal cord.

#### CHEMICAL COMPOSITION.

The information we possess respecting the chemical composition of nervous matter is for the most part founded on analyses of portions of the brain and spinal cord; but the substance contained in the nerves, which is continuous with that of the brain and cord, and similar in physical characters, appears also, as far as it has been examined, to be of the same general chemical constitution. No very careful comparative analysis has yet been made of the grey and white matter, to say nothing of the different structural elements of the nervous substance; and indeed it must be remembered, that, in portions of brain subjected to chemical examination, capillary blood-vessels, connective and perhaps other accessory tissues, as well as interstitial fluid, are mixed up in greater or less quantity with the true nervous matter, and must so far affect the result.

Like most of the other tissues of the body the nervous substance contains a large proportion of water (from three-fourths to four-fifths of its weight). Of the residue which remains after the removal of this by evaporation or other means the larger part consists of a phosphurated fat, which may be obtained crystallized, and in this condition was termed by O. Liebreich *protagon*. The crystalline substance, however, is in reality a mixture of two other substances—*lecithin* and *neurin* (Hoppe-Seyler)—and doubtless includes the fatty acids which were enumerated by Frémy and others: it appears mainly to compose the medullary sheath of the nerves.

**Lecithin** was first obtained from yelk of egg (by Gobley). It contains nearly 4 per cent. of phosphorus, and has a very complex constitution.

**Neurin**, sometimes termed **cholin**, is found also in the bile. It possesses basic properties, and is, moreover, said to be one of the products of decomposition of lecithin.

A substance named **Cerebrin** is also described as being frequently

met with in conjunction with lecithin. Other substances which are found in analyses of the nervous tissues are:—

**Cholesterin** ( $C_{26} H_{44} O$ ) which was long considered to be a fatty body, but is probably more allied to the alcohols. It crystallizes in pearly scales which are tinged blue by treatment with sulphuric acid and iodine.

**Extractive matters.**—These probably belong chiefly to the interstitial fluid; but, however this may be, they may be held to represent the products of decomposition of the nervous substance. The following have been recognised:—

1. *Lactic, formic, acetic, and (traces of) uric acid.*
2. *Inosit.*
3. *Kreatin.*
4. *Hypoxanthin.*
5. *Leucin (in the ox).*

Certain albuminoid substances are also obtained from nervous tissue: they are probably in great part derived from the nerve-cells and axial fibres.

With regard to the reaction of nerve, the same law is said to prevail as in muscle—namely, that the substance of nerves in the living but quiescent state is neutral, but becomes acid after death or prolonged excitement (Funke). The saline or inorganic matters found by incineration are—*phosphoric acid, phosphates of alkalis*, which, as in muscle, largely predominate over other salts, *potash*, as a base, largely exceeding *soda*; *earthy phosphates*, in smaller proportion, *magnesia* prevailing over *lime*; *phosphate of iron*; *chloride of sodium*; *sulphate of potash*; and a trace of *silica*.

The white substance contains nearly 75 per cent. of water; the grey about 85; the proportion of water is less in the spinal cord, and still less in the nerves. The fatty matters amount in the grey substance to nearly 5 and in the white to nearly 15 per cent.; in the nerves the proportion fluctuates largely. It is worthy of note that the brain, during embryonic and infantile life, contains much less fatty matter and more water; moreover, the grey and the white matter do not present the same differences as in after life in the proportions of water and fatty substance which they respectively contain. The brain of embryos of from ten to twenty-two weeks has been found to yield only from 0.99 to 1.5 per cent. of fatty substance; that of the full-grown fœtus from 3 to 4 per cent.

#### VITAL PROPERTIES.

The fibres of nerves are endowed with the property of transmitting impressions, or, rather impulses, the effect of impressions, from the point stimulated towards their central or their peripheral extremities. Certain fibres are employed to conduct towards the nervous centres and are named “afferent,” others to conduct towards their distal extremities, which are distributed in moving parts, and these fibres are named “efferent.”

The greater number of nerves possess both afferent and efferent fibres, and are named compound or moto-sensory, inasmuch as they minister both to sensation and motion. In such compound nerves the two kinds of fibres are mixed together and bound up in the same sheaths; but in the most numerous and best-known examples of this class, the afferent and efferent fibres, though mixed in the trunk and branches of the nerves, are separated at their roots. This is the case in the spinal nerves: these have two roots, an anterior and posterior, both for the most part consisting of many funiculi, and the posterior passing through a ganglion with which the fibres of the anterior root have no connection. Now it has been ascertained by appropriate experiments on animals, that the anterior root is efferent and contains the motor fibres, and that the posterior is afferent and contains the sensory fibres. The fifth pair of cranial nerves has a sensory root furnished

with a ganglion, and a motor root, like the spinal nerves. The glosso-pharyngeal and pneumo-gastric nerves are also decidedly compound in nature; they are also provided with ganglia at their roots, which involve a greater or less number of their fasciculi; but it has not yet been satisfactorily determined whether in these nerves the fibres which have different properties are collected at the roots into separate bundles, nor how they are respectively related to the ganglia. The sympathetic, as already stated, contains both afferent and efferent fibres.

Simple nerves are such as contain either afferent or efferent fibres only. The olfactory, auditory, and optic are simple afferent and sensory nerves. The third, fourth, and sixth, the facial, the spinal accessory and hypoglossal nerves are generally regarded as examples of simple motor nerves; there is reason to believe, at least, that they are simple and motor in their origin, or as far as their proper fibres are concerned, and that the sensibility evinced by some of them in their branches is owing to sensory fibres derived from other nerves which join them in their progress.

The nerves governing the motions of the blood-vessels are commonly spoken of as the "vaso-motorial nerves;" but although this term is often of convenient application, there seems no sufficient reason for reckoning these nerves as a distinct system, any more than motorial nerves distributed to other parts or organs whose motions are independent of the will.

#### DEVELOPMENT OF NERVES.

The knowledge as yet acquired respecting this process is not very positive or consistent, so that much room is left for speculation and conjecture. The *nerve-cells* are doubtless derived from the common embryonic-cells, which, undergoing modification in their substance, send out branches from their circumference and acquire the character of nerve-cells. According to the most generally current descriptions, the *fibres* are stated to be formed by the linear coalescence of long fusiform cells, and to be at first pale and grey, but afterwards to acquire a medullary sheath and become white. This change of aspect is apparent in the human embryo of the fourth or fifth month. According to Kölliker's account of the growth of nerve-fibres at their peripheral ends, as observed in the tail of batrachian larvæ, the existing fibres are prolonged by lines of fusiform cells which coalesce into pale fibres. These send out fine offshoots, which may join with neighbouring fibres, or with branched or stellate cells, which change into branched fibres, and in both of these ways the branching and conjunction of the nerves go on. The first fibres thus generated (embryonic fibres, Köll.) virtually represent bundles of two, three, or more tubular dark-bordered fibres, into which they are speedily converted; the formation of the medullary sheath proceeding outwards along the branches.

The fact pointed out by Ranvier that the medullary sheath of the nerves is divided at regular intervals into a series of segments, each of which possesses a nucleus, and may therefore be looked upon as representing a cell, the primitive sheath being analogous to the cell membrane, would seem to render it probable that these segments are actually formed from cells, which come to be applied around previously-formed axial fibres, and become filled with the fatty matter of the medullary

sheath in the same way as the connective tissue-cells become filled with fat in the development of the adipose tissue. At all events, in young nerves the segments are shorter, and there is a layer of homogeneous or finely granular protoplasmic substance outside the medullary sheath, between it and the primitive sheath : as the nerves increase in size this layer, being more and more encroached upon by fatty substance, eventually almost or entirely disappears, except in the immediate neighbourhood of the nuclei. In the brain and spinal cord at an early period flattened cells are found surrounding the medullated fibres (Ranvier) ; subsequently they disappear or become incorporated with the interstitial tissue of those organs, without having produced either a primitive sheath or constrictions on the fibres.

The fact that the nerve segments of the peripheral nerves are considerably shorter in the young animal points to the existence of an interstitial as well as a terminal growth of nerve-fibres.

Another mode of formation of nerves has been described by Beale and subsequently by Hensen, who state that a fibre may be produced by the lengthening out of a connecting process between two cells, the one of which remains in the central organ as a nerve-cell, whilst the other becomes a peripheral terminal organ. For the details of the description and for other observations on the development of the nerves, the reader is referred to the original memoir.\*

**Re-union and regeneration of nerves.**—The divided ends of a nerve that has been cut across readily reunite, and in process of time true nerve-fibres are formed in the cicatrix, and restore the continuity of the nervous structure. The conducting property of the nerve, as regards both motion and sensation, is eventually re-established through the reunited part. But, immediately after the section, a process of degeneration begins in the peripheral or severed portion of the nerve. The nuclei become multiplied, and the protoplasm about them largely increased in amount, the segments taking on to some extent their embryonic condition. At the same time the medulla of the white fibres degenerates into a granular mass consisting of fatty molecules, and is then totally removed, and eventually the axial fibre also disappears.

The degeneration above referred to does not affect, at least to any great extent, the part of the nerve remaining in connection with the nervous centre, which seems to exert an influence in maintaining the nutrition of the nerve.† The ganglia, as well as the brain and spinal cord, were shown by Waller to be centres of this influence. He found that, in the central and undegenerated portion of a divided spinal nerve, while the fibres belonging to the anterior root owe their integrity to their connection with the spinal cord, those of the posterior root are similarly dependent on the ganglion ; and that, if the posterior root be cut between the ganglion and the spinal cord, not only will the fibres which belong to it in the trunk of the nerve beyond the ganglion remain unchanged, but also those above the ganglion, in the portion of the root left in connection with it ; whereas the segment of the same root which remains connected with the cord but severed from the ganglion degenerates. Section of the sympathetic nerve in the neck is followed by degeneration of the cephalic segment as high as the superior cervical ganglion, but no farther.

In regeneration the new fibres grow afresh from the axial fibres of the central end of the divided nerve-trunk (often more than one from each) ; and, penetrating into the peripheral end of the trunk, grow along this as the axis-cylinders of the new nerves, becoming after a time surrounded with medullary substance.

Beale, *Phil. Trans.*, 1863.

† In the neighbourhood of the divided central end, the nuclei of the primitive sheath multiply, and the white substance appears to break up into fat droplets, but the axis-cylinder remains unaltered. (Ranvier, *Compt. Rend.* lxxv. p. 1831.)

## BLOOD-VESSELS.

The blood, from which the solid textures immediately derive material for their nourishment, is conveyed through the body by branched tubes named blood-vessels. It is driven along these channels by the action of the heart, which is a hollow muscular organ placed in the centre of the sanguiferous system. One set of vessels, named *arteries*, conduct the blood out from the heart and distribute it to the different regions of the body, whilst other vessels named *veins* bring it back to the heart again. From the extreme branches of the arteries the blood gets into the commencing branches of the veins or revent vessels, by passing through a set of very fine tubes which connect the two, and which, though not abruptly or very definitely marked off from either, are generally spoken of as an intermediate set of vessels, and by reason of their smallness are called the *capillary* (*i.e.*, hair-like) *vessels*, or, simply, *the capillaries*.

The conical hollow muscular heart is divided internally into four cavities, two placed at its base, and named auricles, and two occupying the body and apex, named ventricles. The auricles are destined to receive the returning blood from the great veins, which accordingly open into them, and to pass it on into the ventricles; whilst it is the office of the latter to propel the blood through the body. The ventricles have therefore much thicker and stronger sides than the auricles, and the great arterial trunks lead off from them. Each auricle opens into the ventricle of the same side, but the right auricle and ventricle are entirely shut off from those of the left side by an impervious partition placed lengthwise in the heart.

The blood is sent out by the left ventricle into the main artery of the body, named the aorta, and passes through the numerous subordinate arteries, which are branches of that great trunk, to the different parts of the system; then, traversing the capillaries, it enters the veins, and is returned by two great venous trunks, named the superior and inferior venæ cavæ, to the right auricle. In passing from the arteries to the veins the blood changes in colour from red to dark, and is otherwise altered in quality; in this condition it is unfit to be again immediately circulated through the body. On returning, therefore, to the right side of the heart, the blood, now dark and venous, must re-acquire the florid hue and other though less obvious qualities of arterial blood before it is permitted to resume its course. For this purpose, being discharged by the right auricle into the right ventricle, it is driven, by the contraction of that ventricle, along the pulmonary artery and its branches to the lungs, where, passing through the capillary vessels of these organs, it is exposed to the influence of the air, and undergoes the requisite change; and, having now become florid again, it enters the commencing branches of the pulmonary veins, which, ending by four trunks in the left auricle, convey it into that cavity, whence it is immediately discharged into the left ventricle to be sent again along the aorta and through the system as before.

The blood may thus be considered as setting out from any given point of the sanguiferous system and returning to the same place again after performing a circuit, and this motion is what is properly termed

the *circulation* of the blood. Its course from the left ventricle along the aorta, throughout the body, and back by the *venæ cavæ* to the right ventricle, is named the *greater* or *systemic circulation*, and its passage through the lungs by the pulmonary artery and pulmonary veins from the right to the left side of the heart, is termed the *lesser* or *pulmonary circulation*; but the blood must go through both the greater and the lesser circulation in order to perform a complete circuit, or to return to the point from which it started. As the vessels employed in the circulation through the lungs have been named pulmonary, so the aorta which conveys the blood to the system at large is named the systemic artery, and the *venæ cavæ* the systemic veins; whilst the two sets of capillaries interposed between the arteries and veins, the one in the lungs, the other in the body generally, are respectively termed the pulmonary and the systemic capillaries.

The blood flows in the arteries from trunk to branches, and from larger to smaller but more numerous tubes; it is the reverse in the veins, except in the case of the *vena portæ*, a vein which carries blood into the liver. This advehent vein, though constituted like other veins in the first part of its course, divides on entering the liver into numerous branches, after the manner of an artery, sending its blood through these branches and through the capillary vessels of the liver into the efferent hepatic veins to be by them conducted into the inferior vena cava and the heart.

The different parts of the sanguiferous system above enumerated may be contemplated in another point of view, namely, according to the kind of blood which they contain or convey. Thus the left cavities of the heart, the pulmonary veins, and the aorta or systemic artery, contain red or florid blood fit to circulate through the body; on the other hand, the right cavities of the heart with the *venæ cavæ*, or systemic veins, and pulmonary artery, contain dark blood requiring to be transmitted through the lungs for renovation. The former or red-blooded division of the sanguiferous system, commencing by the capillaries of the lungs, ends in the capillaries of the body at large; the latter or dark-blooded part commences in the systemic capillaries and terminates in those of the lungs. The heart occupies an intermediate position between the origin and termination of each, and the capillaries connect the dark and the red sets of vessels together at their extremities, and serve as the channels through which the blood passes from the one part of the sanguiferous system to the other, and in which it undergoes its alternate changes of colour, since it becomes dark as it traverses the systemic capillaries and red again in passing through those of the lungs.

#### ARTERIES.

These vessels were originally supposed to contain air. This error, which had long prevailed in the schools of medicine, was refuted by Galen, who showed that the vessels called arteries, though for the most part found empty after death, really contain blood in the living body.

**Mode of Distribution.**—The arteries usually occupy protected situations; thus, after coming out of the great visceral cavities of the body, they run along the limbs on the aspect of flexion, and not upon that of extension where they would be more exposed to accidental injury.



As they proceed in their course the arteries divide into branches, and the division may take place in different modes. An artery may at once resolve itself into two or more branches, no one of which greatly exceeds the rest in magnitude, or it may give off several branches in succession and still maintain its character as a trunk. The branches come off at different angles, most commonly so as to form an acute angle with the further part of the trunk, but sometimes a right or an obtuse angle, of which there are examples in the origin of the intercostal arteries. The degree of deviation of a branch from the direction of the trunk was supposed to affect the force of the stream of blood, but Weber maintains that it can produce little or no effect in a system of elastic tubes maintained, like the arteries, in a state of distension.

An artery, after a branch has gone off from it, is smaller than before, but usually continues uniform in diameter or cylindrical until the next secession; thus it was found by Hunter that the long carotid artery of the camel does not diminish in calibre throughout its length. A branch of an artery is less than the trunk from which it springs, but the combined area or collective capacity of all the branches into which an artery divides, is greater than the calibre of the parent vessel immediately above the point of division. The increase in the joint capacity of the branches over that of the trunk is not in the same proportion in every instance of division, and there is at least one case known in which there is no enlargement, namely, the division of the aorta into the common iliac and sacral arteries; still, notwithstanding this and other possible exceptions, it must be admitted as a general rule that an enlargement of area takes place. From this it is plain that, since the area of the arterial system increases as its vessels divide, the capacity of the smallest vessels and capillaries will be greatest; and, as the same rule applies to the veins, it follows that the arterial and venous systems may be represented; as regards capacity, by two cones whose apices (truncated it is true) are at the heart, and whose bases are united in the capillary system. The effect of this must be to make the blood move more slowly as it advances along the arteries to the capillaries, like the current of a river when it flows in a wider and deeper channel, and to accelerate its speed as it returns from the capillaries to the venous trunks.

When arteries unite they are said to anastomose or inosculate. Anastomoses may occur in tolerably large arteries, as those of the brain, the hand and foot, and the mesentery, but they are much more frequent in the smaller vessels. Such inosculation admits of a free communication between the currents of blood, and must tend to promote equability of distribution and of pressure, and to obviate the effects of local interruption.

Arteries commonly pursue a tolerably straight course, but in some parts they are tortuous. Examples of this in the human body are afforded by the arteries of the lips and of the uterus, but more striking instances may be seen in some of the lower animals, as in the well-known case of the long and tortuous spermatic arteries of the ram and the bull. In very moveable parts like the lips, this tortuosity will allow the vessel to follow their motions without undue stretching; but in other cases its purpose is not clear. The physical effect of such a condition of the vessel on the blood flowing along it must be to reduce

the velocity, by increasing the extent of surface over which the blood moves, and consequently the amount of impediment from friction; still it does not satisfactorily appear why such an end should be provided for in the several cases in which arteries are known to follow a tortuous course. The same remark applies to the peculiar arrangement of vessels named a "rete mirabile," where an artery suddenly divides into small anastomosing branches, which in many cases unite again to reconstruct and continue the trunk. Of such *retia mirabilia* there are many examples in the lower animals, but, as already remarked, the purpose which they serve is not apparent. The best known instance is that named the *rete mirabile of Galen*, which is formed by the intracranial part of the internal carotid artery of the sheep and several other quadrupeds.

**Physical Properties.**—Arteries possess considerable strength and a very high degree of elasticity, being extensible and retractile both in their length and their width. When cut across, they present, although empty, an open orifice; the veins, on the other hand, collapse, unless when prevented by connection with surrounding rigid parts.

**Structure.**—In most parts of the body the arteries are inclosed in a sheath formed of connective tissue, and their outer coat is connected to the sheath by filaments of the same tissue, but so loosely that, when the vessel is cut across, its ends readily shrink some way within the sheath. The sheath may inclose other parts along with the artery, as in the case of that enveloping the carotid artery, which also includes the internal jugular vein and pneumo-gastric nerve. Some arteries want sheaths, as those for example which are situated within the cavity of the cranium.

Independently of this sheath, arteries (except those of minute size whose structure will be afterwards described with that of the capillaries)

Fig. 107.

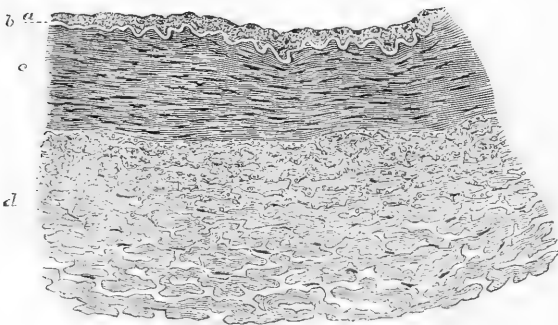


Fig. 107.—TRANSVERSE VERTICAL SECTION OF POSTERIOR TIBIAL ARTERY (MAN). 75 DIAMETERS.

*a*, Epithelioid and Subepithelial layers of inner coat; *b*, elastic layer of inner coat, appearing as a bright line in section; *c*, muscular layer (middle coat); *d*, outer coat, consisting of connective tissue bundles, which become more loosely arranged toward the exterior. In the interstices (seen as white spaces) of the bundles are some connective tissue nuclei, and, especially near the muscular coat, a number of fine elastic fibres cut across.

have been usually described as formed of three coats, named, from their relative position, internal, middle, and external (fig. 107, in section); and as this nomenclature is generally followed in medical and surgical works, and also correctly applies to the structure of arteries so far as it is discernible by the naked eye, it seems best to adhere to it as the basis of our description; although it will be seen, as we proceed, that some of these coats are found on microscopic examination really to consist of two or more strata differing from each other in texture, and therefore reckoned as so many distinct coats by some authorities.

Internal coat (fig. 107, *a*, *b*). This may be raised from the inner surface of the arteries as a fine transparent colourless membrane, elastic but very easily broken, especially in the circular or transverse direction, so that it cannot be stripped off in large pieces. It is very commonly corrugated with very fine and close longitudinal wrinkles, caused most probably by a contracted state of the artery after death. Such is the appearance presented by the internal coat to the naked eye, but by the aid of the microscope, it is found to consist of three different structures, namely: 1. An *epithelioid layer* (fig. 107, *a*, and fig. 108) forming the innermost part or lining. This is a simple layer of thin elliptical or irregularly polygonal cells, which are often lengthened into a lanceolate shape. These epithelioid elements have round or oval nuclei, with nucleoli: the outlines of the cells are often indistinct in the fresh state, but may be brought into view by means of nitrate of silver. 2. A *subepithelial layer* (striated layers of Kölliker). This is composed of a homogeneous connective tissue with a greater or less number of branched corpuscles lying in the cell-spaces of the tissue (fig. 109). In some instances the ground substance is striated or even fibrillated, and pervaded by longitudinal elastic net-

Fig. 108.

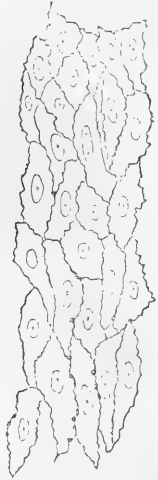

Fig. 108. — EPITHELIOD LAYER LINING POSTERIOR TIBIAL ARTERY. 250 DIAMETERS.

Nitrate of silver preparation.

Fig. 109.

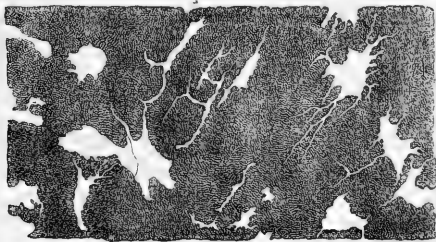


Fig. 109. — CELL-SPACES OF SUB-EPITHELIAL LAYER OF ARTERY (POSTERIOR TIBIAL). 250 DIAMETERS.

The ground substance is stained by nitrate of silver, and the cell-spaces of the tissue are thus made manifest as white patches, the contained cells not being seen.

works of varying fineness. This layer is said to be most constant in the larger arteries: it exists however in the medium-sized ones, and is to be looked upon as of considerable pathological importance, as being that in which, under certain conditions, cell proliferation is most apt to occur. 3. *Elastic layers* (fig. 107, *b*). These form the chief substance of the inner coat. The elastic tissue commonly forms longitudinal networks of fibres (fig. 110), which consist of several layers of different degrees of closeness. Not uncommonly some of these layers take on a membranous character, in which case they form the "perforated" or "fenestrated" membrane of Henle. This consists of a thin and brittle transparent film, and may exist in one or several layers; and in that case it may be stripped off in small shreds, which have a remarkable tendency to curl in at their upper and lower borders, and roll themselves up as represented in fig. 111. The films of

Fig. 110.

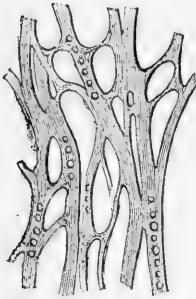


Fig. 110.—ELASTIC NETWORK OF ARTERY. 350 DIAMETERS (Kölliker).

Fig. 111.

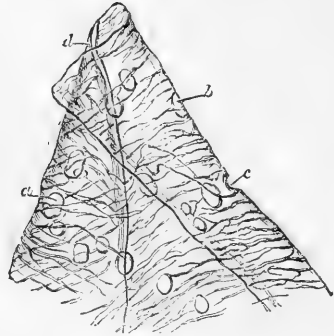


Fig. 111.—PORTION OF FENESTRATED MEMBRANE FROM THE CRURAL ARTERY, MAGNIFIED 200 DIAMETERS (Henle).

*a, b, c*, perforations.

membrane are marked by very fine pale streaks, following principally a longitudinal direction, and joining each other obliquely in a sort of network. Henle considers these lines to be reticulating fibres formed upon the membranous layer. This membrane is further remarkable by being perforated with numerous round, oval, or irregularly shaped apertures of different sizes. In some parts of the arteries the perforated membrane is very thin, and therefore difficult to strip off; in other situations it is of considerable thickness, consisting of several layers; in which case it tends in the outer layers to lose its membranous character: indeed it must be borne in mind that every transition is met with between the fenestrated membrane, as above described, and the longitudinal elastic networks before mentioned.

The inner coat may thus be said to be formed of a layer of flattened epithelioid cells; a layer of delicate connective tissue with branched cells; and elastic layers: the latter consisting of elastic tissue under two principal forms, namely, the longitudinal elastic networks and the fenestrated membrane; and these two forms may coexist in equal

amount, or one may predominate, the other diminishing or even disappearing altogether.

Middle coat (fig. 107, *c*). This consists of plain muscular tissue, in fine bundles, disposed circularly round the vessel, and consequently tearing off in a circular direction, although the individual bundles do not form complete rings. The considerable thickness of the walls of the larger arteries is due chiefly to this coat; and in the smaller ones, it is said to be thicker in comparison with the calibre of the vessel. In the largest vessels and in some small ones it is made up of many layers; and elastic films either finely reticular, or quite similar to the fenestrated membrane of the inner coat, are often found between the layers. The middle coat is of a tawny or reddish yellow colour, not unlike that of the elastic tissue, but, when quite fresh, it has a softer and more translucent aspect. Its more internal part is often described as redder than the rest, but the deeper tint is probably due to staining by the blood after death.

This coat consists mainly of muscular fibre cells (fig. 112 and fig. 113),

Fig. 112.

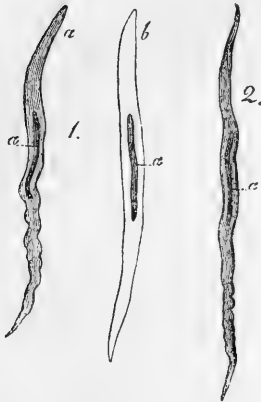


Fig. 113.



Fig. 112.—MUSCULAR FIBRE-CELLS FROM HUMAN ARTERIES. MAGNIFIED 350 DIAMETERS.

1. From the popliteal artery; *a*, natural; *b*, treated with acetic acid. 2. From a small branch of the posterior tibial (from Kölliker).

Fig. 113.—MUSCULAR FIBRE-CELLS FROM SUPERIOR THYROID ARTERY (MAN). 340 DIAMETERS.

seldom more than from  $\frac{1}{300}$  to  $\frac{1}{200}$  of an inch long and frequently presenting a very irregular shape with jagged extremities (fig. 113). Their nuclei are markedly rod shaped and are often slightly curved. Cells are occasionally met with, especially in the larger arteries, which appear to present transitions to the forked cells of which the muscular substance of the heart is composed. Fine elastic fibres are also commonly to be found in this coat mixed with the muscular bundles, and traversing the layers in form of elastic networks, which in the larger arteries pass into the elastic laminae already mentioned.

The elastic fibres are accompanied by white fibres of areolar tissue in

small quantity, the proportion of which increases with the size of the artery. It is important further to note that the muscular tissue of the middle coat is more pure in the smaller arteries, and that the admixture of other tissues increases in the larger-sized vessels; in these, moreover, the muscular cells are smaller. Accordingly, the vital contractility of the arteries, which depends on their middle coat, is very little marked in those of large size, but becomes much more conspicuous in the smaller branches.

**External coat.** (*Tunica adventitia* of the German writers) (fig. 107, *d*). This is composed mainly of fine and closely-felted bundles of white connective tissue, together with a variable amount of longitudinally disposed elastic tissue between the bundles (in the fig. this is seen cut across). This is much more abundant towards the inner part, next the muscular coat, and is frequently described as constituting here a distinct elastic layer: it is most marked in arteries of medium calibre, becoming thinner, and at length gradually disappearing in those of small size.

In large and middle-sized arteries the bundles of white connective tissue chiefly run diagonally or obliquely round the vessel, and their interlacement becomes much more open and lax towards the surface of the artery, where they connect the vessel with its sheath or with other surrounding parts. Longitudinally arranged contractile fibre-cells have been described by various observers in the external coat of some of the larger arteries, and they are said to be occasionally present amongst the circularly disposed fibres of the middle coat, and even in the sub-epithelial layer of the internal. The white tissue is usually of great proportionate thickness in the smaller arteries.

Some arteries have much thinner coats than the rest, in proportion to their calibre. This is strikingly the case with those contained within the cavity of the cranium, and in the vertebral canal; the difference depends on the external and middle coats, which in the vessels referred to are thinner than elsewhere.

**Vessels and Nerves of Arteries.**—The coats of arteries receive small vessels, both arterial and venous, named *vasa vasorum*, which serve for their nutrition. The little nutrient arteries do not pass immediately from the cavity of the main vessel into its coats, but are derived from branches which arise from the artery (or sometimes from a neighbouring artery), at some distance from the point where they are ultimately distributed, and divide into smaller branches within the sheath, and upon the surface of the vessel, before entering its coats. They form a network in the tissue of the external coat, from which a few penetrate into the middle coat, and follow the circular course of its fibres; none have been discovered in the internal coat, unless the observations of Jüschke and Arnold are to be trusted, who affirm that they have seen vessels in that situation. Minute venules return the blood from these nutrient arteries, which, however, they do not closely accompany, and discharge it into the vein or pair of veins which usually run alongside the artery. Lymphatics are present in the outer coat.

Arteries are generally accompanied by larger or smaller nerves; and when, in the operation of tying an artery, these happen to be included along with it in the ligature, great pain is experienced, but the vessel itself, when in a healthy condition, is insensible. Nerves are, nevertheless, distributed to the coats of arteries, probably for governing their

contractile movements. The nerves come chiefly from the sympathetic, but also from the cerebro-spinal system. They form plexuses round the larger arteries, and run along the smaller branches in form of fine bundles of fibres, which here and there twist round the vessel, and single nerve-fibres have been seen closely accompanying minute arteries. The fine branches destined for the artery penetrate to the middle coat, in which they are chiefly distributed. They lay aside their medullary sheath and form a plexus of pale fibres, the finest of which are without nuclei.

Minute ganglia have been described by Beale and others as connected with the arteries, or even in the case of the larger ones, situated in the external coat. From these, fine nerves proceed to be distributed, chiefly in the form of plexuses, to the muscular tissue of the middle coat.

**Contractility.** Besides the merely mechanical property of elasticity, arteries are endowed in a greater or less degree with vital contractility, by means of which they can narrow their calibre. This vital contractility, which has its seat in the plain muscular tissue of the middle coat, does not cause rapid contractions following in rhythmic succession like those of the heart;\* its operation is, on the contrary, slow, and the contraction produced is of long endurance. Its effect, or its tendency, is to contract the area of the arterial tube, and to offer a certain amount of resistance to the distending force of the blood; and as the contracting vessel will shrink the more, the less the amount of fluid contained in it, the vital contractility would thus seem to adjust the capacity of the arterial system to the quantity and force of the blood passing through it, bracing up the vessels, as it were, and maintaining them in a constant state of tension. In producing this effect, it co-operates with the elasticity of the arterial tubes, but it can be shown that after that property has reached its limit of operation the vital contraction can go further in narrowing the artery. The vital or muscular contractility of the arteries, then, counteracts the distending force of the heart and seems to be in constant operation. Hence it is often named "tonicity," and so far justly; but at the same time, like the contractility of other muscular structures, it can, by the application of various stimuli, be artificially excited to more vivid action than is displayed in this natural tonic or balanced state; and, on the other hand, it sometimes relaxes more than the habitual degree, and then the vessels, yielding to the distending force of the heart, become unusually dilated. Such a remission in their contractile force (taking place rather suddenly) is doubtless the cause of the turgescence of the small vessels of the skin which occurs in blushing; and the arteries of erectile organs are probably affected in the same manner, so as to permit an augmented flow of blood into the veins or venous cavities when erection begins.

The vital contractility of small-sized arteries is easily demonstrated in the transparent parts of cold-blooded animals. If the point of a needle be two or three times drawn quickly across one of the little arteries in the web of a frog's foot placed under the microscope, the vessel will be seen slowly to contract, and the stream of blood passing through it becomes smaller and smaller, and, by a repetition of the process, may be made almost entirely to disappear. After persisting in this contracted state for some minutes, the vessel will gradually dilate again to its original size. The same effect may be produced by the application of ice-cold water, and also by electricity, especially the interrupted electric current. Moreover, if one of the small arteries in the mesentery of a frog or of a small warm-blooded animal, such as a mouse (Poiseuille), be compressed so as to take off the distending force of the blood from the part beyond the point where the pressure is applied, that part will diminish in calibre, at first no doubt from its

\* Arteries may, however, exhibit slow rhythmic contractions: this is especially marked in some of the lower animals, *e. g.* the rabbit, in the arteries of the ear of which it may readily be observed. It is probably dependent on the presence of minute ganglia in connection with the vessels.

elasticity, and therefore suddenly, but afterwards slowly. The contractility of the smaller arteries, as well as its subjection to the influence of the nervous system, is beautifully shown in the experiment of cutting and afterwards stimulating the cervical sympathetic nerve in a cat or rabbit. Immediately after the section, the vessels of the ear become distended with blood from failure of their tonic contraction; but, on applying the galvanic stimulus to the upper portion of the nerve, they immediately shrink again, and on interrupting the stimulation they relax as before. The tonic contraction of these vessels appears to be maintained by the medulla oblongata operating through the branches of the cervical part of the sympathetic nerve; it is found, moreover, that stimulation of this so-called "vaso-motor" centre causes marked contraction of the arteries of the body generally, especially the smaller ones.

The contractility of the large arteries is not so conspicuous, and many excellent observers have failed to elicit any satisfactory manifestation of such property on the application of stimuli to these vessels. Others, however, have observed a sufficiently decided, though by no means a striking degree of contraction slowly to follow mechanical irritation or electric stimulation of these arteries in recently-killed animals. To render this effect more evident, C. J. B. Williams adopted a method of experimenting which he had successfully employed to test the irritability of the bronchial tubes. He tied a bent glass tube into the cut end of an artery, and filled the vessel, as well as the bend of the tube, with water; the application of galvanism caused a narrowing of the artery, the reality of which was made manifest by a rise of the fluid in the tube. Cold causes contraction of the larger arteries, according to the testimony of various inquirers; and, as in the smaller arteries, a gradual shrinking in calibre ensues, when the distending pressure of the blood is taken off, by the extinction or impairment of the force of the heart on the approach of death. From the experiments of C. Parry, it would appear that the contraction thus ensuing proceeds considerably beyond what would be produced by elasticity alone, and that it relaxes after death, when vitality is completely extinct, so that the artery widens again to a certain point, at which it is finally maintained by its elasticity.

#### VEINS.

**Mode of distribution.**—The veins are ramified throughout the body, like the arteries, but there are some differences in their proportionate number and size, as well as in their arrangement, which require to be noticed.

In most regions and organs of the body the veins are more numerous and also larger than the arteries, so that the venous system is altogether more capacious than the arterial, but the proportionate capacity of the two cannot be assigned with exactness. The pulmonary veins form an exception to this rule, for they do not exceed in capacity the pulmonary arteries.

The veins are arranged in a superficial and a deep set, the former running immediately beneath the skin, and thence named subcutaneous, the latter commonly accompanying the arteries, and named *venae comites vel satellites arteriarum*. The large arteries have usually one accompanying vein, and the medium-sized and smaller arteries two; but there are exceptions to this rule; thus, the veins within the skull and spinal canal, the hepatic veins, and the most considerable of those belonging to the bones, run apart from the arteries.

The communications or anastomoses between veins of considerable size, are more frequent than those of arteries of equal magnitude.

**Structure.**—The veins have much thinner coats than the arteries, and collapse when cut across or emptied; whereas a cut artery presents a patent orifice. But, notwithstanding their comparative thinness, the



veins possess considerable strength, more even, according to some authorities, than arteries of the same calibre. The number of their coats has been differently reckoned, and the tissues composing them differently described by different writers, and this discrepancy of statement is perhaps partly due to the circumstance that all veins are not perfectly alike in structure. In most veins of tolerable size, three coats may be distinguished, which, as in the arteries, have been named external, middle, and internal.

**Internal coat.**—This is less brittle than that of the arteries, and therefore admits of being more readily peeled off without tearing; but, in other respects, the two are much alike. It consists of an *epithelioid layer*, a *subepithelial connective tissue layer*, said to be the most marked in the *smaller* veins, and the usual *elastic layers*; these occur as dense lamelliform networks of longitudinal elastic fibres, and but seldom as fenestrated membranes.

**Middle coat.**—This coat is much thinner than that of the arteries, and its muscular tissue has a much larger admixture of white connective tissue. Its fibres are both longitudinal and circular, the one set alternating with the other in layers. The former are well-developed elastic fibres, longitudinally reticulating; the circular layers consist of bundles of muscular fibre-cells and white connective tissue, mixed with a smaller proportion of fine elastic fibres. In medium-sized veins the middle coat contains several successions of the circular and longitudinal layers, but the latter are all more or less connected together by elastic fibres passing through the intervening circular layers. In the larger veins the middle coat is less developed, especially as regards its muscular fibres, but in such cases the deficiency may be supplied by muscularity of the outer coat. The middle coat is wanting altogether in most of the hepatic part of the vena cava, and in the great hepatic veins (Kölliker); its muscularity is best marked in the splenic and portal veins.

**External coat.**—This is usually thicker than the middle coat; it consists of dense areolar tissue and longitudinal elastic fibres. In certain large veins, as pointed out by Remak, this coat contains a considerable amount of plain or non-striated muscular tissue. The muscular elements are well marked in the whole extent of the abdominal cava, in which they form a longitudinal network, occupying the inner part of the external coat; and they may be traced into the renal, azygos, and external iliac veins. The muscular tissue *of the external coat* is also well developed in the trunks of the hepatic veins and in that of the vena portæ, whence it extends into the splenic and superior mesenteric.

Other veins present peculiarities of structure, especially in respect of muscularity. 1. The striated muscular tissue of the auricles of the heart is prolonged for some way on the adjoining part of the venæ cavæ and pulmonary veins. 2. The plain muscular tissue is largely developed in the veins of the gravid uterus, in which, as well as in some other veins, it is described as being present in all three coats. 3. On the other hand, muscular tissue is wanting in the following veins, viz., *a*, those of the maternal part of the placenta; *b*, most of the veins of the brain and pia mater; *c*, the veins of the retina; *d*, the venous sinuses of the dura mater; *e*, the cancellar veins of the bones; *f*, the venous spaces of the corpora cavernosa. In most of these cases the veins consist merely of an epithelioid layer and a layer or layers of connective tissue more or less developed; in the corpora cavernosa the epithelium is applied to the trabecular tissue. It may be added that in the thickness of their coats the superficial veins surpass the deep, and the veins of the lower limbs those of the upper.

The coats of the veins are supplied with nutrient vessels, *vasa vasorum*, in the same manner as those of the arteries. *Nerves* are distributed to them in the same manner as to the arteries, but in far less abundance.

**Vital properties.**—Veins, when in a healthy condition, appear, like arteries, to be almost devoid of sensibility. They possess vital contractility, which shows itself in the same manner as that of the arteries, but is greatly inferior in degree, and much less manifest. The muscular parts of the great veins, near the auricles of the heart, on being stimulated, in recently-killed quadrupeds, exhibit quick and decided contractions, somewhat resembling those of the auricles themselves.

Fig. 114.

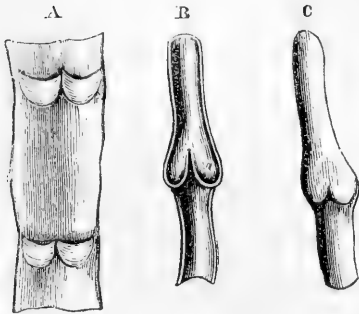


Fig. 114.—DIAGRAMS SHOWING VALVES OF VEINS.

A. Part of a vein laid open and spread out, with two pairs of valves. B. Longitudinal section of a vein, showing the apposition of the edges of the valves in their closed state. C. Portion of a distended vein, exhibiting a swelling in the situation of a pair of valves.

Wharton Jones discovered a rhythmic pulsation in the veins of the bat's wing, the pulsation occurring from ten to twelve times in a minute; and it is worthy of note that the muscular tissue of these vessels is non-striated as in other veins.

**Valves.**—Most of the veins are provided with valves, a mechanical contrivance beautifully adapted to prevent the reflux of the blood. The valves are formed of semilunar folds of the internal coat, strengthened by included connective tissue, which project obliquely into the vein. Most commonly two such folds or flaps are placed opposite each other (fig. 114, A); the convex border of each (which, according to Haller, forms a parabolic curve) is connected with the side of the vein; the other edge

is free, and points towards the heart, or at least in the natural direction of the current of the blood along the vessel, and the two flaps obliquely incline towards each other in this direction. Moreover the wall of the vein immediately above (or nearer the heart than) the curved line of attachment of the valves, is dilated into a pouch or *sinus* on each side (fig. 114, B), so that, when distended with blood or by artificial injection, the vessel bulges out on each side, and thus gives rise to the appearance of a knot or swelling wherever a valve is placed (as in fig. 114, C). From the above description, it is plain that the valves are so directed as to offer no obstacle to the blood in its onward flow, but that, when from pressure or any other cause it is driven backwards, the reflux blood, getting between the dilated wall of the vein, and the flaps of the valve, will press them inwards until their edges meet in the middle of the channel and close it up.

The valvular folds are usually placed in pairs as above described; in the veins of the horse and other large quadrupeds three are often found ranged round the inside of the vessel; but this rarely occurs in the human body. On the other hand, the valves are placed singly in some of the smaller veins, and in large veins single valves are not unfrequently placed over the openings of smaller entering branches; also in the right auricular sinus of the heart there is a single

crenate fold at the orifice of the vena cava inferior, and another more completely covering the opening of the principal coronary vein.

Many veins are destitute of valves. Those which measure less than a line in diameter rarely, if ever, have them. In *man*, valves are wanting in the trunks of the superior and inferior venæ cavæ, in the trunk and branches of the portal vein, in the hepatic, renal, and uterine veins; also in the spermatic (ovarian) veins of the female. In the male, these last-mentioned veins have valves in their course, and in each sex a little valve is occasionally found in the renal vein, placed over the entrance of the spermatic. The pulmonary veins, those within the cranium and vertebral canal, and those of the cancellated texture of bone, as well as the trunk and branches of the umbilical vein, are without valves. Valves are not generally found, and when present are few in number, in the azygos and intercostal veins. On the other hand, they are numerous in the veins of the limbs (and especially of the lower limbs), which are much exposed to pressure in the muscular movements or from other causes, and have often to support the blood against the direction of gravity. No valves are met with in the veins of reptiles and fishes, and not many in those of birds.

#### SMALLER ARTERIES AND VEINS AND CAPILLARIES.

That the blood passes from the arteries into the veins was of course a necessary part of the doctrine of the circulation, as demonstrated by Harvey; but the mode in which the passage takes place was not ascertained until some time after the date of his great discovery. The discovery of the capillary vessels, and of the course of the blood through them, was destined to be one of the first fruits of the use of the microscope in anatomy and physiology, and was reserved for Malpighi (in 1661).

When the web of a frog's foot is viewed through a microscope of moderate power (as in fig. 115), the blood is seen passing rapidly along the small arteries, and thence more slowly through a network of finer channels, by which it is conducted into the veins. These small vessels, interposed between the finest branches of the arteries and the commencing veins, are the capillary vessels. They may be seen also in the lungs or mesentery of the frog and other batrachians, and in the tail and gills of their larvæ: also in the tail of small fishes; in the mesentery of mice or other small quadrupeds; and generally, in short, in the transparent vascular parts of animals which can readily be brought under the microscope. These vessels can also be demonstrated by means of fine injections of coloured material, not only in membranous parts, such as those above mentioned, but also in more thick and opaque tissues, which can be subsequently rendered transparent.

The capillary vessels of a part are most commonly arranged in a network, the branches of which are of tolerably uniform size, though not all strictly equal; and thus they do not divide into smaller branches like the arteries, or unite into

Fig. 115.



Fig. 115.—CAPILLARY BLOOD-VESSELS IN THE WEB OF A FROG'S FOOT AS SEEN WITH THE MICROSCOPE (after Allen Thomson).

The arrows indicate the course of the blood.

larger ones like the veins ; but the diameter of the tubes, as well as the shape and size of the reticular meshes which they form, differs in different textures. Their prevalent size in the human body may, speaking generally, be stated at from  $\frac{1}{3500}$  to  $\frac{1}{2000}$  of an inch, as measured when naturally filled with blood. But they are said to be in some parts considerably smaller, and in others larger than this standard : thus, Weber has measured injected capillaries in the brain, which he found to be not wider than  $\frac{1}{4700}$  of an inch, and Henle has observed some still smaller,—in both cases apparently smaller than the natural diameter of the blood-corpuscles. The capillaries, however, when deprived of blood, probably shrink in calibre immediately after death ; and this consideration, together with the fact that their distension by artificial injection may exceed or fall short of what is natural, should make us hesitate on such evidence to admit the existence of vessels incapable of receiving the red particles of the blood. The diameter of the capillaries of the marrow, or of the medullary membrane, is stated as high as  $\frac{1}{1200}$  of an inch. In other parts, their size varies between these extremes : it is small in the lungs, small also in muscle ; larger in the skin and mucous membranes. The extreme branches of the arteries and the commencing veins in certain parts of the synovial membranes are connected by capillary loops, which are considerably dilated at their point of flexure.

There are differences also in the size or width of the meshes of the capillary network in different parts, and consequently in the number of vessels distributed in a given space, and the amount of blood supplied to the tissue. The network is very close in the lungs and in the choroid coat of the eye, close also in muscle, in the skin, and in most mucous

Fig. 116.

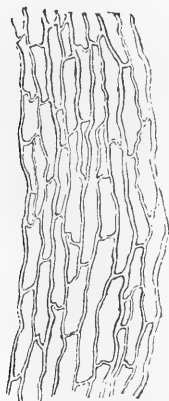


Fig. 116.—INJECTED CAPILLARY VESSELS OF MUSCLE, SEEN WITH A LOW MAGNIFYING POWER.

Fig. 117.

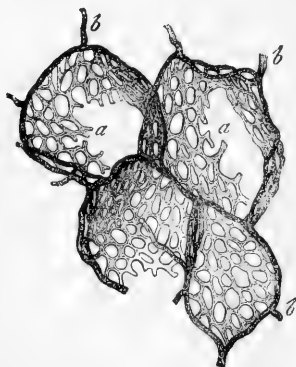


Fig. 117.—NETWORK OF CAPILLARY VESSELS OF THE AIR-CELLS OF THE HORSE'S LUNG, MAGNIFIED.

*a, a*, capillaries proceeding from *b, b*, terminal branches of the pulmonary artery after Frey).

membranes, in glands and secreting structures, and in the grey part

of the brain and spinal cord. On the other hand, it has wide meshes and comparatively few vessels in the ligaments, tendons, and other allied textures. In infants and young persons, the tissues are more vascular than in after-life; growing parts, too, are more abundantly supplied with vessels than those which are stationary.

The figure of the capillary network is not the same in all textures. In many cases the shape of the meshes seems accommodated to the arrangement of the elements of the tissue in which they lie. Thus in muscle, nerve, and tendon, the meshes are long and comparatively narrow, and run conformably with the fibres and fasciculi of these textures (fig. 116). In other parts the meshes are rounded or polygonal, with no one dimension greatly predominating (fig. 117). In the smaller-sized papillæ of the skin and mucous membranes, the vessels of the network are often drawn out into prominent loops.

**Structure of the Smaller-sized Vessels and Capillaries.**—The smallest arteries and veins pass by gradual transition into the capillary vessels, and their finest offsets approach very near to these in structure; they may therefore be conveniently considered together.

Fig. 118.

The wall of the capillaries proper is formed entirely of a simple epithelioid layer, composed of flattened lanceolate cells joined edge to edge, and continuous with the corresponding layer which lines the arteries and veins. The outlines of the cells or their lines of junction one with another may be made apparent by nitrate of silver; after which the nuclei may be brought into view by logwood or carmine (fig. 118). Commonly there are not more than two or three such cells in the cross section of a capillary, but there may be four or five. At the points of junction of the capillaries the cells are much broader and not spindle-shaped, but radiate, with three or four pointed branches fitting in between the cells of the three or four adjoining vessels which meet at the spot (fig. 118 *c*).

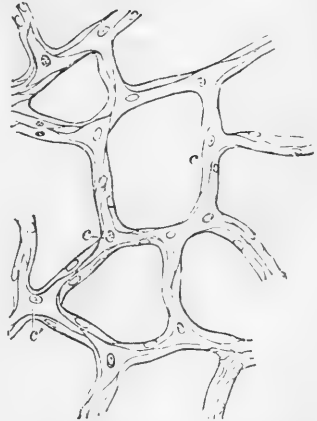


Fig. 118. — CAPILLARY VESSELS FROM BLADDER OF CAT MAGNIFIED (after Chrzonszczewsky.)

The outlines of the cells are stained by nitrate of silver.

A protrusion of processes from the capillary wall has been observed, not only in the progress of development, in the manner to be afterwards detailed, but also in the fully-developed capillaries of the frog's hyaloid membrane (Stricker): for this and other reasons the cells which compose these vessels are regarded as of a protoplasmic nature.

Branched cells of the surrounding connective tissue are sometimes found connected more or less intimately with those forming the capillary wall; this is more especially the case in parts which are pervaded by a supporting network of retiform connective tissue, such as the substance of the lymphatic glands, the solitary and agminated intestinal glands and adjacent mucous membrane, where the small vessels and capillaries may even obtain a continuous covering

from the reticulating processes of the cells. This coating has been named by His, the *adventitia capillaris*.

In vessels one or two degrees larger (small arteries and veins), there is added outside the epithelioid layer (fig. 119, *a, a'*), a layer of plain

Fig. 119.

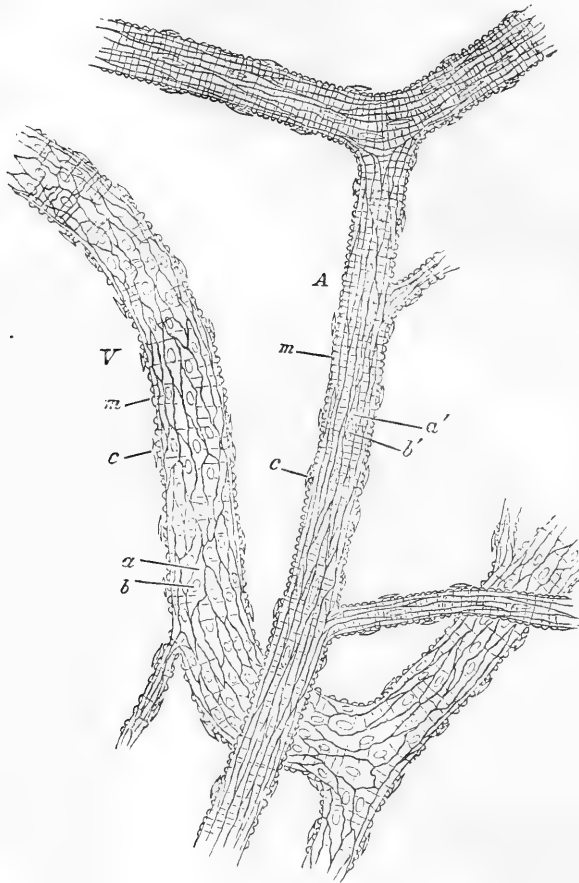


Fig. 119.—A SMALL ARTERY A, AND VEIN V, FROM THE SUBCUTANEOUS CONNECTIVE TISSUE OF THE RAT. TREATED WITH NITRATE OF SILVER. 175 DIAMETERS.

*a, a'*, epithelioid cells with *b, b'*, their nuclei; *m, m*, transverse markings due to staining of substance between the muscular fibre-cells; *c, c*, nuclei of connective tissue corpuscles attached to exterior of vessel.

muscular tissue, in form of the usual oblong contractile fibre-cells, which are directed across the length of the vessel (fig. 119, *m, m*). The elongated nuclei of these cells may be brought into view by means of acetic acid, as shown in fig. 120. This layer corresponds with the middle or muscular coat of the arteries. In the smallest vessels in which it appears the muscular cells are few and apart, and a

single long cell may turn spirally round the tube (Lister); in larger vessels, especially those of the arterial system, they are of course more densely laid on. Outside the muscular coat is the areolar or connective tissue coat, containing fibres and connective tissue corpuscles, with longitudinally placed nuclei.

In vessels of  $\frac{1}{60}$  of an inch in diameter, or even less, the elastic layers of the inner coat may be discovered (fig. 120, A,  $\delta$ ), in the form

Fig. 120.

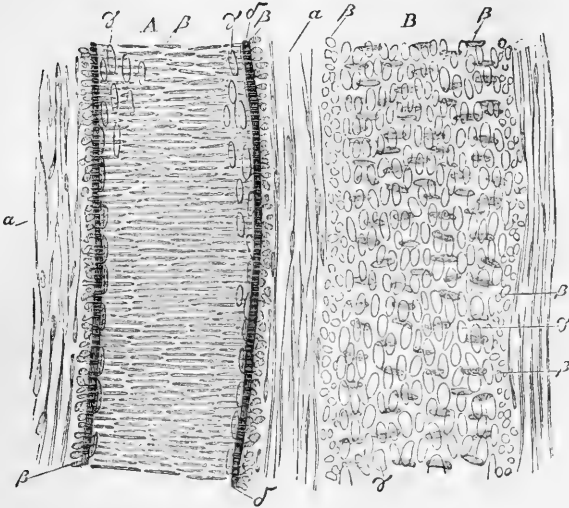


Fig. 120.—A SMALL ARTERY A, WITH A CORRESPONDING VEIN B, TREATED WITH ACETIC ACID, AND MAGNIFIED 350 DIAMETERS (after Kölliker).

$\alpha$ , external coat with elongated nuclei;  $\beta$ , nuclei of the transverse muscular tissue of the middle coat (when seen endwise, as at the sides of the vessel, their outline is circular);  $\gamma$ , nuclei of the epithelium-cells;  $\delta$ , elastic layers of the inner coat.

generally of homogeneous or fenestrated membrane, more rarely of longitudinal reticulating elastic fibres. The small veins, but two or three removes from the capillaries, differ from arteries of corresponding size, chiefly in the inferior development of their muscular tissue; the lining cells of the arteries also are very much longer and narrower than those of the veins. These differences, as well as the comparative size of corresponding vessels, are well shown in the accompanying figures.

**Termination of Arteries.**—The only known termination of arteries is in veins, and this takes place by means of capillary vessels as above described, unless in the maternal part of the placenta and in the interior of erectile organs, in which it has been supposed that small arteries open into wide venous cavities without the intervention of capillaries. Moreover, in the spleen, the arterial capillaries do not at once unite into the commencements of the veins, but open into the interstices of the organ, from which the minute veins collect the blood.

It is said that in certain parts small arteries may pass into small veins without the intervention of true capillaries (Sucquet, Hoyer).

**Erectile, or cavernous tissue.**—By this term is understood a peculiar structure, forming the principal part of certain organs which are capable of being rendered turgid, or erected, by distension with blood. It consists of dilated and freely intercommunicating branches of veins, into which arteries pour their blood, occupying the areolæ of a network formed by fibrous, elastic, and probably contractile bands, named trabeculæ, and enclosed in a distensible fibrous envelope. This peculiar arrangement of the blood-vessels scarcely deserves to be regarded as constituting a distinct texture, though reckoned as such by some writers; it is restricted to a very few parts of the body, and in these is not altogether uniform in character; the details of its structure will, therefore, be considered with the special description of the organs in which it occurs.

#### DEVELOPMENT OF BLOOD-VESSELS.

The first vessels which appear are formed within the ovum, in the germinal membrane, and the process subsequently goes on in growing parts of the animal body. New vessels, also, are formed in the healing

Fig. 121.

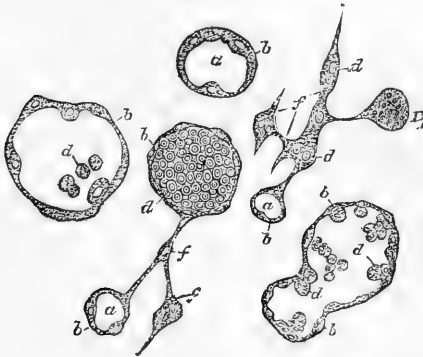


Fig. 121.—CELLS FROM MIDDLE LAYER OF CHICK'S BLASTODERM UNDERGOING DEVELOPMENT INTO BLOOD-VESSELS. MAGNIFIED.

*a*, blood-corpuscles (from Klein).

of wounds and sores, in the organisation of effused lymph, in the restoration of lost parts, and in the production of adventitious growths. The process is in every case essentially the same, although more or less modified according to circumstances.

The first vessels of the embryo-chick, those, namely, which produce the vascular area, originate from nucleated cells belonging to the middle germinal layer. Within these cells vacuoles are formed and, increasing in size, a cavity filled with fluid is in this way produced in the interior of the cell (fig. 121, *a*). Blood-corpuscles (*d*) are found at an early period within the cavity: the mode in which they become developed has been already described (p. 41). The cells, whilst these changes are going on, increase largely in size so as to form vesicles, visible to the naked eye as minute reddish specks, which have been known since the time of Pander as "blood-islands." They are at first isolated, as the name implies, but after a time send out processes which unite with those of neighbouring cells, and the cavities becoming extended into these processes a network of vessels is by this means produced.\*

The wall (*b*) of these primary vessels is therefore composed at first merely of the protoplasm of the original embryonic cells with a few

\* We are here mainly following Klein's description (Wiener Sitzungsber., lxiv. 1870), but according to the more recent account given by Balfour (Quarterly Journal of Microscopic Science, July, 1873), the cells first unite by means of processes into a protoplasmic network, within the substance of which, by the multiplication of the *cell-nuclei*, blood-corpuscles subsequently become developed.



nuclei, derived by division from the original nuclei of those cells, imbedded in it here and there. Subsequently the protoplasm spreads out and becomes differentiated around the nuclei into the flattened cells which compose the wall of the capillaries, and which form the lining membrane of the arteries and veins. The remaining coats of the larger vessels are developed later from cells which come to apply themselves to the exterior of the previously simple tubes and produce the plain muscular and other tissues of which those coats consist.

The process of formation of the blood-vessels has not been so completely traced within the *body* of the embryo chick, but there is no doubt that it is in all respects similar. In mammalia they are produced in like manner from vacuolated cells belonging to the connective tissue. The most favourable object for the study of the development of the blood-vessels and their contained blood-corpuscles is afforded by the subcutaneous tissue of the new-born rat, especially those parts in which fat is being deposited.

Here we observe that many of the connective tissue corpuscles are excessively vacuolated (fig. 122, *v*), and the protoplasm of some

Fig. 122.

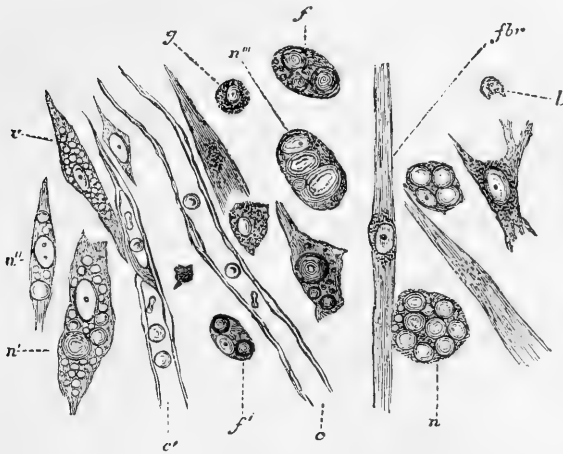


Fig. 122.—DEVELOPMENT OF BLOOD-VESSELS AND BLOOD-CORPUSCLES IN THE CONNECTIVE TISSUE. FROM THE SUBCUTANEOUS TISSUE OF THE NEW-BORN RAT, EXAMINED IN SALT-SOLUTION ( $\frac{1}{2}$  PER CENT.), AND MAGNIFIED ABOUT 350 DIAMETERS.

*n*, *n'*, *n''*, *n'''*, cells containing blood-corpuscles in various stages of development; in *n'''*, the reddish matter is mainly in two large roundish ill-defined patches; in *n*, the hæmoglobin globules are of nearly equal size, and fill the cell; a little above this cell another is seen with three such globules; the nucleus is also apparent; *n'*, and *n''*, exhibit in addition a number of vacuoles; *v*, vacuolated cell without blood corpuscles, applied to another cell the vacuoles of which have united to form a cavity in which two fully-developed corpuscles are observed; this cell is joined to the end of the developing capillary vessel *c'*; *c*, portion of a fully-developed capillary; *f*, *f'*, cells in which fat is being deposited; another is seen to the right of the capillary, between it and *fbr*, fibrillated cell of the connective tissue; *g*, granular connective tissue corpuscle; *l*, leucocyte.

of them presents a decided reddish tinge. In others the red matter has become condensed in the form of globules within the cells (*n*, *n'*,

&c.), varying in size from minute specks to spheroids of the diameter of a blood-corpuscle, or more. At some parts the tissue is completely studded with these cells, each containing a number of such spheroids, and forming, as it were, "nests" of blood-corpuscles or minute "blood-islands." After a time the cells, previously rounded, become elongated and pointed at their ends, sending out processes also to unite with

neighbouring cells. At the same time the vacuoles in their interior become enlarged, and coalesce to form a cavity within the cell, in which the reddish globules, which are now becoming disk-shaped, are found. Finally the cavity extends through the cell processes into those of neighbouring cells and into those sent out from pre-existing capillaries (*c'*). Young capillaries do not exhibit the well-known silver lines when treated with that reagent, for the differentiation of the hollowed cells and cell-processes into flattened cellular elements is usually a subsequent process.

The mode of extension of the vascular system in growing parts, as well as in pathological new formations, is quite similar to that here described, except that blood-corpuscles are not as a rule previously developed within the cells which are to form the blood-vessels.\*

In the tail of batrachian larvæ the process has long been studied and is represented in the adjoining figure (fig. 123) by Kölliker, in which the processes of a stellate cell are seen to meet and join with similar pointed processes which shoot out from the sides of neighbouring capillary vessels, and in this manner the new vessels are adopted into the existing system. The junctions of the cells with each other or with capillary vessels are, at first, of great tenuity, and contrast strongly with the central and wider parts of the cells; they appear then to be solid, but they afterwards become pervious and gradually widen, blood

begins to pass through them, and the capillary network acquires a tolerably uniform calibre. The original vascular network may become closer by the forma-

\* A formation of blood-corpuscles and vessels from cartilage-cells has been described by Heitzmann as occurring in ossifying cartilage.

Fig. 123.

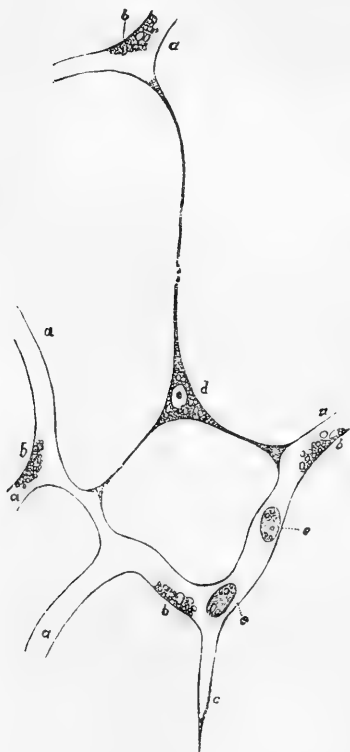


Fig. 123.—CAPILLARY BLOOD-VESSELS OF THE TAIL OF A VERY YOUNG FROG LARVA, MAGNIFIED 350 DIAMETERS (after Kölliker).

*a*, capillaries permeable to blood; *b*, granules, attached to the walls of the vessels and concealing nuclei; *c*, hollow prolongation of a capillary, ending in a point; *d*, a branched cell, containing a nucleus and granules, and communicating by three branches with prolongations of capillaries already formed; *e*, blood-corpuscles.

tion of new vessels in its interstices, and this is effected by similarly metamorphosed cells, arising in the areolæ and joining at various points with the surrounding vessels, and also simply by pointed offshoots from the existing capillaries stretching across the intervals and meeting from opposite sides, so as when enlarged to form new connecting arches.

The blood-vessels may be said to increase in size and capacity in proportion to the demands made on their service. Thus, as the uterus enlarges in pregnancy, its vessels become enlarged, and when the main artery of a limb is tied, or otherwise permanently obstructed, collateral branches, originally small and insignificant, augment greatly in size, to afford passage to the increased share of blood which they are required to transmit, and by this admirable adaptation of them to the exigency, the circulation is restored. In such cases, an increase takes place in length, as well as in diameter, and accordingly the vessels very commonly become tortuous.

### LYMPHATIC SYSTEM.

Under this head we include not only the vessels specially called lymphatics or absorbents, together with the glands belonging to them, but also those named lacteal or chyloferous, which form part of the same system, and differ in no respect from the former, save that they not only carry lymph like the rest, but are also employed to take up the chyle from the intestines during the process of digestion and convey it into the blood. An introductory outline of the lymphatic system has already been given at page 37.

A system of lymphatic vessels is superadded to the sanguiferous in all classes of vertebrated animals, but such is not the case in the invertebrata; in many of these, the sanguiferous vessels convey a colourless or nearly colourless blood, but no additional class of vessels is provided for conveying lymph or chyle, at least none such has hitherto been detected.

**Distribution.**—In man and those animals in which they are present, the lymphatic vessels are found in nearly all the textures and organs which receive blood; the exceptions are few, and with the progress of discovery may yet possibly disappear. It is, however, with the connective tissue of the several textures and organs that the lymphatics are most intimately associated; indeed, as we shall immediately have occasion to notice, these vessels may be said to take origin in spaces in that tissue. The larger lymphatic trunks usually accompany the deeply-seated blood-vessels; they convey the lymph from the plexuses or sinuses of origin towards the thoracic duct. The principal lymphatic vessels of a part exceed the veins in number but fall short of them in size; they also anastomose or intercommunicate much more frequently than the veins alongside of which they run.

It not unfrequently happens that a lymphatic vessel may ensheath an artery or vein either partially or wholly. In the latter case the lymphatic is termed "perivascular."

**Origin.**—Two modes of origin of lymphatic vessels are described, viz., the *plexiform* and the *lacunar*.

*Plexiform.* In this mode of origin, which is by far the most general, and is met with in its most typical form on the surface of aponeurotic structures such as the central tendon of the diaphragm (fig. 124), the vessels begin in form of irregular networks or plexuses which are at various points in connection with the cell-spaces of the connective

tissue in which they lie. The manner of this connection will be more fully considered after the structure of these "lymphatic capillaries" (as the vessels forming the plexuses of origin are termed) has

Fig. 124.

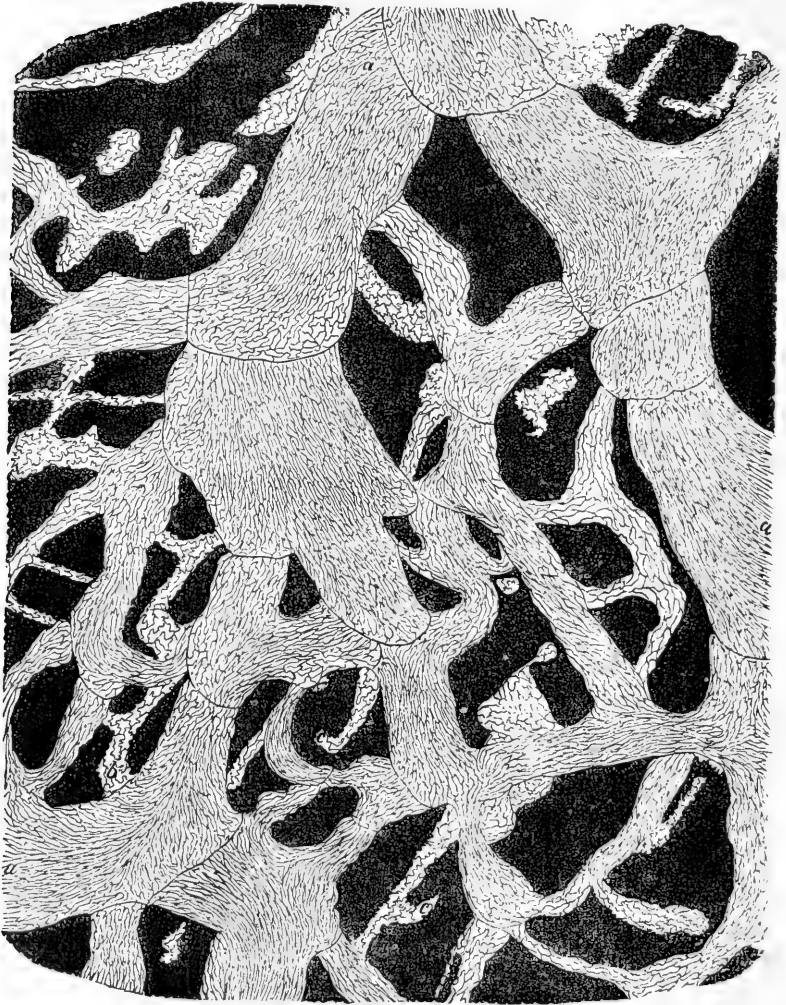


Fig. 124.—LYMPHATIC PLEXUS OF CENTRAL TENDON OF DIAPHRAGM OF RABBIT, PLEURAL SIDE (Klein). MAGNIFIED.

*a*, larger vessels with lanceolate cells and numerous valves; *b*, *c*, lymphatics of origin, with wavy-bordered cells. Here and there an isolated patch of similar cells.

been explained. Out of these plexuses larger vessels emerge at various points and proceed to enter lymphatic glands or to form larger lym-

phatic trunks. In certain structures, such as the skin, the plexuses consist of several strata, becoming finer as they approach the surface, in respect both of the calibre of the vessels and the closeness of their reticulation, as is shown in figure 125. But even the most superficial and finest network is composed of vessels which are larger than the sanguiferous capillaries.

The short anastomosing branches of these plexuses are often of very unequal size, even in the same stratum, some being dilated and almost saccular, whilst others immediately communicating with these are narrow, so that the network may assume a varicose character (see fig. 124). In some situations the plexuses have much the appearance of strata of intercommunicating cavities, and a characteristic example of this appearance is afforded by the intestine of the turtle after its lymphatics have been injected with mercury; these vessels are then seen to emerge from what has all the appearance of a dense stratum of small rounded saccules filled with mercury and lying beneath the surface of the mucous coat. This appearance, however, is produced by the short distended branches of a very close lymphatic network.

Here and there vessels are seen joining the plexuses of origin which arise in the tissue by a blind and often irregular extremity. A long-known and well-marked example of such a mode of commencement is to be found in the lacteals of the intestinal villi, which, although they form networks in the larger and broader villi, arise in others by a single vessel beginning with a blind or closed extremity at the free end of the villus, whence it sinks down to join the general plexus of the intestinal membrane.

*Lacunar.*—In the lacunar mode of origin of the lymphatics, which was shown to exist in the testis by Ludwig and Tomsa, and has since been described in some other glandular organs, the lymphatic vessels proceed from irregular or shapeless spaces in the internal parts; the spaces, that is, which intervene between the several structures of which the organ is composed. Thus, in a gland, they are the spaces which lie between or surround the blood-vessels, secreting tubes or saccules, partitioning or inclosing membranes, and the like. Though shapeless, or at least of no regular form, these anfractuons cavities are limited and defined by a layer of flattened epithelioid cells, agreeing in character with those of the lymphatic vessels. It may be presumed that their opposite sides are in apposition or in near proximity, as in serous membranes, for the lymph deposited in these recesses is not suffered to accumulate, but is drained off by the lymphatic vessels which lead out of them.

Indeed, as will be pointed out further on, the serous cavities themselves may in a certain sense be looked upon as large lymph lacunæ, for it has been shown that in various parts they communicate directly with lymphatics by means of definite apertures.

In some of the lower animals the lacunar condition of lymphatics has been

Fig. 125.

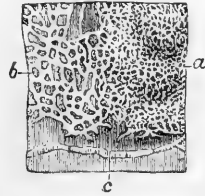


Fig. 125.—LYMPHATIC VESSELS OF THE SKIN OF THE BREAST INJECTED (after Breschet).

*a*, superficial, and *b*, deeper plexus; *c*, a lymphatic vessel, which proceeded to the axillary glands.

longer known. Rusconi found that the aorta and mesenteric arteries of amphibian reptiles are inclosed in large lymphatic spaces. Johannes Müller recognised the spaces which so extensively separate the frog's skin from the subjacent muscles as belonging to the lymphatic system, and Von Recklinghausen has shown that the subcutaneous lymph-spaces of the frog's leg communicate with lymphatic vessels which envelope the blood-vessels of the foot; also that milk injected into these spaces finds its way into the blood. The lymphatic system, in being thus partly constituted by lacunæ or interstitial receptacles, so far agrees with the sanguiferous system of crustaceans and insects.

It has been sometimes maintained that the lymphatics of glandular organs communicate at their origin with the ducts; but, although it is no uncommon thing for matters artificially injected into the ducts of glands, as, for instance, those of the liver and testicle, to pass into the lymphatics, a careful examination of such cases leads to the conclusion that the injected material does not find its way from the ducts into the lymphatics by any naturally existing communication, but by accidental rupture of contiguous walls of the two classes of vessels.

**Structure.**—In structure the larger lymphatic vessels much resemble the veins, only their coats are thinner, so thin and transparent indeed that the contained fluid can be readily seen through them. When lymphatics have passed out from the commencing plexuses and lacunæ, they are found to have three coats. The internal coat is covered with an epithelioid lining, consisting of a single layer of flattened nucleated cells, which have mostly an oblong or lanceolate figure, with an indented or bluntly serrated border, by which the adjacent cells fit to each other (fig. 124, *a*). Beneath the epithelioid layer the inner coat is formed of a layer or layers of longitudinal elastic fibres. The middle coat consists of plain muscular tissue disposed circularly, mixed with finely reticulating elastic fibres taking the same direction. The external coat is composed mainly of white connective tissue with a sparing intermixture of longitudinal elastic fibres, and some longitudinal and oblique bundles of plain muscular tissue. In the thoracic duct there is a subepithelial layer (as in the arteries); and in the middle coat there is a longitudinal layer of white connective tissue with elastic fibres, immediately within the muscular layer.

The larger lymphatics receive vasa vasorum, which ramify in their outer and middle coats: nerves distributed to them have not yet been discovered, although their existence is inferred on physiological grounds.

That the lymphatics are endowed with vital contractility is shown by the effect of mechanical irritation applied to the thoracic duct, as well as by the general shrinking and emptying of the lacteal and lymphatic vessels on their exposure to the contact of cold air, in the bodies of animals opened immediately after death.

The commencing lymphatics or "lymphatics of origin," whether in plexuses or single (as in the villi), have a much simpler structure, their wall being entirely formed of a layer of flattened epithelioid cells either similar in form to those lining the larger vessels or (more frequently) presenting a characteristic waved border like the epidermic cells of grasses and some other plants (figs. 124, *b*, 126, *a*). The outlines of the cells are brought into view by staining with nitrate of silver, after which the nuclei may be made to appear by means of carmine or hæmatoxylin.

**Relation of the lymphatics of origin to the cells and cell-spaces of the connective tissue.**—It has been already stated (p. 57) that the cells of the connective tissue lie in spaces in the ground-substance

which they more or less completely fill. These cells and cell-spaces form in many parts an intercommunicating network of varying fineness extending throughout the substance of the tissue (fig. 126, *d, d*), whilst

Fig. 126.

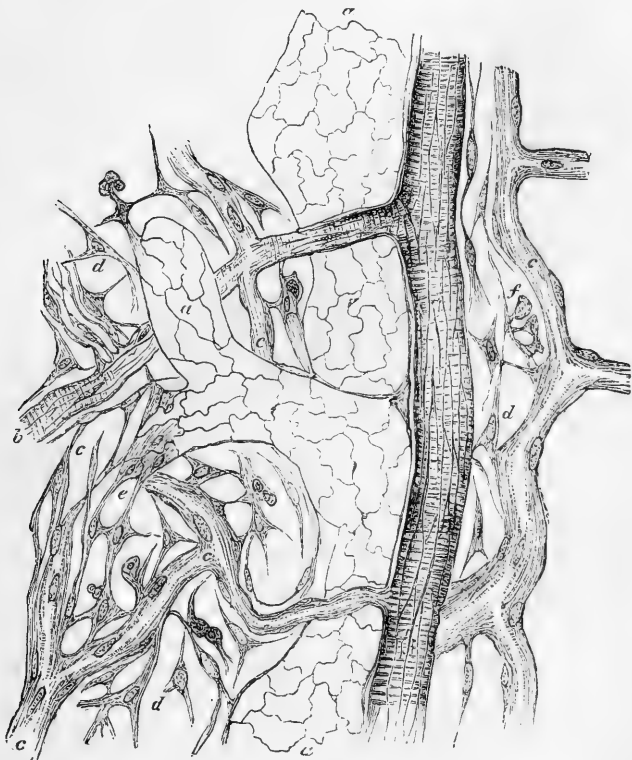


Fig. 126.—NITRATE OF SILVER PREPARATION FROM RABBIT'S OMENTUM (Klein).  
MAGNIFIED.

*a*, Lymphatic vessel; *b*, artery; *c*, capillaries; *d*, branched cells of the tissue which are seen to be connected both with the capillary walls, and, as at *e*, with the lymphatic.

in other parts the cells acquire a broad flattened form, and joining edge to edge with other similar cells may in this way form an epithelioid patch in the ground-substance. Not unfrequently the cells in such a patch take on the wavy border described above as met with in the lymphatics of origin (see fig. 124). Further, the flattened cells which form the walls of the latter vessels are connected here and there both with the more isolated cells of the tissue (fig. 126 *e*) and with those which form the epithelioid patches, and in silvered preparations they appear to be continuous with one another. The epithelioid patches look in fact like a part of the lymphatic, and are commonly regarded as such: it must be understood, however, that the spaces here spoken of, whether containing single cells or groups, are not true *vessels*, but merely vacui-

ties in the ground-substance of the tissue containing flattened cells, which do not form a continuous vascular wall. And although the spaces present a very close relation to the lymphatic vessels, they can hardly be considered as actually opening into them by patent orifices, for the lymphatics proper have a complete wall of flattened cells united by a small amount of intercellular substance: at the same time this thin film can offer but a very slight resistance to the passage of fluid from the tissue into the vessel, or even to the passage of leucocytes or migrating cells, which, as is well known, penetrate the at least equally closed wall of the blood-vessels.

It has been a question whether the cell-spaces of the connective tissue are in every case and completely filled by the cells, or whether they (the spaces) may in some cases be either devoid of cells altogether, or but partially occupied by them: so that room is left for the free passage of fluid. On this point we would remark that in many cases it is impossible to observe a difference between the forms of the *cells* as shown by the gold method, and those of the *spaces* as shown by treatment with solution of nitrate of silver, so that in these, at least, no open lymph-passage can be said to exist; but in other cases the spaces are relatively larger, and here, no doubt, the part unoccupied by the contained cell may be filled by fluid. In œdematous conditions of the tissue, the cell-spaces become somewhat distended with serous fluid, and then in all cases they appear distinctly larger than the cells. So that we may conclude that the so-called *saft-canälchen*- or lymphatic-canalicular-system is in many cases rather potential than actual; that is, where the *saft-canälchen* or lymphatic canaliculi (which correspond with the cell-spaces) are completely filled by protoplasmic cells. Still, lymph can readily find its way between the cells and the ground-substance by which they are closely surrounded. In other cases the cells incompletely fill the cavities, so as to leave a freer passage for both fluid and migratory corpuscles.

**Valves.**—The lymphatic and lacteal vessels are furnished with valves serving the same office as those of the veins, and for the most part constructed after the same fashion. They generally consist of two semilunar folds arranged in the same way as in the valves of veins already described, but deviations from the usual structure here and there occur.

Valves are not present in all lymphatics, but where they exist they follow one another at much shorter intervals than those of the veins, and give to the lymphatics, when much distended, a beaded or jointed appearance. Valves are placed at the entrance of the lymphatic trunks into the great veins of the neck. They are generally wanting in the reticularly arranged vessels which compose the plexuses of origin already spoken of; so that fluid injected into one of these vessels runs in all directions, so as to fill a greater or a less extent of the plexus, and passes along the separate vessels which issue from it.

The lymphatics of fish and naked amphibia are, generally speaking, destitute of valves, and may therefore be injected from the trunks; in the turtle a few valves are seen on the larger lacteals which pass along the mesentery, but none on those upon the coats of the intestine; and valves are much less numerous in the lymphatics and lacteals of birds than in those of mammiferous animals.

**Orifices.**—It was at one time a prevalent opinion among anatomists that the lymphatic and lacteal vessels begin on various surfaces by open mouths, through which extraneous matters are absorbed. This was especially insisted on as regards the commencing lacteals in the intestinal villi. That opinion has been since given up; but more



recently satisfactory evidence of openings in the lymphatics on the surface of the serous membranes has been obtained. Recklinghausen stretched the tendinous centre of the diaphragm, excised from a rabbit, over a ring of cork, covered it with a film of milk, and then, watching it with the microscope, saw the milk-globules at various points drawn down as if in a vortex, and disappearing. He then

Fig. 127.

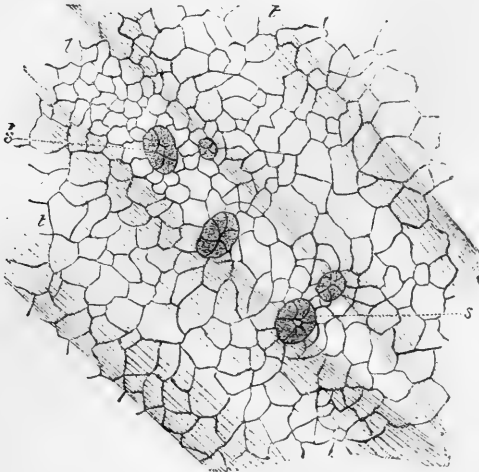


Fig. 127.—SMALL PORTION OF PERITONEAL SURFACE OF DIAPHRAGM OF RABBIT (Klein).  
MAGNIFIED.

*l*, lymph channel below the surface, lying between tendon bundles, *t, t*, and over which the surface-cells are seen to be relatively smaller, and to exhibit five stomata, *S, S'*, leading into the lymphatic. The epithelioid cells of the lymphatic channel are not represented.

found they had passed into the lymphatics of the peritoneal covering of the diaphragm, by small openings, not more than twice the diameter of a blood-corpuscle, over which the epithelioid layer of the peritoneum was similarly perforated. Observations in confirmation of these were made in the Physiological Institute of Leipsic, under the direction of Professor Ludwig, by Dybkowski, who found apertures (answering very nearly to those described by von Recklinghausen) on the dog's pleura, by which the superficial lymphatics open on the surface of the membrane; he also found that fine particles of colouring matter could, under certain conditions, be made to pass from the cavity of the pleura into the lymphatics, and apparently by the openings in question. Similar communications were found by Schweigger-Seidel and Dogiel between the frog's peritoneum and the great lymph-sac (cisterna magna) behind it.

These apertures, or *stomata*, have been more recently investigated by Klein,\* who has further found them in the omentum of mammals. They are surrounded by a ring of small granular

\* The Lymphatic System, Part I. : The Anatomy of Serous Membranes. London, 1873.

cubical cells, and the larger flattened epithelioid cells of the serous membrane are arranged in a somewhat radiated manner in the neighbourhood of the orifice. When the lymphatic is superficial, it may communicate directly with the surface of the membrane; in other cases a short straight canal, lined with cells similar to those bounding the orifice, leads from the vessel to the surface. A curious fact has been pointed out by the same observer, viz., that in *female* frogs and toads the cells lining these short lymphatic canals are furnished with vibratile cilia.

**Termination.**—The absorbent system discharges its contents into the veins at two points, namely, at the junction of the subclavian and internal jugular veins of the left side by the thoracic duct, and at the corresponding part of the veins of the right side by the right lymphatic trunk. The openings, as already remarked, are guarded by valves. It sometimes happens that the thoracic duct divides, near its termination, into two or three short branches, which open separately, but near each other; more rarely, a branch opens into the vena azygos—indeed the main vessel has been seen terminating in that vein. Again it is not uncommon for larger branches, which usually join the thoracic duct, to open independently in the vicinity of the main termination; and this is more apt to happen with the branches which usually unite to form the right lymphatic trunk. By such variations the terminations in the great veins are multiplied, but still they are confined in man to the region of the neck; in birds, reptiles, and fish, on the other hand, communications take place between the lymphatics of the pelvis, posterior extremities and tail, and the sciatic or other considerable veins of the abdomen or pelvis.

The alleged terminations of lymphatics in various veins of the abdomen, described by Lippi as occurring in man and mammalia, have not been met with by those who have since been most engaged in the prosecution of this department of anatomical research, and accordingly his observations have generally been either rejected as erroneous, or held to refer to deviations from the normal condition. Nuhn, of Heidelberg, affirms the regular existence of these abdominal terminations, and refers to three instances which he met with himself. In two of these the lymphatics opened into the renal veins, and in the other into the vena cava.\*

**Lymphatic hearts.**—Müller and Panizza, nearly about the same time, but independently of each other, discovered that the lymphatic system of reptiles is furnished, at its principal terminations in the venous system, with pulsatile muscular sacs, which serve to discharge the lymph into the veins. These organs, which are named lymph-hearts, have now been found in all the different orders of reptiles. In frogs and toads two pairs have been discovered, a posterior pair, situated in the sciatic region, which pour their lymph into a branch of the sciatic or of some other neighbouring vein, and an anterior more deeply-seated pair, placed over the transverse process of the third vertebra, and opening into a branch of the jugular vein. The parietes of these sacs are thin and transparent, but contain muscular tissue, which here and there appears obscurely striated, decussating in different layers, as in the blood-heart. In their pulsations they are quite independent of the latter organ, and are not even synchronous with each other. In salamanders, lizards, serpents, tortoises, and turtles, only a posterior pair have been discovered, which, however, agree in all essential points with those of the frog. In the goose, and in other species of birds belonging to different orders, Panizza discovered a pair of lymph-sacs opening into the sacral veins, and Stannius has since found that these sacs have striated muscular

\* Müller's Archiv, 1848, p. 173.

fibres in their parietes. Nerve-fibres, both dark-bordered and pale, have been observed in the lymph-hearts of the frog, and also nerve-cells in those of the common tortoise (Waldeyer).

**Development of lymphatic vessels.**—The development of lymphatic capillaries has been studied by Klein in the serous membranes, both normal and chronically inflamed. He finds that the process is similar to that of the development of blood-vessels as described by him in the chick. A vacuole is formed within one of the cells of the connective tissue, and becomes larger and larger, so as to produce a cavity filled with fluid, and with the protoplasm of the cell thinned out to form the wall of the vesicle thus formed. From this protoplasmic wall portions bud inwards into the cavity, eventually becoming detached as lymph-corpuscles. Meanwhile the nucleus of the cell has become multiplied, and the resulting nuclei are regularly arranged in the protoplasmic wall, which now exhibits, on treatment with nitrate of silver, the well-known epithelioid marking characteristic of the lymphatic capillaries. To form vessels, these vesicles become connected with one another by means of processes into which their cavities extend.\*

Kölliker has observed the formation of lymphatics from ramified cells in the tails of young salamander-larvæ. He states that the process takes place nearly in the same manner as in the case of sanguiferous capillaries; the only notable difference being, that whilst the growing lymphatics join the ramified cells, and thus extend themselves, their branches very rarely anastomose or become connected by communicating arches.

#### LYMPHATIC GLANDS.

**Lymphatic glands**, named also *conglobate glands*, and by modern French writers *lymphatic ganglions*, are small solid bodies placed in the course of the lymphatics and lacteals, through which the contents of these vessels have to pass in their progress towards the thoracic or the right lymphatic duct. These bodies are collected in numbers along the course of the great vessels of the neck, also in the thorax and abdomen, especially in the mesentery and alongside the aorta, vena cava inferior, and iliac vessels. A few, usually of small size, are found on the external parts of the head, and considerable groups are situated in the axilla and groin. Some three or four lie on the popliteal vessels, and usually one is placed a little below the knee, but none farther down. In the arm they are found as low as the elbow joint.

Lymphatic vessels may pass through two, three, or even more lymphatic glands in their course, whilst, on the other hand, there are lymphatics which reach the thoracic duct without encountering any gland in their way.

The size of these bodies is very various, some being not much bigger than a hempseed, and others as large or larger than an almond or a kidney bean. In shape, too, they present differences, but most of them are round or oval.

\* The cells lining these lymphatic vesicles, which are common in the mesogastrium of the frog and toad in the winter season (owing to the existence of slight chronic inflammation, a condition exceedingly prone to further the development of the lymphatic tissues), bear, in the female of those animals, cilia directed inwards towards the cavity of the vesicles. As the development into vessels proceeds, the cilia disappear (Klein). Remak, who first noticed these ciliated vesicles, took them for cysts in the membrane.

The lymphatics or lacteals which enter a gland are named inferent or afferent vessels (*vasa inferentia* seu *afferentia*), and those which issue from it efferent vessels (*vasa efferentia*). The afferent vessels (fig. 128,

Fig. 123.

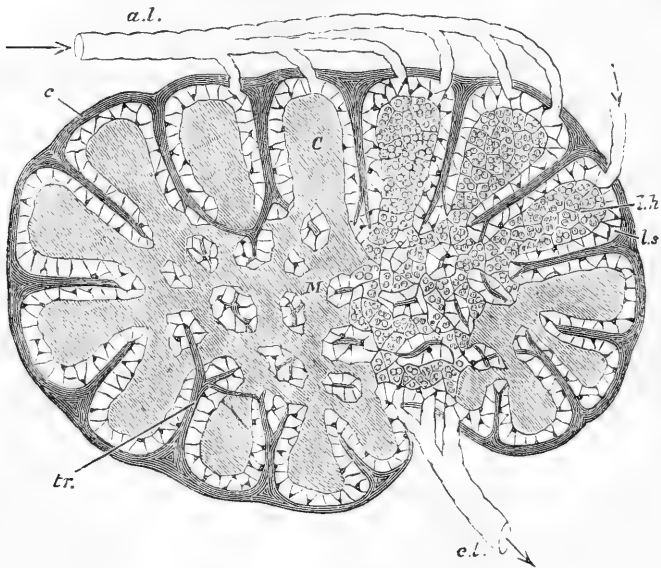


Fig. 123.—DIAGRAMMATIC SECTION OF LYMPHATIC GLAND.

*a, l*, afferent; *e, l*, efferent lymphatics. *C*, cortical substance. *M*, reticulating cords of medullary substance. *l, s*, lymph-sinus; *c*, fibrous coat sending trabeculae, *tr*, into the substance of the gland.

*a, l*), on approaching a gland, divide into many small branches, which enter the gland; the efferent vessels commonly leave the gland in form of small branches, and at a little distance beyond it, or sometimes even before issuing from it, unite into one or more trunks (*e, l*), usually larger in size but fewer in number than those of the afferent vessels.

The internal structure of lymphatic glands has been long a subject of inquiry. Hewson considered that a lymphatic gland essentially consists of a network of finely-divided lymphatic vessels, on and between which capillary blood-vessels are ramified; the whole being gathered up and compacted into a comparatively dense mass by connective tissue, which at the surface of the gland forms for it an enclosing capsule. The afferent and efferent vessels are, according to Hewson, continuous with each other within the gland, and the cellular cavities described as intervening between them and serving as the medium of their communication, were held by him to be nothing more than partial dilatations of some branches of the common connecting plexus.

Hewson's view of the constitution of the lymphatic glands was, until lately, accepted by most anatomists; but modern researches have shown that the structure of these bodies is more complex. The fol-

lowing account is founded chiefly on the descriptions of His and Kölliker.

A lymphatic gland is covered externally with a coat (fig. 128, *c*, 129, *d*) composed of connective tissue, mixed in certain animals, with muscular fibre-cells. This coat or capsule is complete, except at the part where it gives passage to the efferent lymphatics and the larger blood-vessels; and this part of the gland, which often presents a depression or fissure, may be named the *hilus* (fig. 128, 129 *a*). The proper substance of the gland consists of two parts, the *cortical* (*c*), and within this the *medullary*. The cortical part occupies all the superficial part of the gland, except the hilus, and in the larger glands may attain a thickness of from two to three lines. The medullary portion occupies the centre, and extends to the surface at the hilus. It is best marked in the inwardly-seated glands, such as the lumbar and mesenteric, whilst in the subcutaneous glands it is more or less encroached upon by a core of connective tissue (*hilus-stroma*, His), which enters with the larger blood-vessels at the hilus, and surrounds them, together with the lymph-vessels, in the centre of the gland, so that the medullary part is reduced to a layer of no great thickness bounding inwardly the cortical part.

Throughout both its cortical and medullary part the gland is pervaded by a trabecular frame-work which incloses and supports the proper glandular substance. The trabeculae pass inwards from the capsule (fig. 128). They consist, in the ox, chiefly of plain muscular tissue; in man, of connective tissue, sparingly intermixed with muscular fibre-cells. In the cortical part they are mostly lamellar in form, and divide the space into small compartments, *alveoli*, from  $\frac{1}{60}$  to  $\frac{1}{24}$  of an inch wide, which communicate laterally with each other through openings in the imperfect partitions between them (fig. 130 A). On reaching the medullary part the trabeculae take the form of flattened bands or cords, and by their conjunction and reticulation form a freely intercommunicating meshwork throughout the interior. (In the figures they are represented mostly as cut across.) In these alveoles and meshes is included the proper *glandular substance*, which appears as a tolerably firm pulp or parenchyma, agreeing in nature with lymphoid tissue. In the alveoli of the cortical part this forms rounded nodules (fig. 128 *c*, 130 A *d*); in the trabecular meshes of the medullary part it takes the shape of rounded cords (*lymphoid cords*) joining in a corresponding network (figs. 128, M; 130, B, *d*); and, as the containing meshes communicate, so the contained gland-pulp is continuous throughout. But both in the cortical alveoles and the medullary trabecular meshes, a narrow space, left white in the figs. (128 *l, s*; 130, *l, l*) is left all round the gland-pulp, between it and the alveolar partitions and trabecular bands, like what would be left had the pulp shrunk away from the

Fig. 129.

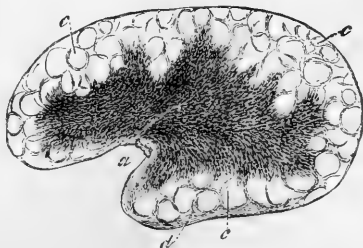


Fig. 129.—SECTION OF A MESENTERIC GLAND FROM THE OX, SLIGHTLY MAGNIFIED.

*a*, hilus; *b*, medullary substance; *c*, cortical substance with indistinct alveoli; *d*, capsule (after Kölliker).

inside of a mould in which it had been cast. This space is both a receptacle and a channel of passage for the lymph that goes through the

Fig. 130.

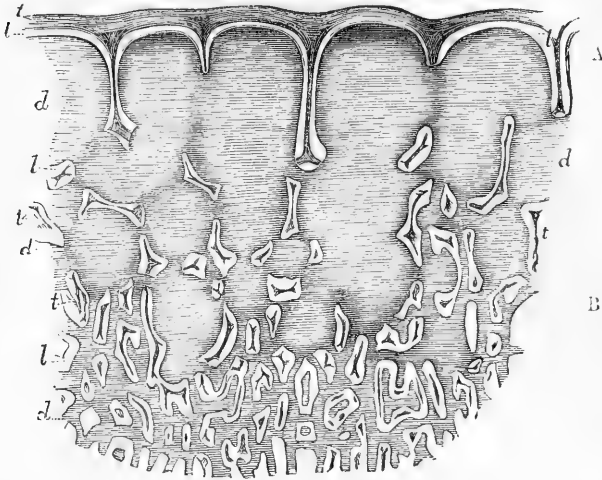


Fig. 130.—SECTION OF A MESENTERIC GLAND OF THE OX (magnified 12 diameters).

The section includes a portion of the cortical part, A, in its whole depth, and a smaller portion of the adjoining medullary part, B; *c, c*, outer coat or capsule sending partitions into the cortical part to form alveoli, and trabeculae, *t, t*, which are seen mostly cut across; *d, d*, the glandular substance forming nodules in the cortical part, A, and reticulating cords in the medullary part, B; *l, l*, lymph-sinus or lymph-channel, left white (after His).

gland; it is the *lymph-sinus* (His), or the *lymph-channel*. It is traversed by retiform connective tissue (fig. 131 *c, c*), in which the nuclei of the spindle-shaped or ramified cells are mostly apparent, and is filled with fluid lymph, containing many lymph-corpuscles, which may be washed out from sections of the gland with a hair pencil, so as to show the sinus, while the firmer gland-pulp, which the sinus surrounds, keeps its place. The latter, the proper glandular substance, is also pervaded and supported by retiform tissue, mostly non-nucleated (fig. 131, *a*), communicating with that of the surrounding lymph-sinus, but marked off from it by somewhat closer reticulation at their mutual boundary, not so close, however, as to prevent fluids, or even solid corpuscles, from passing from the one to the other. This glandular pulp is made up of densely packed lymph-corpuscles, occupying the interstices of its supporting retiform tissue, and is traversed by an abundant network of capillary blood-vessels (*d, d*), which runs throughout the proper glandular pulp, both cortical and medullary, but does not pass into the surrounding lymph-sinus. The stellate cells of the retiform tissue of the lymph-sinus often contain a considerable number of pigment granules. Arteries enter and veins leave the gland at the hilus, surrounded, in some glands, as already said, with a dense inclosure of connective tissue. The arterial branches go in part directly to the glandular substance, but partly run along the trabeculae. The former end in the glandular capillary network above-mentioned, from which

the veins begin, and tend to the hilus alongside the arteries. The branches which run along the trabeculæ are in part conducted to the

Fig. 131.

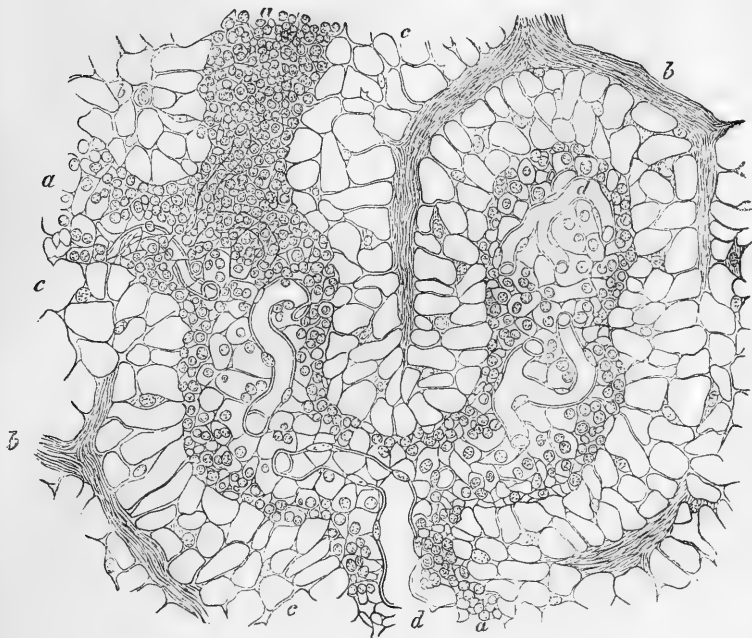


Fig. 131.—SECTION OF THE MEDULLARY SUBSTANCE OF A LYMPHATIC GLAND (Ox).  
300 DIAMETERS. (Von Recklinghausen).

*a, a, a*, follicular or lymphoid cords; *c*, lymph-sinus; *b, b*, trabeculæ; *d, d*, blood-vessels.

coat of the gland to be there distributed; some of their branches pass across the lymph-sinus to reach the glandular substance. The blood-vessels of the gland pulp are supported by its pervading retiform tissue, which is not only connected to them, but forms an additional or adventitious coat round their small branches, and even on some of the capillaries (page 178).

As to the lymphatics of the gland, it seems to be tolerably well made out, that the afferent vessels, after branching out upon and in the tissue of the capsule, send their branches through it to open into the lymph-sinuses of the cortical alveoli, and that the efferent lymphatics begin by fine branches leading from the lymph-sinuses of the medullary part, and forming at the hilus a dense plexus of tortuous and varicose-looking vessels, from which branches proceed to join the larger efferent trunks. The lymph-sinus, therefore, forms a channel for the passage of the lymph, interposed between the afferent and efferent lymphatics, communicating with both, and maintaining the continuity of the lymph-stream. The afferent and efferent vessels, where they open into the lymph-sinus, lay aside all their coats, except the epithelioid lining, which is continued

over the trabeculæ ; covering these, like the walls of the commencing lymph-lacunæ elsewhere, with a layer of flattened cells.

It is not unreasonable to presume that, in the proper glandular substance, there is a continual production of lymph-corpuscles, most probably by fissiparous multiplication, which pass into the lymph-sinus, and that fresh corpuscles are thus added to the lymph as it passes through a gland ; and this view is supported by the fact, that the corpuscles are found to be more abundant in the lymph or chyle after it has passed through the glands. It has been alleged, moreover, that the lymph, after passing the glands, is richer in fibrin, and therefore coagulates more firmly. In any case, it is plain that the numerous blood-capillaries distributed in a gland must bring the blood into near relation with the elements of the lymph ; and the latter fluid, as it must move very slowly through the relatively wide space within the gland, is thus placed in a most favourable condition for some not improbable interchange of material with the blood.

### SEROUS MEMBRANES.

The serous membranes are so named from the apparent nature of the fluid with which their surface is moistened. They line cavities of the body which have no outlet, and the chief examples of them are, the peritoneum, the largest of all, lining the cavity of the abdomen ; the two pleuræ and pericardium in the chest ; the arachnoid membrane in the cranium and vertebral canal ; and the tunica vaginalis surrounding each of the testicles within the scrotum.

**Form and arrangement.**—In all these cases the serous membrane has the form of a closed sac, one part of which is applied to the walls of the cavity which it lines, the *parietal* portion ; whilst the other is reflected over the surface of the organ or organs contained in the cavity, and is therefore named the *reflected* or *visceral* portion of the membrane. Hence the viscera in such cavities are not contained within the sac of the serous membrane, but are really placed behind or outside of it ; merely pushing inwards, as it were, the part of the membrane which immediately covers them, some organs receiving in this way a complete, and others but a partial and sometimes very scanty investment.

In passing from one part to another, the membrane frequently forms folds which in general receive the appellation of ligaments, as, for example, the folds of peritoneum passing between the liver and the parietes of the abdomen, but which are sometimes designated by special names, as in the instances of the mesentery, meso-colon, and omentum.

The peritoneum, in the female sex, is an exception to the rule that serous membranes are perfectly closed sacs, inasmuch as it has two openings by which the Fallopian tubes communicate with its cavity.

A serous membrane sometimes lines a fibrous membrane, as where the arachnoid lines the dura mater, or where the serous layer of the pericardium adheres to its outer or fibrous part. Such a combination is often named a *fibro-serous* membrane.

The inner surface of a serous membrane is free, smooth, and polished ; and, as would occur with an empty bladder, the inner surface of one part of the sac is applied to the corresponding surface of some other part ; a small quantity of fluid, usually not more than merely moistens the contiguous surfaces, being interposed. The parts situated in a cavity lined by serous membrane can thus glide easily against its



parietes or upon each other, and their motion is rendered smoother by the lubricating fluid.

The outer surface most commonly adheres to the parts which it lines or covers, the connection being effected by means of areolar tissue, named therefore "subserous," which, when the membrane is detached, gives to its outer and previously adherent surface a flocculent aspect. The degree of firmness of the connection is very various: in some parts, the membrane can scarcely be separated; in others, its attachment is so lax as to permit easy displacement. The latter is the case in the neighbourhood of the openings through which abdominal herniæ pass; and accordingly, when such protrusions of the viscera happen to take place, they usually push the peritoneum before them in form of a hernial sac.

The visceral portion of the arachnoid membrane is in some measure an exception to the rule of the outer surface being everywhere adherent; for, in the greater part of its extent, it is thrown loosely round the parts which it covers, a few fine fibrous bands being the sole bond of connection; and a quantity of pellucid fluid is interposed, especially in the vertebral canal and base of the cranium, between the arachnoid and the pia mater, which is the membrane immediately investing the brain and spinal cord.

**Structure and properties.**—Serous membranes are thin and transparent, so that the colour of subjacent parts shines through them. They are tolerably strong, with a moderate degree of extensibility and elasticity. They are lined on the inner surface by a simple epithelioid layer of flattened cells (fig. 132), each of which contains a clear, round or oval nucleus with one or two nucleoli. The outlines of the cells may readily

Fig. 132.

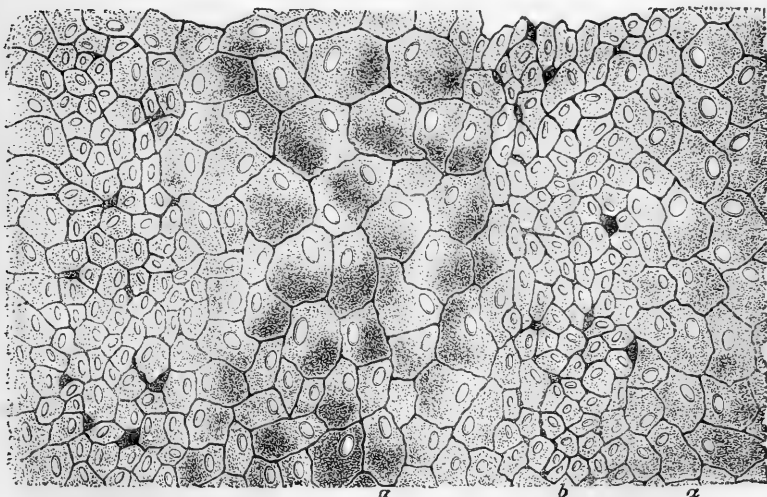


Fig. 132.—PORTION OF EPITHELIOID LAYER OF PERITONEUM FROM DIAPHRAGM OF RABBIT (Klein.)

*a*, larger cells *b*, smaller ones, with here and there a pseudostoma between.

be brought into view by treatment with nitrate of silver. The lines of junction of the cells which are thus made evident, may be straight and even, but are most commonly slightly jagged or sinuous. Here and there between the cells apertures are to be seen, which are of two kinds. The smaller of these, which are also the more numerous, are occupied by processes which are sent up to the surface of the membrane from deeper lying cells (pseudostomata, fig. 132): the larger, on the other hand, the stomata, are true apertures, which are surrounded by a ring of small cubical cells (fig. 127 *s, s'*, page 189), and open into a subjacent lymphatic vessel, either directly or by the medium of a short canal lined with similar cells, as already mentioned in treating of lymphatics. The surface cells of the serous membrane are not everywhere uniform in size (see figs. 127 and 132), but patches are here and there met with in which they are smaller and more granular in appearance. It is not unfrequent also to find evidences of proliferation, especially in the neighbourhood of the stomata and pseudostomata, cells being met with containing two or even many nuclei (Klein).

The substance of the membrane underneath the epithelioid layer is composed of a connective tissue ground substance in which are a variable amount of fibres, both white and elastic; the former, when there are two or more strata, take a different direction in the different planes; the latter unite into a network, and, in many serous membranes, as remarked by Henle, are principally collected into a reticular layer near the surface. The ground substance contains the blood-vessels and lymphatics of the membrane, as well as a large number of flattened connective tissue corpuscles with their corresponding cell-spaces (fig. 133), which are often collected into epithelioid patches. In parts of the membrane in which these corpuscles are more thinly scattered, they possess branching processes, some of which intercommunicate with those of neighbouring cells, whilst others, as before said, pass up to the surface of the membrane (pseudostomata), and others again, become connected to the walls of the lymphatics and blood-vessels (see fig. 126, p. 187).

**Blood-vessels** ending in a capillary network with comparatively wide meshes pervade the subserous tissue and the tissue of the serous membrane.

The **lymphatics** of the serous membranes are exceedingly abundant. Their relation both to the cell-spaces of the tissue and to the surface of the membrane, as well as their general arrangement, has been already noticed (pp. 186—191). They are sometimes met with ensheathing the blood-vessels.

Nodules occur here and there in the substance of the serous membranes which consist of a close network of branched connective tissue-cells amongst which are a number of lymphoid cells or leucocytes, similar to the pale corpuscles of the blood. These nodules, the larger of which have a rich supply of blood-vessels, are developed in connection with the lymphatics, being formed either around those vessels, or actually within them, in which case the cells forming the walls of the lymphatic vessel exhibit processes which project into the interior and join with the enclosed retiform tissue. The cells of this tissue are in fact developed by a proliferation of the flattened cells of the lymphatic, which is of course considerably enlarged at these spots. These lymphatic nodules (peri and endo-lymphangial nodules of Klein)

possess, as do the stomata of the surface, both true and false, considerable importance in a pathological point of view, for it is in connection

Fig. 133.

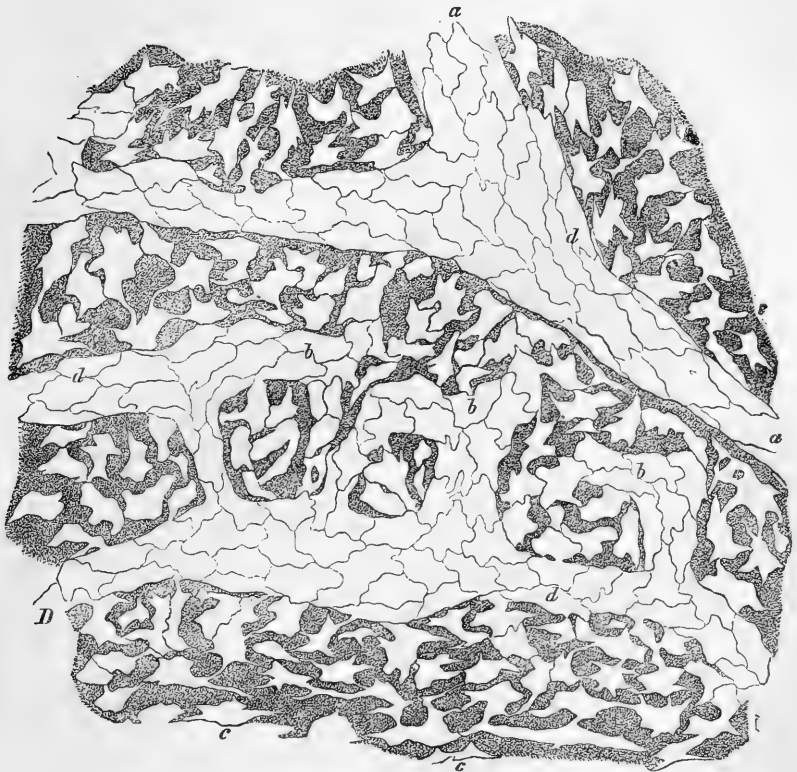


Fig. 133. — PORTION OF SEROUS MEMBRANE OF DIAPHRAGM (PLEURAL) FROM THE RABBIT, TREATED WITH NITRATE OF SILVER AFTER REMOVAL OF SUPERFICIAL EPITHELIOID LAYER. (Recklinghausen.)

*c, c*, cell-spaces of tissue ; *d, d*, commencing lymphatic vessels connected at *b, b*, with the cell-spaces.

with them that proliferation is apt to occur in chronic inflammation of the serous membranes.

The **nerves** of the serous membranes are destined chiefly for the blood-vessels, and for the most part accompany these in their course. A few pale fibres, however, are distributed to the substance of the membrane, in which they form a plexus with large meshes : from the branches of this, fibrils may be traced which unite into a somewhat finer plexus near the surface.

**Fluid.**—The internal surface of serous cavities is moistened and lubricated with a transparent and nearly colourless fluid, which in health exists only in a very small quantity. This fluid, which is doubtless derived from the blood-vessels of the membrane, has been commonly represented as similar in constitution to the serum of the blood. But it was long since remarked by Hewson (and a similar opinion seems to have been held by Haller and Monro), that the fluid obtained

from the serous cavities of recently killed animals coagulates spontaneously, and thus resembles the lymph of the lymphatic vessels, and, we may add, the liquor sanguinis or plasma of the blood, the coagulation being, of course, due to the presence of fibrin, or of its two constituents fibrinogen and para-globulin. Hewson, who regarded the fluid as lymph, found that the coagulability diminished as the quantity increased. Hewson made his observations on the fluid of the peritoneum, pleura and pericardium, in various animals, viz., bullocks, dogs, geese and rabbits.

When the fluid gathers in unusual quantity as in dropsies, it rarely coagulates spontaneously on being let out; but will often yield a coagulum on the addition of para-globulin as already stated. From this it may be inferred that fibrinogen is present, but not the para-globulin requisite to generate fibrin.

The identity in character of the fluid of serous cavities and the lymph-plasma is, it need scarcely be remarked, in keeping with the notion of their being great lymph-spaces in open connection with lymphatic vessels. But this view is quite reconcilable with the mechanical purpose commonly ascribed to these membranes, of lubricating and facilitating the movement of mutually opposed surfaces.

When a serous membrane is inflamed, it has a great tendency to throw out coagulable lymph (or fibrin) and serum, the two constituents of the blood-plasma, the former chiefly adhering to the inner surface of the membrane, whilst the latter gathers in its cavity. The coagulable lymph spread over the surface, in form of a "false membrane," as it is called, or agglutinating the opposed surfaces of the serous sac and causing adhesion, becomes pervaded by blood-vessels, and in process of time converted into areolar tissue.

Breaches of continuity in these membranes are readily repaired, and the newly formed portion acquires all the characters of the original tissue.

### SYNOVIAL MEMBRANES.

Resembling serous membranes in some respects, the synovial membranes are distinguished by the nature of their secretion, for this is a viscid glairy fluid resembling the white of an egg, named *synovia*.

These membranes surround the cavities of joints, and are found in connection with moving parts in certain other situations; their secretion being in all cases intended to lessen friction, and thereby facilitate motion.

The different synovial membranes of the body are referred to three classes, viz., *articular*, *vesicular*, and *vaginal*.

**1. Articular synovial membranes,** or *Synovial capsules of joints*.—These by their synovial secretion lubricate the cavities of the diarthrodial articulations, that is, those articulations in which the opposed surfaces glide on each other. In these cases the membrane may be readily seen covering internally the surface of the capsular and other ligaments which bound the cavity of the joint, and affording also an investment to the tendons or ligaments which happen to pass through the articular cavity, as in the instance of the long tendon of the biceps muscle in the shoulder-joint. On approaching the articular cartilages the membrane does not pass over these, but terminates after advancing but a little way on their surface, with which it is here firmly adherent. So that, it will be seen, the synovial membranes do not form closed bags lying between the articular cartilages as was supposed by the older anatomists, for the main part of the surfaces of the joints are not covered at all by the membrane, nor even by a layer of epithelioid cells, prolonged from the membrane, as some have supposed.

In several of the joints, folds of the synovial membrane, often containing more or less fat, pass across the cavity; these have been called synovial or mucous ligaments. Other processes of the membrane simply project into the cavity at

various points. These are very generally cleft into fringes at their free border, upon which their blood-vessels, which are numerous, are densely distributed. They often contain fat, and then, when of tolerable size, are sufficiently obvious; but many of them are very small and inconspicuous. The fringed vascular folds of the synovial membrane were described, by Dr. Clopton Havers (1691), under the name of the *mucilaginous glands*, and he regarded them as an apparatus for secreting synovia. Subsequent anatomists, while admitting that, as so many extensions of the secreting membrane, these folds must contribute to increase the secretion, have, for the most part, denied them the special character of glands, considering them rather in the light of a mechanical provision for occupying spaces which would otherwise be left void in the motion of the joints, and this view is no doubt right as regards the larger, fat-including folds. The smaller and less obvious fringes have, however, been found, on investigation by Rainey, to be most probably secreting organs as originally supposed by Havers. Rainey found that the processes in question exist in the bursal and vaginal synovial membranes as well as in those of joints, wherever, in short, synovia is secreted. He states that their blood-vessels have a peculiar convoluted arrangement, differing from that of the vessels of fat, and that the layer of cells covering them, "besides including separately each packet of convoluted vessels, sends off from each tubular sheath secondary processes of various shapes, into which no blood-vessels enter."\*

**2. Vesicular or Bursal synovial membranes, *Synovial bursa*, *Bursæ mucosæ*.**—In these the membrane has the form of a simple sac, interposed, so as to prevent friction, between two surfaces which move upon each other. The synovial sac in such cases is flattened and has its two opposite sides in apposition by their inner surface, which is free and lubricated with synovia, whilst the outer surface is attached by areolar tissue to the moving parts between which the sac is placed.

In point of situation, the bursæ may be either deep-seated or subcutaneous. The former are for the most part placed between a muscle or its tendon and a bone or the exterior of a joint, less commonly between two muscles or tendons: certain of the bursæ situated in the neighbourhood of joints not unfrequently open into them. The subcutaneous bursæ lie immediately under the skin, and are found in various regions of the body interposed between the skin and some firm prominence beneath it. The large bursa situated over the patella is a well-known example of this class, but similar though smaller bursæ are found also over the olecranon, the malleoli, the knuckles, and various other prominent parts. It must, however, be observed that, among these subcutaneous bursæ, some are reckoned which do not always present the characters of true synovial sacs, but look more like mere recesses in the subcutaneous areolar tissue, larger and more defined than the neighbouring areolæ, but still not bounded by an evident synovial membrane. These may be looked on as examples of less developed structure, forming a transition between the areolar tissue and perfect synovial membrane.

**3. Vaginal synovial membranes or *Synovial sheaths*.**—These are intended to facilitate the motion of tendons as they glide in the fibrous sheaths which bind them down against the bones in various situations. The best-marked examples of such fibrous sheaths are to be seen in the hand and foot, and especially on the palmar aspect of the digital phalanges, where they confine the long tendons of the flexor muscles. In such instances one part of the synovial membrane forms a lining to the osseo-fibrous tube in which the tendon runs, and another part affords a

\* Proceedings of the Royal Society, May 7th, 1846.

close investment to the tendon. The space between these portions of the membrane is lubricated with synovia and crossed obliquely by one or more folds or duplications of the membrane, in some parts inclosing elastic tissue (Marshall). These are named "fræna," and pass from one part of the membrane to the other.

**Structure of synovial membranes.**—The synovial membranes are composed essentially of connective tissue with blood-vessels and nerves. It was formerly stated that they were lined with an epithelioid layer of flattened cells, similar to those lining the serous membranes, but, as was shown by Hüter, there exists on the synovial membranes no complete lining of the kind. Patches of cells may, it is true, here and there be met with which present an epithelioid appearance (fig. 134, *e*), as, indeed, we know to be the case in the connective tissue of other parts; but most of the surface-cells of the synovial membranes are of the irregularly-branched type (fig. 134, *s*), the surface of the membrane between the cells and sometimes also over them being formed by the ground substance of the connective tissue, whilst here and there small blood-vessels come to the surface from

Fig. 135.

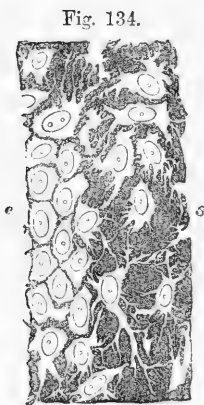


Fig. 134.

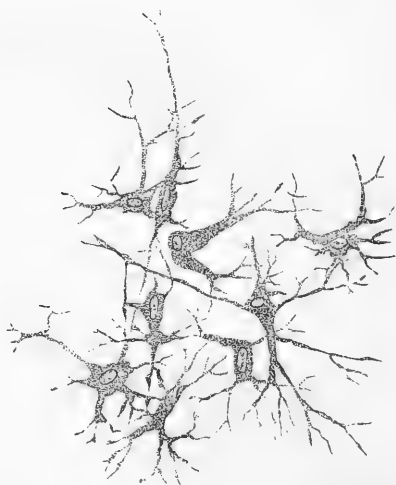

Fig. 134.—CELL-SPACES FROM SYNOVIAL SURFACE OF TENDON (HUMAN). 340 DIAMETERS.  
*e*, part of an epithelioid patch; *s*, more isolated, branched cell-spaces. The nuclei of the cells are faintly indicated.

Fig. 135.—CONNECTIVE-TISSUE CORPUSCLES FROM ARTICULAR SYNOVIAL MEMBRANE OF OX. MAGNIFIED 250 DIAMETERS.

the subjacent parts. The cells and cell-spaces of the synovial membrane are at many places considerably smaller than those of the connective tissue generally: this is owing to a scantiness in the amount of protoplasm, the nuclei being of the usual size and often appearing almost to fill the body of the cell. Sometimes the cell-spaces with

their offsets form a close network of anastomosing channels which, as Reijher has proved,\* are occupied by cell-protoplasm (fig. 135). Such networks are met with more frequently in some animals (ox) than in man.

The cells of the vaginal synovial membrane are often slightly elongated in the direction of the axis of the tendon.

The articular synovial membranes pass, as before said, a certain

Fig. 136.

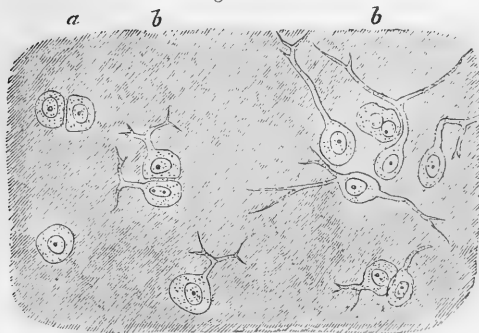


Fig. 136.—TRANSITION OF CARTILAGE CELLS INTO CONNECTIVE TISSUE CORPUSCLES OF SYNOVIAL MEMBRANE. ABOUT 340 DIAMETERS. FROM HEAD OF METATARSAL BONE, HUMAN.

*a*, ordinary cartilage cells; *b*, *b*, with branched processes.

distance over the cartilages of the joints.

They do not, however, end abruptly, but shade off gradually into the surface layer of cartilage, the fibrous tissue disappearing and the cells gradually losing their processes and becoming transformed into cartilage cells (fig. 136), so that it is difficult to say for certain where the one begins and the other ends. This portion of the synovial membrane, which overlies the edge of the cartilage, is known as the "marginal zone;" it is most marked around the convex heads of the bones, and is especially well seen near the lower margin of the patella (Hüter).

The Haversian folds and fringes, at least the larger ones, agree in general structure with the rest of the tissue of the synovial membrane, (except that, as before remarked, some of them contain fat); their surface layer contains for the most part irregularly stellate cells, except over the fat, where we have occasionally observed a true epithelioid arrangement like that of a serous membrane. The smaller non-vascular secondary fringes of Rainey are minute finger-shaped processes projecting from the margins of the larger ones, and consist for the most part of small rounded cells with granular protoplasm and but little intercellular substance; some of them may contain a few connective tissue fibrils or even one or two cartilage-cells (Kölliker).

**Vessels.**—The blood-vessels in and immediately underneath the membrane are sufficiently manifest in most parts of the joints. They advance but a little way upon the cartilages, forming a vascular zone around the margin of each, named "circulus articuli vasculosus" (W. Hunter), in which they end by loops of vessels dilated at the bent part greatly beyond the diameter of ordinary capillaries (Toynbee). In the foetus, these vessels advance further upon the surface of the cartilage.

The vessels of the vaginal synovial membranes are less numerous than those of the synovial membranes of the joints.

\* Journal of Anatomy and Physiology, May, 1874.

Lymphatic vessels have not hitherto been demonstrated in the synovial membranes.

**Nerves.**—W. Krause describes the nerves of the synovial membranes (at least those of the joints) as terminating in peculiar corpuscles allied to end bulbs. Another observer (Nicoladoni) has traced the nerves into a plexus of pale fibrils lying close under the surface of the membrane.

**Development.**—Reyher describes the development of the synovial membranes as follows:—At the time of the formation of a joint the surrounding tissue becomes changed, so that while its outer part develops into the fibrous capsule of the joint, its inner part forms the commencement of the synovial membrane. The cartilage cells on the surfaces of the newly formed joint are at first placed closely together without matrix or intercellular substance; after a time this appears in fine lines between the cells, so that these, in silvered preparations, now present an epithelioid appearance. By a further development of intercellular substance the superficial cells become more separated from one another, and now possess an irregularly branched shape with communicating processes. Near the edge of the cartilage this condition is permanent, so that the marginal zone of the synovial membrane is formed here *in situ* from what was originally cartilage. More towards the centre of the articular surface, however, a further change takes place in the progress of development, for in these parts the cells lose their processes and acquire the characters of ordinary cartilage cells, whilst at the same time the matrix becomes much increased between them, and forms also a thin layer covering their surface.

**Synovia.**—As already stated, this is a viscid transparent fluid; it has a yellowish or faintly reddish tint, and a slightly saline taste. According to Frerichs, the synovia of the ox consists of 94·85 water, 0·56 mucus and cells, 0·07 fat, 3·51 albumin and extractive matter, and 0·99 salts. If a drop of synovial fluid be examined microscopically, it is found to contain (in addition to fat-molecules) a few amoeboid corpuscles, as well as cells similar to those which occur on the surface of the membrane.

## MUCOUS MEMBRANES.

These membranes, unlike the serous, line internal passages, and other cavities which open on the surface of the body, as well as various recesses, sinuses, gland-ducts and receptacles of secretion, which open into such passages. They are habitually subject to the contact of foreign substances introduced into the body, such as air and aliment, or of various secreted or excreted matters, and hence their surface is coated over and protected by mucus, a fluid of a more consistent and tenacious character than that which moistens the serous membranes.

**Distribution.**—The mucous membranes of several different or even distant parts are continuous, and they may all, or nearly all, be reduced to two great divisions, namely the *gastro-pneumonic* and *genito-urinary*. The former covers the inside of the alimentary and air-passages as well as the less considerable cavities communicating with them. It may be described as commencing at the edges of the lips and nostrils, where it is continuous with the skin, and proceeding through the nose and mouth to the throat, whence it is continued throughout the whole length of the alimentary canal to the termination of the intestine, there again meeting the skin, and also along the windpipe and its numerous divisions as far as the air-cells of the lungs, to which it affords a lining. From the nose the membrane may be said to be prolonged into the lachrymal passages, extending up the nasal duct into the lachrymal sac and along



the lachrymal canals until, under the name of the conjunctival membrane, it spreads over the fore part of the eyeball and inside of the eyelids, on the edges of which it encounters the skin. Other offsets from the nasal part of the membrane line the frontal, ethmoidal, sphenoidal and maxillary sinuses, and from the upper part of the pharynx a prolongation extends on each side along the Eustachian tube to line that passage and the tympanum of the ear. Besides these there are offsets from the alimentary membrane to line the salivary, pancreatic, and biliary ducts, and the gall-bladder. The *genito-urinary* membrane invests the inside of the urinary bladder and the whole tract of the urine in both sexes, from the interior of the kidneys to the orifice of the urethra, also the seminal ducts and vesicles in the male, and the vagina, uterus, and Fallopian tubes in the female.

**Attachment.**—The mucous membranes are attached by one surface to the parts which they line or cover by means of areolar tissue, named “submucous,” which differs greatly in quantity as well as in consistency in different parts. The connection is in some cases close and firm, as in the cavity of the nose and its adjoining sinuses; in other instances, especially in cavities subject to frequent variation in capacity, like the gullet and stomach, it is lax and allows some degree of shifting of the connected surfaces. In such cases as the last-mentioned the mucous membrane is accordingly thrown into folds when the cavity is narrowed by contraction of the exterior coats of the organ, and of course these folds, or *rugæ*, as they are named, are effaced by distension. But in certain parts the mucous membrane forms permanent folds, not capable of being thus effaced, which project conspicuously into the cavity which it lines. The best-marked example of these is presented by the *valvule conniventes* seen in the small intestine. These, as is more fully described in the special anatomy of the intestines, are crescent-shaped duplicatures of the membrane, with connecting areolar tissue between their laminae, which are placed transversely and follow one another at very short intervals along a great part of the intestinal tract. The chief purpose of the *valvulae conniventes* is doubtless to increase the surface of the absorbing mucous membrane within the cavity, and it has also been supposed that they serve mechanically to delay the alimentary mass in its progress downwards. A mechanical office has also been assigned to a series of oblique folds of a similar permanent kind, though on a smaller scale, which exist within the cystic duct.

**Physical properties.**—In most situations the mucous membranes are nearly opaque or but slightly translucent. They possess no great degree of tenacity and but little elasticity, and hence are readily torn by a moderate force. As to colour, they cannot be said intrinsically to have any, and when perfectly deprived of blood they accordingly appear white or at most somewhat grey. The redness which they commonly exhibit during life, and retain in greater or less degree in various parts after death, is due to the blood contained in their vessels, although it is true that, after decomposition has set in, the red matter of the blood, becoming dissolved, transudes through the coats of the vessels, and gives a general red tinge to the rest of the tissue. The degree of redness exhibited by the mucous membranes after death is greater in the foetus and infant than in the adult. It is greater too in certain situations; thus, of the different parts of the alimentary canal, it is most marked in the stomach, pharynx, and rectum. Again, the intensity

of the tint, as well as its extent, is influenced by circumstances accompanying or immediately preceding death. Thus the state of inflammation, or the local application of stimuli to the membrane, such as irritant poisons, or even food in the stomach, is apt to produce increased redness; and all the mucous membranes are liable to be congested with blood and suffused with redness when death is immediately preceded by obstruction to the circulation, as in cases of asphyxia, and in many diseases of the heart.

**Structure.**—A mucous membrane is composed of *corium* and *epithelium*. The *epithelium* covers the surface; it may be scaly and stratified as in the mouth and throat, columnar as in the intestine, or ciliated as in the respiratory tract and uterus. The membrane which remains after removal of the epithelium is named the *corium*, as in the analogous instance of the true skin. The corium may be said to consist of a *fibro-vascular layer*, of variable thickness, bounded superficially or next the epithelium by an extremely fine transparent lamella, named *basement-membrane* by Bowman, and *primary membrane*, *limitary membrane*, and *membrana propria* by others who have described it.

The *basement-membrane* is best seen in parts where the mucous membrane is raised into villous processes, or where it forms secreting crypts or minute glandular recesses, such as those which abound in the stomach and intestinal canal (fig. 137, *b*). On teasing out a portion of the gastric or intestinal mucous membrane under the microscope, some of the tubular glands are here and there discovered which are tolerably well cleared from the surrounding tissue, and their parietes are seen to be formed of a thin pellucid film, which is detached from the adjoining fibro-vascular layer, the epithelium perhaps still remaining in the inside of the tube or having escaped, as the case may be. The fine film referred to is the basement-membrane. It may by careful search be seen too on the part of the corium situated between the orifices of the glands, and on the villi, when the epithelium is detached, although it cannot be there so readily separated from the vascular layer. In these parts it manifestly forms a superficial boundary to the corium, passing continuously over its eminences and into its recesses, defining its surface, and supporting the epithelium. In other parts where villi and tubular glands are wanting, and especially where the mucous membrane, more simply arranged, presents an even surface, as in the tympanum and nasal sinuses, the basement-membrane is absent, or at least not demonstrated.

The basement-membrane, as already said, forms the peripheral boundary of the corium; it is in immediate connection with the epithelium. By its under surface it closely adjoins the fibro-vascular layer, with the retiform tissue, *d*, of which it is in connection. The vessels of the corium advance close up to the basement-membrane, but nowhere penetrate it. In structure the membrane in question seems at first sight perfectly homogeneous, but treatment with nitrate of silver brings to view the outlines of flattened epithelioid connective tissue cells, of which it is in reality composed.\*

The *fibro-vascular layer* of the corium is composed of vessels both sanguiferous and lymphatic, with connective tissue—areolar and reti-

\* In the large intestine of the frog, and perhaps also in some other parts, these cells, instead of adhering by their edges, intercommunicate by processes, so as to form a close network instead of a continuous membrane.

form—and, in many parts, non-striated muscular tissue, variously disposed. The nerves also which belong to the mucous membrane are distributed in this part of its structure ; in some parts, the palate and

Fig. 137.

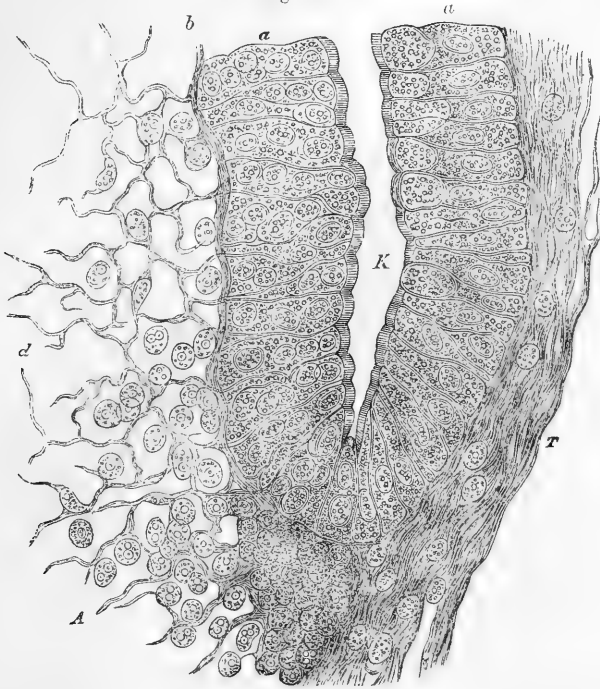

Fig. 137.—TUBULAR GLAND WITH ADJACENT LYMPHOID TISSUE, FROM INTESTINE OF RABBIT (Verson). HIGHLY MAGNIFIED.

K, lumen of gland ; *a, a*, epithelium with thickened striated border ; *d*, lymphoid tissue, from which most of the corpuscles have been removed. Between this and the epithelium is seen the basement-membrane, *b*, in section. *T*, more condensed connective-tissue of the mucous membrane.

vagina for instance, minute branches of the nerves have also been traced extending between and amongst the epithelium cells.

The vessels exist almost universally in mucous membranes. The branches of the arteries and veins, dividing in the submucous tissue, send smaller branches into the corium, which at length form a network of capillaries in the fibro-vascular layer. This capillary network lies immediately beneath the epithelium, or the basement-membrane when this is present, advancing with that membrane into the villi and papillæ to be presently described, and surrounding the tubes and other glandular recesses. The lymphatics also form networks, which communicate with plexuses of larger vessels in the submucous tissue ; their arrangement generally, as well as in the villi, has been already noticed.

The fibres of connective tissue which enter into the formation of the corium are both the white and the elastic. The former are arranged in interlacing bundles, the elastic commonly in networks ; but the amount

of both is very different in different parts. In some situations, as in the gullet, windpipe, bladder, and vagina, the filamentous connective tissue is abundant, and extends throughout the whole thickness of the fibrovascular layer, forming a continuous and tolerably compact web, and rendering the mucous membrane of those parts comparatively stout and tough. In the stomach and intestines, on the other hand, where the membrane is more complex, and at the same time weaker in structure, the elastic fibres are wanting and the white connective tissue is in small proportion; its principal bundles follow and support the blood-vessels, deserting, however, their finer and finest branches which lie next the basement-membrane; and accordingly there exists, for some depth below this membrane, a stratum of the corium in which very few if any filaments of the common areolar tissue are seen. In this stratum of the gastro-enteric mucous membrane, the tubular glands with their lining epithelium are set, and between and around them the numerous sanguiferous capillaries and lymphatic vessels are distributed; but the substance of the membrane in which these parts lie is constructed of retiform connective tissue, which is formed of ramified and reticularly connected corpuscles, with or without nuclei persistent at the points whence the branches divaricate; and in the meshes of this tissue is contained a profusion of granular corpuscles, like those in the lymphatic glands. This structure (fig. 137 and 138 *d*), which prevails in the mucous membrane of the stomach and intestines, both large and small, as well as in some other parts, is named *lymphoid tissue* from its resemblance to the interior tissue of the lymphatic glands, and of other bodies belonging to or supposed to belong to the lymphatic system, and especially those known as the solitary and agminated glands of the alimentary mucous membrane. The tissue forming the last-named bodies, indeed, is often continuous with the lymphoid tissue in their vicinity.

Fig. 133.

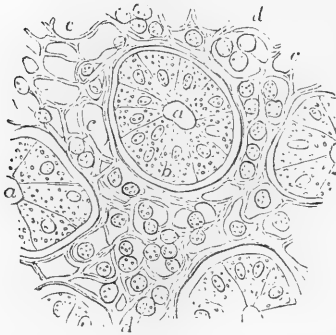


Fig. 133.—LYMPHOID OR RETIFORM TISSUE OF THE INTESTINAL MUCOUS MEMBRANE OF THE SHEEP (from Frey). MAGNIFIED 400 DIAMETERS.

Cross section of a small fragment of the mucous membrane, including one entire crypt of Lieberkühn and parts of several others: *a*, cavity of the tubular glands or crypts; *b*, one of the lining epithelial cells; *c*, the lymphoid or retiform spaces, of which some are empty, and others occupied by lymph-cells as at *d*.

The deepest layer of the mucous membrane is formed usually by non-striated muscular tissue, and is named *muscularis mucosæ*. This lies next to the submucous tissue, and consists of bundles running in many parts both longitudinally and circularly, in others in one of these directions only. Prolongations from it pass up between the glands to be distributed in the villi.

**Papillæ and villi.**—The free surface of the mucous membranes is in some parts plain, but in others is beset with little eminences named papillæ and villi. The *papillæ* are best seen on the tongue; they are small processes of the corium, mostly of a conical or cylindrical figure, containing blood-vessels and nerves, and covered with epithelium. Some are small

The free surface of the mucous membranes is in some parts plain, but in others is beset with little eminences named papillæ and villi. The *papillæ* are best seen on the tongue; they are small processes of the corium, mostly of a conical or cylindrical figure, containing blood-vessels and nerves, and covered with epithelium. Some are small

and simple, others larger and compound or cleft into secondary papillæ. They serve various purposes; some of them no doubt minister to the senses of taste and touch, many appear to have chiefly a mechanical office, while others would seem intended to give greater extension to the surface of the corium for the production of a thick coating of epithelium. The *villi* are most fully developed on the mucous coat of the small intestines. Being set close together like the pile of velvet, they give to the parts of the membrane which they cover the aspect usually denominated "villous." They are in reality little elevations or processes of the superficial part of the corium, covered with epithelium, and containing blood-vessels and lacteals, which are thus favourably disposed for absorbing nutrient matters from the intestine. The more detailed description of the papillæ and villi belongs to the special anatomy of the parts where they occur.

In some few portions of the mucous membrane the surface is marked with fine ridges which intersect each other in a reticular manner, and thus inclose larger and smaller polygonal pits or recesses. This peculiar character of the surface of the membrane, which has been termed "alveolar," is seen very distinctly in the gall-bladder, and on a finer scale in the vesiculæ seminales; still more minute alveolar recesses with intervening ridges may be discovered with a lens on the mucous membrane of the stomach (fig. 139).

**Glands of mucous membranes.**—Many, indeed most, of the glands of the body pour their secretions into the great passages lined by mucous membranes; but there are certain small glands which may be said to belong to the membrane itself, inasmuch as they are found in numbers over large tracts of that membrane, and yield mucus, or special secretions known to be derived from particular portions of the membrane. Omitting local peculiarities the glands referred to may be described as of three kinds, viz. :—

1. *Tubular glands.*—These are minute tubes formed by recesses or inversions of the basement membrane, and lined with epithelium. They are usually placed perpendicularly to the surface, and often very close together, and they constitute the chief substance of the mucous membrane in those parts where they abound, its apparent thickness depending on the length of the tubes, which differs considerably in different regions. The tubes open by one end on the surface; the other end is closed, and is either simple or cleft into two or more branches. The tubular glands are abundant in the stomach, and in the small and large intestines, where they are comparatively short and known as the crypts of Lieberkühn. They exist also in considerable numbers in the mucous membrane of the uterus.

2. *Small compound glands.*—Under this head are here comprehended minute but still true compound glands of the racemose kind, with single branched ducts of various lengths, which open on different parts of the membrane. Numbers of these, yielding a mucous secretion, open into the mouth and windpipe. To the naked eye they have the appearance

Fig. 139.

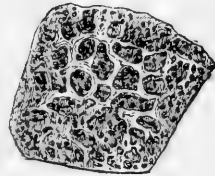


Fig. 139.—PORTION OF MUCOUS MEMBRANE OF THE STOMACH, SLIGHTLY MAGNIFIED. The alveolar pits and small orifices of the tubular glands are seen (after Ecker).

of small solid bodies, often of a flattened lenticular form, but varying much both in shape and size, and placed at different depths below the mucous membrane on which their ducts open. The glands of Brunner, which form a dense layer in the commencing part of the duodenum, are of this kind.

3. *Solitary and agminated glands, conglobate glands* (Henle), *follicular glands* (Kölliker), *lymphoid glands*.—Found in various parts of the alimentary mucous membrane. They may be single (*solitary glands*), or in patches (*agminated glands*), and commonly extend down into the submucous tissue. They are small rounded bodies consisting of fine retiform tissue, supporting radiating blood-capillaries, with lymph-corpuscles in the meshes, and communicating with similar tissue (lymphoid tissue) diffused in the adjacent part of the membrane. Several of these follicles are sometimes placed round a recess of the mucous membrane which opens on the surface, and which may be simple, as in certain glands at the root of the tongue and in the pharynx, or complex and multilocular, as in the tonsils.

These lymphoid follicles, although designated as glands, pour out no secretion on a surface. They are to be regarded as dependencies of the lymphatic system, and as probably concerned in the production of lymph corpuscles. At all events, the lymphatics are extremely abundant in their immediate neighbourhood, and in some places form a kind of sinus closely surrounding the follicle.

The mucous membranes are supplied with nerves, and endowed with sensibility; but the proportion of nerves which they receive, as well as the degree of sensibility which they possess, differs very greatly in different parts. The mode of distribution and termination of these nerves will be dealt with in describing the special anatomy of the parts where they occur.

**Secretion.**—Mucus is a more or less viscid, transparent, or slightly turbid fluid, of variable consistency. It is somewhat heavier than water, though expectorated mucus is generally prevented from sinking in that liquid by entangled air-bubbles. Examined with the microscope, it is found to consist of a fluid, containing solid particles of various kinds, viz., 1. Epithelium particles detached by desquamation; 2. Corpuscles resembling the pale corpuscles of the blood; 3.

Fig. 139\*.

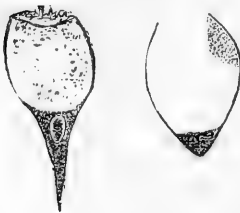

Fig. 139\*.—GLOBET-CELLS FROM TRACHEA OF RABBIT. HIGHLY MAGNIFIED (Klein).

Granules and molecules occasionally. The viscosity of mucus depends on the liquid part, which contains a peculiar substance, named by the chemists *mucin*. This ingredient is precipitated and the mucus rendered turbid by the addition of water or a weak acid, but it may be partly redissolved in an excess of water, and completely so in a strong acid. This mucin is soluble in alkalis, and its acid solutions are not precipitated by ferrocyanide of potassium. Little can, of course, be expected from a chemical analysis of a heterogeneous and inseparable mixture of solid particles with a liquid solution, such as we find in mucus, which is, moreover, subject to differences of quality according to the part of the mucous membrane whence it is derived. Examined thus, however, nasal mucus has been found to yield,

besides water and mucin, alcohol-extract with alkaline lactates, water-extract with traces of albumin and a phosphate, chlorides of sodium and potassium,

and soda. Fat has been obtained by analysis of pulmonary mucus, reputed healthy.

The mucus is secreted partly by the general surface of the membrane, partly by special racemose and tubular glands. It is produced within the epithelium-cells, and accumulates in them during the intervals of secretion, in the columnar epithelium principally near the free extremity. On the addition of water the mucus swells up, and may eventually burst through the end of the cell, appearing on the surface as a pellucid drop. The nucleus and the greater part of the cell-protoplasm are usually forced towards the attached extremity. It is in this manner that the so-called "goblet-cells" appear to be produced: occasionally, in the process of preparing a mucous membrane for microscopical examination, large numbers of the cells may undergo the transformation (fig. 139\*).

**Regeneration.**—The reparatory process is active in the mucous membranes. Breaches of continuity occasioned by sloughing, ulceration, or other causes, readily heal. The steps of the process have been examined with most care in the healing of ulcers of the large intestine, and in such cases it has been found that the resulting cicatrix becomes covered with epithelium, but that the tubular glands are not reproduced.

The mucous membrane of the uterus becomes disintegrated and cast off during each menstrual flow, and is completely regenerated before the next monthly period. The process of destruction and renovation has recently been carefully traced and described by Dr. John Williams (Proceedings of the Royal Society, April, 1874).

## THE SKIN.

The skin consists of the cutis vera or corium, and the cuticle or epidermis.

### EPIDERMIS, CUTICLE, OR SCARF-SKIN.

This belongs to the class of stratified epithelia, the general nature of which has been already considered. It forms a protective covering over every part of the true skin, and is itself non-vascular. The thickness of the cuticle varies in different parts of the surface, measuring in some not more than  $\frac{1}{240}$ th, and in others from  $\frac{1}{24}$ th to  $\frac{1}{12}$ th of an inch. It is thickest in the palms of the hands and soles of the feet, where the skin is much exposed to pressure, and it is not improbable that this may serve to stimulate the subjacent true skin to a more active formation of epidermis; but the difference does not depend solely on external causes, for it is well marked even in the fœtus.

**Structure.**—The cuticle is made up of cells agglutinated together in many irregular layers. The deepest cells are elongated in figure, and placed perpendicularly on the surface of the corium (figs. 140 *b* and 144); they are denticulate at their lower ends, and fit into corresponding fine denticulations of the corium into which they appear to send processes (fig. 144). The perpendicular cells generally form one, but in some places two or three strata; above them are cells of a more rounded shape. These, as first shown by Max Schultze and Virchow, are marked on their surface with numerous ridges and furrows (in some cases with minute spines). The ridges of neighbouring cells do not, however, interlock one with another as was at first supposed, but on the contrary, meet at their summits so as to leave between the cells fine channels through which it is conceived nutrient plasma may be conducted to the cells. These ridged cells form several strata; above, they become gradually more flattened conformably to the surface until a layer is reached in which it becomes difficult in sections to trace the

outlines of the individual cells. Immediately above this, which may be looked upon as the commencement of the horny layer of the epidermis (see below), is a stratum of considerable thickness in which the cells are much enlarged, and the nuclei in many cases no longer visible: towards the surface they pass into the hard flattened scales which are to be thrown off by desquamation. As the cells change their form, they undergo chemical and physical changes in the nature of their contents; for in the deeper layers they consist of a soft, granular, protoplasmic matter, soluble in acetic acid, whilst the superficial ones are transparent, dry, and firm, and are not affected by that reagent. It would seem as if their contents were converted into horny matter, and that a portion of this substance is employed to cement them together. These dry hard scales may be made to reassume their cellular form, by exposure for a few minutes to a solution of caustic potash or soda, and then to water. Under this treatment they are softened by the alkali, and distended by imbibition of water.

Fig. 140.

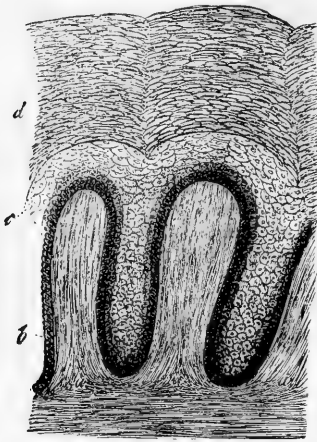


Fig. 140.—SKIN OF THE NEGRO, VERTICAL SECTION, MAGNIFIED 250 DIAMETERS (Kölliker).

*a, a*, cutaneous papillæ; *b*, undermost and dark-coloured layer of oblong vertical epidermis-cells; *c*, mucous or Malpighian layer; *d*, horny layer.

The more firm and transparent superficial part, or horny layer, of the epidermis, *d*, may be separated after maceration from the deeper, softer, more opaque, and recently formed part, which constitutes what is called the Malpighian layer, or *rete mucosum*, *c*.

Many of the cells of the cuticle contain pigment granules, and often give the membrane more or less of a tawny colour, even in the white races of mankind; the blackness of the skin in the negro depends entirely on the cuticle. The pigment is contained principally in the cells of the deep layer or *rete mucosum*, and appears to fade as they approach the surface, but even the superficial part possesses a certain degree of colour. More special details respecting the pigment have been already given (page 51).

Between and amongst the cells of the Malpighian layer leucocytes are occasionally observed. They have no doubt made their way here from the corium.

The under or attached surface of the cuticle is moulded on the adjoining surface of the corium, and, when separated by maceration or putrefaction, presents impressions corresponding exactly with the papillary or other eminences, and the furrows or depressions of the true skin; the more prominent inequalities of the latter are marked also on the outer surface of the cuticle, but less accurately. Fine tubular prolongations of the cuticle sink down into the ducts of the sweat-glands, and are often partially drawn out from their recesses when the cuticle is



detached, appearing then like threads proceeding from its under surface. When a portion of the cuticle is destroyed by a blister, or otherwise, it is readily regenerated.

**Chemical composition.**—The cuticle consists principally of a substance peculiar to the epithelial and horny tissues, and named *keratin*. This horny matter is insoluble in water at ordinary temperatures, and also in alcohol. It is soluble in the caustic alkalies. In composition, it is analogous to the albuminoid principles, but with a somewhat larger proportion of oxygen; like these, it contains sulphur. Besides keratin, the epidermis yields, on analysis, a small amount of fat, with salts, and traces of the oxides of iron and manganese. The tissue of the cuticle readily imbibes water, by which it is rendered soft, thick, and opaque, but it speedily dries again, and recovers its usual characters.

**Development and growth of Epidermis.**—In the earliest condition of the embryo there is a special layer of cells, derived from the primitive embryonic cells, set aside for the production of the epidermis; and it is quite conceivable, and by some histologists considered most probable, that the subsequent generations of epidermic and epithelial cells by which the tissue is throughout life maintained, are derived by unbroken descent from the original embryonic stratum. At the same time, the reproduction of epidermis in cicatrices after wide and deep destruction of the subjacent skin, implies some other source of new cells; unless indeed it be supposed that the new cuticle grows exclusively from the old at the circumference of the sore. Setting aside this supposition, we might conceive the new cells to come from the connective tissue corpuscles, or at least, from migratory cells of the granulating surface of the new-growing skin; and such a mode of reproduction of epidermis has been described as actually observed; moreover, it may be questioned whether, in certain situations, this may not be the regular process by which the growth of epithelium is maintained: the readiness, however, with which a previously obstinate ulcer will often become covered with epidermis if one or two small portions of that tissue are transplanted to its surface from some other part, would indicate, on the other hand, that the presence of some epithelial cells at least is necessary to set up the growth.

When the lowermost cells are elongated and vertical, it is difficult to conceive that they rise up as such, and take their place in the upper strata; for the cells next above them are spheroidal in shape and may be smaller in size. It seems more likely that they divide into or produce the smaller cells. It might be supposed that an oblong vertical cell, by division of its nucleus and separation of the upper portion of the cell-body, produces a new and smaller cell, which rises up, while the parent cell maintains its place, and lengthens out again for a repetition of the process.

#### CORIUM.

The **true skin, cutis vera, derma, or corium**, is a sentient and vascular texture. It is covered and defended, as already explained by the non-vascular cuticle, and is attached to the parts beneath by a layer of areolar tissue, named “subcutaneous,” which, excepting in a few parts, contains fat, and has therefore been called also the “*panniculus adiposus*” (fig. 155, *d*). The connection is in many parts loose and movable, in others close and firm, as on the palmar surface of the hand and the sole of the foot, where the skin is fixed to the subjacent fascia by numerous stout fibrous bands, the space between being filled with a firm padding of fat. In some regions of the body the skin is moved by striated muscular fibres, which may be unconnected to fixed parts, as in the case of the orbicular muscle of the mouth, or may be attached beneath to bones or fasciæ, like the other cutaneous muscles of the face and neck, and the short palmar muscle of the hand.

**Structure.**—The corium is made up of an exceedingly strong and

tough framework of interlaced connective tissue fibres, with blood-vessels and lymphatics. The fibres are chiefly of the white variety, such as constitute the chief part of the fibrous and areolar tissues, and are arranged in stout interlacing bundles, except at and near the surface, where the texture of the corium becomes very fine.\* With these are mixed yellow or elastic fibres, which vary in amount in different parts, but in all cases are present in smaller proportion than the former kind; also connective tissue corpuscles, fusiform or ramified, and for the most part reticularly anastomosing. The interlacement becomes much closer and finer towards the free surface of the corium, and there the fibres can be discovered only by teasing out the tissue, which often acquires an almost homogeneous aspect. Towards the attached surface, on the other hand, the texture becomes much more open, with larger and larger meshes, in which lumps of fat and the small sudatory glands are lodged; and thus the fibrous part of the skin, becoming more and more lax and more mixed with fat, blends gradually with the subcutaneous areolar tissue, to which it is allied in elementary constitution. Bundles of plain muscular tissue are distributed in the substance of the corium wherever hairs occur; and their connection with the latter will be afterwards explained. Muscular bundles of the same kind are found in the subcutaneous tissue of the scrotum, penis, perineum, and areola of the nipple, as well as in the nipple itself. They join to form reticular superimposed layers, which are separated from the parts beneath by a stratum of simple lax areolar tissue, but towards the surface they are immediately applied to the corium. In the areola they are disposed circularly.

In consequence of this gradual transition of the corium into the subjacent tissue, its thickness cannot be assigned with perfect precision. It is generally said to measure from a quarter of a line or less to nearly a line and a half. As a general rule, it is thicker on the posterior aspect of the head, neck, and trunk, than in front; and thicker on the outer than on the inner side of the limbs. The corium, as well as the cuticle, is remarkably thick on the soles of the feet and palms of the hands. The skin of the female is thinner than that of the male.

For convenience of description it is not unusual to speak of the corium as consisting of two layers, the "reticular" and the "papillary." The former, the more deeply seated, takes no part in the construction of the papillæ, but contains in its meshes hair follicles, cutaneous glands, and fat. The latter is divided into papillæ, and receives only the upper portion of the hair-follicles and glands, together with the terminal expansion of the vessels and nerves.

The free surface of the corium is marked in various places with larger or smaller furrows, which also affect the superjacent cuticle. The larger of them are seen opposite the flexures of the joints, as those so well known in the palm of the hand and at the joints of the fingers. The finer furrows intersect each other at various angles, and may be seen almost all over the surface; they are very conspicuous on the back of the hands. These furrows are not merely the consequence of the frequent folding of the skin by the action of muscles or the bending of joints, for they exist in the fœtus. The wrinkles of old persons are of

\* A *membrana propria*, or basement-membrane, is sometimes described as bounding the corium superficially, like that found in the mucous membranes.

a different nature, and are caused by the wasting of the soft parts which the skin covers. Fine curvilinear ridges, with intervening furrows, mark the skin of the palm and sole; these are caused by ranges of the papillæ, to be immediately described.

**Papillæ.**—The free surface of the corium is beset with small eminences thus named, which seem chiefly intended to contribute to the

Fig. 141.

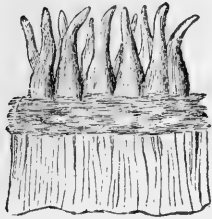


Fig. 142.

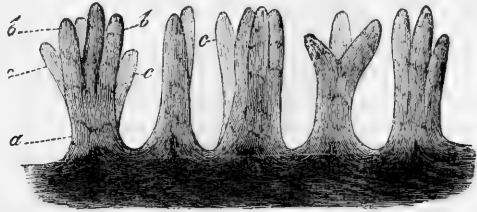


Fig. 141.—PAPILLE, AS SEEN WITH A MICROSCOPE, ON A PORTION OF THE TRUE SKIN, FROM WHICH THE CUTICLE HAS BEEN REMOVED (after Breschet).

Fig. 142.—COMPOUND PAPILLÆ FROM THE PALM OF THE HAND, MAGNIFIED 60 DIAMETERS.

*a*, basis of a papilla; *b*, *b*, divisions or branches of the same; *c*, *c*, branches belonging to papillæ of which the bases are hidden from view (after Kölliker).

perfection of the skin as an organ of touch, seeing that they are highly developed where the sense of touch is exquisite, and *vice versâ*: They serve also to extend the surface for the production of the cuticular tissue, and hence are large-sized and numerous under the nail. The papillæ are large, and in close array on the palm and palmar surface of the fingers, and on the corresponding parts of the foot (fig. 142). There they are ranged in lines forming the curvilinear ridges seen when the skin is still covered with its thick epidermis. They are of a conical figure, rounded or blunt at the top, and sometimes cleft into two or more points, when they are named compound papillæ. They are received into corresponding pits on the under surface of the cuticle. In structure they resemble the superficial layer of the corium generally, and consist of a homogenous tissue, presenting only faint traces of fibrillation, together with a few fine elastic fibres. On the palm, sole, and nipple, where they are mostly of the compound variety, they measure from  $\frac{1}{200}$  to  $\frac{1}{100}$  of an inch in height. In the ridges, the larger papillæ are placed sometimes in single but more commonly in double rows, with smaller ones between them (fig. 156), that is, also on the ridges, for there are none in the intervening grooves. These ridges are marked at short and tolerably regular intervals with notches, or short transverse furrows, in each of which, about its middle, is the minute funnel-shaped orifice of the duct of a sweat-gland (fig. 143). In other parts of the skin endowed with less sensibility, the papillæ are smaller, shorter, fewer in number, and irregularly scattered. On the face they are reduced to from  $\frac{1}{800}$  to  $\frac{1}{500}$  of an inch; and here they at parts disappear altogether, or are replaced by slightly elevated reticular ridges. In parts where they are naturally small, they often become enlarged by chronic inflammation round the margin of sores and ulcers

of long standing, and are then much more conspicuous. Fine blood-vessels enter most of the papillæ, forming either simple capillary loops in each, or dividing into two or more capillary branches, according to the size of the papilla and its simple or composite form, which turn round in form of loops and return to the veins. Other papillæ receive nerves, to be presently noticed.

Fig. 143.

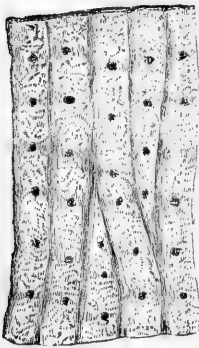


Fig. 143. — MAGNIFIED VIEW OF FOUR OF THE RIDGES OF THE EPIDERMIS, CAUSED BY ROWS OF PAPILLÆ BENEATH, WITH SHORT FURROWS OR NOTCHES ACROSS THEM: ALSO THE OPENINGS OF THE SUDORIFEROUS DUCTS (after Breschet).

**Blood-vessels and lymphatics.**—The blood-vessels divide into branches in the subcutaneous tissue, and, as they enter the skin, supply capillary plexuses to the fat-clusters, sweat-glands, and hair-follicles. They divide and anastomose still further as they approach the surface, and at length, on reaching it, form a dense network of capillaries, with rounded polygonal meshes. Fine branches are seen in the papillæ, as already mentioned. The lymphatics are abundant and large in some parts of the skin, as on the scrotum and round the nipple; whether they are equally so in all parts may be doubted. They form networks, which become finer as they approach the surface, and communicate underneath with straight vessels, and these, after a longer or a shorter course, join larger ones or enter lymphatic glands. The finest and most superficial network, although close to the surface of the corium, is beneath the net of superficial

blood-capillaries; in certain parts on the palm and sole, lymphatics pass into the papillæ, but do not reach their summits. Besides these plexuses, other lymphatics accompany the blood-vessels to which they are applied, two passing commonly to each, and joining and anastomosing over the vessel.

**Nerves.**—Nerves are supplied in very different proportions to different regions of the skin, and according to the degree of sensibility. They pass upwards towards the papillary surface, where they form plexuses, of which the meshes become closer as they approach the surface, and the constituent branches finer. From the most superficial plexus which lies immediately under the epithelium, delicate non-medullated fibrils have been traced passing upwards amongst the cells of the Malpighian layer of the cuticle, where they end, according to some accounts, in slightly bulbous free extremities; according to others, in a plexus of excessively fine fibrils. A large share of the cutaneous nerves is distributed to the hair-follicles, whilst some end in special terminal organs, namely, *end-bulbs*, *tactile corpuscles*, and *Pacinian bodies*. The last-named bodies are seated in the subcutaneous tissue. End-bulbs are found on the glans penis and glans clitoridis, and in some of the papillæ on the red border of the lips. The tactile corpuscles of the skin are more numerous; they are found in certain papillæ of the palm and sole, more sparingly in those of the back of the hand and foot, the palmar surface of the fore-arm, and the nipple. Such papillæ commonly contain no blood-vessels, and are named “tactile,” (fig. 144, *b*), as distinguished from the “vascular” papillæ (*a*). Sometimes, however, a

tactile and a vascular papilla may spring from the same stem. The

Fig. 144.




Fig. 144.—SECTION OF SKIN SHOWING TWO PAPILLÆ AND DEEPER LAYERS OF EPIDERMIS. (Biesiadecki.)

*a*, Vascular papilla with capillary loop passing from subjacent vessel *c*; *b*, nerve papilla with tactile corpuscle, *t*. The latter exhibits transverse fibrous markings: three nerve-fibres, *d*, are represented as passing up to it: at *ff* these are seen in optical section.

structure of these different terminal corpuscles has been already described (pages 147 to 153).

**Chemical composition.**—The corium being composed chiefly of white fibrous tissue, has a corresponding chemical composition. It is, accordingly, in a great measure, resolved into gelatin by boiling, and hence, also, its conversion into leather by the tanning process.

**Development of the cutis.**—The cutis consists at first of cells which may be traced back to the first formative cells of the embryo. Many of them give rise to connective tissue; others to vessels and nerves; and a third portion is converted into fat-cells. The mode of formation of these several elementary tissues has been already described. Progressive development takes place from within outwards, so that the papillæ are formed latest.

#### NAILS AND HAIRS.

The nails and hairs are growths of the epidermis, agreeing essentially in nature with that membrane; their epidermic tissue is destitute of vessels and nerves, and separable from the cutis.

**NAILS.**—The posterior part of the nail which is concealed in a groove of the skin is named its “root,” the uncovered part is the “body,” which terminates in front by the “free edge.” A small portion of the nail near the root, named from its shape the *lunula*, is whiter than the rest. This appearance is due partly to some degree of opacity of the substance of the nail at this point, and partly to the skin beneath being less vascular than in front.

The part of the corium to which the nail is attached, and by which in fact it is secreted or generated, is named the *matrix*. This portion of the skin is highly vascular and thickly covered with large vascular papillæ. Posteriorly the matrix forms a crescentic groove or fold, deep in the middle but getting shallower at the sides, which lodges the root of the nail; the rest of the matrix, before the groove, is usually named the *bed* of the nail. The small lighter coloured part of the matrix next the groove and corresponding with the lunula of the nail, is covered with papillæ having no regular arrangement, but the whole remaining surface of the matrix situated in front of this, and supporting the body of the nail, is marked with longitudinal and very slightly diverging ridges cleft at their summits into rows of papillæ. These ridges, or *laminæ*, as they are sometimes, and perhaps more suitably, named, fit into corresponding furrows on the under surface of the nail. The cuticle, advancing from the back of the finger, becomes attached to the upper surface of the nail near its posterior edge, that is, all round the margin of the groove in which the nail is lodged; in front the cuticle of the point of the finger becomes continuous with the under surface of the nail a little way behind its free edge.

Fig. 145.

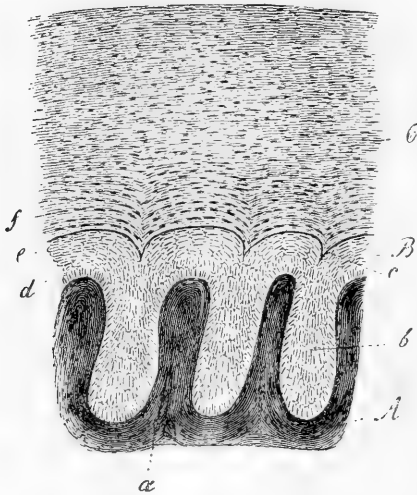


Fig. 145.—VERTICAL TRANSVERSE SECTION THROUGH A SMALL PORTION OF THE NAIL AND MATRIX, HIGHLY MAGNIFIED (Kölliker).

A, corium of the nail-bed, raised into ridges or laminæ, *a*, fitting in between corresponding laminæ, *b*, of the nail; B, Malpighian, and C, horny layer; *d*, deepest and vertical cells; *e*, upper flattened cells of Malpighian layer.

the epidermis, and the upper part (c) with the horny layer. As in the case of the epidermis, the hardened scales may be made to reassume their cellular character by treatment with caustic alkali, and after

The nail, like the cuticle, is made up of epithelial cells. The oldest and most superficial of these are the broadest and hardest, but at the same time very thin and irregular, and so intimately and confusedly connected together that their respective limits are scarcely discernible. They form the exterior, horny part of the nail, and cohere together in irregular layers, so as to give this part a lamellar structure. On the other hand, the youngest cells, which are those situated at the root and under surface, are softer and of a rounded or polygonal shape. The deepest layer differs somewhat from the others in having its cells elongated, and arranged perpendicularly, as in the case of the epidermis. Thus the under part of the nail (fig. 145, B) corresponds in nature with the Malpighian or mucous layer of the epidermis, and the upper part (c) with the horny layer. As in the case of the epidermis, the hardened scales may be made to reassume their cellular character by treatment with caustic alkali, and after

wards with water; and then it is seen that they still retain their nuclei. In chemical composition the nails resemble epidermis; but, according to Mulder, they contain a somewhat larger proportion of carbon and sulphur.

The growth of the nail is effected by a constant generation of cells at the root and under surface. Each successive series of these cells being followed and pushed from their original place by others, they become flattened into dry, hard, and inseparably coherent scales. By the addition of new cells at the posterior edge the nail is made to advance, and by the apposition of similar particles to its under surface it grows in thickness; so that it is thicker at the free border than at the root. The nail being thus merely an exuberant part of the epidermis, the question at one time raised, whether that membrane is continued underneath it, loses its significance. When a nail is thrown off by suppuration, or pulled away by violence, a new one is produced in its place, provided the matrix remains.

**Development of the nails.**—In the third month of intra-uterine life the part of the embryonic corium which becomes the matrix of the nail is marked off by the commencing curvilinear groove, which limits it posteriorly and laterally. The epidermis on the matrix then begins to assume, in its under part, the characters of a nail, which might, therefore, be said to be at first covered over by the embryonic cuticle. After the end of the fifth month it becomes free at the anterior border, and in the seventh month decidedly begins and thenceforth continues to grow in length. At birth the free end is long and thin, being manifestly the earlier formed part which has been pushed forward. This breaks or is pared off after birth, and, as the infantile nail continues to grow, its flattened cells, at first easily separable, become harder and more coherent, as in after-life.

**Rate of growth.**—The average rate of growth of the nails is about  $\frac{1}{32}$  of an inch per week (Benham). Berthold found that the nails grow rather faster in summer than in winter, and faster in the right hand than in the left. He also observed a difference in the nails of different fingers: thus it was fastest in the middle finger and slowest in the thumb. A careful series of experiments by Mr. H. J. Benham, hitherto unpublished, confirm generally the observations of Berthold, but no clear difference could be observed between the two hands, and the growth appeared to be slowest in the little finger. In some individuals these differences were not observed.

**Hairs.**—A hair consists of the root, which is fixed in the skin, the shaft or stem, and the point. The *stem* is generally cylindrical, but

Fig. 146.



Fig. 146.—A, SURFACE OF A WHITE HAIR, MAGNIFIED 160 DIAMETERS. THE WAVED LINES MARK THE UPPER OR FREE EDGES OF THE CORTICAL SCALES. B, SEPARATED SCALES, MAGNIFIED 350 DIAMETERS (after Kölliker).

often more or less flattened: when the hair is entire, it becomes gra-

dually smaller towards the point. The length and thickness vary greatly in different individuals and races of mankind as well as in different regions of the body. Light-coloured hair is usually finer than black.

The stem is covered with a coating of finely imbricated scales, the upwardly projecting edges of which give rise to a series of fine waved transverse lines, which may be seen with the microscope on the surface of the hair (fig. 146, A). Within this scaly covering, by some called the *hair-cuticle*, is a *fibrous substance* which in all cases constitutes the chief part and often the whole of the stem; but in many hairs the axis is occupied by a substance of a different nature, called the *medulla* or *pith*, for which reason the surrounding fibrous part is often named "cortical," although this term is more properly applied to the superficial coating of scales above mentioned. The *fibrous substance* is translucent, with short longitudinal opaque streaks of darker colour intermixed. It may be broken up into straight, rigid, longitudinal fibres, which, when separated, are found to be flattened, broad in the middle and pointed at each end, with dark and rough edges. The fibres may be resolved into flattened cells of a fusiform outline; these are mostly transparent, or marked with only a few dark specks. The colour of the fibrous substance is caused by oblong patches of pigment-granules, and generally diffused colouring matter of less intensity. Very slender elongated nuclei are also discovered by means of reagents, whilst specks or marks of another description in the fibrous substance are occasioned by minute irregularly shaped cavities containing air. These air-lacunules are abundant in white hairs, and in very dark hairs may be altogether wanting; they are best seen too in the former, in which there is no risk of deception from pigment-specks. Viewed by transmitted light they are dark, but brilliantly white by reflected light. When a white hair has been boiled in water, ether, or oil of turpentine, these cavities become filled with fluid, and are then quite pellucid; but when a hair which has been thus treated is dried, the air quickly finds its way again into the lacunæ, and they resume their original aspect.

The medulla or pith, as already remarked, does not exist in all hairs. It is wanting in the fine hairs over the general surface of the body, and is not commonly met with in those of the head; nor in the hairs of children under five years. When present it occupies the centre of the shaft and ceases towards the point. It is more opaque and deep-coloured than the fibrous part; in the white hairs of quadrupeds it is white, but opaque and dark when seen by transmitted light. It seems to be composed of little clusters of cells, differing in shape, but generally angular, and containing minute particles, some resembling pigment-granules, and others like very fine fat granules, but really for the most part air particles, apparently included in some solidified tenacious substance. The whole forms a continuous dark mass along the middle of the stem, interrupted at parts for a greater or less extent. In the latter case, the axis of the stem at the interruptions may be fibrous like the surrounding parts, or these intervals may be occupied by a clear colourless matter; and, according to Henle, some hairs present the appearance of a sort of canal running along the axis and filled in certain parts with opaque granular matter, and in others with a homogeneous transparent substance.

The *root* of the hair is lighter in colour and softer than the stem;



it swells out at its lower end into a bulbous enlargement or knob (fig. 147 *c*), and is received into a recess of the skin named the *hair-follicle*, which, when the hair is of considerable size, reaches down into the subcutaneous fat.

The follicle, which receives near its mouth the opening ducts of one or more sebaceous glands (*k, k*), is somewhat dilated at the bottom, to correspond with the bulging of the root; it consists of an outer coat continuous with the corium (fig. 147, *h*; 148, *d, d'*), and an epidermic

Fig. 147.

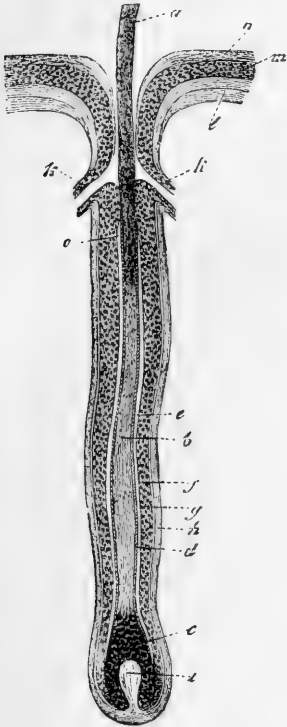


Fig. 147.—MEDIUM-SIZED HAIR IN ITS FOLLICLE, MAGNIFIED 50 DIAMETERS from (Kölliker).

*a*, stem cut short; *b*, root; *c*, knob; *d*, hair-cuticle; *e*, internal and *f*, external root-sheath; *g, h*, dermic coat of follicle; *i*, papilla; *k, k*, ducts of sebaceous glands; *l*, corium; *m*, mucous layer, and *n*, horny layer of epidermis; *o*, upper limit of internal root-sheath (from Kölliker).

Fig. 148.

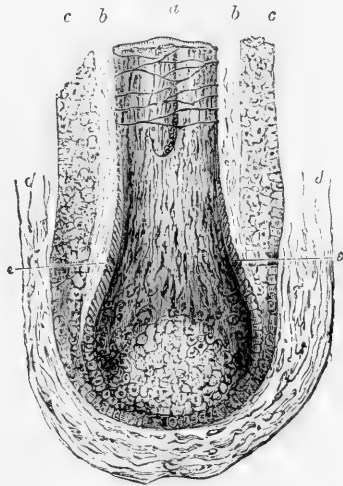


Fig. 148.—MAGNIFIED VIEW OF THE ROOT OF A HAIR (after Kohlrausch).

*a* stem or shaft of hair cut across; *b*, inner, and *c*, outer layer of the epidermic lining of the hair-follicle, called also the inner and outer root-sheath; *d*, dermic or external coat of the hair-follicle, shown in part; *e*, imbricated scales about to form a cortical layer on the surface of the hair. The adjacent cuticle of the root-sheath is not represented, and the papilla is hidden in the lower part of the knob where that is represented lighter.

lining (fig. 147, *e, f*; 148, *b, c*), continuous with the cuticle.

The outer or *dermic* coat of the follicle (fig. 149, 1 in transverse section) is thin but firm, and consists of three layers. The most external (fig. 149, *a*) is formed of connective tissue in longitudinal bundles, without any elastic fibres, but with numerous corpuscles.

It is highly vascular, and provided with nerves. It is intimately connected above with the corium, and determines the form of the follicle. The most internal layer (*hyaline layer*, Kölliker) (fig. 149, *d*) is a

transparent homogeneous membrane, marked transversely on its inner surface with some raised lines, and not reaching so high as the mouth of the follicle; it corresponds with the *membrana propria* or basement membrane of analogous structures, and, like that, probably consists of flattened cells. Between the two is a layer extending from the bottom of the follicle as high as the entrance of the sebaceous glands, composed of an indistinctly fibrous matrix, tearing transversely, and of transversely disposed connective tissue corpuscles, with oblong nuclei. (fig. 149, *c*). This layer, which seems to be a form of connective tissue, receives capillary blood-vessels.

The *epidermic coat* (fig. 149, 2) of the follicle adheres closely to the root of the hair, and commonly separates, in great part, from the follicle and abides by the hair when the latter is pulled out; hence it is sometimes named the "root-sheath." It consists of an outer, softer, and more opaque stratum (fig. 148, *c, c*; 149, *e*), next to the dermic coat of the follicle, and an internal more transparent layer (fig. 148, *b, b*; 149, *f, g*) next to the hair. The former, named also the *outer root-sheath*, and

Fig. 149.

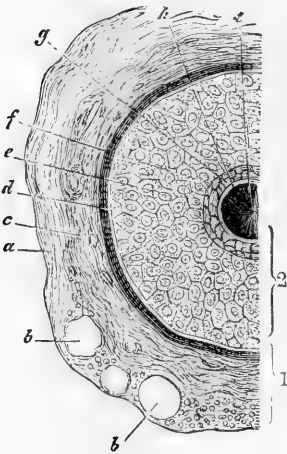


Fig. 149.—SECTION OF HAIR FOLLICLE (Biesiadecki).

1, Dermic coat of follicle; 2, epidermic coat or root-sheath; *a*, Outer layer of dermic coat, with blood-vessels, *b, b*, cut across; *c*, middle layer; *d*, inner or hyaline layer; *e*, outer root-sheath; *f, g*, inner root-sheath; *h*, cuticle of root-sheath; *l*, hair.

by much the thicker of the two, corresponds with the mucous or Malpighian layer of the epidermis in general, and contains soft growing cells, including pigment granules in the coloured races, which at the lower part form a much thinner stratum and pass continuously into those of the hair-knob; the internal layer or *inner root-sheath*, represents the superficial or horny layer of the epidermis according to some authorities; but others maintain that it is not continuous with that part of the skin, but ceases abruptly a little below the orifices of the sebaceous ducts. Lining the root-sheath internally is a layer of imbricated downwardly projecting scales, the *cuticle of the root-sheath* (fig. 149, *h*), which is applied to the cortical scaly cuticle of the hair proper, to whose upwardly directed scales it fits like a mould. Its scales, as well as those of the hair-cuticle, pass, at the bottom of the follicle, into the round cells of the hair-knob. The inner root-sheath itself consists of two layers, which towards the bottom of the follicle become blended into one (fig. 149, *f, g*). The innermost (that next the cuticle) is known as *Huxley's layer*; it consists of flattened polygonal nucleated cells, two or even three deep. The outermost is composed of oblong, somewhat flattened cells without nuclei, in which fissures and holes

are liable to occur from accidental laceration, so as to give it the aspect of a perforated or fenestrated membrane. At the lower part both layers pass into a single layer of large polygonal nucleated cells without openings between them.

The soft, bulbous enlargement of the root of the hair is attached by its base to the bottom of the follicle, and at the circumference of this attached part it is continuous with the epidermic lining. At the bottom of the follicle it, in fact, takes the place of the epidermis, of which it is a growth or extension, and this part of the follicle is the true matrix of the hair, being, in reality, a part of the corium (though sunk below the general surface), which supplies material for

Fig. 150.

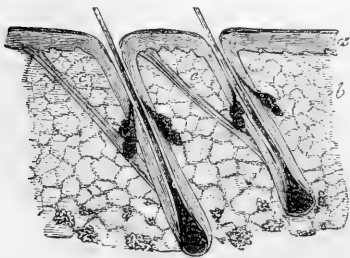


Fig. 151.

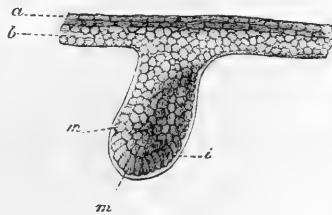


Fig. 150.—SECTION OF THE SKIN OF THE HEAD, WITH TWO HAIR FOLLICLES, SLIGHTLY MAGNIFIED (Kölliker).

*a*, epidermis ; *b*, corium ; *c*, muscles of the hair-follicles.

Fig. 151.—HAIR RUDIMENT FROM AN EMBRYO OF SIX WEEKS, MAGNIFIED 350 DIAMETERS (Kölliker).

*a*, horny, and *b*, mucous or Malpighian layer of cuticle ; *i*, liminary membrane ; *m*, cells, some of which are assuming an oblong figure, which chiefly form the future hair.

the production of the hair. From the bottom of this follicle rises a small vascular papilla, usually of a conical form, which fits into a corresponding excavation of the hair-knob ; in the large tactile hairs on the snout of the seal and some other animals it is very conspicuous. As the follicle, in short, is a recess of the corium, so the hair-papilla is a cutaneous papilla rising up in the bottom of it. The papilla is sometimes of an ovoid shape, and attached to the bottom of the follicle by a narrow base, or a sort of pedicle (fig. 147, *i*). Nervous branches enter the hair-follicles, but their final distribution is obscure. In the tactile hairs of animals, they are described as passing upwards over the outer root-sheath, losing their white substance and forming a close plexus with vertical meshes and numerous nuclei ; finally terminating in an annular expansion, which encircles the hair just below the orifices of the sebaceous glands, and is in immediate connection with the hyaline layer of the follicle. In the larger tactile hairs the bulb is surrounded by cavernous tissue, which lies between the outer and middle layers of the dermic coat.\*

Slender bundles of plain muscular tissue are connected with the hair-follicles (fig. 150). They arise from the most superficial part of the corium, and pass down obliquely to be inserted into the outside of the follicle below the sebaceous glands. They are placed on the side to which the hair slopes, so that their action in elevating the hair is evident. Some anatomists have also described a layer of circularly disposed muscular cells as applied immediately to the outside of the follicle.

\* See papers by Leydig, Stieda, Schöbl, and others.

**Development of hair in the fœtus.**—The rudiments of the hairs may be discerned at the end of the third or beginning of the fourth month of intra-uterine life, as little black specks beneath the cuticle. They at first appear as little pits in the corium (fig. 151), filled with cells of precisely the same nature as those of the Malpighian or mucous layer of the cuticle, with which they are continuous; so it might correctly be said that the hair-rudiments are formed of down-growths of the mucous layer, which sink into the corium. A homogeneous limiting membrane next appears (*i*), inclosing the collection of cells, and continuous above with a similar simple film which at this time lies between the cuticle and the corium; it becomes the innermost or hyaline layer of the dermic coat of the follicle. The hair-rudiments next lengthen and swell out at the bottom, so as to assume a flask-shape (fig. 152). Cells are deposited outside the liminary membrane, which eventually give rise to fibres, corpuscles, and other constituents

Fig. 152.

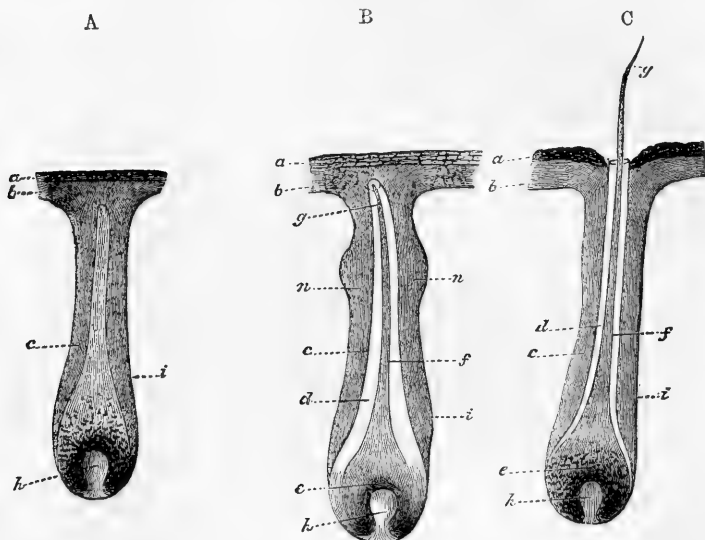


Fig. 152.—A. RUDIMENT OF A HAIR OF THE EYEBROW, MAGNIFIED 50 DIAMETERS (Kölliker).

The cells form an internal cone indicating the position of the future hair. *a*, horny layer of cuticle; *b*, mucous layer; *c*, external layer of root-sheath; *i*, liminary membrane; *h*, papilla.

B.—HAIR-RUDIMENT FROM THE EYEBROW, WITH THE YOUNG HAIR NOT YET RISEN THROUGH THE CUTICLE.

*c*, hair-knob; *f*, stem, and *g*, point of the hair; *d*, internal layer of the root-sheath, still inclosing the hair; *n, n*, commencing sebaceous follicles.

C.—HAIR-FOLLICLE FROM THE EYEBROW WITH THE HAIR JUST PROTRUDED; THE INNER LAYER OF THE ROOT-SHEATH RISES TO THE MOUTH OF THE HAIR-FOLLICLE.

of the dermic coat. While this is going on outside, the cells within the follicle undergo changes. Those in the middle lengthen out conformably with the axis of the follicle, and give rise to the appearance of a short conical miniature hair, faintly distinguishable by difference of shade from the surrounding mass of cells, which are also slightly elongated, but across the direction of the follicle. The papilla (fig. 152, *h*) makes its appearance at the swollen root of the little hair; and the residuary cells contained within the rudimentary follicle form the root-sheath, the inner layer of which, or inner root-sheath, lying next

to the hair (fig. 152, *d*), is soon distinguished by its translucency from the more opaque outer part that fills up the rest of the cavity. The young hair continuing to grow, at last perforates the cuticle (fig. 152, *C. g*), either directly or after first slanting up for some way between the mucous and horny strata: it is often bent like a whip, and then the doubled part protrudes.

The first hairs produced constitute the *lanugo*; their eruption takes place about the fifth month of intra-uterine life, but part of them are shed before birth, and are found floating in the liquor amnii. Kölliker affirms that the infantile hairs are entirely shed and renewed within a few months after birth; those of the general surface first, and afterwards the hairs of the eyelashes and head, which he finds in process of change in infants about a year old.

**Regeneration.**—The new hairs are generated in the follicles of the old (figs. 153 and 154). An increased growth of cells takes place in the soft hair-knob, and in

Fig. 153.

Fig. 154.

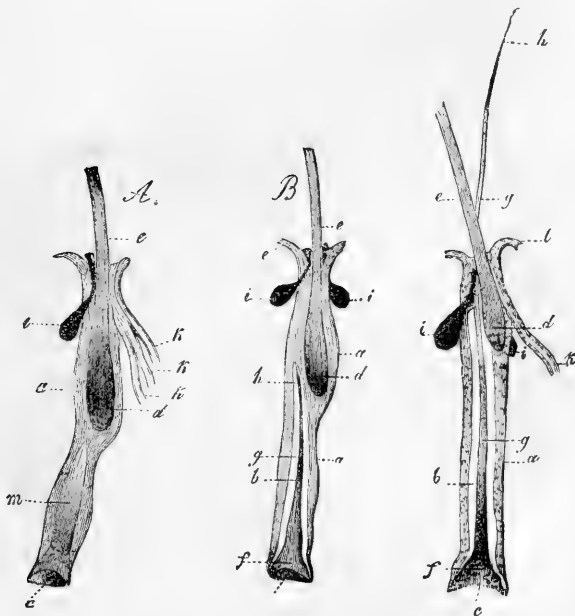


Fig. 153.—TWO EYELASHES OF AN INFANT, PULLED OUT FROM THEIR FOLLICLES, MAGNIFIED 20 DIAMETERS (Kölliker).

A, the new cell-growth forming a cone, *m*, in the interior (as in fig. 152, *A*). In B, the cone has separated into the new hair, *f, g*, and its inner root-sheath, *b, a*; *a*, outer, and *b*, inner root-sheath of new hair; *c*, pit for papilla; *d* and *e*, the knob and stem of old hair; *f*, knob; *g*, stem; and *h*, the point of new hair; *i*, sebaceous glands; *k, k*, sweat-glands here opening into mouth of hair-follicle.

Fig. 154.—EYELASH OF AN INFANT, WITH YOUNG HAIR COME FORTH, MAGNIFIED 20 DIAMETERS (Kölliker).

*l*, epidermis continuous with outer root-sheath; other letters as in preceding figures.

the adjoining part of the root-sheath (the outer layer): the growing mass pushes up the hair knob, and detaches it from its generative papilla. The newly-formed mass of cells occupying the lower part of the follicle, and resting on the papilla, is gradually converted into a new hair with its root-sheath, just as in the primitive process of formation in the embryo; and as the new hair lengthens and emerges from the follicle, the old one, separated from its matrix by the interposition of the

new growth, is gradually pushed towards the opening, and at last falls out, its root-sheath having previously undergone partial absorption. When a hair is pulled out, a new one grows in its place, provided the follicle (from which the growth proceeds) remains entire.

**Growth of hair.**—On the surface of the papilla or vascular matrix, at the bottom of the follicle, there is a growth of nucleated cells. The cells for the most part lengthen out and unite into the flattened fibres which compose the fibrous part of the hair, and certain of them, previously getting filled with pigment, give rise to the coloured streaks and patches in that tissue; their nuclei, at first, also lengthen in the same manner, but, at last, partly become indistinct. The cells next the circumference expand into the scales which form the imbricated cuticular layer. The medulla, where it exists, is formed by the cells nearest the centre; these retain their primitive figure longer than the rest; they become coherent, and their cavities may coalesce by destruction of their mutually adherent parietes, whilst collections of granular particles of fat or pigment, and occasionally minute air globules make their appearance between and in them and around their nuclei, forming an opaque mass, which occupies the axis of the hair.

The substance of the hair, of epidermic nature, is, like the epidermis itself, quite extravascular, but, like that structure also, it is organised and subject to internal organic changes. Thus, in the progress of its growth, the cells change their figure, and acquire greater consistency. In consequence of their elongation, the hair, bulbous at the commencement, becomes reduced in diameter, and cylindrical above. But it cannot be said to what precise distance from the root organic changes may extend. Some have imagined that the hairs are slowly permeated by a fluid from the root to the point, but this has not been proved. The sudden change of the colour of the hair from dark to grey, which sometimes happens, has never been satisfactorily explained: it appears, in some instances at least, to be due to the development of air between and among the cells composing the hair.

Berthold found the rate of growth to be about half-an-inch per month. This was in the hairs of the head. Erasmus Wilson states that in the beard the rate of growth is  $\frac{1}{8}$  inch per week.

**Distribution and arrangement.**—Hairs are found on all parts of the skin except the palms of the hands and soles of the feet, the dorsal surface of the third phalanges of the fingers and toes, the upper eyelids, the glans, and the inner surface of the prepuce. On the scalp they are set in groups, on the rest of the skin for the most part singly. Except those of the eyelashes, which are implanted perpendicularly to the surface, they have usually a slanting direction, which is wonderfully constant in the same parts.

**Chemical nature.**—The chemical composition of hair has been investigated principally by Vauquelin, Scherer, and Van Laer. When treated with boiling alcohol and with ether, it yields a certain amount of oily fat, which is red or dark-coloured, according to the tint of the hair. The animal matter of the hair thus freed from fat, is supposed to consist of a substance yielding gelatine, and a protein compound containing a large proportion of sulphur. It is insoluble in water, unless by long boiling under pressure, by which it is reduced into a viscid mass. It readily and completely dissolves in caustic alkalis. By calcination, hair yields from 1 to  $1\frac{1}{2}$  per cent. of ash, which consists of the following ingredients—viz., peroxide of iron, and according to Vauquelin, traces of manganese, silica, chlorides of sodium and potassium, sulphates of lime and magnesia, and phosphate of lime. With the exception of the bones and teeth, no tissue of the body withstands decay after death so long as the hair, and hence it is often found preserved in sepulchres, when nothing else remains but the skeleton.

#### GLANDS OF THE SKIN.

**The sudoriferous glands or sweat-glands** (figs. 155 and 156).—These are seated on the under surface of the corium, and at variable depths in the subcutaneous adipose tissue. They have the appearance of small round reddish bodies, each of which, when examined with the

microscope, is found to consist of a fine tube, coiled up into a ball (though sometimes forming an irregular or flattened figure); from which the tube is continued, as the duct of the gland, upwards through the

Fig. 155.

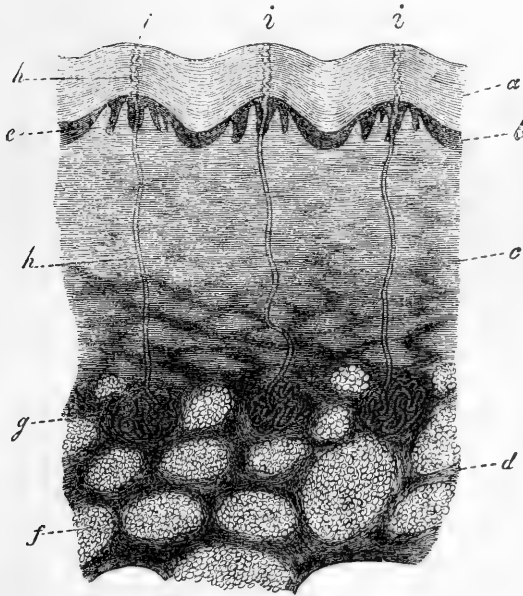


Fig. 156.

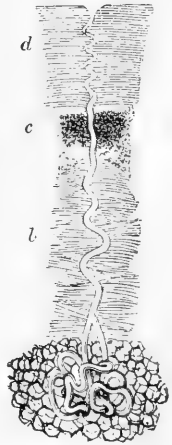


Fig. 155.—VERTICAL SECTION OF THE SKIN AND SUBCUTANEOUS TISSUE, FROM END OF THE THUMB, ACROSS THE RIDGES AND FURROWS, MAGNIFIED 20 DIAMETERS (Kölliker).

*a*, horny, and *b*, mucous layer of the epidermis; *c*, corium; *d*, *panniculus adiposus*; *e*, papillæ on the ridges; *f*, fat-clusters; *g*, sweat-glands; *h*, sweat-ducts; *i*, their openings on the surface.

Fig. 156.—MAGNIFIED VIEW OF A SWEAT-GLAND, WITH ITS DUCT (Wagner).

*a*, the gland surrounded by fat-cells; *b*, the duct passing through the corium; *c*, its continuation through the lower, and *d*, through the upper part of the epidermis.

true skin and cuticle, and opens on the surface by a slightly widened orifice. The duct, as it passes through the epidermis, is twisted like a corkscrew, that is, in parts where the epidermis is sufficiently thick to give room for this; lower down it is but slightly curved. Sometimes the duct is formed of two coiled-up branches which join at a short distance from the gland, as happens to be the case in the specimen represented in fig. 156. The tube, both in the gland and where it forms the excretory duct, consists of an investment of connective tissue, continuous with the corium, and reaching no higher than the surface of the true skin, a thin *membrana propria* and an epithelial lining, consisting of one or more strata of cells (often containing brownish pigment), and continuous with the epidermis, which alone forms the twisted part of the duct. The larger gland-ducts in the axilla, at the root of the penis, on the labia majora, and in the neighbourhood of the anus, contain between their coats a layer of non-striated

muscular fibre-cells arranged longitudinally. In the larger glands, moreover, the duct is rarely simple, being more usually parted by repeated dichotomous division into several branches, which before ending give off short caecal processes; in rare cases the branches anastomose. On carefully detaching the cuticle from the true skin, after its connection has been loosened by putrefaction, it usually happens that the cuticular linings of the sweat-ducts get separated from their interior to a certain depth, and are drawn out in form of short threads attached to the under surface of the epidermis. The coils of the gland-tube are loosely held together by connective tissue (fig. 157), which may form a sort of capsule round the body of the gland. Each little sweat-gland is supplied with a dense cluster of capillary blood-vessels.

Fig. 157.

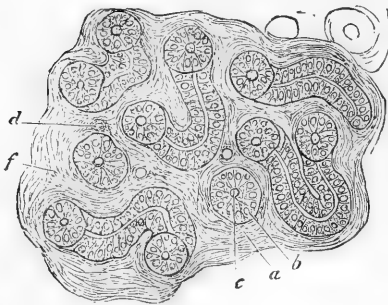


Fig. 157 —SECTION OF A SWEAT-GLAND. HIGHLY MAGNIFIED (Biesiadecki).

The tubules are seen variously cut. *a*, basement-membrane; *b*, lining cells; *c*, lumen of tube; *d*, blood-vessels and uniting connective tissue.

Each little sweat-gland is supplied with a dense cluster of capillary blood-vessels.

The contents of the smaller sweat-glands are fluid, without any formed elements; but in the larger sweat-glands of the axilla the contents are semi-fluid, and abound in fine pale granules and nuclei; or their secretion is extremely viscid, with a varying quantity of large, opaque, colourless, or yellow granules, with nuclei and cells, similar to epithelium-cells; and in both cases it may also contain fat.

**Distribution.**—Sweat-glands exist in all regions of the skin, and attempts have been made to determine their relative amount in different parts, for they are not equally abundant everywhere; but, while it is easy to count their numbers in a given space on the palm and sole, the numerical proportion assigned to them in most other regions must be taken with considerable allowance. According to Krause, nearly 2800 open on a square inch of the palm of the hand, and somewhat fewer on an equal extent of the sole of the foot. He assigns rather more than half this number to a square inch on the back of the hand, and not quite so many to an equal portion of surface on the forehead, and the front and sides of the neck; then come the breast, abdomen, and fore-arm, where he reckons about 1100 to the inch, and lastly, the lower limbs and the back part of the neck and trunk, on which the number in the same space is not more than from 400 to 600.

The size of the sweat-glands also varies. According to the observer last named, the average diameter of the round-shaped ones is about one-sixth of a line; but in some parts they are larger than this—as, for example, in the groin, but especially in the axilla. In this last situation Krause found the greater number to measure from one-third of a line to a line, and some nearly two lines in diameter.

The development of the sweat-glands has been carefully studied by Kölliker. Their rudiments, when first discoverable in the embryo, have much the same appearance as those of the hairs, and, in like manner, consist of processes of the mucous layer of the epidermis, which pass down and are received into corresponding recesses of the corium. They are formed throughout of cells collected into a solid mass of an elongated pyriform, or rather club shape, continuous by its small end with the soft layer of the cuticle, and elsewhere surrounded by a homo-



geneous limiting membrane, which is prolonged above between the corium and cuticle. The subsequent changes consist in the elongation of the rudimentary gland, the formation of a cavity along its axis—at first without an outlet—the prolongation of its canal through the epidermis to open on the surface, and, in the meantime, the coiling up of the gradually lengthening gland-tube into a compact ball, and the twisting of the excretory duct as it proceeds to the orifice. The original homogeneous membrane of the duct becomes thickened and is continuous with the surface of the corium, whilst an epithelium appears within, consisting of several layers of polyhedral or rounded cells.

The ceruminous glands in the auditory passage consist of a tube coiled into a ball, like the sweat-glands; and Kölliker's investigations show such a further correspondence between the two, in structure and mode of development as to lead him to regard the ceruminous glands as a mere local variety of the sudoriferous, which present specialities both of structure and secretion in particular regions of the body.

The **sebaceous glands** (fig. 158) pour out their secretion at the roots of the hairs, for, with very few exceptions, they open into the hair-follicles, and are found wherever there are hairs. Each has a small duct, which opens at a short distance within the mouth of the hair-follicle, and by its other end, leads to a cluster of small rounded secreting saccules, which as well as the duct are lined by epithelium, and usually charged with the fatty secretion, mixed with detached epithelium-particles. The number of saccular recesses connected with the duct usually varies from four or five to twenty; it may be reduced to two or three, in very small glands, or even to one, but this is rare. These glands are lodged in the substance of the corium. Several may open into the same hair-follicle, surrounding it on all sides, and their size is not regulated by the magnitude of the hair. Thus, some of the largest are connected with the fine downy hairs on the alæ of the nose and other parts of the face, and there they often become unduly charged with pent-up secretion.

**Development of the sebaceous glands.**—The rudiments of the sebaceous glands sprout like little buds from the sides of the hair-follicles; they are at first, in fact, excrescences of the external or mucous layer of the root-sheath (fig. 159), and are composed entirely of nucleated cells. Each little process soon assumes a flask shape and is at first solid; but in due time a group of cells containing fat particles appears in its centre, and gradually extends itself along the

Fig. 158.

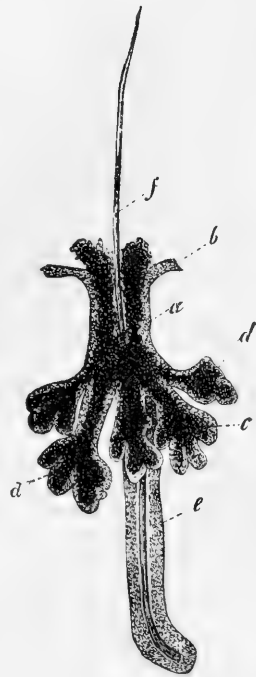


Fig. 158.—SEBACEOUS GLAND FROM THE FACE WITH BRANCHED DUCT, OPENING INTO A HAIR-FOLLICLE, MAGNIFIED 50 DIAMETERS (from Kölliker).

*a*, epithelium continuous with *b*, the mucous layer of epidermis; *c*, contents of gland; *d, d*, the groups of saccules on the branches of the duct; *e*, hair-follicle; *f*, hair.

axis of the pedicle until it penetrates through the root-sheath, and the fat-cells thus escape into the cavity of the hair-follicle, and constitute the first secretion of the sebaceous gland. They are soon succeeded by others of the same kind, and the little gland is established in its office. Additional saccules and recesses, by which the originally simple cavity of the gland is complicated, are formed by budding out of its epithelium, as the first was produced from the epithelial root-sheath, and are excavated in a similar manner.

Fig. 159.

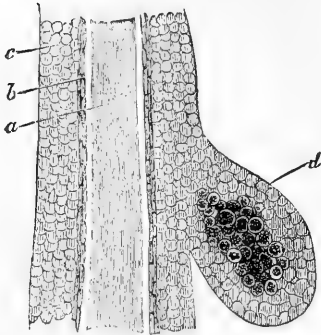


Fig. 159.—DEVELOPMENT OF A SEBACEOUS GLAND IN A SIX MONTHS' FÆTUS, 250 DIAMETERS (Kölliker).

*a*, hair; *b*, inner root-sheath; *c*, outer root-sheath of hair-follicle; *d*, rudiment of sebaceous gland.

It would thus appear that the rudiments of the hair-follicles, sweat-glands, and sebaceous glands, are all derived from the same source. They all originally appear as solid bud-like excrescences of the soft Malpighian or mucous layer of the epidermis, (for the outer stratum of the root-sheath must be regarded as such); these grow down into the corium, in which recesses are formed to receive them, and which, of course, yields the material required both for the production of new cells, for their further growth, and for the maintenance of their secreting function.

**Functions and vital properties of the skin.**—The skin forms a general external tegument to the body, defining the surface, and coming into relation with foreign matters externally, as the mucous membrane, with which it is continuous and in many respects analogous, does internally. It is also a vast emunctory, by which a large amount of fluid is eliminated from the system, in this also resembling certain parts of the mucous membrane. Under certain conditions, moreover, it performs the office of an absorbing surface, but this function is greatly restricted by the epidermis. Throughout its whole extent the skin is endowed with *tactile sensibility*, but in very different degrees in different parts. On the skin of the palm and fingers, which is largely supplied with nerves and furnished with numerous prominent papillæ, the sense attains a high degree of acuteness; and this endowment, together with other conformable arrangements and adaptations, invests the human hand with the character of a special organ of touch. A certain though low degree of vital contractility, depending doubtless on the muscular fibres in its tissue, also belongs to the skin. This shows itself in the general shrinking of the skin caused by naked exposure to cold and by certain mental emotions, and producing the state of the surface named "*cutis anserina*," in which the muscular bundles protrude the hair-follicles with which they are connected, whilst they retract or depress the intermediate cutaneous tissue; and this condition of the skin may be produced locally by the electric stimulus applied by means of the magneto-electric apparatus. The scrotum, as is well known, becomes shrunk and corrugated by the application of cold or mechanical irritation to its surface; but in this case the contraction takes place in the subcutaneous tissue and the skin is puckered.

**Reproduction of skin.**—When a considerable portion of the skin is lost, the breach is repaired partly by a drawing inwards of the adjoining skin, and partly by the formation of a dense tissue, less vascular than the natural corium, and in which, so far as we know, hairs and glands are not reproduced, so that some deny that the cutaneous tissue is regenerated. Still the new part becomes covered with epidermis, and its substance sufficiently resembles that of the corium to warrant its being considered as cutaneous tissue regenerated in a simple form. In small breaches of continuity from cuts inflicted in early life, the uniting part sometimes acquires furrows similar to those of the adjoining surface.

When a considerable portion of the skin is lost, the breach is repaired partly by a drawing inwards of the adjoining skin, and partly by the formation of a dense tissue, less vascular than the natural corium, and in which, so far as we know, hairs and glands are not reproduced, so that some deny that the cutaneous tissue is regenerated. Still the new part becomes covered with epidermis, and its substance sufficiently resembles that of the corium to warrant its being considered as cutaneous tissue regenerated in a simple form. In small breaches of continuity from cuts inflicted in early life, the uniting part sometimes acquires furrows similar to those of the adjoining surface.

## SECRETING GLANDS.

The term gland has been applied to various objects, differing widely from each other in nature and office, but the organs of which it is proposed to consider generally the structure in the present chapter, are those devoted to the function of secretion.

By secretion is meant a process in an organised body, by which various matters, derived from the organism, are collected and discharged at particular parts, in order to be further employed for special purposes in the economy, or to be simply eliminated as redundant material or waste products. Of the former case, the saliva and gastric juice, and of the latter, which by way of distinction is often called "excretion," the urine and sweat may be taken as examples.

Secretion is very closely allied to nutrition. In the one process, as in the other, materials are selected from the general mass of blood and appropriated by textures and organs; but in the function of nutrition or assimilation, the appropriated matter is destined, for a time, to constitute part of the texture or organ, whereas in secretion it is immediately discharged at a free surface. The resemblance is most striking in those cases in which the waste particles of the texture nourished are shed or cast off at its surface, as in the cuticle and other epithelial tissues.

In man, and in animals which possess a circulating blood, that fluid is the source whence the constituents of the secretions are proximately derived; and it is further ascertained, that some secreted matters exist ready formed in the blood, and require only to be *selected* and separated from the general mass, whilst others would seem to be *prepared* from the materials of the blood, by the agency of the secreting organ. Among the secreted substances belonging to the former category, several, such as water, common salt, and albumen, are primary constituents of the blood; but others, as urea, uric acid, and certain salts, are the result of changes, both formative and destructive, which take place in the solid textures and in the blood itself, in the general process of nutrition. Again, as regards those ingredients of the secretions which are prepared or elaborated in the secretory apparatus, it is to be observed, that the crude material may undergo changes in organic form, as well as in chemical composition. Evidence of this is afforded by the solid corpuscles found in many secretions, as well as by the seminal cells and spermatozoa produced in the testicle.

In the structural adaptations of a secreting apparatus, it is in the first place provided that the blood-vessels approach some free surface from which the secretion is poured out. The vessels, however, do not open upon the secreting surface, for their coats, as well as the tissue covering them, are permeable to liquids; and the most favourable conditions for the discharge of fluid are ensured by the division of the vessels into their finest or capillary branches, and by the arrangement of these capillaries in close order, as near as possible to the surface. In this way, their coats are reduced to the greatest degree of tenuity and simplicity, and the blood, being divided into minute streams, is extensively and thoroughly brought into contact with the permeable parietes of its containing channels, as well as effectually and, by reason of its slow motion, for a long time exposed to those influences, whether operating from within or without the vessels, which promote transudation.

Such a simple arrangement as that just indicated is sufficient for the

separation of certain substances from the general mass of the blood ; for the coats of the vessels and tissue superjacent to them are not permeated with equal facility by all its constituents ; and in certain cases the elimination of fluid in the animal body is effected without the necessary aid of any more complicated apparatus. Thus, the exhalation of carbonic acid and watery vapour from the interior of the lungs and air-passages, is probably produced in this simple manner, although the structure of the exhaling membrane is, for other reasons, complex ; and the discharge of fluid into cavities lined by serous membranes, which is known to be preternaturally increased by artificial or morbid obstruction in the veins, may be a case of the same kind.

But another element is almost always introduced into the secreting structure, and plays an important part in the secretory process ; this is the nucleated cell. A series of these cells, which are usually of a spheroidal, polyhedral, or columnar figure, is spread over the secreting surface, in form of an epithelium, which rests on a simple membrane, named the basement-membrane, or *membrana propria*. This membrane, itself extravascular, limits and defines the vascular secreting surface ; it supports and connects the cells by one of its surfaces, whilst the other is in contact with the blood-vessels, and it may very possibly, also, minister, in a certain degree, to the process of secretion, by allowing some constituents of the blood to pass through it more readily than others. But the cells are the great agents in selecting and preparing the special ingredients of the secretions. They attract and imbibe into their interior those substances which, already existing in the blood, require merely to be segregated from the common store and concentrated in the secretion, and they, in certain cases, convert the matters which they have selected into new chemical compounds, or lead them to assume organic structure. A cell thus charged with its selected or converted contents yields them up to be poured out with the rest of the secretion—the contained substance escaping from it either by exudation or by bursting and destruction of the cell itself. Cells filled with secreted matter may also be detached, and carried out entire with the fluid part of the secretion ; and, in all cases, new cells speedily take the place of those which have served their office. The fluid effused from the blood-vessels, no doubt, supplies matter for the nutrition of the secreting structure, besides affording the materials of the secretion, the residue, when there is any, being absorbed.

Examples illustrative of the secreting agency of cells, are afforded both by plants and animals. Thus cells are found in the liver of various animals, and especially of crustaceans and mollusks, some of which contain a substance resembling coloured biliary matter, and others particles of fat. In the urinary organ of mollusks, cells are seen which inclose little opaque masses of uric acid. In mucous glands, the product (mucus) remains in the intervals of secretion stored up within the cells (Watney). The secretion of the sebaceous follicles in man often contains detached cells filled with fat ; and, according to Goodsir's observation, the ink-bag of the cuttle-fish is lined with an epithelium, the constituent cells of which are charged with pigment similar to that which imparts the dark colour to the inky secretion. This last instance, as well as the production of spermatozoa, is an example of the formation of new products within secreting cells, a process further illustrated in plants, which afford abundant and decided evidence of the production

of young cells, spermatic filaments, starch-granules, oil, various colouring matters, and other new compounds, in the interior of cells.

Both in animals and plants, the individual cells which are associated together on the same secreting surface may differ from each other in the nature of their contents. Thus, in the liver of mollusca some cells contain biliary matter, and others contain fat; and in the recent soft part of the epidermis and its appendages, it is quite common to see cells filled with pigment mixed with others which are colourless.

A secreting apparatus, effectual for the purpose which it is essentially destined to fulfil, may thus be said substantially to consist of a simple membrane, named the *membrana propria* or basement-membrane

Fig. 160.



Fig. 160.—PLAN OF A SECRETING MEMBRANE.

*a*, *membrana propria* or basement-membrane; *b*, epithelium, composed of secreting nucleated cells; *c*, layer of capillary blood-vessels.

(marked *a* in the plan, fig. 160), supporting a layer of secreting cells on one of its surfaces (indicated by the dotted line *b*, in the figure), whilst finely ramified blood-vessels are spread over the other (*c*). But whilst the structure may remain essentially the same, the configuration of the secreting surface, or (what amounts to the same thing) of the supporting basement-membrane, presents various modifications in different secreting organs. In some cases, the secreting surface is plain, or, at least, expanded, as in various parts of the serous, synovial, and mucous membranes, which may be looked on as examples of comparatively simple forms of secreting apparatus; but, in other instances, and particularly in the special secretory organs named glands, the surface of the secreting membrane is variously involved and complicated. An obvious, and no doubt a principal, purpose of this complication is to increase the extent of the secreting surface in a secreting organ, and thus augment the quantity of secretion yielded by it. No connection has been clearly shown to exist between the *quality* of the secretion and the particular configuration, either internal or external, of the organ; on the other hand, we know that the same kind of secretion that is derived from a complex organ in one animal, may be produced by an apparatus of most simple form in another.

The more immediate purpose of the complication of the secreting membrane being to augment its surface within a comparatively circumscribed space, there are two principal modes by which the membrane is so increased in extent, namely, by rising or protruding in form of a prominent fold or some otherwise shaped projection (fig. 161, *d*, *e*), or by retiring, in form of a recess (fig. 162, *g*, *h*).

The first-mentioned mode of increase, or that by *protrusion*, is not what is most generally followed in nature, still it is not without example, and, as instances, we may cite the Haversian fringes of the synovial membranes, the urinary organ of the snail, which is formed of membranous lamellæ, and perhaps, also, the choroid plexuses in the

brain, and the ciliary processes in the eye-ball, although secretion may not be the primary office of the last-mentioned structures. In most of these cases, the membrane assumes the form of projecting folds, which, for the sake of further increase of surface, may be again plaited and complicated, or cleft and fringed, at their borders (fig. 161, *e, f*).

The plan of augmenting the secreting surface by *recession* or *inversion* of the membrane, in form of a cavity, is, with few exceptions, that

Fig. 161.



Fig. 161.—PLAN TO SHOW AUGMENTATION OF SURFACE BY FORMATION OF PROCESSES.

*a, b, c*, as in preceding figure; *d*, simple, and *e, f*, branched or subdivided processes.

generally adopted in the construction of secreting glands. The first degree is represented by a simple recess (fig. 162, *g, h*), and such a recess, formed of secreting membrane, constitutes a *simple* gland. The shape of the cavity may be tubular (*g*) or saccular (*h*), and, in either case, it is called indifferently a *crypt*, *follicle*, or *lacuna*, for these names have not been strictly distinguished in their application. Examples of these simple glands are found in the mucous membrane of the stomach, intestines, and uterus. The secreting surface may be increased, in a simple tubular gland, by mere lengthening of the tube, in which case, however, when it acquires considerable length, the tube is coiled up into a ball (fig. 162, *i*), so as to take up less room, and adapt itself to receive compactly ramified blood-vessels. The sweat-glands, already described, and the ceruminous glands of the ear are instances of simple glands formed of a long convoluted tube. But the great means adopted for further increasing the secreting surface is by the subdivision, as well as extension, of the cavity, and when this occurs the gland is said to be *compound*. There is, however, a condition which might be looked on as a step between the simple and compound glands, in which the sides or extremity of a simple tube or sac become pouched or loculated (fig. 162, *k, l*). This form might be named the *multilocular crypt*.

In the compound glands, the divisions of the secreting cavity may assume a tubular or a saccular form, and this leads to the distinction of these glands into the "tubular," and the "saccular," or "racemose."

The *racemose* compound glands (fig. 162, *c*) contain a multitude of saccules, opening in clusters, into the extremities of a branched tube, named the excretory duct. The saccules are rounded, pyriform or thimble-shaped, and then often named "cæcal." They are as usual formed by a proper or basement-membrane, and lined, or often rather filled with secreting cells; they are arranged in groups, round the commencing branches of the duct, into which they open both terminally and laterally (fig. 162, *c, n*); or it might with equal truth be said that the branches of the duct are distended into clusters of saccular dilatations. The ultimate branches of the duct open into larger branches (*o*),

these into larger again, till they eventually terminate in one or more principal excretory ducts (*m*), by which the secretion is poured out of

Fig. 162.

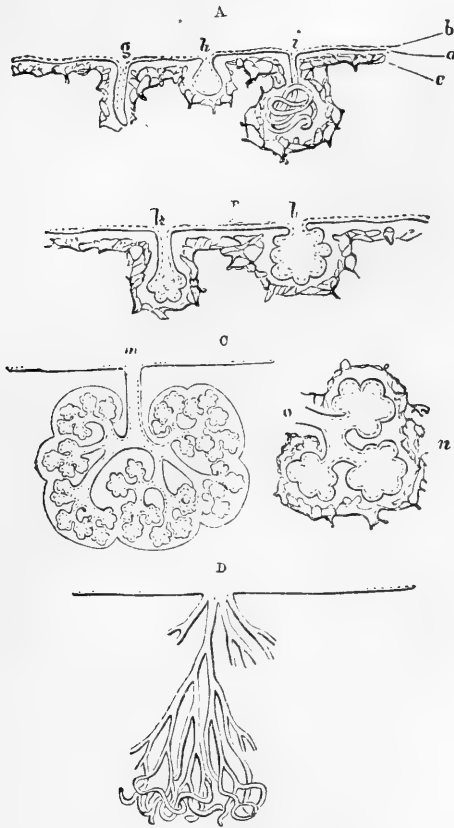


Fig. 162.—PLANS OF EXTENSION OF SECRETING MEMBRANE, BY INVERSION OR RESSION.

A, simple glands, viz., *g*, straight tube; *h*, sac; *i*, coiled tube. B, multilocular crypts; *k*, of tubular form; *l*, saccular. C, racemose, or saccular compound gland; *m*, entire gland, showing branched duct and lobular structure; *n*, a lobule, detached with *o*, branch of duct proceeding from it. D, compound tubular gland.

the gland. It is from the clustered arrangement of their ultimate vesicular recesses that these glands are named "racemose" (in German "traubenförmige Drüsen"); and they, for the most part, have a distinctly lobular structure. The lobules are held together by the branches of the duct to which they are appended, and by interlobular connective tissue which also supports the blood-vessels in their ramifications. The larger lobules are made up of smaller ones, these of still smaller, and so on for several successions. The smallest lobules (*n*) consist of two or three groups of saccules, with a like number of ducts, joining into an immediately larger ramuscule (*o*), which issues from the lobule; and

a collection of the smallest lobules, united by connective tissue and vessels, forms one of the next size, which, too, has its larger branch of the duct, formed by the junction of the ramuli belonging to the ultimate lobules. In this way, the whole gland is successively made up, the number of its lobules and of the branches of its duct depending on its size; for whilst some glands of this kind, like the parotid and pancreas, consist of innumerable lobules, connected by a large and many-branched duct, others, such as the duodenal glands of Brunner and many mucous glands, are formed of but two or three ultimate lobules, or even of a single one, with a duct, minute in size and sparingly branched, to correspond. In fact, a small racemose gland resembles a fragment of a larger one.

The ultimate saccules of a racemose gland or *alveoli*, as they are commonly termed, are almost entirely filled by the secreting cells, only a small cavity being left in the centre communicating with the excretory duct. It would appear, however, that in many cases at least, minute canals lead from the central cavity between the cells, and these may aid in the conveyance of the secretion of the latter towards the duct. It is doubtful whether these intercellular channels have proper walls or are merely formed by the juxtaposition of grooves on the adjacent sides of the cells. Further—the flattened cells which compose the basement-membrane have delicate lamellar processes extending between the alveolar cells, among which they appear to form a sustentacular network (Boll, Ebner).

A great many compound glands, yielding very different secretions, belong to the racemose class. As examples, it will be sufficient to mention the pancreas, the salivary, lachrymal, and mammary glands, with the glands of Brunner already referred to, and most of the small glands which open into the mouth, fauces, and windpipe. From the description given of their structure, it will be understood why the term “conglomerate glands” has been applied especially though not exclusively, to this class. Their smallest lobules were called *acini*, a term which has also been used to denote the saccular recesses in the lobules, and indeed the word *acinus*, which originally meant the seed of a berry or the stone of a grape, or sometimes the grape itself, has been so vaguely applied by anatomists, that it seems better to discard it altogether.

Of the *tubular* compound glands, the most characteristic examples are the testicle and kidney. In these the tubular ducts divide again and again into branches, which, retaining their tubular form, are greatly lengthened out. The branches of the ducts are, as usual, formed of a limitary or basement-membrane (*membrana propria*), lined by epithelium, and in contact, by its opposite surface, with capillary blood-vessels. By the multiplication and elongation of the tubular branches a vast extent of secreting surface is obtained, whilst to save room, the tubes are coiled up into a more or less compact mass, which is traversed and held together by blood-vessels, and sometimes, also, divided into lobules and supported, as in the testicle, by fibrous partitions, derived from the inclosing capsule of the gland. In consequence of their intricately involved arrangement, it is difficult to find out how the tubular ducts are disposed at their extremities. It seems probable, however, that some are free, and simply closed without dilatation, and that others anastomose with neighbouring tubes, joining with them in



form of loops; in the kidney, little round tufts of fine blood-vessels project into terminal or lateral dilatations of the ducts, but without opening into them.

The human liver does not precisely agree in structure with either of the above classes of compound glands. Its ducts, which are neither coiled nor sacculated, would seem to begin within its lobules, in form of a network of excessively fine channels which run between the sides of contiguous polyhedral cells, and these occupy the interstices of the reticular capillary blood-vessels, which also are peculiar, inasmuch as they receive and transmit venous blood.

Besides blood-vessels, the glands are furnished with lymphatics, which in some compound glands proceed from interstitial lymphatic spaces within, as already stated (p. 185). Branches of nerves have also been followed, for some way, into these organs, and the well-known fact, that the flow of secretion in several glands is affected by mental emotions, shows that an influence is exerted on secreting organs through the medium of the nervous system; and this is further shown by the fact that an increased flow may be brought on by direct or reflex stimulation of their nerves. Moreover, fine non-medullated nervous fibres have in several instances been described as forming a network between the alveolar cells; and in the salivary glands, Pflüger has affirmed a direct passage of nerve-fibres, both medullated and non-medullated, into the secreting cells: his observations, however, have not been corroborated by other inquirers.

From what has been stated, it will be apparent that the substance of a gland consists of the ducts, blood-vessels, lymph-vessels and lacunæ, and a few nerves, in some cases connected by an intervening tissue. In the testicle there is a very small amount of intermediate connective tissue, which, with the aid of the blood-vessels, holds the tubules but feebly together, so that the structure is comparatively loose, and readily admits of being teased out; but then it is sufficiently protected and supported by a fibrous capsule on the outside, and fibrous septa within the gland. In the racemose glands there is a good deal of uniting connective tissue, which surrounds collectively each group of saccules, binds together the lobules, and supports the vessels in their ramifications. The substance of the kidney contains scarcely any well-characterised fibrous connective tissue, except bundles which here and there accompany the larger branches of vessels, but there is an abundant, though very delicate, network of retiform tissue in a soft amorphous matter between the tubules and blood-vessels, which binds them together.

*Parenchyma* is a term sometimes employed in describing glandular organs, though it is less in use now than formerly. It is used sometimes to denote the solid part of a gland composed of the various tissues already mentioned; at other times to signify any substance, of whatever nature, lying between the ducts, vessels, and nerves. In this last sense the parenchyma is in certain glands represented by connective tissue, in others by corpuscles and amorphous matter, whilst in some it can scarcely be said to exist.

Some glands have a special envelope, as in the case of the kidney and testicle; others, as the pancreas, have none.

The ducts of glands ultimately open into cavities lined by mucous membrane, or upon the surface of the skin. They are sometimes provided with a reservoir, in which the secretion is collected, to be

discharged when the purposes of the economy so demand. The reservoir of the urine receives the whole of the secreted fluid; in the gall-bladder, on the other hand, only a part of the bile is collected. The vesiculæ seminales afford another example of these laterally appended reservoirs. The ducts are constructed of a basement-membrane and lining of epithelium, and in their smaller divisions there is nothing more; but in the larger branches and trunks a fibro-vascular layer is added, as in the ordinary mucous membrane, with which many of them are continuous, and with which they all agree in nature. A more or less firm outer coat, composed of connective tissue, comes in many cases, to surround the mucous lining, and between the two, or, at any rate, outside the mucous coat, there is in some ducts a deposit of non-striated muscular tissue. The epithelium is usually composed of spheroidal or polyhedral cells at the commencement of the ducts, and is columnar in the rest of their length, though sometimes flattened or scaly, as in the mammary gland.

#### DUCTLESS . OR VASCULAR GLANDS.

There are certain bodies which have received the name of glands on account of their resemblance in general appearance and structure to the ordinary secreting organs. They differ, however, from the latter in the fact of their possessing no ducts for the discharge of secretion; so that their elaborated products must be conveyed into the blood by lymphatic or sanguiferous vessels, with both of which they are for the most part abundantly provided. The bodies in question have been termed "ductless" for this obvious anatomical reason: and "vascular," on certain physiological or theoretic grounds, as they are supposed to effect some change in the blood which is transmitted through them.

To this class belong the following bodies:—the spleen, the thyroid body, thymus gland, suprarenal capsules, pituitary body, the solitary closed follicles of the intestines, the Peyerian glands, the follicular glands at the root of the tongue, and also the lymphatic glands.

The purposes fulfilled by certain of the organs enumerated are still involved in great obscurity, but the majority have apparently the same fundamental constitution. They are essentially made up of corpuscles having the character of lymph- or pale blood-corpuscles, included and supported by retiform connective tissue, traversed throughout by sanguiferous capillaries, and provided with numerous and large lymphatic vessels: their constituent substance, in fact, agrees in structure with what has already been described as lymphoid tissue. This is in some cases formed into small rounded bodies or pellets, which may be either closely grouped together to form the lobules of a gland-like organ (thymus) or distributed in other tissues (follicular glands of mucous membrane, Malpighian corpuscles of the spleen): in other cases the lymphoid substance is in large masses, which may take on a more or less reticular arrangement, with lymph-sinuses occupying the interstices of the network (lymphatic glands).

Some of the organs in question, for example, the thyroid gland, differ altogether from the rest, except in the absence of ducts. The account of these and of the specialities of the "lymphoid" organs is reserved for the part of this work devoted to special anatomy.

# SPECIAL ANATOMY OF THE VISCERA.

## THE THORACIC VISCERA.

The greater part of the thorax is occupied by the lungs, each of which is invested by a serous membrane, the *pleura*. The heart, enclosed by a membranous covering, the *pericardium*, is situated between the lungs in the middle of a space bounded laterally by the right and left pleuræ, and known as the mediastinal space, the septum formed by the union of the two pleuræ being termed the *mediastinum*. The term *anterior mediastinum* is given to the part of this septum in front of the heart and pericardium, and *posterior mediastinum* to the part behind, while that portion which encloses the pericardium is sometimes distinguished as the *middle mediastinum*.

The **anterior mediastinum** (fig. 163, 2), which is of no great depth, is situated in front of the pericardium, between it and the sternum. At its superior part the two layers of pleuræ separate somewhat to enclose the vestiges of the thymus gland; behind the second piece of the sternum they are in contact, but below this the left pleura recedes from its fellow towards the left side, leaving an angular space of some breadth. The *triangularis sterni* muscle bounds this space in front.

The **posterior mediastinum**, stretching from the pericardium to the bodies of the vertebræ, encloses between its layers the lower part of the windpipe and gullet (fig. 163 *a*) the thoracic duct (*d*), the descending aorta (*a*), the azygos vein (*v.a*), and the pneumogastric nerves (*p.n*), together with some lymphatic glands.

## THE PERICARDIUM.

This membranous sac, in which the heart is contained, is of a somewhat conical shape, its base resting on the diaphragm, whilst the upper narrower part surrounds the great vessels as far as their first divisions. It consists of two layers, one external and fibrous, the other internal and serous.

The **fibrous** layer is a dense, unyielding membrane, consisting of fibres which interlace in every direction. At the base of the pericardium this fibrous layer is attached to the upper surface of the diaphragm (fig. 164 *b*), partly to the central tendon, partly to the adjoining muscular surface, especially on the left side. Over a small space near the median line the fibrous structures are continuous, and the connection very firm; elsewhere the attachment is more lax, and is effected mainly by areolar tissue. Above, where the pericardium embraces the large blood-vessels, the fibrous layer is continued for some

distance along them in the form of tubular prolongations, which become gradually lost upon their external coats. The superior vena cava, the four pulmonary veins, the aorta, and the right and left divisions of the pulmonary artery, in all eight vessels, receive investments of this kind.

Fig. 163.




Fig. 163.—TRANSVERSE SECTION OF THE CHEST OF A FETUS, ILLUSTRATING THE RELATIVE POSITION OF THE HEART AND LUNGS AND THE INFLECTIONS OF THE PERICARDIUM AND PLEURA (Allen Thomson after Luschka).

The sketch represents the upper surface of the lower section; the division is carried nearly in a horizontal plane on a level with the interval in front between the fifth and sixth ribs. *s*, the sternum; *c*, the body of the seventh dorsal vertebra; *h*, the right, and *h'*, the left ventricle; *a*, the œsophagus; *p n*, the left pneumogastric nerve; near these letters respectively, the root of the right and left lungs; the right pneumogastric nerve is behind the œsophagus; *a*, the aorta; *va*, the vena azygos; *d*, thoracic duct; 1, the cardiac pericardium; 2, in the anterior mediastinal space, the parietal pericardium; 2', the cavity of the pericardium; 3, the pulmonary pleuræ passing over the surface, and reflected at the roots of the lungs; 3', their cavity, and on the right side, the reflection at the mediastinum to the surface of the pericardium; 4, the parietal or costal pleuræ; *c, c*, the walls of the chest inclosing the ribs, pectoral muscles, &c.

The **serous** layer not only lines the fibrous layer of the pericardium, but, like other serous membranes, is reflected on the surface of the viscus which it invests. It has, therefore, a visceral and a parietal portion. The parietal portion adheres firmly to the fibrous membrane, and becomes continuous with the visceral portion upon the arch of the aorta and other great vessels, about 2 or 2½ inches from the base of the heart. In passing round the aorta and pulmonary artery, it encloses those vessels in a common short tubular sheath

(fig. 164, 5, 5). It is reflected also upon the superior vena cava (*c*), and on the four pulmonary veins (*p*, *p'*), and forms a deep recess or prolonged cavity between the entrance of the right and left veins into the left auricle. The inferior vena cava (*c'*) receives only a

Fig. 164.

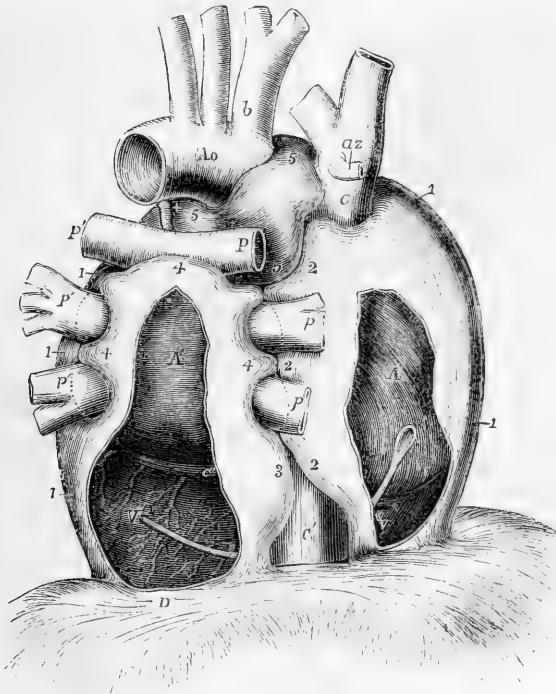


Fig. 164.—SEMI-DIAGRAMMATIC VIEW OF THE PERICARDIUM FROM BEHIND, DESIGNED TO SHOW THE PRINCIPAL INFLEXIONS OF THE SEROUS SAC ROUND THE GREAT VESSELS (Allen Thomson). ONE-HALF THE NATURAL SIZE.

The drawing is taken from preparations in which the heart and vessels had been partially filled by injection, the pericardium inflated and dried in the distended state, and the fibrous continuation on the vessels removed. By the removal of a portion of the pericardium from behind the right and left cavities of the heart, the position of that organ is made apparent. A bent probe is passed within the pericardium from behind the right auricle, in front of the vena cava inferior, to the back of the left ventricle, which may indicate the place where the large undivided sac of the pericardium is folded round that vein. *A*, posterior surface of the right auricle; *A'*, the same of the left; *V*, right ventricle; *V'*, left ventricle; *Ao*, the upper and back part of the aortic arch; *b*, innominate artery; *C*, vena cava superior; *az*, azygos vein; *C'*, vena cava inferior between the diaphragm and its union with the right auricle; *c'*, great coronary vein; +, cord of the ductus arteriosus; *P*, the right, *P'*, the left pulmonary artery; *p*, the right, *p'*, the left pulmonary veins; *D*, the back of the central tendon of the diaphragm; *1*, sac of the pericardium as yet uninflected; *2*, portion of this on the right side which partially surrounds the vena cava superior, the upper and lower right pulmonary veins, and the vena cava inferior; *3*, the portion of the left side which partially surrounds the vena cava inferior; *4*, the portion which is extended upwards behind the left auricle, and partially folds over the pulmonary arteries and veins, and which meets between these different vessels the extensions of the main sac from the right and left; *5*, tubular portion of the pericardium which completely surrounds the aortic and pulmonary arterial trunks.

very scanty covering of this membrane (3, 2), inasmuch as that vessel enters the right auricle almost immediately after passing through the diaphragm, and is only partially surrounded by a reflection of the pericardium in the narrow interval between these parts. None of the vessels, indeed, joining the heart, with the exception of the aorta and pulmonary artery where they are united together, receive a complete covering from the pericardium, or can be said to be entirely enveloped by the sac. In structure the serous layer of the pericardium agrees with that of serous membranes generally, except that no apertures have as yet been discovered in it by which its cavity communicates with lymphatic vessels.

When the left pulmonary artery and subjacent pulmonary vein are separated, a fold of the pericardium will be seen between them, which has been termed by Marshall the "vestigial fold of the pericardium." It is formed by a duplicature of the serous layer, including areolar and fatty tissue, together with blood-vessels, and nerves, and is from half to three-quarters of an inch in length, and from half to one inch deep. It extends from the left superior intercostal vein above the pulmonary artery downwards to the side of the left auricle, where it is lost in a narrow streak which crosses round the lower left pulmonary vein. This fold is × a vestige of a *left superior vena cava* (duct of Cuvier), which exists in early embryonic life. (Marshall, "On the development of the great anterior veins in Man and Mammalia," *Philosoph. Trans.* 1850.)

The pericardium is in relation in front and behind with the mediastina and their contents. Anteriorly also it is overlapped by the pleuræ and to some extent by the lungs, except below, where it approaches the surface in the angular space to the left of the lower piece of the sternum. At the sides it is in contact with the *phrenic nerves*, as well as with the pleuræ and their contained viscera. Its relations to the diaphragm and great vessels have been already noticed.

### THE HEART.

The heart is a hollow muscular organ, divided by a longitudinal septum into a right and a left half, each of which is again subdivided by a transverse constriction into two compartments, communicating with each other, and named **auricle** and **ventricle**. Its general form is that of a blunt cone. Enclosed, as before said, in the pericardium, it is placed behind the sternum and the costal cartilages (fig. 174; on page 254), the broader end, or base, by which it is attached, being directed upwards, backwards, and to the right, and extending from the level of the fourth to that of the eighth dorsal vertebra; the apex downwards, forwards, and to the left. In the living subject its stroke against the wall of the chest is felt in the space between the cartilages of the fifth and sixth ribs, a little below and to the inner side of the left mammilla ( $3\frac{1}{4}$  inches from middle line of sternum and  $1\frac{1}{2}$  inch below nipple): in the dead body the apex is a little higher than during life. The heart, therefore, has a very oblique position in the chest, and projects farther into the left than into the right half of the cavity. Its position is affected to a certain extent by that of the body; thus it comes more into contact with the anterior wall of the chest when the body is in the prone posture or is lying on the left side. In inspiration, on the other hand, when the diaphragm sinks and the lungs expand, it recedes slightly from the chest-wall.

At its base the heart is attached to the great blood-vessels; moreover,

the serous layer of the pericardium is here reflected from the one to the other. In the remainder of its extent the organ is entirely free within the sac of the pericardium. The convex anterior surface looks somewhat upwards as well as forwards towards the sternum and costal cartilages: from these it is partly separated by the pleuræ. The lungs also advance over it to some extent, and encroach still farther during

Fig. 165.—VIEW OF THE HEART, AND GREAT VESSELS FROM BEFORE (R. Quain). ONE-THIRD THE NATURAL SIZE.

The pulmonary artery has been cut short close to its origin in order to show the first part of the aorta. 1, right ventricle; 2, left ventricle; 3, root of the pulmonary artery; 4, 4', arch of the aorta; 4'', the descending thoracic aorta; 5, the appendix and anterior part of the right auricle; 6, those of the left auricle; 7, 7', innominate veins joining to form the vena cava superior; 8, inferior vena cava below the diaphragm; 9, one of the large hepatic veins; +, placed in the right auriculo-ventricular groove, points to the right or posterior coronary artery; +, +, placed in the anterior interventricular groove, indicate the left or anterior coronary artery.

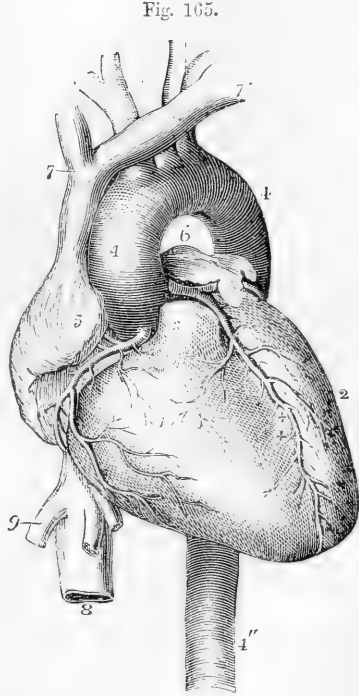


Fig. 165.

inspiration, so as in that condition to leave only a triangular part, not more than two square inches in extent, uncovered.\* The posterior or under surface is flattened, and rests on the diaphragm. Of the two borders or margins formed by the meeting of the anterior and posterior surfaces, the right or lower border, called *margo acutus*, is comparatively thin, and is longer than the upper or left border, which is more rounded and is named *margo obtusus*.

A deep transverse groove, the *auriculo-ventricular furrow*, interrupted in front by the root of the pulmonary artery, divides the heart into the auricular and the ventricular portions; and on the ventricular portion two *longitudinal furrows*, situated one on the anterior, the other on the posterior surface, mark its division into a right and left chamber. They extend from the base of the ventricular portion, and are continuous one with the other a little to the right of the apex, which thus appears to be formed entirely by the wall of the left ventricle. The anterior longitudinal furrow (fig. 165 + +) is nearer to the left border, whilst the posterior furrow approaches nearer to the right border of the heart, the right ventricle forming more of the anterior, and the left more of the posterior surface of the organ. In the transverse and longitudinal furrows run the coronary or cardiac

\* This uncovered part may be marked off on the surface of the chest by two lines drawn from the apex-point to the middle line of the sternum, one horizontal, the other extending obliquely upwards to between the fourth cartilages.

arteries and veins with lymphatic vessels and nerves, imbedded in fatty tissue.

#### CAVITIES OF THE HEART.

The heart, as before remarked, contains four chambers or compartments, a right and a left auricle and a right and a left ventricle.

Fig. 166.

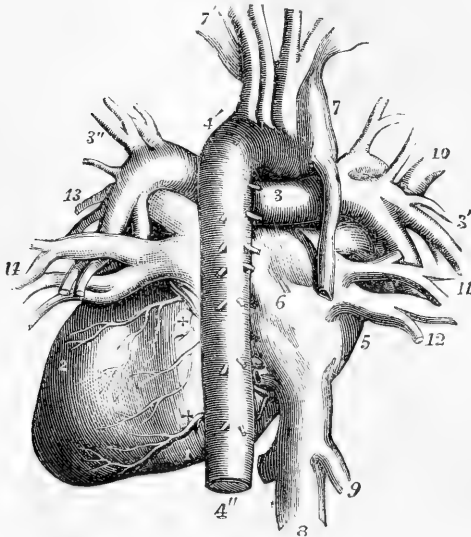


Fig. 166.—VIEW OF THE HEART AND GREAT VESSELS FROM BEHIND (R. Quain).

1, posterior surface of the right ventricle; 2, the same of the left; 3, the right pulmonary artery near the division of the primary trunk; 3', branches of the right pulmonary artery passing into the root of the right lung; 3'', the same of the left; 4, arch of the aorta; 4'', descending thoracic aorta; 5, right auricle; 6, is placed on the division between the right and left auricles; 7, superior vena cava; 7', left vena innominata; 8, trunk of the inferior vena cava; 9, right large hepatic vein; 10, 11, 12, right pulmonary veins; 13, 14, left pulmonary veins; +, +, posterior branches of the right and left coronary arteries.

The **right auricle** (fig. 165, 5) is best brought into view on turning the heart somewhat to the left side; it is then seen to occupy the right and anterior portion of the base of the organ. When thus viewed the auricle appears of a quadrangular form, the superior and inferior venæ cavæ (fig. 167, 1, 2), occupying respectively the upper and lower posterior angles, while a tongue-shaped portion, the *auricular appendix* or *auricle proper*,\* is seen to project from the anterior and upper angle and to turn to the left over the root of the aorta. The main part of the auricle, that into which the great veins directly pour their blood, is commonly named *sinus venosus* or *atrium*, to distinguish it from the auricular appendix. When opened, the interior of the right auricle presents a smooth and even surface, except in the appendix which is ridged vertically with closely set reticulated muscular bands, and upon the anterior wall of the sinus, where similar bundles are seen extending, but here running parallel with one another, like the teeth of a comb, and thence termed *musculi pectinati*.

The posterior wall corresponds with the partition between the two auricles (*septum auricularum*). Near its lower part and just above and to the left of the orifice of the inferior vena cava is an oval depression, the *fovea* or *fossa ovalis* (fig. 167, 3'), the remains of the *foramen ovale* (*vestigium foraminis ovalis*), which is an open passage in the foetal heart from the right to the left auricle. The *fossa ovalis* is bounded above and at the sides by a prominent border, deficient below, the *annulus*

\* So termed from its resemblance to the external ear of some animals.

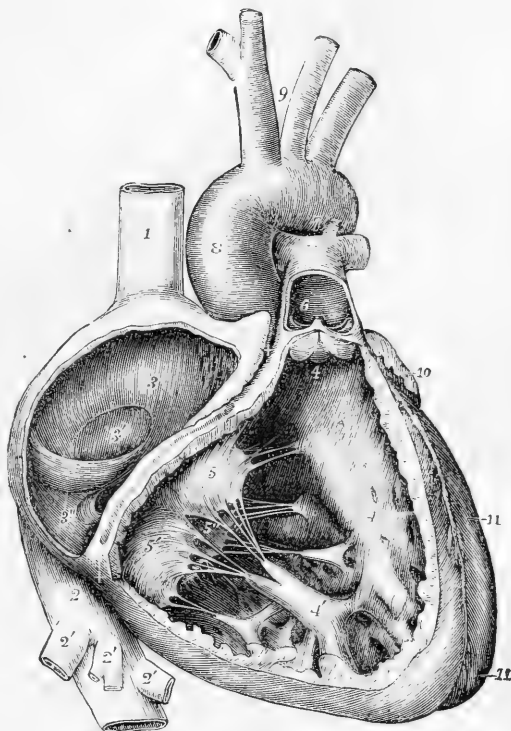


*oralis* or *isthmus Vieussenii*, whilst the floor of the fossa, formed by what was previously a valve, is thin and translucent; and occasionally a small oblique passage leading into the left auricle is left between it and the annular border. At the right part of the cavity are seen the orifices of the superior and inferior cavæ; the former passing down-

Fig. 167.—THE RIGHT AURICLE AND VENTRICLE OPENED AND A PART OF THEIR RIGHT AND ANTERIOR WALLS REMOVED SO AS TO SHOW THEIR INTERIOR (Allen Thomson). ONE-HALF THE NATURAL SIZE.

Fig. 167.

1, the superior vena cava; 2, the inferior vena cava at the place where it passes through the diaphragm; 2', the hepatic veins cut short; 3, placed upon the tubercle of Lower within the cavity of the right auricle; 3', placed in the fossa ovalis, the Eustachian valve is just below; 3'', is placed close to the aperture of the great coronary vein and its valve; +, +, the auriculo-ventricular groove, a narrow portion of the adjacent walls of the auricle and ventricle having been preserved; 4, 4, on the right side of the septum, the cavity of the right ventricle; 4', large anterior columna carnea; 5, the anterior; 5', the inferior, and 5'', the septal segment of the tricuspid valve; 6,



is placed in the interior of the pulmonary artery, a part of the anterior wall of that vessel having been removed, and a narrow portion of it preserved at its commencement where the pulmonary valve is attached. The valve is represented half-closed; two of the segments are seen foreshortened, the third sideways; 7, concavity of the aortic arch close to the cord of the ductus arteriosus; 8, ascending part or sinus of the arch covered at its commencement by the auricular appendix and pulmonary artery; 9, placed between the innominate and left common carotid arteries; 10, appendix of the left auricle; 11, 11, the outside of the left ventricle, the lower figure near the apex.

wards and forwards, the latter, the larger, being directed upwards and inwards. Between the two orifices is a slight projection, better marked in certain quadrupeds than in man, which has received the somewhat misleading name of *tubercle of Lower* (fig. 167, 3).

In front of the orifice of the inferior cava, and partly covering it, is a crescentic fold of the lining membrane, the *Eustachian valve*. This is continuous by its convexity with the margin of the venous orifice, and its anterior cornu is prolonged into the anterior limb of the annulus ovalis. This valve, which is very variable in character in the adult, being

often cribriform or perforated with holes, is an important structure in the foetal heart, and serves the purpose of directing the stream of blood from the inferior cava through the foramen ovale into the left auricle. The other openings into the right auricle are 1,—the *auriculo-ventricular aperture*, situate in front of the inferior vena cava and occupying the anterior and under part of the cavity: it is oval in form and large, admitting three fingers easily; 2, the *orifice of the large coronary vein* of the heart (fig. 167, 3''), situated between the inferior cava and the auriculo-ventricular opening: this is guarded by a semicircular valve, sometimes double, which, although previously figured by Eustachius, is often named valve of Thebesius; 3, *openings of one or two lesser cardiac veins* from the surface of the right ventricle; and 4, the *foramina of Thebesius*, a number of small pits variously situated, some of which are merely recesses closed at the bottom, whilst others are the mouths of small veins (*venae minime cordis*).

Fig. 168.

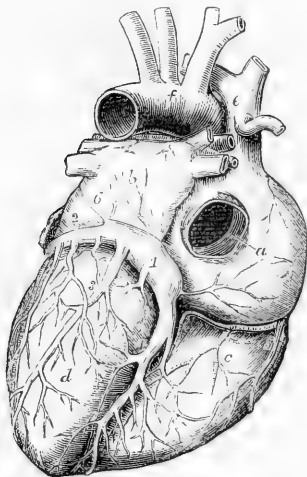


Fig. 168.—VIEW OF THE ADULT HEART, FROM BEHIND, TO SHOW THE CORONARY VEINS (Allen Thomson). ONE-THIRD THE NATURAL SIZE.

*a*, placed on the back of the right auricle, points to the Eustachian valve seen within the opening of the inferior vena cava; *b*, left auricle; *c*, right ventricle; *d*, left ventricle; *e*, vena cava superior; *f*, arch of the aorta; 1, coronary sinus; 2, great coronary vein turning round the heart in the auriculo-ventricular groove; 3, 4, posterior branches; 5, one of the small right cardiac veins passing directly into the right auricle; 6, the vestige of the left superior vena cava proceeding over the left auricle downwards to join the coronary sinus.

The coronary vein (fig. 168, 1) is considerably dilated before it enters the auricle, and this dilated portion, which is imbedded in the posterior wall of the left auricle, is termed the "coronary sinus." At the junction of the coronary vein with the dilated portion there is a valve consisting of one or two segments. Other

small veins likewise enter the coronary sinus, each of them protected by a valve. One of these small veins, the "oblique vein" of Marshall (fig. 168, 6), takes a straight course from the vestigial fold before mentioned, over the back of the left auricle, to open into the coronary sinus. This vein has no valve over its orifice: it, together with the coronary sinus, is to be looked upon as the remnant of the original left superior cava of the embryo (vide antea, p. 242).

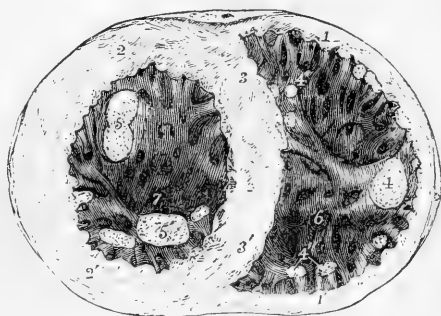The **right** or **anterior ventricle** (fig. 165, 1) occupies the chief part of the anterior surface of the heart, the right border, and a smaller portion of the posterior surface. It extends nearly, but not quite, to the apex. The upper and left angle is prolonged in a conical form to the commencement of the pulmonary artery: this part of the ventricle is named *conus arteriosus*, or *infundibulum*. The muscular wall of this ventricle is thickest at the base, and becomes thinner towards the apex. When the cavity is laid open (fig. 167) the septum of the heart is seen to bulge into it, so that the cross section is crescentic in form (fig. 169). At the base of the ventricle are two

orifices, protected by valves; the *auriculo-ventricular*, of an oval form, and situate towards the right, and that of the *pulmonary artery*, smaller, more elevated, and towards the left. Between the two the wall of the cavity projects downwards, in the form of a thick rounded muscular partition. The inner surface is marked by muscular bundles, "columnæ carneæ," some of which are attached by each extremity to the wall of the ventricle and are free in the middle, others are

Fig. 169.—CROSS SECTION OF THE VENTRICULAR PART OF THE HEART AT TWO-THIRDS FROM THE APEX LOOKING DOWNWARDS INTO THE CAVITIES (Allen Thomson). 2-3RDS THE NATURAL SIZE.

1, 1', Wall of the right ventricle; 2, 2', wall of the left; 3, 3', septum; 4, the principal papillary muscle of the right ventricle; 4', some columnæ carneæ on the septum near the front; 4'', others posteriorly near the septum; 5, 5', the principal papillary muscles of the left ventricle; 6, the deepest part of the cavity of the right ventricle; 7, that of the left ventricle at the apex of the heart.

Fig. 169.



only sculptured in relief, as it were, being continuous with the wall of the ventricle in their whole length; while a third set, forming two principal bundles, an anterior (fig. 167, 4') and a posterior, named *musculi papillares*, are connected at their base with the ventricular wall, and by the other end are attached to small tendinous cords (*chordæ tendineæ*), through which they are connected with the segments of the auriculo-ventricular valve. The inside of the *conus arteriosus* is smooth, and free from columnæ carneæ.

The valve guarding the right auriculo-ventricular opening is composed of three triangular segments, or flaps (anterior, right or inferior, and posterior, or septal), and is hence named the *tricuspid*. The flaps are mainly formed of folds of the endocardium, enclosing fibrous tissue. At their bases, they are continuous with one another, so as to form an annular membrane attached around the margin of the auricular opening: they are directed downwards, and are retained in position within the ventricle by the *chordæ tendineæ*, which are attached to their ventricular surfaces and free margins. The middle part of each segment is thicker than the rest, whilst the marginal part is thin, transparent, and jagged at the edges (compare fig. 173, B, e, e').

The *chordæ tendineæ* from the anterior papillary muscle pass to the cleft between the anterior and inferior segments, to be attached to both: the *chordæ tendineæ* from the posterior papillary muscle are attached in like manner to the posterior and inferior segments: while others forming a third set spring directly from the surface of the septum, sometimes from small eminences upon it, and pass upwards, to be attached to the adjacent borders of the anterior and posterior segments.

During the contraction of the ventricle, the segments of the valve are applied to the opening leading from the auricle, and prevent the blood from rushing back into that cavity. Being retained by the *chordæ tendineæ*, the expanded flaps of the valve resist the pressure of the blood, which would otherwise force

them back through the auricular orifice; the papillary muscles, shortening as the cavity of the ventricle itself shortens, are supposed thus to prevent the valve from yielding too much towards the auricle. In the angles between each pair of the principal segments of the auriculo-ventricular valves there may be found, but not constantly, as many small intermediate lobes.

According to Kürschner (Wagner's Handwörterbuch, art. "Herzthätigkeit"), three kinds of cords belong to each segment; *a*, the first set, generally two to four in number and proceeding from two different sets of papillae, or from one of these and the wall of the ventricle, run to the base or attached margin of the segment, and are there connected also with the tendinous ring round the auriculo-ventricular opening; *b*, the second set, more numerous, and smaller than the first, proceed also from two adjacent papillary muscular groups, and are attached at intervals to the back or ventricular surface of each segment along two or more lines extending from the points of attachment of the tendons of the first order at the base of the valve to near its free extremity; *c*, the third set, which are still more numerous and much finer, branch off from the preceding ones, and are attached to the back and edges of the thinner marginal portions of the valves. A few muscular fibres prolonged from the neighbouring walls penetrate into the segments of the auriculo-ventricular valves.

A fibrous band, sometimes muscular, is often found stretching across the cavity of the right ventricle from the base of the anterior papillary muscle to the septum. It represents the strong "moderator" band found in the heart of the ox and of some other animals.

The valve at the orifice of the pulmonary artery consists of three flaps, a right and left anterior and a posterior, named from their shape *semilunar* or *sigmoid* (figs. 167, 6; 172 I): \* they are constructed similarly to those on the left side at the root of the aorta: and as the characters of the last named are better marked, the more complete description will be reserved until these are treated of.

The **left auricle** (fig. 170, 1') occupies the left and posterior part of the base of the heart. The atrium presents from behind, where it is best seen, a quadrilateral appearance. In front it is in contact with the aorta and pulmonary artery; behind, it receives two pulmonary veins on each side, those from the left lung entering very close together; on the right, it is in contact with the other auricle. The *auricular appendage* (fig. 165, 6) is the only part of the left auricle seen from the front: it extends forwards from the left side of the atrium, and curves towards the right side, resting on the pulmonary artery. It is more curved as well as longer and narrower than that of the right auricle, and its margins are more deeply indented.

The interior of the appendix presents *musculi pectinati* somewhat similar to those in the right side of the heart, but the walls of the sinus venosus are altogether smooth and even, and are also thicker than those of the right auricle. Posteriorly the openings of the pulmonary veins are seen, usually two on each side, and without valves (fig. 170, 1). The two veins of one or both sides sometimes unite into one before entering the auricle, whilst in other cases there is found an additional opening, most frequently on the right side. In the lower and fore part of the auricle is situated the left *auriculo-ventricular* orifice. It is of an oval form, and is rather smaller than the corresponding opening between the right auricle and ventricle. On the septum between the auricles, a

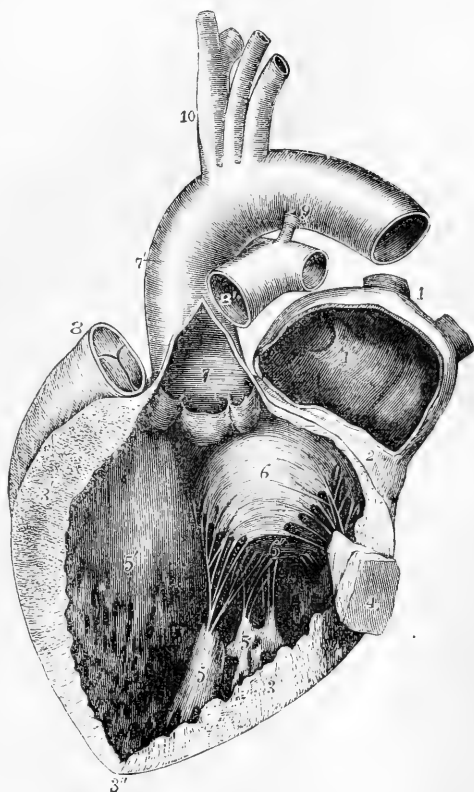
\* Sibson proposes to term the whole apparatus guarding the arterial orifices the *aortic* or *pulmonary valve*, reserving the terms *semilunar* and *sigmoid* to denote the individual flaps or segments.

lunated depression may be observed (1'), comparable to a mark made by the finger-nail on a soft surface. This is the vestige of the foramen ovale, as it appears on the left side. The depression is limited by a slight crescentic ridge, the concavity of which is turned upwards, and which is in fact the border of the now adherent membranous valve, which during foetal life is applied to the left side of the then open foramen ovale. The line of adhesion may vary so as to leave more or less of a pocket-like recess.

Fig. 170.—THE LEFT AURICLE AND VENTRICLE OPENED AND A PART OF THE WALL REMOVED SO AS TO SHOW THEIR INTERIOR (Allen Thomson). ONE-HALF THE NATURAL SIZE.

The commencement of the pulmonary artery has been cut away, so as to show the aorta: the opening into the left ventricle has been carried a short distance into the aorta between two of the semilunar flaps; part of the auricle with its appendix has been removed. 1, the two right pulmonary veins cut short; 1', placed within the cavity of the auricle on the left side of the septum and on the part which forms the remains of the valve of the foramen ovale, of which the crescentic border is seen; 2', a narrow portion of the wall of the auricle and ventricle preserved around the auriculo-ventricular orifice; 3, the left part, 3', the right part, towards the septum, of the cut surface of the wall of the ventricle, seen to become very much thinner towards 3', at the apex; 4, a small part of the wall of the left ventricle which has been preserved with the principal anterior or left papillary muscle attached to it; 5, 5, the large posterior or right papillary muscles; 5', the left side of the septum ventriculorum; 6, the right or aortic segment, and 6', the left or parietal segment of the mitral valve; 7, placed in the interior of the aorta near its commencement and above its valve; 7', the exterior of the great aortic sinus; 8, the upper part of the conus arteriosus with the root of the pulmonary artery and its semilunar valves; 8', the separated portion of the pulmonary artery remaining attached to the aorta by 9, the cord of the ductus arteriosus; 10, the arteries rising from the summit of the aortic arch.

Fig. 170.



The **left** or **posterior ventricle** occupies the left border of the heart, but only about a third of its extent appears on the anterior surface, the rest being seen behind. It is longer and narrower than the right ventricle, and the cross section of its cavity is oval, not crescentic, the septum on this side being concave (fig. 169). Its walls, which, excepting

near the apex, are three times as thick as those of the right ventricle, are thickest at the part where the ventricle is widest, about one-fourth of its length from the base (fig. 170, 3, 3'); from this point they become thinner towards the auricular opening, and still thinner towards the apex (3''), which is, therefore, the weakest part. The lining membrane, which is continuous with that of the left auricle and the aorta, is usually less transparent than that of the right ventricle, especially in later life. In the interior of the cavity are noticed *columnæ carneæ*, *musculi papillares* with *chordæ tendineæ*, and two orifices guarded with valves. The *columnæ carneæ* are smaller than those of the right ventricle, but are more numerous and more closely reticulated. Their intersections are very numerous near the apex of the cavity, and also along its posterior wall, but the upper part of the anterior wall and septum is comparatively smooth. The *musculi papillares* (4, 5) are collected into two groups, which are larger than those of the right ventricle. The two orifices of this ventricle are situated very close together, with one of the segments (fig. 171, 6) of the auriculo-ventricular valve

Fig. 171.

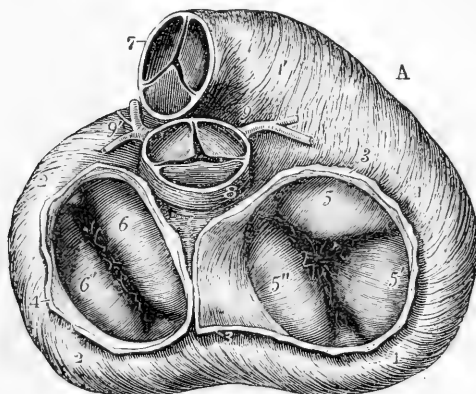


Fig. 171.—VIEW OF THE BASE OF THE VENTRICULAR PART OF THE HEART, SHOWING THE RELATIVE POSITION OF THE ARTERIAL AND AURICULO-VENTRICULAR ORIFICES (Allen Thomson). Two-thirds the natural size.

The muscular fibres of the ventricles are exposed by the removal of the pericardium, fat, bloodvessels, &c.; the pulmonary artery and aorta and the auricles have been removed. The valves are in the closed condition. A, is placed opposite that part which is most anterior when the organ is in the natural position within the body. 1, 1, right ventricle; 1', conus arteriosus; 2, 2, left ventricle; 3, 3, the divided wall of the right auricle; 4, that of the left; 5, the anterior, 5', the right (or inferior), and 5'', the septal segment of the tricuspid valve; 6, the anterior or aortic, and 6', the posterior or parietal segment of the mitral valve. In the angles between these segments are seen smaller fringes; 7, the pulmonary artery; 8, placed upon the root of the aorta; 9, the posterior, 9', the anterior coronary artery.

between: the auricular opening is placed at the left and posterior part of the base of the ventricle; the aortic opening, in close proximity in front and towards the right.

The *bicuspid* or *mitral* valve, at the left auricular opening, resembles in structure the tricuspid valve of the right ventricle, but it is much

thicker and stronger in all its parts, and consists of only two pointed segments, continuous at their attached bases. The larger of the two segments is suspended obliquely to the right and in front of the other, between the auricular and aortic openings: the smaller to the left and posteriorly, and close to the wall of the ventricle. There is usually a smaller lobe at each angle of junction of the two principal segments, more apparent than those between the segments of the tricuspid valve.

As on the right side, the two sets of chordæ tendineæ from the papillary muscles proceed each to an angle between the two segments, and are attached in like manner to their margins and ventricular surfaces (fig. 173, B, *e*, *e'*), so that the muscoli papillares, when they contract, tend to bring the edges of the flaps together. The chordæ tendineæ are stronger and less numerous than in the right ventricle.

The arterial or *aortic orifice* circular in form, and smaller than the auricular, is separated from it only by the attachment of the anterior segment of the mitral valve.

As in the pulmonary artery, its valve consists of three semicircular flaps (*semilunar* or *sigmoid*), (fig. 172, II) each of which is attached by its

Fig. 172.

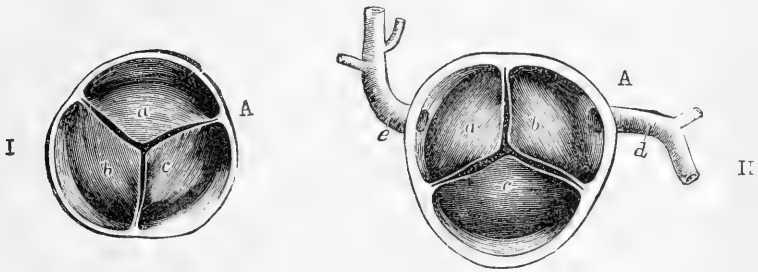


Fig. 172.—THE SEMILUNAR VALVES OF THE AORTA AND PULMONARY ARTERY, SEEN FROM THEIR DISTAL SIDE (Allen Thomson).

I, transverse section of the pulmonary artery immediately above the attachment of the semilunar valves: *a*, the left, and *c*, the right anterior segments; *b*, the posterior segment: opposite each the sinus of Valsalva is seen, and between them the attachment of the valve-segments to the inner wall of the artery.

II, a similar section of the aorta: *a*, the left posterior segment, and *b*, the anterior segment, with the corresponding sinuses of Valsalva, from which the coronary arteries are seen to take their origin; *c*, the right posterior segment; *d*, the posterior, and *e*, the anterior coronary arteries.\*

A, in each case, as in fig. 171.

convex border to the side of the artery at the place where it joins the ventricle, whilst its other border, nearly straight, is free, and projects into the interior of the vessel. The segments are composed of duplicatures of the endocardium, and of enclosed fibrous structure, which varies in thickness at different parts. A tendinous band strengthens the free edge of the valve, and at the middle of that margin there is a slight

\* As a result of the study of sections made from frozen bodies, it would appear that the above nomenclature most correctly describes the natural position of the valve-segments. Those of the pulmonary valve are, however, more commonly known as an anterior, *a*, and two posterior; those of the aortic, as a posterior, *c*, and two anterior.

fibro-cartilaginous thickening, the *nodulus* or *corpus Arantii* (fig. 173, B, 3). Other tendinous fibres, arising from the attached border, run in the valve towards the nodule; occupying its whole extent, except two narrow

Fig. 173.

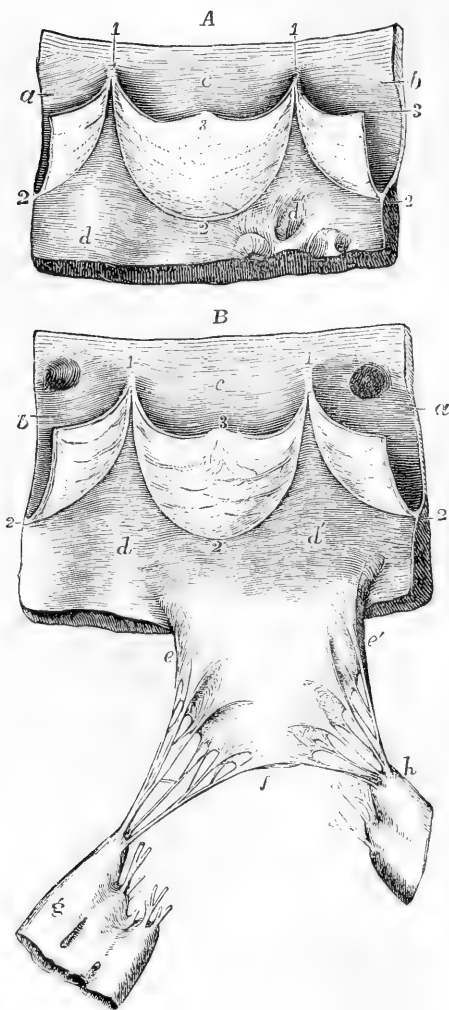


Fig. 173.—VIEWS OF PARTS OF THE SEMILUNAR AND MITRAL VALVES, AS SEEN FROM WITHIN THE VENTRICLE (Allen Thomson).

A, portion of the pulmonary artery and wall of the right ventricle with one entire segment and two half segments of the valve; *a*, half the sinus of Valsalvæ of the left anterior segment; *b*, the same of the posterior segment; *c*, the entire right anterior sinus (see fig. 172, I, in which the lettering is the same as in the present figure); *d*, *d'*, inner surface of the ventricle; 1, the attachment of the extremities of the segments to the inner wall of the artery; 2, the middle of the attached border of the segments; 3, the middle of the free border (*corpus Arantii*).

B, portion of the aorta and wall of the left ventricle with one entire segment and two half segments of the aortic valve, and the right or anterior segment of the mitral valve; *a*, half the left posterior segment and sinus of Valsalva; *b*, the left anterior; *c*, the right posterior sinus of Valsalva and segment entire; in *a*, and *b*, the apertures of the coronary arteries are seen; *d*, *d'*, the inner surface of the wall of the ventricle; 1, 2, and 3, as before; *e*, *e'*, the base of the anterior segment of the mitral valve; *f*, its apex; between *c*, and *e'*, and *f*, the attachment of the branched chordæ tendinæ to the margin and outer surface of the valve segment; *g*, the posterior or right principal musculus papillaris; *h*, the anterior or left principal musculus papillaris: the cut chordæ tendinæ are those which belong to the posterior segment and the small or intermediate segments.

lunated portions, one on each side, adjoining the free margin of the valve. These parts, which are named *lunule* (fig. 173, B), are therefore thinner than the rest. There is also a strengthening fibrous cord surrounding the attached border of each valve. The wall both of the aorta and pulmonary artery is bulged out opposite each semilunar flap: these bulgings are known as the *sinuses of Valsalva*. In the aorta these are situated one anteriorly and two posteriorly (right



and left). From the anterior arises the right coronary artery; from the left posterior the left coronary artery: these vessels being for the supply of blood to the substance of the heart.

The capacity of the sinuses of Valsalva is greater, and the tendinous tissue in the valves is more strongly marked at the mouth of the aorta than at the commencement of the pulmonary artery.

During the contraction of the ventricle the valves lie at first against the sides of the artery, and allow the blood to flow freely past them; but when the column of fluid in the artery is partially thrown back by the elasticity of the coats of that vessel, the sigmoid valves are floated back by the reflux blood, and completely close the arterial orifice. When the valves are thus closed, the whole free border and the thin lunated parts are closely applied to each other, and are held together, as well as exempted from strain, by the opposite and equal pressure of the blood on either side, so that the greater the pressure the more accurate must be the closure. The force of the reflux is sustained by the stouter and more tendinous part of the valve.

The part of the ventricle adjoining the root of the aorta forms a small compartment, the "*aortic vestibule*" of Sibson, the walls of which are fibrous, or, in some parts, fibro-cartilaginous, so that it remains uncollapsed, and allows space for the bulging flaps of the aortic valve to descend during diastole, besides allowing for the closure of the mitral valve during extreme contraction of the ventricle.

#### POSITION OF THE PARTS OF THE HEART WITH RELATION TO THE WALL OF THE THORAX.

The following statements are derived mainly from the observations of Luschka and Allen Thomson: they have been carefully compared with, and, where necessary, modified from those of other observers.\*

Nearly two-thirds of the bulk of the heart lie to the left of the middle line (fig. 174). The *upper edge of the auricles* corresponds with a line extending across the sternum from the second right into the first left intercostal space. The *right auricle* (3') extends laterally from about an inch beyond the right border of the sternum to the middle of the left half of that bone, and vertically from the middle of the second right cartilage to the lower border of the fourth. The point of the *right auricular appendage* is exactly behind the middle line on a level with the upper border of the third costal cartilages (3). The *left auricle* extends vertically from the level of the second left intercostal space to the upper border of the fourth left cartilage; and in breadth corresponds to the body of the eighth dorsal vertebra and the head of the adjoining rib. The apex of the *left auricular appendage* (4) is in the lower part of the second intercostal space or behind the third costal cartilage, about an inch and a quarter from the left of the sternum.

\* Luschka, *Die Brustorgane*, 1857; and *Anatomie des Menschen*, &c., 1863; Walshe, *Diseases of the Heart and Great Vessels*; Sibson, *On the Normal and Abnormal Situation and Structure of the Viscera of the Chest*, in *Trans. of the Provinc. Med. and Surg. Assoc.*, vol. xii., year 1842, and in his *Work on Medical Anatomy*, also article on the Position and Form of the Heart, in *Reynolds' System of Medicine*, vol. iv.; Allen Thomson, *Notice of the case of E. Groux*, &c., with *Observations on the Position and Actions of the Heart*, in *Glasgow Med. Journ.*, April, 1858; Pirogoff, *Anatomia Topographica*; Braune, *Topographisch-Anatomischer Atlas*; Le Gendre, *Anatomie Chirurgicale Homologique*. The three last-mentioned publications give the results obtained by means of sections of the chest at different levels, made whilst frozen.

Fig. 174.

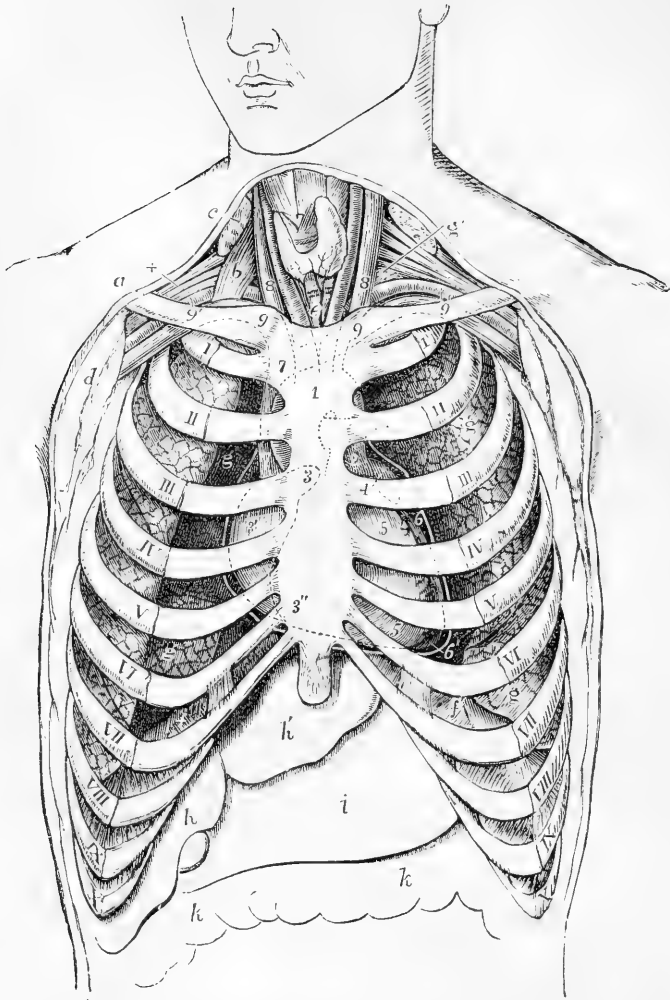


Fig. 174.—SEMI-DIAGRAMMATIC REPRESENTATION OF THE CHEST, TO SHOW THE POSITION OF THE HEART AND GREAT VESSELS, AS SEEN BEHIND THE STERNUM AND COSTAL CARTILAGES (from Luschka and A. Thomson). ONE-FOURTH THE NATURAL SIZE.

The lungs have shrunk from the front of the chest. The heart is slightly higher than during life, and the aorta more to the right. *a*, right clavicle; *b*, scalenus anticus muscle; *c*, sterno-mastoid muscle divided; *d*, pectoral muscles divided; +, axillary nerves above the subclavian artery; *e*, trachea below the isthmus of the thyroid body; *f, f*, upper surface of the diaphragm; *g, g*, surface of the lungs; *g'*, on the left side, apex of the lung or pleura appearing in the neck; *h*, right, *h'*, left lobe of the liver; *i*, stomach; *k, k*, transverse colon; I, to X, first to tenth ribs near their cartilages; 1, placed on the lower part of the manubrium of the sternum, and on the place of the arch of the aorta indicated by dotted lines; 2, placed in the second left intercostal space, on the stem of the pulmonary artery; 3, appendix of the right auricle; 3', on the sinus venosus, behind the third space; 3'', its lower part at the junction of the sixth and seventh right costal cartilages with the sternum; 4, left auricular appendix;

5, 5, right ventricle; 6, left ventricle; 6', apex of the heart: the white line outside the heart is intended to indicate the external pericardium, as if the anterior half were removed by a transverse incision; 7, 7, vena cava superior; 8, 8, internal jugular veins; 9, 9, subclavian veins, joining the jugular; 9, 7, 9, innominate veins; the right rising behind the sterno-clavicular articulation, the left crossing obliquely behind the upper half of the manubrium. The position of the first parts of the innominate artery, left carotid and left subclavian arteries, is indicated behind and below this vein; 9', 9', outer part of the subclavian arteries. It is to be observed that in this figure the attachment of the sixth costal cartilage to the sternum is represented a little too high.

The *right ventricle* extends from above down from the third to the sixth cartilages on the left side.\* The *conus arteriosus* is its most projecting part, being uncovered by lung. The *auriculo-ventricular sulcus* corresponds with a line drawn obliquely upwards from near the sternal end of the 6th costal cartilage on the right side, to the 3rd cartilage on the left. The *rounded margin* formed by the left ventricle extends on the left side from the 3rd cartilage to a point in the fifth space two inches vertically below the nipple. The *sharp margin* formed by the right ventricle passes from the sternal end of the 6th cartilage on the right, and crosses behind the 7th right cartilage, the ensiform (at its upper third), and the 7th left cartilage, to meet the other margin at the apex.

The *apex of the heart* (fig. 174, 6') is situated about  $3\frac{1}{2}$  inches to the left of the middle line, in the fifth intercostal space, close to the upper margin of the sixth rib.

The *auriculo-ventricular openings* lie slightly to the right of the line of the auriculo-ventricular sulcus. The *tricuspid orifice* lies behind the lower fourth of the sternum, its upper border being on a level with the fourth cartilages. The *left auriculo-ventricular opening* extends from the 3rd space to the 5th cartilage behind the left half of the sternum. The *orifice of the pulmonary artery* is placed immediately to the left of the sternum, behind the edge of that bone and the 3rd cartilage; the *aortic orifice*, also partly behind the left half of the sternum, is on a slightly lower level than the orifice of the pulmonary artery (being opposite the lower part of the 3rd cartilage and the 3rd intercostal space), and is covered by it in one-fourth its diameter. The aortic orifice is exactly behind the posterior wall of the conus arteriosus.

#### INTIMATE STRUCTURE OF THE HEART.

The substance of the heart consists chiefly of muscular tissue; but besides this a certain amount of fibrous and fibro-cartilaginous tissue is met with, collected principally at the base of the ventricles around the ventricular orifices.

**Fibro-cartilage and fibrous tissue.**—In the angle between the aortic and the two auriculo-ventricular openings (see fig. 171, close to 8) a fibro-cartilaginous mass is found, which in some animals, as the ox and elephant, is bony, and is known as the *os cordis*. From this central fibro-cartilage processes pass in various directions. One of these, extending downwards to meet the fleshy septum of the ventricles, separates the left ventricle from the right auricle, forming the right boundary of the aortic vestibule. These processes form the bases of what have been described by authors as the *fibrous* or *tendinous rings* of the auriculo-ventricular and arterial openings. The fibrous tissue of these rings is continuous with that which is found in the segments

\* These are sometimes termed the "cardiac cartilages."

of the valves, strengthened on the sides next the septum by the processes from the fibro-cartilage. The rings of the arterial orifices give attachment below to some of the muscular fasciculi of the ventricle, whilst above they present an uneven edge with three deep semilunar notches, to which the middle coat of the artery and the flaps of the valve are firmly attached. The fibres of the middle coat of the artery, here comparatively thin, are not arranged annularly, as in other parts of the vessel, but converge to the intervals between the sinuses of Valsalva, to be attached to the fibrous rings.

The tendinous rings of the aortic and left auricular orifices are confluent, so that when the fibrous tissue is destroyed by boiling the two apertures run into one.

Fig. 175.

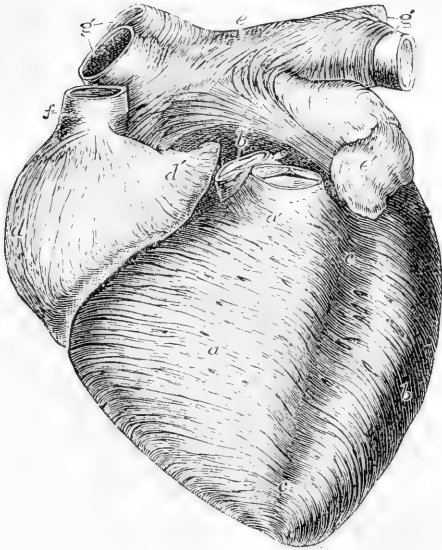


Fig. 175.—ANTERIOR VIEW OF HEART OF A YOUNG SUBJECT DISSECTED AFTER BOILING, TO SHOW THE SUPERFICIAL MUSCULAR FIBRES, TWO-THIRDS THE NATURAL SIZE. (Allen Thomson).

This figure is planned after one of Luschka's, but its details were chiefly taken from an original preparation. The aorta, *b'*, and pulmonary artery, *a'*, have been cut short close to the semilunar valves, so as to show the anterior fibres of the auricles. *a*, superficial layer of the fibres of the right ventricle; *b*, that of the left; *c, c*, anterior interventricular groove, from which the coronary vessels have been removed, *d*, right auricle; *d'*, its appendix, both showing chiefly perpendicular fibres; *e*, upper part of the left auricle; between *c*, and *b'*, the transverse fibres which behind the aorta pass across both auricles; *e'*, appendix of left auricle; *f*, superior vena cava, around which, near the auricle, circular fibres

are seen; *g, g'*, right and left pulmonary veins with circular bands of fibres surrounding them.

**Muscular tissue.**—The microscopical characters of the muscular tissue of the heart have been already considered (p. 119). It remains, however, to notice the general course and arrangement of the fasciculi (or "fibres," as they are ordinarily termed), in the auricles and ventricles respectively, for the muscular bundles of the two are not continuous, being only connected by the fibrous tissue around the auriculo-ventricular orifices: in conformity with this it is seen that after boiling the heart the auricles may be easily separated from the ventricles.

**Fibres of the auricles.**—These consist of a superficial set, common to both cavities, and of deeper fibres proper to each. The *superficial, common* or *transverse* fibres run transversely over both venous sinuses, near the base, and are most numerous on the anterior surface;

some of them pass in at the inter-auricular septum (fig. 175). The deeper fibres, which are *proper* to each auricle, consist of two sets, viz., the looped and the annular fibres. The *looped* fibres pass over the auricle, and seem to be attached by both extremities to the corresponding auriculo-ventricular rings. The *annular* fibres encircle the auricular appendages (fig. 175, *d'*, 176, *e'*), some longitudinal fibres running within them. These annular fibres also surround the entrances of the venæ cavæ (*f, i*) on the right, and of the coronary vein and the pulmonary veins on the left side of the heart (*g, h*),—the muscular fibres extending for some distance from the auricle upon the veins, especially upon the superior vena cava and the pulmonary veins.

**Fibres of the ventricles.**—The muscular fasciculi of the ventricles have a very intricate disposition, which has received great attention from anatomists. Many of the statements, however, are conflicting, and it must be confessed that the subject still admits of further investigation.

Fig. 176.—POSTERIOR VIEW OF THE SAME PREPARATION AS IS REPRESENTED IN THE PRECEDING FIGURE (Allen Thomson).

*a*, posterior surface of the right ventricle with its superficial muscular fibres dissected; *b*, the same of the left ventricle; *c*, posterior interventricular groove, from which the coronary vessels have been removed; *d*, right auricle; *e*, the left, showing some transverse fibres common to both auricles, and others belonging to each; *f*, superior vena cava; *g, g'* pulmonary veins cut short; *h*, sinus of the great coronary vein covered by muscular fibres; *h'* posterior coronary vein joining the principal one; *i*, inferior vena cava; *i'* Eustachian valve.

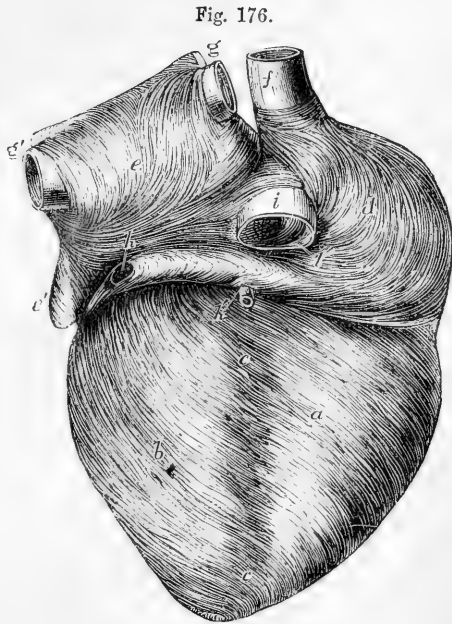


Fig. 176.

It is chiefly the constant twisting and overlapping of the several bundles which renders difficult the investigation of their course and disposition. In order to unravel them with any degree of success, it is best to boil the slightly distended heart for a short time, so as to soften the connective tissue, and then carefully to dissect the organ in part by cutting and in part by tearing asunder the fibres with blunt instruments.\*

The *surface fibres* of the ventricles (figs. 175, 176, 177) extend from the base, where they are attached to the tendinous structures around

\* For convenience of description, the heart, in the following account of the course of the fibres, is supposed placed apex downwards, and with the anterior and posterior surfaces about equally occupied by the two ventricles (as represented in figs. 175, 176).

the orifices, towards the apex of the heart, where they pass with an abrupt twist into the interior of the left ventricle. Their general direction is not vertical but oblique, especially in front (fig. 177), just as if while the base of the organ remained fixed the apex had been twisted half round in the direction of the hands of a watch. They form a distinct thin superficial stratum, best marked at the back of

Fig. 177.

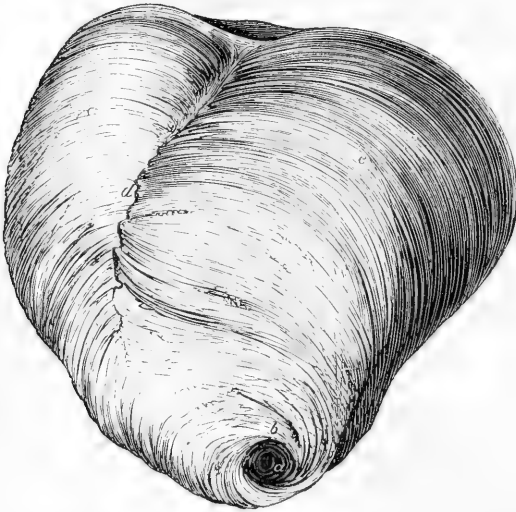


Fig. 177.—SURFACE FIBRES OF VENTRICLES OF HUMAN HEART FROM THE FRONT AND BELOW (Reid).

*b*, bundle of fibres emerging from the interior of the left ventricle at the vortex *a*, and crossing the lower part of the septum uninterruptedly. At *d* the surface fibres are somewhat interrupted.

the right ventricle, for here the direction of the fibres is quite different from those immediately beneath. At the back they pass over the septum without turning in: at the front they are somewhat interrupted by fibres which come out from the septum; except towards the base and apex, where they cross uninterruptedly from one ventricle to the other (fig. 177).

To trace the further course of the surface fibres it is necessary to open the left ventricle. When this is done, and the endocardium cleared away, it is seen that there are here two sets of fibres with which the superficial fibres become continuous. The first of these consists of bundles derived mainly from the left (or anterior) set of papillary muscles, which pass down to the apex of the cavity, turning as they emerge in a half circle around the front of the apex to the right side (fig. 178, *b*). They are continuous on the outside chiefly with those superficial fibres which cross the lower part of the septum in front, and which, spreading out, are attached above to the posterior parts of the tendinous rings at the base. The second set, on the other hand, comes chiefly from the right or posterior papillary muscles, and,

passing behind the first set of fibres in the cavity, turning forwards, emerges in front of them at the apex, around which its fibres twist, to become continuous chiefly with those superficial fibres which cover the anterior surface of the heart, and are attached above to the corresponding parts of the tendinous rings. But since the superficial fibres form a continuous stratum around the ventricles, it is impossible to adjudge any exact limits to the two sets of fibres.

It is very much more difficult to trace the continuity of the *deeper fibres* of the ventricles: those, namely, which form the main part of their thickness.

When the left ventricle is opened, the fibres forming its walls are seen in the interior to take a general direction downwards, those of the anterior wall converging somewhat towards the apex, those of the posterior passing more diagonally from right to left. Traced upwards, they are observed partly to be attached to the aortic and mitral tendinous rings, partly to turn round the margin of the auriculo-ventricular orifice, in continuity with other more external fibres, which, again, come (at least some of them) from the central fibro-cartilage. Traced downwards, they turn round to form the chief substance of the wall of the ventricle, passing in front obliquely upwards again towards the septum. Some of them, however, join the sets of fibres which emerge at the apex and become superficial; and, on the other hand, the deep fibres are joined by the deeper parts of the papillary muscles. Reaching the septum, they for the most part turn into it, and some of them pass at once obliquely upwards, to be attached to the central fibro-cartilage. Others, after indenting or interlocking with bundles, which turn into the septum from the front of the right ventricle, proceed to form the posterior part of that ventricle, passing to its posterior papillary muscle and the central fibro-cartilage or its prolongations; whilst a third set, reinforced by the entering fibres from the right ventricle, take an annular course around the left ventricle. It is excessively difficult to trace the ultimate destination of these annular bundles, for they appear to encircle the ventricle more than once, and to form the main thickness of its wall: but it is probable that taking a more and more oblique course, they either are eventually attached to some of the tendinous or fibro-cartilaginous structures at the base, or pass up into one or other of the papillary muscles at the apex.

The bundles of fibres on the inside of the right ventricle have a general direction from the tricuspid and pulmonary rings to which they are attached above, and from the papillary muscles, especially the anterior, towards the lower and back part of the cavity. Arrived here, some turn sharply round to enter the septum, and partly to pass up in this to the central fibro-cartilage, whilst others pass across the back of the septum into the posterior wall of the left ventricle, and become lost amongst the fibres there. There are besides certain sets of fibres which appear not readily assignable to any of those above described: those, for instance, which encircle the pulmonary orifice, and others which, as Sibson has shown, radiate upwards from the bases of the papillary muscles, especially the anterior papillary of the right ventricle, to be attached to the tendinous structures at the base of the heart, especially to the pulmonary ring, opposite the two anterior sinuses of Valsalva. Moreover, a number of fasciculi encircle both ventricles, apparently without a definite attachment, but, according to Winckler, they

may eventually be traced at one end to the tendinous structures at the base of the heart, and at the other to one of the papillary muscles of the left ventricle.

The peculiar spiral concentration of the fibres of the heart at the apex is known as the *vortex* or *whorl*, and is produced, as already described, by the twisting or interlocking of the fibres in the interior as they pass to be continuous with those on the exterior. It has been thought that a similar continuity was the rule at the base of the heart also, and that few if any of the bundles are attached to the tendinous rings. But although it is true that some bundles may turn round at the auriculo-ventricular openings, this is by no means general, and most of the muscular fasciculi must be described as being attached to the fibrous and fibro-cartilaginous structures at the base, either directly or through the medium of the chordæ tendineæ and segments of the valves.

Fig. 178.

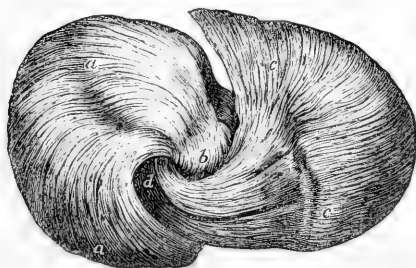


Fig. 178.—VIEW OF THE FIBRES OF THE SHEEP'S HEART, DISSECTED AT THE APEX TO SHOW THE "VORTEX" (Pettigrew).

*a, a*, fibres entering the apex posteriorly at *b*; *c, c*, fibres entering the apex anteriorly at *d*.

In the middle of the thickness of the ventricular wall the fibres are, as before said, annular and transverse (fig. 179, 4, 4'); but, as Ludwig showed, they pass by the most gradual transition into the diagonal ones nearer the surfaces, so that any separation into layers which may be effected (with the exception of the superficial stratum previously described) must be looked upon as in a great degree artificial. Even by those anatomists who contend for the existence of definite strata their number has been very differently stated. Wolff\* conceived that five layers might be made out. Pettigrew† has described as many as seven in the wall of each ventricle, of which the fourth occupies the middle of the thickness of the ventricular wall; the third is continuous above and below with the fifth; the second with the sixth; and the first, or most external, with the seventh, or most internal; the outer layers turning in at the whorl and at the margins of the auriculo-ventricular openings respectively, but without being attached to the tendinous structures at all.

It will be observed that Pettigrew's description differs materially from that given in the text, which, although agreeing in many points with the observations of Ludwig, Winckler, and Sibson,‡ is mainly founded on an entirely fresh investigation of the subject, undertaken with the co-operation of Mr. F. J. Davies, of University College.

**Interstitial structures.**—The interstices between the closely reticulating muscular fibres are filled by connective tissue, with numerous blood-vessels, lymphatics, and nerves. The muscular substance is supplied with blood by the coronary arteries, the origin and course of which, as well as of the coronary vein, are elsewhere described. The smaller branches penetrate into every part of the muscular substance.

The lymphatics (which are found in great number beneath both the pericardium and endocardium), are also, according to Schweigger-Seidel,

\* C. F. Wolff, *De ordine Fibrarum Muscularium Cordis*; Act. Acad. Petropol. 1780—1792.

† Phil. Trans. 1864.

‡ Ludwig, in *Zeitschrift für rationelle Medizin*, 1849; and Müller's *Archiv*. Winckler, in *Archiv für Anatomie und Physiologie*, 1865. Sibson, *Medical Anatomy*, 1869.



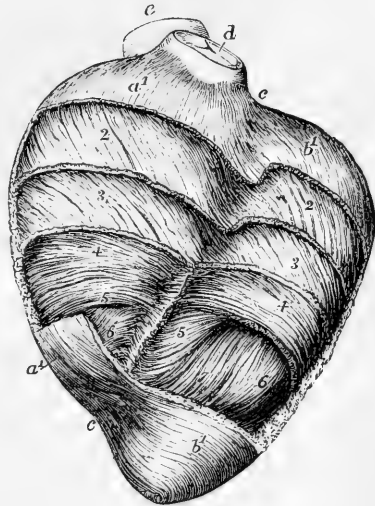
extensively distributed throughout the muscular substance, occurring in the form of freely communicating fissure-like spaces, lying between the muscular bundles, and lined by epithelioid cells; the mode of origin being thus to a certain extent lacunar.

The nerves given off by the cardiac plexuses appear rather small in comparison with the bulk of the heart; they are derived partly from the cerebro-spinal and partly from the sympathetic system (more especially from the pneumogastric nerve, and from the cervical and superior thoracic ganglia of the sympathetic nerve). Besides the larger ganglia in the cardiac plexuses at the base of the heart, the nerves present minute ganglia at different points along their course in its substance, first

Fig. 179.—VIEW OF A PARTIAL DISSECTION OF THE FIBRES OF THE ANTERIOR WALL OF THE VENTRICLES IN A SHEEP'S HEART, DESIGNED TO SHOW THE DIFFERENT DEGREES OF OBLIQUITY OF THE FIBRES (Allen Thomson).

At the base and apex the superficial layer of fibres is displayed: in the intervening space, more and more of the fibres have been removed from above downwards, reaching to a greater depth on the left than on the right side.  $a^1, a^1$ , the superficial layer of the right ventricle;  $b^1, b^1$ , the same of the left ventricle; at 2 this superficial layer has been removed so as to expose the fibres underneath, which are seen to have the same direction as the superficial ones over the left ventricle, but different over the right; at 3 some of these have been removed, but the direction is only slightly different; 4, transverse or annular fibres occupying the middle of the thickness of the ventricular walls; 6, 7, internal fibres passing downwards towards the apex to emerge at the whorl; between  $c, c$ , the anterior coronary or interventricular groove, over which the fibres of the superficial layer are seen crossing; in the remaining part of the groove, some of the deeper fibres turn backwards towards the septum;  $d$ , the pulmonary artery;  $e$ , the aorta.

Fig. 179.



figured and described by Remak.\* The larger nerves course obliquely downwards on the surface of the ventricles beneath the pericardium, crossing the direction of the superficial fibres, and giving off at intervals branches into the muscular substance.

**Endocardium.**—The cavities of the heart are lined by a thin membrane continuous with the inner coat of the bloodvessels, with which in general structure it for the most part agrees. A layer of flattened epithelioid cells covers and lines the inner surface, and beneath this the endocardium consists of connective tissue with a close network of elastic fibres often passing into fenestrated membrane. Muscular fibres are present in some parts. These are for the most part similar to those which compose the chief muscular substance of the heart.

\* Froriep's Notizen, 1838, p. 137; and Müller's Archiv, 1844, p. 463, taf. xii.

In some animals others are found which are only striated at their periphery, and present a beaded appearance, the component cells being much larger and more distinct; these, which are known as Purkinje's fibres, appear to represent a condition of arrested development of the ordinary cardiac fibres. Plain muscular fibre-cells have also been described in some situations; and, in some animals, collections of adipose tissue are met with beneath the endocardium. The membrane is usually more opaque on the right side than on the left; and thicker in the auricles (the left especially) than in the ventricles; it is, however, very thin on the muscoli pectinati of the auricles and on the columnæ carneæ of the ventricles.

#### DIMENSIONS AND WEIGHT OF THE HEART.

**Size.**—It was stated by Laennec, as the result of his experience, that the heart in its natural condition was about equal in size to the closed hand of the individual. It is about five inches long, three and a half in its greatest width, and two and a half in its extreme thickness from the anterior to the posterior surface; but linear measurements of a flaccid organ like the heart must be subject to so many accidental variations as to render them of little value.

**Weight.**—The weight of the heart in the adult is also subject to considerable variation, ranging between rather wide limits, which depend on the general weight of the body and on the sex.

Its mean weight is about 9 or 10 oz. According to Reid's tables, the average weight in the adult male is as high as 11 oz., and in the female 9 oz.; while according to Peacock the average of the male is  $9\frac{3}{4}$  oz., and that of the female 9 oz.

The weight of the heart maintains some general proportion to that of the body. According to Tiedemann this is about 1 to 160; by Clendinning it was found to be 1 to 158 in males, and 1 to 149 in females; and by Reid to be 1 to 169 in a series of thirty-seven males and 1 to 176 in twelve females; but in the healthy males dying suddenly the ratio was as 1 to 173.

It was shown by Clendinning that the heart continued to increase in weight up to an advanced period of life, but at a comparatively slower rate subsequently to the age of twenty-nine years. Subjoined is a tabular statement of some of the average results derived from the observations of these authors.

| CLEDDINNING.  |        |                 |               | REID.          |          |                           |          | PEACOCK. |          |                 |                 |    |   |                 |
|---------------|--------|-----------------|---------------|----------------|----------|---------------------------|----------|----------|----------|-----------------|-----------------|----|---|-----------------|
|               |        | Weight in oz.   |               |                |          | Weight in oz. and drachms |          |          |          | Males. Females. |                 |    |   |                 |
| Age in years. | Males. | Females.        | Age in years. | Males.         | Females. | Males.                    | Females. | Males.   | Females. | Males.          | Females.        |    |   |                 |
| 15 to 29      | ..     | $8\frac{1}{2}$  | ..            | $8\frac{1}{2}$ | 16 to 20 | ..                        | 8 10     | ..       | 6 13     | 8               | $2\frac{2}{3}$  | .. | 8 | $1\frac{2}{3}$  |
| 30 — 50       | ..     | $9\frac{1}{3}$  | ..            | $8\frac{1}{2}$ | 20 — 30  | ..                        | 10 4     | ..       | 8 0      | 9               | $0\frac{1}{7}$  | .. | 8 | $10\frac{1}{7}$ |
| 50 — 60       | ..     | $10\frac{1}{6}$ | ..            | 8              | 30 — 40  | ..                        | 10 8     | ..       | 9 3      | 9               | 7               | .. | 8 | $13\frac{1}{5}$ |
| 60 — +        | ..     | $10\frac{1}{2}$ | ..            | 8              | 40 — 50  | ..                        | 11 7     | ..       | 9 8      | 8               | 11              | .. | 9 | 3               |
|               |        |                 |               |                | 50 — 60  | ..                        | 11 10    | ..       | 9 14     | 9               | 12              | .. | 9 | $7\frac{1}{5}$  |
|               |        |                 |               |                | 60 — 70  | ..                        | 12 6     | ..       | 9 5      | 10              | $13\frac{1}{3}$ | .. | 7 | 0               |
|               |        |                 |               |                | 70 — +   | ..                        | 12 6     | ..       | 9 6      |                 |                 |    |   |                 |

Entirely in accordance with these observations upon the increase of the heart's weight according to age, it has been found by Bizot that this organ continues to enlarge in all its dimensions as life advances, viz., in the length, breadth, and thickness of its walls. The greatest increase was detected in the substance of the left ventricle, and the ventricular septum.\*

\* Reid, in the Lond. and Edin. Monthly Journal of Med. Science, April 1843; T. B. Peacock, in the same journal, in 1846, and reprinted separately, with additional observations, in 1854; Clendinning, in the Medic. Chir. Transact., 1838; Bizot, Mém. de la Soc. Médic. d'Observation de Paris, tom. i. p. 262. 1836.

**Capacity of the auricles and ventricles.**—To determine with precision the absolute and relative capacities of the four cavities of the heart, as they exist during life, is impossible; and their capacity is so much influenced by their different states of distension, and also by the different degrees of contraction of their muscular walls at the moment of death, that no constant numerical relation in this respect can be looked for between them. Hence the most opposite statements prevail, especially with regard to the size of the ventricular cavities.

The auricles are generally stated to be rather less capacious than the ventricles. The right auricle is also said to be larger than the left, in the proportion of 5 to 4. (Cruveilhier.)

The right ventricle is asserted by some to be larger than the left; by others (Lower, Sabatier, Andral) the two are stated to have an equal capacity; Cruveilhier, judging from the effect of injections, has found the left to be the larger of the two. In the ordinary modes of death, the right ventricle is always found more capacious than the left, which is probably owing to its being distended with blood, in consequence of the cessation of the circulation through the lungs: the left ventricle, on the other hand, is found nearly empty, and thus becomes more fully contracted. There are reasons for believing, however, that during life scarcely any difference of capacity exists between the cavities.

**Size of the ventricular openings.**—The right auriculo-ventricular opening, and the orifice of the pulmonary artery, are both found to be somewhat larger after death than the corresponding openings on the left side of the heart. Their circumference is thus stated by Bouillaud. (*Traité des Malad. du Cœur*, tom. i. p. 52. Paris, 1835.)

|                               |                      | Inches and Lines. |      |      |
|-------------------------------|----------------------|-------------------|------|------|
|                               |                      | Max.              | Med. | Min. |
| Auriculo-ventricular orifices | { Right.....         | 4 0               | 3 10 | 3 9  |
|                               | { Left.....          | 3 10              | 3 6  | 3 3  |
| Arterial orifices . . . . .   | { Right (Pulmonary)  | 2 10              | 2 7  | 2 6  |
|                               | { Left (Aortic)..... | 2 8               | 2 8  | 2 4  |

According to observations by Peacock, the average dimensions are somewhat higher:—

|                               |                       | Males. | Females. |
|-------------------------------|-----------------------|--------|----------|
| Auriculo-ventricular orifices | { Right.....          | 4 6    | 4 0      |
|                               | { Left.....           | 3 7    | 3 10     |
| Arterial orifices . . . . .   | { Right (Pulmonary)   | 3 4    | 3 3      |
|                               | { Left (Aortic) ..... | 3 0    | 2 10     |

**ORGANS OF RESPIRATION.**

Besides the heart, the thorax contains the principal organs of respiration, viz., the lungs and a part of the trachea. The larynx, which is affixed to the upper end of the windpipe, and is not only the entrance for air into the respiratory organs from the pharynx, but also the organ of voice, will be described after the lungs.

**THE TRACHEA AND BRONCHI.**

The **trachea** or **windpipe** (fig. 180, *tr.*), the common air-passage of both lungs, is an open tube which commences above at the larynx, and divides below into two smaller tubes, right and left bronchi, one for each lung.

The trachea is placed in the median plane of the body, and extends from the lower border of the cricoid cartilage of the larynx (*c*), on a level with the 5th cervical vertebra in the neck (6th, Braune) to a place opposite the 3rd dorsal vertebra in the thorax, where it is crossed in front by the arch of the aorta, and at or immediately below that point

bifurcates into the two bronchi. It usually measures from four inches to four inches and a half in length, and from three-quarters of an inch to one inch in width; but its length and width are liable to con-

Fig. 180.

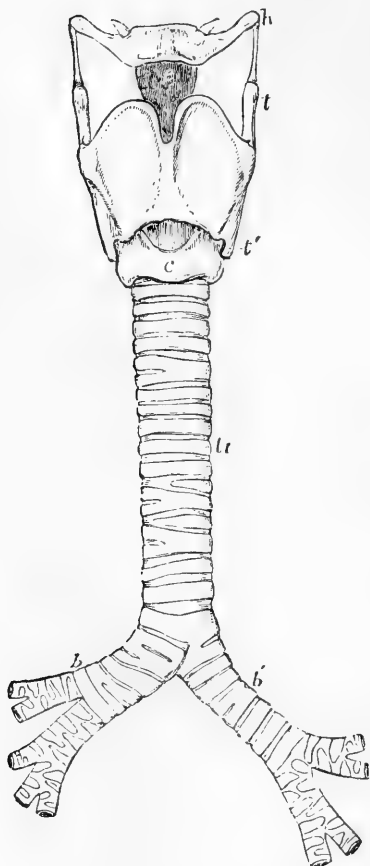


Fig. 180.—OUTLINE SHOWING THE GENERAL FORM OF THE LARYNX, TRACHEA, AND BRONCHI, AS SEEN FROM BEFORE (Allen Thomson). ONE-HALF THE NATURAL SIZE.

*h*, the great cornu of the hyoid bone; *c*, epiglottis; *t*, superior, and *t'*, inferior cornu of the thyroid cartilage; *c*, middle of the cricoid cartilage; *tr*, the trachea, showing sixteen cartilaginous rings; *b*, the right, and *b'*, the left bronchus.

tinual variation, according to the position of the larynx and the direction of the neck; moreover, it usually widens a little at its lower end, and its average diameter is greater in the male than in the female. In front and at the sides the trachea is rendered cylindrical, firm, and resistant, by a series of cartilaginous rings; these, however, are deficient behind, so that the posterior portion is flattened and entirely membranous (fig. 181).

The windpipe is nearly everywhere invested by a loose areolar tissue, abounding in elastic fibres, and is very moveable on surrounding parts. Both in the neck and thorax, it rests behind against the gullet, which intervenes between it and the vertebral column, but towards its lower part projects somewhat to the left side. The recurrent laryngeal nerves ascend to the larynx on each side in the angle between these two tubes.

In the neck the trachea is situated between the common carotid arteries; at its upper end it is embraced by the lateral lobes of the thyroid body, the middle part or isthmus of which lies across it just below the larynx. It is covered in front by the sterno-thyroid and sterno-hyoid muscles, between which, however, there is left an elongated lozenge-shaped interval in the middle line: this interval is covered in by a strong process of the deep cervical fascia, while, more superficially, another layer not so strong crosses between the sterno-mastoid muscles. The inferior thyroid veins and the *arteria thyroidea ima*, when that vessel exists, also lie upon its

anterior surface; whilst at the root of the neck, in the episternal notch, the innominate artery and the left carotid pass obliquely over it as they ascend to gain its sides.

In the thorax, the trachea is covered, above, by the first piece of the sternum, together with the sterno-thyroid and sterno-hyoid muscles; lower down, by the left innominate vein, then by the commencement of the innominate artery and left carotid, which pass round to its sides; next by the arch of the aorta and the deep cardiac plexus of nerves, and, quite at its bifurcation, by the extremity of the pulmonary artery, where this divides into its right and left branches. Placed between the two pleuræ, the trachea is contained in the posterior mediastinum, and has on its right side the pleura and pneumo-gastric nerve, and on the left, the left carotid artery, the pneumo-gastric and its recurrent branch, together with some cardiac nerves.

The **right and left bronchi** (fig. 180, *b*, *b'*) proceed each to the root of its corresponding lung. They differ from each other in length, width, direction, and relation to surrounding parts. The **right bronchus** (*b*), wider but shorter than the left, measuring about an inch in length, passes outwards almost horizontally into the root of the right lung on a level with the fourth dorsal vertebra: it is embraced above by the vena azygos, which hooks forwards over it, to end in the vena cava superior; the right pulmonary artery lies at first below it and then in front of it. On looking down the windpipe towards the bifurcation, the right bronchus appears to be a more direct continuation of the trachea than the left. The **left bronchus** (*b'*), smaller in diameter, but longer than the right, being nearly two inches in length, inclines downwards and outwards beneath the arch of the aorta to reach the root of the left lung, which it enters on a level with the fifth dorsal vertebra, that is, about an inch lower than the right bronchus. The left bronchus crosses

Fig. 181.

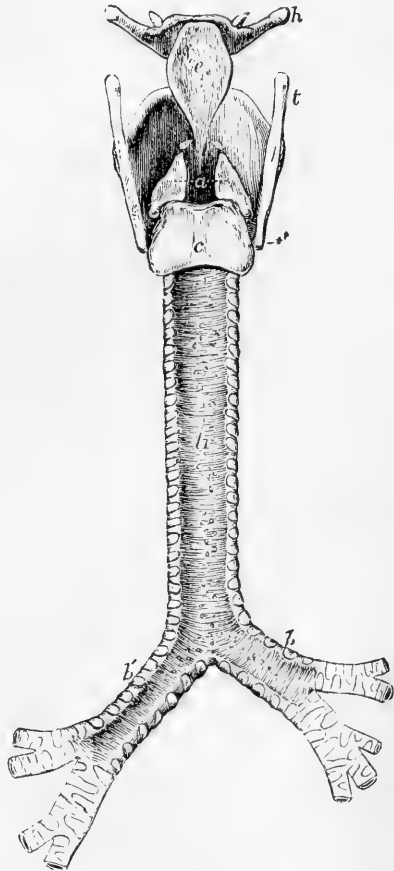


Fig. 181.—OUTLINE SHOWING THE GENERAL FORM OF THE LARYNX, TRACHEA, AND BRONCHI AS SEEN FROM BEHIND (Allen Thomson).

*h*, great cornu of the hyoid bone; *t*, superior, and *t'*, inferior cornu of the thyroid cartilage; *c*, the epiglottis; *a*, points to the back of both the arytenoid cartilages, which are surmounted by the cornicula; *c*, the middle ridge on the back of the cricoid cartilage; *t*, *t'*, the posterior membranous part of the trachea; *b*, *b'*, right and left bronchi.

over the front of the gullet and descending aorta: the arch of the aorta turns backwards and to the left over it, and the left pulmonary artery lies first above it and then on its anterior surface. The remaining connections of each bronchus, as it lies within the root of the corresponding lung, and the mode in which it there subdivides will be afterwards described.

In form the bronchi exactly resemble the trachea on a smaller scale; they are rounded and firm in front and at the sides, where they are provided with imperfect cartilaginous rings, and flattened and membranous behind.

#### STRUCTURE OF THE TRACHEA AND BRONCHI.

The trachea consists of the elastic framework of incomplete cartilaginous rings or hoops, layers of fibrous, muscular, and elastic tissue, and the lining mucous membrane, with glands.

The **cartilages** are from sixteen to twenty in number. Each presents a curve of rather more than two-thirds of a circle, resembling the letter C. The depth from above downwards is from  $1\frac{1}{2}$  to 2 lines, and the thickness half a line. The outer surface of each is flat, but the inner is convex from above downwards, so as to give greater thickness in the middle than at the upper and lower edge. The cartilages are held together by a strong fibrous membrane, which is elastic and extensible up to a certain point, and not only occupies the intervals between them, but is prolonged over their outer and inner surfaces, so that they are, as it were, imbedded in the membrane. The layer covering the outer side of the rings is stronger than that within them; and from this circumstance, together with the roundness of their inner surfaces, they may be felt more readily on the interior than on the exterior of the tube.

The cartilages terminate abruptly behind by rounded ends, but the fibrous membrane is continued across between them, and completes the tube behind; it is here looser in its texture.

The first or highest cartilage, which is connected by the fibrous membrane with the cricoid, is broader than the rest, and often divided at one end. Sometimes it coalesces to a greater or less extent with the cricoid or with the one below. The lowest cartilage, placed at the bifurcation of the trachea, is peculiar in shape; its lower border being prolonged downwards, and at the same time bent backwards so as to form a curved projection between the two bronchi. The cartilage next above this is slightly widened in the middle line. Sometimes the extremities of two adjacent cartilages are united, and not unfrequently a cartilage is divided at one end into two short branches, the opposite end of that next it being likewise bifurcated so as to maintain the parallelism of the entire series. The use of these cartilaginous hoops is to keep the windpipe open, a condition essential for the free passage of air into the lungs.

Within the fibrous membrane at the posterior flattened part of the trachea, is a continuous pale reddish layer of **unstriped muscular fibres**, which pass across, not only between the ends of the cartilages, but also opposite the intervals; they doubtless serve to diminish the area of the tube by approximating the ends of the cartilages. Those opposite the hoops are attached to the ends

of the latter, and encroach also for a short distance upon their inner surface.

Outside the transverse fibres are a few fasciculi having a longitudinal direction. These are said to arise by minute tendons of elastic tissue, in part from the inner surface of the end of the tracheal rings, and in part from the external fibrous membrane.

Situated in the **submucous tissue** immediately beneath the mucous membrane are numerous longitudinal fibres of **elastic tissue**. They are found all round the tube, but are much more abundant along the posterior membranous part, where they are principally collected into distinct longitudinal bundles, which produce visible elevations or flutings of the mucous membrane. These bundles are particularly strong and numerous opposite the bifurcation of the trachea. The elastic fibres serve to restore the windpipe to its ordinary size after it has been stretched.

A quantity of adipose tissue is often found in the submucous areolar tissue.

The trachea is provided with numerous small **mucous glands**. The largest are situated at the back part of the tube, either close upon the outer surface of the fibrous layer, or occupying little recesses formed between its meshes. They are compound glands, and their cavities are lined by a columnar or cubical epithelium: their excretory ducts pass through the muscular layer and the mucous membrane, on the surface of which multitudes of minute orifices are perceptible. Similar but smaller glands are found between the cartilaginous rings, upon and within the fibrous membrane, and still smaller ones close beneath the mucous membrane.

The **mucous membrane** is smooth and of a pale pinkish white colour in health, although when congested or inflamed, it becomes intensely purple or crimson. It contains a considerable amount of lymphoid tissue, the reticulum of which is condensed immediately underneath the epithelium into a well-marked basement membrane, composed of flattened cells which send processes up amongst the epithelium cells. In the deeper parts of the mucous membrane a large number of fine elastic fibres are found. The epithelium consists of more than one layer of cells. The most superficial (fig. 24, p. 47), are columnar and ciliated, and send processes, which are often branched, downwards into the subjacent tissue, to join, it is said, with processes from connective tissue corpuscles. The cilia serve to drive the mucous secretion upwards towards the larynx. Between the smaller or attached ends of these ciliated cells, are found elongated, often spindle-shaped cells, which commonly are prolonged at one end towards the surface, whilst the other end, which is not unfrequently forked, reaches to the subjacent membrane. One or more layers of smaller, more irregularly-shaped cells occupy the deeper part of the epithelium: amongst the epithelial cells a few leucocytes are also found. The cells generally contain mucus, and hence are readily converted into goblets (see p. 211).

**Vessels and Nerves.**—The *arteries* of the trachea are principally derived from the inferior thyroid. The larger branches run for some distance longitudinally, and then form a superficial plexus with rounded meshes. The *veins* enter the adjacent plexuses of the thyroid veins. A rich plexus of *lymphatics* may readily be injected in the mucous membrane and submucous tissue, but the lymphoid follicles, so common

in the alimentary mucous membrane, would appear to be absent here, at least in the normal condition. The *nerves* come from the trunk and recurrent branches of the pneumo-gastric, and from the sympathetic system. Their mode of termination has not yet been satisfactorily traced.

The general structure of the **bronchi** corresponds with that of the trachea in every particular. Their *cartilaginous* rings, which resemble those of the trachea in being imperfect behind, are, however, shorter and narrower. The number of rings in the right bronchus varies from six to eight, whilst in the left the number is from nine to twelve.

The bronchi are supplied by the bronchial arteries and veins, and the nerves are from the same source as those of the trachea.

### THE LUNGS AND PLEURÆ.

The *lungs*, placed one on the right and the other on the left of the heart and large vessels, occupy by far the larger part of the cavity of the chest, and during life are always in accurate contact with the internal surface of its wall. Each lung is attached at a comparatively small part of its flattened inner or median surface by a part named the *root*, and by a thin membranous fold which is continued downwards from it. In other directions the lung is free and its surface is closely covered by a serous membrane, belonging to itself and to the corresponding side of the thorax, and named accordingly, the right or left *pleura*.

#### THE PLEURÆ.

The **pleuræ** are serous membranes forming two shut sacs, quite distinct from each other, which line the right and left sides of the thoracic cavity, form by their approximation in the middle line the mediastinal partition, and are reflected each upon the root and over the entire free surface of the corresponding lung (see fig. 163).

Each pleura consists of a *visceral* and a *parietal* portion. The visceral portion, *pleura pulmonalis*, covers the lung; and the parietal portion lines the ribs and intercostal spaces, *pleura costalis*, covers the upper convex surface of the diaphragm, enters into the formation of the mediastinum, and adheres to the sides of the pericardium.

The **mediastinum**, or partition between the two pleural cavities, is formed by the reflection of each pleura from the anterior wall of the chest backwards on the pericardium to the root of the lung, and from the back of the root of the lung to the vertebral column. Its division into anterior, middle, and posterior mediastina, and the position and contents of each, have been already described (p. 239).

At the root of each lung the visceral and parietal portions of the corresponding pleura are continuous with one another; and, at the lower border of the root, is a triangular fold of the serous membrane, extending vertically along the inner surface of the lung down to the diaphragm, to which it is attached by its extremity; this fold is named *ligamentum latum pulmonis*.

The upper part of the pleura, together with the apex of the corresponding lung, rises into the root of the neck, reaching an inch or even an inch and a half above the first rib, and passes up under cover of the scaleni muscles,—a small slip of which, arising from the transverse process of the last cervical vertebra, is described by Sibson as



expanding into a dome-like aponeurosis or fascia, which covers or strengthens the pleural cul-de-sac, and is attached to the whole of the inner edge of the first rib. The right pleura is generally stated to reach higher in the neck than the left; but, in twenty observations recorded by Hutchinson, the right lung was higher in ten cases, and the left in eight, whilst in two the height was equal on the two sides. Anteriorly the pleural sacs of opposite sides come nearly or altogether into contact behind the second piece of the sternum, and continue so for some distance; but opposite the lower end of the sternum the right pleura passes beyond the middle line or remains close to it, while the left recedes to a variable distance. Inferiorly the pleuræ do not pass quite down to the attachments of the diaphragm, but leave a portion of its circumference in contact with the costal parietes. Owing to the height of the diaphragm on the right side (corresponding with the greater convexity of the liver), the right pleural sac is shorter than the left; it is at the same time wider. In the axillary line, the right pleura extends down to the lower edge of the ninth rib, while the left pleura reaches to the lower edge of the tenth (Luschka).

**Structure.**—The pleura possesses the usual characters of serous membranes. The costal part is the thickest, and may be easily raised from the ribs and intercostal spaces. It is strengthened here by a layer of subserous areolar tissue of considerable thickness. On the pericardium and diaphragm the pleura is thinner and more firmly adherent; but it is thinnest and least easily detached upon the surface of the lungs. A difference is also noticeable in the character of the superficial epithelioid layer, for while on the *pleura costalis* this consists of the ordinary flattened cells, on the *pleura pulmonalis* the cells, at least in some animals, are less distinctly flattened and more granular and polyhedral (Klein). Lymphatic vessels are abundant in and beneath the pleura as in other serous membranes, and they communicate in many parts, by means of stomata, with the cavity of the membrane. In the *pleura costalis* they are only found over the intercostal spaces; not over the ribs (Dybkowsky).

## THE LUNGS.

**Form.**—Each lung is irregularly pyramidal or conical, with the base downwards, and one side (the inner) much flattened. The broad, concave *base* is of a semilunar form, and rests upon the arch of the diaphragm. It is bounded by a thin margin, which is received in the angle between the ribs and the diaphragm, and reaches much lower down behind and at the outer side than in front. The *apex* is blunt, and, as already mentioned, reaches into the root of the neck, above the first rib, where it is separated from the first portion of the subclavian artery by the pleural membrane. The *outer surface*, which moves upon the thoracic parietes, is smooth, convex, and of great extent, corresponding with the arches of the ribs and costal cartilages. The *inner surface* is slightly concave, and in part adapted to the convex pericardium. The *posterior* border is rounded, and is received into the deep groove formed by the ribs at the side of the vertebral column; measured from above downwards, it is the longest part of the lung. The *anterior* border is thin and overlaps the pericardium, forming a sharp edge, which, opposite the middle of the sternum, is separated during inspiration from the corresponding margin of the opposite lung only by the two thin layers of the mediastinal

septum. Upon the inner surface, somewhat above the middle of the lung, and considerably nearer to the posterior than the anterior border, is the *root*, where the bronchi and great vessels join the lung.

Each lung is divided into two lobes by a long and deep *fissure*, which commences upon the posterior border, about three inches from the apex, and extends obliquely downwards and forwards to the anterior edge, penetrating from the outer surface to within a short distance of the root. The *upper lobe* is the smaller, and is conical, with an oblique base, whilst the *lower* is quadrilateral. In the right lung a second and shorter fissure runs forwards and upwards from the principal fissure to the anterior edge, and marks off a small portion, or *middle lobe*, from the lower part of the upper lobe. The left lung has no such middle lobe, but presents a deep notch in its anterior border, into which the apex of the heart (enclosed in the pericardium) is received. Besides these differences the right lung is shorter than the left, owing to the diaphragm rising higher on the right side to accommodate the liver, whilst the left lung is the narrower, owing to the heart and pericardium encroaching on the left half of the thorax. On the whole, however, as is seen on a comparison of their weights, the right is the larger of the two lungs.

At the summits and posterior borders the extent of the lungs corresponds with that of the pleural sacs which contain them, but in front and below the relation is variable, inasmuch as the anterior margins pass forwards most completely between the mediastinal and costal pleura during inspiration, and retire to a variable degree from between them in expiration; and in like manner the inferior margins descend, during inspiration, between the costal and diaphragmatic pleuræ; probably at no time do they ever descend completely to the line of reflection between those membranes.

**Weight, Dimensions, and Capacity.**—The lungs vary much in size and weight according to the quantity of blood, mucous, or serous fluid they may happen to contain, which is greatly influenced by the circumstances immediately preceding death, as well as by other causes. The weight of both lungs together, as generally stated, ranges from 30 to 48 ounces, the more prevalent weights being found between 36 and 42 ounces. The proportion borne by the right lung to the left is nearly that of 22 ounces to 20, taking the combined weight of the two at 42 ounces. The lungs are not only absolutely heavier in the male than in the female, but appear to be heavier in proportion to the weight of the body. The general ratio between the weight of the lungs and body, in the adult, fluctuates, according to the estimate of Krause, between one to thirty-five and one to fifty.

The following tables, deduced from Reid's and Hutchinson's observations, show the average weight of the right and left lungs, and of both lungs together, and also the relative weight of the lungs to the body in a certain number of adults of both sexes.

AVERAGE WEIGHT IN TWENTY-NINE MALES AND TWENTY-ONE FEMALES.—(REID.)

|                      | MALE.          | FEMALE. |
|----------------------|----------------|---------|
| Right lung . . . . . | 24 oz. . . . . | 17 oz.  |
| Left lung . . . . .  | 21 oz. . . . . | 15 oz.  |
|                      | 45 oz.         | 32 oz.  |

AVERAGE IN TWENTY-FIVE MALES AND THIRTEEN FEMALES.—(REID AND HUTCHINSON.)

|                                                 | MALE.     | FEMALE. |
|-------------------------------------------------|-----------|---------|
| Proportionate weight of the lungs to the body . | 1 to 37 . | 1 to 43 |

The *size* and *cubical* dimensions of the lungs are influenced so much by their state of inflation, and are therefore so variable, that no useful application can be made of many of the statements given as to these measurements. It is important, however, to ascertain the quantity of *air* which they contain under different conditions. This subject has been investigated by many inquirers, whose statements on this point, however, are exceedingly various. The volume of air contained in the lungs after a forced expiration, was found by Gréhan to be about 57 cubic inches. After an ordinary expiration it would seem that about as much more is retained in the chest. The amount of air inhaled and expelled in ordinary breathing has been very differently estimated by different observers; it is most probably about 30 cubic inches. According to the extensive researches of Hutchinson, men of mean height, between five and six feet, after an extreme inspiration, expel from the chest, by a forced expiration, on an average, 225 cubic inches of air, at a temperature of 60°. This quantity is called by Hutchinson the *vital capacity* of the lungs. It would be better termed *extreme differential capacity*. If to it be added the average quantity found by Gréhan to be retained in the lungs after complete expiration, the result will yield 282 cubic inches of air at 60°, as the average total capacity of the respiratory organs for air in an adult male of ordinary height.

The *vital capacity* (or difference between extreme expiration and extreme inspiration) was found by Hutchinson to bear a uniform relation to the height of the individual, increasing at the rate of eight cubic inches for every additional inch of stature above five feet; but this relation is affected by the weight and age of the individual, as well as by the posture of the body. It seems to depend rather on the mobility than the size of the chest. (Hutchinson, in *Journal of Statistical Society*, August, 1844; and in *Medico-Chirurg. Transactions*, vol. xxix., 1846; also in the article "Thorax," in *Cyclopædia of Anatomy and Physiology*, and the article "Respiration," by Reid, in the same.)

**Texture and consistence.**—The substance of the lung is of a light porous spongy texture, and, when healthy, is buoyant in water: but in the fœtus, before respiration has taken place, and also in certain cases of congestion, collapse, or consolidation from disease, the entire lungs, or portions of them, sink in that fluid. The specific gravity of a healthy lung, as found after death, varies from 0.345 to 0.746. When the lung is fully distended its specific gravity is 0.126, whilst that of the pulmonary substance, entirely deprived of air, is 1.056 (Krause). When pressed between the fingers, the lungs impart a crepitant sensation, which is accompanied by a peculiar noise, both effects being caused by the air contained in the tissue. On cutting into the lung, the same crepitation is heard, and there exudes from the cut surface a reddish frothy fluid, which is partly mucus from the air-tubes and air-cells, and partly a serous exudation, tinged with blood, and rendered frothy by the admixed air.

The pulmonary tissue is endowed with great elasticity, in consequence of which the lungs collapse to about one-third of their bulk when the thorax is opened. Owing to this elasticity also, the lungs, if artificially inflated out of the body, contract to their previous volume when the air is again allowed to escape.

**Colour.**—In infancy the lungs are of a pale rose-pink colour, which might be compared to blood-froth; but as life advances they become darker, and are mottled or variegated with spots, patches, and streaks

of dark slate-colour, which sometimes increase to such a degree as to render the surface almost uniformly black.

The dark colouring matter found in these streaks is in the form of granules and collections of granules, frequently not inclosed in cells; it is deposited in the interstitial areolar tissue mostly near the surface of the lung, and is not found so abundantly in the deeper substance. It exists sometimes in the air-cells, and on the coats of the larger vessels. Its quantity increases with age, and is said to be less abundant in females than in males. In persons who follow the occupation of miners, more especially colliers, the lungs are often intensely charged with black matter. The black substance seems mainly to consist of particles of carbonaceous substance. It is found also in the bronchial glands; indeed, it appears to be taken up in large measure by the lymphatics. In exceptional cases the adult lungs exhibit only very slight streaks of pigment.

**Condition in the fœtus and changes after birth.**—In the fœtus the lungs contain no air, and consequently sink in water.

For a long time the lungs are very small, and occupy only a limited space at the back part of the chest. In an embryo, 16 lines in length, their proportionate weight to the body was found by Meckel to be 1 to 25; in another, 29 lines long, it was 1 to 27; in another 4 inches in length, 1 to 41; and at the full period, 1 to 70. Huschke found that the lungs of still-born male children were heavier in proportion to the weight of the body than those of female children; the ratio being, amongst females, 1 to 76, and in males, 1 to 55.

The lungs undergo very rapid and remarkable changes after birth, in consequence of the commencement of respiration: these affect their size, position, form, consistence, texture, colour, and weight, and should be carefully studied, as furnishing the only means of distinguishing between a still-born child and one that has respired.

1. *Position, size, and form.*—In a fœtus at the full period, or in a still-born child, the lungs, comparatively small, lie packed at the back of the thorax, and do not entirely cover the sides of the pericardium; subsequently to respiration, they expand, and completely cover the pleural portions of that sac, and are also in contact with almost the whole extent of the thoracic wall, where it is covered with the pleural membrane. At the same time, their previously thin sharp margins become more obtuse, and their whole form is less compressed.

2. *Consistence, texture, and colour.*—The introduction of air and of an increased quantity of blood into the fœtal lungs, which ensues immediately upon birth, converts their tissue from a compact, heavy, granular, yellowish-pink, gland-like substance, into a loose, light, rose-pink, spongy structure, which, as already mentioned, floats in water. The changes thus simultaneously produced in their consistence, colour, and texture, occur first at their anterior borders, and proceed backwards through the lungs: they, moreover, appear in the right lung a little sooner than in the left.

3. *Weight.*—The *absolute weight* of the lungs having gradually increased from the earliest period of development to birth, undergoes at that time, from the quantity of blood then poured into them, a very marked addition, amounting to more than one third of their previous weight: for example, the lungs before birth weigh about one and a half ounce, but, after complete expansion by respiration, they weigh as much as two and a half ounces. The *relative weight* of the lungs to the body, which at the termination of intra-uterine life is about 1 to 70, becomes, after respiration, on an average, about 1 to 35 or 40; a proportion which is not materially altered through life. The *specific gravity* is at the same time changed from 1.056 to about .342.

4. *Changes in the trachea after birth.*—In the fœtus the trachea is flattened before and behind, its anterior surface being even somewhat depressed; the ends of the cartilages touch; and the sides of the tube, which now contains only mucus, are applied to one another. The effect of respiration is at first to render the trachea open, but it still remains somewhat flattened in front, and only later becomes convex.

## ROOT OF THE LUNG.

The root of each lung is composed of the bronchus and the large blood-vessels, together with the nerves, lymphatic vessels, and glands, connected together by areolar tissue, and enclosed in a sheath of the pleura.

The root of the right lung lies behind the superior vena cava and part of the right auricle, and below the azygos vein, which arches over it to enter the superior cava. That of the left lung passes below the arch of the aorta, and in front of the descending aorta. The phrenic nerve descends in front of the root of each lung, and the pneumogastric nerve behind, whilst the ligamentum latum pulmonis is continued from the lower border. The bronchus, together with the bronchial arteries and veins, the lymphatics and lymphatic glands, are placed on a plane posterior to the great blood-vessels; the pulmonary artery lies more forward than the bronchus, and to a great extent conceals it, whilst the pulmonary veins are placed still farther in advance. The pulmonary plexuses of nerves lie on the anterior and posterior aspect of the root, beneath the pleura, the posterior being the larger of the two.

The order of position of the great air-tube and pulmonary vessels from above downwards differs on the two sides; for whilst on the right—side the bronchus is highest and the pulmonary artery next, on the left, the air-tube, in passing obliquely beneath the arch of the aorta, is depressed below the level of the left pulmonary artery, which is the highest vessel. On both sides the pulmonary veins are the lowest of the three.

Before entering the substance of the lung, the bronchus divides into two branches, an upper and a lower, one for each lobe. The lower branch is the larger of the two, and on the right side gives off a third small branch which enters the middle lobe of that lung.

The pulmonary artery also divides, before penetrating the lung to which it belongs, into two branches, of which the lower is the larger and supplies the inferior lobe. On the right side the upper of these two branches gives the branch to the middle lobe. A similar arrangement prevails in regard to the right pulmonary veins, the upper one of which is formed by branches proceeding from the superior and middle lobes of the right lung.

## STRUCTURE OF THE LUNGS.

**Coverings.**—Beneath the serous covering, already noticed, there is placed a thin layer of *subserous* areolar tissue mixed with a large number of elastic fibres. It is continuous with the areolar tissue in the interior of the lung, and has been described as a distinct coat under the name of the second or deeper layer of the pleura. In the lungs of many animals, such as the lion, seal, and leopard, this subserous layer forms a very strong membrane, composed principally of elastic tissue; in others, for instance the guinea-pig, a network of plain muscular fibres is found which have a general radiating direction from the apex. A close plexus of lymphatic vessels is also met with in this sub-pleural tissue: these vessels communicate on the one side by means of stomata with the pleural cavity, and on the other, as will be afterwards noticed, with a network of similar vessels in the interalveolar septa of the lungs (Klein).

**Pulmonary substance.**—The substance of the lung is mainly composed of numerous small *lobules* which are attached to the ramifications of the air-tubes, and are held together by those tubes, by the blood-vessels, and by interlobular areolar tissue. These lobules are of various sizes, the smaller uniting into larger ones; they are bounded by flattened sides, and compactly fitted to each other and to the larger air-tubes and vessels of the lungs, those on the surface of the organ having bases, turned outwards, from half a line to a line in diameter. Though mutually adherent by means of fine areolar tissue, they are quite distinct one from the other, and may be readily separated by dissection in the lungs of young animals, and in those of the human foetus. They may be regarded as lungs in miniature, the same elements entering into their composition as form the lung itself. The structure of a single lobule represents in fact that which is essential in the entire organ, each being made up of the following constituents: the *air-tubes* and their *terminating air-cells*, the *pulmonary* and *bronchial* blood-vessels, with lymphatics, nerves, and interstitial areolar tissue.

The principal divisions of the bronchi, as they pass into the lungs, divide into tubes of less calibre, and these again subdivide in succession into smaller and smaller *bronchial tubes*, or *bronchia*, which,

Fig. 182.

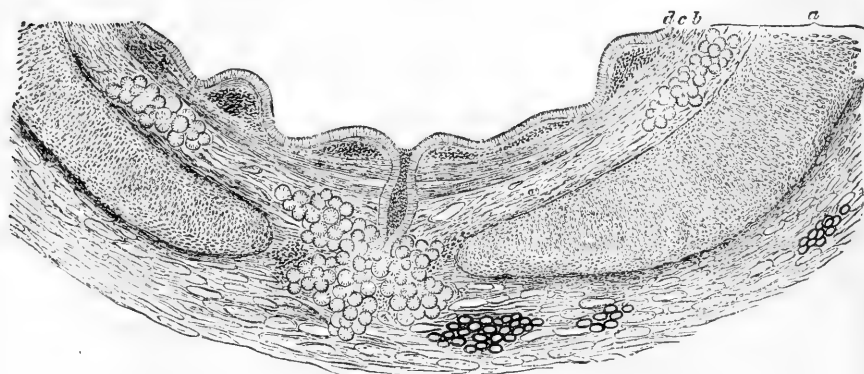


Fig. 182.—PORTION OF TRANSVERSE SECTION OF A BRONCHIAL TUBE ( $\frac{1}{4}$ -INCH IN DIAMETER) (F. E. Schultze). MAGNIFIED 30 DIAMETERS.

*a*, cartilage and fibrous layer with mucous glands, and, in the outer part, a little fat; in the middle, the duct of a gland opens on the inner surface of the tube; *b*, annular layer of involuntary muscular fibres; *c*, elastic layer, the elastic fibres in bundles which are seen cut across; *d*, columnar ciliated epithelium.

diverging in all directions, never anastomose, but terminate separately in the pulmonary lobules. The prevailing form of division is dichotomous; but sometimes three branches arise together, and often lateral branches are given off at intervals from the sides of a main trunk. The larger branches diverge at rather acute angles, but the more remote and smaller ramifications spring less and less acutely. After a certain stage of subdivision each bronchial tube is reduced to a very small size, and, forming what has been termed a *lobular bronchial tube* (fig. 184, *c*),

enters a distinct pulmonary lobule, within which it undergoes still farther division, and at last ends in the small recesses named *air-cells*, *alveoli* or *pulmonary vesicles* (*b*).

Within the lungs the air-tubes are not flattened behind like the bronchi and trachea, but form completely cylindrical tubes. Hence, although they contain the same elements as the larger air-passages, reduced gradually to a state of greater and greater tenuity, they possess certain peculiarities of structure. Thus, the *cartilages* no longer appear as imperfect rings running only upon the front and lateral surfaces of the air-tube, but are disposed over all sides of the tube in the form of irregularly shaped plates and incomplete rings of various sizes. These are most developed at the points of division of the bronchia, where they form a sharp concave ridge projecting inwards into the tube. They may be traced, becoming rarer and rarer and more reduced in size, as far as bronchia only one-half a line in diameter, beyond which the tubes are entirely membranous. The *fibrous* coat extends to the smallest tubes, becoming thinner by degrees and degenerating into areolar tissue. The *mucous membrane*, which extends throughout the whole system of air passages, is also thinner than in the trachea and bronchus, but it retains its ciliated columnar epithelium (fig. 182, *d*). The longitudinal bundles of *elastic fibres* (fig. 182, *c*, in transverse section) are very distinct in both the large and small bronchia, and may be followed by dissection as far as the tube can be laid open, and by the microscope into the smallest tubes. The *muscular* fibres, which in the trachea and bronchi are confined to the back

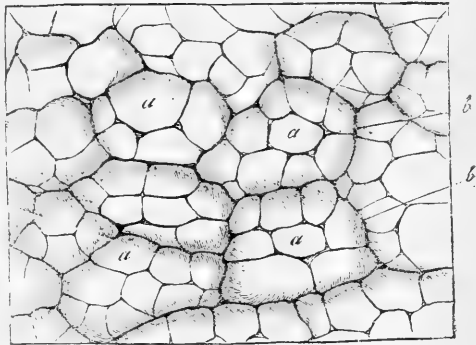
Fig. 183.—PORTION OF THE OUTER SURFACE OF THE COW'S LUNG (from Kölliker after Harting). MAGNIFIED 30 DIAMETERS.

*a*, pulmonary vesicles filled artificially with wax; *b*, the margins of the smallest lobules.

part of the tube, surround the bronchial tubes with a continuous layer of annular fibres, lying inside the cartilaginous plates (fig. 182, *b*); they are found, however, beyond the place where the cartilages cease to exist, and appear as irregular annular fasciculi even in the smallest tubes.

The air-cells are grouped around the terminations of each lobular bronchial tube, and, in the natural state, are always filled with air. They are readily seen on the surface and in a section of a lung, which has been inflated with air and dried; also upon portions of foetal or adult lung injected with mercury or wax (fig. 183, *a*, *a*). In the lungs of some animals, as of the lion, cat, and dog, they are very large, and are distinctly visible on the surface of the organ. In the adult human lung their most common diameter is about  $\frac{1}{100}$ th of an inch,

Fig. 183.



but it varies from  $\frac{1}{160}$ th to  $\frac{1}{70}$ th of an inch; they are larger on the surface than in the interior, and largest towards the thin edges of the organ: they are also said to be very large at the apex of the lung. Their dimensions go on increasing from birth to old age, and they are larger in men than in women. In the infant the diameter is usually under  $\frac{1}{200}$ th of an inch.

The small bronchial tube, as already stated, entering a lobule divides and subdivides a variable number of times, according to the size of the lobule; its divisions, losing their cylindrical form, and being converted into irregular *lobular passages*, are beset, at first sparingly, but afterwards closely and on all sides with numerous little recesses or dilata-

tions, and ultimately terminate near the surface of the lobule in a group of similar recesses. These small recesses, whether seated along the course or at the extremity of an air passage, are the *air-cells*, or *alveoli*; and each group of alveoli, with the comparatively large passage between them, constitutes an *ultimate lobule*, or *infundibulum*, so called from the manner in which it dilates towards its extremity. The arrangement of these finest air-passages and air-cells closely resembles, though on a smaller scale, the reticulated structure of the tortoise's lung, in which large open passages lead in all directions to clusters of wide alveoli, separated from each other by intervening septa of various depths.

At the point where the small bronchial tubes lose their cylindrical character, and become covered on all sides with the cells, their structural elements also undergo a change. The muscular layer disappears or almost so, the longitudinal elastic bundles are broken up into an interlacement of areolar and elastic tissue, which surrounds the commencements of the infundibula, and the columnar ciliated epithelium gives place to a stratum of cubical non-

ciliated cells. The walls of the alveoli, which mainly consist of an indistinctly fibrillated connective tissue with corpuscles scattered here and there, are supported and strengthened by scattered and coiled elastic fibres, especially numerous near their orifices, in addition to which, according to Moleschott and others, there is likewise an intermixture of muscular fibre-cells. The air-cells are lined by a delicate layer of tessellated epithelium, which is most easily demonstrated in the young subject (fig. 185) but is present also in the adult: here, however, the cells are less regular both in size and shape. Their outlines may best be brought into view by treating the tissue with nitrate of silver: their nuclei are for the most part round, and are thus distinguishable from the more oval nuclei of the connective tissue and walls of the blood-vessels. A number of granular rounded amœboid cells are usually

Fig. 184.




Fig. 184. — SEMIDIAGRAMMATIC REPRESENTATION OF TWO INFUNDIBULA, FROM NEAR THE SURFACE OF THE LUNG OF A NEW-BORN CHILD (from Kölliker). 25 DIAMETERS.

*a*, exterior of the two lobuli or infundibula; *b*, pulmonary vesicles or alveoli on these and on *c*, the smallest bronchial ramifications.



Fig. 185.

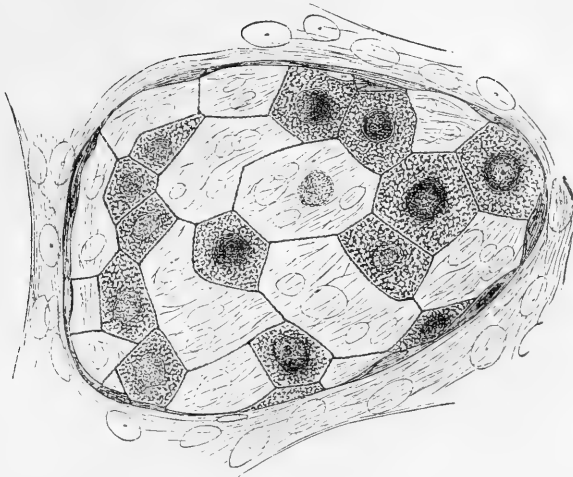


Fig. 185.—AN ALVEOLUS FROM THE LUNG OF A NEW-BORN CHILD, STAINED WITH NITRATE OF SILVER TO SHOW THE EPITHELIUM (F. E. Schultze). 500 DIAMETERS.

Some of the cells are much more distinct and granular than the rest.

to be found free in the air-cells and smaller bronchial tubes: not unfrequently they contain carbonaceous particles. It is conceivable that by the migration of these cells into the pulmonary tissue, the carbon particles may be conveyed into the substance of the lung and thence into the lymphatics and bronchial glands.

Fig. 186.

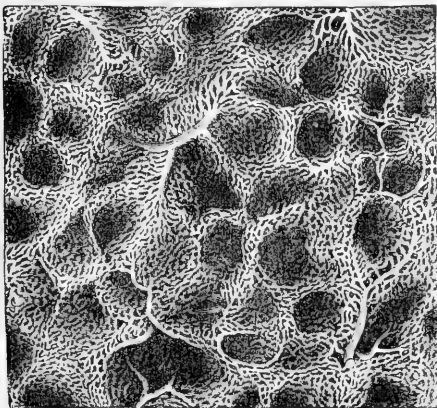


Fig. 186.—CAPILLARY NETWORK OF THE HUMAN LUNG (Kölliker). 60 DIAMETERS.

Fig. 187.

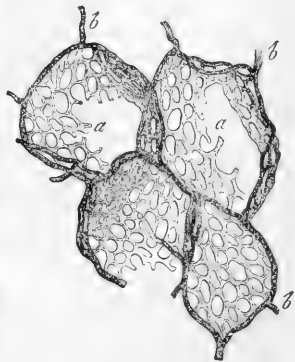


Fig. 187.—CAPILLARY NETWORK OF THE PULMONARY VESICLES OF THE HORSE (from Frey after a preparation by Gerlach). 100 DIAMETERS.

*a*, the capillary network; *b*, the terminal branches of the pulmonary artery passing towards and surrounding in part each pulmonary vesicle.

**Pulmonary vessels.**—The capillary network of the pulmonary vessels (figs. 186 and 187) is spread beneath the epithelium of the air-cells, and is found wherever the finest air-tubes have lost their cylindrical character, and become beset with alveoli. Around the exterior of each alveolus there is an arterial circle, which communicates freely with neighbouring circles, as may be seen near the surface of the lung. From these circular vessels, which vary in diameter from  $\frac{1}{1270}$ th to  $\frac{1}{346}$ th of an inch, the capillary network arises, and covers the bottom of each alveolus, passing also into the interalveolar septa between the walls of adjacent air-cells, and surrounding the mouths of these. As was pointed out by Rainey, the capillary network, in the partitions between contiguous alveoli, is single in the lungs of man and mammalia, although it forms a double layer in the lungs of reptiles.

The capillaries are very fine, measuring, in injected specimens, from  $\frac{1}{2540}$ th to  $\frac{1}{5000}$ th of an inch; the network is so close that the meshes are scarcely wider than the vessels themselves. Those vessels which lie nearest to the mouths of the alveoli are observed arching and coiled over and amongst the elastic fibres found in the interalveolar septa. The capillaries are very superficial, being covered only by the thin layer of tessellated epithelium above mentioned.

The branches of the pulmonary artery accompany the bronchial tubes, but they subdivide more frequently, and are much smaller, especially in their remote ramifications. They ramify without anastomoses, and at length terminate upon the walls of the air-cells and on those of the bronchia in the fine and dense capillary network, from which the radicles of the pulmonary veins arise. The smaller branches of these veins, especially near the surface of the lung, frequently do not accompany the bronchia and arterial branches, but are found to run alone for a short distance through the substance of the organ, finally joining some deeper vein which passes by the side of a bronchial tube, and also forming, according to Rossignol, frequent lateral communications. The veins coalesce into large branches, which at length accompany the arteries, and thus proceed to the root of the lung. In their course through the lung, the artery is usually found above and in front of a bronchial tube, and the vein below.

The pulmonary vessels differ from the systemic in regard to their contents, inasmuch as the arteries convey dark blood, whilst the veins carry red blood. The pulmonary veins, unlike the other veins of the body, are not more capacious than their corresponding arteries; indeed, according to Winslow, Santorini, Haller, and others, they are somewhat less so. These veins have no valves. Lastly, it may be remarked that, whilst the arteries of different lobules are independent (except where a branch of artery supplies two or three lobules) their veins freely anastomose.

**The bronchial vessels.**—The bronchial arteries and veins, which are much smaller than the pulmonary vessels, carry blood for the nutrition of the lung. The bronchial arteries, from one to three in number for each lung, arise from the aorta, or from an intercostal artery, and follow the divisions of the air-tubes through the lung. They are ultimately distributed in three ways: (1) many of their branches ramify in the bronchial lymphatic glands, the coats of the large blood-vessels, and in the fibrous and muscular walls of the large and small air-tubes, and give supply to a copious capillary plexus in the bronchial mucous mem

brane, which in fine bronchial tubes is continuous with that supplied by the pulmonary artery; (2) others form plexuses in the interlobular areolar tissue; (3) branches spread out upon the surface of the lung beneath the pleura, forming plexuses and a capillary network. These may be distinguished from the pulmonary vessels of the superficial air-cells by their tortuous course and open arrangement, by their being outside the tissue investing the lobules, and by ultimately ending in the branches of the *superficial* set of bronchial veins.\*

The bronchial veins have not quite so large a distribution in the lung as the bronchial arteries, since part of the blood carried by the bronchial arteries is returned by the pulmonary veins. The superficial and deep bronchial veins unite at the root of the lung, opening on the right side into the vena azygos, and on the left usually into the superior intercostal vein.

**Lymphatics.**—Part of the lymphatics of the lung take origin from lymphatic capillaries in the interalveolar septa in the usual manner, and where near the surface of the lung come into connection with the *subpleural* lymphatic plexus, previously mentioned (p. 273). They join to form vessels which accompany the branches of the pulmonary artery and vein, running on those vessels in twos or threes, connected by numerous cross branches, and in some cases, becoming perivascular, even completely surrounding the blood-vessel. The branched connective tissue corpuscles with which these *interalveolar* lymphatics are in connection at their origin, send processes upwards to the inner surface of the alveoli, between the epithelial cells (like the pseudostomata of the serous membranes, p. 198).

Other lymphatics, which might be distinguished as bronchial, originate in the mucous membrane of the bronchial tubes, where the connective tissue cells with which they are connected send up processes to the surface as before. From the plexuses of origin they pass through the muscular coat to be distributed in the fibrous layer, where they are most numerous on the side opposite the accompanying branch of the pulmonary artery. Here they not unfrequently are found to enclose nodules or follicles of lymphoid tissue, like those described under "Serous Membranes."†

At the root of the lung the superficial and deep lymphatics unite into a few anastomosing trunks before entering the bronchial lymphatic glands.

**Nerves.**—The nerves to the lung come from the anterior and posterior pulmonary plexuses which are formed chiefly by branches from the pneumogastric nerves, joined by others from the sympathetic system. The fine nervous cords enter at the root of the lung, and follow the air-tubes. Their final distribution requires further examination. According to Remak, whitish filaments from the par vagum follow the bronchia as far nearly as the surface of the lung, and greyish filaments, proceeding from the sympathetic, and having minute ganglia upon them in their course, pass both to the bronchial tubes and pleura. Julius Arnold has described the pulmonary nerves of the frog as ending in pyriform ganglion cells. (Virchow's Archiv. vol. xxviii.)

\* A few small branches of the intercostal arteries also pass to the pulmonary pleura and surface of the lung through the ligamentum latum pulmonis (Turner).

† Burdon-Sanderson, Report of Medical Officer to the Privy Council, 1868. Wywodzoff, Wiener Med. Jahrb. xi. 1866. E. Klein, Proceedings of the Royal Society, January, 1874

## THE LARYNX, OR ORGAN OF VOICE.

The **larynx** is placed at the upper and fore part of the neck, where it forms a considerable prominence in the middle line. It lies between the large vessels of the neck, and below the tongue and os hyoides, to which bone it is suspended. It is covered in front by the cervical fascia along the middle line, and on each side by the sterno-hyoid, sterno-thyroid, and thyro-hyoid muscles, by the upper end of the thyroid body, and by a small part of the inferior constrictor of the pharynx. Behind, it is covered by the pharyngeal mucous membrane, and above it opens into the cavity of the pharynx.

The larynx consists of a framework of cartilages, articulated together, and connected by ligaments, two of which, named the *true vocal cords*, are more immediately concerned in the production of the voice. It also possesses muscles, which move the cartilages one upon another, and modify the form and tension of its apertures, a mucous membrane lining it internally, numerous mucous glands, and, lastly, blood-vessels, lymphatics, and nerves, besides areolar tissue and fat.

## CARTILAGES OF THE LARYNX

The cartilages of the larynx (fig. 188) consist of three single and symmetrical pieces, named respectively the *thyroid cartilage* (*h, i*), the *cricoid cartilage* (*d*), and the *cartilage of the epiglottis* (*f*), and of six others, which occur in pairs, namely, the two *arytenoid cartilages* (*a, a*), the *cornicula laryngis*, and the *cuneiform cartilages*. In all there are nine distinct pieces, but the cornicula and cuneiform cartilages are very small. Only the thyroid and cricoid cartilages are seen on the front and sides of the larynx; the arytenoid cartilages, surmounted by the cornicula laryngis, together with the back of the cricoid cartilage, on which they rest, form the posterior wall of the larynx, whilst the epiglottis is situated in front of, and the cuneiform cartilages on each side of the upper opening.

The **thyroid** cartilage, the largest, consists of two flat lateral plates which are continuous in front, forming a narrow angle with one another like the letter V, most prominent at the upper part. This angular projection is subcutaneous, and is much more marked in the male than in the female, being named in the former the *pomum Adami*. The two symmetrical halves, named the *ala*, are somewhat quadrilateral in form: of each half the anterior border where they are joined is the shortest, the pomum Adami being surmounted by a deep notch (see fig. 180); the free posterior border is thickened and vertical, and is prolonged upwards and downwards into two processes or *cornua* (fig. 188, *b, c*); it gives attachment to the stylo-pharyngeus and palato-pharyngeus muscles; the upper and lower border have each a well-marked sinusity close to the cornu: otherwise the upper is convex, and the lower nearly straight. The flattened *external surface* of each ala is marked by an indistinct oblique line or ridge (fig. 188, immediately below *e*), which, commencing at a tubercle, situated at the back part of the upper border, passes downwards and forwards, so as to mark off the anterior three-fourths of the surface from the remainder. This line gives attachment below to the sterno-hyoid, and above to the thyro-hyoid muscle, whilst the small smooth surface behind it gives origin to part of the inferior constrictor

of the pharynx, and affords attachment by means of areolar tissue, to the thyroid body. On their internal surfaces, the two alæ are smooth and slightly concave. Of the four cornua, all of which bend inwards,

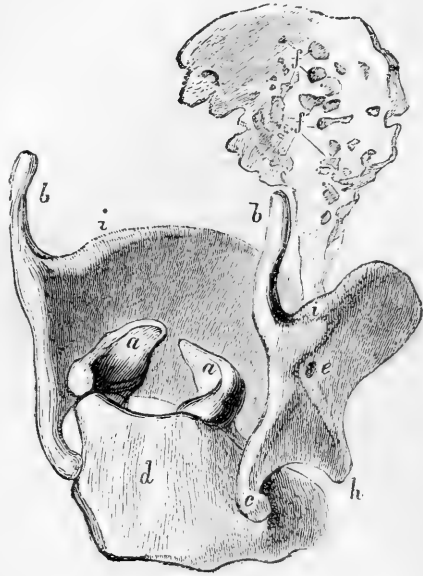Fig. 188. — CARTILAGES OF THE LARYNX SEEN FROM BEHIND AND ON THE RIGHT (Bishop).

*h, i*, thyroid cartilage; the right ala is seen foreshortened; below *e*, the oblique line on its outer surface; *b*, superior, and *c*, inferior cornu of the right side; *d*, cricoid cartilage; to the left of *h*, anterior narrow part of the ring; *a, a*, arytenoid cartilages; *f, f*, epiglottis, the lines point to little pits (for glands) on its surface.

the two *superior* or *great* cornua (fig. 188, *b, b*), pass slightly backwards, and terminate each by a blunt extremity, which is connected, by means of the lateral thyro-hyoid ligament, to the tip of the corresponding great cornu of the os hyoides (fig. 180). The *inferior* or *smaller* cornua (fig. 188, *c*), which are somewhat thicker but shorter, are directed slightly forwards, and each presents, on the inner aspect of the tip, a smooth surface, for articulation with a prominence on the side of the cricoid cartilage.

The **cricoid** cartilage (fig. 188, *d*), so named from being shaped like a signet-ring, is thicker and stronger than the thyroid. It is deep behind, where the thyroid cartilage is deficient, measuring in the male about an inch from above downwards; but in front its vertical measurement is diminished to a fourth or a fifth of an inch. Corresponding with this, the *superior border* is markedly elevated behind, and descends with a deep concavity in front below the thyroid cartilage; while the *inferior border* is horizontal, and connected by membrane to the first ring of the trachea. The posterior elevated part of the upper border is slightly depressed in the middle line (fig. 188); and on the sides of this depression are two convex oval articular facets, directed upwards and outwards, which form a movable joint with the arytenoid cartilages. The *external surface* of the cartilage is convex and smooth in front and at the sides, where it affords attachment to the crico-thyroid muscles, and behind these to the inferior constrictors of the pharynx: in the middle line posteriorly is a slight vertical ridge (fig. 189, *c*) to which some of the longitudinal fibres of the œsophagus are attached. On each side of this ridge is a broad depression occupied by the posterior crico-arytenoid muscle, outside which is a small rounded and slightly raised surface for articulation on either side with the inferior cornu of the thyroid cartilage (fig. 188, *c*). The *internal surface* is covered throughout by the mucous membrane of the larynx. The lower border of the cricoid is circular, but higher up the cartilage

Fig. 188.



is somewhat compressed laterally, so that the passage through it is here elliptical.

The **arytenoid** cartilages (figs. 188, 189, *a*) are two in number, and are symmetrical on each side. They may be compared to three-sided pyramids recurved at the summit, resting by their bases on the posterior and highest part of the cricoid cartilage, and with their tips approaching one another. Each measures five to six lines in height, about three in width, and, in the middle of its inner surface, rather more than a line from before backwards. Of the three faces the *posterior* is broad, triangular, and excavated from above downwards, lodging part of the arytenoid muscle. The *anterior*, convex in its general outline, and somewhat rough, gives attachment to the thyro-arytenoid muscle, and, by a small tubercle, to the corresponding superior or false vocal cord. The *internal* surface, which is the narrowest of the three, and slightly convex, is nearly parallel with that of the opposite cartilage, and is covered by the laryngeal mucous membrane. The anterior and posterior borders, which limit the internal face, ascend nearly in the same vertical plane, whilst the external border, which separates the anterior from the posterior surface, is directed obliquely upwards and inwards.

The *base* of each arytenoid cartilage is slightly hollowed, having towards its inner part a smooth surface for articulation with the cricoid cartilage. Two of its angles are remarkably prominent, viz., one *external*, short, and rounded, which projects backwards and outwards, and into which the posterior and the lateral crico-arytenoid muscles are inserted; the other *anterior*, which is more pointed, and forms a horizontal projection forwards, to which the corresponding true vocal cord is attached.

The *apex* curves backwards and a little inwards, and terminates in a

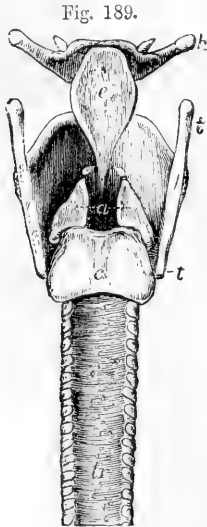


Fig. 189.

Fig. 189.—OUTLINE SHOWING THE POSITION AND FORM OF THE ARYTENOID CARTILAGES FROM BEHIND. ONE-HALF THE NATURAL SIZE.

*h*, hyoid bone; *t*, the superior, and *t'*, the inferior cornu, of the thyroid cartilage; *c*, placed on the median ridge of the back of the cricoid cartilage; *a*, placed between the two arytenoid cartilages, to which the letter points by two dotted lines; the cartilages of Santorini or cornicula are shown above the upper angles; *tr*, the trachea.

blunt point, which is surmounted by a small cartilaginous appendage named "corniculum laryngis."

The **cornicula laryngis**, or **cartilages of Santorini** are two small yellowish cartilaginous nodules of a somewhat conical shape, which are articulated with the summits of the arytenoid cartilages (fig. 189), and serve as it were to prolong them backwards and inwards. They sometimes form part of the arytenoid cartilages.

The **cuneiform cartilages**, or **cartilages of Wrisberg**, are two very small, soft, yellowish cartilaginous bodies, placed, one on each side, in the fold of the mucous membrane which extends from the summit of the arytenoid cartilage to the epiglottis. They have a conical form, with the base directed upwards. They occasion small elevations of the mucous membrane, a little in advance of the cartilages of Santorini, with which, however, they are not directly connected.

The **epiglottis** (fig. 188, *f*; fig. 189, *e*) is a median lamella of yellow cartilage, shaped somewhat like an ovate or obcordate leaf, and covered by mucous membrane. It is placed in front of the superior opening of the larynx, projecting, in the ordinary condition, upwards immediately behind the base of the tongue; but during the act of swallowing it is carried downwards and backwards over the entrance into the larynx, which it covers and protects.

The cartilage of the epiglottis is broad and rounded at its upper free margin, but inferiorly it becomes pointed, and is prolonged by means of a long, narrow, fibrous band (the *thyro-epiglottic ligament*) to the deep angular depression between the ake of the thyroid cartilage, to which it is attached, behind and below the median notch. Its *lateral* borders, which are convex and turned backwards, are only partly free, the lower parts being enveloped in the aryteno-epiglottic folds of mucous membrane. The *anterior* or *lingual* surface is free only in its upper part, where it is covered by mucous membrane. Lower down, the membrane is reflected from it forwards to the base of the tongue, forming three folds or frænula, the middle and lateral glosso-epiglottidean folds. This surface is also connected below with the posterior surface of the os hyoides by means of a median elastic structure named the *hyo-epiglottic ligament*. The *posterior* or *laryngeal* surface, which is free in the whole of its extent, is concavo-convex from above downwards, but concave from side to side: the convexity projecting backwards into the larynx is named the tubercle or cushion. The epiglottis is closely covered by mucous membrane, on removing which, the yellow cartilaginous lamella is seen to be pierced by numerous little pits and perforations, in which are lodged small glands which open on the surface of the mucous membrane.

**Structure of the cartilages of the larynx.**—The epiglottis, the cornicula laryngis and the cuneiform cartilages, are composed of elastic or yellow fibro-cartilage (p. 78), and have little tendency to ossify. The structure of all the other cartilages of the larynx resembles generally that of the costal cartilages (p. 75), like which, they are very prone to ossification as life advances.

#### LIGAMENTS AND JOINTS OF THE LARYNX.

The larynx is connected with the hyoid bone by a broad membrane ending at the sides in two round lateral ligaments. The **thyro-hyoid membrane** or **middle thyro-hyoid ligament**, is a broad, fibrous, and somewhat elastic membrane, which passes up from the whole length of the superior border of the thyroid cartilage to the hyoid bone, where it is attached to the posterior and upper margin of the obliquely inclined inferior surface. Owing to this arrangement, the top of the larynx, when drawn upwards, is permitted to slip within the circumference of the hyoid bone, between which and the upper part of the thyroid carti-

lage there is occasionally found a small synovial bursa. The thyro-hyoid membrane is thick where subcutaneous towards the middle line, but at the sides becomes thin and loose, and is covered by the thyro-hyoid muscles. Behind, is the epiglottis with the mucous membrane of the base of the tongue, separated, however, by adipose tissue and mucous glands. This ligament is perforated by the superior laryngeal artery and nerve of each side. The **lateral thyro-hyoid ligaments**, placed at the posterior limits of the thyro-hyoid membrane, are two rounded yellowish cords, which pass up from the superior cornua of the thyroid cartilage, to the extremities of the great cornua of the hyoid bone. They are distinctly elastic, and frequently enclose a small oblong cartilaginous nodule, which has been named *cartilago triticea*: sometimes this nodule is bony.

The thyroid and cricoid cartilages are connected together by a membranous ligament and synovial articulations. The **crico-thyroid membrane** is divisible into a mesial and two lateral portions. The mesial portion, broad below and narrow above, is a strong triangular yellowish ligament, consisting chiefly of elastic tissue, and is attached to the contiguous borders of the two cartilages. Its anterior surface is convex, is partly covered by the crico-thyroid muscles, and is crossed horizontally by a small anastomotic arterial arch, formed by the junction of the crico-thyroid branches of the right and left superior thyroid arteries. The lateral portions are fixed on each side along the inner edge of the upper border of the cricoid close under the mucous membrane: they become much thinner above, where they are attached in front to the middle of the angle between the alæ of the thyroid cartilage, and behind to the anterior projection of the base of the arytenoid cartilages: the upper edges are free between those attachments and form the **inferior thyro-arytenoid ligaments** or *true vocal cords*.

The **crico-thyroid joints**, between the inferior cornua of the thyroid cartilage and the sides of the cricoid, are two small but distinct articulations, having each a ligamentous capsule and a synovial membrane. The prominent oval articular surfaces of the cricoid cartilage are directed upwards and outwards, while those of the thyroid cartilage, which are slightly concave, look in the opposite direction. The capsular fibres form a stout band behind the joint. The movement allowed is of a rotatory description, the thyroid cartilage revolving on its inferior cornua, and the axis of rotation passing transversely through the two joints.

The **superior thyro-arytenoid ligaments** consist of a few slight fibrous fasciculi, contained within the folds of mucous membrane forming the false vocal cords hereafter to be described, and are fixed in front to the angle between the alæ of the thyroid cartilage, somewhat above its middle, and close to the attachment of the epiglottis: behind, they are connected to the tubercles on the rough anterior surface of the arytenoid cartilages. They are continuous above with scattered fibrous bundles contained in the aryteno-epiglottidean folds.

The **crico-arytenoid joints** are surrounded by a series of thin capsular fibres, which, together with a loose synovial membrane, serve to connect the convex elliptical articular surfaces on the upper border of the cricoid cartilage with the concave articular depressions on the bases of the arytenoid cartilages. There is, moreover, a strong **posterior**



**crico-arytenoid ligament** on each side, arising from the cricoid, and inserted into the inner and back part of the base of the arytenoid cartilage.

The summits of the arytenoid cartilages and the cornicula laryngis have usually a fibrous and synovial capsule to connect them, but it is frequently indistinct.

INTERIOR OF THE LARYNX

The cavity of the larynx is divided into an upper and a lower compartment by the comparatively narrow aperture of the glottis, or *rima glottidis*, the margins of which, in their two anterior thirds, are formed by the lower or *true vocal cords*; and the whole laryngeal cavity, viewed in transverse vertical section (fig. 190), thus presents the appearance of an hour-glass, or of two funnels meeting together by their narrow ends. The upper compartment communicates with the pharynx by the *superior aperture* of the larynx, and contain immediately above the rima glottidis the *ventricles* (*s*) and the upper or *false vocal cords*. The lower compartment passes inferiorly into the tube of the windpipe without any marked constriction or limitation between them. The whole of the interior of the larynx is lined by mucous membrane.

The **superior aperture** of the larynx, by which it communicates with the pharynx, is a triangular opening, wide in front and narrow behind, the lateral margins of which slope obliquely downwards and backwards. It is bounded in front by the epiglottis (fig. 191, A, *e*, and fig. 192, *a*), behind by the summits of the arytenoid cartilages (fig. 191, B, *a*) and cornicula laryngis (*s*) with the angular border of mucous membrane crossing the median space between them, and on the sides by two folds of mucous membrane, the *aryteno-epiglottidean folds*, which, enclosing a few ligamentous and muscular fibres and the cartilages of Wrisberg, pass forwards from the tips of the arytenoid cartilages and

Fig. 190.

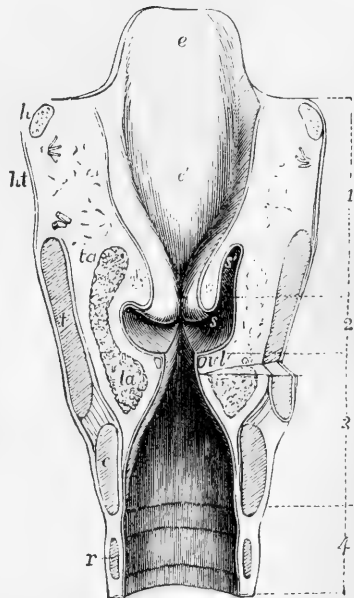


Fig. 190.—ANTERIOR HALF OF A TRANSVERSE VERTICAL SECTION THROUGH THE LARYNX NEAR ITS MIDDLE (Allen Thomson).

1, upper division of the laryngeal cavity; 2, central portion; 3, lower division, continued into 4, part of the trachea; *e*, the free part of the epiglottis; *e'*, its cushion; *h*, the divided great cornua of the hyoid bone; *lt*, thyro-hyoid membrane; *t*, cut surface of the divided thyroid cartilage; *c*, that of the cricoid cartilage; *r*, first ring of the trachea; *ta*, thyro-arytenoid muscle; *vt*, thyro-arytenoid ligament in the true vocal cord covered by mucous membrane at the rima glottidis; *s*, the ventricle; above this, the superior or false cords; *s'*, the sacculus or pouch opened on the right side.

of the arytenoid cartilages and

cornicula to the lateral margins of the epiglottis (fig. 191; and fig. 192, 8, 9, 10).

In studying the form of the laryngeal cavity and its apertures, it is proper to become acquainted with the appearances which they present

Fig. 191.

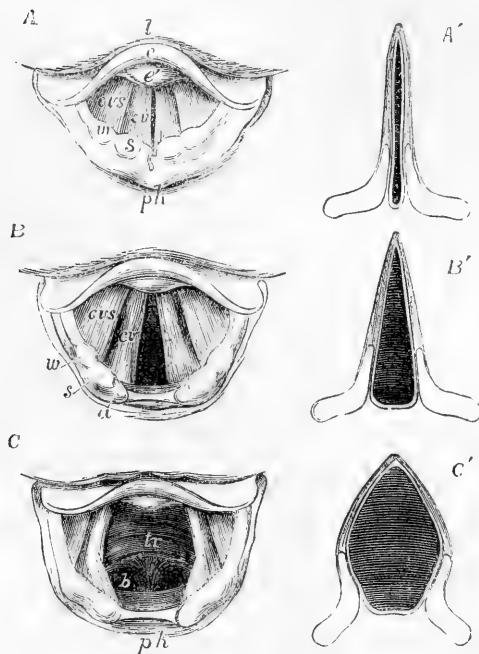


Fig. 191.—THREE LARYNGOSCOPIC VIEWS OF THE SUPERIOR APERTURE OF THE LARYNX AND SURROUNDING PARTS IN DIFFERENT STATES OF THE GLOTTIS DURING LIFE (from Czermak).

A, the glottis during the emission of a high note in singing. B, in easy or quiet inhalation of air. C, in the state of widest possible dilatation as in inhaling a very deep breath. The diagrams A', B', and C', have been added to Czermak's figures to show in horizontal sections of the glottis the position of the vocal ligaments and arytenoid cartilages in the three several states represented in the other figures. In all the figures, so far as marked, the letters indicate the parts as follows, viz. : *l*, the base of the tongue; *e*, the upper free part of the epiglottis; *e'*, the tubercle or cushion of the epiglottis; *ph*, part of the anterior wall of the pharynx behind the larynx; in the margin of the aryteno-epiglottidean fold *w*, the swelling of the membrane

caused by the cartilages of Wrisberg; *s*, that of the cartilages of Santorini; *a*, the tip of the arytenoid cartilages; *c v*, the true vocal cords or lips of the rima glottidis; *c v s*, the superior or false vocal cords; between them the ventricle of the larynx; in C, *t r* is placed on the anterior wall of the receding trachea, and *b* indicates the commencement of the two bronchi beyond the bifurcation, which may be brought into view in this state of extreme dilatation.

on examination during life by means of the laryngoscope, and with the relations of these to the anatomical structure. On thus examining the superior aperture, there are seen on each side two rounded elevations (fig. 191, *s, w*), corresponding respectively to the cornicula and the cuneiform cartilages; while in the middle line in front there is a tumescence of the mucous membrane of the lower part of the epiglottis, enabling that structure to close the aperture more accurately when it is depressed, and named the *tubercle* or *cushion of the epiglottis* (*e'*). The mucous membrane between the arytenoid cartilages is stretched when they are separated (B, C), and folded double when they are approximated (A).\*

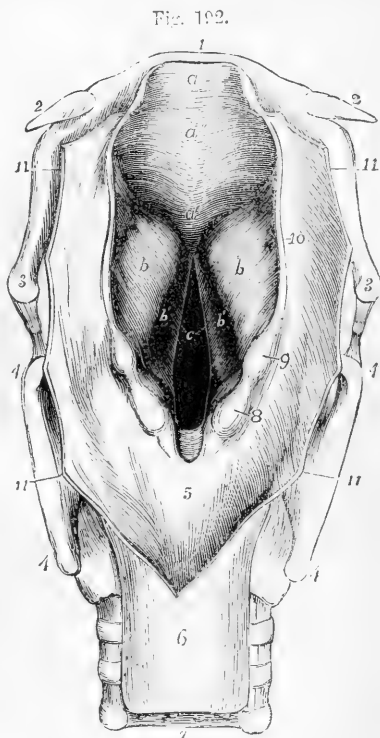
On looking down through the superior opening of the larynx, the *glottis* or *rima glottidis* (fig. 192, *c*) is seen at some distance below, in the form of a long narrow fissure running from before backwards. It

\* Czermak on the Laryngoscope, translated by the New Sydenham Society.

is situated on a level with the lower part of the arytenoid cartilages, and is bounded by the *true vocal cords*. Above the glottis, another pair of projecting folds is seen, the superior or false vocal cords, which are much thinner and weaker and less projecting than the inferior, and are

Fig. 192.—PERSPECTIVE VIEW OF THE PHARYNGEAL OPENING INTO THE LARYNX FROM ABOVE AND BEHIND (Allen Thomson.)

The superior aperture has been much dilated; the glottis is in a moderately dilated condition; the wall of the pharynx is opened from behind and turned to the sides. 1, body of the hyoid bone; 2, small cornua; 3, great cornua; 4, upper and lower cornua of the thyroid cartilage; 5, membrane of the pharynx covering the posterior surface of the cricoid cartilage; 6, upper part of the gullet; 7, membranous part of the trachea; 8, projection caused by the cartilage of Santorini; 9, the same belonging to the cartilage of Wrisberg; 10, aryteno-epiglottidean fold; 11, cut margin of the wall of the pharynx; *a*, free part of the epiglottis; *a'*, its lower pointed part; *a''*, the cushion; *b*, eminence on each side over the sacculus or pouch of the larynx; *b'*, the ventricles; *c*, the glottis: the lines on each side point to the vocal cords.



arched in form. Bounded by the superior and inferior vocal cords are two deep oval depressions, one on each side of the glottis, named the *sinuses*, or *ventricles*, of the larynx (fig. 190, *s*, and fig. 192, *b'*); and leading upwards from the anterior parts of these depressions, external to the superior vocal cords, are two small culs-de-sac, named the *laryngeal pouches* or *sacculi* (fig. 190, *s'*).

The **superior vocal cords**, also called the *false* vocal cords, because they are not immediately concerned in the production of the voice, form on each side a free crescentic margin, bounding the corresponding ventricle of the larynx, the hollow of which is seen on looking down into the laryngeal cavity, the superior vocal cords (*cv*s, fig. 191) being further apart than the inferior.

The **inferior or true vocal cords**, the structures by the vibration of which the sounds of the voice are produced, bound the two anterior thirds of the aperture of the glottis (fig. 192, *c*). The mucous membrane covering them is so thin and closely adherent as to show the yellowish colour of the ligaments through it. Their free edges, which are sharp and straight, and directed upwards, form the lower boundaries of the ventricles, and are the parts thrown into vibration during the production of the voice. Their inner surfaces are flattened, and look towards each other.

The **rima glottidis**, an elongated aperture, situated, anteriorly, between the inferior or true vocal cords, and, posteriorly, between the bases of the arytenoid cartilages, forms a long narrow slit, slightly wider in the centre when nearly closed, as in the production of the voice (fig. 191, A'); when moderately open, as in easy respiration, its shape is that of a long triangle, the pointed extremity being directed forwards, and the base being behind, between the arytenoid cartilages (B); in its fully dilated condition it is lozenge-shaped (the posterior sides being formed by the inner sides of the bases of the arytenoid cartilages), while the posterior angle is truncated (c). The rima glottidis is the narrowest part of the interior of the larynx; in the adult male it measures about eleven lines or nearly an inch in an antero-posterior direction, and three or four lines across at its widest part, which may be dilated to nearly half an inch. In the female, and in males before the age of puberty, its dimensions are less, its antero-posterior diameter being about eight lines, and its transverse diameter about two. The vocal cords are about seven lines long in the adult male, and five in the female.

The **ventricles**, or **sinuses** of the larynx (fig. 190, s, and fig. 192, b'), are narrower at their orifice than in their interior. The outer surface of each is covered by the upper fibres of the corresponding thyro-arytenoid muscle.

The small culs-de-sac named the *laryngeal pouches* (fig. 190, s'), lead from the anterior part of the ventricles upwards, for the space of half an inch, between the superior vocal cords inside, and the thyroid cartilage outside, reaching as high as the upper border of that cartilage at the side of the epiglottis. The pouch is conical in shape, and curved slightly backwards. Its opening into the ventricle is narrow, and is generally marked by two folds of the lining mucous membrane. Numerous small mucous glands, sixty or seventy in number, open into its interior, and it is surrounded by a quantity of fat. Externally to the fat, this little pouch receives a fibrous investment, which is continuous below with the superior vocal cord. Over its laryngeal side and upper end is a thin layer of muscular fibres (compressor sacculi laryngis, aryteno-epiglottideus inferior, Hilton) connected above with those found in the aryteno-epiglottidean folds. The upper fibres of the thyro-arytenoid muscles pass over the outer side of the pouch, a few being attached to its lower part. The laryngeal pouch is supplied abundantly with nerves, derived from the superior laryngeal.

#### MUSCLES OF THE LARYNX.

Besides certain extrinsic muscles elsewhere described—viz., the sterno-hyoid, omo-hyoid, sterno-thyroid, and thyro-hyoid muscles, together with the muscles of the suprahyoid region, and the middle and inferior constrictors of the pharynx, all of which act more or less upon the entire larynx—there are certain *intrinsic muscles* which move the different cartilages upon one another, and modify the size of the apertures and the state of tension of the soft parts. These intrinsic muscles are the *crico-thyroid*, the *posterior* and *lateral crico-arytenoid*, the *thyro-arytenoid*, the *arytenoid*, and the *aryteno-epiglottidean*, together with certain other slender muscular fasciuli. All these muscles, except the arytenoid, which crosses the middle line, are in pairs.

The **crico-thyroid muscle** (fig. 193, 10), is a short thick triangular muscle, seen on the front of the larynx. Its origin from the cricoid cartilage, extends from the median line a considerable way backwards, and its fibres passing upwards and outwards, diverging slightly, are

Fig. 193.

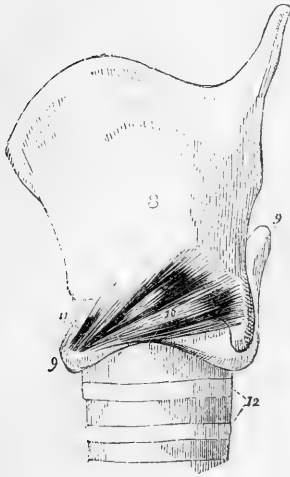


Fig. 194.

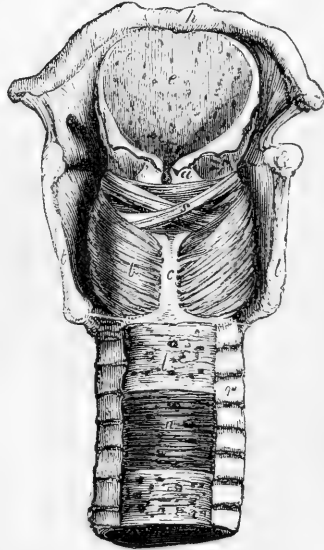


Fig. 193.—LATERAL VIEW OF THE CARTILAGES OF THE LARYNX WITH THE CRICO-THYROID MUSCLE (after Willis).

8, thyroid cartilage; 9, cricoid; 10, crico-thyroid muscle; 11, crico-thyroid membrane; 12, upper rings of the trachea.

Fig. 194.—VIEW OF THE LARYNX AND PART OF THE TRACHEA FROM BEHIND, WITH THE MUSCLES DISSECTED.

*h*, the body of the hyoid bone; *e*, epiglottis; *t*, the posterior borders of the thyroid cartilage; *c*, the median ridge of the cricoid; *a*, arytenoid muscle; *s*, placed on one of the oblique fasciculi; *b*, left posterior crico-arytenoid muscle; *r*, ends of the incomplete cartilaginous rings of the trachea; *l*, fibrous membrane crossing the back of the trachea; *n*, muscular fibres exposed in a part.

inserted into the inferior border of the thyroid cartilage, and into the anterior border of its lower cornu. The lower portion of the muscle, the fibres of which, nearly horizontal, are inserted into the lower cornu, is usually distinct from the rest. Some of the superficial fibres are almost always continuous with the inferior constrictor of the pharynx. The muscles of the two sides separate from one another in the middle line in front, leaving an interval which is triangular with the base upwards. The crico-thyroid membrane is here uncovered.

The **posterior crico-arytenoid muscle** (fig. 194, *b*), situated behind, arises from the broad depression on the corresponding half of the posterior surface of the cricoid cartilage, and its fibres, converging upwards and outwards, are inserted into the outer angle of the base of the arytenoid cartilage, behind the attachment of the lateral crico-arytenoid muscle. The upper fibres are short and almost horizontal;

the middle are the longest and run obliquely; whilst the lower or external fibres are nearly vertical.

In connection with the posterior crico-arytenoid muscle, may be mentioned an occasional small slip in contact with its lower border, viz., the **kerato-cricoid** muscle of Merkel. It is a short and slender bundle, arising from the cricoid cartilage near its lower border, a little behind the inferior cricoid cartilage, and passing obliquely outwards and upwards to be inserted into that process. It usually exists on only one side. Turner found it in seven out of thirty-two bodies. It is not known to be of any physiological significance. (Merkel, *Anat. und Phys. des menschl. Stimm- und Sprachorgans*, Leipzig, 1857; Turner in *Month. Med. Journal*, Feb. 1860.)

Fig. 195.

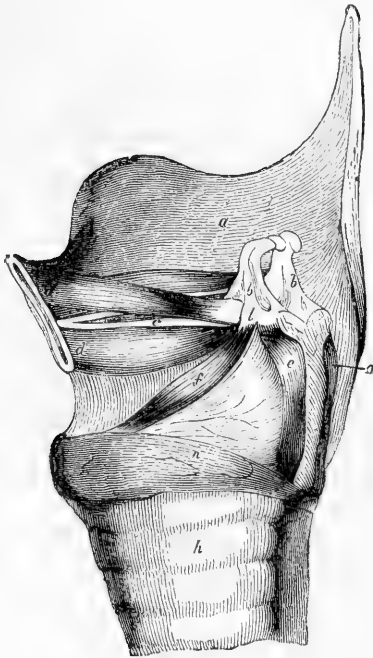


Fig. 195.—SIDE VIEW OF THE LARYNX AFTER REMOVAL OF THE LEFT ALA OF THE THYROID CARTILAGE (Bishop).

The upper thin part of the left thyro-arytenoid muscle has been removed to show the lower part, *d*, supporting the vocal cord, *c*; *a*, inner surface of right ala of thyroid; *b, b*, arytenoid cartilages; *d'*, the small thyro-arytenoid muscle of Semmerring sometimes present; *e*, posterior, and *f*, lateral crico-arytenoid muscles of the left side; *n*, cricoid cartilage; *h*, trachea.

The **lateral crico-arytenoid muscle** (fig. 195, *f*), smaller than the posterior, is in a great measure hidden by the ala of the thyroid cartilage. It arises from the upper border of the side of the cricoid cartilage, its origin extending as far back as the articular surface for the arytenoid. Its fibres pass backwards and upwards, the anterior or upper ones being the longest, and are attached to the outer side of the base of the arytenoid cartilage and to the adjacent part of its anterior surface, in front of the insertion of the posterior crico-arytenoid.

This muscle is covered internally by the mucous membrane, and at its anterior part by the upper part of the crico-thyroid muscle. The upper part is in close contact and indeed is sometimes blended with the thyro-arytenoid.

The **thyro-arytenoid muscle** is situated above the lateral crico-arytenoid. It is thick below and in front, and becomes thinner above and behind. It consists of several distinct fasciculi, which arise in front from the internal surface of the thyroid cartilage, the lower two-thirds, close to the angle formed by the junction of the two alæ, and extend almost horizontally backwards and outwards to

reach the base of the arytenoid cartilage. The lower portion of the muscle (fig. 195 *d*), which forms a thick fasciculus, receives a few additional fibres from the posterior surface of the crico-thyroid mem-

brane, and is inserted into the anterior projection on the base of the arytenoid cartilage and to the surface adjacent, close to the insertion of the lateral crico-arytenoid. The *upper thin portion* of the thyro-arytenoid muscle is inserted higher up on the anterior surface and outer border of the arytenoid cartilage.

The lower portion of the muscle contributes to the support of the true vocal cord lying parallel with it; into the outer surface of the ligament some of its fibres are inserted. The upper thin portion, external to the lower, lies upon the laryngeal pouch and ventricle, close beneath the mucous membrane: indeed the entire muscle may be exposed from the interior of the larynx, by raising the mucous membrane of the sinus and vocal cord. Fibres from this muscle pass round the border of the arytenoid cartilage, and become continuous with some of the oblique fibres of the arytenoid muscle, to be presently described.

Santorini described three thyro-arytenoid muscles, an *inferior* and a *middle*, which are constant, and a *superior*, which is sometimes present. The fibres of the superior fasciculus (fig. 195, *d'*), when present, arise nearest to the notch of the thyroid cartilage, and are attached to the upper part of the base of the arytenoid cartilage. This is named by Sæmmerring the *small* thyro-arytenoid, whilst the two other portions of the muscle constitute the *great* thyro-arytenoid of that author.

**Arytenoid and aryteno-epiglottidean muscles.**—When the mucous membrane is removed from the back of the arytenoid cartilages, a thick band of transverse fibres constituting the arytenoid muscle is laid bare (fig. 194, *a*), and on the surface of this are seen two slender decussating oblique bundles (*s*), formerly described as portions of the arytenoid muscle (*arytenoideus obliquus*), but now more generally considered as parts of the aryteno-epiglottidean muscles, with which they are more closely associated both in the disposition of their fibres and in their action. The *arytenoid* muscle passes straight across, and its fibres are attached to the whole extent of the concave surface on the back of each arytenoid cartilage. The *aryteno-epiglottidean* muscles (fig. 196 *b*) arising near the inferior and outer angles of the arytenoid cartilages, decussate one with the other, and

Fig. 196.

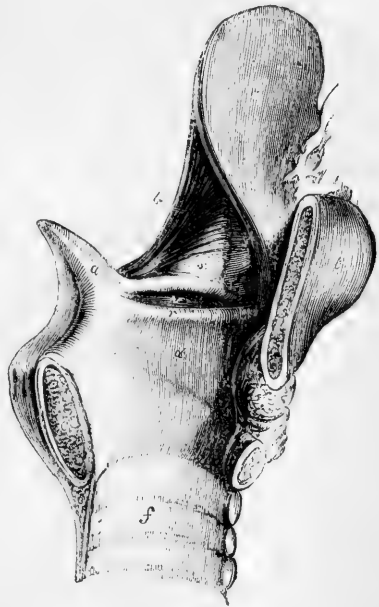


Fig. 196.—VIEW OF THE INTERIOR OF THE LEFT HALF OF THE LARYNX (after Hilton.)

*a*, left arytenoid cartilage; *c, c*, divided surfaces of the cricoid cartilage; *t*, thyroid cartilage; *e*, epiglottis; *v*, left ventricle of the larynx; *r*, left inferior or true vocal cord; *s*, placed on the inner wall of the laryngeal pouch; *b*, aryteno-epiglottidean muscle; *f*, interior of the trachea.

their fibres are partly attached to the upper and outer part of the opposite cartilage, partly pass forwards in the aryteno-epiglottidean fold, and partly join the fibres of the thyro-arytenoid muscle.

A few fibres associated with the anterior and upper part of the thyro-arytenoid muscle have been described as a *thyro-epiglottidean* muscle.

**Actions of the intrinsic muscles of the larynx.**—The *crico-thyroid* muscles produce the rotation forwards and downwards of the thyroid cartilage on the cricoid, which is permitted by the crico-thyroid articulations (fig. 197). In this

Fig. 197.

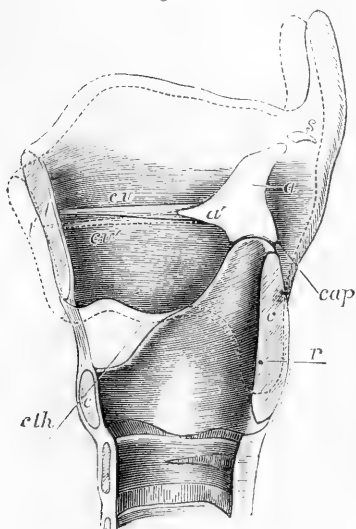


Fig. 197.—OUTLINE OF THE RIGHT HALF OF THE CARTILAGES OF THE LARYNX AS SEEN FROM THE INSIDE, WITH THE THYRO-ARYTENOID LIGAMENT, TO ILLUSTRATE THE ACTION OF THE CRICO-THYROID MUSCLE (Allen Thomson).

*t*, cut surface of the thyroid cartilage in the middle anteriorly; *c, c*, the same of the cricoid cartilage before and behind; *a*, the inner surface of the right arytenoid cartilage; *a'*, its anterior process; *s*, the right cartilage of Santorini; *c r*, the thyro-arytenoid ligament; the position of the lower cornu of the thyroid cartilage on the outside of the cricoid is indicated by a dotted outline, and *r* indicates the point or axis of rotation of the one cartilage on the other; *c t h*, indicates a line in the principal direction of action of the crico-thyroid muscle; *cap*, the same of the posterior crico-arytenoid muscle; the dotted line, of which *t'* indicates a part, represents the position into which the thyroid cartilage is moved by the action of the crico-thyroid muscle; if the arytenoid cartilages are fixed by muscles acting in the direction of *cap*, the vocal cords will be elongated and rendered tense by contraction of the crico-thyroid muscles, as indicated by *c r*.

movement the arytenoid cartilages, being attached to the cricoid cartilage at a level considerably above the axis of rotation, have their distance from the fore-part of the thyroid cartilage increased, and, in this way, the crico-thyroid muscles increase the tension of the vocal cords. The *thyro-arytenoid* muscles are, in their lower parts, the opponents of the crico-thyroid, raising the fore part of the thyroid cartilage and decreasing the tension of the vocal cords; the upper parts of these muscles, being attached higher up on the arytenoid cartilages, depress them.

The *lateral crico-arytenoid* muscles, by pulling forwards the outer angles of the arytenoid cartilages, approximate the vocal cords to the middle line. The *posterior crico-arytenoid* muscles pull backwards the outer angles of the arytenoid cartilages, and thus draw asunder the posterior extremities of the vocal cords, and dilate the glottis to its greatest extent; they are likewise the elevators of the arytenoid cartilages.

The *arytenoid* muscle draws the arytenoid cartilages together, and, from the structure of the crico-arytenoid joints, this approximation when complete is necessarily accompanied with depression. The *aryteno-epiglottidean* muscles at once depress and approximate the arytenoid cartilages, which they include in their embrace, and draw down the epiglottis, so as to contract the whole superior aperture of the larynx



With the aid of the laryngoscope it may be seen that in ordinary breathing the rima glottidis is widely open (fig. 191, B, B'), and that in vocalisation the vocal cords come closely together; which is effected principally, no doubt, by the action of the lateral crico-arytenoid muscles, assisted by the arytenoid and perhaps by the thyro-arytenoid, and accompanied with a varying amount of contraction of the crico-thyroid muscles. The regulation of the tension of the vocal cords and of the width of the aperture of the glottis, in the production of high and low pitched notes, is probably accomplished by the crico-thyroid and thyro-arytenoid muscles. The movement of the thyroid on the cricoid cartilage, effected by these muscles during the passage of the voice from one extreme of the scale to the other, may be detected by placing the tip of a finger over the crico-thyroid ligament. The arytenoid and aryteno-epiglottidean muscles come into action in spasmodic closure of the upper aperture of the larynx; the complete descent of the epiglottis, however, can only take place when the tongue is retracted and the thyroid cartilage pushed against it, as in the act of swallowing.

It is remarked by Henle that, with the exception of the crico-thyroid and posterior crico-arytenoid, the muscles of the larynx, namely, those "which lie in the space enclosed by the laminae of the thyroid cartilage, and above the cricoid, the fibres of which are substantially horizontal, may be regarded in their totality as a kind of sphincter. Such a sphincter is found in its simple form embracing the entrance of the larynx in reptiles; and the complication which it attains in the higher vertebrates arises, like the complication of the muscles generally, from the fibres finding various points of attachment in their course, by which means they are broken up and divided."

#### THE MUCOUS MEMBRANE AND GLANDS OF THE LARYNX.

The laryngeal **mucous membrane** is thin and of a pale colour. In some situations it adheres intimately to the subjacent parts, especially on the epiglottis, and still more in passing over the true vocal cords, on which it is extremely thin and most closely adherent. About the upper part of the larynx, above the glottis, it is extremely sensitive. In or near the aryteno-epiglottidean folds it covers a quantity of loose areolar tissue, which is liable in disease to infiltration, constituting œdema of the glottis. Like the mucous membrane in the rest of the air-passages, that of the larynx is covered in the greater part of its extent with a columnar ciliated epithelium, by the vibratory action of which the mucus is urged upwards. The cilia are found higher up in front than on each side and behind, reaching in the former direction as high as the widest portion of the epiglottis, and in the other directions only to a line or two above the superior vocal cords: above these points the epithelium loses its cilia, and gradually assumes a stratified squamous form, like that of the pharynx and mouth. Upon the vocal cords also the epithelium is squamous, although both above and below them it is ciliated columnar.

**Glands.**—The lining membrane of the larynx is provided with numerous *glands*, which secrete an abundant mucus; and the orifices of which may be seen almost everywhere, excepting upon and near the true vocal cords. They abound particularly upon the epiglottis, in the substance of which are found upwards of fifty small compound glands, some of them perforating the cartilage. Between the anterior surface of the epiglottis, the hyoid bone and the root of the tongue, is a mass of yellowish fat, erroneously named the epiglottidean gland, in or upon which some real glands may exist. Another collection of glands, namely *arytenoid*, is placed within the fold of mucous membrane in front of each arytenoid cartilage, from which a series may be traced for-

wards, along the corresponding superior vocal cord. The glands of the laryngeal pouches have already been described.

#### VESSELS AND NERVES OF THE LARYNX:

The *arteries* of the larynx are derived from the superior thyroid, a branch of the external carotid, and from the inferior thyroid, a branch of the subclavian. The *veins* join the superior, middle, and inferior thyroid veins. The *lymphatics* are numerous, and pass through the cervical glands. Their mode of distribution resembles that in the trachea. The *nerves* are supplied from the superior laryngeal and inferior or recurrent laryngeal branches of the pneumogastric nerves, joined by branches of the sympathetic. The superior laryngeal nerves supply the mucous membrane, and also the crico-thyroid muscles, and in part the arytenoid muscle. The inferior laryngeal nerves supply, in part, the arytenoid muscle, and all the other muscles, excepting the crico-thyroid.

The superior and inferior laryngeal nerves of each side communicate with each other in two places, viz., at the back of the larynx, beneath the pharyngeal mucous membrane, and on the side of the larynx, under the ala of the thyroid cartilage. Numerous ganglion-cells are found on the branches, both on those which enter the muscles, and also underneath the mucous membrane. End-bulbs are also described in the mucous membrane which covers the posterior or laryngeal surface of the epiglottis (Lindemann).

The further details of the distribution of the vessels and nerves are to be found elsewhere.

#### FORMATION AND GROWTH OF THE LARYNX:

The rudimentary larynx consists, according to Valentin, of two slight enlargements having a fissure between them, and embracing the entrance from the pharynx into the trachea. According to Reichert, the rudiments of the arytenoid cartilages are the first to appear. Rathke, however, states that all the true cartilages are formed at the same time, and are recognisable together as the larynx enlarges, the epiglottis only appearing later. In the human embryo, Fleischmann could not detect the cartilages at the seventh week, though the larynx was half a line in length, but at the eighth week there were visible the thyroid and cricoid cartilages, consisting at that period of two lateral halves, which are afterwards united together in the sixth month. Kölliker, on the other hand, states that those cartilages are single from the first.

During childhood the growth of the larynx is very slow. Richerand found that there was scarcely any difference between the dimensions of this organ in a child of three and in one of twelve years of age. Up to the age of puberty the larynx is similar in the male and female, the chief characteristics at that period being the small size and comparative slightness of the organ, and the smooth rounded form of the thyroid cartilage in front. In the female these conditions are permanent, excepting that a slight increase in size takes place. In the male, on the contrary, at the time of puberty, remarkable changes rapidly occur, and the larynx becomes more prominent and more perceptible at the upper part of the neck. Its cartilages become larger, thicker, and stronger, and the ala of the thyroid cartilage project forwards in front so as to form at their union with one another, the prominent ridge of the *pomum Adami*. At the same time, the median notch on its upper border is considerably deepened. In consequence of these changes in the thyroid cartilage, the distance between its angle in front and the arytenoid cartilages behind becomes greater, and the chordæ vocales are necessarily lengthened. Hence the dimensions of the glottis, which, at the time of puberty, are increased by about one-third only in the female, are nearly doubled in the male, and the adult male larynx becomes altogether one-third larger than that of the female.

Towards the middle of life the cartilages of the larynx first show a tendency to ossification; this commences first in the thyroid cartilage, then appears in the cricoid, and lastly in the arytenoid cartilages. In the thyroid cartilage the ossification usually begins at the cornua and posterior borders; it then gradually

extends along the whole inferior border, and subsequently spreads upwards through the cartilage. The cricoid cartilage first becomes ossified at its upper border upon each side, near the two posterior articular eminences, and the ossification invades the lateral parts of the cartilage before encroaching either in front or behind. The arytenoid cartilages become ossified from below upwards.

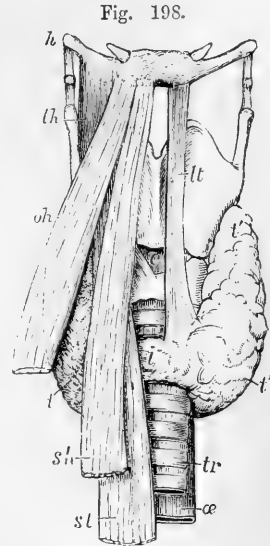
## DUCTLESS GLANDS ON THE LARYNX AND TRACHEA.

### THE THYROID BODY.

The **thyroid body** or **gland** (fig. 198) is a soft reddish and highly vascular organ, consisting of two *lateral lobes*, united together towards their lower ends by a transverse portion named the *isthmus*. Viewed

Fig. 198.—SKETCH SHOWING THE FORM AND POSITION OF THE THYROID BODY (Allen Thomson). ONE-HALF THE NATURAL SIZE.

The larynx and surrounding parts are viewed from before; on the right side the muscles covering the thyroid body are retained, on the left side they are removed; *h*, hyoid bone; *th*, right thyro-hyoid muscle; *oh*, omo-hyoid; *sh*, sterno-hyoid; *st*, sterno-thyroid; *c*, on the crico-thyroid membrane above the cricoid cartilage, points by a dotted line to the right crico-thyroid muscle; *tr*, the trachea; *æ*, the œsophagus appearing behind and slightly to the left of the trachea; *t*, the right lobe of the thyroid body partially seen between the muscles; *t'*, the left lobe entirely exposed; *i*, the isthmus; *lt*, the fibrous or muscular band termed levator thyroideæ, which is more rarely found in the middle line or to the right side, and which existed in the case from which the figure was taken.



as a whole, it is convex on the sides and in front, forming a rounded projection upon the trachea and larynx. It is covered by the sterno-hyoid, sterno-thyroid, and omo-hyoid muscles, and behind them it comes into contact with the sheath of the great vessels of the neck. Its deep surface is concave where it rests against the trachea and larynx. It usually extends so far back as to touch the lower portion of the pharynx, and on the left side the œsophagus also.

The general direction of each lobe is, from below, upwards and backwards, reaching from the fifth or sixth ring of the trachea to the posterior border of the thyroid cartilage, of which it covers the inferior cornu and adjoining part of the ala. The upper thin end of the lobe, which is sometimes called the *cornu*, is usually connected to the side of the thyroid and cricoid cartilages by areolar tissue.

The transverse part, or *isthmus* (*i*), which connects the two lateral lobes a little above their lower ends, commonly lies across the third and fourth rings of the trachea, but is very inconstant in size, shape, and position, and the part of the trachea covered by it differs accordingly. From the upper part of the isthmus, or from the adjacent portion of either lobe, a slender conical process, named, from its shape and position, the *pyramid*, or *middle lobe*, often proceeds upwards to the hyoid bone, to which its apex is attached by loose fibrous tissue.

Commonly this process lies somewhat to the left ; occasionally it is thicker above than below, or is completely detached, or is split into two parts : sometimes it appears to consist of fibrous tissue only. In many cases muscular fasciculi, most frequently derived from the thyro-hyoid muscle, but occasionally independent, descend from the

Fig. 199.

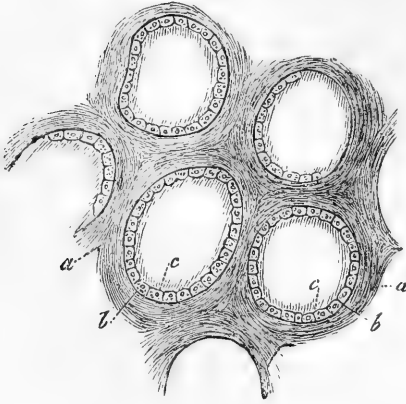


Fig. 199.—MAGNIFIED VIEW OF SEVERAL VESICLES FROM THE THYROID GLAND OF A CHILD (from Kölliker).

*a*, connective tissue between the vesicles ; *b*, capsule of the vesicles ; *c*, their epithelial lining.

hyoid bone to the thyroid gland or its pyramidal process. They are known as the *levator glandulæ thyroideæ* (fig. 198, *lt*). It sometimes, though rarely, happens that the isthmus is altogether wanting the lateral lobes being then connected by areolar or fibrous tissue only : this is the natural condition in some animals.

Each *lateral lobe* measures usually two inches or upwards in length, an inch and a quarter in breadth, and three-quarters of an inch in thickness at its largest part, which is below its middle : the right lobe is usually a few lines longer and wider than the left.

The isthmus measures nearly half an inch in breadth, and from a quarter to three-quarters of an inch in depth.

The *weight* of the thyroid body varies ordinarily from one to two ounces. It is always larger in females than in males, and appears in many of the former to undergo a periodical increase about the time of menstruation. It commonly varies a good deal in size, and occasionally undergoes enormous enlargement, constituting the disease called goitre, or bronchocele. Its *colour* is usually of a dusky brownish red, but sometimes of a yellowish hue. The *function* of the thyroid body is unknown.

**Structure.**—The texture of this organ is firm, and to the naked eye appears coarsely granular. It is invested by a thin transparent layer of dense areolar tissue, which connects it with the adjacent parts, surrounds and supports the vessels as they enter it and imperfectly separates its substance into small masses of irregular form and size. This interstitial areolar tissue is free from fat, and contains elastic fibres.

When the organ is cut into, a yellow glairy fluid escapes from the cut surface. Its substance is composed of multitudes of closed *vesicles*, which are surrounded by capillary vessels, and are held together in groups or imperfect lobules by areolar tissue. The size of the vesicles varies from  $\frac{1}{70}$ th of an inch to that of a millet-seed, so as to be visible to the naked eye,—varying, however, in different individuals, more than in the same thyroid body. They are spherical, ovoid, or flattened, and

perfectly distinct from each other. Each vesicle consists of a simple basement membrane (fig. 199 *b*), with a single epithelial layer of cells (*c*) lining its inner surface; at least in the fœtus and young subject, for it would appear that the cells for the most part become detached in the progress of growth. The fluid coagulates by the action of heat or of alcohol, preserving, however, its transparency.

One of the most frequent pathological changes to which the thyroid body is subject consists in the accumulation within its vesicles of a gelatinous-looking substance (colloid): this may occur without giving rise to very great enlargement of these vesicles, but in certain forms of goître it distends them to an enormous degree.

**Vessels and nerves.**—The *arteries* of the thyroid body are the superior and inferior thyroids of each side, to which is sometimes added a fifth vessel, the *thyroidea ima* of Neubauer and Erdmann. The arteries are remarkable for their large relative size, and for their frequent and large anastomoses; they terminate in a capillary network, upon the outside of the closed vesicles. The *veins*, which are also large, ultimately form plexuses on the surface, from which a superior, middle, and inferior thyroid vein are formed on each side. The superior and middle thyroid veins open into the internal jugular; the inferior veins issue from a plexus formed in front of the trachea, and open on the right side into the superior cava, and on the left into the brachio-cephalic vein. The *lymphatics* of the thyroid body form numerous and large anastomosing trunks, both at the surface of the organ and throughout its substance: they originate, according to the observations of Frey, in the connective tissue which unites the gland-vesicles, with the cavity of which they appear not to be in communication.

The *nerves* are derived from the middle and inferior cervical ganglia of the sympathetic. They accompany the blood-vessels; and have here and there ganglion-cells in their course; their mode of ending is unknown.

**Development.**—Remak states that the thyroid body is developed from the anterior wall of the pharynx. In a human embryo at the third month, Kölliker found the thyroid body consisting of isolated vesicles, with rounded cells in their interior. The multiplication of these vesicles takes place, according to Kölliker, either by constriction and subsequent division of one vesicle into two, or by a process of gemmation. The transverse part of the gland is said to be developed subsequently to the two lateral lobes. In the fœtus, and during early infancy, this organ is relatively larger than in after-life; its proportion to the weight of the body in the new-born infant being that of 1 to 240 or 400, whilst at the end of three weeks it becomes only 1 to 1160, and in the adult 1 to 1800 (Krause). In advanced life the thyroid body is liable to become indurated, and frequently contains earthy deposit; its vesicles also attain a very large size.

#### THE THYMUS GLAND.

The *thymus gland* or *body* is a temporary organ which reaches its greatest size at about the end of the second year of life, after which period it ceases to grow, and is gradually reduced to a mere vestige. Its function is not fully understood, although it is probable that it is in some way connected with the elaboration of the blood in infancy. When examined in its mature state in an infant under two years of age, it appears as a narrow elongated glandular-looking body, situated partly in the thorax, and partly in the lower region of the neck: below, it lies in the anterior mediastinal space, close behind the sternum, and in front of the great vessels and pericardium; above, it extends upwards upon the trachea in the neck. Its colour is greyish, with a pinkish tinge; its consistence is soft and pulpy, and its surface appears distinctly lobulated. It consists of *two lateral lobes*, which touch each

other along the middle line, and are nearly symmetrical in form, though generally unequal in size, sometimes the left, and at other times the right lobe being the larger of the two. An *intermediate lobe* often exists between the two lateral ones, and occasionally the whole body forms a single mass.

Each lateral lobe is of an elongated triangular form. The apex usually mounts up into the neck, reaching as high as to the lower border of the thyroid body. The *base* rests on the upper part of the pericardium, to which it is connected by areolar tissue. The *anterior* surface, slightly convex, is covered by the first and the upper part of the second piece of the sternum, reaching, in the infant at birth, as low down as the level of the fourth costal cartilage. It is attached to the sternum by loose areolar tissue, but opposite the upper part of that bone is separated from it by the origins of the sterno-hyoid and sterno-thyroid, which muscles also cover it in the neck. The *posterior* surface, somewhat concave, rests, in the thorax, upon part of the pericardium; upon the front of the aortic arch and the large arteries arising from it, and also on the left innominate vein. In the neck it lies upon the front and corresponding side of the trachea. Its *external border* is in contact with the corresponding layer of the mediastinal pleura, near the internal mammary artery, and higher up (in the neck), with the sheath of the carotid artery. The *internal border* is in close contact with that of the opposite lobe. The dimensions of the thymus vary according to its stage of development. At birth it measures rather more than two inches in length, an inch and a half in width at its lower part, and about three or four lines in thickness. Its weight at that period is about half an ounce. Its specific gravity, which is at first about 1.050, diminishes as the gland continues to waste.

**Structure.**—The lateral halves or *lobes* of the thymus gland are each invested by a capsule of thin areolar tissue, which sends partitions into the gland between the several lobules: on its outer surface the capsule is covered by a layer of flattened epithelioid cells. Each lobe consists of numerous polyhedral *lobules*, the most of them from two to five lines in diameter, connected by a more delicate intervening areolar tissue. These primary lobules are each made up of a number of small nodules or follicles (fig. 200, *b, b*), as they have been termed. These are, in many respects, similar in structure to ordinary lymphoid follicles, such as those of the tonsils or of Peyer's patches in the intestine: consisting, like these, of retiform tissue, the meshes of which are filled with lymph corpuscles; at the surface of each follicle the retiform tissue is somewhat closer, so as to form a species of capsule for it. In some animals these capsules completely enclose the follicles, but in others, including man, several follicles may be united towards the centre of the lobule, which is then commonly of softer consistence than the other parts, and apt to break down if not perfectly fresh, so as to give the deceptive appearance of a central cavity (see fig. 200). Scattered here and there in the retiform tissue are peculiar corpuscles, composed of a substance which strongly refracts the light, and readily becomes stained by carmine. They present an appearance of concentric striation, and are known as the *concentric corpuscles of Hassall*. They vary in size from that of a blood-corpuscle to three times that diameter, or more; the larger often contain smaller ones in their interior.

According to the description given by Astley Cooper the thymus presents a continuous anfractuous cavity, the extensions of which pass into the lobules: it is probable, however, that the cavity described was produced artificially, the lymphoid tissue towards the centre of each lobule being rather looser than in the outer parts.

**Vessels and Nerves.**—The *arteries* of the thymus are derived from various sources, viz., from the internal mammary, the inferior and superior thyroid, the subclavian and carotid arteries. Their branches penetrate to the centre of the lobules, whence they radiate outwards, terminating in capillary vessels, which form a network within each follicle (fig. 200), and pass at its exterior into the *veins*. These pursue a different course from the arteries: they, for the most part, open into the left innominate vein.\*

The *lymphatics* are large. According to the observations of His on the calf, the larger blood-vessels passing to the centre are each accompanied by two or more lymphatic trunks. These arise from an interlobular plexus, which again is in connection with vessels which surround and enclose the individual follicles (as in the intestinal follicles).

The *nerves* are very minute. Haller thought that they were partly derived from the phrenic nerves, but, according to Cooper, no filaments from these nerves go into the gland, although they reach the investing capsule, as does also a branch from the *descendens noni*. Small filaments, derived from the pneumo-gastric and sympathetic nerves, descend, on the thyroid body, to the upper part of the thymus. Sympathetic nerves also reach the gland along its various arteries.

**Development and Growth.**—The early development of the thymus has been carefully studied by Simon, whose researches were chiefly conducted in the embryos of swine and oxen. In embryos about half an inch in length, it may be distinguished with the aid of the microscope; and in those of one and a half inch, with a simple lens. When first distinguishable, it appears to consist of a simple closed tube, lying along the carotid vessels (most likely the *tube* so described is a collection of embryonic cells enclosed in a membranous capsule). It has no connection with the respiratory mucous membrane, as was supposed by Arnold; and so soon as discoverable, it is found to be perfectly distinct from the thyroid body. At intervals along the sides of this tube or capsule, small projections bud out, and these go on subsequently branching out into groups of two or four,—the formation of the permanent follicles being merely the last repetition of this process. In the human foetus at the seventh week, the thymus is bi-lobed below but still single above; at about the ninth week, it consists of two minute elongated parallel parts, lying chiefly on the upper part of the pericardium; at the twelfth week it is already comparatively broad, and its surface is entirely covered with lobules; it then increases rapidly until birth, but not with

Fig. 200.

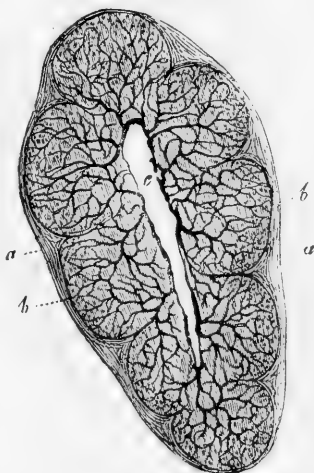


Fig. 200.—TRANSVERSE SECTION OF A LOBULE OF AN INJECTED INFANTILE THYMUS GLAND (from Kölliker). MAGNIFIED.

*a*, capsule of connective tissue surrounding the lobule; *b, b*, follicles; *c*, cleft in the centre of the lobule, probably produced by the shrinking away of the soft follicular substance; from it the blood-vessels are seen to extend towards and ramify in the spheroidal follicles.

\* In some animals the arterial, as well as the venous, branches are found at the periphery of the follicles, to near the centre of which the capillaries converge (as in Peyer's patches).

uniform rapidity, for it grows especially during the seventh, eighth, and ninth months of intra-uterine existence.

After birth, the thymus, as already stated, continues to grow until near the end of the second year. According to the observations of Haugstedt and Simon, it appears for a short time after birth to increase in weight not merely absolutely, but even faster than the rest of the system, and during the next period only to keep pace with the increase of the body. After the second year it ceases to grow, and becomes gradually converted by the eighth or twelfth year into a fatty mass, the corpuscles disappearing or becoming developed into the cells of adipose tissue. At puberty the thymus is generally reduced to a mere vestige which has entirely lost its original structure, and consists of brownish tissue occupying the upper part of the anterior mediastinum. Occasionally it is still found in good condition at the twentieth year; but generally only traces of it remain at that time, and these are rarely discoverable beyond the twenty-fifth or thirtieth year.

The thymus gland presents no difference in the two sexes, and exists, according to Simon, in all animals breathing by lungs. It appears in all to become eventually transformed into a mass of fat.

## ORGANS OF DIGESTION.

The *digestive apparatus* consists mainly of the *alimentary canal*, together with various glands of which it receives the secretions.

The alimentary canal commences at the mouth and terminates at the anus. Its average length is about thirty feet,—about five or six times the length of the body.

The part situated in the head and thorax consists of the organs of mastication, insalivation, and deglutition, and comprises the *mouth*, with the *teeth*, and *salivary glands*, the *pharynx*, and the *œsophagus* or gullet. The part contained in the abdomen and pelvis consists of the stomach and the small and large intestine. The glands which are most intimately connected with digestion are very numerous small glandular organs situated in the mucous membrane of the alimentary canal, and the larger glands, such as the salivary glands, pancreas and liver, whose ducts open on its inner surface.

## THE MOUTH.

The *mouth* is included between the lips and the throat. Bounded by the lips, cheeks, tongue, and the hard and soft palate, it communicates behind with the pharynx through an opening called the *fauces* (isthmus faucium). It is lined throughout by a mucous membrane, which is of a pink rosy hue during life, but pale grey after death, and which presents peculiarities of surface and structure to be noticed hereafter.

The *lips* and *cheeks* are composed externally of skin, and internally of mucous membrane, together with muscles, vessels, and nerves fully described in other parts of this work, some areolar tissue, fat, and numerous small glands. The free border of the lips is protected by a dry mucous membrane, which becomes continuous with the skin, is covered with numerous minute papillæ, and is highly sensitive. In some of these papillæ nerve-end-bulbs, approaching in character to tactile corpuscles, are found (see fig. 101 A, p. 148), in others coiled nerve-fibres (Kölliker). On the inner surface of each lip, the mucous membrane forms a fold in the middle line, connecting the lip with the gums of the corresponding jaw. These are the *fræna* or *frænula* of the lips: that of the upper lip is the larger.



Numerous small glands, called *labial glands*, are found beneath the mucous membrane of the lips, around the opening of the mouth. They are situated between the mucous membrane and the orbicularis oris muscle. They are compound racemose glands of a rounded form, the largest of them not exceeding the size of a split pea; and they open into the mouth by distinct orifices. Small sebaceous glands also occur, at least occasionally, on the part of the red border of the lips which is seen when the mouth is closed.

Between the buccinator muscle and the mucous membrane of the cheek are the *buccal glands*, similar to the labial glands, but smaller. Two or three glands, larger than the rest, found between the masseter and buccinator muscles, and opening by separate ducts near the last molar tooth, are called the *molar glands*. The secretion of these glands is understood to be mucus; whether it has any of the specific properties of saliva is not known. The duct of the parotid gland also opens upon the inner surface of the cheek, opposite to the second upper molar tooth.

Immediately within the lips and cheeks, are the *dental arches*, consisting of the teeth, gums, and alveolar borders of the maxillæ. The *gums* (gingivæ) are composed of a dense connective tissue, cohering very closely with the periosteum of the alveolar processes, and covered by a red and highly vascular mucous membrane, which is smooth in its general surface, but is beset with fine papillæ in the immediate vicinity of the teeth. The epithelium covering it is, like that of the mouth generally, scaly and stratified, containing in the deeper layers numerous cells marked with ridges and furrows, like those described in the epidermis (p. 211).

### THE TEETH.

In the human subject, as in mammalia generally, two sets of teeth make their appearance in the course of life, of which the first comprehends the *temporary, deciduous, or milk teeth*, whilst the second is named the *permanent set*. The temporary teeth are twenty in number, ten in each jaw, and the permanent set consists of thirty-two, sixteen above and sixteen below.

Deficiencies in the number of teeth sometimes occur, and, on the other hand, it is frequently increased by one or more supernumerary teeth. These are usually small, and simple, and although generally distinct, they are sometimes attached to other teeth: they occur more frequently near the front than the hinder teeth, and are more often met with in the upper than in the lower jaw.

#### GENERAL CHARACTERS OF THE TEETH.

A tooth consists of three portions, viz., one which projects above the gums and is named the body or **crow**n, another fixed in the alveolus or socket, the **root**, consisting of the *fang* or *fangs*—and a third, intermediate between the other two, and, from being more or less constricted, named the cervix or **neck** (fig. 201). The size and form of each of these parts vary in the different kinds of teeth.

The roots of the teeth are accurately fitted to the alveoli of the jaws, in which they are implanted. Each alveolus is lined by periosteum (fig. 201, 4), which also invests the contained tooth as high as the cervix. This dental periosteum, sometimes named the periodontal membrane, is said to be richly supplied with nerves. It is blended with the dense

tissue of the gums, which closely surrounds the neck of the tooth. The fangs of all the teeth taper from the cervix to the point, and this

Fig. 201.

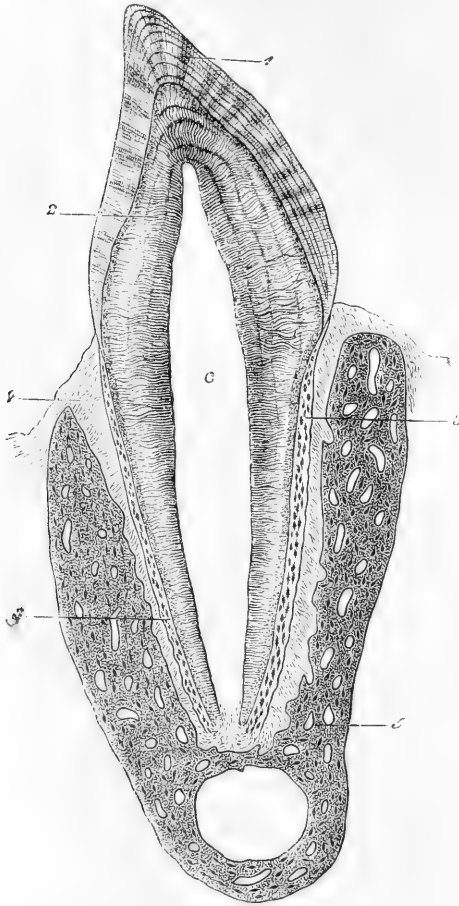


Fig. 201.—VERTICAL SECTION OF PREMOLAR OF CAT. 15 DIAMETERS (Waldeyer).

c, is placed in the pulp-cavity, opposite the cervix or neck of the tooth: the part above is the crown, that below is the root (fang). 1, enamel with radial and concentric markings; 2, dentine with tubules and incremental lines; 3, cement or crusta petrosa, with bone corpuscles; 4, dental periosteum; 5, bone of lower jaw.

form, together with the accurate adjustment to the alveolus, has the effect of distributing the pressure during use over the whole socket, and of preventing it from unduly bearing on the point of the fang, through which the blood-vessels and nerves enter.

The thirty-two permanent teeth consist of four incisors, two canines, four bicuspid, and six molars in each jaw. The twenty temporary teeth are four incisors, two canines, and four molars above and below. There are no bicuspid among the temporary teeth, the eight deciduous molars preceding eight bicuspid

of the permanent set. The relative position and arrangement of the different kinds of teeth in the jaws may be expressed by the following formula, which also exhibits the relation between the two sets in these respects:—

|                       |                           |       |     |     |     |     |     |     |     |
|-----------------------|---------------------------|-------|-----|-----|-----|-----|-----|-----|-----|
| Temporary teeth . . . | { Upper<br>-----<br>Lower | MO.   | CA. | IN. | CA. | MO. | =10 |     |     |
|                       |                           | 2     | 1   | 4   | 1   | 2   |     |     |     |
|                       |                           | ----- |     |     |     |     | =20 |     |     |
| Permanent teeth . . . | { Upper<br>-----<br>Lower | MO.   | BI. | CA. | IN. | CA. | BI. | MO. | =16 |
|                       |                           | 3     | 2   | 1   | 4   | 1   | 2   | 3   |     |
|                       |                           | ----- |     |     |     |     |     |     | =32 |
|                       |                           | 3     | 2   | 1   | 4   | 1   | 2   | 3   | =16 |

THE PERMANENT TEETH.—The **incisors** (fig. 202), eight in number, are the four front teeth in each jaw, and are so named from being

adapted for cutting or dividing the food. Their *crowns* are chisel-shaped (*c*), and have a sharp horizontal cutting edge, which by continued use is bevelled off behind in the upper teeth, but in the lower ones is worn down in front, where it comes into contact with the over-lapping edges of the upper teeth. Before being subjected to wear, the horizontal edge of each incisor is marked by three small prominent points, separated by two slight notches (fig. 202, *d*). The anterior surface of the crown is slightly convex, and the posterior concave. The *fang* is long, single, conical, and compressed at the sides, where it sometimes though rarely presents a slight longitudinal furrow (as in *c*).

The lower incisor teeth are placed vertically in the jaw, but the corresponding upper teeth are directed obliquely forwards. The upper incisors are, on the whole, larger than the lower ones. Of those in the upper jaw the central incisors are the larger; but in the lower jaw, the central incisors are the smaller, and are, indeed, the smallest of all the incisor teeth.

The **canine** teeth, (fig. 203), four in number, are placed one on each side, above and below, next to the lateral incisors. They are larger and stronger than the incisor teeth. The *crown* is thick and conical, convex in front and hollowed behind, and may be compared to that of a large incisor tooth the angles of which have been removed, so as to leave a single central point or *cuspid*, whence the name *cuspidate* applied to these teeth. The point always becomes worn down by use. The *fang* of the canine teeth is single, conical, and compressed at the sides: it is longer than the fangs of any of the other teeth, and is so thick as to cause a corresponding prominence of the alveolar arch: on the sides it is marked by a groove, an indication, as it were, of the cleft or division which appears in the teeth next behind.

The upper canines, popularly called the *eye-teeth*, are larger than the lower, and in consequence of this, as well as of the greater width of the upper range of incisors, they are thrown a little farther outwards than the lower ones. In the dog-tribe, and in the carnivora generally, these teeth acquire a great size, and are fitted for seizing and killing prey, and for gnawing and tearing it when taken as food.

The **bicuspid**s, also called *premolars*, are four in each jaw; they are shorter and smaller than the canines, next to which they are

Fig. 202.

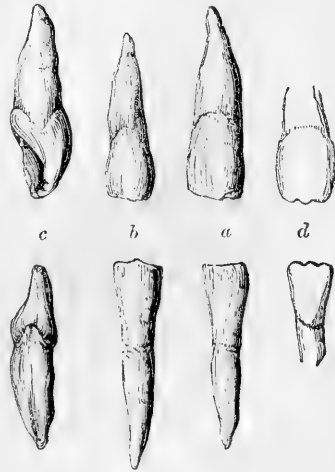


Fig. 202.—INCISOR TEETH OF THE UPPER AND LOWER JAWS.

*a*, front view of the upper and lower middle incisors; *b*, front view of the upper and lower lateral incisors; *c*, lateral view of the upper and lower middle incisors, showing the chisel shape of the crown; a groove is seen marking slightly the fang of the lower tooth; *d*, the upper and lower middle incisor teeth before they have been worn, showing the three points on the cutting edge.

placed. The *crown* is compressed antero-posteriorly, and is convex, not only on its outer or labial surface, like the preceding teeth,

Fig. 203.

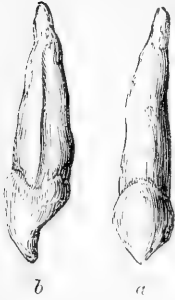


Fig. 203.—CANINE TOOTH OF THE UPPER JAW.

*a*, front view; *b*, lateral view, showing the long fang grooved on the side.

but on its inner surface also, which rises vertically from the gum: it is broader than that of an incisor or canine tooth, and is surmounted by *two* pointed tubercles or cusps, of which the external one is larger and higher than the other. The *fang* is similarly compressed, and is deeply grooved in all cases, showing a tendency to become double. The apex of the fang is generally bifid, and in the second upper bicuspid the root is often cleft for a considerable distance; but the bicuspid teeth are very variable in this respect, and may be, all four, free from any trace of bifidity of the root. The upper bicuspids are larger than the lower ones, and their cusps are more deeply divided. Sometimes the first lower bicuspid has only one tubercle distinctly marked, *i.e.*, the external, and in that case approaches in figure to a canine tooth.

The *molar* teeth (fig. 205), true or large molars, or *grinders*, are twelve in number, and are arranged behind the bicuspid teeth, three on

Fig. 204.

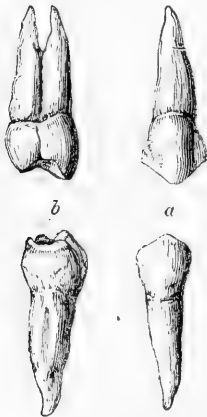


Fig. 204.—FIRST BICUSPID TOOTH OF THE UPPER AND LOWER JAWS.

*a*, front view; *b*, lateral view, showing the lateral groove of the fang, and the tendency in the upper to division.

Fig. 205.



Fig. 205.—FIRST MOLAR TOOTH OF THE UPPER AND LOWER JAWS.

They are viewed from the outer aspect.

each side, above and below. They are distinguished by the large size of the crown, and by the great width of its grinding surface. The first

molar is the largest, and the third is the smallest, in each range, so as to produce a gradation of size in these teeth. The last of the range, owing to its late appearance through the gum, is called the *wisdom-tooth*, *dens sapientiae*. The *crowns* of the molar teeth are low and cuboid in their general form. Their outer and inner surfaces are convex, but the crowns are rather flattened before and behind. The grinding surface is nearly square in the lower teeth, and rhomboidal in the upper, the corners being rounded off; it bears four or five trihedral tubercles or cusps (whence the name *multicuspidati*), separated from each other by a crucial depression. The upper molars have four cusps situated at the angles of the masticating surface; of these the anterior internal cusp is the largest, and is frequently connected with the posterior external cusp by a low oblique ridge. In the upper wisdom-teeth, the two internal cusps are usually blended. The crowns of the lower molars, which are larger than those of the upper, have five cusps, the additional one being placed between the two posterior ones, and rather to the outer side; this is especially evident in the lower wisdom-teeth, in which, however, the crown is smaller and rounder than in the others. The *fangs* of the molar teeth are multiple. In the two anterior molars of the *upper* jaw, they are three in number, viz., two placed externally, which are short, divergent, and directed towards the antrum of the superior maxilla; and a third or internal fang, which is larger and longer, and is directed towards the palate, its posterior border extending as far back as that of the posterior external fang. This third fang is often slightly grooved, especially when the two internal cusps of the crown are very distinct, and sometimes it is divided into two smaller fangs. The two anterior molars of the *lower* jaw have each two broad, compressed fangs, one anterior, the other posterior, which are grooved on the faces that are turned towards each other, as if each consisted of two fangs fused together; they have an inclination or curve backwards in the jaw, and are slightly divergent, but sometimes parallel, or even nearly in contact with each other; more rarely one or both of them is divided into two smaller fangs. In the wisdom-teeth of both jaws the fangs are often collected into a single irregular conical mass, which is either directed backwards in the substance of the jaw, or curved irregularly; this composite fang sometimes shows traces of subdivision, and there are occasionally two fangs in the lower tooth and three in the upper.

The bicuspid and the molar teeth, from the breadth and uneven character of their masticating surface, are fitted for bruising, crushing, and grinding the food.

The range of teeth in each jaw forms a nearly uniform curve, which is not broken by any interval, as is the case in many animals, even in the *Quadrumana*. The upper dental arch is rather wider than the lower one, so that the teeth of the upper jaw slightly overhang those of the lower. This is owing principally to the fact that the lower teeth are placed either vertically, as in front, or are inclined somewhat inwards, as is seen behind and at the sides, while the corresponding teeth of the upper jaw have an inclination forwards in front, and outwards behind. While there is a slight diminution in the height of the crowns of the teeth from the incisors backwards to the wisdom-teeth, there is in man no abrupt change of level along the range. In consequence of the large proportionate breadth of the upper

central incisors, the other teeth of the upper jaw are thrown somewhat outwards, so that in closure of the jaws the canines and bicuspid come into contact partly with the corresponding lower teeth, and partly with those next following; and in the case of the molars, each cusp of the upper lies behind the corresponding cusp of the lower teeth. Since, however, the upper molars and especially the wisdom-teeth are smaller than those below, the dental ranges terminate behind nearly at the same point in both jaws.

**THE MILK-TEETH** (fig. 206).—The temporary **incisor** and **canine** teeth resemble those of the permanent set in their general form; but they are of smaller dimensions. The temporary **molar** teeth present some peculiarities. The hinder of the two is much the larger; it is the largest of all the milk-teeth, and is larger even than the second permanent bicuspid, which it afterwards gives place to. The first upper milk molar has only three cusps, two external and one internal; the second has four. The first lower temporary molar has four cusps, and the second five, of which in the latter case three are external. The

Fig. 206.

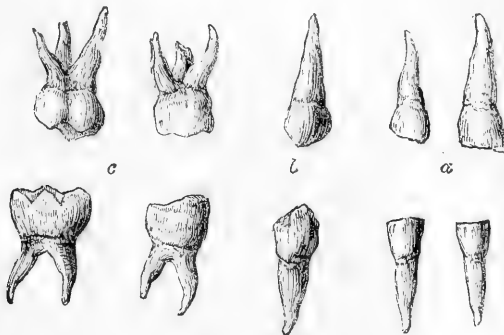


Fig. 206.—MILK TEETH OF THE RIGHT SIDE OF THE UPPER AND LOWER JAWS.  
a, the incisors; b, the canines; c, the molar teeth.

*fangs* of the temporary molars resemble those of the permanent set, but they are smaller, and are more divergent from the neck of the tooth.

#### STRUCTURE OF THE TEETH.

On making a section of a tooth, the hard substance of which it is composed is found to be hollow within (fig. 207). The form of the cavity bears a general resemblance to that of the tooth itself; it occupies the interior of the crown, is widest opposite to or a little above the neck, and extends down each fang, at the point of which it opens by a small orifice. In the incisor teeth the cavity is prolonged above into two fine linear canals, which proceed one to each corner of the crown; in the bicuspid and molar teeth it advances a short distance into each cusp. In the case of a root formed by the blending of two or more fangs, as occurs occasionally in the wisdom-teeth, each division has a separate canal prolonged down to its apex.

**Pulp of the teeth.**—The central cavity of a tooth is called the *pulp cavity*, because it is occupied and accurately filled by a soft, highly

vascular, and sensitive substance, called the *dental pulp*. This pulp consists of jelly-like connective tissue containing fine filaments of the white variety, nucleated cells, blood-vessels and nerves. The cells are partly disseminated in the soft mass and partly form a stratum at the surface of the pulp, where they are elongated, somewhat like the cells of columnar epithelium (see fig. 220, c, p. 318). On extraction of the pulp from the cavity of the tooth, this layer usually remains adherent to the hard tissue, and has been named the *membrana choris*. The oblong cells composing it (*odontoblasts*) send processes into tubules in the dentine, to be afterwards noticed, of which more than one may come from the same cell; lateral offsets, according to Waldeyer, proceed to join adjacent cells, and radical processes connect the superficial cells with others lying deeper in the pulp. The arteries and nerves, which are derived from the internal maxillary and fifth pair respectively, enter by the aperture at the point of each fang. The vessels form a capillary network beneath the superficial cells; the nerves, as described by Boll in the rabbit's incisor, end in fine non-medullated fibres which are distributed abundantly at the surface of the pulp and run up between the superficial cells. Some appear to take the direction of those cell-processes which enter the hard tissue, but they have not with certainty been traced into the dentinal tubules.

**Hard tissues of the teeth.**—The hard part of a tooth is composed of three distinct substances,—viz., the proper dental substance, *ivory* or *dentine*, the *enamel*, and the *cement* or *crusta petrosa*. The dentine constitutes by far the larger portion; the enamel is found only upon the exposed part or crown; and the cement covers with a thin layer the surface of the implanted portion or fang.

The **dentine** (Owen,) forming the principal mass or foundation of the body and root of a tooth, gives to both of these parts their general form, and immediately encloses the central cavity. It resembles very compact bone in its general aspect and chemical relations, but is not identical with it in structure, or in the exact proportions of its earthy and animal constituents.

According to the analyses of Berzelius and Bibra, the dentine of human teeth is composed of 28 parts per cent. of animal, and 72 of earthy matter. The former is resolvable into gelatin by boiling. The composition of the latter, according to Bibra, is as follows, viz., phosphate of lime 66·7 per cent., carbonate of lime 3·3, phosphate of magnesia and other salts, including a trace of fluoride of calcium, 1·8. Berzelius found 5·3 carbonate of lime.

The dentine is penetrated throughout by fine tubes, which being nearly parallel give it a striated aspect (fig. 201). When a thin section is viewed under the microscope by transmitted light, the solid sub-

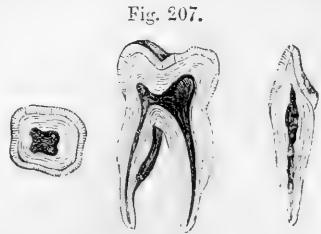


Fig. 207.—SECTIONS OF AN INCISOR AND MOLAR TOOTH.

The longitudinal sections show the whole of the pulp-cavity in the incisor and molar teeth, its extension upwards within the crown, and its prolongation downwards into the fangs with the small aperture at the point of each; these and the cross section show the relation of the dentine and enamel.

stance, or matrix, is transparent and apparently homogeneous, while the tubes, being (in a dried specimen) filled with air, are dark : but when seen with reflected light on a dark ground the latter appear white ; in these respects they resemble lacunæ and canaliculi of bone.

The *dentinal tubules* open at their inner ends into the pulp-cavity, which presents very numerous minute orifices over the whole surface. Thence they pass in a radiated manner through every part of the ivory towards its periphery. In the upper part of the crown they have a vertical direction ; but towards the sides, and in the neck and root, they become gradually oblique, then horizontal, and are finally even inclined downwards towards the point of the fang. The tubules describe in their course two or three gentle curves (*primary* curvatures, fig. 201), and each is besides twisted throughout its whole length

Fig. 208.

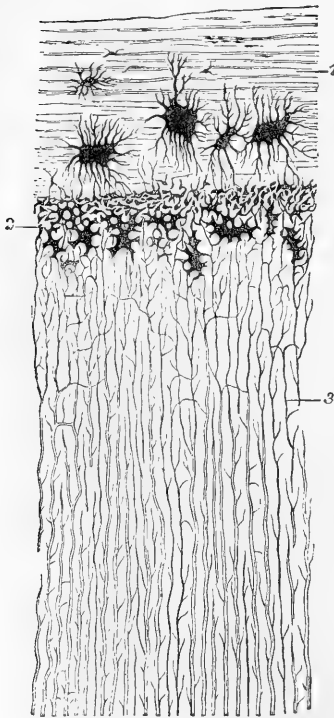


Fig. 208.—SECTION OF FANG, PARALLEL TO THE DENTINAL TUBULES (HUMAN CANINE). MAGNIFIED 300 DIAMETERS. (Waldeyer).

1, cement, with large bone-lacunæ and indications of lamellæ ; 2, granular layer of Purkinje (interglobular spaces) ; 3, dentinal tubules.

also become very fine, terminate

into numerous fine spiral turns, which follow more closely one upon another ; these are the *secondary* curvatures (fig. 208). In form a tubule may accordingly be likened to the thread of a corkscrew, stretched so that the turns are drawn far apart, and their breadth proportionally diminished (Welcker).

The tubes are only slightly divergent as they pass towards the surface ; and, as they divide several times dichotomously, and at first without being much diminished in size, they continue to occupy the substance of the dentine at almost equal distances, and their nearly parallel primary curvatures produce, by the manner in which they reflect the light, an appearance of concentric undulations in the dentine, which may be well seen with a low magnifying power (*Schreger's lines*). The average diameter of the tubules at their inner and larger ends is  $\frac{1}{4500}$ th of an inch, and the distance between adjacent tubules is commonly about two or three times their width. From their sides numerous immeasurably fine branches are given off, which penetrate the hard intertubular substance, where they either anastomose or terminate blindly. These lateral ramuscles are said to be more abundant in the fang. Near the periphery of the ivory they are very numerous, and, together with the main tubules themselves, which there by rapid division and subdivision, imperceptibly by free ends, or by join-



ing together in loops, or in the interglobular cavities shortly to be described.

The tubules are described as having each a proper wall, independent of the intertubular matrix, but intimately adhering to, and under ordinary circumstances indistinguishable from it. This wall, named the *dental or dentinal sheath*, is formed of a calcified membranous tube.\* By steeping sections of decalcified dentine in strong hydrochloric acid, the matrix is destroyed, and the membranous tubes, which consist of a more resisting material (probably elastic substance), remain behind. In sections of hard dentine made across the tubules (fig. 209), the walls of these often appear as a distinct thin border: this may, however, be due to an optical effect.

In properly prepared sections of softened teeth fine processes may be seen passing into the tubules from the surface-cells of the pulp before-mentioned; and it is suggested by Tomes that these are not only subservient to the nutrition of the dentine, but probably also confer on it a certain degree of sensibility. It has been noticed, indeed, that the dentine is more sensitive near the surface than deeper in its substance,—a fact not easily intelligible on the supposition that the sentient tissue is confined to the pulp-cavity. But the sensibility of the teeth may not improbably be in part dependent on the nerves in the dental periosteum (Salter).

In the temporary, and sometimes even in the permanent teeth, the tubules are constricted at short intervals, so as to present a moniliform character. The terminal branches of tubules are occasionally seen to pass on into the cement which covers the fang, and to communicate with canaliculi proceeding from the characteristic lacunæ found in that osseous layer. Tubules have likewise been observed by Tomes passing into the enamel in the teeth of marsupial animals, and in a less marked degree in human teeth.

The *intertubular substance* is translucent. The animal matter which remains in it, after the earth has been removed by an acid, exhibits a tendency to tear in the direction of the tubules, but is in reality a homogeneous substance, deposited in a laminated manner. This was shown by Sharpey, who observed that in the softened teeth of the cachalot or sperm-whale the animal substance was readily torn into fine lamellæ, parallel with the internal surface of the pulp-cavity, and therefore across the direction of the tubules. In these lamellæ the sections of the tubules appear as round or oval apertures, the lamellæ having the same relation to the tubules as those of true bone to the canaliculi. The same tendency to lamination is exhibited by boiling a longitudinal section of tooth with caustic potash, after which it presents closely set, short, and regular fissures, lying at right angles to the tubules, throughout the extent of the dentine (Cleland); moreover, a thin cross-section of a tooth may be broken up, after decalcification, into concentric rings like the year-rings of wood (Salter).

Fig. 209.

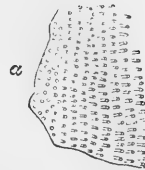

Fig. 209.—SECTIONS OF DENTINAL TUBULES (after Fraenkel).

*a*, cut across; *b*, cut obliquely. (About 300 diameters).

\* Some authorities maintain that the sheaths are not calcified.

This laminated structure is an indication of the deposition of dentinal substance in successive strata in the process of formation of the tooth—the laminæ corresponding with the shape of the pulp-surface at successive stages of the process. Not unfrequently lines, varying in number and breadth, are seen in sections of the fully-formed tooth, conforming in direction with the lamination just spoken

Fig. 210.

Fig. 211.

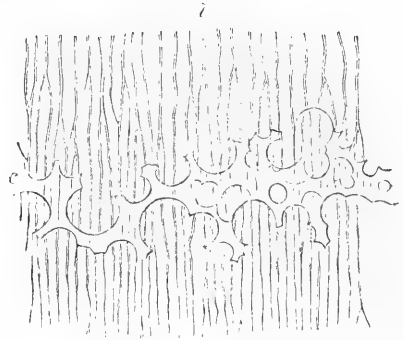
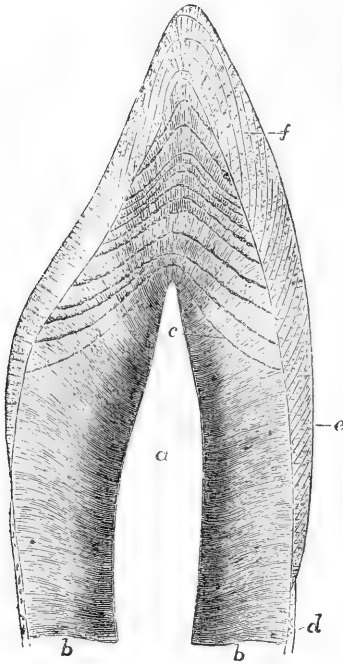


Fig. 210.—VERTICAL SECTION OF THE UPPER PART OF AN INCISOR TOOTH (from Kölliker).  
MAGNIFIED 7 DIAMETERS.

*a*, the pulp-cavity; *b*, dentine; *c*, arched incremental lines; *d*, cement; *e*, enamel with bands indicating the direction of the ranges of fibres; *f*, coloured lines of the enamel.

Fig. 211.—A SMALL PORTION OF THE DENTINE WITH INTERGLOBULAR SPACES (from Kölliker). 350 DIAMETERS.

*b*, the tubules; *c*, portion of incremental line formed by the interglobular spaces, which are here filled up by a transparent material.

of (fig. 210. *c*). They are caused by imperfect calcification of the dentine, which shows little cavities bounded by, and therefore receiving their figure from, minute nodules or globules of dentine, and hence named *interglobular spaces* (fig. 211, *c*). The lines themselves may be termed “incremental” lines (Salter), as they represent stages of deposition of the dentine. The term “contour lines,” which has been applied to them, is inappropriate, inasmuch as they intersect the contour of the tooth. The interglobular spaces, and the globules surrounding them, vary in size within wide limits. A layer, in which they are very fine—*granular layer* of Purkinje (fig. 208, 2)—is not uncommonly found towards the surface of the fang beneath the cement, and sometimes in the crown beneath the enamel: and it may be noticed that the more superficial of the incremental lines are continued into this layer (see fig. 201).

The **enamel** is that hard white covering which encrusts and protects the exposed portion or crown of a tooth. It is the hardest of all the dental tissues, but is gradually worn down by protracted use. It is thickest on the grinding surface and cutting edge of the teeth, and becomes gradually thinner towards the neck, where it ceases. Its extent and thickness are readily seen on charring the tooth, by which the dentine becomes blackened, whilst the enamel, owing to the very small quantity of animal matter in its composition, remains white. According to Bibra it contains of earthy constituents 96.5 per cent., viz., phosphate of lime with traces of fluoride of calcium 89.8, carbonate of lime 4.4, phosphate of magnesia and other salts 1.3; and of animal matter only 3.5 per cent. Berzelius, however, gives the proportion of carbonate of lime as 8, and of animal matter as only 2 per cent.

The enamel is made up entirely of very hard and dense microscopic fibres or prisms, arranged closely together, side by side, and set by one extremity upon the subjacent surface of the dentine (fig. 212). The fibres are disposed in ranges which are set vertically on the grinding surface, but on the sides of the crown get more and more horizontal. Near the dentine the fibres cross one another in the alternate ranges, but become more parallel as they approach the surface of the tooth; from this intercrossing the ranges appear on a section as alternate light and dark stripes passing through the enamel from its inner to its outer surface (as in figs. 201 and 210). This is no doubt owing to the manner in which the different strata affect the light. A series of concentric lines is likewise to be seen crossing the enamel fibres: these are termed *coloured lines* from their brown appearance, but whether caused by pigmentary deposit or otherwise is unascertained. Minute fissures not unfrequently exist in the deep part of the enamel, which run between clusters of the fibres down to the surface of the dentine (fig. 212, *c*); and other much larger and more evident fissures are often observed leading down from the depressions or crevices between the cusps of the molar and premolar teeth. The unworn surface of the enamel is marked by concentric ridges, which may be distinguished with a common magnifying glass.

The enamel-fibres (fig. 213) have the form of solid six-sided prisms. Their diameter is ordinarily about  $\frac{1}{3000}$ th of an inch. They are marked at small intervals by dark transverse lines. The inner ends of the prisms are implanted in minute hexagonal depressions found on the surface of the dentine; whilst the outer ends, somewhat larger in diameter, are free, and

Fig. 212.

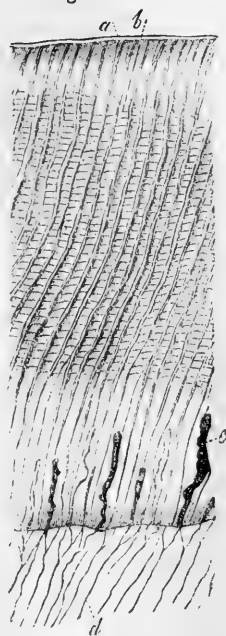
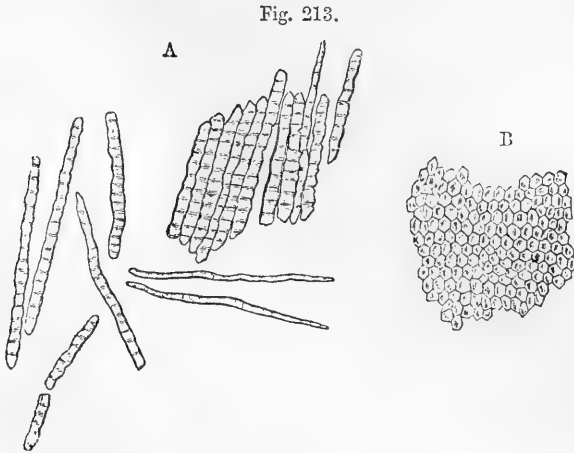


Fig. 212.—THIN SECTION OF THE ENAMEL AND A PART OF THE DENTINE (from Kölliker). 350 DIAMETERS.

*a*, cuticular pellicle of the enamel; *b*, enamel-fibres or columns with fissures between them and cross striæ; *c*, clefts in the enamel communicating with the extremities of some of the tubuli (*d*).

present, when examined with a high magnifying power, a tessellated appearance (fig. 213, B).



213.—ENAMEL FIBRES (from Kölliker). 350 DIAMETERS.

A, fragments and single fibres of the enamel, isolated by the action of hydrochloric acid.  
B, surface of a small fragment of enamel, showing the hexagonal ends of the fibres.

When submitted to the action of dilute acids, the enamel is almost entirely dissolved, and leaves scarcely any discernible traces of animal matter. By the action of an acid, the enamel of newly formed or still growing teeth may be broken up, and its structural elements more easily distinguished.

It is further found, on treatment with acid, that a very thin membrane called by Kölliker “cuticle of the enamel,”—and by Busk and Huxley “*Nasmyth's membrane*” entirely covers the enamel of unworn teeth upon its outer surface (fig. 212, a). This membrane forms a protective covering to the enamel. It is of an epithelial and horny nature, and obstinately withstands prolonged boiling with water as well as the action of acids and other re-agents.

The **crusta petrosa or cement** (fig. 201, 3) is the third substance which enters into the formation of the teeth. This is a layer of true bone, slightly modified in structure, and investing that part of the dentine which is not protected by the enamel. It covers the whole fang, towards the lower end of which it becomes gradually thicker, and is specially developed at the apex, and along the grooves of the compound fangs. As life advances, the cement generally grows thicker, especially near the point of the fang, where it sometimes blocks up the orifice leading to the pulp-cavity.

The crusta petrosa is lamellar in structure, and contains lacunæ and canaliculi resembling those of bone but larger and more irregular (fig. 208, 1). In the deeper layers of the cement the fine canaliculi sometimes anastomose with some of the terminal tubules of the subjacent dentine, as already stated. Where the cement is very thick it may contain vascular canals, analogous to the Haversian canals of bone. On the deciduous teeth the cement is thinner, and contains fewer cells. It has been shown by Sharpey that perforating fibres, similar to those of ordinary

bone, run abundantly through the cement. In chemical composition it resembles bone, and contains 30 per cent. of animal matter. The cement is, according to some, extremely sensitive at the neck of the tooth, if it be exposed by retraction of the gum. This is probably due to the nerves of its periosteal covering. By its connection with the surrounding membranous structures it contributes to fix the tooth in the socket. It is the seat of the bony growths or exostoses sometimes found upon the teeth.

#### FORMATION OF THE TEETH.

A tooth is formed on the same fundamental type of development as a hair. In the latter case a process grows down from the Malpighian layer of the epidermis into the subjacent cutaneous corium, in which a depression is simultaneously produced for its reception. A papilla, soon becoming vascular, rises up from the bottom of the depression into the cellular mass, and the primitive tissue forming the wall of the recess is converted into the coats of a follicle. In the formation of a tooth there is in like manner a downgrowth from the Malpighian layer of the oral epithelium (which corresponds with the epidermis and is derived from the same embryonic layer). The cellular process is received into a recess of the subjacent mucous membrane. In this also a vascular papilla grows up from the bottom, and the simple wall of the cavity is differentiated into a vascular sac or follicle.

The first recognized steps in the development of the teeth take place as early as the seventh week of intra-uterine life. At this time the oral epithelium becomes thickened along the border of the jaws, and its Malpighian layer grows down into a corresponding groove, which is formed to receive it in the soft embryonic tissue of which the jaw then consists. The groove, although filled and covered in by the epithelium, is still faintly indicated by a shallow superficial furrow. This downgrowth of epithelium, which is named the "enamel-germ," forms the foundation of the special structures or organs which generate the enamel in the several teeth, and for the sake of distinction may be termed the **common enamel-germ**. The groove, as well as the changes subsequently occurring in it, was observed by F. Arnold and by Goodsir, who named it the "primitive dental groove," but neither of these observers appears to have noticed the contained epithelium (or at least to have recognized its importance), probably in consequence of its soft and friable substance having been accidentally wiped away. The common enamel-germ, simultaneously with the groove, next increases in depth, and, at the same time, its deeper portion inclines outwards, forming an angle with its more superficial part. It also swells out below, so that a transverse vertical section of it is club or flask-shaped. An increased development then takes place at particular points, corresponding in situation with the ten milk-teeth; and the common enamel-germ thus becomes parted in its deeper portion, or extended by further growth, into as many distinct aggregations of cells, or **special enamel-germs**,—one for each tooth—of a club or flask-shape, connected by a narrowed neck with what remains of the common epithelial ingrowth (fig. 214, A, f). These tooth-germs, as they may now be called, are lodged each in its own recess, which at this time is merely a pit in the soft embryonic tissue, without the membranous

coats which afterwards are formed. From the bottom a **papilla** (*p*) meanwhile rises, soon becoming vascular, and assuming the shape of

Fig. 214.

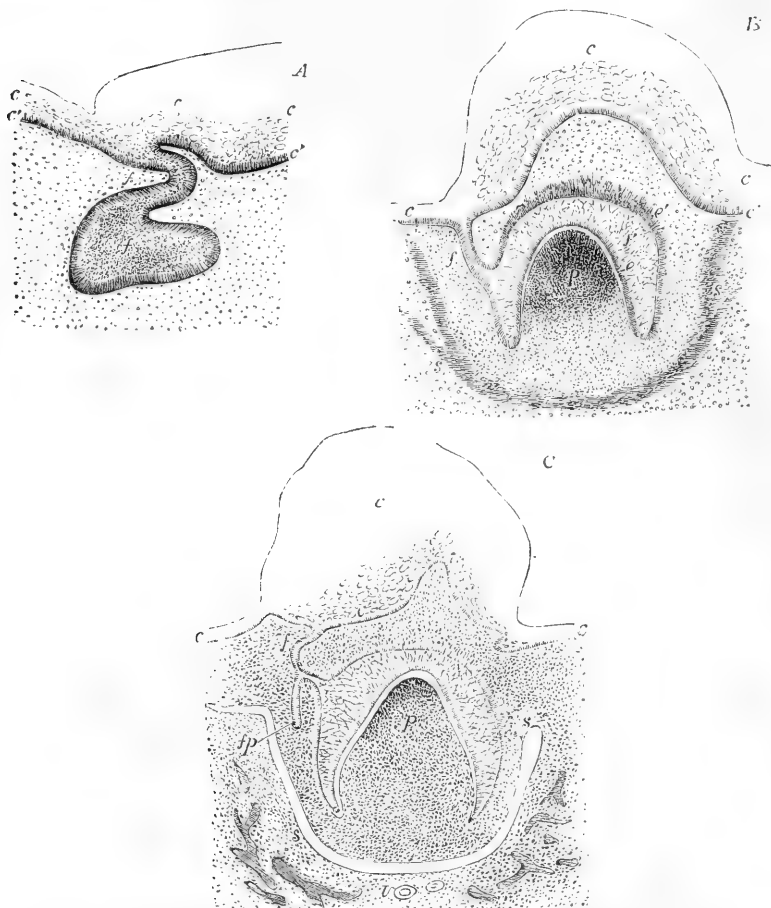


Fig. 214.—DIAGRAMS OF THE MODE OF ORIGIN OF THE DENTAL GERM IN THE RUMINANT (after Kölliker).

The three figures represent transverse sections of the gum and a part of the jaw at or shortly after the period of the formation of the germ, and are designed chiefly to show the relation of the germ to the epithelium.

A, represents a very early condition, when the enamel-germ of a milk or temporary tooth has been formed by a down-growth of the deep layer of the epithelium.

B, represents a later stage, when the tooth-papilla has risen from the surface of the mucous membrane, and has indented the enamel-germ.

C, represents a more advanced stage in which the dental sac has begun to be formed.

*c*, the superficial thick epithelium of the gum only sketched in outline; *c'*, the deep layer; *f*, the epithelial downgrowth; *f'*, the special enamel-germ, afterwards (in B and C) the enamel-organ; *p*, the dental papilla, and afterwards tooth-pulp. In B and C a clear space is seen between the dental pulp and the deeper columnar cells, *c*, of the enamel-organ: it is probably produced by a shrinking of the soft parts away from one another; *s*, the commencement of the dental sac; *f p*, the enamel-germ of the corresponding permanent tooth.

the future tooth-crown. It is received into a corresponding dimple of the enamel-germ, which now comes to resemble in form an inverted cup, and fits upon the papilla (fig. 214, B, *f'*).

Goodsir described the process somewhat differently. According to his account the papillæ first appear in the bottom of the undivided *groove*, and separate loculi are then formed for them by partitions which grow across its deeper part. They thus become lodged in pits which are partitioned off at the bottom of the original groove, and this condition was termed by him the *follicular stage*. It is represented in fig. 216, and in diagrammatic section in fig. 215, Nos. 3 and 4.

According to the same observer, the order in which the papillæ appear is very regular. That of the anterior milk molar is the first (7th week); that of the canine next (8th week); the incisor papillæ next (9th week), the central before the lateral; and that of the posterior milk molar last (10th week). The several papillæ of the upper jaw appear a little earlier than the corresponding ones of the lower. The groove is said to become separated by partitions in corresponding order, and the follicular stage to be completed by the 14th week. The open pits are next closed, and the included enamel-germ cut off from connection with the superjacent epithelium, and finally the sides of the groove

Fig. 215.

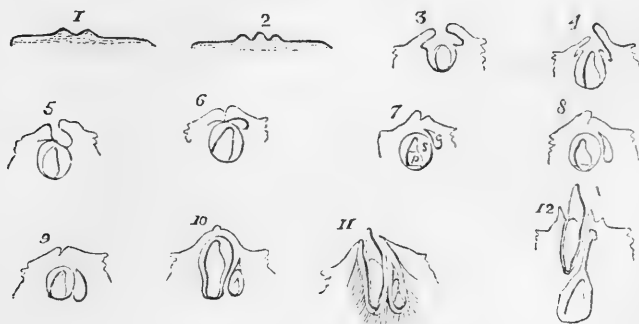


Fig. 215.—DIAGRAMMATIC OUTLINES OF SECTIONS THROUGH THE DENTAL GERMS AND SACS, AT DIFFERENT STAGES OF DEVELOPMENT (from Goodsir).

1, the primitive dental groove of the lower jaw cut across in a fetus of about six weeks; 2, a papilla rising within the dental groove; 3, 4, and 5, represent the follicular stage in which the papilla is seen sunk within the follicle, and the lips of the follicle (opercula) advancing towards each other, gradually meet and close in the follicle; 5, may be looked upon as representing the section indicated by the line *a b*, in fig. 216, through the sac of an incisor tooth, in which a lunated depression (*c*) is left behind; in 6, the sides of the groove are seen to close; in 7, the union of the lips being complete, the follicle becomes a closed sac *s*, containing the dental pulp *p*, and having behind it the lunated depression *c*, now also enclosed, and forming the cavity of reserve for the germ of the corresponding permanent tooth; in the remaining outlines, 8 to 12, are shown the commencement of the cap of dentine on the pulp, the subsequent steps in the formation of the milk tooth, and its eruption through the gum (11); also the gradual changes in the cavity of reserve, the appearance of its papilla, its closure to form the sac of the permanent tooth, its descent into the jaw, behind and below the milk tooth, and the long pedicle (12) formed by its upper obliterated portion. The epithelium which covers the gum, and also that which occupies the dental follicles and sacs, is not represented in these diagrams.

above the separate germs coalesce in its whole length—the process

beginning at the posterior end—and thus by the end of the 15th week the groove is obliterated, and the tooth-germs included in shut sacs; a condition named by Goodsir the *saccular stage* (fig. 215, 6, 7). He described the closing of the pits as taking place by the growth and mutual union of little lappets or opercula over their orifices (fig. 215, 4 and 5; fig. 217 *o*).

Certain lunated depressions, with enclosed epithelium, which are formed one behind each of the milk-follicles about the fourteenth week, escape the general adhesion of the lips of the groove (figs. 214, C, *f*), 217, *c*, 215). These are the germs of the ten anterior permanent teeth as will be afterwards shown.

While the above-described changes are going on, the soft embryonic tissue bounding the cavity which contains the tooth-germ, becomes converted into a vascular *membranous sac*, and the osseous foundation of the maxilla is laid. The jaw is at first in form of a bony gutter,

Fig. 216.

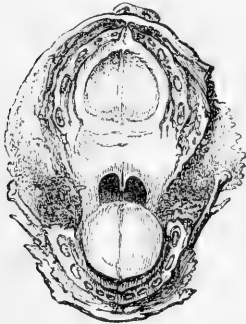


Fig. 217.

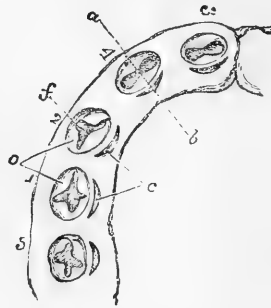


Fig. 216.—ENLARGED VIEW OF THE UPPER AND LOWER DENTAL ARCHES OF A FŒTUS OF ABOUT FOURTEEN WEEKS.

This specimen shows the follicular stage of development of all the milk teeth as described by Goodsir; in each follicle the papilla is seen projecting; but this exposure of the papilla and the cavity of the follicle arises from the accidental loss of the epithelial covering.

Fig. 217.—ENLARGED DIAGRAM OF THE DENTAL ARCH ON THE LEFT SIDE OF THE LOWER JAW OF A FŒTUS OF ABOUT FOURTEEN WEEKS (slightly altered from Goodsir).

*f*, the follicles of the five milk teeth, supposed to be open, showing the dental papillæ within them, and *o*, the opercula on their borders; they are numbered from 1 to 5 in the order of their first appearance; *c*, to the inside of each is the lunated depression forming the commencement of the germ of the corresponding permanent tooth.

in which the teeth-rudiments are lodged; but this is soon divided by osseous partitions into chambers for the several tooth-sacs, at first with wide openings, which afterwards are narrowed, but so as to allow the contained sacs to cohere with the gum along the border of the jaw. The recesses in question are not the alveoli; these are formed subsequently around the fangs of the teeth as they rise into their permanent place, and the jaw is deepened by the growth of its alveolar border.

The **dental sacs** are well seen in the jaw of an infant a few months old, before the eruption of the teeth. They are represented at this stage in fig. 218. They consist of an outer fibro-vascular coat connected with the periosteum, and an inner highly vascular layer with a little jelly-



like tissue interposed between the two. The inner coat is lined with the epithelium of the enamel organ to be hereafter described. Their

Fig. 218.—THE DENTAL SACS EXPOSED IN THE JAW OF A CHILD AT BIRTH.

*a*, the left half seen from the inner side; *b*, the right half seen from the outer side; part of the bone has been removed so as to expose the dental sacs as they lie below the gum; the lower figure shows the sacs of the milk-teeth and the first permanent molar, exposed by removing the bone from the outside; the upper figure shows the same from the inside, together with the sacs of the permanent incisor and canine teeth adhering to the gum.

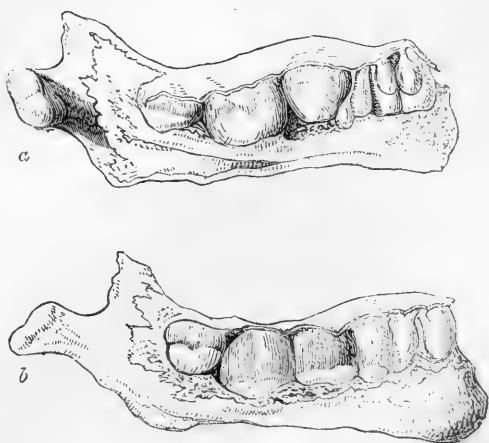

Fig. 218.

blood-vessels are derived partly from the dental arteries which course along the base of the sacs, and partly from those of the gums.

The papillæ, now the dental pulps, acquire a perfect resemblance to the crowns of the future teeth, and then the formation of the hard substance commences in them, as will be immediately described. This process begins very early, and by the end of the fourth month of foetal life thin shells or caps of dentine (fig. 219, 1) are found on all the pulps of the milk-teeth, and a little later on that of the first permanent molar, while at the same time the coating of enamel begins to be deposited on each.

Fig. 219.

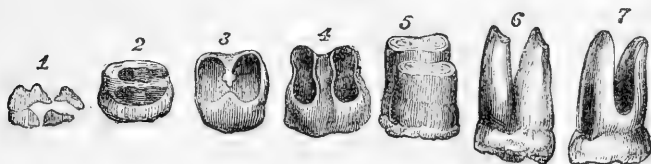


Fig. 219.—DIFFERENT STAGES IN THE FORMATION OF A MOLAR TOOTH WITH TWO FANGS (from Blake).

1, the distinct caps of dentine for five cusps in the earliest stage of formation; in 2, and the remaining figures, the crown is downwards; in 2 and 3, the formation of the crown having proceeded as far as the neck, a bridge of dentine stretches across the base of the tooth-pulp; and in 4, the division of the fangs is thus completed; in 5, 6, and 7, the extension takes place in the fangs.

The cap of dentine increases in extent by a growth around its edges, and in thickness by additions in its interior, while the substance of the pulp decreases in proportion. This growth of the tooth continues until the crown is completed of its proper width, and then the pulp undergoes a constriction at its base to form the cervix of the tooth, and

afterwards elongates and becomes narrower, so as to serve as the basis of the fang. Sooner or later, after the completion of the crown, this part of the tooth appears through the gum, whilst the growth of dentine to complete the fang is continued at the surface of the elongating pulp, which gradually becomes encroached upon by successive formations of hard substance, until only a small cavity is left in the centre of the tooth, containing nothing but the reduced pulp, supplied by slender threads of vessels and nerves, which enter by a small aperture left at the point of the fang after the dentine is completed. In the case of teeth having complex crowns and more than a single fang, the process is somewhat modified. On the surface of the dental pulp of such a tooth, as many separate caps or shells of dental substance are formed as there are eminences or points; these soon coalesce, and the formation of the tooth proceeds as before as far as the cervix. The pulp then becomes divided into two or more portions, corresponding with the future fangs, and the ossification advances in each as it does in a single fang; while, at the same time, a horizontal projection or bridge of dentine is deposited across the base of the pulp, between the commencing fangs, so that if the tooth be removed at this stage and examined on its under surface, its shell presents as many apertures as there are separate fangs (fig. 219, 3 and 4). In all teeth, the pulp originally adheres by its entire base to the bottom of the sac; but, when more than one fang is to be developed, the pulp is, as it were, separated from the sac in certain parts, so that it comes to adhere at two or three insulated spots only, corresponding with the fangs, whilst the dentine continues to be formed along the surrounding free surface of the pulp.

**Formation of the hard tissues of the Teeth.**—The account

already given of the structure of the permanent pulp of a tooth will apply also to that of the papilla or formative pulp of the growing tooth, both before and after the dentine has begun to be formed from it.

It may be added, however, that its capillary vessels, which form a series of loops a short distance beneath the surface, are much more abundant opposite the point or points where calcification is about to commence.

The **dentine** is produced more immediately by the elongated cells (odontoblasts) already described as forming the superficial stratum of the pulp (fig. 220, *c*). These cells send out from their free extremities filamentous processes, as described by Lent, and the intercellular substance of the pulp tissue between and around these processes becomes changed into the solid matrix or intertubular substance

Fig. 220.

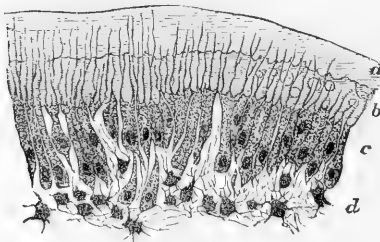


Fig. 220.—PART OF SECTION OF DEVELOPING TOOTH OF YOUNG RAT, SHOWING THE MODE OF DEPOSITION OF THE DENTINE. HIGHLY MAGNIFIED.

*a*, outer layer of fully formed dentine; *b*, uncalcified matrix, with one or two nodules of calcareous matter near the calcified part; *c*, odontoblasts sending processes into the dentine; *d*, pulp. The section is stained with carmine, which colours the uncalcified matrix, but not the calcified part.

processes becomes changed into the solid matrix or intertubular substance

of the dentine, which is thus as it were moulded upon them, so as to form the tubules in which, therefore, the cell-processes are now enclosed. The same cell may continue to spin out a filament until the tubule is completed in its whole length, and it may be that a cell sends out two or more processes, coalescing into one as the cell recedes, so that a branched tubule is thus produced.

According to Waldeyer (with whom Boll seems to agree) it is the substance or protoplasm of the cells which becomes transformed into the dentinal matrix, all except the central part, which remains unaltered, occupying the tubule, and is prolonged by another cell lying deeper in the pulp, with which the first is in connection, and so on in succession. Moreover, he refers the anastomosis of neighbouring tubules to the existence of communicating branches between adjacent cells.

The collogenuous basis of the dentinal matrix is at first uncalcified (fig. 220, *b*), but the material of calcification soon begins to be deposited in nodules or globules, which run together into a uniform hard substance (*a*). In parts where this coalescence partially fails the uncalcified matter between the globules shrinks up when the tooth has become dry, so as to leave the interglobular spaces previously described (p. 310). The globular mode of deposition is indicated also by the inner surface of the growing dentine, which is nodulated (Czermak); and, indeed, separate nodules may sometimes be seen in the soft tissue of the growing matrix (see fig. 220).

Purkinje and Raschkow described a fine pelucid homogeneous membrane (*membrana preformativa*) covering the surface of the pulp before the commencement of calcification, but the existence of such a coating is at best doubtful, and at any rate whether present or not, it appears to be of no significance in the development of the teeth. It may possibly be the first uncalcified deposit of dentinal matrix.

**The Enamel.**—The surface cells of the enamel-germ line the dental sac in the form of a tessellated or cubical epithelium (fig. 221, *e*). On the other hand the cells which lie next the surface of the pulp become elongated and attenuated into a prismatic shape, precisely like a columnar epithelium (*d* fig. 221). The central cells,

Fig. 221.




Fig. 221.—A SECTION THROUGH THE ENAMEL ORGAN AND DENTAL SAC FROM THE TOOTH OF A CHILD AT BIRTH (from Kölliker). 250 DIAMETERS.

*a*, outer dense layer of the dental sac; *b*, inner looser texture of the same with capillary blood-vessels and a somewhat denser layer towards the enamel organ; *c*, spongy substance; *d*, inner cells; and *e*, outer cellular layer of the enamel organ.

those, namely, which are situated between these two layers, undergo remarkable changes. Originally spheroidal, they for a time merely increase in number, but eventually, assuming a stellate form, they send out branches which join with one another (fig. 221, *c*), whilst a clear jelly-like matter collects in their interstices. Next, however, to the tessellated layer is a stratum of epithelial cells, which retain their original spheroidal shape.

Into the cavity containing the enamel-germ numerous small papillary processes of the vascular sac and adjacent mucous membrane project, and between these, on the other hand, epithelial processes extend from the enamel-germ into the membrane. The enamel-germ is now designated the "enamel organ," *organon adamantinæ* of Purkinje, who named the columnar epithelium on the surface of the pulp the *membrana adamantinæ*, or enamel membrane.

The enamel prisms appear to be formed by the columnar cells of the enamel-organ, either by direct calcification of their substance or by deposition. It is true that in sections a space is commonly observed between the cells and the newly-formed enamel but this is probably produced after death by a shrinking of the soft parts. The process of formation commences next to the forming dentine, almost as soon indeed as the latter begins to be produced. The enamel substance is at first soft and friable, but gets hard eventually. The enamel organ extends no farther than the crown of the tooth, to which, therefore, the deposit of enamel is limited. As the formation of enamel becomes completed the rest of the enamel organ dwindles away: the superficial tessellated layer is believed to become the "cuticula dentis."

The **cement** begins to be formed simultaneously with or soon after the dentine of the fang by the subperiosteal tissue, as in the formation of the superficial layers of a bone.

**Eruption of the temporary Teeth.**—At the time of birth the crowns of the anterior milk-teeth, still enclosed in their sacs, are completed within the jaw, and their fangs begin to be formed. Their appearance through the gums follows a regular order, but the period at which each pair of teeth is cut varies within certain limits. The eruption commences at the age of seven months, and is completed about the end of the second year. It begins with the central incisors of the lower jaw, which are immediately followed by those of the upper jaw; and, as a general rule, each of the lower range of teeth rises through the gum before the corresponding tooth of the upper set. The following scheme indicates, in months, the order and time of eruption of the milk-teeth:—

| MOLARS. |    | CANINES. | INCISORS. |   |   |   | CANINES. | MOLARS. |    |
|---------|----|----------|-----------|---|---|---|----------|---------|----|
| 24      | 12 | 18       | 9         | 7 | 7 | 9 | 18       | 12      | 24 |

Before the teeth protrude through the gum, this undergoes some peculiar changes: its edge at first becomes dense and sharp, but, as the tooth approaches it, the sharp edge disappears, the gum becomes rounded or tumid, and is of a purplish hue; the summit of the tooth is seen like a white spot or line through the vascular gum, and soon afterwards rises through it. As the crown of the tooth advances to its ultimate position, the elongated fang becomes surrounded by a bony socket or alveolus. Before the eruption, the mucous membrane is studded with a number of small white bodies, which were described by Serres as

glands (*dental glands*), and were supposed by him to secrete the tartar of the teeth. Meckel thought they were small abscesses, because no aperture could be detected in them. In a foetus of six months, they were found by Sharpey to be small round pearl-like bodies, in form of small spherical capsules of various sizes, filled with epithelium. They are probably the prominences, or sprouts of the outer epithelial layer of the enamel organ, already referred to.

**Development of the permanent Teeth.**—The preceding description of the structure of the dental sacs and pulps and of the mode of formation of the several parts of a tooth, applies to the permanent as well as to the milk-teeth. The origin and progressive development of the sacs and pulps of the permanent teeth have still to be considered. Ten permanent teeth in each jaw succeed the milk-teeth, and six are superadded further back in the jaw. It will be convenient to treat first of the ten anterior teeth or teeth of succession.

The sacs and pulps of these teeth have their foundations laid before birth, behind those of the milk set. Reverting to the follicular stage of the temporary teeth, which is completed about the fourteenth week, it will be remembered that behind each milk-follicle there is formed a small recess (fig. 214, c, *fp*), which is filled with epithelium derived from the common enamel-germ, and this forms the germ of the corresponding permanent tooth. As already stated, these recesses escape the general adhesion of the sides of the dental groove, so that when the latter closes they are converted into so many cavities, enclosing epithelium, which were called by Goodsir, "*cavities of reserve.*" They are ten in number in each jaw, and are formed successively from before backwards. These cavities soon elongate and recede into the substance of

Fig. 222.

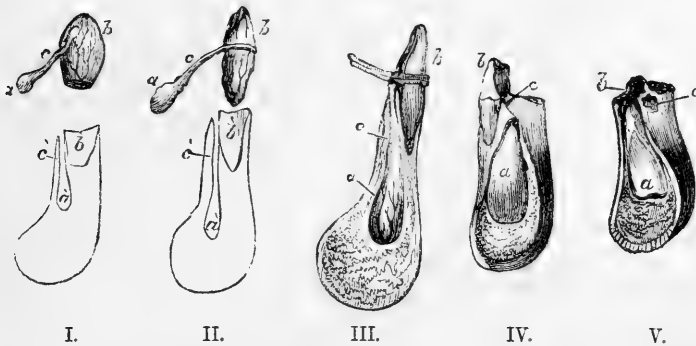


Fig. 222.—SKETCHES SHOWING THE RELATIONS OF THE TEMPORARY AND PERMANENT DENTAL SACS AND TEETH (after Blake, with some additions).

The lower parts of the first three figures, which are somewhat enlarged, represent sections of the lower jaw through the alveolus of a temporary incisor tooth: *a*, indicates the sac of the permanent tooth; *c*, its pedicle; *b*, the sac of the milk tooth or the milk tooth itself; *a'*, *b'*, indicate the bony recesses in which the permanent and temporary teeth are lodged, and *c'*, the canal by which that of the former leads to the surface of the bone behind the alveolus of the temporary tooth. The fourth and fifth figures, which are nearly of the natural size, show the same relations in a more advanced stage, in IV., previous to the change of teeth, in V., when the milk-tooth has fallen out and the permanent tooth begins to rise in the jaw; *c*, the orifice of the bony canal leading to the place of the permanent tooth.

the gum behind the germs of the milk teeth, above and behind in the upper jaw, below and behind in the lower. In the meantime, a papilla appears in the bottom of each, (that for the central incisor appearing first, at about the sixth month,) and they become closed in above in a similar manner to the germs of the temporary teeth as already described. When these changes have taken place, the sac of the permanent tooth adheres to the back of that for the temporary tooth. Both of them then continue to grow rapidly, and after a time it is found that the bony socket not only forms a cell for the reception of the milk-sac, but also a small posterior recess or niche for the permanent-tooth-sac, with which the recess keeps pace in its growth. In the lower jaw, to which our description may now, for convenience, be confined, it is found that at length the permanent sac so far recedes in the bone as to be lodged in a special osseous chamber at some distance below and behind the milk-tooth, the two being completely separated from each other by a bony partition. In descending in the jaw, the sac for the permanent tooth acquires at first a pear-shape, and is then connected with the gum by a solid pedicle (fig. 222, I., II., c). The recess in the jaw (*a'*) has a similar form, drawn out into a long canal for the pedicle which opens on the edge of the jaw, by an aperture behind the corresponding milk-tooth. The permanent tooth is thus separated from the socket of the milk-tooth by a bony partition, against which, as well as against the root of the milk-tooth just above it, it presses in its rise through the gum, so that these parts are in a greater or less extent absorbed. When this has proceeded far enough, the milk-tooth becomes loosened, falls out or is removed, and the permanent tooth takes its place. The absorption of the dental substance commences at or near the ends of the fangs, and proceeds upwards until nothing but the crown remains. The cement is first attacked, and then the dentine: but the process is similar in the two tissues. The change is not produced merely by pressure, but, as in the case of the absorption of bone, through the agency of multi-nucleated absorbing cells or osteoclasts, developed at the time, and applied to the surface of the tooth.

Fig. 223.

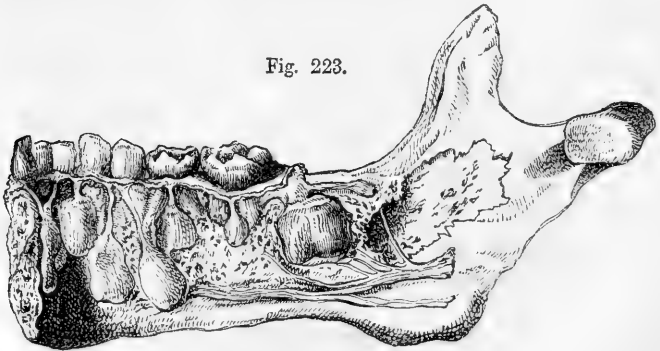


Fig. 223.—PART OF THE LOWER JAW OF A CHILD OF THREE OR FOUR YEARS OLD, SHOWING THE RELATIONS OF THE TEMPORARY AND PERMANENT TEETH.

The specimen contains all the milk-teeth of the right side, together with the incisors of the left; the inner plate of the jaw has been removed, so as to expose the sacs of all the permanent teeth of the right side, except the eighth or wisdom tooth, which is not yet formed. The large sac near the ramus of the jaw is that of the first permanent molar, and above and behind it is the commencing rudiment of the second molar.

The six posterior (or "superadded") permanent teeth, that is, the three permanent molars on each side, do not come in the place of other teeth. They arise from successive extensions of the dental groove and enamel-germ carried backwards in the jaw, posterior to the milk-teeth, and named by Goodsir "*posterior cavities of reserve.*"

During the general adhesion of the dental groove occurring at the fifteenth week, the part posterior to the last temporary molar follicle continues unobliterated, and thus forms a cavity filled by an enamel-germ, in the fundus of which a papilla ultimately appears, and forms the rudiment of the first permanent molar tooth; this takes place very early, viz., at the sixteenth week. The deepest part of this cavity is next converted by adhesion into a sac, which encloses the papilla, whilst its upper portion with its contained epithelium, elongates backwards so as to form another cavity of reserve, in which, at the seventh month after birth, the papilla for the second molar tooth appears. After a long interval, during which the sac of the first permanent molar and its contained tooth have acquired great size, and that of the second molar has also advanced considerably in development, the same changes once more occur and give rise to the sac and papilla of the wisdom-tooth, the rudiments of which are visible at the sixth year. The subsequent development of the permanent molar teeth takes place from these sacs just like that of the other teeth.

Calcification begins first in the anterior permanent molar teeth. Its order and periods may be thus stated for the upper jaw, the lower being a little earlier: First molar, five or six months after birth; central incisor, a little later; lateral incisor and canine, eight or nine months; two bicuspids, two years or more; second molar, five or six years; third molar, or wisdom-tooth, about twelve years.

**Eruption of the permanent teeth.**—The time at which this occurs in regard to each pair of teeth in the lower jaw is exhibited in the sub-joined table. The corresponding teeth of the upper jaw appear somewhat later.

|                               |            |
|-------------------------------|------------|
| Molar, first . . . . .        | 6 years.   |
| Incisors, central . . . . .   | 7 "        |
| " lateral . . . . .           | 8 "        |
| Bicuspids, anterior . . . . . | 9 "        |
| " posterior . . . . .         | 10 "       |
| Canines . . . . .             | 11 to 12 " |
| Molars, second . . . . .      | 12 to 13 " |
| " third (or wisdom) . . . . . | 17 to 25 " |

It is just before the shedding of the temporary incisors—*i.e.*, about the sixth year, that there is the greatest number of teeth in the jaws. At that period there are all the milk-teeth, and all the permanent set except the wisdom-teeth, making forty-eight (see fig. 224.)

During the growth of the teeth the jaw increases in depth and length, and undergoes changes in form. In the child it is shallow, but it becomes much deeper in the adult. In the young subject the alveolar arch describes almost the segment of a circle; but in the adult the curve is semi-elliptical. The increase which takes place in the length of the jaw arises from a growth behind the position of the milk-teeth, so as to provide room for the three additional teeth on each side belonging to the permanent set. At certain periods in the growth of the jaws there is not sufficient room in the alveolar arch for the growing sacs of the permanent molars; and hence the latter are found at certain stages of their

development to be enclosed in the base of the coronoid process of the lower jaw, and in the maxillary tuberosity in the upper jaw, but they afterwards successively assume their ultimate position as the bone increases in length. The space

Fig. 224.

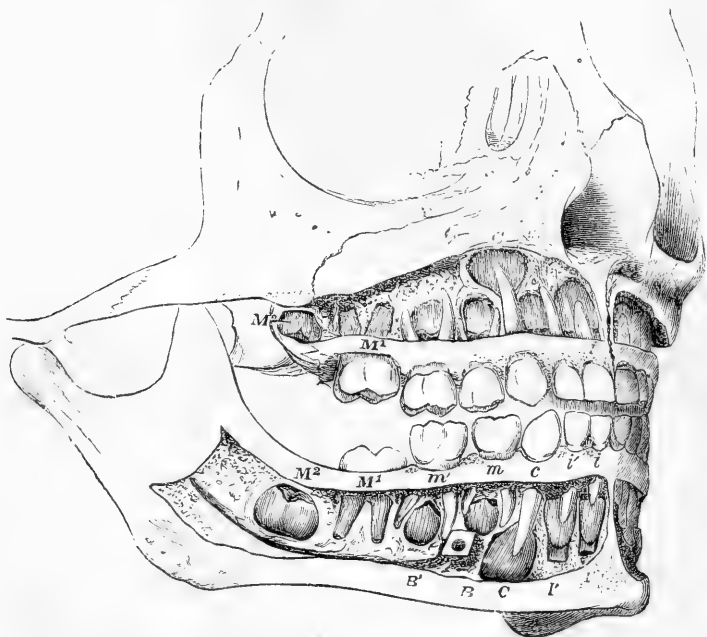


Fig. 224.—THE TEETH OF A CHILD OF SIX YEARS, WITH THE CALCIFIED PARTS OF THE PERMANENT TEETH EXPOSED (Allen Thomson, after Heule).

The whole of the teeth of the right side are shown, together with the three front teeth of the left side : in the upper and lower jaws the teeth are indicated as follows, viz. :— 1, *milk-teeth*—*i*, inner or first incisor ; *i'*, outer or second incisor ; *c*, canine ; *m*, first molar ; *m'*, second molar. 2, *permanent teeth*—*I*, inner or first incisor ; *I'*, outer or second incisor ; *C*, canine ; *B*, first bicuspid ; *B'*, second bicuspid ; *M*<sup>1</sup>, the first molar, which has passed through the gums ; *M*<sup>2</sup>, the second molar, which has not yet risen above the gums : the third molar is not yet formed.

taken up by the ten anterior permanent teeth very nearly corresponds with that which had been occupied by the ten milk-teeth ; the difference in width between the incisors of the two sets being compensated for by the smallness of the bicuspids in comparison with the milk-molars to which they succeed. Lastly, the angle formed by the ramus and body of the lower jaw differs at different ages ; thus it is obtuse in the infant, approaches nearer to a right angle in the adult, and again becomes somewhat obtuse in old age.

#### SECONDARY DENTINE.

Under this head are included certain varieties of hard tissue liable to be formed in the pulp-cavity of a tooth after the regular production of the dentine is completed. These, as hitherto noticed and described, are the following\* :—

1. **Osteodentine** (Owen).—This is a hard substance which becomes deposited

\* Salter, Guy's Hospital Reports ; and Dental Pathology and Surgery.



on the inner surface of the dentine, so that the central cavity of a tooth becomes gradually diminished in size, whilst the pulp slowly shrinks or disappears. This additional substance, formerly regarded as an extension of the cement into the interior of the tooth,—has been shown to have a distinct structure, in part resembling dentine, and in part bone. It is traversed by canals, which contain blood-vessels, and are surrounded by concentric lamellæ like the Haversian canals of bone. From these canals, numerous tubules radiate, larger than the canaliculi of bone, resembling, in this respect, and also in their mode of ramification, the tubes of the dentine. This new growth may indeed be compared to a collection of miniature pulps, each surrounded by its appertaining dentine, pierced by radiating tubules. It may or may not coalesce with the previously formed dentine; it appears to be produced by a slow conversion of the dental pulp.

2. **Dentine of Repair** (Salter).—When the outer surface of the dentine becomes denuded at any place, so that the peripheral ends of the tubules are there exposed, as may happen in the crown from injury or wear of the enamel, or at the cervix from continued friction and abrasion of the cement, a deposition of dental matter occurs on the inner surface of the dentine exactly corresponding in position and extent with the area occupied by the central ends of the exposed tubules. Many of the affected tubules become subsequently filled up by a deposit of hard matter within them, so that on section both the secondary dentine and the corresponding part of the primary dentine appear clearer and more transparent than the remainder of the dentinal substance (see fig. 225).

When the surface-injury has been considerable, the dentine of repair is largely in excess, and may in such cases completely fill up the pulp-cavity.

## THE TONGUE.

The *tongue* is a muscular organ covered with mucous membrane. By its muscular structure it takes part in the processes of mastication and deglutition, and in the articulation of speech, while its mucous membrane is endowed with common and tactile sensibility and is the seat of the sense of taste. The tongue occupies the concavity of the arch of the lower jaw; posteriorly it is connected with the hyoid bone, and the back part of its upper surface forms the floor of the arch of the fauces; inferiorly it receives from base to apex the fibres of the genio-glossus muscle, and through the medium of that muscle is attached to the lower jaw.

A.—**MUCOUS MEMBRANE.**—On the *under surface* of the tongue the mucous membrane is smooth and thin. It forms a fold in the middle line called the *frænum lingue*, placed in front of the anterior border of the genio-glossi muscles. On each side below, as the mucous membrane passes from the tongue to the inner surface of the gums, it is reflected over the sublingual gland. Not far from the line continued forwards from the frænum, the ranine vein may be distinctly seen through the mucous membrane, and close to it lies the ranine artery. Further out

Fig. 225.

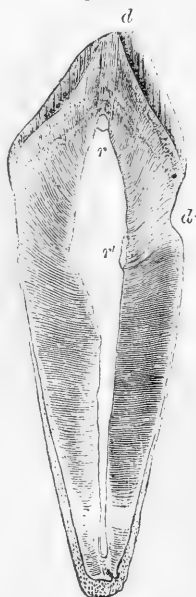


Fig. 225.—LONGITUDINAL SECTION OF INCISOR TOOTH SHOWING DENTINE OF REPAIR. SLIGHTLY MAGNIFIED. (Reduced from Salter.)

*d, d'*, denuded surfaces of dentine; *r, r'*, corresponding deposits of secondary dentine. Two or three incremental lines are observed in the dentine.

is an elevated line with a fimbriated margin directed outwards, which extends to the tip. The ducts of the right and left submaxillary glands end by papillary orifices placed close together, one on each side of the frænum; and further back, between the sides of the tongue and the

Fig. 226.

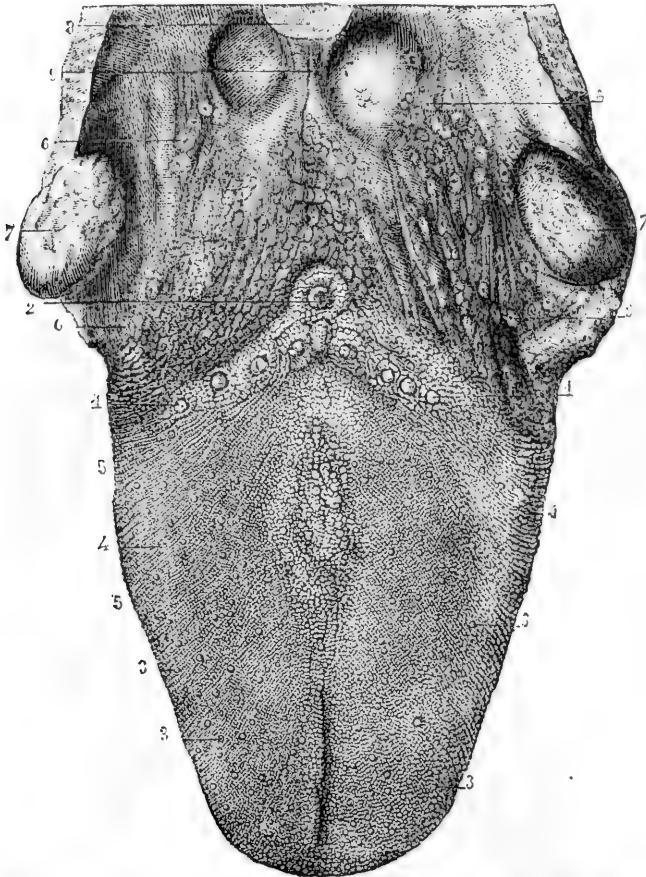


Fig. 226.—PAPILLAR SURFACE OF THE TONGUE, WITH THE FAUCES AND TONSILS (from Sappey).

1, 2, circumvallate papillæ; in front of 2, the foramen cæcum; 3, fungiform papillæ; 4, filiform and conical papillæ; 5, transverse and oblique ranges; 6, mucous glands at the base of the tongue and in the fauces; 7, tonsils; 8, part of the epiglottis; 9, median glosso-epiglottidean fold or frænum epiglottidis.

lower jaw, are found the orifices of the several ducts belonging to the sublingual glands.

The *upper surface* or *dorsum* of the tongue (fig. 226), is convex in its general outline, and is marked along the middle for nearly its whole length by a slight furrow called the *raphé*, which indicates its bilateral symmetry. About half an inch from the base of the tongue, the raphé

often terminates in a depression, closed at the bottom, which is called the *foramen cæcum* (Morgagni), and in which several mucous *glands* open. Three folds, named the glosso-epiglottic folds or *frænula*, of which the middle one is the largest (*frænulum epiglottidis*), pass backwards from the base of the tongue to the epiglottis. The upper surface of the tongue in front of the foramen cæcum (the anterior two-thirds) is covered with small eminences named *papillæ*. They are found also upon the tip and borders, where, however, they gradually become smaller, and towards its under surface they disappear. These *papillæ* are distinguished into three orders, *circumvallatæ*, *fungiform* and *filiform*, varying both in size and form, but all of them visible to the naked eye; they themselves, like the rest of the mucous membrane of the tongue and mouth generally are covered with closely set, microscopic secondary *papillæ* hidden under the epithelium, which correspond with those of the skin, and are each occupied by a long loop of capillary blood-vessels.

The large **circumvallatæ papillæ** (fig. 226, 1, 2), from seven to twelve in number, are found on the back part of the tongue, arranged in

Fig. 227.—VERTICAL SECTION OF CIRCUMVALLATE PAPILLA FROM THE CALF (Engelmann). 25 DIAMETERS.

A, the papilla; B, the surrounding wall. The figure shows the nerves of the papilla spreading towards the surface, and towards the taste-buds which are imbedded in the epithelium at the sides: in the sulcus on the left the duct of a gland is seen to open.

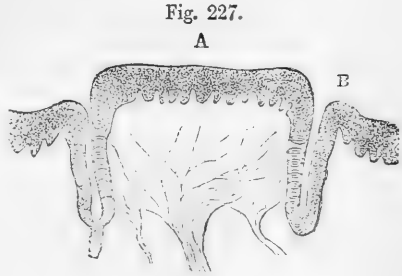


Fig. 227.

A

B

two rows, which run obliquely backwards and inwards, and meet towards the foramen cæcum, like the arms of the letter V. They are situated in cup-like depressions of the mucous membrane, and have the shape of a truncated cone, of which the smaller end is attached to the bottom of the cavity, and the broad flattened base appears on the surface (fig. 227). They are therefore surrounded by a circular trench (*fossa*), around which again is an annular elevation of the mucous membrane (*vallum*), and in some of them there is found a central depression, into which the ducts of one or more glands open. The epithelium covering the *papillæ*

Fig. 228.

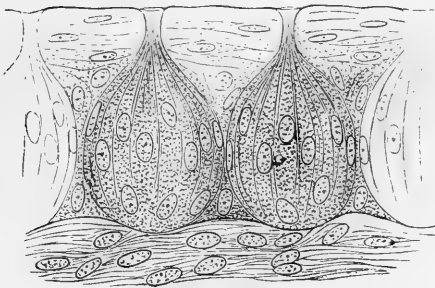


Fig. 228.—TWO TASTE-BUDS FROM THE PAPILLA FOLIATA OF THE RABBIT. 450 DIAMETERS (Engelmann).

*vallatæ* is thick and stratified, as elsewhere in the mouth, and completely conceals the minute secondary *papillæ*. Forming a zone around the sides of the papilla are found, imbedded in this thick epithelium, peculiar

ovoidal or flask-shaped bodies, composed of modified epithelium cells and believed to be special organs of taste. These *taste-buds*, as they have been termed, are comparable in form and structure to the leaf-buds of a plant (fig. 228). By their bases they are in contact with the corium, while their apices, which appear as round openings or pores when viewed from the surface, emerge between the ordinary epithelium cells. The latter are flattened around the taste-buds, enclosing them in a sort of nest. The taste-buds themselves may be described as consisting of a cortical and a central part. The cells composing the cortical part are long and flattened with tapering ends (fig. 229 *c*), and are in contact by their edges, extending from base to apex of the organ (fig. 228); they are disposed in more than one layer, and enclose the central part like the external scales of a leaf-bud. The enclosed or central cells (fig. 229 *a*), on the other hand are not flattened but spindle-shaped.

Fig. 229.

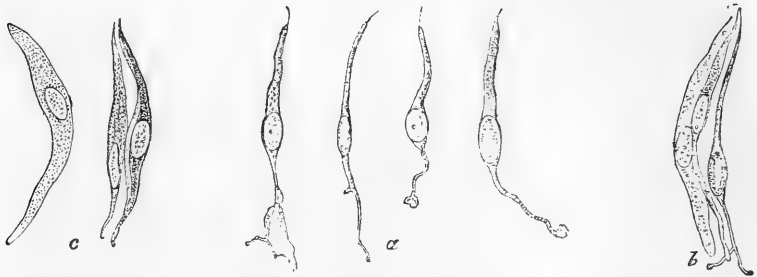


Fig. 229.—VARIOUS CELLS FROM TASTE-BUD OF RABBIT. 600 DIAMETERS (Engelmann).

*a*, Four cells from central part; *b*, two cortical cells, and one central cell, in connection; *c*, three cells from cortical part.

having an enlargement near the middle where the nucleus is situated, and being prolonged at each end by a process, one of which extends upwards towards the apex of the taste-bud, and is surmounted by an excessively fine styliform extremity which projects at the orifice, whilst the other, which is commonly more slender and sometimes divided or branched at its extremity, passes down into the corium of the mucous membrane, and is described as being connected with a plexus of fine nervous fibrils found in this situation. The similarity of these *central* or *gustatory cells* with the well-known olfactory cells of Max Schultze will be at once apparent.

The taste-buds were discovered by Lovèn and Schwalbe, independently of each other.\* They have now been found on the sides (but never on the upper surface) of the papillæ vallatæ of a great number of animals, and are seen also on some of the fungiform papillæ to be immediately described. Their structure is most readily studied in the rabbit and hare, for in these animals there is found at each side of the base of the tongue an oval laminated structure, the so-called *papilla foliata*, the laminae composing which contain in the epithelium of their opposed surfaces great numbers of those bodies. A small area, situate just in front of the anterior pillar of the fauces, of variable appearance, but usually with five longi-

\* Lovèn, Schwalbe, Arch. f. mikr. Anat. 1867, and Arch. f. mikr. Anat. 1868; Engelmann, in Stricker's Handbook; Krause, Göttinger Nachrichten, 1870. According to Krause the distribution of the taste-buds follows that of the glosso-pharyngeal nerve.

tudinal folds, which are studded with taste-buds, exists in the human tongue, and is regarded as representing a papilla foliata.

According to Engelmann, each taste-bud is composed of from 15 to 30 cells.

The taste organs of the Amphibia have been longer recognised. They occur in the form, not of buds but of patches interspersed here and there amongst the ordinary ciliated and columnar epithelium which covers the upper surface and sides of the tongue.\*

Flask-shaped bodies, resembling the taste-buds in structure, were long since described by Leydig as occurring in fish. They are found both in the skin and in the mucous membrane of the mouth, and are believed to be gustatory organs.

The **fungiform papillæ**, more numerous than the last, are small rounded eminences scattered over the middle and fore part of the dorsum of the tongue (fig. 226, 3); but they are found in greater numbers and closer together at the apex and near the borders. They are easily distinguished in the living tongue owing to their deep red colour. They are narrow at their point of attachment, but are gradually enlarged towards their free extremities, which are blunt and rounded (fig. 230).

The **conical and filiform papillæ** are the most numerous of all, as well as the smallest. They are minute, conical, tapering, or cylindrical eminences, which are densely set over the greater part of the dorsum of the tongue (fig. 226, 4), but towards the base gradually disappear. They are arranged in lines diverging from the raphè, at first in an oblique direction like the two ranges of the papillæ vallatæ, but gradually becoming transverse towards the tip of the tongue. At the sides they are longer and more slender, and arranged in parallel rows, perpendicular to the border of the tongue.

The secondary papillæ, borne by the filiform, are peculiar both in containing a number of elastic fibres, giving them greater firmness, and in the character of their epithelial covering, which is dense and imbricated, and forms a separate process over each, greater in length than the papilla which it covers (fig. 231, *e, f*). Over some of the filiform papillæ these processes form a pencil of fine fibres, approaching in some cases in appearance to hairs.

Fig. 230.




Fig. 230.—SURFACE AND SECTIONAL VIEW OF A FUNGIFORM PAPILLA (from Kölliker after Todd and Bowman).

A, the surface of a fungiform papilla partially denuded of its epithelium (35 diameters); *p*, secondary papillæ; *e*, epithelium.

B, section of a fungiform papilla with the blood-vessels injected. *a*, artery; *v*, vein; *c*, capillary loops of simple papillæ in the neighbourhood, covered by the epithelium; *d*, capillary loops of the secondary papillæ; *e*, epithelium.

\* Billroth in Archiv f. Anat. u. Phys. 1858: Hoyer in the same journal for 1859: Axel Key, in the same for 1861: Engelmann in Zeitsch. f. Wiss. Zool. 1867.

The papillæ, besides being the parts chiefly concerned in the special sense of taste, also possess, in a very acute degree, tactile sensibility ;

Fig. 231.

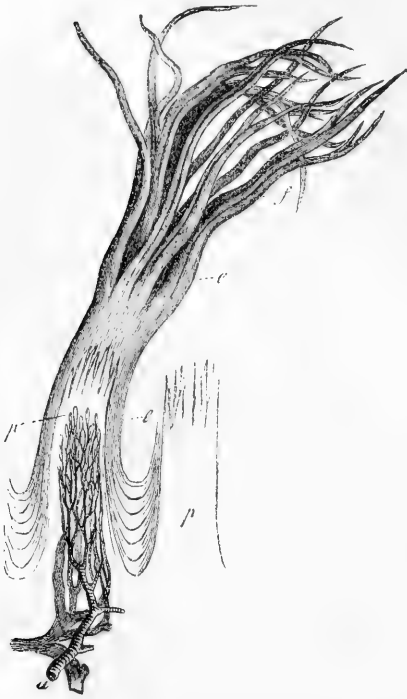

Fig. 231.—Two FILIFORM PAPILLE, ONE WITH EPITHELIUM, THE OTHER WITHOUT. 35 DIAMETERS. (From Kölliker, after Todd and Bowman).

*p*, the substance of the papillæ divided at their upper extremities into secondary papillæ ; *a*, artery, and *v*, vein, connected by capillary loops ; *e*, epithelial covering, laminated between the papillæ, but extended into hair-like processes, *f*, from the extremities of the secondary papillæ.

(Elnor). Other small glands are found also beneath the mucous membrane of the borders of the tongue. There is, in particular, a group on the under surface of the tongue on each side near the apex. They are there aggregated into a small oblong mass, out of which several ducts proceed and open in a line on the mucous membrane.

The mucous membrane of the tongue, at least its posterior part, is largely composed of retiform or lymphoid tissue, which is collected at numerous points into the denser nodular masses known as follicular glands, or lymphoid follicles. The blood-vessels and lymphatics of this part of the membrane are numerous and large, but the papillæ on its surface are comparatively small, and are completely concealed by the thick

and the filiform papillæ, armed with their denser epithelial covering, serve a mechanical use, in the action of the tongue upon the food, as is well illustrated by the more developed form which these papillæ attain in many carnivorous animals. The papillary surface of the tongue is supplied abundantly with nerves. In the papillæ fungiformes the nerves are large and numerous, and form a plexus with brush-like branches ; but they are still more abundant, and of greater size, in the papillæ circumvallatæ, where they are chiefly distributed in the neighbourhood of the taste-buds (fig. 227).

**Glands.**—The mucous membrane of the tongue is provided with numerous small racemose glands called *lingual glands*, collected principally about the posterior part of its upper surface, near the papillæ vallatæ and foramen cæcum, into which last the ducts of several open. These glands have commonly been supposed to secrete mucus, but it has been recently ascertained that some of them, those, namely, which open in the trenches around the papillæ vallatæ, and at other parts where taste-buds occur, yield a more watery secretion

superjacent epithelium. Here and there the mucous membrane exhibits recesses or crypts (fig. 232), either simple or surrounded by smaller ones which open into them. The walls of these recesses are generally studded with lymphoid nodules; and they receive many of the ducts of the mucous glands.

**B. — MUSCULAR SUBSTANCE.**—The substance of the tongue is chiefly composed of muscular fibres running in different but determinate directions. Many belong to muscles which enter at its base and under surface, and attach it to other parts: these are called the *extrinsic muscles* of the tongue, and are elsewhere described. Others which constitute the *intrinsic* or proper muscles, and are placed entirely within the substance of the organ, will be here more particularly noticed. They are as follows:—

The **lingualis superficialis** (noto-glossus, Zaglas), consisting mainly of longitudinal fibres, is placed on the upper surface of the tongue, immediately beneath the mucous membrane, and is traceable from the apex of the organ backwards to the hyoid bone (figs. 233, 234, *l s*). The individual fibres do not run the whole of this distance, but are attached at intervals to the sub-mucous and glandular tissues. The entire layer becomes thinner towards the base of the tongue, near which it is overlapped at the sides by a thin plane of oblique or nearly transverse fibres derived from the palato-glossus and hyo-glossus muscles. According to Zaglas, the fibres of this muscle are directed forwards and outwards.

The **lingualis inferior** (lingualis muscle of Douglas, Albinus, and others) consists of a rounded muscular band, extending along the under surface of the tongue from base to apex, and lying outside the genio-hyo-glossus between that muscle and the hyo-glossus (fig. 234, *li*). Posteriorly, some of its fibres are lost in the substance of the tongue, and others reach the hyoid bone. In front, having first been joined, at the anterior border of the hyo-glossus muscle, by fibres from the stylo-glossus, it is prolonged beneath the border of the tongue as far as its point.

The **transverse** muscular fibres of the tongue (figs. 233, 234, *tr*) form together with the intermixed fat a considerable part of its substance. They are found in the interval between the upper and lower longitudinal muscles, and they are interwoven extensively with the other muscular fibres. Passing outwards from the median plane, where they take origin from a fibrous septum, they reach the dorsum and borders of the tongue. In proceeding outwards, they separate, and the superior

Fig. 232.

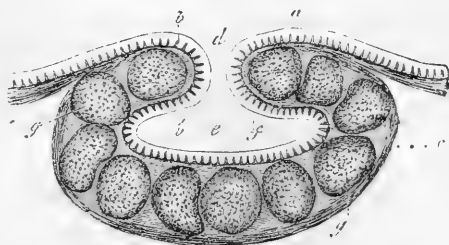


Fig. 232.—SECTION OF A LYMPHOID CRYPT FROM THE ROOT OF THE TONGUE. 30 DIAMETERS. (Kölliker).

*a*, epithelial lining; *b*, papillæ of the mucous membrane; *c*, outer part of the crypt, formed of connective tissue; *d*, outlet, and *e*, cavity of the crypt; *g*, surrounding follicles.

fibres incline upwards, forming a series of curves with the concavity turned upwards. The fibres of the palato-glossus muscle are found by

Fig. 233.

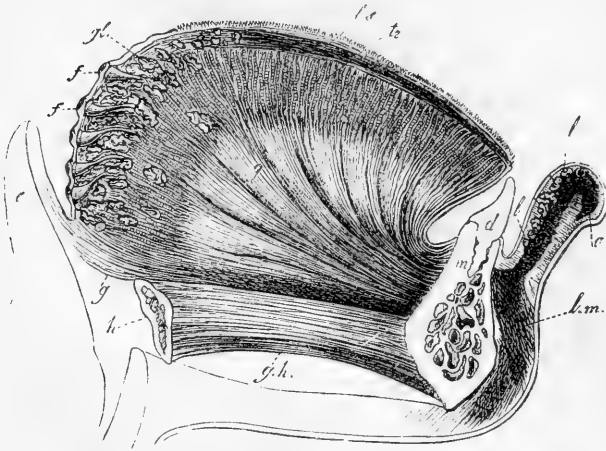


Fig. 233.—LONGITUDINAL VERTICAL SECTION OF THE TONGUE, LIP, &c. (from Kölliker and Arnold).

*m*, symphysis of the lower jaw; *d*, incisor tooth; *h*, hyoid bone; *g h*, genio-hyoid muscle; *g*, genio-hyo-glossus spreading along the whole of the tongue; *t r*, transverse muscle; *l s*, superior longitudinal muscle; *g l*, lingual glands; *f*, lymphoid crypts; *c*, epiglottis; *l*, section of the lip and labial glands; *o*, cut fibres of the orbicularis oris; *l m*, levator menti.

Zaglas and Henle to be continuous with fibres of the transverse set.

**Vertical fibres** (musculus perpendicularis externus of Zaglas), decussating with the transverse fibres and the insertions of the genio-glossus (fig. 234, *h'*), form a set of curves in each half of the tongue

Fig. 234.

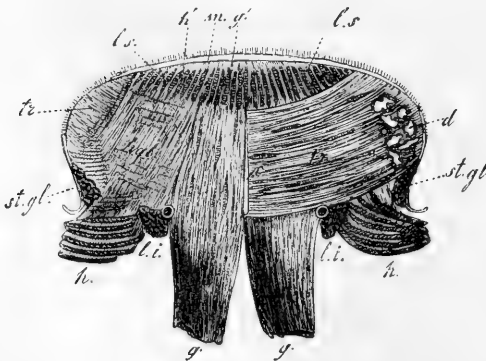


Fig. 234.—TRANSVERSE VERTICAL SECTION OF THE TONGUE IN FRONT OF THE PAPILLÆ VALLATÆ, SEEN FROM BEFORE (from Kölliker).

*g*, the genio-hyo-glossi muscles; *g'*, the vertical fibres of the right side traced upwards to the surface; *l i*, inferior longitudinal muscle with the divided ranine artery; *t r*, transverse muscle, entire on one side, but partially removed on the other, where the other muscles pass through it; *c*, septum linguæ; *h*, hyo-glossus; *h g l*, its fibres spreading upwards almost vertically outside the

genio-hyo-glossus; *h'*, vertical fibres reaching the surface; *l s*, divided plates of the fibres of the superior longitudinal muscle between the vertical fibres; *s t*, *g l*, stylo-glossus; *d*, glands near the border of the tongue.



with their concavity outwards, and extending down and out from the dorsum to the under surface of the border, so that those which are outermost are shortest. (Zaglas, "On the Muscular Structure of the Tongue," in Goodsir's Annals, I. p. 1.)

Examined in transverse sections, the muscular fibres are seen to be arranged so as to render the substance divisible into an outer part or *cortex* and an internal or central part. The fibres of the cortex are principally longitudinal, derived superiorly from the lingualis superior, further outwards from the hyo-glossus, on the side from the stylo-glossus, and beneath this from the lingualis inferior. They ensheath the medullary part on all sides except inferiorly, where the genio-glossi muscles enter it between the inferior linguales. In the medullary part are found, imbedded in fat, the decussating fibres of the transverse muscle passing across, the genio-glossi radiating upwards and outwards, and the vertical muscles arching downwards and outwards. In addition to the movements which may be given to the tongue by the extrinsic muscles, this organ is capable of being curved upwards, downwards, or laterally by its cortical fibres, it is flattened by the vertical fibres, and its margins are again drawn together by the transverse: whilst the two last mentioned, acting together, would tend to lengthen the organ.

The septum of the tongue is a thin fibrous partition which extends forwards from the hyoid bone to the tip, and divides one half of the medullary part of the tongue from the other, but does not penetrate into the cortex.

The **arteries** of the tongue are derived from the lingualis, with some small branches from the facial and ascending pharyngeal. With these the veins for the most part correspond.

The **nerves** of the tongue (exclusive of branches from the sympathetic nerves) are three; viz., the lingual or **gustatory** branch of the **fifth** pair, which supplies the papillæ and mucous membrane of the fore part and sides of the tongue to the extent of about two-thirds of its surface; the lingual branch of the **glossopharyngeal**, which sends filaments to the mucous membrane at the base of the tongue, and especially to the papillæ vallatæ; and, lastly, the **hypoglossal** nerve, which is distributed to the muscles. Microscopic ganglia exist upon the expansion of the glossopharyngeal nerve, and in the sheep and calf upon the gustatory division of the fifth.

The detailed description of the blood-vessels and nerves will be found elsewhere.

#### THE PALATE.

The roof of the mouth is formed by the palate, which consists of two portions; the fore part being named the hard palate, and the back part, the soft palate.

The osseous framework of the *hard* palate, already described with the bones of the face, is covered by the periosteum, and by the lining membrane of the mouth, which adhere intimately together. The mucous membrane, which is continuous with that of the gums, is thick, dense, rather pale, and much corrugated, especially in front and at the sides; but is smoother, thinner, and of a deeper colour behind. Along the middle line is a ridge or raphè, ending in front in a small eminence, which corresponds with the lower opening of the anterior palatine canal, and receives the terminal filaments of the naso-palatine and anterior palatine nerves. The membrane of the hard palate is provided with many muciparous glands, which form a continuous layer between the

membrane and the bone ; and, like the rest of the mouth, it is covered with a squamous stratified epithelium.

In the rabbit fine nervous fibrils have been traced forming a plexus in the epithelium (Elin).

The *soft* palate (*velum pendulum palati*) is formed of a doubling of mucous membrane inclosing muscular fibres and numerous glands. It constitutes an incomplete and moveable partition between the mouth and the pharynx, continued from the posterior border of the hard palate,

Fig. 235.

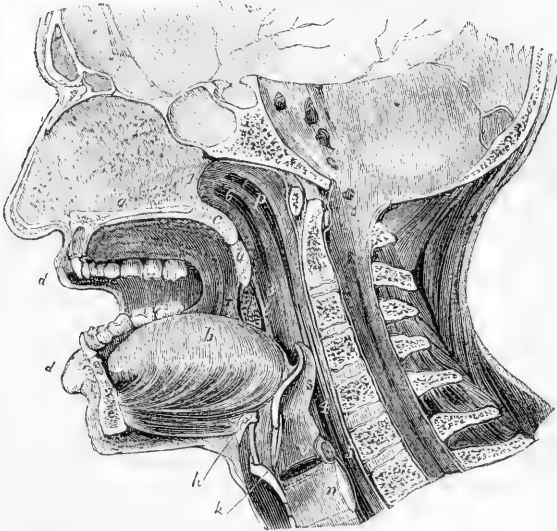


Fig. 235.—ANTERO-POSTERIOR VERTICAL SECTION THROUGH THE HEAD A LITTLE TO THE LEFT OF THE MIDDLE LINE, SHOWING THE RELATIONS OF THE NASAL AND BUCCAL CAVITIES, THE PHARYNX, LARYNX, &c.

*a*, nasal septum, and below it the section of the hard palate ; *b*, the tongue ; *c*, soft palate ; *d*, the lips ; *u*, the uvula ; *r*, anterior pillar of the fauces ; *i*, posterior pillar ; *t*, the tonsil placed between the pillars ; *p*, upper part of the pharynx ; *h*, body of the hyoid bone ; *k*, thyroid cartilage ; *n*, cricoid cartilage ; *v*, on the upper vocal cords above the glottis ; *s*, epiglottis ; *l*, posterior opening of the nares ; *3*, behind the isthmus faucium ; *4*, opposite the superior opening of the larynx ; *5*, passage into the œsophagus ; *6*, opening of the right Eustachian tube.

obliquely downwards and backwards (fig. 235, *c*). Its form and its inferior connections, bounding the isthmus of the fauces, have been already described, together with the muscles which enter into its composition.

The anterior or under surface of the velum, which is visible in the mouth, is concave. The mucous membrane, continuous with that of the hard palate, is thinner and darker : it is covered with a similar epithelium. The median ridge or raphè, which is continued backwards from the hard palate to the base of the uvula, indicates the original separation of the velum into two lateral halves.

The posterior surface of the soft palate, slightly convex or arched, is continuous above with the floor of the posterior nares. It is slightly elevated along the middle line, opposite to the uvula. The greater

portion of its mucous membrane, as well as that of the free margin of the velum, is covered with scaly, stratified epithelium; but quite at its upper portion, near the orifice of the Eustachian tube, the epithelium is columnar and ciliated. In the new-born child the whole posterior surface is covered with ciliated epithelium (Klein), but this becomes subsequently replaced by squamous; the epithelium of the gland-ducts, however, retains in many instances its ciliated character.

On both surfaces of the velum are found numerous small compound glands, called the *palatine* glands. They particularly abound on the upper surface, where, they form almost a complete layer under the mucous membrane; they are also very abundant in the uvula.

#### THE TONSILS.

The **tonsils** (*tonsillæ*, *amygdalæ*) are two prominent bodies, which occupy the recesses formed, one on each side of the fauces, between the anterior and posterior palatine arches and the pillars of the fauces (fig. 235, *t*).

They are usually about half an inch in length, and a third in width and thickness; but they vary much in size in different individuals.

The outer side of the tonsil is connected with the inner surface of the superior constrictor of the pharynx, and approaches very near to the internal carotid artery. Considered in relation to the surface of the neck, the tonsil corresponds to the angle of the lower jaw, where it may be felt beneath the skin when it is enlarged. Its inner surface, projecting into the fauces between the palatine arches, presents from twelve to fifteen orifices, which give it a perforated appearance. These orifices lead into recesses or crypts in the substance of the tonsil, like those already described (pp. 330-1) as occurring at the back part of the upper surface of the tongue. The tonsils contain a large amount of lymphoid tissue; indeed this appears to constitute their main substance.

These structures receive a very large supply of blood from various arteries, viz., from the tonsillar and palatine branches of the facial artery, and from the descending palatine, the ascending pharyngeal and the *dorsalis linguae*. From these arteries fine branches and capillaries are distributed abundantly to the lymphoid tissue and follicles and to the papillæ of the mucous membrane which lines the recesses. The veins are numerous, and enter the tonsillar plexus on its outer side. The nerves come from the glosso-pharyngeal nerve, and from the fifth pair. Lymphatics are abundant, and, as in the pharynx, are collected into a deep and superficial layer.

#### THE SALIVARY GLANDS.

The saliva, which is poured into the mouth, and there mixed with the food during mastication, is secreted by three pairs of glands, named from their respective situations, *parotid*, *submaxillary*, and *sublingual*. Agreeing in their general physical characters and minute structure, these glands differ in their size, form, and position.

#### THE PAROTID GLAND.

The parotid (fig. 236, *p*) is the largest of the three salivary glands. It lies on the side of the face, in front of the ear, and extends deeply into the space behind the ramus of the lower jaw. Its weight varies from five to eight drachms.

Its outer surface is convex and lobulated, and is covered by the skin

and fascia, and partially by the platysma muscle. It is bounded above by the zygoma, below by a line drawn backwards from the lower border of the jaw to the sterno-mastoid muscle, and behind by the external meatus of the ear, the mastoid process, and sterno-mastoid muscle. Its

Fig. 236.

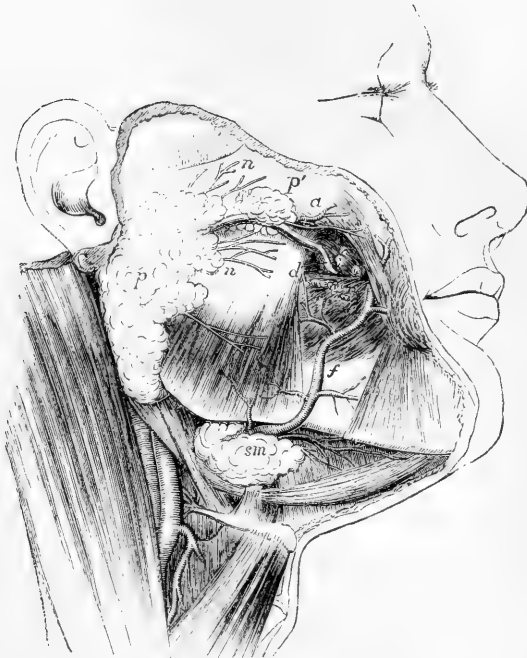

Fig. 236.—SKETCH OF A SUPERFICIAL DISSECTION OF THE FACE, SHOWING THE POSITION OF THE PAROTID AND SUBMAXILLARY GLANDS (Allen Thomson). TWO-FIFTHS THE NATURAL SIZE.

*p*, the main part of the parotid gland; *p'*, the small part, which lies alongside the duct, on the masseter muscle; *d*, the duct of Stenson before it perforates the buccinator muscle; *a*, transverse facial artery; *n, n*, branches of the facial nerve emerging from below the gland; *f*, the facial artery passing out of a groove in the submaxillary gland and ascending on the face; *sm*, superficial larger portion of the submaxillary gland lying over the posterior part of the mylo-hyoid muscle.

anterior border, which lies over the ramus of the lower jaw, is less distinctly defined, and stretches forwards to a variable extent on the masseter muscle. It is from this anterior border of the gland that the excretory duct passes off; and there is frequently found in connection with the duct, and lying upon the masseter muscle, a small process or a separated portion of the gland (*p'*), which is called *glandula socia parotidis*. On trying to raise the deeper part of the parotid gland from its position, it is found to extend far inwards, between the mastoid process and the ramus of the jaw, towards the base of the skull, and to be intimately connected with several deep-seated parts. Thus, above, it reaches into and occupies the posterior part of the glenoid cavity; behind and below, it touches the digastric muscle, and rests

on the styloid process and styloid muscles; and, in front, under cover of the ramus of the jaw, it advances a certain distance between the external and internal pterygoid muscles.

The internal carotid artery and internal jugular vein are close to the deep surface of the gland. The external carotid artery, accompanied by the temporal and internal maxillary veins, passes through the parotid gland, and in that situation divides into the temporal and internal maxillary arteries, the former soon giving off the auricular and transverse facial branches of the temporal. The gland is also traversed by the facial nerve, which divides into branches within its substance, and it is pierced by branches of the great auricular nerve.

The **parotid duct**, named also **Stenson's duct** (d. Stenonianus), appears at the anterior border of the gland, about one finger's breadth below the zygoma, and runs forwards over the masseter muscle, accompanied by the socia parotidis, when that accessory portion of the gland exists, and receiving its ducts. At the anterior border of the masseter, the duct (*d*) turns inwards through the fat of the cheek and pierces the buccinator muscle; and then, after running for a short distance obliquely forwards beneath the mucous membrane, opens upon the inner surface of the cheek, by a small orifice opposite the crown of the second molar tooth of the upper jaw. Its direction across the face may be indicated by a line drawn from the lower margin of the concha of the ear to a point midway between the red margin of the lip and the ala of the nose. The length of the Stenonian duct is about two inches and a half, and its thickness about one line and a half. At the place where it perforates the buccinator, its canal is as large as a crow-quill, but at its orifice it is smaller than in any other part, and will only admit a fine probe.

The vessels of the parotid gland enter and leave it at numerous points. The arteries are derived directly from the external carotid, and from those of its branches which pass through or near the gland. The veins correspond. The lymphatics join the deep and superficial set in the neck; and there are often one or more lymphatic glands embedded in the substance of the parotid. The nerves come from the sympathetic (carotid plexus), and also, it is said, from the facial and the superficial temporal and great auricular nerves.

An instance is recorded by Gruber of a remarkable displacement of the parotid on one side; the whole gland being situated on the masseter muscle as if it were an enlarged socia parotidis. (Virchow's Archiv, xxxii., p. 328.)

#### THE SUBMAXILLARY GLAND.

The submaxillary gland (figs. 236, 237, *sm*), the next in size to the parotid, is of a spheroidal form, and weighs about 2 or 2½ drachms. It is situated immediately below the base and the inner surface of the inferior maxilla, and above the digastric muscle. In this position it is covered by the skin, fascia and platysma myoides, and its inner surface rests on the mylo-hyoid, hyo-glossus, and stylo-glossus muscles; above, it corresponds with a depression on the inner surface of the jaw-bone; and it is separated behind from the parotid gland merely by the stylo-maxillary membrane. The facial artery, before it mounts over the jaw-bone, lies in a deep groove upon the back part and upper border of the gland.

The **duct** of the submaxillary gland, named **Wharton's duct** (*d'*, fig. 237), which is about two inches in length, passes off, together with

a thin process of the glandular substance, round the posterior border of the mylo-hyoid muscle (*mh*), and then runs forwards and inwards above that muscle, between it and the hyo-glossus and genio-hyo-glossus, and beneath the sublingual gland, to reach the side of the frænum linguæ. Here it terminates, close to the duct of the opposite side, by a narrow orifice, which opens at the summit of a soft papilla (*d*) seen beneath the tongue. The obvious structure of this gland is like that of the parotid; but its lobes are larger, its surrounding areolar web is finer, and its attachments are not so firm. Moreover, its duct has much thinner coats than the parotid duct.

The blood-vessels of the submaxillary gland are branches of the facial and lingual arteries and veins. The nerves include those derived from the submaxillary ganglion, and through this, doubtless, from the chorda tympani, as well as branches from the mylo-hyoid division of the inferior dental nerve, and the sympathetic.

#### THE SUBLINGUAL GLAND.

The sublingual gland (fig. 237), the smallest of the salivary glands, is of a narrow oblong shape and weighs scarcely one drachm. It is

Fig. 237.

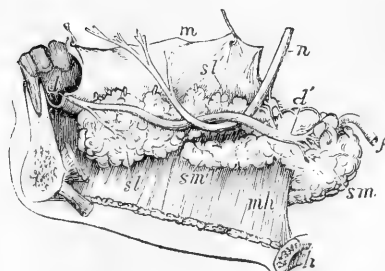


Fig. 237.—VIEW OF THE RIGHT SUBMAXILLARY AND SUBLINGUAL GLANDS FROM THE INSIDE (Allen Thomson).

A part of the right side of the jaw, divided from the left at the symphysis, remains; the tongue and its muscles have been removed; but the mucous membrane of the right side is retained and is drawn upwards so as to expose the sublingual glands; *sm*, the larger superficial part of the submaxillary gland; *f*, the facial artery passing through it; *sm'*, deep portion prolonged on the inner side of the mylo-hyoid muscle *mh*; *sl*, is placed below the anterior large part of the sublingual gland, with the duct of Bartholin partly

shown; *s'*, placed above the hinder small end of the gland, indicates one or two of the ducts perforating the mucous membrane; *d*, the papilla, at which the duct of Wharton opens in front behind the incisor teeth; *d'*, the commencement of the duct; *h*, the hyoid bone; *n*, the gustatory nerve.

situated along the floor of the mouth, where it forms a ridge between the tongue and the gums of the lower jaw, covered only by the mucous membrane. It reaches from the frænum linguæ, in front, where it is in contact with the gland of the opposite side, obliquely backwards and outwards for rather more than an inch and a half. On its inner side it rests on the genio-hyo-glossus; beneath, it is supported by the mylo-hyoid muscle (*mh*), which is interposed between it and the main part of the submaxillary gland; but it is here in close contact with the Whartonian duct, with the accompanying deep portion of the last-named gland, and also with the lingual branch of the fifth pair of nerves.

The lobules of the sublingual gland are not so closely united together as those of the other salivary glands, and the ducts from many of them open separately into the mouth, along the ridge which indicates the position of the gland. These ducts, named **ducts of Rivinus**, are from eight to twenty in number. Some of them open into the duct of

Wharton. One, longer than the rest (which is occasionally derived in part also from the submaxillary gland), runs along the Whartonian duct, and opens either with it or very near it; this has been named the duct of Bartholin.

The blood-vessels of this gland are supplied by the sublingual and submental arteries and veins. The nerves are numerous, and are derived from the lingual branch of the fifth.

#### STRUCTURE OF THE SALIVARY GLANDS.

These glands are constructed on the compound racemose type. Their ducts (traced backwards), after branching a certain number of times, terminate in moderately fine ramuscules, around which the terminal recesses of the gland are grouped, and into which they open. These terminal recesses, saccules, or alveoli (fig. 238 *b*) are lined and almost

Fig. 238.

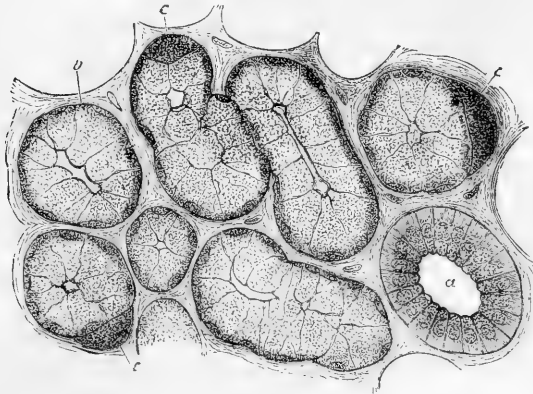


Fig. 238. —SECTION OF THE SUBMAXILLARY GLAND OF THE DOG, STAINED WITH CARMINE. HIGHLY MAGNIFIED (Kölliker).

*a*, cross-section of small salivary duct; *b*, an alveolus containing salivary cells; *c*, semilunar body.

filled by an epithelium, the cells of which (*salivary cells*) are spheroidal in form, with flattened sides where they touch one another, and consist each of granular protoplasm enclosing a nucleus, which, in sections, generally appears flattened up against the base of the cell. This position of the nucleus is, however, produced after death; in the unaltered condition it occupies a more central position in the cell (as shown in fig. 240).

In the submaxillary gland (and also, to a less extent, in the sublingual, but never in the parotid) the salivary-cells for the most part contain mucus, and the swelling up of this by imbibition of water is not improbably the cause of the altered position of the nucleus, as happens in the formation of goblet-cells from columnar epithelium.

When isolated, the salivary cells not unfrequently exhibit processes, one from the base of each cell: according to Kölliker the projection is flattened and overlaps the base of a neighbouring cell. A similar relation of the alveolar cells has also been pointed out in Brunner's glands of the intestine, which belong to the same class as the salivary glands (Schwalbe).

The salivary alveoli are bounded externally by a basement membrane, which, however, appears in some cases to be incomplete, owing to the flattened cells which compose it being branched and stellate instead of epithelioid. Moreover these cells send processes inwards which form a sustentacular network amongst the salivary cells.\*

A delicate intra-alveolar reticulum is described by various observers, enclosing in its meshes the alveolar cells. It is at present uncertain whether the appearance is to be referred to the sustentacular network of cell-processes above mentioned, or to the network of intercellular passages shown in fig. 239, or to an independent cause.

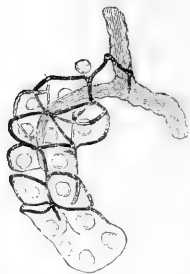
In sections of the submaxillary gland there is to be seen here and there in the alveoli a peculiar half-moon-shaped granular mass, staining deeply with carmine, and lying between the salivary-cells and the enclosing basement membrane (fig. 238, *c*). This body, which was first noticed by Gianuzzi, and has been regarded as of considerable importance, we are inclined to look upon, with Pflüger, as most probably due to a post-mortem change consequent on the presence of mucus within the more central cells—these becoming swollen by imbibition, and compressing the marginal cells, which contain no mucus, against the basement membrane. In accordance with this view it may be stated that the semilunar body is not found in those animals (rabbits) in which the salivary-cells contain no mucus, nor in the glands of other animals (dogs) the cells of which have been caused to discharge their contained mucus by irritation of the nerves proceeding to the gland (Heidenhain).

The smallest ducts of the gland, those into which the alveoli open, are composed only of a basement membrane and a simple layer of flattened epithelium. After a short course the character of the epithelium changes rather abruptly, the cells becoming large and columnar, smaller towards the lumen of the tube, and each containing a roundish nucleus near the centre (fig. 238, *a*). The part of the cell nearest the lumen of the duct is homogeneous or granular in character, whereas the part nearest the basement membrane appears finely striated longitudinally. In the ducts of the parotid gland this striated appearance is said to be absent.

Pflüger states that the striation is due to the presence of excessively fine varicose fibrils, and that these are directly continuous with those forming the axis-cylinders of nerves, which he describes as penetrating the basement membrane.

The free ends of the cells, which project into the lumen, present a mosaic appearance when seen from the surface.

Fig. 239.



The larger ducts acquire a coating of fibrous and elastic tissue outside the basement membrane, and, except in those of the sublingual gland, a few plain muscular fibre-cells are also to be found: the columnar epithelium becomes at the same time gradually shorter and shorter, until in the main ducts it is cubical or even tessellated.

Fig. 239.—AN ALVEOLUS OF A COMPOUND RACEMOSE GLAND, INJECTED FROM THE EXCRETORY DUCT. HIGHLY MAGNIFIED.

Hardly anything but the dark injecting fluid is shown; the alveolar cells and nuclei are only faintly indicated; those of the duct are not represented at all. The injection is seen filling the central cavity of the alveolus, and passing from this in fine channels (represented by black reticulating lines), between and around the cells (after Saviotti).

According to the observations of Pflüger and Ewald, the central cavities of the

\* Boll, Arch. f. mikr. Anat. v.



alveoli communicate with fine passages (salivary capillaries)—like the biliary capillaries to be afterwards described—which pass between and around the salivary-cells. Their statements on this point agree generally with those previously made by Langerhans and Saviotti with reference to the pancreas, a gland of similar structure (see fig. 239.)

The blood-vessels of the salivary glands are numerous, and form a close capillary network outside the basement membrane both of the alveoli and the ducts.

The lymphatics were described by Gianuzzi as commencing in the form of fissures between and around the alveoli, but further investigations are required on this point. The issuing lymphatics accompany the blood-vessels.

The nerves are large and numerous, and many of them exhibit minute ganglia. Some of them have been observed to terminate in Pacinian corpuscles of a simple kind (Krause).

According to Pflüger,\* the basement membrane of the alveoli, as well as of the ducts, is perforated by the nerves, which lose their medullary sheath, and, breaking up into a number of branches, become connected with the protoplasm of the cells, either directly (fig. 240, A) or by the medium of small multipolar ganglion-cells (B). Others he describes as passing into the cell-nuclei. Other observers, however, have hitherto failed to corroborate these statements.

Fig. 240.

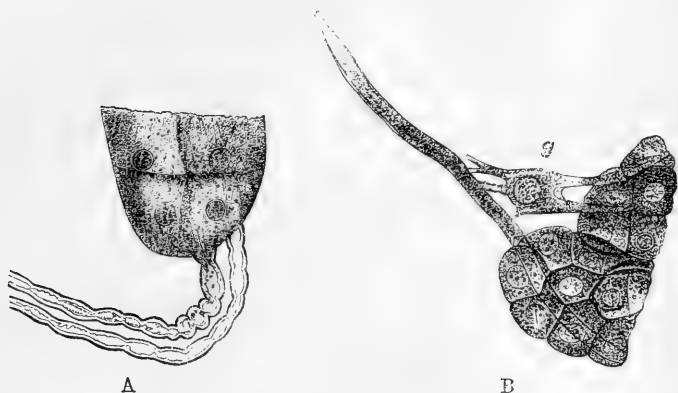


Fig. 240.—ILLUSTRATING PFLÜGER'S VIEWS OF THE TERMINATION OF NERVES IN THE ALVEOLAR CELLS (from Stricker's Handbook).

A, Direct passage of nerve into a salivary cell; B, by the medium of a multipolar ganglion-cell, *g*.

It may be added that Pflüger believes (and in this he is to some extent supported by Heidenhain) that the cells both of the alveoli and of the smaller ducts undergo extensive disintegration during the active state of the gland, and are afterwards renovated.

#### THE PHARYNX.

The pharynx is that part of the alimentary canal which unites the cavities of the mouth and nose to the œsophagus. It extends from the base of the skull to the lower border of the cricoid cartilage, and forms a sac open at the lower end, and imperfect in front, where it presents apertures leading into the nose, mouth and larynx.

The velum pendulum palati projects backwards into the pharynx, and

\* Arch. f. mikr. Anat. V. ; and article, "Salivary Glands," in Stricker's Handbook.

during the passage of the food completely separates an upper from a lower part by means of the contraction of the muscles connected with it which are placed in the posterior pillars of the fauces. Seven openings lead into the cavity of the pharynx; viz., above the velum, the two posterior openings of the nares (*choanae narium*, fig. 241, 1), and at the sides the apertures of the Eustachian tubes (6); while below the velum, there is first the passage leading from the mouth (3); then the superior opening of the larynx (4), and lastly the passage into the œsophagus (5).

The pharynx is about four inches and a half in length, and is considerably wider across than it is deep from before backwards. Its width above is moderate; its widest part is opposite the cornua of the hyoid bone, and below this it rapidly contracts like a funnel towards its termination in the gullet, opposite the cricoid cartilage, where it is narrowest.

Fig. 241.

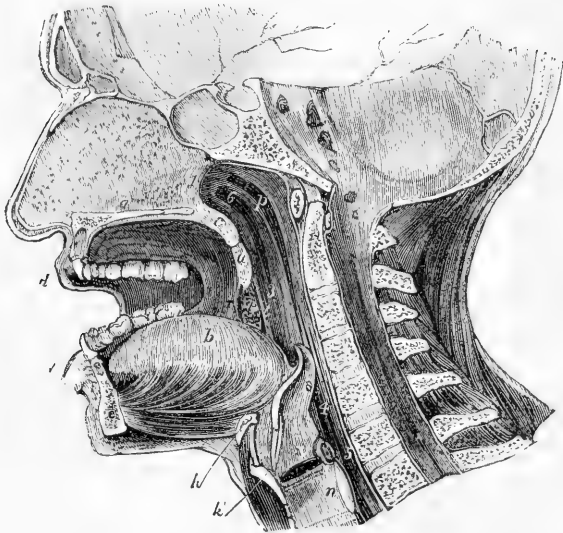


Fig. 241.—ANTERO-POSTERIOR VERTICAL SECTION THROUGH THE HEAD A LITTLE TO THE LEFT OF THE MIDDLE LINE, SHOWING THE RELATIONS OF THE NASAL AND BUCCAL CAVITIES, THE PHARYNX, LARYNX, &c.

*a*, nasal septum, and below it the section of the hard palate; *b*, the tongue; *c*, soft palate; *d*, the lips; *u*, the uvula; *v*, anterior pillar of the fauces; *i*, posterior pillar; *t*, the tonsil placed between the pillars; *p*, upper part of the pharynx; *h*, body of the hyoid bone; *k*, thyroid cartilage; *n*, cricoid cartilage; *v*, on the upper vocal cords above the glottis; *s*, epiglottis; 1, posterior opening of the nares; 3, behind the isthmus faucium; 4, opposite the superior opening of the larynx; 5, passage into the œsophagus; 6, opening of the right Eustachian tube.

**Attachments.**—The walls of the pharynx are formed by a fascia or layer of fibrous tissue, named the pharyngeal aponeurosis, dense at its upper part but lax and weak below, which is surrounded by muscles and lined by a mucous membrane. At its upper end this fibrous wall is attached to the posterior part of the body of the sphenoid bone,

and passes outwards to the petrous portion of the temporal. It is strengthened in the middle line by a strong band descending between the *recti antici* muscles from a part of the basilar process of the occipital bone (which often presents a marked tubercle).

The pharynx is usually described as directly attached superiorly to the basilar process of the occipital bone; it is certain, however, from dissections in both young and old subjects, that the *recti capitis antici* muscles come quite forward to the anterior extremity of the basilar process; that the posterior wall of the pharynx at its upper end forms a cul-de-sac on each side opposite the tip of the petrous bone, and lies in a curve, with its convexity forwards, in front of the *recti* muscles; and that the only connection of the pharynx with the occipital bone is by means of the mesial band, which has just been described, and which forms a cranio-pharyngeal ligament (Cleland). The tubercle from which this band principally springs is sometimes named *tuberculum pharyngeum*.

Behind, the pharynx is loosely connected by areolar tissue to the prevertebral fascia covering the bodies of the cervical vertebrae and the muscles which rest upon them. At the sides it has similar connections with the styloid process and its muscles, and with the large vessels and nerves of the neck. In front, it is attached in succession to the sides of the posterior nares, the mouth and the larynx. Thus, commencing above by a tendinous structure only, at the petrous portion of the temporal bone and the Eustachian tube, the pharynx is connected by means of muscle and fibrous membrane, first, with the internal pterygoid plate, then with the pterygo-maxillary ligament, and next with the mylo-hyoid ridge of the lower jaw; below this, it is attached to the sides of the tongue, to the hyoid bone, and stylo-hyoid ligament; and, still lower down, to the thyroid and cricoid cartilages.

**Structure.**—The *muscles* of the pharynx are the superior, middle and inferior constrictors, the stylo-pharyngeus, and the palato-pharyngeus. They are already described.

The *mucous membrane* is continuous at the several apertures with that of the adjacent cavities. It varies somewhat in its character in different parts. Its upper portion is thick where it adheres to the base of the skull, but much thinner near the entrance of the Eustachian tubes and the posterior nares: in this situation numerous racemose mucous *glands* are found collected in a layer beneath the mucous membrane; lymphoid follicles also exist throughout the whole of the pharynx. A collection of these, forming a glandular mass similar to that forming the tonsils, stretches across the back of the pharyngeal cavity between the orifices of the two Eustachian tubes (Kölliker). In the part opposite the fauces, the mucous membrane exactly resembles that of the mouth. Lower down it becomes paler, and at the back of the larynx it forms several longitudinal folds. According to Henle, the epithelium upon the upper portion of the pharynx, as low down as a horizontal line level with the floor of the nares, is columnar and ciliated; but, below that point, it is squamous and destitute of cilia.

### THE ŒSOPHAGUS.

The *œsophagus* or gullet, the passage leading from the pharynx to the stomach, commences at the cricoid cartilage opposite the lower border of the fifth cervical vertebra (sixth, Braune), and descending along the front of the spine, passes through the diaphragm opposite the

ninth dorsal vertebra, and there ends by opening into the cardiac orifice of the stomach.

**Form and position.**—The length of the œsophagus is about nine or ten inches. It is of smaller diameter than any other division of the alimentary canal, its narrowest part being at the commencement behind the cricoid cartilage; it is also slightly constricted in passing through the diaphragm, but, below that, widens into the stomach. The œsophagus is not quite straight in its direction, but presents three slight curvatures. One of these is an antero-posterior flexure, corresponding with that of the vertebral column in the neck and thorax. The other two are slight lateral curves; for the œsophagus, commencing in the median line, inclines to the left side as it descends to the root of the neck; thence to the fifth dorsal vertebra it gradually resumes the mesial position; and finally, it deviates again to the left, at the same time coming forward towards the œsophageal opening of the diaphragm.

**Connections.**—In the lower cervical and upper dorsal region the œsophagus is applied to the anterior surface of the spine, being connected with it and with the longus colli muscle by loose areolar tissue; between it and the bodies of the upper dorsal vertebræ the thoracic duct ascends obliquely from right to left: its lower third is placed in front of the aorta. In the *neck*, the œsophagus lies close behind the trachea, and the recurrent laryngeal nerve ascends on either side in the angle between them; on each side is the common carotid artery, and also a part of the thyroid body, but, as the œsophagus inclines to the left side, it is in more immediate connection with the left carotid. In the *thorax*, the œsophagus is successively covered in front by the lower part of the trachea, by the commencement of the left bronchus, and by the back of the pericardium. The aorta, except near the diaphragm, where the œsophagus is in front of the vessel, lies rather to the left, and the vena azygos to the right; the pneumogastric nerves descend in close contact with its sides, and form a plexus around it, the left nerve proceeding gradually to the front, and the right nerve retiring behind it. Lastly, the œsophagus, which is here placed in the interval between the two pleuræ, comes partially in contact with both of these membranes.

**Structure.**—The walls of the gullet are composed of three coats; viz., an external or muscular, a middle or areolar, and an internal or mucous coat. Outside the muscular coat there is a layer of areolar tissue, with well marked elastic fibres, which is sometimes spoken of as a distinct coat.

The **muscular coat** consists of an *external* longitudinal layer (seen in section in fig. 242, *b*) and an *internal* circular layer (*c*). This twofold arrangement of the muscular fibres prevails throughout the whole length of the alimentary canal; but the two layers are here much thicker, more uniformly disposed, and more evident than in any other part except quite at the lower end of the intestine. The external or *longitudinal* fibres are disposed at the commencement of the tube in three fasciculi, one in front, and one on each side. The lateral fasciculi are blended above with the inferior constrictor of the pharynx; the anterior fasciculus arises from the back of the cricoid cartilage at the prominent ridge between the posterior crico-arytenoid muscles, and its fibres spreading out on each side of the gullet as they descend, soon blend

with those of the lateral bundles to form a continuous layer around the tube. The internal or *circular* fibres are separated above by the fibres of the lateral longitudinal fasciculi from those of the inferior constrictor of the pharynx. The rings which they form around the tube have a horizontal direction at the upper and lower part of the œsophagus, but in the intervening space are slightly oblique. At the lower end of the œsophagus, both layers of fibres become continuous with those of the stomach.

The muscular coat of the upper end of the œsophagus is of a well-marked red colour, and consists wholly of striped muscular fibres; but lower down, where it becomes somewhat paler, these are gradually replaced by plain muscular fibres, which form almost the whole of the lower half. A few striped fibres, however, are found mixed with the others throughout its whole length, and even, it is said, on the cardiac end of the stomach (Ficinus).

The longitudinal fibres of the œsophagus are observed by Hyrtl to be sometimes joined by a broad band of smooth muscle, passing upwards from the left pleura, and sometimes also by another from the left bronchus.

The **areolar** or **submucous** coat is placed between the muscular and mucous coats, and connects them loosely together. It exceeds the mucous membrane considerably in thickness, and in it are contained the glands (fig. 242), which open on the mucous membrane.

The **mucous membrane** is of firm texture, and is paler in colour than that of the pharynx or stomach. From its loose connections its outer surface is freely movable on the muscular tunic; and when the latter is contracted, as happens when the œsophagus is not giving passage to food, the mucous lining is thrown into longitudinal folds, which are in mutual contact. These folds disappear again on distension of the canal.

Minute papillæ (*f*) are seen upon the mucous membrane, and the whole is covered with a thick stratified scaly epithelium, which can be traced as far as the cardiac orifice of the stomach, where it suddenly passes into one of a different character, as will be hereafter noticed.

The small compound racemose glands, named *œsophageal glands*, which are for the most part situate as before stated in the submucous

Fig. 242.

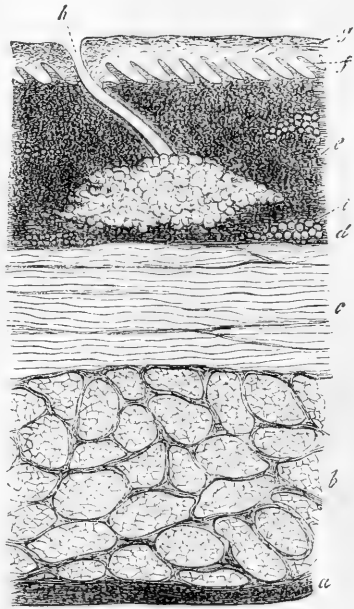


Fig. 242.—SECTION OF THE COATS OF THE HUMAN ŒSOPHAGUS, 50 DIAMETERS Kölliker).

The section is transverse, and from near the middle of the gullet. *a*, fibrous covering; *b*, divided fibres of the longitudinal muscular coat; *c*, transverse muscular fibres; *d*, submucous or areolar layer; *f*, papillæ of mucous membrane; *g*, laminated epithelial lining; *h*, opening of a mucous gland, of which the saccular part is seen imbedded in the submucous tissue; *i*, fat vesicles.

tissue, are especially numerous at the lower end of the tube. A few of the smallest which are found in the immediate neighbourhood of the opening into the stomach are situate almost wholly in the substance of the mucous membrane.

Next to the submucous coat the mucous membrane is bounded by longitudinally disposed plain muscular fibres which, imperfect above, form a continuous layer towards the lower end of the tube (*muscularis mucosæ*).

Duplicity of the œsophagus in part of its extent, without other abnormality, has been recorded (Blaes, quoted by Meckel).

The *blood-vessels* of the œsophagus have for the most part a longitudinal arrangement; *lymphatics* are found in both the submucous and mucous coats, a certain amount of lymphoid tissue also being present in the latter. The *nerves* form a gangliated plexus between the two layers of the muscular coat, as in other parts of the alimentary canal.

## THE ABDOMINAL VISCERA.

As that part of the digestive canal which is found beneath the diaphragm, and consists of the stomach and intestines, is situated within the cavity of the *abdomen*, and occupies, together with the liver (the secretion of which it receives), by far the greater part of that cavity, the general topographic relations of the abdominal viscera may here be briefly explained.

### THE ABDOMEN.

The abdomen is the largest cavity in the body, and is lined by an extensive and complicated serous membrane, named the peritoneum.

It extends from the diaphragm above to the levatores ani muscles below, and is subdivided into two parts: an upper and larger part, the *abdomen*, properly so called; and a lower part, named the *pelvic cavity*. The limits between the abdominal and pelvic portions of the cavity are marked by the brim of the pelvis.

The enclosing walls of this cavity are formed principally of muscles and tendons which have been already described. They are strengthened internally by a layer of fibrous tissue lying between the muscles and the peritoneum, the different parts of which are described under the names of fascia transversalis, fascia iliaca, and anterior lumbar fascia. These walls are pierced by several apertures, through which are transmitted the great vessels and some other parts, such as the several diaphragmatic apertures for the aorta, vena cava, and œsophagus, and the femoral arches and inguinal canals. In the median fibrous substance of the anterior wall lies the umbilical cicatrix. The cavity of the pelvis is also lined with strong fasciæ, and partially by peritoneum, and at its lower part are the apertures for the transmission of the rectum and the genito-urinary passages.

**Regions.**—For the purpose of enabling reference to be made to the situation and condition of the contained organs, the *abdomen proper* has been artificially subdivided into certain regions, the boundaries of which are indicated by lines drawn upon the surface of the body (fig. 243). Thus, two horizontal lines drawn round the body divide the

cavity into three zones; viz. an upper, a middle, and a lower. One of these lines commences at the level of the most prominent point of the ninth costal cartilages, the other line, opposite the crest of the ilium. Each of these zones again is subdivided into three parts by means of two perpendicular lines, drawn from the cartilage of the eighth rib, on each side, down to the middle of Poupart's ligament.

The upper zone is thus marked off into the right and left *hypochondriac* regions (fig. 243, 4, 4) and the *epigastric* region (1), the depression in the upper part of which is called *scrobiculus cordis*, or pit of the stomach. The middle zone is divided into the *umbilical* region (2) in the middle, and the right and left *lumbar* regions (5, 5); and the inferior zone into the *hypogastric* region (3) in the middle, and the *iliac* region (6, 6) at each side.

On opening the abdominal cavity from the front, the transverse colon is seen passing from right to left and separating the viscera into an upper and lower group. In the upper group are comprised the liver, stomach, spleen, and the commencing part of the small intestine; in the lower, more or less hidden by the great omentum, are the remaining parts of the small intestine, surrounded by the great intestine and dipping into the pelvis, where they come into relation with the rectum and bladder, and in the female also with the uterus. Lying more posteriorly, and hidden by the intestines, are the pancreas and kidneys.

The surfaces of the viscera which are in contact one with another, and with the wall of the cavity are rendered glistening by a coating derived from the lining membrane of the cavity, the *peritoneum*; and the various organs are found to be attached by means of folds or duplicatures of that membrane, termed *mesenteries* and *omenta*, which include the blood-vessels, nerves, and lymphatics belonging to each organ.

Subjoined is an enumeration of the viscera situated in the different regions of the abdomen.

- |                            |   |                                                                                                                                                                                 |
|----------------------------|---|---------------------------------------------------------------------------------------------------------------------------------------------------------------------------------|
| Epigastric region . . .    | { | The right part of the stomach, the pancreas, and part of the liver.                                                                                                             |
| Hypochondriac, right . . . | { | The right lobe of the liver, with the gall-bladder, part of the duodenum, the hepatic flexure of the colon, part of the right kidney with the corresponding suprarenal capsule. |

Fig. 243.

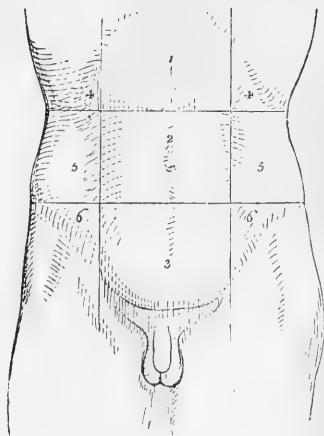


Fig. 243.—OUTLINE OF THE ANTERIOR SURFACE OF THE ABDOMEN, SHOWING THE DIVISION INTO REGIONS.

1, epigastric region; 2, umbilical; 3, hypogastric; 4, 4, right and left hypochondriac; 5, 5, right and left lumbar; 6, 6, right and left iliac.

|                               |                                                                                                                                                                                                                                                      |
|-------------------------------|------------------------------------------------------------------------------------------------------------------------------------------------------------------------------------------------------------------------------------------------------|
| Hypochondriac, left . . . . . | } The large end of the stomach, with the spleen and narrow extremity of the pancreas, the splenic flexure of the colon, and the upper part of the left kidney with the left suprarenal capsule. Sometimes also a part of the left lobe of the liver. |
| Umbilical . . . . .           |                                                                                                                                                                                                                                                      |
| Lumbar, right . . . . .       |                                                                                                                                                                                                                                                      |
| Lumbar, left . . . . .        |                                                                                                                                                                                                                                                      |
| Hypogastric . . . . .         |                                                                                                                                                                                                                                                      |
| Iliac, right . . . . .        |                                                                                                                                                                                                                                                      |
| Iliac, left . . . . .         |                                                                                                                                                                                                                                                      |

## THE PERITONEUM.

The **peritoneum** or serous membrane of the abdominal cavity is by far the most extensive and complicated of the serous membranes. Like the others it may be considered to form a shut sac, on the outside of which are placed the viscera which it covers. In the female, however, the two Fallopian tubes open at their free extremities into the cavity of the peritoneum. The internal surface is free, smooth, and moist. The external or attached surface adheres partly to the parietes of the abdomen and pelvis, and partly to the outer surface of the viscera situated within them. The *parietal* portion is connected with the fascia lining the abdomen and pelvis by means of a layer of areolar tissue, distinct from the abdominal fasciæ, and named the *subperitoneal* layer; it is more firmly adherent along the middle line of the body in front, as well as to the under surface of the diaphragm. The *visceral* portion, which is thinner than the other, affords a more or less complete covering to most of the abdominal and pelvic organs.

The *folds* of the peritoneum are of various kinds. Some of them, constituting the *mesenteries*, connect certain portions of the intestinal canal with the posterior wall of the abdomen; they are, the mesentery properly so called for the jejunum and ileum, the meso-cæcum, transverse and sigmoid meso-colon, and the meso-rectum. Other duplicatures exist, which are called *omenta*; they are the great omentum or epiploön, the small omentum, and the gastro-splenic omentum. Lastly, certain reflexions of the peritoneum from the walls of the abdomen or pelvis to viscera which are not portions of the intestinal canal, are named *ligaments*: such are the ligaments of the liver, spleen, uterus, and bladder.

These folds or ligaments will be specially described with the viscera with which they are connected.

Like other serous membranes the peritoneum is continuous throughout its whole extent, and its continuity may be traced from any one point to any other near or distant; but the description of this will be most readily understood after an account has been given of the several viscera to which the membrane is related.



## THE STOMACH.

The œsophagus, as already said, terminates in the stomach, from which the intestine leads off.

This organ is seated in the left hypochondriac and the epigastric regions, extending somewhat into the right hypochondrium. It lies in part against the anterior wall of the abdomen, and in part beneath the liver and diaphragm, and above the transverse colon.

In *shape* it is somewhat conical or pyriform. The left extremity (fig. 244, *c*), is the larger, and is named the cardiac, *great* or *splenic* end. The *right* or *small* end is also named the *pyloric* extremity. Of its two orifices, the one by which food enters from the œsophagus is named the *cardiac* orifice (*o*), the other, by which it passes into the duodenum, and which is placed on a somewhat lower level, and more forwards, is the *pyloric* orifice (*p*).

The cardiac orifice is two or three inches from the great extremity, which projects to the left, forming the *great cul-de-sac* or *fundus*.

Between the cardiac and the pyloric orifices, the outline of the stomach is curved along its upper and lower borders. The upper border, about three or four inches in length, is concave, and is named the *lesser curvature* (*b*); while the lower border, which is much longer, and, except towards the pylorus, convex, forms the *greater curvature* (*a*).

Towards the pylorus, the small end of the stomach describes a double bend, opposite to the first turn of which is a prominence or bulging, sometimes named the *small cul-de-sac* or *antrum pylori* (*d*).

**Dimensions.**—These vary greatly in different subjects, and also according to the state of distension of the organ. When moderately filled, its length is about ten or twelve inches; and its diameter at the widest part, from four to five inches. It weighs, when freed from other parts, about four ounces and a half in the male, and somewhat less in the female (Clendinning).

**Connections.**—The borders of the stomach are connected with folds of peritoneum in their whole extent. Thus, the superior border is connected with the under surface of the liver by a duplicature of peritoneum, the gastro-hepatic or lesser omentum, and at the left of the cardia between it and the diaphragm is a small fold termed the gastro-phrenic ligament; to the inferior border is attached the great omentum, beneath which is the transverse arch of the colon, while at the left extremity it is connected with the spleen by a duplicature of peritoneum, continuous with the left border of the great omentum, and named the gastro-splenic ligament. The blood-vessels and lym-

Fig. 244.

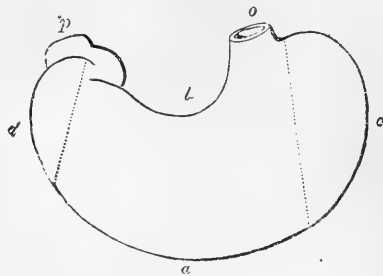


Fig. 244.—DIAGRAMMATIC OUTLINE OF THE STOMACH.

*a*, great curvature; *b*, lesser curvature; *c*, left end, great cul-de-sac, or fundus; *d*, small cul-de-sac, or antrum pylori; *o*, œsophageal orifice or cardia; *p*, duodenal orifice or pylorus.

phatics of the stomach pass within these duplicatures of the membrane, and reach the organ along its two curvatures. Its anterior and posterior surfaces are free, smooth, and covered with peritoneum. The anterior surface, which is directed upwards as well as forwards, is in contact above with the diaphragm and the under surface of the liver, and lower down with the abdominal parietes opposite the epigastric region, which is hence named the *pit of the stomach*. The posterior surface is turned downwards and backwards, and rests upon the transverse meso-colon, behind which are the pancreas and great vessels of the abdomen.

At its cardiac orifice it is continuous with the gullet, and is there fixed by a reflection of peritoneum to the œsophageal opening in the diaphragm. The pyloric extremity, situated lower down, nearer to the surface, and having greater freedom of motion, is continuous with the duodenum, is covered by the concave surface of the liver, and in some cases touches the neck of the gall-bladder.

When the stomach is distended, its position and direction are changed. The great curvature is elevated and at the same time carried forwards, whilst the anterior surface is turned upwards, and the posterior surface downwards.

#### STRUCTURE.

The stomach has four coats, named, in order from without inwards, the serous, muscular, areolar or submucous, and mucous coats (fig. 245). Taking all the coats together, they are thinner than those of the œsophagus, but rather thicker than those of the intestines generally. They are thickest at the pyloric end, and thinnest in the great cul-de-sac.

Fig. 245.

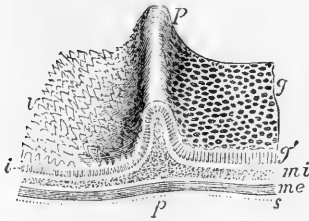


Fig. 245.—DIAGRAMMATIC VIEW IN PERSPECTIVE OF A PORTION OF THE COATS OF THE STOMACH AND DUODENUM, INCLUDING THE PYLORUS (Allen Thomson).

*g*, the inner surface of the gastric mucous membrane; *g'*, section of the mucous membrane with the pyloric gastric glands; *r*, the villous surface of the mucous membrane of the duodenum; *i*, section of the same with the intestinal glands or crypts of Lieberkühn; *p p*, the ridge of the pyloric ring, with a section of its component parts; *m i*, deep or circular layer of muscular fibres: these are seen in the section to form the pyloric sphincter; *m e*, external or longitudinal layer of muscular fibres; *s*, the serous covering.

The **external or serous coat** (*s*), derived from the peritoneum, is a thin, smooth, transparent, and elastic membrane which closely covers the entire viscus, excepting along its two curvatures. Along the line of these curvatures the attachment is looser, leaving an interval occupied by the larger blood-vessels.

The second or **muscular coat**, is composed of plain muscular tissue, forming three sets of fibres, disposed in layers, and named, from their direction, the longitudinal, the circular, and the oblique fibres.

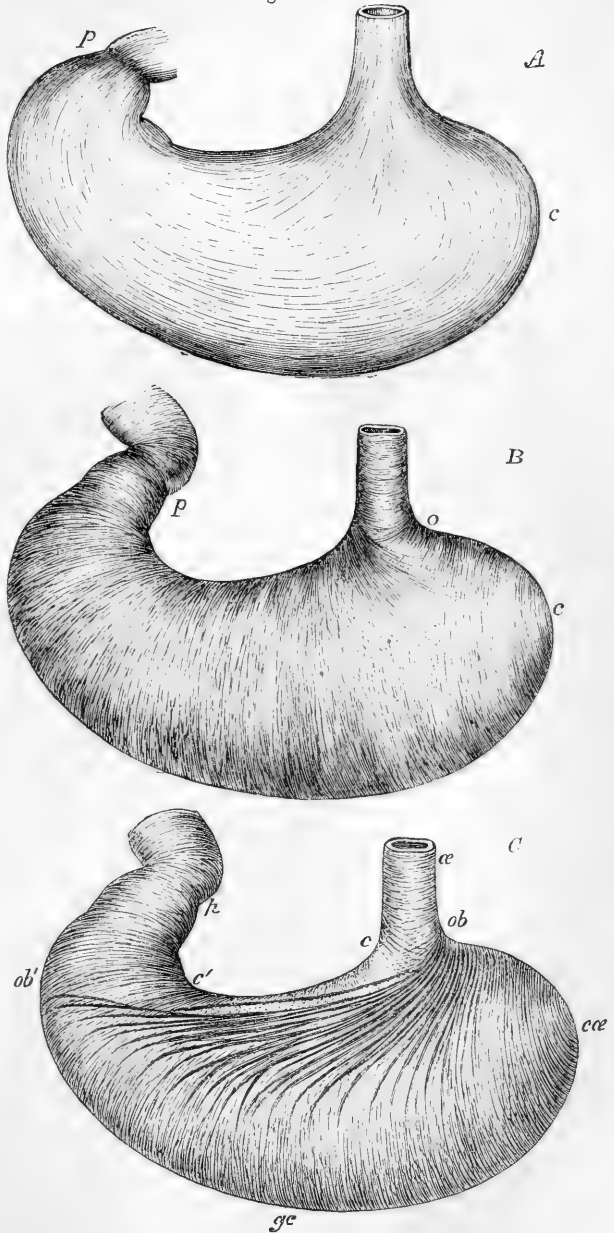
The first or outermost layer consists of the *longitudinal* fibres (fig. 245, *me*, fig. 246,  $\Delta$ ), which are in direct continuity with those of the œsophagus. They spread out in a radiating manner from the cardiac orifice, and are found in greatest abundance along the curvatures, espe-

cially the lesser one. On the anterior and posterior surfaces they are very thinly scattered, or scarcely to be found, but towards the pylorus

Fig. 246.

Fig. 246.—SKETCH OF THE DISTRIBUTION OF MUSCULAR FIBRES IN THE STOMACH (Allen Thomson). ONE-THIRD THE NATURAL SIZE.

A, external layer of longitudinal fibres, as seen from the outside; B, middle layer of circular fibres as seen on removing the longitudinal layer; C, oblique fibres exposed by removing some of the fibres of the circular layer, the cut edges of which are seen below the lesser curvature; *c*, the cardiac end; *p*, the pyloric end; in *A*, the stronger longitudinal fibres passing along the lesser and greater curvatures, and all round the pyloric end, are shown, and the radiating fibres spreading from the end of the gullet over the front (and back) of the stomach; in *B*, the nearly uniform layer of circular fibres, in two sets crossing each other very obliquely at *o*, and at the cardiac end becoming concentric to the centre of the great cul-de-sac; in *C*, the oblique fibres, *ob*, *ob'*, which form a continuation of the circular fibres of the gullet (*æ*) and spread from the left side of the cardia, gradually merging into the deeper circular fibres with which, towards *cæ*, they entirely blend.



are well marked and form a thick uniform layer, which, passing over

the pylorus, becomes continuous with the longitudinal fibres of the duodenum.

The second set consists of the *circular* fibres (fig. 245, *mi*, fig. 246, *B*), which form a complete layer over the whole extent of the stomach. They commence by small and thinly scattered rings at the left extremity of the great cul-de-sac, describe larger and larger circles as they surround the body of the stomach concentric to its curved axis, and towards the pyloric end again form smaller rings, and at the same time become much thicker and stronger than at any other point. At the pylorus itself, they are gathered into an annular bundle (fig. 245 in section), which projects inwards into the cavity, and forms, within the annular fold of mucous membrane, the pyloric sphincter. Some of the circular fibres appear to be continued from those of the œsophagus, spreading from its right side.

The innermost muscular layer is incomplete, and consists of the *oblique* fibres (fig. 246, *C*). These are continuous with the circular fibres of the gullet; they embrace the cardiac orifice on the left, where they form a considerable stratum and from that point descend obliquely upon the anterior and posterior surfaces of the stomach, where they spread out from one another, and taking the direction of the circular fibres, gradually disappear. A similar set of fibres are noticed by Henle, and more fully described by Pettigrew as proceeding from the right side of the cardia and spreading over the front and back of the great cul-de-sac: these are in part continuous with the circular layer. The oblique fibres are best seen from the inside of the stomach, after removing the mucous membrane.

The **areolar** or **submucous coat** of the stomach is a distinct layer placed between the muscular and mucous coats, and connected with both: it consists essentially of areolar tissue, in which occasional fat-cells may be found; and it is the seat of division and passage of the blood-vessels.

The **internal** or **mucous coat** is a smooth, soft, rather thick and pulpy membrane, which has generally a somewhat pink hue owing to the blood in its capillary vessels, but after it has been well washed, is of a greyish white or pale straw colour. In some cases, however, it presents this pale aspect without any previous washing. In infancy the vascular redness is more marked, the surface having then a rosy hue; but it becomes paler in childhood, and in aged persons is often of an ash-grey colour. During digestion its vessels become congested, and when examined in that condition it is always of a much brighter pink than at other times.

After death a few hours often suffice to change its colour to a dirty brown tint, mottled and streaked in some cases with dull red lines, corresponding with the course of the veins. This alteration is owing to the exudation of the colouring matter of the blood, and is especially met with in old subjects, in whom the mucous membrane is always thin. In acute inflammation, or after the introduction of irritating substances or of strong acrid poisons, it becomes of a bright red, either all over or in spots, patches or streaks of variable sizes. Corrosive poisons, the gastric juice, and sometimes regurgitating bile, may stain it variously, black, brown, yellow, or green. As was pointed out by Yelloly, in cases of obstructed venous circulation, as when death occurs from hanging or from drowning, and from certain diseases of the heart, the surface of the stomach is reddened; but the amount of vascularity may vary also from circumstances which are not well understood.

The mucous membrane is thickest in the pyloric region, and thinnest in the great cul-de-sac. It always becomes thinner in old age.

It is connected with the muscular coat by means of the intervening submucous layer so loosely as to allow of considerable movement or displacement. In consequence of this, and of the want of elasticity of the mucous membrane, the internal surface of the stomach, when that organ is in a contracted state, is thrown into numerous convoluted ridges, *rugæ*, which are produced by the wrinkling of the mucous, together with the areolar coat, and are entirely obliterated by distension of the stomach. These folds are most evident along the greater curvature, and have a general longitudinal direction.

On examining the gastric mucous membrane closely with the aid of a simple lens, it is seen to be marked throughout, but more plainly towards the pyloric extremity, with small depressions named *alveoli*,\* which have a polygonal figure, and vary from about  $\frac{1}{200}$ th to  $\frac{1}{100}$ th of an inch across, being larger and more oblong near the pylorus.

Towards the pyloric region of the stomach the margins of these alveoli are elevated into pointed processes or fringes, which may be compared to rudimentary villi, the perfect forms of those appendages existing only in the small intestine, and making their appearance in the duodenum, immediately beyond the pylorus.

The thick stratified epithelium of the œsophagus passes abruptly at the cardia into a simple layer of columnar epithelium, which completely covers the inner surface of the stomach, and extends to a variable distance into the mouths of the gastric glands. It agrees essentially with the similar epithelium which covers the intestine, and which will be afterwards more particularly described.

As first shown by Sprott Boyd, the alveoli are dotted all over with small round apertures, which are the mouths of minute tubular glands (*gastric glands*), placed perpendicularly to the surface, closed at their deep extremity, which extends almost to the submucous areolar tissue, and opening at the other end on the inner surface of the stomach. On making a vertical section of the membrane, and submitting it to microscopic examination, it is seen to consist almost entirely of these small *tubuli*, arranged close to and parallel with each other (fig. 247, *a*). Their diameter varies from  $\frac{1}{500}$ th to  $\frac{1}{300}$ th of an inch, and their length from  $\frac{1}{60}$ th to  $\frac{1}{20}$ th of an inch. At the cardiac end of the stomach, where the membrane is thinnest, they are shorter, and are for the most part simply tubular; but, in approaching the pyloric portion, they gradually become longer and assume a more complicated

Fig. 247.

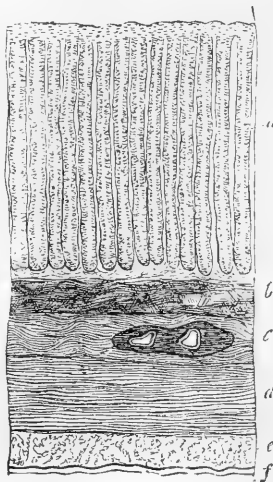


Fig. 247.—VERTICAL TRANSVERSE SECTION OF THE COATS OF A PIG'S STOMACH. 30 DIAMETERS (from Kölliker).

*a*, gastric glands; *b*, muscular layer of the mucous membrane; *c*, submucous or areolar coat; *d*, circular muscular layer; *e*, longitudinal muscular layer; *f*, serous coat.

\* The alveoli were termed "stomach-cells" by Boyd.

form, for, though simple near their orifices, they may, towards their deep or closed extremity, be cleft into two or three, or even eventually into six or eight branches (figs. 248 and 249). The glands have externally a basement membrane, composed of flattened cells joined edge to edge, and with processes which on the one side join the retiform tissue of the mucous membrane, and on the other side, more delicate, extend in amongst and support the enclosed epithelium cells.\*

Fig. 248.

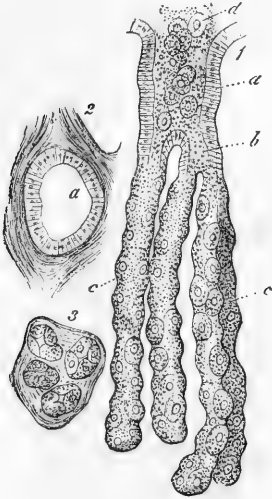


Fig. 248. — PEPTIC GASTRIC GLANDS FROM THE DOG'S STOMACH, MAGNIFIED (from Frey).

1, longitudinal view; *a*, mouth of the gland; *b*, one of the first tubular divisions of the gland; *c*, the single tubes partly occupied by the peptic cells; *d*, some of the cells pressed out; 2, cross section near the mouth, showing the epithelial lining; 3, cross section of the simple tubes, near the neck of the gland.

occupied, except a small channel left along the middle, by finely granular, polyhedral or angular cells, which, from their position, may be termed the "central" cells of the gland (*h*). According to Heidenhain, these extend up into the neck of the gland, and become continuous with the columnar epithelium there.

It is only quite recently that attention has been more especially drawn to these central cells (Heidenhain, Rollett). From the changes which they appear to undergo during the functional activity of the stomach, Heidenhain was led to infer that it is these cells, and not those ordinarily known as peptic cells, which are concerned in the secretion of pepsin, hence he named them the principal cells

\* These sustentacular processes are much more developed in the gastric glands of some animals (porpoise, pig) than in those of the human stomach (F. E. Schultze, Heidenhain).

Two kinds of glands are distinguished, which differ from one another both in the character of the enclosed cells, and, it is believed, in the nature of their secretion. Those of the one kind (fig. 249, *m*), which are simpler in structure and fewer in number than the others, and are found most numerous in the pyloric region, are lined throughout by an epithelium which is continuous with and in many respects similar to the columnar epithelium which covers the general surface of the stomach between the mouths of the glands. In the deeper parts, however, of these *pyloric glands*—or *mucous glands* as they have been termed from the supposed nature of their secretion—the lining cells become shorter and more cubical, and according to Ebstein approach in character to the "central" cells of the other glands. These, which are commonly known as *peptic glands*, are lined to a variable depth by the columnar epithelium cells (fig. 248, *a*), which are then (at the neck of the gland) succeeded by large spheroidal or ovoidal coarsely granular cells, which have long been known as "peptic" cells (fig. 248, *c*; fig. 249, *p*, 1). Towards the bottom (or *fundus*) of the gland, however, the peptic cells do not form a regular lining, but are found only here and there (fig. 249, *p*, *p*, 2) producing generally an outward bulging of the basement membrane where they occur; the rest of the tube is here occu-

(Hauptzellen) of the gland. The columnar epithelium cells of the mouths of the glands, as well as of the general surface, contain and secrete mucus, and are hence very readily transformed into goblet-cells after death. In some animals, the dog, for example, it is found that the pyloric part possesses only the so-called mucous glands; the cardiac part only peptic, the two kinds passing, however, gradually the one into the other. In the human subject, however, the two kinds of glands are less distinctly separated.

Between and at the base of the glands the mucous membrane consists of a delicate connective tissue with retiform or lymphoid tissue in small amount.

The stomachs of young persons, to all appearance healthy, sometimes present a mammillated aspect, due to little elevations of the surface, which are produced by local accumulations of lymphoid tissue, and somewhat resemble the solitary follicles of the intestine in appearance. The lymphoid accumulations in question are, however, situated amongst the glands near the surface of the stomach, and do not extend into the submucous tissue; moreover they are not distinctly circumscribed, but fade off into the surrounding retiform tissue.

A thin layer of plain muscular tissue (*muscularis mucosæ*) bounds the mucous membrane externally, separating it from the submucous tissue (fig. 247, *b*). It commonly consists of more than one stratum (an outer longitudinal and an inner circular), and is better marked in some animals than in man. Offsets pass from it between the gastric glands towards the surface of the mucous membrane.

**Vessels and Nerves.**—The stomach is a highly vascular organ. Its arterial branches, derived from all three divisions of the cœliac axis, reach the stomach between the folds of the peritoneum, and form, by anastomosing together, two principal arterial arches, which are placed along its two curvatures. After

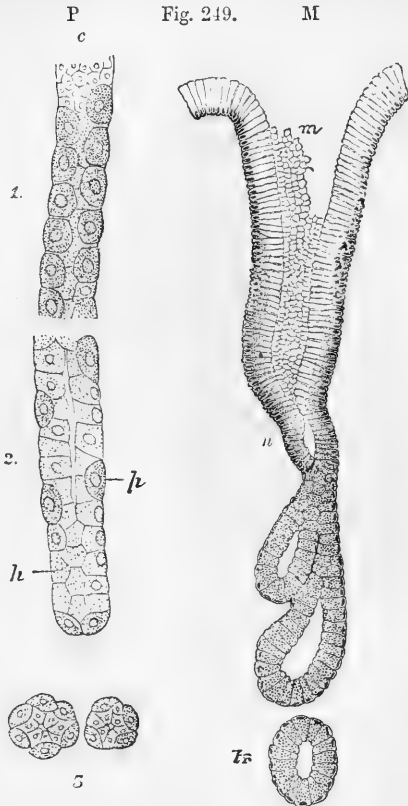


Fig. 249.—GASTRIC GLANDS FROM THE DOG'S STOMACH, HIGHLY MAGNIFIED.

P. PORTIONS OF A "PEPTIC" GLAND.

1, neck of the gland; 2, fundus; 3, transverse section; *p*, peptic cells (Belegzellen); *h*, central cells (Hauptzellen); *c*, ends of columnar cells (after Heidenhain).

M. A PYLORIC OR MUCOUS GLAND.

*m*, mouth; *n*, neck; *tr*, a deep portion cut transversely (after Ebstein).

ramifying between the several coats and supplying them with blood (especially giving off numerous capillaries to the muscular coat) and after dividing into very small vessels in the submucous areolar tunic, the ultimate arterial branches (fig. 250, *a*) enter the mucous membrane, and ramifying freely, pass to its surface

Fig. 250.

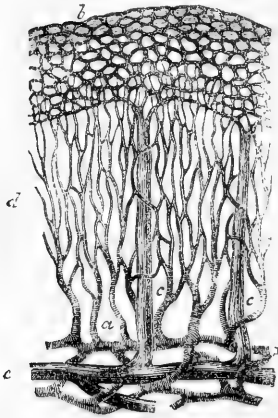


Fig. 250. — PLAN OF BLOOD-VESSELS OF STOMACH (from Brinton).

*a*, small arteries passing up from submucosa to break up into the fine capillary network, *d*, between the glands; *b*, coarser capillary network around the mouths of the glands; *c*, *e*, veins passing vertically downwards from the superficial network to join into larger trunks; *e*, in the submucosa. (The arteries in the submucous coat do not anastomose so freely as here represented.)

this network pierce the muscular coats, then follow the direction of the blood-vessels beneath the peritoneal investment, and traverse lymphatic glands found along the two curvatures of the stomach.

The *nerves*, which are large, consist of the terminal branches of the two pneumo-gastric nerves, belonging to the cerebro-spinal system, and of offsets from the sympathetic system, derived from the solar plexus. The left pneumo-gastric nerve descends on the front, and the right upon the back of the stomach. Numerous small ganglia have been found by Remak and others on both the pneumo-gastric and sympathetic twigs. The nerves form gangliated plexuses both between the layers of the muscular coat and in the submucous coat. Their ultimate ending has not been traced.

**The pylorus.**—While there is no special apparatus at the cardiac orifice of the stomach for closing the passage from the oesophagus, the opening at the pyloric end, leading from the stomach into the duodenum, is provided with a sphincter muscle. On looking into the

\* Om lymfvägarna i magsäckens slemhinna. Nord. Med. Arkiv, 1873. See also H Watney, in Centr. f. d. Med. Wiss. 48, 1874.



pyloric end of the stomach, the mucous membrane is seen projecting in the form of a circular fold, called the *pylorus*, leaving a correspondingly narrow opening (fig. 266, *p*). Within this fold are circular muscular fibres, belonging to the general system of circular fibres of the alimentary canal, which are here collected in the form of a strong band, whilst the longitudinal muscular fibres and the peritoneal coat pass over the pyloric fold to the duodenum, and do not enter into its formation (fig. 253). Externally the pylorus may be easily felt, like a thickened ring, at the right end of the stomach, where also a slight external constriction is visible. Internally its opening is usually circular and less than half an inch across, so that it is the narrowest part of the whole alimentary canal.

Occasionally the orifice is oval, and it is often placed a little to one side. Sometimes the circular rim is imperfect, and there are found instead two crescentic folds, placed one above and the other below the passage (Huschke); and, lastly, there is occasion- ally but one such crescentic fold.

FIG. 251.




Fig. 251.—LYMPHATICS OF THE HUMAN GASTRIC MUCOUS MEMBRANE, INJECTED (from Löwén).

The tubules are only faintly indicated; *a*, muscularis mucosæ; *b*, plexus of fine vessels at base of glands; *c*, plexus of larger, valved lymphatics in submucosa.

## THE SMALL INTESTINE.

The **small intestine** (fig. 252, *D, J, I*) commences at the pylorus, and after many convolutions terminates in the large intestine. It measures on an average about twenty feet in length in the adult, and gradually becomes slightly narrower from its upper to its lower end. Its convolutions occupy the middle and lower part of the abdomen, and are surrounded by the large intestine. They are connected with the back of the abdominal cavity, and are held in their position by a fold of the peritoneum, named the mesentery, and by numerous blood-vessels and nerves.

The small intestine is arbitrarily divided into three portions, which have received different names; the first ten or twelve inches immediately succeeding to the stomach, and comprehending the widest and most fixed part of the tube, being called the *duodenum*, the upper two-fifths of the remainder being named the *jejunum*, and the lower three-fifths the *ileum*. There are no distinct lines of demarcation between these three parts, but there are certain peculiarities of connection and certain differences of internal structure to be observed in

comparing the upper and lower ends of the entire tube, which will be pointed out after it has been described as a whole.

Fig. 252.

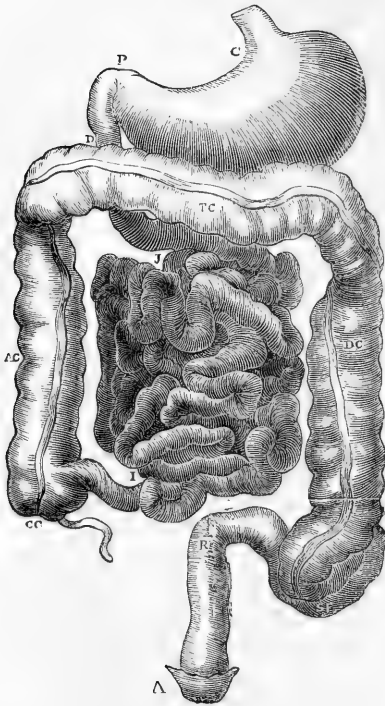


Fig. 252.—DIAGRAM OF THE ABDOMINAL PART OF THE ALIMENTARY CANAL (Brinton).

c, the cardiac, and p, the pyloric end of the stomach; d, the duodenum; j, i, convolutions of the small intestine; cc, caecum, with the vermiform process; ac, ascending, tc, transverse, and dc, descending colon; sf, sigmoid flexure; r, rectum; a, anus.

#### STRUCTURE OF THE SMALL INTESTINE.

The small intestine, like the stomach, is composed of four coats, viz., the serous or peritoneal, muscular, areolar, and mucous.

The external or **serous coat** almost entirely surrounds the intestinal tube in the whole extent of the jejunum and ileum, leaving only a narrow interval behind, where it passes off and becomes continuous with the two layers of the mesentery. The line at which this takes place is named the *attached* or *mesenteric border* of the intestine. The duodenum, however, is but partially covered by the peritoneum.

The **muscular coat** consists of two layers of fibres; an outer longitudinal, and an inner or circular set. The *longitudinal* fibres constitute an entire but comparatively thin layer, and are most obvious along the free border of the intestine. The *circular* layer is thicker and more distinct and its fibres are placed more closely together, clefts however being left here and there between the bundles.

The muscular tunic becomes gradually thinner towards the lower part of the small intestine.

It is pale in colour, and is composed of plain muscular tissue, the cells of which are of considerable length. The progressive contraction of these fibres, commencing in any part of the intestine, and advancing in a downward direction, produces the peculiar *vermicular* or *peristaltic* movement by which the contents are forced onwards through the canal. In this movement the circular fibres are mainly concerned; but the longitudinal fibres also aid in it; and those found along the free border of the intestine may have the effect of straightening or unfolding, as it were, its successive convolutions.

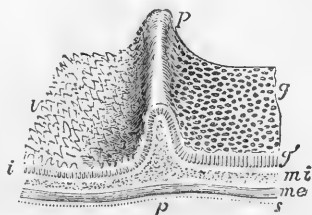
The **areolar** or **submucous coat** of the small intestine is a tolerably distinct and whitish layer, of a loose texture, which is connected more firmly with the mucous than with the muscular coat, between which two

it is placed. By turning a portion of the intestine inside out, and then blowing forcibly into the cavity, the areolar tunic may be inflated, the air being driven into its areolar tissue through the part at which

Fig. 253.—DIAGRAMMATIC VIEW IN PERSPECTIVE OF A PORTION OF THE COATS OF THE STOMACH AND DUODENUM, INCLUDING THE PYLORUS (Allen Thomson).

*g*, inner surface of the gastric mucous membrane; *g'*, section of the mucous membrane with the pyloric gastric glands; *r*, the villous surface of the mucous membrane of the duodenum; *i*, section of the same with the intestinal glands or crypts of Lieberkühn; *pp*, the ridge of the pyloric ring, with a section of its component parts; *mi*, deep or circular layer of muscular fibres: these are seen in the section to form the pyloric sphincter; *mc*, external or longitudinal layer of muscular fibres; *s*, the serous covering.

Fig. 253.



the peritoneal investment is wanting. It supports the mucous membrane, and forms a layer of loose substance in which the vessels divide and subdivide into smaller branches, preparatory to entering that membrane. It consists of areolar tissue, mixed with fine elastic fibres.

The internal coat or **mucous membrane**, is characterised by presenting all over its inner surface a finely flocculent or shaggy appearance, like the pile upon velvet, owing to its being thickly covered with minute processes, named *villi*; hence it is also named the *villous coat*. It is one of the most vascular membranes in the whole body, and is naturally of a reddish colour in the upper part of the small intestine, but becomes paler, and at the same time thinner, towards the lower end. It is covered like that of the stomach with a columnar epithelium throughout its whole extent, and next to the submucous coat is bounded by a layer of plain muscular tissue (*muscularis mucosæ*); between this and the epithelium the substance of the membrane, apart from the tubular glands which will be afterwards described, consists mainly of retiform tissue which supports the blood-vessels and lacteals, and encloses in its meshes numerous lymph-corpuscles.

The folds and wrinkles found upon the inner surface of the œsophagus and stomach may be completely obliterated by full distension of those parts of the alimentary canal. In the lining membrane of the small intestine, however, there exist besides such effaceable folds, other permanent ones, which cannot be obliterated, even when the tube is forcibly distended. These permanent folds are the **valvulæ conniventes**, or valves of Kerkring (fig. 254). They are crescentic projections of the mucous membrane, placed transversely to the course of the bowel, each of them reaching about one-half or two-

Fig. 254.

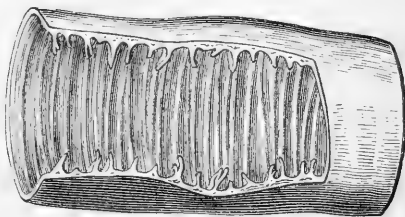


Fig. 254.—PORTION OF SMALL INTESTINE LAID OPEN TO SHOW THE VALVULÆ CONNIVENTES (Brinton).

thirds of the distance round the interior of the tube, and they follow closely one upon another along the intestine. The largest are about  $2\frac{1}{2}$  inches long and  $\frac{1}{3}$  of an inch wide at the middle or broadest part. Large and small ones are often found to alternate with each other. Some of them are bifurcated at one end, and others terminate abruptly, appearing as if suddenly cut off. Each consists of a fold of the mucous membrane, that is, of two layers placed back to back, united together by the sub-mucous areolar tissue. They contain no part of the circular or of the longitudinal muscular coats. Being extensions of the mucous membrane, they serve to increase the absorbent surface to which the food is exposed, and are said to contribute to delay its passage along the intestine.

There are no *valvulae conniventes* quite at the commencement of the duodenum; a short distance from the pylorus they begin to appear: beyond the point at which the bile and pancreatic juice are poured into the duodenum they are very large, regularly crescentic in form and placed so near to each other that the intervals between them are not greater than the breadth of one of the valves; they continue thus through the rest of the duodenum and along the upper half of the jejunum; below that point they begin to get smaller and farther apart; and finally, towards the middle of the ileum, having gradually become more and more irregular and indistinct, sometimes even acquiring a very oblique direction, they altogether disappear.

The **villi**, peculiar to the small intestine, and giving to its internal surface the velvety or villous appearance already spoken of, are small processes of the mucous membrane, which are closely set on every part of the inner surface of the small intestine, over the *valvulae conniventes*, as well as between them. They are best displayed by placing a piece of intestine, well cleansed from its mucus, under water, and examining it with a simple lens.

The villi are, as a rule, conical and flattened in form (figs. 255, 257): some are more cylindrical (fig. 256), sometimes with an enlarged or clubbed extremity. Occasionally two or three are connected together at their base.

Their length varies from  $\frac{1}{4}$ th to  $\frac{1}{3}$ rd of a line, or even more; and the broad flattened kinds are about  $\frac{1}{6}$ th or  $\frac{1}{8}$ th of a line wide, and  $\frac{1}{20}$ th or  $\frac{1}{24}$ th of a line thick. They are largest and most numerous in the duodenum and jejunum, and become gradually shorter, smaller, and fewer in number in the ileum. In the upper part of the small intestine Krause estimated their number at from 50 to 90 in a square line, and in the lower part at from 40 to 70 in the same space: he calculates their total number to be at least four millions.

In structure a villus consists of a prolongation of the proper mucous membrane, and is, like that, covered by epithelium and encloses a network of blood-vessels, one or more lacteal vessels, and a few plain muscular fibre-cells, these being all supported and held together by retiform or lymphoid tissue, which at the surface under the epithelium is condensed into a basement membrane upon which the epithelial cells are set. Nerves have not yet been demonstrated in the villi, although they are probably not wanting. Each villus receives, as a rule, one small *arterial* twig, which runs up the centre to near the middle of the villus, where it begins to break up into a number of capillaries. These form near the surface, beneath the epithelium and limiting membrane, a fine capillary network, from which the blood is returned for the most

Fig. 255. — MAGNIFIED VIEW OF THE BLOOD-VESSELS OF THE INTESTINAL VILLI.

The drawing was taken from a preparation injected by Lieberkühn, and shows in each villus a small artery and vein with the intermediate capillary network.

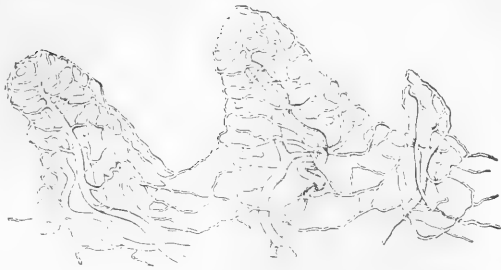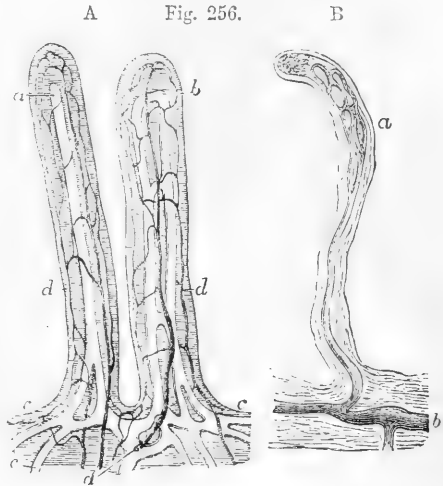


Fig. 255.

Fig. 256. — INJECTED LACTEAL VESSELS IN THE VILLI OF THE HUMAN INTESTINE.

A, two villi in which the lacteals are represented as filled with white substance and the blood-vessels with dark : 100 diameters (Teichmann). *a, b*, the lacteal vessels, single in one villus and double in the other ; *c*, the horizontal lacteal vessels with which those of the villi communicate ; *d*, the blood-vessels, consisting of small arteries and veins with capillary network between.

B, injected lacteal (shaded dark) in a villus, showing an example not very common of a looped network *a*, which is connected by a single vessel with the horizontal lacteal vessel *b*: the preparation was made from the intestine of a young man who died suddenly while digestion was going on : 80 diameters (from W. Krause).



A Fig. 256.

B

Fig. 257. — VERTICAL SECTION OF THE INTESTINAL MUCOUS MEMBRANE OF THE RABBIT (slightly altered from Frey).  $\frac{1.00}{1}$ .

Two villi are represented, in one of which the dilated lacteal alone is shown, in the other the blood-vessels and lacteal are both seen injected, the lacteal white, the blood-vessels dark : the section is carried through the tubular glands into the submucous tissue : *a*, the lacteal vessels of the villi ; *a'*, horizontal lacteal, which they join ; *b*, capillary blood-vessels in one of the villi ; *c*, small artery ; *d*, vein ; *e*, the epithelium covering the villi ; *f*, tubular glands or crypts of Lieberkühn, some divided in the middle, others cut irregularly ; *i*, the submucous layer.

A, cross section of three tubular glands more highly magnified.

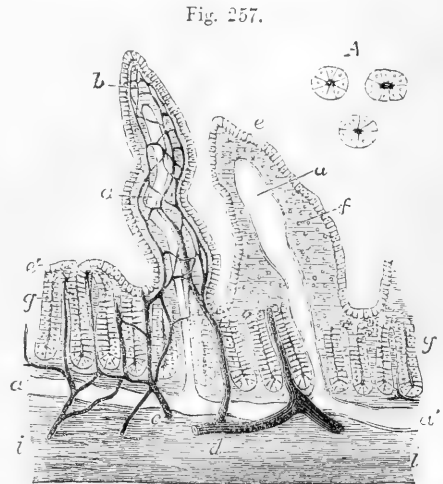


Fig. 257.

part by a single *vein*, which in man commences near the tip of the villus, and passes through the mucous membrane into the submucosa without receiving lateral twigs.\*

The lacteal lies in the centre of the villus (figs. 256, 257), and is in the smaller villi usually a single vessel, with a closed and somewhat expanded extremity, and of considerably larger diameter than the capillaries of the blood-vessels around. According to the observations of Teichmann, there are never more than two intercommunicating lacteals in a single villus in the human subject; but both he and Frey found a copious network in the villi of the sheep. Like the lymphatics elsewhere, the lacteals in the villi are bounded by a delicate layer of flattened epithelioid cells. These are connected with the branched cells of the retiform tissue, and these again with the flattened cells which form the basement membrane; from the latter, prolongations extend between the epithelium cells towards the surface.

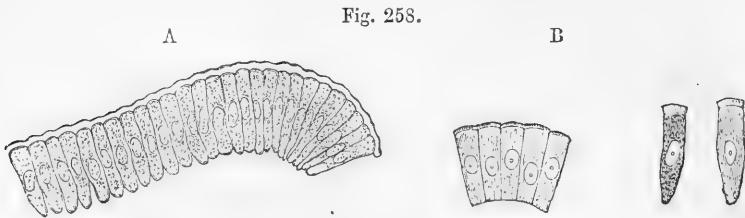


FIG. 258.—EPITHELIUM OF THE INTESTINAL VILLUS OF A RABBIT (from Kölliker).

A,  $\frac{300}{1}$ ; B,  $\frac{350}{1}$

A, series of the columnar epithelial cells separated from a villus; a cuticular membrane or border is seen passing over the free ends of the cells.

B, some of the same cells showing the striation of the border.

The columnar epithelium cells (fig. 258), which cover not only the villi but also the rest of the surface of the intestine, and extend into the tubular glands (fig. 259) are granular in appearance; each with a clear oval nucleus and a tapering extremity next the basement membrane. At the free or superficial end they present a distinct layer of highly refracting substance with vertical striæ running through it. This layer was first recognised by Kölliker and by Funke, who both considered the striæ to represent minute perforating canals; while Brettauer and Steinach, and likewise Henle, maintained them to be solid rods. The cells for the most part contain mucus, which swells up on the addition of water, transforming them into goblet-cells (see p. 211).

There has been considerable question as to the manner in which fatty matters, which are of course indiffusible through the moist animal membranes, find their way from the interior of the gut into the commencement of the lacteals. It was formerly believed that the minute fatty globules were conveyed into the interior of the villus by the medium of the columnar epithelium cells of the surface, and in accordance with this both Kölliker and Donders have described minute particles of oil as passing through the striated base of the cells. Moreover, during digestion, the epithelial cells become turbid with minute oil-droplets in their interior; and at a subsequent stage the tissue of the villus generally appears pervaded with similar fatty par-

\* The general arrangement of the vascular supply of the villi varies considerably in different animals.

ticles, and the central lacteal becomes filled with them. According to our own observations, the amoeboid lymph-corpuscles contained in the meshes of the retiform tissue, and which also extend amongst the columnar epithelium cells of the surface, become filled with fat globules during digestion: and we think it probable that these cells may serve as carriers of fatty matters into the lacteal, just as the white blood-corpuscles are known to convey minute solid particles out of the blood vessels and into the lymphatics. Other authorities are of opinion that the fat is conveyed into the lacteal through the branched cells of the retiform tissue.

With reference to the presence of fat in the epithelium-cells of the intestine, it must be borne in mind that, as pointed out by Virchow, the columnar epithelium of other parts, the bile-ducts and gall-bladder, for example, also becomes filled with fatty particles during digestion (although at a somewhat later stage); and in these cases the fat cannot have entered the cells by a process of direct absorption, but must have been elaborated and deposited within the cells themselves, probably serving for their nutrition.

The muscular tissue within the villus was discovered by Brücke: it consists of a thin stratum of plain fibre-cells disposed longitudinally around the lacteal; on being stimulated in animals, they produce an obvious retraction of the villus.

This muscular tissue is a prolongation from the muscularis mucosæ: the fibre-cells at the sides and towards the end of the villus pass from the lacteal to be attached to the basement membrane; usually their attachment to this is forked, a connective tissue corpuscle filling up the interval (Watney).\*

Two kinds of small secreting glands open on the inner surface of the intestine, viz., the crypts of Lieberkühn, and Brunner's glands, the last being peculiar to the duodenum. In addition to these, numerous lymphoid nodules are found, which are either scattered and isolated (solitary glands) or collected into patches (Peyer's glands).

The **crypts of Lieberkühn**, the smallest but most numerous of these glandular structures, are found in every part of the small intestine, opening between the villi (fig. 257, *g*). They consist of minute tubes, closed at their attached extremity, and placed more or less perpendicularly to the surface, upon which they open. They appear to be analogous to the tubuli of the stomach, but are not so thickly set, and are hardly ever divided. Similar tubules also occur throughout the whole mucous membrane of the large intestine. The crypts of Lieberkühn vary in length from the  $\frac{1}{30}$ th to the  $\frac{1}{10}$ th of a line, and their diameter is about  $\frac{1}{50}$ th of a line. The walls of the tubes are thin, formed of the basement membrane, lined with a columnar epithelium (fig. 259), which, as elsewhere, possesses the thickened border.

**Brunner's glands** are small rounded compound glands, first pointed out by Brunner, which exist in the duodenum, where they are most numerous at the upper end, in general occupying thickly a space extending a little way from the pylorus. A few of them are said also to be found quite at the commencement of the jejunum. They are imbedded in the submucous coat, and may be exposed by dissecting off the muscular coat from the outside of the intestine. In structure they resemble the small glands which are found in various parts of the lining membrane of the mouth and elsewhere, each consisting of a

\* Proceedings of the Royal Society, No. 152, 1874, and *Centralblatt, f. d. med. Wiss.* 48, 1874, where also will be found other facts having reference to the structure of the villi and the absorption of fat.

number of saccules or alveoli, situate at the terminal ramifications of the duct, which latter penetrates the muscularis mucosæ, and opens upon the inner surface of the intestine.

They present transitions between compound racemose and compound tubular glands.\*

The solitary glands (glandulæ solitariae) are soft, white, rounded, and slightly prominent bodies about the size of a millet-seed, which are found scattered over the mucous membrane in every part of the small intestine (fig. 260). They are found as well at the mesenteric as at the free

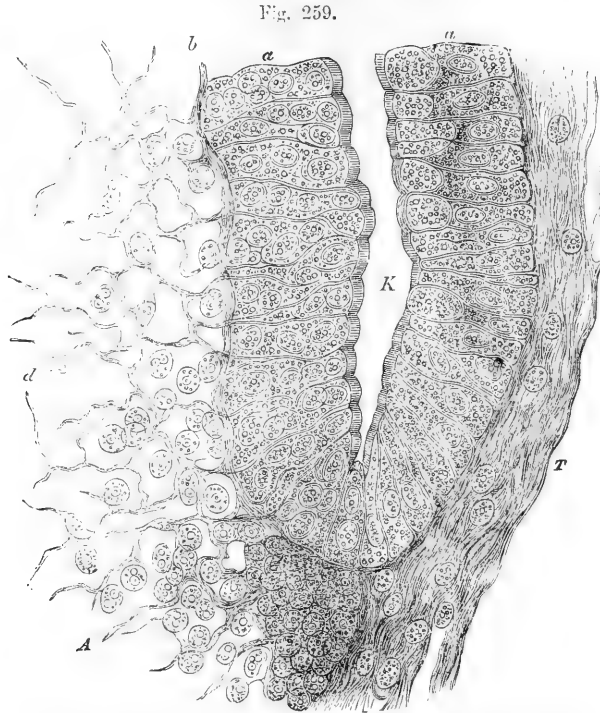


Fig. 259.—DEEP PART OF A CRYPT OF LIEBERKÜHN FROM THE RABBIT'S INTESTINE, SEEN IN VERTICAL SECTION. HIGHLY MAGNIFIED (Verson).

a, columnar epithelium ; d, lymphoid tissue of the mucous membrane seen to be connected with the basement membrane, and to extend between the epithelium cells. T, arcolar tissue ; k, lumen of gland.

border, both between and upon the valvulæ conniventes, and are rather more numerous in the lower portion of the bowel. These so-called

Fig. 260.

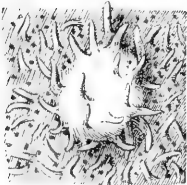


Fig. 260.—SOLITARY GLAND OF THE SMALL INTESTINE (from Behm). 10 DIAMETERS.

The lighter part of the figure represents the elevation produced by the gland ; on this a few villi are seen, and on the surrounding surface of the mucous membrane numerous villi and crypts of Lieberkühn.

glands are in structure similar to the lymphoid follicles of various parts already described, consisting of more or less insulated clumps of dense retiform tissue, the meshes of which are closely packed with lymph-corpuscles and pervaded by fine capillaries. They are here and there united at the sides with the surrounding lymphoid tissue, but are at

\* Schwalbe, Archiv. f. mikr. Anat. viii. 1872.



most points distinctly marked off from it, partly owing to the fact that their supporting retiform tissue becomes closer and finer, partly owing to their being closely surrounded by a rich plexus of lymphatic vessels; or they may even hang, as it were, into a lymph (or lacteal) sinus, which entirely surrounds the follicle, except above. The epithelium over the follicles often shows a large number of lymph corpuscles between the epithelial cells. The main part of the follicle is situated in the submucous tissue; but it extends upwards, piercing the muscularis mucosæ, into the mucous membrane, causing a slight bulging of this towards the interior of the gut (as in fig. 264, *dd*). The prominent part of the follicle has villi upon it, and, placed around very irregularly, are seen the mouths of the crypts of Lieberkühn (fig. 260).

The **agminated glands** or **glands of Peyer** (who described them in 1677), are groups or patches of lymphoid follicles. The groups have an oblong figure (fig. 261), and vary from half an inch to two or even four inches in length, being about half an inch, or rather more, in width: they are placed lengthways in the intestine at that part of the tube most distant from the mesentery; and hence, to obtain the best view of them, the bowel should be opened by an incision along its attached border.

The lymphoid nodules (fig. 264) which by their aggregation make up a Peyer's patch are in almost all respects similar to the solitary glands above described. As a rule, however, their surface is free from villi, and the crypts of Lieberkühn are collected in circles around the follicles (fig. 262). In the situation of Peyer's patches, the mucous and submucous coats of the intestine adhere more closely together than elsewhere, so that it is there impossible to inflate the areolar coat. Fine blood-vessels are distributed abundantly on the exterior of the follicles, and give off still finer capillary branches, which, supported by

Fig. 261.

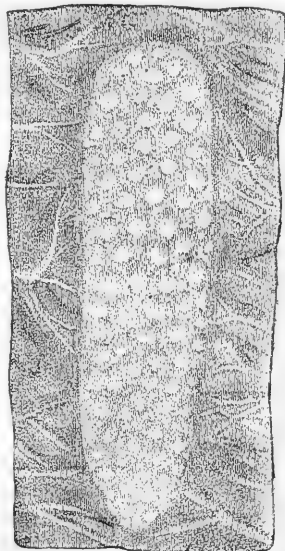
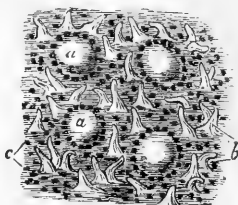


Fig. 261.—A SMALL PATCH OF PEYER'S GLANDS FROM THE ILEUM. SLIGHTLY MAGNIFIED (Behm.)

Fig. 262.—ENLARGED VIEW OF A PART OF A PATCH OF PEYER'S GLANDS, SHOWING FOUR FOLLICLES. MAGNIFIED ABOUT 10 DIAMETERS.

The figure shows the surface of the intestinal mucous membrane over part of a patch, occupied by villi, between which are the orifices of the crypts of Lieberkühn; except over the four follicles, where there are no villi. The crypts of Lieberkühn are arranged chiefly in circles round the nodules.

Fig. 262.



the retiform tissue, are disposed principally in lines converging to the centre (fig. 263).

Fig. 263.

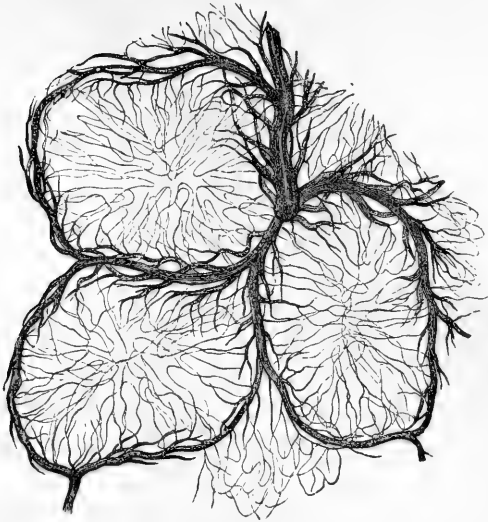


Fig. 263.—PORTION OF AN INJECTED PEYER'S PATCH (from Kölliker). MAGNIFIED.

The drawing was taken from a preparation made by Frey: it represents the fine capillary network spreading from the surrounding blood-vessels into the interior of three lymphoid nodules, from the intestine of the rabbit.

Fig. 264.

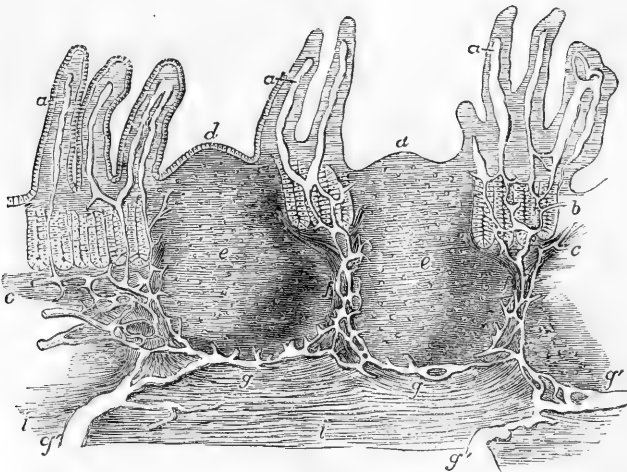


Fig. 264.—VERTICAL SECTION OF A PORTION OF A PATCH OF PEYER'S GLANDS, WITH THE LACTEAL VESSELS INJECTED (after Frey). 32 DIAMETERS.

The specimen is from the lower part of the ileum: *a*, villi, with their lacteals left white; *b*, some of the tubular glands; *c*, the muscular layer of the mucous membrane; *d*, the cupola or projecting part of Peyer's follicles; *e*, their central part; *f*, the reticulated lacteal vessels occupying the lymphoid tissue between the follicles, joined above by the lacteals from the villi and mucous surface, and passing below into *g*, the reticulated lacteals under the follicles, which again pass into *g'*, the larger lacteals of the submucous layer, *i*.

The lacteal plexuses, which are abundant in the whole extent of the intestine, are especially rich where they surround the follicles of Peyer's glands (fig. 264), often forming sinuses as in the case of the solitary follicles above described.

In all, from twenty to thirty of these oblong patches may in general be found; but in young persons dying in health, as many as forty-five have been observed. They are larger and placed at shorter distances from each other, in the lower part of the ileum; but in the upper portion of that intestine and in the lower end of the jejunum, the patches occur less and less frequently, become smaller, and are of a nearly circular form; they may, however, be discovered occasionally in the lower portion of the duodenum.

Still smaller irregularly shaped clusters of these follicles are sometimes found scattered throughout the intestine.

It was formerly presumed without question that Peyer's and the other closed follicles in the alimentary tract constituted a peculiar capsular form of secreting glands; but there is now no doubt that they are more immediately connected with the lymphatic system, and their similarity on a small scale to the structure of the lymphatic glands is unmistakable. It is found that the glands of Peyer are best marked in the young subject. After middle life they become less obvious, and are said to disappear completely in advanced age.

**Vessels and Nerves.**—The branches of the mesenteric artery, having reached the attached border of the intestine, pass round its sides, dividing into numerous ramifications and frequently anastomosing at its free border. Most of the larger branches run immediately beneath the serous coat; they then pierce the muscular coat, supplying it with vessels as they pass, and ramify in the submucous areolar layer, so as to form a close network, from which still smaller vessels pass on into the mucous coat, and terminate in the capillary network of the folds, villi, and glands of that membrane. The fine capillaries of the muscular coat are arranged in two layers of oblong meshes, which correspond in direction with the longitudinal and circular muscular fibres. The veins accompany the arteries.

The *lymphatics* of the intestine (lacteals) may be conveniently distinguished as those of the mucous membrane, and those of the muscular coat. Those of the mucous membrane form a copious plexus (fig. 264) which receives the central vessels of the villi and pervades both the mucous and submucous layers—in the latter being of considerable size, and forming, as before mentioned, a close plexus or a sinus around the base of each lymphoid follicle; but there is not, in the human subject at least, the same distinct division into two strata which has been found in the stomach (Teichmann). From the submucous plexus larger vessels proceed and pierce the muscular coat to open into the lymphatics which lie under the peritoneal coat, and which are especially developed along a narrow strip at the attachment of the mesentery. With regard to the lymphatics of the muscular coat, the main plexus is situated between the circular and longitudinal layers of fibres; and there are likewise close plexuses threading the whole thickness of the muscular wall. These muscular lymphatics are in complete continuity with those of the mucous membrane, and pass into larger vessels at the mesenteric border, which again run into the lacteal vessels of the mesentery. To these absorbents of the muscular coat Auerbach gives the name of “inter-laminar plexus.”\*

The *nerves* of the small intestine are chiefly derived from the superior mesenteric plexus. This plexus is formed superiorly by nervous branches, of which those in the middle come from the cœliac plexus, and the lateral ones proceed directly from the semilunar ganglion, and it also receives contributions from the vagus nerve. The plexus and plexiform branches into which it divides cling at first very closely to the larger divisions of the superior mesenteric artery, and, dividing similarly with the ramifications

\* Virchow's Archiv, vol. xxxiii. p. 340.

of the arteries, the branches of the nerves, retaining still a wide plexiform arrangement, pass onwards to the different parts of the intestine between the two folds of the mesentery, and finally, separating somewhat from the blood-vessels, reach the intestine in very numerous branches to be distributed in its coats. Passing first between the longitudinal and circular layer of the muscular coat, they here form a close gangliated plexus throughout the whole extent of the intestine (shown in fig. 265, A, as exhibited under a low power). This, which is known as "Auerbach's plexus," or the "plexus myentericus," and which is principally composed of non-medullated fibres, gives off fine branches to the muscular substance, these first forming a smaller plexus amongst the muscular fibres. Other larger branches pass between the circular bundles of fibres to reach the submucous layer, where they form a second richly gangliated plexus (Meissner's, fig. 265, B, under a high power), the threads of which are much finer than those of the intermuscular network.

From Meissner's plexus nervous fibres pass to be distributed to the muscular layer of the mucous membrane, breaking up into fine fibrils which take the direction of the fibre-cells of this layer, whilst other excessively fine fibrils form a comparatively open plexus in the proper tissue of the mucous coat near the basement membrane, and appear to send branches towards the epithelium, but the further course of these has not been traced.

Fig. 265.

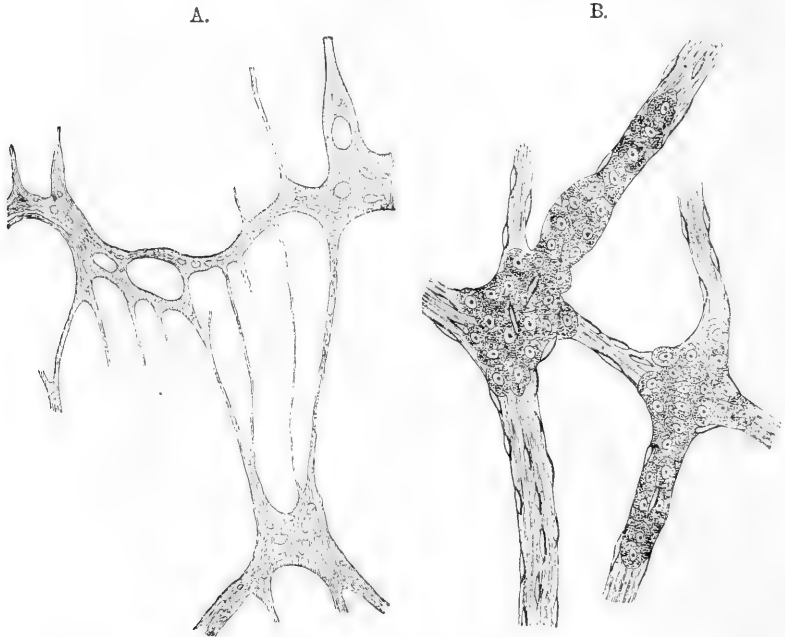


Fig. 265 (from Kölliker); A.—NERVOUS PLEXUS OF AUERBACH, FROM THE MUSCULAR COAT OF A CHILD'S INTESTINE. 20 DIAMETERS.

Three perforated ganglionic masses are seen united by several nervous cords.

B.—SMALL PORTION OF MEISSNER'S SUBMUCOUS NERVOUS PLEXUS FROM THE INTESTINE OF A CHILD. 350 DIAMETERS.

Two ganglia are represented, of which the cells are seen spreading into the nerve-twigs connected with the ganglia: the fusiform particles on the nerve-twigs are nuclei of connective tissue corpuscles.

## SPECIAL CHARACTERS AND CONNECTIONS OF THE SEVERAL PARTS OF THE SMALL INTESTINE.

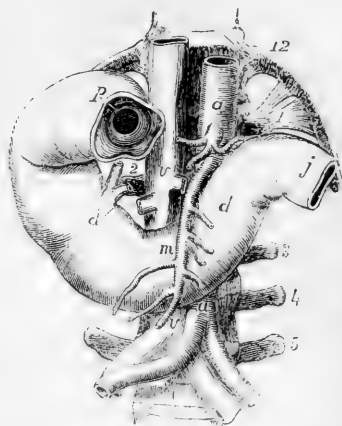
**DUODENUM.**—This is the shortest and widest part of the small intestine. In length it measures 10 or 12 inches, or about the breadth of twelve fingers; hence its name.

It varies in diameter between an inch and a half and two inches. In its course it describes a single large curve somewhat resembling a horseshoe, the convexity of which is turned towards the right, whilst the concavity embraces the head of the pancreas.

Fig. 266. —VIEW OF THE DUODENUM FROM BEFORE (slightly altered from Luschka).  $\frac{1}{4}$

12, the twelfth dorsal vertebra and rib; 1, 3, 4, 5, transverse processes of the first, third, fourth, and fifth left lumbar vertebræ; 2, that of the second on the right side; *a, a*, the abdominal aorta above the coeliac axis and also near the bifurcation; *m*, superior mesenteric artery; *v, v*, the vena cava above the renal veins and near the bifurcation; *p*, placed on the first part of the duodenum, points to the pyloric orifice seen from the side next the stomach, of which a small part is left connected with the intestine; *d*, on the descending or second part of the duodenum, indicates the termination of the common bile-duct and the pancreatic duct; *d'*, the third or oblique part of the duodenum; *j*, the commencement of the jejunum.

Fig. 266.



It has no mesentery, and is covered only partially by the peritoneum. Its muscular coat is comparatively thick, and its mucous membrane towards the pylorus is the seat of the glands of Brunner, already described. The common bile-duct and the pancreatic duct open into this part of the intestinal canal.

Three portions of the duodenum are described by anatomists.

The first, or *superior* portion, between two and three inches long, extends from the pylorus upwards, backwards, and to the right, as far as beneath the neck of the gall-bladder, where it bends suddenly downwards. The first portion of the duodenum is for the most part free, and invested by peritoneum like the stomach. Above, and in front of it, are the liver and gall-bladder, and it is commonly found stained by the exudation of bile from the latter a few hours after death. Behind it is the biliary duct, with the blood-vessels passing up to the liver.

The second, or *descending* portion, commencing at the bend below the neck of the gall-bladder passes downwards as low as the second or third lumbar vertebra, where the bowel turns across to the left to form the third portion. This part of the duodenum is invested by the peritoneum on its anterior surface only,—the posterior surface being connected to the right kidney and the vertebral column by areolar tissue. In front is the transverse colon and mesocolon, the upper layer of which is continuous with the peritoneal covering of the duodenum. To the left is the head of the pancreas (see fig. 282), which adapts itself to

the shape of the intestine on that side, and, according to Verson, some of the longitudinal muscular fibres of the gut are intercalated amongst the contiguous lobules of the gland. The common bile-duct descends behind the left border of this part of the duodenum, and, together with the pancreatic duct, which accompanies it for a short distance, perforates the coats of the intestine obliquely near the lower part of its left or concave border. In the interior of this part of the intestine the *valvulae conniventes* appear numerously; and a downwardly projecting, papillary eminence of the mucous membrane is found immediately below one of these, about four inches below the pylorus, on the inner and back part of the intestine, at the apex of which is seen the common orifice of the biliary and pancreatic ducts.

The third, *transverse* or oblique portion (*d'*), somewhat the longest and narrowest, beginning on the right of the third lumbar vertebra, crosses in front of the second obliquely from right to left. It makes its appearance below the transverse mesocolon, and, continuing to ascend for an inch or more, ends in the jejunum (*j*) at the left side of the vertebral column, immediately behind the root of the transverse mesocolon, and the commencement of the mesentery, and has the vena cava inferior and the aorta behind it, while in front of it the superior mesenteric vessels (*m*) pass from beneath the pancreas to enter the mesentery.

At its termination the duodenum forms an abrupt angle with the commencement of the jejunum. This is due to its being maintained, at that point, in its position, by a strong fibrous band descending from the left crus of the diaphragm and the tissue around the cœliac axis. According to Treitz, muscular fibres come from both these sources to this part of the duodenum. In subjects in which the intestines are large and dilated, the curve of the duodenum may descend to the level of the iliac crest, but, owing to the support given by the band alluded to, its terminal extremity maintains a uniform position.

**JEJUNUM AND ILEUM.**—The *jejunum*, originally so called from its having been supposed to be empty after death, follows the duodenum, and includes the upper two-fifths of the remainder of the small intestine, while the succeeding three-fifths constitute the *ileum*, so named from its numerous coils or convolutions. Both the jejunum and the ileum are attached and supported by an extensive fold of peritoneum termed the *mesentery*. The mesentery of the small intestine, although greatly frilled out in front to correspond in length with the jejunum and ileum to which it affords support, is attached posteriorly by a very short border which extends from the level of attachment of the transverse colon immediately to the left of the middle line, directly down to the right iliac fossa, where the ileum falls into the cæcum. At its widest part the length of the mesentery is from four to six inches between its vertebral and its intestinal border. Between the two layers of peritoneum of which it consists are placed, besides some fat, numerous branches of the superior mesenteric artery and vein, together with nerves, lacteal vessels, and mesenteric glands. The convolutions of the jejunum are situated in part of the umbilical and left iliac regions of the abdomen; while the ileum occupies part of the umbilical and right iliac regions, together with the hypogastric, and descends into the pelvis, from which its lower end, supported by the mesentery, which is here very short, ascends obliquely to the right and somewhat backwards, over the corresponding *psaos* muscle, and ends in the right iliac fossa, by opening into the inner side of the commencement of the

large intestine. The character of the intestine gradually changes from its upper to its lower end, so that portions of the two intestines, remote from each other, present certain well-marked differences of structure, which may be here enumerated. Thus, the jejunum is wider, and its coats are thicker; it is more vascular, and therefore it has a deeper colour; its valvulae conniventes are long, wide and numerous; its villi are well developed; and the patches of Peyer's glands are smaller, less frequent, and sometimes confined to its lower part. The ileum, on the other hand, is narrower; its coats are thinner and paler; the valvulae conniventes are small, and gradually disappear towards its lower end; the villi are shorter; and the groups of Peyer's glands are larger and more numerous. The diameter of the jejunum is about one inch and a half, that of the ileum about one inch and a quarter. A given length of the jejunum weighs more than the same of the ileum.

At a point in the lower part of the ileum it is not very uncommon to find a pouch or *diverticulum* given off from the main tube. The origin of these diverticula is explained by reference to the history of development, from which it appears that they arise from a portion of the ductus vitello-intestinalis, or tube uniting the intestine with the umbilical vesicle, remaining pervious. They are not to be confounded with hernial protrusions of the mucous membrane, which may occur at any point.

### THE LARGE INTESTINE.

The large intestine extends from the termination of the ileum to the anus. It is divided into the caecum (including the vermiform appendix), the colon and the rectum; and the colon is again subdivided, according to its direction, into four parts, called the ascending, transverse, and descending colon, and the sigmoid flexure.

The length of the large intestine is usually about five or six feet; being about one-fifth of the whole length of the intestinal canal. Its diameter, which greatly exceeds that of the small intestine, varies at different points from two inches and a half to about one inch and a half. It diminishes gradually from its commencement at the caecum to its termination at the anus; excepting that there is a well-marked dilatation of the rectum just above its lower end.

In outward form, the greater part of the large intestine differs remarkably from the small intestine; for, instead of constituting an even cylindrical tube, its surface is thrown into numerous sacculi, marked off from each other by intervening constrictions, and arranged in three longitudinal rows, separated by three strong flat bands of longitudinal muscular fibres. This sacculated structure is not found in the rectum.

### STRUCTURE OF THE LARGE INTESTINE.

The large intestine has four coats, like those of the stomach and small intestine, namely, the serous, muscular, areolar or submucous, and mucous.

The **serous coat** is quite similar to that of the small intestine, except that, along the colon and upper part of the rectum, it is developed into numerous little projections, which enclose a certain amount of fat, and are termed *appendices epiploicae*.

The **muscular coat**, like that of the other parts of the intestinal

canal, consists of external longitudinal and internal circular fibres. The *longitudinal* fibres, although found in a certain amount all round the intestine, are, in the cæcum and colon, principally collected into three remarkable flat longitudinal bands (fig. 267, *lm*; fig. 270). These bands, sometimes called the ligaments of the colon, are about half an inch wide, and half a line thick; they commence upon the extremity of the cæcum, at the attachment of the vermiform appendix, and may be traced along the whole length of the colon as far as the commencement of the rectum, where they spread out, so as to surround that part of

Fig. 267.

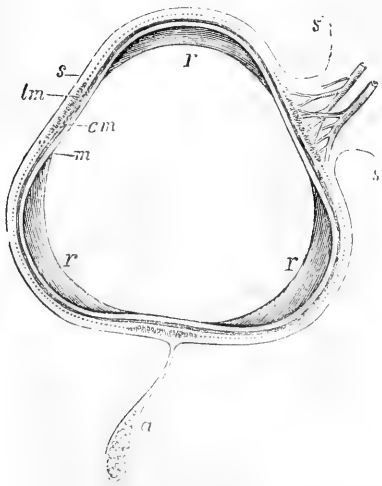


Fig. 267.—OUTLINE SKETCH OF A SECTION OF THE ASCENDING COLON (Allen Thomson).  $\frac{2}{3}$

*s*, the serous or peritoneal covering; *s', s''*, reflection of this at the attached border forming a short wide mesentery, between the folds of which the blood-vessels are seen passing to the colon; *a*, one of the appendices epiploicæ hanging from the inner border; *lm*, indicates at the free border one of the three bands formed by the thickening of the longitudinal muscular coat; the dotted line continued from the margins of these bands represents the remainder of the longitudinal muscular coat, and the thick line within it, marked *cm*, represents the circular muscular layer; *m*, the mucous membrane at the flattened part; *r*, the crescentic bands or indentations which divide the sacculi.

the intestinal tube with a uniform layer of longitudinal muscular fibres. One of these bands, named the *posterior*, is placed along the attached border of the intestine; another runs along its *anterior* border, and, in the transverse colon, corresponds with the attachment of the great omentum; whilst the third band (*lateral*) is found on the inner border of the ascending and descending colon, and on the under border of the transverse colon. It is along the course of this third band that the appendices epiploicæ are most of them attached (fig. 267, *a*). Measured from end to end, these three bands are shorter than the intervening parts of the tube; and the latter are thus thrown into the sacculi already mentioned: accordingly, when the bands are removed by dissection, the sacculi are entirely effaced, and the colon, elongating considerably, assumes the cylindrical form. The transverse constrictions seen on the exterior of the intestine, between the sacculi, appear on the inside as sharp ridges separating the cells, and are composed of all the coats. In the vermiform appendix the longitudinal muscular fibres form a uniform layer.

The *circular* muscular fibres form only a thin layer over the general surface of the cæcum and colon, but are accumulated in larger numbers between the sacculi. In the rectum, especially towards its lower part, the circular fibres form a very thick and powerful muscular layer.

The **submucous** or **areolar** coat resembles in all respects that of the small intestine.



The **mucous membrane** differs from that of the small intestine in being quite smooth and destitute of villi. Viewed with a lens, its

Fig. 268.

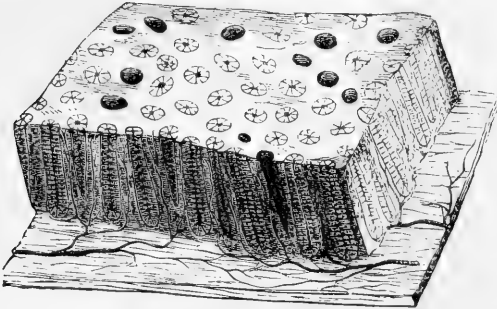


Fig. 268.—DIAGRAMMATIC VIEW (MAGNIFIED) OF A SMALL PORTION OF THE MUCOUS MEMBRANE OF THE COLON (Allen Thomson).

A small portion of the mucous membrane cut perpendicularly at the edges is shown in perspective; on the surface are seen the orifices of the crypts of Lieberkühn or tubular glands, the most of them lined by their columnar epithelium, a few divested of it and thus appearing larger; along the sides the tubular glands are seen more or less equally divided by the section; these are resting on a wider portion of the submucous tissue, from which the blood-vessels are represented as passing into the spaces between the glands.

surface is seen to be marked all over by the orifices of numerous tubular glands (*crypts of Lieberkühn*) (fig. 268), resembling those of the small intestine, but longer and more numerous, and placed more closely together and at more regular intervals.

Besides these, there are scattered over the whole large intestine *lymphoid follicles*, similar to the solitary glands of the small intestine, but less prominent. They are most numerous in the cæcum and in its vermiform appendix; being placed closely all over the latter.

The epithelium, which covers the general surface of the mucous membrane, and lines the tubular glands, is of the columnar kind, and in every respect similar to that of the small intestine. As in the stomach the mucous membrane consists of areolar connective tissue with a certain amount of retiform tissue, and is bounded next the submucous coat by a layer of plain muscular fibres (*muscularis mucosæ*), which sends prolongations up between the glands to be attached to the basement membrane near the surface, in the same way as in the villi of the small intestine.

Fig. 269.

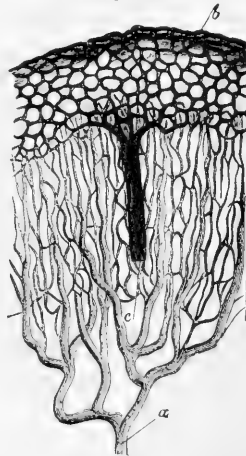


Fig. 269.—BLOOD-VESSELS OF LARGE INTESTINE AS SEEN IN VERTICAL SECTION (Kölliker).

*a*, artery passing up from submucosæ; *c*, vein arising from capillary plexus, *b*, around the mouths of the glands.

**Vessels and Nerves.**—In the large intestine a similar arrangement of capillary plexuses and venous radicles obtains, as has been described in the stomach (fig. 269). The arrangement of the lymphatics also presents great similarity: the lymphatics of the mucous membrane have here been longer recognized.

Nervous plexuses similar to those of the small intestine are also found in the muscular and submucous coats of the large intestine.

**SPECIAL CHARACTERS AND CONNECTIONS OF THE DIFFERENT PARTS OF THE LARGE INTESTINE.**

**THE CÆCUM.**—The *intestinum cæcum*, or *caput cæcum coli*, is that part of the large intestine which is situated below the entrance of the ileum (fig. 270, cc). Its length is about two inches and a half, and its diameter nearly the same: it is the widest part of the large intestine.

Fig. 270.

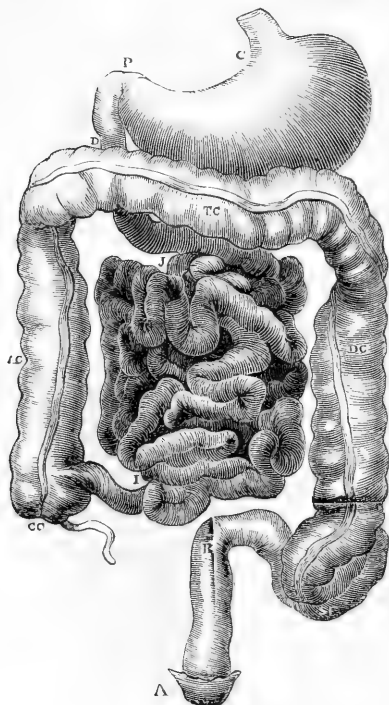


Fig. 270.—STOMACH AND INTESTINES.

cc, caecum; ac, ascending; tc, transverse; and dc, descending parts of the colon; sf, sigmoid flexure; r, rectum.

The cæcum is situated in the right iliac fossa, immediately behind the anterior wall of the abdomen. It is covered by the peritoneum in front, below, and at the sides: but behind it is usually destitute of peritoneal covering, and is attached by areolar tissue to the fascia covering the right iliacus muscle. In this case the cæcum is comparatively fixed; but in other instances the peritoneum surrounds it almost entirely, and forms a duplicature behind it, called *meso-cæcum*.

Coming off from the inner and back part of the cæcum, at its lower end, is a narrow, round, and tapering portion of the intestine, named the *appendix cæci*, or *appendix vermiformis* (figs. 270, 271). The width of this process is usually about that of a large quill or rather more, and its length varies from three to six inches, these dimensions differing much in different cases. Its general direction is upwards and inwards behind the cæcum; and after describing a few slight turns it ends in a blunt point. It is retained in its position by a small fold of peritoneum, which forms its mesentery. The caecal

appendix is hollow as far as its extremity: and its cavity communicates with that of the cæcum by a small orifice, sometimes guarded by a valvular fold of mucous membrane.

So far as is known, this appendix is peculiar to man and certain of the higher apes, and to the wombat; but in some animals, as in the rabbit and hare, the distal part of the cæcum, being diminished in

diameter and thickly studded with lymphoid follicles, may represent a condition of the appendix.

**Ileo-cæcal or ileo-colic valve.**—The lower part of the small intestine (fig. 271 *i*), ascending from left to right, and from before backwards,

Fig. 271.—VIEW OF THE ILEO-COLIC VALVE FROM THE LARGE INTESTINE (after Santorini).  $\frac{1}{2}$

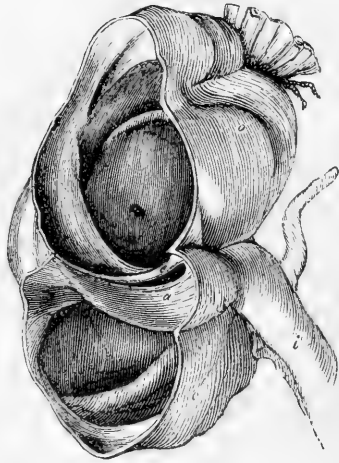
The figure shows the lowest part of the ileum, *i*, joining the cæcum, *c*, and the ascending colon, *o*, which have been opened anteriorly, so as to display the ileo-colic valve; *a*, the lower, and *e*, the upper segment of the valve.

enters the commencement of the large intestine, with a considerable degree of obliquity, about two inches and a half from the bottom of the cæcum, and opposite the junction of the latter with the ascending colon. The opening leading from the ileum into the large intestine is guarded by a valve composed of two segments or folds. This is the *ileo-cæcal* or *ileo-colic* valve: it is also called the valve of Bauhin and the valve of Tulpus, although Fallopius had described it before either of those anatomists.

The entrance between the two segments of the valve is a narrow elongated slit-like aperture, lying nearly transverse to the direction of the great intestine. It is rounded and widened at its anterior end which is turned slightly to the left, but the posterior end is narrow, and pointed. It is bounded above and below by two prominent semi-lunar folds, which project inwards towards the cæcum and colon. The upper of these (fig. 271, *e*) is horizontal in direction, the lower and larger (*a*) more oblique. At each end of the aperture these folds coalesce, and are then prolonged as a single ridge on each side for some distance round the cavity of the intestine, forming the *fræna* or *retinacula* of the valve. The opposed surfaces of the valvular folds which look towards the ileum, and are continuous with its mucous surface, are covered like it with villi; while their other surfaces, turned toward the large intestine, are smooth and destitute of villi. When the cæcum is distended, the *fræna* of the valve are stretched, and the marginal folds brought into apposition, so as completely to close the aperture and prevent reflux into the ileum, while at the same time no hindrance is offered to the passage of additional matter from thence into the great intestine.

Each segment of the valve consists of two layers of mucous membrane, continuous with each other along the free margin, and including between them, besides the submucous areolar tissue, a number of muscular fibres, continued from the circular fibres of the ileum and of the large intestine. The longitudinal muscular fibres and the peritoneal

Fig. 271.



coat take no part in the formation of the valve, but are stretched across it uninterruptedly from one intestine to the other.

**THE COLON.**—The **ASCENDING COLON**, situated in the right lumbar and hypochondriac regions, commencing at the cæcum opposite to the ileo-cæcal valve, ascends vertically to the under surface of the liver, near the gall-bladder, where it proceeds forwards and then turns abruptly to the left, forming what is named the *hepatic flexure* of the colon. The ascending colon is smaller than the cæcum, but larger than the transverse colon. It is overlaid in front by some convolutions of the ileum, and is bound down firmly by the peritoneum, which passes over its anterior surface and its sides, and generally leaves an interval in which its posterior surface is connected by areolar tissue with the fascia covering the quadratus lumborum muscle, and with the front of the right kidney. In some cases, however, the peritoneum passes nearly round it, and forms a distinct though very short right meso-colon.

The **TRANSVERSE COLON** passes across from the right hypochondrium, through the upper part of the umbilical region, into the left hypochondrium. Sometimes it is found as low as the umbilicus or even lower. At each extremity it is situated deeply towards the back part of the abdominal cavity, but in the middle it curves forwards, and lies close to the anterior wall of the abdomen. Hence it describes an arch, the concavity of which is turned towards the vertebral column; and it has accordingly been named the *arch of the colon*.

Above, the transverse colon is in contact with the under surface of the liver, the gall-bladder, the great curvature of the stomach, and the lower end of the spleen. Below it are the convolutions of the small intestine, the third portion of the duodenum being behind it. It is invested by the general peritoneum, which forms a separate fold for it behind, the *transverse meso-colon*, and in front it adheres to the sac of the omentum.

The **DESCENDING COLON** is continuous with the left extremity of the transverse colon by a sudden bend named the *splenic flexure*. At this bending there is found a remarkable fold of peritoneum, the *costo-colic* or *pleuro-colic ligament*, which stretches with a lunated free border to the colon from the diaphragm, opposite the 10th or 11th rib. As was pointed out by Haller, it supports the spleen although unconnected with that organ, and might be termed “*sustentaculum lienis*.” The colon then descends almost perpendicularly through the left hypochondriac and lumbar regions to the left iliac fossa, where it ends in the sigmoid flexure. The peritoneum affords a covering to it only in front and at the sides, whilst behind it is connected by areolar tissue to the left crus of the diaphragm, the quadratus lumborum, and the left kidney. It is usually concealed behind some convolutions of the jejunum.

The **SIGMOID FLEXURE** of the colon, situated in the left iliac fossa, consists of a double bending of the intestine upon itself in the form of the letter S, immediately before it becomes continuous with the rectum at the margin of the pelvis opposite to the left sacro-iliac articulation. It is attached by a distinct meso-colon to the iliac fossa, and is very movable. It is placed immediately behind the anterior parietes, or is concealed only by a few turns of the small intestine. The sigmoid flexure is the narrowest part of the colon.

**THE RECTUM.**—The lowest portion of the large intestine, named the

*rectum*, extends from the sigmoid flexure of the colon to the anus, and is situated entirely within the true pelvis, in its back part (fig. 272, *r, r*).

Commencing opposite the left sacro-iliac articulation, it is directed at first obliquely downwards, and from left to right, to gain the middle line of the sacrum. It then changes its direction, and curves forwards in front of the lower part of the sacrum and the coccyx, and behind the bladder, vesiculæ seminales and prostate in the male, and at the back of the cervix uteri and vagina in the female. Opposite the

Fig. 272.

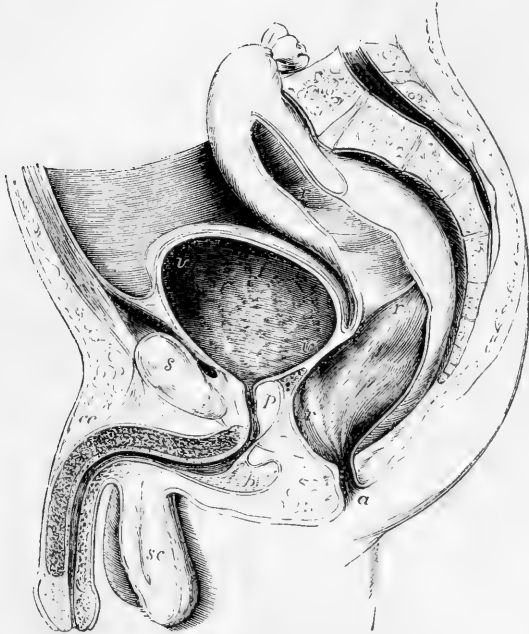


Fig. 272.—VERTICAL SECTION OF THE PELVIS AND ITS VISCERA IN THE MALE  
(from Houston).  $\frac{1}{3}$

This figure is introduced to illustrate the form, position, and relations of the rectum; it also shows the bladder and urethra with the pelvic inflection of the peritoneum over these viscera: *r, r, r*, the upper and middle parts of the rectum, and at the middle letter the fold separating the two; *r, a*, the lower or anal portion; *v*, the upper part of the urinary bladder; *v'*, the base, at the place where it rests more immediately on the rectum; *p*, the prostate gland and prostatic portion of the urethra; *b*, the bulb; *c, c*, the corpus cavernosum penis and suspensory ligament; *sc*, the scrotum; *s*, symphysis pubis.

prostate it makes another turn, and inclines downwards and backwards to reach the anus. The *intestinum rectum*, therefore, so called from its original description being derived from animals, is far from being straight in the human subject. Seen from the front, the upper part of the rectum presents a lateral inclination from the left to the median line of the pelvis, sometimes passing beyond the middle to the right; and when viewed from the side (fig. 272), it offers two curves, one corresponding with the hollow front of the sacrum and coccyx, and

the other at the lower end of the bowel, forming a shorter turn in the opposite direction.

Unlike the rest of the large intestine, the rectum is not sacculated, but is smooth and cylindrical; and it has no separate longitudinal bands upon it. It is about eight inches in length, and at its upper end is rather narrower than the sigmoid flexure, but becomes dilated into a large ampulla or reservoir immediately above the anus.

The upper part of the rectum, covered by peritoneum, is in contact in front with the back of the bladder (or uterus in the female), unless some convolutions of the small intestine happen to descend between them. The ureter and branches of the internal iliac artery are in contact with it on the left side. It is attached behind to the sacrum by a duplicature of peritoneum named the *meso-rectum*. Lower down the peritoneum covers the intestine in front and at the sides, and at last in front only; still lower, it quits the intestine altogether, and is reflected forwards to ascend in the male upon the back of the bladder, in the female on the back of the upper part of the vagina and the uterus. In passing from the rectum to the bladder, the peritoneum forms a cul-de-sac, the recto-vesical pouch, which extends downwards between the intestine and the bladder to within an inch or more from the base of the prostate, and is bounded above at each side by a lunated fold of the serous membrane, of which the left is almost always the larger (posterior ligaments of the bladder).

Below the point where the peritoneum ceases to cover it, the rectum is connected to surrounding parts by areolar tissue, which is mostly loaded with fat. In this way it is attached behind to the front of the sacrum and the coccyx, and at the sides to the coccygei and levatores ani muscles. In front, it is in immediate connection with a triangular portion of the base of the bladder (fig. 272, *v'*); on each side of this, with the vesiculæ seminales; and farther forwards, with the under surface of the prostate (*p*). Below the prostate, where the rectum turns downwards to reach the anus, it becomes invested by the fibres of the internal sphincter, and embraced by the levatores ani muscles, by which, as well as by the triangular ligament of the urethra, it is supported. Lastly, at its termination it is surrounded by the external sphincter ani muscle.

In the female, the lower portion of the rectum is firmly connected with the back of the vagina.

For convenience of description the rectum is sometimes divided arbitrarily into three parts; the first or uppermost, about  $3\frac{1}{4}$  inches long, extending to the centre of the 3rd sacral vertebra: the middle part (3 inches) from this point to the tip of the coccyx; whilst the lowermost, about an inch and a half long, curves back to the anus.

**Structure of the rectum.**—The rectum differs in some respects from the rest of the large intestine, in the structure of both its muscular and its mucous coats.

The *muscular coat* is very thick: the external or longitudinal fibres form a uniform layer around it, and cease near the lower end of the intestine; the internal or circular fibres, on the contrary, become more numerous in that situation, where they form what is named the internal sphincter muscle. The longitudinal fibres are paler than the circular

but both layers become darker and redder towards the termination of the bowel.

The *mucous membrane* of the rectum is thicker, redder, and more vascular than that of the colon; and it moves more freely upon the muscular coat;—in this respect resembling the lining membrane of the œsophagus. It presents numerous folds of different sizes, and running in various directions, nearly all of which are effaced by the distension of the bowel. Near the anus these folds are principally longitudinal, and seem to depend on the contraction of the sphincter muscles outside the loosely connected mucous membrane. The larger of these folds were named by Morgagni the *columns* of the rectum (*columnæ recti*). These columns contain longitudinal muscular fibres (apparently part of the *muscularis mucosæ*), which terminate both superiorly and inferiorly in elastic tissue (Treitz). Higher up in the intestine, the chief folds are transverse or oblique. Three prominent folds, larger than the rest, being half an inch or more in depth, and having an oblique direction in the interior of the rectum, have been pointed out specially by Houston. One of these projects backwards from the upper and fore part of the rectum, opposite the prostate gland; another is placed higher up, at the side of the bowel; and the third still higher. From the position and projection of these folds, they may more or less impede the introduction of instruments (Dublin Hospital Reports, vol. v.).

**Vessels and Nerves of the Rectum.**—The *arteries* of the rectum spring from three sources, viz., the superior hæmorrhoidal branches from the inferior mesenteric; the middle hæmorrhoidal branches from the internal iliac directly or indirectly; and, lastly, the external or inferior hæmorrhoidal branch from the pudic artery. The arrangement of the vessels is not the same throughout the rectum. Over the greater part the arteries penetrate the muscular coat at short intervals, supplying its layers as they pass through, and, at once dividing into small branches in the submucosa, form a network by their inter-communication. Towards the lower end, for four or five inches, the arrangement is different. Here the vessels, having penetrated the muscular coat at different heights, assume a longitudinal direction, passing in parallel lines towards the end of the bowel. In their progress downwards they communicate with one another at intervals, and they are very freely connected near the orifice, where all the arteries join by transverse branches of considerable size. (Quain, Diseases of the Rectum.)

The *veins* are very numerous, and form a complex interlacement resembling that of the arteries just described, and named the *hæmorrhoidal plexus*. After following a longitudinal course upwards similar to that of the arteries which they accompany, they end partly in the internal iliac vein by branches which accompany the middle hæmorrhoidal artery, and partly in the inferior mesenteric vein. Hence, the blood from the rectum is returned in part into the vena cava, and in part into the portal system.

The *lymphatics* enter some glands placed in the hollow of the sacrum, or those of the lumbar series.

The *nerves* are very numerous, and are derived from both the cerebro-spinal and the sympathetic systems. The former consist of branches derived from the sacral plexus; and the latter, of offsets from the inferior mesenteric and hypogastric plexuses.

#### THE ANUS AND ITS MUSCLES.

The *anus*, or lower opening of the alimentary canal, is a dilatable orifice, surrounded internally by the mucous membrane, and externally by the skin, which two structures here become continuous with and pass into each other. The skin around the borders of the anus, which

is thrown into wrinkles during the closed state of the orifice, is covered with numerous papillæ, and is provided with hairs and sebaceous follicles.

The lower end of the rectum and the margin of the anus are, moreover, embraced by certain muscles, which serve to support the bowel, and to close its anal orifice. These muscles, proceeding from within outwards, are, the internal sphincter, the levatores ani, the coccygei, and the external sphincter. The three last muscles have already been described.

The **internal sphincter** muscle (sphincter ani internus) is a muscular ring or rather belt, surrounding the lower part of the rectum, an inch above the anus, and extending over about half an inch of the intestine. It is two lines thick, and is paler than the external sphincter. Its fibres are continuous above with the circular muscular fibres of the rectum, and, indeed, it consists merely of those fibres more numerous developed than elsewhere, and prolonged farther down than the external longitudinal fibres.

Kohlrausch describes a thin stratum of fibres between the mucous membrane and the internal sphincter, these fibres having a longitudinal direction. Henle thinks this is nothing more than the stratum of fibres belonging to the proper mucous coat; but Kohlrausch gives it a distinct name, the sustentator tunicae mucosæ. (Kohlrausch, Anat. und Phys. d. Beckenorgane. Leipzig, 1854.)

Ellis further describes a thin layer of involuntary muscle with radiating fibres which pass from the submucous tissue inside the internal sphincter to end in the subdermic tissue outside. (Illustrations of Dissections. London, 1865. P. 243.)

## THE LIVER.

The liver is an important glandular organ, very constant in the animal series, being found in all vertebrate, and, in a more or less developed condition, in most invertebrate tribes. It secretes the bile, and appears to act, in a manner as yet imperfectly understood, upon the blood which is transmitted through it. Moreover there is formed in its texture a starchy substance (glycogen), very easily converted into sugar.

The liver is the largest gland in the body, and by far the most bulky of the abdominal viscera. It measures about 10 or 12 inches transversely from right to left, between 6 and 7 inches from its posterior to its anterior border, and about  $3\frac{1}{2}$  inches from above downwards where thickest, which is towards the right and posterior part. The average bulk, according to Krause, is 88 cubic inches; according to Beale, one hundred. The ordinary weight in the adult is between 50 and 60 ounces.

According to the facts recorded by Reid, the liver weighed, in 43 cases out of 82, between 48 and 58 ounces in the adult male; and in 17 cases out of 36, between 40 and 50 ounces in the adult female. It is generally estimated to be equal to about 1-36th of the weight of the whole body; but in the fœtus, and in early life, its proportionate weight is greater.

The specific gravity of the liver, according to Krause and others, is between 1.05 and 1.06; in fatty degeneration this is reduced to 1.03, or even less.

The liver is solid to the feel, and of a dull reddish-brown colour, with frequently a dark-purplish tinge along the margin. It has an upper surface smooth and convex, and an under surface, which is uneven and



concave; the circumference is thick and rounded behind and on the right, but becomes gradually less so towards the left and front borders, which are sharp and thin.

The liver is divided into two unequal lobes, a right and a left, and on the under surface of the right lobe are three secondary lobes or lobules, named the lobe of Spigelius, the caudate or tailed lobe, and the square lobe.

Five fissures or fossæ are likewise described; viz., the transverse or portal; the umbilical fissure and the fissure of the ductus venosus, together forming the longitudinal fissure; the fossa of the vena cava and the fossa for the gall bladder.

**SURFACES.**—The **upper surface** of the organ is convex, smooth, and covered with peritoneum. It is marked off into a right portion, large and convex, and a left portion, smaller and flatter, by the line of attachment of the fold of peritoneum named the falciform or broad ligament.

The **under surface** (fig. 273) looks somewhat backwards, and is concave and uneven. It is invested with peritoneum everywhere except where the gall-bladder is adherent to it, and at the portal fissure and fissure of the ductus venosus, where the fold of peritoneum (lesser omentum) comes off, which encloses the blood-vessels and ducts of the

Fig. 273.

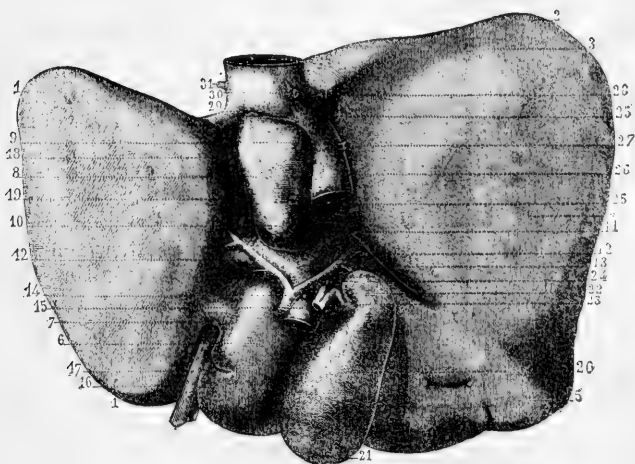


Fig. 273.—LOWER SURFACE OF THE LIVER WITH THE PRINCIPAL BLOOD-VESSELS AND DUCTS (from Sappey).  $\frac{1}{3}$

1, left lobe; 2, 3, 4, 5, right lobe; 6, lobulus quadratus; 7, pons hepatis; 8, 9, 10, lobulus Spigelii; 11, lobulus caudatus; 12, 13, transverse or portal fissure with the great vessels; 14, hepatic artery; 15, vena portæ; 16, anterior part of the longitudinal fissure, containing 17, the round ligament or remains of the obliterated umbilical vein; 18, posterior part of the same fissure, containing 19, the obliterated ductus venosus; 20, 21, 22, gall-bladder; 23, cystic duct; 24, hepatic duct; 25, fossa containing 26, the vena cava inferior; 27, opening of a small vein from the capsule of the organ; 28, small part of the trunk of the right hepatic vein; 29, trunk of the left hepatic vein; 30, 31, openings of the right and left diaphragmatic veins.

viscus, and passes to the smaller curvature of the stomach. On this surface the lobes and fissures of the liver are observed.

**LOBES.**—The **right** and **left** lobes are separated from each other on the under surface by the longitudinal fissure, and in front by the interlobular notch: on the convex surface of the liver there is no other indication of a separation between them than the line of attachment of the broad ligament. The right lobe is much larger and thicker than the left, which constitutes only about one-fifth or one-sixth of the entire gland.

The **lobulus quadratus (anonymus)** (fig. 273, 6) is situated between the gall-bladder and the great longitudinal fissure, and in front of the portal or transverse fissure. It is somewhat oblong from before backwards.

The **lobulus Spigelii** (8, 9, 10), more prominent and less regular in shape than the quadrate lobe, lies behind the fissure for the portal vein, and is bounded on the right and left by the fissures which contain the inferior vena cava and the remains of the ductus venosus (25, 19).

The **lobulus caudatus** (11) is a sort of ridge which extends from the base of the Spigelian lobe to the under surface of the right lobe. This, in the natural position of the parts, passes forwards above the passage named foramen of Winslow, the Spigelian lobe itself being situated behind the small omentum, and projecting into the omental sac.

**FISSURES.**—The **transverse** or **portal** fissure (fig. 273, 12, 13) is the most important, because it is here that the great vessels and nerves enter, and the hepatic duct passes out. It lies transversely between the lobulus quadratus and lobulus Spigelii, and meets the longitudinal fissure nearly at right angles. At its two extremities, the right and left divisions of the hepatic artery and portal vein, together with the nerves and deep lymphatics, enter the organ, while the right and left hepatic ducts emerge.

The **longitudinal** fissure, between the right and the left lobes, is divided into two parts by its meeting with the transverse fissure. The anterior part (16), named the **umbilical** fissure, contains the umbilical vein in the foetus, and the remnant of that vein in the adult, which then constitutes the round ligament (17). It is situated between the square and the left lobe of the liver, the substance of which often forms a bridge (*pons hepatis*) across the fissure, so as to convert it partially or completely into a canal. The posterior part (18) is named the fissure of the **ductus venosus** (*fossa ductus venosi*); it is situated between the lobe of Spigelius and the left lobe and lodges the ductus venosus in the foetus, and in the adult a slender cord or ligament (19) into which that vein is converted.

The *fissure* or *fossa* of the **vena cava** (25) is situated at the back part of the liver, between the Spigelian lobe and the right lobe, and is separated from the transverse fissure by the caudate lobe. It is prolonged upwards in an oblique direction to the posterior border of the liver, and may be said to join behind the Spigelian lobe with the fissure for the ductus venosus. It is at the bottom of this fossa that the blood leaves the liver by the hepatic veins, which end here in the vena cava. As in the case of the umbilical fissure, the substance of the liver in some cases unites around the vena cava, and encloses that vessel in a canal.

The last remaining fissure, or rather **fossa** (*fossa cystis felleæ*), is that for the lodgment of the *gall-bladder* (21); it is sometimes continued into a slight rounded notch on the anterior margin of the liver.

*Two shallow impressions* are seen on the under surface of the right lobe; one in front (*impressio colica*), corresponding with the hepatic flexure of the colon; and one behind (*impressio renalis*), corresponding with the right kidney.

**BORDERS.**—The **anterior** border of the liver, a thin, free, and sharp margin, is the most movable part. Opposite the longitudinal fissure it presents a notch, and, to the right of this, there is often another slight notch opposite the fundus of the gall-bladder.

The **posterior** border, which is directed backwards and upwards, is thick and rounded on the right side, but becomes gradually thinner towards the left. It is the most fixed part of the organ, and is firmly attached by areolar tissue to the diaphragm. This border of the liver is curved opposite to the projection of the vertebral column, and has a deep groove for the reception of the ascending vena cava.

Of the two **lateral** borders of the liver, the **right** is placed lower down, and is thick and obtuse; whilst the **left** is the thinnest part of the gland, is raised to a higher level, and reaches the cardiac part of the stomach.

**LIGAMENTS.**—The five ligaments of the liver are, with one exception, only folds of serous membrane. One of these, the **coronary** ligament, is a reflection of peritoneum around the somewhat triangular portion of the posterior border of the liver, which is immediately adherent to the diaphragm and at either end is continued into two short folds—the **right** and **left lateral** or **triangular** ligaments, of which the left is the longer and more distinct. Another of these so-called ligaments is the **broad, falciform, or suspensory** ligament, a wide thin membrane, formed of two cohering layers of peritoneum. By one of its margins it is connected with the under surface of the diaphragm, and with the sheath of the right rectus muscle of the abdomen as low as the umbilicus; by another it is attached along the convex surface of the liver, from the posterior border to the notch in the anterior border: the remaining margin is free, and contains between its layers the **round ligament**, a dense fibrous cord, the remnant of the umbilical vein of the fœtus, which ascends from the umbilicus, within the lower edge of the broad ligament, and enters the longitudinal fissure on the under surface.

**POSITION WITH REGARD TO NEIGHBOURING PARTS.**—Occupying the right hypochondriac region, and extending across the epigastric region into a part of the left hypochondrium, the liver is accurately adapted to the vault of the diaphragm above, and is covered, to a small extent in front, by the abdominal parietes. The right portion reaches higher beneath the ribs than the left, corresponding thus with the elevated position of the diaphragm on the right side. The liver is separated by the diaphragm from the concave base of the right lung, the thin margin of which descends so as to intervene between the surface of the body and the solid mass of the liver.

The convex surface is protected, on the right, by the six or seven lower ribs, and in front by the cartilages of the same and by the ensiform cartilage—the diaphragm, of course, being interposed. The situation of the liver is modified by the position of the body, and also by the movements of respiration; thus, in the upright or sitting posture, it reaches below the margin of the thorax; but in the recumbent position ascends an inch or an inch and a half higher up,

and is entirely covered by the ribs, except a small portion opposite the substernal notch. Again, during a deep inspiration, the liver descends below the ribs, and in expiration retires upwards behind them. In females it is often permanently forced downwards below the costal cartilages, owing to the use of tight stays; sometimes it reaches nearly as low as the crest of the ilium; and, in many such cases, its convex surface is indented from the pressure of the ribs.

To the left of the longitudinal fissure the liver is in contact with the pyloric extremity and anterior surface of the stomach, on which it moves freely. When the stomach is quite empty, the left part of this surface of the liver may overlap the cardiac end of that viscus. To the right of the longitudinal fissure the liver rests upon the first part of the duodenum and the hepatic flexure of the colon. Farther back it is in contact with the upper part of the right kidney and suprarenal capsule.

**VESSELS AND NERVES.**—The two vessels by which the liver is supplied with blood are the hepatic artery and the vena portæ. The **hepatic artery** (fig. 273, 14), a branch of the cœliac axis, is small in comparison with the organ to which it is distributed. It enters the transverse fissure, and there divides into a right and left branch, for the two principal lobes.

By far the greater part of the blood which passes through the liver,—and in this respect it differs from all other organs of the human body,—is conveyed to it by a large vein, the **vena portæ** (fig. 273, 15). This vein is formed by the union of the veins of the stomach, intestines and omenta as well as those of the pancreas and spleen, and also those from the gall-bladder. It enters the transverse fissure, or *porta*, and, like the hepatic artery, divides into two principal branches.

The hepatic artery and portal vein, lying in company with the bile-duct, ascend to the liver between the layers of the gastro-hepatic omentum, above the foramen of Winslow, and thus reach the transverse fissure. In this course the bile-duct is to the right, the hepatic artery to the left, and the large portal vein behind the other two. They are accompanied by numerous lymphatic vessels and nerves. The branches of these three vessels accompany one another in their course through the liver nearly to their termination; and are surrounded for some distance by a common areolar investment (Glisson's capsule), which is prolonged into the interior of the organ.

The **hepatic veins**, which convey the blood away from the liver, pursue through its substance an entirely different course from the other vessels, and pass out at its posterior border, where, at the bottom of the fossa already described, they end by two or three principal branches, besides a number of smaller ones, in the vena cava inferior.

The **lymphatics** of the liver, large and numerous, form a deep and a superficial set. Their mode of origin and distribution will be afterwards described.

The **nerves** are derived partly from the cœliac plexus, and partly from the pneumogastric nerves, especially from the left pneumogastric. They enter the liver supported by the hepatic artery and its branches; along with which they may be traced a considerable way in the portal canals, but their ultimate distribution is not known.

**EXCRETORY APPARATUS.**—The excretory apparatus of the liver consists of the hepatic duct, the cystic duct, the gall-bladder, and the common bile-duct.

The **hepatic duct**, formed by the union of a right and left branch, which issue from the bottom of the transverse fissure and unite at a very obtuse angle, descends to the right, within the gastro-hepatic omentum, in front of the vena portæ, and with the hepatic artery to its left. Its diameter is about two lines, and its length nearly two inches. At its lower end it meets with the cystic duct, descending from the gall-bladder; and the two ducts uniting together at an acute angle, form the common bile-duct.

The **gall-bladder** (fig. 273, 20) is a pear-shaped membranous sac, 3 or 4 inches long, about an inch and a half across its widest part, and capable of containing from 8 to 12 fluid-drachms. It is lodged obliquely in a fossa on the under surface of the right lobe, with its large end or *fundus* (21), which projects beyond the anterior border of the liver, directed downwards, forwards, and to the right, whilst its *neck* (22), is inclined in the opposite direction. The gall-bladder is attached above to the liver by areolar tissue and vessels, along the fossa formed between the quadrate lobe and the remainder of the right lobe. Below, it is free and covered by the peritoneum, which is here reflected from the liver, so as to support the gall-bladder. Sometimes, however, the peritoneum completely surrounds the latter, which is then suspended at a little distance from the under surface of the liver. The *fundus*, which is free, projecting, and always covered with peritoneum, touches the abdominal parietes immediately beneath the margin of the thorax, opposite the tip of the tenth costal cartilage. Below, the gall-bladder rests on the commencement of the transverse colon; and, farther back, is in contact with the duodenum, and sometimes with the pyloric extremity of the stomach. The *neck*, gradually narrowing, forms two curves upon itself like the letter S, and then, becoming much constricted, and changing its general direction altogether, it bends downwards and terminates in the cystic duct.

The gall-bladder is supplied with blood by the *cystic* branch of the right division of the hepatic artery, along which vessel it also receives nerves from the cœliac plexus. The cystic veins empty themselves into the vena portæ.

The **cystic duct** is about an inch and a half in length. It runs downwards and to the left, and unites with the hepatic duct to form the common bile-duct.

The **common bile-duct**, *ductus communis choledochus*, the largest of the ducts, being from two to three lines in width, and nearly three inches in length, conveys the bile from the liver and the gall-bladder into the duodenum. It passes downwards and backwards, continuing the course of the hepatic duct, between the layers of the gastro-hepatic omentum, in front of the vena portæ, and to the right of the hepatic artery. Passing behind the first part of the duodenum it reaches the descending portion and continues downwards on the inner and posterior aspect of that part of the intestine, covered by or included in the head of the pancreas, and, for a short distance, in contact with the right side of the pancreatic duct. Together with that duct, it then perforates the muscular wall of the intestine, and, after running obliquely for three quarters of an inch between its coats, and forming an elevation beneath the mucous membrane, it becomes somewhat constricted, and opens by a common orifice with the pancreatic duct on the inner surface of the duodenum, near the junction of the second and third portions of

that intestine, and three or four inches below the pylorus, as already described.

**Varieties.**—The liver is not subject to great or frequent deviation from its ordinary form and relations. Sometimes it retains the thick rounded form which it presents in the fœtus; and it has occasionally been found without any division into lobes. On the contrary, Sæmmerring has recorded a case in which the adult liver was divided into twelve lobes; and similar cases of subdivided liver (resembling that of some animals) have been now and then observed by others. A detached portion, forming a sort of *accessory* liver, is occasionally found appended to the left extremity of the gland by a fold of peritoneum containing blood vessels.

The gall-bladder is occasionally wanting; in which case the hepatic duct is much dilated within the liver, or in some part of its course. Sometimes the gall-bladder is irregular in form, or is constricted across its middle, or, but much more rarely, it is partially divided in a longitudinal direction. Direct communications by means of small ducts (named hepato-cystic), passing from the liver to the gall-bladder, exist regularly in various animals; and they are sometimes found, as an unusual formation, in the human subject.

The right and left divisions of the hepatic duct sometimes continue separate for some distance within the gastro-hepatic omentum. Lastly, the common bile-duct not unfrequently opens into the duodenum, apart from the pancreatic duct.

#### STRUCTURE OF THE LIVER.

The liver has two coverings, viz., a serous or peritoneal, already sufficiently referred to, and a proper areolar coat.

The *areolar* or *fibrous* coat invests the whole gland. Opposite to the parts covered by the serous coat, it is thin and difficult to demonstrate; but where the peritoneal coat is absent, as at the posterior border of the liver, and in the portal fissure, it is denser and more evident. Its inner surface is attached to the hepatic glandular substance, being there continuous with the delicate areolar tissue which lies between the small lobules of the gland. At the transverse fissure it becomes continuous with the *capsule of Glisson*, by which name, as already noticed, is designated a sheath of areolar tissue which surrounds the branches of the portal vein, hepatic artery, and hepatic duct, as they ramify in the substance of the liver, and which becomes more delicate as the vascular branches become smaller.

**Hepatic lobules.**—The proper substance of the liver, which has a mottled aspect when closely observed, is compact, but not very firm. It is easily cut or lacerated, and is not unfrequently ruptured during life from accidents in which other parts of the body have escaped injury. When the substance of the liver is torn, the broken surface is not smooth but coarsely granular, the liver being composed of a multitude of small **lobules** (figs. 274 and 275), which vary from half a line to a line in diameter (1—2 millimetres). *~ c*

These lobules are closely packed polyhedral masses, and in some animals, as in the pig, are completely isolated one from another by areolar tissue continuous with the fibrous coat of the liver and with the capsule of Glisson; but in the human subject, and in most animals, although very distinguishable, they are not completely insulated, being confluent in a part of their extent. Notwithstanding this the lobules of the human liver are sufficiently marked out by interlobular fissures, although these are incomplete.

The lobules of the liver have, throughout its substance, in general the polyhedral form of irregularly compressed spheroids; but on the surface they are flattened and angular. They are all compactly ar-

Fig. 274.

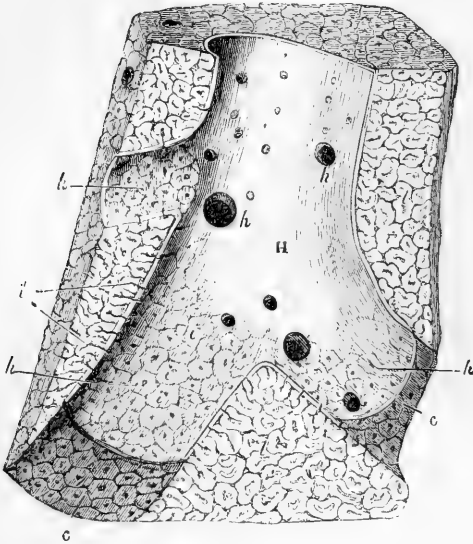


Fig. 274.—SECTION OF A PORTION OF LIVER PASSING LONGITUDINALLY THROUGH A CONSIDERABLE HEPATIC VEIN, FROM THE PIG (after Kiernan). ABOUT 5 DIAMETERS.

H, hepatic venous trunk, against which the sides of the lobules are applied; *h, h, h*, three sublobular hepatic veins, on which the bases of the lobules rest, and through the coats of which they are seen as polygonal figures; *i*, mouth of the intralobular veins, opening into the sublobular veins; *i'*, intralobular veins shown passing up the centre of some divided lobules; *c, c*, walls of the hepatic venous canal, with the polygonal bases of the lobules.

ranged round the sides of branches of the hepatic veins (fig. 274), each lobule resting by a smooth surface or *base*, upon the vein, and being connected with it by a small venous trunklet, which begins in the centre of the lobule, and passes out from the middle of its base to end in the larger subjacent vessel. The small veins proceeding from the centre of the lobules are named the *intralobular* or *central* veins (*i*), and those on which the lobules rest, the *sublobular* veins (*h*). If one of these sublobular veins be opened (as in the figure), the bases of the lobules may be seen through the coats of the vein, which are here very thin, presenting a tessellated appearance, each little polygonal space representing the base of a lobule, and having in its centre a small spot, which is the mouth of the intralobular vein (*i*).

Each lobule consists of a mass of cells penetrated from the circumference to the centre by a close network of blood capillaries, as well as by the minute capillary commencements of the bile-ducts, with the intervention of little other tissue. For the sake of clearness, the disposition of the vessels of the liver may be considered first.

**Blood-vessels.**—The *hepatic veins* commence in the centre of each lobule by the convergence of its capillaries into a single independent

Fig. 275.

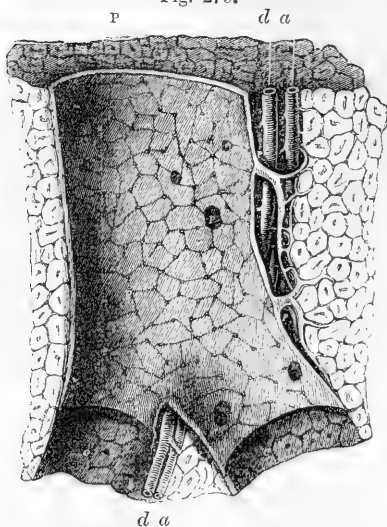


Fig. 275.—LONGITUDINAL SECTION OF A PORTAL CANAL, CONTAINING A PORTAL VEIN, HEPATIC ARTERY, AND HEPATIC DUCT, FROM THE PIG (after Kiernan). ABOUT 5 DIAMETERS.

p, branch of vena portæ, situated in a portal canal, formed amongst the hepatic lobules of the liver; p, p, larger branches of portal vein, giving off smaller ones (i, i), named interlobular veins; there are also seen within the large portal vein numerous orifices of interlobular veins arising directly from it; a, hepatic artery; d, biliary duct; at c, c, the venous wall has been partially removed.

various sizes, and join together. Uniting into larger and larger vessels, they end at length in hepatic venous trunks, which receive no intralobular veins. Lastly, these venous trunks, converging towards the posterior border of the liver, and receiving in their course other sublobular veins, terminate in the vena cava inferior, as already described. In this course the hepatic veins and their successive ramifications are unaccompanied by any other vessel. Their coats are thin; the sublobular branches adhere immediately to the lobules, and even the larger trunks have but a very slight areolar investment connecting them to the substance of the liver. Hence the divided ends of these veins are seen upon a section of the liver as simple open orifices, the thin wall of the vein being surrounded closely by the solid substance of the gland.

The *portal vein* and *hepatic artery*, which, accompanied by the emerging *biliary ducts*, enter the liver at the transverse fissure, have a totally different course, arrangement, and distribution, from the hepatic vein. Within the liver the branches of these three vessels lie together in certain canals, called *portal canals*, which are tubular passages formed in the substance of the gland, commencing at the transverse fissure, and branching upwards and outwards from that part in all directions. Each portal canal (even the smallest) contains one principal branch of the vena portæ, of the hepatic artery, and of the biliary duct (fig. 275); the whole being invested within the larger portal canals by the capsule of Glisson.

The *portal vein* subdivides into branches which ramify *between* the lobules, anastomosing freely around them, and are named *interlobular* or *peripheric* veins. From these, still finer vessels pass into the lobules at their circumference (fig. 278, 3), and end in the capillary network from which the intralobular or central (hepatic) veins take origin.



Within the portal canals the branches of the portal veins receive small "vaginal veins," and also the "capsular veins," from the fibrous coat of the liver, both returning blood which has been distributed by

Fig. 276.




Fig. 276.—CAPILLARY NETWORK OF THE LOBULES OF THE RABBIT'S LIVER (from Kölliker). ABOUT 40 DIAMETERS.

The figure is taken from a very successful injection of the hepatic veins made by Harting: it shows nearly the whole of two lobules, and parts of three others: *p*, portal branches running in the interlobular spaces; *h*, hepatic veins penetrating and radiating from the centre of the lobules.

Fig. 277.

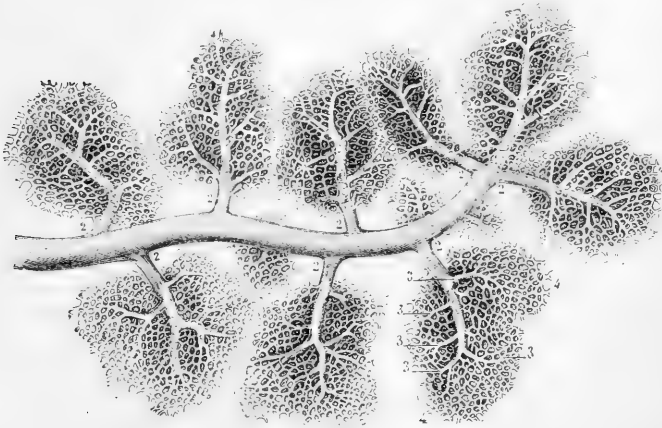


Fig. 277.—INJECTED TWIG OF A HEPATIC VEIN WITH SUBLOBULAR VEINS PASSING INTO THE HEPATIC LOBULES (from Sappey). ABOUT 30 DIAMETERS.

1, small sublobular hepatic vein; 2, intralobular veins passing into the base of the lobules; 3, their smaller subdivisions; 4, capillary network of communication with the extreme ramifications of the vena portæ.

corresponding branches of the hepatic artery to be immediately described.

The *hepatic artery* terminates in three sets of branches, termed vaginal,

Fig. 278.




Fig. 278.—CROSS SECTION OF A LOBULE OF THE HUMAN LIVER, IN WHICH THE CAPILLARY NETWORK BETWEEN THE PORTAL AND HEPATIC VEINS HAS BEEN FULLY INJECTED (from Sappey). 60 DIAMETERS.

1, section of the intralobular or central vein ; 2, its smaller branches collecting blood from the capillary network ; 3, interlobular or peripheric branches of the vena portae with their smaller ramifications passing inwards towards the capillary network in the substance of the lobule.

capsular, and interlobular. The *vaginal* branches ramify within the portal canals, supplying the walls of the ducts and vessels, and Glisson's capsule. The *capsular* branches appear on the surface of the liver spread out on the fibrous coat, accompanied by their veins. The *interlobular* branches accompany the interlobular veins, but are much smaller : they transmit blood directly to a part of the capillary network of the lobules intermediate between the portal and hepatic veins.

The *capillary network* of the lobules is very close, so that commonly the interval between two vessels is not greater than the diameter of one or two liver cells (fig. 279, 280). Moreover the vessels composing it are comparatively large ( $\frac{1}{2500}$ th of an inch), and in specimens in which it has been filled with transparent injection, can be seen, not only to pass in a radiating manner, as before described, between the intra- and interlobular veins, but also in the human subject to be continued from one lobule to another.

The distribution of the portal and hepatic veins within the lobules, as just described, has suggested an explanation of the mottled aspect of the liver, an appearance which formerly led to the erroneous idea of there being two substances in each lobule, one darker than the other. The colour of the hepatic substance itself is pale yellow, and would be uniform throughout, were it not varied according to the quantity of blood contained in its different vessels. Thus, if the system of hepatic veins be congested, the centre of each lobule is dark, and its margin pale ; this is the common case after death, and was named by

Kiernan *passive* congestion. In what is considered an *active* state of hepatic congestion, the dark colour extends to the portal system, across the interlobular fissures, leaving intermediate spaces, which remain as irregular pale spots: this state occurs especially in diseases of the heart. When, on the other hand, the portal system is congested, which is rare, and occurs chiefly in children, the margins of the lobules are dark, and their centres pale.

**The Hepatic Cells.**—The interstices between the blood-vessels are, as before said, almost entirely filled by the hepatic cells. These are of a compressed spheroidal or polyhedral form, having a mean diameter of from  $\frac{1}{1000}$ th to  $\frac{1}{840}$ th of an inch. They possess no cell

membrane. Their substance appears granular and of a faint yellowish tinge, and they contain each a clear round nucleus, within which again are one or two nucleoli. Not unfrequently two nuclei are to be found in a cell; and, on the other hand, it is stated that some of the cells may be altogether devoid of nuclei. In many cases the cells have larger and smaller fat-globules in their interior, which may conceal the nucleus, and the amyloid matter produced by the liver has also been recognised in the cells. When isolated in an indifferent fluid they are said to exhibit slow changes of form. Moreover, myosin has been detected in them. The liver-cells are packed between and around the vessels, and in sections

made at right angles to the intralobular veins, appear as if radiating from the centre of the lobules towards their circumference. They form a continuous network, or sponge-work (fig. 279), the more obvious openings in which are the spaces occupied by the blood-capillaries. The walls of the latter are not, as at first sight they appear to be, immediately in contact with the liver cells, but are separated from them by a delicate membrane composed of flattened cells; the space between this membrane and the capillary wall serves for the passage of lymph (MacGillavry).

The hepatic cells may be washed away from thin sections, and then the network of blood-capillaries is brought more clearly into view; and likewise, according to Henle, narrow bands, which he regards as formed of connective tissue, are to be seen crossing the intervals: some have regarded them as the network of the minute bile passages to be immediately described.

**Commencement of the Ducts.**—The larger bile-ducts accompany,

Fig. 279.

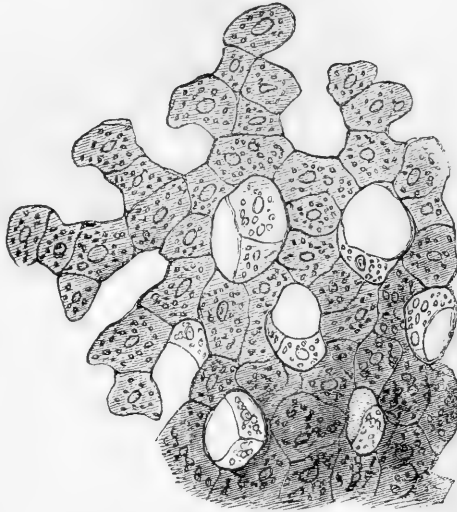


Fig. 279.—A SMALL PORTION OF A LOBULE OF THE HUMAN LIVER HIGHLY MAGNIFIED, SHOWING THE HEPATIC CELLS IN CONNECTION AND THE CAPILLARY SPACES BETWEEN THEM (from Kölliker). 450 DIAMETERS.

as before said, the branches of the portal vein, and ramify in the outer part of each lobule. When a thin section of the hardened tissue is examined under a high power of the microscope, minute apertures may occasionally be observed between the sides of adjacent liver cells (fig. 280). These are the sections of fine intercellular passages which form

Fig. 280.

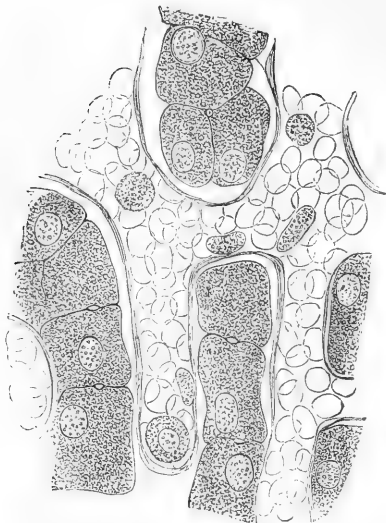


Fig. 281.

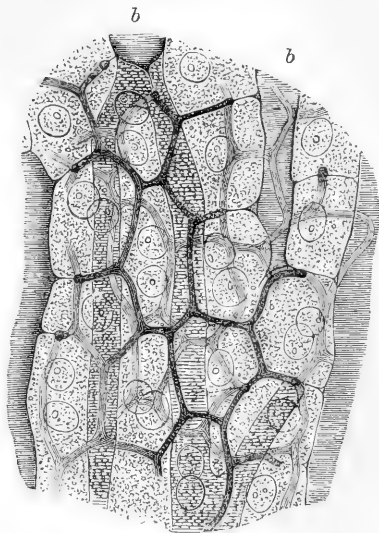


Fig. 280.—SECTION OF LIVER (CHILD) HARDENED IN CHROMIC ACID. HIGHLY MAGNIFIED (Hering).

The liver cells have shrunk somewhat from the walls of the capillaries, which are filled with red corpuscles. Half-a-dozen pale corpuscles are also seen within the vessels. The minute apertures between two cells are the fine bile passages.

Fig. 281.—SECTION OF RABBIT'S LIVER WITH THE INTERCELLULAR NETWORK OF BILIARY CAPILLARIES INJECTED. HIGHLY MAGNIFIED (Hering).

Two or three layers of cells are represented ; *b, b*, blood capillaries.

a close network (fig. 281) between and around the individual cells, much finer and closer than the blood-capillary network, from the branches of which they run apart. These passages, which have been called *biliary capillaries*, may be looked upon as the commencements of the biliary ducts, for towards the circumference of the lobule they open into the ducts, and, indeed, may with care be injected from the trunk of the bile duct, at least in the outer parts of the lobule, as first shown by Budge, Andrejewic and MacGillavry.

To demonstrate the intercellular network throughout the whole extent of the lobules, Chrzonszczewsky's method of natural injection must be employed. He introduced a saturated watery solution of pure sulph-indigotate of soda, in repeated doses, into the circulation of dogs and sucking-pigs, by the jugular vein; and in an hour and a half afterwards the animals were killed and the blood-vessels either washed out with chloride of potassium introduced by the portal vein, or were injected with gelatine and carmine. In specimens prepared in this way the fine network of gall-ducts throughout each lobule is filled with

blue, while the intervening cells remain free from colour. By killing the animals sooner after the injection, the blue colouring matter was found within the hepatic cells, thus demonstrating that it was through their agency that the canals were filled. Further experiments were made in animals in which the portal vein and hepatic artery respectively had been tied, and the result obtained was that, when the hepatic artery had been tied, the peripheral parts of the lobules showed the blue canals, while the centre of each was left colourless; and that, when the portal vein had been tied, the reverse effect was produced—the centre of each lobule showing blue canals, while in the intervening spaces only the larger ducts were seen, showing that, as previously stated, the capillary network of the lobules is in part supplied directly by the hepatic artery.

It is still a matter of doubt whether the intercellular passages above described possess proper walls distinct from the cells, or whether they are to be regarded as mere channels formed by the apposition of corresponding grooves on the sides of the cells, but the balance of evidence appears to be in favour of the former supposition. It is worthy of remark that the biliary capillaries are almost always found on the flattened surfaces, seldom or never running along the corners of the cells.

**Lymphatics of the Liver.**—Lymphatics are seen on the prolongations of Glisson's capsule between the lobules (interlobular), where they accompany the blood-vessels, and in some cases surround and enclose them. They originate from the spaces around the capillaries of the lobules (p. 391). In the pig's liver lymphoid follicles have been noticed by Kisselew and Chrzonszczewsky, in connection with the interlobular lymphatics. These deep lymphatics unite into larger vessels which run along the portal canals and emerge at the portal fissure. They are in communication with a close subperitoneal plexus on the under surface of the organ. The corresponding plexus on the upper surface communicates, through the ligaments of the liver, with the thoracic lymphatics.

**Structure of the Ducts.**—The larger bile-ducts have strong distensible areolar coats, containing abundant elastic tissue, and the largest, a certain amount of plain muscular tissue. They are lined with columnar epithelium. The minute ramifications between the lobules have walls composed simply of a basement membrane, with a lining of columnar epithelium. As they pass into the lobules, however, this columnar epithelium becomes shorter and broader, and approaches more and more in character to the hepatic cells, at the same time filling up the tube so that only a very small passage is left. The basement membrane is no longer complete, and the intercellular bile passages open freely into the minute ducts. In the portal canals, where they are somewhat larger, the ducts present numerous openings on the inner surface, which are scattered irregularly in the larger ducts, but in the subdivisions are arranged in two longitudinal rows, one at each side of the vessel. These openings were formerly supposed to be the orifices of mucous glands; but while the main ducts are studded with true mucous glands of lobulated form and with minute orifices, the openings now referred to belong to saccular and tubular recesses, which are often branched and anastomosing, and may be beset all over with caecal projections (Theile). Sappey and Henle, who have made these recesses the subject of special investigation, find that they are so numerous as sometimes to conceal the parent tube, and on this Henle was led to base a suggestion (*System. Anat.*) that they and not the liver cells are engaged in the secretion of bile.

In the duplicature of peritoneum forming the left lateral ligament of the liver, and also in the two fibrous bands which sometimes bridge over the fossa for the vena cava and the fissure of the umbilical vein, there have been found biliary ducts of considerable size which are not surrounded with lobules. These *aberrant ducts* as they are called, were described by Ferrein and afterwards by Kiernan; they anastomose together in form of a network, and are accompanied by branches of the vena portæ, hepatic artery, and hepatic vein.

**Structure of the Gall-bladder.**—Besides the peritoneal investment and the mucous lining, the gall-bladder possesses an intermediate muscular and connective tissue coat, of considerable strength. This consists mainly of bands of dense shining white fibres, which interlace in all directions. Intermingled with these are plain muscular fibres, which have principally a longitudinal direction, but some run transversely. This coat forms the framework of the organ, and supports the larger blood-vessels and lymphatics. The nerves form a gangliated plexus in it; partly also immediately beneath the serous coat (L. Gerlach).

The *mucous membrane*, which is generally strongly tinged with bile, is elevated upon its inner surface into very numerous small ridges, which, uniting together into meshes, leave between them depressions of different sizes and of various polygonal forms. This gives the interior of the gall-bladder an alveolar aspect, which is similar to what is seen on a smaller scale in the vesiculæ seminales. These alveolar intervals become smaller towards the fundus and neck of the gall-bladder; and at the bottom of the larger ones, other minute depressions, which may be seen with a simple lens, lead into numerous mucous recesses. The whole of the mucous membrane is covered by columnar epithelium, and it secretes an abundance of viscid mucus.

At the places where the neck of the gall-bladder curves on itself there are strong folds of its mucous and areolar coats projecting into the interior.

In the *cystic duct*, the mucous membrane is elevated internally in a similar manner into a series of crescentic folds, which are arranged in an oblique direction, and succeed closely to each other, so as to present very much the appearance of a continuous spiral valve. When distended, the outer surface of the duct appears to be indented in the situation of these folds, and dilated or swollen in the intervals, so as to present an irregularly sacculated or twisted appearance. In the structure of its wall, the cystic duct resembles the gall-bladder.

## THE PANCREAS.

The *pancreas* (fig. 282, *h t*) is a long, narrow, flattened gland of a reddish cream colour, larger at one end than at the other, and lying across the posterior wall of the abdomen, behind the stomach, and opposite the first lumbar vertebra. Its larger end, the *head*, turned to the right, is embraced by the curvature of the duodenum, whilst its left or narrow extremity, the *tail*, reaches to a somewhat higher level, and is in contact with the spleen.

The pancreas varies considerably, in different cases, in its size and weight. It is usually from 6 to 8 inches long, about  $1\frac{1}{2}$  inch in average breadth, and from half an inch to an inch in thickness, being thicker at its head and along its upper border than elsewhere. The weight of the gland, according to Krause and

Clendenning, is usually from  $2\frac{1}{4}$  oz. to  $3\frac{1}{2}$  oz. ; but Meckel has noted it as high as 6 oz., and Sæmmerring as low as  $1\frac{1}{2}$  oz.

The anterior surface of the pancreas is covered with the posterior wall of the sac of the omentum, and is concealed by the stomach, which

Fig. 282.

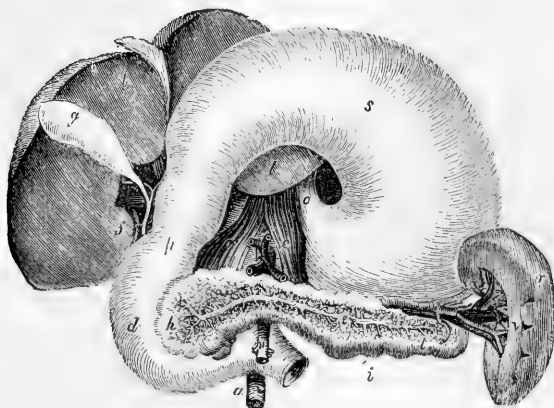


Fig. 282.—VIEW OF THE PANCREAS AND SURROUNDING ORGANS. 1-5th.

In this figure, which is altered from Tiedemann, the liver and stomach are turned upwards to show the duodenum, the pancreas, and the spleen : *l*, the under surface of the liver ; *g*, gall-bladder ; *f*, the common bile duct, formed by the union of the cystic duct from the gall-bladder, and the hepatic duct coming from the liver ; *o*, the cardiac end of the stomach, where the œsophagus enters ; *s*, under surface of the stomach ; *p*, pyloric end of the stomach ; *d*, duodenum ; *h*, head of the pancreas ; *t*, tail, and *i*, body of that gland ; the substance of the pancreas is removed in front, to show the pancreatic duct (*e*) and its branches ; *r*, the spleen ; *v*, the hilum, at which the blood-vessels enter ; *c, c*, crura of the diaphragm ; *n*, superior mesenteric artery ; *a*, aorta.

glides upon it. The posterior surface is attached by areolar tissue to the vena cava, the aorta, the superior mesenteric artery and vein, the commencement of the vena portæ, and the pillars of the diaphragm (*c, c*), all of which parts, besides many lymphatic vessels and glands, are interposed between it and the upper lumbar vertebræ : to the left of the vertebral column it is attached similarly to the left suprarenal capsule and kidney and to the renal vessels. Of the large vessels situated behind the pancreas, the superior mesenteric artery (*n*) and vein are embraced by the substance of the gland, the lower extremity of the head curving somewhat behind them,\* so as sometimes to enclose these vessels in a complete canal, through which they pass downwards and forwards, and then emerge from beneath the lower border of the pancreas, between it and the termination of the duodenum. The cœliac axis is above the pancreas ; and in a groove along the upper border of the gland are placed the splenic artery and vein, the vein pursuing a straight, and the artery a tortuous course, and both supplying numerous branches to the pancreas, the narrow extremity of which is thus attached to the inner surface of the spleen (*r*). The head of the pancreas, embraced by

\* This part of the gland is sometimes marked off from the rest, and is then named the *lesser pancreas*.

the inner curved border of the duodenum, is attached more particularly to the descending and transverse portion of that intestine, encroaching slightly on both the anterior and posterior surface. The ductus communis choledochus passes down behind the head of the pancreas, and is generally received into a groove or canal in its substance.

**Structure.**—The pancreas belongs to the class of compound racemose glands. In its general characters, and also in its intimate structure it closely resembles the salivary glands, to the description of the minute structure of which the reader is referred (p. 339). It is somewhat looser and softer in its texture than those organs, the lobes and lobules being less compactly arranged.

The alveolar cells differ from those of the submaxillary gland in not containing mucus, resembling in this respect the cells of the parotid: moreover, the columnar cells of the ducts appear to be devoid of the striated base seen in those of the submaxillary, and the ducts themselves have an irregular, angular shape: but in all essential points of structure, and in the distribution of the vessels and nerves, the two glands, as far as is known, entirely agree.

The principal excretory duct (fig. 282, *e*), called the **pancreatic duct** or **canal of Wirsung** (by whom it was discovered in the human subject in 1642), runs through the entire length of the gland, from left to right, buried completely in its substance, and placed rather nearer its lower than its upper border. Commencing by the union of the small ducts derived from the groups of lobules composing the tail of the pancreas, and receiving in succession at various angles, and from all sides, the ducts from the body of the gland, the canal of Wirsung increases in size as it advances towards the head of the pancreas, where, amongst other large branches, it is usually joined by one derived from that portion of the gland called the lesser pancreas. Curving slightly downwards, the pancreatic duct then comes into contact with the left side of the ductus communis choledochus, which it accompanies to the back part of the descending portion of the duodenum. Here the two ducts, placed side by side, pass very obliquely through the muscular and areolar coats of the intestine, and terminate, as already described, on its internal mucous surface, by a common orifice, situated at the junction of the descending and horizontal portions of the duodenum, between three and four inches below the pylorus. The pancreatic duct, with its branches, is readily distinguished from the glandular substance, by the very white appearance of its thin fibrous walls. Its widest part, near the duodenum, is from 1 line to  $1\frac{1}{2}$  line in diameter, or nearly the size of an ordinary quill; but it may be easily distended beyond that size. It is lined by a remarkably thin and smooth mucous membrane, which near the termination of the duct occasionally presents a few scattered recesses.

**Varieties.**—Sometimes the duct is double up to its point of entrance into the duodenum; and a still further deviation from the ordinary condition is not unfrequently observed, in which there is a *supplementary* duct, derived from the lesser pancreas or some part of the head of the gland, opening into the duodenum by a distinct orifice, at a distance of an inch or more from the termination of the principal duct. It sometimes occurs that the pancreatic duct and the common bile duct open separately into the duodenum.

**Vessels and Nerves.**—Like the salivary glands, the pancreas receives its blood-vessels at numerous points. Its arteries are derived from the splenic and from the superior and inferior pancreatico-duodenal branches of the hepatic and



superior mesenteric. Its blood is returned by the splenic and superior mesenteric veins. Its lymphatics terminate in the lumbar vessels and glands. The nerves of the pancreas are derived from the solar plexus.

### THE SPLEEN.

The spleen (fig. 282, *r*) is a soft highly vascular and easily distensible organ, of a dark bluish or purplish grey colour. It is situated in the left hypo-chondrium, between the cardiac end of the stomach, and the diaphragm. It is the largest of the organs termed ductless glands.

The shape of the spleen is somewhat variable: it forms usually a compressed oval mass, placed nearly vertically in the body, and having two faces, one external, convex, and free, and which is turned to the left; the other internal and concave, which is directed to the right, and is applied to the cardiac end or great cul-de-sac of the stomach: it also presents an anterior sharper and a posterior blunter margin.

The convex face of the spleen, smooth and covered by the peritoneum, is in contact with the under surface of the left side of the diaphragm, and corresponds with the ninth, tenth, and eleventh ribs. The internal concave face is divided by a vertical fissure, named the *hilus* (*v*), into an anterior and posterior portion, both covered with peritoneum, continued round the borders from the convex surface. The anterior of these two portions is the larger, and is closely applied to the stomach; the posterior is in apposition with the left pillar of the diaphragm and left suprarenal capsule. The anterior border of the spleen is thinner than the posterior, and is often slightly notched, especially towards the lower part (see fig. 282). The lower end is pointed, and is in contact with the left end of the arch of the colon (splenic flexure), and rests on the costo-colic ligament. The position of the hilus corresponds with the line of attachment of the gastro-splenic omentum, a fold of peritoneum, continuous with the left border of the great omentum, attaching the spleen to the left extremity of the stomach. Along the bottom of this fissure are large openings, which transmit blood vessels, with lymphatics and nerves, to and from the interior of the organ. In some cases there is no distinct fissure, but merely a row of openings for the vessels; and in others the situation of the hilus is occupied by a longitudinal ridge, interrupted by the vascular orifices. A portion of variable extent behind the hilus, and towards its lower end, will usually be observed deriving its peritoneal covering from the sac of the omentum, at least in the young subject.

The spleen varies in magnitude more than any other organ in the body; and this not only in different subjects, but, as may be ascertained by percussion, in the same individual, under different conditions. On this account it is difficult or impossible to state what are its ordinary weight and dimensions: in the adult it measures generally about 5 or  $5\frac{1}{2}$  inches from the upper to the lower end, 3 or 4 inches from the anterior to the posterior border, and 1 or  $1\frac{1}{2}$  inch from its external to its internal surface; and its usual volume, according to Krause, is from  $9\frac{3}{4}$  to 15 cubic inches. In the greater number of a series of cases examined by Reid, its weight ranged from 5 to 7 ozs. in the male, and was somewhat less in the female; but even when perfectly free from disease, it may fluctuate between 4 and 10 ounces. Gray states that the proportion of the spleen to the weight of the adult body varies from 1 : 320 to 1 : 400. In the fœtus the proportion is as 1 : 350. After the age of forty the average weight gradually diminishes, so that in old age the weight of the spleen is to that of the body as 1 : 700. The specific gravity of this organ, according to Haller, Sœmmerring, and Krause is about

1060. In intermittent and some other fevers the spleen is much enlarged, reaching below the ribs, and often weighing as much as 18 or 20 lbs. In enlargement and solidification it has been known to weigh upwards of 40 lbs; and it has been found reduced by atrophy to the weight of two drachms.

Small detached roundish nodules are occasionally found in the neighbourhood of the spleen, similar to it in substance. These are commonly named *accessory* or *supplementary* spleens (*splenculi*; *lienculi*). One or two most commonly occur, but a greater number, and even up to twenty-three, have been met with. They are small rounded masses, varying from the size of a pea to that of a walnut. They are usually situated near the lower end of the spleen, either in the gastro-splenic omentum, or in the great omentum. These separate *splenculi* in the human subject bring to mind the multiple condition of the spleen in some animals; as does also the deeper notching of the anterior margin of the organ which sometimes occurs in man.

#### STRUCTURE OF THE SPLEEN.

The spleen has two membranous investments—a serous coat derived from the peritoneum, and a special albuginous fibro-elastic tunic. The substance of the organ, which is very soft and easily lacerated, is of a dark reddish-brown colour, but acquires a bright red hue on exposure to the air. Sometimes, however, the substance of the spleen is paler, and has a greyish aspect. It also varies in density, being occasionally rather solid, though friable. The substance of the organ consists of a reticular framework of whitish elastic bands or *trabeculae*, of a large proportion of blood-vessels, and of a peculiar intervening pulpy substance, besides nerves and lymphatic vessels.

The **serous** coat is thin, smooth, and firmly adherent to the elastic tunic beneath. It closely invests the surface of the organ, except at the places of its reflection to the stomach and diaphragm, and at the hilus.

The **tunica propria** (284, A), much thicker and stronger than the serous coat, is whitish in colour and highly elastic. It is continuous with the trabecular structure within. Along the hilus this coat is reflected into the interior of the spleen, in the form of large trabeculae, supported and enclosed by which run the blood-vessels and nerves; so that these are, as it were, ensheathed by prolongations of the fibrous coat. These sheaths ramify with the vessels which they include, as far as their finer subdivisions, and are connected with the numerous trabecular processes which pass into the interior from the whole inner surface of the fibrous coat. The arrangement of the sheaths and trabeculae may be easily displayed in the spleen of the ox by pressing and washing out the pulp from a section; and then they are seen to form a close reticulation through the substance. Thus, the proper coat, the sheaths of the vessels, and the trabeculae, all of a highly elastic nature, constitute a distensible framework, which contains in its interstices or areolae the vessels and the red pulpy substance of the spleen. These fibrous structures are composed of interlaced bundles of areolar tissue containing a large amount of fine elastic tissue. In addition to these elements, in the spleen of the pig, the dog, and the cat, and to a smaller extent in that of the ox and sheep, there is found an abundant admixture of plain muscular fibre-cells, resembling those of the middle coat of arteries. A scanty admixture of similar fibres occurs also in the trabeculae and fibrous coat of the human spleen (Meissner, W. Müller). The elasticity of the fibrous coat and trabeculae, together

with whatever amount of muscularity they may possess, renders the spleen capable of the great and sudden alterations in size to which it is subject.

The **pulp** of the spleen is of a dark reddish-brown colour: when pressed out from between the trabeculæ it resembles grumous blood, and, like that, acquires a brighter hue on exposure to the air.

When a thin section is examined under the microscope the pulp is seen to consist of a reticulum of branched connective-tissue corpuscles, which are of various forms and sizes; in some parts little but the intercommunicating branches remaining, forming a fine retiform tissue, in other parts the cells being larger and in closer connection (fig. 285, *p*). These corpuscles, which may be termed the *supporting cells of the pulp*, contain each a clear oval nucleus, like connective tissue cells generally; moreover, in teased-out preparations of the fresh spleen substance it is not uncommon to find within them yellowish pigment granules of various sizes, presumed to be derived from blood corpuscles; indeed, every stage of retrogressive metamorphosis of blood corpuscles may be noticed to occur within them. The interstices between these sustentacular cells are, in sections, always found to be occupied by blood (fig. 285, *b*), the white corpuscles being, however, in rather larger proportion than in ordinary blood, especially in the neighbourhood of the Malpighian corpuscles to be immediately described.

**Blood-vessels.**—The splenic artery and vein, alike remarkable for their great proportionate size, having entered the spleen by six or more branches, ramify in its interior, enclosed within the trabecular sheaths already described. The smaller branches of the arteries leave the trabeculæ, and, passing into the proper substance of the spleen, terminate in small tufts of capillary vessels arranged in pencils (fig. 283).

The external or connective tissue coat of these smaller arteries becomes transformed into lymphoid tissue, which forms a comparatively thick sheath along each. This lymphoid sheath becomes suddenly dilated here and there into small spheroidal bodies, measuring on an average  $\frac{1}{70}$  of an inch in diameter, but varying in size from much smaller than this up to  $\frac{1}{5}$ th of an inch, and closely resembling the lymphoid follicles met with in the intestine and elsewhere. These lymphoid expansions may be seen on the surface of a fresh section of the organ as light-coloured spots scattered in the dark substance composing the pulp, and have been long noticed and described as the **Malpighian corpuscles** of the spleen (fig. 283; fig. 284, *c*). In some cases they are developed upon one side only of the arterial wall, upon which they then appear to be sessile; whilst in other instances—and this is the most frequent in the human subject—the expansion takes place all round the circumference of the vessel, by which they appear to be pierced, and which is generally smaller in these cases and sends off radiating branches which are distributed in the Malpighian corpuscle. This latter then appears attached by a short peduncle to the vessel of which its artery is a branch.

The Malpighian corpuscles are, as just stated, localized expansions of the lymphoid tissue of which the external coat of the smaller arteries of the spleen is formed. The reticulum of the tissue is comparatively open, being almost absent towards the centre of the corpuscle: at the confines it becomes closer; there is, however, no distinct boundary separating it from the retiform tissue of the pulp

(Busk and Huxley). The meshes are densely packed with lymphoid corpuscles, and the tissue is traversed by blood capillaries.

Fig. 283.

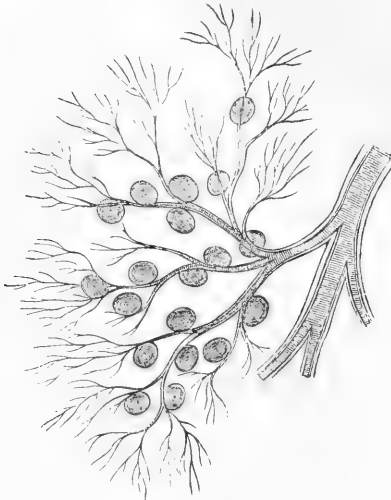


Fig. 283. — SMALL ARTERY FROM DOG'S SPLEEN WITH MALPIGHIAN CORPUSCLES ATTACHED. 10 DIAMETERS (Kölliker).

Fig. 284.

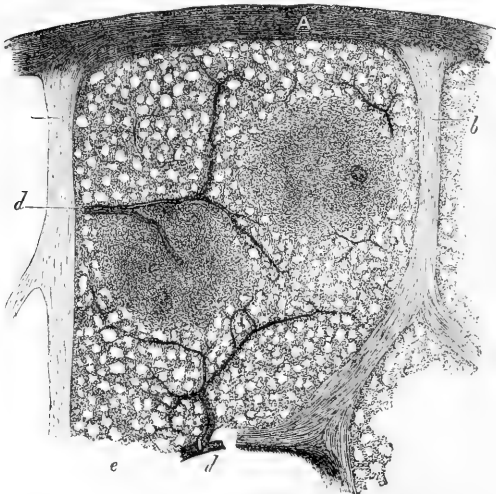


Fig. 284.—VERTICAL SECTION OF A SMALL SUPERFICIAL PORTION OF THE HUMAN SPLEEN (from Kölliker). LOW POWER.

A, peritoneal and fibrous covering; *b*, trabeculae; *c c'*, Malpighian corpuscles, in one of which an artery is seen cut transversely, in the other longitudinally; *d*, injected arterial twigs; *e*, spleen-pulp.

The small arteries terminate in capillaries, the walls of which, as described by W. Müller, after a longer or shorter course, lose their tubular character, the cells composing them acquiring processes and becoming connected by these with the connective tissue cells of the pulp. In this manner their blood flows directly into the interstices of the pulp tissue. The veins, which often exhibit transverse markings, perhaps due to a corresponding arrangement of the retiform tissue on their surface, commence in this tissue in the same manner as the capillaries terminate; that is to say, the layer of flattened cells which lines and mainly composes their walls, on being traced back, loses its epithelioid character, and the cells, becoming thickened and enlarged and their nuclei prominent,

are found to be separated from each other, but connected by processes with, and passing into those of the pulp (fig. 285). The small veins take a different course from the corresponding arteries, for they soon pass to and are conducted upon and within the trabeculae, freely joining and anastomosing, whereas the arteries appear to have few or no anastomoses within the substance of the organ.

From the description above given, it would appear that the blood in passing through the spleen is brought into immediate relation with the elements of the pulp, and no doubt

undergoes important changes in the passage; in this respect resembling the lymph as it passes through the lymphatic glands. Two modifications which are probably effected in it may be here pointed out. In the first place the lymphoid tissue ensheathing the arteries, together with that composing the Malpighian corpuscles, would appear, like the same tissue in the lymphatic glands and other parts, to be the seat of the production of pale blood corpuscles. At the circumference of this tissue, these may pass into the interstices of the pulp, and so get into the blood. It is found, in fact, that the blood of the splenic vein is extremely rich in pale corpuscles. In the second place, red blood-corpuscles would appear to be taken into the interior of the pulp-cells, their colouring matter being transformed into pigment, which is then probably carried to the liver by the splenic vein, to be eliminated with the bile (Kölliker). Splenic cells have, in fact, been noticed, when examined on the warm stage, to take red corpuscles, which were in contact with them, into their interior.

Fig. 285.

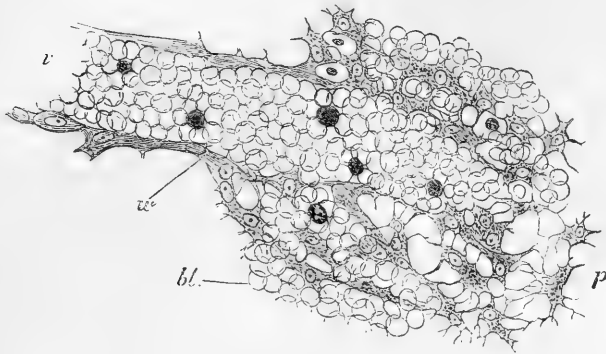


Fig. 285.—THIN SECTION OF SPLEEN-PULP, HIGHLY MAGNIFIED, SHOWING THE MODE OF ORIGIN OF A SMALL VEIN. CHROMIC ACID PREPARATION.

*v*, the vein, filled with blood-corpuscles, which are in continuity with others, *bl*, filling up the interstices of the retiform tissue of the pulp. At *p* the blood-corpuscles have been omitted from the figure, and the branched cells are better seen; *w*, wall of the vein. The small shaded bodies amongst the red blood-corpuscles are pale corpuscles.

The **lymphatics** of the spleen are described as forming two systems, a *trabecular* and a *peri-vascular*. The vessels belonging to the former run in the trabeculae and are in communication with a superficial net-work in the capsule. The peri-vascular take origin in the interstices of the lymphoid tissue which ensheaths the smaller arteries, and forms the Malpighian corpuscles; they do not, therefore, at first form distinct vessels. When these are seen they commonly run in pairs, one on either side of an artery, uniting over it by frequent anastomoses, and sometimes partially or wholly enclosing it. At the hilus the two sets of lymphatics join and proceed along the gastrosplenic omentum to the neighbouring lymphatic glands.

The **nerves**, derived from the solar plexus, surround and accompany the splenic artery and its branches. They have been traced by Remak deeply into the interior of the organ.

The following works on the spleen may be referred to:—Gray, *Structure and Use of the Spleen*, 1854; Busk and Huxley on the Malpighian Bodies, in the Sydenham Society's translation of Kölliker's *Histology*; also Huxley, in *Micro. Jour.*, ii., p. 74; Billroth, in *Zeitschrift f. Wiss. Zoologie*, xi; W. Müller, *Ueber d. fein. Ban der Milz*, 1865, and in Stricker's *Handbook*; Stieda, in *Virch. Arch.*, xxiv.; Schweigger-Seidel, *Virch. Arch.*, xxvii.; Tomsa, *Wiener Sitzungsber.*, xviii.; Kyber, *Arch. f. Mikr. Anat.*, vi.

## THE URINARY ORGANS.

THE urinary organs consist of the *kidneys*, the glands by which the urine is secreted, and the *wreters*, *bladder*, and *wrethra*, serving for its reception and evacuation. As being locally connected, the *suprarenal* capsules are usually described along with these organs, although they have no relation, so far as is known, to the secretion of urine.

## THE KIDNEYS.

The *kidneys*, two in number, are deeply seated in the lumbar region, lying one on each side of the vertebral column, at the back part of the abdominal cavity, and behind the peritoneum. They are on a level with the last dorsal and the two or three upper lumbar vertebræ, the right kidney being a little lower than the left, probably in consequence of the vicinity of the large right lobe of the liver. They are maintained in this position by their vessels, and by a quantity of surrounding loose areolar tissue, which usually contains much fat (*tunica adiposa*).

The kidneys measure about 4 inches in length,  $2\frac{1}{2}$  inches in breadth, and  $1\frac{1}{4}$  inch or more in thickness. The left is usually longer and narrower than the right. The **weight** of the kidney is usually stated to be about  $4\frac{1}{2}$  oz. in the male, and somewhat less in the female.

According to Clendinning, the two kidneys of the male weigh on an average  $9\frac{1}{2}$  oz., and those of the female 9 oz. The estimate of Rayer is  $4\frac{1}{3}$  oz. for each organ in the male, and  $3\frac{2}{3}$  oz. in the other sex. Reid's observations (made on sixty-five males and twenty-eight females, between the ages of twenty-five and fifty-five) would indicate a higher average weight, viz., rather more than  $5\frac{1}{2}$  oz. in the former, and not quite 5 oz. in the latter,—the difference between the two sexes being therefore upwards of half an ounce. The *prevalent* weights of the kidney, as deduced from the tables of Reid, are, in the adult male (160 observations) from  $4\frac{1}{2}$  oz. to 6 oz., and in the adult female (74 observations) from 4 oz. to  $5\frac{1}{2}$  oz. The tables more recently published by Peacock give still higher average results as to the weight of these organs. The two kidneys are seldom of equal weight, the left being almost always heavier than the right. The difference, according to Rayer, is equal to about one-sixth of an ounce. The actual average difference was found by Reid in ninety-three cases (male and female) to be rather more than one-fourth of an ounce. The *proportionate* weight of the two kidneys to the *body* is about 1 to 240. The *specific gravity* of the renal substance is about 1.052.

The surface of the kidney is smooth, and of a deep red colour. Its form is peculiar: it is compressed from before backwards with a convex outer, and concave inner border, and somewhat enlarged extremities.

**Connections.**—The *anterior surface*, more convex than the posterior, looks somewhat outwards, and is partially covered at its upper end by the peritoneum. The duodenum and ascending colon, both destitute of peritoneum behind, are in contact with the anterior surface of the right kidney, and the descending colon with that of the left. The front of the right kidney, moreover, touches the under surface of the liver, and that of the left the lower extremity of the spleen. The *posterior surface*, imbedded in areolar tissue, rests firstly upon the corresponding pillar of the diaphragm, in front of the eleventh and twelfth ribs: secondly, on the anterior layer of lumbar fascia, covering the *quadratus lumborum*

muscle ; and, lastly, on the psoas muscle. The *external border*, convex in its general outline, is directed somewhat backwards towards the wall of the abdomen. The *internal border*, concave and deeply excavated towards the middle, is directed a little downwards and forwards. It presents a longitudinal *fissure* bounded by an anterior and posterior lip, and named the *hilus of the kidney*, at which the vessels, the excretory duct, and the nerves enter or pass out. In this hilus, the renal vein lies in front, the artery and its branches next, and the expanded excretory duct or ureter behind and towards the lower part. The *upper end* of the kidney, which is larger than the lower, is thick and rounded, and supports the suprarenal capsule, which descends a little way upon its anterior surface. This end of the kidney reaches, on the left side, to about the upper border of the eleventh rib, and on the right, half a rib's breadth lower. It is moreover directed slightly inwards, so that the upper ends of the two kidneys are nearer to each other than the lower ends, which are smaller and somewhat flattened, diverge slightly from the spine, and reach nearly as low as the crest of the ilium. It may here be remarked that, by placing the larger end of the kidney upwards and its flatter surface backwards, or by noticing the relation of the parts in the hilus, the side of the body to which the organ belongs may be determined.

**Varieties.**—The kidneys present varieties in form, position, absolute and relative size, and number. Thus, they are sometimes found longer and narrower, and sometimes shorter and more rounded than usual. Occasionally one kidney is very small, whilst the other is proportionately enlarged. The kidneys may, one or both, be situated lower down than usual, even in the pelvis.

Instances are now and then met with in which the two kidneys are joined by their lower ends across the front of the great blood-vessels and vertebral column. The conjunct organ has usually the form of a semicircle, the concavity of which is directed upwards—hence the appellation of the *horse-shoe* kidney. Sometimes two united kidneys are situated on one or other side of the vertebral column, in the lumbar region, or, but much more rarely, in the cavity of the pelvis. In other very rare cases three glandular masses have been found, the supernumerary organ being placed either in front or on one side of the vertebral column, or in the pelvic cavity.

**Obvious Structure.**—The kidney is surrounded by a proper fibrous coat, which forms a thin, smooth, but firm investment, closely covering the organ. It consists of dense fibro-areolar tissue, together with numerous fine elastic fibres, and can easily be detached from the substance of the gland, to which it adheres by minute processes of connective tissue and vessels.

On splitting open the kidney by a longitudinal section, from its outer to its inner border, the fissure named the hilus (fig. 286, *h, h*) is found to extend some distance into the interior of the organ, forming a cavity called the *sinus* of the kidney (*s*). This is enclosed on all sides except at the hilus by the solid substance of the organ ; and is lined by an inward prolongation of the fibrous coat. The solid part consists of a *cortical* and a *medullary* substance ; the latter being arranged in separate conical masses named “pyramids of Malpighi,” with their broad bases (*b, b*) directed towards the surface, and their points towards the sinus, where they form prominent *papillæ*. The pyramids are imbedded in the cortical substance, which separates them from each other, and encloses them everywhere except at the papillæ, which emerge from it and project into the sinus.

The external or cortical substance (*a*) is situated immediately within the fibrous capsule, and forms the superficial part of the organ throughout its whole extent to the depth of about two lines, and moreover sends

Fig. 286.

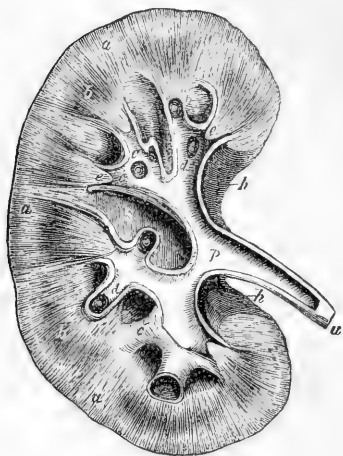


Fig. 286.—PLAN OF A LONGITUDINAL SECTION THROUGH THE PELVIS AND SUBSTANCE OF THE RIGHT KIDNEY. ONE-HALF THE NATURAL SIZE.

*a*, the cortical substance; *b, b*, broad part of two of the pyramids of Malpighi; *c, c*, the divisions of the pelvis named calices, or infundibula, laid open; *c'*, one of these unopened; *d, d*, summit of the pyramids or papillæ projecting into calices; *e, e*, section of the narrow part of two pyramids near the calices; *p*, pelvis or enlarged portion of the ureter within the kidney; *u*, the ureter; *s*, the sinus; *h*, the hilus.

This, within the sinus, divides usually into three, but sometimes only two primary tubular divisions, and these at length end in a larger number of short, truncated but comparatively wide branches named *calices* or *infundibula*, which receive the papillæ into their wide mouths and are attached around the bases of those prominences, from which, of course, they catch the issuing urine.

A single calix often surrounds two, sometimes even three papillæ, which are in that case united together; hence, the calices are in general not so numerous as the papillæ. The spaces between the calices are occupied by a considerable amount of fat, imbedded in which are seen the main branches of the renal vessels.

Like the rest of the ureter, the pelvis and greater part of the calices consist of three coats, viz., a strong external fibro-areolar and elastic tunic, which becomes continuous around the bases of the papillæ with that part of the proper coat of the kidney which is continued into the sinus; secondly, a thin internal mucous coat, which, or at least its epithelium, is reflected over the summit of each papilla; and thirdly,

prolongations inwards (*septula renum*, or *columnæ Bertini*) between the pyramids as far as the sinus and bases of the papillæ. It is of a nearly uniform light crimson brown appearance, and is soft and easily lacerated in directions vertical to the surface. The medullary portion of the kidney is more dense than the cortical, and is distinctly striated, owing to its consisting of small diverging uriniferous tubes, and to its blood-vessels being arranged in a similar manner. There are generally more than twelve pyramids, but their number is inconstant, varying from eight to eighteen. Towards the papillæ the pyramids are of a lighter colour than the cortical substance, but at their base they are usually purplish and darker.

**Excretory Apparatus.** — On squeezing a fresh kidney which has been split open, a little urine will be seen to drain from the papillæ by fine orifices on their surface. The secretion is carried away and conveyed into the bladder by the ureter. This long tube on being traced up to the kidney is seen to be somewhat enlarged, and then to expand, as it enters the fissure, into a large funnel-shaped dilatation named the *pelvis*.



between these two, a double layer of muscular fibres, longitudinal and circular. The longitudinal fibres are lost near the extremity of the calix, but the circular fibres, according to Henle, form a continuous circular muscle round the papilla where the wall of the calix is attached to it.

The pyramidal masses found in the adult kidney indicate the original separation of this gland into lobules in the earlier stages of its growth (fig. 299). Each of these primitive lobules is in fact a pyramid surrounded by a proper investment of cortical substance, and is analogous to one of the lobules of the divided kidneys, seen in many of the lower animals. As the human kidney continues to be developed, the adjacent surfaces of the lobules coalesce and the gland becomes a single mass; the contiguous parts of the originally separate cortical investments, being blended together, form the partitions between the pyramids already described. Moreover, upon the surface of the kidney even in the adult, after the removal of the fibrous capsule, faintly marked furrows may be traced on the cortical substance, opposite the intervals in the interior between the several Malpighian pyramids; and not unfrequently instances occur in which a deeper separation of the original lobules by grooves remains apparent in the adult kidney.

**Tubuli uriniferi.**—On examining the summit of one of the papillæ carefully, especially with the aid of a lens, a number of small orifices may be seen varying in diameter from  $\frac{1}{300}$ th to  $\frac{1}{200}$ th of an inch. They are frequently collected in large numbers at the bottom of a slight depression or *foveola* found near the summit of the papilla, but most commonly the surface is pitted over with about a score of small depressions of this sort. On tracing these minute openings into the substance of the pyramids, they are discovered to be the mouths of small tubes or ducts, the *uriniferous tubes* before mentioned, which thus open upon the surface of the several papillæ into the interior of the calices.

As these tubuli pass up into the pyramidal substance, they bifurcate again and again at very acute angles, their successive branches running close together in straight and

Fig. 287.

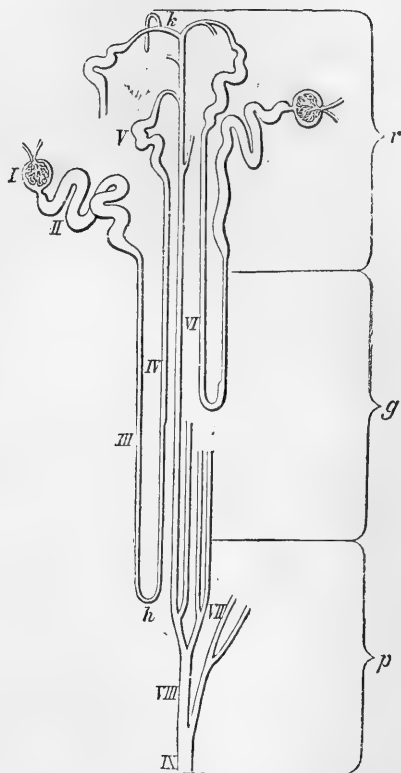


Fig. 287.—DIAGRAM OF THE COURSE AND ARRANGEMENT OF THE URINIFEROUS TUBES (from Ludwig).

*p*, corresponds to the apical part, and *g*, to the base of a pyramid of Malpighi; *r*, cortical part; IX, excretory tube; VIII, VII, VI, straight or collecting tube with its branches; V, junctional tube; IV, ascending limb of Henle's loop (*h*); III, descending limb; II, commencing convoluted tube; I, Malpighian capsule with glomerulus.

slightly diverging lines, and they continue thus to divide and subdivide until they reach the sides and bases of the pyramids, whence they pass, greatly augmented in number, into the cortical substance, where they become convoluted. In the cortical part the straight tubules belonging to a Malpighian pyramid are continued for some way, in several groups or bundles, the tubules in the centre of which approach nearer the surface than those at the sides, which sooner become convoluted, so that conical bundles are formed which have been termed *pyramids of Ferrein*, several of which therefore correspond to a single Malpighian pyramid.

The tubes commence in the cortical substance by spherical dilatations (fig. 287, 1) enclosing like a capsule the vascular Malpighian tufts to be afterwards described. Arising in this manner, the tubes are at first much convoluted (II); they then become smaller (III), pass straight down in the pyramid towards the papilla, and return again (IV), forming the *looped tubes of Henle*. Each of these tubes on returning to the cortical substance becomes again convoluted (V), and joins one of the straight *collecting tubes* (VI). This part is named the *junctional tube*. The collecting tubes uniting together eventually form the *excretory tubes* (IX) (often called *ducts of Bellini*), which open on the papillæ.

**Structure of the tubules.**—The tubules consist in every case of a basement membrane and epithelium, but the form and character of the

Fig. 288.



Fig. 288.—CONVOLUTED TUBULES OF KIDNEY. ABOUT 400 DIAMETERS.

*a*, transverse, *a'*, longitudinal section of a tubule from the human kidney; *b*, portion of a tubule from the dog's kidney, showing the striated appearance of the base of the cells, somewhat analogous to that observed in the tubules of the submaxillary gland.

latter, as well as the size of the tubes, varies considerably in the different parts. In the straight or collecting and excretory tubes the epithelium is columnar in form, the cells are distinct, and the lumen of the tube is of considerable size. These tubules are largest near their termination, at a short distance from which within the papillæ, their diameter varies, according to Huschke, from  $\frac{1}{240}$ th to  $\frac{1}{430}$ th of an inch. Further on in the pyramid they become smaller, measuring about  $\frac{1}{600}$ th of an inch in diameter, and then do not diminish as they continue to bifurcate, but remain nearly of the same uniform average diameter.

The convoluted tubes (*tubuli contorti*), which form the greater part of the cortical substance, and, together with vessels and connecting stroma, the whole of its outermost portion, vary in diameter, but com-

Fig. 290.

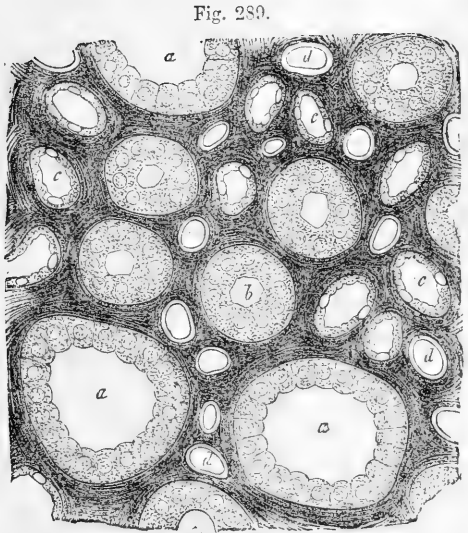


Fig. 289.

Fig. 289.—TRANSVERSE SECTION OF A PAPILLA OF THE PIG'S KIDNEY. 400 DIAMETERS (Kölliker).

*a, a*, collecting tubes with short columnar epithelium; *b, b*, larger; *c, c*, smaller tubes of Henle; *d, d*, blood-vessels.

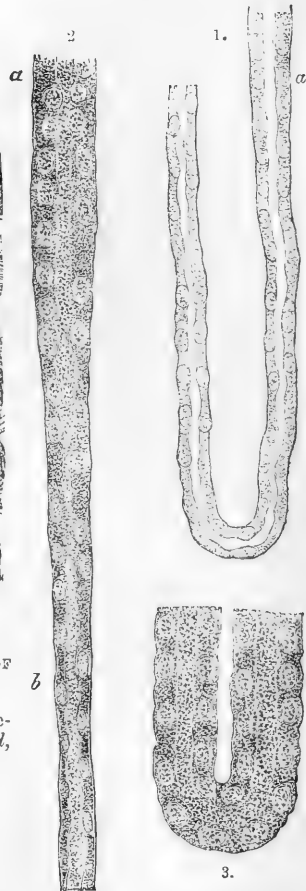

Fig. 290.—TUBES OF HENLE, FROM THE PIG'S KIDNEY. 400 DIAMETERS (Kölliker).

1, loop formed by the narrower variety of Henle's tube; 2, passage of the broader variety, *a*, into the narrower, *b*; 3, loop formed by the broader variety of tube, with granular epithelium.

mously maintain the same average width as the smaller straight tubes, namely  $\frac{1}{600}$ th of an inch. In the convoluted tubes the epithelium is extremely granular, the nuclei are, in the fresh state, for the most part obscured, and the epithelium in many cases almost fills the tubule, so as to leave but a comparatively small lumen. In most animals it is scarcely possible to make out the lines of junction between the individual cells (fig. 288, *b*, from the dog), but in the human kidney the latter are much more distinct (fig. 288, *a, a'*), being separated by clefts, which extend almost to the basement membrane.

Fig. 291.

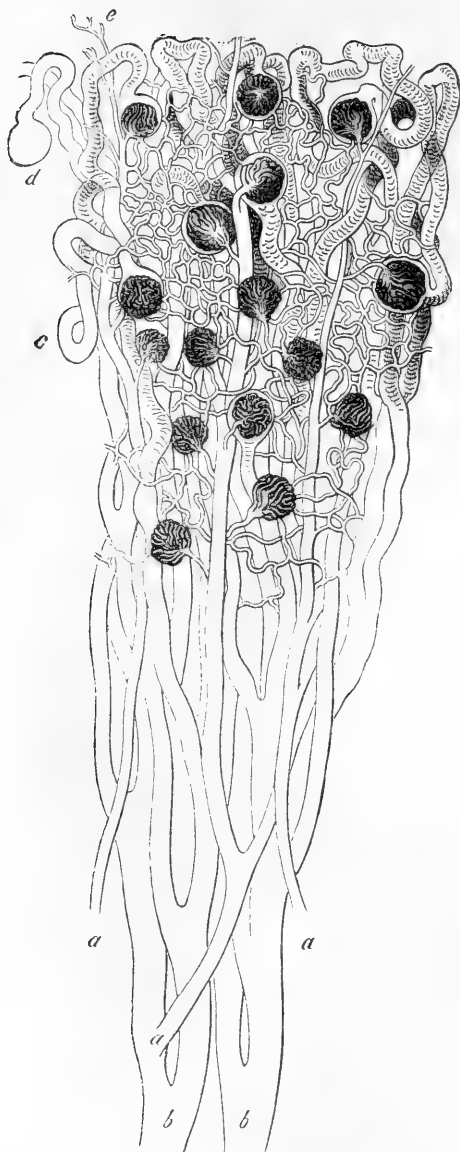


Fig. 291.—DIAGRAMMATIC REPRESENTATION OF A PART OF THE STRAIGHT AND CONVOLUTED URINIFEROUS TUBES WITH THE GLOMERULI (from Frey, after a drawing by Müller).

*b, b*, two large straight tubes in the medullary substance of the pyramid; *c*, convoluted tubes with several of their terminations in the Malpighian capsules as in *d*; *a, a*, three arteries passing up the pyramid and dividing into branches to the glomeruli; the efferent vessels are also seen, and the network of capillaries between them and the veins. The looped tubules of Henle are not represented.

According to the description of Heidenhain, the epithelium of these tubules mainly consists of minute thickly-set rod-shaped particles, which rest by one end against the basement membrane, whilst the other projects towards the centre of the tube, surrounding the nuclei, which are imbedded in a certain amount of unaltered protoplasm. He states that it is the optical sections of these "rods" which produce the well-known granular appearance of the epithelium of the convoluted tubules.

The descending limb of the loop of Henle is very small in diameter, but has a distinct lumen, being lined by flattened cells, each with an oval nucleus which produces a slight bulging into the interior of the tube (fig. 289, *c, e*; fig. 290, 1). The ascending limb is much wider than the descending, but its lumen is comparatively small, for the epithelium approaches more in character to that of the convoluted tubules having a granular appearance, and almost filling the tube (fig. 289, *b*; fig. 290, 3). The bend of the loop is formed sometimes by the larger, sometimes by the smaller kind of tubule, Schweigger-Seidel.

Imbedded among the convoluted tubules in irregular rows between the pyramids of Ferrein are the **Malpighian corpuscles**. These are small rounded bodies about  $\frac{1}{120}$ th of an inch in dia-

meter, but sometimes only  $\frac{1}{200}$ th or  $\frac{1}{70}$ th of an inch. They consist each of a membranous capsule, containing a tuft of blood-vessels. The vascular tuft or *glomerulus* is formed by a small *afferent* artery (fig. 292, *f*; fig. 293, *v*, *v'*), breaking up at once into a number of minute branches, which form convoluted loops, and are re-united in a single, somewhat smaller *efferent* vessel (fig. 292, *g*; fig. 293, *e*, *e'*), placed close

Fig. 292,

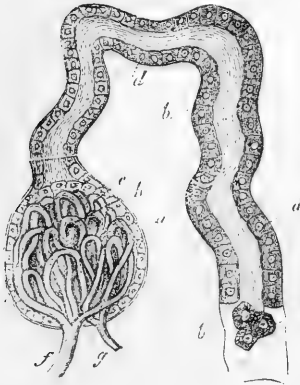


Fig. 293.

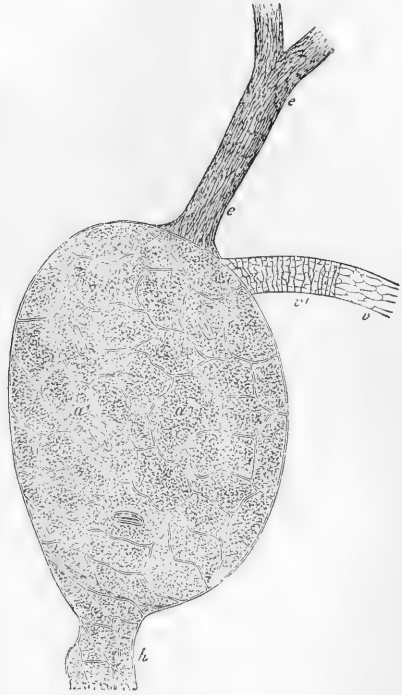


Fig. 292.—SEMIDIAGRAMMATIC REPRESENTATION OF A MALPIGHIAN BODY IN ITS RELATION TO THE URINIFEROUS TUBE (from Kölliker). 300 DIAMETERS.

*a*, capsule of the Malpighian body continuous with *b*, the membrana propria of the coiled uriniferous tube; *c*, epithelium of the Malpighian body; *d*, epithelium of the uriniferous tube; *e*, detached epithelium; *f*, afferent vessel; *g*, efferent vessel; *h*, convoluted vessels of the glomerulus.

Fig. 293.—MALPIGHIAN CORPUSCLE FROM THE RABBIT'S KIDNEY: NITRATE OF SILVER PREPARATION. HIGHLY MAGNIFIED (Ludwig).

*v*, vas afferens, showing its epithelioid lining: at *v'*, the transverse muscular fibres are also seen; *e*, vas efferens; *a*, *a'*, basement membrane of capsule with epithelioid markings, passing at *h* into that of the commencing uniniferous tubule.

to the afferent: the further history of the afferent and efferent vessels will be given later. The *capsule*, by which the glomerulus is enclosed, is formed of a basement membrane lined by flattened epithelium (fig. 294, *d*). It receives the two vessels at one part; and at another is continued as already stated into a convoluted uriniferous tubule, as was first pointed out by Bowman (fig. 292). The epithelium lining the capsule is reflected over the glomerus, the cells becoming thicker and less flattened (fig. 294, *c*); it is doubtful whether in the adult they in all cases form a continuous layer over the vascular tuft, but in the fœtus it is not difficult to recognise both layers. Sometimes the tuft is divided into two or or three bunches of vessels, in which case the

epithelium dips down between the bunches. The basement membrane, both of the capsule and of the uriniferous tubule, is formed of flat epithelioid cells (fig. 293, *a, a'*).

Fig. 294.

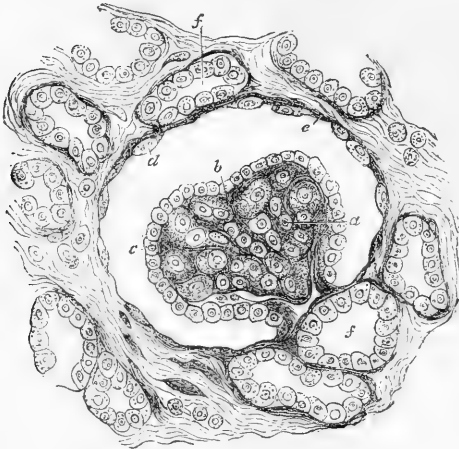


Fig. 294.—SECTION OF CORTICAL SUBSTANCE OF KIDNEY: HUMAN FÆTUS. HIGHLY MAGNIFIED (Klein).

*a*, glomerulus with blood-vessels not fully developed; *c*, epithelium covering it continuous with *d*, flattened epithelium lining Bowman's capsule; *f, f*, convoluted tubes.

dividing and subdividing, to reach the bases of the pyramids, where they form arches between the cortical and medullary parts, which how-

**Blood-vessels.** — The kidneys are highly vascular, and receive their blood from the renal arteries, which are very large in proportion to the size of the organs they supply. Each renal artery divides into four or five branches, which, passing in at the hilus, between the vein and ureter, may be traced into the sinus of the kidney, where they lie amongst the infundibula, together with which they are usually embedded in a quantity of fat. Penetrating the substance of the organ between the papillæ, the arterial branches enter the cortical substance found in the intervals between the pyramids of Malpighi, and proceed in this,

Fig. 295.

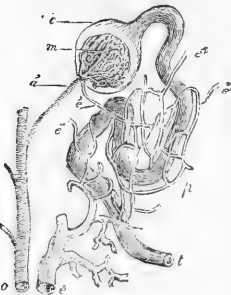


Fig. 295.—DIAGRAM SHOWING THE RELATION OF THE MALPIGHIAN BODY TO THE URINIFEROUS DUCTS AND BLOOD-VESSELS (after Bowman).

*a*, one of the interlobular arteries; *a'* afferent artery passing into the glomerulus; *c*, capsule of the Malpighian body; *t*, uriniferous tube; *e, e'*, efferent vessels which subdivide in the plexus *p*, surrounding the tube, and finally terminate in the branch of the renal vein, *e*.

ever are not complete, and in this respect differ from the freely anastomosing venous arches which accompany them. From the arches smaller "interlobular" arteries (fig. 296, *ai*) are given off, which pass outwards between the double layers of Malpighian capsules which intervene between the pyramids of Ferrein; and from these interlobular arteries are derived the afferent arteries of the glomeruli. The renal arteries give branches likewise to the capsule of the kidney which anastomose with branches of the lumbar arteries, and that so freely that Ludwig was able partially to inject the kidneys

Fig. 296.

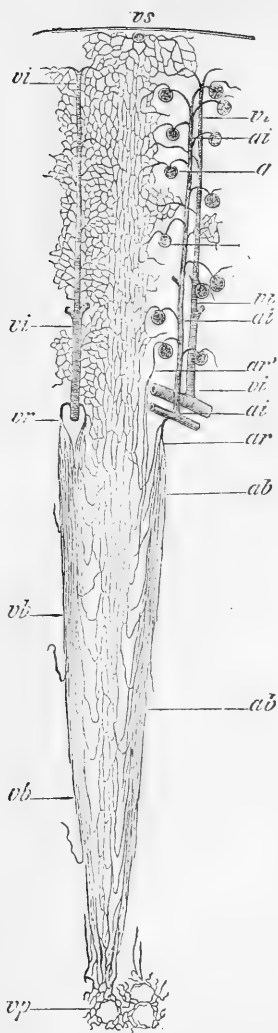


Fig. 297.

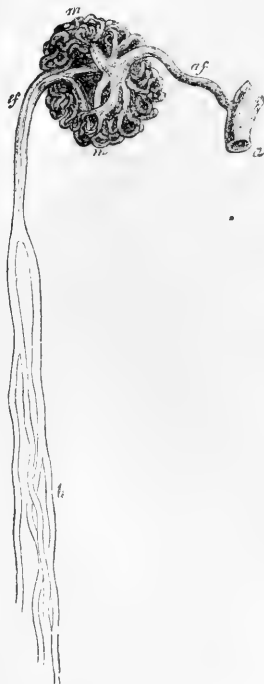

Fig. 297. — INJECTED GLOMERULUS FROM THE INNER PART OF THE CORTICAL SUBSTANCE OF THE HORSE'S KIDNEY. 70 DIAMETERS (from Kölliker after Bowman).

*a*, interlobular artery; *af*, afferent artery; *m*, convoluted vessels of the glomerulus; *ef*, efferent or straight arteriole; *b*, its subdivision in the medullary substance.

Fig. 296. — DIAGRAM OF THE DISTRIBUTION OF THE BLOOD-VESSELS IN THE KIDNEY (from Ludwig).

*ai*, *ai*, interlobular artery giving off numerous *vasa afferentia* to the glomeruli, *g*; the *vasa efferentia* are seen to break up into capillaries amongst the convoluted tubules in the cortical substance, and their blood is collected partly by the *venae stellatae* or *stellulae*, *vs*, near the surface of the kidney, partly by the interlobular veins, *vi*, *vi*, which accompany the interlobular arteries. From the lowermost glomeruli some of the *vasa efferentia* pass down amongst the straight tubules of the medullary substance as the so-called false *arteria recta*, *ar'*. The true *arteria recta*, *ar*, spring directly from the main branches of the interlobular arteries, and run down in bundles, *ab*, towards the apex of the pyramid, breaking up into capillaries with long meshes. Their blood is returned to the interlobular veins, *vi*, by the *venae rectae*, *vr*. *vp*, represents the fine venous plexus around the apices of the pyramids.

of a dog from the aorta after the renal arteries had been tied. Within the glomerulus the afferent artery fig. 297, (*af*) breaks up into convoluted capillary branches, which are gathered together again to form the efferent vessel (*ef*). The efferent vessel is so far comparable with the vena portæ of the liver that it breaks up again into capillaries, which form a close honeycomb network surrounding the convoluted tubules (fig. 295, *e'*), and a less copious network with elongated meshes round the straight tubes of the cortical substance. Within the medullary

Fig. 298.

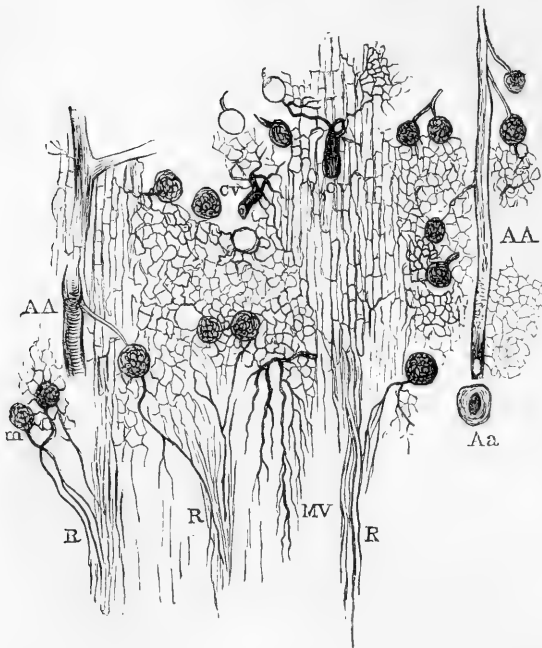


Fig. 298. — LONGITUDINAL SECTION OF A PART OF THE MEDULLARY SUBSTANCE AND THE ADJACENT CORTICAL SUBSTANCE OF THE KIDNEY, SHOWING THE BLOOD-VESSELS INJECTED (from Southey).

The figure is designed principally to show the origin of the vasa recta. AA, ascending arteries divided longitudinally; Aa, transverse section of anastomotic arch; C V, cortical veins; m, glomeruli; R R, arteræ rectæ; M V, R medullary veins.

substance are found numbers of straight vessels, *vasa recta*, which lie between the uriniferous tubes, and, at the bases of the Malpighian pyramids, are arranged in bundles extending inwards from between the pyramids of Ferrein. These vessels partly break up into capillaries, from which returning veins arise, and partly form loops similar to those of the looped tubules of Henle. The vasa recta take origin partly from the vasa efferentia from the innermost glomeruli (fig. 296, *ar'*; fig. 297, *b*), partly from the renal arteries without intervention of the glomeruli (fig. 296, *ar*).

Small veins, arising by numerous venous radicles from the capillary network of the kidney, are seen near the surface of the gland, and collect the blood from the capillary plexus around the convoluted tubules which mainly compose this part. These vessels, some of which have a stellate arrangement (*stellulae*, Verheyen, fig. 296, *vs*), are joined by numerous branches from the fibrous coat of the kidney, and, passing through the cortical substance, end in larger veins, which again unite into arches around the bases of the pyramids of Malpighi. The arches receive the interlobular veins (fig. 296, *vi*) which accompany the inter-



lobular arteries, receiving capillaries from the cortical substance, and also the straight veins of the pyramids, which commence in a beautiful plexus (*vp*, fig. 296) around the orifices of the tubuli on the surface of the papillæ. The venous trunks then proceed, in company with the arteries, through the cortical septula between the pyramids, to the sinus of the kidney. Joining together, they escape from the hilus, and ultimately form a single vein, which lies in front of the artery, and ends in the inferior vena cava.

**Lymphatics.**—The lymphatics of the kidney are numerous, consisting of a superficial set forming a plexus in the fibrous capsule, and of deep lymphatics which issue from the hilus with the blood-vessels. According to the researches of Ludwig and Zawarykin, there appears to be a network of freely intercommunicating lymphatic spaces between the tubules, in communication both with the lymphatics of the surface and those which issue with the blood-vessels at the hilus. These spaces are similar to those previously found by Ludwig and Tomsa in the testicle. They are most abundant in the cortical substance.

**Nerves.**—The nerves which have been traced into the kidneys are small. They come immediately from the renal plexus and the lesser splanchnic nerve, and contain filaments derived from both the sympathetic and cerebro-spinal systems. They may be traced accompanying the arteries as far as their finer branches, but it is uncertain how they end.

**Intertubular Stroma.**—Between the tubules and vessels of the kidney, although they are disposed closely together, a small amount of interstitial substance of the nature of connective tissue is found. It has a fibrous character in the vicinity of the chief ramifications of the blood-vessels. Fibres are likewise described by Ludwig and Zawarykin as passing around the Malpighian corpuscles, and others by Henle, coiling around the tubes of the medullary substance. The stroma is more marked in the cortical substance, where it consists mainly of connective tissue corpuscles, than in the greater part of the medullary; but according to Henle it is very abundant towards the apices of the papillæ. It is much more abundant in animals than in man, and in the human kidney is more apparent in the young than in the adult, and also much richer in corpuscles (fig. 294); in this respect resembling the connective tissue generally.

Among writings on the kidney, the following may be here referred to:—Bowman, in *Philos. Trans.* 1842; Henle, *Zur Anatomie der Nieren*. Göttingen, 1862, and in his *Handbuch*; Ludwig and Zawarykin, in *Wiener Acad. Sitzungsbericht.* vol. xlviii. 1864; Chrzonszczewsky, in *Virchow's Archiv.* xxxi. 1864; Schweigger-Seidel, *Die Nieren des Menschen und der Säugethiere*, Halle, 1865; Southey, in *St. Bartholomew's Hosp. Reports*, 1865; Heidenhain *Arch. f. Mikr. Anat.* x. 1874. Also, on the stroma, Beer, *Die Bindesubstanz d. menschlichen Nieren*, Berlin, 1859.

### SUPRARENAL BODIES.

The *suprarenal bodies* or *capsules*, or suprarenal glands (*capsulæ atrabiliarie seu renes succenturiati* of old anatomists), are two flattened bodies, each of which has a somewhat crescentic or bent triangular shape, and surmounts the corresponding kidney (fig. 299). The *upper* border, convex and thin, is often considerably elevated in the middle so

as to form two sides of a triangle. The lower border is concave, and rests upon the anterior and inner part of the summit of the kidney, to which it is connected by loose areolar tissue: it is thick, and almost always deeply grooved. The *posterior* surface rests upon the diaphragm. Its *anterior* surface is covered on the right side by the liver, and on the left by the pancreas and spleen: it presents an irregular fissure named the *hilus*, from which the suprarenal vein emerges (fig. 300, *v*). The right capsule, like the right kidney, is placed lower down than the left.

Fig. 290.

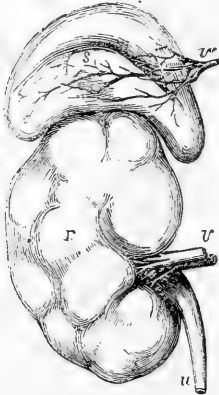


Fig. 300.

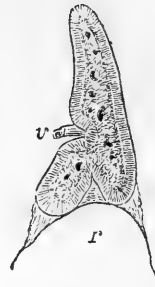


Fig. 299.—FRONT VIEW OF THE RIGHT KIDNEY AND SUPRARENAL BODY OF A FULL-GROWN FŒTUS (Allen Thomson).

This figure shows the lobulated form of the foetal kidney, *r*; *v*, the renal vein and artery; *u*, the ureter; *s*, the suprarenal capsule, the letter is placed near the sulcus in which the large veins (*v'*) are seen emerging from the interior of the organ.

Fig. 300.—SECTION OF THE SUPRARENAL BODY.

A vertical section of the suprarenal body of a foetus, twice the natural size, showing the lower notch by which it rests on the summit of the kidney, and the anterior notch by which the veins issue, together with the distinction between the medullary and cortical substance.

The suprarenal capsules vary in size in different individuals, and the left is usually somewhat narrower at its base, but longer from above downwards, and larger than the right. They measure from an inch and a quarter to an inch and three-quarters in height, and about an inch and a quarter in width; their thickness is from two to three lines. The *weight* of each in the adult is from one to two drachms.

**Structure.**—Besides a covering of areolar tissue mixed frequently with much fat, the suprarenal capsules have a thin fibrous investment. On the exterior their colour is yellowish or brownish-yellow. When divided (fig. 300), they are seen to consist of two substances: one, *external* or *cortical*, is of a deep yellow colour, firm and striated, and forms the principal mass of the organ; the other, *internal* or *medullary*, is in the adult of a dark brownish-black hue, and so soft and pulpy that some anatomists have erroneously described a cavity within it.

The **fibrous investment** (fig. 301, *a*), is so intimately connected with the deeper parts that it cannot be removed without lacerating the subjacent structure. Its deeper layers are destitute of elastic fibres, and are particularly rich in connective tissue corpuscles: they are continuous with the septa which enter into the formation of the substance of the organ.

The **cortical part** of the suprarenal body, examined in a section with a low magnifying power (fig. 301, 1), is seen to consist of a fibrous stroma, in which are imbedded column-like groups of cells. The groups measure on an average  $\frac{1}{700}$ th of an inch in diameter, and are arranged vertically to the surface of the organ. In the deepest part of the cortex, however, the colour is darker, and the columnar arrangement is lost, the stroma being more equally distributed (*d*); and immediately beneath the fibrous coat there is another narrow zone in which the stroma forms oval spaces, of which it is difficult to say whether they communicate with the extremities of the columns or not (*b*). These inner and outer layers have been named by J. Arnold respectively *zona reticularis* and *zona glomerulosa*, while he applies the term *zona fasciculata* to the main part (*c*); but the transition from one of these parts to another is not sudden nor indicated by any line of demarcation.

The cells which form the groups and columns of the cortical substance are polyhedral in form (fig. 302): their protoplasm is finely granular but not unfrequently contains yellowish oil globules. The cells vary from  $\frac{1}{26000}$ th to  $\frac{1}{13500}$ th of an inch in size: each has a clear round nucleus.

The small arteries, entering from the surface, run parallel to these columns, frequently anastomose together between them, and surround each column of cells with a fine capillary network. Small bundles of nerves pass inwards in the septa between the columns to reach the medullary part of the organ, and their fibres begin to spread out in the *zona reticularis*, but do not appear to be distributed to the cortical substance.

The **medullary part** (fig. 301, 2) of the suprarenal capsule is marked off from the cortical part by a layer of loose connective tissue.

Fig. 301.

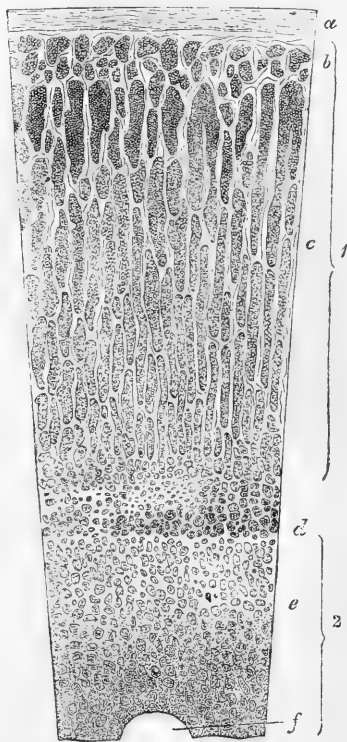


Fig. 301.—VERTICAL SECTION OF SUPRARENAL BODY: HUMAN. MAGNIFIED (Eberth).

1, cortical substance; 2, medullary substance: *a*, capsule; *b*, zona glomerulosa; *c*, zona fasciculata; *d*, zona reticularis; *e*, groups of medullary cells; *f*, section of a large vein.

In the thinner parts of the adult organ there is no medullary part, and the layer of connective tissue referred to is found separating the deep surfaces of two opposed portions of the cortical part; but in the young state the distinction of cortical and medullary probably extends throughout the whole. The medullary part is traversed in the centre by venous trunks, which receive the whole of the blood which has passed through the organ. The stroma is delicate and arranged in a reticular manner; in its meshes are enclosed groups of cells, which differ from those of the cortex in being coarsely granular, destitute of oil-globules, and some of them branched. Moreover they become

Fig. 302.

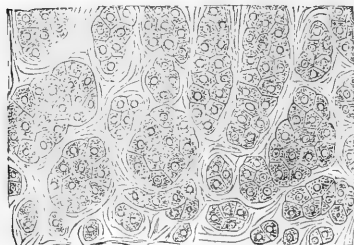


Fig. 302. — CELLS AND CELL-GROUPS FROM THE OUTERMOST LAYER OF THE CORTICAL SUBSTANCE OF THE SUPRARENAL BODY. HIGHLY MAGNIFIED (Eberth).

stained of an intense yellow or brown by solutions of yellow chromate of potash, whereas the cortical cells are but slightly tinged by that re-agent. The bundles of nerves which pass through the cortical substance run between it and the medullary substance, and then form a copious interlacement which extends through the whole of the medullary stroma. Indeed, some observers (Leydig and Luschka) have regarded the cells of the medullary substance as nerve-cells; and Luschka states that he has found them connected with nerve-fibres; but this still requires confirmation. Moers, whilst denying that the cells generally of the medullary parenchyma are nervous, nevertheless describes ganglia on the nerves where their bundles begin to break up. The medullary substance receives its blood by the continuation inwards of the capillary network of the cortex, the blood from which is collected by venous radicles which open into the stems in the centre of the organ and these emerge at the hilus.

**Vessels.**—The suprarenal bodies receive *arteries* from three sources, viz., from the aorta, the phrenic, and the renal arteries. The distribution of their capillary vessels has already been mentioned.

The *veins*, which pass out from the centre, are usually united into one for each organ. The right vein enters the vena cava inferior immediately, whilst the left, after a longer course, terminates in the left renal vein.

The *lymphatics* are imperfectly known. Kölliker has seen a few small trunks upon the surface; and Luschka has, in addition, observed others emerging from the interior in company with the vein.

**Nerves.**—The nerves are exceedingly numerous. They are derived from the solar plexus of the sympathetic, and from the renal plexuses. According to Bergmann, some filaments come from the phrenic and pneumogastric nerves. They are made up mainly of dark-bordered white fibres, of different sizes, and they have many small ganglia upon them before entering the organ. The nerves are especially numerous in the lower half, and inner border.

*Accessory suprarenal capsules* are occasionally met with, attached by connective tissue to the main bodies; and varying from a small size up to that of a pea. According to Duckworth they possess no medullary part.

On the subject of the suprarenal capsules may be consulted,—Bergmann, Dissertation, Göttingen, 1839; Ecker, *Der feinere Bau der Nebennieren*, Braunschweig, 1846; Simon on the Thymus Gland; Frey, article "Suprarenal Capsules,"

in Cyclop. of Anat. and Phys. ; G. Harley, in the Lancet, June, 1858 ; Duckworth, in St. Bartholomew's Hosp. Reports, 1865 ; Moers, in Virchow's Archiv, 1864, vol. xxix. p. 336 ; J. Arnold, Virchow's Archiv, 1866, vol. xxxv. p. 64 ; v. Brunn, Arch. f. mikr. Anat. viii. ; Eberth., Stricker's Handbook ; Leydig, Kölliker Luschka, and Henle, in their Handbooks.

**Function.**—Nothing is known positively with regard to the function of the suprarenal capsules. The opinion which has met with most acceptance among physiologists is that these bodies belong to the class of blood-vascular glands, and exert some influence upon the elaboration or disintegration of nutritive material. Bergmann, however, who was the first to point out the richness of their nervous supply, suggested that they were parts of the sympathetic nervous system, and in this opinion he has been followed by Leydig and Luschka ; while Kölliker states that, upon anatomical grounds, he is inclined to consider the cortical and medullary portions as functionally different ; the former belonging to the group of vascular or ductless glands, the latter appearing to be an apparatus appertaining to the nervous system. Brown-Séquard found that injuries to the spinal cord in its dorsal region produced congestion and subsequent hypertrophy of the suprarenal bodies. Addison has shown that a bronzed tint of skin, together with progressive emaciation and loss of strength, is to be found in conjunction with various forms of disease more or less involving and altering the structure of these bodies.

### THE URETERS.

The *ureters* are two tubes which conduct the urine from the kidneys into the bladder. The dilated commencement of each, situated in the pelvis of the kidney and into which the calices pour their contents, has already been described. Towards the lower part of the hilus of the kidney the pelvis becomes gradually contracted, and opposite the lower end of the gland, assuming the cylindrical form, receives the name of ureter. These tubes extend downwards to the posterior and under part or base of the bladder, into which they open, after passing obliquely through its coats.

The ureters measure from fourteen to sixteen inches in length ; their ordinary width is about that of a goose-quill. They are frequently, however, dilated at intervals, especially near the lower end. The narrowest part of the tube, excepting its orifice, is that contained in the walls of the bladder.

Each ureter passes, at first, obliquely downwards and inwards, to enter the cavity of the true pelvis, and then curves forwards and inwards, to reach the side and base of the bladder. In its whole course, it lies close behind the peritoneum, and is connected to neighbouring parts by loose areolar tissue. Superiorly, it rests upon the psoas muscle, and is crossed, very obliquely from within outwards, below the middle of the psoas, by the spermatic vessels, which descend in front of it. The right ureter is close to the inferior vena cava. Lower down, the ureter passes either over the common or the external iliac vessels, behind the termination of the ileum on the right side and the sigmoid flexure of the colon on the left. Descending into the pelvis, it enters the fold of peritoneum forming the corresponding posterior false ligament of the bladder, and, reaching the side of the bladder near the base (*u.* fig. 304), runs downwards and forwards in contact with it, below the obliterated hypogastric artery, and is crossed upon its inner side, in the male, by the vas deferens (*i*), which passes down between the ureter and the bladder. In the female, the ureters run along the sides

of the cervix uteri and upper part of the vagina before reaching the bladder.

Having reached the base of the bladder, about two inches apart from one another, the ureters enter its coats, and running obliquely through them for about three-quarters of an inch, open at length upon the inner surface by two narrow and oblique slit-like openings, which are situated, in the male, about an inch and a half behind the prostate gland, and about the same distance from each other. This oblique passage of the ureter through the vesical walls, while allowing the urine to flow into the bladder, has the effect of preventing its reflux.

**Structure.**—The walls of the ureter are pinkish or bluish white in colour. They consist of an external fibrous coat, a middle coat of plain muscular tissue, and a mucous lining. According to Huschke and Obersteiner the muscular coat possesses two layers of longitudinal fibres and a middle circular layer: Henle finds only an inner longitudinal and an outer circular layer; while Kölliker, who admits the inner longitudinal and the circular as the principal layers, describes longitudinal fibres external to the circular layer which are absent at the upper part of the tube.

The *mucous membrane*, thin and smooth, presents a few longitudinal folds when the ureter is laid open. It is prolonged above to the papillæ of the kidney, and below becomes continuous with the lining membrane of the bladder. The epithelium (fig. 303) is of a peculiar character, like that of the bladder. It is stratified, consisting of at least three layers of cells, in the uppermost of which the cells are somewhat cubical, with depressions on their under surface, which

fit upon the rounded ends of a second layer of pear-shaped cells; then follow one or more layers of rounded or oval cells, with processes extending down to the mucous membrane.

**Vessels and nerves.**—The ureter is supplied with blood from small branches of the renal, the spermatic, the internal iliac, and the inferior vesical arteries. The veins end in various neighbouring vessels. The nerves come from the inferior mesenteric, spermatic, and hypogastric plexuses. They form a plexus in the outer coat, containing a few ganglion-cells.

**Varieties.**—Sometimes there is no funnel-shaped expansion of the ureter at its upper end into a pelvis, but the calices unite into two or more narrow tubes, which afterwards coalesce to form the ureter. Occasionally, the separation of these two tubes continues lower down than usual, and even reaches as low as the bladder, in which case the ureter is double. In rare cases, a triple ureter has been met with.

In instances of long-continued obstruction to the passage of the urine, the ureters occasionally become enormously dilated, and their opening into the bladder becomes direct, so as to lose its valvular action.

Fig. 303.

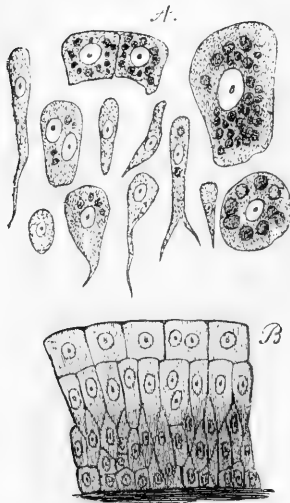


Fig. 303.—EPITHELIUM FROM THE PELVIS OF THE HUMAN KIDNEY (Kölliker). 350 DIAMETERS.

A, different kinds of epithelial cells separated; B, the same in situ.

## THE URINARY BLADDER.

The *urinary bladder* (*vesica urinaria*) is a hollow membranous and muscular receptacle, which receives the urine poured into it through the ureters, retains it for a longer or shorter period, and finally expels it through the urethra.

During infancy it is pyriform, and lies chiefly in the abdomen, but in the adult it is situated in the pelvic cavity behind the pubes, and in the male, in front of the rectum; in the female, it is separated from the rectum by the uterus and vagina.

Fig. 304.

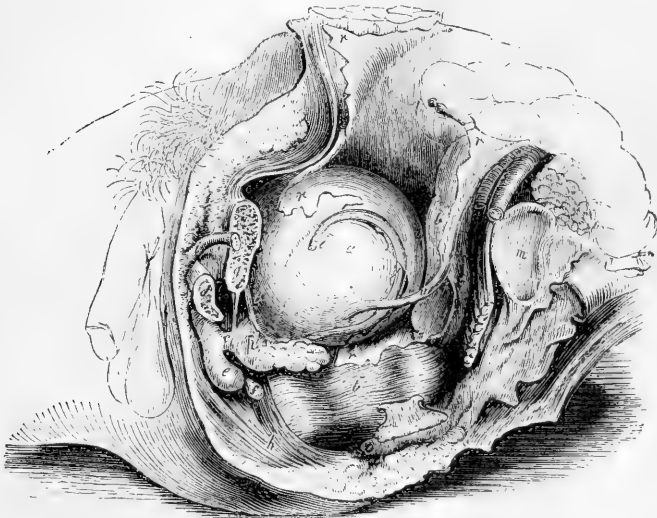


Fig. 304.—LATERAL VIEW OF THE VISCERA OF THE MALE PELVIS (R. Quain).  $\frac{1}{4}$

The left os ilium has been disarticulated from the sacrum, the spinous process of the ischium cut through, and the pubes divided to the left of the symphysis; *a*, the bladder; *b*, *b'*, the rectum; *c*, membranous part of the urethra; *d*, section of the left crus or corpus cavernosum; *e*, bulb of the spongy body of the urethra; *f*, Cowper's gland; *g*, section of the body of the pubes; *h*, sphincter ani muscle; *i*, part of the left vas deferens; *m*, articular surface of the sacrum; *n*, divided spine of the ischium; *o*, coccyx; *p*, prostate gland; *r*, *r*, peritoneum; *r'*, recto-vesical pouch; *u*, left ureter; *v*, left vesicula seminalis.

The size and shape of the bladder, its position in the abdomino-pelvic cavity, and its relations to surrounding parts, vary greatly, according to its state of distension or collapse. When empty, the bladder lies deeply in the pelvis, and in a vertical antero-posterior section presents a triangular appearance, being flattened before and behind, having its base turned downwards and backwards, whilst its apex reaches up behind the symphysis pubis. The surfaces named anterior and posterior have thus a considerable inclination. When moderately full, it is still contained within the pelvic cavity, and has a rounded form (fig. 304, *a*), but when completely distended, it rises above the brim of the pelvis, and becomes egg-shaped; its larger end, which is called the *base* or *inferior fundus*, being directed towards the rectum in the male

and the vagina in the female; and its smaller end, or *summit*, resting against the lower part of the anterior wall of the abdomen. Immediately in front of the base is the thickened portion named the *cervix*, or *neck*, which bounds the outlet of the bladder, and connects it below with the urethra.

The long axis of the distended bladder is inclined obliquely upwards and forwards from the base to the summit, in a line directed from the coccyx to a point between the pubes and the umbilicus. In being gradually distended, the bladder curves slightly forwards, so that it becomes more convex behind than in front, and its upper end is by degrees turned more and more towards the front of the abdomen. Lastly, the bladder, when filled, appears slightly compressed from before backwards, so that its diameter in that direction is less than from side to side. In its ordinary state, the longest diameter in the male is from base to summit; but in the female its breadth is often greater than its height. The average capacity of the bladder is often stated to be greater in the female than in the male; and, no doubt, instances of very large female bladders are not unfrequent, but these have probably been the result of unusual distension: in the natural condition, according to Luschka and Henle, the female bladder is decidedly smaller than that of the male.

**Connections.**—While freely movable in all other directions upon surrounding parts, the bladder is fixed below to the walls of the pelvis by the neck, and by fibrous bands given off from the recto-vesical fascia, named the *true ligaments* of the bladder. It is supported, moreover, by strong areolar connections with the rectum or vagina, according to the sex, in a slighter degree by the two ureters, the obliterated hypogastric arteries and the urachus, by numerous blood-vessels, and, lastly, by a partial covering of the peritoneum, which, in being reflected from this organ in different directions, forms duplicatures, named the *false ligaments* of the bladder.

The *anterior surface* is entirely destitute of peritoneum, and is in apposition with the triangular ligament of the urethra, the subpubic ligament, the symphysis and body of the pubes, and, if the organ be full, the lower part of the anterior wall of the abdomen. It is connected to these parts by loose areolar tissue, and to the back of the pubes by two strong bands of the vesical fascia, named the *anterior true ligaments*. This surface of the bladder may be punctured above the pubes without wounding the peritoneum.

The *posterior surface* is entirely free, and covered everywhere by the peritoneum, which in the male is prolonged also for a short distance upon the base of the bladder. In the male, this surface is in contact with the rectum, and in the female with the uterus, some convolutions of the small intestine descending between it and those parts, unless the bladder be very full. Beneath the peritoneum, in the male, a part of the vas deferens is found on each side of the lower portion of this surface.

The *summit* (sometimes named the superior fundus) is connected to the anterior abdominal wall by a tapering median cord, named the *urachus*, which is composed of fibro-areolar tissue, mixed at its base with some muscular fibres which are prolonged upon it from the bladder. This cord, becoming narrower as it ascends, passes upwards from the apex of the bladder between the linea alba and the peritoneum, to reach



the umbilicus, where it becomes blended with the dense fibrous tissue found in that situation. The urachus, which forms in the early foetal state a tubular communication between the urinary bladder and the allantoic vesicle, preserves, according to Luschka, vestiges of its original condition in the form of a long interrupted cavity, with irregularities and dilatations, lined with epithelium similar to that of the bladder, and sometimes communicating by a fine opening with the vesical cavity.\*

The *sides* of the bladder, when it is distended, are rounded and prominent, and are each of them crossed obliquely by the cord of the obliterated hypogastric artery, which is connected posteriorly with the superior vesical artery, and runs forwards and upwards to the umbilicus, approaching the urachus above the summit of the bladder. Behind and above this cord the side of the bladder is covered with the peritoneum, but below and in front of it the peritoneum does not reach the bladder, which is here connected to the sides of the pelvic cavity by loose areolar tissue containing fat, and, near its anterior and lower part, by the broad expansion from the recto-vesical fascia, forming the *lateral true ligament*. The vas deferens crosses obliquely the lower part of this lateral surface, from before backwards and downwards, and turning over the obliterated hypogastric artery, descends upon the inner side of the ureter, along the posterior surface, to the base of the bladder.

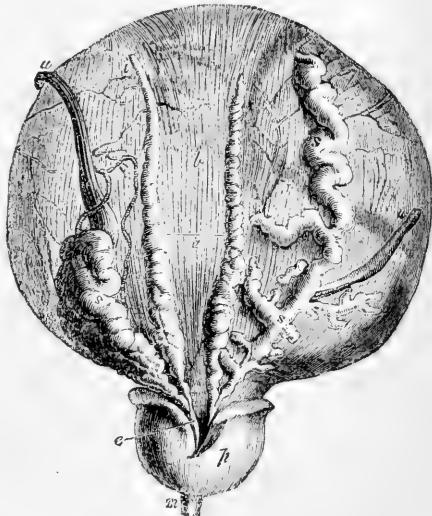
The *base* or *fundus* (fig. 305) (inferior fundus) is the widest part of the bladder. It is directed backwards as well as downwards, and differs according to the sex in its relations to other parts. In the *male* it rests

Fig. 305.—BASE OF THE MALE BLADDER WITH THE VESICULÆ SEMINALES, VASA DEFERENTIA, AND PROSTATE EXPOSED (from Haller). ONE-HALF THE NATURAL SIZE.

*a*, line of reflection of the peritoneum in the recto-vesical pouch; *b*, the part above this from which the peritoneum has been removed, exposing the longitudinal muscular fibres; *i*, left vas deferens ending in *e*, the left ejaculatory duct; *s*, left vesicula seminalis joining the same duct; the right vas deferens, and the right vesicula seminalis, marked *s*, *s*, unravelled, are also shown; *p*, under side of the prostate gland; *m*, small part of the membranous portion of the urethra; *u*, *u*, the ureters, of which the right is turned to the side.

upon the second portion of the rectum, and is covered posteriorly for a short space by the peritoneum, which, however, is immediately reflected from thence upon the rectum, so as to form the *recto-vesical pouch* (fig. 304, *r*). In front of the line of reflection of the serous membrane, the

Fig. 322.



\* Virchow's Archiv, 1862, and Anat. d. Mensch., vol. ii. p. 229.

base of the bladder is destitute of peritoneum, and adherent to the rectum by dense fibro-areolar tissue over the extent of a triangular area bounded at the sides by the vasa deferentia and vesiculæ seminales (fig. 305, *s, s*), whilst its apex in front reaches the prostate gland (*p*). It is in this space, which in the natural state of the parts is by no means so large as it appears after they are disturbed in dissection, that the bladder may be punctured from the rectum without injury to the peritoneum. In the *female*, the base of the bladder is of less extent, and does not reach so far back in the pelvis as in the male: for it rests against the front of the neck of the uterus and the anterior wall of the vagina, both of which organs intervene between it and the rectum. This part of the bladder adheres to the vagina, and above that adhesion the peritoneum forms a pouch between it and the uterus, much shallower than the recto-vesical pouch of the male.

The *cervix* or *neck* of the bladder is a term commonly applied to the part of the bladder at which the cavity terminates in the urethra, and is often indefinitely used, so as to include a considerable portion either of the bladder or urethra. It may be conveniently retained to denote the region of the immediate neighbourhood of the urethral orifice. It is the most strongly muscular part of the bladder, and in the male it is closely connected with the base of the prostate gland, by which it is supported. It was formerly described as an infundibular projection, but, as pointed out by Kohlrausch, no such arrangement exists. The urethral orifice is in both sexes the part of the bladder which in the erect posture is lowest; it lies at the angle of meeting of the base and the anterior surface.

It was formerly believed that the base was the lowest part of the bladder in the adult male, and hence the origin of the term. The inferior position of the urethral orifice was supposed to be peculiar to women and children. The more correct views, however, now entertained with respect to the inclination of the pelvis have led to altered notions of the relative elevation of the pelvic viscera. A consideration of the following circumstances will contribute to an accurate conception of the position of the vesical outlet. The symphysis pubis is placed very obliquely; the ischial tuberosities are little lower than the inferior margin of the symphysis pubis, and the triangular ligament is therefore almost horizontal; the lower part of the sacrum and the coccyx are nearly vertical, being only slightly curved forwards, and the tip of the coccyx is on a somewhat higher level than the inferior margin of the symphysis pubis; the curve and position of the rectum are determined by those of the sacrum and coccyx until it passes in front of the coccyx, when it turns vertically downwards; the prostate gland, situated entirely on the upper or interior side of the triangular ligament, rests on the last turn of the rectum, and the base of the bladder is in contact with the rectum above that place.

**Ligaments of the bladder.**—The *true ligaments* of the bladder, four in number, two anterior and two lateral, all derived from the vesical portion of the recto-vesical fascia, have been already noticed.

The *false ligaments* or *peritoneal folds* are described as five in number. Two of them, named *posterior* false ligaments or *recto-vesical* folds, run forwards in the male along the sides of the rectum to the posterior and lateral aspect of the bladder, and bound the sides of the recto-vesical cul-de-sac. In the female these posterior folds pass forwards from the sides of the uterus, and are comparatively small. The two *lateral* false ligaments extend from the iliac fossæ to the sides of the bladder, each separated from the corresponding posterior ligament by a prominent

angle in which the obliterated hypogastric artery lies. The *superior* false ligament (ligamentum suspensorium) is the portion of peritoneum between the ascending parts of the epigastric arteries, and reaches from the summit of the bladder to the umbilicus.

**Interior of the bladder.**—On opening the bladder, its internal surface is found to be lined by a smooth membrane, which is comparatively loosely attached to the other coats, so that in the empty condition of the organ it is nearly everywhere thrown into small wrinkles or rugæ, which disappear as soon as the bladder is distended. Besides these, the interior of the bladder is often marked by reticular elevations or ridges, corresponding with fasciculi of the muscular coat.

At the lower and anterior part of the bladder is seen the orifice leading into the urethra, around which the mucous membrane is corrugated longitudinally. Immediately behind the urethral opening, at the anterior part of the fundus, is a smooth triangular surface, having its apex turned forwards, which, owing to the firmer adhesion of the mucous membrane to the subjacent tissues, never presents any rugæ, even when the bladder is empty. This surface is named the *trigone* (trigonum vesicæ, Lieutaud); at its posterior angles are the orifices of the two ureters, situated about an inch and a half from each other, and nearly the same distance from the anterior angle, where the bladder opens into the urethra.

The orifices of the ureters, presenting the appearance of oval slits, are directed obliquely forwards and inwards: they are united by a curved elevation, convex forwards, which extends generally outwards and backwards beyond them, and which corresponds in position with a muscular band which joins them together and to the neck of the bladder. Proceeding forwards from opposite the middle of this, is another slight elevation of the mucous surface, named the *uvula vesicæ* (luette vesicale), which projects from below into the urethral orifice. In the female, the trigone is small, and the uvula indistinct. In the male the uvula lies a little in advance of the middle lobe of the prostate, and is sometimes prolonged on the floor of the prostatic portion of the urethra. It is produced by a thickening of the submucous tissue. In its natural state this may contribute to the more perfect closure of the orifice of the bladder; when enlarged by disease it frequently produces serious obstruction at the commencement of the urethra.

#### STRUCTURE OF THE BLADDER.

The bladder is composed of a *serous*, a *muscular*, and a *mucous* coat, united together by areolar tissue, and supplied with numerous blood-vessels and nerves.

The **serous or peritoneal coat** is a partial covering, investing only the posterior and upper half of the bladder, and reflected from it upon the surrounding parts in the manner already described in detail.

The **muscular coat** consists of unstriped muscular fibres, so arranged as to warrant the usual description of them as forming layers, the outer of which consists of bundles of fibres more or less longitudinal, and the next of fibres more circular in disposition; while beneath this, is another delicate longitudinal layer more recently recognised.

The *external or longitudinal fibres* (fig. 306, A, a, B, b, and fig. 307) are most distinctly marked on the anterior and posterior surfaces of the bladder. Commencing in front at the neck of the organ,

from the pubes in both sexes (musculi pubo-vesicales), and, in the male, from the adjoining part of the prostate gland, they may be traced upwards along the anterior surface to the summit of the bladder; and they may likewise be followed down over the posterior surface and base to the under part of the neck of the bladder, where they become attached to the prostate in the male, and to the front of the vagina in the

Fig. 306.

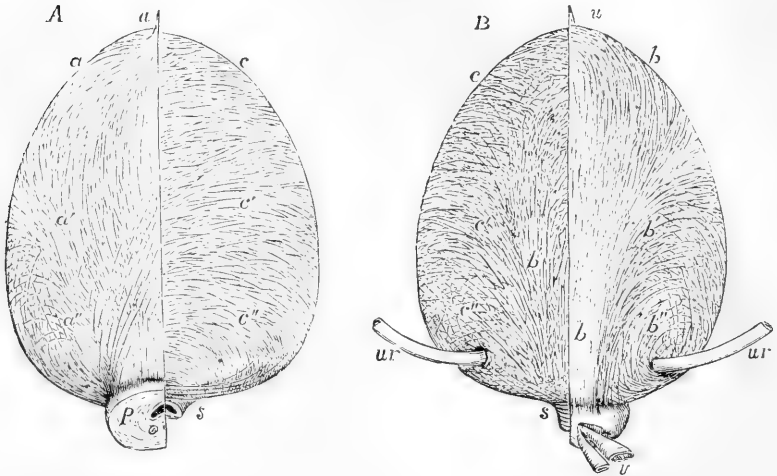


Fig. 306, A.—VIEW OF THE MUSCULAR FIBRES OF THE BLADDER FROM BEFORE (Allen Thomson, after Pettigrew).  $\frac{1}{2}$

On the right side the superficial fibres are shown; on the left the deep or circular fibres chiefly are displayed. *a*, on the right side, the median and most superficial bands of the longitudinal fibres, in which a slight decussation of fibres is seen; *a'*, those diverging somewhat; *a''*, the lowest, which pass much more obliquely; the attachment of the longitudinal fibres to the prostate is shown; on the left side *c*, the upper, *c'*, the middle, *c''*, the lowest set of circular or deeper fibres; at *s*, the thickest and most transverse sets of these fibres forming the sphincter; *p*, half the prostate left on the right side, the left having been removed; *u*, the urachus, into which some of the longitudinal fibres are seen prolonged.

Fig. 306, B.—VIEW OF THE MUSCULAR FIBRES OF THE BLADDER FROM BEHIND (Allen Thomson, after Pettigrew).  $\frac{1}{2}$

On the right side the superficial fibres are displayed; on the left the deeper fibres of the same kind or intermediate fibres, and some of the circular fibres; *b*, *b*, the median, most superficial and strongest bands of longitudinal fibres on the right side; *b'*, the more diverging set of fibres near the middle of the bladder; *b''*, the most divergent fibres which surround the entrance of the ureters; on the left side, *c*, *c'*, and *c''*, indicate the deeper circular fibres passing round at various levels and crossing with the deeper diverging fibres posteriorly; *s*, the most transverse fibres at the neck forming the sphincter; *u*, the urachus; *ur*, the ureters; the left half of the prostate has been removed to show the sphincter; *v*, part of the right vas deferens and vesicula seminalis.

female. Upon the sides the superficial fascioli run more or less obliquely, and often intersect one another: in the male they reach the prostate. At the summit a few are continued along the urachus (fig. 306, *u*). The longitudinal fibres taken together, constitute what has been named the *detrusor urinae* muscle.

The so-called *circular* fibres (fig. 306, *c*, *c'*, *c''*) form a thin and somewhat irregular reticulated layer distributed over the body of the bladder,

having various appearances in different bladders. Their course may in general be looked upon as transverse, but for the most part throughout the upper two-thirds of the bladder they cross one another in very oblique bands: towards the lower part of the organ they assume a more circular course, and upon the fundus and trigone form a tolerably regular layer. Close to and around the cervix, in immediate connection with the prostate in the male, they densely encircle the orifice and constitute what has been named the *sphincter vesicae*, which, however, is not distinct from the other fibres.

The *third stratum* of fibres, still more deeply situated, and which might be termed internal longitudinal, was first described by Ellis, who

Fig. 307.—VIEW OF THE MUSCULAR FIBRES OF THE BLADDER FROM THE LEFT SIDE (Allen Thomson, after Pettigrew).  $\frac{1}{3}$

The anterior and posterior superficial fibres are seen running from below upwards, crossing each other by their divergence on the sides of the bladder, and are indicated by the same letters as in the preceding figures; at *c*, a portion of the anterior longitudinal fibres has been removed so as to expose the deeper circular fibres.

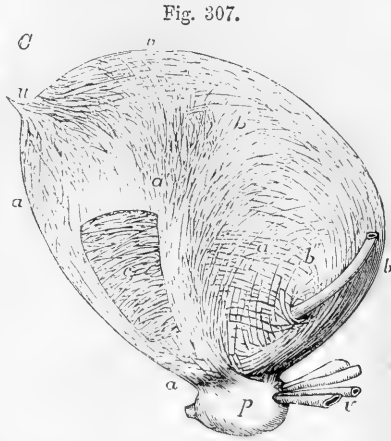
distinguished it as “submucous.” It is very delicate, and its fibres, directed longitudinally, are disposed in a regular manner round the cavity of the bladder.

The muscular coat of the bladder forms so irregular a covering, that, when the organ is much distended, intervals arise in which the walls are very thin; and, should the internal or mucous lining protrude in any spot through the muscular bundles, a sort of hernia is produced, which may go on increasing, so as to form what is called a vesical sacculus, or *appendix vesicae*, the bladder thus affected being termed *sacculated*. Hypertrophy of the muscular fasciuli, which is liable to occur in stricture of the urethra or other affections impeding the issue of the urine, gives rise to that condition named the *fasciculated* bladder, in which the interior of the organ is marked by strong reticulated ridges or columns, with intervening depressions.

On the muscular arrangements of the bladder, see Ellis, in *Trans. Med. Chir. Society*, 1856, and *Demonstrations of Anatomy*; Pettigrew, in *Phil. Trans.* for 1866; Sabatier, *Rech. Anat. et Phys. sur les Appareils musculaires correspondants à la vessie et à la prostate dans les deux sexes*, 1864.

Next to the muscular coat, between it and the mucous membrane, but much more intimately connected with the latter, is a well-marked layer of areolar tissue, the vascular or **submucous coat**. This submucous areolar layer contains a large quantity of very fine coiled fibres of elastic tissue.

The **mucous membrane** of the bladder is soft, smooth, and of a pale rose colour. It is continuous above with the lining membrane of the ureters and kidneys, and below with that of the urethra. It adheres loosely to the muscular tissue, and is thus liable to be thrown into wrinkles, except at the trigone, where it is always more even. It is



covered with a stratified epithelium, which is composed of three layers of cells. Of these, those forming the middle layer are pyriform (fig. 308, *b*), the upper end being rounded; whilst the lower end of each cell is prolonged down to the corium, between small, rounded or irregular cells forming the lowermost layer. The cells of the superficial stratum (*a*) are large and flattened (more so in some animals than in man), covering one, two, or more of the pyriform cells, over which their lower surface is as it were moulded, presenting well-marked depressions (with

Fig. 308

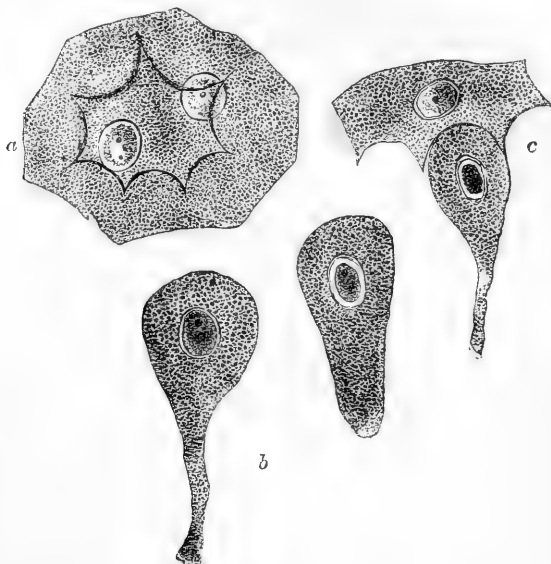

Fig. 308.—EPITHELIAL CELLS FROM BLADDER OF RABBIT. ABOUT 500 DIAMETERS. (Klein.)

*a*, large flattened cell from the superficial layer, with two nuclei, and with strongly marked ridges and intervening depressions on its under surface; *b*, pear-shaped cells from the second layer; *c*, showing the manner in which the pyriform cells are adapted to the depressions of the superficial cells.

intervening ridges), into which the rounded ends of the pyriform cells fit (*c*). These large flattened cells have frequently more than one nucleus. There are no villi upon the vesical mucous membrane, but it is provided with minute recesses and with small racemose glands lined with columnar epithelium, which are most abundant in the vicinity of the neck of the bladder.

**Vessels.**—The *superior vesical arteries* proceed from the remaining pervious portions of the hypogastric arteries; in the adult they appear as direct branches of the internal iliac. The *inferior vesical arteries* are usually derived from the anterior division of the internal iliac. In the female the uterine arteries also send branches to the bladder. The neck and base of the organ appear to be the most vascular portions. The *veins* form large plexuses around the neck, sides, and base of the bladder; they eventually pass into the internal iliac veins. The *lymphatics* follow a similar course.

The **nerves** are derived partly from the hypogastric plexus of the sympathetic, and partly from the sacral plexus of the cerebro-spinal system. The former are

said to be chiefly distributed to the upper part of the bladder, whilst the spinal nerves may be traced more directly to its neck and base. According to Kisseleer, the nerves form a network immediately under the epithelium, from which filaments pass amongst the epithelium cells. Gangliated plexuses of nerves accompany the blood-vessels, and send branches both to these and to the muscular coat of the bladder (F. Darwin).

#### THE URETHRA.

The urethra is a membranous tube directed in the median line first vertically and then from behind forwards, beneath the arch of the pubes, in which situation it opens in the female into the vulva, while in the male it is enclosed in the corpus spongiosum, and prolonged beneath the corpora cavernosa penis. In the female, it serves simply as the excretory passage for the urine; in the male, it conducts also the seminal fluid. The detailed anatomy of the male and female urethra will be given with that of the organs of generation of the respective sexes.

### REPRODUCTIVE ORGANS.

#### I. IN THE MALE SEX.

UNDER this head are included—1, the testes or reproductive glands, with their excretory apparatus, and their integumental and other coverings in the scrotum; and, 2, the uro-genital canal or urethra, together with certain accessory parts, such as the prostate and Cowper's glands. The second group of these organs, being most nearly related to those which have gone before, will be first described. They are all closely connected with the urethra, which in the male is at once the outlet for the urine from the bladder and the products of secretion from the sexual glands. This canal, extending from the neck of the bladder to the extremity of the penis, is surrounded in its first part by the prostate gland, and there receives the excretory ducts of the testicles and vesiculæ seminales; its second part passes through the triangular ligament of the perineum; the canal is then surrounded by the bulb and cylindrical part of the spongy body as it passes along the perineum and penis, and lastly it goes through the glans of that organ.

#### THE PROSTATE GLAND.

The *prostate gland* is a firm, glandular, and muscular body, somewhat resembling a chestnut in shape and size, which adjoins the neck of the bladder, and encloses the first part of the urethra: it is placed in the pelvic cavity, on the inner aspect of the subpubic fascia, and rests posteriorly upon the rectum. Its form may be compared to that of a short cone flattened anteriorly, with its base in contact with the bladder, and cut obliquely, so that its posterior or rectal surface is larger than its anterior or pubic surface. It usually measures about an inch and a half across at its widest part, an inch and a quarter from its base to its apex, and nearly an inch in depth or thickness. Its ordinary weight is about six drachms.

The anterior or pubic surface of the prostate is flattened and marked

with a slight longitudinal furrow; it is about half an inch or rather more from the pubic symphysis, and there, as well as at the

Fig. 309.

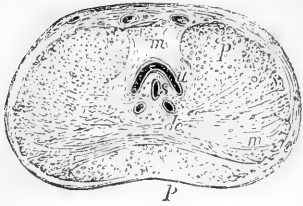


Fig. 309.—TRANSVERSE SECTION OF THE PROSTATE GLAND THROUGH THE MIDDLE. (A.T.)

*u*, the urethra into which the eminence of the caput gallinaginis rises from below; *s*, the sinus or utricle cut through; *d c*, the ejaculatory ducts; *m*, superiorly, the deep sphincter muscular fibres; *m*, lower down, intersecting muscular bands in the lateral lobes of the prostate; *p, p'*, glandular substance.

sides, the gland is connected to the pubic arch by the reflexion of the pelvic fascia, which forms the pubo-prostatic *ligaments* or *anterior ligaments* of the bladder. The posterior or rectal surface is smooth, and is marked by a slight depression, or by two grooves, which meet in front, and correspond with the course of the seminal ducts, as well as mark the limits of the lateral lobes in this situation: it is in close apposition

Fig. 310.

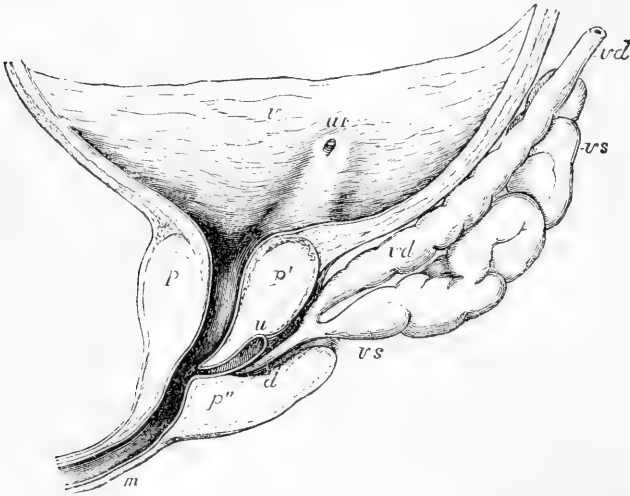


Fig. 310.—LONGITUDINAL MEDIAN SECTION OF THE LOWER PART OF THE BLADDER AND PROSTATE GLAND (after E. H. Weber).

*r*, inner surface of the urinary bladder; *ur*, opening of the right ureter, from which a slight elevation runs down to the neck of the bladder; *p*, fore part of the prostate; *p'*, the so-called middle lobe; *p''*, the right lateral lobe; *u*, the urethra; *d*, the right ejaculatory duct; *vd*, vas deferens; *vs*, vesicula seminalis.

with the rectum, immediately in front of the bend from the middle to the lower or anal part of that viscus, where the surface and posterior border of the gland can be felt by the finger introduced into the intestine. The sides are convex and prominent, and are covered by the anterior portions of the levatores ani muscles, which pass back on each



side, from the symphysis pubis and anterior ligament of the bladder, and embrace the sides of the prostate. This part of each levator ani is occasionally separated from the rest of the muscle by areolar tissue, and has been named *levator prostate*. The base of the gland is of considerable thickness, and is notched in the middle: its apex is turned towards the triangular ligament. As already stated, the prostate encloses the first part of the urethra. The canal runs nearer to the anterior than to the posterior surface of the gland, so that in general it is about three lines distant from the former and four or five from the latter; but it frequently varies greatly in this respect. The prostatic portion of the urethra is about an inch and a quarter long, and is dilated in the middle; it contains the colliculus seminalis and the openings of the seminal and prostatic ducts, as will be afterwards more particularly described. The common or ejaculatory seminal ducts, which pass forwards from the vesiculæ seminales, also traverse the lower part of the prostate, enclosed in a special hollow part of the gland, and open into the urethra; and in the middle, close in front of these, is the prostatic utricle.

This gland is usually described as consisting of three lobes, two of which, placed laterally, and meeting behind in the posterior notch, and continuous in front of the urethra, are of equal size; the third, or *middle* lobe, is a smaller pyriform or three-sided mass, intimately connected with the other two, and fitted in between them and the neck of the bladder and adjacent part of the urethra. When prominent it corresponds to the elevation in the urinary bladder called uvula. The separation between the lobes of the prostate, which is little marked in the natural state, becomes often much more apparent in disease.

**Structure.**—The prostate gland is covered externally by a dense fibrous coat, which is continuous with the recto-vesical fascia, and with the posterior layer of the triangular ligament. Adams describes the fibrous capsule as divisible into two layers, between which the prostatic plexus of veins is enclosed. The glandular substance is associated with a large quantity of plain muscular tissue, which forms the principal part of the stroma of the organ. This muscular tissue forms an external layer below the fibrous capsule, and extends everywhere through the glandular substance: there is also a strong layer of circular fibres continuous posteriorly with the sphincter vesicæ, and in front with the thin layer surrounding the membranous part of the urethra. The part of the prostate in front of the urethra is almost entirely muscular, and in the hinder part the muscular substance is in greatest quantity near the bladder. The glandular substance is spongy and yielding; its colour is reddish grey, or sometimes of a brownish hue. It consists of numerous small saccules, or terminal vesicles, opening into elongated tubes, which unite into a smaller number of excretory ducts. The epithelium is columnar both in the vesicular terminations and in the canals. In the upper part of the gland the acini are small and hemispherical; in the middle and lower parts the tubes are longer and convoluted at their ends. The capillary blood-vessels spread out as in other similar glands on the ducts and clusters of vesicles, and the different glandular elements are united by areolar tissue, and supported by processes of the deep layer of the fibrous capsule and muscular stroma. The ducts open by from twelve to twenty or more orifices upon the floor of the urethra, chiefly in the

hollow on each side of the colliculus seminalis. (Adams, Cyclop. of Anat. vol. iv., p. 147.)

**Vessels and Nerves.**—The prostate is supplied by branches of the vesical, hæmorrhoidal, and pudic arteries. Its veins form a plexus embedded in the fibrous covering round the sides and base of the gland, which is highly developed in old subjects. These veins communicate in front with the dorsal vein of the penis, and behind with branches of the internal iliac vein. According to Adams, the lymphatics, like the veins, are seen ramifying between the two layers of the fibrous capsule. The nerves, which are derived from the hypogastric plexus, consist of both medullated and non-medullated fibres, and are interspersed with single or small heaps of ganglionic cells. Pacinian bodies have also been observed on the superficial nerves. (Klein in Stricker's Handbuch.)

**Prostatic fluid.**—This is mixed with the seminal fluid during emission; as obtained from the human prostate soon after death, it has a milky aspect, which is ascribed by Adams to the admixture of a large number of epithelial cells, and he thinks it probable that, as discharged during life, it is more transparent. According to the same observer, the prostatic fluid has an acid reaction, and presents, under the microscope, numerous molecules, epithelial particles both squamous and columnar, and granular nuclei about  $\frac{1}{3300}$  inch in diameter. As age advances, when this gland is disposed to become enlarged, its ducts often contain small round concretions of laminated appearance, and varying from a small size up to that of a millet seed; they sometimes contain carbonate of lime, but are principally composed of animal matter, which in some of them appears to be entirely amylaceous, in others albuminous, and more frequently is of a mixed character. (Virchow's Cellular Pathology, by Chance, p. 369.)

### THE PENIS.

The penis, which supports the greater part of the urethra in the male, is composed principally of an erectile tissue, arranged in three long somewhat cylindrical masses, which are enclosed in fibrous sheaths, and are united together so as to form a three-sided prism which receives a covering from the general integument. Of these masses, two, named *corpora cavernosa penis*, placed side by side, form the principal part of the organ, whilst the other, situated beneath the two preceding, surrounds the canal of the urethra, and is named *corpus cavernosum urethrae* or *corpus spongiosum*.

The penis is attached at its root to the symphysis of the pubes, and to the pubic arch; in front it ends in an enlargement named the *glans*, which is structurally similar to and continuous with the corpus spongiosum. The intermediate portion or *body* of the penis, owing to the manner in which its three component parts are united together, has three somewhat flattened sides and three rounded borders: the upper and anterior side is named the *dorsum*. The *glans penis*, which is slightly compressed above and below, presents at its extremity a vertical fissure forming the external orifice of the urethra; its base, which is wider than the body of the penis, is hollowed out to receive the narrowing extremities of the corpora cavernosa; its border is rounded and projecting, and is named the *corona glandis*, behind which is a constriction of the penis named the *cervix*. The median fold of integument attaching the glans below the urethral orifice to the inferior border of the penis is named the *frænum* of the prepuce.

**The Integuments.**—The integument of the penis, which is continued from that of the pubes and scrotum, forms a simple investment as far as the neck of the glans. At this part it leaves the surface and is doubled up in a loose cylindrical fold, constituting the *prepuce* or *foreskin*. The inner layer of this fold returns to the penis behind the cervix, where it is firmly attached; and from thence the integument, becoming again adherent, is continued forwards over the corona and glans, as far as the orifice of the urethra, where it meets with the mucous membrane of the urethra. Upon the body of the penis the skin is thin, free from fat, and, in the anterior two-thirds of its length, from hairs also; in these respects differing remarkably from that on the pubes, which is thick, covers a large cushion of fat, and, after puberty, is beset with hairs: the skin of the penis is moreover very movable and distensible, and is of a darker colour than that of the neighbouring parts. At the free margin of the prepuce the integument changes its character, and approaches to that of a mucous membrane, being red, thin, and moist. Numerous sebaceous glands are collected round the cervix of the penis and corona glandis; they are named the *glands of Tyson*, or *glandulæ odoriferæ*, their secretion having a peculiar odour.

Upon the surface of the glans penis the integument again changes its character; it ceases to contain glands, but is beset with large papillæ, which are very vascular and extremely sensitive, and it adheres most intimately and immovably to the spongy tissue of the glans.

Beneath the skin, on the body of the penis, the ordinary superficial fascia is very distinct; it is continuous with that of the groin, and also with the dartos tissue of the scrotum. Near the root of the organ there is in front a dense band of fibro-elastic tissue, named the *suspensory ligament*, lying amongst the fibres of the superficial fascia; it is triangular in form; its anterior border is free, above it is connected with the fore part of the pubic symphysis, and below it runs down upon the dorsum of the penis.

The integuments of the penis are supplied with blood by branches of the dorsal artery of the penis and external pudic; the veins join the dorsal and external pudic veins. Their nerves are derived from the dorsal and anterior superficial perineal branches of the pudic nerves.

#### THE CORPORA CAVERNOSA.

The **corpora cavernosa** form the principal part of the body of the penis, and chiefly determine its form and consistence in the state of erection. They are two cylindrical bodies, placed side by side, flattened on their median aspects, and closely united and in part blended together along the middle line in the anterior three-fourths of their length; whilst at the back part, in contact with the symphysis pubis, they separate from each other in the form of two bulging and then tapering processes named *crura*, which, extending backwards, are attached to the pubic and ischial rami, and are invested by the *erectores penis* or *ischio-cavernosi* muscles. The enlarged portion at the root, named by Kobelt the *bulb of the corpora cavernosa*, attains a much greater proportionate development in some quadrupeds than in man. In front, the corpora cavernosa are closely bound together into a blunt conical extremity, which is covered by the glans penis and firmly connected to its base by fibrous tissue.

The under surface of the united cavernous bodies presents a longitudinal groove, in which is lodged the corpus spongiosum, containing

Fig. 311.

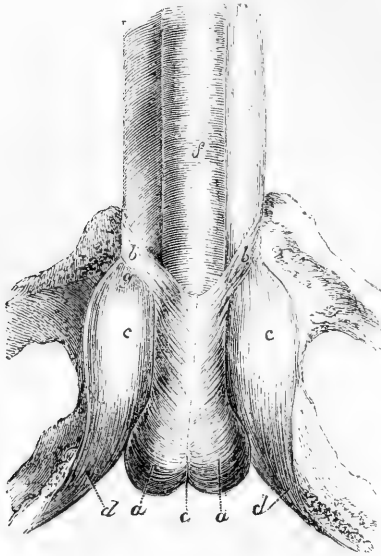


Fig. 311.—ROOT OF THE PENIS ATTACHED TO THE RAMI OF THE PUBES AND ISCHIUM (from Kobelt).  $\frac{2}{3}$

*a, a*, accelerator urinae muscle covering the bulb of the spongy body of the urethra, which presents at *c*, posteriorly, a median notch; *b, b*, anterior slips of the muscle or bulbo-cavernosi; *c, c*, crura of the penis, presenting an oval dilatation or bulb of the corpus cavernosum; *d, d*, erectores penis muscles; *f*, corpus spongiosum urethrae.

the greatest part of the canal of the urethra. The upper or anterior surface is also marked with a slight median groove in which the dorsal vein of the penis is situated, and near the root is attached to the pubes by the suspensory ligament.

**Structure.**—The median septum between the two corpora cavernosa is thick and complete near the root of the penis; but farther forward it becomes thinner,

and only imperfectly separates their two cavities, for it presents, particularly towards the anterior extremity, numerous clefts, extending from the dorsal to the urethral edge, and admitting of a free communi-

Fig. 312.

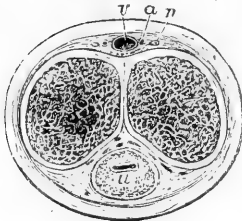


Fig. 312.—TRANSVERSE SECTION OF THE PENIS IN THE DISTENDED STATE (altered from Henle).

The outer line indicates the integument surrounding the deeper parts; the erectile tissue of the corpora cavernosa and the septum pectiniforme are shown in section; *u*, placed on the section of the spongy body, below the urethra; *v*, the single dorsal vein; *a*, the dorsal artery, and *n*, the nerve, of one side.

cation between the erectile tissue of the two sides. From the direction of these slits, the intermediate white portions of the septum resemble somewhat the teeth of a comb,

and hence have received the name of *septum pectiniforme*.

The external fibrous investment of the cavernous structure is white and dense, from half a line to a line thick, and very strong and elastic. It is composed for the most part of longitudinal bundles of shining white fibres, with numerous well-developed elastic fibres, enclosing the two corpora cavernosa in a common covering; and internal to this, each compartment is surrounded by a layer of circular fibres, which enter into the formation of the septum.

From the interior of the fibrous envelope, and from the sides of the septum, numerous lamellæ, bands, and cords, composed of fibrous elastic

and plain muscular tissue, and named *trabeculae*, pass inwards, and run through and across the cavity in all directions, thus subdividing it into

Fig. 313.—PORTION OF THE ERECTILE TISSUE OF THE CORPUS CAVERNOSUM MAGNIFIED, SHOWING THE AREOLAR STRUCTURE AND THE VASCULAR DISTRIBUTION (from J. Müller).



*a*, a small artery supported by the larger trabeculae, and branching out on all sides; *b*, the tendril-like arterial tufts or helicine arteries of Müller; *c*, the areolar structure formed by the finer trabeculae.

a multitude of interstices occupied by tortuous veins, and giving the entire structure a spongy character.

The trabeculae, whether lamelliform or cord-like, are larger and stronger near the circumference than along the centre of each cavernous body, and they also become gradually thicker towards the crura. The venous interspaces, conversely, are larger in the middle than near the surface; their long

Fig. 314.

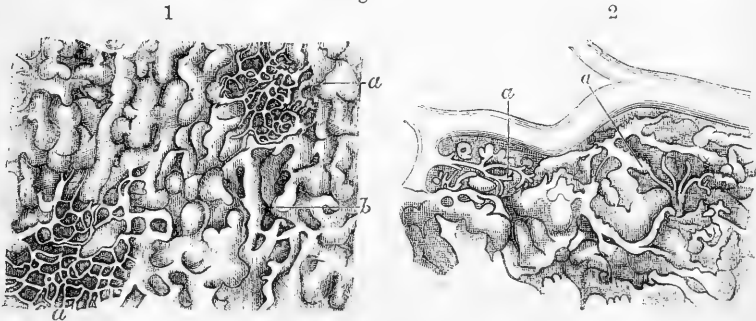


Fig. 314.—ERECTILE TISSUE FROM THE PERIPHERAL PART OF THE CORPUS CAVERNOSUM PENIS, MAGNIFIED WITH A LOW POWER (from Frey after Langer).

1, *a* and *b*, superficial and deeper cortical network of veins; 2, *a*, passage of arterial ramuscles into the veins of the deeper cortical network.

diameter is, in the latter situation, placed transversely to that of the penis; and they become larger towards the forepart of the penis. They are lined by a layer of flattened epithelioid cells similar to that lining other veins. The trabeculae contain the ordinary white fibrous tissue and fine elastic fibres, together with a considerable quantity of pale

muscular fibres, and in many of them small blood-vessels and nerves occupy the interior.

The intertrabecular spaces thus form a labyrinth of intercommunicating venous areolæ divided by the trabecular tissue, and opening freely from one corpus cavernosum to the other through the septum, especially in front. The blood is carried away from these spaces by two sets of veins, the one joining the prostatic plexus and pudendal veins below; the others passing into the dorsal vein superiorly. Of these last some issue from between the corpus cavernosum and the spongy body of the urethra, encircling the penis nearly at right angles, while others pass more directly into the dorsal vein from the upper surface.

The principal arteries of the corpora cavernosa are the cavernous branches of the pudic arteries (*profundæ penis*), of the right and left sides; but the dorsal artery of the penis also sends small twigs through the fibrous sheath of the corpora cavernosa, along the upper surface, especially in the fore part of the penis. Within the cavernous tissue, the numerous branches of arteries are supported by the trabeculæ, in the middle of which they run, and terminate in two modes; some of them subdividing into branches of capillary minuteness which open into the intertrabecular spaces; while others form tendril-like twigs which project into the spaces, and end in peculiar curling dilated extremities to which attention was first called by J. Müller, who named them *helicine* arteries, and regarded them as a special structure belonging to the erectile tissue. The extremity of each curled dilatation would appear

Fig. 315.

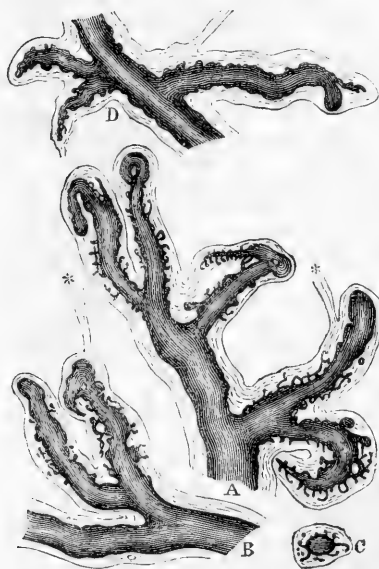

Fig. 315.—HELICINE ARTERIES WITH THEIR SHEATHS, &c. (from Henle). MAGNIFIED WITH A LOW POWER.

A and B, from the corpus cavernosum penis; D, from the corpus spongiosum urethre; C, transverse section of one of the helicine arteries; in this and the other figures the smaller lateral prolongations of the arterial vessels into the sheath are shown; \*\*, fasciculi of connective tissue passing off from the summit of two of the sheaths.

to be bound down by a small fibrous band, which according to Henle is usually solid, but is said by Kölliker to contain a capillary continuation of the blood-vessel. The helicine arteries are most abundant in the posterior part of the corpora cavernosa, and are found in the corresponding part of the corpus spongiosum also; but they have not been seen in the glans penis.

Various views have been taken by different anatomists of the nature of these tufted vascular processes. The very full researches of Langer appear to show that they are nothing

more than arterial loops or convolutions thrown into peculiar forms by the manner in which they are bound down by the trabeculæ in which they run. They are most distinct in man, but are not constant in animals, so that, whatever may be their use, they do not appear to be essential to the process of erection.

According to Langer the deep arteries of the corpora cavernosa, penetrating by the side of the septum, and dividing within the trabeculæ, terminate in the following several ways : 1st, over the whole surface of the corpora cavernosa and close to the fibrous sheath and septum, they form by their division true capillaries which communicate with the deeper cortical venous network ; 2nd, into this network there also open directly arterial twigs of about  $\frac{1}{400}$ th of an inch in diameter, without any intermediate capillary division ; and 3rd, arterial vessels of from  $\frac{1}{400}$ th to  $\frac{1}{500}$ th of an inch in diameter open, without the intervention of capillaries, into the larger venous spaces of the interior. Capillary networks also surround the arterial branches and the trabeculæ of the deeper parts of the corpora cavernosa. (C. Langer, in Sitzungsbericht der Wien. Acad., vol. xvi. p. 120.)

## CORPUS SPONGIOSUM.

The *corpus spongiosum urethrae* commences in front of the triangular ligament of the perineum, where it is placed between the diverging crura of the corpora cavernosa, and somewhat behind their point of junction. The enlarged and rounded posterior extremity is named the *bulb*, and is situated below the urethra. It extends forwards as a cylindrical, or slightly tapering body, lodged in the groove on the under side of the united cavernous bodies, as far as their blunt conical anterior extremity, over which it expands so as to form the glans penis already described. In the whole of this extent it encloses the urethra.

The posterior bulbous part, or *bulb of the urethra*, varies in size in different subjects. It receives an investment from the triangular ligament on which it rests, and is embraced by the accelerator urinæ, or bulbo-cavernosus muscle. The posterior extremity of the bulb exhibits, more or less distinctly, a subdivision into two lateral portions or lobes, separated by a slight furrow on the lower surface, and by a slender fibrous partition within, which extends for a short distance forwards ; in early infancy this is more marked. It is above this part that the urethra, having pierced the triangular ligament, enters the bulb, surrounded obliquely by a portion of the spongy tissue, named by Kobelt the *colliculus bulbi*, from which a layer of venous erectile tissue passes back upon the membranous and prostatic portions of the urethra to the neck of the bladder, lying closely beneath the mucous membrane. At first the urethra is nearer the upper than the lower part of the corpus spongiosum, but it soon gains and continues to occupy the middle of that body.

**Structure.**—This is essentially the same as regards the vascular part with that of the corpora cavernosa, but with a much less quantity of the external fibrous and deeper trabecular structure. Like the corpora cavernosa, it is distended with blood during erection, but never acquires the same rigidity. The outer fibrous tunic is much thinner, is less white in colour, and contains more elastic tissue ; the areolæ are smaller, and directed for the most part with their long diameter in the line of that

of the penis; the trabeculæ are finer and more equal in size; and the veins form a nearly uniform plexus between them; in the glans, the meshes of this plexus are smallest and most uniform. Plain muscular fibres immediately surround the canal of the urethra, and also form part of the external coat of the spongy substance. The helicine arteries are found in the spongy body, especially towards the bulb, but not in the part which forms the glans penis. A considerable artery derived from the internal pudic enters the bulb on each side, and supplies the greater part of the spongy body, sending branches as far as the glans penis, but this part is chiefly supplied by branches from the arteria dorsalis. Besides these, Kobelt describes, as constantly present, another but much smaller branch of the pudic artery, entering the bulb on the upper surface, about an inch from its posterior extremity, and running forwards in the corpus spongiosum to the glans. It is only in the spongy body of the bulb that the arteries open directly into the veins: there in part, and elsewhere entirely, it is by the intervention of capillaries. Veins issue from the glans and adjoining part of the spongy body, to end in the vena dorsalis penis; those of the rest of the spongy body for the most part pass backwards through the bulb, and end in the prostatic and pudic venous plexuses: some emerge from beneath the corpora cavernosa, anastomose with their veins, and end partly in the cutaneous veins of the penis and scrotum, and partly in the pudic and obturator veins.

The **lymphatics** of the penis form a dense network on the skin of the glans and prepuce, and also underneath the mucous lining of the urethra. They pass chiefly into the inguinal glands. Deep-seated lymphatics are also described as issuing from the cavernous and spongy bodies, and passing under the pubic arch with the deep veins, to join the lymphatic plexuses in the pelvis.

The **nerves** of the penis are derived from the dorsal and superficial perineal branches of the pudic nerve and from the hypogastric plexus of the sympathetic. The former are distributed to the skin and mucous membrane, the latter entirely to the cavernous and spongy bodies. Krause observed end-bulbs on the nerves of the penis, and Schweigger-Seidel found Pacinian bodies on the nerves of the glans.

#### URETHRA OF THE MALE.

The *male urethra* extends from the neck of the bladder to the extremity of the penis. Its total length is about eight inches and a half, but varies much according to the length of the penis, and the condition of that organ. Its diameter varies at different parts of its extent, as will be stated more particularly hereafter. The tube consists of a continuous mucous membrane, supported by an outer layer of submucous tissue connecting it with the several parts through which it passes. In the submucous tissue there are, throughout the whole extent of the urethra, two layers of plain muscular fibres, the inner fibres disposed longitudinally, and the outer in a circular direction. The urethra is described under the three divisions of the *prostatic, membranous, and spongy* portions.

1. The first, or **prostatic portion**, is the part which passes through the prostate gland. It is about 15 lines in length, is the widest part of the canal, and is wider in the middle than at either end: at the neck



of the bladder its diameter is nearly 4 lines, in the next part it widens a little, so as to be rather more than 4 lines, and in old persons 5 or 6,

Fig. 316.

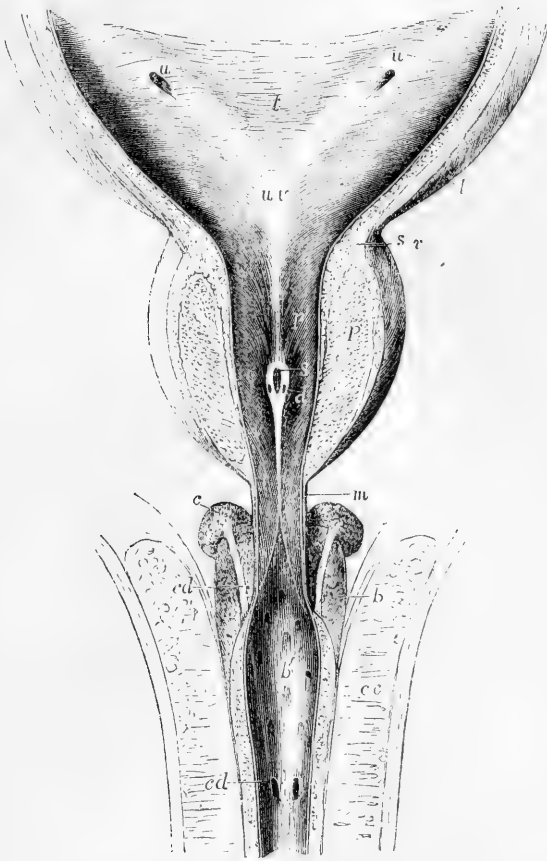

Fig. 316.—THE LOWER PART OF THE BLADDER AND THE PROSTATIC, MEMBRANOUS, AND BULBOUS PARTS OF THE URETHRA OPENED FROM ABOVE. (A. T.)

A portion of the wall of the bladder and the upper part of the prostate gland have been removed, the corpora cavernosa penis have been separated in the middle line and turned to the side, and the urethra has been slit up; the bulb is left entire below, and upon and behind it the glands of Cowper with their ducts have been exposed. *t*, placed in the middle of the trigonum vesicæ; *u u*, oblique apertures of the ureters; from these an elevation of the wall of the bladder is shown running down to *u v*, the uvula vesicæ; *l*, the longitudinal muscular fibres of the bladder passing down upon the prostate; *s v*, the circular fibres of the sphincter surrounding the neck; *p*, the glandular part of the prostate; *p'*, the prostatic portion of the urethra; from the uvula vesicæ a median ridge is seen descending to the caput gallinaginis, in which *s* indicates the opening of the sinus pocularis, and *d*, that of one of the ductus ejaculatorii; *m*, the commencement of the membranous portion of the urethra; *b*, the bulb of the spongy body; *U'*, the bulbous part of the urethra; *c*, one of Cowper's glands; *cd*, *cd*, course and orifice of its duct lying upon the bulb, and passing forward between the spongy body and the urethra, into which along with its fellow it opens; *c c*, one of the corpora cavernosa.

farther on it diminishes like a funnel, until, at its anterior limit, it is smaller than at its commencement. It passes through the upper part of the prostate, above the middle lobe, so that there is more of the gland below it than above. Though enclosed in the firm glandular substance, it is more dilatable than any other part of the urethra; but immediately at the neck of the bladder, it is, as elsewhere stated, much more resistant. The transverse section of the urethra, as it lies in the prostate, is widened from side to side and curved with the convexity upwards, the upper and under mucous surfaces being in contact.

The lining membrane of the prostatic portion of the urethra is thrown into longitudinal folds, when not distended by fluid. Towards the neck of the bladder, a slight elevation on the lower surface passes back into the uvula vesicæ. Somewhat in advance of this, and continued from it along the floor of the passage, projects a narrow median ridge, about 8 or 9 lines in length, and  $1\frac{1}{2}$  line in its greatest height; this ridge gradually rises into a peak, and sinks down again at its anterior or lower end, and is formed by an elevation of the mucous membrane and subjacent tissue. This is the crest of the urethra (*crista urethræ*), which also receives the names of *colliculus seminalis*, *caput gallinaginis* and *verumontanum*. On each side of this ridge the surface is slightly depressed, so as to form a longitudinal groove, named the *prostatic sinus*, the floor of which is pierced by numerous foramina, the orifices of the prostatic ducts. Through these a viscid fluid oozes out on pressure; the ducts of the middle lobe open behind the urethral crest, and some others open before it. The prostatic urethral mucous membrane is covered by a flat laminated epithelium.

*Vesicula prostatica*.—At the fore part of the most elevated portion of the crest, and exactly in the middle line, is a recess, upon or within the margins of which are placed the slit-like openings of the common seminal or ejaculatory ducts, one at each side. This median depression leads into the prostatic vesicle, which has been named also *sinus peculiaris*, or *utricle*. It was first described by Morgagni, and has more lately attracted renewed attention, as corresponding with the structure which in the female is developed into the uterine passage.

The vesicle forms a cul-de-sac running upwards or backwards, from three to five lines deep, and usually about one line wide at its entrance and for some distance up, but acquiring a width of at least two lines at its upper end or fundus. The narrow portion runs in the urethral crest, and its fundus appears to lie behind and beneath the middle lobe, and between the two lateral lobes of the prostate. Its parietes, which are distinct, and of some thickness, are composed of fibrous tissue and mucous membrane, together with a few muscular fibres, and enclose on each side the ejaculatory duct; numerous small ramified and convoluted glands open on its inner surface. The epithelial lining is of the flat laminated kind. According to Kobelt and others, the *caput gallinaginis* contains some well-marked erectile and plain muscular tissue, and it has been supposed that this eminence, when distended with blood, may offer an obstacle to the passage of the semen backwards into the bladder. (E. H. Weber, *Zusätze zur Lehre vom Baue und Verrichtungen der Geschlechts-Organen*, 1846; Huschke in *Sœmmerring's Anatomie*, vol. v.; Leuckart, "*Vesicula Prostatica*," in *Cyclop. of Anat. & Phys.*)

2. The **membranous portion** of the urethra comprises the part between the apex of the prostate and the bulb of the corpus spongio-

sum. It measures three quarters of an inch along its anterior, but only about half an inch on its posterior surface, in consequence of the projection backwards on it of the bulb. This is the narrowest division of the urethra. In the middle its circumference is 0.6 of an inch: at the end 0.5. It is placed beneath the pubic arch, the anterior concave surface being distant nearly an inch from the bone, leaving an interval, occupied by the dorsal vessels and nerves of the penis, by areolar tissue, and some muscular fibres. Its lower convex surface is turned towards the perinaeum, opposite to the point of meeting of the transverse muscles: it is separated by an interval from the last part of the rectum. About a line in front of the prostate, it emerges from between the anterior borders of the levatores ani, and passes through the deep layer of the subpubic fascia; it is then placed between that and the anterior layer or triangular ligament through which it passes somewhat farther forwards, and has both of these fibrous membranes prolonged upon it, the one backwards and the other forwards. Between these two layers the urethra is surrounded by erectile tissue, by some veins, and also by the fibres of the *compressor urethrae* muscle beneath it. On each side are Cowper's glands. The proper or plain muscular fibres of this portion of the urethra are continued over the outer and inner surfaces of the prostate into the muscular fibres of the bladder posteriorly, and into those of the spongy portion of the urethra anteriorly. (Hancock.)

3. The **spongy portion** of the urethra, by far the longest and most variable in length and direction, includes the remainder of the canal, or that part which is surrounded by the erectile tissue of the corpus spongiosum. Its length is about six inches. The part contained within the bulb, sometimes distinguished as the *bulbous portion*, or sinus, is somewhat dilated. The succeeding portion, as far as the glans, is of uniform diameter, being intermediate in this respect between the bulbous and membranous portions. The cross section of its canal appears like a transverse slit. The canal of the urethra, situated in the glans has, on the contrary when seen in a cross section, the form of a vertical slit: in this part, which is from four to six lines in length, the canal is again considerably dilated, forming what is named the *fossa navicularis*.

Lastly, at its orifice, which is a vertical fissure from two and a half to three lines in extent, and bounded by two small lips, the urethra is again contracted and reaches its narrowest dimensions. From the resistant nature of the tissues at its margin, this opening does not admit so large a sound or catheter as even the membranous portion of the canal.

The **mucous membrane** of the urethra possesses a lining of stratified epithelium, of which the superficial cells are columnar, except for some distance from the orifice, where they are squamous, and where the subjacent membrane is beset with papillæ. Outside the mucous membrane there is a layer of convoluted vascular structure, and external to that a layer of plain circular muscular fibres separating it from the proper substance of the spongy body.

The whole lining membrane of the urethra is beset with small race-mose mucous glands and follicles, commonly named the glands of Littre, the ducts of which pass obliquely forwards through the membranes. They vary much in size and in the extent to which their cavities are

ramified and sacculated. Besides these there are larger recesses or lacunæ, opening by oblique orifices turned forwards or down the canal. These are most abundant along the floor of the urethra, especially in its bulbous part. One large and conspicuous recess, situated on the upper surface of the fossa navicularis, is named the *lacuna magna*. A median fold of the membrane rising from the inferior surface of this part of the urethra has been named the valve of the fossa navicularis.

**Cowper's glands.**—In the bulbous portion of the urethra, near its anterior end, are the two openings of the ducts of *Cowper's glands*. These small glandular bodies are seated farther back than the bulb, beneath the fore part of the membranous portion of the urethra, between the two layers of the subpubic fascia, the anterior layer supporting them against the urethra. The arteries of the bulb pass above, and the transverse fibres of the compressor urethræ beneath these glands. They are two small firm rounded masses, about the size of peas, and of a deep yellow colour. They are compound vesicular or racemose glands, composed of several small lobules held together by a firm investment. This latter, as well as the walls of the ducts, contains muscular tissue. The branched ducts which commence in saccular crypts, unite outside each gland to form a single excretory duct. These ducts run forward near each other for about an inch or an inch and a half, first in the spongy substance and then beneath the mucous membrane, and terminate in the floor of the bulbous part of the urethra by two minute orifices opening obliquely. These glands secrete a viscid fluid, the use of which is not known; they appear to diminish in old age; sometimes there is only one present, and it is said both may be absent.

Occasionally there is a third glandular body in front of and between Cowper's glands; this has been named the *anterior prostate* or *ante-prostatic gland*.

The muscles in connection with the urethra and penis have been already described with the muscles of the perinæum in the first volume.

## THE TESTICLES, AND THEIR ACCESSORY STRUCTURES.

The *testicles* or *testes*, the two glandular organs which secrete the seminal fluid, are situated in the pouch of integument termed the *scrotum*, each being suspended by the spermatic cord. The latter parts will be first described.

The **spermatic cord.**—The parts which form this cord are the excretory duct of the testicle, named the vas deferens, the spermatic artery and veins, lymphatics, nerves, and connecting areolar tissue. Besides this last the cord has several coverings in common with the testis. The structures mentioned come together to form the cord at the internal or deep abdominal ring, and, extending through the abdominal wall obliquely downwards and towards the middle line, escape at the superficial or external abdominal ring, whence the cord descends over the front of the pubes into the scrotum.

### COVERINGS OF THE TESTIS AND CORD.

THE INGUINAL CANAL.—By the term inguinal canal is understood the space occupied by the spermatic cord as it passes through the abdominal

wall. It extends from the deep to the superficial abdominal ring, and is about an inch and a half in length. In the upper part of this course, the cord has placed behind it the fascia transversalis, and is covered in front by the lower fibres of the internal oblique and transversalis muscles; lower down it lies in front of the conjoined tendon of these muscles, the fibres of which have arched inwards over it, and its cremasteric covering is in contact anteriorly with the aponeurosis of the external oblique muscle. The inguinal canal is therefore said to be bounded posteriorly by the fascia transversalis above and the conjoined tendon below, and anteriorly by fibres of the transversalis and internal oblique muscles above, and the aponeurosis of the external oblique muscle below; while its floor is formed by the curving backwards of Poupart's ligament, and its roof by the apposition of the layers of the abdominal wall and the arched fibres of the internal oblique muscle.

As it enters the inguinal canal, the cord receives a covering from the infundibuliform fascia, a thin layer continuous with the fascia transversalis, and prolonged down from the margin of the deep abdominal ring; within the canal it receives a covering from the cremaster muscle and its layer of fascia; and as it emerges from the canal there is added, superficially to this, the intercolumnar fascia prolonged from the margin of the superficial abdominal ring.

**THE SCROTUM.**—The *scrotum* forms a purse-like investment for the testes and part of the spermatic cords. Its condition is liable to some variations according to the state of the health and other circumstances: thus it is short and corrugated in robust persons and under the effects of cold, but becomes loose and pendulous in persons of weak constitution, and under the relaxing influence of heat. A superficial division into two lateral halves is marked by a slight median ridge, named the *raphe*, extending forwards to the under side of the penis, and backwards along the perinæum to the margin of the anus.

The coverings of the cord and testis in the scrotum may be enumerated from without inwards as follows, viz., the *skin*, *superficial fascia* and *dartos tissue*, the *intercolumnar fascia*, the *cremaster muscle* and *fascia*, and the *infundibuliform fascia*, which is united to the cord by a layer of loose areolar tissue; lastly, the special serous membrane of the testicle, named the *tunica vaginalis*, which forms a close sac, of which one part lines the scrotum and the other closely envelopes the testicle.

1. The **skin** of the scrotum is very thin, and is of a darker colour than elsewhere; it is generally thrown into rugæ or folds, which are more or less distinct according to the circumstances already mentioned. It is furnished with sebaceous follicles, the secretion from which has a peculiar odour, and it is covered over with thinly scattered crisp and flattened hairs, the bulbs of which may be seen or felt through the skin when the scrotum is stretched. The superficial blood-vessels are also readily distinguished through this thin integument.

2. Immediately beneath the skin of the scrotum there is found a thin layer of a peculiar loose reddish-brown tissue, endowed with contractility, and named the **dartos tunic**. This subcutaneous layer is continuous with the superficial fascia of the groin, perinæum, and inner side of the thighs, but assumes a different structure, and is entirely free from fat. The dartoid tissue is more abundant on the fore part

of the scrotum than behind, and, moreover, it forms two distinct sacs, which contain the corresponding testes, and are united together along the middle line so as to establish a median partition between the two glands named the *septum scroti*, which is adherent below to the deep surface of the raphe, and reaches upwards to the root of the penis. The dartos is very vascular, and, as was first shown by Kölliker, owes its contractile properties to the presence of a considerable amount of unstriped muscular tissue. Its contractility is slow in its action; it is excited by the application of cold and of mechanical stimuli, but, apparently, not by electricity. By its general contraction the skin of the scrotum is drawn together and more or less corrugated.

3. The **intercolumnar** or **spermatic fascia**, a very thin and transparent but relatively firm layer, derived from the tendon of the external oblique muscle of the abdomen, is attached above to the margins of the external ring, and is prolonged downwards upon the cord and testicle. It lies at first beneath the superficial fascia, and lower down beneath the dartos, and it is intimately connected with the layer next mentioned.

4. The **cremasteric** layer is composed of scattered bundles of striped muscular fibres, connected together into a continuous covering by intermediate areolar membrane. The red muscular portion, which is continuous with the lower border of the internal oblique muscle of the abdomen, constitutes the *cremaster muscle*, and the entire covering is named the *cremasteric fascia*. By the action of the cremaster the cord is shortened and the testicle is raised towards the body.

5. The **infundibuliform fascia**, continuous above with the *fascia transversalis* and the subperitoneal areolar membrane, and situated immediately beneath the cremasteric fascia, invests the cord completely, and is connected below with the posterior part of the testicle and the outer surface of its serous tunic. On forcing air beneath the infundibuliform fascia, a quantity of loose and delicate areolar tissue is seen to connect its deep surface with the vas deferens and spermatic blood-vessels, and to form lamellæ between them. This areolar tissue is continuous above with the subserous areolar tissue found beneath the peritoneum on the anterior wall of the abdomen; below, it is lost upon the back of the testicle. Together with the infundibuliform fascia, it forms the *fascia propria* of A. Cooper.

Lying amongst this loose areolar tissue, in front of the upper end of the cord, there is often seen a fibro-areolar band, which is connected above with the pouch of peritoneum found opposite the upper end of the inguinal canal, and which passes downwards for a longer or shorter distance along the spermatic cord. Occasionally it may be followed as a fine cord, as far as the upper end of the tunica vaginalis; sometimes no trace of it can be detected. It is the vestige of a tubular process of the peritoneum, which in the fetus connects the tunica vaginalis with the general peritoneal membrane. The testicle is placed within the abdomen during the greater part of foetal life; but at a period considerably prior to its escape from the abdominal cavity, a pouch of peritoneum already extends down into the scrotum. Into this pouch, or *processus vaginalis peritonæi*, the testicle projects from behind, supported by a duplicature of the serous membrane, named the *mesorchium*. Sooner or later after the gland has descended into the scrotum, the upper part or neck of this pouch becomes contracted and finally

obliterated, from the internal abdominal ring down nearly to the testicle, leaving no trace but the indistinct fibrous cord already described, while the lower part remains as a closed serous sac surrounding the testicle, and which is thence named the tunica vaginalis.

In the female foetus an analogous pouch of peritoneum descends for a short distance along the round ligament of the uterus, and has received the appellation of the *canal of Nuck*. Of this traces may almost always be seen in the adult.

**Varieties.**—The neck of the processus vaginalis sometimes becomes closed at intervals only, leaving a series of sacculi along the front of the cord ; or a long pouch may continue open at the upper end, leading from the abdominal cavity into the inguinal canal. In other instances, the peritoneal process remains altogether pervious, and the cavity of the tunica vaginalis is thus made continuous with that of the peritoneum. In such a case of congenital defect, a portion of intestine or omentum may descend from the abdomen into the inguinal canal and scrotum, and constitute what is named a congenital hernia. Lastly, one or both testes may remain permanently within the abdomen, or their descent may be delayed till after puberty, when it may occasion serious disturbance. Retention of the testes in the abdomen (cryptorchismus) is, in many instances, the accompaniment of arrested development of the glandular structure ; it is, however, a peculiarity which may be present without impotence.

In a few mammals, as the elephant, the testes remain permanently within the abdomen ; in a much larger number, as the rodentia, they only descend at each period of rut. The complete closure of the tunica vaginalis is peculiar to man, and may be considered as connected with his adaptation to the erect posture.

Fig. 317.—THE LEFT TUNICA VAGINALIS OPENED, SHOWING THE TESTIS, EPIDIDYMIS, &c., FROM THE OUTER SIDE. (A. T.)

*p, p*, the cut edges of the parietal tunica vaginalis drawn aside laterally, as well as above and below ; *t*, the body of the testicle ; *e*, the globus major of the epididymis ; *e'*, the globus minor, near which, *f*, a fold of the tunica vaginalis (or ligament) passes from the body of the testis to the side ; in the upper part of the figure the tunica vaginalis has been slightly dissected off at the place of its reflection on the cord to show *vd*, the vas deferens, and *g*, the organ of Giraldès ; *G*, the three small nodules of this organ enlarged about ten times, and showing the remains of tubular structure within them ; *h*, hydatid of Morgagni.

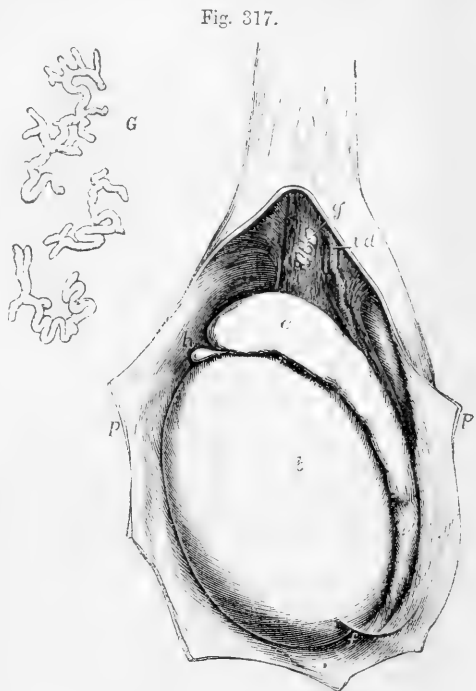

Fig. 317.

6. The **tunica vaginalis**.—This tunic forms a shut sac, of which the opposite free surfaces are in contact with each other. Like the serous

membranes in general, of which it presents one of the simplest forms, it may be described as consisting of a *visceral* and a *parietal* portion. The visceral portion, *tunica vaginalis testis*, closely invests the greater part of the body of the testis, as well as the epididymis, between which parts it is depressed in the form of a pouch (digital fossa), and lines their contiguous surfaces, and it adheres intimately to the proper fibrous tunic of the gland. Along the posterior border of the gland, where the vessels and ducts enter or pass out, the serous coat, having been reflected, is wanting. This portion of the serous covering frequently presents villous prolongations on the borders of the epididymis and upper end of the testis; these processes, sometimes of considerable length, are covered in some places with cylindrical, in others with layers of flat epithelium (Luschka, in Virchow's Archiv, Vol. VI., p. 321, and La Valette St. George, in Stricker's Handbuch, p. 523).

The parietal or scrotal portion of the tunica vaginalis is more extensive than that which covers the body of the testis; it reaches upwards, sometimes for a considerable distance, upon the spermatic cord, extending somewhat higher on the inner than on the outer side. It also reaches downwards below the testicle, which, therefore, appears to be suspended at the back of the serous sac, when this latter is distended with fluid; a fold, or so-called ligament, being left projecting at the lower end of the epididymis.

#### **Vessels and nerves of the scrotum and spermatic cord.**

—The *arteries* are derived from several sources. Thus, the two external pudic arteries, branches of the femoral, reach the front and sides of the scrotum, supplying the integument and dartos; the superficial perineal branch of the internal pudic artery is distributed to the back part of the scrotum; and, lastly, more deeply seated than either of these is a branch given from the epigastric artery, named cremasteric, which is chiefly distributed to the cremaster muscle, but also supplies small branches to the other coverings of the cord, and by its ultimate divisions anastomoses with the other vessels. The artery of the vas deferens, a long slender vessel derived from the superior vesical, accompanies the tube in its whole length. The *veins*, which, from the thinness of the integuments, are apparent on the surface of the scrotum, follow the course of the arteries. The veins of the cord form the spermatic or pampiniform plexus elsewhere described. The *lymphatics* pass into the inguinal lymphatic glands.

The *nerves* also proceed from various sources. Thus, the ilio-inguinal, a branch of the lumbar plexus issuing by the external abdominal ring, supplies the integuments of the scrotum; this nerve is joined also by a filament from the ilio-hypogastric branch of the same plexus: sometimes two separate cutaneous nerves come forward through the external ring. The two superficial perineal branches of the internal pudic nerve accompany the artery of the same name and supply the inferior and posterior parts of the scrotum. The inferior pudendal, a branch of the small sciatic nerve, joins with the perineal nerves, and with them is distributed to the sides and fore part of the scrotum. Lastly, the spermatic branch of the genito-crural nerve reaching the spermatic cord at the internal abdominal ring, passes with it through the inguinal canal, and supplies the fibres of the cremaster muscle, besides sending a few filaments to the other deep coverings of the cord and testicle.



## THE TESTICLES.

The *testes*, or principal reproductive glands (*διδυμος, ορχις*), are suspended obliquely in the scrotum by means of the cord and membranes already described; they are usually placed at unequal heights, that of the left side being lower than the other. They are of an ovoid form, but are slightly compressed laterally, so that they have two somewhat flattened sides or faces, an upper and a lower end, an anterior and a posterior border. They are about an inch and a half long, an inch and a quarter wide from back to front, and nearly an inch thick from side to side. The weight of each varies from three-quarters of an ounce to an ounce, the left being often a little the larger of the two.

The front and sides of the testicle, together with the upper and the lower ends, are free, smooth, and closely invested by the tunica vaginalis. The posterior border is attached to the spermatic cord, and it is here that the vessels and nerves enter or pass out. When the testis is suspended in its usual position, its upper end is directed obliquely forwards and outwards, as well as upwards, whilst the lower, which is rather smaller, has the opposite direction. It follows from this that the posterior or attached border is turned upwards and inwards, and the outer flattened face slightly backwards.

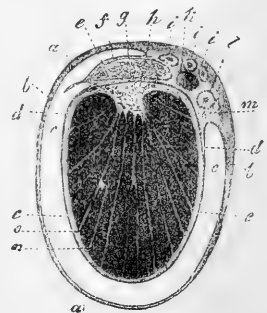
Attached to the posterior border of the gland, and resting also on the neighbouring portion of its outer face, is placed a long narrow body, the *epididymis*, which forms part of the excretory apparatus of the testicle, and is principally composed of the convolutions of a long tortuous canal or efferent duct, to be presently described. Its upper extremity, considerably larger than the lower, projects forwards on the upper end of the testis, and is named the *head* or *globus major*; the lower, which is more pointed, is termed the *tail*, or *globus minor*; whilst the intervening

Fig. 318.—TRANSVERSE SECTION THROUGH THE RIGHT TESTICLE AND THE TUNICA VAGINALIS (from Kölliker).

*a*, connective tissue enveloping the parietal layer of the tunica vaginalis; *b*, this layer itself; *c*, cavity of the tunica vaginalis; *d*, reflected or visceral layer adhering to *e*, the tunica albuginea; *f*, covering of epididymis (*g*) on the right or outer side; *h*, mediastinum testis; *i*, branches of the spermatic artery; *k*, spermatic vein; *l*, vas deferens; *m*, small artery of the vas deferens; *n*, lobules of the testis; *o*, septa or processes from the mediastinum to the surface.

portion is named the *body*. The convex surface of the epididymis and the thin anterior border are free, and covered by the tunica vaginalis. The concave surface, or that directed towards the testis, except at the upper and lower ends, is also free, and invested by the same tunic, which here forms the digital pouch between the epididymis and the outer face of the testicle, and nearly surrounds the epididymis, except along its posterior border, which is united to the gland by a duplicature of the serous membrane, containing numerous blood-vessels. At its upper and lower extremity, the epididymis is attached to the testicle by fibrous tissue and a reflection of the tunica vaginalis, the *globus major* also by the efferent ducts of the testicle.

Fig. 318.



At the back of the testis and epididymis, beneath the fascia propria, there is found, opposite the lower two-thirds of the testis, a considerable amount of unstriped muscular tissue, the inner muscular tunic of Kölliker.

Situated on the front of the globus major, somewhat to the outer side, there is usually found one or more small pedunculated bodies formed by an extension of the tunica vaginalis and containing connective tissue and blood-vessels. These are the *hydatids of Morgagni*. One of them of a more regularly pyriform shape and more constant than the rest, lies closely between the head of the epididymis and the testicle, and is regarded as the remains of the foetal structure termed Müller's duct.

The testis is enclosed in a strong capsule, the **tunica albuginea**. This is a dense unyielding fibrous membrane, of a white colour, and of considerable thickness, which immediately invests the soft substance of the testicle, and preserves the form of the gland. It is composed of bundles of fibrous tissue, which interlace in every direction. The surface is covered by the tunica vaginalis, except along the posterior border of the testicle, where the spermatic vessels pass through and the two extremities of the epididymis are attached.

In the interior, the fibrous tissue of the tunica albuginea is prolonged from the posterior border, for a few lines into the substance of the gland, so as to form within it an incomplete vertical septum, known as the *corpus Highmorianum*, and named by Astley Cooper *mediastinum testis*. It extends from the upper nearly to the lower end of the gland, and it is wider above than below. The firm tissue of which it is composed is traversed by a network of seminal ducts, and by the larger blood-vessels of the gland, which are lodged in channels formed in the fibrous tissue.

From the front and sides of the corpus Highmorianum numerous slender fibrous cords and imperfect septa of connective tissue are given off in radiating directions, and are attached by their outer ends to the internal surface of the tunica albuginea at different points, so as to assist in maintaining the general shape of the testicle, and enclose the several

Fig. 319.

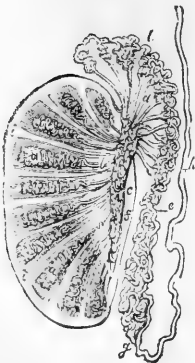


Fig. 319.—PLAN OF A VERTICAL SECTION OF THE TESTICLE, SHOWING THE ARRANGEMENT OF THE DUCTS.

The true length and diameter of the ducts have been disregarded. *a, a*, tubuli seminiferi coiled up in the separate lobes; *b*, vasa recta; *c*, rete vasculosum; *d*, vasa efferentia ending in the coni vasculosi; *l, e, g*, convoluted canal of the epididymis; *h*, vas deferens; *f*, section of the back part of the tunica albuginea; *i, i*, fibrous processes running between the lobes; *f* to *s*, mediastinum

lobes into which the substance of the gland is divided. According to Kölliker plain muscular fibres are prolonged upon these septula from behind. The whole internal surface of the tunica albuginea is covered by a multitude of fine blood-vessels, which are branches of the spermatic artery and veins, and are held together by a delicate areolar web. Similar delicate ramifications of vessels are seen on the various fibrous offsets of the mediastinum, upon which the blood-vessels are thus supported in the

interior of the gland. This vascular network, together with its connecting areolar tissue, constitutes the *tunica vasculosa* of Astley Cooper.

**Minute structure.—Seminal tubes.**—The proper glandular substance of the testicle is a soft but consistent mass of a reddish-yellow colour, which is divided into numerous small lobes of conical form, with the larger ends turned towards the surface of the testicle, and the smaller towards the mediastinum. The number of these *lobes* (*lobuli testis*) has been estimated at 250 by Berres, and at upwards of 400 by Krause. They differ in size according to their position, those which occupy the middle of the gland and reach its anterior border being longer and larger than the rest. They consist almost entirely of small convoluted tubes, named *tubuli seminiferi*, in the interior of which the seminal product is secreted. Each lobe contains one, two, three, or even more of these convoluted tubules, the coils of which, being only loosely held together, may be more or less successfully unravelled by careful dissection under water. Lauth estimates their mean number to be 840, and the average length of each two feet and a quarter. Their diameter, which is uniform throughout their whole course, is from  $\frac{1}{200}$ th to  $\frac{1}{150}$ th of an inch. They present two kinds of convolutions, each tube having a fine and regular undulation, which gives a granular appearance to the whole mass, and this undulating tube being again thrown into complicated folds, which are compressed so as to be elongated in the direction of the lobule. The lobules are never quite distinct, for here and there tubules are always to be found passing from one to another; and it sometimes happens that lobules which are divided by a distinct plane of contact at one part, are intimately connected at another; so that the division of the mass into lobules varies greatly in its extent, and hence the different estimates of the number of the lobules by different anatomists. The walls of the *tubuli seminiferi* are composed of a basement membrane consisting of several layers of flattened cells (Mihalkovics). The walls of the tubes are sufficiently strong to bear the forcible injection of mercury, which has been commonly employed for their investigation and their display in preserved specimens.

The mode in which the tubes commence appears to be twofold—viz., by free closed extremities, hid within the lobules, but more frequently by anastomosing arches or loops. After an exceedingly tortuous course, they at length, in approaching the corpus Highmori, become at first slightly flexuous and then nearly straight. The separate *tubuli* of each lobe, and then those of adjoining lobes, unite together into larger tubes, which enter the fibrous tissue of the mediastinum and, being placed amongst the branches of the blood-vessels, form the straight tubes or *vasa recta*.

**Spermatic Cells.**—The interior of the tubes is occupied by cellular contents which, in the young subject, assume somewhat the appearance of an epithelial lining, but in the adult fill the whole tube with a confused mass of cells. In some instances, however, the cells are ranged in radii from the circumference to the centre, and a passage or lumen is left in the interior. Throughout the mass the cells are in various stages of advance towards the formation of the seminal product, some fully formed spermatic filaments being seen in the centre, and the cells of the circumference being least developed.

It has been asserted by some observers that the spermatic cells are

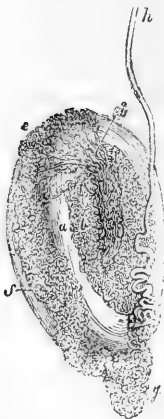
not free, but are embedded in a sort of protoplasmic trabecular network within which they are formed. This was first stated by Sertoli, in 1864, and more recently a detailed description of such a delicate trabecular structure has been given by Merkel, whose views are supported by several other observers. (Merkel, in Du Bois-Reymond's Archiv, 1869 and 1871, and La Valette St. George, in Schultze's Archiv, vol. i.) On the other hand it is asserted as the result of renewed observations that the alleged framework is the product of artificial processes. (Mihalkovics, in Ludwig's Arbeiten, 1874.) It seems most probable, therefore, that the seminal or spermatid cells are produced as in other tubular glands by development from the layer of cells lying originally on the inside of the basement membrane of the tubes. (Kölliker's Handbuch, 1867, p. 526.)

The intervals between the glandular tubes are occupied by blood-vessels, lymphatics and nerves, embedded in a peculiar tissue of a rather undefined character, but presenting a large quantity of the nuclear and molecular elements, so that Henle compares it to the cortical substance of the brain, or the contents of ganglionic cells. In this substance there are large interstitial spaces lined with flat nuclear epithelium, in which Ludwig and Tomsa have shown that the lymphatics of the testicle commence. (Wien. Sitzungsbericht, vol. xlv. p. 221, 1862.)

The *vasa recta* pursue a comparatively straight course; they are upwards of twenty in number, and are from  $\frac{1}{30}$ th to  $\frac{1}{70}$ th of an inch in diameter. They pass upwards and backwards through the fibrous tissue, as already stated, and end in a close network of tubes, named by Haller the *rete vasculosum testis*, which lies in the substance of the corpus Highmori, along the back part of the testicle, but in front of the primary subdivisions of the spermatid blood-vessels before these enter the gland. The tubes composing the rete have very thin walls. According to Kölliker, indeed, they have none proper to them, but are mere channels in

Fig. 320.

Fig. 320.—DUCTS OF THE TESTICLE INJECTED WITH MERCURY (from Haller).



*a*, body of the testicle; *b*, tubuli in the interior of the gland; *c*, rete vasculosum; *d*, vasa efferentia terminating in the coni vasculosi; *e*, *f*, *g*, convoluted canal of the epididymis; *h*, vas deferens ascending from the globus minor of the epididymis.

the fibrous stroma, lined with squamous epithelium. According to Henle the epithelium of the tubes in the rete testis already begins to assume the columnar character which it possesses in the after parts of the ducts. They conduct the secretion to the upper end of the testis, where they open into the vasa efferentia.

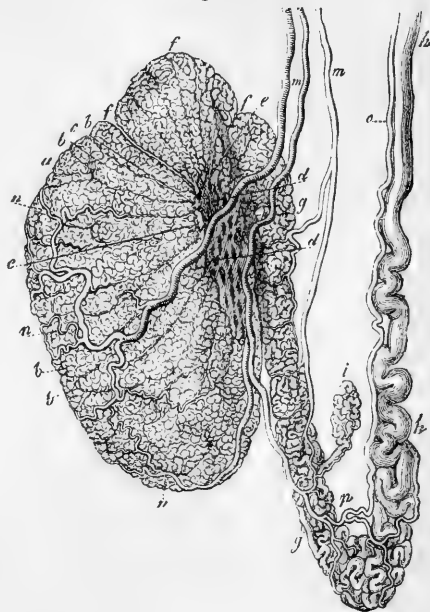
The *vasa efferentia* are from twelve to fifteen, or sometimes twenty in number; they perforate the tunica albuginea beneath the globus major of the epididymis, of which they may be said to form a part, and in the convoluted canal of which they ultimately terminate. On emerging from the testis, these vasa efferentia are straight, but, becoming more and more convoluted as they proceed towards the

epididymis, they form a series of small conical masses, the bases of which are turned in the same direction, and which are named *coni vasculosi*. They are about  $\frac{1}{50}$ th of an inch in diameter. Their walls contain, besides fibrous tissue, longitudinal and transverse plain muscular fibres. The largest of the cones is about eight lines long, and when unrolled, each is found to consist of a single coiled duct, varying from six to eight inches in length, and the diameter of which gradually decreases from the testis to the epididymis (Huschke). Opposite the globus major these separate efferent vessels open, at intervals which, in the unravelled tube, are found to be about three inches in length, into a single canal or duct, the intervening and subsequent convolutions of which constitute the epididymis itself.

The **canal of the epididymis** is disposed in very numerous coils, and extends from the globus major downwards to the globus minor or tail, where, turning upwards, it is continued on as the *vas deferens*. When its complicated flexuosities are unrolled, it is found to be twenty feet and upwards in length. The smallest windings are supported and held together by fine areolar tissue; but, besides this, numerous fibrous

Fig. 321.—INJECTED TESTICLE, EPIDIDYMIS, AND VAS DEFERENS (from Kölliker after Arnold).

Fig. 321.



*a*, body of the testicle; *b*, lobules; *c*, vasa recta; *d*, rete vasculosum; *e*, vasa efferentia; *f*, coni vasculosi; *g*, epididymis; *h*, vas deferens; *i*, vas aberrans; *m*, branches of the spermatic artery passing to the testicle and epididymis; *n*, ramification in the testis; *o*, deferential artery; *p*, its union with a twig of the spermatic artery.

partitions are interposed between larger masses of the coils, which have been named the *lobes* of the epididymis, the general direction of which is across that body. The canal of the epididymis is, at its commencement, about  $\frac{1}{70}$ th of an inch in diameter, but diminishing as it proceeds towards the globus minor, it is about  $\frac{1}{100}$ th of an inch, after which it again increases in size, and becomes less deeply convoluted as it approaches the vas deferens. Its coats, which are at first very thin, become thicker in its progress.

The vasa efferentia and the tube of the epididymis differ from the other portions of the ducts of the testis in the possession of thicker walls, provided with a considerable amount of plain muscular fibres. The epithelial lining cells are columnar or prismatic in form and are ciliated. In the epididymis the cells are greatly elongated, in the vasa efferentia they are shorter; in the lower part of the epididymis the cilia disappear

(O. Becker, 1856, corroborated in the human subject by Kölliker). The ciliary movement is stated by Becker to be in an outward direction in the ducts.

#### VAS DEFERENS.

The **vas deferens**, or excretory duct of the testis, is a hard nearly cylindrical tube, which forms the continuation upwards of the convoluted canal of the epididymis. It commences at the lower end of the epididymis, and, at first rather tortuous but afterwards becoming straight, it ascends upon the inner side of the epididymis, and along the back of the testicle, separated from both, however, by the blood-vessels passing to and from the gland. Continuing, then, to ascend in the spermatic cord, the vas deferens accompanies the spermatic artery, veins and nerves, as far as the internal abdominal ring. Between the testicle and the external ring its course is nearly vertical: it lies behind the spermatic vessels, and is readily distinguished by its hard cord-like feel. It then passes obliquely upwards and outwards along the inguinal canal, and reaching the inner border of the internal abdominal ring, it leaves the spermatic vessels (which extend to the lumbar region), and turns suddenly downwards and inwards into the pelvis, crossing over the external iliac vessels, and turning round the outer or iliac side of the epigastric artery. Running beneath the peritoneum, it reaches the side of the bladder, upon which it descends, curving backwards and downwards to the under surface of that viscus, and finally passes forwards to the base of the prostate gland. In its course within the pelvis, it crosses over the cord of the obliterated hypogastric artery, and lies to the inner side of the ureter. Beyond this point, where it ceases to be covered by the peritoneum, it is attached to the coats of the bladder, in contact with the rectum, and gradually approaching its fellow of the opposite side. Upon the base of the bladder, the vasa deferentia are situated between two elongated receptacles, named the seminal vesicles; and, close to the base of the prostate, each vas deferens ends by joining with the duct from the corresponding seminal vesicle on its outer side to form one of the common seminal or ejaculatory ducts.

The vas deferens measures nearly two feet in length. In the greater part of its extent it is cylindrical or slightly compressed, and has an average diameter of about one-tenth of an inch; but towards its termination, beneath the bladder, it becomes enlarged and sacculated, forming the *ampulla* of Henle, and resembling in shape and structure a part of the seminal vesicle. Previously to its junction with the duct of that vesicle, it again becomes narrowed into a smaller and straight cylindrical canal. The walls of the vas deferens are very dense and strong, and feel hard to the touch, owing to the large proportion their thickness bears to the inner cavity of the tube, which is scarcely more than one-sixth of the whole diameter. In the sacculated portion the passage is much wider, and the walls are thinner in proportion. Small simple and branched tubular glands, similar to those of the vesiculæ seminales, beset the mucous membrane of this portion of the duct (Henle).

Besides an external areolar investment, and an internal lining membrane, the vas deferens is provided with an intermediate thick tunic, which is dense in structure, somewhat elastic, and of a deep yellowish colour. This coat consists principally of longitudinal muscular fibres, mixed with some circular ones. Huschke describes two longitudinal

layers with intermediate circular fibres. The external and middle layers are thick and strong; but the internal longitudinal stratum is extremely thin, constituting not more than  $\frac{1}{5}$ th of the muscular coat. The vasa deferentia of the dog, cat, and rabbit were found by E. Weber to exhibit lively peristaltic contractions when stimulated by means of electricity.

The surface of the lining membrane is pale; it is thrown into three or four fine longitudinal ridges, and, besides this, in the sacculated portion of the duct, is marked by numerous finer rugæ which enclose irregular polyhedral spaces, resembling in this alveolar character the lining membrane of the vesiculæ seminales. The epithelium is of the columnar kind, and not ciliated.

**Vas aberrans.**—This name was applied by Haller to a long narrow tube, or diverticulum, discovered by him, and almost invariably met with, which leads off from the lower part of the canal of the epididymis, or from the commencement of the vas deferens, and, becoming tortuous and convoluted, is rolled up into an elongated mass which extends upwards for an inch or more amongst the vessels of the spermatic cord, where the tube ends by a closed extremity. Its length, when it is unravelled, ranges from about two to twelve or fourteen inches; and its width increases towards its blind extremity. Sometimes this diverticulum is branched, and occasionally there are two or more such aberrant ducts. Its structure appears to be similar to that of the vas deferens. Its origin is probably connected with the Wolffian body of the foetus, but the exact mode of its formation and its office are unknown. Luschka states that occasionally it does not communicate with the canal of the epididymis, but appears to be a simple serous cyst.

**Organ of Giralde's.**—The small body thus named is situated in the front of the cord immediately above the caput epididymis (see Fig. 317, G). It consists usually of several small irregular masses containing convoluted tubules lined with squamous epithelium, and is scarcely to be recognised until the surrounding connective tissue has been rendered transparent by re-agents. It has also received the name of *parepididymis*. Its tubules appear to be vestiges of the glomerular part of the Wolffian body. (Giralde's, in Bulletin de la Soc. Anat. de Paris, 1857, and in Journal de la Physiologie, 1861, also in Proceed. Roy. Soc. vol. ix, p. 231.)

#### THE SEMINAL VESICLES AND EJACULATORY DUCTS.

The **vesiculæ seminales** are two membranous receptacles, situated, one on each side, upon the base of the bladder, between it and the rectum. When distended, they form two long-shaped sacculated bodies, somewhat flattened on the side next the bladder, to which they are firmly attached, and convex on their inferior surface; they are widened behind and narrow in front. Their length is usually about two inches, and their greatest breadth from four to six lines; but they vary both in size and shape in different individuals, and also on opposite sides of the same subject.

Their posterior obtuse extremities are separated widely from each other, but anteriorly they converge so as to approach the two vasa deferentia, which run forwards to the prostate between them. With

the vasa deferentia thus interposed, they occupy the two diverging sides of the triangular portion of the base of the bladder, which lies upon the rectum, and is bounded behind by the line of reflexion of the recto-vesical fold of the peritoneum. The seminal vesicles themselves also rest upon the rectum, but are separated from it by a layer of the recto-vesical fascia, which attaches them to the base of the bladder.

Fig. 322.

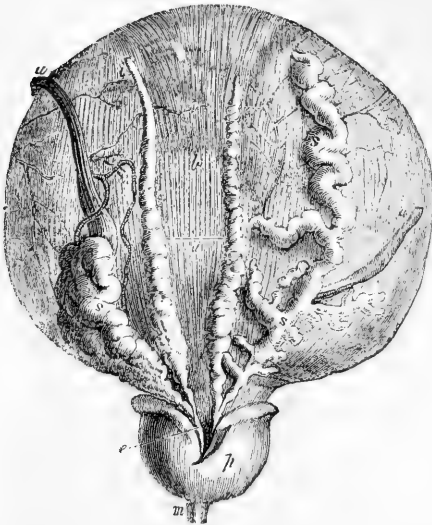

Fig. 322.—DISSECTION OF THE BASE OF THE BLADDER AND PROSTATE GLAND, SHOWING THE VESICULÆ SEMINALES AND VASA DEFERENTIA (from Haller).

*a'*, lower surface of the bladder at the place of reflexion of the peritoneum; *b*, the part above covered by the peritoneum; *i*, left vas deferens, ending in *e*, the ejaculatory duct; *s*, left vesicula seminalis joining the same duct; *s*, *s*, the right vas deferens and right vesicula seminalis, which has been unravelled; *p*, under side of the prostate gland; *m*, part of the urethra; *u*, *u*, the ureters, the right one turned aside.

The sacculated appearance of the vesiculæ seminales is owing to their peculiar formation. Each consists of a tube somewhat coiled and repeatedly

doubled on itself, and firmly held in that condition by a dense fibrous tissue. When unrolled, this tube is found to be from four to six inches long, and about the width of a quill. Its posterior extremity is closed, so that it forms a long cul-de-sac; but there are generally, if not always, several longer or shorter branches or diverticula connected with it, which also end by closed extremities. The anterior extremity of the tube of the vesicula, becomes straight and narrowed, and ends opposite the base of the prostate by uniting on its inner side, at an acute angle, with the narrow termination of the corresponding vas deferens to form a single canal, which is the common seminal or ejaculatory duct.

In structure, the vesiculæ seminales resemble very closely the adjoining sacculated portions of the vasa deferentia. Besides an external fibro-areolar investment, connected with the recto-vesical fascia, they have a proper coat, which is firm, dense, and somewhat elastic, and consists of rigid white fibres and of others of a deep yellowish-brown hue. The muscular layer of the walls is thin compared to that of the vas deferens; but a considerable amount of plain muscular tissue is found covering the posterior surface and extending transversely between the two vesiculæ. There are also longitudinal muscular fibres traced from those of the bladder. (Ellis and Henle.) The mucous membrane is pale, or has a light yellowish-brown colour, given to it apparently by the tubular glands which beset it in the same manner as in the ampulla



of the vas deferens. It is traversed by very many fine rugæ, which form an alveolar structure resembling that seen in the gall-bladder, but deeper and enclosing much finer meshes. The epithelium of the vesiculæ is of the short prismatic kind; its particles have a granular character.

The seminal vesicles serve as receptacles or reservoirs for the semen, as is proved by a microscopic examination of their contents; but, besides this, it is probable that they secrete a peculiar fluid which is incorporated with the semen.

The **common seminal or ejaculatory ducts**, two in number, are formed on each side by the junction of the narrowed extremities of the corresponding vas deferens and vesicula seminalis, close to the base of the prostate gland. From this point they run forwards and upwards, at the same time approaching each other, and then pass side by side through the prostate between its middle and two lateral lobes. After a course of nearly an inch, during which they become gradually narrower, they end in the floor of the prostatic portion of the urethra by two small slit-like orifices placed on the verumontanum, one on each prominent margin of the opening of the prostatic sinus. For a short distance the ejaculatory ducts run in the substance of the walls of the vesicle.

The coats of the common seminal duct, as compared with those of the vas deferens and vesicula, are very thin. The strong outer tunic almost entirely disappears after the entrance of the ducts between the lobes of the prostate, but muscular fibres may be traced into the prostatic portion; and the mucous membrane becomes gradually smoother as it passes into that of the urethra. According to Henle, the muscular fibres of the duct are separated by blood-vessels as it passes through the prostate and form the trabeculæ of a layer of cavernous tissue.

These ejaculatory ducts convey the fluid; contained in the seminal vesicles and vasa deferentia into the urethra. Their canal gradually narrows as they approach their termination, where its diameter is reduced to the fiftieth of an inch.

#### VESSELS AND NERVES OF THE TESTIS.

The testicle and its excretory apparatus receive blood-vessels and nerves from sources which are different from those giving the vascular and nervous supply of the coverings of those parts.

The **spermatic artery**, or proper artery of the testicle, is a slender and remarkably long branch, which arises from the abdominal aorta, and passing down the posterior abdominal wall reaches the spermatic cord, and descends along it to the gland. In early foetal life its course is much shorter, as the testis is then situated near the part of the aorta from which the artery arises. As the vessel approaches the testicle, it gives off small branches to the epididymis, and then divides into others which perforate the tunica albuginea at the back of the gland, and pass through the corpus Highmorianum; some spread out on the internal surface of the tunica albuginea, whilst others run between the lobes of the testis, supported by the fibrous processes of the mediastinum. The smallest branches ramify on the delicate membranous septa between the lobes, before supplying the seminiferous tubes.

The vas deferens receives from the superior vesical artery a long slender branch which accompanies the duct, and hence is named the

**deferent artery**, or *artery of the vas deferens*. It ramifies on the coats of the duct, and reaches as far as the testis, where it anastomoses with the spermatic artery.

The **spermatic veins** commence in the testis and epididymis, pass out at their posterior border, and unite into larger vessels, which freely communicate with each other as they ascend along the cord, and form the *pampiniform plexus*. Ultimately two or three veins follow the course of the spermatic artery into the abdomen, where they unite into a single trunk, that of the right side opening into the vena cava, and that of the left into the left renal vein.

The **lymphatics** accompany the spermatic vessels and terminate in the lumbar lymphatic glands, which encircle the large blood-vessels in front of the vertebral column. According to Ludwig and Tomsa, as previously stated, they begin from intercommunicating lymph spaces which occupy the intervals between the tubuli seminiferi.

The **nerves** are derived from the sympathetic system. The spermatic plexus is a very delicate set of nervous filaments, which descend upon the spermatic artery from the aortic plexus. Some additional filaments, which are very minute, come from the hypogastric plexus, and accompany the artery of the vas deferens. It is affirmed by Letzerich (Virchow's Archiv, vol. xlii., p. 510), that the axial filaments of the nerves penetrate the external wall and membrana propria of the seminal tubes, and terminate within in "shining granular protoplasmic masses." These observations, however, have not been confirmed on examination by La Valette St. George. (Stricker's Handbuch, p. 543.)

The vesiculæ seminales receive branches from the inferior vesical and middle hæmorrhoidal arteries. The veins and lymphatics correspond. The nerves belong to the sympathetic system, and come from the hypogastric plexus.

**The Semen.**—The *semen* is a thick whitish fluid, which consists of a liquor seminis, the seminal granules, and the spermatic filaments. It is the combined product of the testes and the accessory generative glands.

Fig. 323.



Fig. 323.—SPERMATIC FILAMENTS FROM THE HUMAN VAS DEFERENS (from Kölliker).

1, magnified 350 diameters; 2, magnified 800 diameters; a, from the side; b, from above.

The **liquor seminis** is colourless, transparent, and of an albuminous nature. It contains floating in it, besides squamous and columnar epithelium cells, oil-like globules and minute granular matter, *seminal granules* (Wagner), and the *spermatozoa* or spermatic filaments.

The **seminal granules** are rounded colourless corpuscles, having a granular aspect. They have an average diameter of about  $\frac{1}{4000}$ th of an inch, and may be allied to mucus-corpuscles.

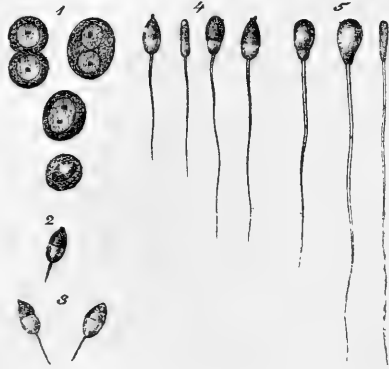The **Spermatic filaments** or Corpuscles (Spermatozoa, spermatic animalcules,) are peculiar microscopic bodies which constitute the essential element for fecundation of the ovum. During life, and for some hours after being removed from the testicle, they perform rapid

vibratory or lashing movements. Each consists of a flattened oval part or so-called body, and of a long slender filiform tail. The body is about  $\frac{1}{6000}$ th of an inch long and  $\frac{1}{10000}$ th broad, and the entire corpuscle is from  $\frac{1}{500}$ th to  $\frac{1}{200}$ th of

an inch in length. The body often contains a minute spot, and at its junction with the narrow filament or tail, there is frequently a slight thickening, or

Fig. 324. — SPERMATIC CELLS AND FILAMENTS OF THE BULL UNDERGOING DEVELOPMENT (from Kölliker).

1, spermatic cells with one or two nuclei, one of them clear; 2, 3, free nuclei with spermatic filaments forming; 4, the filaments elongated and the body widened; 5, filaments nearly fully developed.



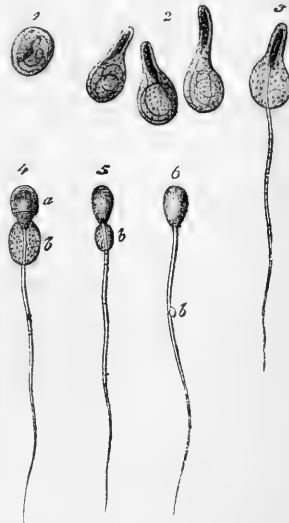
projecting fringe or collar, which is most apparent in corpuscles not fully developed.

The spermatic corpuscles are produced by a process of transformation taking place within the cells which occupy the seminiferous tubes of the body of the testicle: it is completed in the progress of the cells through the rete testis and vasa efferentia, in which last most of the spermatic filaments are free, and have acquired their vibratory motile power. The process of transformation was first clearly shown by Kölliker in mammalia, in which he described the spermatic cells as having formed within them by division a smaller or greater number of

Fig. 325.—ESCAPE OF THE SPERMATIC CORPUSCLES FROM THEIR CELLS, IN THE SAME ANIMAL.

1, spermatic cell containing the spermatozoon coiled up within it; 2, the cells elongated by the partial uncoiling of the spermatic filament; 3, a cell from which the filament has in part become free; 4, the same with the body also partially free; 5, spermatozoon from the epididymis with vestiges of the cell adherent; 6, spermatozoon from the vas deferens showing the small enlargement, *b*, on the filament.

Fig. 325.



nuclei, each one of which gives rise to a filamentous corpuscle. (Handbuch der Gewebelehre, 1867, p. 527, and Zeitsch. f. Wissen. Zool., vol. vii.) Subsequent observers have in the main confirmed the views of Kölliker, the only difference of importance between them being that some, as Merkel and La Valette St. George, appear to regard the internal progeny of the spermatic cells as complete cells rather than nuclei. Adopting the language of the latter observers, it appears that the so-called body or head of the corpuscle is produced by a change of form and consistence in the part of the cell containing the nucleus, which projects more and more to one side: the tail or filament begins as a fine-pointed projection from the opposite side of the cell, and extends rapidly as a filament, at first within the cell-wall, bulging out the wall as it increases in length, and finally breaking through its confine-

ment. The slight intermediate enlargement, which some have called body, and which is most to be seen before the process of formation is complete, appears to be due to the remains of the cell adhering to the head and tail, which have extended beyond its confines. The nucleolus may be seen for a time within the head. (Schweigger-Seidel, in Schultze's Archiv, vol. i., La Valette St. George, in Stricker's Handbuch, p. 539, Merkel, in Du Bois-Reymond's Archiv, 1871.)

The vibratile or lashing motion of the filament belongs to the fully developed condition of the corpuscle, and causes the progressive eel-like advance when floating in fluid. It is closely allied to ciliary motion, and, indeed, the spermatic corpuscle may be regarded as in some measure analogous to a unciliated cell.

The filamentous form and ciliary vibratile movement belong to the fully developed spermatic corpuscles of by far the greater number of animals, extending to the lowest as well as the highest in the scale. Exceptional non-filamentous forms, with absence of vibratile motion occur in the crustacea and nematoid worms, but the origin of the corpuscles from spermatic cells is nevertheless the same in these as in other animals.

(Wagner and Leuckart, Article "Semen" in Cyclop. of Anat. and Phys.; Kölliker in Handbuch.)

## REPRODUCTIVE ORGANS IN THE FEMALE.

The reproductive organs in the female consist of the ovaries, uterus, and Fallopian tubes, which are named the *internal*, and the vagina, clitoris, nymphæ, labia, and other parts included in the vulva, named the *external* organs of generation.

### THE VULVA

The *vulva*, or *pudendum*, is a general term, which includes all the parts perceptible externally, viz., the mons Veneris, the labia, the hymen or carunculæ, the clitoris, and the nymphæ. The urethra also may be described in connection with these parts.

**Integuments and Labia.**—The integument on the fore part of the pubic symphysis, elevated by a quantity of areolar and adipose substance deposited beneath it, and covered with hair, is termed the *mons Veneris*. The *labia pudendi* (labia externa v. majora) extend downwards and backwards from the mons, gradually becoming thinner as they descend. They form two rounded folds of integument so placed as to leave an elliptic interval (*rima*) between them, the outer surface of each being continuous with the skin, and covered with scattered hairs, whilst the inner is lined by the commencement of the genito-urinary mucous membrane. Between the skin and mucous membrane there is found, besides fat, vessels, nerves, and glands, some tissue resembling that of the dartos in the scrotum of the male, to which the labia in the main correspond. The labia majora unite beneath the mons and also in front of the perineum, the two points of union being called the anterior and posterior commissures. The posterior or inferior commissure is about an inch distant from the margin of the anus, and this interval is named the perineum of the female. Immediately within the posterior commissure, the labia are connected by a slight transverse fold (*frænulum pudendi*), which has also received the name of *fourchette*, and is frequently torn in the first parturition. The space between it and the commissure has been called *fossa navicularis*.

**Clitoris.**—Beneath the anterior commissure, and concealed between the labia, is the *clitoris*, a small elongated body corresponding in conformation and structure to a diminutive penis, but differing in having

no corpus spongiosum or urethra connected with it below. It consists of two *corpora cavernosa*, which are attached by *crura* to the rami of the ischium and pubes, and are united together by their flattened inner surfaces so as to form an incomplete pectiniform septum. The body of the clitoris, which is about an inch and a half long, but is hidden beneath the mucous membrane, is surmounted by a small *glans*, consisting of spongy erectile tissue. The glans is imperforate, highly sensitive, and surrounded superiorly by a membranous fold, analogous to the prepuce. There is a small suspensory ligament attached to the upper border, like that of the penis, and in front of this the clitoris is dependent. The two ischio-cavernous muscles, named in the female *erectores clitoridis*, have the same connections as in the male, being inserted into the *crura* of the *corpora cavernosa*.

**Nymphæ.**—From the glans and preputial covering of the clitoris two narrow pendulous folds of mucous membrane pass backwards for about an inch and a half, one on each side of the entrance to the vagina. These are the *nymphæ* (*labia interna v. minora*). Their inner surface is continuous with that of the vagina; the external insensibly passes into that of the *labia majora*. They contain vessels between the laminae of tegumentary membrane, but, according to Kobelt, no erectile plexus; indeed, they would seem to correspond to the cutaneous covering of the male urethra (supposed to be split open below), while the erectile structure corresponding to the bulb and spongy body, in two separate right and left halves, lies deeper, as will be presently explained. (Kobelt *Die männlichen und weiblichen Wohlustergane*, 1844.)

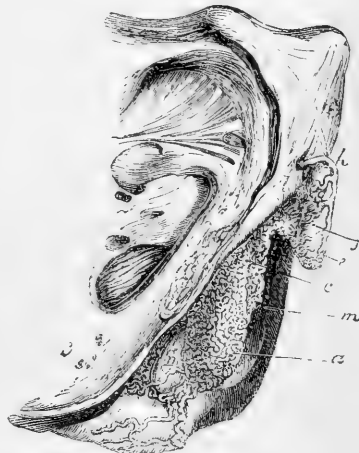Fig. 326.—LATERAL VIEW OF THE ERECTILE STRUCTURES OF THE EXTERNAL ORGANS IN THE FEMALE (from Kobelt).  $\frac{2}{3}$

The blood-vessels have been injected, and the skin and mucous membrane have been removed; *a*, bulbus vestibuli; *c*, plexus of veins named *pars intermedia*; *e*, glans clitoridis; *f*, body of the clitoris; *h*, dorsal vein; *l*, right crus clitoridis; *m*, vestibule; *n*, right gland of Bartholin.

**Vestibule.**—Between the nymphæ is the angular interval called the *vestibule*, in which is situated the circular *orifice* of the *urethra*, or *meatus urinarius*, about an inch below the clitoris and just above the entrance to the vagina. The membrane which surrounds this orifice is rather prominent in most instances, so as readily to indicate its situation.

**Orifice of the Vagina.**—Immediately below the orifice of the urethra is the *entrance* to the *vagina*, which, in the virgin, is usually more or less narrowed by the *hymen*. This is a thin duplicature of the mucous membrane, placed at the entrance to the vagina; its form varies very considerably in different persons, but is most frequently semilunar, the concave margin being directed forwards towards the

Fig. 326.



pubes. Sometimes it is circular, and is perforated only by a small round orifice, placed usually a little above the centre; and occasionally it is cribriform, or pierced with several small apertures; and it may in rare instances completely close the vagina, constituting "imperforate hymen." On the other hand, it is often reduced to a mere fringe, or it may be entirely absent. After its rupture, some small rounded elevations remain, called *carunculae myrtiformes*.

The **mucous membrane** may be traced inwards from the borders of the labia majora, where it is continuous with the skin: it forms a fold over the vascular tissue of the nymphæ, and is then prolonged into the urethra and vagina. It is smooth, reddish in colour, is covered by a scaly epithelium, and is provided with a considerable number of mucous crypts or follicles, and with glands which secrete an unctuous and odorous substance. The mucous crypts and follicles are especially distinct on the inner surface of the nymphæ, and near the orifice of the urethra. The sebaceous glands are found beneath the prepuce, and upon the labia majora and outer surface of the nymphæ.

The **glands of Bartholin** (or of Duverney), corresponding to Cowper's glands in the male, are two reddish yellow round or oval bodies, measuring about half an inch in the longest diameter, lodged one on each side of the commencement of the vagina, between it and the *erectores clitoridis* muscles, beneath the superficial perineal fascia, and in front of the transverse muscles. Their ducts, which are long

Fig. 327.

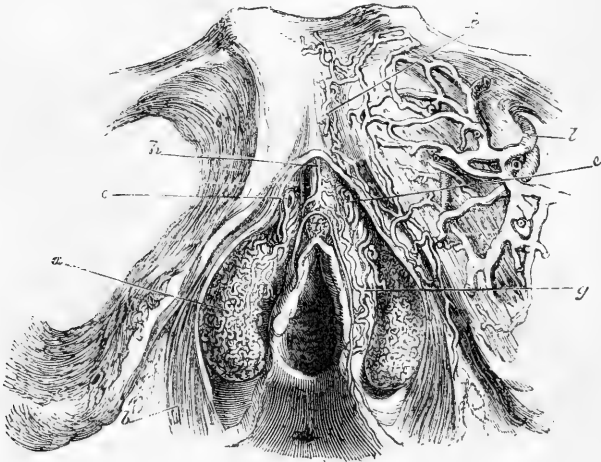


Fig. 327.—FRONT VIEW OF THE ERECTILE STRUCTURES OF THE EXTERNAL ORGANS IN THE FEMALE (from Kobelt). 3

*a*, bulbus vestibuli; *b*, sphincter vaginae muscle; *c, c*, venous plexus or pars intermedia; *f*, glans clitoridis; *g*, connecting veins; *h*, dorsal vein of the clitoris; *k*, veins passing beneath the pubes; *l*, the obturator vein.

and single, run forward and open on the inner aspect of the nymphæ, outside the hymen or *carunculae myrtiformes*.

**Erectile tissue.**—All the parts of the vulva are supplied abundantly

with blood-vessels, and in certain situations there are masses composed of venous plexuses, or erectile tissue, corresponding to those found in the male. Besides the corpora cavernosa and glans clitoridis, already referred to, there are two large leech-shaped masses, the *bulbi vestibuli*, about an inch long, consisting of a network of veins, enclosed in a fibrous membrane, and lying one on each side of the vestibule, a little behind the nymphæ. They are rather pointed at their upper extremities, and rounded below: they are suspended, as it were, to the crura of the clitoris and the rami of the pubes, covered internally by the mucous membrane, and embraced on the outer side by the fibres of the constrictor vaginae muscle. They are together equivalent to the bulb of the urethra in the male, which, it will be remembered, presents traces of a median division. In front of the bipartite bulb of the vestibule is a smaller plexus on each side, the vessels of which are directly continuous with those of the bulbus vestibuli behind, and of the glans clitoridis in front. This is the *pars intermedia* of Kobelt, and is regarded by him as corresponding with the part of the male corpus spongiosum urethrae which is in front of the bulb: it receives large veins coming direct from the nymphæ.

**Blood-Vessels.**—The outermost parts of the vulva are supplied by the superficial pudendal arteries; the deeper parts and all the erectile tissues receive branches from the internal pudic arteries, as in the male. The veins also in a great measure correspond; there is a vena dorsalis clitoridis, receiving branches from the glans and other parts as in the male; the veins of the bulbus vestibuli pass backwards into the vaginal plexuses, and are connected also with the obturator veins: above they communicate with the veins of the *pars intermedia*, those of the corpora cavernosa and the glans of the clitoris, and also with the vena dorsalis. The lymphatics accompany the blood-vessels.

**Nerves.**—Besides sympathetic branches, which descend along the arteries, especially for the erectile tissues, there are other nerves proceeding from the lumbar and sacral plexuses; those from the former being branches of the genitocrural, and those from the latter of the inferior pudendal and internal pudic nerves, which last sends comparatively large branches to the clitoris. The mode of termination is not known with certainty; tactile corpuscles have been seen in the human clitoris, and Pacinian bodies in that of some animals.

#### THE FEMALE URETHRA.

The *female urethra* is short as compared with that of the male sex. It is about an inch and a half in length, and is wide and capable of great distension; its ordinary diameter is about three or four lines, but it enlarges towards its vesical orifice. The direction of this canal is mainly downwards with a slight curvature forwards. It lies embedded in the anterior wall of the vagina, from which it can only be separated by dissection.

The external orifice, or *meatus urinarius*, opens in the vulva, nearly an inch below and behind the clitoris; between the nymphæ, and immediately above the entrance to the vagina. From its orifice, which is its narrowest part, the canal passes upwards and backwards between the crura of the clitoris and behind the pubes, gradually enlarging into a funnel-shaped opening as it approaches and joins the neck of the bladder. There is also a dilatation in the back of the canal, just within the meatus.

The mucous membrane is whitish, except near the orifice; it is raised into longitudinal plicæ, which are not entirely obliterated by distension, especially one which is particularly marked on the lower or posterior surface of the urethra. Near the bladder the membrane is soft and pulpy, with many tubular mucous glands. Lower down these increase in size and lie in groups between the longitudinal folds, and immediately within and around the orifice, the lips of which are elevated, are several larger and wider crypts.

The lining membrane is covered with a scaly epithelium, but near the bladder the particles become spheroidal. The submucous areolar tissue contains elastic fibres. Outside this there is a highly vascular structure, in which are many large veins. Between the anterior and posterior layers of the triangular ligament, the female urethra is embraced by the fibres of the compressor urethræ muscle.

The *vessels* and *nerves* of the female urethra are very numerous, and are derived from the same sources as those of the vagina.

#### THE VAGINA.

The *vagina* is a membranous and dilatable passage, extending from the vulva to the uterus, the neck of which is embraced by it. It rests below and behind on the rectum, supports the bladder and urethra in front, and is enclosed between the levatores ani muscles at the sides. It is slightly curved and is directed upwards and backwards: its axis corresponding below with that of the outlet of the pelvis, and higher up with that of the pelvic cavity. In consequence of its curvature and its reaching higher on the back than on the front of the os uteri, its length is greater along the posterior than along the anterior wall, by about an inch and a half. Each end of the vagina is somewhat narrower than the middle part: the lower, which is continuous with the vulva, is the narrowest part, and has its long diameter from before backwards; the middle part is widest from side to side, being flattened from before backwards, so that its anterior and posterior walls are ordinarily in contact with each other: at its upper end it is rounded, and expands to receive the vaginal portion of the neck of the uterus, which is embraced by it at some distance above the os uteri. The vagina reaches higher up on the cervix uteri behind than in front, so that the uterus appears, as it were, to be inserted into its anterior wall.

On the *inner surface* of the vagina, anteriorly and posteriorly, a slightly elevated ridge extends from the lower end upwards in the middle line, forming the *columns* of the vagina, or *columnæ rugarum*. Numerous dentated transverse ridges, called *rugæ*, are also observed, particularly in persons who have not borne children, running at right angles from the columns. These columns and rugæ are most evident near the entrance of the vagina and on the anterior surface, and gradually become less marked, and disappear towards its upper end.

**Structure and connections.**—The walls of the vagina are thickest in front, in the vicinity of the urethra, which indeed may be said to be imbedded in the anterior wall of the vaginal passage; in other situations they are thinner. The vagina is firmly connected by areolar tissue to the neck of the bladder, and only loosely to the rectum and levatores ani muscles; at the upper end, for about a fourth part of its length, its posterior surface receives a covering from the peritoneum,



which descends in the form of a cul-de-sac thus far between the vagina and the rectum.

Externally the vagina presents a coat of dense areolar tissue, and beneath this its walls are composed of unstriated muscle, which is not

Fig. 323.

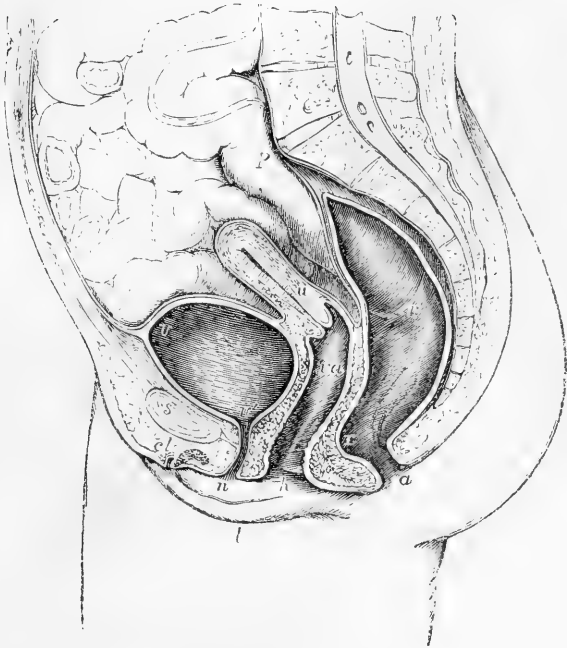


Fig. 323.—SECTIONAL VIEW OF THE VISCERA OF THE FEMALE PELVIS (after Houston and from nature). (A. T.)  $\frac{1}{4}$

The pelvic viscera having been distended and hardened with alcohol previously to making the section, appear somewhat larger than natural. *p*, promontory of the sacrum; *s*, symphysis of the pubes; *v*, the upper part of the urinary bladder; *v'*, the neck; *v', n*, the urethra; *u*, the uterus; *va*, the vagina; *r*, the point of union of the middle and lower parts of the rectum; *r'*, the fold between the middle and upper parts of the rectum; *a*, the anus; *l*, the right labium; *n*, the right nymphæ; *h*, the hymen; *cl*, the divided clitoris with the prepuce.

distinctly separable into strata, but is composed chiefly of fibres internally circular and externally longitudinal. Round the tube a layer of loose erectile tissue is found, which is most marked towards the vulva.

At its lower end, the vagina is embraced by striated muscular fibres, which constitute the *sphincter vaginae*, already described.

The mucous membrane, besides the columns and rugæ, is provided with conical and filiform papillæ, numerous muciparous glands and follicles, especially in its upper smoother portion and round the cervix uteri. This membrane, which is continuous with that of the uterus, is covered with a squamous epithelium.

**Vessels and Nerves.**—The vagina is largely supplied with vessels and nerves. The arteries are derived from branches of the internal iliac, viz., the vaginal, internal pudic, vesical, and uterine. The veins correspond; but they first surround the vagina with numerous branches, and form at each side a plexus named the *vaginal plexus*. The nerves are derived from the hypogastric plexus of the sympathetic, and from the fourth sacral and pudic nerves of the spinal system; the former are traceable to the erectile tissue.

#### THE UTERUS.

The *uterus* (or *womb*, *matrix*, *ἰστέρον*.) is a hollow, muscular organ, with very thick walls, situated in the pelvic cavity between the rectum and the urinary bladder. In the case of pregnancy it receives the ovum, retains and supports it during the development of the fœtus, and expels it at the time of parturition. The Fallopian tubes, extending from each upper angle of the uterus to their ovarian opening, conduct the ovum from the ovary to the uterine cavity. During utero-gestation, the uterus undergoes a great enlargement in size and capacity, as well as important structural changes.

Fig. 329.

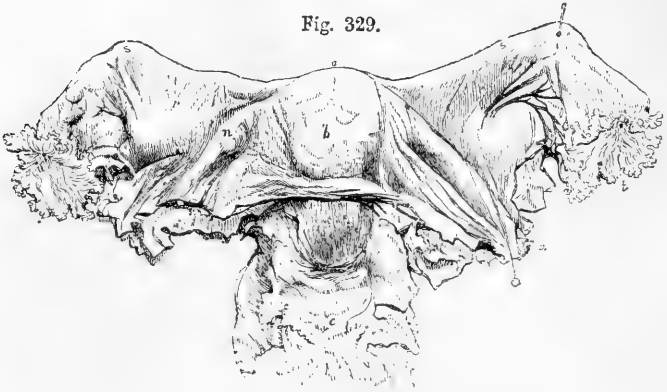


Fig. 329.—ANTERIOR VIEW OF THE UTERUS AND ITS APPENDAGES.  $\frac{1}{2}$

*a*, fundus; *b*, body; *c*, cervix; *e*, front of the upper part of the vagina; *n, n*, round ligaments; *r, r*, broad ligaments; *s, s*, Fallopian tubes; *t*, their fimbriated extremities; *u*, ostium abdominale; the position of the ovaries is indicated through the broad ligaments, and the cut edge of the peritoneum is shown along the side of the broad ligaments and across the front of the uterus.

In the fully developed virgin condition, which is that to which the following description mainly applies, it is a somewhat pear-shaped body, flattened from before backwards, free above, and connected below with the vagina, into the upper end of which its lower extremity projects. It does not reach above the brim of the pelvis. Its upper end is directed upwards and forwards, the lower downwards and backwards; so that its axis corresponds with that of the inlet of the pelvis, and forms an angle or sudden curve with the axis of the vagina, which corresponds more nearly with that of the outlet of the cavity. The uterus projects upwards into a fold of the peritoneum, by which the body is invested both before and behind, and the neck also behind, but in front the peritoneum does not descend farther than the body. Its free surface is in

contact with the other pelvic viscera, some convolutions of the small intestine usually lying upon and behind it. From its two sides the peritoneum is reflected in the form of a broad duplicature, named the *ligamentum latum*, which, together with the parts contained within it, will be presently described.

The average dimensions of the uterus are about three inches in length, two in breadth at its upper and wider part, and nearly an inch in thickness : its weight is from seven to twelve drachms. It is usually described as possessing a *fundus*, body, and neck.

The *fundus* is the broad bulging upper end of the body, and projects upwards from between the points of attachment of the Fallopian tubes. The *body* gradually narrows as it extends from the fundus to the neck ; its sides are nearly straight ; its anterior and posterior surfaces are both somewhat convex, but the latter more so than the former. At the points of union of the sides with the rounded superior border are two projecting angles, with which the Fallopian tubes are connected, the round ligaments being attached a little before, and the ovarian ligaments behind and beneath them ; these three parts are all included within the peritoneal duplicature of the broad ligaments. The *neck*, or *cervix uteri*, narrower and more rounded than the rest of the organ, is nearly an inch in length ; it is continuous above with the body, and, becoming somewhat smaller towards its lower extremity projects into the upper end of the tube of the vagina, which is united all round with the substance of the uterus, but extends upwards to a

Fig. 330.

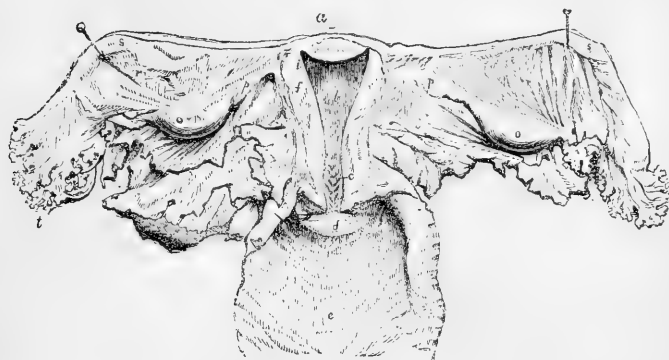


Fig. 330.—POSTERIOR VIEW OF THE UTERUS AND ITS APPENDAGES.

The cavity of the uterus has been opened by the removal of the posterior wall, and the upper part of the vagina has been laid open ; *a*, fundus ; *b*, body ; *c*, cervix ; *d*, anterior lip of the os uteri externum ; *e*, the interior of the vagina ; *f*, section of the walls of the uterus ; *i*, opening of the Fallopian tube ; *o*, ovary ; *p*, ligament of the ovary ; *r*, broad ligament ; *s*, Fallopian tube, *t*, its fimbriated extremity.

greater distance behind than in front. The projecting portion of the uterus is sometimes named the *vaginal part*. The lower end of the uterus presents a transverse aperture, by which its cavity opens into the vagina ; this is named variously *os uteri*, *os uteri externum*, and (from a supposed likeness to the mouth of the tench fish) *os tincae*. It is bounded by two thick lips, the posterior of which is the thinner and

longer of the two, while the anterior, although projecting less from its vaginal attachment, is lower in position, and, when the tube is closed, comes into contact with the posterior wall of the vagina. These borders or lips are generally smooth, but, after parturition, they frequently become irregular, and are sometimes fissured or cleft.

The walls of the uterus are of great thickness, and the cavity is thus proportionately much reduced in size. The part within the body is triangular, and flattened from before backwards, so that its anterior and posterior walls touch each other. The base of the triangle is directed upwards, and is curvilinear, the convexity being turned towards the interior of the uterus. The cavity, narrowing gradually, is prolonged through the wall of the organ towards its two superior angles, at each of which a minute foramen leads into the narrow canal of the Fallopian tube. At the junction of the body with the neck, the cavity is slightly constricted, and thus forms what is sometimes named the *internal orifice* (*os uteri internum, isthmus vel ostium uteri*); this opening is often smaller than the *os externum*, and is of a circular form. That portion of the cavity which is within the *neck* is tubular and slightly flattened before and behind; it is somewhat dilated in the middle, and opens inferiorly into the vagina by the *os tinæ*. Its inner surface is marked by two longitudinal ridges or columns, which run, one on the anterior, the other on the posterior wall, and from both of which rugæ are directed obliquely upwards on each side, so as to present an appearance which has been named *arbor vite uterinus*, also *palmeæ plicatæ*: this structure is most strongly marked anteriorly.

**STRUCTURE.**—The walls of the uterus consist of an external serous covering, an internal mucous membrane, and a thick intermediate substance which is chiefly muscular. The serous covering or *peritoneal* layer has been already referred to.

**Muscular Wall.**—The thick middle part of the wall of the uterus is of a very dense consistence: it is mainly composed of bundles of muscular fibres of the plain variety, of small size in the unimpregnated uterus, but greatly enlarged in the gravid state. These fibres interlace closely with each other, but are disposed in bands and layers, and are intermixed with fibro-areolar tissue, a large number of blood-vessels and lymphatics, and some nerves. The areolar tissue is more abundant near the outer surface. The arrangement of the muscular fibres is best studied in the uterus at the full period of gestation, in which the bands and layers formed by them become augmented in size, and much more distinctly developed. They may be referred to three sets or orders, viz., external, internal, and intermediate. Those of the *external* set are arranged partly in a thin superficial sheet, immediately beneath the peritoneum, and partly in bands and incomplete strata, situated more deeply. A large share of these fibres, beginning as longitudinal bands at the cervix, arch transversely and obliquely over the fundus and adjoining part of the body of the organ, and converge at either side towards the commencement of the round ligaments, along which they are in part prolonged to the groin. Others pass off in like manner to the Fallopian tubes, and strong transverse bands from the anterior and posterior surfaces are extended into the ovarian ligaments. A considerable number of thinly scattered fibres also pass at each side into the duplicature of the broad ligament, and others are described as running back from the cervix of the uterus into the recto-uterine folds of

the peritoneum. The fibres of the subperitoneal layer are much mixed with areolar tissue, especially about the middle of the anterior and posterior surfaces of the uterus, in which situation many of the superficial fibres appear to have as it were a median attachment from which they diverge. The fibres of the *intermediate* layer, which is comparatively thin, begin chiefly on the back of the uterus, and stretch over the fundus and towards the sides, running somewhat irregularly between the blood-vessels. The *inner layer*, which is much the thickest of the three, consists of bands of fibres which are disposed with comparative regularity in its upper part, being arranged there in numerous concentric rings round the openings of the two Fallopian tubes, the widest circles of the two series meeting from opposite sides in the middle of the uterus. In the lower part of the body, and in the cervix the internal fibres run more transversely, crossing each other at narrow angles in the most various directions. They form the so-called sphincters of the os internum and os externum. At the neck, however, there are also longitudinal fibres within the strong transverse fibres of the layer now described. (Hélie, Rech. sur la dispos. des fibres musculaires de l'utérus, Paris, 1869.)

The long spindle-shaped cells of the uterine muscular tissue are very closely united together by cement substance, forming bundles which are again connected by areolar tissue. The fibre-cells possess distinct oval nuclei; they are about  $\frac{1}{110}$ th of an inch in length in the unimpregnated uterus, but attain sometimes the length of  $\frac{1}{40}$ th of an inch in the gravid condition.

**Mucous Membrane.**—The mucous membrane lining the cavity of the body of the uterus differs greatly from that of the interior of the cervix, a marked line of distinction separating the two parts at the isthmus.

The *membrane of the cervix* is much firmer than that of the body. Between the rugae of the so-called *arbor vitæ* there are numerous follicular glands, which are lined with cubical epithelium, contain a clear alkaline fluid, and open by minute orifices on the surface. In the lower half of the cervix the mucous membrane is beset with vascular papillæ. The epithelium of the cervix as a whole is cylindrical and ciliated: towards the os externum this passes into transitional and flat epithelium. Besides the follicular glands now mentioned, there are also the so-called *ovula Nobothi*, a set of clear or yellowish vesicles of variable size, but visible to the naked eye, embedded in the folds of the membrane, and extending down to the os externum. These may arise from closed and distended follicles; but their exact nature is still doubtful.

During pregnancy the mucous glands of the cervix secrete a considerable quantity of tenaceous mucus, which effectually closes the passage downwards from the uterine cavity.

The *mucous membrane of the triangular cavity of the body* is smooth, and in the unimpregnated state entirely devoid of ridges, and is of a peculiar soft or delicate spongy consistence, and of a dull, reddish colour. With a magnifying lens of an inch focus its surface is seen to be covered with a great many closely set small spots, in which may be detected the orifices of the utricular glands. This mucous membrane appears to be without any supporting connective tissue, and its thickness is made up mainly of its proper glands, between which is a somewhat confused mass of small nuclei, cells of various form and size,

fibres in different stages of development, together with a considerable quantity of intervening granular substance, and some plain muscular fibres derived from the inner muscular layer of the uterine wall.

*Uterine glands.*—In the dog, as first shown by Sharpey (Müller's *Physiol.*, by Baly, 1842, p. 1574), and in various other animals, there are two forms of the uterine glands; but in the human species it appears that there is only one form, viz., that of more or less convoluted and generally simple tubes. They are also, however, sometimes a little branched. Their form is generally that of equal cylinders throughout the length of the tube, with a slight dilatation in many towards the deep or closed extremities (E. H. Weber, *Zusätze zur Lehre vom Baue, &c., der Geschlechtsorgane*, 1846). Being set perpendicularly to the surface, and slightly convoluted, they are necessarily somewhat longer than the thickness of the membrane. Towards the fundus, the outer parts of the glands lie somewhat more obliquely.

Each gland is composed of a delicate basement membrane, with embedded nuclei, and this is lined with prismatic nucleated epithelial cells, placed with their broader bases and nuclei towards the outer wall, and their narrow ends towards the lumen of the tube. (G. Lott, in *Rollett's Untersuch. II.*, Leipzig, 1871, and Chrobak, in *Stricker's Handbuch, &c.*; John Williams, M.D., *The Struct. of the Mucous Memb. of the Uterus*, 1875. See also Henle's *Handb. der system. Anatomie*, vol. ii.)

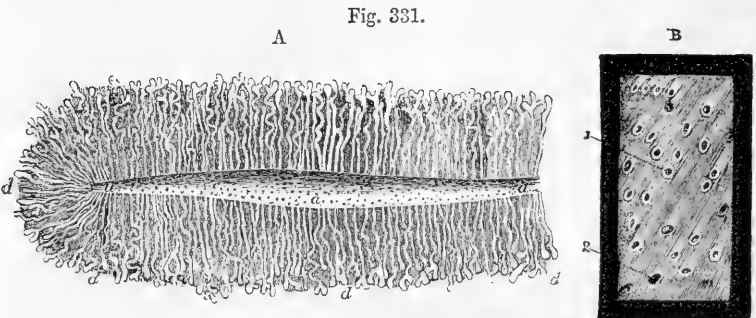


Fig. 331, A.—SECTION OF THE GLANDULAR STRUCTURE OF THE HUMAN UTERUS AT THE COMMENCEMENT OF PREGNANCY (from E. H. Weber).  $\frac{1}{2}$

*a*, part of the cavity of the uterus showing the orifices of the glands; *d*, a number of the tubular glands, some of which are simple, others slightly convoluted and divided at the extremities.

Fig. 331, B.—SMALL PORTION OF THE UTERINE MUCOUS MEMBRANE AFTER RECENT IMPREGNATION, SEEN FROM THE INNER SURFACE (from Sharpey).  $\frac{1}{2}$

The specimen is represented as viewed upon a dark ground, and shows the orifices of the uterine glands, in most of which, as at 1, the epithelium remains, and in some, as at 2, it has been lost.

In a number of animals the glandular epithelium is ciliated, a fact which was observed by Allen Thomson in the uterine glands of the sow in 1846, but was first published by Leydig in 1852, after an observation by Nylander. (Müller's *Archiv.*, 1852, p. 375.) Many observers failed to detect this ciliated structure in the human uterine glands: but its existence was asserted by C. F. Friedländer in 1870, and more recently it has been fully ascertained by J. Williams, who also observed

the active ciliary motion. The epithelium of the general surface of the mucous membrane of the uterus is columnar and ciliated throughout.

*Ligaments of the uterus.*—Where the peritoneum is reflected from the uterus to the bladder in front, and to the rectum behind, it forms, in each position, two semilunar folds, named respectively, the *vesico-uterine*, and the *recto-uterine folds*, or sometimes the *anterior* and the *posterior ligaments* of the uterus.

The *broad ligaments* (*ligamenta lata*) are formed on each side by a fold or double layer of the peritoneum, which is directed laterally outwards from the anterior and posterior surfaces of the uterus, to be connected with the sides of the pelvic cavity. Between the two layers of the serous membrane are placed, first, superiorly, the Fallopian tube, which runs along the upper margin of the broad ligament; secondly, the round ligament, which is a little farther down in front; thirdly, on the posterior surface, the ovary and its ligament, which lie in a special extension of the *ligamentum latum*; and, lastly, throughout the greater part of the broad ligament, blood-vessels, lymphatics, and nerves, with spreading fibres from the superficial muscular layer of the uterus. The *ligament of the ovary* is merely a dense fibro-areolar cord, containing some uterine muscular fibres, and measuring about an inch and a half in length, which extends from the inner end of the ovary to the upper angle of the uterus, which it joins immediately behind and below the point of attachment of the Fallopian tube; it causes an elevation of the posterior layer of the serous membrane, and, together with the ovary itself, forms the lower limit of a triangular portion of the broad ligament, which has been named the *ala respirationis* or bat's wing.

The *round ligaments* are two flat, cord-like bundles of fibres, about four or five inches in length, attached to the upper angles of the uterus, one on either side (*ligamentum teres uteri*), immediately in front of the Fallopian tube. From this point each ligament proceeds upwards, outwards, and forwards, to gain the internal inguinal ring, and after having passed, like the spermatic cord in the male, through the inguinal canal, reaches the fore part of the pubic symphysis, where its fibres expand and become united with the substance of the *mons Veneris*. Besides areolar tissue and vessels, the round ligaments contain plain muscular fibres, which are prolonged into them from the outer muscular layer of the uterine wall. Each ligament also receives a covering from the peritoneum, which, in the young subject, projects under the form of a tubular process for some distance into the inguinal canal: this, which resembles the *processus vaginalis* originally existing in the same situation in the male, is named the canal of Nuck; it is generally obliterated in the adult, but is sometimes found even in advanced life.

**Blood-vessels.**—The *arteries of the uterus* are four in number, viz., the right and left *ovarian* (which correspond to the spermatic of the male) and the two *uterine*. Their origin, as well as the mode in which they reach the uterus and ovaries, has been already described. They are remarkable for their frequent anastomoses, and also for their singularly tortuous course; within the substance of the uterus they seem to be placed in little channels or canals. The *veins* correspond with the arteries; they are very large, and form the uterine plexuses, and their thin walls are in immediate contact with the uterine tissue. The course of the lymphatics has been previously described; they are very large and abundant in the gravid uterus.

**Nerves.**—The distribution of the nerves has been previously described. They are derived from the inferior hypogastric plexuses, the spermatic plexuses, and the third and fourth sacral nerves. They consist of both medullated and plain fibres; they are in greatest number in the neck, where they run into the papillæ of the mucous membrane.

In animals small ganglia have been observed in the submucous tissue connected with the plain fibres. According to Frankenhäuser, the dark bordered fibres run into the muscles, dividing into plain fibres before they form bulbs, and are at last traceable into the nuclei of the muscular cell-fibres (Chrobak, in Stricker's Handbuch, and Frankenhäuser, Die Nerven der Gebärmutter, &c., Jena, 1867). The nerves, especially the dark bordered fibres increase considerably during pregnancy.

**Periodic structural changes in the Uterus.**—The changes which accompany menstruation and gestation may be shortly indicated here.

According to the observations of J. Williams, already quoted, which confirm and greatly extend those of previous inquirers, it appears that at each successive recurrence of *menstruation* a complete removal of the glandular part of the mucous membrane takes place by a process of softening and molecular disintegration which commences, along with the menstrual discharge, close to the cervix, or at the os internum, and advances progressively towards the fundus during the remaining days of the flow of blood. Previous to this periodic change, in addition to greatly increased general vascularity of the parts, the mucous membrane becomes very much thicker, attaining a diameter of a fifth or even a quarter of an inch, and the utricular glands are proportionally enlarged. The process of disintegration reaches as far as the inner muscular fibres which run between the deepest parts of the glands; and as the smaller blood-vessels are similarly affected, the hemorrhage is the direct result of their destruction and open condition.

The process of restoration of the uterine membrane and its glands, which is effected in the interval, and which begins even before the cessation of the menstrual flow, proceeds in the same order from the lower end upwards to the fundus of the cavity, and consists in a very rapid proliferation of the cells and nuclei which occupy the interstices of the inner muscular fibres, and among which are probably embedded the deepest parts of the utricular glands. The lining membrane of the cervix does not participate in the changes now referred to.

In *gestation* more extensive alterations ensue, which necessarily affect the size, shape, and position of the uterus, the thickness and amount of substance in its walls, the dimensions and form of its cavity, and the character of its cervix and of its os externum and os internum. Its weight increases from about one ounce to a pound and a half or even three pounds. Its colour becomes darker, its tissue less dense, its muscular bundles more evident, and the fibres more developed. A very great increase takes place in the muscular tissue, and this increase is the result not only of the enlargement of already existing elements, the fibre-cells becoming enlarged to the extent of from seven to eleven times in length, and from two to five times in breadth (Kölliker), but also of new formation. The increase in length and thickness is general; the new formation occurs mainly in the innermost layers, and continues until the sixth month of pregnancy, when it ceases. The round ligaments become enlarged, and their muscular structure more marked; the broad ligaments are encroached upon by the intrusion of the growing uterus between their layers. The mucous membrane and the glands of the body of the uterus undergo an enlargement very similar to that which precedes menstruation, and they subsequently become the seat of peculiar changes, which lead to the formation of the decidua, to be more particularly stated under Development; whilst the membrane of the cervix loses its columns and rugæ. The blood-vessels and lymphatics are greatly enlarged, and it is observed that the arteries become exceedingly tortuous as they ramify upon the organ. The nerves, as stated above, undergo also considerable enlargement.

After parturition, the uterus gradually but rapidly diminishes till it regains the



size and structure of the unimpregnated condition. During this change the enlarged muscular fibres undergo fatty degeneration and become subsequently absorbed, while a new set of minute fibre-cells are developed. After the first pregnancy, however, the organ never regains its original virgin character. In those who have had children its weight usually remains from two to three ounces; its cavity is larger; the os externum is wider and more rounded, and its margins often puckered or fissured; the arteries continue much more tortuous, and its muscular fibres and layers remain more defined than in the virgin.

Fig. 332.

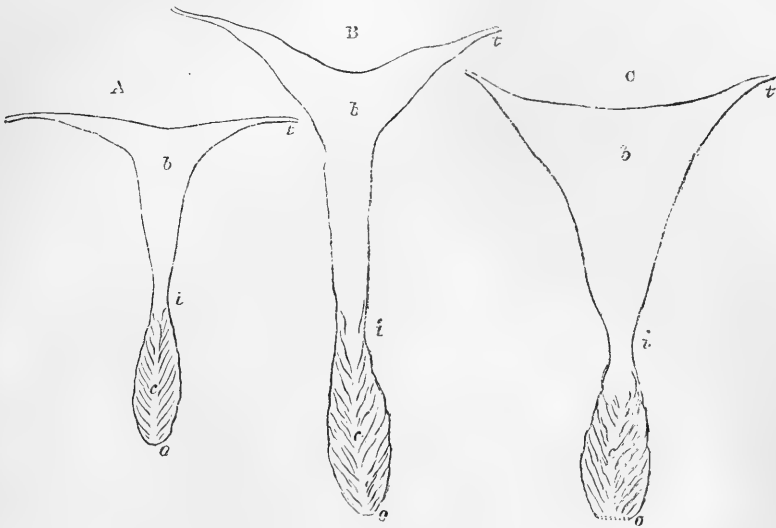


Fig. 332.—OUTLINES OF MOULDS OF THE UTERINE CAVITY IN DIFFERENT STATES (after F. Guyon). NATURAL SIZE.

A, in a virgin of 17 years of age; B, in a woman of 42 years who had not borne children; C, in a woman of 35 years who had borne children; *b*, cavity of the body; *c*, that of the cervix; *i*, the isthmus or os internum; *o*, os externum; *t*, passage of the upper angle into the Fallopian tube.

**Changes from Age.**—In the infant, the neck of the uterus is larger than the body; the fundus is not distinguished either by breadth or convexity of outline, and the cavity is remarkably narrow, and tapers out from the middle on both sides so as to present an approach to the two-horned form prevalent in animals. These parts afterwards enlarge gradually, until, at puberty, the pyriform figure of the womb is fully established. The arbor vitæ is very distinct, and indeed at first reaches upward to the highest part of the cavity. The shape of the cavity of the body varies also in after life; but it remains comparatively narrow up to the age of puberty, and retains the same form to a great degree in all women who have borne no children. It is chiefly, therefore, in those who have been pregnant that its form is widely triangular. (Fel. Guyon, *Cavité de l'Utérus*, &c. *Journ. de la Physiol.* vol. ii, p. 186.)

From the gradual effects of more advanced age alone, independent of impregnation, the uterus shrinks, and becomes paler in colour, and harder in texture; its triangular form is lost; the body and neck become less distinguishable from each other; the orifices also become less characteristic.

For further details with regard to the structure of the uterus and its changes, the reader is referred to the article by Farre on "Uterus and its Appendages" in *Cyclop. of Anat. and Phys.*

**Malformations.**—The uterus is subject to numerous congenital malformations, especially in connection with abnormal conditions of the other genital organs. These will be referred to under Development. As a malformation affecting the uterus itself may here be mentioned the more or less double or divided state of the cavity, produced by the prolongation of a septum downwards into it from the fundus. This is sometimes only partial and confined to the upper part of the cavity; while in other instances it involves the whole cavity or also that of the cervix; and even extends through a part or the whole of the vagina.

#### THE FALLOPIAN TUBES.

These tubes may be considered as ducts of the ovaries, or oviducts, and serve to convey the ovum from thence into the uterus. They are inclosed, as already stated, in the free margin of the broad ligaments, and are between three and four inches in length. Their inner or attached extremities, which proceed from the upper angles of the uterus, are narrow and cord-like; but they soon begin to enlarge, and proceeding outwards, one on each side, pursue an undulatory course, and at length, having attained the width of about a sixth of an inch or more, they bend backwards and downwards towards the ovary, about an inch beyond which they terminate in an expanded extremity, the margin of which is divided deeply into a number of irregular processes named *fimbriæ*; one of these, somewhat longer than the rest, is attached to the

Fig. 333.

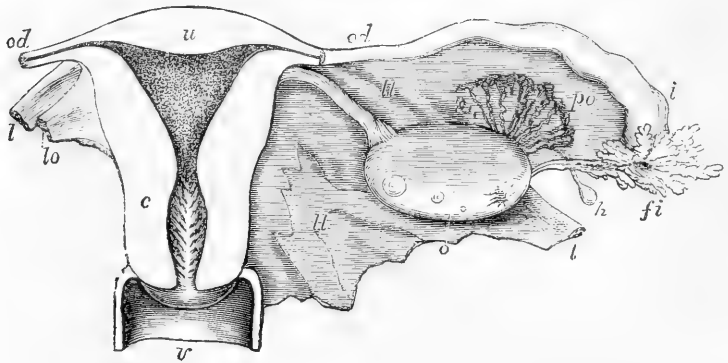


Fig. 333.—DIAGRAMMATIC VIEW OF THE UTERUS AND ITS APPENDAGES, AS SEEN FROM BEHIND. (A. T.)  $\frac{2}{3}$

The uterus and upper part of the vagina have been laid open by removing the posterior wall; the Fallopian tube, round ligament, and ovarian ligament have been cut short, and the broad ligament removed on the left side; *u*, the upper part of the uterus; *c*, the cervix opposite the os internum; the triangular shape of the uterine cavity is shown, and the dilatation of the cervical cavity with the rugæ termed *arbor vitæ*; *v*, upper part of the vagina; *od*, Fallopian tube or oviduct; the narrow communication of its cavity with that of the cornu of the uterus on each side is seen; *l*, round ligament; *lo*, ligament of the ovary; *o*, ovary; *i*, wide outer part of the right Fallopian tube; *fi*, its fimbriated extremity; *po*, parovarium; *h*, one of the hydatids frequently found connected with the broad ligament.

outer end of the corresponding ovary. The wide and fringed end of the Fallopian tube, or rather *trumpet*, as the term “*tuba*” literally signifies, is turned downwards and towards the ovary, and is named the *fimbriated extremity* (*morsus diaboli*). In the midst of these fimbriæ, which are arranged in a radiated manner, the tube itself opens by a

round constricted orifice, *ostium abdominale*, placed at the bottom of a sort of fissure leading from that fringe which is attached to the ovary. It is by this orifice that an ovum is received at the time of its liberation from the ovary, and is thence conveyed along the tube, which narrows very much towards its uterine extremity, and opens into the womb by a minute orifice, admitting only a fine bristle, and named *ostium uterinum*. The canal becomes gradually larger towards its abdominal orifice, where it is again somewhat contracted: hence the term *isthmus*, given by Henle to the uterine half, and *ampulla* to the outer half of the Fallopian tube. A second smaller fimbriated opening not unfrequently occurs at a short distance from the main one.

Beneath the external or peritoneal coat the walls of the tube contain, besides areolar tissue, plain muscular fibres like those of the uterus, arranged in an external longitudinal and an internal circular layer. The mucous membrane lining the tubes is thrown into longitudinal plicæ, which are broad and numerous in the wider part of the tube, and in the narrower part are broken up into very numerous arborescent processes: it is continuous, on the one hand, with the lining membrane of the uterus, and at the other end of the tube with the peritoneum; presenting an example of the direct continuity of a mucous and serous membrane, and making the peritoneal cavity in the female an exception to the ordinary rule of serous cavities, *i. e.*, of being perfectly closed. The epithelium in the interior of the Fallopian tube is, like that of the uterus, columnar and ciliated; the inner surface of the fimbriæ is also provided with cilia, and Henle has even detected ciliated epithelium on their outer or serous surface, but it here soon passes into the scaly epithelium of the peritoneal membrane. The mechanism by which the minute ovum, when it escapes from the ovary, is carried into the cavity of the uterus is not yet fully understood. Neither the vascular turgescence nor the muscular contractions, which may no doubt accompany the passage, appear to be the immediate agents, and it seems more probably due, in greatest part, if not entirely, to the ciliary movement which proceeds in a direction downwards in the tube from the fimbriated extremity. It does not appear that there are glands, as was at one time supposed, in the mucous membrane lining the Fallopian tubes.

### THE OVARIES.

The **ovaries** (*ovaria, testes muliebres*), the productive organs corresponding more immediately to the bodies of the testicles of the male, are two somewhat flattened oval bodies, which are placed one on each side, with their long diameter nearly horizontally across the pelvis. They lie at the back of the broad ligament of the uterus, and are enveloped by its posterior membranous layer. The weight of each ovary is from sixty to a hundred grains, and they usually measure about one inch and a half in length, three quarters of an inch in width, and nearly half an inch in thickness; but their size is variable, both according to the period of life and their state of greater or less functional activity. Each ovary is free on its two sides, also along its posterior border, which has a convex outline; but it is attached to the broad ligament by its anterior border, which is straighter than the other, and along the line of its attachment it exhibits a deep groove or *hilus* by which the vessels and nerves enter. Its inner end is generally narrower than the outer, and

is attached to the dense cord already described as the *ligament* of the *ovary*, which connects it with the uterus. Its outer extremity is more obtuse and rounded, and has attached to it the middle or ovarian fimbria of the Fallopian tube.

Fig. 334.

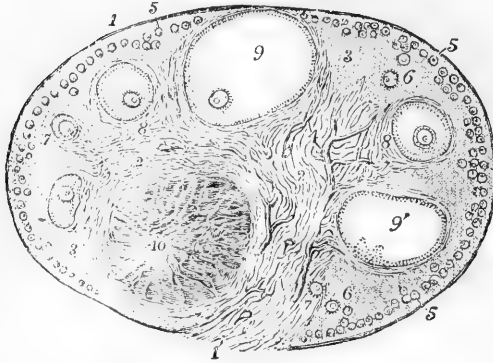


Fig. 334.—SECTION OF THE PREPARED OVARY OF THE CAT (from Schrön). ♀

1, outer covering and free border of the ovary; 1', attached border; 2, the ovarian stroma, presenting a fibrous and vascular structure; 3, external fibro-nuclear substance; 4, blood-vessels; 5, ovi-germs in their earliest stages lying near the surface; 6, ovi-germs which have begun to enlarge and to pass more deeply into the ovary; 7, ovi-germs round which the Graafian follicle and tunica granulosa are now formed, and which have passed

somewhat deeper into the ovary and are surrounded by firm fibrous stroma; 8, more advanced Graafian follicle with the ovum imbedded in the cells of the proliferous disc; 9, the most advanced follicle containing the ovum, and approaching the surface; 9', a follicle from which the ovum has accidentally escaped; 10, corpus luteum presenting radiated columns of cellular structure.

#### STRUCTURE OF THE OVARY.

The ovary consists essentially in man, as in all the higher animals, of an ovarian stroma, composed of connective tissue with blood-vessels, nerves, and some muscular fibres, an outer epithelial covering, and the embedded Graafian follicles with the ova.

The external surface of the ovary is of a whitish colour, and in early life is comparatively smooth and even; but in later life it becomes more or less uneven and is marked by pits and scars. It is covered by a membrane which, though somewhat different in its minute structure, is originally continuous with the peritoneum.

The superficial epithelium of the ovary differs from that of the peritoneum in the neighbourhood in being decidedly prismatic or columnar: and it gives to the surface a dull appearance as compared with the shining smoothness of the serous membranes in general. A distinct line of demarcation exists at the base of the ovary, where the two kinds of epithelium pass into each other. To this ovarian epithelium, from its relation in early life to the origin of the ova, the name *germ-epithelium* has been given by some authors.

Below the outer membrane a firm layer of fibrous tissue, permeated by the superficial blood-vessels, encloses all the deeper parts. This has been compared to the dense fibrous covering of the testicle, and thence named *tunica albuginea ovarii*, but without sufficient reason, for it is not nearly so strong or distinct. It is in fact no more than a condensed part of the ovarian stroma, and not unfrequently is divisible into several subordinate layers.

The deeper substance of the ovary or *stroma* is chiefly composed of a fine fibro-nuclear tissue, in which the nuclei are remarkably abundant and distinct. It is also mixed with some elastic tissue, and is permeated by blood-vessels, which are large towards the hilus where they enter, and become gradually smaller towards the surface. Along these blood-vessels in the deeper part of the ovary bands of muscular fibres run, having apparently entered from the broad ligament; but they do not extend into the more superficial parts of the ovarian stroma.

There is a general disposition of radiation of the bands of stroma from the hilus towards the surface, determined in the deeper part perhaps by the blood-vessels, but in the superficial part modified by its relation to the Graafian follicles.

Fig. 335.

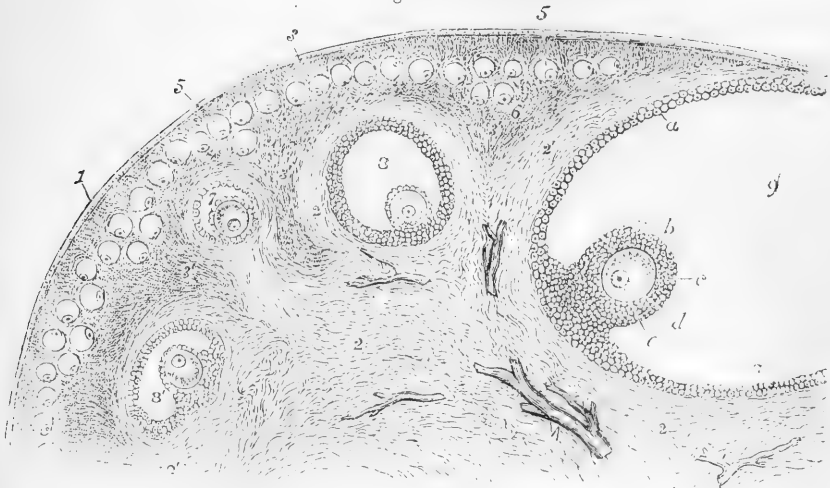


Fig. 335.—PORTION OF THE SECTION OF THE PREPARED CAT'S OVARY, REPRESENTED IN THE PRECEDING FIGURE, MORE HIGHLY MAGNIFIED (FROM SCHÖN).

1, outer covering of the ovary; 2, fibrous stroma; 3, superficial layer of fibro-nuclear substance; 3', deeper parts of the same; 4, blood-vessels; 5, ovigerms forming a layer near the surface; 6, one or two of the ovigerms sinking deeper and beginning to enlarge; 7, one of the ovigerms farther developed, now enclosed by a prolongation of the fibrous stroma, and consisting of a small Graafian follicle, within which is situated the ovum covered by the cells of the discus proligerus; 8, a follicle farther advanced; 8', another which is irregularly compressed; 9, the greater part of the largest follicle, in which the following parts are seen; a, cells of the tunica granulosa lining the follicle; b, the reflected portion named discus proligerus; c, vitellus or yolk part of the ovum, surrounded by the zona pellucida; d, germinal vesicle; e, germinal spot.

**Graafian Follicles.**—Immediately under the superficial covering of the ovary there is a layer of stroma somewhat different from the deeper parts, and which is so uniformly spread over the organ as to have received the name of cortical layer. This is particularly obvious in the ovaries of young children, in whom this layer is comparatively thick, and its appearance is granular from the accumulation in it of an immense number of closely set small vesicles, constituting the early condition of the ovarian or Graafian follicles with their contained ova. These more numerous and small vesicles, or follicles, are

absent from the succeeding stratum of the stroma, but somewhat larger cavities of the same kind, distended with fluid and containing ova, are observed in smaller numbers embedded in the ovarian stroma for a certain distance from the surface, but not extending to the deepest part or that near the hilus. Of this second set of Graafian follicles, the deepest are usually of the largest size, or most advanced.

Further, in the ovaries of females who are approaching the period of puberty, and during the whole of the child-bearing period of life, there may be seen towards the surface, or even more or less projecting upon it, a few larger follicles of various sizes, from a twentieth to a sixth of an inch, which are the Graafian follicles with ova approaching or arrived at a state of maturity. The more advanced of these seem to have made their way from the deeper part by the absorption or at the expense of the ovarian substance between them and the surface. They still remain covered at the most projecting part by a thin layer of the fibrous stroma and the epithelium. The smaller blood-vessels running round the follicle from below, and minutely subdivided on its inner surface, converge towards a point near the middle of the most projecting part, called the *stigma*. This marks the spot where the rupture of the vesicle ultimately occurs, when at the time of full maturation the vesicle opens, and its ovum and other contents escaping pass into the open extremity of the Fallopian tube. This rupture of a Graafian vesicle, or it may be of more than one, occurs in healthy females at every successive menstrual period. After the discharge of its contents, the Graafian follicle is rapidly filled with a peculiar reddish-yellow mass of granular elongated cells, which are rapidly developed in its interior, constituting the first stage of formation of the body termed *corpus luteum*. When pregnancy occurs, this body enlarges, and becoming more solid, advances to a fuller stage of development, which is maintained during the greater part of the time of utero-gestation. But in the unimpregnated female the corpus luteum begins to retrograde within ten or twelve days after its commencement, and afterwards rapidly shrinks and ultimately disappears. It thus happens that, without pregnancy, the ovaries may naturally present during the whole of the child-bearing period of life the corpora lutea of menstruation, or their vestiges, in various stages of advance or decline.

The Graafian follicles in the ovary of middle life are to be found in very various stages of development. 1st. By far the most numerous and the smallest lie in the cortical layer already described. The size of these is remarkably uniform, the largest scarcely passing  $\frac{1}{100}$  of an inch. These exist from an early period of foetal life, and are in such numbers that it is estimated with great certainty that the ovaries of a female child at birth do not contain less than 70,000 follicles, each one of which contains an ovum. 2nd. In the deeper stratum of the ovary is found a succession of follicles in very much smaller numbers, and of very various sizes from  $\frac{1}{100}$  to  $\frac{1}{50}$ , or even  $\frac{1}{20}$  of an inch. And 3rd. There are the larger and fewer follicles advancing to and projecting on the surface.

The more advanced Graafian follicles appear to have a very consistent wall formed of the ovarian stroma; but it is doubtful whether the two coverings which have been described as belonging to them deserve to be regarded structurally as distinct envelopes. Two layers of condensed tissue may indeed be seen surrounding the cavity of the

more developed follicles. One of these situated next the cavity is composed of condensed fine connective tissue: it contains a network of

Fig. 336.

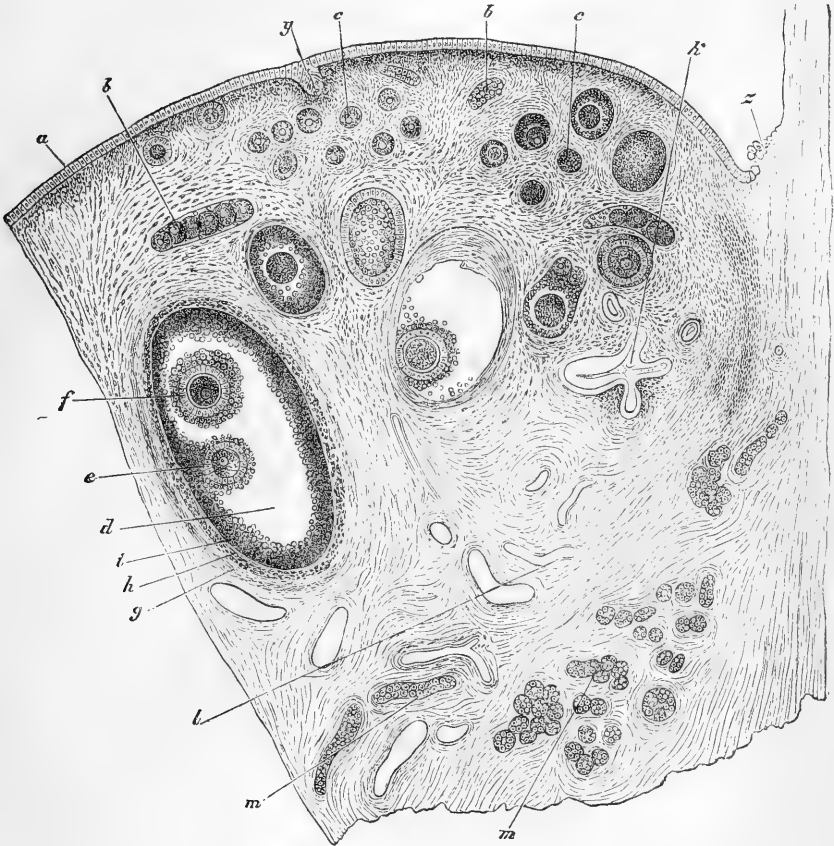


Fig. 336.—SECTION OF THE OVARY OF AN ADULT BITCH (Waldeyer). 25

*a*, germ-epithelium; *b*, ovarian tubes or strings of ovigerms; *c*, *c*, earlier follicles; *d*, more advanced follicles; *e*, discus proligerus and ovum; *f*, second ovum in the same follicle; *g*, alleged tunica fibrosa folliculi; *h*, tunica propria; *i*, follicular epithelium (tunica granulosa); *k*, collapsed retrograde follicle; *l*, blood-vessels; *m*, *m*, longitudinal and transverse sections of cellular tubes of the parovarium; *y*, involuted portion of the germ-epithelium of the surface; *z*, place of the transition from periton to germinal or ovarian epithelium.

finely divided capillary blood-vessels, and has been named the vascular, or proper tunic of the follicle. The other, called the fibrous tunic, is more strongly fibrous, and forms a condensed layer situated close to the first. But, excepting in their greater degree of condensation, these layers do not differ essentially from the tissue of the ovarian stroma.

**Tunica granulosa.**—Within the vascular or proper tunic of the follicle, and adherent to its inner surface, there is a distinct lining of

peculiar opaque granular and prismatic cells in several layers, forming the membrana or tunica granulosa of authors. In the earliest stages of formation, before the follicle has expanded, this layer of cells lies close to the ovum, but as the follicles enlarge there comes to be formed within the granular layer a space of variable size filled with clear fluid, which holds a quantity of albumen in solution, so as to be coagulable by heat and chemical re-agents. The ovum is now found to be embedded in a thickened portion of this cellular layer, the *cumulus* or *discus proligerus* of Von Baer, so as to be placed near the inner surface on one side of the follicle. The position of the ovum within the follicle appears to be subject to some variation. It was formerly described as being always on the side next the surface of the ovary; but according to more recent observations it is as frequently situated on the deeper side of the follicle. The cells of the tunica granulosa and discus proligerus are without distinct external walls; they possess a considerable quantity of protoplasm of an opaque or granular aspect, and are provided with oval nuclei. Near the inner surface of the follicle, and on the outer surface of the ovum, they assume a more elongated prismatic or pediculated form than in other parts of the membrane.

**The ovarian ovum.**—Each Graafian follicle usually contains only a single ovum, but occasionally, though seldom, two ova, and very rarely three, have been observed in the same follicle. The ovum, first discovered by Von Baer in 1827, is a spherical body of about  $\frac{1}{120}$  of an inch in diameter, and of an opaque yellowish white colour. When fully formed it consists essentially of the following parts, viz.: 1st., a firm transparent external vesicular membrane termed *zona pellucida*, or *vitelline membrane*; 2nd., a mass of granular protoplasm filling the vesicle and constituting the *yolk*, or *vitellus*, in which a number of oil globules of variable size are suspended; 3rd, embedded in the yolk protoplasm, and situated on one side near the surface, a small clear vesicle of about  $\frac{1}{720}$  of an inch in diameter, filled with a finely granular fluid, the *germinal vesicle*; and 4th, within this vesicle a dark granular spot, of about  $\frac{1}{3000}$  of an inch in diameter, the *macula germinativa*.

Fig. 337.

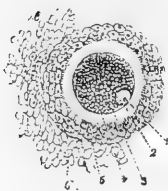


Fig. 337.—OVUM OF THE SOW REMOVED FROM THE GRAAFIAN FOLLICLE, WITH ITS CELLULAR COVERING (from M. Barry).

1, germinal spot; 2, germinal vesicle; 3, yolk; 4, zone pellucida or external covering of the ovum; 5, part of the tunica granulosa or proligerous disc; 6, some adherent cells.

The whole ovum was compared by Schwann to an organic cell, and this view is still in general maintained; the zona representing the cell wall, the yolk the protoplasmic cell contents, or their product, the germinal vesicle the nucleus, and the macula the nucleolus.

The part of the ovum which is first formed is the germinal vesicle, or nucleus, which, at so early a period as the tenth or eleventh week of foetal life, has been observed to take its origin from one of the cells of the epithelial covering or *germinal epithelium* of the incipient ovary, by its undergoing enlargement and becoming embedded in the ovarian substance. The inclosing ovarian stroma thus constitutes the first form of a Graafian follicle, and follicle and germ may be considered



as arising simultaneously, although doubtless the germs may be held to have had previous existence as parts of the germinal epithelium covering the primordial structure of the ovary. By the middle of foetal life, or at the end of the fifth month, the follicle, which is at first only a space for the germ in the ovarian stroma, has received a simple lining of scattered cells, which afterwards in their more developed form constitute the tunica granulosa, and the germinal vesicle is by the same time surrounded by a small quantity of clear protoplasm, or commencing yolk, which separates the vesicle from the granular cells. Still later the zona pellucida appears as a clear membranous covering of the yolk protoplasm. By the sixth or seventh month of foetal life an immense number of such small ova closely embraced by the enclosing Graafian follicles have appeared, so that the ovary appears to be almost entirely occupied by them; and as they may be counted in prepared specimens of sections, it is easy to estimate their number in the entire ovary. The result of such estimates gives

Fig. 338

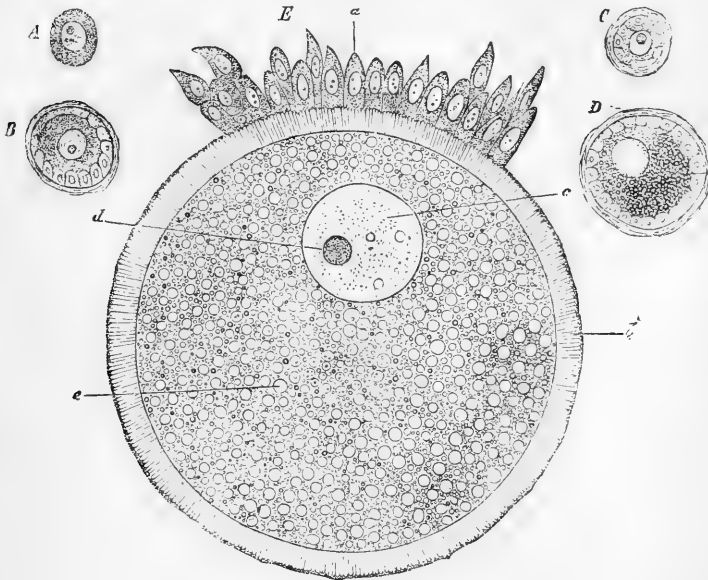


Fig. 338.—OVA IN DIFFERENT STAGES OF PROGRESS (Waldeyer). HIGHLY MAGNIFIED.

A, primordial ovum from human foetus of eight months; B, early follicle of rabbit with ovum enclosed; C, the same of the pigeon; D, another of the same more advanced, the secondary yolk commencing; E, ovum of the rabbit from a follicle of  $\frac{1}{50}$  of an inch in diameter; *a*, epithelium of the discus proligerus; *b*, zona pellucida, showing radiated linear structure, perhaps too strongly marked; *c*, germinal vesicle; *d*, germinal macula; *e*, yolk substance with fine granules and small oil globules.

an amount of not less than 30,000 or 40,000 for each ovary of the human foetus before birth. The formation of new ova and Graafian follicles probably still continues for some time, but at a much slower rate than during foetal life.

The *zona pellucida* of the mature ovarian ovum, when viewed with a low magnifying power, appears clear or homogeneous, but according to some observers, when sufficiently magnified, it presents an appearance of minute radial striation, which has been considered to indicate in it the existence of a porous structure, somewhat of the same nature as that which is very obvious in the vitelline membrane of fishes and some other animals.

Through this membrane, as has been proved by observations in several mammiferous animals, the spermatic filaments pass in order to effect fecundation; but it is difficult to comprehend how they are transmitted, as no micropyle, or other aperture of sufficient size, has yet been detected in the zona of man or Mammals.

Fig. 339.

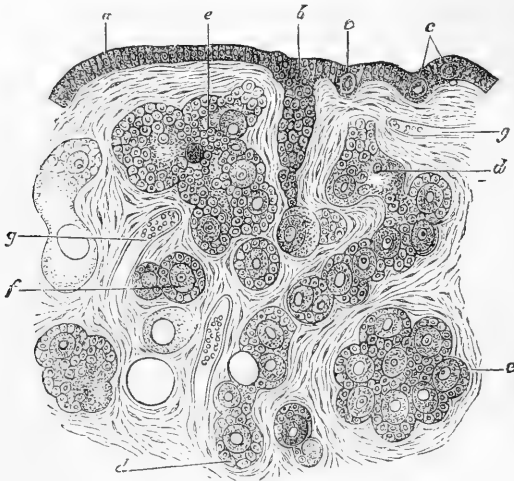


Fig. 339.—THIN TRANSVERSE SECTION OF THE OVARY OF A NEWLY BORN CHILD  
HIGHLY MAGNIFIED (Waldeyer).

*a*, Ovarian or germinal epithelium; *b*, formation of an ovarian tube; *c*, *c*, ovigerms lying in the germ-epithelium; *d*, *d*, longer tube forming follicles (according to Pflüger's and Waldeyer's views); *e*, *e*, germ-spherules forming ova and follicles; *f*, earliest distinctly formed follicle with ovum and granular cells; *g*, *g*, blood-vessels.

The germinal vesicle with its nucleus or macula belongs to the ovum only, while it is still within the Graafian follicle. At the time of complete maturation of the ovum, and even for a short time previous to the bursting of the wall of the follicle by which the ovum escapes, the germinal vesicle already begins to become flaccid and collapse, and when the ovum has escaped from the follicle, the vesicle is no longer to be perceived in the mass of granular protoplasm which constitutes its germinal part.

**Formation of the Ovum and Graafian follicle.**—The mode of origin of the ova and Graafian follicles will be described under Development. As connected, however, with the structure of the ovary in relation to the ova and their origin, it is proper to refer at this place to the view first suggested by

Valentin (Müller's Archiv., 1838, p. 526), and since maintained as the result of careful observation by Pflüger (1863), that the ova are at first formed in groups within tubes, which thus constitute an original and characteristic feature in the structure of the ovary.

By the elaborate researches of Waldeyer (Eierstock und Ei, Leipzig, 1870, and in Stricker's Handbuch, p. 568.) it was ascertained that the ovigerms or primordial ova derive their origin from the superficial layer of cells or germ epithelium, covering the mass of blastema which lies to the inside of the Wolffian body, and which constitutes the common germinal matrix of the ovary and testicle. According to Waldeyer's observations, while the ovigerms themselves come from the superficial epithelium, and thus exist from an early period of foetal life, the Graafian follicles owe their origin to an outgrowth of the subjacent vascular connective tissue which constitutes the ovarian stroma. Brush-like processes of this tissue growing out from the surface, involve in their meshes the enlarged epithelial cells which form the commencing ova, and at the same time enclose groups of other less developed epithelial cells, which come to be arranged round the larger ovigerms, and thus constitute the commencement of the cells of the membrana granulosa. According to Waldeyer's view, therefore, both the primordial ova and the cells of the membrana granulosa spring from the germ-epithelium of the reproductive blastema, while the wall of the Graafian follicle is a production of the vascular connective tissue of the stroma.

A somewhat different view has been presented by Kölliker, as the result of observations made on the fœtus of several animals (Sitz. der Phys. Med. Gesellsch. in Wurtzburg, May, 1874); for while he agrees with Waldeyer in referring the first origin of the ova to the germ epithelium, he is inclined to consider the membrana granulosa as proceeding from other cellular elements, existing in connection with the ovarian stroma. These cellular elements, he conceives, are contained in a set of medullary cords or canals extending upwards into the ovary from its attached border, and they furnish the cellular coverings to the primordial ova by spreading outwards upon them, and enclosing them, first in groups, and later each one singly. He regards these cords as the same which have been described as the epo-phoron or remains of the Wolffian body in the ovary.

These different views appear to be in some measure reconciled, and new light thrown upon the subject, by the independent observations of James Foulis, made in the human fœtus, and in calves and kittens, and which, from observation of the specimens, the writer can in most points confirm ("Development of Ova and Structure of the Ovary," &c., by Dr. James Foulis, in Proceed. of Roy. Soc. of Edin., April, 1875). By these researches the origin of the ovigerms or primordial ova from the superficial germ epithelium is fully confirmed, and the stroma of the ovary is shown to be produced by a direct growth from the subjacent tissue situated on the median side of the Wolffian body. The nucleus of each epithelial corpuscle becomes the germinal vesicle of the primordial ovum: a nucleolus soon appears within (the macula), and a clear homogeneous protoplasm collecting round the vesicle, forms the commencement of the yolk. The enclosure of the primordial ova in a Graafian follicle takes place by the outgrowth of processes of the connective tissue of the stroma, so that the former, being surrounded by these processes, become more and more embedded in the substance of the ovary. At the same time, however, the germ-epithelium corpuscles increase in number by proliferation, and extending themselves inwards are in their turn enclosed singly or in clusters by the processes of the stroma. But what is most important and novel in these observations is this, that Dr. Foulis has traced the formation of the cells of the membrana granulosa to the nuclei of the fibro-nuclear tissue constituting the stroma, which gradually insinuate themselves round each primordial ovum, along with the processes of the vascular tissue of the stroma which afterwards forms the wall of the follicle. The connective-tissue nuclei which first surround each ovigerms are comparatively few in number; but they soon increase by cell multiplication, and form the complete membrana granulosa by which the follicle is lined.

On the subject of the ovum, in addition to the works previously quoted, the following may be mentioned:—Martin Barry's Researches on Embryology, in

Phil. Trans., 1838 and 1839; Allen Thomson, Article "Ovum," in Cyclop. of Anat. and Phys.; Farre, "Uterus and Appendages," in the same; Kölliker's *Entwickelungs-geschichte*; Pflüger, *Die Eierstöcke*, Leipzig, 1863; Schrön, in *Zeitsch. f. Wissensch. Zoologie*, vol. xii. p. 409; Gröhe, in *Virchow's Archiv*, vol. xxvi. p. 271, and vol. xxix. p. 450; Bischoff's Works; Henle, in his *Handbuch*, vol. ii.; W. His, *Die erste Entwick. des Hühnchens*, &c., 1868; Ed. Van Beneden, in *Mem. Cour., &c., de l'Acad. Roy. de Belgique*, 1870; Foster and Balfour, *Elements of Embryology*, 1874.

The ovum of mammals appears to have been seen by Messrs. Prevost and Dumas as early as 1824, but imperfectly recognised. Von Baer was undoubtedly the first clearly to point out its nature and seat within the Graafian follicle. (*De ovi Mammal. et hom. genesi*, Lipsiæ, 1827.) The discovery of the germinal vesicle in the ovarian ovum of birds was made by J. E. Purkinje in 1825. That of the mammiferous ovum was announced by Coste in 1833, and T. W. Jones had independently observed it. The macula was by discovered Rud. Wagner in 1834.

**Vessels and nerves of the ovaries and Fallopian tubes.**—The ovaries are most directly supplied by the ovarian *arteries*, analogous to the spermatic in the male, which anastomose freely by an internal branch with the termination of the uterine arteries. Sometimes this anastomotic branch is so large that the ovary seems to be supplied almost entirely by the uterine artery. The ovarian artery always sends numerous branches to the Fallopian tube. The smaller arteries penetrate the ovary along its attached border, pierce the proper coat, and run in flexuous parallel lines through its substance. The *veins* correspond, forming a plexus near the ovary named the pampiniform plexus. The *nerves* are derived from the spermatic or ovarian plexus; and also from one of the uterine nerves, which invariably send an offset to the Fallopian tube.

**Parovarium.**—The organ so named by Kobelt, or the Organ of Rosenmüller, its first describer, is a structure which can usually be brought plainly into view by holding against the light the fold of peritoneum between the ovary and Fallopian tube (see fig. 333). It consists of a group of scattered tubules lying transversely between the Fallopian tube and ovary, lined with epithelium, but having no external openings. The tubules converge, but remain separate at their ovarian end, and at the other are more or less distinctly united by a longitudinal tube. The duct which unites them is sometimes of considerable size, and is prolonged for some distance downwards, in the broad ligament. Its more developed form in some animals, as the cow and pig, constitutes the duct of Gaertner, afterwards referred to as arising from a persistent condition of the Wolffian duct.

The origin of this vestige of a foetal structure will be more fully referred to under Development. Here it is sufficient to state that it corresponds essentially to the epididymis of the male, and is in the female, therefore, due to the persistence of the upper or sexual division of the Wolffian body, which has been distinguished by Banks, Dursy, and others from the lower or primordial-kidney part of that organ. The remains of the latter part of the Wolffian body, in the male sex, constituting the organ of Giralde's, have been already referred to in the description of the testicle. From the observations of His in birds, and of Waldeyer in Mammals, it appears that vestiges of this structure are also sometimes to be detected in the adult female, in the shape of obscure or imperfect tubular remains, situated in the broad ligament nearer to the uterus than the parovarium, and more obvious remains of these are very apparent in the early stages of foetal life in man and most animals.

With a view to the distinction of these several vestiges in the two sexes, the following tabular enumeration of them is given, with the names proposed by Waldeyer printed in italics, viz. :—

The upper or non-glomerular part of the Wolffian body forms—

1. In the male, the *Epididymis*.
2. In the female, the Parovarium, Organ of Rosenmüller, or *Epoophoron*.

The lower or primordial-kidney part of the Wolffian body forms—

1. In the male, the organ of Giraldès, Parepididymis or *Paradidymis*.
2. In the female, the *Paroophoron* (Eierstock und Ei. p 142).

## THE PERITONEUM.

The abdominal viscera having now been described, as well as the disposition of the peritoneum in relation to each of them, it remains to give an account of that membrane in its whole extent, and to trace its continuity over the various parts which it lines or covers.

After lining the anterior wall of the abdomen, the peritoneum passes round on either side to the lumbar region, where it meets with the right and left portions of the great intestine. On the right side it completely invests the lower rounded end of the cæcum with the vermiform appendix ; but the rest of the cæcum it covers only before and on the sides, a part of the bowel behind, of variable extent, being immediately adjacent to the iliac fascia, except in rare instances where the membrane goes entirely round and forms a mesocæcum. It is disposed in a similar manner on the ascending colon which is in immediate apposition with the right kidney and other parts behind ; although here, too, the investment may be complete with a resulting right mesocolon.

Leaving the right colon, the peritoneum gives a scanty covering to the anterior face of the right kidney and adjoining third portion of the duodenum where that intestine comes down from behind the transverse mesocolon ; lower down it continues over muscles and vessels to the root of the mesentery, advances forwards to form the right layer of that process, turns round the jejunum and ileum, affording them their peritoneal coat, and returns back to the vertebræ, thus completing the mesentery on the left side. The membrane now reaches the left colon, first passing in front of the left kidney, which being less covered by colon than the right one, gets more of the peritoneum. After investing the left colon much in the same manner as the right, the peritoneum, thus traceable horizontally round the abdomen, is continued over the lateral wall on the left side. Where the colon forms its sigmoid flexure it is completely invested by peritoneum, which attaches it by a comparatively free and moveable sigmoid mesocolon to the fascia of the left iliac fossa.

From this part, and from the lower end of the mesentery the peritoneum is continued into the pelvis. It there invests the upper part of the rectum completely, forming a meso-rectum behind. Lower down the membrane gradually quits the intestine, first behind, then at the sides, and finally in front, whence it is reflected on the inferior fundus and posterior part of the bladder in the male, and forms here the *rectovesical pouch*, the mouth of which is bounded by a crescentic fold on each side, but larger on the left, the two being named *plicæ semilunares*. From the superior fundus the peritoneum passes to the recti muscles. Here

it covers the remains of the urachus in the median line, and the closed umbilical artery on either side, which as it passes from the os pubis to the abdominal wall raises the peritoneum into a well-marked fold, separating two shallow pits named *internal and external inguinal pouches* (more fully described with the special anatomy of the groin). In the female the peritoneum passes from the rectum to the upper part of the vagina, and over the posterior and anterior surfaces of the uterus, whence it goes to the bladder. The recto-vaginal pouch, like the recto-vesical, is bounded above by its semilunar folds, and the uterine peritoneum forms at the sides the broad ligaments of the uterus, along the upper border of which the Fallopian tubes receive from it a serous covering; but at their fimbriated openings the peritoneum is continuous with the mucous membrane lining the tubes.

The peritoneum, on being traced to the upper part of the abdomen, is found to line the vault of the diaphragm, adhering moderately to the muscular and firmly to the tendinous part, and continuing down behind as far as the hinder border of the liver and the œsophageal opening. It then passes forward on the liver, forming the falciform, coronary, and lateral ligaments of that organ, already specially described.

Turning round the anterior border it passes back on the under surface, but after covering the lobulus quadratus, and arriving at the transverse fissure, it meets with a peritoneal layer from behind, and in association with it, stretches from the liver to the stomach, to form the lesser omentum, as will be presently explained. To the right of this part it invests the gall-bladder, more or less completely, and the under surface of the right lobe, gives a complete covering to the adjacent part of the duodenum, and passes to the upper end of the right kidney, forming here a slight fold, named hepato-renal ligament. It then covers the hepatic flexure of the colon, and reaches the right colon, on which it has been already traced. To the left of the transverse and the longitudinal fissure the peritoneum invests the whole of the left lobe, and stretches out as the long left lateral ligament above and beyond the œsophageal opening. It then passes down over that opening and covers the front and left side of the gullet, spreads over the left end of the stomach, where it passes off to invest the spleen, forming a duplicature named the gastro-splenic ligament, or gastro-splenic omentum, for it is connected below with the great omentum, and often reckoned as a part of it. When the membrane passes from the diaphragm to the œsophagus it forms a small duplicature in the angle between them, named the gastro-phrenic ligament; it extends also as a stout and well-marked fold (the costo- or phrenocolic ligament) from the diaphragm opposite the tenth and eleventh ribs to the splenic flexure of the colon, then passes over the splenic flexure, and reaches the left kidney and descending colon, where it has been already described.

*Omenta.*—The arrangement of the remaining part of the peritoneum—that between the stomach, liver, and transverse colon—is somewhat complex, in consequence of the membrane forming in this situation a second and smaller sac, which communicates towards the right with the general cavity by a narrow throat, named the *foramen of Winslow*. This passage, which readily admits a finger, is situate behind the bundle of hepatic vessels which stretches between the liver and commencing duo-

denum ; behind the orifice is the vena cava ; it is bounded above by the

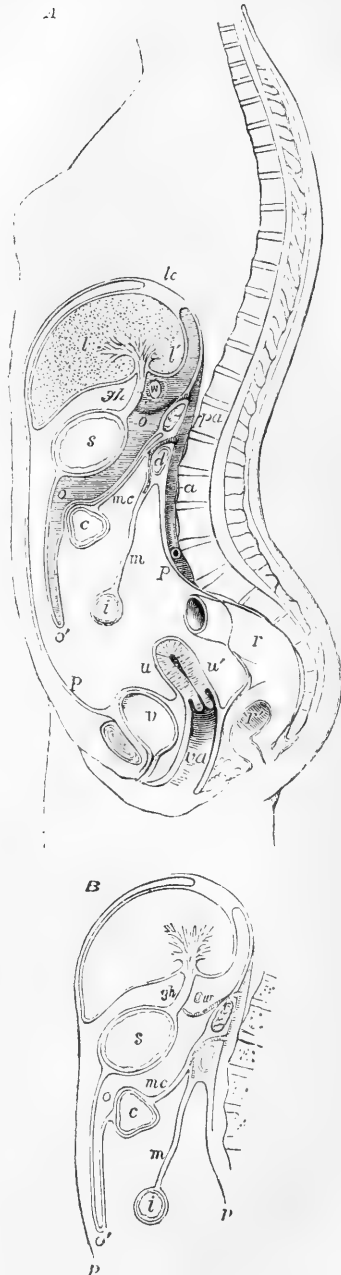
Fig. 340, A.—DIAGRAMMATIC OUTLINE OF A SUPPOSED SECTION OF THE BODY, SHOWING THE INFLECTIONS OF THE PERITONEUM IN THE FEMALE (Allen Thomson).  $\frac{1}{2}$

The upper part of the section is a little to the right of the mesial plane of the body, through the quadrate and Spigelian lobes of the liver ; below, it is supposed to be mesial: *lc*, placed above the diaphragm opposite to the coronary ligament of the liver ; *l*, the liver ; *l'*, lobe of Spiegel ; *s*, stomach ; *c*, transverse colon ; *i*, the small intestine ; *pa*, pancreas ; *a*, the aorta ; *d*, the duodenum ; *v*, urinary bladder ; *u*, uterus ; *r*, rectum ; *r'*, its middle part opened ; *va*, vagina ; *p*, *p*, the parietal peritoneum lining the front and back of the abdominal cavity ; the line representing the inflections of the greater sac of the peritoneum will be traced from the neighbourhood of *lc*, where it passes on the upper surface of the liver over the upper and lower surfaces of that organ, in the front of *gh*, the gastro-hepatic omentum, over the front of the stomach, down to *o'*, the outer layer of the great omentum, whence it passes back to the vicinity of the pancreas, and re-descends as the upper layer of the transverse meso-colon ; after enclosing the colon it returns on the lower surface of the transverse meso-colon, *mc*, to the root of the mesentery, *m* ; it now forms the mesentery and encloses the small intestine, returning to the posterior wall of the abdomen, whence it passes over the rectum, *r*, descends into the recto-vaginal pouch, *u'*, covers the back and front of the uterus and the bladder partially, and regains the anterior abdominal wall above the pubes. As connected with the lesser sac of the peritoneum, *w* marks the position of the foramen of Winslow as if seen beyond the section ; the lesser sac, with the cavity of the omentum, is shaded with horizontal lines, and is marked *oo* : round this space the line of the peritoneum may be traced from the diaphragm over the lobe of Spiegel, to the back of the gastro-hepatic omentum, thence behind the stomach and down into the great omentum ; it then ascends to the pancreas, which it covers, and thence reaches again the diaphragm.

B is a sketch of part of a section similar to that of A, but showing the view more commonly taken, according to which the two layers of the meso-colon are continuous with the posterior pair of the layers of the great omentum.

Spigelian lobe where joined by the lobulus caudatus ; its lower boundary is formed by the duo-

Fig. 340.



denum and a curve of the hepatic artery. From this opening the lesser sac spreads out to the left behind the general or main sac of the peritoneum. It covers a part of the posterior abdominal wall, but in front and below it is applied to the back of the main sac, to which it adheres except where the stomach is interposed. Moreover, it indents, as it were, the back of the main sac, and between the stomach and colon protrudes into it in form of a great pouch—the bag of the omentum,—which thus has a double coat, formed by the apposition of the membranes of both sacs. To trace this arrangement more particularly: suppose a finger pushed into the foramen of Winslow, and the thumb brought to meet it from before, to the left of the hepatic vessels; the membrane held between is double; its anterior layer (from the greater sac), turns round the hepatic vessels into the foramen, and then belongs to the lesser sac. The double membrane, so constituted, is the lesser or hepato-gastric omentum. From the point indicated it may be followed to the transverse fissure of the liver, where its laminae separate, the anterior, which has already been traced from above, spreading on the adjacent part of the liver, the posterior covering the lobulus Spigelii, where it will be again met with. The attachment of the combined layers continues backwards from the left end of the transverse fissure along the fossa ductûs venosi to the diaphragm, on which it runs a short way to reach the œsophagus, where the anterior lamina covers the end of that tube in front and on the left, and the posterior lamina invests it on the right and behind. From this point, as far as the pylorus, the lesser omentum is attached to the lesser curvature of the stomach, where its laminae separate—one covering the anterior and the other the posterior surface of the organ—but meeting again at the great curvature, they pass down in conjunction to a variable distance before the small intestine to form the anterior part of the great omental sac, and then turn up to form its posterior wall. Meeting next with the transverse colon, the two laminae separate, and enclose that intestine, but meet again behind it to form the transverse mesocolon. This extends back to the lower border of the pancreas, from which its inferior layer is continued down over the posterior wall of the abdomen, and forms the mesentery, where it has been already recognised. The superior layer, on the other hand, which, as will be understood, belongs to the lesser sac, covers the front of the pancreas, the celiac artery and its main divisions with the adjacent part of the diaphragm, and may extend to the left end of the pancreas and lower end of the spleen, partially investing the latter organ and forming part of the gastro-splenic ligament. It then goes forward on the lobulus Spigelii to the transverse fissure, and the line of attachment of the lesser omentum of which it then becomes the under layer. More to the right the layer in question passes over the vena cava, and continues into the general peritoneum beyond the foramen of Winslow. The gastric and hepatic arteries, especially the former (Huschke), may raise the membrane into folds which project into the cavity.

From the description given it will be understood that, as the sides or walls of the great omental bag consist of two peritoneal layers, its whole thickness (in its usually empty and collapsed state) will comprehend four layers. But although the bag may be inflated in its whole extent in the infantile body, its sides afterwards



cohere, and it becomes impervious in its lower part. Fat, moreover, accumulates between its laminae; long slender branches also pass down into it from the gastro-epiploic vessels.

The part of the membrane just described, which is attached to the great curvature of the stomach and transverse colon, which is connected also with the gastro-splenic ligament (or omentum), is usually named the *great or gastro-colic omentum*. This may reach the hepatic flexure, and pass a certain way down on the right colon, and this part has been distinguished by Haller and others as the *omentum colicum*. The great omentum (proper) usually reaches lower down at its left border, and it is said that omental inguinal herniæ are more common on the left side.

The description now given of the relation of the omentum to the meso-colon agrees with the appearances most frequently seen in the adult subject, and with the account usually given in English works of Anatomy; the exterior (here also posterior) layer of the great omentum being described as separating from the layer within, belonging to the omental sac, when it reaches the transverse colon so as to pass behind or below that viscus, and as proceeding from thence backwards to the abdominal wall as the posterior or lower layer of the transverse meso-colon. It was, however, long ago pointed out by Haller, and the view has been confirmed by the observations of J. F. Meckel, J. Müller, Hansen, and Huschke, that in the foetus, and occasionally in the child, or even in the adult, the two ascending layers of the omentum, though adherent to the transverse colon, may be separated from it and from the transverse meso-colon, so as to demonstrate that the transverse meso-colon is really a distinct duplicature of peritoneum. This view has been adopted by Holden and Luschka in their more recent works, and has been verified by Allen Thomson. Figures 340 A, and B, show diagrammatically the difference of the two views.

It appears, therefore, that a portion of peritoneum, which in the foetus passes above the transverse colon to the back of the abdomen, and is thence reflected forwards as the upper layer of the meso-colon, disappears in the adult; the peritoneal layers between which it was interposed having cohered to form the transverse meso-colon. It is conceivable that the foetal duplicature may be obliterated by absorption of its substance as the adhesion goes on between the layers, between which it is placed; or, more probably perhaps, it may be drawn or pushed forward from its place in the progress of visceral development, and thus effaced.

## MAMMARY GLANDS.

The mammary glands (mammaræ), which yield the milk in the female, are accessory parts to the reproductive system. They give a name to a large class of animals (Mammalia), which are distinguished by the possession of these organs. When fully developed in the human female, they form, together with the integuments and a considerable quantity of fat, two rounded eminences (the breasts) placed one at each side on the front of the thorax. These extend from the third to the sixth or seventh rib, and from the side of the sternum to the axilla. A little below the centre of each breast, on a level with the fourth rib, or a little lower, projects a small conical body named the *nipple* (mamilla), which points somewhat outwards and upwards. The surface of the nipple is dark, and around it there is a coloured circle or *areola*, within which the skin is also of a darker tinge than elsewhere. In the virgin, these parts are of a rosy pink colour, differing somewhat according to the complexion of the individual, and they are always darker in women who have borne children. Even in the second month of the first pregnancy, the areola begins to enlarge and acquire a darker tinge; these changes go on increasing as gestation advances, and are regarded as signs to be relied on in judging of suspected pregnancy. After lactation is over, the dark colour subsides, but never entirely disappears. The skin of the nipple is marked with many wrinkles, and is covered with papillæ; besides this, it is perforated at the tip by numerous foramina, which are the openings of the lactiferous ducts: and near its base, as well as upon the surface of the areola, there are scattered rounded elevations, which are caused by the presence of little glands with branched ducts, four or five of which open on each elevation. The tissue of the nipple contains a large number of vessels, together with much plain muscular tissue, and its papillæ are highly sensitive; it becomes firmer and more projecting from mechanical excitement,—a change mainly caused by contraction of the muscular fibres, which form concentric circles round the base, and some radiating bands running from base to apex of the nipple.

The base of the mammary gland is somewhat oval, flattened, or slightly concave, and has its longest diameter directed upwards and outwards towards the axilla. The gland lies in connective tissue continuous with the superficial fascia, its base resting on the pectoral muscle, and separated from it by a layer of firm areolar tissue continuous with the deep fascia. The thickest part of the gland is near the centre, opposite the nipple.

On the surface, and penetrating also between the lobes, there is a large quantity of fat, which mainly gives the full and smoothly rounded form to the gland. This fat is of a firm consistence and bright yellow colour, and is subdivided into lobules by partitions of connective tissue. It is entirely absent from the nipple and areola.

## STRUCTURE OF THE MAMMA.

The glandular substance of the mamma consists of numerous distinct lobes held together by firm intervening fibrous or areolar tissue, and

having adipose tissue penetrating between them. Each of these lobes is provided with an excretory duct, and is subdivided into smaller lobes, and these again into smaller and smaller lobules, which are flattened or depressed, and are united by areolar tissue, blood-vessels, and ducts. The substance of the lobules is of a pale reddish cream-colour, especially as contrasted with the adjacent fat, and is rather firm. It is composed principally of the vesicular commencements of the lactiferous ducts, which appear like clusters of small rounded vesicles, having a diameter from ten to thirty times as great as that of the capillary vessels by which they are surrounded. These vesicles open into the smallest branched ducts, which, uniting together to form others of larger size, finally end in a single excretory canal corresponding

Fig. 341.

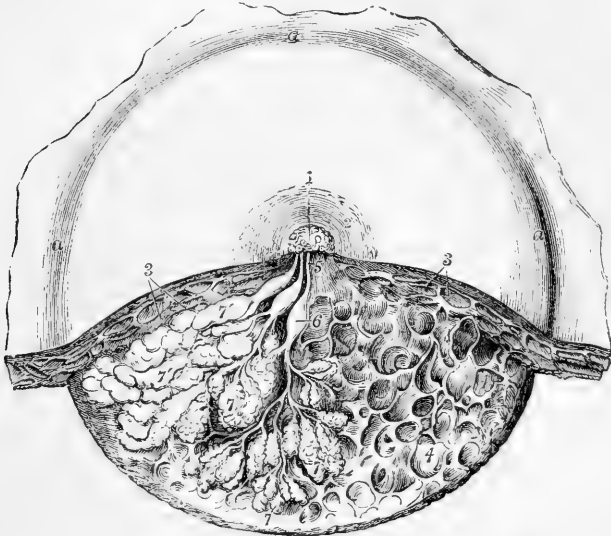


Fig. 341.—DISSECTION OF THE LOWER HALF OF THE FEMALE MAMMA DURING THE PERIOD OF LACTATION (from Luschka).  $\frac{3}{4}$

*a, a, a*, undissected part of the mamma; 1, the mamilla; 2, areola; 3, subcutaneous masses of fat; 4, reticular loculi of the connective tissue which support the glandular substance and contain the fatty masses; 5, three lactiferous ducts passing towards the mamilla where they open; 6, one of the sinus lactei or reservoirs; 7, some of the glandular lobules which have been unravelled; 7', others massed together.

to one of the chief subdivisions of the gland. The canals formed thus are named the *galactophorous ducts*, and are from fifteen to twenty in number; they converge towards the areola, beneath which they become considerably dilated, especially during lactation, so as to form *ampullæ* or *sinuses* two or even three lines wide, which serve as small temporary reservoirs for the milk. At the base of the nipple all these ducts, again reduced in size, are assembled together, those in the centre being the largest, and then proceed, side by side, surrounded by areolar tissue and vessels, and without communicating with each other, to the summit of the mamilla, where they open by separate orifices; these orifices are seated in little depressions, and are smaller than the ducts

to which they respectively belong. The walls of the ducts are composed of areolar tissue, with longitudinal and circular elastic fibres. Both the terminal vesicles and the ducts are lined with short columnar epithelium, which passes into the flat kind near the external openings on the nipple.

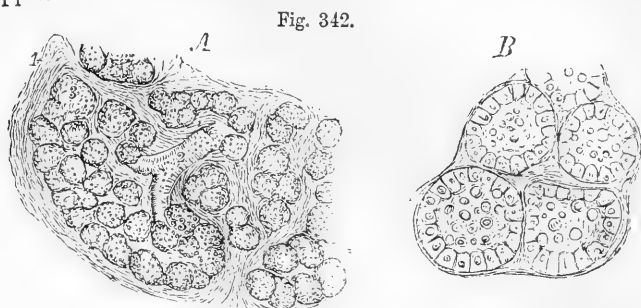


Fig. 342.

Fig. 342.—MAGNIFIED VIEWS OF THE GLANDULAR SUBSTANCE OF THE MAMMA DURING THE PERIOD OF LACTATION (from Henle).

A, section of a small lobule of the gland, magnified 60 diameters; 1, stroma of connective tissue supporting the glandular tissue; 2, terminal ramuscule of one of the gland-tubes; 3, glandular vesicles.

B, four glandular vesicles magnified 200 diameters, showing the lining epithelial cells and some milk-globules.

**Difference according to sex.**—The mamma begins to be formed as early as the fourth month of fetal life, but its subsequent growth is comparatively tardy. At the third or fourth year of infancy, there is little or no difference in male and female children. The fuller development of the gland in the female occurs only towards puberty.

In the adult male the mammary gland and all its parts exist, but quite in a rudimentary state, the gland itself measuring only from six to nine lines across, and two lines thick, instead of four inches and a half wide and one and a half thick, as in the female. Occasionally the male mamma, especially in young subjects, enlarges and gives out a thin watery fluid; and, in some rare cases, it has secreted milk. (W. Gruber, On the Male Mamma, in Mem. of the Petersburg Acad., 1866.)

**Blood-vessels and Nerves.**—The *arteries* which supply the mammary glands are the long thoracic and some other branches of the axillary artery, the internal mammary, and the subjacent intercostals. The *veins* have the same denomination. Haller described a sort of anastomotic venous circle surrounding the base of the nipple as the *circulus venosus*. The *nerves* proceed from the anterior and middle intercostal cutaneous branches.

**Varieties.**—Two or even three nipples have been found on one gland. An additional mamma is sometimes met with, and even four or five have been observed to co-exist; the supernumerary glands being most frequently near the ordinary pair, but sometimes in a distant part of the body, as the axilla, thigh, or back.

## THE CEREBRO-SPINAL AXIS.

Under this head it is intended to describe the Central Organs of the Nervous System, both as regards their general conformation and their minute structure. The central ganglia of the sympathetic system have been described along with the sympathetic nerves.

The *cerebro-spinal axis* is contained partly within the cavity of the cranium, and partly within the vertebral canal; it is divided by anatomists into the *brain* or *encephalon*, and the enlarged upper mass placed within the cranium, and the *spinal cord* contained within the vertebral canal. It is symmetrical in its form and structure throughout, consisting of a right and a left half, separated to a certain extent by longitudinal fissures, and presenting, in their plane of union, various portions of white and grey nervous substance which cross from one side to the other, and form the *commissures* of the brain and spinal cord.

Enclosed within the skull and the vertebral canal, the cerebro-spinal axis is protected by the bony walls of those two cavities; it is also surrounded by three membranes, which afford it additional protection and support, and are subservient to its nutrition. These envelopes, which will be described hereafter, are, 1st, a dense fibrous membrane named the *dura mater*, which is placed most superficially; 2nd, a serous membrane called the *arachnoid*; and, 3rd, a highly vascular membrane named the *pia mater*, which is next to, and closely invests the surface of the brain and cord.

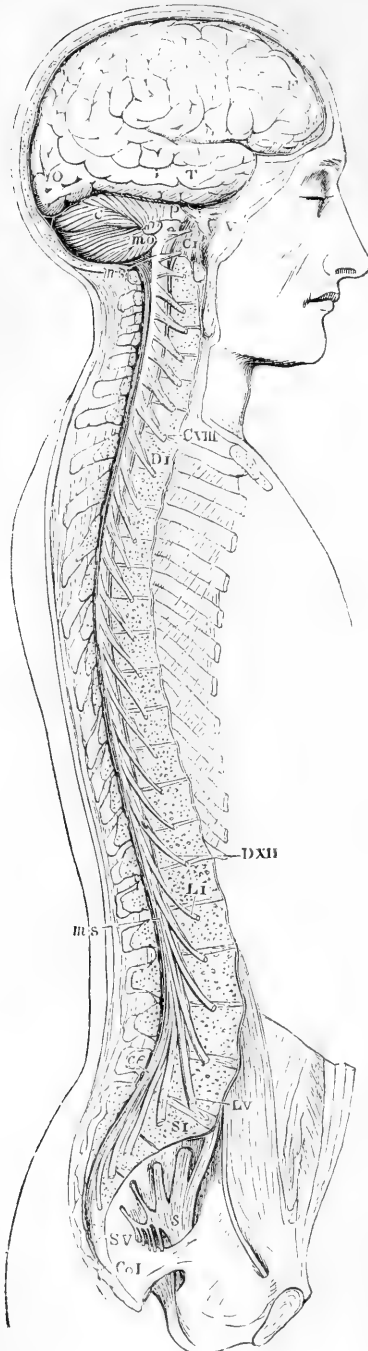
### A.—SPINAL CORD.

#### EXTERNAL FORM.

The *spinal cord*, or *spinal marrow* (*medulla spinalis*), is that part of the cerebro-spinal axis which is situated within the vertebral canal. It extends from the margin of the foramen magnum of the occipital bone to about the lower part of the body of the first lumbar vertebra. Above, it is continued into the *medulla oblongata*; below, it ends in a slender filament, the *filum terminale* or *central ligament* of the spinal cord (fig. 344 B').

Invested closely by a proper membrane (the *pia mater*), the cord is enclosed within a sheath (*theca*) considerably longer and larger than itself, formed by the *dura mater*, and separated from the walls of the canal by numerous venous plexuses, and much loose areolar tissue (fig. 345). Between the *dura-matral* sheath and the *pia mater* is another membrane (the *arachnoid*), and between the latter and the *pia mater* is a fluid called the *cerebro-spinal fluid*. Within this space the cord is kept in position by proper ligaments, which fix it at different points to its sheath, and by the roots of the spinal nerves,—an anterior and a posterior root belonging to each,—which pass across the space from the surface of the cord towards the intervertebral foramina. From

Fig. 343.



its lower part, where they are closely crowded together, the roots of the lumbar and sacral nerves descend nearly vertically to reach the lumbar intervertebral and the sacral foramina, and form a large bundle of nervous cords named the *cauda equina*, which occupies the termination of the cord (17, fig. 345).

Fig. 343. — VIEW OF THE CEREBRO-SPINAL AXIS OF THE NERVOUS SYSTEM (after Bourguery).  $\frac{1}{2}$

The right half of the cranium and trunk of the body has been removed by a vertical section; the membranes only of the brain and spinal marrow have been removed, and the roots and first part of the fifth and ninth cranial, and of all the spinal nerves of the right side, have been dissected out and laid separately on the wall of the skull and on the several vertebræ opposite to the place of their natural exit from the crania-spinal cavity.

F, T, O, lateral surface of the cerebrum; C, cerebellum; P, pons Varolii; *m o*, medulla oblongata; *m s*, upper and lower extremities of the spinal marrow; *c e*, on the last lumbar vertebral spine, marks the cauda equina; *v*, the three principal branches of the nervous trigeminus or fifth pair; C I, the sub-occipital or first cervical nerve; above this is the ninth pair; C VIII, the eighth or lowest cervical nerve; D I, the first dorsal nerve; D XII, the last or twelfth; L I, the first lumbar nerve; L V, the last or fifth; S I, the first sacral nerve; S V, the fifth; Co I, the coccygeal nerve; *s*, the left sacral plexus.

Although the cord usually ends near the lower border of the body of the first lumbar vertebra, it sometimes terminates a little above or below that point, as opposite to the last dorsal or to the second lumbar vertebra. The position of the lower end of the cord also varies according to the state of curvature of the vertebral column, in the flexion forwards of which, the end of the cord is slightly raised. In the fœtus, at an early period, the cord occupies the whole length of the vertebral canal; but, after the third month, the canal and the roots of the lumbar and sacral nerves begin to grow more rapidly than the cord itself, so that at birth the lower end reaches only to the third lumbar vertebra.

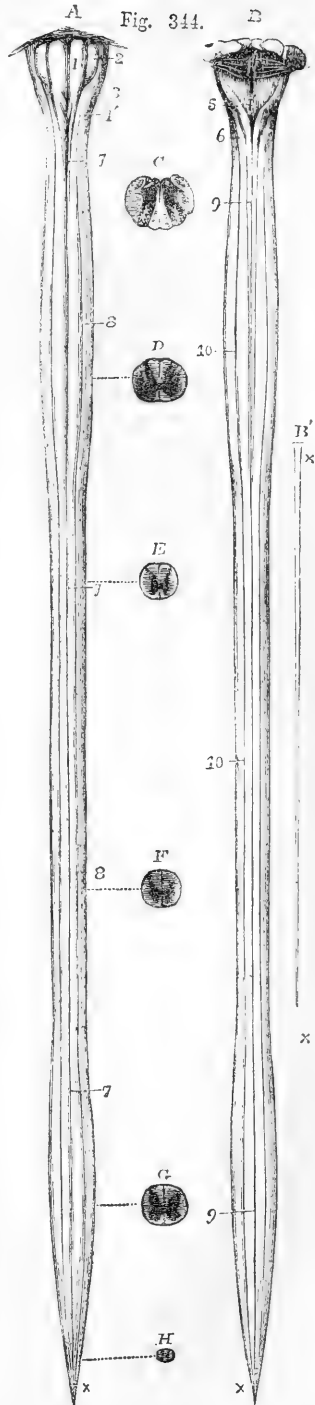
Fig. 344.—ANTERIOR AND POSTERIOR VIEWS OF THE MEDULLA OBLONGATA AND SPINAL CORD WITH SECTIONS (Allen Thomson).  $\frac{1}{2}$

The cord has been divested of its membranes and the roots of the nerves. A presents an anterior, B a posterior view, showing the upper cervical), and the lower (lumbar) enlargements. In these figures the filiform prolongation, represented separately in B', has been removed; C shows a transverse section through the middle of the medulla oblongata; D, a section through the middle of the cervical enlargement of the spinal cord; E, through the upper region of the dorsal part; F, through its lower; G, through the middle of the lumbar enlargement; and H, near the lower end of its tapering extremity.

1, anterior pyramids; 1', their decussation; 2, olivary bodies; 3, restiform bodies; 4, posterior surface of the medulla oblongata; 4', calamus scriptorius; 5, posterior pyramids; 6, posterior lateral columns passing up into the restiform bodies; 7, 7, anterior median fissure extending through the whole length of the spinal cord; 8, 8, anterior lateral groove; 9, 9, posterior median fissure; 10, 10, posterior lateral groove; x, lower end of the tapering extremity of the cord; x, x, in B', the filiform prolongation of the cord and its pia-matral covering.

**Size and extent.**—The length of the spinal cord is from fifteen to eighteen inches. In general form it is cylindrical, somewhat flattened before and behind. It presents two enlargements—an upper or cervical, and a lower or lumbar (fig. 344, D and G). The cervical enlargement is of greater size and extent than the lower. It reaches from the third cervical to the first dorsal vertebra; its greatest diameter is from side to side. The lower or lumbar enlargement is situated nearly opposite the last dorsal vertebra; its antero-posterior diameter is nearly equal to the transverse. Below this enlargement, the cord tapers in the form of a cone (*conus medullaris*), from the apex of which the small filiform prolongation is continued downwards for some distance within the sheath.

The cervical and lumbar enlargements have an evident relation to the large size of the nerves which supply the upper and lower limbs, and which are connected with those regions of the cord. At the commencement of its development in the embryo, the spinal cord is destitute of these enlargements, which, in their first appearance and subsequent progress, correspond with the growth of the limbs.



The **terminal filament** (*filum terminale*, central ligament) (fig. 346, *b, b.*) descends in the middle line amongst the nerves composing the cauda equina, and, becoming blended with the lower end of the sheath opposite to the first or second sacral vertebra, passes on to be fixed to the lower end of the sacral canal, or to the base of the coccyx.

Fig. 345.

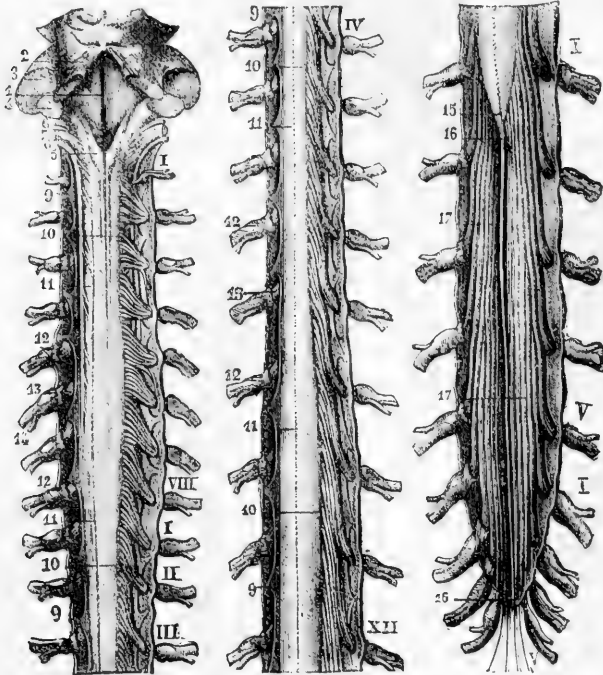


Fig. 345.—POSTERIOR VIEW OF THE MEDULLA OBLONGATA AND OF THE SPINAL CORD WITH ITS COVERINGS AND THE ROOTS OF THE NERVES (from Sappey).  $\frac{1}{2}$

The theca or dura-matral sheath has been opened by a median incision along the whole length, and is stretched out to each side. On the left side, in the upper and middle parts (A and B), the posterior roots of the nerves have been removed so as to expose the ligamentum denticulatum; and along the right side the roots are shown passing out through the dura mater. The roman numbers indicate the different processes in the cervical, dorsal, lumbar, and sacral regions; 9, several of the pointed processes of the ligamentum denticulatum; 10, origin of several posterior roots; 11, posterior median fissure; 12, ganglia of the spinal nerves; 13, part of the anterior roots seen on the left side; 14, the united nerve; 15, tapering lower end of the spinal cord; 16, *filum terminale*; 17, cauda equina.

Internally, it is a prolongation for about half its length of some of the nervous elements of the cord: externally, it consists of a tube of the pia mater or innermost membrane, which, being attached at its lower end to the dura mater and vertebral canal, keeps pace with the latter in its growth, whilst the cord relatively shortens. It is distinguished by its silvery hue from the nerves amid which it lies. Small blood-vessels may sometimes be seen upon it.

**Figures.**—When removed from the vertebral canal, and divested



of its membranes, the spinal cord is seen to be marked by longitudinal *fissures*. Of these, two, which are the most obvious, run along

Fig. 346.—LOWER PART OF THE SPINAL CORD WITH THE CAUDA EQUINA AND SHEATH, SEEN FROM BEHIND (Allen Thomson).  $\frac{1}{2}$

The sheath has been opened from behind and stretched towards the sides; on the left side all the roots of the nerves are entire; on the right side both roots of the first and second lumbar nerves are entire, while the rest have been divided close to the place of their passage through the sheath. The bones of the coccyx are sketched in their natural relative position to show the place of the filum terminale and the lowest nerves.

*a*, placed on the posterior median fissure at the middle of the lumbar enlargement of the cord; *b, b*, the terminal filament, drawn slightly aside by a hook at its middle, and descending within the dura-matral sheath; *V, v'*, its prolongation beyond the sheath and upon the back of the coccygeal bones; *c, c*, the dura-matral sheath; *d*, double foramina for the separate passage of the anterior and posterior roots of each of the nerves; *e, e*, pointed ends of several processes of the ligamentum denticulatum; *Dx*, and *Dxii*, the tenth and twelfth dorsal nerves; *Lt*, and *Lv*, the first and fifth lumbar nerves; *Sl*, and *Sv*, the first and fifth sacral nerves; *Cr*, the coccygeal nerve.

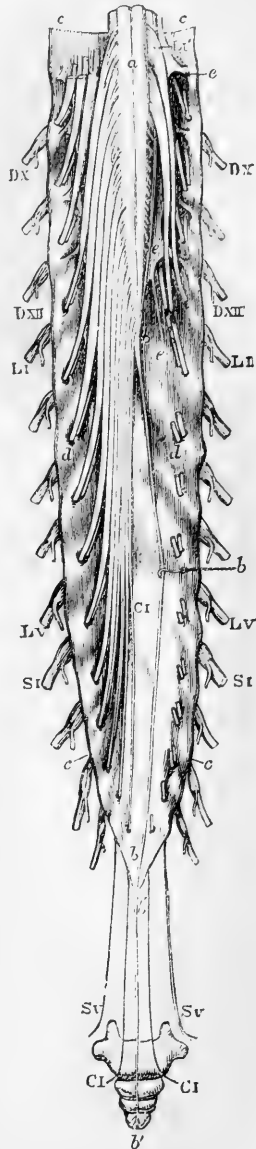
the middle line, one in front and the other behind, and are named the *anterior* and *posterior median fissures*.

The *anterior median fissure* (fig. 347, 1) is more distinct than the posterior, and penetrates about one-third of the thickness of the cord, its depth increasing towards the lower end. It contains a fold of the pia mater, and also many blood-vessels, which are thus conducted to the centre of the cord. At the bottom of this fissure is seen the transverse connecting portion of white substance named the *anterior white commissure*.

The *posterior median fissure* (fig. 347, 2) is less marked in the greater part of its extent than the anterior, but becomes more evident towards the upper part of the cord. Its position is marked, especially in the lumbar enlargement and in the cervical region, by a superficial furrow. It is not an actual fissure, for, although the lateral halves of the posterior part of the cord are quite separate, there is no distinct inflection of the pia mater between them, but merely a septum of connective tissue and blood-vessels which passes in nearly to the centre of the cord, as far as the *posterior grey commissure*.

Besides these two *median* fissures, two *lateral* furrows or fissures have

Fig. 346.



been described on each side of the cord, corresponding with the lines of attachment of the anterior and posterior roots of the spinal nerves.

The *posterior lateral fissure* (fig. 347, 4) is a superficial depression along the line of attachment of the posterior roots.

The *anterior lateral fissure*, which is often described in the line of the origin of the anterior roots of the nerves, has no real existence as a groove. The fibres of these roots in fact, unlike the posterior, do not dip into the spinal cord in one narrow line, but spread over a space of some breadth. Thus, each lateral half of the cord is divided superficially by the posterior lateral fissure into a *posterior* and an *antero-lateral* column. The attachment of the anterior roots, however, divides the latter into anterior and lateral portions.

On the posterior surface of the cord, and most evidently in the upper

Fig. 347.

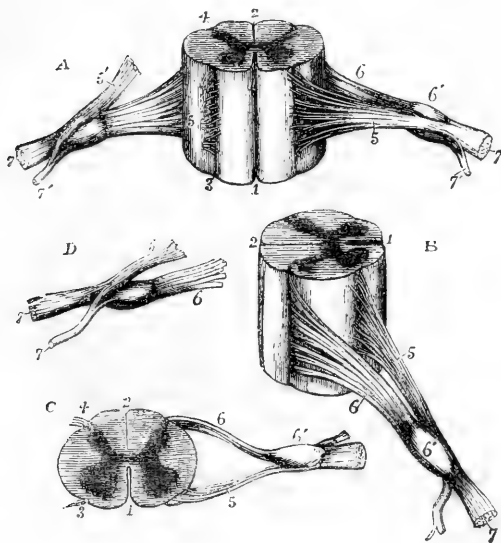


Fig. 347. — DIFFERENT VIEWS OF A PORTION OF THE SPINAL CORD FROM THE CERVICAL REGION WITH THE ROOTS OF THE NERVES. Slightly enlarged (Allen Thomson).

In A, the anterior surface of the specimen is shown, the anterior nerve-root of the right side being divided; in B, a view of the right side is given; in C, the upper surface is shown; in D, the nerve-roots and ganglion are shown from below. 1, the anterior median fissure; 2, posterior median fissure; 3, anterior lateral depression, over which the anterior nerve-roots are seen to spread; 4, posterior lateral groove into which the posterior roots are seen to sink; 5, anterior roots passing the ganglion;

5', in A, the anterior root divided; 6, the posterior roots, the fibres of which pass into the ganglion, 6'; 7, the united or compound nerve; 7', the posterior primary branch, seen in A and D to be derived in part from the anterior and in part from the posterior root.

part, there are two slightly marked longitudinal furrows situated one on each side, close to the posterior median fissure, and marking off, at least in the cervical region, a slender tract, named the *posterior median column*. Between the anterior and posterior roots of the spinal nerves, on each side, the cord is convex, and sometimes presents a longitudinal mark corresponding with the line of attachment of the ligamentum denticulatum.

#### INTERNAL STRUCTURE OF THE SPINAL CORD.

The spinal cord consists of white and grey nervous substance. The white matter, forming by far the larger portion of the cord, is

situated externally, whilst the grey matter is disposed in the interior.

The **white substance** of the anterior and posterior columns is penetrated by the median fissures, and by trabeculae of connective tissue

Fig. 348.

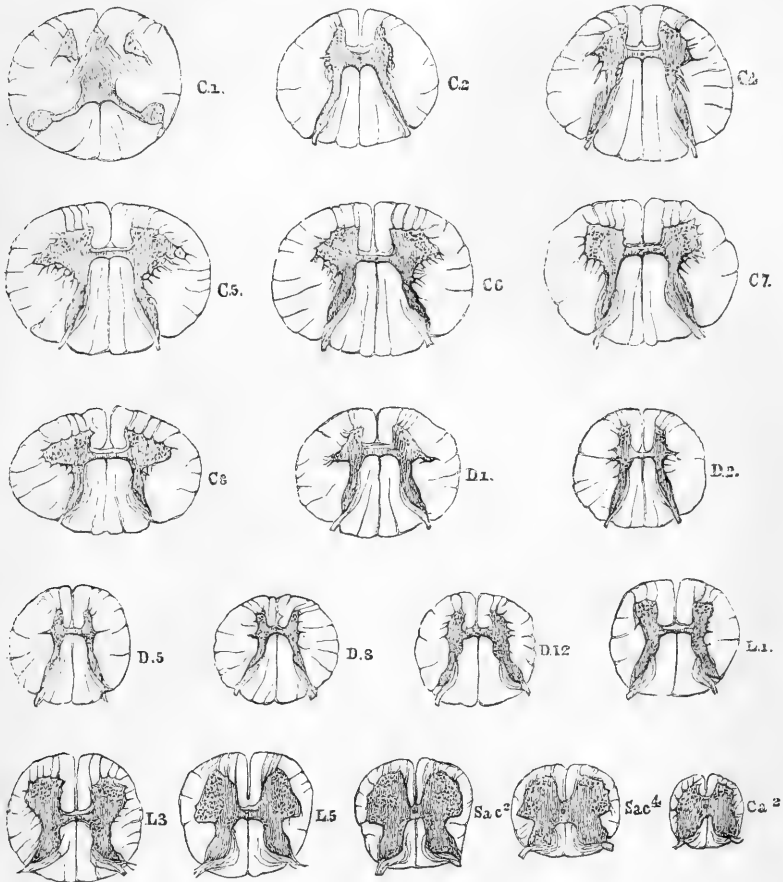


Fig. 348.—TRANSVERSE SECTIONS OF SPINAL CORD AT DIFFERENT HEIGHTS. MAGNIFIED TWO DIAMETERS.

The letters and numbers indicate the position of each section : C 1, C 2, &c., at level of first cervical nerve, second cervical nerve ; D 1, &c., first dorsal, &c. ; L 1, &c., first lumbar, &c. ; sac. 2, second sacral ; ca. 2, second coccygeal nerve. The grey substance is shaded dark, and the nerve-cells within it are indicated by dots.


extending inwards from the surface. Most of these are irregular and indistinct, but in the cervical region a septum extends forwards and inwards from the fissure just described which bounds the posterior median column. This column is thus marked off from the rest of the posterior column as a wedge-shaped area on each side of the posterior median fissure.

The **grey substance**, as seen in a transverse section of any part of the cord, presents two crescent-shaped masses, placed one in each lateral half, with their convexities towards one another, and joined across the middle by a transverse portion, the *grey* or *posterior commissure* of the cord. Each of these grey crescents has an *anterior* and a *posterior cornu* or horn. The posterior, generally longer and narrower, approaches the posterior lateral fissure: the anterior, shorter and thicker, extends towards the place of attachment of the anterior roots of the nerves, thus dividing the antero-lateral column into the anterior and lateral portions of white substance. On the outer surface of each crescent, between the two cornua, processes from the grey substance form a network which encloses portions of the white column. This is seen especially in the cervical region. A layer of white substance separates the grey commissure from the bottom of the anterior median fissure, and is named the *anterior* or *white commissure*.

The back part of the posterior horn, which is somewhat enlarged, is called the *caput cornu posterioris* (fig. 350, *a*); the narrower portion which connects it with the rest of the grey substance being called the *cervix cornu* (fig. 350, *b*). At the tip of the caput cornu the grey matter has a peculiar semitransparent aspect, whence it was named by Rolando *substantia cinerea gelatinosa*.

The grey crescents vary in form in different parts of the cord (see fig. 348). In the dorsal region both anterior and posterior cornua are narrow. In the cervical and lumbar regions the anterior cornua are large and broad, constituting cylindrical or prismatic columns of grey substance. The posterior cornua are narrow in the cervical, but very broad in the lumbar region. The grey matter is seen in a series of sections to be, relatively to the white, most abundant in the lumbar region of the cord, less so in the cervical region, and least so in the dorsal. The actual amount of white matter is greatest in the neck, of grey matter in the lumbar region. Towards the lower end of the cord the double crescentic form gradually disappears, and the grey matter is collected into a central mass, which is indented before and behind and at the sides. At its extreme point, according to Remak and Valentin, the cord consists of grey matter only.

Fig. 349. Fig. 349.—SECTION OF LOWER EXTREMITY OF SPINAL CORD. MAGNIFIED ABOUT SIX TIMES.



In A, the peculiar form of the lower extremity of the central canal is seen, and in B, its opening on the posterior surface.

The **commissure** connecting the two halves of the cord measures  $\frac{1}{25}$ th or  $\frac{1}{30}$ th of an inch in average thickness, and consists, as already mentioned, of two portions—*anterior white*, and *posterior grey commissures*. The anterior is proportional in size to the size of the nerve roots. The posterior is largest in the upper part of the *conus medullaris*.

In it is contained the central canal.

**Central canal.**—Extending through the whole length of the spinal cord, in the substance of the grey commissure, there is a minute central canal which, in prepared transverse sections of the cord, is barely visible, as a speck, with the naked eye. Superiorly, it is continued into and opens out at the *calamus scriptorius* of the fourth

ventricle ; and inferiorly, at the extremity of the conus medullaris, it becomes enlarged, shaped like the letter T, and extends backwards to the surface of the cord, being covered in only by pia mater and connective tissue. This canal, {though minute, is an object of considerable interest as a typical part of the structure of the cord, it being the permanent remains of the cavity of the cylinder formed by the spinal cord at the earliest period of its development. It is more distinctly seen in fishes, reptiles, and birds than in mammals.

## MINUTE STRUCTURE.

The substance of the spinal cord consists of a large proportion of nervous substance, supported in a delicate framework of connective tissue, and containing numerous minute blood-vessels. The white matter presents nerve-fibres, but is almost destitute of nerve-cells: the grey matter contains both elements.

**Connective tissue** takes part in the structure of the cord to a very considerable extent. It forms a complete covering surrounding the white substance beneath the pia mater, and from this covering trabeculæ of connective tissue extend into the white substance (fig. 351, e, e). A narrow layer of gelatinous connective tissue lies upon the surface, fills up its inequalities, and sends prolongations with the fibrous septa. These, with the exception of those above described (p. 493), are irregular, and extend a variable depth into the cord, some reaching the grey substance. They divide and ramify, and their ultimate subdivisions are continuous with a peculiar delicate matrix in which the nerve fibres are embedded, and which is termed by Virchow the *neuroglia*. It contains many minute granule-like nuclei, and is supposed to be derived, in part at any rate, from peculiar changes in connective tissue cells (see p. 136). In the posterior median column the connective tissue is remarkably abundant. In the grey matter there is also much connective tissue, especially in the immediate neighbourhood of the central canal. Whether the smallest cells of the grey substance are really nervous or belong to the connective tissue is still undecided, but it is certain that many of the nuclei belong to the connective tissue.

**White substance.**—The *fibres* are in greatest part longitudinal ; the principal exceptions being those contained in the commissure, and in the roots of the nerves. The longitudinal fibres are finer in the posterior columns, and posterior parts of the lateral columns, than in other parts, and the deepest fibres are smaller than those placed more superficially. (Kölliker.) The larger fibres are about  $\frac{1}{1500}$  inch in diameter, the smaller are about  $\frac{1}{10}$ th of that size. A few branching nerve-cells exist in the neighbourhood of the grey matter.

**Grey substance.**—The *fibres* of the grey substance are for the most part not more than one-half the diameter of their continuations in the white substance and in the nerve-roots, but among them there are a few of larger size. They are very various in their direction, and are arranged in a complete network, except those which are connected with the roots of the nerves, which pass in definite directions, arranged in compact groups. The fine network appears to be, in part, at any rate, composed of the fine branching processes of the nerve cells.

The *nerve-cells* of the grey matter are of two kinds. Firstly, there are very large branched cells, from  $\frac{1}{400}$  to  $\frac{1}{200}$  of an inch in size, con-

taining nuclei and pigment; secondly, there are smaller cells, ranging from  $\frac{1}{3000}$  to  $\frac{1}{4000}$  of an inch, the majority being from  $\frac{1}{12000}$  to  $\frac{1}{6000}$  of an inch in size.

The smaller cells occur scattered throughout the whole of the grey matter, and are aggregated also in the *substantia gelatinosa* at the extremity of the caput cornu posterioris, where they are scattered in a finely granular basis, and among them pass many fine nerve-fibres derived from the posterior roots.

The larger cells are collected into groups. In the anterior horn they are placed chiefly in its anterior and in its outer portions, although scattered cells occur throughout the cornu. The two groups (with

Fig. 350.

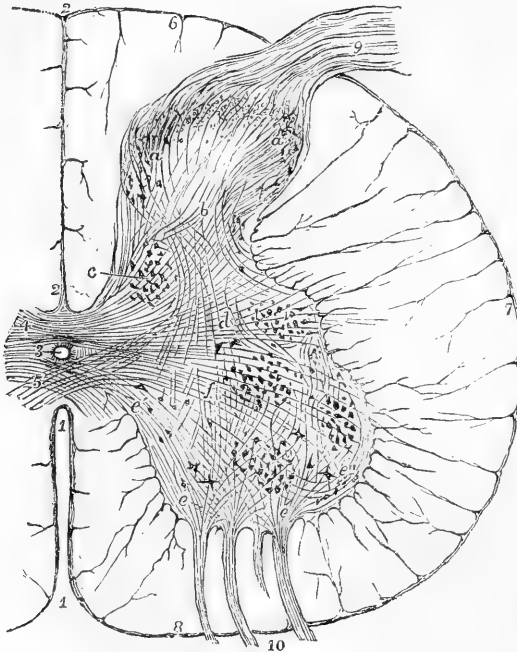


Fig. 350.—TRANSVERSE SECTION OF HALF THE SPINAL MARROW IN THE LUMBAR ENLARGEMENT. (Allen Thomson.) §

This is a semidiagrammatic representation taken from a prepared specimen, and founded in part on the statements of Lockhart Clarke and of Kölliker.

1, anterior median fissure; 2, posterior median fissure; 3, central canal lined with epithelium; 4, posterior commissure; 5, anterior commissure; 6, posterior column; 7, lateral column; 8, anterior column; (at each of these places and throughout the white substance the trabecular prolongations of the pia mater are shown;) 9, fasciculus of posterior nerve root entering in one bundle; 10, fasciculi of anterior roots entering in four spreading bundles of fibres; a, a, caput cornu

posterioris with large and small cells, and above them the gelatinous substance; b, in the cervix cornu, decussating fibres from the nerve roots and posterior commissure; c, posterior vesicular columns (of Clarke); d, fibres running transversely from the posterior commissure into the lateral columns; near d, the lateral group of cells, intermedio-lateral tract; e, e, fibres of the anterior roots, entering the anterior cornu, and passing through among the radiating cells, but not joining their processes; e', fibres from the anterior roots which decussate in the anterior commissure; e'', external fibres from the roots running round the outside of the anterior grey cornu towards the lateral columns; f, fibres from the posterior commissure and from the posterior cornu running towards the anterior. Three groups of cells are seen in the anterior cornu; of these the anterior are external and internal, the posterior are chiefly external or lateral.

which the anterior nerve-roots are connected) are well defined, especially in the cervical and lumbar enlargements. The outer group is usually cylindrical, the anterior prismatic in form, and the latter is often broken up into two or three smaller groups.

In the posterior cornu the large cells are collected chiefly into a compact group, the *posterior vesicular column* (of Clarke) (fig. 350, *c*), which occupies the inner half of the cervix. The cells lie among fine interlacing fibres, some horizontal, derived chiefly from the posterior roots of the nerves, and many longitudinal. Some cells are small and others large, with processes running in different directions, but especially upwards and downwards, parallel to the vertical fibres. This group is skirted by fibres (also chiefly from the posterior roots) which curve around it, and among which lie other fusiform nerve-cells. This group of cells is largest near the upper part of the lumbar enlargement (fig. 348, L 1), where it has a diameter of  $\frac{1}{25}$ th of an inch, and causes a projection on the inner surface of the cervix cornu. It can be traced upwards through the dorsal region, becoming less distinct, and ceasing before the middle of the cervical enlargement is reached. Below the middle of the lumbar enlargement it is indistinct. In the upper part of the conus medullaris a group of cells behind the central canal, on each side, occupies nearly the position of this column, but has different histological connections. (Clarke.)

In the outer portion of the grey matter, midway between the anterior and posterior cornua, is a small group of cells, the *tractus intermediolateralis* (of Clarke) (fig. 350, *d*), which occupies a projection on the surface of the grey matter. It extends from the upper part of the lumbar to the lower part of the cervical enlargement, being larger in the

Fig. 351.

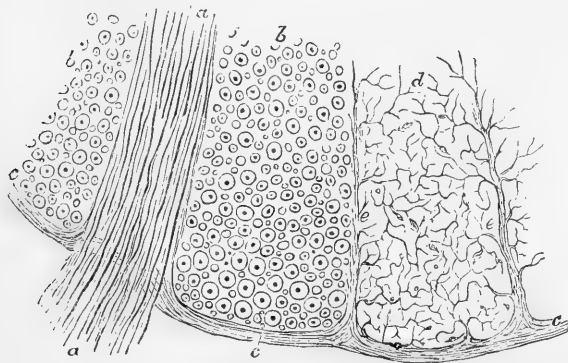


Fig. 351.—A SMALL PORTION OF A TRANSVERSE SECTION OF THE HUMAN SPINAL CORD NEAR THE SURFACE AT THE ENTRANCE OF A BUNDLE OF THE ANTERIOR ROOTS. (Allen Thomson.)  $\frac{300}{1}$

This figure, which is somewhat diagrammatic, is intended to show the relation to the nervous substance of the pia-matral sheath of the cord and the processes of connective tissue prolonged from it between the longitudinal and other nerve fibres. *a, a*, a bundle of the anterior roots; *b, b*, transverse sections of part of the anterior columns of the cord in which the dark points are the axis-cylinders, and the circles represent the outline of the medullary substance: in these parts the connective tissue is not represented, and many of the smallest nerve-fibres have also, for the sake of clearness, been omitted; *c*, the pia-matral covering of the cord; *d*, one of the compartments of the anterior column enclosed by septa of connective tissue prolonged from the pia mater, and exhibiting the fine frame-work of connective tissue, *e, e*, extending through among the nerve-fibres, which last have been omitted.

upper part than in the middle of the dorsal region. In the upper part of the cervical region a group of cells reappears in the same situation, and is traversed by the roots of the spinal accessory nerve. The cells of the intermedio-lateral tract are of large and medium size, and many of them are fusiform, lying transversely. They are probably connected with fibres which run transversely from the commissure across the central portion of the grey substance.

**Commissures.**—The *anterior commissure* consists of medullated nerve fibres which pass on each side, some into the anterior white column, others into the anterior horn. Their course is not strictly transverse, many fibres which enter the anterior part of the commissure at one side leave it at the posterior portion on the other side. There is thus a double decussation at the middle line (fig. 350). Sometimes part of the fibres have an ascending or descending direction, or are displaced by the vessels which pass into the cord from the anterior fissure.

The *posterior commissure* is composed of fine grey nerve fibres, running transversely and most abundant behind the central canal. On each side of the canal is an area occupied chiefly by gelatinous substance, in which are a few longitudinal fibres and granules. Close to the canal many small round or angular cells are scattered, some branching, others containing many nuclei (probably connective tissue cells).

The **central canal** is lined with a layer of cylindrical ciliated epithelium. In the adult its lumen is not unfrequently occupied by cells and granular material, and, the epithelium layer being indistinct, the cells within it appear continuous with those in its vicinity.

The **filum terminale** is said to contain in its upper portion a continuation of the central canal, surrounded by gelatinous substance and nerve fibres. In its lower portion it consists of connective tissue only.

Fig. 352.

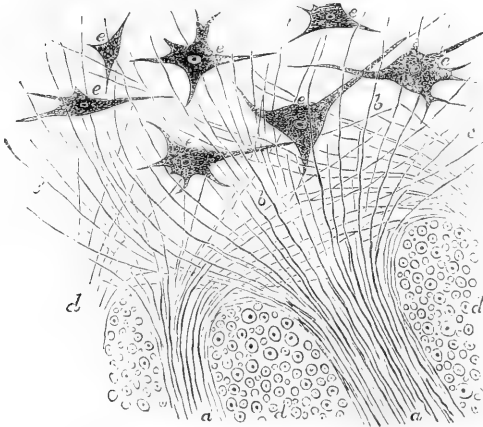


Fig. 352.—A SMALL PORTION OF A TRANSVERSE SECTION OF THE SPINAL CORD AT THE PLACE WHERE TWO BUNDLES OF THE FIBRES OF THE ANTERIOR ROOTS PASS INTO THE GREY SUBSTANCE. (Allen Thomson.)  $\frac{1}{300}$ .

This figure may be looked upon as representing the inner ends of the anterior roots of the nerves, of which the outer part is shown in fig. 346. *a, a*, the two bundles of fibres of the anterior root passing between the compartments of longitudinal fibres of the cord; *b, b*, the same fibres running backwards through the grey substance towards the posterior cornua; *c, c'*,

those spreading in the anterior cornua, on the one side towards the anterior commissure, and on the other round the outer side of the anterior cornu; *d, d*, portions of three compartments of the anterior columns in which the longitudinal fibres of the cord are shown in transverse section; *e, e*, large radiated and nucleated cells in the grey substance of the anterior cornu—some with three, others with a greater number of processes emanating from them: no direct communication is shown between these processes and the nerve fibres of the roots.



**Origin of the spinal nerves.**—The anterior and posterior roots of the spinal nerves are attached along the sides of the cord, and opposite to the corresponding cornua of the grey matter; the posterior roots in a straight line at the posterior lateral groove, and the anterior roots scattered somewhat irregularly upon the surface (fig. 347, B).

The fibres of the *anterior roots* may be traced into and through the anterior cornua (fig. 350, *c, e*). In it they diverge in different directions, passing among the large multipolar cells with which some are probably connected. Many fibres pass backwards in the substance of the anterior cornu, where some of them would appear to form connections with fibres proceeding from other parts of the cord, and others to spread obliquely upwards and downwards; an external group reach the lateral column, and an internal group cross in the anterior white commissure to the anterior cornu of the opposite side.

The fibres of the *posterior roots*, on reaching the posterior cornu, diverge from each other and enter the grey substance, some immediately through the substantia gelatinosa, others after curving through the outer portions of the posterior columns and round the inner side of the caput cornu (fig. 350, 9). Of those which pass through the gelatinous substance, a large number immediately turn upwards and downwards, and blend with the fine plexus of nerve-fibres which constitutes the central portion of the grey matter, reaching, probably, some the anterior cornu, and others by the posterior commissure the opposite side of the cord. Of the fibres of the posterior roots which enter the grey substance in front of the substantia gelatinosa, some pass forwards at once through the grey substance, while others enter and blend with the posterior vesicular columns of nerve-cells. Another set of fibres slant principally upwards, but some downwards, in the white substance of the posterior columns, and, interlacing with each other, most probably enter the grey matter at different heights. Some are lost to view in the posterior white columns, and it is uncertain whether or not they immediately ascend through these columns to the brain.

A narrow grey line extends from the apex of the posterior horn to the posterior lateral furrow, and consists of connective tissue and fine nerve fibres. It was formerly thought to be part of the posterior nerve root.

Much discussion has taken place as to the course of the fibres in the cord, and their ultimate destination. It is easily understood that, by the examination of sections difficult to prepare, limited in extent, liable to undergo changes in the preparation, and giving views confined each to little more than a thin lamina, it is scarcely to be expected that the full history of many tortuous fibres can be accurately ascertained. Thus it remains still undecided whether any of the fibres of the nerve-roots pass up all the way to the brain. Volkmann concluded that none of them reached the brain, arguing from measurements of the size of the cord in different regions, that the cord could not contain in its upper regions all those nerve-fibres which were traceable to it in the lower. Kölliker pointed out the fallacy of this conclusion, in so far as Volkmann had not made proper allowance for the diminished size of the fibres as they ascend in the cord; but although Volkmann's argument was thereby invalidated, it appears impossible to prove by microscopic observations that fibres of nerve-roots traced into the grey matter, and observed to emerge into the white matter, do not again re-enter the grey and terminate there.

There seems little doubt that the radiating prolongations of the cells are in actual continuity with the axial filaments of nerve-fibres, whether proceeding from nerve-roots or from different parts of the cord itself.

## B.—THE ENCEPHALON.

The encephalon admits of being conveniently divided into the medulla oblongata, the cerebellum with the pons Varolii, and the cerebrum.

The *medulla oblongata* is the part continuous with the spinal cord: it rests on the basilar process of the occipital bone, and on its superior or dorsal surface presents a groove continuous with the central canal of the spinal cord.

The *cerebellum* occupies the posterior fossa of the cranium. By the mesial part of its anterior and inferior surface, it forms the roof of a space, the floor of which is the grooved posterior surface of the medulla oblongata, and which is named the fourth ventricle of the brain. On each side of this, the cerebellum is connected with the medulla oblongata and cerebrum, and also receives the fibres of the *pons Varolii*, which is a commissure, uniting the two hemispheres of the cerebellum, and passing beneath and between the fibres which extend upwards from the medulla oblongata.

The *cerebrum* includes all the remaining and much the largest part of the encephalon. It is united with the parts below by a comparatively narrow and constricted portion or *isthmus*, part of which, forming

Fig. 353.

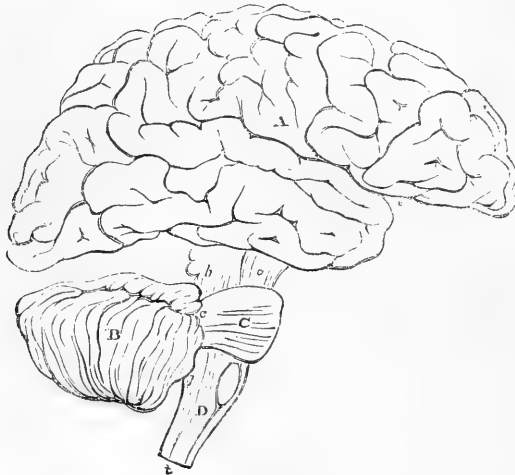


Fig. 353.—PLAN IN OUTLINE OF THE ENCEPHALON, AS SEEN FROM THE RIGHT SIDE.  $\frac{1}{3}$

The parts are represented as separated from one another somewhat more than natural so as to show their connections. A, cerebrum; *e*, fissure of Sylvius; B, cerebellum; C, pons Varolii; D, medulla oblongata; *a*, peduncles of the cerebrum; *b*, *c*, *d*, superior, middle, and inferior peduncles of the cerebellum; the parts marked *a*, *b*, *c*, C, form the isthmus encephali.

the crura cerebri, descends into the pons Varolii, and through it is continued into the medulla oblongata, whilst another part joins the cerebellum. Situated on the fibres which extend up from the constricted part, are a series of eminences, named, from behind forwards, the corpora quadrigemina, optic thalami, and corpora striata; and springing from the front and outer side of the corpora striata are the large convoluted cerebral hemispheres, which expand from this place in all directions, concealing the eminences named, and occupying the vault of the cranium, the anterior and middle cranial fossæ, and the superior fossæ of the occipital bone. The cerebral hemispheres are united together by a principal and smaller commissures; by means of which there is enclosed a cavity, which is subdivided into various ventricles, viz., the two lateral, the third, and the fifth.

## THE MEDULLA OBLONGATA.

The *medulla oblongata* is bounded above by the lower border of the pons Varolii, whilst it is continuous below with the spinal cord, on a level with the upper border of the atlas, at a point which corresponds with the lower extremity of the anterior pyramids, to be presently described. It inclines obliquely downwards and backwards; its anterior surface rests in the basilar groove, whilst its posterior surface is received into the fossa named the vallecula, between the hemispheres of the cerebellum, and there forms the floor of the fourth ventricle. To its sides several large nerves are attached.

Fig. 354.—VIEW OF THE ANTERIOR SURFACE OF THE PONS VAROLII AND MEDULLA OBLONGATA.

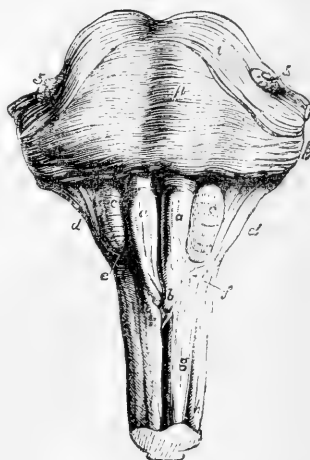*a, a*, anterior pyramids; *b*, their decussation; *c, c*, olivary bodies; *d, d*, restiform bodies; *e*, arciform fibres; *f*, fibres described by Solly as passing from the anterior column of the cord to the cerebellum; *g*, anterior column of the spinal cord; *h*, lateral column; *p*, pons Varolii; *i*, its upper fibres; *5, 5*, roots of the fifth pair of nerves.

The term *medulla oblongata*, as employed by Willis and Vieussens, and by those who directly followed them, included the crura cerebri and pons Varolii, as well as that part to which by Haller first, and by most subsequent writers, this term has been restricted.

It is of a pyramidal form, having its broad extremity upwards: it is expanded laterally at its upper part: its length from the pons to the lower extremity of the pyramids is about an inch and a quarter; its greatest breadth is nearly an inch; and its thickness, from before backwards, is about three-quarters of an inch.

**Fissures.**—The *anterior* and *posterior median fissures* which partially divide the spinal cord are continued up into the medulla oblongata. The anterior fissure terminates immediately below the pons in a recess,

Fig. 354.



the *foramen cæcum* of Vicq d'Azyr; the posterior fissure is continued upwards into the floor of the fourth ventricle, where it opens and expands in a superficial furrow, and is gradually lost.

In other respects an entirely different arrangement of the parts prevails from that in the cord. The surface of each half of the medulla presents four eminences or columns, which are met with in the following order, from before backwards, viz.: the anterior pyramids, the olivary bodies, the restiform bodies, and the posterior pyramids.

The **anterior pyramids** (fig. 354, *a, a*) are two bundles of white substance, placed one on either side of the anterior fissure, and marked off from the olivary body externally by a slight depression. They become broader and more prominent as they ascend towards the pons Varolii. At their upper end they are constricted, and thus enter the substance of the pons, through which their fibres may be traced into the peduncles of the brain.

In the lower part, a portion of each pyramid, arranged in several bundles, which interlace with the corresponding bundles of the other pyramid, passes downwards across the fissure to the opposite side. This *decussation of the pyramids* (fig. 354, *b*; fig. 357, *B*) is not complete, but involves the greater part of the innermost fibres. When traced from below, it is found that the whole or a great part of the decussating fibres come forward from the deep portion of the lateral columns of the cord, and advance to the surface between the diverging anterior columns, which are thus thrown aside. Other decussating fibres come from the posterior grey substance, and as these, together with the fibres from the lateral column, cross the anterior horn, they receive from the latter additional fibres. The decussation is more superficial, and therefore of greater apparent extent, in some brains than in others.

The outer smaller portion of each pyramid does not decussate; it consists of fibres, derived from the anterior column of the cord: these ascend, and are joined by the decussating portion from the opposite side. Together they form a prismatic bundle or column of white fibres, which extends deeply into the substance of the medulla, and is triangular in a cross section.

The anterior pyramid contains no grey matter, but a grey layer which lies behind it, between it and the olivary body, has been described as its nucleus. This consists of medium-sized stellate nerve-cells, lying between transverse and longitudinal fibres, and embedded in a gelatinous substance.

The **olivary bodies** (fig. 354, *c*) are two masses placed to the outer side of the pyramids, and sunk to a considerable depth in the substance of the medulla oblongata, appearing on its surface as two smooth oval eminences. They do not reach the pons Varolii above, being separated from it by a deep depression; nor do they extend so far down as the pyramids.

They consist externally of white substance, of which the fibres chiefly run longitudinally; and internally of a grey nucleus, named *corpus dentatum* or *ciliare*, or *olivary nucleus*.

The *olivary nucleus* (fig. 357, *D, o*) appears, on making a section, whether horizontal or vertical, through the middle, to present the form of a zig-zag line of a light yellowish colour, circumscribing a whitish substance within, and interrupted towards the centre of the medulla.

It is arranged in the form of a capsule, which is open at its upper and inner part, and has its sides corrugated or plicated, so as to give the indented appearance to a section. This capsule is, moreover, surrounded with white matter externally, and through its open part white fibres pass into or issue from its interior, and connect it with other parts of the brain. It contains small, round and stellate cells, lying in a gelatinous substance and among the fibres which pass through it. A separate grey lamina above it, of similar structure, has been termed the *accessory olivary nucleus*.

The external fibres of the anterior columns of the cord, which at the decussation of the pyramids are thrown outwards, are continued upwards, on the surface of the medulla oblongata, and then pass, partly on the outside of, and partly beneath the olivary bodies—being joined in their further progress by the fibres issuing from the olivary nucleus. To these fibres the term *olivary fasciculus* (fig. 356, *o'*) has been applied.

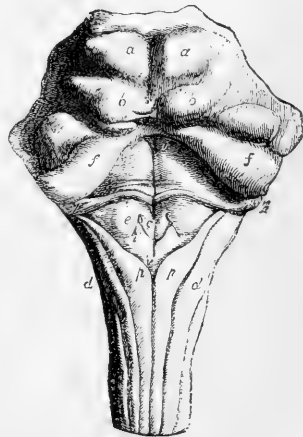
The **restiform bodies** (figs. 354 and 355, *d*), placed behind and to the outer side of the olivary bodies, are two lateral rounded eminences or columns directly continuous with the posterior, and with part of the antero-lateral columns of the cord; they diverge slightly as they ascend, and thus occasion the greater width of the medulla at its upper part. Each of them passes into the corresponding hemisphere of the cerebellum, and constitutes its inferior peduncle. At first they are in contact with the small tracts of the medulla, named the posterior pyramids; but higher up they become free and prominent, and assist in forming the lateral boundaries of the fourth ventricle. There is a considerable quantity of grey matter in their interior.

By far the larger portion of the white substance of the restiform body consists of longitudinal fibres, which include all those belonging

Fig. 355.—VIEW OF THE POSTERIOR SURFACE OF THE PONS VAROLII, CORPORA QUADRIGEMINA, AND MEDULLA OBLONGATA.

*a, a*, the upper pair of corpora quadrigemina; *b, b*, the inferior; *f, f*, superior peduncles of the cerebellum; *c*, eminence connected with the nucleus of the hypoglossal nerve; outside *e* is the external auditory nucleus; beneath *e* and *i*, that of the vagus nerve; *d, d*, restiform bodies; *p, p*, posterior pyramids; *v, v*, groove in the middle of the fourth ventricle, ending below in the calamus scriptorius; *7, 7*, roots of the auditory nerves. (See also Fig. 358.)

Fig. 355.



to the posterior column of the cord except the posterior median column, some derived from the lateral column, and also a small band from the anterior column. This last-named band runs obliquely below the olivary body, and, as was shown by Solly, connects the anterior column with the cerebellum.

The **posterior pyramids** (fasciculi graciles) (fig. 355, *p p*) of the medulla oblongata, the smallest of the four pairs of columns into which it is divided, are situated one on each side of the posterior median

fissure. They consist of white fibres, continuous with those of the posterior median columns of the cord, and contain much grey matter. They increase in size as they ascend until they reach the point where the medulla opens out to form the floor of the fourth ventricle; and there, diverging from one another, they appear to taper and become closely applied to the restiform bodies. Their fibres quit these bodies, however, and pass up to the cerebrum.

The **floor of the fourth ventricle** (figs. 355 and 358), or space between the medulla and cerebellum, is formed by that portion of the back of the medulla oblongata which is situated above the divergence of the posterior pyramids. Upon it, the central grey matter of the medulla oblongata, is, as it were, opened out to view. It is marked by a median furrow, ending inferiorly in the *calamus scriptorius* (fig. 355, *v*), and at its lower end is a tubular recess, passing down the centre of the medulla for a few lines. This, which has been sometimes named the *ventricle of Arantius*, is the upper expanded portion of the central canal of the spinal cord.

In the upper part of the floor of the fourth ventricle are two longitudinal eminences, one on each side of the middle furrow, greyish below, but appearing white higher up. These are formed by two bundles of white fibres, mixed with much grey matter, the *fasciculi teretes* (fig. 358, 1).

Surmounting the free inner margin of the restiform body and posterior pyramid is a thin lamina, the *ligula*, occupying the angle between the cerebellum and the restiform body, and stretching towards its fellow of the opposite side. It derives a certain interest from indicating how the cylinder, which is closed in the spinal cord, might be completed in this region of the medulla oblongata by the union of the opposite margins.

**Transverse fibres.**—Crossing the grey matter in the floor of the fourth ventricle several transverse white lines, or *striae medullares*, are usually observed, passing outwards from the median fissure, and round the sides of the restiform bodies (figs. 355 and 358, 2). Some of these white striae form part of the roots of the auditory nerves, a few run slantingly upwards and outwards on the floor of the ventricle, whilst others again embrace the corresponding half of the medulla oblongata. These transverse lines are sometimes wanting, in which case the white fibres on which they depend probably exist at some depth below the surface.

A set of superficial white fibres on the fore part and sides of the medulla oblongata, crossing over it below the olivary bodies, was described by Santorini and Rolando as *fibræ vel processus arciformes*. They belong to a system of white fibres which pass transversely or horizontally outwards, and are probably continuous with the septal fibres about to be noticed. Sometimes the greater part of the pyramidal and olivary bodies is covered by a thin stratum of these transverse fibres, which appear to issue from the anterior median fissure; but, most commonly, these superficial fibres are found only at the lower extremity of the olive, as the arciform fibres already mentioned.

Besides the superficial transverse fibres now referred to, the medulla oblongata presents other horizontal fibres in its interior, some of them disposed in a mesial *raphe* or *septum* (fig. 357, *R*), and numerous others proceeding from that septum transversely outwards. Of these last, the majority, entering the olivary bodies, form the whole of their

white substance ; and then passing radiately through the grey capsule, turn backwards to the restiform body and lateral column, those of them which pierce the anterior wall of the capsule arching round it to reach their destination. Other fibres pass behind the olivary into the restiform bodies, and seem to terminate in the grey substance of the floor of the fourth ventricle.

**Origin of Nerves.**—From the surface of the medulla certain of the cranial nerves arise, namely, the sixth from the anterior pyramids close to the pons, the facial and auditory from the restiform body close to the pons, the glosso-pharyngeal, pneumo-gastric, and spinal accessory from the lateral portion of the medulla, the hypoglossal from the groove between the anterior pyramid and olivary body. Their fibres may be traced to grey matter in or near the floor of the fourth ventricle (see p. 510 and 568).

Fig. 356. —DIAGRAMMATIC REPRESENTATION OF THE PASSAGE OF THE COLUMNS OF THE MEDULLA OBLONGATA UPWARDS AND DOWNWARDS.

A, the specimen, which is seen from before, includes the medulla oblongata and the pons Varolii, with a small portion of the spinal marrow. The left lateral column (that to the reader's right) has been lifted out of its place to the side, and the anterior and posterior columns of that side remain undisturbed : the right anterior and posterior columns have been removed, and the lateral column remains in its place. The upper part of the right pyramid is removed. The transverse fibres of the pons Varolii have been divided in circumscribed portions to different depths corresponding with the several places of passage of the columns of the medulla.

P, pons Varolii, part of the anterior surface, where it has been left entire ; *p*, the right and left pyramids, the upper part of the right has been cut away ; *p'*, the fibres of the left pyramid, as they ascend through the pons, exposed by the removal of the superficial transverse fibres ; *p''*, placed on the deeper transverse fibres of the pons on the right side, below the divided fibres of the pyramid (these transverse fibres a little lower down constitute the part known as the "trapezium") ; *a*, left anterior column of the cord, passing upwards into the undecussated part of the anterior pyramid, and into *a'*, the olivary column ; *o*, olivary body ; *o'*, the continuation of the olivary column ascending deeply through the pons and exposed by the removal of a small portion of the deeper transverse fibres ; *o''*, the same fibres divided by a deeper incision on the right side ; *l*, the right lateral column, passing upwards into the following parts, viz., *x*, the deeper part passing by decussation into the left pyramid ; *r*, the part passing into the restiform body ; *ft*, the part ascending in the back of the fourth ventricle as the fasciculus teres ; to the outside of this are seen the ascending fibres of the posterior pyramid ; *l'*, the left lateral column drawn aside from its place in the spinal cord ; the fasciculus teres, *ft*, and the part to the restiform body, *r*, cut short ; *x*, the deeper part passing by decussation into the right pyramid ; *r'*, the part of the restiform body derived from the anterior column of the spinal cord ; *pc*, the posterior column of the left side exposed by the removal of the lateral column, and shown ascending to the restiform body as the fasciculus cuneatus, *fc* : on the right side the posterior column being removed, *fc*, points to this fasciculus cuneatus cut short below.

B, explanatory outline of the section of the spinal cord. *a*, anterior columns ; *p*, posterior ; *l*, lateral.

Fig. 356.

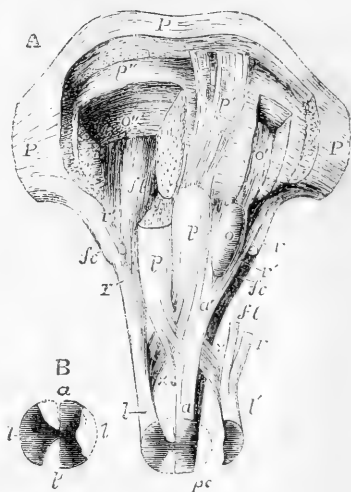


Fig. 357.

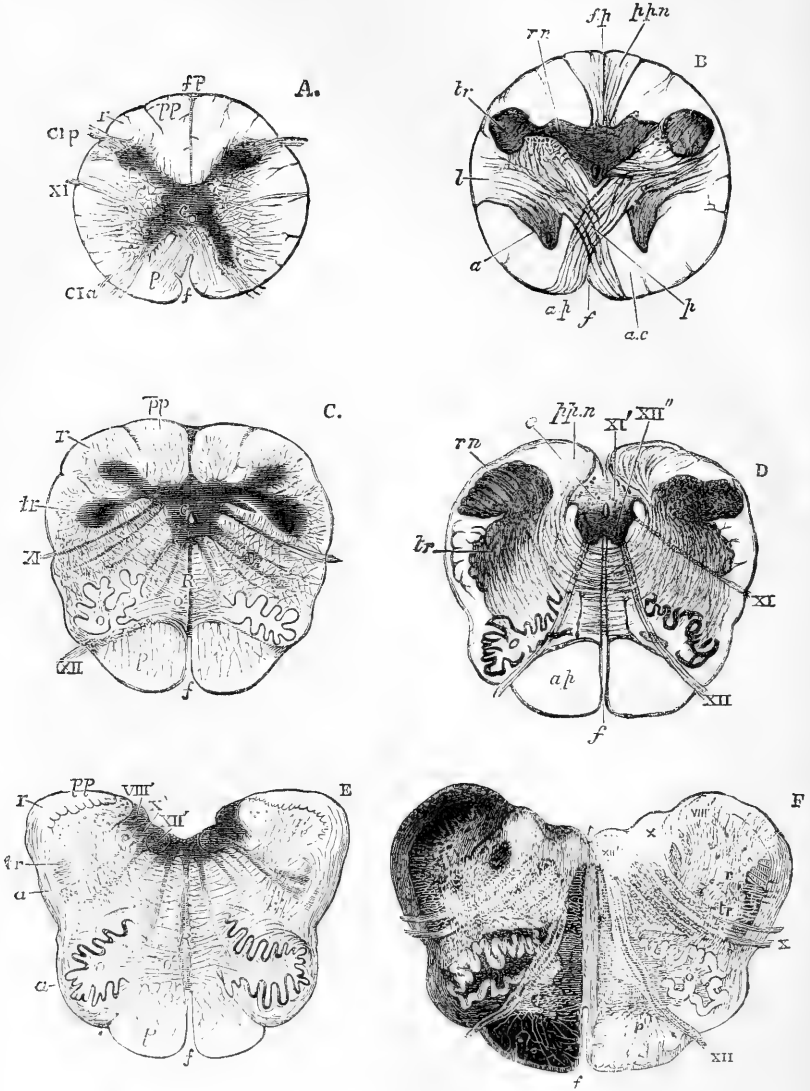


Fig. 357.—MAGNIFIED DIAGRAMATIC VIEWS OF TRANSVERSE SECTIONS OF THE MEDULLA OBLONGATA (B & D from Lockhart Clarke, A, C, E after Lockhart Clarke and Reichert. F, from Stilling).

In all, the grey substance is indicated by darker shading.

The sections represented are, A at the lower part of the decussation of the pyramids; B, through the middle of the decussation; C, through the lowest part of the olivary bodies; D, just below, and E, just above, the point of the calamus scriptorius; F, a little higher, through the lower part of the fourth ventricle.



*c*, central canal and grey substance surrounding it; *f*, anterior median fissure; *fp*, posterior median fissure; *r*, and *rn*, restiform body and nucleus; *pp*, and *ppn*, posterior pyramid and its nucleus; *tr*, tubercle of Rolando; *l*, lateral column; the anterior column of the cord is indicated by *p* in A, its remains by *a c* in B; *p* in the other figures indicates the anterior pyramid; in B, its decussation; *a* in B points to the remains of the anterior cornu; in E to the superficial arciform fibres: *l*, lateral column; *o*, olivary body; *o'*, the commissural fibres proceeding from its interior; *R*, raphe; *C*, I, *a*, and *C* I. *p*, anterior and posterior roots of first cervical nerves; *viii'* (E and F), inner auditory nucleus; *x*, pneumogastric nerve; *x'* (*x* in F), its nucleus; *xi*, spinal accessory nerve; *xi'*, its nucleus; *xii*, hypoglossal nerve; *xii'*, its nucleus (which should extend nearer to the middle line than is represented in E).

**Course of fibres from the spinal cord upwards through the medulla oblongata.**—Assuming, for convenience of description, the existence of three white columns of the cord, these are disposed as follows.

1. The *posterior column*, with the exception of the posterior median column (from which it is here distinguished as the *processus cuneatus*), enters into the formation of the restiform body, which ascends to the cerebellum. The posterior median column (posterior pyramid or *fasciculus gracilis*) ascends to the cerebrum.

2. The *lateral column* ascends towards the base of the olivary body, and is disposed of in three ways; (1,) some of its fibres from the surface and deep part join the restiform body and proceed with it to the cerebellum; (2,) a large number pass obliquely inwards, then come forwards between the anterior columns, and, crossing the median plane, appear as the fibres of decussation, and form the chief part of the opposite anterior pyramid; (3,) the remaining fibres pass up to the cerebrum, as the *fasciculus teres*, appearing on the back of the pons Varolii, in the upper part of the floor of the fourth ventricle.

3. The *anterior columns* (fig. 356, *a*, *a'*) having reached the apex of the anterior pyramids, are thrust aside from their median position by the decussating fibres derived from the lateral columns, and are then distributed in three divisions. (1,) A very small division, ascends obliquely backwards beneath the olivary body, and joins the restiform body (Solly) (fig. 356, *r'*). (2,) Another division passes directly upwards, and its fibres embrace the olivary nucleus, above which they are again collected together, and are joined by other fibres arising from the nucleus, so as to form the *olivary fasciculus* (fig. 356, *o'*); this ascends through the pons and at the side of the cerebral peduncle under the name of the *fillet* (fig. 363, *f*), and reaches the *corpora quadrigemina* and the cerebral hemispheres. (3,) The remaining division of the anterior column ascends into the anterior pyramid, forming its outer part. The anterior pyramids therefore are composed of fibres from the lateral column and grey substance of the opposite side, and from the anterior column of the same side, and are continued up through the pons into the peduncles of the cerebrum.

It is to be remembered, however, that the separation between these different tracts of white fibres cannot be clearly followed out through the whole structure of the medulla oblongata, but that they are more or less blended with one another.

**Grey matter of medulla oblongata followed upwards from the cord.**—At the level of the first cervical nerve (fig. 357, A, 348, C, 1), the central grey substance is increased in size, the posterior horn on each side is thrown outwards, its neck is slender and its extremity (*caput cornu*) is

enlarged. Between the central canal (*c*) and the bottom of the anterior median fissure are the decussating fibres. A little higher (fig. 357, B) the caput cornu has increased in size and is connected with the neck only by a network. The central grey substance is encroached upon by the fibres from the lateral columns which course forwards and inwards to the decussation (*p*) and separate the anterior cornua from the rest of the grey substance. The substance of the posterior pyramid becomes filled with cells and fibres which are connected with the posterior cornu near its origin. This constitutes the post-pyramidal nucleus or ganglion (*ppn*). A little further out, on each side, a projection backwards from the cervix cornu into the restiform body constitutes the rudiment of the restiform nucleus (*rn*). Still higher up the medulla (fig. 357, C) these masses of grey matter have increased in size, so that on a level with the lower part of the olivary bodies, that which was the caput cornu posterioris approaches the surface, behind the restiform body, and becomes known as the grey tubercle of Rolando (*tr C, D and E*). Still higher up, the post-pyramidal and restiform ganglia coalesce, and both they and the grey tubercle become connected with the nuclei of origin of certain nerves.

The olivary nuclei which appear on the outer side of the anterior pyramids are unconnected with the system of grey matter prolonged from the spinal cord.

The anterior pyramids are free from grey matter in their interior, and are separated from the rest of the medulla by strong septa of connective tissue, and from one another by a *raphe*, which extends back to the grey matter surrounding the central canal, and which contains mesial horizontal fibres, named *septa*.

**Nerve nuclei.**—A continuous series of collections of grey matter, which extends from beneath the corpora quadrigemina, downwards along the floor of the fourth ventricle and the centre of the medulla oblongata as far as the decussation of the pyramids, constitutes the nuclei of origin of the cranial nerves from the third to the hypoglossal. Those nuclei contained in the medulla oblongata proper give origin to the hypoglossal, the spinal accessory, the vagus, and the glosso-pharyngeal nerves. Just above the decussation the narrowed central grey matter which surrounds the canal contains numerous very large multipolar cells, arranged in definite groups in front and behind the canal, and symmetrical on the two sides. Those in front of the canal (fig. 257, D XI') give origin to the fibres of the *hypoglossal* nerve, which may be seen extending from them through the olivary body to emerge at its inner side. From the cells behind the canal (XI'), the upper roots of the *spinal accessory nerve* arise and pass out through the lateral column (XI). At the point of the calamus scriptorius this nucleus becomes divided into two parts as the central canal of the cord opens into the fourth ventricle, and it increases in size at the expense of the adjacent part of the posterior pyramid. Its cells then give origin to the fibres of the pneumogastric or vagus nerve and constitute the *vagal nucleus*. Higher up (E and F) the hypoglossal nucleus comes to the surface, and dividing, pushes apart the two halves of the vagal nucleus, which have increased in size, partly at the expense of the adjacent post-pyramidal nucleus. Their cells frequently contain brown pigment and lie in a dense network of fine nerve-fibres. Still higher the hypoglossal nuclei become smaller, the vagal nuclei also lessen in size, and a group of cells appears

to the outside and in front of the vagal nucleus, which gives origin to the fibres of the glosso-pharyngeal nerve. The post-pyramidal and restiform ganglia have by this time become blended, and constitute the lower part of the inner nucleus of the auditory nerve (fig. 357, F VIII').

At the point of the calamus scriptorius the prominence on each side of the median furrow indicates the position of the lower part of the vagal nucleus. A little higher up these vagal eminences diverge, and between them the hypoglossal nuclei come to the surface. A depression on each side of the vagal eminence separates it from that of the inner auditory nucleus. Beneath this groove, just below the striæ medullares, lies the nucleus of the glosso-pharyngeal nerve. The hypoglossal nuclei cease near the striæ medullares, but the eminence beneath which they lie blends with that of the vagal nucleus and is continued upwards as the "eminencia teres." Beneath it, above the striæ medullares, lies the common nucleus of the sixth and facial nerves. (See p. 513.)

#### THE PONS VAROLII.

The *pons Varolii* or *tuber annulare* (mesocephalon of Chaussier), forms an eminence of transverse fibres above and in front of the medulla oblongata, below and behind the crura cerebri, and between the lateral hemispheres of the cerebellum. (Fig. 361.) Its margins are arched; the superior much more so than the inferior, and at the sides its transverse fibres are much more gathered together, forming, at the place where it passes into the cerebellum, a narrower bundle, which is named the *middle crus of the cerebellum*. In the middle line the pons presents a shallow groove in which the basilar artery lies, and it is perforated by small branches of the artery.

The superficial fibres are transverse in their general direction, but while the middle fibres pass directly across, the lower set ascend slightly, and the superior fibres, which are the most curved, descend obliquely to reach the crus cerebelli on each side; and some of the latter cross obliquely the middle and lower fibres, so as to conceal them at the sides.

INTERNAL STRUCTURE.—The pons consists of the longitudinal or peduncular fibres prolonged upwards from the medulla oblongata, of its own transverse or commissural fibres, through which the longitudinal fibres pass, and of a large intermixture of grey matter. When the superficial transverse fibres are removed, the prolonged fibres of the anterior pyramids come into view; these, as they ascend through the pons, are separated into smaller bundles, intersected by other transverse white fibres, which, with those upon the surface, are all continued into the middle peduncle of the cerebellum (see fig. 358).

Opposite the lower part of the pons, behind the fibres from the anterior pyramids, is another set of transverse fibres, which have a very uniform course (fig. 359, T). They constitute the *trapezium*, so called because in most of the lower animals, in which the lower fibres of the pons are not developed and the anterior pyramids are small, these transverse fibres partially appear on the surface in an area of a somewhat four-sided shape. Externally they curve round, and many are connected with, a collection of grey matter above them, called the superior olivary body, and then course outwards, across the fibres of the facial

nerve and in front of the grey tubercle, to reach the middle crus of the cerebellum.

The *median septum* or *raphe*, which exists in the medulla oblongata, is prolonged throughout the whole height of the pons in its back part, but becomes indistinct in approaching the front or basilar surface, except towards its upper and lower edge, where the superficial fibres of the pons are manifestly continuous in the median line with these septal fibres. Bundles of white fibres, belonging to the same system, encircle the crura cerebri at their emergence from the upper border of the pons.

The *grey matter* consists of small round and fusiform cells and forms a network among the bundles of fibres.

**The fourth ventricle.**—The space left between the medulla oblongata in front, and the cerebellum behind (figs. 358, and 362, *n*; 384, *v* 4), is named the fourth ventricle, or *ventricle of the cerebellum*.

The cavity of the ventricle is of a flat rhomboidal shape, being contracted above and below, and widest across its middle part. It is bounded laterally by the superior peduncles (fig. 358, 5), and by the line of union of the medulla oblongata and the cerebellum. Behind, it is covered in above by the valve of Vieussens, which extends across between the superior peduncles of the cerebellum, and below by part of the inferior vermiform process of the cerebellum which projects into it. The upper end of the ventricle is continuous with the Sylvian aqueduct or passage (*iter*) leading up to the third ventricle.

Fig. 358.

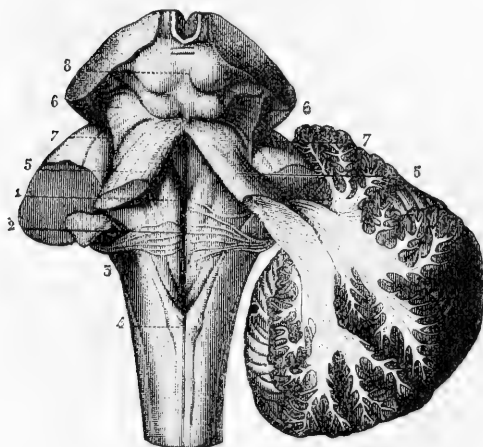


Fig. 358.—VIEW OF THE FLOOR OF THE FOURTH VENTRICLE WITH THE POSTERIOR SURFACE OF THE MEDULLA OBLONGATA AND NEIGHBOURING PARTS (from Sappey after Hirschfeld and Leveillé).

On the left side the three cerebellar peduncles have been cut short; on the right side the white substance of the cerebellum has been preserved in connection with the superior and inferior peduncles, while the middle one has been cut short.

1, median groove of the fourth ventricle with the fasciculi teretes, one on each side; 2, the same groove at the place where the white striae of the auditory nerve emerge from it to cross the

floor of the ventricle; 3, inferior peduncle or restiform body; 4, posterior pyramid; above this the calamus scriptorius; 5, superior peduncle or processus a cerebello ad cerebrum; on the right side the dissection shows the superior and inferior peduncles crossing each other as they pass into the white centre of the cerebellum; 6, fillet to the side of the crura cerebri; 7, lateral grooves of the crura cerebri; 8, corpora quadrigemina.

The anterior surface or *floor* of the fourth ventricle is formed by the back of the medulla oblongata and pons Varolii. It is shaped like a

lozenge, truncated at its upper part. Below, it is bounded by the diverging posterior pyramids and restiform bodies, surmounted by the ligula.

The portion below the auditory striæ has been already described. Just above the striæ the eminentia teres forms a convex prominence on each side of the median furrow. To its outer side is a depression, *fovea anterior*, and above this, near the upper part of the ventricle, is a collection of pigment beneath the surface of a shallow depression, which thus has a greyish tint, and is known as the *locus ceruleus*.

The *lining membrane* of the ventricle is continuous with that of the ventricles in the interior of the cerebrum, through the aqueduct of Sylvius, in which situation it is marked by delicate rugæ, oblique or longitudinal in direction. At the sides it is reflected from the medulla to the cerebellum, and extends for a considerable distance outwards, in the form of a pouch, between the flocculus and the seventh and eighth nerves. At the lower end of the ventricle, there is, as was ascertained by Magendie, a narrow orifice in the membrane by which the cavity communicates with the subarachnoid space.

Projecting into the fourth ventricle at each side, and passing from the point of the inferior vermiform process outwards and upwards to the outer border of the restiform bodies, are two small vascular processes, which have been named the *choroid plexuses* of the fourth ventricle.

**The grey matter in the floor of the fourth ventricle** has been in part described in connection with the medulla oblongata.

Opposite the middle of the fourth ventricle, beneath the eminentia teres on each side, lies the common nucleus of the *sixth and seventh (facial) nerves* (fig. 359, VII'). These nerves to reach it pass upwards as

Fig. 359.

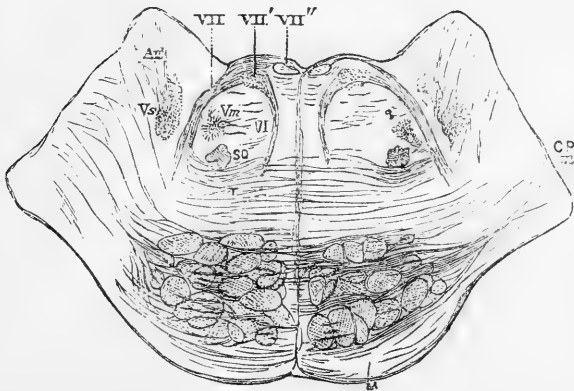


Fig. 359.—SECTION THROUGH THE PONS VAROLII, OPPOSITE MIDDLE OF EMINENTIA TERES.

VI, sixth nerve; VII, facial nerve; VII', common nucleus of seventh and sixth nerves; VII'', descending portion of seventh; vs, sensory nucleus of fifth nerve; vm, motor nucleus of fifth nerve (Lockhart Clarke); Au, auditory nucleus; so, superior olivary body; t, transverse fibres of "trapezium"; below these are seen the cut bundles of fibres from the anterior pyramids. C P. m, middle peduncle of cerebellum cut across. M, superficial transverse fibres.

well as backwards through the pons, the sixth having a tolerably straight course, and the seventh curving inwards, to reach the nucleus which is much nearer to the middle line than is the place of emergence of the nerve from the side of the medulla. The nucleus consists of a column of large multipolar nerve cells, and in it nearly all the fibres of the sixth nerve, and a considerable number of those of the facial end. Other fibres of the facial, however, pass above the upper extremity of the nucleus and then, turning down, descend on its inner side as a compact bundle (fig. 359, VII"), and opposite the lower part of the nucleus radiate outwards and downwards, some to the superior olivary body (s o) and others to an adjacent group of nerve cells from which also (higher up) the fibres of the motor root of the fifth nerve arise (v m).

The prominence outside the vagal nucleus in the lower part of the ventricle marks the position of the *inner nucleus* of the *auditory nerve* (fig. 355). It is triangular on section, and consists of oval and stellate nerve cells, smaller than those of the facial nucleus, and imbedded in a granular matrix. It is closely connected below with the nucleus of the glossopharyngeal nerve, and above, with that of the fifth nerve. The *outer nucleus*, a little higher up, is placed to the outer side of the inner nucleus, and consists of the grey network of cells and fibres into which the restiform and post-pyramidal nuclei have become transformed. (Lockhart Clarke.) The auditory nerve divides into two nearly equal parts; the posterior division curves round the restiform body, and arises chiefly from the inner nucleus: the anterior division passes through the substance of the inferior peduncle of the cerebellum, and arises from both nuclei; some fibres of the anterior division pass with the restiform body directly to the cerebellum, where they have been traced to the superior vermiform process. Both portions of the auditory nerve contain many nerve cells; in the inferior or outer portion they constitute a pyriform swelling at the anterior edge of the restiform body.

The *sensory portion of the fifth nerve* arises from a collection of grey substance beneath the outer part of the floor of the fourth ventricle in its middle third. It is derived chiefly from the continuation upwards of the grey tubercle of Rolando, which constitutes a grey network outside the facial nerve (fig. 359, v s). The cells are small and arranged in clusters separated by the fasciculi of origin of the nerve. In front of the nucleus a bundle of descending fibres passes down, mingled with much grey matter, to the lower part of the medulla oblongata. As the fibres of the fifth pass to the nucleus, they are intimately connected with the fibres of the anterior division of the auditory nerve. The fibres of the *motor* root of the fifth, have been traced by Lockhart Clarke to a collection of cells close to the outer angle of the fourth ventricle, on the inner side of the trunk of the fifth nerve. The prolongation downwards of this nucleus (fig. 359, V m), is situated near the superior olivary body, and with it some fibres of the facial are also connected.

The *superior olivary body* (fig. 359, s o) is a collection of small nerve cells, which lies above the outer part of the trapezium. In man it is very much smaller than the inferior olivary body, to which it does not present much resemblance. In some animals, however, it is larger, and presents a distinctly sinuous outline. From it some of the fibres of the trapezium arise.

From these nuclei, groups of nerve-cells may be traced for a considerable distance down the medulla. The relation of the auditory nuclei, and of the sensory nucleus of the fifth, to the grey matter of the medulla, has been already spoken of. In the position of the motor nucleus of the fifth, cells can be traced as far as the point of the calamus scriptorius. From the facial nucleus, a group of cells extends down to the inner side of the hypoglossal nucleus, to the lowest part of which it may be traced. This relation is of considerable interest in connection with the conjoined movements of the lips and tongue.

(For fuller details on the anatomy of the medulla oblongata and pons Varolii the reader is referred to Lockhart Clarke's paper in the Philosophical Transactions for 1868, to Meynert's article on the Brain in Stricker's Histology, to Henle's Handbuch der Anatomie, Bd. iii., Abth. 2, and to Kölliker's Handbuch der Gewebelehre, 5th ed.)

#### THE CEREBELLUM.

The *Cerebellum hinder brain*, consists of a *body* and of three pairs of *crura* or *peduncles*, by which it is connected with the rest of the cerebro-spinal axis.

The cerebellum is covered with grey cortical substance, rather darker than that of the cerebrum. Its greatest diameter is transverse, and extends to about three and a half or four inches: its width from before backwards is about two or two and a half inches; and its greatest depth is about two inches, but it is much thinner round its outer border.

Fig. 360.—OUTLINE OF THE UPPER SURFACE OF THE CEREBELLUM. (Allen Thomson.)  $\frac{1}{2}$

At the upper part of the figure, the crura cerebri and parts behind them have been cut through and left in connection with the cerebellum.

III. the third pair of nerves lying upon the crura cerebri; *c r*, white matter or crust of the crura cerebri; *l n*, locus niger; *t*, tegmentum containing grey matter in the upper part of the crura; *a s*, aqueduct of Sylvius; *q*, corpora quadrigemina, the upper elevations divided; *s v*, superior vermiform process, some of the foremost folia, immediately behind *q*, form the central lobe (of Reil); *l q*, lobulus quadratus; *p s*, posterior superior lobe; *f h*, horizontal fissure; *p i*, posterior inferior lobe; *n*, the notch between the hemispheres.

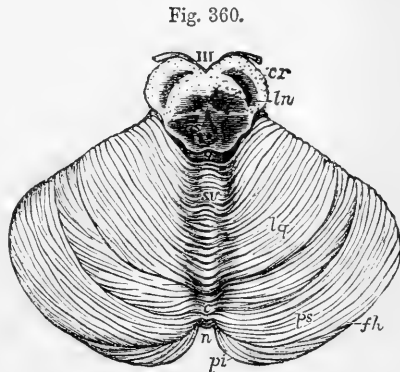


Fig. 360.

It consists of two lateral *hemispheres* joined together by a median portion called the *vermiform process*, which in man is distinguishable only as a small though well marked part below, named the *inferior* vermiform process, and a mere elevation above, called the *superior* vermiform process (fig. 360). In birds, and in animals lower in the scale, this middle part of the cerebellum alone exists; and in most mammals it forms a central lobe very distinct from the lateral portions.

The hemispheres are separated behind by a deep *notch* (fig. 360, *n*).

Superiorly, the median portion or upper vermiform process, though slightly elevated, is not marked off from the hemispheres, so that the general surface of the organ, which is here inclined and flattened on each side, is uninterrupted. Below, the hemispheres are convex, and are separated by a deep fossa, named the *vallecula*, which is continuous with the notch behind, and in which the inferior vermiform process (fig. 361, 2, 2; fig. 362, *cpu*) lies concealed in a great measure by the surrounding parts. Into this hollow the medulla oblongata is received in front, and the falx cerebelli behind.

The **peduncles** are named superior, middle, and inferior, and connect the hemispheres of the cerebellum with the brain, spinal cord, and with each other.

The *superior peduncles* (fig. 358, 5), *crura ad cerebrum* or *processus ad testes*, together with the valve of Vieussens, a lamina stretched between them, connect the cerebellum with the cerebrum.

The *inferior peduncles* (fig. 358, 3), *crura ad medullam*, are the upper extremities of the restiform bodies.

The *middle peduncles* (fig. 361, 8), or *crura ad pontem*, much the largest, are the lateral extremities of the transverse fibres of the pons Varolii. They connect together the two halves of the cerebellum inferiorly.

All these peduncles pass into the interior of the cerebellum at its fore part.

**Folia.**—The cerebellum, at the surface, and for some depth, consists of numerous nearly parallel laminae or folia, which are composed of grey

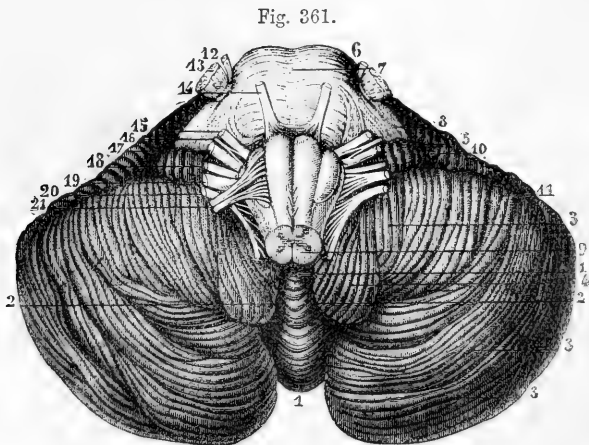


Fig. 361.—INFERIOR SURFACE OF THE CEREBELLUM WITH THE PONS VAROLII AND MEDULLA OBLONGATA (from Sappey after Hirschfeld and Leveillé).  $\frac{2}{3}$

1, placed in the notch between the cerebellar hemispheres, is below the inferior vermiform process; 2, 2, median depression or vallecula; 3, 3, 3, the biventral, slender, and posterior inferior lobules of the hemisphere; 4, the amygdala; 5, flocculus or sub-peduncular lobule; 6, pons Varolii; 7, its median groove; 8, middle peduncle of the cerebellum; 9, medulla oblongata; 10, 11, anterior part of the great horizontal fissure; 12, 13, smaller and greater roots of the fifth pair of nerves; 14, sixth pair; 15, facial nerve; 16, pars intermedia; 17, auditory nerve; 18, glosso-pharyngeal; 19, pneumogastric; 20, spinal accessory; 21, hypoglossal nerve.



and white matter, and might be compared with the gyri of the cerebrum, but are smaller and without convolution. These laminae are separated by slightly-curved grooves or sulci of different depths.

**Fissures.**—One principal fissure, or sulcus, named the *great horizontal fissure* (fig. 360, *f h*), divides the cerebellum into an upper and a lower portion. It begins in front at the entrance of the middle peduncles, and passes horizontally backwards round the outer border of the hemispheres. From this primary fissure, numerous others proceed on both the upper and under surfaces, forming nearly parallel curves, having their concavities turned forwards, and separating the folia from each other. All these furrows do not go entirely round the hemisphere, for many of them coalesce one with another; and some of the smaller furrows have even an oblique course between the others. Moreover, on opening the larger fissures, many of the folia are seen to lie concealed within them, and do not reach the surface of the cerebellum.

**Lobes.**—Certain fissures, which are deeper than the rest, and constant in their position, have been described as separating the cerebellum into lobes, which are named as follows.

The *central lobe*, situated on the upper surface (fig. 360, 9), consists of about eight folia, immediately adjoining the anterior concave border. The *superior and anterior lobe*, sometimes called *quadrate* (l. q.), and the *superior and posterior lobe* (p. s.), are placed between the central lobe and the great horizontal fissure. On the under surface (fig. 362) are seen

Fig. 362.

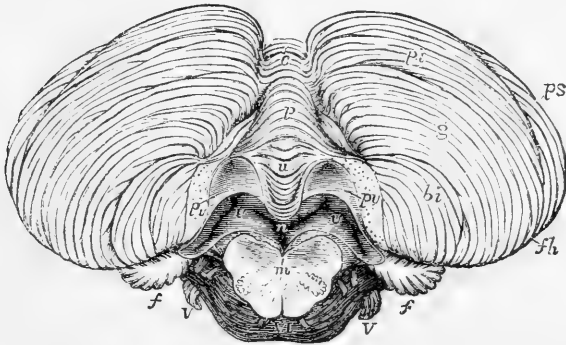


Fig. 362.—INFERIOR SURFACE OF THE CEREBELLUM WITH THE POSTERIOR MEDULLARY VELUM (Allen Thomson after Reil and Reichert, and from nature).  $\frac{2}{3}$

The medulla oblongata has been in great part removed by a cut passing through it near the pons Varolii; the two amygdaloid lobules have also been removed, and the medulla and pons Varolii pulled downwards in order to bring into view the posterior medullary velum.

*p s*, posterior superior lobe of the cerebellum; *f h*, horizontal fissure; *p i*, posterior inferior lobe; *g*, lobulus gracilis; *b i*, biventral lobe; *c*, placed on the folia which pass across between the hemispheres of opposite sides; *p*, pyramid; *u*, uvula; *n*, placed in the fourth ventricle immediately below the nodule; *p v*, on each side, placed on the cut surface where the amygdalæ have been removed, points by a line to the posterior medullary velum; *v*, *v*, cavity of the fourth ventricle within the borders of the velum and behind the inferior cerebellar peduncles; the cavity extends on each side into the pedicle of the flocculus; *f*; *m*, section of the medulla oblongata, in which the posterior opening of the olivary capsules of grey matter is shown; VI, sixth nerves; V, roots of the fifth nerves, and above them, the facial and auditory roots.

successively the *inferior posterior* lobe, the *slender* lobe, the *biventral* lobe, the *amygdala* (fig. 361, 4), and the *subpeduncular lobe* or *flocculus*. This last-named lobe projects behind and below the middle peduncle of the cerebellum. It is connected by a slender pedicle of white fibres to the rest of the hemisphere; but its exposed surface is grey, and is subdivided into five or six small laminae.

**Vallecula.**—Within the vallecula (fig. 362), or on its borders, the following parts are seen.

Commencing from behind, a conical and laminated projection named the *pyramid* (*p*), is first met with. In front of that is another smaller projection, called the *uvula* (*u*), which is placed between the two rounded lobes at the sides of the vallecula, named the *amygdala* (removed at *p*, *v*); these terms having been suggested by a comparison with the parts so named in the throat. Between the uvula and amygdalæ on each side, but concealed from view, is extended a ridge of grey matter indented on the surface, and named the *furrowed band*. Still further forward is the anterior pointed termination of the inferior vermiform process, named the *nodule* (above *n*), which projects into the fourth ventricle, and has been named the *laminated tubercle* (Malacarne). On each side of the nodule is a thin white lamella of a semilunar form, which is attached by its posterior convex border, and is free and concave in front (*p v*). The outer ends of these lamellæ are attached to the flocculi, and the inner ends to the nodule, and to each other in front of that projection. The two lamellæ together constitute the *posterior medullary velum*, which has been compared with the valve of Vieussens,—the one being attached to the superior extremity and the other to the inferior extremity of the middle or vermiform portion of the cerebellum. This posterior velum is covered in and concealed by the amygdalæ, and cannot be properly seen until those lobules have been turned aside or removed, as in the figure (see also fig. 384).

**INTERNAL STRUCTURE.**—The central part is composed of white matter, which sends out spreading and gradually thinning layers into the interior of all the laminae, larger and smaller, of the grey substance which form a continuous covering on the surface. In consequence of this arrangement of the white and grey substances, sections of the cerebellum crossing the laminae, and dividing the grey and white substance together, present a beautifully foliated or arborescent appear-

Fig. 363.

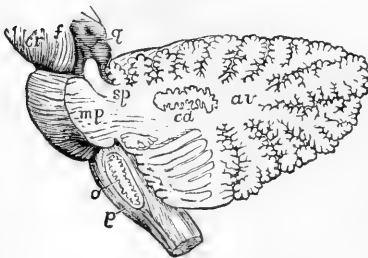


Fig. 363.—OUTLINE SKETCH OF A VERTICAL SECTION OF THE CEREBELLUM TO SHOW THE CORPUS DENTATUM IN ITS MEDULLARY STEM. (Allen Thomson.)  $\frac{2}{3}$

The section has been carried through the left lateral part of the pons so as to divide the superior peduncle and pass nearly through the middle of the left cerebellar hemisphere. The olivary body has also been divided longitudinally so as to expose in section its corpus dentatum.

*cr*, crus cerebri; *f*, fillet; *g*, corpora quadrigemina; *sp*, superior peduncle of the cerebellum divided; *mp*, middle

peduncle or lateral part of the pons Varolii, with fibres passing from it into the white stem; *av*, continuation of the white stem radiating towards the arbor vitæ of the folia; *cd*, corpus dentatum; *o*, olivary body with its corpus dentatum; *p*, anterior pyramid.

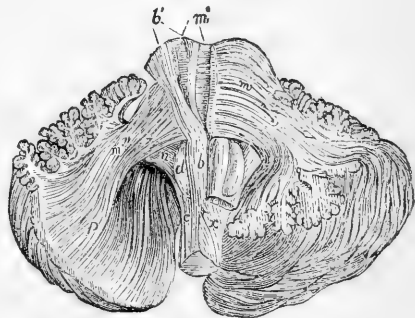
ance, named *arbor vite* (*a v*, fig. 363, 384). This appearance is seen in any vertical section, but it is most perfect in that which passes through the median plane, where the relative quantity of the central white matter is small. The foliations are arranged somewhat pinnately, the section of each primary lamina having those of secondary laminae clustered round it like leaflets on a stalk.

In the lateral hemispheres, where the peduncles enter, the white matter is more abundant; and, if a section be made through either hemisphere half way between its centre and the middle of the vermiform process, it will display a nucleus of grey matter, which is named the **corpus dentatum** of the cerebellum (*c d*). This structure, very similar to that already described in the olivary body of the medulla oblongata, presents the appearance of a waved line of compact yellowish brown matter, surrounded by white substance and containing whitish matter within. This line is interrupted at its upper and inner part. In whatever direction the section is carried through the corpus dentatum, this waved line is seen, so that the dentate body may be described as consisting of a plicated pouch or capsule of grey substance open at one part and inclosing white matter in its interior, like the corpus dentatum of the olivary body. White fibres may be traced from it to the superior peduncles of the cerebellum and to the valve of Vieussens.

Fig. 364.—VIEW OF A DISSECTION OF THE FIBRES OF THE MEDULLA OBLONGATA AND PONS VAROLII (from Arnold).  $\frac{3}{8}$

*b*, the anterior pyramid; *b'*, its fibres traced upwards through the pons Varolii; *c*, olivary column; *d*, olivary body; *m*, superficial transverse fibres of the pons on its left side; *m'*, the deeper transverse fibres of the right side; *m''*, the prolongation of these fibres as middle peduncle of the cerebellum; *p*, *q*, their continuation into the laminae and folia of the cerebellum; *n*, inferior peduncle; *x*, the decussating part of the left lateral column crossing to the right anterior pyramid.

Fig. 364.



The fibres in the primary lamellæ can be traced continuously from the peduncles of the cerebellum. Upon these central plates are laid other *collateral lamellæ*, which are not connected with the fibres proceeding from the middle of the cerebellum, but merely pass from one folium to another.

The *grey* matter is not uniform throughout its whole thickness, but is composed of two or more layers differing in colour and other characters;—resembling, in this respect, the cortical substance of the posterior convolutions of the cerebrum.

The fibres composing the peduncles of the cerebellum are arranged in its interior in the following manner. The middle peduncles, which are the most superficial, enter the lateral parts of the cerebellum; they may be traced into the folia of these parts, and form a large part of each hemisphere (fig. 364, *m''*). The inferior peduncles (fig. 365, *n q*) pass upwards into the middle part of the cerebellum, in the folia of which they are distributed, especially in those of the upper surface. The superior peduncles (*v*; see also fig. 358), which are placed nearest to the middle line, are principally connected with the folia of the inferior vermi-

form process; but a considerable number of their fibres pass into or issue from the grey capsule of the corpus dentatum.

Fig. 365.

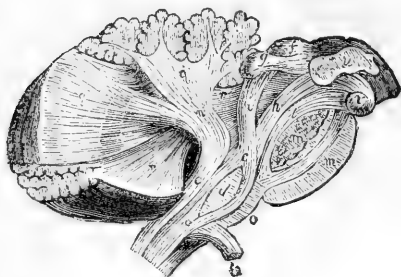


Fig. 365.—THE COLUMNS OF THE MEDULLA OBLONGATA TRACED UPWARDS INTO THE CEREBELLUM AND CEREBRUM (from Arnold).  $\frac{2}{3}$

*a*, part of the anterior column which ascends in the olivary column; *b*, decussating portion of the lateral column forming the pyramid and turn down; *c*, olivary fasciculus ascending deeply through the pons; *d*, olivary body; *e*, restiform body; *f*, *g*, corpora quadrigemina; *h*, *i*, the fillet; *h*, the part which ascends to the cerebral peduncle; *i*, the part passing up to the corpora quadrigemina; *m*, *m*, the transverse fibres of the pons divided; *n*, inferior peduncle of the cerebellum;

*o*, septal fibres of the medulla oblongata; *q*, fibres of the inferior peduncle continued into the laminae of the cerebellum; *r*, *r*, superior peduncle; *t*, fasciculus teres; *u*, thalamus; *v* corpus albicans.

A very different account from that which has generally been received of the course and relations of the tracts of nervous substance of the cerebellum has recently been put forward by Luys, but has not yet received corroboration. According to the statement of this author, all the fibres of the cerebellar peduncles arise from the interior of the corpora dentata; the cells of those centres receive externally fibres from the laminated periphery of the cerebellum, and internally give origin to the peduncular fibres; the fibres of the inferior peduncles of opposite sides cross the middle line and terminate in the interior of the olivary nuclei; and the fibres of the superior peduncles, likewise decussating in the mesial plane before quitting the cerebellum, terminate in a grey centre of the interior of the tegmentum of the crus cerebri, and thus the fibres of the cerebellum form a separate system indirectly connected with the fibres of the rest of the cerebro-spinal axis. (Luys, in Journ. de l'Anat. et de Physiol., 1864, p. 225.)

**MINUTE STRUCTURE.**—The cortical grey substance is composed of an external clear grey layer, an inner greyish-red “granule” layer, and between the two a single layer of large cells with long processes, termed the corpuscles of Purkinje. Outside all is the layer of fibres and vessels of the pia mater.

The **external layer** (fig. 366, *b*) consists of a delicate matrix, probably of the nature of connective tissue, containing cells and fibres. Most of the fibres have a direction at right angles to the surface; the greater part of them are the processes of the large nerve cells which lie between the two layers. Others are fine connective tissue fibres, analagous to the sustentacular fibres of the retina, and connected by a broad base with the pia-matral covering. The corpuscles are granule-like bodies, some very small, and connected probably with the connective tissue matrix, others larger and surrounded by protoplasm from which processes extend. Some of the corpuscles are connected with the processes of the larger cells.\* (See fig. 367.) The inner part of this layer, con-

\* A connection described by Lockhart Clarke (Proc. Roy. Soc., 1863), and subsequently by Obersteiner, and recently confirmed (independently) by Mr. H. R. O. Sankey, student of University College.

tiguous with the corpuscles of Purkinje, contains some nerve fibres parallel to the surface.

Fig. 366.—STRUCTURE OF CORTEX OF CEREBELLUM (from a drawing by Mr. H. R. O. Sankey).

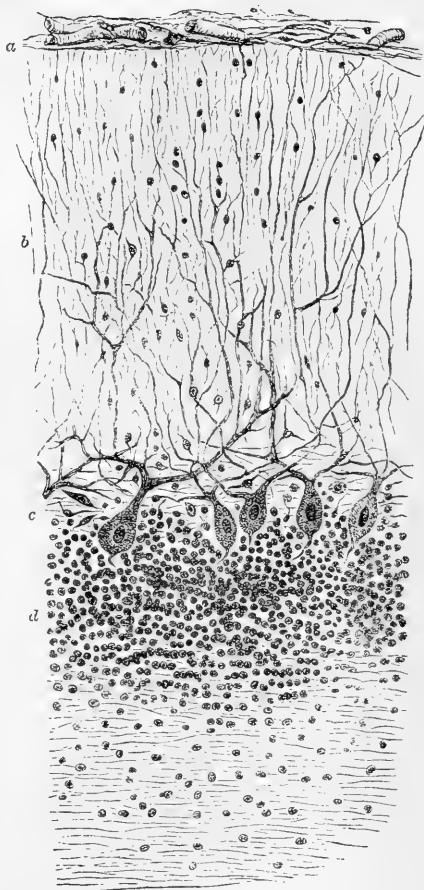
Fig. 366.

*a*, pia mater; *b*, external layer; *c*, layer of corpuscles of Purkinje; *d*, inner or granule layer; *e*, medullary centre.

The **inner layer**, "granule layer," (fig. 366 *d*), next the medullary centre, consists of granule-like corpuscles which lie in dense groups, in a gelatinous matrix, containing a plexus of fine nerve fibres. The corpuscles vary in size from  $\frac{1}{4000}$ th to the  $\frac{1}{2500}$ th of an inch, the larger being less densely scattered around the corpuscles of Purkinje. Some are round, others angular, and possess a protoplasmic envelope with processes, supposed to be connected with the plexus of fine nerve fibres, among which they lie.

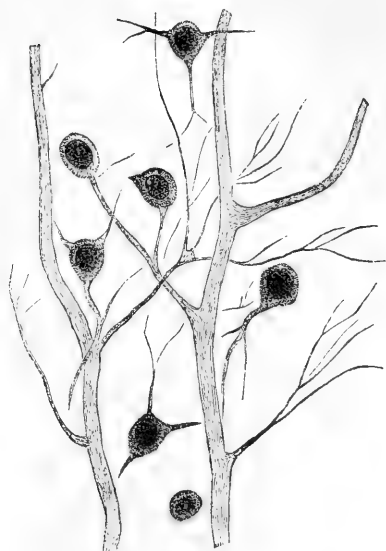
The *cells of Purkinje* (*c*) lie in a single layer, between the outer and inner layers of the cortex. Their distance apart is greater on the sides than at the apex of the convolution. Some are irregular in shape, but many are flask-shaped, their long axis being at right angles to the surface; the diameter of the larger cells is the  $\frac{1}{800}$ th to  $\frac{1}{1000}$ th of an inch; each contains a spherical nucleolated nucleus. Processes extend from them into both the outer and inner layers: the outer process is much the larger, and is granular or finely striated in texture. It divides usually near the cell, and its branches, either at once or after a short horizontal course, pass towards the surface, dividing repeatedly. Some are apparently connected with the angular corpuscles of this layer, but most can be traced almost to the outer surface, and are there lost. They have been said to turn back and end in the granule layer. The inner process is fine, undivided, and passes into the granule layer. It is supposed to be continuous with the axis cylinder of a nerve fibre.

The **medullary centre**, consists of nerve fibres arranged in parallel or interlacing bundles, which pass off on each side and form the central



stem of the laminæ, whence they radiate into the cortex. They disappear in the granule layer, and are commonly believed to be continuous with

Fig. 367.



the outer processes of the corpuscles of Purkinje, but some consider that they arise, in part at least, by the union of the fine fibres of the plexus in which the granules of the outer layer are embedded.

Fig. 367.—FROM THE OUTER LAYER OF THE CEREBELLUM (from a drawing by Mr. H. R. O. Sankey). PROCESSES OF THE CORPUSCLES OF PURKINJE, CONNECTED, BY THEIR FINER BRANCHES, WITH THE CORPUSCLES OF THE OUTER LAYER. (Highly magnified.)

The structure of the *corpus dentatum* resembles that of the olivary body. Stellate cells,  $\frac{1}{1500}$ th to  $\frac{1}{2500}$ th inch in size, lie in several layers, among a plexus of finer nerve fibres, passing in various directions, but chiefly from without inwards.

## THE CEREBRUM.

The *cerebrum*, or brain proper, constitutes the highest and much the largest portion of the encephalon. It consists of the following parts, viz., the peduncular masses of the crura cerebri and processus a cerebello ad cerebrum; the series of eminences or cerebral centres or ganglia concealed from view, named corpora quadrigemina, optic thalami and corpora striata; the cerebral hemispheres, which are by far the most bulky part of the cerebrum; various commissural structures including the corpus callosum and fornix; and lastly some smaller structures, viz., the pineal and the pituitary bodies, and the olfactory bulbs.

### EXTERIOR OF THE CEREBRUM.

The *cerebral hemispheres* together form an ovoid mass, flattened on its under side, and placed in the cranium with its smaller end forwards, its greatest width being opposite to the parietal eminences. They are separated in the greater part of their extent by the great longitudinal fissure.

Each cerebral hemisphere has an outer, convex surface, in contact with the vault of the cranium; an inner or median, flat surface, which forms one side of the longitudinal fissure; and an irregular under surface, in which is a deep cleft, the fissure of Sylvius. In front of this

cleft the under surface rests in the anterior fossa of the base of the skull, and behind it in the middle fossa, and further back still, on the tentorium cerebelli.

The *great longitudinal fissure* (fig. 372, *ll*), seen upon the upper surface of the brain, extends from before backwards throughout its whole length in the median plane, and thus separates the cerebrum, as already stated, into a right and left hemisphere. On opening this fissure, it is seen, both before and behind, to pass quite through to the base of the cerebrum; but in the middle it is interrupted by a large transverse mass of white substance, named the *corpus callosum*, which connects the two hemispheres together. While the brain is in its natural situation, this fissure is occupied by a vertical process of the dura mater—the *falx cerebri*—which dips down between the two hemispheres, not quite reaching to the corpus callosum.

THE SURFACE OF THE HEMISPHERES is composed of grey matter, and is moulded into numerous smooth and tortuous eminences, named *convolutions* or *gyri*, which are marked off from each other by deep furrows, called *sulci*, or *anfractuosities*.

**Lobes of the cerebrum.**—These are five in number, termed respectively, *frontal*, *parietal*, *occipital*, *temporo-sphenoidal* and *central*. The three former are in contact with the bones after which they are named, though their limits do not correspond to those of the bones; the fourth occupies the middle or temporo-sphenoidal fossa in the base of the skull, while the central lobe or island of Reil lies within the fissure of Sylvius. The divisions between these lobes are marked by certain conspicuous fissures and by artificial lines connecting those fissures. Their real limits will be better understood when the convolutions and fissures have been described.

Formerly it was customary to divide each hemisphere into three lobes, an anterior, in front of the fissure of Sylvius, a middle, behind that fissure and resting in the temporo-sphenoidal fossa, and a posterior lobe behind it, resting on the tentorium cerebelli. The division into five lobes, now generally adopted, was first made by Gratiolet.

**The Convolution**s are covered closely throughout by the vascular investing membrane, the pia mater, which sends processes down to the bottom of the sulci between them, while the serous covering, the arachnoid membrane, passing from one convolution to another, over their summits and without dipping between them. In general, the depth of a convolution exceeds its thickness; and its thickness, near the summit, is somewhat greater than through its base.

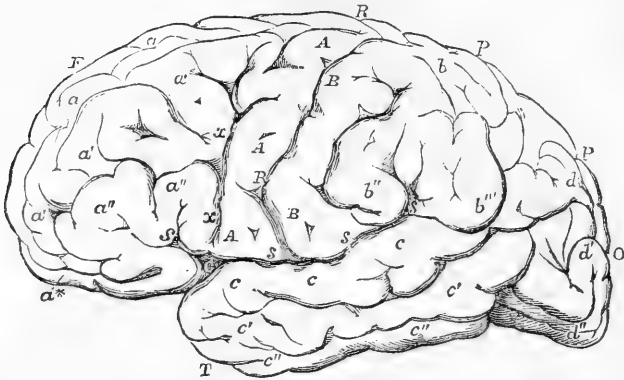
Since the external grey or cortical substance is continuous over the whole surface of the cerebral hemispheres, being found alike within the sulci and upon the gyri, a far greater extent of grey matter is thus exposed to the vascular surface of the pia mater with a given size of the brain, than could have been the case had the hemispheres been plain and destitute of convolutions.

**The Fissures** between the convolutions are generally from half an inch to an inch in depth, but vary in this respect both in different brains and in different parts of the same brain. In all brains certain primary fissures can be recognised, on which the division into lobes has been founded, and these it will be convenient to describe first.

THE PRIMARY OR INTERLOBAR FISSURES are three in number, the fissure of Sylvius, the fissure of Rolando (or central sulcus), and the parieto-occipital fissure.

The **fissure of Sylvius** (see figs. 375, s, and 370) commences on

Fig. 368.

Fig. 368. --OUTLINE OF THE CEREBRUM AS SEEN FROM THE LEFT SIDE.  $\frac{1}{2}$ 

F, frontal lobe; P, parietal lobe; T, temporal lobe; O, occipital lobe; R, R, fissure of Rolando; s, s, fissure of Sylvius, posterior division; s, its anterior division; C, at the junction of the two, marks the place of the central lobe or convolutions of the island of Reil; p, the place of the vertical or occipital fissure; a, a', a'', superior, middle, and inferior frontal convolutions; a\*, orbital convolutions; x, x, transverse frontal fissure; A, ascending frontal convolution; B, ascending parietal convolution; b, superior parietal lobule; b'', supra marginal convolution; b'', angular convolution; c, c', c'', upper, middle and lower temporo-sphenoidal convolutions; d, d', d'', upper, middle and lower occipital convolutions.

Fig. 369.

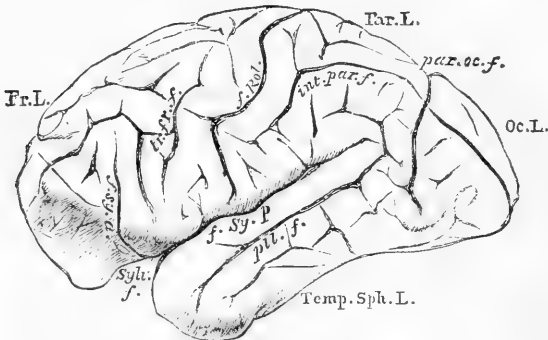


Fig. 369.—FIGURE OF BRAIN OF CHIMPANZEE (from Gratiolet).

Fr. L., frontal lobe; Par. l., parietal lobe; Oc. L., occipital lobe; Temp. Sph. L., temporo-sphenoidal lobe; Sylv. f., fissure of Sylvius; f. Sy. a., f. Sy. p., its anterior and posterior limbs; f. Rol., fissure of Rolando; tr. fr. f., transverse frontal fissure; int. par. f., intra-parietal fissure; par. oc. f., parieto-occipital fissure.



the under surface of the brain, close to the anterior perforated spot, and passes transversely outwards to the lateral surface of the hemisphere, where it divides into a short anterior ascending limb, and a longer posterior horizontal limb. The fissure in the base is a deep cleft, of which the posterior lip projects over the anterior. This part differs from other fissures in being due to a fold of the whole brain in its development, the others being due merely to duplications of the cortical layer. Within the fissure of Sylvius is the isolated group of convolutions of the island of Reil or "central lobe."

The anterior or ascending limb (*f. Sy. a.*), about an inch in length, runs upwards and forwards into the frontal lobe, the lowest convolution of which curves round it.

The posterior or horizontal limb (*f. Sy. p.*) passes backwards, ascend-

Fig. 370.

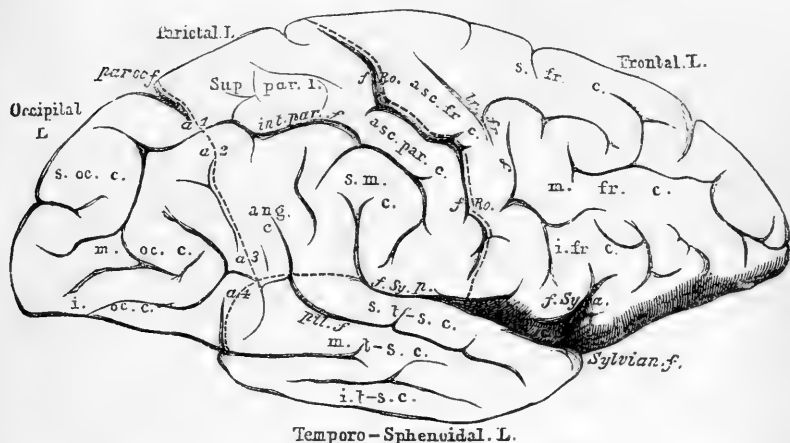


Fig. 370.—CONVOLUTIONS OF OUTER SURFACE OF RIGHT HEMISPHERE. FROM A SIMPLY CONVOLUTED EUROPEAN BRAIN. About  $\frac{1}{2}$

The convolutions are, for the most part, indicated by Roman, the fissures by italic letters. The dotted lines indicate the divisions into lobes, the names of which are given in full at the margin of the hemisphere. *f. Ro.*, fissure of Rolando; *par.-oc. f.*, parieto-occipital fissure; *f. Sy. a.*, anterior limb, and *f. Sy. p.*, posterior limb, of the fissure of Sylvius; *s. fr. c.*, *m. fr. c.*, *i. fr. c.*, superior, middle, and inferior frontal convolutions; *asc. fr. c.*, ascending ditto; *asc. par. c.*, ascending parietal convolution; *Sup. par. l.*, superior parietal lobules; *s. m. c.*, supra-marginal convolution; *ang. c.*, angular convolution; *int. par. f.*, intra-parietal fissure; *s. oc. c.*, *m. oc. c.*, *i. oc. c.*, superior, middle, and inferior occipital convolutions; *s. t.-s. c.*, *m. t.-s. c.*, *i. t.-s. c.*, superior, middle and inferior temporo-sphenoidal convolutions; *pll. f.*, parallel fissure; *a<sup>1</sup>*, *a<sup>2</sup>*, *a<sup>3</sup>*, *a<sup>4</sup>*, first, second, third and fourth annectant convolutions; *c. L.*, within the fissure of Sylvius, central lobe, or Island of Reil.

ing slightly, through the middle third of the hemisphere. Its extremity is usually bent vertically upwards. It separates the parietal lobe above, from the temporo-sphenoidal lobe below it.

The group of convolutions, which occupy the angle between the two divisions of the fissure of Sylvius, has been collectively termed the "*operculum.*"

The **fissure of Rolando** (fig. 370, *f. Ro.*) or *Central Sulcus*, extends

across the lateral convex surface of the hemisphere. It commences above, behind the vertex, near the great longitudinal fissure, and passes downwards and forwards to end close behind, but above, the bifurcation of the fissure of Sylvius, into the posterior limb of which it has been seen, though very rarely, to open. Its position and direction are such that the fissures of the two sides, seen from above, form a V-shaped line, open in front. It is rarely interrupted in its course, and is very uniform in man and most of the primates. It appears early in development, about the fifth month.

This fissure separates the frontal from the parietal lobe, and its position on the surface of the hemisphere varies with the degree of development of the frontal lobe. The parallel convolutions which it separates are named respectively the ascending or transverse frontal and ascending parietal convolutions.

The **Parieto-occipital fissure**, or perpendicular fissure (fig. 370, *par. cc. f.*), is best marked on the median surface of the hemisphere, where it appears as a deep cleft extending downwards and a little forwards from the margin of this surface to near the posterior extremity of the corpus callosum. On the convex surface it is continued transversely outwards for a variable distance, generally about an inch, as the *external parieto-occipital fissure*. This fissure is taken as the division between the parietal and occipital lobe. The size of its external portion depends (inversely) on the size of the convolution which curves round its outer extremity and connects the parietal with the occipital lobe. In consequence of the development in man of this and similar connecting convolutions, this fissure is much less marked in the human brain than in that of the higher apes. It appears about the fourth or fifth month.

**OUTER SURFACE OF THE HEMISPHERES.—LOBES.**—These are determined chiefly by fissures on the outer, which are for the most part absent on the median surface. It is convenient therefore to consider them in relation to the outer surface only, and subsequently to describe the median surface as a whole.

The **Frontal Lobe** (fig. 370) is the anterior portion of the brain in front of the fissure of Sylvius at the base, and of the fissure of Rolando on the outer side. On the median surface there is no corresponding demarcation. The inferior surface of the frontal lobe, which is in contact with the orbital plate, is called the *orbital surface*; the upper arched aspect is the *frontal surface*.

**FRONTAL SURFACE.**—The *convolutions* are four in number, three antero-posterior, one above the other, and one transverse behind them.

The *ascending or transverse frontal convolution* (asc. fr. c.) is placed in front of the fissure of Rolando, which it thus bounds. Below, it commences just above and behind the bifurcation of the fissure of Sylvius, and thence courses upwards and backwards to the margin of the great longitudinal fissure. Commonly above, and almost invariably below, it is connected with the convolution (ascending parietal) behind the fissure of Rolando, and thus that fissure is isolated.

The portion of the frontal surface anterior to this convolution is occupied by complex convolutions running more or less in an antero-posterior direction, and usually to be distinguished into three, an upper, middle, and lower. These may or may not arise superficially from the ascending frontal convolution; they are usually in their course connected one with another by secondary convolutions.

The *superior*, or *first frontal convolution* (s. fr. c.), at the margin of the great longitudinal fissure, commonly commences superficially at the upper end of the ascending frontal convolution, and extends to the anterior extremity of the hemisphere, where, tapering, it passes over to the orbital surface. The inner aspect of this convolution appears on the median surface of the hemisphere.

The *middle* or *second frontal convolution* (m. fr. c.) arises deeply or superficially from the ascending frontal below the last, and runs thence to the anterior extremity of the hemisphere. It is usually broad, and often much subdivided.

The *inferior* or *third frontal convolution* (i. fr. c.) forms the lower and outer portion of the frontal lobe. It arises superficially, or sometimes deeply, from the lower extremity of the ascending convolution, just above the bifurcation of the fissure of Sylvius, arches round the ascending limb of that fissure, and extends to the anterior extremity of the hemisphere.

*Fissures of the frontal surface.*—The *transverse frontal fissure*, “præcentral sulcus,” lies in front of the ascending frontal convolution, and parallel to the fissure of Rolando. Its extent depends on the mode of origin of the superior, middle, and inferior frontal convolutions from the ascending frontal. When these arise superficially the fissure is interrupted, and may be inconspicuous; when the inferior frontal convolution arises deeply, this fissure is continuous with the fissure of Sylvius, of which it has, in consequence, been regarded as the ascending limb.

Two *antero-posterior fissures*, the *superior* and *inferior frontal* separate the corresponding convolutions from the middle frontal: they are often very irregular, being bridged over by secondary convolutions.

*ORBITAL SURFACE* (fig. 375) presents two *fissures*; the *olfactory sulcus*, straight, parallel with the great longitudinal fissure, and lodging the olfactory bulbs.

The *orbital sulcus*, irregular, often triradiate, lying in the centre of the lobule.

*Convolution.*—Between the olfactory sulcus and the longitudinal fissure is the *straight convolution*, continuous, at its anterior extremity, with the superior frontal.

Three convolutions are sometimes described as lying around the orbital sulcus, and named according to their position, the *inner*, the *anterior*, and the *outer* or posterior orbital convolutions.

The **Parietal Lobe** (fig. 370) lies behind the frontal and in front of the occipital lobe. Below it is the temporo-sphenoidal lobe. It is bounded in front by the fissure of Rolando, behind by the parieto-occipital fissure, and by an arbitrary continuation of the line of that fissure to the outer boundary. Internally it is bounded by the great longitudinal fissure, and externally by the posterior limb of the fissure of Sylvius as far as this preserves its horizontal direction, and then by a line continuing that direction to the posterior boundary.

*Fissure.* The *intra-parietal fissure* (fig. 370, *int. par. f.*) arches through the parietal lobe, commencing in its anterior inferior angle, where it is sometimes, though rarely, continuous with the fissure of Sylvius. It ascends at first parallel to the fissure of Rolando, and then turns backwards horizontally to the back of the lobe, extending nearly to the termination of the external portion of the parieto-occipital fissure, past which

it is often continued into the occipital lobe. Its horizontal portion divides the parietal lobe into two portions, superior and inferior parietal lobules, and it may be bridged across by a secondary convolution connecting those lobules.

Fig. 371.

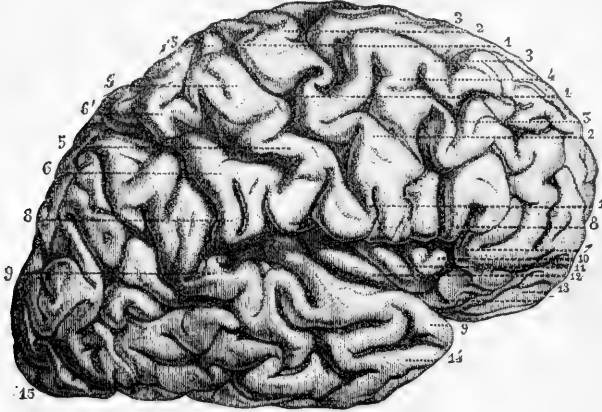


Fig. 371.—LATERAL VIEW OF THE RIGHT CEREBRAL HEMISPHERE (from Sappey after Foville).  $\frac{1}{2}$

1, fissure of Rolando; 2, ascending frontal convolution; 3, superior, 3', middle, and 7, inferior frontal convolutions; 4, a bridging convolution between the superior and middle frontal convolutions; 5, ascending parietal convolution; 6, 8, supra-marginal convolution (8 in front points to part of the inferior frontal convolution); 9, 9, superior temporo-sphenoidal convolution; 10, 11, 12, convolutions of the island of Reil or central lobe; 13, orbital convolutions; 14, lower extremity of middle temporo-sphenoidal convolution; 15, occipital lobe.

*Convolutions.* The *ascending parietal* is the convolution which lies behind the fissure of Rolando, and parallel to the ascending frontal convolution, with which it is usually continuous, both above and below, the connection below being much larger than that above. In its lower half the ascending parietal convolution lies in front of the commencement of the intra-parietal fissure. Above, it is continuous with the superior parietal lobule.

The *superior parietal lobule* (fig. 370) is that part of the parietal lobe which lies above the intra-parietal fissure, and behind the last described convolution. Its posterior limit is the boundary of the parietal lobe, the external parieto-occipital fissure, outside the extremity of which a narrow convolution usually connects this lobule with the occipital lobe, and is termed the first connecting or annectant convolution.

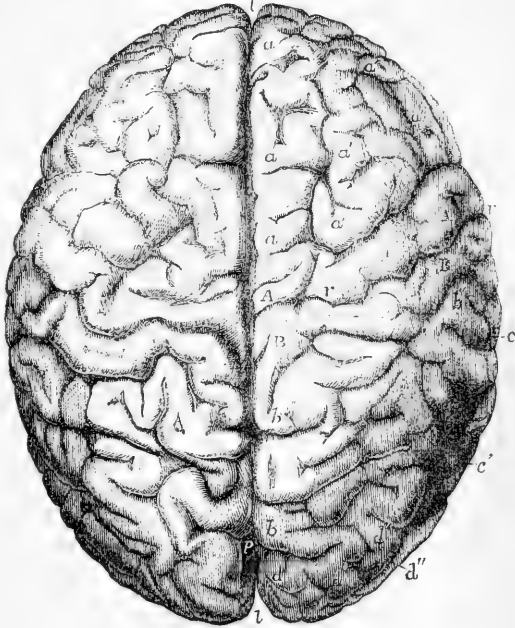
The *inferior parietal lobule* (fig. 370) lies behind the ascending and below the horizontal part of the intra-parietal fissure. It is divided somewhat artificially into two convolutions, a supramarginal gyrus, above and in front of the extremity of the Sylvius fissure, and an angular gyrus behind it.

The *supra-marginal convolution* (s. m. c.) lies behind the lower end of the intra-parietal sulcus, beneath which it is usually continuous with the ascending parietal convolution. It is bounded above by the same

fissure, and passes into the angular gyrus above the extremity of the fissure of Sylvius, except in the rare instances in which the Sylvian fissure is prolonged into the intra-parietal sulcus.

Fig. 372.—UPPER SURFACE OF THE BRAIN SHOWING THE CONVOLUTIONS (from R. Wagner).  $\frac{1}{2}$

Fig. 372.



This view was taken from the brain of a famous mathematician, Professor C. F. Gauss, who died in 1854, aged 78. It is selected as an example of a well-formed brain of the average size with fully developed convolutions.

*a*, superior or first frontal convolution; *a'*, second or middle frontal; *a''*, third or inferior frontal; *A*, *A*, ascending frontal convolution; *B*, *B*, ascending parietal convolution; *b*, superior parietal lobule; *b''*, inferior parietal lobule; *c*, first or upper temporo-sphenoidal convolution; *d*, first or upper occipital convolution; *d''*, second or middle; *d'''*, third or lower; *l*, *l*, the superior longitudinal fissure; *r*, the fissure of

Rolando; *p*, the external parieto-occipital fissure (which appears, in consequence of the position of the brain, nearer than it really is to the posterior extremity).

The *angular gyrus* (*ang. c.*) is bounded in front by the terminal ascending portion of the fissure of Sylvius, above by the intra-parietal sulcus, below it is continuous with the superior (and sometimes with the middle) temporo-sphenoidal convolution, and behind with the occipital lobe by means of one or two (second and third) annectant convolutions.

The **Occipital Lobe** (*fig. 370*) lies behind the parietal, and forms the posterior extremity of the hemisphere. Below, it is continuous with the temporo-sphenoidal lobe. It occupies the superior fossa of the occipital bone, and rests on the tentorium. Its limits are to a considerable extent artificial. In front it is bounded by the external parieto-occipital fissure, and by a line continuing the direction of the fissure across the annectant convolutions to meet the inferior boundary of the parietal lobe, and thence continued to the lower edge of this surface at the anterior edge of the tentorium.

Its *convolutions*, complex and ill-defined, are commonly described as three in number, *superior*, *middle*, and *inferior*. They are continuous with the convolutions of the parietal and temporo-sphenoidal lobes by the four *annectant* or *connecting convolutions*, of which the *first*, passing round the extremity, or in rare cases deeply across the bottom, of the external

parieto occipital fissure, connects the superior occipital convolution with the superior parietal lobule, the *second* unites the middle occipital and angular convolution, the *third* often connects the same convolutions, and also with them the middle temporo-sphenoidal, and the *fourth* connects the inferior occipital with the middle or inferior temporo-sphenoidal convolution.

*Fissures.*—The three occipital convolutions are separated by two fissures, the *superior and inferior occipital*, of which the superior is often continuous with the intra-parietal. Its lower part may have a more or less vertical direction, and has then been termed the transverse occipital.

The **Temporo-sphenoidal lobe** (fig. 370, &c.) is bounded in front and above by the commencement and posterior limb of the fissure of Sylvius. Behind, it is continuous with the occipital lobe. Three nearly parallel convolutions can usually be distinguished; a *superior* bounding below the posterior limb of the Sylvian fissure, and continuous behind with the angular convolution, a *middle* continuous with the angular gyrus, or middle occipital convolution, by the fourth annectant gyrus and an *inferior* continuous with the inferior occipital. These convolutions are separated by two *fissures*, of which the superior, from its relation to the Sylvian fissure has been termed the *parallel fissure*. The inferior is commonly interrupted by a secondary gyrus connecting the middle and inferior convolutions.

The **Central Lobe, or Island of Reil** (figs. 371, 10, 12; fig. 376, c), lies deeply within the fissure of Sylvius, being rarely visible except when the lips of that fissure are separated. It is a triangular eminence forming a sort of Delta between the two divisions of that fissure, and consists of about six short, straight convolutions (*gyri operati*) which radiate outwards from a point just external to the anterior perforated

Fig. 373.

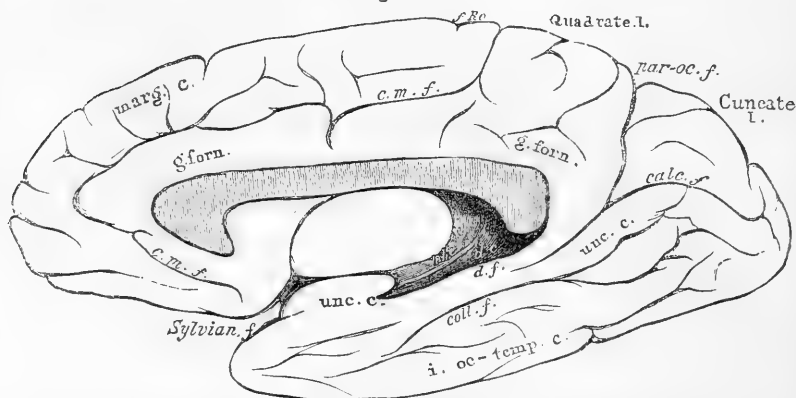


Fig. 373.—CONVOLUTIONS OF THE MEDIAN AND TENTORIAL SURFACES OF RIGHT HEMISPHERE. FROM A SIMPLY CONVOLUTED EUROPEAN BRAIN. ABOUT  $\frac{1}{2}$

Marg. c., marginal convolution; g. forn., gyrus fornicatus or convolution of the corpus callosum; unc. c., uncinate convolution; i. oc-temp. c., inferior occipito-temporal convolution; d. c., dentate convolution; f. Ro., depression corresponding to the upper extremity of the fissure of Rolando; par-oc. f., parieto-occipital fissure; calc. f., calcarine fissure; coll. f., collateral fissure; d. f., dentate fissure; t. h. tænia hippocampi.

spot. Its anterior convolution is continuous at the bottom of the limiting sulcus with the adjacent posterior orbital: its posterior convolution joins the temporo-sphenoidal lobe. Externally it is separated by a deep sulcus from the contiguous convolutions of the *operculum*, *i. e.*, the extremity of the ascending parietal, ascending frontal, and inferior frontal convolution. The island of Reil covers the extra-ventricular nucleus of the corpus striatum. It appears earlier than any other division of the cerebrum, both in the fœtus and in the animal series.

THE INTERNAL OR MEDIAN AND TENTORIAL SURFACE (fig. 373), as already said, does not present the same division into lobes as does the external surface.

**Fissures.**—The internal part of the *parieto-occipital fissure* is continuous, at the margin of the longitudinal fissure, with the external portion. Thence it extends downwards and forwards, presenting a slight curve with the convexity forwards, and blends with the calcarine fissure.

The *calcarine fissure* commences at the posterior extremity of the hemisphere, usually in a bifurcated manner, and extends forwards to terminate beneath the posterior extremity of the corpus callosum. It is joined by the *parieto-occipital fissure*.

The *calloso-marginal fissure* (*c m f*) commences beneath the anterior

Fig. 374.

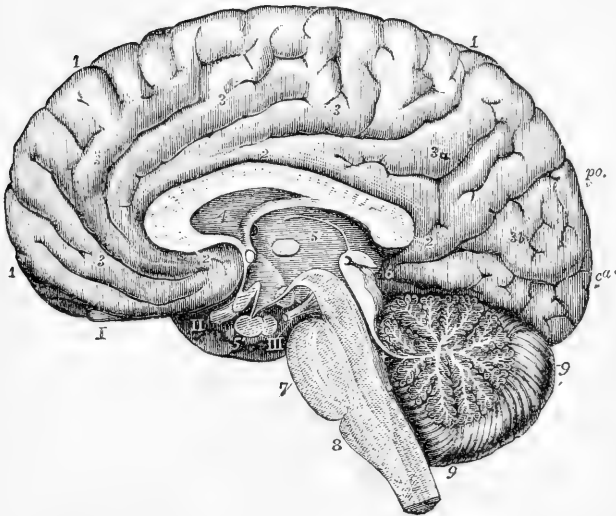


Fig. 374.—RIGHT HALF OF THE BRAIN DIVIDED BY A VERTICAL ANTERO-POSTERIOR SECTION (from various sources and from nature). (Allen Thomson.)  $\frac{1}{2}$

*po*, parieto-occipital fissure; *cc*, posterior extremity of calcarine fissure; I, 1, marginal convolution; 2, 2, gyrus fornicatus; 3, 3, 3, secondary convolutions passing between this and the preceding; 3*a*, quadrate lobule; 3*b*, cuneate lobule; 4, the fifth ventricle, and above it the divided corpus callosum; 5, the third ventricle (see fig. 384); 5', pituitary body; 6, corpora quadrigemina and pineal gland; +, the fourth ventricle; 7, pons Varolii; 8, medulla oblongata; 9, cerebellum I, the olfactory bulb; II, the right optic nerve, the commissure cut through; III, right third nerve.

extremity of the corpus callosum, and courses first forwards, then upwards, and then backwards, parallel with the edge of the longitudinal fissure, and finally turns upwards to end at this edge just behind the position of the upper extremity of the fissure of Rolando. It separates the marginal convolution from the convolution of the corpus callosum, hence its name.

**Convolution.**—*The marginal convolution* commences in front of the anterior perforated spot, and extends along the edge of the longitudinal fissure as far as the termination of the calloso-marginal fissure at the upper margin of this surface. Over this margin it is continuous with the superior frontal convolution, and its continuation (straight convolution) on the orbital surface. It is commonly broken up by secondary fissures, one of which often runs parallel to part of the calloso-marginal fissure. A secondary convolution not uncommonly connects it with the next gyrus.

*The convolution of the corpus callosum, gyrus fornicatus* (g. forn., fig. 373), commences near the anterior perforated spot, and, turning round the anterior extremity of the corpus callosum runs backwards along its upper surface, and then, bending down behind its posterior extremity, takes the name of the uncinate convolution. On its outer side is the calloso-marginal fissure as far as the latter extends.

*The quadrate lobule* (præcuneus), is a four-sided area lying between the internal part of the parieto-occipital fissure behind, and the termination of the calloso-marginal fissure in front. It is variously subdivided into small gyri, of which the highest is continuous with the superior parietal lobule, and the lowest forms part of the gyrus fornicatus.

*The cuneate lobule* (occipital lobule) is a wedge-shaped area lying between the internal parieto-occipital and the calcarine fissures.

**Occipito-temporal region.**—The convolutions of the lower part of the occipital lobe and the inner temporo-sphenoidal convolutions are continuous, and may be considered together as three in number.

*The superior occipito-temporal convolution* (*uncinate* or *hippocampal convolution*) extends from near the posterior extremity of the hemisphere to the anterior portion of the temporo-sphenoidal lobe, lying at first beneath the calcarine fissure, and then beneath the dentate fissure. Its anterior extremity is rounded into a hook called by Vicq-d'Azyr the "crotchet;" hence its name. Beneath the posterior extremity of the corpus callosum this convolution is joined by the gyrus fornicatus, in front of the calcarine fissure.

*The inferior occipito-temporal convolution* has a similar extent and parallel course, reaching through the occipital and temporo-sphenoidal lobes of which it forms the lower margin.

A *middle occipito-temporal convolution* may be sometimes distinguished between the two just described.

*The dentate or hippocampal fissure* commences within the posterior extremity of the gyrus fornicatus, which separates it from the calcarine fissure. Thence it extends downwards and forwards, ending below in the notch of the uncinate convolution. Its floor is formed by grey matter, called the fascia dentata (see p. 548). This fissure corresponds to the elevation of the hippocampus major within the lateral ventricle.

*The collateral fissure* lies below the uncinate gyrus and parallel to the calcarine and dentate fissures. It extends beneath the floor of the



descending cornua of the lateral ventricle, where it corresponds to the lower part of the eminentia collateralis.

**BASE OF THE CEREBRUM** (fig. 375).—From the front of the pons Varolii, two white masses extend, marked on the surface with longitudinal striæ, and having somewhat the appearance of large bundles of fibres. They pass forwards and outwards to enter the inner and under part of the right and left cerebral hemispheres, of which they are the *peduncles* or *crura*. Immediately before entering the corresponding hemisphere, each is crossed by a flattened white cord, named the *optic tract* (fig. 376), which, adhering by its upper border to the peduncle, is directed forwards and inwards, and meets in front with its fellow of

Fig. 375.

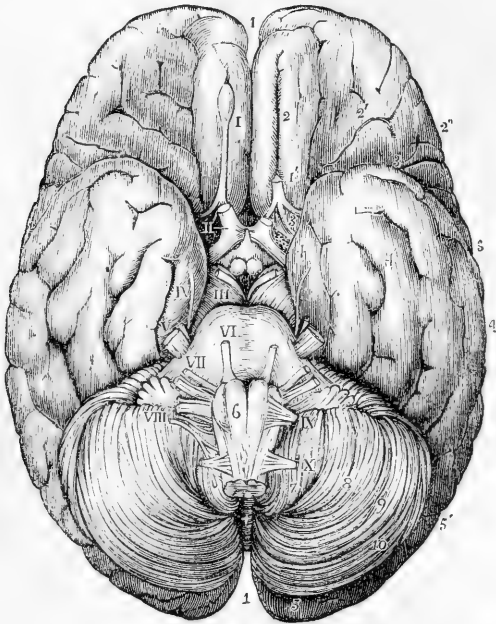


Fig. 375.—BASE OF THE BRAIN WITH THE ORIGINS OF THE CEREBRAL NERVES.  
(Allen Thomson.)  $\frac{1}{2}$

This figure is taken from an adult male brain which had been hardened in alcohol.

1, superior longitudinal fissure; 2, within it the straight olfactory tract and sulcus for the convolution; 2', orbital convolutions; 2'', inferior frontal convolution; 3, 3, 3, fissure of Sylvius; 4, 4, 4, temporo-sphenoidal lobe; 5, 5', occipital lobe; 6, on the right anterior pyramid of the medulla oblongata above the decussation; 7, amygdaloid lobe of the cerebellum; 8, biventral lobe; 9, lobulus gracilis; 10, posterior inferior lobe; +, the inferior vermiform process; I, olfactory bulb; I', the tract divided on the left side; II, in the anterior perforated spot, marks the right optic nerve; the left has been cut short; III, on the right crus cerebri, denotes the third pair; IV, the fourth pair; V, the trigeminus; VI, on the pons Varolii, the sixth; VII, also on the pons Varolii, the facial with the auditory nerve on its outer side; VIII, on the right lobe of the cerebellum below the horizontal fissure and the flocculus, indicates the group of nerves below the auditory, *i. e.*, the glosso-pharyngeal, pneumogastric, and spinal accessory; IX, on the upper part of the left amygdaloid lobe, denotes the hypoglossal nerve; X, on the same, the suboccipital nerve.

the opposite side to form the optic commissure, from the fore part of which the optic nerves proceed.

Limited behind by these diverging peduncles, and in front by the converging optic tracts, is a lozenge-shaped interval, called the *interpuncular space*, in which are found, in series from behind forwards, the

Fig. 376.

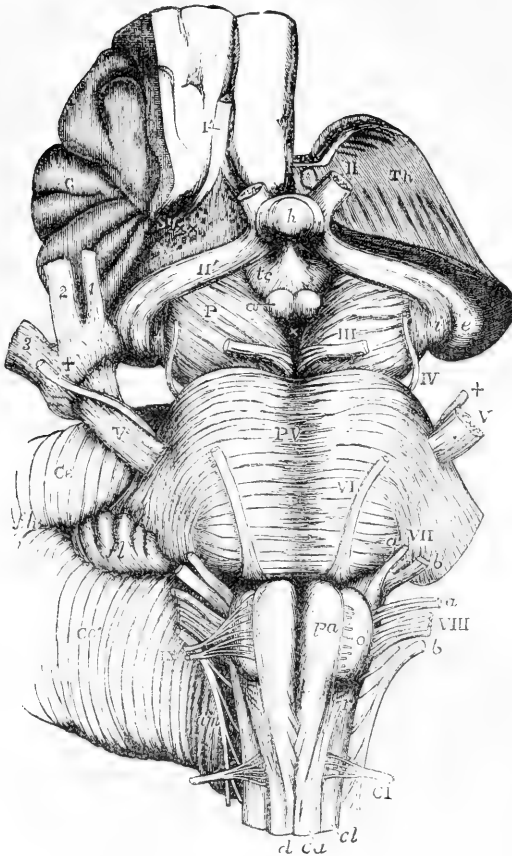


Fig. 376.—VIEW FROM BEFORE OF THE MEDULLA OBLONGATA, PONS VAROLII, CRURA CEREBRI, AND OTHER CENTRAL PORTIONS OF THE ENCEPHALON. (Allen Thomson.)

On the right side the convolutions of the central lobe or island of Reil have been left, together with a small part of the anterior cerebral convolutions: on the left side these have been removed by an incision carried between the thalamus opticus and the cerebral hemisphere.

1', the olfactory tract cut short and lying in its groove between two convolutions; II, the left optic nerve in front of the commissure; II', the right optic tract; Th, the cut surface of the left thalamus opticus; C, the central lobe or island of Reil; Sy, fissure of Sylvius; x x, locus perforatus anterior; e, the external, and i, the internal corpus geniculatum; h, the hypophysis cerebri or pituitary body; tc, tuber cinereum with the infundibulum; a, one of the corpora albicantia; P, the cerebral peduncle or crus; f, the fillet; III, close to the left oculo-motor nerve; x, the locus perforatus posticus; PV, pons Varolii;

V, the greater root of the fifth nerve; +, the lesser or motor root; on the right side this + is placed on the Gasserian ganglion, and points to the lesser root, where it proceeds to join the inferior maxillary nerve; ophthalmic division of the fifth nerve; 2, superior maxillary division; 3, inferior maxillary division; VI, the sixth nerve; VII a, the facial; VII b, the auditory nerve; VIII, the pneumogastric nerve; VIII a, the glosso-pharyngeal; VIII b, the spinal accessory nerve; IX, the hypoglossal nerve; fl, the flocculus; fh, the horizontal fissure of the cerebellum (Ce); am, the amygdala; pa, the anterior pyramid; o, the olivary body; r, the restiform body; d, the anterior median fissure of the spinal cord, above which the decussation of the pyramids is represented; ca, the anterior column; cl, the lateral column of the spinal cord; C I, the suboccipital or first cervical nerve.

posterior perforated space, the corpora albicantia, and the tuber cinereum, from which is prolonged the infundibulum attached to the pituitary body.

The **posterior perforated space** (locus perforatus posticus) (fig. 376, ×) is a deep fossa situated between the peduncles, the bottom of which is composed of greyish matter, connecting the diverging crura together. It is perforated by numerous small openings for the passage of blood-vessels; and some horizontal white striæ usually pass out of the grey matter and turn round the peduncles immediately above the pons.

The **corpora albicantia** or mammillaria are two round white eminences in front of this fossa, each about the size of a small pea, surrounded by grey matter, and connected together across the middle line.

The corpora albicantia are formed, as will hereafter be explained, by the anterior extremities of the fornix; hence they have also been named *bulbs of the fornix*. In the foetus they are at first blended together, and they become separated about the beginning of the seventh month. In most vertebrate animals there is but one white eminence or corpus albicans in their place.

The **tuber cinereum** (fig. 376, *t c*) is a lamina of grey matter extending forwards from the corpora albicantia to the optic commissure, to which it is attached, and forming, as afterwards described, part of the floor of the third ventricle. In the middle it is prolonged into a hollow conical process, the infundibulum, to the extremity of which is fixed the pituitary body.

The **pituitary body** or *hypophysis cerebri* (fig. 376, *h*), formerly called pituitary gland, from its being erroneously supposed to discharge *pituita* into the nostrils, is a small reddish grey mass, of a somewhat flattened oval shape, widest in the transverse direction, and occupying the sella turcica of the sphenoid bone. It consists of two lobes, of which the anterior is larger, and concave behind, where it embraces the smaller posterior lobe. Its weight is from five to ten grains. In the adult it is solid, and of a firm consistence.

The anterior lobe consists of two kinds of matter, one hard and grey, the other, situated within, softer and of a yellowish-white colour. The posterior lobe is darker and redder than the anterior. Both are very vascular.

The pituitary body appears to approach in structure to the vascular or ductless glands, such as the thyroid and suprarenal bodies, &c. According to Sharpey's observations, with which those of subsequent writers agree, it differs greatly in structure, at least in its anterior and larger lobe, from any other part of the encephalon. The substance of the anterior lobe appears to be constituted by a membranous tissue forming little round cavities or loculi, which are packed full of nucleated cells. The loculi are formed of transparent, simple membrane, with a few fibres and corpuscles resembling elongated cell-nuclei disposed round their walls. The cells contained in the cavities are of various sizes and shapes, and not unlike nerve-cells or ganglion-globules; they are collected into round clusters, filling the cavities, and are mixed with a semi-fluid granular substance. This thin granular matter, together with the cells and little specks of a clear glairy substance like mucus, can be squeezed from the cut surface, in the form of a thick, white, cream-like fluid.

In the foetus, the pituitary body is proportionally large, and contains a cavity

which communicates, through that of the infundibulum, with the third ventricle. This body is constantly present, and has the same connection with the brain in all vertebrate animals.

The **optic commissure**, or *chiasma* (fig. 375), is constituted by the union of the two optic tracts in front of the tuber cinereum, and from it the two optic nerves proceed. In it the nerve fibres of each side undergo a partial decussation. The larger proportion of the fibres of each optic tract cross over to the opposite side, a smaller proportion proceed to the eye on the same side, and other fibres are said to pass from one optic tract to the other along the posterior portion of the commissure, while others pass from one nerve to the other along the anterior part of the commissure. Thus each angle is rounded by fibres which pass between its adjacent limbs. The optic tracts are said to receive an accession of fibres from the lamina cinerea, and also from the "basal optic ganglion," a collection of grey matter which lies on the outer side of the tuber cinereum, and is the source of fibres which pass immediately without decussation, to the optic nerve of the same side.

In the middle line of the base of the brain, in front of the optic commissure, is the anterior portion of the great longitudinal fissure, which passes down between the hemispheres. At a short distance in front of the commissure, this fissure is crossed transversely by a white mass, which is the anterior recurved extremity of the corpus callosum. On gently turning back the optic commissure, the *lamina cinerea* is seen, a thin connecting layer of grey substance, occupying the space between the corpus callosum and the commissure, and continuous above the commissure with the tuber cinereum. It is connected at the sides with the grey substance of the anterior perforated space, and forms part of the anterior boundary of the third ventricle: it is somewhat liable to be torn in removing the brain from the skull; and, in that case, an aperture would be made into the fore part of the third ventricle.

At a short distance outwards from the lamina cinerea is the **anterior perforated space** (*locus perforatus anticus*), a depression near the entrance of the Sylvian fissure, floored with grey matter, and pierced with a multitude of small holes for the passage of blood-vessels, most of which are destined for the corpus striatum,—the adjacent portion of the brain beneath which it lies.

The grey surface of each perforated space is crossed by a broad white band, which may be traced from the middle of the under surface of the corpus callosum in front, backwards and outwards along the side of the lamina cinerea towards the entrance of the Sylvian fissure. These bands of the two sides are named the *peduncles of the corpus callosum*.

**Olfactory tract and bulb** (figs. 375, 1, and 376, 1').—From the front of the anterior perforated space a nerve-like process extends—the olfactory tract. It is lodged in a hollow (olfactory sulcus) in the under (orbital) surface of the frontal lobe, close to the longitudinal fissure. It ends anteriorly in an oval swelling—the olfactory bulb, which consists chiefly of grey substance, and gives origin to the small nerves which proceed, through the foramina of the ethmoid bone, to the nose. Traced backwards, the olfactory tract is connected with the cerebrum by three roots. The *outer* root passes, as a white streak, outwards and backwards along the anterior margin of the perforated space, towards

the Sylvian fissure, where it disappears. It has been traced by different observers to the island of Reil, the optic thalamus (Valentin), and to a nucleus in the substance of the temporo-sphenoidal lobe, in front of the anterior extremity of the hippocampus. (Rolando, Foville, Luys.) The *middle*, or grey root (tuber olfactorium), is of pyramidal shape, and consists of grey substance on the surface, prolonged from the adjacent part of the anterior lobe and anterior perforated space. Within it are some white fibres, which have been said by some to join the inner root, by others to be connected with the corpus striatum. The *inner* root consists of white fibres, which pass to the inner and posterior part of the anterior lobe, and are believed to be connected with the extremity of the gyrus fornicatus, or to pass over to the opposite hemisphere.

When the entire encephalon is viewed from below, the back part of the under surface of the cerebrum is concealed by the cerebellum and the pons Varolii. If, however, these parts be removed, it will be seen that the two hemispheres of the cerebrum are separated behind as they are in front, by the descent of the great longitudinal fissure between them, behind the posterior extremity of the corpus callosum.

#### INTERNAL PARTS OF THE CEREBRUM.

The anatomy of the interior of the cerebrum is most conveniently studied by removing successive portions of the hemispheres by horizontal sections, beginning from above.

The first horizontal section to be made about half an inch above the corpus callosum, displays the internal white matter of each hemisphere, speckled with red spots where its blood-vessels have been divided, and surrounded on all sides by the grey matter which is seen to follow closely the convoluted surface, and to be of nearly equal thickness at all points. This white central mass in each hemisphere was named by Vicq-d'Azyr *centrum ovale minus*. On separating the remaining portions of the two hemispheres from each other, two sulci are seen to exist between the corpus callosum and the gyri immediately in contact with it, viz., the gyrus fornicatus of each side.

Another section being made at the level of the corpus callosum, the white substance of that part is seen to be continuous with the internal medullary matter of both hemispheres: and the large white medullary mass thus displayed, surrounded by the border of cortical substance, constitutes what is generally described as the *centrum ovale* of Vieussens.

The **corpus callosum** or **great commissure** (trabs cerebri) (fig. 377) connects the centres of the two hemispheres. It is a white structure, with a length not quite half that of the brain, and approaches nearer to the front than the back of the hemispheres. It is about an inch in width behind, and somewhat narrower in front. Its thickness is greater at the ends than in the middle, and is greatest behind, where it is nearly half an inch. It is arched from before backwards. Its upper surface is distinctly marked by transverse furrows, which indicate the direction of the greater number of its fibres. It is also marked in the middle by a longitudinal line, the *raphe*, which is bounded laterally by two white tracts, placed close to each other, named *striae longitudinales*, or *nerves of Lancisi* (fig. 377, 3). On each side, near the margin, are seen other longitudinal lines (*striae longitudinales laterales*) occasioned by a few scanty white fibres.

In front, the corpus callosum is reflected downwards and backwards, between the anterior lobes, forming a bend named the *genu* (fig. 377, 5). The inferior or reflected portion, which is named the *rostrum*, becomes gradually narrow as it descends, and is connected by means of the lamina cinerea with the optic commissure. It also gives off the two bands of white substance, already noticed as the *peduncles* of the corpus callosum, which, diverging from one another, run backwards across the anterior perforated space on each side to the entrance of the Sylvian fissure.

Behind, the corpus callosum terminates in a free thickened border, the under surface of which is also free for a short distance.

The under surface of the corpus callosum is connected behind with the fornix, a structure to be presently described, and in the rest of its

Fig. 377.

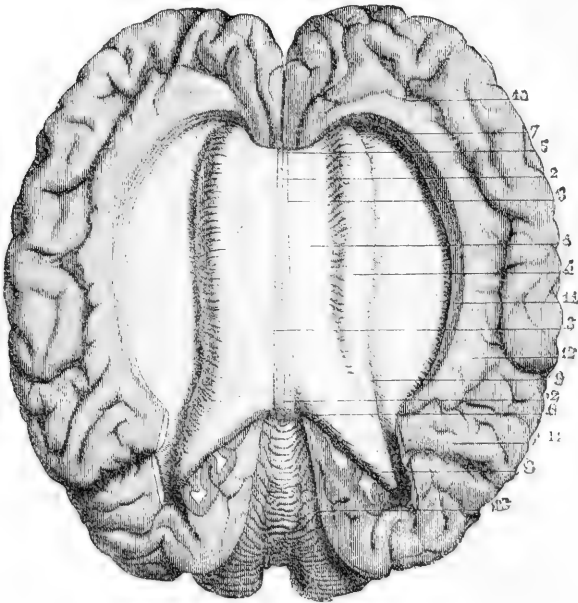


Fig. 377.—VIEW OF THE CORPUS CALLOSUM FROM ABOVE (from Sappey after Foville).  $\frac{1}{2}$

The upper surface of the corpus callosum has been fully exposed by separating the cerebral hemispheres and throwing them to the side; the gyrus fornicatus has been detached, and the transverse fibres of the corpus callosum traced for some distance into the cerebral medullary substance.

1, the upper surface of the corpus callosum; 2, median furrow or raphe; 3, longitudinal striae bounding the furrow; 4, swelling formed by the transverse bands as they pass into the cerebrum; 5, anterior extremity or knee of the corpus callosum; 6, posterior extremity; 7, anterior, and 8, posterior part of the mass of fibres proceeding from the corpus callosum; 9, margin of the swelling; 10, anterior part of the convolution of the corpus callosum; 11, fissure between the corpus callosum and its convolution opened out; outside 12, is the termination of the calloso-marginal fissure, and behind 14 is the parieto-occipital fissure, and between the two the quadrate lobule; 13, upper surface of the cerebellum.

length with the septum lucidum, a vertical partition between the two lateral ventricles.

Although it presents a few longitudinal white fibres on its surface, the corpus callosum consists almost entirely of fibres having a transverse course towards each side, and spreading in a radiating manner into the substance of the two hemispheres. As the transverse fibres from the anterior and posterior portions of the cerebrum are necessarily aggregated in large numbers near the corresponding ends of the corpus callosum, its greater thickness at those points, in comparison with the rest of its extent, is accounted for; and, since the posterior lobe reaches further beyond the corpus callosum than the anterior, the greater thickness behind is also explained.

**Lateral ventricles**, or *ventriculi tricornes*.—By making a longitudinal cut through the corpus callosum at a short distance on each side of the middle line, and about midway between the two ends of the hemispheres, an opening is made into the right and left *lateral ventricles* of the brain (fig. 378). These ventricles form part of the general ventricular space within the cerebrum; they are serous cavi-

Fig. 378.

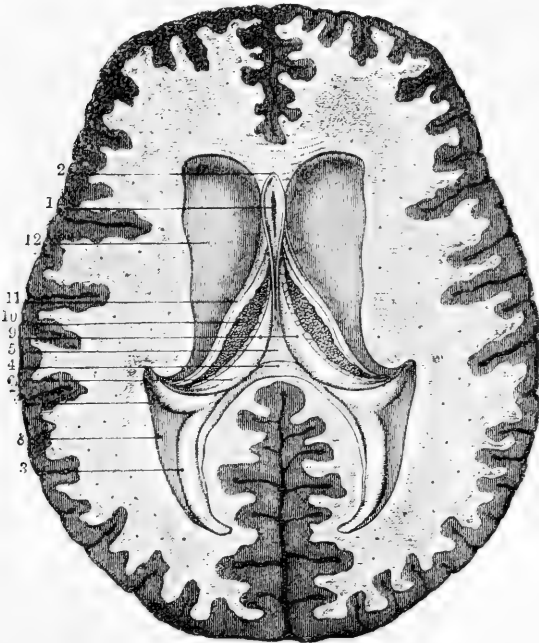


Fig. 378.—HORIZONTAL SECTION OF THE BRAIN SHOWING THE LATERAL VENTRICLES AND THE FIFTH VENTRICLE OPENED (from Sappey after Vicq-d'Azyr).  $\frac{1}{2}$

1, the fifth ventricle; 2, the two laminae of the septum lucidum meeting in front of it; 3, lesser hippocampus of the posterior cornu; 4, horizontal section of the posterior swelling of the corpus callosum; 5, middle part of the fornix, where it has been separated from the corpus callosum; 6, posterior pillar of the fornix; 7, hippocampus major descending in the middle cornu; 8, eminentia collateralis; 9, lateral parts of the fornix; 10, choroid plexus; 11, tania semicircularis; 12, corpus striatum.

ties, and are lined by a delicate epitheliated structure, the *ependyma ventriculorum*, which, at certain parts in the adult, and probably throughout its whole extent in the foetus, is provided with cilia. In the natural state the walls of the ventricles are moistened internally with a serous fluid, which sometimes exists in considerable quantity, even in a healthy brain.

It was formerly a subject of dispute whether the lining of the ventricles consisted of epithelium only, or also of a membrane. It is now recognised that a peculiar form of connective tissue is found throughout the substance of the brain, similar to that which has been described in the spinal cord, and like it called neuroglia. A layer of this substance, unmixed with nerve-tissues, but in direct continuity with the interstitial web, and not a distinct membrane, supports the epithelium.

The form of the epithelial cells appears to vary in different parts; these cells being, according to Kölliker, of the flat pavement kind in the third ventricle, and more spherical in the lateral ventricles; and, according to Gerlach, cylindrical in the aqueductus Sylvii.

From the central part or body of each lateral ventricle the cavity is extended forwards, backwards, and downwards, thus forming an *anterior*, a *posterior*, and a *middle* or *descending cornu* (fig. 371).

Fig. 379.

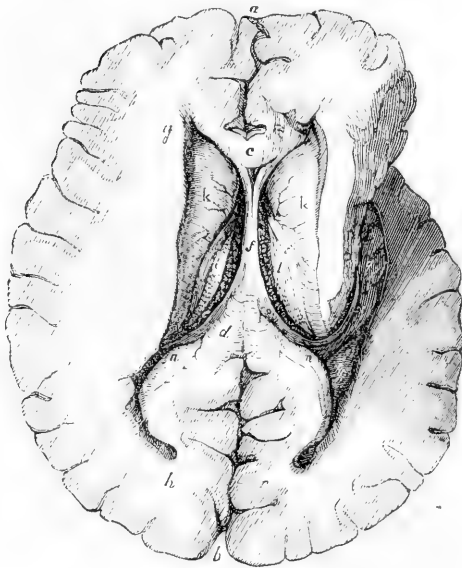


Fig. 379.—THE LATERAL VENTRICLES OPENED BY A HORIZONTAL SECTION, AND THE MIDDLE CORNU EXPOSED ON THE RIGHT SIDE.  $\frac{1}{2}$

*a, b*, anterior and posterior parts of the great longitudinal fissure; *c*, section of the anterior part of the corpus callosum; *d*, posterior part of the same; *e*, the left choroid plexus; *f*, the fornix; *g*, the anterior; *h*, the posterior, and *q*, the descending cornu of the lateral ventricle; *k, k*, corpora striata; *l, l*, optic thalami; *n, n*, right and left hippocampus minor; *o*, posterior pillar of the fornix; *v*, the corpus fimbriatum into which it passes; *g*, cornu ammonis or pes hippocampi; *h*, the medullary substance of the cerebral hemisphere; *r*, part of the cortical substance showing alternate grey and

white matter; *s, s*, tenia semicircularis; *y*, eminentia collateralis.

The *body* of each lateral ventricle is roofed by the corpus callosum, and is separated from its fellow by a vertical partition, the *septum lucidum* (fig. 378, 2), which descends from the corpus callosum to the fornix. In the floor of the ventricle there is seen behind one half



of the *fornix*, which is a thin layer of white brain-substance, broad behind and narrow in front (fig. 378, 9) : external and anterior to this is the *choroid plexus of the lateral ventricle* (fig. 378, 10), a red vascular fringe, forming the border of the *velum interpositum*, a fold of pia mater extending inwards, on which the fornix rests : external and anterior to the choroid plexus is the anterior and outward part of the *optic thalamus*, appearing from beneath it (fig. 379, *l*) ; outside and in front of the thalamus is the *corpus striatum* ; and between these two bodies is a narrow flat band, the *tenia semicircularis*.

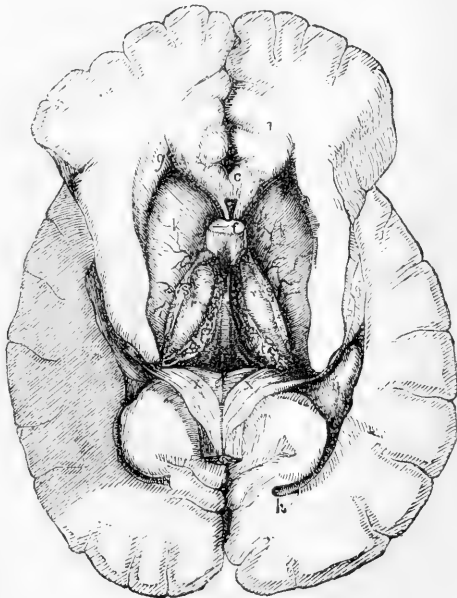
The *anterior cornu* (fig. 379, *g*) is the blind anterior extremity of the ventricle, projecting a little way into the white substance of the frontal lobe. It is covered by the corpus callosum, and turns forwards and outwards round the anterior free extremity of the corpus striatum, descending as it proceeds, and bounded behind by that body, and in front by the reflected part of the corpus callosum.

The *middle or descending cornu* turns round the back part of the optic thalamus, which appears in its cavity and forms its anterior boundary, while its remaining boundaries are formed by the hemisphere. At its commencement it is directed backwards and outwards ; then, passing downwards with a sweep, it curves forwards, and at its extremity has a marked inclination inwards. The principal object seen upon the floor of the cornu is the *hippocampus major* (*pes hippocampi* or *cornu ammonis*), a large white eminence extending the whole length of the cornu (figs. 379, 381, 6, 6'). The hippocampus major becomes enlarged

Fig. 380.—A DEEP VIEW OF THE LATERAL VENTRICLES AND THEIR CORNUA WITH THE VELUM INTERPOSITUM.  $\frac{1}{2}$

Fig. 380.

The fornix has been divided near its anterior pillars and turned back. *c*, the anterior part of the corpus callosum divided ; *e*, the lyra on the lower surface of the corpus callosum and fornix ; *f*, anterior pillars of the fornix divided (these are represented of too large a size) ; *g*, anterior, and *h*, posterior cornu of the lateral ventricle ; *k, k*, corpora striata ; *q*, hippocampus major in the lower part of the middle cornu ; *r, r*, thalami optici ; *s, s*, tenia semicircularis ; *t, t*, choroid plexus ; *v*, velum interpositum ; *x, x*, posterior pillars of the fornix ; *y*, eminentia collateralis.



towards its anterior and lower extremity, and is indented or notched on its edge, so as to present some resemblance to the paw of an animal, whence it has been called the *pes hippocampi*. The white fibres of its surface form only a thin

layer, and beneath them is cineritious matter continuous with that of the surface of the hemisphere. Along the inner edge of this eminence is seen a narrow white band, named *corpus fimbriatum* or *tænia hippocampi* (fig. 381, 6), which is prolonged from the fornix; to the inner side of the tænia is a part of the choroid plexus, and next to that the back of

Fig. 381.

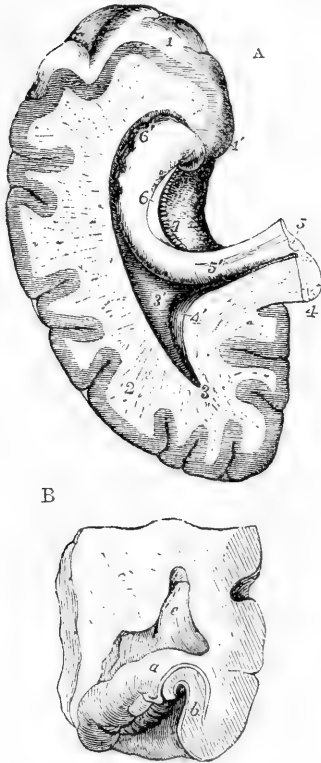


Fig. 381, A.—LOWER AND BACK PART OF THE CEREBRUM OF THE LEFT SIDE, SHOWING THE POSTERIOR AND DESCENDING CORNUA OF THE LATERAL VENTRICLE OPENED (altered from Hirschfeld and Leveillé).  $\frac{1}{2}$

1, Apex of temporo-sphenoidal lobe; 1', unciniate convolution; 2, cut surface of the cerebral hemisphere; 3, point of the posterior cornu of the lateral ventricle; 3', eminentia collateralis; 4, cut surface of the lower and back part of the corpus callosum divided near the middle; 4', placed on the extension of the corpus callosum into the cerebral hemisphere, points by a line to the hippocampus minor in the posterior cornu; 5, cut edge of the posterior pillar of the fornix passing down at 5', into the hippocampus major and corpus fimbriatum; 6, placed on the hippocampus major points to the continuation of the corpus fimbriatum or tænia hippocampi; 6', lower part of hippocampus major; 7, fascia dentata on the inside of the white substance of the tænia.

Fig. 381, B.—SECTION OF THE RIGHT HIPPOCAMPUS MAJOR TO SHOW THE ARRANGEMENT OF THE GREY AND WHITE SUBSTANCE (from Mayo).

a, white layer on the surface of the hippocampus; b, grey substance which is involuted from the surface of the neighbouring convolution; c, fascia dentata; d, unciniate convolution; between c and d dentate fissure; e, (placed on the eminentia collateralis) cavity of the lateral ventricle.

the optic thalamus. This cornu differs from the others in respect that it is not a mere cul-de-sac, but, by the separation of the membranes, can be made to communicate in its whole length with the surface of the brain by the fissure through which the choroid plexus enters.

The *posterior cornu* projects backwards into the substance of the posterior lobe. At its extremity it is pointed, and directed inwards. On its inner side is a curved and pointed longitudinal eminence, named *hippocampus minor*, *ergot*, or *calcar avis*; and at the junction of the posterior with the descending cornu, between the hippocampus major and minor, is a smooth eminence, named *eminentia collateralis*, or *pes accessorius*, which may extend some way down the descending cornu behind the great hippocampus.

The hippocampus minor is only the convex side of the fold of cortical substance which forms the calcarine sulcus, and in like manner the eminentia collateralis corresponds with the posterior branch of the fissure of Sylvius.

The hippocampus minor is not peculiar to the human brain, but has been found in the brains of quadrumana. In the human subject the posterior cornu varies greatly in size, and the hippocampus minor is still more variable in its development, being sometimes scarcely to be recognised, and at others proportionally large. It is usually most developed where the posterior cornu is longest; but the length of the posterior cornu, and prominence of the hippocampus minor, are by no means in proportion to the dimensions of the hemisphere, but rather seem to be associated with thinness of both the medullary and the cortical substance.

The **septum lucidum** (fig. 378) is a thin translucent partition, placed between the two lateral ventricles. It extends vertically between the corpus callosum above, and the anterior part of the fornix below; and, as the latter sinks down in front away from the corpus callosum, the septum is deep before and narrow behind, in form somewhat resembling an obovate leaf. Anteriorly it lies in the hollow of the bend of the corpus callosum, in front of the fornix.

The septum lucidum is double, being composed of two distinct laminae, having an interval between them, which contains fluid and is lined by an epitheliated membrane. This is the *fifth ventricle*, *ventricle of the septum*, or *Sylvian ventricle*.

Each of the laminae of the septum which form the sides of the fifth ventricle, consists of a layer of white substance on the middle, and a layer of grey matter upon each surface.

In the human embryo, and also in some animals, the cavity of this ventricle communicates with that of the third ventricle in front and below; but in the adult human brain it forms a separate and insulated cavity. Tarin described a small fissure in it between the pillars of the fornix; but this is unusual. In disease it is sometimes distended with fluid.

The **fornix** (fig. 379, *f*) is an arched band of white longitudinal fibres, which appears partly in the floor of both lateral ventricles. It consists of two lateral halves, which are separated from each other in front and behind, but between those points are joined together in the mesial plane. The two parts in front form the *anterior pillars* of the fornix; the middle conjoined part is named the *body*; and the hind parts, which are again separated from each other, form the *posterior pillars*.

The *body* of the fornix is triangular in shape, being broad and flattened behind, where it is connected with the under surface of the corpus callosum, and narrower in front as it dips down to leave that body,—the space between them being filled up by the septum lucidum. Its lateral edges are in contact with the choroid plexuses, and its under surface rests upon the velum interpositum. The space beneath the velum interpositum, and between the two optic thalami, forms the third ventricle, to be afterwards described.

The *anterior crura* or *pillars* of the fornix (fig. 383, *e*), cylindrical in form, descend, slightly apart from each other, through a quantity of grey matter on the sides of the third ventricle, between the corpora striata. Curving backwards as they descend, they reach the corpora albicantia. There each crus turns upon itself, making a twisted loop which forms the white portion of the corpus albicans of its own side, and ascends to enter the substance of the optic thalamus. These crura are connected with the peduncles of the pineal gland, and with the tænia semicircularis, as will be afterwards described.

Immediately behind the anterior pillars is an interval on each side between the anterior part of the fornix and the groove where the optic thalamus and corpus striatum meet. This interval leads from the lateral ventricle to the third ventricle. The openings of opposite sides, passing downwards and backwards, meet in the middle line below, and thus is produced a passage, single below, but dividing into two branches above, somewhat like the letter Y, and forming a communication between the third ventricle and both lateral ventricles. This passage is named the *foramen of Monro*, or *foramen commune anterius*.

The *posterior crura* or *pillars* of the fornix (fig. 378, 6) are the diverging continuations backwards of the two flat lateral bands of which the body is composed. At first they adhere to the under surface of the corpus callosum, then, curving outwards, each crus enters the descending cornu of the corresponding lateral ventricle, where part of its fibres are bestowed on the surface of the great hippocampus and the remainder are prolonged as a narrow band of white matter, named *tenia hippocampi* or *corpus fimbriatum*, which skirts the concave margin of the hippocampus major, and extends to its extremity.

On examining the under surface of the fornix and corpus callosum, there are seen posteriorly the thickened border or pad, and in front of it the diverging halves of the fornix, between which a triangular portion of the corpus callosum appears, marked with transverse, longitudinal, and oblique lines. To this part the term *lyra* has been applied (fig. 382, 12).

The **transverse fissure of the cerebrum** is the passage by which the pia mater passes from the surface into the ventricles of the brain to form the choroid plexus. It may be laid open in its whole extent, after the lateral ventricles have been opened, by completely dividing the fornix and corpus callosum in the middle line, and raising the divided parts from the undisturbed velum interpositum below. It will then be found that, in like manner, the posterior and middle portions of the brain, including the hippocampus major and corpus fimbriatum, may be raised from the subjacent parts as far as the extremity of the descending cornu of the lateral ventricle. The transverse fissure is, therefore, a fissure extending from the extremity of the descending cornu on one side, over the constricted part of the cerebrum, to the extremity of the descending cornu of the other side. It is bounded above by the corpus callosum and fornix in the middle, and more externally on each side by a free margin of the hemisphere: inferiorly it is bounded near the middle line by the corpora quadrigemina, and on each side by the posterior part of the optic thalamus.

In the *free margin of the hemisphere*, brought into view by opening out the part of the transverse fissure which leads into the descending cornu of the lateral ventricle, there are seen (fig. 381) (1st) the ribbon-like ledge formed by the corpus fimbriatum, along the hippocampus major: (2nd) beneath this, a small grey indented ridge, the *fascia dentata*; and (3rd) beneath the *fascia dentata*, the gyrus hippocampi. On making a transverse section (fig. 381, B), it is seen that the corpus fimbriatum forms the free margin of the white substance of the hemisphere, and that the *fascia dentata* is the free margin of the cortical substance, and is continuous with the grey matter of the hippocampus major, and that thus the hippocampus major is the swelling in reverse of the sulcus between the *fascia dentata* and gyrus hippocampi (*uncinate*

convolution). The fascia dentata can be traced up to the pad or bourrelet : its upper part is free of dentations, and is sometimes named *fasciola cinerea*. The dentations correspond with blood-vessels passing to and from the choroid plexus.

Fig. 382.

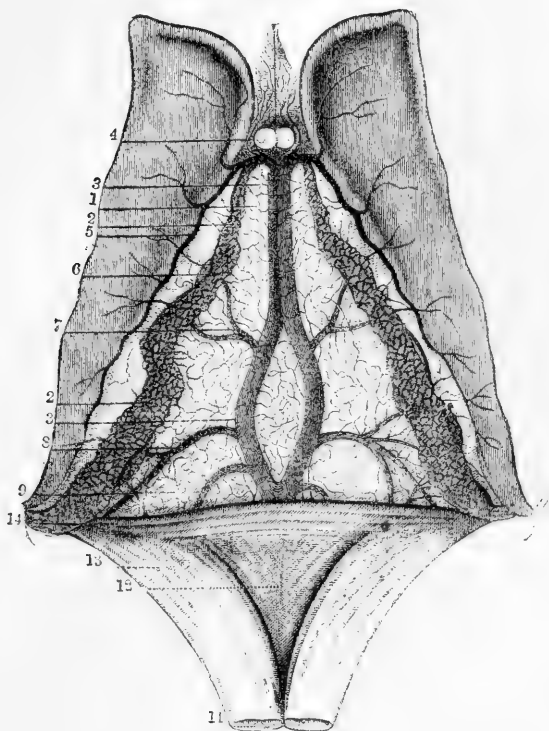


Fig. 382.—VIEW OF THE UPPER SURFACE OF THE VELUM INTERPOSITUM, CHOROID PLEXUS, AND CORPORA STRIATA (from Sappey after Vicq-d'Azyr).  $\frac{2}{3}$

1, fore part of the tela choroidea or velum interpositum ; 2, choroid plexus ; 3, left vein of Galen partly covered by the right ; 4, small veins from the front of the corpus callosum and the septum lucidum ; 5, veins from the corpus striatum ; 6, convoluted marginal vein of the choroid plexus ; 7, vein rising from the thalamus opticus and corpus striatum ; 8, vein proceeding from the inferior cornu and hippocampus major ; 9, one from the posterior cornu ; 10, anterior pillars of the fornix divided in front of the foramen of Monro ; 11, fornix divided near its fore part and turned backwards ; 12, lyra ; 13, posterior pillar of fornix united with, 14, the corpus callosum behind, and covered by the choroid plexus as it descends into the inferior cornu.

The **velum interpositum** or **tela choroidea** (fig. 382), the membrane which connects the choroid plexuses of the two sides together, is a prolongation of the pia mater through the transverse fissure. It corresponds in extent with the fornix, which rests upon its upper surface ; and its more highly vascular free borders, projecting into the lateral ventricles, form the choroid plexuses.

The *choroid plexuses* (fig. 382, 2) appear like two knotted fringes reaching from the foramen of Monro, where they meet together beneath

the fornix, to the point of each descending cornu. They consist of a highly vascular villous membrane. The villi with which they are covered are again divided upon their surfaces and at their borders into small processes, along which fine vessels are seen to run. Numerous small vessels pass between the plexuses and the surface of the corpora striata, as well as other neighbouring parts, and the epithelium of the ventricles is continued over their surface. Thus it is only at the foramen of Monro that the epithelial lining of the lateral ventricles is continuous with that of the third ventricle.

The epithelium changes its character where it covers the plexus. It is there composed of large spheroidal corpuscles, in each of which is seen, besides a distinct nucleus, several yellowish granules, and one or more dark round oil-drops. According to Henle each of these cells is provided with short, slender, acuminate, transparent, and colourless processes.

On raising the velum interpositum, two slight vascular fringes are seen running along its under surface, and diverging from each other behind. They form the *choroid plexuses* of the third ventricle.

The choroid artery enters the velum interpositum at the point of the descending cornu; and other arteries enter from behind, beneath the corpus callosum. The greater number of the veins terminate in two principal vessels named the veins of Galen, which run backwards on the velum interpositum, and passing out beneath the corpus callosum pour their blood into the straight sinus, having generally first united into a single trunk.

The velum having been removed, the optic thalami are brought fully into view, together with the cavity of the third ventricle situated between them, while, behind the third ventricle, between it and the upper surface of the cerebellum, are seen the pineal body, the corpora quadrigemina, the valve of Vieussens, and the superior peduncles of the cerebellum.

The **third ventricle** is a narrow longitudinal cleft placed between the optic thalami, which bound it on its two sides. It is covered above by the velum interpositum and the fornix. Beneath, its floor is formed by the following parts, which have been already described as seen on the base of the cerebrum; viz., commencing from behind, the posterior perforated space, the corpora albicantia, the tuber cinereum and infundibulum, and the lamina cinerea, the last of which also serves to close it in front, as high as the anterior commissure. Behind, is the anterior opening of the aqueduct of Sylvius. The cavity is crossed by three commissures, named from their position, anterior, middle, and posterior.

The *middle* or *soft commissure* is composed almost entirely of grey matter, and connects the two thalami. It is variable in size, and sometimes wanting; it is liable to be torn across in examining the brain.

The *anterior commissure* is a round bundle of white fibres, placed immediately in front of the anterior pillars of the fornix, and crossing between the corpora striata. It marks the anterior boundary of the ventricle; its fibres extend laterally through the corpora striata a long way into the substance of the cerebral hemispheres, connecting the two temporo-sphenoidal lobes.

The *posterior commissure*, also white but of smaller size, is placed across the back part of the ventricle, between the posterior parts of the thalami, immediately before and below the pineal body, with which and with the corpora quadrigemina it is intimately connected. It consists

of transverse white fibres, a continuation of a series of transverse fibres which underlie the corpora quadrigemina. Its fibres, passing through the thalami, diverge in the white substance of the hemisphere.

The **corpora striata** (*anterior cerebral ganglia*), situated in front and to the outer side of the optic thalami, are two large ovoid masses of grey matter, the greater part of each of which is embedded in the

Fig. 383.

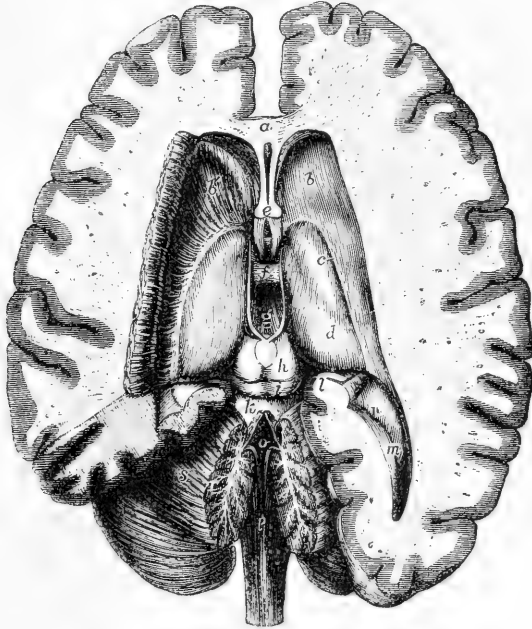


Fig. 383.—DISSECTION OF THE BRAIN FROM ABOVE, EXPOSING THE LATERAL,—THIRD, AND FOURTH VENTRICLES, WITH THE SURROUNDING PARTS (from Hirschfeld and Leveillé).  $\frac{1}{2}$

*a*, the anterior part or knee of the corpus callosum divided; its fibres are seen spreading on each side into the cerebral hemispheres; *b*, anterior part of the surface of the right corpus striatum in the anterior cornu of the lateral ventricle; *b'*, the same on the left side, in which the grey substance has been dissected so as to show the peduncular medullary fibres spreading through the corpus striatum into the cerebral hemisphere; *c*, points by a line to the tænia semicircularis; *d*, surface of the thalamus opticus; *e*, the anterior pillars of the fornix divided; below, they are seen descending in front of the third ventricle, and between them is seen a part of the anterior commissure; above the letter is seen the fifth ventricle represented as a slit between the two laminae of the septum lucidum; *f*, placed on the soft or middle commissure; *g*, in the posterior part of the third ventricle; on either side of this letter is the white stria or peduncle of the pineal gland; immediately below the letter is the small posterior commissure and the pineal gland; *h*, the upper, and *i*, the lower of the corpora quadrigemina; *k*, superior peduncle of cerebellum; and close to this the valve of Vieussens, which is partly divided by a median incision along with the middle lobe of the cerebellum, so as to open up the fourth ventricle; *l*, the hippocampus major and corpus fimbriatum separated from the posterior pillar of the fornix and descending into the middle cornu of the lateral ventricle; *m*, posterior cornu of the lateral ventricle and hippocampus minor; *n*, eminentia collateralis; *o*, the cavity of the fourth ventricle; *p*, posterior surface of the medulla oblongata; *r*, section of the middle lobe showing the arbor vitæ; *s*, upper surface of the cerebellum brought into view on the left side by the removal of the posterior extremity of the left hemisphere.

middle of the white substance of the hemisphere of the brain, whilst a part comes to the surface in the body and anterior cornu of the lateral ventricle. This *intraventricular* portion of the corpus striatum (*nucleus caudatus*) is of a pyriform shape, its larger end being turned forwards, and its narrow end being directed outwards and backwards, so that the optic thalami of the two sides are received between the diverging corpora striata. On cutting into it, there may be seen at some depth from the surface white fibres, which are prolonged from the corresponding cerebral peduncle, and give it the streaked appearance from which it has received its name.

The *extraventricular* portion of the corpora striata, *nucleus lenticularis*, is separated from the intraventricular part by a layer of white substance,

Fig. 384.

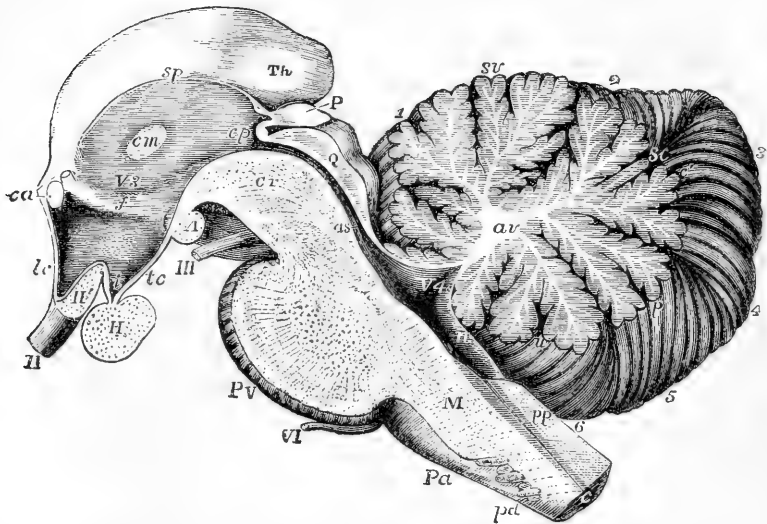


Fig. 384.—RIGHT HALF OF THE ENCEPHALIC PEDUNCLE AND CEREBELLUM AS SEEN FROM THE INSIDE OF A MEDIAN SECTION (Allen Thomson after Reichert).

II, right optic nerve; II' optic commissure divided; III, right third nerve; VI, sixth nerve; V 3, third ventricle; *Th*, back part of the thalamus opticus; *H*, section of the pituitary body; *A*, corpus albicans; *P*, pineal gland; *c a*, points by a lower line to the anterior commissure divided, and by an upper line to the divided anterior pillar of the fornix; *l c*, lamina cinerea; *i*, infundibulum (cavity); *t c*, tuber cinereum; *f*, mark of the anterior pillar of the fornix descending in the wall of the third ventricle; *c m*, commissure mollis; *s p*, stria pinealis or peduncle of pineal gland; *c p*, posterior commissure, above it the peduncle of the pineal gland, and below it the upper end of the passage to the fourth ventricle; *Q*, corpora quadrigemina (section); *a s*, aqueduct of Sylvius near the fourth ventricle; *P V*, pons Varolii divided in the middle; *M*, medulla oblongata; *p a*, right anterior pyramid; *p d*, decussating bands cut across; *p p*, posterior pyramids; *c*, central canal, divided, with grey substance surrounding it. In the cerebellum, *a v*, stem of white substance in the centre of the middle lobe of the cerebellum, ramifying towards the arbor vitae; *s v*, superior vermiform process or vertical portion of the middle lobe; *s c*, single folium, which passes across between the posterior superior lobes, *c'*, the folia, which unite the posterior inferior lobes; *p*, pyramid; *u*, uvula; *n*, nodule; *1*, part of the laminae of the square lobe; *2*, posterior superior lobe; *3*, posterior inferior lobe; *4*, lobulus gracilis; *5*, biventral lobe; *6*, amygdaloid lobe.



and is seen only on section of the hemisphere. Its horizontal section resembles that of a biconvex lens, being wider in the centre than at either end, hence its name. Its antero-posterior diameter corresponds closely with that of the Island of Reil, and its greatest width is opposite the anterior edge of the optic thalamus. On a transverse vertical section through the middle it appears triangular, the apex of the triangle being directed inwards, and two clear lines, parallel to the outer side, divide it into three zones, of which the outer is striated and the inner slightly reddish in tint. On its outer side is the grey lamina, termed the *claustrum* (p. 564).

Along the inner border of each corpus striatum, and in a depression between it and the optic thalamus, is seen a narrow whitish semitransparent band, named *tenia semicircularis*, or *stria terminalis* (fig. 383, *c.*), which is continued backwards into the white substance of the roof of the descending cornu of the ventricle. In front it reaches the corresponding anterior pillar of the fornix, and descends in connection with that cord of white substance.

The **thalami optici** (*posterior cerebral ganglia*) (*d*, fig. 383) are of an oval shape, and rest on the corresponding cerebral crura, which they in a manner embrace. On the outer side each thalamus is bounded by the corpus striatum and *tænia semicircularis*. The upper surface, which is white, is free and prominent, and is partly seen in the lateral ventricle, and partly covered by the fornix. The part which is seen in the lateral ventricle is more elevated than the rest, and is named the *anterior tubercle*. The posterior and inner part of the upper surface, beneath the fornix, is likewise prominent and is termed the *posterior tubercle* (*pulvinar*) (*th*, in fig. 384). The posterior surface, which is also white and free, projects into the descending cornu of the lateral ventricle. The inner sides of the two thalami are in partial contact one with the other. They present grey substance uncovered with white, and are generally connected together by a transverse portion, which forms the middle or soft commissure of the third ventricle. According to Meynert, the grey matter on the inner surface is distinct from that of the interior of the thalamus.

The **pineal body** or **gland** (*conarium*) (fig. 383) is a small reddish body, which is placed beneath the back part of the corpus callosum, and rests upon the anterior elevation of the corpora quadrigemina. It is adherent to the under surface of the velum interpositum, so that it is liable to be torn away from the brain in removing that membrane. It is about the size of a small cherry-stone. Its base of attachment, which is its broader part, is directed forwards, and is connected with the rest of the cerebrum by white substance. This white substance is principally collected into two small rounded bundles, named *peduncles* of the pineal gland (fig. 384, *s p*), which pass forwards upon the optic thalami along their upper and inner borders, and may be traced as far as the anterior pillars of the fornix, in conjunction with which they descend. These peduncles are connected with each other behind, and the band of union between them is adherent to the back of the posterior commissure.

The pineal gland is very vascular. It is hollowed out into two or more cells, which, sometimes at least, open anteriorly into the ventricle, and almost always contain, beside a viscid fluid, many round and angular corpuscles densely massed together, and a quantity of gritty matter, named *acervulus cerebri*. This consists of microscopic round

particles, aggregated into small compound masses, which are again collected into larger groups. It is composed of the so-called amyloaceous or amyloid bodies, and of earthy salts combined with animal

Fig. 385.

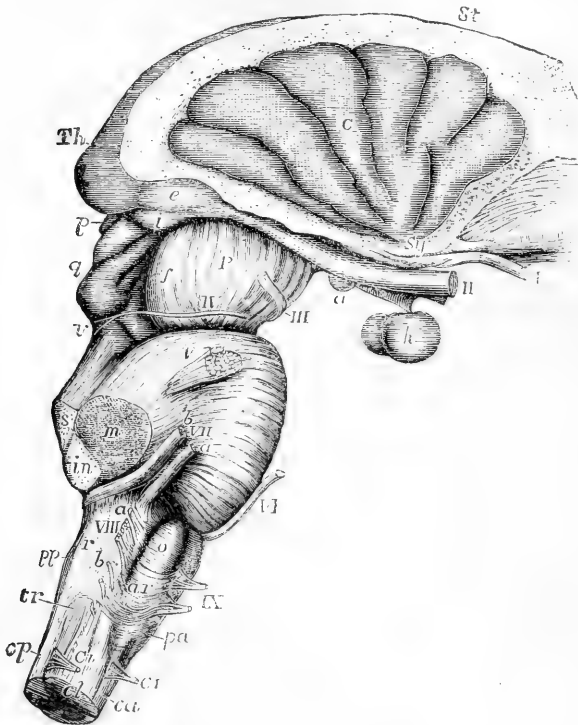


Fig. 385.—VIEW OF THE MEDULLA OBLONGATA, PONS VAROLII, CRURA CEREBRI, AND CENTRAL PARTS OF THE ENCEPHALON FROM THE RIGHT SIDE. (Allen Thomson.)

The corpus striatum and thalamus opticus have been preserved in connection with the central lobe and crura cerebri, while the remainder of the cerebrum has been removed.

*St*, upper surface of the corpus striatum; *Th*, back part of the thalamus opticus; *C*, placed on the middle of the five or six convolutions constituting the central lobe or island of Reil, the cerebral substance being removed from its circumference; *Sy*, fissure of Sylvius, from which these convolutions radiate, and in which are seen the white striæ of the olfactory tract; *I*, the olfactory tract divided and hanging down from the groove in the convolution which lodges it; *II*, optic nerves a little way in front of the commissure; *a*, right corpus albicans with the tuber cinereum and infundibulum in front of it; *h*, hypophysis or pituitary body; *e*, external, and *i*, internal corpus geniculatum at the back part of the optic tract; *P*, peduncle or crus of the cerebrum; *f*, fillet; *III*, right oculomotor nerve; *p*, pineal gland; *q*, corpora quadrigemina; *IV*, trochlear nerve rising from *v*, the valve of Vieussens; *V*, placed on the pons Varolii above the right nervus trigeminus; *s*, the superior, *m*, the middle, and *in*, the inferior peduncles of the crus cerebelli cut short; *VI*, the sixth nerve; *VII a*, facial nerve; *VII b*, auditory nerve; on the medulla oblongata the parts are indicated as follows: *VIII*, placed opposite to the cut end of the pneumo-gastric nerve; *a*, the glosso-pharyngeal; and *b*, the uppermost fibres of the spinal accessory nerve; *IX*, the hypoglossal nerve; *p a*, anterior pyramid; *o*, olivary body; *ar*, arciform fibres; *p p*, posterior pyramid; *r*, restiform body; *tr*, eminence corresponding to the tubercle of Rolando; at the commencement of the spinal cord, *c a*, indicates the anterior, *c p*, the posterior, and *c l*, the lateral columns; *C I*, anterior and posterior roots of the suboccipital or first cervical nerve.

matter, viz., phosphate and carbonate of lime, with a little phosphate of magnesia and ammonia (Stromeyer). It is found at all ages, frequently in young children, and sometimes even in the fœtus. It cannot, therefore, be regarded as the product of disease.

Beneath the peduncle of the pineal gland, is a collection of grey matter distinct from the rest of the thalamus and called the ganglion of the peduncle of the pineal gland (ganglion of the habenula). Fibres arise from it and pass down to the crus.

This sabulous matter is frequently found on the outside of the pineal body, or even deposited upon its peduncles. It is found also in the choroid plexuses; and scattered corpora amylacea occur in other parts of the membranes of the brain. Huschke has pointed out that the pineal body is larger in the child and the female than in the adult male. In the brains of other mammals it is proportionally larger than in the human subject, and less loaded with the matter of acervulus cerebri.

Whether the pineal gland consists of nerve-tissue is still uncertain. Meynert regards it as one of the centres for the fibres of the crus, but Henle and others consider that it resembles most the supra-renal capsules.

The **corpora** or **tubercula quadrigemina** are four rounded eminences, separated by a crucial depression, and placed two on each side of the middle line, one pair before the other. They are connected with the back of the optic thalami, and with the cerebral peduncles at either side; and they are placed above the passage leading from the third to the fourth ventricle.

The upper or anterior tubercles (*nates*) are somewhat larger and darker in colour than the posterior (*testes*). In the adult, both pairs are solid, and are composed of white substance on the surface, and of grey matter within. (See p. 563.)

They receive bands of white fibres from below, the majority of which are derived from the fillet (see p. 556). A white cord also passes up on each side from the cerebellum to the corpora quadrigemina, and is continued onwards to the thalami: these two white cords are the *processus a cerebello ad cerebrum*, or superior peduncles of the cerebellum. At each side of the corpora quadrigemina there proceed outwards two white bands, prominent on the surface and sometimes named anterior and posterior *brachia*. The fibres of the anterior pass to the thalamus opticus, the inner corpus geniculatum, and the optic tract; those of the posterior to the inner corpus geniculatum and the crus cerebri. According to Meynert, many of their fibres pass directly to the cortical substance of the hemisphere.

In the human brain the quadrigeminal bodies are small in comparison with those of animals. In ruminant, soliped, and rodent animals, the anterior tubercles are much larger than the posterior, as may be seen in the sheep, horse, and rabbit; and hence the name *nates*, formerly applied to the anterior, and *testes* to the posterior tubercles. In the brains of carnivora, the posterior tubercles are rather the larger. In the fœtus of man and mammals these eminences are at first single on each side, and have an internal cavity communicating with the ventricles. They are constant in the brains of all vertebrate animals; but in fishes, reptiles, and birds, in which animals they receive the name of optic lobes, they are only two in number, and hollow: in marsupialia and monotremata, they are also two in number, but are solid.

**Optic tracts and corpora geniculata.**—The optic tracts, which have already been referred to in connection with the base of the cere-

brum, are attached to and embrace the under side of the corresponding peduncles, and may be traced back to the thalami. Each tract is somewhat cylindrical towards the optic commissure, where it is connected with a deposit of grey matter adjacent to the tuber cinereum. It becomes flattened and broader as it approaches the thalamus, and makes a bend as it turns round the peduncle to reach the back part of that body. Near this bend, which is named the *knee* (*genu*), and to the outer side of the corpora quadrigemina, are placed two small oblong and flattened eminences connected with the posterior extremity of the optic tract. They are small masses of grey matter about the size and shape of coffee-beans, placed one on the outer and one on the inner side of the genu of the optic tract, and hence they are named respectively *corpus geniculatum externum* and *internum*. They send fibres into the optic tract and also into the thalamus of the same side. Other fibres go directly from the optic tract to the thalamus, passing between the outer corpus geniculatum and the crus cerebri, and others to the anterior corpora quadrigemina.

The fibres of the optic tract are therefore derived from three sources, viz., the thalamus, the corpora quadrigemina, and the corpora geniculata.

Beneath the tract as it passes over the crus is a band of fibres passing in the same direction, called the "*collar of the crus*." They are connected behind with the optic thalamus, and in front with the tuber cinereum and inner part of the corpus striatum.

The **processus a cerebello ad cerebrum**, *superior peduncles of the cerebellum*, are two large white cords extending downwards and somewhat outwards from the corpora quadrigemina to the fore part of the cerebellum, and connecting the latter with the cerebrum. They rest upon the crura cerebri, to which they are united, and between them is the valve of Vieussens. Some of their fibres decussate beneath the corpora quadrigemina.

The **valve of Vieussens** (*velum medullare anterius*), (fig. 383) stretched between the processus a cerebello ad cerebrum, is a thin layer of nervous matter, which lies over the passage from the third to the fourth ventricle, and, lower down, covers in a part of the fourth ventricle itself. It is narrow in front, where it is connected with the quadrigeminal bodies, and broader behind, where it is continuous with the median portion of the cerebellum.

The valve is composed of white substance, superficial in its upper portion, but concealed in its lower half by a few transverse ridges of grey matter, which appear as if prolonged from the grey lamellæ of the cerebellum with which the valve is there continuous. Within it is some grey substance, which constitutes the *nucleus of the roof of the fourth ventricle* of Stilling, and is supposed to connect the two dentate nuclei.

From between the posterior quadrigeminal tubercles a slight median ridge, named *frænulum*, descends a little way upon the valve; and on the sides of this the commencing fibres of the fourth pair of nerves pass transversely outwards. The back part of the valve is overlapped and concealed by the superior vermiform process of the cerebellum.

**Aqueduct of Sylvius.**—Beneath the corpora quadrigemina a narrow canal connects the third ventricle in front with the fourth ventricle behind. It varies in shape in different parts, being T-shaped behind,

elongated vertically in front. A thick layer of grey substance occupies its floor, beneath which, on each side, is the common nucleus of the third and fourth nerves.

#### INTERNAL STRUCTURE OF THE CEREBRUM.

The cerebrum, like the rest of the encephalon, is composed of white and grey substance, the white pervading nearly the whole of its extent, though more exclusively composing its deeper parts; the grey forming a covering of some thickness over the whole surface of the convolutions, and in certain of the deeper parts either collected into distinct masses or scattered among the bundles of nerve fibres, such as the corpora striata, thalami optici, corpora quadrigemina, and crura cerebri. To the grey substance, the names of *cineritious* and *cortical* have been applied; to the white that of *medullary*.

THE WHITE MATTER of the encephalon consists of tubular fibres, varying in size in different parts, but in general still smaller than those of the cord, their average diameter being the  $\frac{1}{10000}$ th of an inch. Non-medullated fibres are seen only in the neighbourhood of the grey matter in the basal ganglia and cortex. The fibres of the white substance present no divisions. They are arranged in bundles sepa-

Fig. 386.

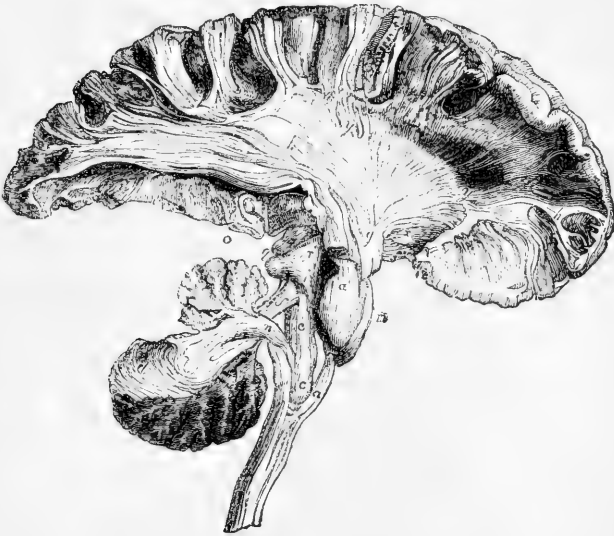

Fig. 386.—SKETCH OF A DISSECTION SHOWING THE CONNECTION OF THE COLUMNS OF THE MEDULLA OBLONGATA WITH THE CEREBRUM AND CEREBELLUM (from Mayo).  $\frac{1}{2}$

In the lower part of the figure the medulla oblongata is entire where it is prolonged downwards into the spinal cord; *a*, the anterior pyramid; *a'*, its continuation upwards into the pons Varolii (*m*); *c*, olivary body; *c'*, olivary fasciculus; behind *c'*, the fasciculi teretes are represented; *d*, the white laminae in part of the cerebellum; *f*, superior peduncle of the cerebellum; *g*, anterior part or crust of the cerebral peduncle; *h*, part of the fibres radiating from the peduncle into the right cerebral hemisphere, of which a considerable extent is shown containing parts of the frontal, parietal, and occipital lobes; *h, y, y*, part of the corona radiata; *h'* (in front), central fibres of the convolutions; *i*, fillet; *l*, back of the thalamus opticus; *m*, pons Varolii; *n*, inferior peduncle of the crus cerebelli; *o*, section of the pes hippocampi; *r*, tegmentum; *y, y*, show the white fibres issuing from the corpus striatum.

rated by a network of delicate connective tissue, consisting of cells possessing distinct nuclei and delicate processes, which unite to form incomplete laminae.

The general direction which the fibres follow is best seen in a brain that has been hardened by immersion in alcohol, although it is true that in an ordinary dissection of such hardened masses with the scalpel, we do not then trace the single fibres, but only the smaller bundles and lamellae which they form by their aggregation. It must also be admitted that where they intimately decussate, the tearing of fibres across is liable to be mistaken for the separation of sets of fibres one from the other; it is necessary to correct such errors by the examination of sections under the microscope. The microscopic examination of the cerebrum, however, is as yet still less complete than that of the spinal marrow and medulla oblongata. By the dissection of artificially prepared brains, aided in part by microscopic observation, the following general facts have been ascertained.

The fibres of the cerebrum, though exceedingly complicated in their arrangement, and forming many different groups, may be referred to three principal systems, according to the general course which they take, viz. :—1. *Ascending* or *peduncular fibres*, which pass from the medulla oblongata to the hemispheres, and constitute the peduncles of the cerebrum. These fibres increase in number as they ascend through the pons, and still further in passing through the optic thalami and striated bodies, beyond which they spread in all directions into the hemispheres. 2. *Transverse* or *commissural fibres*, which connect the two hemispheres together. 3. *Longitudinal* or *collateral fibres*, which, keeping on the same side of the middle line, connect more or less distant parts of the same hemisphere.

1. The **Peduncular fibres**, in each hemisphere, consist of a main body and of certain accessory bundles of fibres.

Fig. 387.

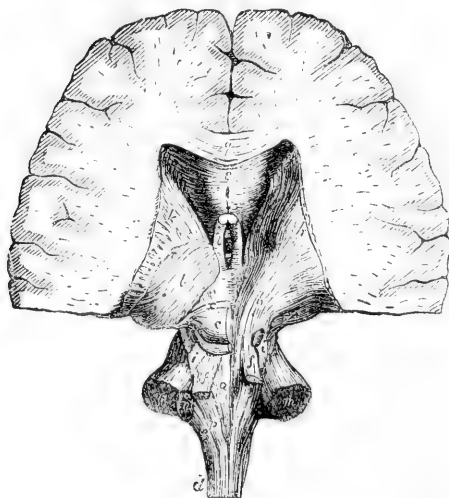


Fig. 387.—POSTERIOR VIEW OF THE PEDUNCLES OF THE CEREBRUM AND CEREBELLUM (after Arnold).  $\frac{1}{2}$

The lower and fore part of the cerebral hemispheres is preserved, the cerebellum is completely detached from its peduncles, and on the right side the corpora quadrigemina and thalamus opticus have been dissected. *a*, fasciculus teres of the left side; *b*, fibres of the tegmentum ascending through the right thalamus; *c*, left corpora quadrigemina; *d*, lateral column of the cord; *e*, restiform body; *f*, superior peduncles of the cerebellum; *g*, fibres of the crust; *i*, *i'*, the fillets; *k*, *k'*, corpora striata; *l*, the left thalamus; *m*, *m'*, sections of the middle peduncles of the cerebellum; *n*, section of the left inferior peduncle; *p*, left posterior pyramid; *q*, section of the corpus callosum; *s*, under

surface of the same, and below it the cavity of the fifth ventricle; *e*, left anterior pillar of the fornix; *y*, decussation of the radiating fibres with the crossing fibres of the corpus callosum.

The *main body* is derived from the anterior pyramid, from the fasciculi teretes, and from the posterior pyramid. After it has passed through the pons, and become increased in amount, it is separated into two parts in the crus cerebri by a layer of dark cineritious matter, named *locus niger*. The lower or superficial part, which is derived from the anterior pyramid, consists almost entirely of white fibres, collected into coarse fasciculi, and is named the *crusta* or *basis*, or the *fasciculated portion* of the peduncle (Foville) (fig. 388, *g*). It contains also fibres from the nerve nuclei of the medulla, and from the middle peduncle of the cerebellum. The upper part, composed principally of the fasciculus teres and posterior pyramid, is named the *tegmentum* (*b*). It is softer and finer in texture, and is mixed with much grey matter.

Still increasing in number within the peduncle, these two sets of fibres ascend to the thalamus and corpus striatum. A much larger number of fibres diverging from these bodies appear to pass to the medullary substance of the hemispheres than are contained in the crura. The actual continuity of the individual fibres spreading out in the hemisphere with those peduncular fibres which enter the substance of the thalamus and corpus striatum is doubted by many authors, and among them, by Kölliker, who believe that the connection between the fibres is effected by the branching cells of the ganglia. Some fibres certainly pass by or through the ganglia, directly to the convolutions. The

Fig. 388.—VIEW OF A DISSECTION OF THE FIBRES IN THE LEFT CEREBRAL HEMISPHERE FROM BELOW (after Mayo).  $\frac{1}{2}$

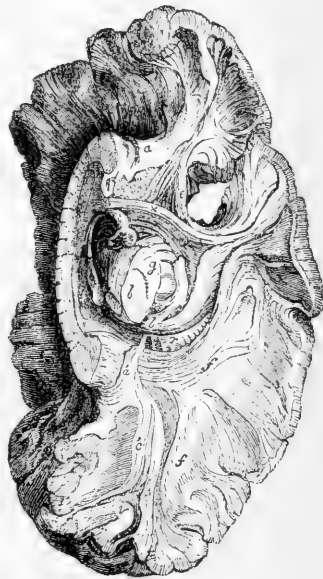
The lower part of the temporo-sphenoidal lobe has been removed. *a*, the anterior and *a'*, the posterior part of the fillet of the corpus callosum; *b*, *g*, section of the crus cerebri; *b*, tegmentum; *g*, crust separated from the last by the locus niger; *c*, fibres stretching from the back part of the corpus callosum into the posterior lobe; *e*, fasciculus uncinatus connecting the anterior and middle lobes across the Sylvian fissure; *f*, *f*, transverse fibres from the corpus callosum passing into the cerebral hemispheres; *l*, back part of the thalamus; *m*, corpus albicans; *q*, median section of the corpus callosum; *r*, radiating fibres of the hemispheres; *t*, anterior pillar of the fornix descending into the corpus albicans (*m*); *v*, collateral fibres of the convolutions;  $\times$ , anterior commissure.

posterior fibres of the tegmentum pass directly to the surface, as do also those of the crus, which separate the lenticular and caudate nuclei of the corpus striatum.

The assemblage of radiating fibres in each hemisphere might be compared to a fan, bent into the form of an incomplete hollow cone, having its concave surface turned downwards and outwards; hence the name *corona radiata* applied to them by Reil, and *fibrous cone* by Mayo (fig. 388).

The *accessory fibres* of the peduncular system are as follows:—

Fig. 388.



*a.* The superior peduncles of the cerebellum (processus ad cerebrum), which are continued up beneath the corpora quadrigemina, and form part of the tegmentum. Some of these fibres are believed by Meynert to be connected with the cells of the corpus striatum.

*b.* The bundle of fibres on each side, named the *fillet* (lemniscus) (i, fig. 387). This, which is originally derived from the anterior column of the cord, proceeds from the olivary fasciculus of the medulla oblongata, as previously described. Reinforced by fibres from the corpus dentatum of the olivary body, it ascends through the back part of the pons, still increasing in size. Appearing at the side of the cerebral peduncle, above the upper border of the pons, it divides into two portions, of which one crosses over the superior peduncle of the cerebellum to the corpora quadrigemina, meeting its fellow of the opposite side, while the other is continued upwards with the fibres of the tegmentum.

*c.* Fibres from the middle peduncles of the cerebellum are believed to turn upwards in the pons and join those of the crusta. (Meynert, Broadbent.)

*d.* The crusta also contains fibres which pass upwards from the grey nuclei in the floor of the fourth ventricle.

*e.* Other fibres accessory to the peduncles take their rise in the grey matter of the corpora quadrigemina (constituting their *brachia*), and proceed on, the anterior to the thalami optici and surface of the inner corpora geniculata; the posterior to the inner corpora geniculata and thence to the crura cerebri.

*f.* Lastly, fibres of another set, also joining the peduncles, are derived from the corpora geniculata.

2. The **transverse commissural** or connecting fibres of the cerebrum, include the following sets.

*a.* The cross fibres of the corpus callosum pass laterally into the substance of the hemispheres, some being directed upwards, whilst others spread outwards on the roof of the lateral ventricles, forming there what is named the *tapetum*. Intersecting the peduncular radiating fibres, they spread out into the hemispheres, reaching everywhere the grey matter of the convolutions. In the middle of the white centre of the hemisphere the ascending fibres preponderate, but gradually disappear towards the corpus callosum, while, on the other hand, towards the convolutions all the fibres assume an ascending direction, and the decussation disappears. It is doubtful whether any of the ascending fibres of the corona radiata enter the corpus callosum.

*b.* The *fibres of the anterior commissure*, exceedingly fine, pass laterally into the corpora striata, and bending backwards, extend a long way into the middle of the hemisphere, and are distributed to the temporo-sphenoidal lobes (fig. 388 ×).

*c.* The *fibres of the posterior commissure* run through the optic thalami, and are soon lost in the substance of the hemispheres outside these bodies.

3. The **longitudinal or collateral system** of fibres includes those of the fornix, tænia semicircularis, and striæ longitudinales of the corpus callosum, already sufficiently described; and likewise the following.

*a.* *Fibres of the gyrus fornicatus; fillet of the corpus callosum* (Mayo).—These fibres constitute the white substance of the gyrus fornicatus, and take a longitudinal course immediately above the transverse fibres of the corpus callosum (fig. 389, *a a'*). In front they bend downwards



within the gyrus to which they belong, and are connected with the anterior perforated space, being joined by certain longitudinal fibres which run along the under surface of the corpus callosum near the middle line, passing near and upon the upper edge of the septum lucidum. Behind, they turn round the back of the corpus callosum and thence descend to the point of the middle lobe, where, according to Foville, they again reach the perforated space. Offsets from these fibres pass upwards and backwards into the secondary convolutions derived from the gyrus fornicatus in the longitudinal fissure.

*b. Fasciculus uncinatus.*—Under this name is described a white bundle, seen on the lower aspect of the hemisphere, passing across the bottom of the Sylvian fissure, and connecting the frontal with the temporo-sphenoidal lobe (fig. 388, *e*). The fibres of this bundle expand at each extremity, and the more superficial of them are curved or hooked sharply between the contiguous parts of the anterior and middle lobes,—whence it has derived its name.

*c.* The convolutions of the cerebrum are connected with each other by white fibres, which lie immediately beneath the cortical substance. Some of them pass across the bottom of the sulcus between adjacent convolutions; whilst others, which are longer and run deeper, connect convolutions situated at a greater distance from one another.

Fig. 389.

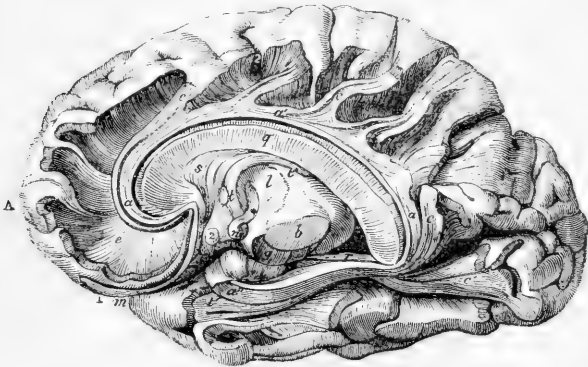


Fig. 389.—VIEW OF A DISSECTION OF THE FIBRES OF THE GYRUS FORNICATUS AND FORNIX, IN THE RIGHT HEMISPHERE (slightly altered from Foville).  $\frac{1}{2}$

A, the anterior lobe; B, the posterior lobe; *a, a', a''*, fibres of the gyrus fornicatus; *c, c'*, oblique bands of fibres of some of its accessory gyri; *b*, tegmentum, and *g*, crust of the crus cerebri, separated by the locus niger; *l*, thalamus; *m*, fissure of Sylvius; *n*, corpus albicans; *q*, median section of the corpus callosum; *s*, septum lucidum; *t*, the fornix, its anterior pillar descending into the corpus albicans, and then emerging from that at its termination (\*) in the thalamus; 1, the olfactory bulb; 2, the optic commissure.

**Foville's Views.**—The researches of Foville have led him to differ considerably from other anatomists as to the course of the fibres of the cerebrum, as will be seen from the following statement of his views.

1. The *crust* or *fasciculated portion* of each cerebral peduncle, derived from the anterior pyramid, forms by itself the peduncular fibrous cone, and is thence continued on into the radiating fibres of the cerebrum, which are destined only for the convolutions on the convex surface of the hemisphere, including the outer half of the marginal convolution of the longitudinal fissure, and the inner half of the convolution around the Sylvian fissure.

2. The fibres of the *tegmentum*, having entered the thalamus, pass on in two ways—no part of them, however, joining the radiating peduncular fibres.

*a.* One set pass upwards through the thalamus and corpus striatum, above which they then turn inwards, and, joining with those of the opposite side, form the transverse fibres of the corpus callosum. The corpus callosum is therefore regarded as a commissure of the cerebral peduncles only—none of its cross fibres spreading into the convolutions, as is generally believed.

*b.* The second set of fibres of the *tegmentum*, corresponding with the fasciculi *teretes* and part the posterior pyramids, run forwards near the middle line, along the under side of the third ventricle and corpus striatum, through the grey matter in front of the pons, to the anterior perforated space. The remaining part of the posterior pyramid forms the *tænia semicircularis*, which, passing down in front of the anterior pillar of the fornix, also reaches the perforated space. From this space more fibres are reflected upwards on the sides of the corpus striatum to join the corpus callosum.

3. As dependencies of the posterior peduncular fibres, and connected with them at the borders of the anterior perforated space, are :—

*a.* Several sets of longitudinal arched fibres, which embrace, in a series of rings, the radiating peduncular system. These are—the deep fibres of the *tænia semicircularis*—a somewhat similar band beneath the outer part of the corpus striatum—the half of the fornix with the corpus fimbriatum—the longitudinal fibres placed on the upper and under surface of the corpus callosum, and those of the septum lucidum; and, lastly, two remarkable systems of longitudinal fibres—one constituting the entire white substance of the gyrus fornicatus (from end to end), also of its accessory convolutions, and of the inner half of the marginal convolution of the longitudinal fissure; and the other, forming the white substance of the convolutions of the island of Reil, and the adjoining half of the convolution of the Sylvian fissure. None of the parts just named receive fibres from the radiating peduncular set.

*b.* In connection with this system is a thin stratum of white fibres, found upon the internal surface of the ventricles, and prolonged through the transverse fissure into the reticulated white substance covering the lower end of the gyrus fornicatus; whence it extends, as an exceedingly thin layer of medullary matter, all over the cortical substance of the hemisphere.

*c.* The anterior commissure does not reach the convolutions, but radiates upon the outer sides of the corpora striata and thalami.

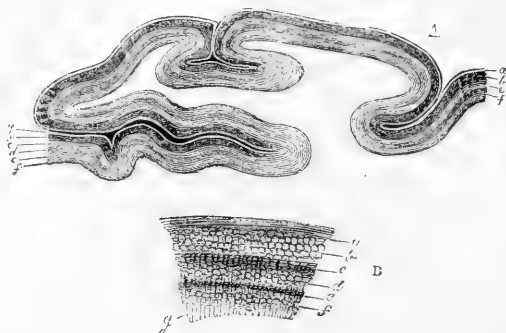
THE GREY MATTER of the cerebrum may be considered in three categories, according as it is placed (*a*) on the convoluted surface, (*b*) at the base, and (*c*) in the interior of the cerebrum.

(A.) ON THE CONVOLUTED SURFACE the grey matter forms a continuous layer divided into two and in some regions into three strata, by interposed thin layers of paler substance. In examining a section from without inwards, we meet with—1. A thin coating of white matter situated on the surface, which on a section appears as a faint white line, bounding the grey surface externally (fig. 390, *a*). This superficial white layer is not equally thick over all parts of the cortical substance, but becomes thicker as it approaches the borders of the convoluted surface; it is accordingly less conspicuous on the lateral convex aspect of the hemispheres, and more so on the convolutions situated in the longitudinal fissure which approach the white surface of the corpus callosum, and on those of the under surface of the brain. It is especially well marked on the temporo-sphenoidal lobe, near the descending cornu of the lateral ventricle, where the convoluted surface is bounded by the posterior pillar of the fornix, and it has been there described under the name of the *reticulated white substance*. 2. Immediately beneath the white layer just described, is found a comparatively thick layer of grey or reddish grey matter, the colour of which, as indeed of the grey substance generally, is deeper or lighter

according as its very numerous vessels contain much or little blood. Then follow, 3. Another thin whitish layer; and 4. A thin grey

Fig. 390.—SECTION OF THE CORTICAL SUBSTANCE OF A CEREBRAL CONVOLUTION (from Remak).

Fig. 390.



In A, the parts are nearly of the natural size. To the right of the figure, *a* and *c* are two white, and *b* and *f* two grey strata; to the left of the figure, an additional white layer, *e*, divides the first grey into two, *b* and *d*. In B, a small part of the cortical substance of a convolution is represented, magnified to show more clearly the relative position of the strata;

*a*, superficial white layer; *b*, reddish grey layer; *c*, intermediate white layer; *d*, inner part of the outer grey layer; *e*, thin white layer; *f*, inner grey layer; *g*, radiating white fibres from the medullary substance of the convolution passing into the layers of the cortical substance.

stratum. This last lies next to the central white matter of the hemisphere. In some convolutions, especially in the occipital region, a paler layer (fig. 390, B) divides the outer grey layer into two (*b* and *d*).

This cortical grey substance of the convolutions contains cells and fibres embedded in a matrix. In this matrix most observers (Ehrenberg, Henle, Boll) have found only a granular structure, while others (as Max Schultze) believe that it consists of a network of fibres. It contains nuclei, and is probably of the nature of connective tissue (neuroglia), similar to that which supports the elements in other parts of the nerve centres (p. 136), and later researches have traced in it a similar corpuscular structure.

The cells are of various forms and sizes,—spherical, angular, fusiform, pyramidal, stellate,—many of them with numerous processes. Some of these branching cells are irregular in form and position, others are more regularly pyramidal in shape, and have the apex of the pyramid turned towards the surface of the convolution. The average size of the larger pyramidal cells is  $\frac{1}{1500}$ th of an inch in diameter at the base, and each contains a rounded nucleus having an average diameter of  $\frac{1}{2500}$ th of an inch. They commonly contain a little yellowish pigment. The process from the apex may be traced for some distance towards the surface of the convolution, and is then lost. The mode of its termination is unknown. Several fine branching processes pass from the angles at the base of these cells and run outwards or towards the medullary centre. Some of these divide and ramify, the branches forming a network of fine anastomosing fibres, while others have been traced inwards undivided, and are supposed to be continuous with the axis-cylinder of a nerve fibre. The undivided axis-cylinder process, according to some observers, arises from the centre of the base of the cell, as in some other parts of the nervous system. The processes of these cells, as well as the body of the cell itself, are said to possess a distinct longi-

tudinal striation. The smaller angular corpuscles are also nucleated and provided with processes which run in various directions, and probably unite into a fine network. Rounded cells, tolerably uniform in size, (about  $\frac{1}{2500}$ th of an inch in diameter) also occur. They have no visible processes. Both these and the angular cells often appear to lie within clear spaces in the matrix.

The **fibres** radiate from the white centre of each convolution in all directions into the grey cortex, having a course for the most part perpendicular to the free surface. In passing through the grey substance they are arranged in bundles about  $\frac{1}{1800}$ th of an inch in diameter, and thus separate some of the nerve cells, giving them a columnar arrangement. The direction of the fibres varies, according to the part of the convolution in which they occur, whether near the summit or the base, and the radiating fibres are wanting in the sulcus between two convolutions, where the fibres have an arciform course, corresponding to the surface of the sulcus, and seem to connect the adjacent convolutions. Other fibres pass in all directions through the grey substance, connecting its several layers. Gerlach has called attention to the presence of bundles of medullated fibres at right angles to the radiating bundles, and forming with them a large-meshed network, in the interstices of which is a still finer network, composed of the finest non-medullated nerve fibres, and formed, he believes, by the interlacement and anastomosis of the ramifying processes from the nerve cells. The coarser fibres are said to arise from the cell-processes, either directly, or indirectly through this fine network.

**Layers of the cortex.**—The form and arrangement of the cells differ at various depths from the surface of the convolution, and as these variations possess considerable uniformity, several layers are constituted, having more or less definite histological characters. Their correspondence to the stratification distinguishable by the naked eye is, however, somewhat doubtful. Differences exist between the arrangement of the structural elements in different parts of the brain. The most common type is that which is best seen in the convolutions of the parietal lobe. In this most observers agree in recognising five layers \* (fig. 391).

1. The most external layer is narrow, about  $\frac{1}{10}$ th of the whole thickness of the grey cortex. It is pale, and contains few cells, and those are small, oval, pyramidal, stellate, with fine processes, and are embedded in a granular material. A few nerve fibres occur in it, and have been said to be connected with the nerves of the pia mater. Some observers have described a network of fine fibres throughout the layer connected with the processes of its cells. On account of the small number of nervous elements the connective tissue elements of the cortex can be seen in this layer with more distinctness than elsewhere.

2. The next layer, of nearly the same width, is composed of small thickly-set nerve cells, oval, angular, or pyramidal, with branching processes.

3. The third layer is of paler tint and much greater width. It contains pyramidal branching cells, large and small, arranged as above described, with the pointed extremities towards the surface of the convolution, and separated into groups by bundles of radiating fibres. The inner portion of the layer, in which the cells are larger and the

\* The division into five layers, described by Mevner, is substantially that of Dr. Lockart Clarke (Proc. Royal Soc., 1863).

separation into groups more distinct, has been described as a separate layer by Lockhart Clarke.

Fig. 391.

Fig. 391.—SECTION OF CEREBRAL CONVOLUTION (Meynert).


1, Superficial layer of scattered corpuscles; 2, dense layer of small angular corpuscles; 3, broader layer of pyramidal corpuscles, separated into columns by the radiating nerve-fibres; 4, narrow layer of small irregular corpuscles; 5, layer of fusiform and irregular cells in medullary centre.

4. The fourth layer is narrower, and contains many small, irregularly-shaped, often "granule-like," corpuscles, round or angular, with fine processes, placed irregularly and less distinctly separated into groups.

5. The fifth layer, of greater width than the last, is composed of fusiform and irregular cells. The fusiform corpuscles have a definite arrangement, being placed for the most part vertically at the summit of a gyrus, but parallel to the surface of a sulcus, where they correspond in direction to the arciform fibres passing from one convolution to another, with which they are said to be connected.

Beneath the last layer is the medullary centre, with which it gradually blends. The fibres of the white substance, as they radiate into the grey matter, become finer, in consequence, it is thought, of dividing or branching.

The chief deviations from this type are due to variations in the large pyramidal cells, which in places lose their characteristic size and distribution. The most conspicuous variation occurs in some parts of the occipital region, especially near the sulcus hippo-



campi. There the large pyramidal cells are few in number, and the broad layer in which they occur consequently changes its characters, being split up by layers containing few corpuscles.

In the Sylvian fissure the fusiform cells are more abundant than elsewhere, and from their number in the claustrum (p. 564) this layer has been termed by Meynert the "claustral formation." The cornu ammonis is formed almost exclusively of the large pyramidal corpuscles, and the layer in which these corpuscles occur has, in like manner, been termed the "formation of the cornu ammonis."

Fig. 392.

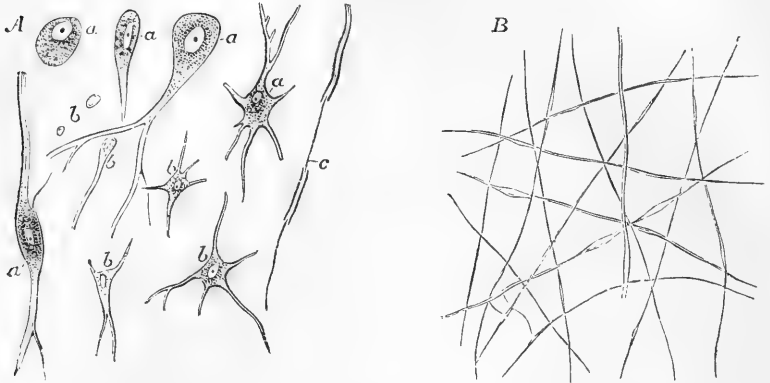


Fig. 392.—MINUTE STRUCTURE OF THE CEREBRAL SUBSTANCE (from Kölliker), MAGNIFIED 220 DIAMETERS.

A, cells and structural elements from the inner part of the cortical substance of the cerebral convolutions; *a*, larger cells, chiefly from the middle grey layer, showing a variable number of radiating processes; *b*, smaller cells from the more superficial grey layer, in part belonging to connective tissue; *c*, a nerve-fibre with its axis-filament partly exposed.

B, finest nerve-fibres from the superficial white layer of the cortical substance of a convolution, some showing the varicose condition.

(B.) GREY MATTER AT THE BASES.—The grey matter of the **lamina cinerea, tuber cinereum, and posterior perforated spot**, appears both in the base of the brain and in the floor of the third ventricle. These collections present many large stellate nerve-cells containing yellowish pigment. From the tuber cinereum a few fibres pass to the optic nerves. The lamina cinerea is connected externally with the grey matter of the anterior perforated spot, and from that point a continuity of grey matter can be traced to the swelling of the olfactory bulb.

**Olfactory tract and bulb.**—The *tuber olfactorium* (or grey root) contains pyramidal nerve-cells, similar to those of the convolutions, but more densely arranged. The *olfactory tract*, or "nerve," consists, in its upper half, of grey matter, containing large granules, nuclei, and small cells, and traversed by a few fibres, continuous with those of the middle root. The other fibres occupy the lower half of the nerve. *Olfactory bulb.*—The upper portion is occupied by medullated fibres, prolonged from the nerve and separated into superficial and deep laminae, by granular substance, the granules being large and arranged in several layers. On the under surface of the bulb is a layer of non-

medullated nerve-fibres, arranged in interlacing bundles, which give origin to the filaments that pass from the bulb to the nose. The grey substance which lies between this layer and the lower medullated layer contains numerous large granules and small angular and branching nerve-cells. The granules are most abundant in the upper portion, where they are arranged in flat groups; the nerve-cells exist chiefly in the lower part, contiguous to the gelatinous nerve-fibres, which probably arise from them.

The grey matter of the **anterior perforated spot** is continuous above with that of the corpus striatum and lenticular nucleus. Thus also continuity is established between the grey matter of the surface and that of the interior of the brain.

(C.) GREY MATTER OF THE INTERIOR.—This may be examined in the series of its deposits from behind forwards.

In the **crura cerebri**, the grey matter is collected into a dark mass, the *locus niger*, which lies between the crust and the tegmentum, and is also diffused among the fasciculi of the tegmentum; it extends through the whole width of the crus, and from the anterior edge of the pons to the corpora albicantia, and is continuous behind with the grey matter of the pons and medulla oblongata. It consists of nerve-cells, of various form, about  $\frac{1}{1500}$ th of an inch average diameter, somewhat smaller than those of the locus cœruleus, and containing much dark pigment. In the upper part of each tegmentum is a round reddish grey centre, *the nucleus of the tegmentum*, the red centre of Stilling, the superior olive of Luys, lying near the side of the third ventricle. It is due to a deposit of finely granular substance, containing branching pigmented nerve-cells.

**Corpora quadrigemina.**—In the centre of each grey matter is also found, which is more abundant, although the cells are smaller, in the posterior than in the anterior. In the former, the cells do not exceed  $\frac{1}{2000}$ th of an inch diameter, but in the latter they are fewer, larger, and more distinctly branched. The grey matter of the corpora quadrigemina is continuous in front with that of the optic thalamus, and behind with that of the pons, and, by means of the nucleus of the roof of the fourth ventricle, with the dentate nuclei of the cerebellum.

**Corpora geniculata.**—Grey matter occurs in both. The *inner* contains numerous small nerve-cells similar to those of the corpora quadrigemina, mingled with fibres which pass through it from the same source. Among them are also nuclei lying in clear spherical spaces. The *outer* is densely filled with large yellow branching and fusiform cells, and among them pass the fibres of the outer portion of the optic tract, gathered in four or six laminae, which alternate with thicker layers of the cellular substance.

The **optic thalamus** consists of grey matter which is mingled very uniformly with the interlacing fibres of which it is in great measure composed. The cells, most abundant in the anterior tubercle, are large, stellate, and pigmented, about  $\frac{1}{1200}$ th of an inch in diameter. A large proportion of them are fusiform, with two processes, and there are fewer small cells in the thalamus than in the other ganglia.

The *middle or grey commissure*, connecting the two thalami, consists of small cells, densely massed together, and containing yellow pigment.

The **corpus striatum** contains much grey matter, arranged in two chief masses. One of them, the intraventricular, is seen in the lateral

ventricle; the other, or extraventricular, situated more externally and inferiorly, is hidden in the white mass of the hemisphere. It is separated from the first by the white substance of the corona radiata, which appears on a horizontal section as a broad white band extending from behind forward between the two grey masses, and traversed by streaks of grey matter passing from one to the other. The intraventricular part, also named the nucleus caudatus (corpus striatum proper of Henle and others) is connected below with the lamina cinerea, and with that part of the grey matter of the optic thalamus which is seen in the third ventricle. The extraventricular part, named nucleus lenticularis, is continuous below with the caudate nucleus, and with the grey matter of the anterior perforated space. Striæ of grey matter pass from one centre to the other. Between the lenticular nucleus and the island of Reil, which lies opposite to it, there intervenes a thin lamelliform deposit of grey matter, the *claustrum* (Burdach), *nucleus tæniciformis* (Arnold), which, in transverse section, is seen as a thin line.

The *caudate nucleus* presents nerve-cells, large and small, in great abundance, scattered among the fibres which pass through it, and embedded in a granular substance containing nuclei. Three forms of cells have been described,—large multipolar cells, about  $\frac{1}{1200}$  inch in diameter, having branching processes, and containing rounded nuclei and pigment; similar but smaller cells, about half that size, and small elements like nuclei, but differing from the nuclei of the connective tissue. No axis-cylinder process has been distinguished in any of the cells of the corpus striatum. Peculiar clear spherical areas, containing a large granule, a nucleus, or a nucleus surrounded by granules, also occur in it (Henle).

Of the *lenticular nucleus* the two inner zones (see p. 549) contain numerous large branching nerve-cells, yellowish in tint, many of them surrounded by clear spherical areas. The striation of the outer zone is due to radiating bundles of nerve-fibres alternating with grey matter in which are clear spaces containing granules and nuclei, such as are found in the corpus striatum.

The *claustrum* contains scattered nerve-cells, most of which contain yellow pigment, and which resemble in their fusiform shape and bipolar processes the cells of the posterior vesicular columns of the spinal cord.

**Meynert's Terminology.**—According to Professor Meynert, of Vienna, the structural arrangement of the brain differs in many respects from the description commonly given of it. His terminology also differs from that in ordinary use. The details of the conclusions to which he arrives will be found in his article on the brain, in Stricker's "Handbook of Histology."

He groups the grey substance of the central nervous system into four categories.

1. The superficial grey substance of the cerebral hemispheres.
2. The grey substance of the cerebral ganglia (corpus striatum proper, lenticular nucleus, optic thalamus, corpora quadrigemina, locus niger, &c.).
3. The grey substance which surrounds the central cavities of the brain and spinal cord. Commencing above at the infundibulum, it lines the fifth ventricle and the aqueduct of Sylvius, extends through the fourth ventricle, and surrounds the canal of the spinal cord.

4. The cerebellum and its appendages, including the grey substance traversed by its commissural fibres in the anterior medullary velum and the pons.

If the whole tract of nervous conduction, from the grey matter of the cerebral convolutions, on the one hand, to the peripheral terminations of the nerves of



sense and motion on the other, be regarded as a whole, it is seen to traverse the second and third groups of grey substance, that of the cerebral ganglia, and that of the central grey substance. These divide it into three segments,—an upper, middle, and lower. These three segments are termed *projection systems*, since the function of the whole nervous tract may be considered as being to project the external world on the cerebral convolutions, and conversely the changes in the cerebral convolutions upon the motor organs.

*First projection system* (P. S. I.) between the convolutions above and the cerebral ganglia (corpus striatum, &c.) below, corresponds for the most part to the corona radiata (Stabkranz).

*Second projection system* (P. S. II.), between the cerebral ganglia above and the central grey matter below. As the latter extends from the fifth ventricle to the lower end of the spinal cord, the fibres of this system are of very various lengths.

*Third projection system* (P. S. III.) from the grey matter of the central cavities to the muscles and terminations of the sensory nerves, corresponding nearly to the peripheral nerves.

The other systems of fibres are (as commonly enumerated) the *commissural*, consisting of the corpus callosum and anterior commissure, which unite identical regions of different hemispheres, and the *association system* of fibres which unite non-identical regions of the same hemisphere.

In the passage from P. S. I. to P. S. II., which is effected in the cerebral ganglia, the fibres undergo considerable reduction in number, the fibres of the crus being much fewer than those of the corona radiata. On the other hand, in the transition from P. S. II. to P. S. III., in the grey substance of the central cavities, the fibres undergo a great increase in number: the peripheral nerve-fibres being much more numerous than those of the crus or cord.

The division of the fibres of the crus into two portions, an anterior or lower *crusta* (Fuss), and an upper or posterior *tegmentum* (Haube), may be extended to the cerebral ganglia in which the fibres of each portion respectively terminate above.

The ganglia connected with the crusta are the lenticular nucleus, the corpus striatum proper, and locus niger. They are connected (by P. S. I.) chiefly with the anterior part of the brain, and subserve chiefly voluntary motion.

The ganglia of the tegmentum are the optic thalami, corpora quadrigemina, corpora geniculata interna, corpora albicantia, and subserve chiefly reflex movements.

Certain fibres, thought to be sensory, pass up from the posterior columns of the cord, and form the posterior and outer fasciculi of the crusta of the crus cerebri. They pass through no ganglion, but ascend behind the optic thalamus to the cortex of the temporal lobes.

The cerebellar grey substance is connected with that of the cerebrum by two groups of fibres.

1. The connecting arm (Bindearm), processus a cerebello ad cerebrum, arises from the corona radiata, and passes under the thalamus and corpora quadrigemina, to mix with the fibres of the tegmentum, and reach the cerebellum after a total decussation.

2. The size of the crusta above the pons, is much greater than that of the motor tract below; and this is due to the fact that some of its fibres turn aside in the pons and reach the cerebellum through the middle peduncle.

The union of the cerebellum with the spinal cord is also double, through the fasciculus cuneatus and fasciculus gracilis, from the posterior column, and the restiform body, from the lateral column.

The large size of the pons is due to the interlacement of the arms of the cerebellum with the projection system.

#### ORIGIN OF THE CRANIAL NERVES.

The surface attachments of the cranial nerves remain to be described, and it will be convenient to recapitulate at the same time their deep connections.

The **first or olfactory nerve**, or tract, is attached to the under surface of the frontal lobe, in front of the anterior perforated space, by three roots, named external, middle, and internal.

The *external or long root* passes outwards as a band of white fibres, along the anterior margin of the perforated space, towards the posterior border of the fissure of Sylvius, where it disappears. Its fibres have been traced by different observers to the island of Reil, the optic thalamus (Valentin), and to a nucleus in the substance of the temporo-sphenoidal lobe, in front of the anterior extremity of the hippocampus (Rolando, Luys, Foville).

The *middle or grey root* is of pyramidal shape, and consists of grey matter on the surface continuous with the adjacent grey substance of the anterior perforated space. Within it are white fibres, which have been said to go to the corpus striatum, or to join the fibres of the inner root.

Fig. 393.

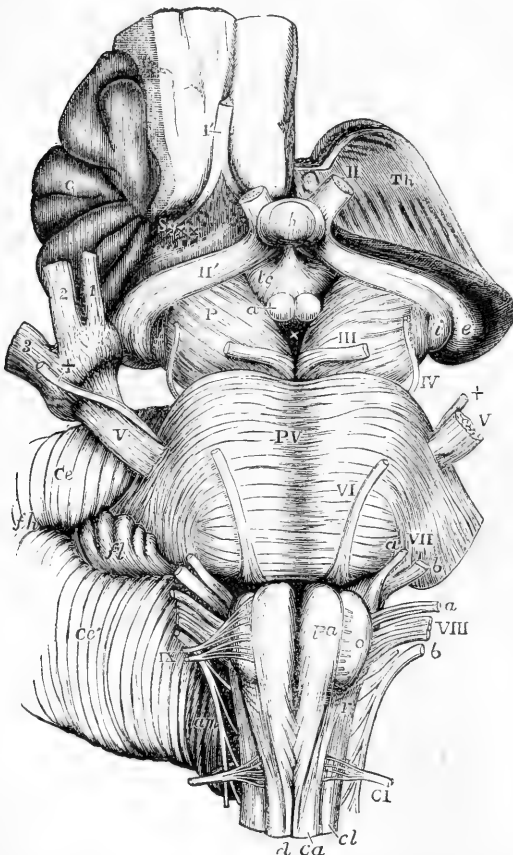


Fig. 393. — VIEW FROM BELOW OF THE CONNECTIONS OF THE PRINCIPAL NERVES WITH THE BRAIN (Allen Thomson).

The full description of this figure will be found at page 534. The following references apply to the roots of the nerves.

I, the right olfactory tract cut short and lying in its groove; II, the left optic nerve in front of the commissure, which is concealed by the pituitary body (*b*); II'. The left tract is seen passing back into *e*, the external, and *i*, the internal corpus geniculatum; III, the left oculo-motor nerve; IV, the fourth or trochlear nerve; V, the greater root of the fifth nerve; +, the lesser or motor root; on the right side this + is placed on the Gasserian ganglion; VI, the sixth nerve; VII *a*, the facial (the origin of which is shown as extending downwards too far); VII *b*, the auditory nerve; VIII *a*, the pneumo-gastric nerve; VIII *b*, the glosso-pharyngeal; VIII *b*, the spinal accessory nerve; IX, the hypoglossal nerve; C I, the first cervical nerve.

With this fig. 385 may be compared.

The *inner root*, not always distinct, is composed of white fibres from the inner and posterior part of the frontal lobe. They are said to be

connected with the gyrus fornicatus, or to cross over to the opposite side.

**Second or optic nerves.** Each optic tract may be traced backwards from the commissure, across the crus, to the under surface of the optic thalamus, at the posterior extremity of which it ends by blending with the corpora geniculata. Its fibres may be traced into the corpora geniculata, the optic thalamus, and the anterior of the corpora quadrigemina. Those which enter the thalamus pass, some through the corpora geniculata, some beneath the inner corpus geniculatum, between it and the crus (as the middle root of some authors) to reach the cells of the lower stratum of the thalamus. A few fibres arise in the base of the brain, from the lamina cinerea, and from a collection of grey matter on the outer side of the tuber cinereum.

**Third or oculo-motor nerve.** Each nerve arises from the inner surface of the crus cerebri, immediately in front of the pons, by a number of fasciculi which are attached to the surface in an oblique line.

The fibres, diverging, pass backward through the substance of the tegmentum of the crus, some through the locus niger, some through the tegmental nucleus, to reach the grey nucleus in which the majority of them end. This is a column of multipolar nerve-cells, beneath the grey floor of the aqueduct of Sylvius, below the corpora quadrigemina, and extending beneath the upper part of the fourth ventricle.

The **fourth or trochlear nerve**, which appears in the base at the outer side of the crus cerebri, arises from the surface of the valve of Vieussens, immediately behind the corpora quadrigemina, and close to the middle line.

In the substance of the valve, the fibres of each root divide into three groups. Of these, one, *ascending*, passes obliquely forwards and upwards in the wall of the aqueduct of Sylvius, to end in the posterior part of the nucleus beneath the corpora quadrigemina, the anterior part of which gives origin to the fibres of the third nerve. A second group of *descending* fibres pass on the outer side of the locus cœruleus to the neighbourhood of the nucleus of the fifth nerve. A third group of *decussating* fibres cross to the other side, to join the ascending or descending fibres of the other nerve.

The **fifth nerve** (*trifacial* or *trigeminal*) arises from the side of the pons Varolii, nearer to the upper than to the lower border. It consists of two parts of unequal size, the smaller, motor, root being separated from the other by a few transverse fibres of the pons.

Both roots curve backwards and downwards in the substance of the pons, towards the outer angle of the floor of the fourth ventricle, near the fovea centralis. The fibres of the sensory root turn outwards, most of them to end in a collection of nerve-cells on their outer side, continuous below with the grey tubercle of Rolando. Some fibres pass inwards beneath the floor of the fourth ventricle to the middle line. Others descend in front of the nucleus, to the lower part of the medulla. The fibres of the small root go to a group of large multipolar nerve-cells, to the inner side of the fibres of the nerve, and near the outer angle of the floor of the fourth ventricle. The prolongation downwards of this nucleus (seen at Vm, in fig. 359) extends to the lower part of the medulla.

The **sixth or abducent nerve** arises from the front of the anterior pyramid, close to the lower edge of the pons, to which it is some-

times adherent. Its fibres pass backwards and a little outwards, to reach the nucleus common to this and the facial nerve, a column of large multipolar nerve-cells, beneath the eminentia teres in the middle of the floor of the fourth ventricle. In the inner part of this nucleus most of the fibres end.

The **facial nerve** (*portio dura of the seventh pair*) appears at the lower border of the pons Varolii in a line with the attachment of the fifth nerves. It emerges from the medulla oblongata, in the outer part of the depression between the olivary body and the diverging restiform body (inferior peduncle of cerebellum), and is often firmly adherent, as a flattened band, to the lower edge and even for a short distance to the upper surface of the pons. On its outer side is the auditory nerve. A separate fasciculus of the facial nerve (*intermediate part*) is sometimes attached to both auditory and facial nerves.

The fibres pass backwards and inwards through the medulla towards the floor of the fourth ventricle, where many end in the outer part of the common nucleus, just described as lying beneath the eminentia teres in the middle of the fourth ventricle. A considerable number of fibres pass above the nucleus and turn round it, just beneath the surface of the ventricular floor, to descend as a compact bundle on the inner side of the common nucleus; lower down these fibres diverge outwards and forwards to the superior olivary body and adjacent lower part of the nucleus of the motor root of the fifth nerve (fig. 359).

The **auditory nerve** (*portio mollis of the seventh pair*) appears at the lower edge of the pons on the outer side of and close to the facial nerve. It is also united to the lower edge of the pons opposite the inner side or middle of the restiform body from which it emerges. A large and conspicuous portion of the nerve curves outwards round the restiform body.

The fibres of the nerve divide into two corresponding bundles, one the *posterior*, winds round the restiform body, with which it is connected by some fibres of origin, to reach the inner auditory nucleus, a large collection of nerve cells, in the outer side of the lower part of the floor of the fourth ventricle. The other, or *anterior* division, passes, a little higher up, through the substance of the restiform body to end chiefly in the outer auditory nucleus, a network of cells and fibres, to the outer side of the inner nucleus and of this part of the nerve. Some of its fibres go to the inner nucleus, others pass with the restiform body to the cerebellum. Both portions contain much grey matter, which on the posterior part forms a pyriform swelling. The trunk is also joined by some fibres from the striæ medullares.

The **glosso-pharyngeal nerve** arises from the side of the medulla by a series of five or six roots attached in a vertical line to the surface of the restiform body, the highest being close to the auditory nerve. The fibres pass backwards and inwards, through the medulla, to reach a column of nerve-cells placed deeply beneath the lower and outer part of the floor of the fourth ventricle, between the highest part of the vagal nucleus and the lower part of the internal auditory nucleus.

The **pneumogastric or vagus nerve** arises from the side of the medulla by a series of twelve or more roots, which are attached to the restiform body in a vertical line below those of the glosso-pharyngeal nerve. The fibres pass backwards to a large group of nerve cells beneath the lowest part of the floor of the fourth ventricle, where they

cause a prominence on the surface. At the point of the calamus scriptorius the nuclei are in contact at the middle line, but a little higher up are separated by the hypoglossal nuclei.

The **spinal accessory nerve** arises by a long series of roots, the upper of which are attached to the side of the medulla, below those of the pneumogastric, while the remainder arise from the cervical portion of the spinal cord, as low down as the sixth or seventh pair of nerves. The upper roots pass inwards to a nucleus which lies on each side at the back of, and close to, the central canal, and is continuous, above, with the nucleus of the pneumogastric nerve. The lower roots pass through the lateral columns of the cord to the grey substance and curve forwards into the anterior cornu.

The **hypoglossal nerve** arises by a series of fine roots attached to the furrow between the anterior pyramid and the olivary body. They pass backwards, through the inner part of the olivary body, to reach their nucleus, a long column of nerve cells, the lower part of which lies in front of the central canal on each side, and, higher up, comes forward to form a prominence on the floor of the fourth ventricle, close to the middle line.

## THE MEMBRANES OF THE BRAIN AND SPINAL CORD.

The cerebro-spinal axis is protected by three *membranes*, named also *meninges*. They are:—1. An external fibrous membrane, named the *dura mater*, which closely lines the interior of the skull, and forms a loose sheath in the spinal canal; 2. An internal areolo-vascular tunic, the *pia mater*, which accurately covers the brain and spinal cord; and 3. An intermediate membrane, the *arachnoid*, which lies over the *pia mater*, the two being in some places in close connection, in others separated by a considerable space.

### THE DURA MATER.

The *dura mater* is a very strong dense inelastic fibrous tunic of considerable thickness. Its inner surface, turned towards the brain and spinal cord, is smooth and lined with epithelium, which has been generally regarded as constituting a parietal reflection of the arachnoid membrane. The space between the *dura mater* and arachnoid, formerly in like manner regarded as the sac of the arachnoid, has been conveniently termed the *subdural space*. The outer surface of the *dura mater* is connected with the surrounding parts, in a somewhat different manner in the cranium and in the spinal canal.

In the cranium it adheres to the inner surface of the bones, and forms their internal periosteum. The connection between the two depends, in a great measure, on blood-vessels and small fibrous processes, which pass from one to the other; and the *dura mater*, when detached and allowed to float in water, presents a flocculent appearance on its outer surface, in consequence of the torn parts projecting from it. The adhesion between the membrane and the bone is more intimate opposite the sutures, and also at the base of the skull, which is uneven, and perforated by numerous foramina, through which the *dura mater* is prolonged to the outer surface, being there continuous with the pericranium. The fibrous tissue of the *dura mater* becomes blended with the areolar sheath of the nerves at the foramina which give exit to them.

In leaving the skull, the dura mater is intimately attached to the margin of the foramen magnum; but within the vertebral canal it forms a loose sheath around the cord (*theca*), and is not adherent to the bones, which have an independent periosteum. Towards the lower end of the canal, a few fibrous slips proceed from the outer surface of the dura mater to be fixed to the vertebræ. The space intervening between the wall of the canal and the dura mater is occupied by loose fat, by watery areolar tissue, and by a plexus of spinal veins.

Fig. 394.

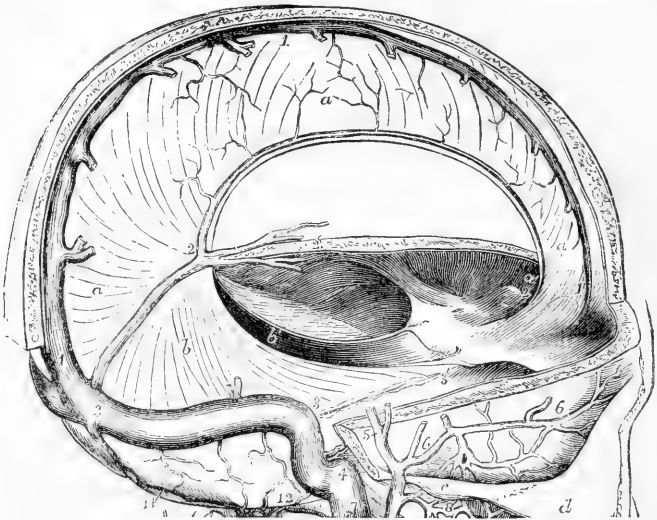


Fig. 394.—THE CRANIUM OPENED TO SHOW THE FALX OF THE CEREBRUM, AND TENTORIUM OF THE CEREBELLUM. (Allen Thomson.)  $\frac{1}{2}$

*a*, right side of the falx cerebri; *a'*, its anterior narrow part attached to the crista galli; *b*, tentorium cerebelli of the right side, united to the base of the falx cerebri from 2 to 3, in the line of the straight sinus, and attached to the superior border of the petrous bone between 3 and 3'; *b'*, aperture between the right and left divisions of the tentorium for the isthmus cerebri; 1, 1, the superior longitudinal sinus; 2, 2, the inferior; 3, 3, the lateral sinus; 3, 3', the superior petrosal sinus; 3', is close to the anterior clinoid process.

Opposite each intervertebral foramen the dura-matral theca presents two openings, placed side by side, which give passage to the two roots of the corresponding spinal nerve. It is continued as a tubular prolongation on the nerve, and is lost in its sheath. Besides this, it is connected with the circumference of the foramen by areolar tissue.

The fibrous tissue of the dura mater, especially within the skull, is divisible into two distinct layers, and at various places these layers separate from each other and leave intervening channels, called *sinuses*. These sinuses, which have been elsewhere described, are canals for venous blood, and are lined with a continuation of the internal membrane of the veins.

The dura mater also sends inwards into the cavity of the skull three strong membranous *processes*, or *partitions*, formed by duplication of its inner layer. Of these, one descends vertically in the median plane, and

is received into the longitudinal fissure between the two hemispheres of the cerebrum. This is the *falx cerebri*. The second is an arched or vaulted partition, stretched across the back part of the skull, between the cerebrum and the cerebellum; it is named the *tentorium cerebelli*. Below this, another vertical partition, named *falx cerebelli*, of small extent, passes down between the hemispheres of the cerebellum.

The *falx cerebri* is narrow in front, where it is fixed to the crista galli, and broader behind, where it is attached to the middle of the upper surface of the tentorium, along which line of attachment the straight sinus is situated. Along its upper convex border, which is attached above to the middle line of the inner surface of the cranium, runs the superior longitudinal sinus. Its under edge is free, and reaches to within a short distance of the corpus callosum, approaching nearer to it behind. This border contains the inferior longitudinal sinus.

The *tentorium*, or *tent*, is elevated in the middle, and declines downwards in all directions towards its circumference, thus corresponding in form with the upper surface of the cerebellum. Its inner border is free and concave, and leaves in front of it an oval opening, through which the isthmus encephali descends. It is attached behind and at the sides by its convex border to the horizontal part of the crucial ridges of the occipital bone, and there encloses the lateral sinuses. Farther forward it is connected with the upper edge of the petrous portion of the temporal bone—the superior petrosal sinus running along this line of attachment. At the point of the pars petrosa, the external and internal borders meet, and may be said to intersect each other—the former being then continued inwards to the posterior, and the latter forwards to the anterior clinoid process.

The *falx cerebelli* (*falx minor*) descends from the middle of the posterior border of the tentorium, with which it is connected, along the vertical ridge named the internal occipital crest, towards the foramen magnum, bifurcating there into two smaller folds. Its attachment to the bony ridge marks the course of the posterior occipital sinus, or sinuses.

**Structure.**—The dura mater consists of white fibrous and elastic tissue, arranged in bands and laminae, crossing each other. In the spinal dura mater the bundles have a more nearly parallel arrangement. A layer of pavement epithelium exists upon its inner surface, which was formerly regarded as belonging to the serous membrane lining it. A similar layer of epithelium also covers both sides of the spinal dura mater. The cranial membrane is traversed by numerous blood-vessels which are chiefly destined for the bones. An extensive system of lymph canals has been described, formed chiefly by the spaces between the fibrous trabeculae, and bounded by cellular membranes. Minute nervous filaments, derived from the fourth, fifth, and eighth cranial nerves, and from the sympathetic, are described, as entering the dura mater of the brain. Nervous filaments have likewise been traced in the dura mater of the spinal column. (Luschka and Rüdinger, quoted by Hyrtl.)

#### THE PIA MATER.

The *pia mater* is a delicate, fibrous, and highly vascular membrane, which immediately invests the brain and spinal cord.

Upon the hemispheres of the brain it is applied to the entire cortical surface of the convolutions, and dips into all the sulci, which thus

contain a double layer. From its internal surface numerous small vessels enter the substance of the brain, and hence this inner surface is very flocculent, and is named *tomentum cerebri*. On the cerebellum a similar arrangement exists, but the membrane is finer, and the double fold only distinct in the larger sulci. The pia mater is also prolonged through the transverse fissure into the lateral ventricles, and there forms the velum interpositum and choroid plexus. It is also prolonged into the fourth ventricle, where it forms the choroid plexus of the fourth ventricle.

On the *spinal* cord the pia mater has a very different character from that which it presents on the encephalon, so that it has even been described by some as a different membrane under the name *neurilemma of the cord*. It is thicker, firmer, less vascular, and more adherent to the subjacent nervous matter: its greater strength is owing to its containing fibrous tissue, which is arranged in longitudinal shining bundles. A fold of this membrane dips down into the anterior fissure of the cord, and serves to conduct blood-vessels into that part. A thinner process passes into the greater part of the posterior fissure. At the roots of the nerves, both in the spine and in the cranium, the pia mater becomes continuous with the neurilemma.

The pia mater of the cord presents a conspicuous fibrous band, running down in front over the anterior median fissure. This was named by Haller, *linea splendens*.

**Structure.**—The pia mater consists of interlaced bundles of connective tissue, having a more regular arrangement in the outer and inner layers, while in the middle is a network of fine elastic fibres. On the cord the outer fibres are for the most part parallel and longitudinal, and the inner network consists of peculiar stiff fibres bending suddenly and enclosing angular interspaces. Beneath them is a fine membrane continuous with the neuroglia of the cord. On the cord pigmented cells are sometimes scattered among the elastic fibres. The pia mater contains great numbers of blood-vessels, which subdivide in it before they enter the nervous substance. Each vessel lies in a canal, the walls of which are composed of a more dense arrangement of the fibres of the membrane (perivascular canal). The diameter of the canal may be two or three times that of the contained vessel. A similar sheath, derived from the pia mater, accompanies the vessel into the substance of the brain. At its commencement it is loose and funnel-shaped and can be injected from the subarachnoid cavity. On the cerebrum the inner layer of the pia mater is adherent to the cortical substance of the convolutions, but on the cerebellum a space exists between the two, traversed by fibres which pass from the cerebellum to the pia mater. This space is continuous with the intervals between the perivascular sheaths and the brain substance.

According to Fohmann and Arnold, the pia mater contains numerous lymphatic vessels. Purkinje describes a retiform arrangement of nervous fibrils, derived, according to Kölliker and others, from the sympathetic, the third, sixth, facial, pneumogastric, and accessory nerves.

The spinal pia mater is supplied by nerves from the sympathetic.

#### THE ARACHNOID MEMBRANE.

The *arachnoid* is a delicate membrane which invests the brain and spinal cord, outside the pia mater, and much less closely than that mem-



brane. It passes over the various eminences and depressions on the cerebrum and cerebellum, without dipping down into the sulci and smaller fissures. Beneath it, between it and the pia mater, is a space (subarachnoid space) in which is a considerable quantity of fluid (subarachnoid fluid).

The outer surface of the arachnoid is in contact with the smooth inner surface of the dura mater, the epithelium upon which has been regarded as a parietal layer of the arachnoid, closely united with the dura mater. At certain recesses, and near the longitudinal sinus, a small amount of loose connective tissue beneath the epithelium may be distinguished from the dense fibres of the dura mater. With this epithelium the arachnoid membrane (or visceral layer, as it was termed) has been thought to be continuous at the various foramina, the two thus constituting a closed sac similar to that of the pleura. But since the inner surface of the dura mater in the greater part of its extent does not present any distinct tissue which can be regarded as an attached membrane, Kölliker, Henle, and others consider that there is no justification for the assumption of a parietal layer of the arachnoid. Moreover recent investigations into the relation between the arachnoid and dura mater on the nerve roots as they leave the cranio-vertebral cavity have shown that there is no such reflection of the arachnoid on to the dura mater as had been supposed. (Axel Key and Retzius).

The **subarachnoid space** is wider and more evident in some positions than in others. Thus, in the longitudinal fissure, the arachnoid does not descend to the bottom, but passes across, immediately below the edge of the falx, at a little distance above the corpus callosum. In the interval thus left, the arteries of the corpus callosum run backwards along that body. At the *base* of the brain and in the *spinal canal* there is a wide interval between the arachnoid and the pia mater. In the base of the brain, this subarachnoid space extends in front over the pons and the interpeduncular recess as far forwards as the optic nerves, and behind it forms a considerable interval between the cerebellum and the back of the medulla oblongata. In the spinal canal it surrounds the cord, being there of considerable extent. It is occupied, in both brain and cord, by trabeculæ and thin membranous extensions of delicate connective tissue, connected on the one hand with the arachnoid, and on the other with the pia mater. This tissue is most abundant where the space between the two membranes is least. It is dense in the neighbourhood of the vessels, and is continuous with the tissue of their walls.

The subarachnoid space communicates with the ventricles of the brain by means of the foramen of Magendie, the opening into the lower part of the fourth ventricle, through the membrane which closes it (p. 513). Two other openings through this membrane exist, one on each side, behind the upper roots of the glosso-pharyngeal nerve into the pouch-like extension of the membrane beneath the flocculus (Mierzejewsky).

A certain quantity of *fluid* is contained between the arachnoid membrane and the dura mater; but it has been shown by Magendie that the chief part of the cerebro-spinal fluid is lodged in the subarachnoid space in the meshes of the trabecular tissue.

The ligamentum denticulatum divides the spinal subarachnoid space into anterior and posterior portions. Magendie also pointed out the

existence of a sort of septum (*septum posticum*), dividing the subarachnoid space at the back of the cord, the relations of which have been carefully studied by Axel Key and Retzius. It is a thin membranous partition, which passes in the median plane from the pia mater covering

Fig. 395.

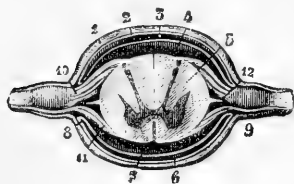


Fig. 395.—TRANSVERSE SECTION OF THE SPINAL CORD AND ITS ENVELOPES (from Sappey after Hirschfeld and Leveillé).

1, dura mater or theca ; 2, supposed parietal layer of the arachnoid membrane ; 3, internal or loose arachnoid ; 4 and 7, subarachnoid cavity or space ; 5, hinder part of the antero-lateral column ; 6, subdural space between the arachnoid and the dura mater ; 8, supposed reflection of the one fold of the arachnoid into the other ; 9, sheath furnished to the spinal nerve by the

dura mater ; 10, posterior ganglionic root ; 11, smaller anterior root ; 12, section of the ligamentum denticulatum. This figure does not show the septum which posteriorly divides the subarachnoid space into right and left parts : this would be placed between the arachnoid at 3, and the pia mater covering the posterior surface of the cord.

the posterior median fissure of the cord to the opposite part of the loose portion of the arachnoid membrane. It is most perfect in the cervical region, being incomplete below, and consists of numerous fine lamellæ, enclosing between them small spaces, within which run the larger blood-vessels. Trabeculæ connect the nerve-roots with the inner surface of the arachnoid, and in the dorsal region fine membranes extend between the posterior nerve-roots and the posterior septum.

The nerves as they pass from the brain and spinal cord receive two sheaths, an outer from the dura mater, and an inner from the arachnoid. Upon the optic nerve these sheaths remain distinct and separate, so that the space which each encloses may be injected, the outer from the subdural, the inner from the subarachnoid space. On the other nerves the arachnoidal sheath soon ceases, and the single sheath may be injected from either the subdural or subarachnoid cavity. Separate sheaths surround each bundle of the larger nerves, and the injection passes readily along the nerves even as far as the limbs.

There thus exists a continuity between the ventricles of the brain, the subarachnoid space, the perivascular canals of the cerebral substance, and the perineural spaces within the nerve sheaths.

**Structure.**—When examined under the microscope, the arachnoid is found to consist of distinct riband-like bundles of fine fibrous tissue interlaced with one another. The intervals between these bundles are filled up by delicate membranes, composed of expanded cells, the nuclei of which persist and are scattered over the structure. Several layers of this tissue, arranged in a complex way, constitute the arachnoid membrane. The subarachnoid trabeculæ consist of bundles of similar fine fibrillar tissue, each of which is surrounded by a delicate nucleated sheath, also composed of cells, and continuous with the intertrabecular cell-membranes of the arachnoid itself. Some of the finer trabeculæ are said to be surrounded by a spiral fibre. The subarachnoid membranous expansions have a similar structure. Volkmann has described a rich plexus of nerves in the arachnoid membrane of certain ruminants. Kölliker has failed to detect their presence; but they have been again described by Boehdalek, who traces them to the portio minor of the

fifth, the facial, and accessorius nerves; and they have likewise been followed by Luschka.

**Cerebro-spinal fluid.**—This is a very limpid serous fluid, which occupies the subarachnoid space. When collected immediately after death, its quantity was found by Magendie in the human subject to vary from two drachms to two ounces. It is slightly alkaline, and consists, according to an analysis by Lassaigne, of 98·5 parts of water, the remaining 1·5 per cent. being solid matter, animal and saline. In experiments made on the dog, it was found by Magendie to be reproduced in thirty-six hours, after it had been drawn off by puncturing the membranes at the lower part of the cord. When pressure is made upon the brain, the quantity of fluid in the spinal subarachnoid space is increased, and conversely, it may be forced from the spinal cavity upwards into the cranium.

**Ligamentum denticulatum.**—This is a narrow fibrous band which runs along each side of the spinal cord in the subarachnoid space, between the anterior and posterior roots of the nerves, commencing above at the foramen magnum, and reaching down to the lower pointed end of the cord (fig. 395, 12, and fig. 345). By its inner edge this band is connected with the pia mater of the cord, while its outer margin is widely denticulated; its denticulations are attached by their points to the inner surface of the dura mater, and thus serve to support the cord along the sides, and to maintain it in the middle of the cavity. The first or highest denticulation is fixed opposite the margin of the foramen magnum, between the vertebral artery and the hypoglossal nerve; the others follow in order, alternating with the successive pairs of spinal nerves. In all, there are about twenty-two of these points of insertion. The denticulations in the lower cervical region are very long, and ascend slightly to their attachments. At the lower end, the ligamentum denticulatum may be regarded as continued into the terminal filament of the spinal cord, which thus connects it to the dura mater at the lower end of the sheath. The free edge, in the intervals between the denticulations, is slightly thickened, and, in the body, is closely applied to the inner surface of the arachnoid, with which it is often directly connected by fine trabeculæ. The denticulations do not perforate the arachnoid but receive from it funnel-shaped sheaths, which accompany them to the inner surface of the dura mater. (Axel Key and Retzius, Max Schultze's Archiv. 1873).

**Structure.**—It consists of white fibrous tissue, mixed with many exceedingly fine elastic fibres which are seen on applying acetic acid. Several layers of fine connective tissue trabeculæ may be traced: they are surrounded by sheaths, which are composed of delicate nucleated cells, and here and there expand into membranes. It is continuous on the one hand with the fibrous tissue of the pia mater, and on the other with that of the dura mater.

**Glandulæ Pacchioni.**—Upon the external surface of the dura mater, in the vicinity of the longitudinal sinus, are seen numerous small pulpy looking elevations, generally collected into clusters, named glands of Pacchioni. The inner surface of the calvarium is marked by little pits, which receive these prominences. Similar excrescences are seen on the internal surface of the dura mater, and upon the pia mater on each side of the longitudinal sinus, and also projecting into the interior of that sinus. Occasionally they are found also in other situations.

On a careful examination of the connections of these bodies it will be found that the elevations found on the outer surface of the dura mater and within the longitudinal sinus, in no instance take origin in those positions, but that they are grape-like bodies which are attached more deeply, and in their growth have perforated the dura mater. Their precise origin and nature were long the subject of conflicting opinions, but it has been satisfactorily shown by Luschka that they are only an enlarged condition of normal villi of the arachnoid, and that no other structure is involved in their formation. On each side of the sinus, and communicating with it, are large venous spaces in the dura mater; into these the villi project even in new-born animals, and those which perforate the dura mater and appear on the surface have their inner parts in such spaces. Each villus is covered by an epitheliated membrane, continuous with the arachnoid. Outside this is another fine membranous sheath, proceeding from the dura mater, and the interval between the two is continuous with the subdural space. Within the villus is a spongy trabecular tissue, continuous with the subarachnoid tissue, and of similar structure. (Luschka, in Müller's Archiv. 1852; and "Die Adergeflechte des Menschlichen Gehirns," 1855. See also Cleland "On Tumours of the Dura Mater, &c." in the Glasgow Medical Journal, 1863. Axel Key and Retzius, Nordiskt Med. Arkiv. 1870—1874, and Virchow's Jahresbericht.)

#### BLOOD-VESSELS OF THE BRAIN AND SPINAL CORD.

The origin and course of these vessels have already been described in the Section Angiology. In passing to their distribution the several arteries, having passed across the arachnoid cavity, enter the subarachnoid space and then divide and subdivide into branches, which, in their farther ramification in the nervous centres, are supported by the pia mater, and, it may be remarked, are more deeply placed in the various fissures and sulci than the small veins, which do not accompany the arteries, but pursue a different course and are seen upon the surface of the pia mater.

Moreover, it is to be observed that, whilst the main branches of the arteries are situated at the base of the brain, the principal veins tend towards the upper surface of the hemispheres, where they enter the superior and inferior longitudinal sinuses: the veins of Galen, however, coming from the lateral ventricles and choroid plexuses, run backwards to the straight sinus.

#### BLOOD SUPPLY OF THE BRAIN.

It may be convenient here to recapitulate the sources of the blood-supply to the several parts of the encephalon.

The *medulla oblongata* and *Pons Varolii* are supplied by branches from the anterior spinals, the vertebrals, the basilar and the posterior cerebrals. The branches enter the pons and medulla in two sets, lateral or radicular, and median, —the latter passing in the septum to the grey matter on the upper surface.

**Cerebellum.**—The *under surface* is supplied by the posterior inferior cerebellar arteries from the vertebrals, and the anterior inferior from the basilar. The *upper surface* is supplied chiefly by the superior cerebellar arteries from the basilar: its posterior portion from the posterior inferior cerebellar.

**Cerebrum.**—*Convulsions, outer surface, frontal lobe.*—The superior frontal and anterior two-thirds of the middle frontal convolution, with the upper extremity of the ascending frontal, are supplied by the anterior cerebral. The

inferior frontal convolution, the posterior extremity of the middle frontal, and the greater part of the ascending frontal convolutions are supplied by the middle cerebral. The orbital surface is supplied, outside the orbital sulcus, by the middle cerebral: within that sulcus (including the olfactory bulb) by the anterior cerebral.

*Parietal lobe.*—All the convolutions of the parietal lobe are supplied by the middle cerebral artery.

The *occipital lobe* is supplied by the posterior cerebral artery.

*Temporo-sphenoidal lobe.*—The superior, and upper part of the middle temporo-sphenoidal convolutions are supplied by the middle cerebral artery. The lower portion of the lobe by the posterior cerebral.

*Inner surface.*—The whole anterior and upper portion, as far back as the parieto-occipital fissure, is supplied by the anterior cerebral artery; the cuneate lobule and the occipito-temporal region by the posterior cerebral.

The *grey substance at the base* of the cerebrum is supplied by small twigs from the adjacent vessels of the circle of Willis, or the commencing cerebral vessels.

*Central parts—corpus striatum.*—Both nucleus caudatus and nucleus lenticularis are supplied almost exclusively by the middle cerebral artery. The anterior part of the caudate nucleus only being supplied by the anterior cerebral.

The *optic thalamus* is supplied by the posterior cerebral artery, except its inner and outer portion, which is supplied by the middle cerebral.

The corpora quadrigemina and corpora geniculata are both supplied by the posterior cerebral artery.

For further details on the subject the reader is referred to Vol. I., p. 378, and to a series of articles by M. Duret in the Archives de Physiologie for 1873 and 1874.

## SIZE AND WEIGHT OF THE ENCEPHALON.

In the following table, illustrating the average weight of the adult male and female brain, the results obtained by Sims, Clendinning, Tiedemann, and J. Reid have been brought together in such a form as to exhibit in groups the most commonly prevailing weight; the numbers being also simplified by the omission of fractions. (Sims, "Medico-Chirurg. Trans." vol. xix., pp. 353—7; Clendinning, "Medico-Chirurg. Trans.," vol. xxi., pp. 59—68; Tiedemann, "Das Hirn des Negers," Heidelberg, 1837, pp. 6. 7; Reid, "London and Edinburgh Monthly Journal of Medical Science," April, 1843, p. 298, &c.)

According to Table A, the maximum weight of the adult male brain, in a series of 278 cases, was 65 oz., and the minimum weight 34 oz. In a series of 191 cases, the maximum weight of the adult female brain was 56 oz., and the minimum 31 oz.; the difference between the extreme weights in the male subject being no less than 31 oz., and in the female 25 oz. By grouping the cases together in the manner indicated by brackets, it is shown that in a very large proportion the weight of the male brain ranges between 46 oz. and 53 oz., and that of the female brain between 41 oz. and 47 oz. The *prevailing* weights of the adult male and female brain may therefore be said to range between those terms; and, by taking the mean, an *average* weight is deduced of 49½ oz. for the male, and of 44 oz. for the female brain,—results which correspond closely with the statements generally received.

Although many female brains exceed in weight particular male brains, the general fact is sufficiently shown, that the adult male encephalon is heavier than that of the female,—the average difference being from 5 to 6 oz. This general superiority in absolute weight of the male over the female brain has been ascertained to exist at every period of life. In new-born infants the brain was found by Tiedemann to weigh on an average from 14¼ oz. to 15¾ oz. in the male, and from 10 oz. to 13½ oz. in the female:—a fact of considerable interest in practical midwifery; for it has been shown that difficult labours occur in by far the largest number in the birth of male children. (Simpson, London and Edinburgh Monthly Journal of Medical Science, 1845.)

A. Table of the Average Weight of the Male and Female Brain.

| MALES, aged 21 years and upwards. |                                             |       |            |       |                              | FEMALES, aged 21 years and upwards.                             |                            |                                             |       |            |       |                                                   |                                                                 |
|-----------------------------------|---------------------------------------------|-------|------------|-------|------------------------------|-----------------------------------------------------------------|----------------------------|---------------------------------------------|-------|------------|-------|---------------------------------------------------|-----------------------------------------------------------------|
| Weight in oz. avoirdupois.        | Number of brains at each weight observed by |       |            |       | Total number at each weight. | Classification into three groups to show the prevailing weight. | Weight in oz. avoirdupois. | Number of brains at each weight observed by |       |            |       | Total number at each weight.                      | Classification into three groups to show the prevailing weight. |
|                                   | Clendinning.                                | Sims. | Tiedemann. | Reid. |                              |                                                                 |                            | Clendinning.                                | Sims. | Tiedemann. | Reid. |                                                   |                                                                 |
| 34                                | —                                           | —     | —          | 1     | 1                            | 62 cases. { from 34 oz. to 45 oz. } Difference 11.              | 31                         | —                                           | —     | —          | 1     | 32 cases. { from 31 oz. to 40 oz. } Difference 9. |                                                                 |
| 37                                | —                                           | —     | —          | —     | —                            |                                                                 | 32                         | —                                           | —     | —          | —     |                                                   | 1                                                               |
| 38                                | —                                           | —     | —          | —     | —                            |                                                                 | 35                         | —                                           | —     | —          | —     |                                                   | —                                                               |
| 39                                | 1                                           | 3     | —          | 1     | 4                            |                                                                 | 36                         | —                                           | —     | —          | —     |                                                   | —                                                               |
| 40                                | —                                           | —     | —          | 1     | 1                            |                                                                 | 37                         | —                                           | —     | —          | —     |                                                   | —                                                               |
| 41                                | —                                           | —     | —          | —     | —                            |                                                                 | 38                         | —                                           | —     | —          | —     |                                                   | —                                                               |
| 42                                | —                                           | —     | —          | —     | —                            | 39                                                              | —                          | —                                           | —     | —          | —     |                                                   |                                                                 |
| 43                                | —                                           | —     | —          | —     | —                            | 40                                                              | —                          | —                                           | —     | —          | —     |                                                   |                                                                 |
| 44                                | 1                                           | 6     | —          | —     | 7                            | 41                                                              | —                          | —                                           | —     | —          | —     |                                                   |                                                                 |
| 45                                | 6                                           | 8     | —          | 1     | 15                           | 42                                                              | —                          | —                                           | —     | —          | —     |                                                   |                                                                 |
| 46                                | 2                                           | 6     | —          | 8     | 20                           | 43                                                              | 6                          | 6                                           | —     | 7          | 19    |                                                   |                                                                 |
| 47                                | 2                                           | 6     | —          | 10    | 18                           | 44                                                              | 5                          | 4                                           | —     | 13         | 23    |                                                   |                                                                 |
| 48                                | 4                                           | 5     | —          | 11    | 25                           | 45                                                              | 4                          | 9                                           | —     | 20         | 20    |                                                   |                                                                 |
| 49                                | 3                                           | 3     | —          | 12    | 19                           | 46                                                              | —                          | —                                           | —     | 12         | 15    |                                                   |                                                                 |
| 50                                | 4                                           | 4     | —          | 13    | 26                           | 47                                                              | —                          | —                                           | —     | 7          | 24    |                                                   |                                                                 |
| 51                                | 3                                           | 3     | —          | 19    | 27                           | 48                                                              | —                          | —                                           | —     | 7          | 14    |                                                   |                                                                 |
| 52                                | 3                                           | 5     | —          | 4     | 6                            | 49                                                              | —                          | —                                           | —     | 1          | 10    |                                                   |                                                                 |
| 53                                | 4                                           | 3     | —          | 10    | 20                           | 50                                                              | —                          | —                                           | —     | 4          | 7     |                                                   |                                                                 |
| 54                                | 3                                           | —     | —          | 5     | 11                           | 51                                                              | —                          | —                                           | —     | 4          | 6     |                                                   |                                                                 |
| 55                                | —                                           | —     | —          | 4     | 6                            | 52                                                              | 1                          | —                                           | —     | 1          | 1     |                                                   |                                                                 |
| 56                                | —                                           | —     | —          | 6     | 7                            | 53                                                              | —                          | —                                           | —     | 1          | 1     |                                                   |                                                                 |
| 57                                | —                                           | —     | —          | 7     | 7                            | 54                                                              | —                          | —                                           | —     | 1          | 1     |                                                   |                                                                 |
| 58                                | —                                           | —     | —          | 7     | 7                            | 55                                                              | —                          | —                                           | —     | 1          | 1     |                                                   |                                                                 |
| 59                                | —                                           | —     | —          | 3     | 6                            | 56                                                              | —                          | —                                           | —     | 1          | 1     |                                                   |                                                                 |
| 60                                | —                                           | —     | —          | 1     | 1                            |                                                                 |                            |                                             |       |            |       |                                                   |                                                                 |
| 61                                | —                                           | —     | —          | 1     | 1                            |                                                                 |                            |                                             |       |            |       |                                                   |                                                                 |
| 62                                | —                                           | —     | —          | 1     | 1                            |                                                                 |                            |                                             |       |            |       |                                                   |                                                                 |
| 63                                | —                                           | —     | —          | 1     | 1                            |                                                                 |                            |                                             |       |            |       |                                                   |                                                                 |
| 65                                | —                                           | —     | —          | 1     | 1                            |                                                                 |                            |                                             |       |            |       |                                                   |                                                                 |
| Tot. 35 + 78 + 39 + 120 = 278.    |                                             |       |            |       |                              | Tot. 30 + 72 + 12 + 77 = 191.                                   |                            |                                             |       |            |       |                                                   |                                                                 |

With the above results the observations of Peacock, published in the "Monthly Journ. of Med. Science" for 1847, and further observations by the same author in the "Journ. of the Pathol. Soc." in 1860, in the main agree.

The elaborate table compiled by Rudolph Wagner, and published in his "Vorstudien zu einer wissenschaft. Morphol. und Physiol. des Menschl. Gehirns," 1860, containing 964 recorded cases in which the weight of the brain had been ascertained, may also be referred to as another recent useful contribution to the knowledge of this subject.

In illustration of the variation in the average weight of the brain at different ages Table B. is given, deduced from the elaborate researches of Dr. Robert Boyd, in the examination of the brains of 2,086 sane persons of both sexes dying in the St. Marylebone Infirmary, and published in the "Philos. Trans. for 1860. The weights are stated in oz. avoird. and decimal fractions of them.

Anatomists have differed considerably in their statements as to the period at which the brain attains its full size, and also as to the effect of old age in diminishing the weight of this organ. Sæmmering held that the brain reached its full size as early as the third year; the Wenzels and Sir W. Hamilton fixed the period about the seventh, and Tiedemann between the seventh and eighth years. Gall and Spurzheim were of opinion that the brain continued to grow until the fortieth year. The observations of Sims, Tiedemann, and Reid, appear to show that in both sexes the weight of the brain in general increases rapidly up to the seventh year, then more slowly to between sixteen and twenty, and again more slowly to between thirty-one and forty, at which time it reaches its maximum point. Beyond that period there appears a slow but progressive dimi-

nation in weight, amounting to about 1 oz., during each subsequent decennial period; thus confirming the opinion that the brain diminishes in advanced life. According to Peacock, the maximum weight of the brain is attained between the ages of twenty and thirty years. The table of Boyd inserted below would appear to show a somewhat earlier period as that at which the maximum is reached in both sexes, and that the period of decline scarcely begins before sixty years. With this result the observations of Huschke, made upon the brains of 359 men and 245 women, in general agree. ("Schädel, Hirn, und Seele des Menschen und der Thiere, &c.," 1854.)

B. Table of the Weight of the Brain of Males and Females at different Ages.

| PERIODS OF LIFE.                           | MALES.                         |          |          |          | FEMALES. |          |          |                 |     |
|--------------------------------------------|--------------------------------|----------|----------|----------|----------|----------|----------|-----------------|-----|
|                                            | Number weighed.                | Maximum. | Minimum. | Average. | Average. | Minimum. | Maximum. | Number weighed. |     |
| 1 Children prematurely still-born .....    | 25                             | 13.1     | 1.31     | 5.6      | 4.62     | 1.29     | 9.13     | 18              |     |
| 2 Children still-born at full period ..... | 43                             | 22       | 9.37     | 13.87    | 12.25    | 8.       | 15.12    | 31              |     |
| 3 New-born infants .....                   | 42                             | 15.37    | 6.       | 11.65    | 10.      | 1.75     | 16.      | 39              |     |
| 4 Under 3 months .....                     | 16                             | 32.75    | 10.5     | 17.42    | 15.94    | 11.      | 32.5     | 20              |     |
| 5 From 3 to 6 months .....                 | 15                             | 30.75    | 10.75    | 21.29    | 19.76    | 13.      | 34.75    | 25              |     |
| 6 From 6 to 12 months .....                | 46                             | 36.13    | 17.75    | 27.42    | 25.7     | 16.37    | 39.13    | 40              |     |
| 7 From 1 to 2 years .....                  | 34                             | 41.25    | 23.25    | 33.25    | 29.8     | 18.      | 37.      | 33              |     |
| 8 From 2 to 4 years .....                  | 29                             | 50.5     | 30.5     | 38.71    | 34.97    | 27.75    | 44.5     | 29              |     |
| 9 From 4 to 7 years .....                  | 27                             | 49.5     | 24.5     | 40.23    | 40.11    | 34.75    | 48.25    | 19              |     |
| 10 From 7 to 14 years .....                | 22                             | 57.25    | 39.25    | 45.96    | 40.78    | 34.      | 52.      | 18              |     |
| 11 From 14 to 20 years .....               | 19                             | 58.5     | 36.5     | 48.54    | 43.94    | 37.5     | 52.      | 16              |     |
| 12 From 20 to 30 years .....               | 59                             | 57.      | 39.25    | 47.9     | 43.7     | 35.75    | 55.25    | 72              |     |
| 13 From 30 to 40 years .....               | 110                            | 60.75    | 33.75    | 48.2     | 43.09    | 33.25    | 53.      | 89              |     |
| 14 From 40 to 50 years .....               | 137                            | 60.      | 33.75    | 47.75    | 42.81    | 27.5     | 52.5     | 106             |     |
| 15 From 50 to 60 years .....               | 119                            | 59.      | 30.5     | 47.44    | 43.12    | 36.25    | 52.5     | 103             |     |
| 16 From 60 to 70 years .....               | 127                            | 59.5     | 36.25    | 46.4     | 42.69    | 32.5     | 54.      | 149             |     |
| 17 From 70 to 80 years .....               | 104                            | 55.25    | 37.75    | 45.5     | 41.27    | 29.25    | 49.5     | 143             |     |
| 18 Upwards of 80 years .....               | 24                             | 53.75    | 41.      | 45.34    | 39.77    | 33.25    | 48.      | 77              |     |
| Averages in                                | Persons above 14 years .....   | 699      | 58.      | 36.1     | 47.1     | 42.5     | 33.1     | 52.1            | 760 |
|                                            | Persons from 14 to 70 years .. | 571      | 59.12    | 35.      | 47.7     | 43.15    | 33.8     | 53.15           | 535 |

All other circumstances being alike, the size of the brain appears to bear a general relation to the mental power of the individual,—although many instances occur in which this rule is not applicable. The brain of Cuvier weighed upwards of 6½ oz., and there are other recorded examples of brains belonging to men of great talent which nearly equalled it in weight. (Emile Rousseau, "Maladie et autopsie de M. G. Cuvier." Lancette Française, Mai 26, 1832.) On the other hand, the brain in idiots is remarkably small. In three idiots, whose ages were sixteen, forty, and fifty years, Tiedemann found the weight of their respective brains to be 19¾ oz., 25¾ oz., and 22½ oz.; and Dr. Sims records the case of a female idiot twelve years old, whose brain weighed 27 oz. Allen Thomson has found the brain of a dwarfish idiot girl seventeen years of age to weigh 18½ oz. after preservation in alcohol.

The human brain is found to be absolutely heavier than that of all the lower animals except the elephant and whale. The brain of the elephant, according to Perrault, Moulins, and Sir A. Cooper, weighs between 8 and 10 lbs.; whilst that of the whale was found by Rudolphi, in a specimen 75 feet long, to weigh upwards of 5 lbs.

The relative weight of the encephalon to the body is liable to great variation; nevertheless, the facts to be gathered from the tables of Clendinning, Tiedemann,

and Reid, furnish this interesting general result. In a series of 81 males, the average proportion between the weight of the brain and that of the body at the ages of twenty years and upwards, was found to be as 1 to 36.5; and in a series of 82 females, to be as 1 to 36.46. In these cases the deaths were the result of more or less prolonged disease; but in six previously healthy males, who died suddenly from disease or accident, the average proportion was 1 to 40.8.

The proportionate weight of the brain to that of the body is much greater at birth than at any other period of life, being, according to Tiedemann, about 1 to 5.85 in the male, and about 1 to 6.5 in the female. From the observations already referred to, it further appears that the proportion diminishes gradually up to the tenth year, being then about 1 to 14. From the tenth to the twentieth year, the relative increase of the body is most striking, the ratio of the two being at the end of that period about 1 to 30. After the twentieth year, the general average of 1 to 36.5 prevails, with a further trifling decrease in advanced life.

Viewed in relation to the weight of his body, the brain of man may be stated generally to be heavier than the brains of the lower animals; but there are some exceptions to the rule, as in the case of certain species of small birds, in the smaller apes, and in some small rodent animals.

The attempts hitherto made to measure or estimate the relative proportions of the different convoluted parts of the cerebrum to each other and to the degree of intelligence, either more directly or by the cranioscopic methods, have been attended with little success. The more recent researches of Rudolph Wagner, which have been farther prosecuted by his son, hold out some promise, when fully carried out, to afford more definite results.

These researches had for their object to institute an accurate comparison between the brains of certain persons of known intelligence, cultivation, and mental power, and those of persons of an ordinary or lower grade. As examples of brains of men of superior intellect, he selected those of Professor Gauss, a well-known mathematician of eminence, and Professor Fuchs, a clinical teacher; and as examples of brains of ordinary persons, those of a woman of 29 and a workman named Krebs, all of which he examined and measured with scrupulous care.

The general result of R. Wagner's researches upon these and other brains may be stated to be as follows. 1st. Although the greatest number of brains belonging to men of superior intellect are found to be heaviest or largest, yet there are so many instances in which the brains of such persons have not surpassed, or have even fallen below the average size of the brains of ordinary persons, that superiority of size cannot in the present state of our knowledge be regarded as a constant accompaniment of superiority of intellect, even when due regard has been paid to the comparative stature and other circumstances of the individuals.

2nd. It would appear that, in the brains of certain persons of superior intellect, the cerebral convolutions have been found more numerous and more deeply divided than in those of persons of ordinary mental endowments and without cultivation. But numerous exceptional instances are also found of paucity of convolutions coincident with superior intellect, which make it impossible at present to deduce any certain conclusion with respect to the relation between the number or extent of the convolutions and the intellectual manifestations in different persons.

The careful measurement of all the convolutions and the intervening grooves in the four brains above mentioned has been carried out by the younger Wagner, and the tables and results of these measurements published by him as an appendix to his father's treatise. (Hermann Wagner, "Maasbestimmungen der Oberfläche des Grossen Gehirns," &c., Cassel und Göttingen, 1864.)

The following short table extracted from Hermann Wagner's memoir, and simplified by the omission of small fractions and by the reduction of the measurements from square millimetres to English square inches, may give the reader some idea of the nature of the inquiry.



*Comparative measurement of the extent of surface of the Convolution of the Cerebrum and its lobes.*

|                      | Surface of each lobe separately. |           |            |           | Free and deep surfaces of Cerebrum. |                          | Whole surface of Cerebrum. |
|----------------------|----------------------------------|-----------|------------|-----------|-------------------------------------|--------------------------|----------------------------|
|                      | Frontal.                         | Parietal. | Occipital. | Temporal. | Free surface.                       | Deep or covered surface. |                            |
| 1. Gauss . . . . .   | 139.                             | 70.6      | 59.4       | 68.4      | 112.8                               | 228.2                    | 341.                       |
| 2. Fuchs . . . . .   | 143.4                            | 69.5      | 59.        | 67.5      | 110.7                               | 231.3                    | 342.                       |
| 3. Woman . . . . .   | 130.                             | 65.       | 51.        | 66.8      | 107.5                               | 209.9                    | 317.5                      |
| 4. Workman . . . . . | 113.2                            | 62.3      | 50.5       | 62.       | 97.4                                | 193.6                    | 291.                       |

**WEIGHT OF THE SEVERAL PARTS OF THE ENCEPHALON.**

As the result of observations made in reference to this subject, on the brains of 53 males and 34 females, between the ages of twenty-five and fifty-five, Dr. J. Reid has given the following table :—

|                                        | Males. |                  | Females. |                  | Difference. |                 |
|----------------------------------------|--------|------------------|----------|------------------|-------------|-----------------|
|                                        | oz.    | drs.             | oz.      | drs.             | oz.         | drs.            |
| Average weight of cerebrum . . . . .   | 43     | 15 $\frac{3}{4}$ | 38       | 12               | 5           | 3 $\frac{3}{4}$ |
| „ cerebellum . . . . .                 | 5      | 4                | 4        | 12 $\frac{1}{4}$ | 0           | 7 $\frac{3}{4}$ |
| „ pons and medulla oblongata . . . . . | 0      | 15 $\frac{3}{4}$ | 1        | 0 $\frac{1}{4}$  | 0           | 0 $\frac{3}{4}$ |
| „ entire encephalon . . . . .          | 50     | 3 $\frac{1}{2}$  | 44       | 8 $\frac{1}{2}$  | 5           | 11              |

With these results the observations of Huschke, derived from a special examination of the brains of 22 females and 38 males, mainly agree.

From this it appears, that the proportionate weight of the cerebellum to that of the cerebrum is, in the male, as one to 8 $\frac{1}{2}$ , and in the female, as 1 to 8 $\frac{1}{4}$ . The cerebellum attains its maximum weight from the twenty-fifth to the fortieth year ; but the increase in weight after the fourteenth year is shown to be relatively greater in the female than in the male. The whole cerebellum apart from the pons and medulla is heavier in the male ; the lateral lobes of the cerebellum are also heavier in the male. In the male the vermiform process increases gradually from the twentieth to the fiftieth year ; in the female it remains stationary during that period, and after the fiftieth year diminishes rapidly.

In the new-born infant the ratio of the weight of the cerebellum to that of the whole brain is strikingly different from that observed in the adult, being, according to Chaussier, between 1 to 13 and 1 to 26 ; by Cruveilhier it was found to be 1 to 20. Huschke found the weight of the cerebellum, medulla oblongata, and pons together in the new-born infant, as compared with that of the brain, to be in the proportion of 1 to 15, and 1 to 13. In the adult the proportions were 1 to 7, and 1 to 6.

In most mammalia, the cerebellum is found to be heavier in proportion to the cerebrum, than it is in the human subject ; in other words, the cerebrum in man is larger in proportion to the cerebellum.

Sæmmering pointed out the fact that the brain is larger, in proportion to the nerves connected with it, in man than in the lower animals.

A comparison of the width of the cerebrum with that of the medulla oblongata shows that the proportionate diameter of the brain to that of the medulla oblongata is greater in man than in any animal, except the dolphin, in which creature, however, it must be remembered that the cerebral lobes exhibit a disproportionate lateral development. The width of the cerebrum in man, as

compared with that of the medulla oblongata at its base or broadest part, is about 7 to 1, while in many quadrupeds it is as 3 to 1 or even as 2 to 1.

#### WEIGHT OF THE SPINAL CORD.

Divested of its membranes and nerves, the spinal cord in the human subject weighs from 1 oz. to  $1\frac{3}{4}$  oz., and therefore its proportion to the encephalon is about 1 to 33. Meckel states it as 1 to 40.

The disproportion between the brain and the spinal cord becomes less and less in the descending scale of vertebrata, until at length, in cold-blooded animals, the spinal cord becomes heavier than the brain. Thus, in the mouse, the weight of the brain, in proportion to that of the spinal cord, is as 4 to 1; in the pigeon, as  $3\frac{1}{3}$  to 1; in the newt only as  $\frac{5}{9}$  to 1; and in the lamprey, as  $\frac{1}{75}$  to 1.

In comparison with the size of the body, the spinal cord in man may be stated in general terms to be much smaller than it is in animals. In regard to the cold-blooded animals, to birds, and to small mammalia, this has been actually demonstrated, but not in reference to the larger mammalia.

R. Wagner states as follows, the proportion of the weight of the spinal marrow taken as 1 to the encephalon and its parts—

|                                   |       |         |
|-----------------------------------|-------|---------|
| <i>a.</i> to the nerve roots      | : : 1 | : 0.53  |
| <i>b.</i> to the medulla and pons | : : 1 | : 1     |
| <i>c.</i> to the cerebellum       | : : 1 | : 5.18  |
| <i>d.</i> to the cerebrum         | : : 1 | : 42.78 |
| <i>e.</i> to the encephalon       | : : 1 | : 48.96 |

#### SPECIFIC GRAVITY OF THE ENCEPHALON.

The specific gravity of the different parts of encephalon has of late attracted some attention from its having been observed that it varies to some extent in different kinds of disease. From the researches of Bucknill, Sankey, Aitken, and Peacock, it appears that the average specific gravity of the whole encephalon is about 1036, that of the grey matter 1034, and that of the white 1040. There are also considerable differences in the specific gravity of some of the internal parts. (William Aitken, "The Science and Practice of Medicine," 1865, vol. ii. p. 265; J. C. Bucknill, in "The Lancet," 1852; Sankey, in the "Brit. and For. Med. Chir. Review," 1853; Thos. B. Peacock, in the Trans. of the Pathol. Soc. of London, 1861-2.)

## ORGANS OF THE SENSES.

In this place will be described the organs of sight, hearing, and smell—the higher organs of special sense. The description of the organ of touch is given with the skin, and that of the organ of taste with the tongue.

## THE EYE.

The organ of vision, strictly speaking, consists only of the ball or globe of the eye ; but connected with the eyeball externally are muscles, nerves, and blood-vessels, elsewhere described, as well as other parts specially destined for its protection, and known as the appendages of the eye (*tutamina oculi*), of which an account will first be given.

## THE EYELIDS AND CONJUNCTIVA.

The eyelids (*palpebræ*) are moveable portions of integument, strengthened toward their margins by a thin lamina of dense fibrous tissue. A mucous membrane lines their inner surface, and is reflected thence in the form of a pellucid covering on the surface of the eyeball. This is named the conjunctival membrane or *conjunctiva*.

The upper lid is larger and more moveable than the lower, all the transparent part of the globe being covered by it when the eye is closed ; it is chiefly by the elevation of this lid that the eye is opened, the movement being effected by a muscle (*levator palpebræ*) devoted exclusively to this purpose. At the outer and inner angles (*canthi*) of the eye the eyelids are united. The interval between the angles—*fissura palpebrarum*—varies in length in different persons, and, according to its extent, gives the appearance of a larger or a smaller eye, the size of the globe being nearly the same. The greater part of the edge of each eyelid is flattened, but towards the inner canthus it is rounded off for a short space, at the same time that it somewhat changes its direction ; where the two differently formed parts join, there exists on each lid a slight conical elevation—*papilla lachrymalis*—the apex of which is pierced by the aperture or *punctum* of the corresponding lachrymal canalicule.

In the greater part of their extent the lids are applied to the surface of the eyeball ; but at the inner canthus, opposite the *puncta lachrymalia*, there intervenes a vertical fold of conjunctiva, the *plica semilunaris*, which rests on the eyeball ; whilst, occupying the recess of the angle at the border of this fold, is a spongy-looking reddish elevation, formed by a group of sebaceous glands which open into the follicles of very fine hairs. It is named the *caruncula lachrymalis*. The *plica semilunaris* is the rudiment of the third eyelid (*membrana nictitans*) found in many animals. It contains a small amount of plain muscular tissue (H. Müller).

**Structure of the lids.**—The skin covering the eyelids is thin and delicate, and covered with excessively fine, downy hairs ; at the line of the eyelashes it joins the conjunctival mucous membrane which lines the inner surface of the lids. The *cutis vera* is remarkable for containing ramified pigment cells. Beneath the skin, and between it and the conjunctiva, the following structures are successively met with, viz. :

The fibres of the orbicularis muscle; loose connective tissue; the so called tarsal cartilages, together with a thin fibrous membrane, the palpebral ligament, which attaches them to the margin of the orbit; and, finally, the Meibomian glands. In the upper eyelid there is, in addition, the insertion of the levator palpebræ superioris, in the form of a fibrous expansion attached to the upper or anterior surface of the tarsal cartilage.

Fig. 396.

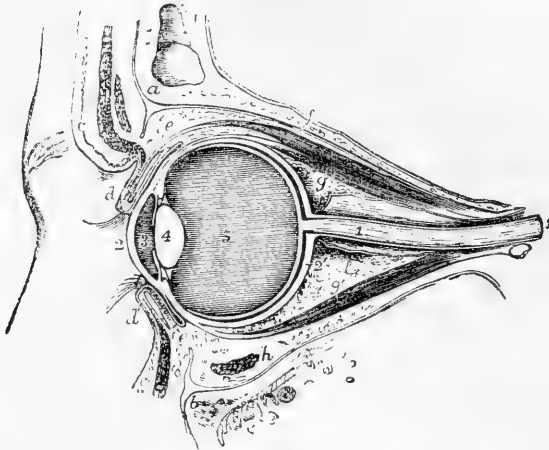


Fig. 396.—VERTICAL SECTION OF THE LEFT ORBIT AND ITS CONTENTS.

The section has been carried first obliquely through the middle of the optic foramen and optic nerve as far as the back of the eyeball, and thence forward through the eyeball, eyelids, &c. *a*, frontal bone; *b*, superior maxillary; *c*, eyebrow; *d*, the upper, and *d'*, the lower eyelid, partially open, showing the section of the tarsal cartilages, the eyelashes, &c.; *e, e*, the reflection of the conjunctiva from the upper and lower eyelids to the surface of the eyeball; *f*, the levator palpebræ superioris muscle; *g*, the upper, *g'*, the lower rectus muscle; *h*, the inferior oblique muscle divided; *1, 1*, the optic nerve divided in its sheath; *2*, the cornea; *2'*, the sclerotic; *3*, aqueous chamber; *4*, crystalline lens; *5*, vitreous chamber.

The *orbicularis muscle* is closely adherent to the skin by fine connective tissue entirely devoid of fat, but glides loosely on the tarsal cartilages. A marginal fasciculus lies within the line of the eyelashes, separated by the bulbs of the lashes from the other fibres, and constituting the *musculus ciliaris Riolani*.

The *tarsal cartilages (tarsi)* are two thin elongated plates formed of dense connective tissue, without, according to most observers, any intermixture of cartilage-cells. They are placed one in each lid, and serve to give shape and firmness to those parts. The upper cartilage, the larger, is half oval in form, being broader near the centre and narrowing towards the angles of the lids. The lower is thinner, much narrower, and more nearly of an uniform breadth throughout. Their free or ciliary edge, which is straight, is thicker than any other part. At the inner canthus they are fixed by fibrous slips of the tendon of the orbicularis muscle; and at the outer angle are attached to the malar bone by a fibrous band belonging to the palpebral ligament, and named the *external tarsal ligament*.

The *palpebral ligament* is a fibrous membrane placed beneath the

orbicularis muscle, attached peripherally to the margin of the orbit, and internally to the tarsi, with which its tissue is continuous. The membrane is thickest at the outer part of the orbit.

On the ocular surface of each lid are seen from twenty to thirty parallel vertical rows of yellow granules, lying immediately under the conjunctival mucous membrane, and known as the *Meibomian glands* (fig. 397, 6, 6). They are compound sebaceous glands, imbedded in grooves at the back of the tarsi; and they open on the free margin of the lids by minute orifices, generally one for each. The glands consist of nearly straight tubes, closed at the end, with numerous small caecal appendages projecting from the sides. The tubes are lined for some distance by stratified epithelium continuous with that of the skin: the glandular recesses have a lining of cubical epithelium and are filled with the fatty secretion. According to

Colosanti the glands have a basement membrane, and a muscular layer outside this: he further describes a network of fine nervous fibrils amongst the epithelium cells.

A layer of unstriped muscular tissue is contained in each eyelid; that of the upper arising from the under surface of the levator palpebrae, that of the lower from the neighbourhood of the inferior oblique muscle, and each being inserted near the margin of the tarsus. A few fibres are also to be found in the plica semilunaris (H. Müller). It may also be mentioned in this place that the same writer describes a layer of unstriped muscle crossing the spheno-maxillary fissure, corresponding to a more largely developed layer found in the extensive aponeurotic part of the orbital wall of various mammalia. This set of fibres has been more particularly described by Turner.\*

The *eyelashes* (cilia) are strong short curved hairs, arranged in two or more rows along the margin of the lids, at the line of union between the skin and the conjunctiva. The upper lashes are more numerous and longer than the lower, and are curved in an opposite direction. Near the inner canthus the hairs are weaker and more scattered. Immediately within the eyelashes, between them and the muscle of Riolan, is a row of large modified sweat-glands, which open into the mouths of sebaceous glands (not the Meibomian).

**Structure of the conjunctiva.**—The conjunctiva consists of the palpebral part, with which may be included the plica semilunaris and

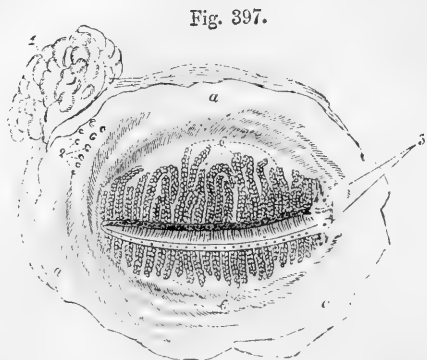


Fig. 397.—MEIBOMIAN GLANDS OF THE LEFT EYELIDS AS SEEN FROM BEHIND.

*a, a*, palpebral conjunctiva; 1, lachrymal gland; 2, openings of seven or eight of its ducts; 3, upper and lower puncta lachrymalia; 6, 6, ends of the upper and lower Meibomian glands, of which the openings are indicated along the margins of the eyelids.

\* H. Müller in Zeitschr. f. wiss. Zool. 1858, p. 541; W. Turner, in Nat. Hist. Rev. 1862, p. 106.

caruncula, and of the ocular part or conjunctiva bulbi, in which may be distinguished the sclerotic and corneal portions: each of these parts presents distinctive characters. The epithelium of the conjunctiva varies somewhat at different parts, but is mainly columnar, with smaller cells between the fixed ends of the columnar cells. Near the skin and cornea it shades off into the stratified epithelium which covers these parts.

The *palpebral portion* of the conjunctiva is thicker and more vascular than any other part of the membrane, and presents numerous fine papillæ freely supplied with nerves. It passes through the puncta lachrymalia into the canaliculi, and is continuous with the lining membrane of the lachrymal sac. Although closely united to the tarsi, it exhibits, nevertheless, numerous small creases or folds, which are visible with a lens. A layer of small racemose or tubulo-racemose glands is found on the ocular surface of the lids, immediately under the conjunctiva, and beyond the ends of the Meibomian glands (Sappey, W. Krause). Their minute ducts open near the line of reflection of the conjunctiva upon the globe of the eye (*fornix conjunctivæ*).

The *sclerotic portion*.—The conjunctiva changes its character at the line of reflection from the eyelids, becoming thinner and losing its papillary structure: it is loosely connected to the eyeball by submucous tissue. It is transparent and a few blood-vessels are generally visible in it in the healthy condition, but under the influence of inflammatory congestion a copious network of vessels very irregularly disposed comes into view. These vessels are derived from the palpebral and lachrymal arteries.

Another set of vessels exists on the surface of the sclerotic, and are seen when congested. These are entirely sub-conjunctival and adherent to the sclerotic coat; they are less tortuous than the conjunctival set, and are derived from the muscular and anterior ciliary branches of the ophthalmic artery: they remain immoveable on pressure of the eyelid, whereas the conjunctival vessels of course shift with that membrane. These sclerotic vessels dip in near the cornea, and appear to unite with a deeper minute network disposed in closely set straight lines, which radiate from the margin of the cornea, and the gorged condition of which is well known to ophthalmic surgeons as characteristic of scleratitis.

The *corneal conjunctiva* consists almost entirely of epithelium, any underlying membrane being extremely thin, transparent, and adherent to the anterior layers of the cornea, in connection with which it will be again referred to. Around the circumference vessels lie between it and the cornea, and form a circle of anastomotic capillary loops. This plexus of vessels extends farther inwards in the fœtus.

A well developed network of *lymphatics* exists throughout the sclerotic and palpebral portions of the conjunctiva; but at the margin of the cornea a sudden diminution takes place in the size of the meshes and diameter of the vessels, which become irregular, and come into connection with ramified cell-spaces in the cornea.

The *nerves* in the membrane, as far as the cornea, seem to have the same arrangement as in the skin. Their mode of ending has not been traced with certainty, but according to Krause many of them terminate in end-bulbs.

The mucous membrane of the palpebral conjunctiva contains, especially at its back part, a large quantity of lymphoid tissue. Lymphoid follicles have also been described in the conjunctiva (Bruch), but their existence in man is doubtful (Waldeyer).

## THE LACHRYMAL APPARATUS.

The parts which constitute the lachrymal apparatus are the following, viz. :—The gland by which the tears are secreted, situated at the upper and outer side of the orbit, together with its excretory ducts : the two canals into which the fluid is received near the inner angle : and the sac with the nasal duct continued from it, through which the tears pass into the inferior meatus of the nose.

The **lachrymal gland**, an oblong flattened body, about the size of a small almond, is placed in the upper and outer part of the orbit, a little behind the anterior margin. The upper surface of the gland, convex, is lodged in a slight depression in the orbital plate of the frontal bone, to the periosteum of which it adheres by fibrous bands ; the lower surface is adapted to the convexity of the eyeball, and is in contact with the upper and the outer recti muscles. The fore part of the gland, separated from the rest by a thin layer of fascia, and sometimes described as a distinct gland (*glandula lachrymalis inferior*, Rosenmüller), is closely adherent to the back of the upper eyelid, and is covered on the ocular surface merely by the conjunctiva ; its lobules are small and separate, with minute ducts, some opening separately, others joining the ducts from the principal gland, which are also very small. The number from both divisions of the gland seldom exceeds twelve or fourteen. After running obliquely under the mucous membrane, and separating at the same time from each other, they open in a row at the fornix conjunctivæ, by separate orifices, at its upper outer part. In minute structure the lachrymal gland resembles the salivary glands.

**Lachrymal canals.**—On the margin of each lid, near the inner angle, and in front of the fold of membrane called *plica semilunaris*, is a small elevation (*papilla lachrymalis*), as already mentioned. Each papilla is perforated by a minute aperture, *punctum lachrymale* ; and at these apertures commence two narrow canals, *canaliculi* (fig. 398, 1, 1), which convey the tears from the eye to the lachrymal sac. The upper canal is rather the smaller and longer of the two : it first ascends from the punctum ; then makes a sudden bend, and is directed inwards and downwards to join the lachrymal sac. The lower canal descends from the corresponding punctum, and then takes a nearly horizontal course inwards. Both canals are dilated where bent. In some cases they unite near the end ; more commonly they open separately, but close together, into the sac.

Fig. 398.

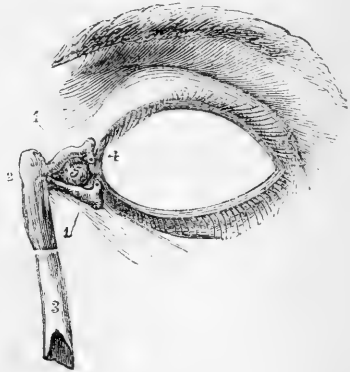


Fig. 398.—FRONT OF THE LEFT EYELIDS, WITH THE LACHRYMAL CANALS AND NASAL DUCT EXPOSED.

1, 1, upper and lower lachrymal canals, showing towards the eyelids the narrow bent portions and the puncta lachrymalia ; 2, lachrymal sac ; 3, the lower part of the nasal duct ; 4, *plica semilunaris* ; 5, *caruncula lachrymalis*.

The **lachrymal sac** and **nasal duct** constitute together the passage by which the tears are conveyed from the lachrymal canals to the cavity of the nose. The lachrymal sac (fig. 398, 2), the slightly dilated upper portion of the passage, is situated at the side of the nose, near the inner canthus of the eye, and lies embedded in a deep groove in the unguinal and upper maxillary bones. Its upper end is closed and rounded, and the lower end gradually narrows into the nasal duct. On the outer side, and a little in front, it receives the lachrymal canals; and here it is placed behind the *tendo palpebrarum*, and some of the inner fibres of the orbicular muscle of the lids; while on its orbital surface is the *tensor tarsi* muscle. The sac is composed of fibrous and elastic tissues, adhering closely to the bones above mentioned, and strengthened by fibrous processes sent from the *tendo palpebrarum*, which crosses a little above its middle. The inner surface is lined by a reddish mucous membrane, which is continuous through the canaliculi with the conjunctiva, and through the nasal duct with the mucous membrane of the nose.

The nasal duct (*ductus ad nasum*), about six or seven lines in length, grooving the upper maxillary bone, descends to the fore part of the lower meatus of the nose, the osseous canal being completed by the unguinal and lower turbinated bones. A tube of fibrous membrane, continuous with the lachrymal sac, adheres to the parietes of this canal, and is lined by mucous membrane, which, at the opening into the nose, is often arranged so as to form an imperfect valve. The nasal duct is rather narrower in the middle than at either end; its direction is not quite vertical, but inclined slightly outwards and backwards.

The mucous membrane in the canaliculi possesses a stratified, scaly epithelium, but in the nasal sac and duct a ciliated epithelium as in the nose.

Various valves have been described in connection with the lachrymal sac and canals. One, the valve of Hasner, is formed by the mucous membrane of the nose overhanging the inferior orifice of the nasal duct, and has had imputed to it the function of preventing entrance of foreign matters in violent expiratory movements; but the disposition of the mucous membrane at this orifice appears to be subject to considerable variation. Another fold, the valve of Huschke, placed at the opening of the canaliculi into the lachrymal sac, is supposed by some to prevent the return of the tears from the sac into those tubes, but, by others, it is declared to be inconstant, and insufficient, even when present, to close the orifice. A third fold, the valve of Foltz, is described as forming a projection inwards on one side of the vertical part of each canaliculus, near the *punctum lachrymale*, and as being sufficient to close the tube when it is flattened by the pressure of the fibres of the orbicularis and *tensor tarsi* muscles as in winking. The experiments of Foltz on rabbits go to prove that the *punctum lachrymale* having been turned backwards towards the eye in winking, and the canaliculus being compressed by the muscles, as soon as the pressure is removed the canaliculus resumes its open form, and so sucks in tears which by the next compression in winking are forced onwards into the lachrymal sac; and also, that when the muscles are paralysed, the canaliculi cease to carry away the tears. See review of Foltz's paper in *Dublin Quarterly Journal*, Feby. 1863; also, Hyrtl, *Topogr. Anatomie*.

## THE GLOBE OF THE EYE.

The globe or ball of the eye is a composite structure of spheroidal form, placed in the fore part of the orbital cavity, and receiving the



thick stem of the optic nerve behind. The recti and obliqui muscles closely surround the greater part of the eyeball, and are capable of changing its position within certain limits: the lids, with the plica semilunaris and caruncle, are in contact with its covering of conjunctiva in front; and behind it is supported by a quantity of loose fat and connective tissue.

The eyeball is composed of segments of two spheres, of which the anterior is the smaller and more prominent: the segment of the larger posterior opaque sphere corresponds with the limit of the sclerotic coat, and the translucent portion of the smaller sphere with that of the cornea.

From before backwards the ball measures about nine-tenths of an inch, and its transverse diameter exceeds this measurement by about a line.

Except when directed towards near objects, the axes of the eyes are nearly parallel; the optic nerves, on the contrary, diverge considerably from one another, and each nerve enters the corresponding eye about a tenth of an inch to the inner or nasal side of the axis of the globe.

The eyeball consists of several concentric coats, and of certain fluid and solid parts contained within them. The coats or membranes are three in number, viz.: an external fibrous covering, named *sclerotic* and *cornea*; a middle vascular, pigmented, and in part also muscular membrane, the *choroid* and the *iris*: and an internal nervous stratum, the *retina*. The enclosed refracting media, three in number, are the *aqueous humour*, the *vitreous body*, and the *lens* with its *capsule*.

Around the eyeball there is an adventitious tunic of fascia, *tunica vaginalis oculi*, or capsule of Tenon, which is perforated by the tendons of the recti and obliqui muscles, and connected with the sclerotic by merely the most delicate connective tissue. This capsule, which in reality consists of two membranous layers lined by flattened epithelioid cells, and enclosing a lymph space, separates the eyeball from the orbital fat, and enables it to glide freely in its movements.

### THE SCLEROTIC COAT.

The sclerotic (cornea opaca), the tunic of the eye on which the maintenance of the form of the organ chiefly depends, is a strong, opaque, unyielding fibrous structure. It extends over about five-sixths of the eyeball (fig. 399, 2), joining in front with the cornea. The outer surface is white and smooth, except where the tendons of the recti and obliqui muscles are inserted into it. The inner surface is a light brown colour, and rough from the presence of a delicate connective tissue (*membrana fusca*), which unites it with the choroid coat, and through which branches of the ciliary vessels and nerves cross obliquely. The sclerotic is thickest at the back part of the eye, and thinnest at about a quarter of an inch from the cornea: at the junction with the latter, it is again somewhat thickened. The optic nerve pierces this coat about one-tenth of an inch internal to the axis of the ball, and the opening is somewhat smaller at the inner than at the outer surface of the coat. The outer fibrous sheath of the nerve blends with the sclerotic at the margin of the aperture: in consequence of this arrangement, when the nerve is cut off close to the eyeball, the funiculi seem to enter by a group of pores; and to the part of the sclerotic thus perforated the

name of *lamina cribrosa* is sometimes given. Around this cribrous opening are smaller apertures for vessels and nerves

Fig. 399.

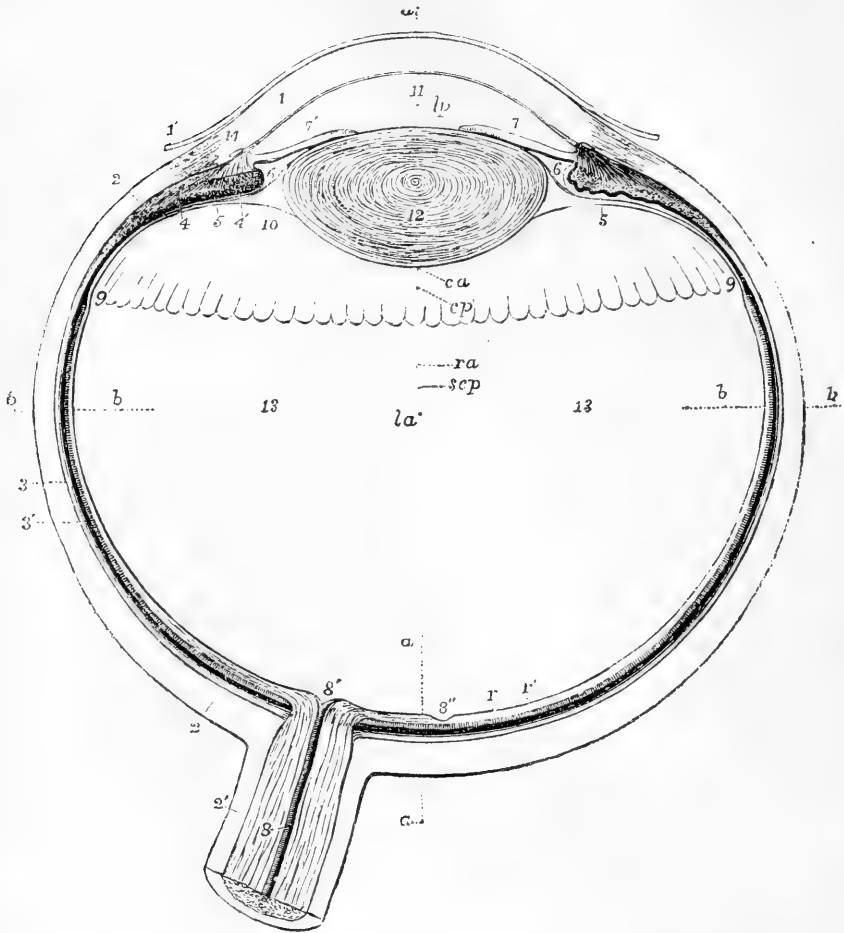


Fig. 399.—VIEW OF THE LOWER HALF OF THE RIGHT ADULT HUMAN EYE, DIVIDED HORIZONTALLY THROUGH THE MIDDLE. MAGNIFIED FOUR TIMES. (A. THOMSON.)

The specimen from which this outline is taken was obtained by dividing the eye of a man of about forty years of age in the frozen state. It was carefully compared with other specimens obtained in a similar manner; and in the drawing averages have been given in any particulars in which differences among them presented themselves.

1, the cornea; 1', its conjunctival layer; 2, the sclerotic; 2', sheath of the optic nerve passing into the sclerotic; 3, 3', the choroid; 4, ciliary muscle, its radiating portion; 4', cut fibres of the circular portion; 5, ciliary fold or process; 6, placed in the posterior division of the aqueous chamber, in front of the suspensory ligament of the lens; 7, the iris (outer or malar side); 7', the smaller, inner, or nasal side; 8, placed on the divided optic nerve, points to the arteria centralis retinae; 8', colliculus or eminence at the passage of the optic nerve into the retina; 8'', fovea centralis retinae; r, the nervous layer of the retina; r', the bacillar layer; 9, ora serrata at the commencement of the ciliary part of the retina; 10, canal of Petit; 11, anterior division of the aqueous chamber in front of the

pupil; 12, the crystalline lens, within its capsule; 13, the vitreous humour; *a, a, a*, parts of a dotted line in the axis of the eye; *b, b, b, b*, a line in the transverse diameter. It will be observed that from the pupil being placed nearer the inner side the axis of the eyeball, *a, a*, does not pass exactly through the centre of the pupil, and that this line falls a little to the inner side of the fovea centralis. The following letters indicate the centres of the curvatures of the different surfaces, assuming them to be nearly spherical, viz.: *c a*, of the anterior surface of the cornea; *c p*, posterior surface; *l a*, anterior surface of the lens; *l p*, posterior surface; *s c p*, posterior surface of the sclerotic; *r a*, anterior surface of the retina.

In connection with this figure the following average dimensions of the parts of the adult eye in fractions of an English inch may be stated:—

|                                                                                                                                |       |
|--------------------------------------------------------------------------------------------------------------------------------|-------|
| Transverse diameter of the eyeball . . . . .                                                                                   | 1'    |
| Vertical diameter (Krause) . . . . .                                                                                           | 0.96  |
| Antero-posterior diameter . . . . .                                                                                            | 0.96  |
| Diameter of the optic nerve with its sheath . . . . .                                                                          | 0.16  |
| Diameter of the nervous part at its passage through the choroid membrane . . . . .                                             | 0.09  |
| Greatest thickness of the sclerotic, choroid, and retina together . . . . .                                                    | 0.08  |
| Greatest thickness of the sclerotic posteriorly . . . . .                                                                      | 0.05  |
| Smallest thickness at the sides and in front . . . . .                                                                         | 0.025 |
| Greatest thickness of the cornea . . . . .                                                                                     | 0.055 |
| Distance from the middle of the posterior surface of the cornea to the front of the lens . . . . .                             | 0.07  |
| Antero-posterior diameter of the lens . . . . .                                                                                | 0.19  |
| Transverse ditto . . . . .                                                                                                     | 0.35  |
| Greatest thickness of the ciliary muscle and ciliary processes together . . . . .                                              | 0.06  |
| Greatest thickness of the ciliary muscle . . . . .                                                                             | 0.035 |
| Thickness of the iris . . . . .                                                                                                | 0.015 |
| Length of the radius of curvature of the anterior surface of the cornea (regarding it approximately as spherical) . . . . .    | 0.305 |
| Radius of the posterior surface . . . . .                                                                                      | 0.275 |
| Radius of curvature of the anterior surface of the lens . . . . .                                                              | 0.36  |
| Radius of the posterior surface . . . . .                                                                                      | 0.21  |
| Approximate length of the radius of curvature of the outer surface in the posterior half of the retina . . . . .               | 0.485 |
| Approximate radius of curvature of the external surface of the posterior part of the sclerotic coat . . . . .                  | 0.5   |
| Distance of the middle of the posterior surface of the lens from the middle of the retina . . . . .                            | 0.575 |
| Distance between the centre of the spot of entrance of the optic nerve and the middle of the fovea centralis retinae . . . . . | 0.14  |
| Diameter of the base of the cornea . . . . .                                                                                   | 0.48  |
| Diameter of the base of the iris transversely . . . . .                                                                        | 0.45  |
| Diameter of the base of the iris vertically . . . . .                                                                          | 0.43  |
| Diameter of the pupil . . . . .                                                                                                | 0.14  |

**Structure.**—The sclerotic coat is formed of connective tissue, and yields gelatine on boiling. Its fibres are combined with fine elastic tissue, and amongst them lie numerous connective tissue corpuscles lodged in cell spaces, but not by any means so regularly arranged as in the cornea. Some of the cells are pigmented. The bundles are disposed in layers both longitudinally and transversely, the longitudinal arrangement being most marked at the surfaces. These layers communicate at intervals so as not to be separable for any distance.

A few blood-vessels permeate the fibrous texture in the form of a network of capillaries with very wide meshes. In the neighbourhood of the cornea a zone of greater vascularity exists, which has been already noticed in the description of the sclerotic conjunctiva.

## THE CORNEA.

The cornea (*cornea pellucida*), the transparent fore part of the external coat, admits light into the interior of the eyeball. It is nearly circular in shape, but is occasionally wider in the transverse direction, and its arc extends to about one-sixth of the circumference of the whole globe. Having a curvature of a smaller radius than the sclerotic, it projects forwards beyond the general surface of curvature of that membrane: the degree of its curve varies, however, in different persons, and at different periods of life in the same person, being more prominent in youth than in advanced age. Its thickness is in general nearly the same throughout, viz., from  $\frac{1}{25}$  to  $\frac{1}{35}$  of an inch, excepting towards the outer margin where it becomes somewhat thinner. The posterior concave surface exceeds slightly in extent the anterior or convex, in consequence of the latter being encroached on by the superficial part of the sclerotic; the cornea being overlapped by the sclerotic (to which it is joined by continuity of tissue) like a watch glass by the edge of the groove into which it is received (see fig. 399).

## STRUCTURE OF THE CORNEA.

The cornea may be described as consisting of three parts—a stratified epithelium in front (fig. 400, 1), continuous with the epithelium of the conjunctiva; a middle part, *substantia propria*, or *cornea proper* (3), continuous with the sclerotic, composed of modified connective tissue; and a homogeneous elastic lamella (4), bounding it behind, and itself covered with a simple layer of epithelium-like cells (5).

**Epithelium of the Cornea.**—The epithelium covering the front of the cornea is of the stratified kind. The lowermost cells are columnar, with a flattened base, where they rest on the *substantia propria*, and a rounded apex, upon which a cell of the next layer commonly fits. To the base of each is attached a broad, flattened, strongly refracting process, which projects under one of the neighbouring cells. Above these columnar cells are several layers of more rounded cells, some of which (the fingered cells of Cleland) have projections from their under surface, which pass between the cells below. The uppermost of these rounded or polygonal cells present well-marked ribs and furrows, similar to those described in the cuticle; while, quite superficially, are three or four strata of flattened scaly epithelium cells, which retain their nuclei. Indications of division of the cells are observed both amongst the columnar set and amongst the more rounded ones above them (Cleland).

**The proper substance** of the cornea is composed, as before said, of a modified form of connective tissue, all the constituents of which have very nearly the same index of refraction, so that in the perfectly fresh condition it is difficult, even with the best lenses, to make out any structure at all. After death, however, and with the assistance of reagents, it may be ascertained to consist of alternating lamellæ of fibrous tissue (about sixty in number, Bowman), the planes of which are parallel to the surfaces of the cornea. The fibres of which the lamellæ are composed are nearly straight, have a definite direction in each layer; and cross one another at right angles in the alternate layers (fig. 400, *b, d*). It must, however, be understood that the latter are not individually distinct, but give off frequent offsets to the layers above

and below, so that they cannot readily be stripped away for any distance. The fibrils are collected into roundish bundles, which, as

Fig. 400.




Fig. 400.—VERTICAL SECTION OF HUMAN CORNEA FROM NEAR THE MARGIN (Waldeyer).  
MAGNIFIED.

1, epithelium ; 2, anterior homogeneous lamina ; 3, substantia propria corneæ ; 4, posterior homogeneous (elastic) lamina ; 5, epithelioid layer of the anterior chamber ; *a*, most anterior layer of the substantia propria with oblique fibres ; *b*, fibres cut across, producing a dotted appearance ; *c*, corneal corpuscles appearing fusiform in section ; *d*, bundles of fibres cut longitudinally, presenting a homogeneous appearance ; *e*, transition to the sclerotic, with more distinct fibrillation, and surmounted by a thicker epithelium ; *f*, small blood-vessels cut across.

well as the laminæ they form, are, as in the connective tissue elsewhere, separated from each other by ground substance. The latter is in greater abundance between the fibrous strata than elsewhere, and in

these parts the cell-spaces of the tissue are found. These cell-spaces, which are readily demonstrated by staining the tissue with nitrate

Fig. 401.

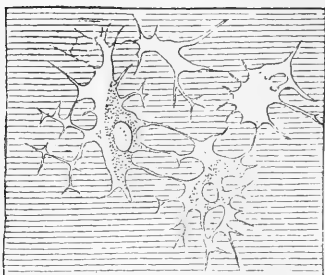


Fig. 401.—CELL-SPACES OF THE CORNEA ; MAN (Waldeyer). HIGHLY MAGNIFIED.

The figure is taken from a fresh preparation examined in aqueous humour. In each of the two lower spaces a corneal corpuscle is represented as partially filling the space.

the corpuscles is clear and hyaline, except in the neighbourhood of the large nucleus, where it is granular ; they send long branching processes along the anastomosing canals of the cell-spaces, which in some cases appear to join with those of neighbouring corpuscles. In vertical sections they appear fusiform (fig. 400, c), but horizontal sections show them to be flattened conformably with the surface. Examined on the warm stage, the corpuscles are said to exhibit slow amœboid movements in the form of protraction and retraction of their processes. These, however, are not to be confounded with the more active movements of leucocytes which may be traversing the space.

In the human cornea the cell-spaces can be filled with fluid injection by sticking the muzzle of a fine syringe into the tissue, and employing a very low pressure ; in this way a network of anastomosing stellate figures is obtained (Recklinghausen's canals) : if, however, the injection-fluid be too consistent, or if too great force be employed, the injection becomes extravasated in the interstices of the fibril bundles, the direction of which it takes ; and the appearance is produced of minute swollen tubular passages running at right angles to one another in the different layers (Bowman's corneal tubes). This appearance may still more readily be obtained if air is injected into the tissue instead of mercury (the fluid used by Bowman), and it is seen that the injection always stops at the margin of the cornea, where the tissue becomes denser as it passes into the sclerotic, whereas Recklinghausen's canals are continued into the cell-spaces of the latter.

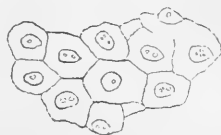The part of the cornea immediately beneath the anterior epithelium, for a thickness of from  $\frac{1}{2000}$  to  $\frac{1}{1200}$  of an inch, is denser than the rest of the tissue, and entirely free from corpuscles (fig. 400, 2). It was named the anterior elastic lamina by Bowman, but appears not to differ materially in structure from the rest of the corneal substance, fibres from which may be seen passing obliquely towards, and becoming lost in it (binding fibres) (fig. 400, a).

of silver, but also make their appearance after a time in the fresh tissue without the addition of any reagent (fig. 401), are flattened conformably with the lamella, are of an irregularly stellate figure, and freely communicate by their offsets both with others on the same plane and with those above and below. The regularity of arrangement which principally characterises them as compared with the cell-spaces of connective tissue elsewhere is no doubt dependent on the laminated structure of the cornea.

The corpuscles of the tissue—*corneal corpuscles*—lie within these cell-spaces, corresponding generally with them in form, but without entirely filling them, the room left serving for the passage of lymph and leucocytes. The protoplasm of

The **membrane of Demours or Descemet** (fig. 400, 4) (posterior elastic lamina, Bowman), not very closely united with the fibrous part of the cornea, is transparent and glassy in appearance. It is firm and structureless, but very brittle and elastic; and when shreds are removed from it they tend to curl up with the attached surface innermost. It appears not to be affected by acids, by boiling in water, or by maceration in alkalis. In thickness it varies from  $\frac{1}{30000}$  to  $\frac{1}{20000}$  of an inch. It is lined with an epithelioid covering (fig. 400, 5), which resembles that on serous membranes, consisting of a single layer of flattened polygonal cells with distinct nuclei (fig. 402). At its circumference the membrane breaks up into bundles of fibres, which are partly continued into the front of the iris, forming the "pillars of the iris," and partly into the fore part of the choroid and sclerotic coats.

Fig. 402.

Fig. 402.—PART OF THE EPI-  
THELIOID LAYER OF THE  
MEMBRANE OF DEMOURS.

To these festoon-like processes passing between the iris and posterior part of the cornea, at its junction with the sclerotic, and which are very much more marked in the eyes of the sheep and the ox than in the human eye, the name *ligamentum pectinatum iridis* was given by Hneek. The processes in question are covered with epithelioid cells, continued from Descemet's membrane, but these cells do not stretch across the *intervals* between the processes, so that the cavity of the aqueous chamber is prolonged into, and freely communicates with, cavernous spaces\* in the tissue between the processes (fig. 403, 3). A similar, but rather larger space is found slightly anterior to these in the substance of the sclerotic, close to its junction with the cornea. This, which is elliptical in section, is known as the *sinus circularis iridis*, or *canal of Schlemm* (fig. 403, 4), and is said to communicate, through the other spaces, with the aqueous chamber of the eye, owing to the open nature of the tissue in this situation, and the breaking up of the membrane of Demours into distinct bundles, as just described. But, on the other hand, the canal of Schlemm, and the other cavernous spaces in its neighbourhood, are in communication with the *veins* of the anterior part of the sclerotic, and therefore the aqueous chamber must also through them communicate with the veins. In support of this, it is stated that both the spaces and the veins become filled with coloured fluid when this has been injected into the anterior chamber. Why the blood does not find its way into the latter during life is not fully understood, since no valves have as yet been discovered in the veins which lead out from the spaces: the reason is, probably, that a greater resistance is offered to its passage here than to its return by the ordinary paths.

The above statements are mainly derived from the account given by Schwalbe; but, according to Leber, the results obtained were due to a diffusible colouring matter having been employed for filling the anterior chamber: when a non-diffusible one is used it never penetrates into the canal of Schlemm, which is simply a large circular terminal vein, or a collection of two or three plexiform veins uniting at frequent intervals into one trunk.

\* Larger in many animals, where they are known as the spaces of Fontana.

Fig. 403.

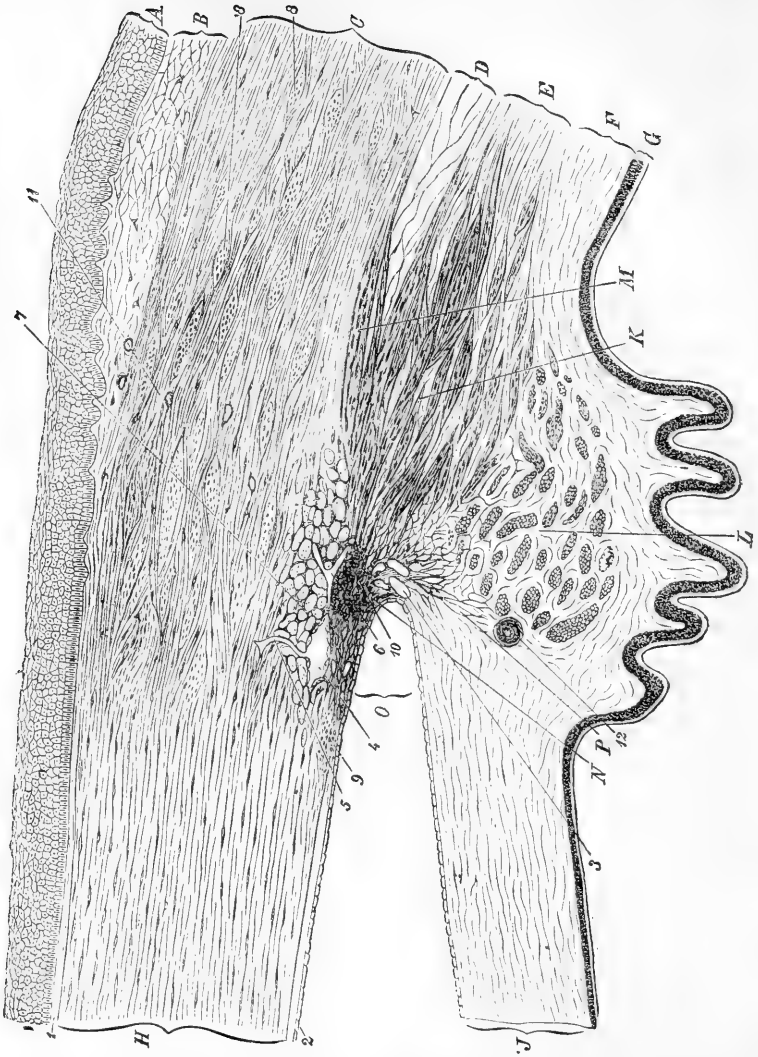


Fig. 403.—SECTION (FROM THE EYE OF A MAN, AGED 30), SHOWING THE RELATIONS OF THE CORNEA, SCLEROTIC, AND IRIS, TOGETHER WITH THE CILIARY MUSCLE, AND THE CAVERNOUS SPACES NEAR THE ANGLE OF THE ANTERIOR CHAMBER (Waldeyer). MAGNIFIED.

A, epithelium; B, conjunctival mucous membrane; C, sclerotic; D, membrana suprachoroidea; E, opposite the ciliary muscle; F, choroid, with ciliary processes; G, tapetum nigrum and pars ciliaris retinae; H, cornea (substantia propria); J, iris; K, radiating and meridional, and L, circular or annular bundles of the ciliary muscle; M, bundles passing to the sclerotic; N, tissue (ligamentum pectinatum iridis) at the angle, O, of the anterior chamber; P, line of attachment of the iris; 1, anterior homogeneous lamina of the cornea; 2, posterior homogeneous lamina, covered with epithelioid cells which are continued over the front of the iris; 3, cavernous spaces at the angle of the anterior chamber (spaces of Fontana); 4, canal of Schlemm, with epithelioid lining, and with a



vessel, 5, leading from it; 6, other vessels; 7, bundles of fibres of the sclerotic running equatorially, cut across; 8, larger ones in the substance of the sclerotic; 9, fine bundles cut across, at limit of cornea; 10, point of origin of meridional bundles of ciliary muscle; 11, blood-vessels in sclerotic and conjunctiva, cut across; 12, section of one of the ciliary arteries.

**Vessels and nerves.**—In a state of health the cornea is not provided with blood-vessels, except at the circumference, where they form very fine capillary loops and accompany the nerves. Neither are any lymphatic vessels discoverable, unless the channels in which the nerves run, and which are lined with flattened cells and in connection with the cell spaces, are to be taken as representing them. The *nerves*, on the other hand, are very numerous. Derived from the ciliary nerves, they enter the fore part of the sclerotic, and are from forty to forty-five in number (Waldeyer). Continued into the fibrous part of the cornea, they retain their dark outline for  $\frac{1}{20}$ th to  $\frac{1}{10}$ th of an inch, and then, becoming transparent, ramify and form a plexus through the laminated structure. From this *primary plexus* other nerves proceed to form a much finer and closer plexus—but of which the cords yet consist of several nerve-fibrils—at the surface of the cornea, immediately beneath the epithelium, and from this *secondary* or *subepithelial plexus* excessively fine, varicose, ultimate fibrils (fig. 404, *b*) pass among the epithelium cells, and form here a terminal network, the *intra-epithelial plexus*, which extends almost to the free surface (fig. 404, *c, c*).

Fig. 404.

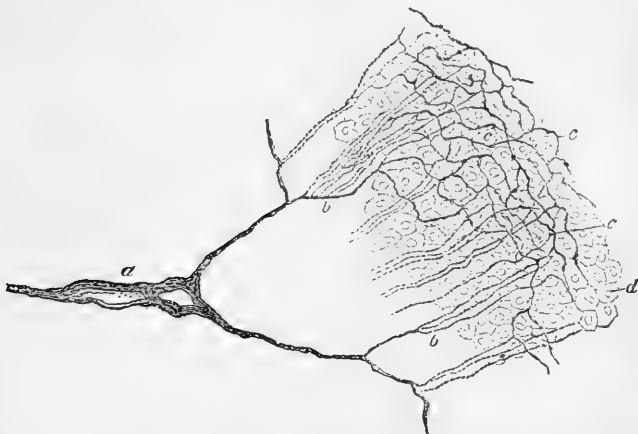


Fig. 404.—INTRA-EPITHELIAL PLEXUS OF CORNEA OF RABBIT, STAINED BY CHLORIDE OF GOLD. OBLIQUE VIEW. 300 DIAMETERS (Klein).

*a*, part of subepithelial plexus; *b, b*, tufts of fine varicose fibrils; *c*, network of these amongst, *d*, the deeper epithelial cells.

In addition to the nerves which are destined for the epithelium, others, for the proper substance of the cornea, come off from the primary plexuses, and, after uniting into one or more secondary plexuses, the cords of which are still composite, eventually form, in and among the laminae, a terminal network of ultimate fibrils, the meshes of which are much more open than those of the intra-epithelial network. An actual connection of the nerves with the corpuscles of the cornea has never been satisfactorily shown.

The larger branches of the nerves are covered with a sheath of flattened cells which, as before mentioned, are in connection with the corpuscles of the cornea. At the points of junction of the plexus, nuclei are frequently seen, but these appear to belong to the ensheathing cells, and not to be interpolated in the course of the fibres.

### THE CHOROID COAT.

The choroid coat of the eye (*tunica choroidea s. vasculosa*) is a dark brown membrane lying between the sclerotic and the retina. It reaches

Fig. 405.

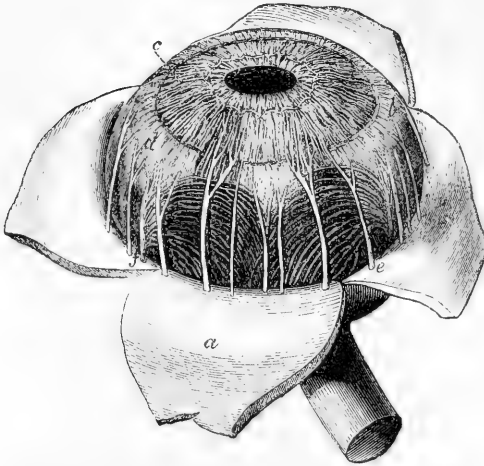


Fig. 405.—CHOROID MEMBRANE AND IRIS EXPOSED BY THE REMOVAL OF THE SCLEROTIC AND CORNEA (after Zinn). TWICE THE NATURAL SIZE.

*a*, one of the segments of the sclerotic thrown back; *b*, ciliary muscle; *c*, iris; *e*, one of the ciliary nerves; *f*, one of the vasa vorticosa or choroidal veins.

forwards nearly to the cornea, where it ends by a series of plaits or folds named ciliary processes, disposed in a circle projecting inwards at the back of the circumferential portion of the iris. At the hinder part, where the tunic is thickest, the optic nerve is transmitted. The outer surface is rough, and is connected to the sclerotic by loose connective tissue and by vessels and nerves. The inner surface, which is smooth, is covered by the hexagonal pigmented cells of the retina (which were formerly described as belonging to the choroid).

The *ciliary processes*, about seventy in number, are arranged radially

Fig. 406.

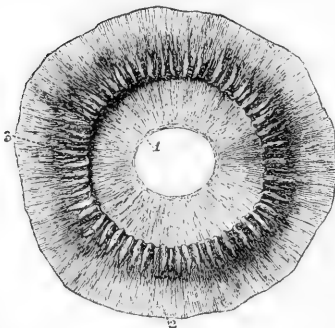


Fig. 406.—CILIAL PROCESSES AS SEEN FROM BEHIND.  $\frac{2}{3}$

1, posterior surface of the iris, with the sphincter muscle of the pupil; 2, anterior part of the choroid coat; 3, one of the ciliary processes, of which about seventy are represented.

together in form of a circle. They consist of larger and smaller folds or thickenings, without regular alternation; the small folds number about one-third of the large. Each of the larger folds, measuring about  $\frac{1}{10}$ th of an inch in length and  $\frac{1}{30}$ th in depth, forms a rounded projection

at its inner or axial end, which is free from the pigment which

invests the rest of the structure ; but externally they become gradually narrower, and disappear in the choroid coat. The smaller processes are only half as deep as the others. At and near the internal or anterior extremities the processes are connected by lateral loop-like projections. The plications of the ciliary processes fit into corresponding plications of the suspensory ligament of the lens, to be afterwards described.

#### STRUCTURE OF THE CHOROID.

The choroid consists mainly of blood-vessels united by a delicate connective tissue, with numerous large ramified cells (for the most part pigmented), united by their branches, and containing numerous leucocytes in the meshes, like lymphoid tissue. From a difference in the fineness of its constituent blood-vessels, the choroid resolves itself into two strata, outer and inner ; the former containing the larger branches, and the latter the capillary ramifications.

In the **outer part** of the coat are situated, as just stated, the larger branches of the vessels. The arteries (*short ciliary*) are comparatively large and numerous, and piercing the sclerotic close to the optic nerve (fig. 407, 1), divide into branches which are directed at first forwards before they bend inwards to end on the

inner part ; whilst the veins (*vasa vorticosa*), external to the arteries, are disposed in curves as they converge to four or five principal trunks (fig. 408, 1, 1) which pass through the sclerotic about half way between the margin of the cornea and the entrance of the optic nerve. In the intervals between the vessels are elongated and stellated pigment-cells

Fig. 407.

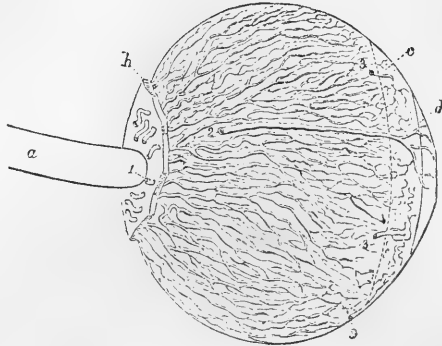


Fig. 407.—LATERAL VIEW OF THE ARTERIES OF THE CHOROID AND IRIS (from Arnold).

*a*, optic nerve ; *b*, part of the sclerotic left behind ; *c*, region of ciliary muscle ; *d*, iris ; 1, posterior ciliary arteries piercing the sclerotic and passing along the choroid ; 2, one of the long ciliary arteries ; 3, anterior ciliary arteries.

Fig. 408.

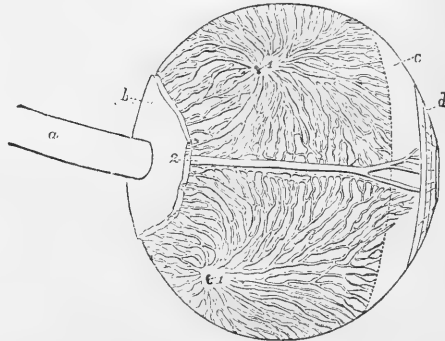


Fig. 408.—LATERAL VIEW OF THE VEINS OF THE CHOROID (from Arnold).

1, 1, two trunks of the vena vorticiosa at the place where they leave the choroid and pierce the sclerotic coat.

with fine offsets, which intercommunicate and form a network or stroma (fig. 409). Towards the inner part of the tunic, this network passes gradually into a web without pigment.

Fig. 409.

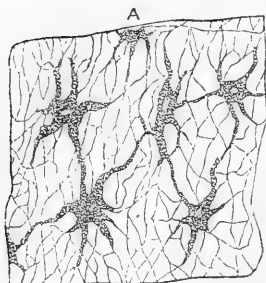


Fig. 409. — RAMIFIED PIGMENT CELLS OF THE CHOROID (Köl- liker). 300 DIAMETERS.

Externally the choroid is bounded by a membranous layer similar to the *lamina fusca* of the sclerotic, and known as the *lamina supra-choroidea* (fig. 403, D). It is loosely united to the lamina fusca by vessels and bands of connective tissue enclosing pigment-cells, and the enclosing laminae as well as the uniting structures are coated with epithelioid cells, a lymph space being thus formed between the sclerotic and choroid. This space communicates with that of the capsule of Tenon before described (p. 589) (Schwalbe).

The **inner part** of the choroid coat (*tunica Ruyschiana s. chorio-capillaris*) is formed mainly by the capillaries of the choroidal vessels.

From the ends of the arteries the capillaries radiate, and form meshes which are more delicate and smaller than in any other texture, being especially fine at

Fig. 410.

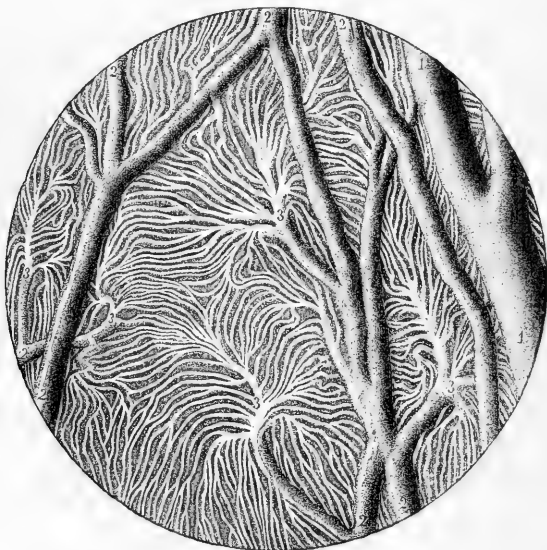


Fig. 410.—INJECTED BLOOD-VESSELS OF THE CHOROID COAT (from Sappey). 30 DIAMETERS.

1, one of the larger veins ; 2, small communicating vessels ; 3, branches dividing into the smallest vessels.

the back of the eyeball (fig. 410). The network reaches as far forwards as about  $\frac{1}{3}$ th of an inch from the cornea, or opposite the end of the

retina, where its meshes become larger, and join those of the ciliary processes.

On the inner surface of the tunica Ruyschiana is a structureless or finely fibrillated transparent membrane, the *membrane of Bruch*, which lies next to the pigmentary layer of the retina, and anteriorly, in the region of the ciliary processes, presents on its inner surface numerous microscopic reticulating folds.

The **ciliary processes** have the same structure as the rest of the choroid; but the capillary plexus of the vessels is less fine and has meshes with chiefly a longitudinal direction; and the ramified cells, fewer in number, are devoid of pigment towards the free extremities of the folds.

The *blood-vessels* of the ciliary processes (fig. 413, *d*) are very numerous, and are derived from the anterior ciliary, and from those of the fore part of the choroidal membrane. Several small arterial branches enter the outer part of each ciliary process, at first running parallel to each other and communicating sparingly. As they enter the prominent folded portion, the vessels become tortuous, subdivide minutely, and inosculate frequently by cross branches. Finally they form short arches or loops, and turn backwards to pour their contents into the radicles of the veins. On the free border of the fold, one artery, larger than the rest, extends the whole length of each ciliary process, and communicates through intervening vessels with a long venous trunk which runs a similar course on the attached surface.

**Ciliary muscle.**—At the anterior part of the choroid, between it and the sclerotic, is a zone of plain muscular tissue, the *ciliary muscle* of Bowman. It arises (fig. 403, 10) by a thin tendon from the forepart of the sclerotic close to the cornea, and between the canal of Schlemm and the spaces of Fontana, and its fibres, spreading out, are directed backwards (fig. 403, *κ*), to be inserted into the choroid opposite to the ciliary processes, and partly further back, the fibres passing equatorially and intercrossing so as to form peculiar stellate figures. A small portion (the outermost) is sometimes inserted into the sclerotic (fig. 403, *μ*). These antero-posterior, or *meridional and radiating fibres*, pass at the side next the iris into a ring of fibres (*L*), which have a circular course around the insertion of the iris. This set forms the *circular ciliary muscle* of H. Müller. This circular muscle is much developed in hypermetropic eyes, but is atrophied, or may even, it is said, be absent in myopic (Iwanoff). The ciliary muscle, at least its circular part, was formerly described as the *ciliary ligament*.

## THE IRIS.

The *iris* is the contractile and coloured membrane which is seen behind the transparent cornea, and gives the tint to the eye. In its centre it is perforated by an aperture—the *pupil*.

By its circumferential border, which is nearly circular, the iris is connected with the choroid, the cornea, and the ciliary muscles: the free inner edge is the boundary of the pupil, and is constantly altering its dimensions during life. The iris measures  $\frac{1}{2}$  an inch across, and, in a state of rest, about  $\frac{1}{5}$ th of an inch from the circumference to the pupil. Its surfaces look forwards and backwards. The anterior, variously coloured in different eyes, is marked by wavy lines converging towards

the pupil, near which they join in a series of irregular elevations ; and, internal to these, other finer lines pass to the pupil. The posterior surface is covered with dark pigment, prolonged from the pigmentary layer of the retina ; and, this being removed, there is seen at the margin of the pupil a narrow circular band of fibres (sphincter muscle of the pupil), with which the converging lines are blended.

The **pupil** is nearly circular in form, and is placed a little to the inner side of the centre of the iris. It varies in size according to the contraction or relaxation of the muscular fibres, this variation ranging from  $\frac{1}{10}$ th to  $\frac{1}{3}$ rd of an inch, and regulating the quantity of light admitted to the eyeball.

#### STRUCTURE OF THE IRIS.

Fibrous and muscular tissues form the framework of the iris, and pigment cells are scattered through the texture. It contains also numerous vessels and nerves. In front and behind is placed a distinct layer of pigmented cells. The delicate epithelioid layer of the membrane of Descemet (fig. 403,2) is continued from the margin of the cornea over the front of the iris ; its cells are smaller and more granular than those which cover the membrane of Descemet, but are otherwise similar.

The **stroma** consists of cells and fibres of connective tissue, the latter directed radially towards the pupil, and circularly at the circumference ; these, interweaving with one another, form a web which is more open in the substance of the iris than near the surfaces.

The **muscular tissue** is of the non-striated kind, and is disposed as a ring (*sphincter*) around the pupil, and as rays (*dilatator*) from the centre to the circumference.

The *sphincter* (fig. 411, *a*) is the flat narrow band on the posterior surface of the iris, close to the pupil, and is about  $\frac{1}{40}$ th of an inch wide. At the edge of the pupil the fibres are close together, but at the peripheral border they are separated, and form less complete rings.

The *dilatator* (*b, b*), less apparent than the sphincter, begins at the ciliary or outer margin of the iris, and its fibres, collected into bundles,

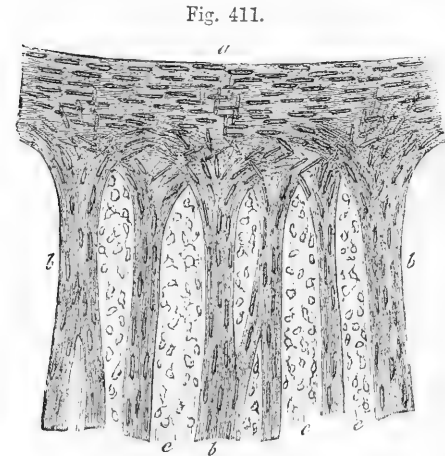


Fig. 411.—A SMALL PART OF THE IRIS, SHOWING THE MUSCULAR STRUCTURE (from Kölliker). 350 DIAMETERS.

The specimen is from an albino-rabbit, and has been treated with acetic acid : *a*, the sphincter muscle at the margin of the pupil ; *b*, fasciculi of the dilatator muscle ; *c*, connective tissue with nuclei of cells rendered evident by the acid.

or forming a continuous membrane, situated near the posterior surface, converge towards the pupil, and form a network by their intercommunications. At the pupil they blend with the sphincter, some reach-

ing near to its inner margin ; and at the ciliary margin also they arch round and take a somewhat circular direction.

In the substance of the iris anteriorly and throughout its thickness are variously-shaped ramified **pigment cells** like those in the choroid. The pigment contained in them is yellow, or of lighter or darker shades of brown, according to the colour of the eye. At the posterior surface is a covering of dark pigment, the *uvca* of authors ; this is continuous with the (retinal) pigmentary layer lining the choroid and the ciliary processes, and here consists of several strata of small roundish cells filled with dark pigment. The colour of the iris depends on the pigment ; in the different shades of blue eye it arises from the black pigment of the posterior surface appearing more or less through the texture, which is only slightly coloured or is colourless ; but in the black, brown, and grey eye, the colour is due to the pigment scattered through the iris substance.

**Pupillary membrane** (*membrana pupillaris*).—In foetal life a delicate transparent membrane thus named closes the pupil, and completes the curtain of the iris. The pupillary membrane contains minute vessels, continuous with those of the iris and of the capsule of the crystalline lens ; they are arranged in loops, which converge towards each other, but do not quite meet at the centre of the pupil (fig. 412). At about the seventh or eighth month of foetal life these vessels gradually disappear ; and, in proportion as the vascularity diminishes, the membrane itself is absorbed from near the centre towards the circumference. At the period of birth, often a few shreds, sometimes a larger portion, and occasionally the whole membrane is found persistent.

#### Vessels and nerves of the iris.

The *long ciliary arteries*, two in number, pierce the sclerotic a little before, and one on each side of, the optic nerve. Having gained the interval between the sclerotic and choroid coats, they extend horizontally forwards (fig. 407, 2) through the loose connective tissue to the ciliary muscle. In this course they lie nearly in the horizontal plane of the axis of the eyeball, the outer vessel being however a little above, and the inner one a little below the level of that line. A short space behind the fixed margin of the iris each vessel (fig. 414, 1, 1) divides into an upper and a lower branch, and these, anastomosing with the corresponding vessels on the opposite side and with the anterior ciliary, form a vascular ring (*circulus major*) in the ciliary muscle. From this circle smaller branches arise to supply the muscle ; whilst others (fig. 414, 5) converge towards the pupil, and there, freely communicating by transverse offsets from one to another, form a second circle of anastomosis (*circulus minor*), from which capillaries are continued inwardly and end in small veins.

Fig. 412.

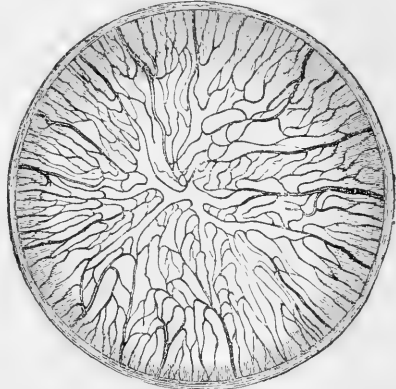


Fig. 412.—PUPILLARY MEMBRANE OF NEW-BORN KITTEN, INJECTED (Kölliker, from a preparation by Thiersch). MAGNIFIED.

The *anterior ciliary arteries* (fig. 414, 2, 2), five or six in number, but smaller than the vessels just described, are supplied from the muscular and lachrymal branches of the ophthalmic artery, and pierce the sclerotic about a line behind the margin of the cornea; they divide into branches which supply the ciliary processes, and join the *circulus major*.

Besides these special arteries, numerous minute vessels enter the iris from the ciliary processes.

The *veins of the iris* follow closely the arrangement of the arteries just described. The canal of Schlemm communicates with this system of vessels.

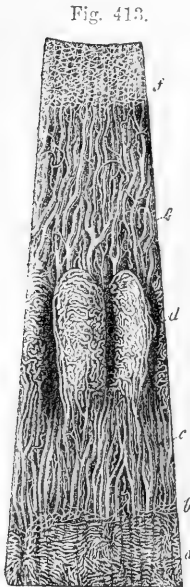


Fig. 413.—VESSELS OF THE CHOROID, CILIARY PROCESSES AND IRIS OF A CHILD (Arnold). MAGNIFIED 10 TIMES.

*a*, capillary network of the posterior part of the choroid ending at *b*, the ora serrata; *c*, arteries of the corona ciliaris, supplying the ciliary processes *d*, and passing into the iris *e*; *f*, the capillary network close to the pupillary margin of the iris.

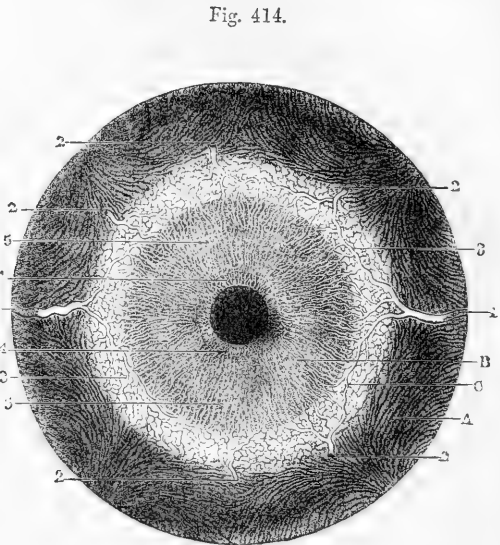


Fig. 414.—FRONT VIEW OF THE BLOOD-VESSELS OF THE CHOROID COAT AND IRIS FROM BEFORE (Arnold). MAGNIFIED  $2\frac{1}{2}$  TIMES

*A*, choroid; *B*, iris; *C*, ciliary muscle, &c.; 1, 1, long ciliary arteries; 2, 2, five of the anterior ciliary arteries ramifying at the outer margin of the iris; 3, loop of communication between one of the anterior and one of the long ciliary arteries; 4, internal circle and network of the vessels of the iris; 5, external radial network of vessels.

The *ciliary nerves* (fig. 415, 1), about fifteen in number, and derived from the lenticular ganglion and the nasal branch of the ophthalmic division of the fifth nerve, pierce the sclerotic near the entrance of the optic nerve, and come immediately into contact with the choroid. They are somewhat flattened in form, are partly imbedded in grooves on the inner surface of the sclerotic, and communicate occasionally with each other before supplying the cornea and entering the ciliary muscle. When the sclerotic is carefully separated from the subjacent structures,



these nerves are seen lying on the surface of the choroid, into which they send branches, and in which they form between and amongst the blood-vessels a fine plexus of pale fibres rich in ganglion-cells, the

Fig. 415.

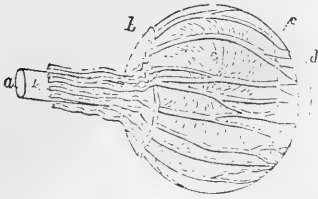


Fig. 416.

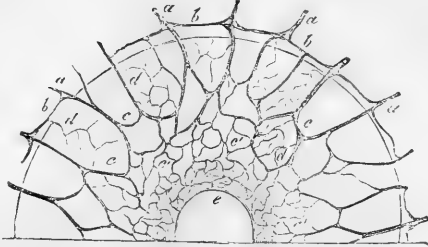


Fig. 415.—LATERAL VIEW OF THE CILIARY NERVES (Arnold). DIAGRAMMATIC.

*a*, optic nerve; *b*, back part of the sclerotic; *c*, ciliary muscle; *d*, iris; *e*, outer surface of the choroid coat; *l*, five of the ciliary nerves passing along the sheath of the optic nerve, piercing the sclerotic posteriorly, and thence passing forward on the choroid membrane to the ciliary muscle and iris. The nerves are represented too large.

Fig. 416.—DISTRIBUTION OF NERVES IN THE IRIS (Kölliker). 50 DIAMETERS.

The preparation was from the eye of an albino rabbit; *a*, smaller branches of the ciliary nerves advancing from the choroid; *b*, loops of union between them at the margin of the iris; *c*, arches of union in the iris; *c'*, finer network in the inner part; *e*, sphincter pupillae muscle.

groups of cells being often applied to the walls of the vessels. Within the ciliary muscle the nerves also subdivide minutely, forming here another plexus, which contains a number of medullated fibres and the cells of which are smaller. A few recurrent branches appear to pass back from it into the choroid coat, but the greater number pass on to the iris (fig. 416, *a, a'*). In the iris the nerves follow the course of the blood-vessels, dividing into branches, which communicate with one another as far as the pupil, forming a close plexus of fine non-medullated fibres. Their ultimate termination is not ascertained.

### RETINA OR NERVOUS TUNIC.

The retina is a delicate almost pulpy membrane, which contains the terminal part of the optic nerve. It lies within the choroid coat, and rests on the hyaloid membrane of the vitreous humour. It extends forwards nearly to the outer edge of the ciliary processes of the choroid, where it ends in a finely indented border—*ora serrata*. From this border there is continued onwards a thin layer of transparent, nucleated cells of an elongated or columnar form, constituting the *pars ciliaris retinae*, which reaches as far as the tips of the ciliary processes, and there disappears. The thickness of the retina diminishes from behind forwards, varying from  $\frac{1}{50}$ th of an inch to  $\frac{1}{200}$ th of an inch. In the fresh eye it is translucent and of a light pink colour; but after death it soon becomes opaque, and this change is most marked under the action of water, alcohol, and other fluids. Its outer surface is covered with a layer of hexagonal pigment-cells which, as the study of the development of the parts shows, must be regarded as belonging to the retina and not to the choroid, to which it has usually been ascribed. More-

over the pigment-cells send fine non-pigmented offsets between the external retinal elements. When the choroid is detached these offsets

Fig. 417.

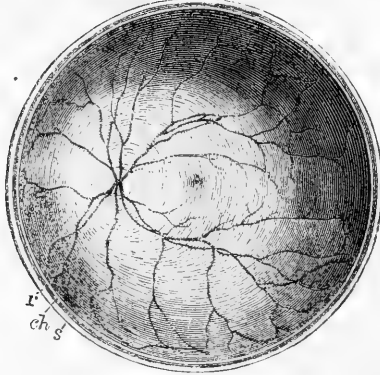


Fig. 417.—THE POSTERIOR HALF OF THE RETINA OF THE LEFT EYE VIEWED FROM BEFORE (Henle). Twice the natural size.

*s*, cut edge of the sclerotic; *ch*, choroid; *r*, retina: in the interior at the middle the macula lutea with the depression of the fovea centralis is represented by a slight oval shade; towards the left side the light spot indicates the colliculus or eminence at the entrance of the optic nerve, from the centre of which the arteria centralis is seen sending its branches into the retina, leaving the part occupied by the macula comparatively free.

are ruptured and the pigmentary layer comes away with it. The inner surface of the retina is smooth: on it the following objects may be seen (fig. 417). In the axis of the ball is a yellow spot—*macula lutea* (*limbus luteus*, Sömmerring)—which is somewhat elliptical in shape, and about  $\frac{1}{10}$ th of an inch in diameter: in the centre of this, again, is a slight

Fig. 418.

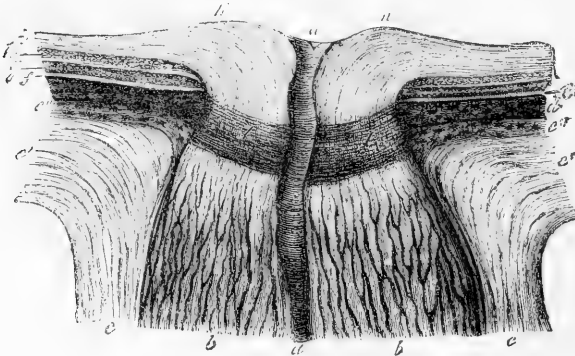


Fig. 418.—SECTION THROUGH THE MIDDLE OF THE OPTIC NERVE AND THE TUNICS OF THE EYE AT THE PLACE OF ITS PASSAGE THROUGH THEM (Ecker). ♀

*a*, arteria centralis retinae; *b*, fasciculi of optic nerve fibres with neurilemma; *c*, sheath of the optic nerve, passing into *c'*, the sclerotic coat; *c''*, membrana fusca; *d*, choroid; *e, f*, layer of rods and cones; *g*, the nuclear layers; *h*, layer of nerve-cells; *i*, layer of nerve-fibres; *k*, colliculus or eminence at the entrance of the optic nerve; *l*, lamina cribrosa.

hollow, *fovea centralis*, and, as the retina is thinner here than elsewhere, the pigmentary layer is clearly visible through it, giving rise to an appearance as of a hole through the tunic. About  $\frac{1}{10}$ th of an inch inside the yellow spot is the round disc, *porus opticus*, where the optic nerve expands, and in its centre the point from which the vessels of the retina branch. At this place the nervous substance is slightly elevated so as to form an eminence (*colliculus nervi optici*) (fig. 418, K, K.).

MICROSCOPIC STRUCTURE OF THE RETINA.

When vertical sections of the retina, *i.e.*, sections made perpendicularly to its surface, are submitted to microscopic examination, eight distinct strata are recognizable, together with certain fibrous structures which pass vertically through the membrane and connect the several layers.

Fig. 419

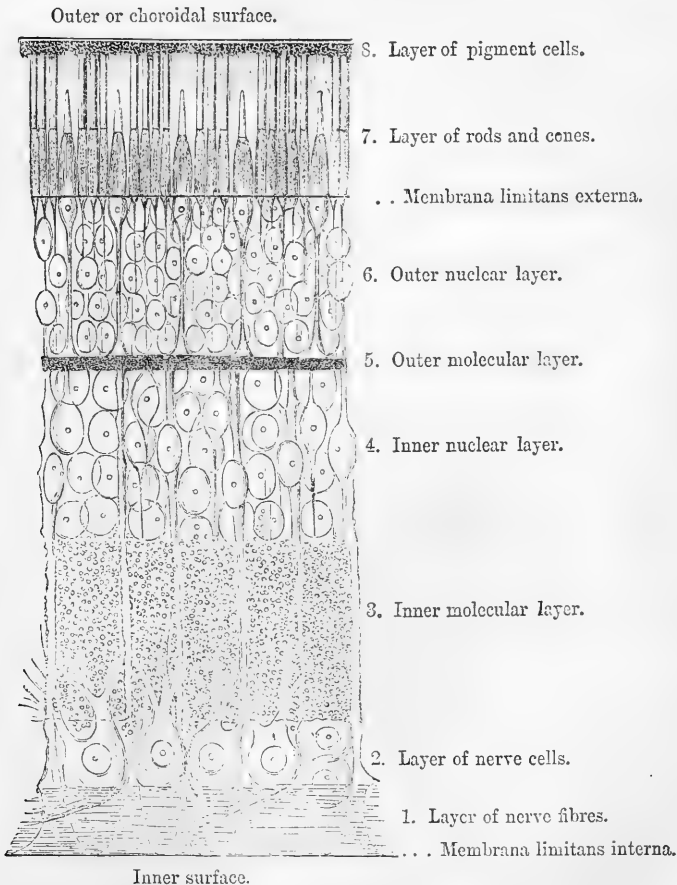


Fig. 419.—DIAGRAMMATIC SECTION OF THE HUMAN RETINA (Schultze).

The following are the designations of the layers, from within outwards :—

1. The layer of nerve-fibres (nerve-layer).
2. The layer of nerve-cells (ganglionic layer).
3. The inner molecular layer.
4. The inner nuclear layer.
5. The outer molecular layer (internuclear).
6. The outer nuclear layer.
7. The layer of rods and cones (columnar layer, Jacob's membrane).
8. The layer of hexagonal pigment cells (pigmentary layer).

In addition to these eight strata two excessively delicate membranes are described—the one, *membrana limitans interna*, bounding the retina on its inner surface, next to the hyaloid membrane of the vitreous humour; the other, *membrana limitans externa*, lying between the outer nuclear layer and the layer of rods and cones; but, as will be afterwards explained, these so-called “membranes” are merely the boundary lines of the sustentacular tissue of the retina. The accompanying figure, from Max Schultze, represents (somewhat diagrammatically) the general arrangement and structure of the layers.

Fig. 420.

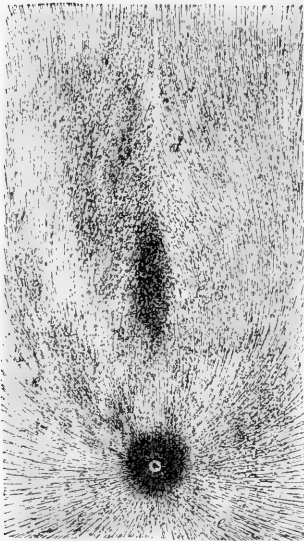


Fig. 420.—PART OF THE LAYER OF NERVE-FIBRES ON THE INNER SURFACE OF THE RETINA (Kölliker). SLIGHTLY MAGNIFIED.

*a*, colliculus opticus; *b*, yellow spot; *c*, *d*, bundles of nerve fibres passing round this; *e*, *e*, bundles radiating in all directions from the point of entrance of the nerve.

**1. Layer of nerve-fibres.**—The optic nerve (fig. 418, *b b*) passes at the porus opticus directly through the thickness of the retina to reach its inner surface, on which it spreads out in form of a membrane (fig. 420) towards the ora serrata. Its fibres, which are destitute of a primitive sheath and vary much in size, lose their medullary sheath on reaching the retina, consisting there of axis-cylinder only (Bewman). They are collected into small bundles, which, compressed laterally, intercommunicate and form a delicate web with narrow elongated meshes. At the yellow spot this layer is wanting (fig. 420, *b*), elsewhere it forms a continuous stratum, gradually diminishing in thickness in front, interrupted only by the enlarged ends of the fibres of Müller to be afterwards described (p. 615). The nerve-bundles, as well as the cells of the next layer, are partially covered and supported by flattened connective tissue corpuscles.

**2. Ganglionic layer.**—Immediately external to the nerve-fibre layer is a stratum of nerve-cells (figs. 419, 422, 2), of a spheroidal or pyriform figure, and having in the fresh condition a pellucid aspect. Each cell has a single unbranched process extending obliquely from its rounded inner extremity amongst the fibres of the preceding layer, with one of which it is no doubt continuous. From the opposite

end of the cell, which is frequently imbedded in the granular substance of the succeeding layer, one or more much thicker processes extend outwards for a variable distance into that stratum, and after branching dichotomously once or twice become lost in its substance. The number of nerve cells and consequently the thickness of the ganglionic layer in the different regions of the retina varies exceedingly. Over the greater part of the retina they form a single stratum, but in the neighbourhood of the yellow spot they are placed two or three deep. At the spot itself (fig. 426, 2) they are very thickly set (from eight to ten deep); the cells are also much smaller here, and are bipolar. Towards the ora serrata, on the other hand, there is but a single stratum, and that frequently incomplete.

3. **Inner molecular layer.**—Next in order to the ganglionic layer comes a comparatively thick stratum of a granular-looking substance, which in the perfectly fresh condition presents, under high powers of the microscope, the appearance of a pale, homogeneous matrix with numerous minute clear globules or granules, imbedded in it. The fibres of Müller pass through the substance composing this layer without being directly connected with it; the offsets of the ganglion-cells can also be traced into it for a greater or less distance; and, finally, the fine, varicose central processes of the nuclear bodies of the layer next to be described, can be followed a short distance into the layer in question (fig. 422), passing in the direction of the ganglionic and nervous layers. Flattened cells, similar to those noticed in the nerve-fibre and ganglionic layers, are also said to occur in the inner molecular layer, especially on its surfaces (Golgi and Manfredi).

The exact nature of the substance composing this layer is still a matter of doubt. By Max Schultze it was described as a reticulating mass with numerous fine intercommunicating meshes, supported in which was supposed to be a fine network formed by ramifications of the ganglion-cell processes, which become lost to view in this layer. Schultze further described it as being of the same nature as and intimately connected with the system of Müllerian fibres. Schwalbe, however, has shown that these pass through the inner molecular layer sometimes with a smooth contour and always without giving off lateral offsets to it; and, moreover, that they are of a different chemical nature from the substance of the molecular layer.

4. **Inner nuclear layer.**—This is mainly composed of several strata of characteristic transparent nucleus-like bodies, which are frequently known collectively as the "inner granules," but are nevertheless of three or four distinct kinds. Those of one kind, few in number, are connected with the fibres of Müller as these pass through the layer, and will most conveniently be described with those fibres. Those of the *second* kind (fig. 422, 4), by far the most numerous, are prolonged at either end into a delicate fibre, and contain each a clear, round or oval nucleus, with a distinct nucleolus. These last (the nucleus and nucleolus) resemble very closely the analogous structures found in ganglion-cells, and indeed the bodies in question are commonly regarded as bipolar nerve-cells, but with the protoplasm of the cell very small in amount, devoid of granules, and principally collected at either end of the cell.

Of the cell processes or fibres which proceed from these ends, the inner one, or that extending into the inner molecular layer towards the ganglionic and nerve-fibre layers, is finer than the other, is always unbranched, and commonly exhibits minute varicosities similar to those on the ultimate

fibrils of the nerves. A direct connection of these inner processes with the outwardly extending branches of the large nerve-cells of the ganglionic layer has never been completely substantiated; but it is considered probable that some of them may be so connected, while others may pass directly to the nerve-layer and there become continued into a nerve-fibre. The outer prolongation or process of the bipolar cell is on the other hand thicker than the inner one, and, moreover, after a longer or shorter course, divides into branches. This division commonly occurs just beyond the limit of the inner nuclear layer, immediately within the succeeding (outer molecular) layer; frequently it is into two, which pass off almost at a right angle. The further destination of these branches is unknown, but they are believed to break up into exquisitely fine fibrils, forming a plexus in this situation. The outer process differs further from the inner in not exhibiting varicosities; occasionally it has a finely granular appearance. These cells have sometimes, but rarely, been observed to possess more than two such processes (Ritter, Hulke).

The relative length of the inner and outer process naturally differs according to the position of the individual cell in the nuclear layer; if the cell is near the inner molecular layer the outer process will have a longer course to reach the outer molecular layer, and, conversely, if the cell is near the latter; in almost all cases, however, the inner process is the longer of the two, extending, as before mentioned, for some distance into the contiguous molecular layer. At the macula lutea these processes or fibres of the inner nuclear layer have a markedly oblique direction, in other parts of the retina they run vertically towards the surfaces.

The *third* kind of "inner granule" is entirely different from the other two. The cells, each of which has a distinct nucleus and nucleolus, are exclusively collected at the innermost part of the inner nuclear layer, where in man they form an almost complete stratum (Vintschgau). They appear to be devoid of processes, but further

Fig. 421.

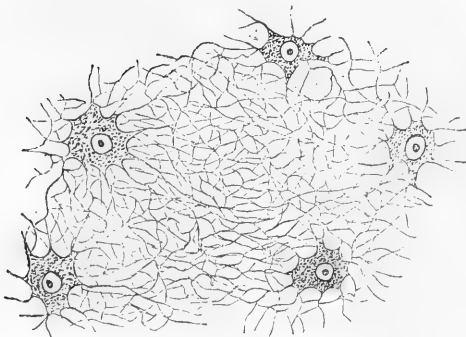


Fig. 421.—BRANCHED CELLS WITH THE UNITING FELTWORK OF FIBRES FROM THE OUTER MOLECULAR LAYER OF THE HORSE'S RETINA (Schwalbe). HIGHLY MAGNIFIED.

investigations are required as to their nature, as well as with regard to certain other cells (*fourth* variety) which are scattered here and there in the *outermost* part of the layer, next to the outer molecular layer, and are distinguished from the ordinary "inner granules" by their rounded form and larger size, and also, according to W. Krause, in possessing only one process—an inner one—which he

regards as a terminal nerve-fibre.

5. **Outer molecular layer.**—The outer molecular layer is much thinner than the inner, but otherwise presents, in vertical sections of hardened

retina, a similar granular appearance, with a few scattered nuclei in its substance, and in which, in the human retina and in that of most mammals, it is difficult to make out any definite structure. In the horse's retina, however, as Rivolta and others have shown, it is possible, in properly prepared and isolated portions of the layer, to ascertain the existence within it of flattened, irregular or stellate, finely branched, delicately granular cells to which the nuclei in question belong (fig. 421). The cell-offsets, which are excessively fine, form by repeated branching and union a close network or feltwork throughout the layer; the substance of which is in this way formed by them. The nuclei of the cells are clear and distinct, each with a comparatively large nucleolus; the fine fibres of the network are stated by Golgi and Manfredi to exhibit varicosities like nerve-fibrils, but according to Schwalbe the varicose fibrils in all probability do not actually form a part of the network but are intercalated in its meshes. It is, therefore, uncertain whether these cells are to be regarded as of a nervous nature themselves or merely as supporting structures for the true nervous elements. There is little doubt that a similar structure exists in mammalia generally.

**6. Outer nuclear layer.**—This (figs. 419, 422, 6) resembles very closely at first sight the inner nuclear layer, appearing, like that, to consist of several strata of clear, oval or elliptical, nuclear corpuscles (outer granules), from the ends of which delicate fibres are prolonged. They differ, however, essentially from the inner granules, and may be readily distinguished from them. These outer granules are of two kinds, which present well-marked differences and are known respectively as the rod-granules and cone-granules, according as they are connected with the rods or with the cones of the next retinal layer. Those which are connected with the *rods* are, in most parts of the retina, by far the more numerous, and form the main thickness of the outer nuclear layer. They may be regarded as enlargements or swellings in the course of delicate fibres (rod-fibres), which extend from the inner ends of the rods at the *membrana limitans externa* through the thickness of this layer to the outer molecular layer. The enlargements, of which there is but one to a fibre, situate at any part of its course, are each occupied by an elliptical nucleus which is devoid of a nucleolus, but which, in the fresh condition, exhibits a remarkable cross-striped appearance (Henle), the strongly refracting substance which mainly composes it being interrupted by bands or disks of a clearer less refracting material, usually two in number, one on each side of the middle line (fig. 422), but occasionally single and median (see the left-hand one in fig. 422). The rod-fibres are of excessive fineness, and exhibit frequently minute varicosities in their course: each is directly continuous at the outer end with one of the rods, but at the inner end appears usually to terminate in a somewhat larger varicosity, from the margin of which exquisitely fine fibrils may, in some animals, be traced extending into the substance of the outer molecular layer.

Those outer granules which are connected with the *cones* are, in most parts of the retina, much fewer in number than the rod-granules, from which they are distinguished by their shape, which is somewhat pyriform, by the absence of transverse striation, and by their position—for they occupy the part of the outer nuclear layer nearest the *membrana limitans externa*, and the larger end of each is thus in close proximity to the base of the corresponding cone, with which it is

Fig. 422.

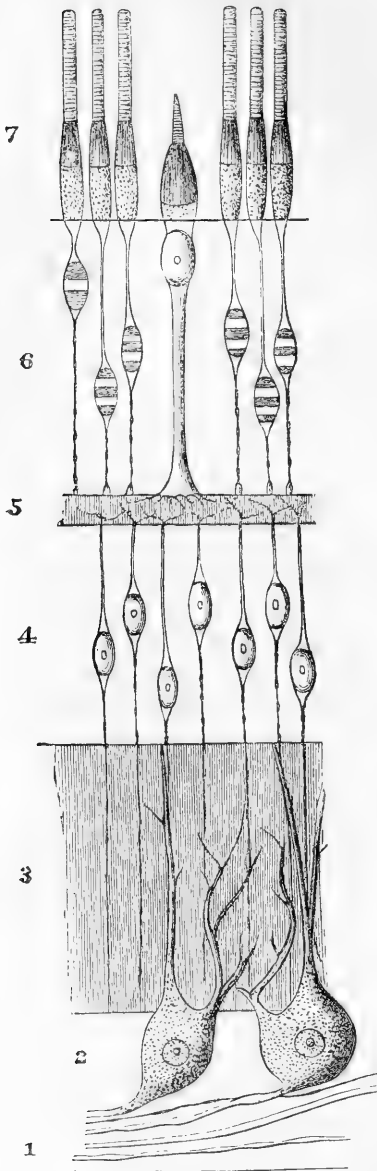


Fig. 422.—THE NERVOUS AND EPITHELIAL ELEMENTS OF THE RETINA (SEMIDIAGRAM-MATIC). After Schwalbe.

The numbers are the same as in fig. 419. The extent of the molecular layers is indicated merely by lines of shading.

directly connected, or there is at most a short, comparatively thick stalk uniting the two (see fig. 422). At the macula lutea, however, where only cone-granules are met with, many of them are further removed from the limiting membrane, and the stalk is then longer and more attenuated. The nucleus of each, which, as in the case of the rod-granules, occupies almost all the enlargement, contains a distinct nucleolus. The cone-fibre is very much thicker than the rod-fibres above described. It passes from the smaller end of the pear-shaped enlargement straight through the outer nuclear layer to reach the outer molecular layer, upon which it rests by a somewhat spread-out end. From the edges of this, numerous excessively-fine fibrils pass into the substance of the molecular layer. Moreover a delicate striation or fibrillation has occasionally been described in the cone-fibre itself.

**7. The layer of rods and cones.**—Bacillary layer (fig. 422, 7). The elements which compose this layer are, as their name implies, of two kinds, those of the one kind—the *rods*—having an elongated cylindrical form; the *cones* on the other hand being shorter, much thicker, bulged at the inner end or base, and terminated externally by a finer tapering portion. Both rods and cones are closely set in a pallisade-like manner over the whole extent of the retina between the *membrana limitans externa* and the pigmentary layer (fig. 419, 7); except at the macula lutea, where only cones are met with, the rods far exceed the cones in number. Their relative number and arrangement is well exhibited when the layer is viewed from the outer surface, as in fig. 423, where *a* represents a portion of the layer from the macula lutea; *b*, from the im-



mediate neighbourhood of the latter, and *c*, from the peripheral part of the retina.

The rods and the cones, although differing thus in shape and size

Fig. 423.—OUTER SURFACE OF THE COLUMNAR LAYER OF THE RETINA (Kölliker). 350 DIAMETERS.

*a*, part within the macula lutea, where only cones are present; *b*, part near the macula, where a single row of rods intervenes between the cones; *c*, from a part of the retina midway between the macula and the ora serrata, showing the preponderance of the rods.

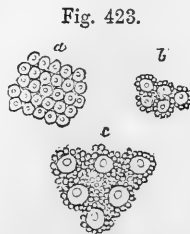
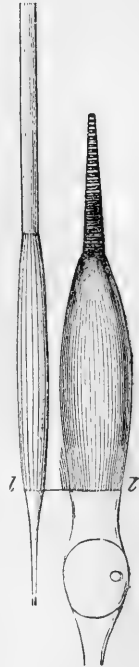


Fig. 423.

Fig. 424.

Fig. 424.—A ROD AND A CONE FROM THE HUMAN RETINA (Max Schultze). HIGHLY MAGNIFIED.

In the rod the longitudinal striation of both the outer and inner segments is shown; in the cone the transverse striation of the outer segment and the longitudinal of the inner. In both the fibrillation of the inner segment is much more extensive than usual; *l*, limitans externa.



agree in many points of structure. Thus, each consists of two distinct segments—an inner and an outer; the division between the two occurring, in the case of the rods, about the middle of their length (in man); in the cones at the junction of the finer tapering end-piece with the basal part; consequently, the outer and inner segments of the rods are nearly similar in size and shape, the inner being, however, slightly bulged as a rule, whereas the inner segment of each cone far exceeds the outer one in size, the latter appearing merely as an appendage of the inner segment (fig. 424). The two segments both of the rods and cones exhibit well-marked differences, both in their chemical and optical characters, as well as in the structural appearances which may be observed in them. Thus, while in both the outer segment is doubly refracting in its action upon light, the inner is, on the contrary, singly refracting: the inner becomes stained by carmine, iodine, and other colouring fluids, whilst the outer remains colourless. The outer segment in both shows a tendency to break up into a number of minute super-imposed disks, whereas the inner segment is itself again distinguishable into two parts—an outer part, apparently composed of fine fibrils, and an inner part, homogeneous, or finely granular, and at the membrana limitans externa, directly continued into a rod or cone-fibre, the disposition of which in the outer nuclear layer has been already described.

In the *outer segments* of the rods there can be detected by the aid of a powerful microscope, besides a delicate transverse striation (fig. 422), corresponding to the superposed disks of which, as above indicated, they appear composed, also fine longitudinal markings which are due to slight linear grooves by which they are marked in their whole extent. Externally the segment projects into the pigmentary layer with a somewhat rounded-off extremity. Internally it is overlapped for a short distance by a delicate fibrillated prolongation

of the margin of the inner segment. The outer segments of the *cones* taper gradually to a blunt point and do not appear to exhibit the superficial groovings, but the transverse markings are somewhat more evident than in the rods (fig. 424), although they do not so readily break up into the separate disks as in the latter. This has been accounted for by supposing the existence of an excessively delicate membrane covering the whole of the outer segment of the cones.

In the *inner segments*, the proportion which the fibrillated part bears to the homogeneous basal part differs in the rods and cones. In the rods the fibrils usually occupy only the outer third of the inner segment (fig. 422), ceasing abruptly at its junction with the middle third; in the cones, on the other hand, they occupy about the outer two-thirds of the segment, only the part nearest the *membrana limitans* remaining free from fibrils. The fibrils in question are for the most part straight and parallel, and strongly refracting. Sometimes, in the cones, instead of this outer part of the inner segment appearing fibrillated, it appears homogeneous, but is nevertheless well marked off from the inner part by its strong refractivity.

This condition of a part of the inner segment of the cones is much better marked in most of the lower vertebrata, where it is met with as a distinct strongly refracting body, situated in the middle or outer part of the segment, and is known from its shape as the "ellipsoid." Moreover, in these animals, the fibrils are absent from the inner segments of the rods also, a peculiar, strongly refracting "lenticular" body being met with at their outer part, corresponding to the ellipsoid of the cones. Further, in birds, reptiles, and amphibia, there is found in the extreme outer part of the inner segment of each cone a minute globular body, apparently of a fatty nature, which in some is clear and colourless, but in many cones is brightly-coloured of a tint varying in different cones from red to green—red and yellow being the most common. Blue and violet are not met with, but by the action of iodine the colours of all become changed to blue. Sometimes the whole inner segment is found to be slightly tinted of the same colour as the "oil-globule." In all vertebrates below mammals, double- or twin-cones are here and there met with, which resemble two cones joined near their base, but separate and distinct towards their apex. Numerous other differences and peculiarities are found in animals: thus in birds the cones are more numerous than the rods; in many reptiles only cones are met with; while in some fishes (sharks and rays), in most nocturnal mammals, and in the owl, the cones are either altogether absent or are but few and rudimentary.

Fig. 425.

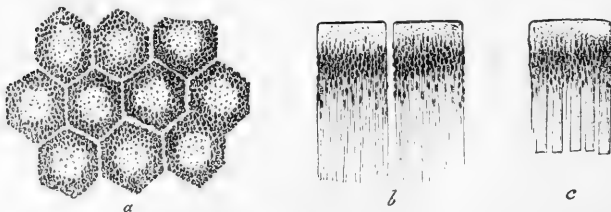


Fig. 425.—PIGMENTED EPITHELIUM OF THE HUMAN RETINA (Max Schultze.) HIGHLY MAGNIFIED.

*a*, cells seen from the outer surface with clear lines of intercellular substance between; *b*, two cells seen in profile with fine offsets extending inwards; *c*, a cell still in connection with the outer ends of the rods.

8. **The pigmentary layer.**—This layer, which bounds the retina externally, and was formerly known as the hexagonal pigment of the choroid, consists of a single stratum of hexagonal epithelium cells (fig. 425). The outer surface of each cell—that which is turned towards the choroid—is smooth and flattened, and the part of the cell near this surface is devoid of pigment, and usually contains the nucleus; the inner boundary, on the other hand, is not well marked, for the substance of the cell, which here is loaded with pigment, is prolonged into excessively fine, straight, filamentous processes (fig. 425, *b*), which extend for a certain distance between and amongst the outer segments of the rods and cones. The pigment granules are placed for the most part, both in the cells and cell-processes, with their long axes at right angles to the surface of the retina. The intervals between the rods and cones are only partially filled by the processes of the hexagonal pigment-cells; the remaining part appears to be occupied by a clear pellucid material which, according to Henle and H. Müller, is of a soft elastic consistence during life and in the fresh condition, but soon liquefies after death; but according to Schwalbe, would appear to be normally liquid. In the embryo, between the hexagonal pigment and the remainder of the retina, there is a distinct cavity or cleft filled with fluid (remains of primary optic vesicle).

**The sustentacular tissue of the retina: Müllerian or radial fibres.**—In addition to the elements above described, which are for the most part special to the particular layer where they occur, there are certain other structures which are common to all the layers, passing through the whole thickness of the retina from the inner almost to the outer surface, and, if not actually themselves of the nature of connective tissue, at least serving the same kind of purpose, namely, to bind together and support the more essential and delicate structures of the membrane. These sustentacular fibres or fibres of Müller, commence at the inner surface of the retina by a broad conical base or foot, which is not solid but hollowed out, the hollow being filled by granular protoplasmic substance, and often containing a nucleus. The feet of adjoining fibres are united together at their edges, so as to give, in vertical sections of the retina, the appearance of a distinct boundary line (fig. 419); this has been named *membrana limitans interna*, but, as may be inferred from the above description, it is in no way a continuous or independent membrane. The fibres pass through the nerve- and ganglionic layers, with a smooth contour, or with but two or three well-marked lateral projections from which fine lamellar processes extend amongst the elements of these layers: gradually diminishing in size they then traverse the inner molecular layer, without, according to Schwalbe, becoming actually connected with the soft substance which mainly composes it, although in the mammalian retina the fibres are marked by slight projections in passing through this layer. In the inner nuclear layer they again give off excessively delicate flattened processes from their sides, which pass around the inner granules and serve to support them. Moreover, each Müllerian fibre is here characterised by the presence of a clear oval or elliptical nucleus (already mentioned in the description of the inner nuclear layer), containing a distinct nucleolus, and situated at one side of, and in close apposition to the fibre to which it belongs. On reaching the outer nuclear layer (after passing through the outer molecular) the fibres of Müller break

up into fine fibrils and thin transparent lamellæ, and in this form they pass outwards through the layer, between the outer granules and the rod and cone-fibres, more or less enclosing these structures, and sometimes forming almost complete, delicate sheaths for them. At the level of the bases or central ends of the cones and rods, the numerous offsets unite around those structures along a definite line which marks the boundary between the outer nuclear layer and the layer of rods and cones, and has been termed *membrana limitans externa*. This also, like the *m. l. interna*, is in no way a continuous membrane, nor is it isolable from the Müllerian fibres; indeed, numerous fine fibrillar offsets of these pass a short distance beyond the so-called limiting membrane, and closely invest the bases of the inner segments of the rods and cones.

The Müllerian fibres sometimes exhibit a fine striation. They swell up and become indistinct on treatment with acetic acid and dilute alkalis, but much more slowly than connective tissue fibrils; moreover, they are not dissolved by boiling in water. They are much less developed in the central and posterior part of the retina than in the peripheral and anterior; towards the ora serrata they are very distinct and closely set.

**Structure of the Macula lutea and fovea centralis** (fig. 426).—The peculiarities in structure which these present have been for the most part incidentally noticed in the preceding description of the retina layers. Thus in the first place no rods are met with, and the cones are

Fig. 426.

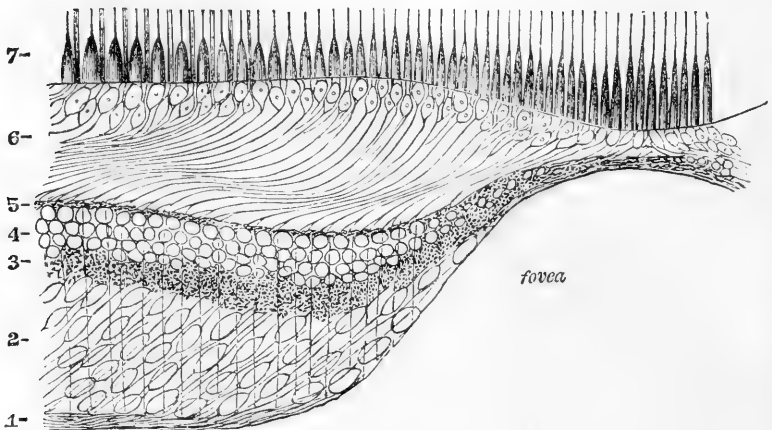


Fig. 426.—VERTICAL SECTION THROUGH THE MACULA LUTEA AND FOVEA CENTRALIS; DIAGRAMMATIC (after Max Schultze).

1, nerve layer; 2, ganglionic layer; 3, inner molecular; 4, inner nuclear; and 5, outer molecular layers; 6, outer nuclear layer, the inner part with only cone-fibres forming the so-called external fibrous layer; 7, cones and rods.

much longer and narrower, especially opposite the fovea centralis, than elsewhere. All the other layers are very much thinned at the fovea, but towards its margin most of them are thicker than at any other

part of the retina. The ganglionic layer (2) is especially thickened, the cells being from six to eight deep, bipolar and situated rather obliquely. The nerve-fibre layer (1) gradually gets thinner towards the edge of the fovea, the fibres dipping in to join the inner ends of the bipolar ganglion-cells. The fibre which passes from the other end of each of the latter is said to bifurcate, each branch becoming connected with a granule of the inner nuclear layer (Merkel). The inner granules are also somewhat obliquely disposed, are large, and near the bottom of the fovea, where the layers of nerve-cells and of inner granules run together, they can hardly be differentiated (Hulke). The outer nuclear layer (6) is occupied in the greater part of its thickness by the very long and obliquely disposed cone-fibres; the corresponding nucleated enlargements are only two or three deep, and take up a comparatively small portion of the layer.

The yellow tint of the macula is deepest towards the centre: it is due to a diffuse colouring matter which is seated in the interstices between the elements of the several layers, except in the layer of cones and the outer nuclear layer. It is soluble in water or alcohol, and absorbs the blue and violet rays of the spectrum.

**Structure of the ora serrata and pars ciliaris.**—At the *ora serrata* the numerous complex layers of the retina for the most part disappear, and in front of the *ora serrata*, the retina is repre-

sented merely by a single stratum of elongated columnar cells with the pigmentary layer external to them (*pars ciliaris*). The transition is, in man, somewhat abrupt, all the changes being met within a zone of about  $\frac{1}{250}$  in. only in breadth. The layer of rods and cones (fig. 427, *g*) first disappears, the cones continuing rather further than the rods, but soon ceasing; the nerve- and ganglionic layers, which were already very thin near the ora, here cease altogether; the inner molecular layer (*c*), which is now largely occupied by Müllerian fibres, retains its thickness up to a certain

point, and then suddenly terminates with a rounded off margin (*a'*), while the nuclear layers, outer and inner, (*f*, *d*), here become merged into a single layer, which is continuous with the columnar cells of the *pars ciliaris*. These (fig. 427, *m*), which are at first of considerable length, become gradually shorter anteriorly; they are finely granular or striated in appearance (fig. 428, 2), each with a clear oval nucleus at the outer part of the cell, near the pigmentary layer. The

Fig. 427.

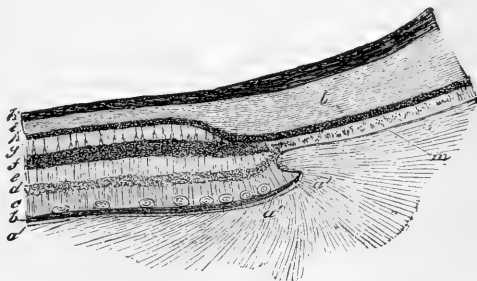


Fig. 427.—VERTICAL SECTION THROUGH THE CHOROID AND RETINA NEAR THE ORA SERRATA (Kölliker). 60 DIAMETERS.

*a*, hyaloid membrane; *b*, limiting membrane and nervous layer of the retina; *c*, ganglionic and inner molecular layers with closely set Müllerian fibres; *d*, inner nuclear; *e*, outer molecular; *f*, outer nuclear layer; *g*, columnar layer; *h*, pigment; *i*, *k*, choroid; *l*, part of one of the ciliary processes; *m*, pars ciliaris of the retina. (The recess shown at *a'* is not constant.)

inner end may be rounded, pointed, square, or even branched; the sides of the cells, too, are sometimes uneven.

These cells are considered by Kölliker to correspond with the Müllerian fibres of the retina, but according to Schwalbe these fibres, or rather their united inner ends, are more probably represented by a delicate membrane, which covers the inner ends of the columnar cells and sends fine offsets around and between them, and which he believes to be continuous with the *membrana limitans interna*.

**Vessels of the Retina.**—A single artery (*arteria centralis retinae*) passes between the bundles of fibres of the optic nerve to the inner surface of the retina at the middle of the papilla optici (fig. 418, *a*).

Fig. 428.

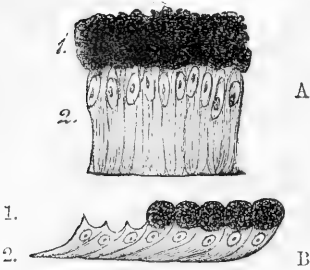


Fig. 428.—A SMALL PORTION OF THE CILIARY PART OF THE RETINA (Kölliker). 250 DIAMETERS.

A, human; B, from the ox; 1, pigment-cells; 2, cells forming the pars ciliaris.

It is accompanied by the corresponding vein and soon divides into branches (fig. 417), usually two, one above, the other below, each of these again dividing into two branches which arch out towards the sides; the outer ones are somewhat the larger, and as they bend round the macula lutea they send numerous fine branches into it which end at the margin of the fovea centralis in capillary loops. The main branches of the vessels pass forwards in the nerve-fibre layer, dividing dichotomously as they proceed, and giving off fine offsets to the substance of the retina, where they form a close capillary network, but this does not extend beyond the inner nuclear layer. So that the outer retinal layers are entirely destitute of blood-vessels, and moreover the vascular system of the retina is nowhere in direct communication with the choroidal vessels. Near the entrance of the optic nerve, however, it comes into communication with some offsets from the sclerotic coat, and the choroidal vessels also send in branches, which join the long-meshed network in the optic nerve furnished by the central artery. The arteries of the retina have the usual coats, but the veins resemble capillaries in structure, their walls consisting of a single layer of epithelioid cells. Outside this layer is a space (perivascular lymphatic, His) both in the veins and capillaries, bounded externally by a second epithelioid layer (forming the wall of the lymphatic). Outside this again is found, in the case of the veins, a layer composed of a peculiar retiform tissue; they appear to have no plain muscular tissue in their wall. These perivascular lymphatics are in communication with the lymphatics of the optic nerve, and may be filled by injecting coloured fluid underneath the sheath which that nerve derives from the pia mater. Other lymph-spaces also become injected by the same process, viz., the interstices between the nerve bundles which radiate from the papilla optici, the capillary space between the limitans interna and the hyaloid membrane of the vitreous humour, and finally even the irregular interstice between the pigmentary layer and the layer of rods and cones (Schwalbe).

## THE VITREOUS BODY.

The vitreous body, the largest of the transparent parts through which the light passes to reach the retina, occupies the centre of the eyeball. It is quite pellucid in aspect, and of a soft gelatinous consistence. Sub-globular in form, it fills about four-fifths of the ball, and serves as a support for the delicate retina, but it may be readily separated from the latter, except behind, at the entrance of the optic nerve, where the connection is closer, the retinal vessels having here entered it in foetal life. At the fore part it is hollowed out for the reception of the lens and its capsule, to which its substance is closely adherent.

The surface of the vitreous humour is covered everywhere except in front by a thin glassy membrane, named *hyaloid*, which lies between it and the retina. No vessels enter the vitreous humour in the adult, and its nutrition must, therefore, be dependent on the surrounding vascular structures, viz., the retina and the ciliary processes.

Although in the fresh state apparently structureless, or at least presenting under the microscope but faint traces of structural elements—the so-called corpuscles of the vitreous humour to which we shall immediately recur,—yet in preparations hardened in weak chromic acid, or acted upon in certain other ways, it is possible to make out a more or less distinct lamellation of the vitreous body, especially its peripheral part, that, namely, nearest the retina, which part in the human eye has a somewhat firmer consistence than the more central portion.

From the appearances (fig. 429) which have been obtained with such modes of preparation it has been conjectured by various observers that at least in this part the vitreous substance is divided into enclosed, flattened compartments by a number of excessively delicate membranes arranged concentrically and therefore parallel to the surface, but the existence of such membranous partitions has not been conclusively demonstrated. That, however, the vitreous substance does in some way consist of a firmer material—whether or not

in the shape of continuous membranes—enclosing in its meshes the more fluid portion, is shown by the fact that if either the whole or a piece of the vitreous humour be thrown upon a filter, a small proportion always remains upon the latter; although by far the larger part drains away, and may be collected as a clear watery fluid.

In addition to the above-mentioned concentric striation, a radial marking has also been observed in sections of the human vitreous

Fig. 429.

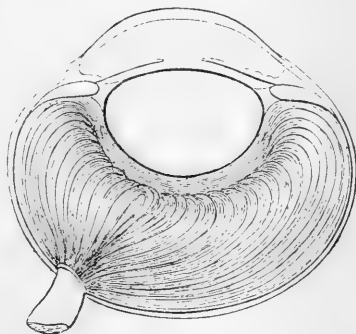


Fig. 429.—HORIZONTAL SECTION OF THE HORSE'S EYE, HARDENED IN CHROMIC ACID (after Hannover).

The vitreous humour appears concentrically and meridionally striated throughout its whole depth.

humour, made transversely to the axis of the eyeball (fig. 430), but whether there is any pre-existent structure to account for the appearance is not known. It is conceivable that these appearances may be merely produced by the manner in which the albuminous substance has undergone coagulation by the reagent employed.

Fig. 430.




Fig. 430.—TRANSVERSE SECTION OF HUMAN EYE, HARDENED IN CHROMIC ACID, SHOWING RADIAL STRIATION OF THE VITREOUS BODY (after Hannover).

However this may be, there exists, nearly but not quite in the axis of the eye, a definite structure in the shape of a distinct canal, about a line in diameter, filled with fluid and extending from the *papilla optici* to the back of the lens capsule where it apparently terminates blindly. This is the *canalis hyaloideus* or *canal of Stilling*. It is best shown in the fresh eye, and may be also injected by forcing a coloured solution under the pia-matral sheath of the optic nerve (Schwalbe). The canal widens somewhat towards its posterior part: its wall is composed of an excessively delicate homogeneous membrane.

Scattered about throughout the substance of the vitreous humour are a variable number of corpuscles, for the most part capable of exhibiting amœboid movement and many of them apparently of the nature of white blood corpuscles. Some of the cells here met with are remarkable for the very large vacuoles which they contain, and which distend the body of the corpuscle, pushing the nucleus to one side; the cell processes are for the most part peculiar in possessing numerous little secondary bud-like swellings, or they may present a varicose appearance, like strings of pearls. Similar bodies are also found floating free in the vitreous humour. Iwanhoff further describes other cells, especially frequent near the periphery, of a stellate and spindle-shaped form and possessing similar processes.

The fluid collected from the vitreous humour consists chiefly of water; it contains, however, some salts with a little albumen, in the form of an albuminate of soda, and, in the human eye, also traces of mucin.

**The hyaloid membrane** invests, as before mentioned, the whole of the vitreous humour, except in front, where the membrane passes forwards to the anterior part of the margin of the lens, becoming also firmer in consistence and distinctly fibrous in structure. This portion of the hyaloid is known as the *zonula of Zinn*, and the *suspensory ligament of the lens* (fig. 431, z, l l). The posterior part, or hyaloid proper, is exceedingly thin and delicate, and is readily thrown into folds when detached. Under the microscope it presents no appearance of structure: but, flattened against its inner surface are generally to be seen a number of granular nucleated corpuscles, which exhibit amœboid movements: they appear to be merely migrated white blood corpuscles. The ciliary part or zonula, on the other hand, presents radiating meridional fibres, stiff in appearance, and apparently intermediate in character between elastic and white fibres of connective tissue; they commence generally about opposite the ora serrata, and confer considerable stoutness upon this portion of the hyaloid membrane, which here, as its name implies, assists in supporting the lens, to the capsule of which it is anteriorly firmly attached. Moreover, this part of the



hyaloid, being opposite to the ciliary processes, differs from the rest in the fact that instead of presenting a smooth and even surface, it exhibits, when separated, small, regular folds—*processus ciliares zonula*—

Fig. 431.

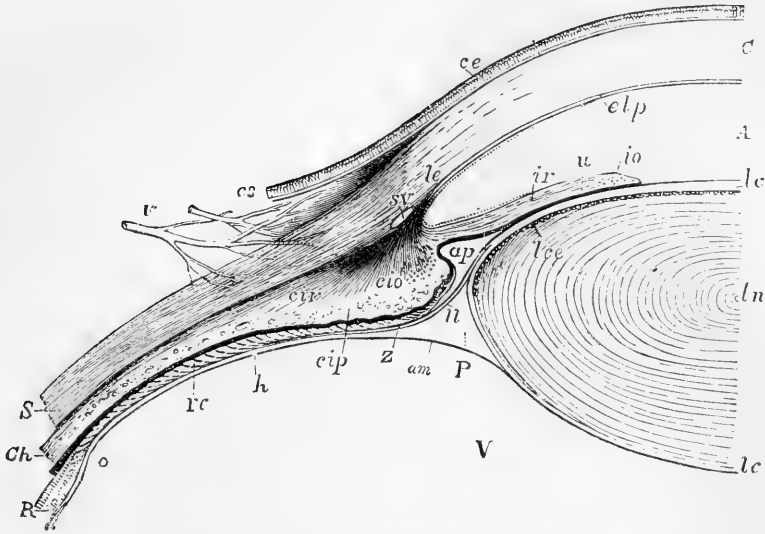


Fig 431.—SECTIONAL VIEW OF THE CONNECTIONS OF THE CORNEA, SCLEROTIC, IRIS, CILIARY MUSCLE, CILIARY PROCESSES, HYALOID MEMBRANE AND LENS.  $\frac{1}{2}$

The specimen extends from the middle of the lens to the ora serrata on the inner side of the right eye. C, cornea; cs, conjunctiva; ce, epithelium of the conjunctiva; elp, posterior elastic layer; le, ligamentum pectinatum iridis; S, sclerotic; A, the aqueous chamber; ap, the recess forming the posterior division of the aqueous chamber; SV, canal of Schlemm; ir, radiating muscle of the iris; io, divided fibres of the sphincter muscle; u, pigment layer or uvea; ln, centre of the crystalline lens; lc, capsule of the lens; lce, layer of cells in front of the lens; cir, radiating ciliary muscle; cio, divided annular fibres; cip, ciliary process; Ch, choroid; R, retina; o, ora serrata; rc, the ciliary part of the retina; h, hyaloid membrane; P, canal of Petit; Z, zonule of Zinn; U, suspensory ligament of the lens proceeding from the hyaloid covering the ciliary process towards the front of the capsule of the lens; am, anterior margin of the vitreous humour, V.

(in the intervals of which a small amount of pigment commonly remains attached): these fit closely into the intervals between the true ciliary processes. Between the last named and the lens the ligament is free from plaits, and forms part of the posterior boundary of the aqueous chamber. Its posterior surface is turned towards the vitreous humour, but is separated from the latter near the lens by a zonular space, triangular in section, named the *canal of Petit* (fig. 431, P). During life, in all probability, the vitreous humour extends into and almost or entirely occupies this space; but after death it may be injected with fluid or distended with air: if this be done after removal of the anterior parts which support and enclose it, the folds of the suspensory ligament on its front are distended, and the canal presents a sacculated appearance, as in fig. 432.

According to another and more generally received account the hyaloid membrane divides in front into two layers; an anterior, continued forwards as the zonule of Zinn, and a posterior, passing behind the lens; the canal of Petit being contained between them.

Fig. 432.

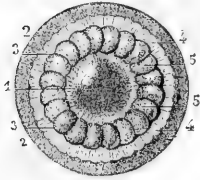


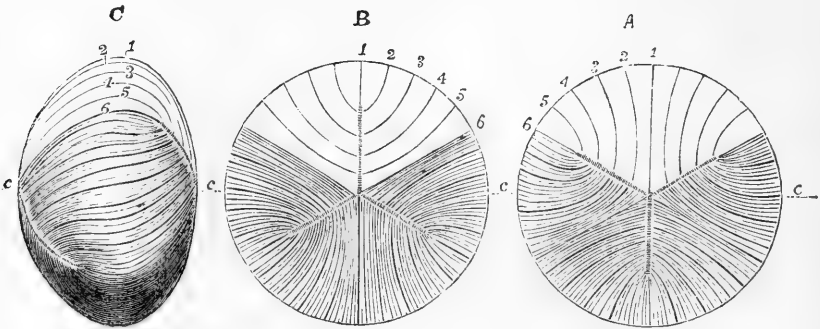
Fig. 432.—VIEW FROM BEFORE OF THE CANAL OF PETIT INFLATED (from Sappey).

The anterior parts of the sclerotic, choroid, iris and cornea having been removed, the remaining parts are viewed from before, and the canal of Petit has been inflated with air through an artificial opening. 1, front of the lens; 2, vitreous body; 3, outer border of the canal of Petit; 4, outer part of the zonule of Zinn; 5, appearance of sacculated dilations of the canal of Petit.

### THE LENS.

The lens (*lens crystallina*) is a transparent solid body, of a doubly convex shape, with the circumference rounded off. It is completely enclosed by a transparent elastic membrane known as the *capsule of the lens*. The anterior surface is in contact with the iris towards the pupil, receding from it slightly at the circumference; the posterior

Fig. 433.

Fig. 433.—OUTLINES ILLUSTRATING THE COURSE OF THE FIBRES IN THE FETAL CRYSTALLINE LENS.  $\frac{2}{3}$ 

This diagram represents the typical or more simple state of the fibres in the full-grown fetal or infantile condition; the three dotted lines radiating at equal angles of  $120^\circ$  from the centre indicate the position of the intersecting planes, where they reach the surface; the figures 1, 2, 3, 4, 5, and 6, indicate certain fibres selected arbitrarily at equal distances in one-sixth part of the lens to show their course from the front to the back; A, the anterior surface; B, the posterior surface; C, the lateral aspect: in these several figures, for the sake of clearness, a few lines only are introduced into the upper third, while in the lower two-thirds a greater number are marked; but no attempt is made to represent the number existing in nature; the parts of the dotted line marked c, are on a level with the centre of the several lenses.

rests closely on the vitreous body. Around the circumference is the canal of Petit. Its convexity is not alike on the two surfaces, being greater behind; moreover, the curvature is less at the centre than towards the margin. It measures about  $\frac{1}{3}$ rd of an inch across, and  $\frac{1}{5}$ th from before backwards. In a fresh lens, divested of its capsule,

the outer portion is soft and easily detached; the succeeding layers are of a firmer consistence; and in the centre the substance becomes much harder, constituting the so-called nucleus. On the anterior and posterior surfaces are faint white lines directed from the poles towards the circumference; these in the adult are somewhat variable and numerous

Fig. 434.

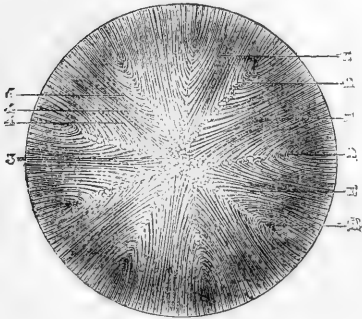


Fig. 434.—FRONT VIEW OF THE FIBROUS STRUCTURE OF THE ADULT LENS (from Sappey after Arnold). †

In this figure more numerous planes of intersection of the fibres are shown than in fig. 433.

Fig. 435.

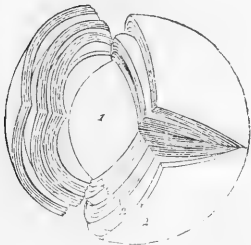


Fig. 435.—LAMINATED STRUCTURE OF THE CRYSTALLINE LENS, SHOWN AFTER HARDENING IN ALCOHOL (Arnold). †

on the surface (fig. 434), but in the fetal lens throughout, and towards the centre of the lens in the adult, they are three in number, diverging from each other like rays at equal angles of  $120^\circ$  (fig. 433, B and C). The lines at opposite poles have an alternating position (not being over one another), thus of those seen on the posterior surface, one is directed vertically upwards (fig. 433, B), and

Fig. 436.

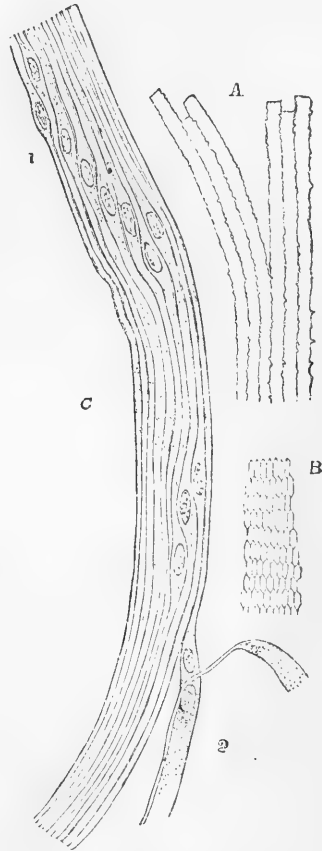


Fig. 436.—FIBRES OF THE CRYSTALLINE LENS. 350 DIAMETERS.

A, longitudinal view of the fibres of the lens from the ox, showing the serrated edges. B, transverse section of the fibres of the lens from the human eye (from Kölliker). C, longitudinal view of a few of the fibres from the equatorial region of the human lens (from Henle). Most of the fibres in C are seen edgewise, and, towards 1, present the swellings and nuclei of the "nuclear zone;" at 2, the flattened sides of two fibres are seen.

the other two downwards and to either side, whereas those on the anterior surface are directed one directly downwards and the other two upwards and to the sides (A). These lines are the edges of planes or septa within the lens diverging from the axis, and receiving the ends of the lens-fibres, which here abut against one another. As Tweedy has pointed out, they may be seen, by the aid of the ophthalmoscope, even during life.

#### STRUCTURE OF THE LENS AND ITS CAPSULE.

When the lens has been hardened and the capsule removed, a succession of concentric laminae may be detached from it like the coats from an onion. They are, however, not continuous all round as a rule, being apt to separate into parts opposite the radiating lines above described (fig. 435). The laminae are composed of long, riband-shaped, microscopic fibres,  $\frac{1}{50000}$  inch broad, which adhere together by their edges, the latter being often finely serrated (fig. 436, A), and pass in a curved direction (fig. 436, C), from the intersecting planes of the anterior half of the lens to those of the posterior half, or *vice versa*: in this course no fibre passes from one pole to the other, but those fibres which begin near the pole or centre of one surface, terminate near the marginal part of a plane on the opposite surface, and conversely; the intervening fibres passing to their corresponding places between. The arrangement will be better understood by a reference to fig. 433, C, where the course of the fibres is diagrammatically indicated.

The lens fibres, as the history of their development shows, are to be looked upon as very much elongated cells. In the young state each has a clear oval nucleus, but in the fully-formed lens the nuclei have disappeared from the fibres which form the more internal parts of the lens, and only remain in the most superficial layers. Here they are found, not quite in the middle of each fibre, but slightly nearer the anterior end, their situation nearly corresponding in adjacent fibres, and they form by their juxtaposition the so-called "nuclear zone" around the lens. The superficial fibres further differ from the more deeply seated ones in being softer, and in possessing a plain, unserrated margin.

Fig. 437.

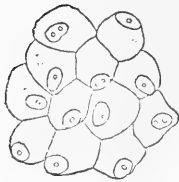

Fig. 437.—CELLS LYING BETWEEN THE LENS AND ITS CAPSULE (from Bowman).  $\frac{250}{1}$

The extremities of all the fibres are softer and more readily acted on by reagents than the middle parts, and the axial or more internal part of a fibre more so than the external, but the transition is gradual from one to the other, and there is no definite membrane enclosing each fibre. The lens-fibres when cut across are seen to be six-sided prisms (fig. 436, B). By reason of this shape, and the serrations of their edges, they fit very exactly the one to the other with but little interfibrillar cementing substance between. This is met with in rather larger quantity in the intersecting planes between the ends of the fibres. In fishes, and some other animals, the edges of the lens-fibres are much more distinctly and regularly toothed than in man.

At the back of the lens the fibres are directly in contact with the inner surface of the capsule, but in front they are separated from the latter by a single layer of flattened, polygonal, nucleated cells (fig. 437),

which covers the whole anterior surface underneath the capsule. Towards the edge or equator of the lens the appearance and character of these cells undergo a change: they first gradually take on a columnar form, and then, becoming more and more elongated, present every transition to the nucleated lens-fibres of the superficial layers, into which they are directly continuous. This transition is more gradual and easily traced in the lens of some animals than in man (see fig. 438).

Fig. 438.




Fig. 438.—SECTION THROUGH THE MARGIN OF THE RABBIT'S LENS, SHOWING THE TRANSITION OF THE EPITHELIUM INTO THE LENS-FIBRES (Babuchin).

The capsule of the lens is a transparent, structureless membrane, somewhat brittle and elastic in character, and when ruptured the edges roll outwards. It is very permeable to fluid, and in chemical reactions appears to be intermediate between elastic and white connective tissue, for it is slowly acted on by acids and dissolves by long boiling in water, but the solution does not gelatinize in the cold. The body of the lens itself contains about 60 per cent. water, and 30 per cent. solid matter; chiefly albuminoids.

The fore part of the capsule, from about  $\frac{1}{16}$  inch from the circumference, where the suspensory ligament joins it, is much thicker than the back: at the posterior pole of the lens the capsule is very thin indeed. In the adult it, like the lens itself, is entirely non-vascular, but in the fœtus there is a network of vessels in the capsule, supplied by the terminal branch of the arteria centralis retinae, which passes from the optic papilla through the canal of Stilling in the vitreous humour to reach the back of the capsule, where it divides into radiating branches. After forming a fine network, these turn round the margin of the lens and extend forwards to become continuous with the vessels in the pupillary membrane and iris.

After death a small quantity of fluid (liquor Morgagni) frequently collects between the back of the lens and the capsule: it appears to be derived from the breaking down of the lens fibres. There is no epithelium in this situation as in front.

**Changes in the lens by age.**—In the *fœtus*, the lens is nearly spherical (fig. 439, *a*): it has a slightly reddish colour, is not perfectly transparent, and is softer, and more readily broken down than at a more advanced age.

In the *adult*, the anterior surface of the lens becomes more obviously less convex than the posterior (fig. 439, *b*); and the substance of the lens is firmer, colourless, and transparent.

In *old age*, it is more flattened on both surfaces (*c*); it assumes a yellowish or amber tinge, and is apt to lose its transparency as it gradually increases in toughness and specific gravity.

Fig. 439.



Fig. 439.—SIDE VIEW OF THE LENS AT DIFFERENT AGES.

*a*, at birth with the deepest convexity; *b*, in adult life with medium convexity; *c*, in old age with considerable flattening of the curvatures.

### AQUEOUS HUMOUR AND ITS CHAMBER.

The aqueous humour fills the space in the fore part of the eyeball, between the capsule of the lens with its suspensory ligament and the cornea. It differs little from water in its physical characters; but it contains a small quantity of some solid matter, chiefly chloride of sodium, dissolved in it. The iris, resting in part upon the lens, divides the aqueous chamber partially into two, named respectively the anterior and posterior chambers. This subdivision is incomplete in the adult, but in the fœtus before the seventh month it is completed by the *membrana pupillaris*, which, by its union with the margin of the pupil, closes the aperture of communication between the two chambers.

The *anterior chamber* is limited in front by the cornea and behind by the iris, while opposite the pupil it is bounded by the front of the lens and capsule.

The *posterior chamber* was originally so named in the belief that a distinct free space intervened between the iris and the capsule of the lens. It is now, however, well ascertained by observations on the living eye, and by sections made in the frozen state, that the iris comes into contact with the capsule of the lens, both at the pupillary margin and at the adjoining part of the posterior surface; and the term posterior chamber can therefore—unless it be employed to indicate the want of continuity between those opposed structures, where no space actually intervenes—only be applied to the angular interval existing at the circumference between the ciliary processes, the iris, and the suspensory ligament.\*

### THE EAR.

THE organ of hearing is divisible into three parts: the external ear (fig. 440, 1, 2), the tympanum or middle ear (3), and the labyrinth or internal ear (6). The first two of these are to be considered as accessories to the third, which is the sentient portion of the organ.

#### THE EXTERNAL EAR.

In the external ear are included the *pinna*—the part of the outer ear which projects from the side of the head—together with the *meatus* or passage which leads thence to the tympanum, and which is closed at its inner extremity by a membrane (*membrana tympani*) interposed between it and the middle ear.

#### THE PINNA.

**Superficial configuration.**—The general form of the pinna or auricle, as seen from the outside, is concave, to fit it for collecting and concentrating the undulations of sound, but it is thrown into various elevations and hollows, to which distinct names have been given. The largest and deepest concavity, a little below the centre of the organ, is called the *concha* (fig. 441, 7); it surrounds the entrance to the external auditory meatus, and is unequally divided at its upper and anterior part by a ridge, which is the beginning of the helix. In front of the

\* For the most recent and complete account of the anatomy of all the parts composing and connected with the organ of vision the reader is referred to the elaborate articles by Merkel, Waldeyer, Schwalbe, Iwanoff, and Arnold, in Graefe and Saemisch's *Handbuch der gesammten Augenheilkunde*; which, we may add, has been freely consulted in compiling the present description.

Fig. 440.

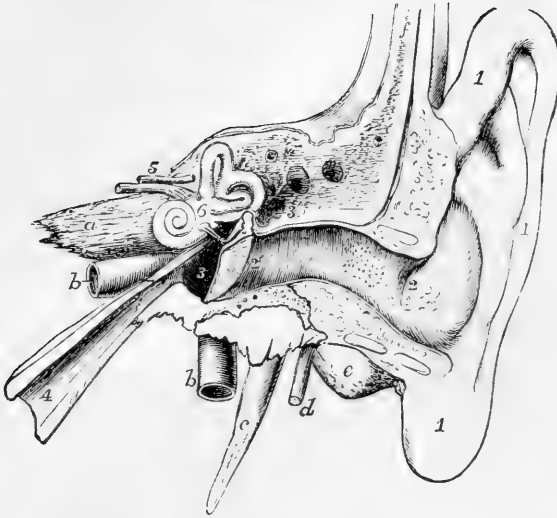


Fig. 440.—DIAGRAMMATIC VIEW FROM BEFORE OF THE PARTS COMPOSING THE ORGAN OF HEARING OF THE LEFT SIDE (after Arnold).

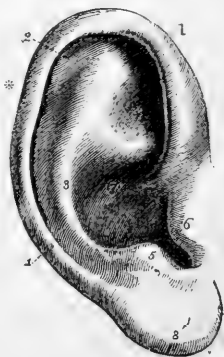
The temporal bone of the left side, with the accompanying soft parts, has been detached from the head, and a section has been carried through it transversely so as to remove the front of the meatus externus, half the tympanic membrane, and the upper and anterior wall of the tympanum and Eustachian tube. The meatus internus has also been opened, and the bony labyrinth exposed by the removal of the surrounding parts of the petrous bone. 1, the pinna and lobe; 2 to 2', meatus externus; 2', membrana tympani; 3, cavity of the tympanum; 3', its opening backwards into the mastoid cells; between 3 and 3', the chain of small bones; 4, Eustachian tube; 5, meatus internus containing the facial (uppermost) and the auditory nerves; 6, placed on the vestibule of the labyrinth above the fenestra ovalis; a, apex of the petrous bone; b, internal carotid artery; c, styloid process; d, facial nerve issuing from the stylo-mastoid foramen; e, mastoid process; f, squamous part of the bone covered by integument.

Fig. 441.—OUTER SURFACE OF THE PINNA OF THE RIGHT AURICLE.  $\frac{3}{4}$

1, helix; 2, fossa of the helix; 3, antihelix; 4, fossa of the antihelix; 5, antitragus; 6, tragus; 7, concha; 8, lobule.

concha, and projecting backwards over the meatus auditorius, is a conical prominence, the *tragus* (fig. 441, 6), covered usually with hairs. Behind this, and separated from it by a deep notch (*incisura intertragica*), is another smaller elevation, the *antitragus* (5). Beneath the antitragus, and forming the lower end of the auricle, is the *lobule* (8), which is devoid of the firmness and elasticity that characterise the rest of the pinna. The thinner and larger portion of the pinna is bounded by a prominent and incurved margin, the *helix* (1), which, springing above and rather within the tragus, from the hollow of the

Fig. 441.



concha, surrounds the upper and posterior margin of the auricle, and gradually loses itself in the back part of the lobule.\* Within the helix is another curved ridge, the *antihelix* (3), which, beginning below at the antitragus, sweeps round the hollow of the concha, forming the posterior boundary of that concavity, and is divided superiorly into two diverging ridges. Between the helix and the antihelix is a narrow curved groove, the *fossa of the helix* (*fossa innominata, scaphoidea*) (2); and in the fork of the antihelix is a somewhat triangular depression, the *fossa of the antihelix* (*fossa triangularis vel ovalis*) (4).

**Structure.**—The pinna consists mainly of yellow fibro-cartilage and integument, with a certain amount of adipose tissue. It has several ligaments and small muscles of minor importance.

The *skin* covering it is thin, closely adherent to the cartilage, and contains sebaceous follicles, which are most abundant in the hollows of the concha and scaphoid fossa.

The *cartilage* (figs. 442, 443) forms a thin plate, presenting all the inequalities already described as apparent on the outer surface of the pinna, and on its cranial surface having prominences the reverse of the concha and the fossa of the helix, while between these is a depression in the situation of the antihelix. The cartilage is not confined to the pinna, but enters likewise into the construction of the outer part of the external auditory canal. When dissected from other structures, it is seen to be attached by fibrous tissue to the rough and prominent margin of the external auditory meatus of the temporal bone. The tubular part is cleft in front from between the tragus and fore part of the helix inwards to the bone, the deficiency being filled with fibrous membrane; the whole cartilage may be looked upon as an elongated plate, the lower part of which is folded round in front so as to bring it nearly into contact with the upper part. There is no cartilage in the lobule: it contains only fat and tough connective tissue. Behind the prominence of cartilage which forms the antitragus is a deep notch, separating it from the cartilage of the helix, which here forms a tail-like process descending towards the lobule (fig. 443). At the fore part of the pinna, opposite the first bend of the helix, is a small conical projection of the cartilage, called the *process of the helix*, to which the anterior ligament is attached. Behind this process is a short vertical slit in the helix; and on the surface of the tragus is a similar but somewhat longer fissure. A deep fissure passes back between the commencement of the helix and the tube of the ear, and another passing outwards and backwards from the deep end of the longitudinal cleft separates the part forming the tragus from the rest of the tube, so that the tube is continuous with the pinna only by means of a narrow isthmus. One or two other irregular gaps or fissures partially divide the cartilaginous tube transversely, and the whole of these deficiencies are termed *fissures of Santorini*. The substance of the cartilage is very pliable, and is covered by a firm fibrous perichondrium.

Of the *ligaments of the pinna*, the most important are two, which

\* A slight pointed projection which is occasionally observed in the human subject at the margin of the helix (at a place indicated by the asterisk in fig. 441) is of interest as representing the much more distinct pointed extremity met with in the expanded ears of quadrupeds (Darwin, "The Descent of Man," 2nd edition, p. 15). The point in question happens to be distinctly seen in the cartilage represented in fig. 442.



assist in attaching it to the side of the head. The *anterior* ligament, broad and strong, extends from the process of the helix to the root of the zygoma. The *posterior* ligament fixes the back of the auricle (opposite the concha) to the outer surface of the mastoid process of the temporal bone. A few fibres attach the tragus also to the root of the zygoma. Ligamentous fibres are likewise placed across the fissures and intervals left in the cartilage.

Of the *muscles of the pinna*, those which are attached by one end to the side of the head, and move the pinna as a whole, have been already described (vol. i.): there remain to be examined several smaller muscles, composed of thin layers of pale-looking fibres, which extend from one part of the pinna to another, and may be named the special muscles of the organ. Six such small muscles are distinguished; four being placed on the outer and two on the inner or deep surface of the pinna.

The *smaller muscle of the helix* (fig. 442, 1) is a small bundle of oblique fibres, lying over, and firmly attached to, that portion of the helix which springs from the bottom of the concha.

The *greater muscle of the helix* (fig. 442, 2) lies vertically along the anterior margin of the pinna. By its lower end it is attached to the process of the helix; and above, its fibres terminate opposite the point at which the ridge of the helix turns backwards.

The *muscle of the tragus* (fig. 442, 3) is a flat bundle of short fibres covering the outer surface of the tragus: its direction is nearly vertical.

The *muscle of the antitragus* (fig. 442, 4) is placed obliquely over the antitragus and behind the lower part of the antihelix. It is fixed at

Fig. 442.—CARTILAGE OF THE PINNA EXPOSED, WITH THE MUSCLES ON ITS OUTER SURFACE.

1, musculus heliæ minor; 2, m. heliæ major; 3, tragus; 4, antitragus.

Fig. 442.

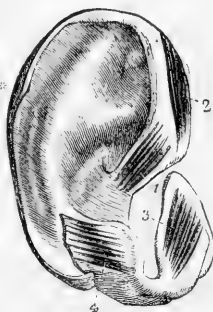


Fig. 443.

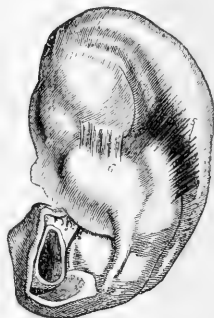


Fig. 443.—INNER SURFACE OF THE CARTILAGE OF THE PINNA WITH THE SMALL MUSCLES ATTACHED.

5, transversus auriculæ muscle; 6, obliquus auriculæ muscle.

one end to the antitragus, from which point its fibres ascend to be inserted into the tail-like extremity of the helix, above and behind the lobule.

The *transverse muscle* (fig. 443, 5) lies on the inner or cranial surface of the pinna, and consists of radiating fibres which extend from the back of the concha to the prominence which corresponds with the groove of the helix.

The *oblique muscle* (Tod) (fig. 443, 6) consists of a few fibres stretching from the back of the concha to the convexity directly above it, across the back of the inferior branch of the antihelix, and near the fibres of the transverse muscle.

**Vessels and nerves of the pinna.**—The *posterior auricular artery*, a branch from the external carotid, is distributed chiefly on the posterior or inner surface, but sends small branches round and through the cartilage to ramify on the outer surface of the pinna. Besides this artery, the auricle receives others—the *anterior auricular* from the temporal in front, and a small artery from the occipital behind.

The *veins* correspond much in their course with the arteries. They join the temporal vein, and their blood is returned therefore through the external jugular.

The *great auricular nerve*, from the cervical plexus, supplies the greater part of the back of the auricle, and sends small filaments with the posterior auricular artery to the outer surface of the lobule and the part of the ear above it. The *posterior auricular nerve* derived from the facial, after communicating with the *auricular branch of the pneumogastric*, ramifies on the back of the ear and supplies the retractor muscle. The upper muscles of the auricle receive their supply from the *temporal branches* of the same nerve. The *auriculo-temporal* branch of the third division of the fifth nerve gives filaments chiefly to the outer and anterior surface of the pinna.

#### THE EXTERNAL AUDITORY CANAL.

The external auditory canal, *meatus auditorius externus* (fig. 440), extends from the bottom of the concha (2) to the membrane of the tympanum (2'), and serves to convey the vibrations of sound to the middle chamber of the ear. The canal is about one inch and a quarter in length. In its inward course it is inclined somewhat forwards (fig. 444); and it presents likewise a distinct vertical curve (fig. 440),

Fig. 444

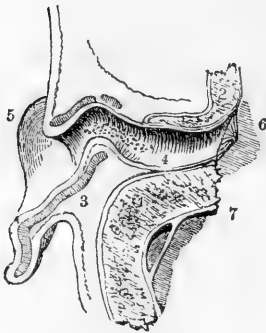


Fig. 444.—VIEW OF THE LOWER HALF OF THE AURICLE AND MEATUS IN THE LEFT EAR DIVIDED BY A HORIZONTAL SECTION (after Sömmerring)

1 and 2, cut surfaces of the bony part of the meatus; 3, cut surface of the cartilage of the pinna; 4, external meatus with the openings of numerous ceruminous glands indicated; 5, lobule; 6, membrane of the tympanum; 7, dura mater lining of the skull.

being directed at first somewhat upwards, and afterwards turning over a convexity of the osseous part of its floor, and dipping downwards to its termination,—a change of direction which must be borne in mind by the surgeon in introducing specula into the ear. The calibre of the passage is smallest about the middle. The outer opening is largest from above downwards, but the inner end of the tube is slightly widest in the transverse direction. At the inner extremity the tube is terminated by the *membrana tympani*, which is placed obliquely, with the inferior margin inclined towards the mesial plane; and thus, as shown in fig. 440, the floor of the meatus is longer than its roof.

The meatus is composed of a tube partly cartilaginous and partly osseous, and is lined by a prolongation of the skin of the pinna.

The *cartilaginous* part occupies somewhat less than half the length of the passage. It is formed by the deep part of the cartilage of the pinna, already described.

The *osseous portion* is a little longer and rather narrower than the cartilaginous part. At its inner end it

presents a narrow groove, which extends round the sides and floor of the meatus, but is deficient above; into this the margin of the membrana tympani is inserted.

The skin of the meatus is continuous with that covering the pinna, but is very thin, especially in the osseous part, and becomes gradually thinner towards the bottom of the passage. In the osseous part it adheres very closely to the periosteum, and at the bottom of the tube is stretched over the surface of the membrana tympani, forming the outer layer of that structure. After maceration in water, or when decomposition has advanced, the epidermic lining of the passage may be separated and drawn out entire, and then it appears as a small tube closed at one end somewhat like the finger of a glove. Towards the outer part the skin possesses fine hairs and sebaceous glands; and in the thick subdermic tissue over the cartilage are many small oval glands of a brownish yellow colour, agreeing in form and structure with the sweat glands, but larger. The cerumen or ear-wax is secreted by these glands, *glandulæ ceruminosæ*, and their numerous openings may be seen to perforate the skin of the meatus. These accessory parts are absent over the bony part of the tube.

**Vessels and nerves.**—The external auditory meatus is supplied with arteries from the posterior auricular, internal maxillary and temporal arteries; and with nerves chiefly from the temporo-auricular branch of the fifth nerve. The principal branches of the arteries course along the upper and back wall of the canal. The nerves break up into numerous branches on reaching the osseous part.

**State in the infant.**—The auditory passage is in a very rudimentary state in the infant, for the osseous part begins to grow out of the temporal bone only at the period of birth, and thus the internal and middle parts of the ear are brought much closer to the surface than in the adult.

### THE MIDDLE EAR OR TYMPANUM.

The tympanum or drum, the middle chamber of the ear, is a narrow irregular cavity in the substance of the temporal bone, placed between the inner end of the external auditory canal and the labyrinth. It receives the atmospheric air from the pharynx through the Eustachian tube, and contains a chain of small bones, by means of which the vibrations communicated from without to the membrana tympani are in part conveyed across the cavity to the sentient part of the internal ear, and by which also pressure is maintained on the contents of the internal ear, varying in amount according to the tension of the membrana tympani. The tympanum contains certain minute muscles and ligaments, which belong to the bones referred to, as well as nerves, some of which end within the cavity, whilst others merely pass through it to other parts. A roof and floor, an outer and inner wall, and an anterior and posterior boundary are commonly described.

The *roof* of the tympanum is formed by a thin plate of bone, which may be easily broken through so as to obtain a view of the tympanic cavity from above; it is situated on the upper surface of the petrous portion of the temporal bone, near the angle of union with the squamous portion, from which in its development it is derived. The *floor* is narrow, in consequence of the outer and inner boundaries being inclined towards each other.

The *outer wall* is formed, to a small extent, by bone, but mainly by

a thin semitransparent membrane—*membrana tympani* (fig. 445, 1), which closes the inner end of the external auditory meatus. Immediately in front of the ring of bone into which the *membrana tympani* is inserted, is the inner extremity of the fissure of Glaser, which gives passage to the *laxator tympani* muscle, and attachment to the *processus gracilis* of the malleus. Close to the back of this fissure is the opening of a small canal (named by Cruveilhier the canal of Huguier), through which the *chorda tympani* nerve usually escapes from the cavity of the tympanum and the skull.

Fig. 445.

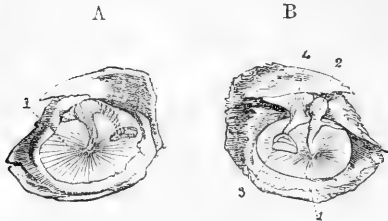


Fig. 445. — RIGHT MEMBRANA TYMPANI AS SEEN FROM THE OUTER AND INNER SIDE RESPECTIVELY.

A, the outer surface; B, the inner; in the latter the small bones are seen adherent to the membrane and adjacent parts of the temporal bone; in A, the shaded part indicates the small bones as partially seen through the membrane; 1, *membrana tympani*; 2, malleus; 3, stapes; 4, incus.

The *membrana tympani* is an ellipsoidal disc, the longer axis of which is directed from behind and above, forwards and downwards, and is about  $4\frac{1}{2}$  lines in length: the shorter being about 4 lines. It is inserted into the groove already noticed at the end of the meatus externus, and so obliquely that the membrane inclines towards the anterior and lower part of the canal at an angle of about  $55^\circ$ . The handle of the malleus (fig. 445, 2), one of the small bones of the tympanum, descends between the middle and inner layers of the *membrana tympani* to a little below the centre, where it is firmly fixed; and, as the direction of this process of the bone is somewhat inwards, the outer surface of the membrane is thereby rendered somewhat conical (see fig. 440), being depressed towards the centre.

Although very thin, the *membrana tympani* is composed of three distinct structures. A prolongation of the skin of the external meatus forms the outer layer; the mucous membrane lining the cavity of the tympanum furnishes an inner layer; and between these two is the proper substance of the membrane, mainly composed of fibrous tissue. The greater number of the fibres radiate from near the centre at the attachment of the handle of the malleus (fig. 445), but there are also circular fibres which are situated within or more interiorly than the radial, and close to the circumference, and form a dense, almost ligamentous ring. Owing to the presence of the circular fibres, the radial fibres are not straight, but are slightly bowed outwards, so that between the most depressed part and the attached border the membrane is slightly convex outwardly.

This is particularly well marked at the upper and anterior part, where the fibres stretch across the mouth of a small notch in the bony ring to which the membrane is attached (notch of Rivinus). The notch is occupied by a lax part of the membrane (*membrana flaccida*, Shrapnell), consisting of loose connective tissue, with vessels and nerves covered

by skin and mucous membrane. It is here that apertures are liable to become formed in the membrane as a consequence of inflammation.

The membrane is supplied with blood-vessels, but they are chiefly confined to the skin and mucous membrane covering the surfaces; a few are, however, found in the proper fibrous membrane, and form a communication between the two systems above named. Those of the skin are mostly supplied by a small artery which passes from above parallel to and along the handle of the malleus. The nerves for the most part accompany the blood-vessels, supplying them and then passing to form a subepithelial plexus both in the cutis and in the mucosa. Lymphatic vessels are, according to Kessel, tolerably abundant in all three layers.

The *inner wall* of the tympanum, which separates it from the internal ear, is very uneven, presenting several elevations and foramina. Near its upper part is an ovoid, or nearly kidney-shaped opening—*fenestra ovalis* (fig. 446, 2), which leads into the cavity of the vestibule. This opening, the long diameter of which is from before backwards, with a slight inclination downwards in front, is occupied in the recent state by the base of the stapes, and the annular ligament connected with that plate of bone. Above the fenestra ovalis, and between it and the roof of the tympanum, a ridge indicates the position of the aqueduct of Fallopius, as it passes backwards, containing the portio dura of the seventh nerve. Below is a larger and more rounded elevation, caused by the projection outwards of the first turn of the cochlea, and named the *promontory*, or *tuber cochleæ* (fig. 446, 4); it is marked by grooves, in which lie the nerves of the tympanic plexus.

Fig. 446.

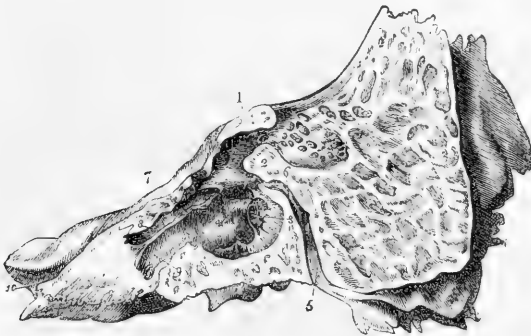

Fig. 446.—INNER WALL OF THE OSSEOUS TYMPANUM AS EXPOSED BY A LONGITUDINAL SECTION OF THE PETROUS AND MASTOID BONE (from Gordon).

1, opening of the tympanum into the mastoid cells; 2, fenestra ovalis; 3, fenestra rotunda; 4, promontory; 5, aqueduct of Fallopius, or canal of the facial nerve; 6, junction of the canal for the chorda tympani with the aqueduct; 7, processus cochleariformis; 8, groove above it for the tensor tympani muscle; 9, Eustachian tube; 10, anterior orifice of the carotid canal.

Below and behind the promontory, and somewhat hidden by it, is a slightly oval aperture named *fenestra rotunda*, which lies within a funnel-shaped depression (fig. 446, 3). In the macerated and dried bone the fenestra rotunda opens into the scala tympani of the cochlea; but, in the recent state, it is closed by a thin membrane.

The membrane closing the fenestra rotunda—the *secondary membrane of the tympanum* (Scarpa)—is rather concave towards the tympanic cavity, and is composed of three strata like the *membrana tympani*; the middle layer being fibrous, and the outer and inner derived from the membranes lining the cavities between which it is interposed, viz., the tympanum and the cochlea.

The *posterior wall* of the tympanum presents at its upper part one larger (fig. 446, 1), and several smaller openings, which lead into irregular cavities, the *mastoid cells*, in the substance of the mastoid process of the temporal bone. These cells communicate, for the most part, freely with one another, and are lined by a thin mucous membrane continuous with that of the tympanum. Behind the fenestra ovalis, and directed upwards, is a small conical eminence, called the *pyramid*, or *eminentia papillaris* (fig. 447, 12). Its apex is pierced by a foramen, through which the tendon of the stapedius muscle emerges from a canal which turns downwards in the posterior wall of the tympanum, and joins obliquely the descending part of the aqueduct of Fallopius.

The *anterior extremity* of the tympanum is narrowed by the gradual descent of the roof, and is continued into the Eustachian orifice (fig. 447). Of the two compartments of this orifice, the lower, lined with mucous membrane, forms the commencement of the Eustachian tube; the upper, about half an inch long, lodges the tensor tympani muscle, and opens into the tympanum immediately in front of the fenestra ovalis, surrounded by the expanded and everted end of the cochleariform process (fig. 446, 7), which separates it from the lower compartment.

Fig. 447.

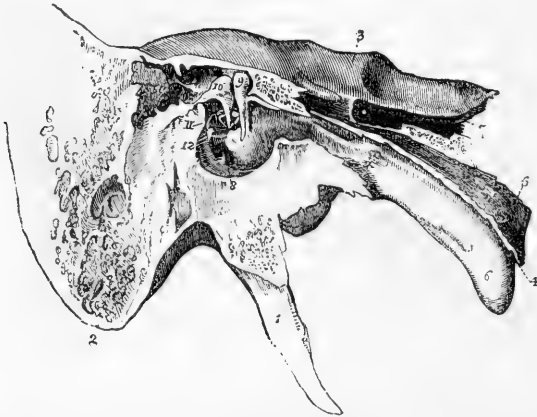


Fig. 447.—ANTERO-POSTERIOR SECTION OF THE TEMPORAL BONE, SHOWING THE INNER WALL OF THE TYMPANUM, WITH THE EUSTACHIAN TUBE AND SMALL BONES IN THE RECENT STATE (from Arnold).

1, styloid process; 2, mastoid process; 3, the upper part of the petrous bone; 4, pharyngeal end of the Eustachian tube; 5, its cartilage; 6, its mucous surface; 7, carotid canal; 8, fenestra rotunda; 9, malleus; 10, incus; 11, stapes; 12, pyramid and stapedius muscle; above 9, and behind 10, the suspensory ligament of the malleus and the posterior ligament of the incus are also seen.

The **Eustachian tube** is a canal, formed partly of bone, partly of cartilage and membrane, which leads from the cavity of the tympanum to

the upper part of the pharynx. From the tympanum it is directed forwards and inwards, with a slight inclination downwards; its entire length is about an inch and a half. The *osseous* division of the Eustachian tube, already described in the Osteology, is placed at the angle of junction of the petrous portion of the temporal bone with the squamous portion. The *anterior* part of the tube is formed of a triangular piece of cartilage, the edges of which are slightly curled round towards each other, leaving an interval at the under side, in which the canal is completed by dense but pliable fibrous membrane. The tube is trumpet-shaped, being narrow behind, and gradually expanding until it becomes wide in front; the anterior part is compressed from side to side, and is fixed to the inner pterygoid process of the sphenoid bone. The anterior opening is oval in form, and is placed obliquely at the side and upper part of the pharynx, into which its prominent margin projects behind the lower meatus of the nose, and above the level of the hard palate. Through this aperture the mucous membrane of the pharynx is continuous with that which lines the tympanum, and under certain conditions air passes into and out of that cavity.

## SMALL BONES OF THE EAR.

Three small bones (*ossicula auditūs*) are contained in the upper part of the tympanum: of these, the outermost (*malleus*) is attached to the membrana tympani; the innermost (*stapes*) is fixed in the fenestra ovalis; and the third (*incus*) placed between the other two, is connected to both by articular surfaces. The malleus and incus are in direction nearly vertical, the stapes horizontal. They form together an angular and jointed connecting rod between the membrana tympani and the membrane which closes the fenestra ovalis.

The **malleus** or hammer bone (fig. 448, A), consists of a central thicker portion, with processes of different lengths. At the upper end of the bone is a rounded *head* (*capitulum*) (fig. 448, A, 1), which presents internally and posteriorly an irregularly oval surface covered with cartilage, for articulation with the incus. Below the head is a constricted *neck* (*cervix*); and beneath this another slight enlargement of the bone, to which the processes are attached. The *handle* (*manubrium*) of the malleus (fig. 448, A, 2) is a tapering and slightly twisted

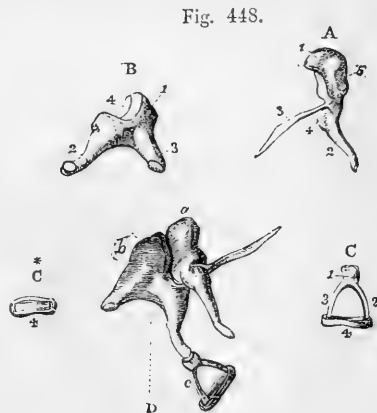


Fig. 448.—BONES OF THE TYMPANUM OF THE RIGHT SIDE (from Arnold). TWICE THE NATURAL SIZE.

A, malleus; 1, its head; 2, the handle; 3, long or slender process; 4, short process. B, incus; 1, its body; 2, the long process with the orbicular process; 3, short or posterior process; 4, articular surface receiving the head of the malleus. C, stapes; 1, head; 2, posterior crus; 3, anterior crus; 4, base. C\*, base of the stapes. D, the three bones in their natural connection as seen from the outside; a, malleus; b, incus; c, stapes.

process, compressed from before back-

wards to near its point, where it is flattened laterally : it descends, with a slight inclination forwards and inwards, between the middle and inner layers of the membrana tympani, to the former of which it is closely attached both by means of its periosteal covering and also by a dense fibro-cartilaginous tissue extending its whole length, except near the root of the process, where it is less firmly united to the membrane. The *long process* (processus gracilis) (fig. 448, A, 3) is a very slender spiculum of bone, which in the adult is usually converted, except a small stump, into ligamentous tissue. Even where it still exists it is commonly broken off in its removal from the tympanum, in consequence of its union with the temporal bone ; it projects at nearly a right angle from the front of the neck of the malleus, and extends thence obliquely downwards and forwards to the Glaserian fissure. Its end is flattened and expanded, and is connected by ligamentous fibres and by bone to the sides of the fissure. The *short process* (processus brevis vel obtusus) (fig. 448, A, 4) is a low conical eminence situate at the root of the manubrium, beneath the cervix, and projecting outwards towards the upper part of the membrana tympani.

The **incus** (fig. 448, B), has been compared to an anvil in form ; but it resembles perhaps more nearly a tooth with two fangs widely separated. It consists of a body and two processes. The *body* presents in front a concavo-convex articular surface (4), which is directed upwards and forwards, and receives the head of the malleus. The surfaces of the joint thus formed are covered with articular cartilage and enclosed by a synovial membrane. The *shorter* of the two processes (crus breve) (3), of the incus projects nearly horizontally backwards from the upper part of the body of the bone, and is connected by ligamentous fibres with the posterior wall of the tympanum near the entrance of the mastoid cells. The *long process* (crus longum) (2) tapers rather more gradually, and descends nearly vertically behind the handle of the malleus : at its extremity it is bent inwards, and is suddenly narrowed into a short neck ; and upon this is set a flattened rounded tubercle (processus lenticularis), tipped with cartilage. This tubercle, which articulates with the head of the stapes, was formerly, under the name of *os orbiculare* seu *lenticulare*, described as a separate bone, which indeed it originally is in childhood.

The **stapes** (fig. 448, C), the third and innermost bone of the ear, is in shape remarkably like a stirrup, and is composed of a head, a base, and two crura. The *head* is directed outwards, and has on its end a slight depression, covered with cartilage, which articulates with the lenticular process of the incus. The *base* is a plate of bone placed in the fenestra ovalis. Its form is irregularly oval, the upper margin being curved, while the lower is nearly straight (fig. 448, c\*). Its border is encircled by hyaline cartilage, which also covers its vestibular surface. The margin of the fenestra ovalis has also a covering of the same tissue, and the opposed cartilaginous surfaces are closely connected, and their movement of the stapes is limited by a network of elastic fibres passing between, and, near the tympanic and vestibular cavities, forming especially a dense ligamentous band (Rüdinger). The crura of the stapes diverge from a constricted part (*neck*) of the bone, situated close to the head, and are attached to the outer surface of the base near its extremities. The anterior crus is the shorter and straighter of the two. The crura, with the base of the



stapes, enclose a small triangular or arched space, which in the recent state is occupied by a thin membrane stretched across. A shallow groove runs round the opposed surfaces of the bone, and into this the membrane is received.

#### LIGAMENTS AND MUSCLES OF THE TYMPANUM.

**Ligaments.**—In the articulations of the small bones of the ear with one another the connection is strengthened by ligamentous fibres.\*

Their attachment to the walls of the tympanum is effected partly by the reflections of the mucous membrane lining that cavity, but chiefly by muscles and by the following ligaments.

The *anterior ligament of the malleus* is a comparatively strong and broad band of, for the most part, short fibres, which connects the anterior wall of the tympanum close to the Glaserian fissure with the base of the processus gracilis and the anterior part of the body of the malleus.

The *suspensory ligament of the malleus* consists of a small bundle of fibres, which passes downwards and outwards from the roof of the tympanum to the head of the malleus, and serves to check its movement in an outward direction.

The *posterior ligament of the incus* extends from near the point of the short crus directly backwards towards the posterior wall of the tympanum, where it is attached near to the entrance to the mastoid cells.

Arnold describes an upper ligament which attaches the incus, near its articulation with the malleus, to the roof of the tympanum.

**Muscles.**—There are three well-determined muscles of the tympanum. Sömmerring describes four, and some authors a larger number; but the descriptions of these last muscles are not confirmed by later research. Of the three muscles generally recognised, two are attached to the malleus, and one to the stapes.

\* These articulations are commonly described as synovial joints, but, according to Brunner (Knapp and Moos' Archiv, 1874), they are more of the nature of symphyses, with fibrocartilage between the contiguous surfaces.

Fig. 449.

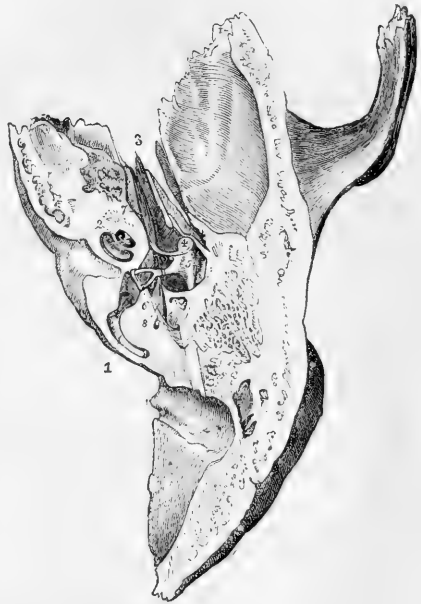

Fig. 449.—VIEW OF THE CAVITY OF THE RIGHT TYMPANUM FROM ABOVE.

The cavity of the tympanum and a part of the labyrinth have been exposed by a horizontal section removing the upper part of the temporal bone. 1, posterior semicircular canal opened; 2, the cavity of the cochlea opened; 3, osseous part of the Eustachian tube; 4, head of the malleus; 5, incus; 6, stapes, with its base set in the fenestra ovalis; 7, tensor tympani muscle; 8, stapedius.

The *tensor tympani* (*musculus internus mallei*) (fig. 449, 7), is the largest of these muscles. It consists of a tapering fleshy part, about half an inch in length, and a slender tendon. The muscular fibres arise from the cartilaginous end of the Eustachian tube and the adjoining surface of the sphenoid bone, and from the sides of the upper compartment of the Eustachian orifice. In this canal the muscle is conducted nearly horizontally backwards to the cavity of the tympanum. Immediately in front of the fenestra ovalis the tendon of the muscle bends at nearly a right angle over the end of the *processus cochleariformis* as round a pulley, and, contained in a fibrous sheath, passes outwards, to be inserted into the inner part of the handle of the malleus, close to its root.

The *laxator tympani* (*laxator tympani major*, Sömmerring) is generally believed to be distinctly muscular, but being partly concealed by a band of fibrous tissue, doubts are still entertained by some observers as to whether the structure known under this name is of a muscular or ligamentous nature. Arising from the spinous process of the sphenoid bone, and slightly from the cartilaginous part of the Eustachian tube, it is directed backwards, passes through the Glaserian fissure, and is inserted into the neck of the malleus, just above the root of the *processus gracilis*.

The *laxator tympani minor* of Sömmerring (*posterior ligament of the malleus*, Lincke) is made up of reddish fibres, which are fixed at one end to the upper and back part of the external auditory meatus, pass forwards and inwards between the middle and inner layers of the *membrana tympani*, and are inserted into the outer border of the handle of the malleus, and the short process near it (Sömmerring, *Icones Organi Auditûs Humani*, 1801).

The *stapedius* is a very distinct muscle, but is hid within the bone, being lodged in the descending part of the aqueductus Fallopii and in the hollow of the pyramid. The tendon issues from the aperture at the apex of that little elevation, and passing forwards, surrounded by a fibrous sheath, is inserted into the neck of the stapes posteriorly, close to the articulation of that bone with the lenticular process of the incus.

A very slender spine of bone has been found occasionally in the tendon of the stapedius in man: and a similar piece of bone, though of a rounder shape, exists constantly in the horse, the ox, and other animals. This circumstance is the more interesting in connection with the fact that cartilage occupies the position of the stapedius before the muscle is developed.

Fig. 450.

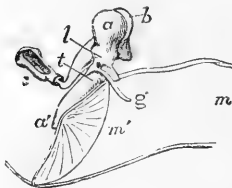


Fig. 450.—OUTLINE OF THE THREE SMALL BONES OF THE LEFT EAR AS SEEN FROM BEFORE. TWICE THE NATURAL SIZE.

This figure is designed to illustrate the effect of the action of the tensor and laxator muscles of the tympanic membrane in connection with their relation to the axis of rotation of the malleus. *a*, *a'*, the malleus, *b*, the incus seen behind it; *c*, the stapes; *m*, *m'*, the inner part of the meatus externus closed by the tympanic membrane; *g*, *processus gracilis*; the line *t*, indicates the direction and position of the tendon of the tensor tympani pulling the lower part of the malleus

inwards, the line *l*, that of the laxator tympani pulling inwards the upper half of the malleus so as to force the handle outwards.

*Actions*.—The malleus and incus move together round an axis extending backwards from the attachment of the *processus gracilis* of the malleus in the Glasc-

rian fissure to the attachment of the short process of the incus posteriorly. The tendon of the tensor tympani muscle passing from within to be inserted below that line, pulls the handle of the malleus inwards (fig. 450. *z*), while the laxator tympani inserted above that line, by pulling the head of the bone inwards (*l*), moves the handle outwards. The incus, moving along with the malleus, pushes the stapes inwards towards the internal ear when the membrana tympani is made tight, and draws that bone in an opposite direction, when the membrana tympani is relaxed. In this movement the head of the stapes is slightly raised as well as pressed inwards, and the upper margin of its base moves more than the lower. But the cavity of the inner ear is full of liquid; and its walls are unyielding, except at the fenestra rotunda; when, therefore, the stapes is pushed inwards the secondary membrane of the tympanum, which blocks up the fenestra rotunda, must be made tense by pressure from within. The attachment of the handle of the malleus, however, to the membrana tympani allows greater freedom of movement to that process than is allowed to the stapes by the ligaments of its base, and when the movement of the stapes ceases, the malleus rotates on the head of the incus without dragging the stapes further from the fenestra ovalis; and hence, probably, the necessity of a moveable articulation between those bones. The action of the stapedius muscle is obviously to draw the head of the stapes backwards, in doing which the hinder end of the base of that bone will be pressed against the margin of the fenestra ovalis, while the fore part will be withdrawn from the fenestra.\*

#### THE LINING MEMBRANE OF THE TYMPANUM.

The mucous membrane of the tympanum is continuous with that of the pharynx through the Eustachian tube, and is further prolonged from the tympanum backwards into the mastoid cells. Two folds which cross the breadth of the cavity descend from the part of the membrane which lines the roof. The anterior fold turns round the tendon of the tensor tympani muscle; the posterior fold passes round the stapes. The malleus and incus are invested by the lining of the outer wall of the cavity. The mucous membrane which lines the cartilaginous part of the Eustachian tube resembles much the membrane of the pharynx, with which it is immediately continuous; it is thick and vascular, is covered by laminated epithelium surmounted by vibratile cilia, and is provided with many simple mucous glands which pour out a thick secretion: in the osseous part of the tube, however, this membrane becomes gradually thinner. In the tympanum and the mastoid cells the mucous membrane is paler, thinner, and less vascular, and secretes a less viscid, somewhat yellow fluid. Between it and the periosteum is a more or less developed network of fibrous bundles, which are here and there raised above the general surface, causing corresponding projections of the mucous membrane. Moreover, in various places on the interlacing bundles, peculiar swellings occur of various sizes, which appear to be caused by the super-addition of concentrically arranged fibres upon the smaller bundles, and produce an appearance similar to that of miniature Pacinian corpuscles (Politzer, Kessel). The epithelium in the tympanic cavity is for the most part columnar and ciliated, but the roof, the promontory, the ossicula, and the membrana, are covered with a simple layer of flattened, non-ciliated cells (v. Troeltsch).

\* For further information with regard to the anatomical relations of the bones and membranes, and the mode in which they act, see Helmholtz, *Die Mechanik der Gehörknöchelchen und des Trommelfells*, Pflüger's Archiv, vol. i.; also English Translation, American edition.

## VESSELS AND NERVES OF THE TYMPANUM.

The **arteries** of the tympanum, though very small, are numerous, and are derived from branches of the external, and from the internal carotid.

The fore part of the cavity is supplied chiefly by the *tympanic branch* of the internal maxillary, which enters by the fissure of Glaser. The back part of the cavity including the mastoid cells, receives its arteries from the *stylo-mastoid branch* of the posterior auricular artery, which is conducted to the tympanum by the aqueduct of Fallopius. These two arteries form by their anastomosis a vascular circle round the margin of the membrana tympani. The smaller arteries of the tympanum are, the *petrosal branch* of the middle meningeal, which enters through the *hiatus Fallopii*; branches through the bone from the *internal carotid* artery, furnished from that vessel whilst in the carotid canal; and occasionally a twig along the Eustachian tube from the *ascending pharyngeal* artery.

The **veins** of the tympanum empty their contents through the middle meningeal and pharyngeal veins, and through a plexus near the articulation of the lower jaw, into the internal jugular vein.

**Nerves.**—The tympanum contains numerous nerves; for, besides those which supply the parts of the middle ear itself, there are several which serve merely to connect nerves of different origin.

The lining membrane of the tympanum is supplied by filaments from the tympanic plexus, which occupies the shallow grooves on the inner wall of the cavity, particularly on the surface of the promontory.

The *tympanic plexus* (fig. 451) is formed by the communications between, 1st, the tympanic branch (nerve of Jacobson) from the petrous ganglion of the glosso-pharyngeal; 2nd, a filament from the carotid plexus of the sympathetic; 3rd, a branch which joins the great superficial petrosal nerve; 4th and lastly, the small superficial petrosal nerve, from the otic ganglion.

Numerous ganglion cells are present both in the uniting cords and also at the points of junction of the plexus.

Fig. 451.

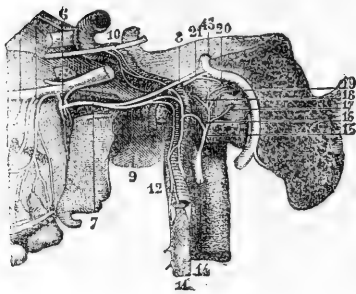


Fig. 451.—VIEW OF THE TYMPANIC PLEXUS OF NERVES (after Hirschfeld and Leveillé).

6, spheno-palatine ganglion; 7, Vidian nerve; 8, great superficial petrosal nerve; 9, carotid branch of the Vidian nerve; 10, part of the sixth nerve connected by twigs with the sympathetic; 11, superior cervical ganglion of the sympathetic; 12, carotid branch; 13, facial nerve; 14, glosso-pharyngeal nerve; 15, nerve of Jacobson; 16, its twig to the sympathetic; 17, filament to the fenestra rotunda; 18, filament to the Eustachian tube; 19, filament to the fenestra ovalis; 20, union of external deep petrosal nerve with the lesser superficial petrosal; 21, internal deep petrosal twig uniting with the great superficial petrosal.

The nerve of Jacobson (fig. 451, 15) enters the tympanum by a small foramen near its floor, which forms the upper end of a short canal in the petrous portion of the temporal bone, beginning at the base of the skull between the carotid foramen and the jugular fossa. The nerve from the carotid plexus is above and in front of this, and passes through the bone directly from the carotid canal. The branch to the great superficial petrosal nerve (fig. 451, 21) is lodged in a canal which opens on the inner wall of the tympanum in front of the fenestra

ovalis. The small superficial petrosal nerve (fig. 451, 20) also enters at the fore part of the cavity beneath the canal for the tensor tympani.

The tensor tympani muscle obtains its nerve from the otic ganglion; the laxator tympani is said to be supplied by the chorda tympani: and the stapedius is figured by Sümmering as receiving a filament from the facial nerve.

The *chorda tympani* is invested by a tubular reflection of the lining membrane of the tympanum; its course across the cavity has already been described.

### THE INTERNAL EAR, OR LABYRINTH.

The inner, essential part of the organ of hearing, is contained in the petrous portion of the temporal bone. It consists of a complex cavity—the osseous labyrinth—hollowed out of the bone, and containing the membranous labyrinth.

The *osseous labyrinth* is incompletely divided into three parts, named the vestibule (fig. 452, 1), the semicircular canals (3, 4, 5), and the cochlea (6, 7). They are lined throughout by a thin periosteal covering, within which there is a clear fluid named perilymph, or liquor Cotunnii.

The *membranous labyrinth* being distinctly smaller than the bony labyrinth, a space is left between the two, occupied by the perilymph just referred to. The membranous structure supports minute ramifications of the auditory nerve, and encloses a fluid named the endolymph.

### THE OSSEOUS LABYRINTH.

The **vestibule** forms a central chamber of the labyrinth, which communicates in front with the cochlea, behind with the semicircular canals, on the outer side with the cavity of the tympanum, and on the inner side with the meatus auditorius internus. It is irregularly ovoidal in shape from before backwards, and is slightly flattened or compressed from without inwards: except in the last-mentioned direction, in which it is somewhat smaller, it measures about  $\frac{1}{2}$ th of an inch in diameter.

The outer wall, which separates it from the cavity of the tympanum, is perforated by the fenestra ovalis, which in the recent state is closed by the base of the stapes.

At the fore part of the inner wall is a small round pit, the *fovea hemispherica* (fig. 453, 2), pierced with many small holes, which serve to transmit branches of the auditory nerve from the internal auditory meatus. This fossa is limited behind by a vertical ridge named *crista vestibuli*, or eminentia pyramidalis. Behind the crest is the small oblique opening of a canal, the *aqueduct of the vestibule* (fig. 453, 4), which extends to the posterior surface of the petrous bone.

In the roof is an oval depression, placed somewhat transversely, *fovea hemi-elliptica* (fig. 453, 1), the inner part of which is separated by the crest from the hemispherical fossa.

At the back part of the vestibule are five round apertures, leading into the semicircular canals: and at the lower and fore part of the cavity is a larger opening, which communicates with the scala vestibuli of the cochlea—*apertura scalæ vestibuli*.

The **semicircular canals** are three bony tubes, situate above and

behind the vestibule, into which they open by five apertures, the contiguous ends of two of the canals being joined. They are unequal in length, but each tube is bent so as to form about two-thirds of a circle ;

Fig. 452.



Fig. 453.

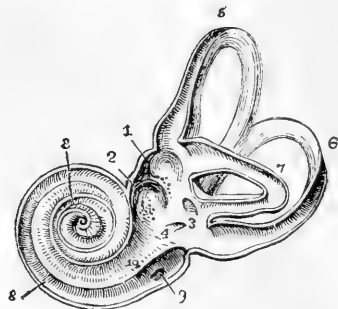


Fig. 452.—RIGHT BONY LABYRINTH, VIEWED FROM THE OUTER SIDE (after Sömmerring).  $\frac{2\frac{1}{2}}{1}$ .

The specimen here represented is prepared by separating piecemeal the looser substance of the petrous bone from the dense walls which immediately enclose the labyrinth. 1, the vestibule ; 2, fenestra ovalis ; 3, superior semicircular canal ; 4, horizontal or external canal ; 5, posterior canal ; \* \* \*, ampullæ of the semicircular canals ; 6, first turn of the cochlea ; 7, second turn ; 8, apex ; 9, fenestra rotunda. The smaller figure in outline below shows the natural size.

Fig. 453.—VIEW OF THE INTERIOR OF THE LEFT LABYRINTH (from Sömmerring).  $\frac{2\frac{1}{2}}{1}$ .

The bony wall of the labyrinth is removed superiorly and externally. 1, fovea hemi-elliptica ; 2, fovea hemispherica ; 3, common opening of the superior and posterior semicircular canals ; 4, opening of the aqueduct of the vestibule ; 5, the superior, 6, the posterior, and 7, the external semicircular canals ; 8, spiral tube of the cochlea (scala tympani) ; 9, opening of the aqueduct of the cochlea ; 10, placed on the lamina spiralis in the scala vestibuli.

and each presents, at one end, a slightly dilated part, called the *ampulla*. The canals are compressed laterally, and measure about  $\frac{1}{20}$ th of an inch across ; but in the ampulla each has a diameter of  $\frac{1}{10}$ th of an inch.

The canals differ from one another in direction, in length, and in position with regard to the vestibule. The *superior* semicircular canal (fig. 452, 3, fig. 453, 5) is *vertical* and transverse, and it rises higher than any other part of the labyrinth ; its place is indicated by a smooth arched projection on the upper surface of the petrous bone. The ampullary end of this canal is the external and anterior, and opens by a distinct orifice into the upper part of the vestibule ; whilst the opposite extremity joins the non-dilated end of the posterior semicircular canal, and opens by a common aperture with it into the back part of the vestibule (fig. 453, 3). The *posterior* semicircular canal (fig. 452, 5, fig. 453, 6), *vertical* and longitudinal in direction, is the longest of the three tubes : its ampullary end is placed at the lower and back part of the vestibule ; and the opposite end terminates in the common canal above described. The *external* semicircular canal (fig. 452, 4, fig. 453, 7) arches *horizontally* outwards, and opens by two distinct orifices into the upper and back part of the vestibule. The

canal is shorter than either of the other two : its ampulla is at the outer end, above the fenestra ovalis.

Fig. 454.

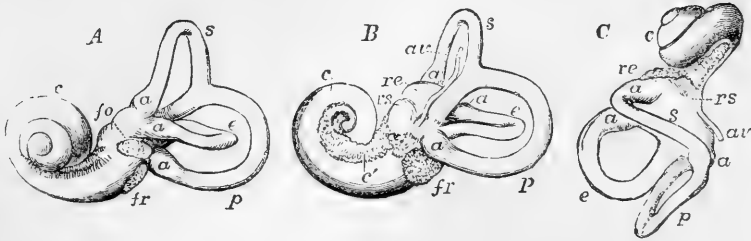


Fig. 454.—VIEWS OF A CAST OF THE INTERIOR OF THE LABYRINTH (from Henle). †

Such casts may easily be made in fusible metal, and give a very correct view of the form of the different parts of the labyrinthic cavity. A, view of the left labyrinth from the outer side ; B, the right labyrinth from the inner side ; C, the left labyrinth from above ; s, the superior, p, the posterior, and e, the external semicircular canals ; a, their several ampullæ ; re, fovea hemi-elliptica of the vestibule ; rs, fovea hemispherica ; av, aqueduct of the vestibule ; fo, fenestra ovalis ; fr, fenestra rotunda ; c, the coiled tube of the cochlea ; c', the first part of tube towards the base with the tractus foraminosus spiralis.

The **cochlea** (fig. 452, 6) is the most anterior division of the internal ear. When cleared of the surrounding less dense bony substance in which it lies imbedded, it presents the form of a blunt cone, the base of which is turned towards the internal auditory meatus, whilst the apex is directed outwards, with an inclination forwards and downwards, and is close to the canal for the tensor tympani muscle. It measures about a quarter of an inch in length, and the same in breadth at the base. The osseous cochlea consists of a gradually tapering spiral tube, the inner wall of which is formed by a central column, or *modiolus* (fig. 456, 1), around which it winds. It is partially divided along its whole extent by a spiral lamina (2), projecting into it from the modiolus. From this osseous spiral lamina membranous structures are in the recent condition stretched across to the outer wall of the tube, and thus completely separate two passages or *scalæ*, one on each side of the spiral lamina, which communicate one with the other only by a small opening, named *helicotrema*, placed at the apex of the cochlea.

That the cochlea is justly to be considered as an elongated tube, coiled spirally on the modiolus, is illustrated by the simple pouch-like form of the rudimentary cochlea of birds (fig. 455) as well as by the history of its development.

The *spiral osseous canal* is about an inch and a half long, and about the tenth of an inch in diameter in its widest part (at the commencement). From this point the canal makes two turns and a half around the central pillar (from left to right in the right ear, and in the opposite direction in the left ear), and ends by an arched and closed extremity called the *cupola*, which forms the summit of the cochlea.

Fig. 455.

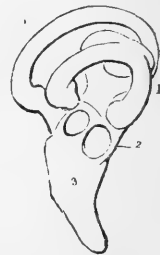

Fig. 455. — OSSEOUS LABYRINTH OF THE BARN OWL (*STRIX FLAMMEA*) (from Breschet). †

1, semicircular canals ; 2, vestibule ; 3, cochlea in the form of a short straight tube.

The first coil, being much the widest in its curve and composed of the largest portion of the tube, nearly hides the second turn from view ;

Fig. 456.

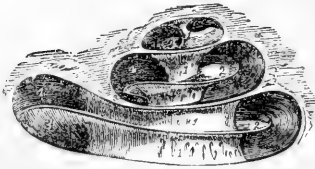


Fig. 457.

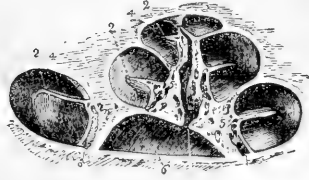


Fig. 456.—DIAGRAMMATIC VIEW OF THE OSSEOUS COCHLEA LAID OPEN.

1, modioli or central pillar ; 2, placed on three turns of the lamina spiralis ; 3, scala tympani ; 4, scala vestibuli.

Fig. 457.—VIEW OF THE OSSEOUS COCHLEA DIVIDED THROUGH THE MIDDLE (from Arnold).  $\frac{5}{1}$

1, central canal of the modioli ; 2, lamina spiralis ossea ; 3, scala tympani ; 4, scala vestibuli ; 5, porous substance of the modioli near one of the sections of the canalis spiralis modioli.

and, bulging somewhat into the tympanum, forms the round elevation on the inner wall of that cavity called the promontory.

The *modioli* (*columella cochleæ*) forms the central pillar or axis around which the tube and lamina turn spirally. It is much the thickest within the first turn of the cochlea, rapidly diminishing in size in the succeeding parts. The outer surface is dense, being, in fact, composed of the walls of the spiral tube ; but the centre is spongy as far as the last half coil, and is pierced by many small canals, for the passage of the nerves and vessels to the lamina spiralis : one of these canals, larger than the rest (*canalis centralis modioli*), runs from the base through the centre of the modioli.

The *lamina spiralis ossea* is a thin, flat plate, growing from and winding around the modioli, and projecting into the spiral tube, so as to divide it partly into two. Its free margin, which gives attachment in the recent state to the membranous septum, does not reach farther than about half of the distance between the modioli and the outer wall of the spiral tube. The osseous lamina terminates close to the apex of the cochlea in a hooklike process (*hamulus*), which partly bounds the helicotrema.

The lamina is thin and dense at its free margin ; but nearer the modioli it is composed of two dense outer plates enclosing a more open and spongy structure, in which are numerous small canals for vessels and nerves, continuous with, but running at right angles to, the canals in the modioli. Winding around the modioli, close to the lamina spiralis, is a small canal, named by Rosenthal the *canalis spiralis modioli*.

The *scale* in the osseous cochlea are two in number, distinguished as the scala tympani and scala vestibuli.

The *scala tympani*, the portion of the tube on the basal side of the lamina spiralis, commences at the fenestra rotunda, where in the recent state it is separated from the tympanum by the secondary membrane of the tympanum. Near its commencement is the orifice of a small canal (*aqueductus cochleæ*, fig. 453, 9), which extends downwards and inwards through the substance of the petrous part of the temporal bone to near



the jugular fossa, and transmits a small vein. The *scala vestibuli* is rather narrower than the *scala tympani* in the first turn of the cochlea ; it commences from the cavity of the vestibule, and communicates, as already described, with the *scala tympani* at the apex of the modiolus.

#### THE MEMBRANOUS LABYRINTH.

As before stated, within the osseous labyrinth, and separated from its lining membrane by the perilymph, membranous structures exist in which the ultimate ramifications of the auditory nerve are spread. In the vestibule and semicircular canals these structures have a general resemblance in form to the complicated cavity in which they are contained. They do not, however, lie loose within the osseous cavity, as would appear from fig. 458, but are more or less united with its lining periosteum by fibrous bands conveying blood-vessels, which stretch across the space between, and serve thus to fix the membranous sacs and tubes. In the cochlea the membranous structures complete the septum between the *scalæ* already mentioned, and enclose an intermediate passage, the *canalis membranaceus*. As before stated, the liquid contained within the membranous labyrinth is distinguished as *endolymph*.

**VESTIBULE.** — The *membranous vestibule* consists of two closely connected sacs, and the parts by which they are united to the membranous semicircular canals and canal of the cochlea.

The larger of the two sacs, the *common sinus* or **utricle** (fig. 458, *i i*), is of an oblong form, slightly flattened from without inwards. It is lodged in the upper and back part of the osseous vestibule, occupying the fovea hemi-elliptica. Opposite the crista vestibuli several small branches of the auditory nerve enter from the foramina in the bone ; and here the walls of the common sinus are thicker and more opaque than elsewhere. A small mass of calcareous particles, *otoliths* or *otoconia*,

Fig. 458.

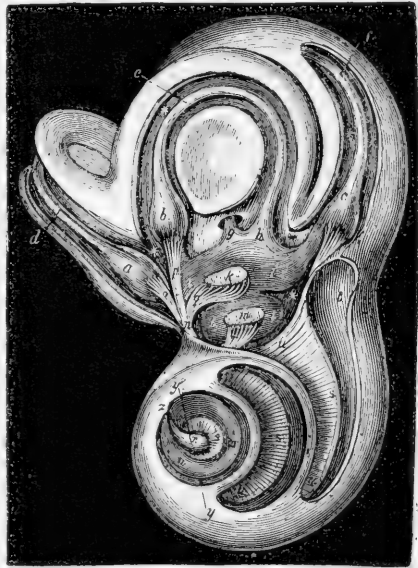

Fig. 458.—THE INTERIOR OF THE LEFT LABYRINTH WITH ITS MEMBRANOUS PARTS AND NERVES (from Breschet). MAGNIFIED.

The outer wall of the osseous labyrinth is in part removed so as to display the membranous parts within. *a*, *scala vestibuli* ; *t*, *scala tympani* of the cochlea : *s, s*, *lamina spiralis* ; *i, i*, *utricle* or *common sinus* with its group of *otoliths*, *k* ; *l*, *saccule* with its *otoliths* ; *a*, *membranous ampulla* of the superior semicircular canal, *d* ; *b*, *ampulla* of the horizontal, *e*, and *c*, that of the posterior semicircular canal, *f* ; *n*, *anterior division* of the auditory nerve giving branches, *q, o, p*, to the utricle and the ampullæ of the superior and external canals ; *g*, the united part of the superior and posterior canals ; *h*, the posterior extremity of the external canal ; \* \*, space containing perilymph.

lies within the sac, attached to its wall (fig. 458, *k*). These otoliths are crystals of carbonate of lime, rhombic, octahedral, or six-sided, often pointed at their extremities.

The ends of all the membranous semicircular canals open into the utricle.

The smaller vestibular vesicle, the **saccul**e (*U*), is more nearly spherical than the common sinus, but, like it, is somewhat flattened. It contains similar otoconia in its wall (fig. 458, *m*). The saccul is situated in the lower and fore part of the cavity of the osseous vestibule, close to the opening from the scala vestibuli of the cochlea, and is received into the hollow of the fovea hemispherica, from the bottom of which many branches of nerve enter it.

A minute canal, lined with epithelium, passes from the utricle along the aqueductus vestibuli to end blindly near the posterior surface of the petrous bone. It is joined near its origin by a similar one from the saccul, so that in this way the cavity of the saccul is brought into communication with that of the utricle (Boettcher). Lastly, the saccul is connected with the membranous canal of the cochlea by means of a short, narrow canal, the *canalis reuniens* (Hensen).

**SEMICIRCULAR CANALS.**—The **membranous semicircular canals** are about one-third the diameter of the osseous tubes in which they are lodged, and are dilated into ampullæ within the ampullary enlargements of those tubes. In section they are oval or somewhat elliptical (fig.

Fig. 459.

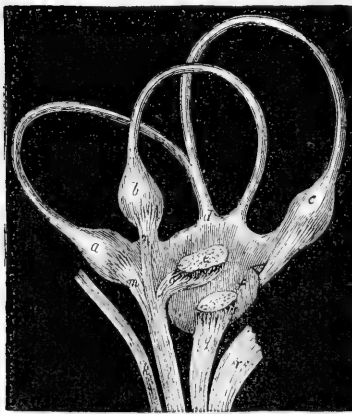


Fig. 460.

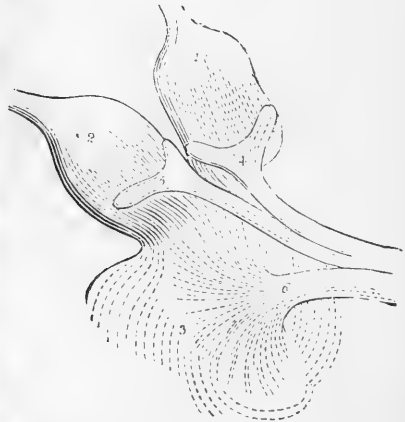

Fig. 459.—MEMBRANOUS LABYRINTH AND NERVOUS TWIGS DETACHED, MAGNIFIED (Breschet)

*k*, facial nerve in the meatus auditorius internus; *l*, anterior division of the auditory nerve giving branches, *o*, *m*, *n*, to the utricle and the ampullæ of the superior and external canals; *g*, posterior division of the auditory nerve, giving branches to the saccul, *b*, posterior ampulla, *c*, and cochlea, *r*; *d*, the united part of the superior and posterior canals.

Fig. 460.—AMPULLÆ OF THE SUPERIOR AND EXTERNAL SEMICIRCULAR CANALS AND PART OF THE COMMON SINUS, SHOWING THE ATTACHMENT OF THE NERVES (from Steifensand). 2<sup>p</sup>

1, membranous ampulla of the superior canal; 2, that of the external canal; 3, part of the common sinus; 4 and 5, fork-like swellings of the nerves at their ampullary distribution; 6, twig of the auditory nerve spreading in the common sinus.

462). At the ampullæ they are thicker and less translucent than in the rest of their extent, and nearly fill their bony cases. That part of each which is towards the concavity of the semicircle of the canal is free; whilst the opposite portion is fixed to the wall of the bony canal; and in the ampulla this part is flattened, receives branches of nerves and blood-vessels, and presents on its inner surface a transverse projection, *septum transversum* or *crista acustica*, which partly divides the cavity into two.

**Auditory nerve: vestibular division.**—At the bottom of the meatus auditorius internus the auditory nerve divides into an anterior and a posterior branch, which, broken up into minute filaments, pass through the perforations of the cribriform plate which separates the meatus from the internal ear, and are distributed respectively to the cochlea and vestibule. In both branches, as well as in the trunk, there are numerous nerve-cells. The *vestibular nerve* (fig. 459) divides into five branches, which proceed respectively to the utricle, the saccule, and the three ampullæ of the semicircular canals; those for the utricle and the superior and external semicircular canals enter the cavity in a group along the *crista vestibuli*; the fibrils for the sacculus (*q*) enter the vestibule by a smaller group of foramina, which are situated below those just described, and open at the bottom of the fovea hemispherica; the branch for the posterior semicircular canal is long and slender, and traverses a small passage in the bone behind the foramina for the nerve

Fig. 461.

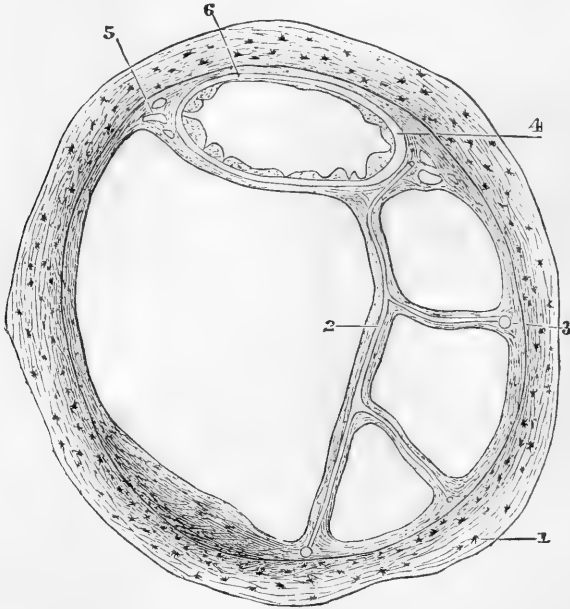


Fig. 461.—SECTION OF ONE OF THE HUMAN SEMICIRCULAR CANALS (Rüdinger).  
MAGNIFIED.

1, Osseous wall; 2, fibrous bands with included blood-vessels, united at 3 with the periosteum; 4, membranous canal with its three layers; 5, short fibrous bands (with intervening spaces) uniting the membranous canal firmly to the periosteum; 6, union of its outermost layer with the periosteum.

of the sacculus. The nerves of the ampullæ enter the flattened or least prominent side of the ampullæ, where they each form a forked swelling (4, 5, fig. 460), which corresponds with the transverse septum already described, in the interior of the dilatation. No nerves have been found extending to any other parts of the semicircular canals.

**Structure.**—Three layers can be distinguished in the membranous walls of the semicircular canals, an outer fibrous stratum, an inner epithelial lining, and between the two a homogeneous tunica propria. These layers are not of equal thickness throughout, for at those parts where the walls are in contact with and supported by the bone (fig. 461, 6), or rather its periosteal lining, namely, along the side which is turned towards the convexity of the semicircle, they are thinner than at the rest of the circumference, where they lie free and are bathed by the perilymph. The difference in thickness affects the fibrous layer and the tunica propria only, for the epithelium forms throughout a lining of simple flattened cells.

Fig. 462.

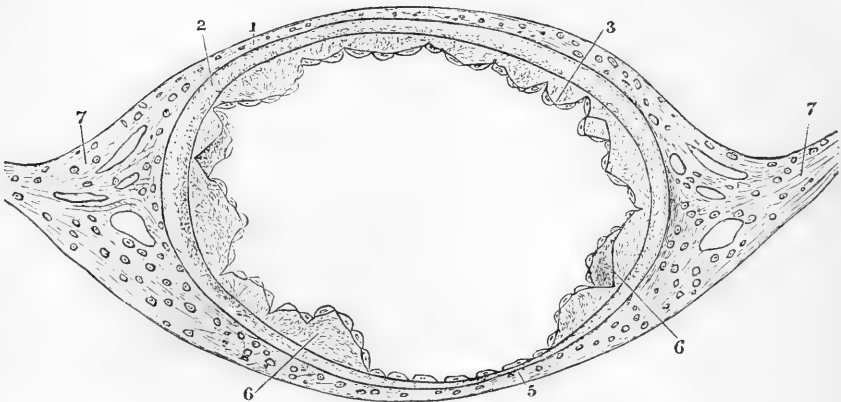


Fig. 462.—SECTION OF MEMBRANOUS SEMICIRCULAR CANAL, MUCH MAGNIFIED (Rüdinger).

1, outer fibrous layer ; 2, tunica propria ; 3, 6, papilliform projections with epithelial covering ; 5, fixed side of the canal, with very thin tunica propria without papillæ ; 7, fibrous bands passing to periosteum.

The *fibrous layer* (fig. 462, 1), which contains some irregular pigment-cells, is apparently composed of ordinary fibrous tissue, similar to that of the periosteum, with which it becomes continuous at the parts where the two structures are in contact. It is especially developed at the ends of the oval section, whence well-marked bands of fibrous tissue pass to the periosteum (fig. 462, 7). From here, also, the more delicate bands of fibrous tissue above described commonly arise, which traverse the perilymph to become connected with the periosteum of the opposite wall of the canal (fig. 461, 2). Both along these bands and also more directly from the contiguous periosteum, numerous small blood-vessels pass into the fibrous layer and there break up into a coarse capillary network, the branches of which do not, in man, pass into the tunica propria.

The *tunica propria* is a clear, glassy, membranous structure continuous around the whole tube, although thinning off very much opposite the part where the membranous canal is in contact with the bone (fig. 462, 5). Externally it is not very distinctly marked off from the fibrous coat: internally it presents not a smooth surface but a number of papilliform eminences (fig. 462, 3, 6), which project into the interior of the canal except at the thinnest part. According to Rüdinger, these eminences are found almost constantly in the adult.

The epithelial lining is continuous, both over and between the papilliform projections. In the human semicircular canals the cells are of the same nature and form throughout, but in many of the lower animals—birds and fish—a part takes on somewhat of a columnar character, while in one species of fish, (*Salmo hucho*), as described by Rüdinger, a tract of cells along the whole length of each canal becomes remarkably developed into two rows of heaped-up, rounded cell-bodies, from each of which a long filament extends to the wall of the canal in a direction transverse to the axis.

The meaning of these modifications of structure is unknown. No nerves have hitherto been seen proceeding to the parts in question; but they apparently represent the much more developed peculiarly modified epithelium which, as we shall immediately see, is found in the ampullæ and in the saccule and utricle opposite the parts where the corresponding branches of the auditory nerve enter, and which receives the ultimate terminations of those nerves.

The ampullæ, as well as the saccule and utricle, agree generally in structure with the semicircular canals: at the part, however, where they are connected to the osseous wall the fibrous outer layer forms a loose-meshed tissue, and the *tunica propria* is very much thickened, and in the ampullæ causes a rounded transverse projection into the cavity of each, the *septum transversum*, or *crista acustica*, before mentioned. Over this projection, and also to a certain extent in its neighbourhood, the epithelium is of an elongated columnar form (fig. 463, *c*), and is surmounted by long and fine cilium-like processes (auditory hairs (*h*)), which are, however, not spontaneously vibratile, but project stiffly into the endolymph. These hairlets are said to belong not to the columnar epithelium cells themselves, but to spindle-shaped cells (*sp*), which lie between

Fig. 463.

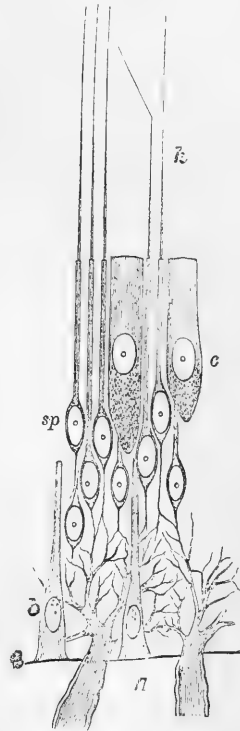


Fig. 463.—DIAGRAM OF THE AUDITORY EPITHELIUM AND THE MODE OF TERMINATION OF THE NERVES OF THE AMPULLÆ (after M. Schultze).

*c*, columnar epithelium; *sp*, spindle-shaped cells, each supporting an auditory hair, *h*; *b*, basal supporting cells; *n*, two nerve fibres passing through the *tunica propria* to join the plexus in the epithelium; *l*, limit of *tunica propria*.

the columnar, and are supported by them. Finally, as described by Max Schultze, a layer of columnar epithelium (*b*) rests upon the tunica propria by the broad ends of the cells, whilst the opposite, tapering ends project between the other epithelial and nervous elements, which they no doubt assist to support. The branches of the auditory nerve (*n*) pass directly through the loose-meshed tissue above mentioned and through the thickened tunica propria;

Fig. 464.

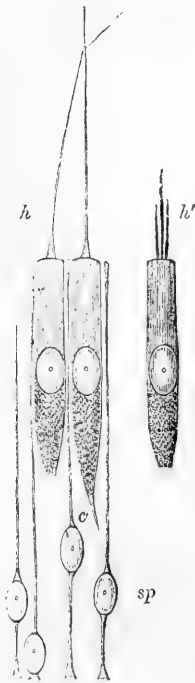


Fig. 464.—AUDITORY EPITHELIUM FROM AMPULLA OF A FISH (Retzius). HIGHLY MAGNIFIED.

*h*, auditory hairs; *h'*, the basal end of one broken up into finer filaments; *sp*, spindle-cells; *c'*, attenuated extremity of columnar cell.

The whole question must be regarded as at present undecided, according to the same observer, the nerves retain their medullary sheath some little way beyond the limit of the tunica propria, and their axis fibres do not form an anastomosing network, but after merely branching two or three times pass directly, as just stated, into the attenuated ends of the columnar cells, which he accordingly terms the "auditory" cells. He further states that the auditory hairs are very liable to break up under the influence of reagents into a bunch of more delicate hairlets (*h'*).\*

The whole question must be regarded as at present undecided,

\* Anatomische Untersuchungen; Das Gehörlabyrinth der Knochenfische, Stockholm, 1872.

further investigation being necessary to inquire into the relative accuracy of the two views.

The spindle- or fibre-cells and the auditory hairs were first described by Max Schultze,\* and bring to mind the so-called olfactory cells of the nasal mucous membrane, to be presently described, and the gustatory cells which are met with in the special organs of taste. Moreover, as we shall immediately see, cells bearing similar stiffly projecting hairs are met with also in the cochlea; and in all these places it is thought probable that there is a direct connection between the hair-bearing cells and the nerves of special sense, although owing to the extremely delicate nature of the parts and the difficulty of manipulation, such connection has, perhaps, never yet been undoubtedly observed. The minute structure of the parts just described has been chiefly worked out in the comparatively large membranous labyrinth of fishes, but is no doubt more or less similar in all vertebrata.

The foregoing description, although referring more particularly to the characters of the epithelium and mode of nerve distribution in the cristæ acusticæ of the ampullæ, is equally applicable to the maculæ acusticæ of the saccule and utricle. The nerves which are supplied to the maculæ seem, however, to spread out more and to be less markedly limited in their distribution than those which go to the ampullæ (see fig. 460). Both saccule and utricle contain in their cavity and lying in contact with the nerve-epithelium a little mass of otoliths, which, however, do not float free in the fluid, but appear enclosed in a delicate cuticular investment. Otoliths are also found scattered here and there in the ampullæ and semicircular canals. Their use is not sufficiently known.

**COCHLEA.**—The **membranous cochlea** resembles the membranous

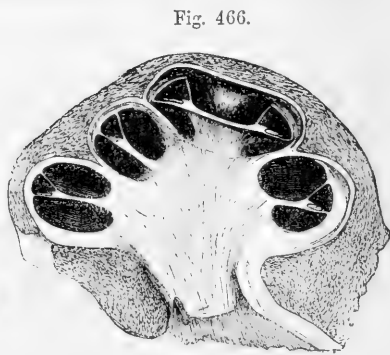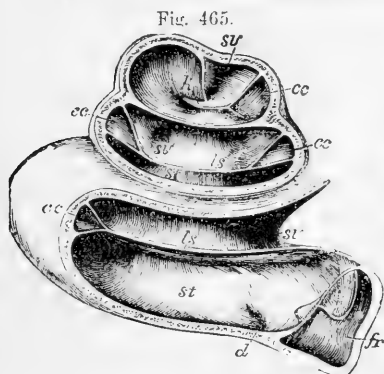


Fig. 465.—LEFT COCHLEA OF A CHILD SOME WEEKS OLD (Reichert).  $\frac{1}{1}$

The drawing was taken from a specimen which had been preserved in alcohol, and was afterwards dried; a section is made so as to show the lamina spiralis, scalæ, and cochlear canal in each of the three coils: the membranous spiral lamina is preserved, but the appearances connected with the organ of Corti, &c., have been lost from drying. *fr*, fenestra rotunda with its membrane; *st*, scala tympani; *sv*, scala vestibuli; *ls*, lamina spiralis; *h*, hamulus; *cc*, canalis cochleæ; *d*, opening of the aqueductus cochleæ.

Fig. 466.—VERTICAL SECTION OF THE COCHLEA OF A FETAL CALF (Kölliker).  $\frac{1}{1}$

In this specimen the external wall was ossified, but the modiolus and spiral lamina were still cartilaginous; the section shows in each part of the cochlear tube the two scales with the intermediate canalis cochleæ and lamina spiralis.

\* Müller's Archiv, 1858.

semicircular canals just described in consisting of a tube, lined by epithelium and containing endolymph, partly surrounded by a clear space containing perilymph, but it differs from them materially both in shape and in the modifications presented by its epithelial lining. In macerated specimens, the two parts into which the osseous tube of the cochlea is divided are, it will be remembered, only imperfectly separated by the osseous spiral lamina which projects from the columella; but in the fresh specimen the tube is separated completely into three distinct parts by means of two membranes, which extend along its whole length (figs. 465, 466). In the first place the lamina spiralis is directly prolonged by a comparatively strong, well-marked membrane, the *basilar membrane* (fig. 467, *b*), which stretches straight across to the outer wall of the cochlea, and is here connected to an inward projection of the lining periosteum and sub-periosteal tissue known as the *spiral ligament* (*lsp*). The basilar membrane thus helps to complete the upper\* limit of the scala tympani (*ST*), but does not enter into the lower boundary of the scala vestibuli, for a second, much more delicate membrane, known as the membrane of Reissner (*R*) passes from the upper part of the lamina a little distance

Fig. 467.

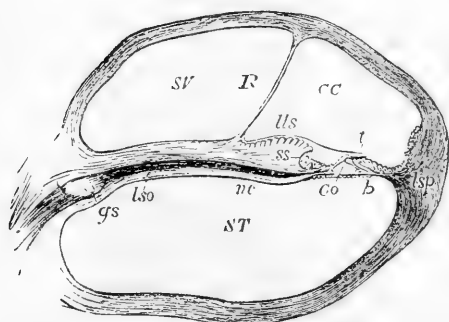


Fig. 467.—SECTION THROUGH ONE OF THE COILS OF THE COCHLEA, DIAGRAMMATIC (altered from Henle).  $\frac{3}{4}$

S T, scala tympani; S V, scala vestibuli; C C, canalis cochleæ; R, membrane of Reissner forming its vestibular wall; *l s o*, lamina spiralis ossea; *l l s*, limbus laminae spiralis; *s s*, sulcus spiralis; *n c*, cochlear nerve; *g s*, ganglion spirale; *t*, membrana tectoria; *b*, membrana basilaris; *C o*, rods of Corti; *l s p*, ligamentum spirale.

*canalis membranaceus*, or *ductus cochlearis* (figs. 465, 467, *CC*, fig. 469, *DC*). It terminates in a blind pointed extremity at the apex, and another at the base. That at the apex, extending beyond the hamulus, is fixed to the wall of the cupola, and partly bounds the helicotrema; that at the base fits into the angle at the commencement of the osseous

\* To avoid repetition it may here be stated that for convenience sake the cochlea is considered in the present description as having its larger part or base lowermost, and the domed extremity uppermost, although of course this is far from being the relative position of the parts whilst within the body. Moreover, parts nearer the columella are spoken of as *inner*; parts nearer the external wall as *outer*.

from its end, and stretches obliquely upwards and outwards, also to become connected with the lining periosteum; neither of the lines of insertion of this membrane are prominently marked. The oblique direction of the membrane of Reissner causes a triangular space to be shut off between it and the basilar membrane, which is bounded externally by the outer osseous wall of the cochlea lined by periosteum: and this space, extending throughout the whole length of the osseous tube, and lined throughout by an epithelium variously modified in different parts, is known distinctively as the *canal of the cochlea*



spiral lamina in front of the floor of the vestibule. Near to this blind extremity the canalis membranaceus receives a small canal, lined with epithelium, *canalis reuniens* (Hensen), which is continued from the saccule of the vestibule like the neck of a flask, and enters the canal of the cochlea abruptly nearly at a right angle (fig. 468, *cr*). The cavity of the canalis membranaceus is thus rendered continuous with that of the saccule.

It is the structures which are found upon the *floor* of this spirally-wound triangular canal of the cochlea that claim more particular attention, for it is to them that the branches of the cochlear nerve are distributed, and upon them the function of the cochlea as a part of the auditory apparatus appears more especially dependent.

The floor itself of the cochlear canal is formed of a narrow portion of the spiral lamina external to the membrane of Reissner, and of the basilar membrane. In the macerated specimen this part of the lamina thins off gradually to a fine edge like the blade of a knife, but in the recent condition (fig. 467, *ls*) it retains its thickness for some distance (or even exhibits a slight increase), and then abruptly terminates with a border which in section is C-shaped with the lower limb of the C much more prolonged and tapering than the upper. This lower limb is in fact the section of the end of the osseous lamina, together with a thin membranous layer which covers it, and which is directly prolonged into the basilar membrane. This membrane, as well as the whole thickened upper part of the edge of the spiral lamina, not being ossified, disappears in the process of maceration. The thickened

part (fig. 467, *ls*), with its somewhat overhanging, crest-like end (fig. 469, *Cr*), is known as the *limbus* of the spiral lamina, and the groove which it overhangs, and which in section is represented by the bay of the C, is known as the *spiral groove* (fig. 467, *ss*, fig. 469, *S. sp. i*).

The tissue of which the **limbus** is composed seems to be a form of connective tissue; but it differs in different parts. Towards the under and inner part there are in particular numerous corpuscles, and the texture is distinctly fibrous, but above there are few or no corpuscles, and the tissue is more homogeneous; although a faint fibrillation in a radial direction, *i.e.*, from within outwards, may still be traced in it. This faintly fibrillated tissue is prolonged, as just intimated, beyond

Fig. 468.

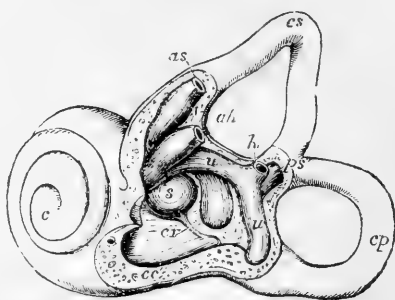


Fig. 468.—THE LEFT LABYRINTH OF A CHILD AT BIRTH, PARTIALLY OPENED ON ITS OUTER SIDE TO SHOW THE COMMENCEMENT OF THE MEMBRANOUS CANAL OF THE COCHLEA (slightly altered after Reichert).  $\frac{1}{2}$

The external or horizontal canal has been removed; *c s*, superior canal; *c p*, posterior canal; *a s*, membranous ampulla and tube of the superior canal cut short; *a h*, that of the external or horizontal canal; *h*, undilated end of the horizontal canal in front of the common opening of the superior and posterior canals; *p s*, united superior and posterior canals; *u*, utricle; *s*, saccule; *c c*, vestibular part or commencement of the membranous canal of the cochlea; *c r*, canalis reuniens connecting it with the saccule; *c*, cochlea.

the osseous lamina, into the basilar membrane. Near its termination, close to the junction with the basilar membrane, it is perforated with a number of regularly-arranged, elongated apertures (fig. 470, *p*), which serve for the transmission upwards of the nerve-fibres. The latter, in their course from the spiral ganglion to the auditory epithelium, are lodged, as far as this, in canals in the lower osseous part of the spiral lamina. Their arrangement here will be afterwards more fully described.

Fig. 469.

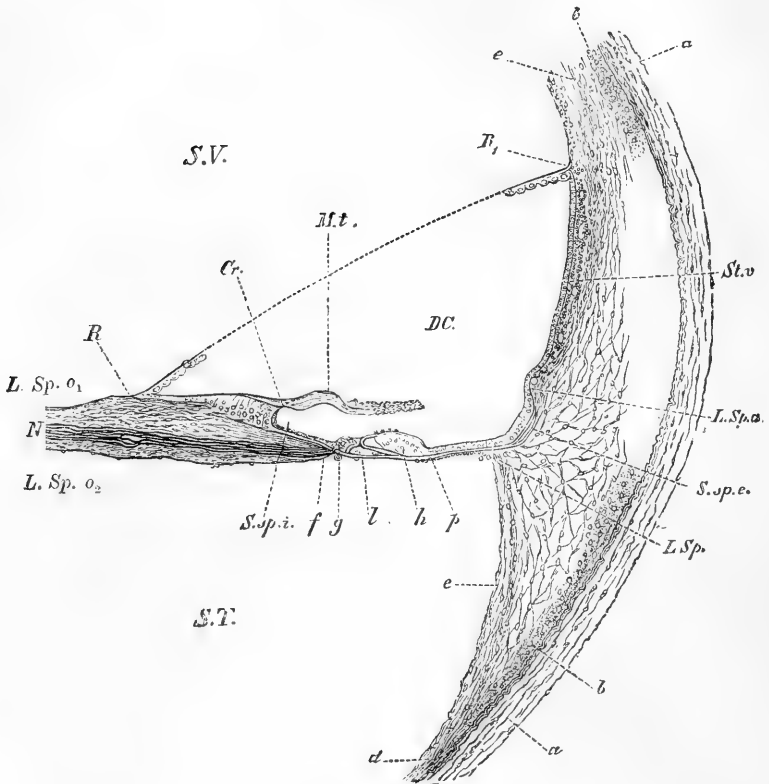


Fig. 469.—VERTICAL SECTION OF THE FIRST TURN OF THE COCHLEA OF A CHILD A YEAR AND A HALF OLD. 100 DIAMETERS (Waldeyer).

*SV*, scala vestibuli; *ST*, scala tympani; *DC*, duct or canal of the cochlea; *L.sp.o<sub>1</sub>*, *L.sp.o<sub>2</sub>*, vestibular and tympanal layer of the osseous spiral lamina with the stratum of nerve-fibres, *N*, between; *a, a*, outer bony wall of cochlea; *b, b*, and *d*, periosteum; *e, e*, connective tissue thickening forming at *L.Sp.* the spiral ligament; *St.v.*, stria vascularis; *L.Sp.a*, prominence known as the accessory spiral ligament, containing a spirally running blood-vessel, the *vas prominens*; *S.sp.i.*, spiral groove (inner); *S.sp.e.*, so-called external spiral groove; *R, R<sub>1</sub>*, section of Reissner's membrane, the middle part indicated only by a dotted line; from *R* to *Cr.*, limbus laminae spiralis; *M.t.*, membrana tectoria, somewhat raised up from its natural position; *f—p*, organ of Corti; *f*, nerves turning up to enter epithelium; *g*, inner hair-cell region; *h*, region of the outer hair-cells; *l*, basilar membrane underneath rods of Corti.

When the limbus is viewed from above, the edge is seen to present, not a continuous line, but a succession of tooth-like projections (fig. 470, *Cr*), which give it a jagged aspect. These projections are continued as flattened eminences a short distance on the upper surface of the limbus, which is, therefore, not smooth, but, at least near the edge, marked in this way with eminences and intervening furrows. Nearer the line of origin of the membrane of Reissner, however, it becomes more uniform, and here, too, its epithelial covering, which is directly continuous with that of the under surface of Reissner's membrane, is evenly distributed; whereas at the crest itself the epithelial cells are, in the adult, only found in the furrows: so that the tooth-like prominences project between the rows of epithelium into the cochlear canal. Immediately below the overhanging projections, the epithelium again runs together into a uniform single layer which lines the spiral groove, and is continuous externally with the more specialized cells, presently to be described as forming the organ of Corti.

The **basilar membrane** stretches, as before-mentioned, straight between the osseous lamina and the spiral ligament on the outer wall, and separates the canal of the cochlea from the scala tympani. It increases in breadth from the base to the apex of the cochlea, while the breadth of the osseous spiral lamina diminishes. Thus in the first turn of the cochlea, this membrane forms about half of the breadth of the septum made by it and the osseous lamina; but towards the apex of the cochlea the proportion between the two parts is gradually changed, until, near the helicotrema, the membranous part is left almost un-

Fig. 470.

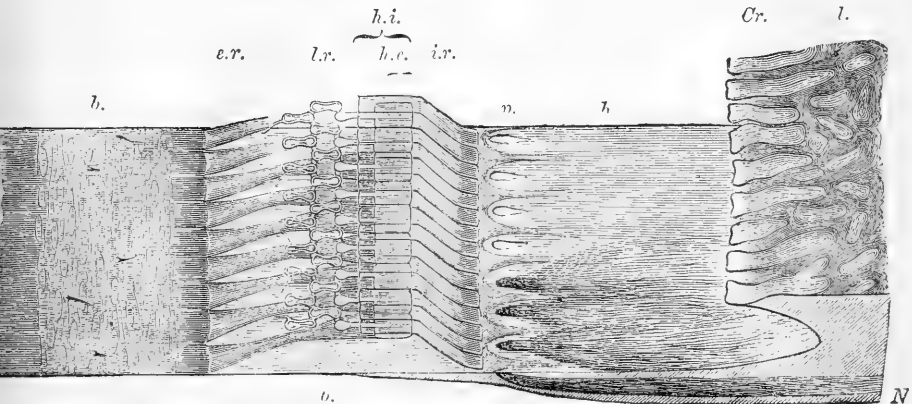


Fig. 470.—SEMI-DIAGRAMMATIC VIEW OF PART OF THE BASILAR MEMBRANE AND TUNNEL OF CORTI OF THE RABBIT, FROM ABOVE AND THE SIDE. Much magnified.

*l*, limbus; *Cr*, extremity or crest of limbus with tooth-like projections; *b b*, basilar membrane; *p*, perforations for transmission of nerve fibres *N*, which are represented at the lower part of the figure, but omitted for the sake of clearness in the upper; *i.r.*, fifteen of the inner rods of Corti; *h.i.*, their flattened heads seen from above; *e.r.*, nine outer rods of Corti; *h.e.*, their heads, with the phalangeal processes extending outward from them and forming, with the two rows of phalanges, the lamina reticularis, *l.r.* The fibres of the outer rods are seen to be continued into the striation of the basilar membrane, through which the connective tissue fibres and nuclei of the undermost layer are seen. Portions of a few of the basilar processes of the outer hair-cells remain attached to the membrane.

ported by any plate of bone. The exact nature of the tissue composing the proper substance of the membrane is unknown, but it is probably analogous, at least the uppermost stratum, to that composing the rods of Corti, to be afterwards described. It is somewhat stiff in consistence, and may readily be broken up into straight fibres which have a radial direction, corresponding with a striation which the membrane, especially its outer part, presents when viewed on the flat (fig. 470). Externally, at its attachment to the spiral ligament, it breaks up into diverging fibres, which spread into that projection. On the upper surface of the membrane is the epithelium which forms the organ of Corti, and the single layer of cells which is continued from this externally (fig. 469): on the under surface it is covered by a layer of connective tissue (often described as part of the membrane), the fibres of which have a longitudinal direction, parallel with the spiral, and across the direction of the fibres of the membrane proper. There are numerous intermixed spindle-shaped corpuscles in this tissue, which is in continuity with the lining periosteum of the scala tympani. Small blood-vessels are found in it, but as a rule extending only over the inner part of the membrane. They are usually terminated by a rather larger longitudinally running vessel, situate opposite the outer rods of Corti, and known as the *vas spirale*.

The **membrane of Reissner** (figs. 467, 469, *R*), separates the scala vestibuli from the canal of the cochlea. It is composed of an excessively delicate and almost homogeneous layer of connective tissue continuous with the lining periosteum of the scala vestibuli, and is covered on the surface which is turned to the cochlear canal with a simple layer of delicate scaly epithelium continuous below with that on the limbus and above with that lining the outer wall of the canal (fig. 469). The cells have each a circular flattened nucleus, and not unfrequently contain fat droplets of various sizes. The vestibular side of the membrane of Reissner is quite smooth, and is covered with a layer of flattened epithelioid connective-tissue cells, readily distinguishable from the true epithelial cells on the other side as well by their greater delicacy of outline, and their larger size, as by the history of their development. A few blood-capillaries are continued into the membrane from the neighbouring periosteum.

The **periosteum** which lines the scala vestibuli and scala tympani, consists of ordinary connective tissue. There is no continuous lining of flattened cells on the free surface (that bathed by the perilymph), such as covers the surface of serous membranes. That, on the other hand, which bounds the canal of the cochlea externally, is very much thickened by a development of retiform connective tissue, and is covered by the epithelium of that tube, which here forms a single layer of cubical cells, many of which contain pigment. The periosteum, moreover, forms usually a slight inward projection a little above the ligamentum spirale, containing a prominent blood-vessel (fig. 469, *L. sp. a*). The substance of the periosteum is also frequently pigmented immediately under the epithelium of the tract between this prominence and the membrane of Reissner, and from containing large and numerous blood-vessels, is often termed *stria vascularis* (*St.v.*). Immediately beneath the epithelium is a basement membrane, through which, in sections, processes may here and there be seen passing from the epithelium to the subjacent tissue.

The **ligamentum spirale** (fig. 469, *LSp*) appears in sections as a pointed projection from the outer wall of the cochlea, with the basilar membrane attached to its apex. It is composed of a retiform connective tissue, many of the cells of which have an elongated shape and radiate from the point of attachment of the basilar membrane. They have been considered by some to be muscular, but there is no distinct proof of their contractile nature.

**ORGAN OF CORTI.**—

The epithelium which covers the basilar membrane requires a careful description, including as it does the highly-specialised structures which are known by the name of the **organ of**

Fig. 471.

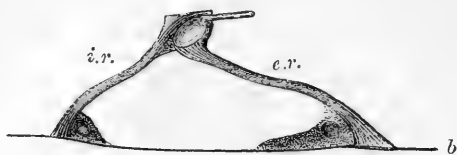


Fig. 471.—A PAIR OF RODS OF CORTI, FROM THE RABBIT'S COCHLEA, IN SIDE VIEW. HIGHLY MAGNIFIED.

*b, b*, basilar membrane; *i.r.*, inner rod; *e.r.*, outer rod. The nucleated protoplasmic masses at the feet are also shown.

Fig. 472.

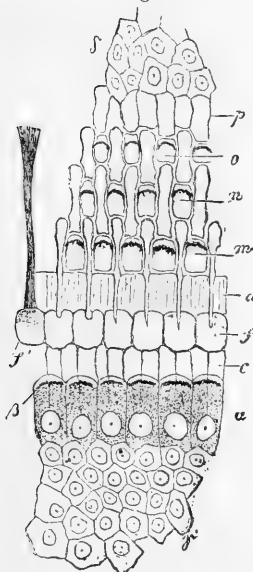


Fig. 472.—SKETCH OF LAMINA RETICULARIS AND ADJOINING STRUCTURES FROM THE CAT. HIGHLY MAGNIFIED (Kölliker).

*a*, inner hair-cells with hairlets; *b*; *γ*, epithelium of spiral groove; *c*, *d*, inner rods, the junction between the individual heads at *d* not being represented; *e*, *f*, heads of outer rods; *m*, *n*, *o*, rings of l. reticularis with circles of hairlets; *p*, cuticular tissue external epithelial cells, *δ*.

Fig. 473.

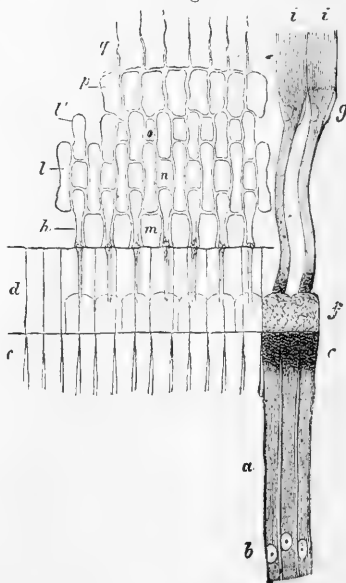


Fig. 473.—SIMILAR FIGURE FROM THE CALF (Kölliker).

*a*, *b*, *c*, inner rods; *d*, their heads; *e*, *i*, feet of ditto; *h*, phalangeal process from head of outer rod; *ll*, phalanges of l. reticularis; the other letters as in fig. 472.

**Corti.** The central part of this apparatus is formed by two sets of stiff, rod-like bodies—the inner and outer *rods of Corti* (figs. 470, 471)—which stand by one end, the foot, upon the basilar membrane, the outer series (*o.r.*), at some little distance from the inner (*i.r.*), and thence are inclined towards each other—the outer series inwards and the inner series outwards—so as to meet by their upper ends or heads, which are thus in contact. In this way each pair of rods forms a sort of arch with slanting sides (fig. 471), and since both inner and outer rods are, respectively, in lateral juxtaposition, the double series of inclined columns forms a tunnel (fig. 470) along the whole extent of the basilar membrane, which in the natural condition is filled with endolymph.

On the inner side of the inner rods is a row of epithelial cells—*inner hair-cells*—which are surmounted by a brush of fine, short, stiff hairlets, and external to the outer rods are three or four successive rows of similar but more elongated cells—*outer hair-cells*—which are inclined in a direction more or less parallel with that of the corresponding series of rods. The hairlets of these outer hair-cells project through rings (fig. 470, *m, n, o*), which surround the tops of the cells, and which are bounded by minute, fiddle-shaped cuticular structures—the so-called *phalanges*—connected both to one another and to the heads of the outer rods. A *reticular lamina* (fig. 470, *l.r.*) is thus formed which covers this part of the organ of Corti, like a wire net.

On either side of the two sets of hair-cells the epithelium, becoming gradually shorter, passes continuously into the simple layer of cubical cells which is found both in the spiral groove and also covering the outermost part of the basilar membrane.

The whole organ is, in addition to the reticular lamina, covered by a comparatively thick, fibrillated, and, to all appearance, highly elastic membrane—the *tectorial membrane* (fig. 469, *M.t.*)—which is attached by one edge to the upper surface of the limbus, falls over the crest of the latter and rests by the other edge and by the adjoining part of its under surface on the rods of Corti and the hair-cells, converting in this way the spiral groove into a canal. It will be necessary to describe more minutely these several parts of the organ of Corti.

**Rods of Corti.**—The inner and outer rods of Corti differ considerably from one another in size and shape, although agreeing, for the most part, as regards the details of their structure. Each inner rod may be best compared in shape to a human ulna, the upper end of the rod being pretty accurately represented by the head of that bone, the olecranon and coronoid processes, as well as the concave articular surface between, being readily recognisable. The outer rods, on the other hand, somewhat resemble in shape a swan's head and neck; the rounded part, which represents the back of the head, fitting into, and being connected with, the concave surface on the head of the corresponding inner rod (or rather of two or three inner rods, for the latter are smaller and more numerous than the outer ones), while the part which represents the bill projects outwards and becomes connected with the phalanges of the lamina reticularis, aiding to form the first series of rings for the hair-cells. Both inner and outer rods are more slender about the middle of their length and expand again below, so as to rest upon the basilar membrane by a somewhat widened foot. Both are distinctly striated throughout their length (fig. 474), and the striation or fibrillation, as is particularly well seen in the outer rods, passes, at the point of attach-

ment of the feet, continuously into that of the basilar membrane, to which they are thus intimately connected (fig. 470). Occupying most of the head of the outer rod is an oval part free from fibres, and staining with carmine more readily than the rest: this appears to represent the nucleus of an epithelial cell from which the rod was originally developed. A similar, but smaller nucleus is sometimes, but not always, to be seen in the head of the inner rod, at a place corresponding with the part that represents the root of the coronoid process; and the substance of the rod presents in its neighbourhood a somewhat granular protoplasmic appearance, as if there were here the remains of an original epithelial cell (fig. 474). But there is another trace of cell-formation always to be found in connection with both inner and outer rods, in shape of a little mass of protoplasm, enclosing a rounded nucleus, which occurs near the base of the rod and fills up the angle which it makes with the plane of the basilar membrane (fig. 471). Sometimes these masses of protoplasm extend along the last-named membrane until they come into contact, and then the floor of the arch of Corti is covered by them.

As before mentioned, the inner rods are more numerous than the outer,\* they are moreover more closely set so as to touch one another along their whole length, whereas the outer rods are only in contact laterally by their heads; finally the outer rods are in all parts longer than the inner, and in the upper turns of the cochlea considerably so (Winiwarter, Urban Pritchard). How the two sets of rods are jointed together at their heads is not very clear; it is certain that but very little movement can be permitted, if any; for the basilar membrane to which they are securely fixed below is stiff and seemingly inelastic, and the heads of adjacent rods are in close juxtaposition laterally. It is not improbable that the service which the rods and the other cuticular structures here serve, is to keep the parts which more immediately minister to the sense of hearing in a state of sufficient tension to be readily acted on by vibrations.

**Hair-cells.**—The inner hair-cells are closely applied against the inner side (that turned towards the limbus) of two or three of the corresponding rods, the cells being considerably larger in diameter than the rods. They are very like somewhat short, columnar epithelium, and are prolonged below into a process, or it may be more than one, which, according to Waldeyer, is directly connected to one of the nerve fibres which turn up through the lamina spiralis just below these cells. Under them, and extending also below the gradually decreasing columnar epithelium, is an ill-characterised layer of protoplasmic cells with large round nuclei, amongst which fine nerve-fibres are said to run in a radial direction. Uniting the upper ends of the columnar cells internal to the rods, is a considerable amount of intercellular cuticular tissue, and this also forms around the top of each inner hair-cell a sort of ring, which is connected with slight projections on the flattened heads of the inner rods, and appears to represent the lamina reticularis here.

The outer hair-cells are peculiar in shape. They are cylindrical at the upper end, where they fit into the rings of the lamina reticularis and bear the hairlets, but lower down are ribbon-shaped, being flattened from within out, so that, when seen in profile, they look

\* According to Waldeyer there are altogether in the human cochlea about 6000 of the inner rods and 4500 of the outer ones.

narrow (as in fig. 474), but when seen from above each cell appears nearly uniform in size throughout (fig. 475). At the lower end the cells seem to end for the most part with a rounded extremity (fig. 475, *b*) slightly bulged to one side, whilst from the other side a process (*p*) is prolonged which continues the oblique direction of the cell parallel to the direction of the outer rod, and is fixed below to the basilar membrane. (These processes were broken away in the specimen from which fig. 474 was taken.) The nucleus of the cell may be either in the upper end, in the middle, or in the rounded projection at the lower end. It is possible that there may occasionally be two nuclei in one cell, one at the upper and the other at the lower extremity, but such is by no means so frequently the case as is sometimes described.

Fig. 474.

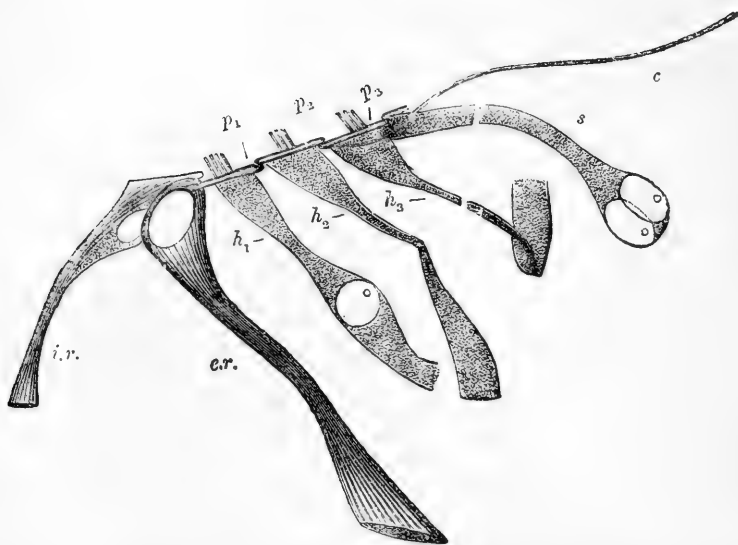


Fig. 474.—PROFILE VIEW OF INNER AND OUTER ROD IN CONNECTION WITH THREE HAIR-CELLS, AND PART OF LAMINA RETICULARIS (FROM THE GUINEA-PIG). BICHROMATE OF POTASH PREPARATION. VERY HIGHLY MAGNIFIED.

*i.r.*, inner rod; *o.r.*, outer rod; *h<sub>1</sub>*, *h<sub>2</sub>*, *h<sub>3</sub>*, hair-cells of first, second, and third rows respectively. They appear, especially the second and third, narrow in the middle, the thin edge of the riband being seen, but below have become accidentally twisted so that the flattened side is brought into view. A nucleus is visible in *h<sub>1</sub>*, but none is seen in *h<sub>2</sub>*, *h<sub>3</sub>*, probably owing to its being contained in the part of the cell the edge of which is turned towards the observer. The lower ends of all three, together with their basilar processes, have become broken off in the preparation of the specimen; *s*, one of the succeeding epithelial cells; *c*, cuticular thread attached to lamina reticularis; *p*, phalangeal process of outer rod; *p<sub>1</sub>*, *p<sub>2</sub>*, *p<sub>3</sub>*, phalanges of lamina reticularis seen in section.

In most animals there are three series of outer hair-cells, and a corresponding number of rings and phalanges in the lamina reticularis, but in man there are four series (fig. 469, *h*), and the lamina is correspondingly larger. Outside the hair-bearing cells the columnar cells are much elongated and obliquely disposed (fig. 474, *s*), but they become more and



more shortened and acquire a more vertical direction, gradually passing into the simple, short columnar or cubical epithelium on the outer part of the basilar membrane. Between all these cells, as with those internal to the inner hair-cells, is a marked amount of cuticular deposit which is continuous with the outer end of the lamina reticularis (fig. 473, *p*), and may be looked upon as prolonging this. Moreover, attached here and there to the phalanges of the lamina, processes or threads of cuticular substance may often be seen hanging downwards between the hair-cells (fig. 470 and fig. 474, *c*). These probably belong to certain cells which lie below the hair-cells and in proximity to or resting upon the basilar membrane. But the exact character of the cells in this situation and their relation to the hair-cells, have hitherto baffled observation. In the guinea-pig these underlying cells appear grouped, for the most part, into an irregular protoplasmic mass in which the rounded ends of the hair-cells lie embedded, and from which curved, stiff-looking processes pass in different directions forming a sort of supporting framework. The successive series of outer hair-cells are not in contact with one another (although the cells of each series are so, laterally), but there is a distinct interval between them filled, apparently, only by endolymph, which also occupies the meshes of the sustentacular framework just mentioned. The whole region has the appearance of being kept in a state of tension by means of stiff cuticular structures, which serve to unite and at the same time to keep apart, the reticular lamina above, and the basilar membrane below.

Considerable differences occur in the compactness with which the elements in the outer hair-cell region are arranged both in different animals and in different parts of the cochlea of the same animal. It is in the upper turns of the cochlea that the arrangement which has just been described obtains, and it may be best seen in the cochlea of the guinea-pig, which, indeed, for various reasons offers better facilities for observation both on this and other points, than that of any other animal we have examined.

One or two peculiarities are observable in the guinea-pig's cochlea, but they do not materially complicate the observation. For instance, the outer hair-cell region is developed into an arching projection, the external part of the arch being formed by large flattened cells, and passing abruptly into the low-lying cubical epithelium of the outer part of the basilar membrane. This arched projection is best seen in the upper turns; and it may further be noticed, that in the uppermost turn the flattened epithelial cells above-mentioned, possess the highly-interesting peculiarity of containing large fat droplets so as to cause them almost to appear like young fat-cells: the meaning of this development of fat is entirely unknown.

The **tectorial membrane** is the last special structure which remains

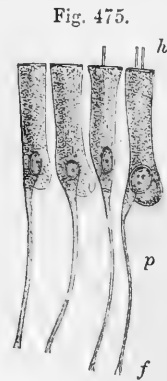


Fig. 475.—FOUR OUTER HAIR-CELLS IN CONNECTION, WITH THEIR BASILAR PROCESSES. FROM THE GUINEA-PIG. HIGHLY MAGNIFIED.

The cells belong to the same series and are viewed flat. *h*, one or two hair-lets which have remained attached; *b*, bulged lower end of cell; *p*, basilar process, protoplasmic above but becoming cuticular below and slightly expanded at the extremity *f*, which is broken away from the basilar membrane.

to be described in connection with the organ of Corti. It arises, as before stated, on the limbus, not far from the line of origin of Reissner's membrane, but the extent to which it covers the limbus, varies in different animals. It overlies the projecting teeth at the edge of the limbus, and also the epithelium between: all this part of the membrane is thin and delicate, imperceptibly shading off towards the inner edge of attachment. As the membrane projects over the crest of the limbus, it swells out below into a pad-like projection which, as before stated, covers in and partly fills up the spiral groove, and rests below upon the rods of Corti and contiguous structures. Towards its external edge the membrane again thins out, and overlies the outer hair-cell region as a delicate film presenting a somewhat reticular appearance, as if impressed by or moulded on the subjacent structures. The thickened part of the membrane is distinctly fibrous in appearance (the fibrillation extending from within, out), and after immersion in weak solutions of chromic acid, or bichromate of potash, it appears to possess considerable toughness and elasticity. Waldeyer states, however, that in the perfectly fresh condition it is soft and pulpy, and he considers that it may serve as a damper to prevent any too violent vibrations of the fluid which is in immediate contact with the hair-cells. It must be remembered that from its position the hairlets borne by the latter must necessarily be in contact with the under surface of this membrane. About its origin nothing certain is known, but it appears to be formed as a cuticular deposit or secretion from the epithelial cells, upon which, even at a comparatively early stage of development, it may be seen to lie.

**Vessels and nerves of the cochlea.**—The *cochlear branches of the internal auditory artery*, twelve or fourteen in number, arising at the bottom of the internal auditory meatus, traverse the many small canals in the modiolus and bony lamina spiralis, and form in the latter a capillary plexus that joins at intervals the *vas spirale*, previously mentioned. From this plexus offsets are distributed in the form of a fine network on the periosteum, but the vessels do not anastomose across the *membrana basilaris*.

The *veins of the cochlea* issue from the grooves of the cochlear axis and, joining the veins of the vestibule and semicircular canals at the base of the modiolus, pour their contents into the superior petrosal sinus.

The *cochlear branch of the auditory nerve* is shorter, flatter, and broader than any of the other nerves of the internal ear, and perforates the bone by groups of minute foramina at the bottom of the internal meatus, below the opening of the Fallopian aqueduct. These groups are arranged in a shallow spiral furrow (*tractus spiralis foraminulentus*) in the centre of the base of the cochlea; and they lead into small bony canals, which follow first the direction of the axis of the cochlea, through the modiolus, and then radiate outwards, between the plates of the bony lamina spiralis. In the centre of the spiral tract is a larger foramen which leads to the *canalis centralis modioli*. Through this foramen and canal the filaments for the last half-turn of the lamina spiralis are conducted; whilst the first two turns are supplied by filaments which occupy the smaller foramina and bent canals. In the bone, the nerves have dark outlines, and near the root of the spiral lamina they pass outwards through a spirally wound ganglionic cord, the so-called *ganglion spirale*, situated in the special bony canal, *canalis*

Fig. 476.

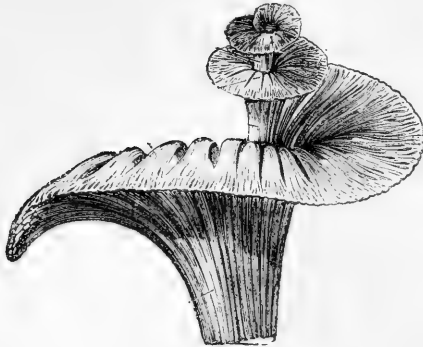

Fig. 476.—GENERAL VIEW OF THE MODE OF DISTRIBUTION OF THE COCHLEAR NERVE, ALL THE OTHER PARTS HAVING BEEN REMOVED.

*spiralis modioli*, already mentioned. Here each nerve fibre most probably has a ganglion-cell interpolated in its course. From the outer side of the ganglion, the fibres, still possessing the dark outline, pass

Fig. 477.

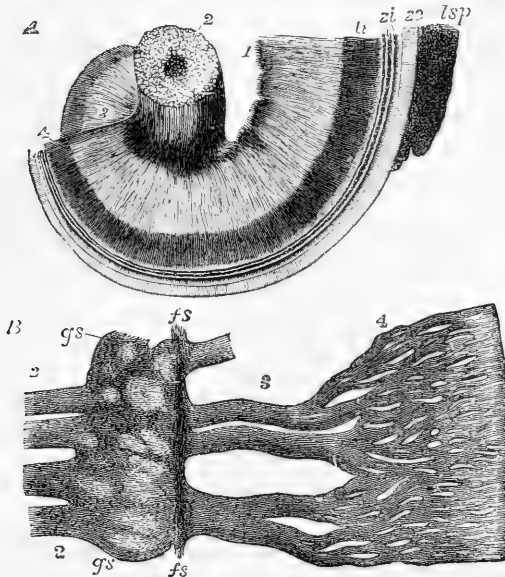


Fig. 477.—DISTRIBUTION OF THE COCHLEAR NERVES IN THE LAMINA SPIRALIS (after Henle).

A, part of the modioli and spiral lamina, viewed from the base, showing the cochlear nerves forming a network ; 1, filaments of the nerve issuing from the tractus spiralis foraminulosus ; 2, branches of the nerve entering by the central canal of the modioli ; 3, wide plexus in the bony lamina spiralis ; 4, close plexus at its border. B, part of the nerves extracted and more highly magnified ; 2, twigs of the nerve from the modioli close to the lamina spiralis ossea ; *gs*, spiral ganglion ; *fs*, nerve-fibres running spirally along the outer part of the ganglion swelling ; 3, wide plexus ; 4, close plexus of nerve-fibres as in A.

onwards with a plexiform arrangement, at first in more or less distinct but anastomosing cords (fig. 477, B, 3), contained in distinct canals in the bony lamina, but afterwards spreading out into an almost continuous stratum of intermingling fibres, to be again gathered up, near the edge of the osseous lamina, into conical bundles which turn abruptly upwards, and passing through the elongated apertures previously described, in the membranous stratum covering the bone, enter amongst the epithelial structures which form the organ of Corti, in the region of the inner hair-cells.

Little is known positively with regard to the actual mode of ending of the nerves amongst these structures. As they pass through the apertures in the membrane, they lose their medullary sheath and dark borders, and are continued as simple axis-cylinders. Their further course is still a matter of doubt. Some of them are stated by Waldeyer to pass directly into the lower ends of the inner hair-cells, and others to pass outwards between the rods of Corti, stretching across the tunnel which these enclose, eventually ending in the outer hair-cells, but these statements, although not improbable, yet require confirmation. It is possible that the real termination of the nerves is to be found not in the hair-cells themselves but in the subjacent irregular protoplasmic cells, which both in the character of their nucleus, and in other particulars are not very unlike nerve-cells.

The following numbers show the average dimensions of various parts of the human cochlea. They are copied from Waldeyer (article "Cochlea" in Stricker's Handbook), and represent the size in micromillimeters.\*

|                                                           |         |
|-----------------------------------------------------------|---------|
| Cochlear canal, breadth, 1st turn . . . . .               | 800     |
| "    "    "    2nd turn . . . . .                         | 700     |
| "    "    "    extreme height . . . . .                   | 500     |
| Reissner's membrane, breadth, 1st turn . . . . .          | 900     |
| "    "    "    2nd turn . . . . .                         | 700     |
| Limbus laminae spiralis, breadth, 1st turn . . . . .      | 300     |
| "    "    "    2nd turn . . . . .                         | 200—250 |
| Rods of Corti, space between attachment of feet . . . . . | 66—70   |
| "    "    height of arch . . . . .                        | 12      |
| "    "    length of inner rods . . . . .                  | 50      |
| "    "    length of outer rods . . . . .                  | 60—66   |
| Hair-cells, length of inner . . . . .                     | 18      |
| "    "    length of outer, with basilar process . . . . . | 48      |
| "    "    length of hairlets . . . . .                    | 4       |
| Membrana tectoria, extreme breadth . . . . .              | 200—230 |
| "    "    extreme thickness . . . . .                     | 50      |

## THE NOSE.

The nose is the special organ of the sense of smell. It has also other functions to fulfil;—for, communicating freely with the cavities of the mouth and lungs, it is concerned in respiration, voice, and taste; and by means of muscles on its exterior, which are closely connected with the muscles of the face, it assists more or less in expression.

This organ consists of, first, the anterior prominent part, composed of bone and cartilages, with muscles already described, which slightly move the cartilages, and two orifices, *anterior nares*, opening down-

\* A micromillimeter is the  $\frac{1}{1000}$ th part of a millimeter, or the  $\frac{1}{25000}$ th part of an inch, and is generally represented by the Greek letter  $\mu$ .

wards; and, secondly, of the two nasal fossæ, in which the olfactory nerves are expanded. The nasal fossæ are separated from each other by a partition, *septum nasi*, formed of bone and cartilage: they communicate with hollows in the neighbouring bones (ethmoid, sphenoid, frontal, and superior maxillary); and they open backwards into the pharynx through the *posterior nares*. The skin of the nose is studded, particularly in the grooves of the alæ or outer walls of the nostrils, with numerous small openings, which lead to sebaceous follicles. Within the margin of the nostrils there is a number of short, stiff, and slightly curved hairs—*vibrissæ*—which grow from the inner surface of the alæ and *septum nasi*.

## CARTILAGES OF THE NOSE.

These are the chief support of the outer part of the organ. They occupy the triangular opening seen in front of the nasal cavity in the dried skull, and assist in forming the septum between the nasal fossæ. There are usually reckoned two large and three small cartilages on each side, and one central piece or cartilage of the septum.

Fig. 478.

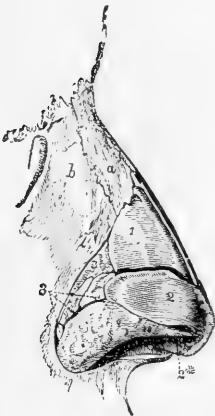


Fig. 478.—LATERAL VIEW OF THE CARTILAGES OF THE NOSE (Arnold).  $\frac{3}{4}$

*a*, right nasal bone; *b*, nasal process of the superior maxillary bone; 1, upper lateral cartilage or wing-like expansion of the septal cartilage; 2, lower lateral cartilage (outer part); 2\*, inner part of the same; 3, sesamoid cartilages.

Fig. 479.

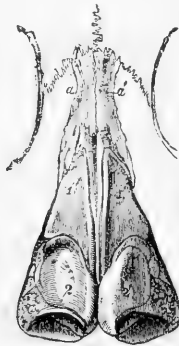

Fig. 479.—FRONT VIEW OF THE CARTILAGES OF THE NOSE (Arnold).  $\frac{3}{4}$

*a*, *a'*, nasal bones: 1, 1', upper lateral cartilages or wing-like expansions of the septal cartilage; 2, 2', lower lateral cartilages.

Fig. 480.

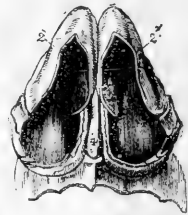


Fig. 480.—VIEW OF THE CARTILAGES OF THE NOSE FROM BELOW (Arnold).  $\frac{3}{4}$

2, 2', outer part of the lower lateral cartilages; 2\*, 2\*, inner part of the same; 4, lower edge of the cartilage of the septum.

The *upper lateral cartilages* (*cartilagine laterales nasi*) (figs. 478 and 479, 1) are situated in the upper part of the projecting portion of the nose, immediately below the free margin of the nasal bones. Each is flattened and triangular in shape, and presents one surface outwards, and the other inwards towards the nasal cavity. The anterior

margin, thicker than the posterior one, meets the lateral cartilage of the opposite side above, but is closely united with the edge of the cartilage of the septum below; so closely indeed, that by some, as Henle, the upper lateral is regarded as reflected wings of the median cartilage. The inferior margin is connected by fibrous membrane with the lower lateral cartilage; and the posterior edge is inserted into the ascending process of the upper maxilla and the free margin of the nasal bone.

The *lower lateral cartilages* (cartilaginee alarum nasi) (fig. 478, 2, 2') are thinner than the preceding, below which they are placed, and are chiefly characterised by their peculiar curved form. Each consists of an elongated plate, so bent upon itself as to pass in front and on each side of the nostril to which it belongs, and by this arrangement serve to keep it open. The outer portion is somewhat oval and flattened, or irregularly convex externally. Behind, it is attached to the margin of the ascending process of the upper maxilla by tough fibrous membrane, in which are two or three cartilaginous nodules (*cartilaj. minores vel sesamoideæ*) (fig. 478, 3); above, it is fixed, also by fibrous membrane, to the upper lateral cartilage, and to the lower and fore part of the cartilage of the septum. Towards the middle line it is curved backwards (fig. 480), bounding a deep mesial groove, at the bottom of which it meets with its fellow of the opposite side, and continues to pass backwards, forming a small part of the *columna nasi*, below the level of the cartilage of the septum. This inner part of the cartilage of the ala is thick and narrow, curls outwards, and ends in a free rounded margin (2\*), which projects outwards towards the nostril. The lower and most prominent portion of the ala of the nose, like the lobule of the ear, is formed of thickened skin with subjacent tissue, and is unsupported by cartilage.

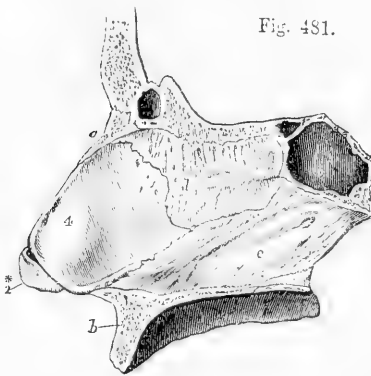


Fig. 481.—OSSEOUS AND CARTILAGINOUS SEPTUM OF THE NOSE, SEEN FROM THE LEFT SIDE (Arnold).  $\frac{2}{3}$

*a*, right nasal bone; *b*, superior maxillary bone; *c*, sphenoidal sinus; *d*, perpendicular plate of the ethmoid bone; *e*, vomer; 2\*, inner part of the right lower lateral cartilage; 4, cartilage of the septum.

latter. The posterior margin is fixed to the lower and fore part of the central plate of the ethmoid bone (*e*); and the lower margin is received into the groove of the vomer (*v*), as well as into the median ridge between the superior maxillæ.

This cartilage is the persistent anterior extremity of the primordial cranium. In young subjects it is prolonged back to the body of the pre-sphenoid bone; and in many adults an irregular thin band remains between the vomer and the central plate of the ethmoid.

#### NASAL FOSSÆ.

The nasal fossæ, and the various openings into them, with the posterior nares, have been previously described as they exist in the skeleton, and the greater part of that description is also applicable generally to the nose in a recent state; but it is proper to mention certain differences in the form and dimension of parts, which depend on the arrangement of the lining membrane, viz.—

Throughout the whole of the nasal fossæ it is to be observed that—

Firstly, owing to the thickness of the membrane in question, (which not only lines the walls of the fossæ, but covers the spongy bones on both sides,) the nasal cavity is much narrower in the recent state. Secondly, in consequence of the prolongations of membrane on their free margins, the turbinate bones, and more particularly the lower pair, appear in the recent state to be both more prominent, and longer in the direction, from before backwards, than in the dried skull. Thirdly, by the arrangement of the mucous membrane around and over the orifices which open into the nasal fossæ, some of the foramina in the bones are narrowed, and others completely closed.

Fig. 482.

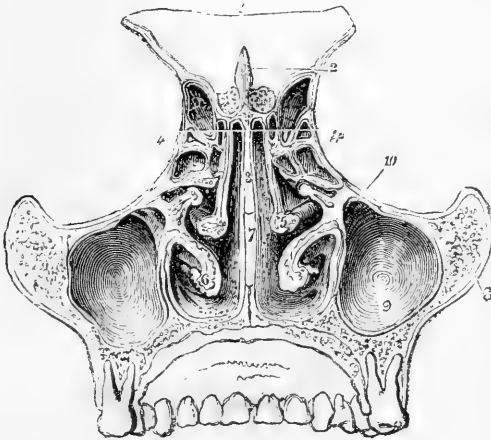


Fig. 482.—TRANSVERSE VERTICAL SECTION OF THE NASAL FOSSÆ SEEN FROM BEHIND (Arnold).  $\frac{3}{4}$

1, part of the frontal bone; 2, crista galli; 3, perpendicular plate of the ethmoid; between 4 and 4, the ethmoid cells; 5, right middle spongy bone; 6, left lower spongy bone; 7, vomer; 8, malar bone; 9, maxillary sinus; 10, its opening into the middle meatus.

In the individual parts of the nasal fossæ the following particulars are to be noticed.

In the *upper meatus*, the small orifice which leads into the posterior ethmoidal cells is lined by a prolongation of the thin mucous membrane which continues

into those cavities; but the spheno-palatine foramen is covered over by the Schneiderian membrane, so that no such opening exists in the recent nasal fossa.

In the *middle meatus*, the aperture of the infundibulum is nearly hidden by an overhanging fold of membrane; it leads directly into the anterior ethmoidal cells, and through them into the frontal sinus. Below and behind this, the passage into the antrum of Highmore is surrounded by a circular fold of the pituitary membrane (sometimes prominent and even slightly valvular), which leaves a circular aperture much smaller than the foramen in the bony meatus.

In the *lower meatus* the inferior orifice of the nasal duct is defended by one or two folds of membrane; and when there are two, the folds are often adapted so accurately together as to prevent even air from passing back from the cavity of the nose to the lachrymal sac.

In the *roof* the apertures in the cribriform plate of the ethmoid bone are closed by the membrane, but the openings into the sphenoidal sinuses receive a prolongation from it.

In the *floor* the incisor foramen is in the recent state generally closed. Sometimes, however, a narrow funnel-shaped tube of the mucous membrane descends for a short distance into the canal, but is closed before it reaches the roof of the palate. Vesalius, Stenson, and Santorini, believed that this tube of membrane opened generally into the roof of the mouth by a small aperture close behind the interval between the central incisor teeth. Haller, Scarpa, and more recently, Jacobson, find that in man it is usually closed, and often difficult of detection. (See Cuvier's Report on a paper by Jacobson, "Annales du Museum d'Hist. Naturelle;" Paris, 1811; vol. xviii. p. 412.)

#### MUCOUS MEMBRANE.

The pituitary or Schneiderian membrane, which lines the cavities of the nose, is a highly vascular mucous membrane, inseparably united,

Fig. 483.

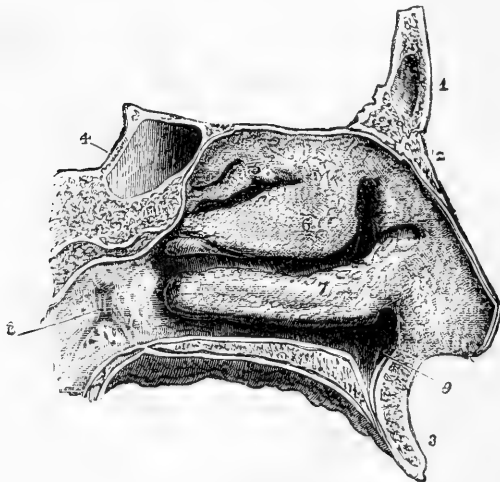


Fig. 483.—OUTER WALL OF THE LEFT NASAL FOSSA, COVERED BY THE PITUITARY MEMBRANE (Arnold).  $\frac{3}{4}$

1, frontal bone; 2, left nasal bone; 3, superior maxillary; 4, body of the sphenoid with the sphenoidal sinus; 5, projection of the membrane covering the upper spongy bone; 6, that of the middle; 7, that of the lower; the upper, middle, and lower meatuses are seen below the corresponding spongy bones; 8, opening of the Eustachian tube; 9, depression of the lining membrane of the nose in the anterior palatine canal.



like that investing the cavity of the tympanum, with the periosteum and perichondrium, over which it lies. It is continuous with the skin through the nostrils; with the mucous membrane of the pharynx through the posterior apertures of the nasal fossæ; with the conjunctiva through the nasal duct and lachrymal canaliculi; and with the lining membrane of the several sinuses which communicate with the nasal fossæ. The pituitary membrane, however, varies much in thickness, vascularity, and general appearance in these different parts. It is thickest and most vascular over the turbinate bones (particularly the inferior), from the most dependent parts of which it forms projections in front and behind, thereby increasing the surface to some extent. On the septum nasi the pituitary membrane is also very thick and spongy; but in the intervals between the turbinate bones, and over the floor of the nasal fossæ, it is considerably thinner. In the maxillary, frontal, and sphenoidal sinuses, and in the ethmoidal cells, the mucous lining membrane, being very thin and pale, contrasts strongly with that which occupies the nasal fossæ.

In respect of the characters of the mucous membrane, three regions of the nasal fossæ may be distinguished. Thus, the region of the external nostrils, including all the part which is roofed by the nasal cartilages, is lined with stratified squamous epithelium; and the remainder is divisible into two parts, viz., the olfactory region in which the epithelium is non-ciliated and columnar, and the respiratory region in which, as also in the sinuses, it is ciliated and columnar. The membrane in the respiratory part, consisting of the inferior turbinated and all the lower portions of the fossæ, is studded with numerous racemose mucous glands, which open by orifices apparent on the surface. These are most numerous about the middle and hinder parts of the nasal fossæ, and are largest at the back of the septum near the floor of the nasal cavity. They are much smaller and less numerous in the membrane lining the several cavities which communicate with the nasal fossæ.

**Olfactory mucous membrane.**—The olfactory region or that in which the olfactory nerve is distributed, includes the upper and middle turbinated parts of the fossæ, and the upper portion of the septum. It is extremely vascular, a close plexus of large capillary vessels being found under the lining membrane throughout its whole extent. Its mucous membrane is thicker and more delicate in consistence than that of the ciliated region, being soft and pulpy. It has a distinct yellow colour in man; brown in some animals. The glands of this region are numerous, but are of a more simple structure than those in the lower part of the fossæ; amongst them, however, some ordinary racemose glands are occasionally to be found. The columnar cells on its

Fig. 484.

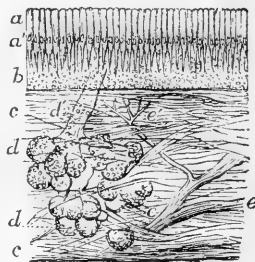


Fig. 484.—VERTICAL SECTION OF A SMALL PORTION OF THE MEMBRANE OF THE NOSE FROM THE OLFACTORY REGION (Ecker). 50 DIAMETERS.

*a*, coloured part of the epithelium; *a'*, nuclei; *b*, deeper part containing the olfactory cells; *c*, connective tissue of the mucous membrane; *d*, one of the glands; *d'*, its duct; *e*, twig of the olfactory nerve; *e'* small twig passing towards the surface.

surface are prolonged at their deep extremities into a process generally somewhat thickened towards its deeper end, which usually includes a number of fatty granules; and from this thickened part branches proceed, which are stated by Exner and Martin to communicate with those of neighbouring cells, so as to form a communicating network throughout the extent of the membrane, underneath the epithelium. Between and amongst these branching central ends of the columnar cells there are a large number of peculiar spindle-shaped cells (fig. 485, *b*), each consisting of a large, clear nucleus surrounded by a relatively small amount of granular protoplasm. From each cell proceeds a superficial and a deep process. The superficial process (*c*) is a cylindrical or slightly tapering thread passing directly to the surface, and terminating abruptly

Fig. 485.

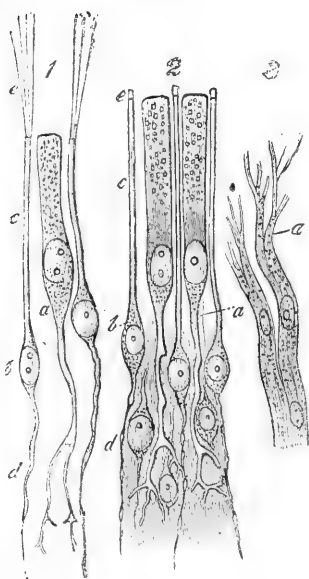


Fig. 485.—CELLS AND TERMINAL NERVE-FIBRES OF THE OLFACTORY REGION (from Frey after Schultze). HIGHLY MAGNIFIED.

1, from the frog; 2, from man; *a*, epithelial cell, extending deeply into a ramified process; *b*, olfactory cells; *c*, their peripheral rods; *e*, their extremities, seen in 1 to be prolonged into fine hairs; *d*, their central filaments; 3, olfactory nerve-fibres from the dog; *a*, the division into fine fibrillae.

at the same level as the epithelial cells between which it lies: the deep process (*d*) is more slender, and passes vertically inwards. This last frequently presents a beaded appearance similar to that observed in fine nerve-filaments, and considered to be of a similar accidental origin. These cells were termed by Max Schultze, their discoverer, *olfactory cells*, to distinguish them from the columnar epithelium cells above described, than which they are much more numerous, and which they entirely surround with their fine rod-like peripheral processes. It is probable that their fine varicose central processes are directly continuous with the fibrils of the olfactory nerve, but the continuity has never been actually observed. The nucleated bodies of the olfactory cells are several rows deep, and form a layer of considerable thickness beneath the columnar cells.

The superficial process of the olfactory cell was observed by Schultze to be surmounted by a short, stiff projection (fig. 485, *2e*), and has been so described by others; but it is now agreed that this appearance results from the coagulation of albuminous matter escaped from the interior of the process. Long and fine hair-like processes do, however, exist on the olfactory membranes of amphibia, reptiles, and birds (fig. 485, *1c*), but they have not been observed in mammals.

A doubt has been thrown by Exner upon the definiteness of the distinction between the epithelial and the olfactory cells of this region: he states that every transition may

be met with between the two, and that the central processes of both end in a common network, to which, moreover, the nerve fibrils are distributed.

The subject has since been again carefully investigated by Martin, who upholds the correctness of Max Schultze's views.\*

Fig. 486.

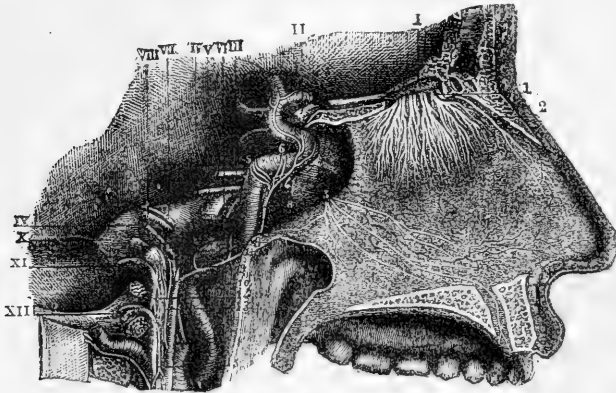


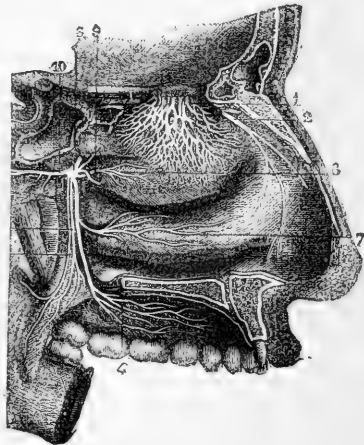
Fig. 486.—NERVES OF THE SEPTUM NASI, SEEN FROM THE RIGHT SIDE (from Sappey, after Hirschfeld and Leveillé).  $\frac{2}{3}$

I, the olfactory bulb; 1, the olfactory nerves passing through the foramina of the cribriform plate, and descending to be distributed on the septum; 2, the internal or septal twig of the nasal branch of the ophthalmic nerve; 3, naso-palatine nerves.

Fig. 487.—NERVES OF THE OUTER WALL OF THE NASAL FOSSE (from Sappey, after Hirschfeld and Leveillé).  $\frac{2}{3}$

1, network of the branches of the olfactory nerve, descending upon the region of the superior and middle turbinated bones; 2, external twig of the ethmoidal branch of the nasal nerve; 3, sphenopalatine ganglion; 4, ramification of the anterior palatine nerves; 5, posterior, and 6, middle divisions of the palatine nerves; 7, branch to the region of the inferior turbinated bone; 8, branch to the region of the superior and middle turbinated bones; 9, naso-palatine branch to the septum cut short.

Fig. 487.



**Olfactory Nerve.**—The filaments of this nerve, lodged at first in grooves on the surface of the bone, enter obliquely the substance of the Schneiderian membrane, and pass to their distribution between its mucous and fibrous layers. The nerves of the septum (fig. 486) are rather larger than those of the outer wall of the nasal fossæ; they extend over the upper third of the septum, and as they descend become very indistinct. The nerves of the outer wall are divided into two groups—the posterior

\* Exner, Wiener Sitzungsberichte, 1870 and 1872; H. Newell Martin, "Journal of Anat. and Physiol.," vol. viii.

branches being distributed over the surface of the upper spongy bone, and the anterior branches descending over the plain surface of the ethmoid and the middle spongy bone.

The nerves as they descend, ramify and unite in a plexiform manner, and the filaments join in brush-like and flattened tufts, which, spreading out laterally and communicating freely with similar offsets on each side, form a fine network, with elongated and narrow intervals between the points of junction.

In their nature the olfactory filaments differ much from the ordinary dark-bordered fibres of the cerebral and spinal nerves: they possess no medullary sheath, are pale, and finely granular in aspect, firmly adherent one to another, and have oval corpuscles on their surface (fig. 488).

The greater part of the mucous membrane of the nasal fossæ is provided also with nerves of common sensibility, derived from branches of the fifth pair: the distribution of these has already been described.

Fig. 488.

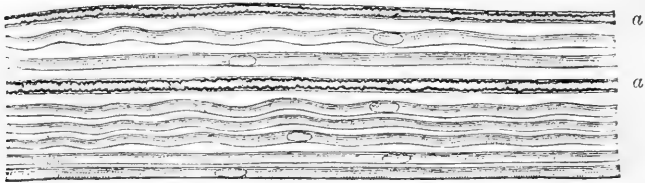


Fig. 488.—NERVE-FIBRES FROM THE OLFACTORY MUCOUS MEMBRANE (Max Schultze).  
Magnified between 400 and 500 diameters.

From a branch of the olfactory nerve of the sheep; at *a, a*, two dark bordered or medullated fibres, from the fifth pair, associated with the pale olfactory fibres.

## EMBRYOLOGY;

## OR, DEVELOPMENT OF THE FÆTUS AND ITS ORGANS.

It is proposed to bring together in the present Section a short statement of the manner in which the parts of the body originate in the embryo, and acquire by development in the course of fetal life their complete form and structure. The collected facts bearing upon this subject constitute the department of anatomy known as Embryology, Embryological or Fœtal Anatomy, or Fœtal development,—a knowledge of which is not only most interesting in itself, but is also of great importance for the elucidation of adult human anatomy and the whole science of Organic Morphology.

Although much attention has been given to the structure of the human fœtus at different periods of its growth, yet the materials are still wanting for a detailed history of its early development; accordingly it is necessary for further elucidation to have recourse to the information obtained by studying the process in animals. But this illustration from analogy is fully warranted by the general conformity in the plan of development which has been ascertained to prevail among the higher vertebrate animals, and by the agreement with this plan of the more important phenomena which it has been possible to observe in the human species. In what follows, therefore, while the main object will be to state the more important facts which have been ascertained as to the development of the human ovum and embryo, the history of the phenomena as they occur in birds and mammals will also be referred to in so far as it tends to throw light on human embryology.

1. THE OVUM: ITS MATURATION, FECUNDATION AND SEGMENTATION: FORMATION OF THE BLASTODERM.

**The mature ovarian ovum.**—The unfecundated ovarian ovum which is approaching maturity, and is about to be discharged from the Graafian follicle and pass into the Fallopian tube, is composed of the following parts, viz. :—1. The firm, almost homogeneous external *vitelline membrane*, which is termed *zona pellucida* in mammals; 2. The *yolk substance* or *vitellus*, a mass of soft or semifluid protoplasmic matter, involving numerous granules and oil globules, and containing embedded in it, near the surface; 3. The *germinal vesicle*, consisting of a spheroidal delicate enclosing membrane with protoplasmic fluid and fine granules within, and containing in its earlier states if not to the last; 4. The *germinal spot* or *macula*.

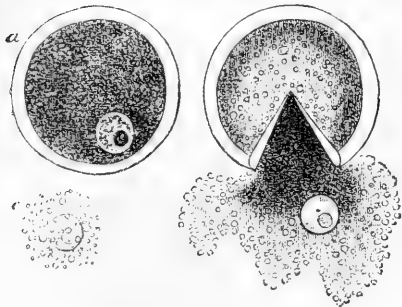
The ovarian ovum, therefore, may be regarded as a complete organised cell, in which the yolk forms the protoplasmic contents, the germinal vesicle the nucleus, and the macula the nucleolus.

**Distinction of the germ.**—In the ovum of the mammal the whole yolk-substance is so uniformly of the same appearance and structure throughout that, but for the presence of the germinal vesicle, little distinction can be perceived between one part and another; and, further,

the greater part of the yolk is immediately engaged in the first or preliminary changes which precede the occurrence of embryonic development. The whole yolk-mass, or its greater part, is therefore directly formative or germinal, or, as it has been said, the ovum is *holoblastic*.

But in birds and reptiles, in which the ova are comparatively large, the greater part of the yolk forming the yellow yolk substance, takes no immediate part in the first formative processes, and these are restricted to the small whitish flat disc, called the *cicatricula* in the fowl's egg, which is composed of fine granular protoplasm, occupies a determinate place on the surface of the larger yolk-mass, and, so long as the yolk remains in the ovary, has the germinal vesicle situated in its centre.

Fig. 489.

Fig. 489.—OVARIAN OVUM OF A MAMMIFER.  $\frac{200}{1}$ 

*a*, The entire ovum, viewed under pressure; the granular cells have been removed from the outer surface, the germinal vesicle is seen in the yolk substance within; *b*, the external coat or zona burst by increased pressure, the yolk protoplasm and the germinal vesicle having escaped from within; *c*, germinal vesicle more freed from the yolk substance. In all of them the macula is seen.

To the part thus distinguishable from the rest of the yolk the name of *germ* may be given; and it has also been styled the

primary or germinal or *formative yolk*, and the protoplasm or protoblast, while the remainder of the yolk-substance has been called the nutritive or *food yolk*, the secondary yolk or deutoplasm. The oviparous ovum has therefore been named *meroblastic*, or partially germinal.

It is not known whether in the mammals' ovum the whole yolk ought to be considered as purely germinal, or whether, as seems more probable, some nutritive yolk may not be combined intimately with the germinal substance; but even if so, it is obvious that the germinal bears a much larger proportion to the nutritive yolk than in the bird or reptile, and, as will appear more clearly hereafter, there is thus some foundation for the distinction between the holoblastic and the meroblastic forms of ova, although it may be that in different animals these forms pass insensibly into one another.

In both kinds of ova, however, whether holoblastic or meroblastic, the subsequent phenomena of development show that the spot where the organising process begins, occupies a determinate situation in the ovum, and that the first rudiments of the embryo arrange themselves in a determinate order round a central point in the germ.

There is, therefore, in the ova of birds and mammals, a part of the yolk which is more immediately germinal, and a central point of that germ from which development spreads, to which the name of *germinal pole* may be given. The centre of the germ is probably coincident with the place last occupied by the germinal vesicle.

**Disappearance of the germinal vesicle.**—The most marked change in the interior of the ovum which is known to accompany its maturation and escape from the ovary is the disappearance of the

germinal vesicle,—a phenomenon which occurs in all vertebrates, and in a large proportion of, but probably not all invertebrate animals. This change is independent of fecundation. The details of the process have not been traced in mammals, but from various observations in birds and batrachia, and more especially from the recent minute researches of Oellacher in fishes, it follows that the disappearance of the vesicle really depends on its extrusion from the substance of the yolk in which it was imbedded, and is attended with the bursting or breaking down of its delicate outer membrane; so that when the vesicle is thrust out on the surface of the yolk, and opened out, its fluid contents must be effused in the space intervening between the vitelline membrane and the surface of the yolk. The actual expulsion of the vesicle in the trout's ovum is attributed by Oellacher to the contractions of the yolk protoplasm, and the expulsion of the vesicle in this animal takes place previous to the rupture of its membrane and dispersion of its contents. (Archiv. f. Mikroskop. Anat. vol. viii. p. 24.)

Fig. 490.—MATURE OVARIAN OVUM OF THE  
GUINEA-PIG (from Bischoff.)  $\frac{350}{1}$

The zona pellucida is hidden by the adherent cells of the membrana granulosa, which have assumed a pediculated form next its surface. The finely granular yolk substance fills the cavity of the zona. The germinal vesicle has disappeared.

The time at which the disappearance takes place seems to be subject to some variation. Most frequently it is close upon the time of the escape of the ovum from the Graafian follicle; but sometimes it is several hours later, and in other instances it seems to occur previously; and, indeed, in many cases


preparatory changes in the position, form, and consistence of the vesicle have been observed while the ovum was still within the ovary.

As the mammiferous ovum leaves the ovary it has still adhering to its outer surface one or two layers of the cells belonging to that part of the tunica granulosa with which it was surrounded in the Graafian follicle. These cells assume towards the period of maturation more or less of a pediculated form (see fig. 490), but after one or two days they gradually fall away from the surface of the zona, and leave that membrane free in the Fallopian tube.

**Fecundation.**—Should the ovum not be fecundated it is carried down through the female passages by the ciliary action of the lining membrane, and is lost by absorption or removal. But if seminal matter is present in the tubes, and the ovum is subjected to its influence within a due time, so that fecundation is effected, there immediately follows the commencement of a series of changes in the yolk protoplasm, which result in the formation in a determinate situation of a stratum of organised cells constituting the laminar germ named the *blastoderm*, which is the seat of all subsequent processes of development in the ovum.

The encounter of the ovum with the seminal filaments or spermatozoa generally takes place in the upper part of the Fallopian tube or

Fig. 490.



oviduct, and it is now ascertained that the spermatozoa not only adhere in numbers to the external surface of the ovum, but actually penetrate through the zona, so as to come in contact with and possibly also combine with the substance of the yolk (see figs. 491, 492, and 493). We are, however, entirely ignorant of the nature of the operation of the spermatozoa upon the substance of the germ. The shrivelled remains of these particles are seen for days adherent to the ova, and even in the substance of the germ, and though doubtless they at last disappear, it has not been determined whether this is by combination of their substance with that of the germ or in what other way the mutual or reciprocal action of the male and female generative elements may take place.

The fact remains as one of the most remarkable in the whole range of biological phenomena, that by the contact of an inappreciable amount of the male product with the germinal material of the ovum, the latter passes from an apparently inert condition into one of genetic activity,

Fig. 491.

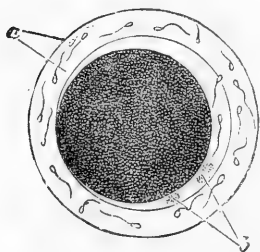


Fig. 491.—OVUM OF THE RABBIT FROM THE FALLOPIAN TUBE, TWELVE HOURS AFTER IMPREGNATION (from Bischoff). <sup>250</sup>

A few granular cells adhere to the outer surface of the zona, in which and in the zona itself spermatozoa are seen; *a*, zona; *b*, two hyaline globules within the cavity left by the shrinking of the yolk.

the ultimate result of which is the accomplishment of a series of the most complicated phenomena of organic formation and growth, giving rise to a new being, which, while it may be of either sex,

repeats in all respects the characters of the species, and may inherit in a greater or less degree the minutest peculiarities, whether structural or functional, of either or of both its parents.

There are two changes following impregnation which have been observed in the mammal's ovum, and which are deserving of notice, though their import is not yet known. One of these changes consists in a certain contraction or diminution in the size, and an increase in the apparent compactness or firmness of the mass of the yolk, so that a larger space than before, filled with clear fluid, comes to intervene between the yolk and the surrounding zona. The other change referred to is the appearance in this space of one, or most frequently two, and occasionally of three, clear or hyaline spherules, which are easily distinguished from the surrounding fluid by their peculiar highly refracting outline (Quatrefages, Ed. Van Beneden, Bischoff). These spherules are of variable size, but generally their diameter is from one-tenth to one-fifteenths of that of the mammal's ovum (fig. 491, *b*, and 492, *A*). They are perfectly hyaline and homogeneous and do not appear to possess any external envelope. They remain visible for some days during the early phases of yolk-segmentation, about to be described, and hence by some they have been named *segmentation globules*. Their source and destination, however, are entirely unknown.

**Segmentation of the yolk or germ.**—After the disappearance of the germinal vesicle the germinal part of the yolk constitutes for a time a non-nucleated mass of protoplasm; and if then subjected to the influence of fecundation it undergoes the change of segmentation, which results in the conversion of the germ or germinal part of the yolk into



a layer of organised cells. This new organised structure, the blastoderm of Pander, is the future seat of embryonic development.

A segmenting process of this kind is universal throughout animals as a prelude to the commencement of embryonic development; but it differs greatly in its extent, and somewhat also in its nature, according to the proportional relation of the directly germinal to the nutritive components of the yolk in different classes of animals. Thus in mammals, the process of cleavage appears to be complete, or to involve the whole mass of the yolk protoplasm, with which the germ is coextensive, at least in the first steps of the process; while in the bird's egg, which is pre-eminently *meroblastic*, the segmentation is restricted in the first instance to the disc of the cicatricula, and the great mass of the yolk substance takes no share in the change.

In intermediate forms of ova, as in amphibia and osseous fishes the segmenting division extends to a greater or less width over the yolk,

Fig. 492.

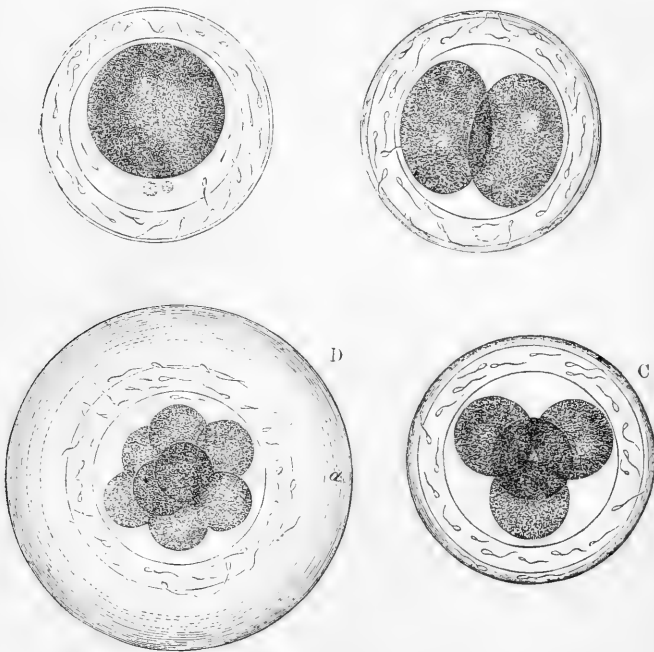


Fig. 492.—OVA OF THE RABBIT UNDERGOING SEGMENTATION IN THEIR DESCENT THROUGH THE FALLOPIAN TUBE. (From Bischoff.)  $\frac{200}{\mu}$

A, the ovum from the middle part of the tube twelve or fifteen hours after impregnation, the germinal vesicle has disappeared, the yolk is contracted, and two hyaline globules are seen in the cavity between it and the zona; rotation of the yolk took place in the direction of the arrows; B, ovum a little more advanced, the first segmentation has taken place, a clear globule or nucleus is seen in both the yolk spheres: spermatozoa adhere everywhere to the zona; C, an ovum four hours later than that shown in B, the second segmentation has taken place; D, ovum from the lower part of the tube in which the third stage of segmentation is completed, and eight yolk spheres are formed, the albuminous covering is increased in thickness: diameter of the whole,  $\frac{1}{100}$ th of an inch.

just in proportion to the respective limits of the germinal and nutritive parts of the yolk; but always affecting first the germinal part, and extending subsequently outwards from the germinal pole as a centre.

The process of segmentation has not been seen in the human subject, for the human ovum has not yet been detected in the progress of its descent through the Fallopian tubes; but the phenomena have been observed with care by Bischoff and others in a variety of mammiferous animals, and as no important differences have been found to occur among them, there is no reason to doubt the similarity of the process in man. The yolk cleavage sets in within a few hours of the entrance of the mammiferous ovum into the tube, and continues to progress regularly during its descent towards the uterus, soon after its arrival in which the process is completed. The duration of this varies in different animals, being not more than from three to four days in the rabbit, in which it is the shortest known, and extending to from seven to eight days in the dog. It probably occupies not less than eight days in the human subject.

In the bird's egg the segmentation of the cicatricula is accomplished between the time of the entrance of the yolk into the oviduct and that of its being laid with its albuminous, membranous, and shell coverings, which may vary from 16 or 20 to 24 or 30 hours; and there may be some difference in the degree of completeness of the segmenting process at the time of the exclusion of the egg, according to the time the egg has taken to pass through the oviduct, the season of the year, and other circumstances.

Fig. 493.

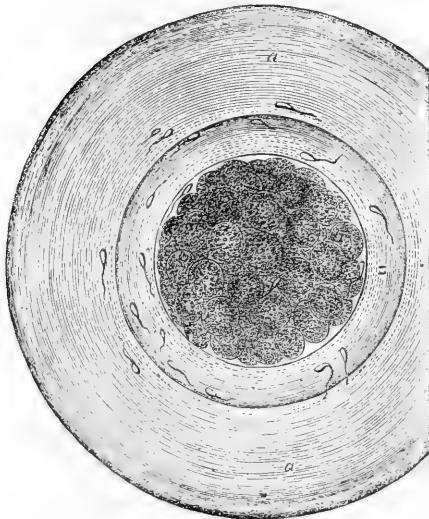


Fig. 493.—OVUM OF THE RABBIT SIXTY-EIGHT HOURS AFTER IMPREGNATION (Allen Thomson).  
250  
1.

This ovum is probably in the sixth stage of segmentation. Spermatozoa were observed within the zona. *z*, the zona; *a*, the thick layer of albumen peculiar to the rabbit's ovum at this stage.

*a. Segmentation of the mammal's ovum.*—This process may be shortly described as follows:—First the whole mass of yolk-protoplasm, contracted as before mentioned, splits into two somewhat ovoid or ellipsoid masses, by the formation of a fissure which begins on the surface and speedily runs through the whole thickness of the yolk

(fig. 492, B). The two masses so formed lie somewhat pressed together within the vitelline membrane; each mass presenting nearly the same appearance and structure as the whole yolk did previous to its cleavage. But as soon as this change has taken place, and according to some

observers even previous to its commencement, there may be seen within each mass a small clear space similar to a nucleus. To these precursors of nuclei the name of *blastide* has been given.

In the next stage each of the two first segments becomes cleft so as now to form four (c), each one of these having its clear spherule or nucleus within; a third division resolves the masses into eight, of like composition with those which preceded them (d), the segments becoming of less and less size in successive stages, as meanwhile the bulk of the ovum as a whole undergoes little increase. The fourth stage ends in a division into 16 segments, the fifth into 32, the sixth into 64 (fig. 493), the seventh into 128, and the eighth into 256 (fig. 494). But it is right here to observe that while it is possible in the earlier stages to trace the reduplication of individual masses so that the succession of their numbers, when the division is complete in each stage, follows in the series of the multiples of two, yet, as the division of the different masses in any stage is not simultaneous, other and as they might be termed irregular numbers may be observed, especially in the earlier intervals of division; as for example, three between the first and second stage, or five, six, or seven masses between the second and third, and so on. In the more advanced stages, from the great increase in number, it becomes almost impossible to follow the division of individual masses.

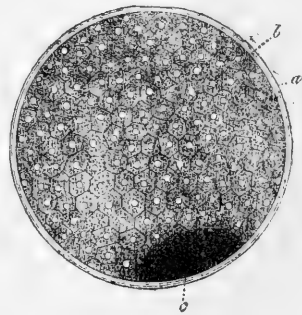
It is also deserving of notice that while the earlier clefts seem to pass right through the yolk and its first segments, so as to involve in the first four or five stages the whole mass of the yolk, in the later stages they do not do so, and the process seems to be in so far different, that the segmenting spheres come to be collected on the surface, and a mass of unsegmented granular and semi-fluid protoplasm or yolk substance remains within. However this may be effected, it is certain that the later division involves only the superficial set of spherules, and when the process is completed, the yolk mass comes thus to be covered by a layer of these protoplasmic spherules or segment globules, each of which possesses a nucleus and may after a time also acquire an external envelope, so as to present in all respects the features of a fully formed organised cell. (See the account of the histological relations of these spherules in the General Anatomy, p. 9).

Fig. 494.—OVUM OF THE RABBIT FROM THE UTERUS. (from Kölliker after Bischoff).  $\frac{100}{1}$

The whole surface of the yolk is now divided into cellular compartments. A dark spot below marks the position of a quantity of granular spheres inside the cellular elements of the blastoderm. *a*, the albuminous layer, now much thinned out and incorporated with the zona; *b*, the cells of the outer layer of the blastoderm resulting from segmentation; *c*, the spot of granular opaque spheres.

*b. Segmentation in the bird's ovum.*—In the ova of birds the segmenting process is somewhat different from that now described in mammals, seeing that it is restricted to the germinal disc or cicatricula. From the researches of Coste and several concurrent observations it appears that

Fig. 494.



the first division is effected by a groove or fissure which passes through the thickness of the germinal disc, having probably a direction at right angles to the long axis of the egg. This is crossed by a second fissure so as to divide the disc into four parts near the centre. A third cleavage or fissuring is still of the same radial character, dividing the disc into eight parts or sections; but this is succeeded by another in a different direction, which may be named concentric, and which has the effect of separating from the rest those parts of the radial segments of the disc which are next to the germinal centre: a subsequent alternating succession of radial and concentric fissures ends by dividing the whole disc into organised nucleated cells of a similar kind with those by which the whole of the mammiferous yolk becomes covered. A third set of fissures, which may be termed horizontal, must also occur to complete the separation of the segmented masses from the subjacent material. In this manner the germinal disc or cicatricula of the bird's egg has already, before the commencement of incubation, that is, during its descent through the oviduct and previous to being laid, been converted by the organising process of segmentation into the layer of cells which constitutes the blastoderm. The cicatricula of the laid egg is therefore of quite a different structure from that of the ovarian ovum, though occupying the same place and presenting much the same appearance to the unassisted eye. This layer appears to be double from the first in the bird's egg, or to consist of two strata of cells, differing somewhat in their character.

Fig. 495.

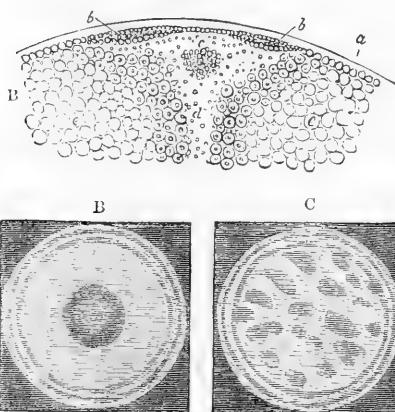


Fig. 495.—CICATRICULA OF THE BIRD'S EGG.

A, diagrammatic section through the cicatricula of a newly laid egg; *a*, vitelline membrane; *b*, segmented germ disc; *c*, below this the germ cavity; *d*, the yolk cavity within the white yolk; *e*, *e*, the yellow yolk substance.

B, view from above of the cicatricular or germ disc of a newly laid impregnated egg in which segmentation has been complete. The opaque area is seen surrounding the central transparent area.

C, cicatricula of an unimpregnated hen's egg, showing the vacuolar structure produced by incomplete segmentation.

In this process there is much which is obscure and still imperfectly known, and much to excite our curiosity. The source of the first segment nucleus has not been discovered, nor is it known whether or in what way it may be related to the dispersed contents of the germinal vesicle or to its macula, and we are equally in the dark as to what may be the influence of the spermatic element upon the germ, and what the forces by which the cleavage and the formation of the multiplying spheres are brought about.

**Contractile and other movements in the germ.**—With respect to the last

mentioned topic it may be remarked that certain heaving and rotatory motions which have been observed by several embryologists immediately before and during the occurrence of the cleavage, indicate the play of contractile and it may be of other forces within the protoplasm; and these forces have been supposed to have some relation to the nucleus. Recent observations by Flemming in the ovum of *Anodonta*, of Oellacher in that of the trout, and of Goette in the toad, seem to show that there is some structural condition related to the process of division which may have a connection with its occurrence; for in the eggs of these animals the space within the domain of each segment sphere about to be formed is occupied by fine filaments radiating from the centre towards the circumference, and preceding the formation of the clear nuclear space within. It is probable that the hyaline globules may be the result of the first yolk contraction.

**Secondary Segmentation.**—The segmenting process previously described may be called *primary*, for it is not yet ascertained in how far the whole of the blastoderm, considered as the organised substratum for the development of the new being, owes its origin directly to the first process of germ segmentation, or to what extent a later process of an analogous kind may contribute to the formation of some of its deeper elements. The most recent observations, such as those of Oellacher and Goette on the egg of the bird, of Ray Lankester on the ova of Cephalopoda, and of Balfour on that of sharks, would tend to support the view that in meroblastic ova at least, the process of segmentation, considered as one of conversion of the yolk into blastodermic elements, is not completed in the first series of such divisions, but continues to take place in a modified form for some time afterwards, thus extending the blastoderm over the surface of the yolk more and more by the addition of newly acquired elements. These elements appear to be formed from new centres of cell organisation external to the limits of the germinal part of the ovum, by what may be called a process of free cell formation, and to contribute mainly to the production of the deeper part of the blastoderm. (Ray Lankester in *Ann. & Mag. of Nat. Hist.*, 1873, p. 81, and F. M. Balfour in *Journ. of Microscop. Science*, July, 1873 and 1874; Goette in *Archiv. für Mikroskop. Anat.*, vol. x., 1874.)

**Partial segmentation in unfecundated ova.**—It is proper further to state that although the process of segmentation as now described is the necessary preliminary to the formation of the blastoderm and is only complete in ova which have been perfectly fecundated, yet an imperfect or partial kind of segmentation has been found also to occur in unfecundated ova. This has now been observed in a variety of animals, such as mollusca, fishes, batrachia, and also in the mammiferous ovum (see Bischoff, *Ann. d. Sc. Nat.* 1844, and Müller's *Archiv.* 1847; Leuckart, article "Zeugung" in Wagner's *Handwörterbuch der Physiol.*, 1852). Oellacher has recently investigated these phenomena with care in the egg of the fowl, from which it appears certain that some degree of segmentation of the germ does occur in unfecundated ova, but that it is of an irregular and incomplete kind as compared with that which follows impregnation, that it never goes on to the formation of a complete cellular blastoderm, and that although some of the earlier stages of segmentation are gone through and the germ is to some extent divided into segment areas, yet these are afterwards broken up by vacuoles and other unnatural processes of development, and no true blastodermic layer of cells is formed (fig. 495, c). Enough, however, has been seen to show that some formative power resides in the germinal part of the yolk independently of the concurrence of the male element. It is not improbable that this segmentation in unfecundated ova may occur to a greater extent in the lower than in the higher animals.

## 2. THE BLASTODERM; ITS STRUCTURE AND RELATION TO THE DEVELOPMENT OF THE EMBRYO.

**Position and extent.**—It has already been stated that in the bird's egg the result of segmentation is the conversion of the germinal disc into an organised cellular blastoderm, which, from the time of its first

formation, and before any incubation has taken place, already consists of two layers of cellular elements (fig. 496, s and D).

These two layers differ considerably. The cells of the upper layer are of smaller diameter, about  $\frac{1}{2400}$ ", more compactly laid together, so as to be slightly compressed, and shortly prismatic, and are all provided with distinct nuclei. Those of the lower layer are of somewhat larger size, and of a more granular aspect, so as to hide the nucleus, which appears, however, to exist in the greater number, and the whole of these cells are rather scattered in reticular groups than united into a distinct and consistent layer (His). Below this layer there is a narrow space occupied by clear fluid between the germ and the surface of the white yolk, to which the name of *subgerminal cavity* is given, and in this space a number of granular spherules or formative cells are found, somewhat similar to the cells of the lower layer.

Fig. 496.

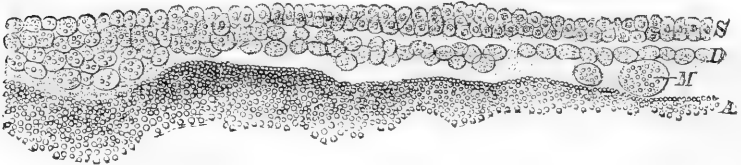


Fig. 496.—MICROSCOPIC VIEW OF A VERTICAL SECTION THROUGH HALF THE BLASTODERM OF A NEWLY-LAID EGG. (From Stricker). <sup>220</sup><sub>1</sub>

S, upper layer of small nucleated cells; D, lower layer of larger granular cells; M, segment spherules lying in the subgerminal cavity; A, substance of the white yolk below the germ.

In mammals, too, it would appear from the observations of Bischoff, Coste, Reichert, and others, that the blastoderm which covers the yolk after the completion of segmentation, though not double from the first, comes soon to consist of two layers. The exact time and mode of the appearance of a second layer are, however, still imperfectly known: and, from the difficulty belonging to the question of secondary segmentation in the deeper part of the yolk previously adverted to, it may be doubtful how far the whole blastoderm of mammals is to be regarded as the direct product of a primary segmentation, or a part of it is due to a later organising process.

There is, however, a great difference in the relation of the primitive blastoderm to the rest of the ovum in birds and in mammals. In the former, as already stated, previous to incubation, this organised cellular disc covers only a very limited part of the surface of the yolk, while in mammals it completely surrounds the yolk from the first, and thus constitutes the *reticular blastoderm* of Coste, Reichert, and other authors.

From the first the blastodermal disc of birds shows a difference in its central and peripheral parts, the former being thinner and more transparent, and thus forming the so-called *transparent area*, the latter being thicker and more opaque, is the *opaque area*. But in mammals the central portion of the primitive blastoderm presents no defined transparent area, and differs chiefly at first from the rest by its greater thickness, and it is by later changes accompanying development that there arises a thickened opaque disc, the *embryonal spot* of Coste, and

that still later in this disc, when expanded and altered in shape, there is formed the first trace of the embryo. The same distinction, however, as in birds, appears in the end between a transparent or embryonal area, and an opaque peripheral area, a part of which is occupied by the vessels of the first circulation.

In birds the blastoderm spreads itself rapidly during the first stages of incubation by cell-multiplication over the surface of the yolk, until at last the whole is covered by its layers; but in mammals, as the yolk is still of comparatively small size after segmentation is complete, but undergoes soon afterwards very rapid and great enlargement, and as it is completely covered by the primitive blastoderm, it is obvious that that membrane must undergo corresponding extension, not by marginal, but by interstitial cellular multiplication.

**Trilaminar structure.**—The bilaminar blastoderm which results directly from segmentation soon undergoes farther changes, by which a third most important element is introduced into its composition, so that, at an early period of development and previous to the actual formation of any part of the embryo, it is found to consist of three layers of cellular elements, placed one above the other. These layers may, from their relative position on the yolk, be named the outer, middle, and inner blastodermic membranes, *ectoderm*, *mesoderm*, and *endoderm*, or, following the nomenclature of Foster and Balfour, *epiblast*, *mesoblast*, and *hypoblast*, the upper, middle, and lower germs; and the ovum of birds and mammals may thus, along with that of a considerable number of animals, be styled *triploblastic*.

The origin of the middle layer is still involved in some obscurity. By one set of observers it is considered to be most closely connected with the original lower layer, and while the original upper layer of the primitive bilaminar blastoderm remains undivided, constituting the *epiblast*, the looser substance of the original lower layer undergoes a differentiating change, by which there is separated from its under part a thin lamina of flattened united cells to form the *hypoblast*, while the remaining portion, with rounded cells of a different structure, becomes distinct superiorly, and accumulates between the upper and lower layers, especially towards the centre, to form the foundation of the *mesoblast*, which according to this view would result, like the *epiblast* and *hypoblast*, from the primary segmentation. But by other embryologists, it is held that a part, if not the whole, of the *mesoblast* proceeds from a secondary process of segmentation or cell formation occurring below the original blastoderm; and further, that the new cells which thus give rise to the *mesoblast* are carried from below towards the place where they form that layer by migratory movements, the nature of which is not yet understood.

Leaving the question of the origin of the middle layer for farther remark hereafter, we shall here state in the shortest and most general terms the relation ascertained to subsist between the three several constituents of the organised germ and the origin of the rudiments of the embryo and other parts developed from the ovum. In doing so, if allowance be made for the differences previously noted, the same description may apply to the fundamental formative processes of birds and of mammals.

**Relation of the Layers to Development.**—With respect to the histogenetic changes which accompany the conversion of parts of the

blastoderm into the several organs and textures, the reader is referred to the various parts of the section on General Anatomy in which the development of the textures is treated of. Here it is enough to state, that in the upper layer or epiblast of the bird's ovum it is mainly by endogenous cell-multiplication that the increase of substance and extension of area is effected; that in the lower layer, there is, according to Foster and Balfour, continued conversion of the cells of the white yolk into those of the hypoblast; and that in the mesoblast there is prolonged addition of cellular elements by new production of formative cells from below the germ; and further, that in all the three layers it is mainly by internal differentiation of the various groups of the cells so formed that are produced the different kinds of formative bases, or initial deposits, whether cellular or extra-cellular, which are converted by farther changes into the rudiments of the several organs and textures of the animal body or its fetal appendages. But, while the formative processes consist essentially in minute histogenetic changes, they are also accompanied by changes of form which are more obvious. Thus the folding or inflection of certain of the layers of the blastoderm which brings about the enclosure of the visceral cavity of the body, or that which accompanies the formation of the amnion; the progressive rising of the dorsal laminae and their final union, which attends the closure of the canal for the brain and spinal cord; the increased accumulation of formative cells in one place leading to growth and increase, and their diminution or removal in others leading to atrophy; the fusion of certain membranes or masses of tissue uniting parts which were previously separate, and the fission or solution of continuity between other masses producing their separation; the excavation of one set of hollows and the obliteration of others, as in the case of blood-vessels and ducts,—are only a few examples of developmental changes, which are dependent, no doubt, more immediately on textural differentiation, but which indicate different forms and modes in which the constructive processes are brought about.

The following is the general relation of the several germinal layers to the production of different systems and organs of the embryo and its accessory parts in so far as yet discovered.

1. From the *epiblast* proceed the epidermis and its appendages, the great nervous centres, and the principal parts of the eye, ear, and nose; one layer of the amnion and yolk-sac, and in mammals, probably the outer layer of the permanent chorion.

2. From the *hypoblast* proceed the epithelial lining of the whole alimentary canal (excepting that of the mouth), and of the lungs, the epithelial lining of the ducts of the glands connected with the alimentary canal, and also the deep layer of the yolk-sac and allantois.

3. From the *mesoblast* proceed in general all the parts of the skeleton, the muscles, fasciæ, and tendons, the peripheral nerves, the true skin, the connective tissue, the vascular system and blood, the muscular and fibrous coats of the alimentary canal and all other visceral passages, the serous membranes, the parenchyma of many glands, and the genito-urinary system, together with the outer layer of the amnion, the vascular layers of the yolk-sac, the allantois and the chorion, and the fœtal part of the placenta.

—The mesoblast does not, however, serve as the basis of these very



various parts indifferently or equally throughout its whole extent, but in the following divisions, viz., First, by a central mesial or axial part, out of which proceed the rudiments of the protovertebral segments of the body; and, Second, by two lateral parts which undergo subdivision into an upper and lower lamina, the first of these subdivisions containing the rudiments mainly of volunतो-motory parts, the walls of the body, or *somato-pleural elements*; and the second forming the involunतो-motory parts, as in the walls of the alimentary canal, heart, &c., or *splanchno-pleural elements*: the space formed by the separation of these two sets of parts is the visceral or *pleuro-peritoneal cavity*.

From the foregoing enumeration of the several parts of the embryo which are traceable in their origin to one or other of the layers of the blastoderm, it must not be inferred that these initial elements remain each distinct or separate from the rest, while undergoing the formative changes of conversion. Some of them, doubtless, do maintain their independence in a remarkable degree, as is the case with most of the parts derived from the hypoblast, and some of those from the epiblast; but in the case of parts proceeding from the mesoblast, this independence is in a great measure lost; and notwithstanding the original separation, we see, especially in the vascular and nervous systems and in the connective tissue, that in the course of their farther development, there is a great amount of spreading of one into the other sets of the blastodermic elements.

**Discovery of the Blastodermic Elements.**—We owe to C. F. Wolff, as described in his *Theoria Generationis*, published in 1759, the first proof derived from observation of the actual new formation of, the organs of the embryo (epigenesis) from the simple granular (cellular) elements of the yolk, and to a later work of the same author (*On the Formation of the Intestine*, which originally appeared in 1769, and was republished in German by J. F. Meckel in 1812) the first suggestion of the laminar constitution of the germ. The full discovery, however, of the three layers of the blastoderm, and especially their relation to the development of the organs and systems of the embryo, was, under the influence of Doellinger's teaching at Würzburg, the work of Pander, and was first published in his inaugural dissertation at that University in 1817. The segmentation of the yolk, noticed by Swammerdam and Spallanzani, was first described in batrachia by Prevost and Dumas in 1823, in a Memoir which was followed by an important series of contributions by the same authors to the history of the development of reptiles, birds, and mammals. The discovery of the germinal vesicle of the bird's egg by Purkinje in 1825 led the way to more minute observation of the constitution of the germinal part of the ovum. But the foundation of embryology as a modern science was most surely laid by C. E. von Baer of Königsberg (originally the associate of Pander and pupil of Doellinger), who discovered the ovum of mammals in 1827, and in his work entitled "*Die Entwicklungsgeschichte der Thiere, Beobachtungen und Reflexionen*," 1829—1837, gave the fullest, the most accurate, and the most philosophical account of the development of animals which has ever appeared. The contemporaneous researches of H. Rathke, also the pupil of Doellinger along with Pander and Von Baer, contributed greatly to the advance of embryological knowledge.

The investigations of Schwann "*On the conformity in the structure and growth of plants and animals*," published in 1839, threw new light upon the histological composition of the ovum and blastoderm and their relation to the phenomena of development (see *General Anatomy*, p. 6 *et seq.*); and in the years contemporaneous with Von Baer's researches, and following their publication, many important contributions appeared which greatly extended the scientific knowledge of the subject; among the authors of which may be mentioned here, as the most prominent, the names of Valentin, Rusconi, R. Wagner, Reichert,

Kölliker, M. Barry, Bischoff, Coste, and Remak. The knowledge of the development of the ovum and embryo of mammalia was especially advanced in the succeeding decennial period by the valuable memoirs of Bischoff on the rabbit, dog, guinea-pig, and roe-deer, published successively between 1847 and 1854, and an important addition was made to the history of human development and that of some animals by the publication of the elegant and elaborate work of Coste in 1847 and several following years.

To the careful observations of Remak more particularly, as described in his work on the development of the fowl and the frog, published in 1851-54, we owe the fullest and most consistent account of the structure and formation of the blastoderm and of the relation of its several parts to the earlier phenomena of embryonic development. The Lectures of Kölliker, published in 1861, formed the most valuable addition to the history of development in the ten years succeeding the publication of the researches of Remak. In 1868 the blastoderm and its early transformations were subjected to renewed examination in the elaborate researches of His (*Untersuch. üb. die erste Anlage des Wirbelthierleibes*). In the succeeding years appeared the varied researches of Dursy on the development of the head, Waldeyer on the ovaries, Oellacher on birds and fishes, and Goette on batrachia and birds, and numerous others, so that every year brings forth numerous original contributions to different departments of the subject. In 1874 there appeared the first English treatise on the development of the embryo since the time of Harvey, in the excellent "Elements of Embryology," by M. Foster and F. M. Balfour—the latter of whom is also the author of important original researches quoted in the course of this section. In the same year a short and useful systematic work on the Embryology of Vertebrate animals has appeared by Dr. Schenk of Vienna.

**Origin of the Mesoblast.**—Although there is the general agreement before indicated among embryologists as to the trilaminar structure of the blastoderm in the ovum of the higher vertebrates, when it has made some progress in development, and as to the general relation of the several layers to the production of the systems and organs of the embryo, there is by no means the same unanimity of views as to the manner in which the different layers, and more especially the lower and middle layers, come into existence.

Fig. 497.

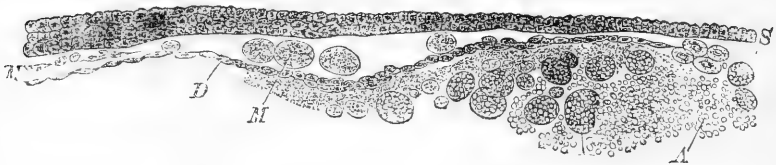


Fig. 497.—MICROSCOPIC VIEW OF A VERTICAL SECTION THROUGH THE BLASTODERM OF THE BIRD'S EGG AFTER TWELVE HOURS OF INCUBATION. (From Stricker.)  $\frac{350}{1}$

S, upper layer of cells or epiblast; D, lower layer now forming a single continuous layer of flat cells, or hypoblast; M, large formative cells beginning to form the middle layer, or mesoblast; A, subgerminal part of the yolk.

In the egg of the fowl the cells of the middle layer begin to make their appearance in the central part of the blastoderm between the two original or primitive layers from the eighth to the twelfth hour of incubation, while about the same time a lower layer becomes distinct, as before stated, by the arrangement in a single layer of the lowest cells, their assumption of the flattened form, and their mutual union somewhat after the manner of a pavement-like epithelium. But while this is apparent towards the centre of the blastoderm there is accumulated towards the periphery in a thickened zone (opaque area) a quantity of cells of larger size and granular aspect in which no division into an under

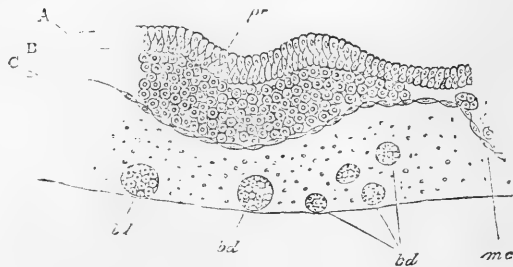
and middle layer is yet to be perceived. According to most observers the original upper layer takes no share in these changes, but remains distinct and undergoes the changes which belong to its own phases of development.

With respect to the formation of the hypoblast it would appear to be no more, at least in its central part, than a differentiation or change of form occurring in cells existing from an earlier period in the primitive lower layer; while its peripheral extension is probably owing to the conversion into its pavement-like cells of the subjacent elements of the white yolk. But as to the manner in which the mesoblast takes its origin, two distinct kinds of views exist among embryologists. According to one of these, following the suggestion of Remak, the cells of the mesoblast take their rise by a process of separation from the cells of the primitive lower layer by changes which are coincident with the conversion of the deepest set of those cells into the continuous lamina of hypoblast. And as a modification of this view may be mentioned that of His, according to which a middle layer (though not distinguished by him as such by name) arises in common from the formative cells of both upper and lower primitive layers through an axial plate, into which he holds they unite.

According to the other view, which originated in the Vienna school, and has received much support from a number of observers emanating from it (Stricker, Waldeyer, Peremeschko, Klein, Oellacher and Goette), the cells which form the middle layer do not proceed either from the epiblast or hypoblast in the place which they ultimately occupy, but these cells arise as new products of cell formation below the hypoblast, pass by migratory movement into the seat of the mesoblast, either through the hypoblast, or, as most hold, round its peripheral margin, and thence into the central part of the blastoderm, where all are agreed the cells of the mesoblast first come to be collected in any considerable quantity. Having once gained this position, or, in other words, a certain portion of mesoblast having been thus formed in the axial or central plate of the embryonic area, its cells speedily multiply and rapidly extend themselves, both by thickening in the centre and by spreading towards the periphery: other mesoblastic cells continue to be introduced from below at the margin of or through the hypoblast, so as to complete the formation of a middle layer by the eighteenth or twentieth hour.

Fig. 498.—SECTION OF A BLASTODERM AT RIGHT ANGLES TO THE LONG AXIS OF THE EMBRYO, NEAR ITS MIDDLE, AFTER EIGHT HOURS' INCUBATION (from Foster and Balfour).

Fig. 498.



A, epiblast formed of two layers of cells; B, mesoblast thickened below the primitive groove; C, hypoblast formed of one layer of flattened cells; *pr*, primitive groove; *mc*, mesoblast cell; *bd*, formative cells in the so-called segmentation or subgerminal cavity. (The line of separation between the epiblast and mesoblast below the primitive groove is too strongly marked in the figure.)

Among the most recent observers, Klein and Balfour favour the migratory view: the latter, however, in a somewhat modified form, as he has arrived at the conclusion that the mesoblast takes its origin not directly from the epiblast or hypoblast, but in part from cells which are included (as the result of the first segmentation) in the blastoderm between those of its upper and lower layers, and partly from the larger spheres or formative cells which are the product of a later process of cell production occurring in the lower part of the germ, and which migrate from the place of their formation in the germ cavity, round the margin of the hypoblast into the space above it. The researches of Goette lead nearly

to the same conclusion as those of Balfour, and if confirmed would go far to prove the occurrence of a secondary or prolonged segmentation in the subgerminal yolk, to which allusion was previously made.

It is right, however, to state that on the other side there is the weighty authority of Kölliker, who, in association with the younger Virchow, has recently sought in vain for the evidence of such migration as has been described by the observers previously referred to, and attributes the formation of the mesoblast entirely to the proliferation of cells connected originally with the lower surface of the epiblast.

**Difference in Animals.**—The foregoing description applies to the symmetrical position and central mode of development of the blastoderm which belong to the ova of reptiles, birds and mammals; but it is right to state that in the lower vertebrata, or in amphibia and in osseous and cartilaginous fishes, there are several remarkable differences. Among these may be particularly noticed the non-symmetrical development of the blastoderm, and the excentric position of the commencement of the embryo; the involution of the epiblast at the aperture of the blastoderm termed 'anus' by Rusconi, or blastopore, at which the cells of the epiblast become continuous with the larger deeper cells from which the mesoblast and hypoblast originate. (See F. M. Balfour, "On the Development of the Elasmobranch Fishes," and "Comparison of the Development of Vertebrates," in the *Quart. Journ. of Microscop. Science* for Oct. 1874, and July, 1875; E. Ray Lankester, "On the Primitive Cell Layers of the Embryo," &c., in the *Ann. and Mag. of Nat. Hist.* for 1871.)

**The Blastoderm of Mammals.**—A variety of observations have shown that the blastoderm of mammals consists, when fully formed, essentially of the same kinds of elements arranged in three layers, as previously described in birds; but the mode of formation of these layers has not yet been fully investigated. By the observations of Bischoff, Coste, and Reichert, it was ascertained that as the result of the first segmentation the yolk became invested with a complete superficial covering of distinct nucleated cells, which may be looked upon as corresponding to the upper or outer layer, or epiblast. Within this there remains for a time a thick plate or rounded mass at one side of opaque spherules, which seemed to be segment spherules not yet converted into cells, and the interior of the yolk was elsewhere filled with a granular fluid. Some time later, or about the fifth day in the rabbit's ovum, a thickened spot, the germinal area of Bischoff, or tache embryonnaire of Coste, gradually made its appearance in the place where the primitive trace of the embryo is afterwards formed. This consisted in a thickening of the layer already formed, and of an accumulation of a layer of new cells below it, which, gradually extending itself over the surface of the yolk, gives a second covering of cells to the whole.

In a carefully conducted series of recent observations, Hensen finds (*Zeitsch. für Anat. u. Entwick. Leipz.* Nov. 1875) that in the rabbit's ovum, at the time when the germinal disc is still round (5 days 4 hours) the epiblast, with its central thickening, forms a complete vesicular covering of the yolk, but that the hypoblast, lying below the disc, does not extend over more than a third of the circumference. The cells of the middle layer are at this time restricted to the hinder part of the germ disc, in which place the primitive trace of the embryo first appears. Kölliker also, in the same animal (*Verhandl. d. Physik. Med. Gesellsch. z. Würzburg*, Nov., 1875) describes the inner layer (hypoblast) as spreading rapidly over the inner surface of the outer layer or epiblast, so as at last to give a complete double covering to the yolk.

In sections of a vesicular blastoderm of the cat, prepared by Mr. Schäfer, but not yet described, two layers may, as he has pointed out to me, be seen, the outer of which (epiblast) lies immediately within the primitive chorion and is co-extensive with it, whilst the inner layer (hypoblast), although also complete, forms a smaller ring than the outer, and is in contact with the latter at one place only. Both layers, although elsewhere formed of a single stratum of cells, are here slightly thickened, but especially the outer (as if a mesoblast were about to be developed from it): the hypoblast at this place appears bounded superficially by a delicate cuticular film.

### SHORT OUTLINE OF THE MORE GENERAL PHENOMENA OF THE DEVELOPMENT OF THE OVUM.

**Distinction of Embryonic and Peripheral Phenomena.**—From what has gone before it will be seen that the fundamental phenomena of development in the ovum consist essentially in changes which take place in the several layers of the blastoderm. Considered individually and minutely, they are mainly of the nature of cell multiplication and cell differentiation. Regarded as a whole they may be placed under two divisions, according as 1st, they have their seat in the parts from which the future embryo is formed, and are therefore *intra-embryonic*, or, 2nd, are *extra-embryonic*, and connected with the production of other parts, having usually a membranous form, which surround the embryo within the ovum, and form principally the amnion, yolk-sac, allantois, and chorion. It is to be remarked, however, that although in the progress of development all these membranes are mainly peripheral or extra-embryonic in their situation, they are not entirely so in their origin, for one of them—the allantois—springs originally from a part within the body of the embryo; and all of them, in mammals at least, by the original continuity of the blastoderm, are necessarily united at certain places with parts of the embryo. Hence they have been called foetal appendages or foetal membranes.

Fig. 499.

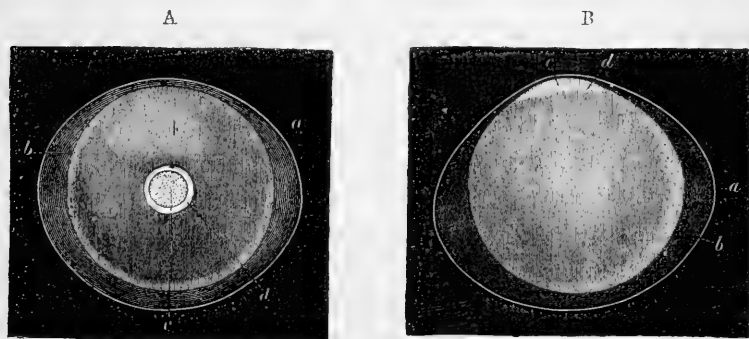


Fig. 499.—OVUM OF THE RABBIT FROM THE UTERUS (from Kölliker after Bischoff).

The ovum was about one seventh of an inch in diameter; *a*, the remains of the zona pellucida or external membrane; *b*, the vesicular blastoderm; *c*, the germinal area; *a'*, the outer limb of the double layer.

It is also to be held in remembrance that in birds, the blastoderm, which is originally restricted to the comparatively narrow limits of the cicatricula, extends itself rapidly in the earlier periods of incubation over the surface of the yolk; while in mammals, the whole yolk is from the first covered by the vesicular blastoderm directly resulting from segmentation. In both, however, there may be distinguished a central and peripheral region of the blastoderm, and to the central part, as being the more immediate seat of the development of the embryo and its organs, without attempting to define very closely its limits, the name of

embryonic area may be given. From this area, as from a centre, the changes of development in some measure emanate or spread towards the periphery. In birds the central area is from the first distinguished from the surrounding part by greater transparency and thinness of the blastoderm, and thus (as already described) arises the distinction of the transparent and opaque areas. In mammals, on the other hand, the germinal part of the blastoderm is at first entirely opaque, forming the embryonic disc of Coste, Bischoff, and others; and it is by a subsequent change that a part of this disc clears up or becomes thin and transparent, and that an opaque area is formed in the peripheral part. In both birds and mammals the embryonic area, from being simply round at first, becomes soon somewhat pyriform, and subsequently oval or contracted in the centre, like the body of a violin.

Fig. 500.

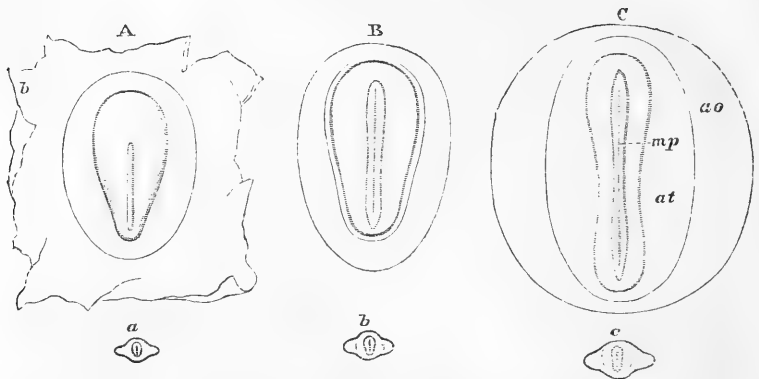


Fig. 500.—FIRST APPEARANCE OF THE PRIMITIVE TRACE AND MEDULLARY CANAL IN THE OVUM OF THE DOG (from Bischoff).

*a*, *b*, and *c*, represent the natural size of the ova of which the several germinal area are represented in A, B, and C. In A the germinal area is pyriform, and the primitive trace occupies two-thirds of the narrow hinder end. In B the trace is elongated and on the two sides are the raised medullary plates, *mp*, with the primitive groove between. In C the distinction between transparent area, *at*, and opaque area, *ao*, is marked by the outline.

It is in the hinder narrower part of this embryonic area, when it has assumed the pyriform shape, that the earliest trace of the embryo can be discerned. This forms the well known primitive streak and groove of authors, but it appears from the observations of Dursy and Balfour in the chick, and of Hensen in the rabbit, that the primitive trace and groove, which are the first indications of embryonic formation, are only transitory and evanescent, and that they are succeeded by the medullary groove and dorsal plates, which commence beyond the cephalic end of the primitive trace, and grow backwards towards the caudal extremity, so as gradually to thrust out as it were at the end the shrivelled remains of the primitive trace. The anterior extremity of this medullary groove becomes afterwards the cephalic, and the posterior extremity or that towards the primitive trace becomes the caudal part of the cranio-vertebral axis of the embryo.

This primitive axis constitutes in some measure the centre of subsequent changes of development. It consists mainly of a thickening produced by the accumulation of blastodermic cells.

1.—INTRA-EMBRYONIC PHENOMENA OF DEVELOPMENT.

**Axial Rudiment of the Embryo.—Cerebro-spinal Axis.**—The genetic changes which lead to the first formation of the rudiments of the embryo may be briefly sketched as follows :—

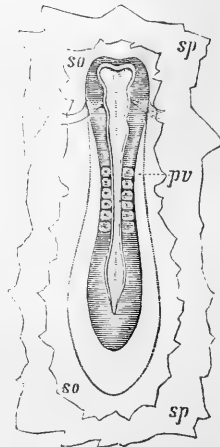
The longitudinal thickening of the blastoderm, which forms the primitive trace, belongs at first chiefly to the upper layer or epiblast, but soon extends to the central part of the middle layer or mesoblast. The hypoblast takes no share in its production.

The elongated plate or thickening is very soon separated towards the cephalic end of the primitive trace by a median groove or linear depression into two lateral plates, which, thickening to some extent, rise into ridges and thus constitute the laminae dorsales, or dorsal ridges. The groove deepening, and the ridges becoming more elevated, there is then formed a canal, and by the further elevation of the ridges, their approach to each other, and their final coalescence in the middle line, the canal is gradually closed in along the dorsal line. The part of the upper layer which has undergone this inflection and enclosure acquires considerable increased thickness, but still a cavity remains in its interior. The part where it was closed dorsally now becomes separated from the upper layer or epiblast with which it was originally continuous, and the latter passes subsequently free and entire across the dorsal line.

Fig. 501.—EMBRYO OF THE DOG SEEN FROM ABOVE, WITH A PORTION OF THE BLASTODERM ATTACHED.

Fig. 501.

The medullary canal is not yet closed, but shows the dilatation at the cephalic extremity with a partial division into the three primary cerebral vesicles; the posterior extremity shows a rhomboidal enlargement. The cephalic fold crosses below the middle cerebral vesicle. Six primordial vertebral divisions are visible; *so*, the upper division of the blastoderm; *sp*, the lower division, where they have been cut away from the peripheral parts.



This canal is wider at the cephalic extremity in which the rudiment of the brain is situated, it is of uniform diameter in the succeeding or middle part, and at the caudal extremity remains open for a time, but is closed in at a later period like the rest.

The rudiment of the great nervous centre arises in a thickening of the central portion of the enclosed epiblast which is originally continuous with the rest of the upper layer; but this part which forms the brain and spinal marrow exhibits considerable thickening at an early stage, thus constituting what by some have been called the medullary plates, while the canal is still open, and subsequently folded round dorsally and closed in the form of a medullary tube, within which

is situated the medullary cavity or common ventricle of the brain and spinal marrow. There is at first no distinction between the medullary or nervous structure and the containing walls: these last, including the dura-matral sheath, are derived later from development of mesoblastic elements.

In birds and mammals it does not appear that there is at first any line of separation or distinction between the medullary part and the rest of the epiblast, but in *batrachia* a difference of colour in the corneous layer marks a distinction between it and the deeper part which forms the medullary rudiments.

**The Notochord.**—One of the next steps in early development as observed in the bird is the formation from a central columnar portion of the mesoblast of an axial cord occupying the future place of the bodies of the vertebræ and basis of the cranium. This constitutes the notochord or *chorda dorsalis* (see fig. 504 and sections in figs. 502 and 503, *ch*).

Fig. 502.

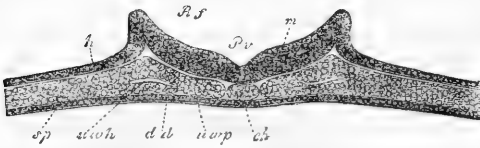


Fig. 502.—TRANSVERSE SECTION THROUGH THE EMBRYO OF THE CHICK AND BLASTODERM AT THE END OF THE FIRST DAY (from Kölliker).

*h*, epiblast; *dd*, hypoblast; *sp*, mesoblast; *Pv*, primitive or medullary groove; *m*, medullary plates; *ch*, chorda

dorsalis; *uwp*, primordial vertebral plate; *uwh*, commencement of division of mesoblast into its upper and lower laminae; between *Rf* and *h* the dorsal laminae or ridges which by their approximation close in the medullary canal.

Its structure is simply cellular, and it takes no direct part in the formation of the bodies of the vertebræ or cranial basis, but comes later to be surrounded by the formative substance out of which these parts of the skeleton are developed. In mammals and in cartilaginous fishes its formation appears to be later than in birds. In man and the higher vertebrates its remains are to be seen for a longer or shorter period of foetal life within the cranio-vertebral osseous axis, but in the lowest vertebrates, as *Amphioxus* and *Cyclostomatous* fishes, in which the

Fig. 503.

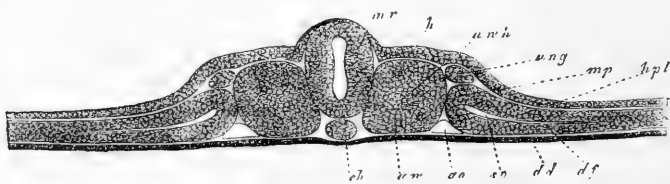


Fig. 503.—TRANSVERSE SECTION THROUGH THE EMBRYO OF THE CHICK AND BLASTODERM ON THE SECOND DAY (from Kölliker).

*dd*, hypoblast; *ch*, chorda dorsalis; *uwp*, primordial vertebræ; *m r*, medullary plates; *h*, corneous layer or epiblast; *uwh*, cavity of the primordial vertebral mass; *mp*, mesoblast dividing at *sp* into *hpl*, somatopleure, and *df*, splanchnopleure; *ung*, Wolffian duct.



vertebræ are not developed or are imperfect, it attains much larger proportions, and itself constitutes the principal vertebral axis.

**Protovertebræ.**—On either side of this axial cord a thick mass or plate of mesoblast is collected along its whole length, and very soon there appear several transverse clefts in these plates forming the commencement of protovertebral segmentation. The first formed of these divisions is near the anterior or uppermost of the future cervical vertebræ, and they rapidly extend backwards in the posterior or lower cervical and dorsal region (fig. 501, *pv*, and fig. 503, *uv*). The divisions becoming more distinct, separate small quadrilateral masses, which have received the name of *protovertebræ*, by which it is meant to indicate that they are not the same with the permanent vertebral pieces of the skeleton, but rather correspond to embryonic somatomes, or *metameric segments*, corresponding closely in number with the permanent vertebral divisions, but including the rudiments of other parts, such as those of the spinal nerves, along with those of the vertebræ.

The basis of the cranium, into which the notochord extends, does not at first present any transverse division similar to that of the vertebral portion of the axis, and the notochord itself is at first without segmentation, and forms therefore a simple and entire cylinder.

**Pleural Cleavage of the Lateral Parts of the Mesoblast.\***—Together with the formation of the protovertebral plates and their transverse segmentation, another important change begins in the lateral part of the mesoblast external to these plates, which consists in its cleavage into an upper or outer and a lower or inner lamina, and the consequent formation between them of an interval or space (figs. 503, *sp*, and 504, *pp*). The two laminae thus separated constitute respectively the *somatopleure* and *splanchnopleure* portions of the mesoblast, and the space between them is the commencement of the pleuro-peritoneal cavity, which afterwards forms by its partition within the embryo the pleuræ, pericardium, and peritoneum, and which beyond

Fig. 504.

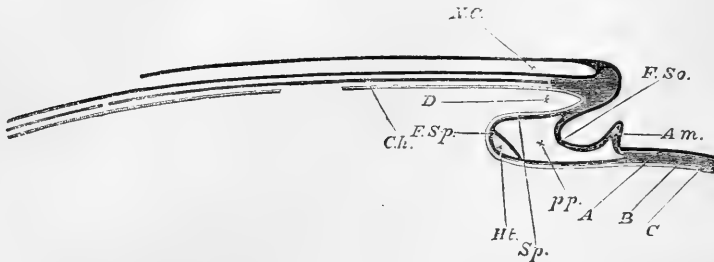


Fig. 504.—DIAGRAMMATIC LONGITUDINAL SECTION THROUGH THE AXIS OF AN EMBRYO (from Foster and Balfour)

The section is supposed to be made at a time when the head-fold has commenced, but the tail-fold has not yet appeared. *A*, epiblast; *B*, mesoblast; *C*, hypoblast; *FSo*, fold of the somatopleure; *FSp*, fold of the splanchnopleure; *Am*, commencing (head) fold of the amnion; *NC*, neural canal, closed in front, but still open behind; *Ch*, notochord,—in front of it, uncleft mesoblast in the base of the cranium; *D*, the commencing foregut, or alimentary canal; *Ht*, heart; *pp*, pleuro-peritoneal cavity.

\* "Pleural" is here used in the sense "parietal."

the embryo extends into the space between the amnion and the other developed membranes of the ovum.

**Inflection of the Walls of the Body of the Embryo.**—The first rudiments of the embryo, as before described, lie prone and flat on the surface of the yolk, consisting almost entirely in thickenings, with some incurvations, of certain parts of the blastoderm. In the formation of these parts the two upper layers, epiblast and mesoblast, are alone concerned, and the hypoblast takes no part in them, but passes thin and flat across the space occupied by the embryonic rudiments.

In the further progress of development a great change of form is now produced by the downward inflection of the whole three layers of the blastoderm, in consequence of which the embryo rises, as it were, out of the plane of the rest of this membrane, and begins to be notched off from its peripheral parts. The first of these folds, termed *cephalic*, (fig. 504) takes place at the extremity of the embryo which contains the rudiment of cranium representing the head, and precedes by a considerable interval the other folds. A similar downward fold subsequently follows at the caudal extremity, and there is also between the cephalic and caudal folds a simultaneous depression of the layers of the blastoderm in lateral folds, so that the embryo takes in some measure the form of an inverted boat, with its keel upwards, and its hollow side opening towards the yolk cavity, and the fore part being, as it were, partially covered in by the deck of the cephalic fold. Thus are produced the downward ventral or visceral plates which form the side walls of the head and trunk; and at a later period, by the increased constriction or convergence of the folds round the place of communication between the embryo and the peripheral parts of the blastoderm, there is formed the umbilicus (see figs. 510 and 512).

Fig. 505.

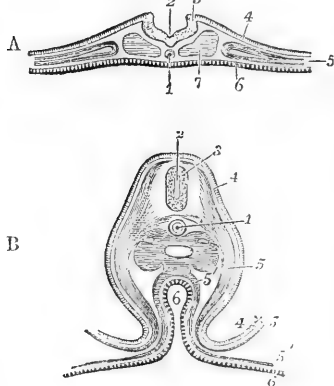


Fig. 505.—TRANSVERSE SECTION THROUGH THE EMBRYO-CHICK BEFORE AND SOME TIME AFTER THE CLOSURE OF THE MEDULLARY CANAL, TO SHOW THE UPWARD AND DOWNWARD INFLECTIONS OF THE BLASTODERM (after Remak).

A. At the end of the first day. 1, notochord; 2, primitive groove in the medullary canal; 3, edge of the dorsal lamina; 4, corneous layer or epiblast; 5, mesoblast divided in its inner part; 6, hypoblast or epithelial layer; 7, section of protovertebral plate.

B. On the third day in the lumbar region. 1, notochord in its sheath; 2, medullary canal now closed in; 3, section of the medullary substance of the spinal cord; 4, corneous layer; 5, somatopleure of the mesoblast; 5', splanchnopleure (one figure is placed in the pleuro-peritoneal cavity); 6, hypoblast layer in the intestine and spreading over the yolk; 4 x 5, part of the fold of the amnion formed by epiblast and somatopleure.

The fundamental steps, therefore, in the development of the vertebrate embryo result in the formation in the axial part, or head and trunk of the body, of two cavities, of which one is situated above and the other below the notochordal axis; the upper constituting the cranio-vertebral canal, and containing the rudiment of the cerebro-

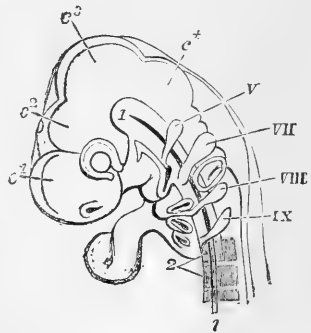
spinal nervous centre; the lower forming the walls of the body which enclose the great nutritive viscera in the thoracic, abdominal and pelvic divisions of the trunk;—along with which may be associated the parts which form the face and jaws, and which enclose the cavities of the nose, mouth, and pharynx, including in their substance the hyoid bone and its accompanying branchial arches.

**The Cerebro-spinal nervous Centre.**—The brain and spinal cord have at first together the form of an elongated tube, of which the primary wall is of nearly equal thickness throughout. The cylindrical portion in the region of the protovertebræ forms the spinal cord. In the dilated cephalic portion, constituting the rudimentary brain, there is from a very early period a partial division into three portions by slight intervening constrictions of the wall of the medullary tube. These constitute the three *primary encephalic vesicles*, and give rise in the next stage of development to the five fundamental portions of the brain usually recognised by embryologists and comparative anatomists, viz., forebrain, interbrain, midbrain, hindbrain and afterbrain. The general cavity enclosed by the inflection and union of the medullary plates constitutes the mesial ventricles of the brain and the canal of the spinal cord.

Fig. 506.—MAGNIFIED SIDE VIEW OF THE HEAD AND UPPER PART OF THE BODY OF AN EMBRYO-CHICK OF THE FOURTH DAY (adapted from Remak and Huxley).

Fig. 506.

1, chorda dorsalis; 2, three of the upper primitive cervical vertebræ; C<sup>1</sup>, one of the vesicles of the prosencephalon, with the nasal fossa below; C<sup>2</sup>, vesicle of the thalamencephalon, with the eye below it; C<sup>3</sup>, the middle cerebral vesicle; C<sup>4</sup>, the cerebellum, between which and the cervical vertebræ is the medulla oblongata. At the anterior extremity of the chorda dorsalis, where it reaches the post-sphenoid, is seen the rectangular bend of the middle of the cranium, which takes place at the sella turcica; and in front of this, towards the eye, the pointed infundibulum; V, the rudiment of the trigeminus nerve; VII, the facial; VIII, the vagus; IX, the hypoglossal; in front and below these numbers respectively, first, the upper and lower jaw, with the first cleft, which becomes the meatus auditorius externus; and lower down the second, third, and fourth arches and clefts in succession; in front of these the aortic bulb attaches the heart; between VII and VIII, the auditory vesicle.



**The Nerves.**—The peripheral nerves are formed, quite independently of the nerve centres, in mesoblastic elements along with the vascular and other tissue composing the parts in which they are distributed. The anterior and posterior roots of the spinal nerves and the roots of the cranial nerves (excepting the optic, which has a special connection with the brain) probably arise as outgrowths from the medullary wall of the cerebro-spinal centres.

**Organs of the Senses.**—To the earliest period also belongs the formation of the rudiments of the principal organs of the senses, viz., the eye, ear and nose. The mode of origin differs, however, in the three. In the eye, which is the earliest to appear, the retina, or nervous part, is an extension from the anterior encephalic vesicle, while the lens is derived by development from an involuted portion of the

epiblast, and other ocular structures proceed from the mesoblast. In the ear the labyrinth originates by involution of its cavity from the epiblast in the neighbourhood of the third encephalic vesicle, and the auditory nerve growing out from the medullary wall of the third

Fig. 507.

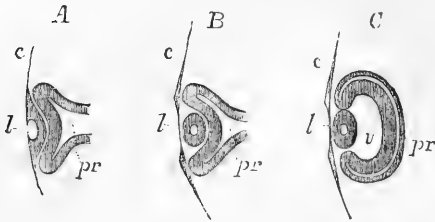


Fig. 507.—SECTION OF THE COMMENCING EYE OF AN EMBRYO IN THREE STAGES.

A. Commencement of the formation of the lens by depression of a part of C, the corneous layer; *pv*, the primitive ocular vesicle now doubled back on itself by the depression of the commencing lens.

B. The lens depression enclosed and the lens beginning to be

formed in the inner side, the optic vessel more folded back.

C. A third stage in which the secondary optic vesicle, *v*, begins to be formed.

encephalic vesicle, is subsequently extended into the ear vesicle; while the middle and outer ear cavities are developed from mesoblastic elements in connection with the first and second post-oral subcranial plates and the intervening pharyngeal cleft. In the nose likewise the open cavity afterwards occupied by the distributed extremities of the olfactory nerves originates by depression or involution from the epiblast in front of the first encephalic vesicle of the cranium.

**Vascular system.**—The next important series of changes by which the foundations of the great organic systems are laid consists in the formation of the rudiments of the heart, blood-vessels and blood, and in the establishment of the first circulation. The several parts of the sanguiferous system all originate in the deeper or splanchnopleural division of the mesoblast, but once formed in this section of the blastoderm the blood-vessels very soon extend into all other parts which are vascular.

Fig. 508.

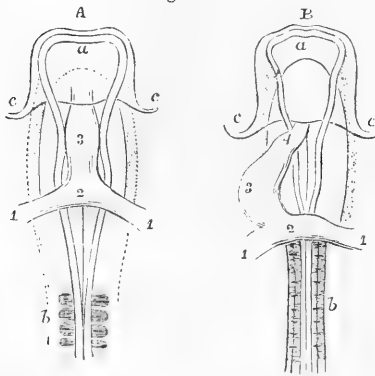


Fig. 508.—OUTLINES OF THE ANTERIOR HALF OF THE EMBRYO CHICK VIEWED FROM BELOW, SHOWING THE HEART IN ITS EARLIER STAGES OF FORMATION (after Remak). <sup>29</sup>

A, Embryo of about 28 to 30 hours; B, of about 36 to 40 hours; *a*, anterior cerebral vesicle; *b*, proto-vertebral segments; *c*, cephalic fold; 1, 1, primitive omphalo-mesenteric veins entering the heart posteriorly; 2, their union in the auricle of the heart; 3, the middle part of the tube corresponding to the ventricle; 4 (in B) the arterial bulb.

The formation of the heart, blood-vessels and blood is nearly simultaneous, and the rhythmic contractions of the heart begin

as soon as the blastodermic cells have arranged themselves in the first simple tubular form of the organ.

While the heart or propelling organ is being formed within the body of the embryo, the greater number of the primitive blood-vessels are developed in the peripheral part of the blastoderm in the vascular and transparent areas, and comparatively few arise in the embryo; these last consisting at first only of the two vessels, the primitive double aorta, which carry the blood from the heart to the arteries distributed in the peripheral area, and the corresponding venous trunks which return the blood from the area to the centre of the circulation. These primitive vessels become afterwards the omphalo-mesenteric arteries and veins of the yolk-sac.

Fig. 509.

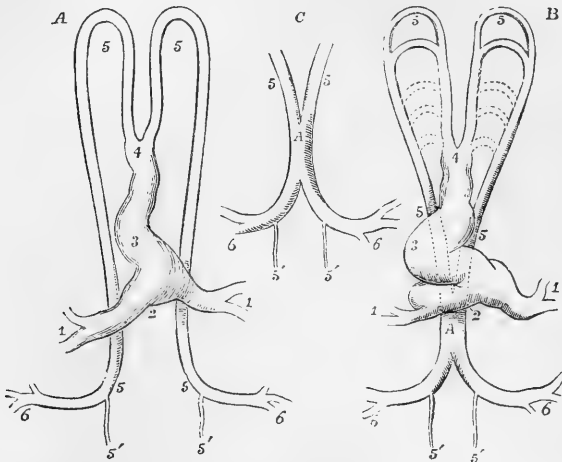


Fig. 509.—DIAGRAMMATIC OUTLINES OF THE HEART AND PRIMITIVE VESSELS OF THE EMBRYO CHICK AS SEEN FROM BELOW AND ENLARGED.

A, soon after the first establishment of the circulation; B, C, at a somewhat later period; 1, 1, the veins returning from the vascular area; 2, 3, 4, the heart, now in the form of a notched tube; 5, 5, (upper) the two primitive aortic arches; 5, 5, (lower) the primitive double aorta; A, the single or united aorta; 5', 5', the continuation of the double aortæ beyond the origin of the large omphalo-mesenteric arteries, 6, 6.

The first rudiment of the heart consists of an elongated tubular contractile chamber hollowed out of a mass of mesoblastic cells in front of the reflection of the cephalic fold into the flat part of the blastoderm. This tube is divided into two at its anterior and posterior extremities, and perhaps it is originally entirely double. Posteriorly the heart-chamber receives the nascent blood from the entering venous channel on each side, and anteriorly it opens into two arterial vessels, which passing one on each side of the primitive pharyngeal cavity, and turning backwards below the protovertebral plates, form the two primitive aortæ before mentioned, from each of which by a sudden bend outwards, as observed in birds, the omphalo-mesenteric arteries pass off into the vascular area. There is, however, some difference in the number and form of these arteries in birds and mammals, but in all of them the first circulation begins in a similar vascular area, and among the earliest veins formed is a circular or terminal sinus

surrounding the vascular area and receiving the blood from the capillary or subdivided vessels of the area within.

**Alimentary Canal.**—The formation of the rudiment of the alimentary canal or primitive intestine takes place below or within the boat-shaped part of the embryo previously described by the folding in, soonest at the cephalic and later at the caudal extremities, and subsequently along the sides, first of the hypoblast, from which the epithelial lining only of the intestine is formed, and afterwards of certain parts of the splanchnopleure section of the mesoblast which give rise by their meeting in the middle to the mesentery, and furnish in their extension over the intestinal tube the muscular and peritoneal coats and the connective-tissue and vascular elements of the gut.

The primitive alimentary canal is thus constituted in its early form by an anterior and posterior cæcal tube, of which the anterior is the first produced,—both of them closed at the extremity by the reflected layers of the blastoderm,—and by a wide middle part between the tubular portions, which at first has the form of a groove or gutter running under the vertebral axis of the embryo, and completely open below into the cavity of the yolk-sac. As development proceeds, the intestinal folds involve more and more of this central open part and convert it into the tubular form; and the opening into the yolk is thus gradually narrowed, while the reflected part of the blastodermic layers which pass between the yolk-sac and the intestine becomes lengthened out so

Fig. 510.

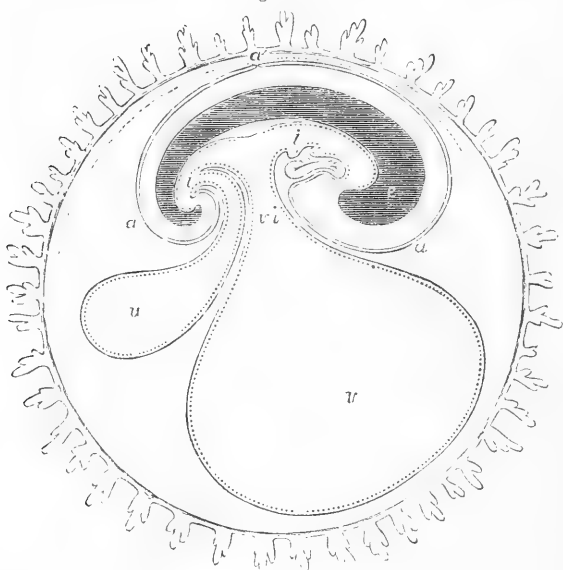


Fig. 510.—DIAGRAMMATIC SECTION THROUGH THE OVUM OF A MAMMAL IN THE LONG AXIS OF THE EMBRYO.

*c*, the cranio-vertebral axis; *i, i'*, the cephalic and caudal portions of the primitive alimentary canal; *a*, the amnion; *a'*, the point of reflection into the false amnion; *v*, yolk sac, communicating with the middle part of the intestine by *v i'*, the vitello-intestinal duct; *u*, the allantois. The ovum is surrounded externally by the villous chorion.

as to take the form of an elongated duct known as the *ductus vitello-intestinalis* (see figs. 510 and 512).

As the parts constituting the face are at first entirely absent, there is necessarily no cavity corresponding to the mouth, but as the structures which give rise to the jaws and face come to be developed below the cranium, the buccal and nasal cavities are generally deepened by the increasing projection of these parts, and the mouth at last communicates with the forepart of the primitive alimentary canal by an opening formed into it at the fauces. The mouth, therefore, derives its lining from the epiblast and forms no part of the original hypoblastic inflection which gives rise to the pharyngeal cavity.

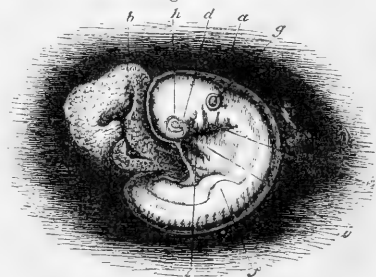
The posterior opening of the alimentary canal is formed at a considerably later period than that of the fauces. When first produced by the solution of continuity in the posterior reflection of the blastodermic layers, it represents in mammals as well as in birds a cloaca, or part of the primitive intestine common to the alimentary canal and the genito-urinary passages.

**Reproductive and urinary organs.**—As completing the present short notice of the development of the rudiments of the principal organs of the embryo, there may, lastly, be mentioned the temporary organs named the *Wolffian bodies*, with their ducts and associated parts, which are the precursors of, and are very constantly and intimately associated with, the first origin and subsequent evolution of the reproductive and urinary organs. These bodies, when fully formed, constitute a pair of symmetrical organs which occupy nearly the whole extent of the abdominal cavity, and consist mainly of short transverse tubes presenting a glomerular vascular structure very similar to that which exists in the glandular structure of the permanent kidneys. They have thus been named the *primordial kidneys* (see fig. 513, W, p. 702).

The Wolffian bodies arise mainly in connection with the central portion of the mesoblast, and as the permanent kidneys and their ducts, the testicles and ovaries, and the respective male and female passages are in their origin all intimately connected with the Wolffian bodies, we may look upon the urinary organs and the internal reproductive organs as equally products of the middle layer. The external sexual

Fig. 511.—HUMAN EMBRYO OF ABOUT FOUR WEEKS (from Kölliker after A. Thomson).  $\frac{5}{8}$   
f, the anterior limb rising as a semi-circular plate from the lateral ridge. (The figure is elsewhere described).

Fig. 511.



organs are integumental in their origin, and may be considered as arising in the epiblast and mesoblast jointly.

**The Limbs.**—The limbs do not commence till after the rudiments of all the organs already referred to have made their appearance. They are to be regarded as out-growths from the lateral part of the trunk, and take their origin by a sort of budding out or extension of the elements composing the

wall of the trunk in two determinate places, which are nearly the same in all vertebrate animals, and receiving prolongations of the bones, muscles, nerves, and blood-vessels corresponding to a certain number of the vertebral somatomes in the situation of the anterior and posterior limbs respectively.

## 2. EXTRA-EMBRYONIC PHENOMENA OF DEVELOPMENT OF THE OVUM.

**Fœtal Membranes.**—While the changes before described in the central part of the blastoderm lead to the formation of the rudiments of the embryo, there are simultaneously developed in its peripheral parts, or extended into them from within, certain membranes which lie external to the body of the embryo, but are for a time more or less organically connected with it by the original continuity of the blastodermic elements in which both sets of parts originate.

Of these membranes, the yolk-sac exists in all vertebrate animals; the amnion and allantois are common to birds and mammals, but are absent in amphibia and fishes; and the chorion, in the sense in which the name will be employed here, may be considered as peculiar to mammals.

**The Yolk-sac.**—This name is given to an organised and vascular covering formed by the extension of the layers of the blastoderm over the surface of the yolk within the original vitelline membrane. In human embryology it has also received the name of *umbilical vesicle*. It consists originally of all the layers of the blastoderm, and in fishes and amphibia retains these throughout the whole term of development\* ;

Fig. 512.—DIAGRAMMATIC SECTIONS OF THE OVUM IN DIFFERENT STAGES OF DEVELOPMENT TO SHOW THE PROGRESS OF FORMATION OF THE MEMBRANES (from Kölliker).

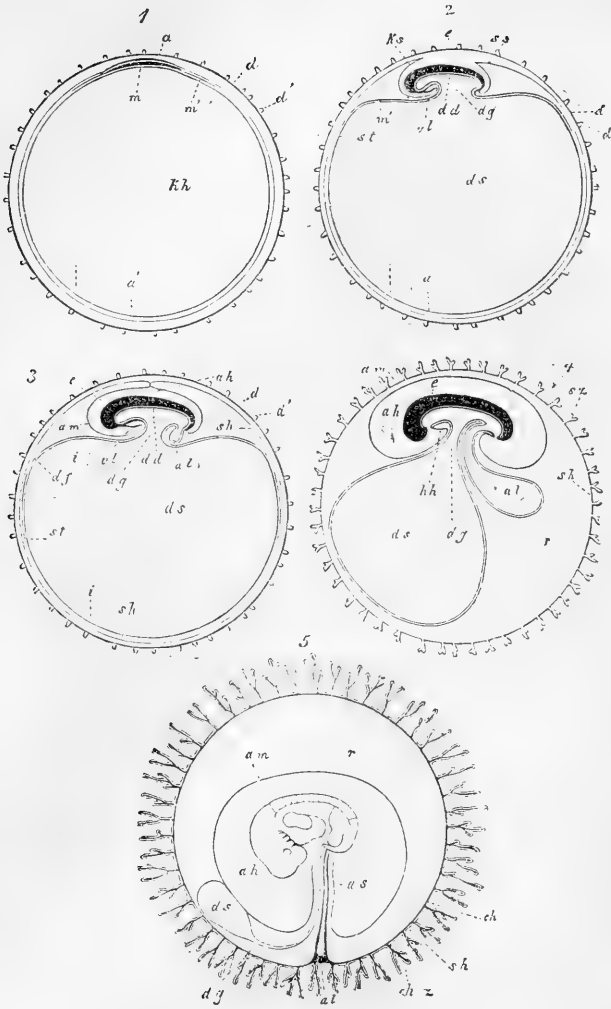
1. Ovum in which the chorion has begun to be formed, with the blastoderm and rudiment of the embryo within. 2. Ovum in which the cephalic and caudal folds have contracted the umbilical aperture towards the yolk-sac, and the amniotic folds are turning towards the dorsal aspect. 3. The amniotic folds being completed have met in the dorsal region; the umbilical opening is more contracted, and the allantois has begun to sprout. 4. The true amnion is detached from the reflected or false amnion which has disappeared or combined with the chorion; the cavity of the amnion is more distended; the yolk-sac is now pediculated, the allantois projects into the space between amnion, chorion, and yolk-sac, and the villi of the chorion begin to ramify. 5. The ovum when it has become embedded in the uterine decidua; the yolk-sac (umbilical vesicle) is now connected to the fetus by a long duct, the amnion is increased in volume; the allantois remains only as a pediculated vesicle towards the attachment of the short umbilical cord to the part of the chorion where the placenta is about to be formed. The vascular layer of the allantois has now combined with the chorion, the villi of which have undergone further development.

*d*, vitelline membrane or primitive chorion; *d'*, commencing villi of the chorion; *sp*, epiblast; *sz*, villi of the chorion more advanced; *ch*, permanent chorion with which the vascular layer of the allantois is combined; *ch*, *z*, true vascular villi of the chorion; *am*, amnion; *ah*, its cavity; *ks*, cephalic fold; *ss*, caudal fold of the amnion; *a*, the embryonal rudiment in the epiblast; *m*, that in the hypoblast or mesoblast; *st*, margin of the vascular area in its early stages; *dd*, hypoblast; *kh*, hollow of the vesicular blastoderm, becoming afterwards *ds*, the hollow of the yolk-sac; *dg*, ductus vitello-intestinalis; *al*, allantois; *e*, embryo; *v*, original space between amnion and chorion; *cl*, wall of the thorax in the region of the heart; *hh*, pericardial cavity.

\* The batrachia seem to be an exception to this statement, but only in consequence of the yolk sac being so extremely limited that it merges in the intestine itself. The yolk-sac and primitive intestine are in fact combined together, there being no umbilical constriction between them.



Fig. 512.



but in the higher animals, as the greater part of the epiblast and somatopleure layer of the mesoblast comes to be detached from the surface of the yolk by the expansion of the amnion and allantois, the hypoblast and splanchnopleure layer of the mesoblast are alone the permanent constituents of the wall of the yolk-sac; and through these last the membrane of the yolk-sac is continuous with the wall of the intestine in the vitello-intestinal aperture.

The yolk-sac is the seat of the first circulation of the blood in the omphalo-mesenteric vessels of its vascular area, and in oviparous animals especially these vessels spread at a later period over the whole surface of the yolk in the membrane which forms the sac. The food-

material of the yolk is probably absorbed by these vessels and conveyed by them as nourishment into the system of the embryo. In many of these animals however a quantity of the yolk substance also remains at the end of incubation, and by actual transference into the intestine of the embryo serves for a time as its digestible food.

In mammals the yolk-sac grows for a time with the embryo and other parts of the developing ovum, and the yolk substance within it must undergo a corresponding increase. There are however great differences among the different tribes of mammals in the extent of the development of the yolk-sac during uterogestation. In some it remains large and vascular, while in others it becomes atrophied and its vessels are obliterated at a comparatively early period. In rodentia it attains its

Fig. 513.

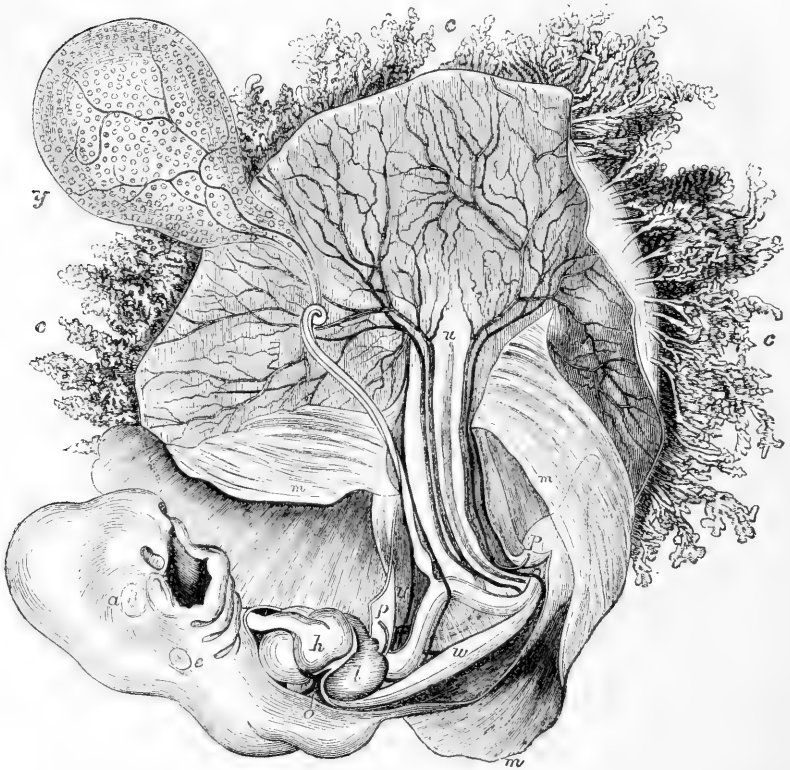


Fig. 513.—MAGNIFIED VIEW OF THE HUMAN EMBRYO OF FOUR WEEKS WITH THE MEMBRANES OPENED (from Leishman after Coste).

*y*, the umbilical vesicle with the omphalo-mesenteric vessels, *v*, and its long tubular attachment to the intestine; *c*, the villi of the chorion; *m*, the amnion opened; *u*, cul de sac of the allantois, and on each side of this the umbilical vessels passing out to the chorion; *a*, in the embryo, the eye; *e*, the ear vesicle; *h*, the heart; *l*, the liver; *o*, the upper, *p*, the lower limb; *w*, Wolffian body, in front of which the mesentery and fold of intestine. The Wolfian duct and tubes are not represented.

highest degree of development, and comes in contact for a space with the interior of the chorion. In ruminants it is very soon elongated into two attenuated tubes which extend towards the ends of the ovum. In carnivora it is of considerable size, stretching through the ovum towards its opposite poles.

In the human species it retains its vascularity and continues to grow up to the fifth or sixth week, at which time it has assumed a pyriform shape, and is connected by a tubular vitelline duct with the intestine.

But notwithstanding all these varieties of form and development of the yolk-sac in the more advanced stages, we recognise the same fundamental structure and relations to other parts as in oviparous animals. Thus in human embryos of from two up to four weeks there have been observed the same progressive changes from the wide communication of the yolk-sac with the open primitive intestine, to the narrower vitello-intestinal aperture, and the subsequent elongation of this into a tubular vitello-intestinal duct (figs. 511 and 513).

The human yolk-sac or umbilical vesicle, which expands proportionally with the early increase of the ovum, never, however, surpasses the size of a small pea; in an ovum of from five to six weeks it lies loosely in the space between the amnion and chorion. At a later period, the duct elongating with the umbilical cord, the vesicle remains in the same relation to these membranes: it now also becomes flattened and more closely attached in the narrower space remaining between them. In the third month it is found connected with a coil of intestine which in the form of a hernia occupies the umbilical cord outside the abdomen of the embryo. At a later period the much elongated and attenuated duct with the omphalo-mesenteric vessels, now impervious and shrunk, may still be traced through the umbilical cord, while the flattened vesicle may be found, even up to the end of the term of uterogestation, somewhat further removed from the place of implantation of the umbilical cord on the internal surface of the placenta, but still between the amnion and chorion.

**The Amnion.**—This vesicular covering of the embryo does not exist in amphibia and fishes, but in reptiles, birds, and mammals, it is formed at an early stage of development, and contains a fluid in which the fetus is suspended by the attachment of its umbilical cord or an equivalent uniting medium.

The structure of the amnion is essentially similar in the three classes of animals in which it exists and its mode of formation nearly the same. It is destitute of blood-vessels, and consists of two layers, derived respectively, the inner from the epiblast, and the outer from the somatopleure layer of the mesoblast; the first consisting of distinct nucleated cells, the second presenting a fibrous structure. To its external or fibrous layer it also owes the property of muscular contractility, which it possesses in a considerable degree.

The formation of the amnion takes place by the gradual backward inflection from the flat part of the blastoderm adjoining the embryo of the two layers before mentioned, first at the cephalic, and a little later at the caudal extremity and at the sides (see fig. 512, 2, 3, and 4, *ks, ss, am*), so that the two layers of which the amnion is composed are lifted up and separated from the remaining two lower layers (splanchnopleure and hypoblast) of the blastoderm, by a space which is the same as, or rather

a peripheral extension of the pleuro-peritoneal cavity. The embryo thus comes to sink down as it were (the cephalic part before the rest) into the hollow produced by the rising of the amniotic folds round it.

The backward folds deepening more and more, gradually converge on the dorsum of the embryo, and at last come together (fig. 512, 3), the margins of the reflection narrowing rapidly and being finally completely obliterated or lost by their convergence and by the subsequent dissociation of the inner from the outer divisions of the folds (fig. 512, 4). The separated inner division now becomes the entire closed sac of the amnion, connected only with the rest of the parts at the umbilical constriction where it is continuous with the integument of the embryo. The outer dissociated division is the *false amnion* of Pander and Von Baer, passing out into the remaining peripheral part of the blastoderm, and constituting for a time an external covering of the ovum, which in birds and reptiles appears afterwards to be lost by thinning or absorption; but which in mammals may be connected with the development of the permanent chorion in a manner to be referred to hereafter.

Fig. 514.

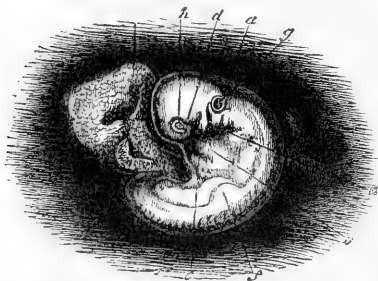


Fig. 514.—HUMAN EMBRYO OF BETWEEN THE THIRD AND FOURTH WEEK, MAGNIFIED ABOUT FIVE DIAMETERS (from K lliker after Allen Thomson).

*a*, amnion adherent (unusually) to the interior of the chorion in the dorsal region; *b*, umbilical vesicle or yolk-sac with a wide communication with the intestine; *c*, lower jaw; *d*, superior maxillary process; *e*, second postoral plate, and behind it other two, with the pharyngeal clefts behind each; *f*, commencement of the anterior limb; *g*, primitive auditory vesicle; *h*, eye; *i*, heart.

In the human ovum, as in most mammals, the amnion is formed at a very early period. The membrane lies at first so close to the embryo that it is with difficulty distinguished from the surface of the body: but after the dorsal closure is completed, it is soon separated by the fluid which accumulates in its cavity.

The muscular contractility possessed by the amnion doubtless resides in its outer layer derived from the somatopleure. The contractions appear to be rhythmic, as they may be seen in the opened incubated egg of the fowl, or even in the entire egg, by means of a bright light in a dark chamber, from the sixth or seventh day of incubation; and it is probable that they are of a similar nature in mammals.

The amniotic fluid contains about 1 per cent. of solid matter, consisting chiefly of albumen, but also traces of urea, which is probably derived from the urinary secretion of the fœtus.

It would appear that there is a difference in the structure of the reflected or false amnion in birds and in mammals. In the former it is composed of the same two layers as the amnion itself, but in mammals the development of the mesoblast appears to cease at the place of reflection of the true into the false amnion, so that the latter consists only of the corneous layer or epiblast.

**The Allantois: Urinary Vesicle.**—Although this membrane becomes in the more advanced stage of development widely distributed

in the periphery of the ovum, yet in its origin it differs from the other membranes now under consideration in its close connection with one of the internal organs of the embryo. As already stated, this membrane does not exist as a foetal structure in fishes or amphibia.

In reptiles, birds and mammals, it is formed in connection with the hinder part of the primitive intestine, is the bearer of an extended capillary distribution of the umbilical or hypogastric vessels, and in combination with them performs important functions connected with the nutrition of the foetus and the aëration of the foetal blood.

The recent observations of His and of Dobrynin have shown that it springs from splanchnopleure elements of the mesoblast and hypoblast, below and in front of the caudal extremity of the embryo close to the place of division of the mesoblast into its somatopleural and splanchnopleural laminae. The former of these is reflected in the caudal fold of the amnion already described; the latter buds out from the end of the primitive intestine into the pleuro-peritoneal space, and receives within it an evolution or outfolded process of the hypoblastic lining of the alimentary canal. It is placed at first rather behind the part which later becomes the cloaca, the orifice of which is still closed: but very soon it is doubled forwards upon the cloaca, so as to lie below it, and when this orifice is afterwards opened it forms the common outlet of the intestine and the allantois (fig. 510, and fig. 512, 3 and 4).

The blood-vessels, which are developed with great rapidity in the outer layer of the allantois, are formed in connection with those which become the two umbilical arteries and the corresponding umbilical veins, which last, however, do not run entirely in the same course as the arteries, but join the omphalo-mesenteric and pass towards the liver; one of the original veins very frequently becoming obliterated, as occurs in the human subject. The capillary network spread over the surface of the allantois appears almost as soon as the first prominence of the membrane begins to bud out from the wall of the primitive intestine, and the vessels appear at first to be in direct connection with the terminations of the two primitive aortæ; but subsequently, when the two aortæ coalesce, the umbilical arteries appear as branches of the iliac arteries (see the Development of the Vascular System).

The allantois in expanding takes the shape of a pediculated flask-like vesicle, extends into the pleuro-peritoneal space, and is filled with fluid like the other membranes of the ovum. It is usually directed towards the right side of the embryo, or the opposite from that on which the yolk-sac is laid. In its subsequent great expansion in the egg of birds the allantois spreads out in a flattened form over the whole internal surface of the membrane of the shell, thus coming to occupy more and more of the space previously held by the albumen, the rapid liquefaction and disappearance of which are coincident with the greatest expansion of the allantois and other membranes.

The allantois, though greatly flattened out in its most advanced state, still consists of an outer and an inner wall, separated by the fluid, and both bearing the finely ramified blood-vessels, which, however, are most richly distributed on the outer division; and in these last it is easy to see, on opening an egg during incubation from the eighth day onwards, the marked difference of colour of the blood in the outgoing and returning vessels from the action of the surrounding air on the blood which has passed through the capillaries.

It is also worthy of notice that from the time when the allantois has attained some size, it, like the amnion, is possessed of contractility, which probably resides in its external layer; and accordingly, on opening an incubated egg, from the effect of change of temperature or other stimuli, active motions may be perceived, caused by the alternate contraction and relaxation of different parts.

In mammalia the origin and early development of the allantois are nearly the same as in birds, but in a more advanced stage of development, the important connection which the outer layer of this membrane has with the formation of the vascular part of the chorion and foetal placenta, modifies considerably the relations of the membrane to the other parts of the ovum. In all of them, however, the two layers of the allantois (splanchnopleure and hypoblast) are easily distinguished from each other, the internal being entirely devoid of blood-vessels, of a simple cellular structure, and containing the fluid with which the inner sac of the allantois is filled. The external layer, on the other hand, is highly vascular, and is composed of fibro-cellular and contractile fibrous elements.

In the ruminants, pachydermata and the cetacea, the allantois attains to very large dimensions, extending widely into the greatly elongated ovum. In the carnivora it passes round the middle of the ovum externally in accordance with the zonal form of their placenta, while in the rodentia and in man its vesicular or deeper membrane at least, containing the fluid, has a much more limited expansion, and stops apparently in its growth as soon as it has assumed the flask-like form and has reached the interior of the chorion. This appears to be the most probable explanation of the appearance, described by several embryologists, and observed also more than once by the writer, of a pyriform space extending in early human ova from the umbilicus to the inside of the chorion at the place where the placenta is beginning to appear or will afterwards be formed. (See a recently described case by W. Krause in Reichert and Dubois, *Archiv*, 1875.) But in this and all other forms the umbilical vessels which pass out of the embryo are placed externally to the vesicle of the allantois or its continuation by the urachus towards the urinary bladder: and these vessels undergoing an extremely rapid development, pass off into the chorion and placenta, which thus owe their vascular structures to the outer layer of the allantois.

In the human subject the allantois is both of very early formation, and its non-vascular or internal part ceases to extend itself at a very early period, that is, before the end of the fourth week. But already by this time the blood-vessels of the outer layer, by themselves or more probably in association with a connective-tissue layer in which they were originally situated, have overrun the whole interior of the chorion, and very soon furnish to the developing villi of that structure, the fibrous element with vessels, of which they secondarily become possessed. The manner of the completion of this process will be apparent from what follows, as to the formation of the chorion (Von Baer, Reichert, Remak, Kölliker).

**The Chorion.**—The ovum of the mammifer when it enters the cavity of the uterus is covered only by the vitelline membrane, or zona pellucida, which is of ovarian origin, and as a rule (notwithstanding the apparent exception of the rabbit to be afterwards referred to) it does not appear that it acquires any other covering for some days after its arrival in the uterus. By the time, however, that it becomes fixed in that part of the uterus which it is to occupy during the subsequent period of its intrauterine life, a great change takes place in the nature of the external covering of the ovum, by its conversion into a new

membrane, which acquires more or less of a composite villous structure, becomes vascular throughout the whole or a part of its extent, and which, by its farther development, comes to form the principal means on the side of the ovum of establishing an organic connection between the embryo and the uterus. While the name of *prochorion*, or primitive chorion, might without impropriety be given to the altered and expanded zona pellucida as the sole early covering of the ovum in mammals, the term *chorion* is most suitably reserved for the newly formed membrane here referred to.

By some authors, indeed, the name of chorion has been applied to the external covering of the ovum of all animals without regard to its source or its relations to other parts. Thus by some the vitelline membrane has been regarded as a chorion when it appeared that no other membrane existed external to it; and by others the name has been given to such adventitious parts as the albumen, shell, or shell membrane of the ovipara: but such a use of the term chorion is liable to create confusion, and it seems more expedient that it should be restricted to the peculiar external covering of the mammiferous ovum, which, as will be shown hereafter, is not an original constituent of the ovum like the vitelline membrane, but a structure of new formation in the course of development.

Fig. 515.—VIEW OF THE CHORION OF THE HUMAN OVUM OF ABOUT FOUR OR FIVE WEEKS, OPENED (from Kölliker after Allen Thomson). NATURAL SIZE.

This figure gives a general view of the villous structure of the chorion previous to the formation of a placenta, and shows the large space which frequently intervenes at an early period between the amnion and chorion.

At a very early period in the majority of mammals, and especially in the human species, the chorion acquires numerous villous processes over the whole or a part of its outer surface. These soon undergo a great development, and constitute a peculiar feature in the human ovum, whence the membrane has been known in human embryology as the *chorion frondosum*, or shaggy chorion.

The blood-vessels borne by the developed villi of the chorion, and named umbilical in human anatomy, are originally derived from those of the allantoid membrane, and are the seat of an extended circulation of the foetal blood in a system of outgoing arteries and returning veins with their intervening widely diffused capillary vessels. It is by this system of vascular chorionic villi being brought into contact or close proximity with the blood-vessels of the uterus, that the essential conditions of uterogestation, as regards the continued supply of nourishment to the foetus and the aëration of its blood, are secured in the whole class of mammiferous animals. There is, however, very great difference among these animals in the extent and form of the development of the villous structure of the chorion now referred to, as well as of the concomitant changes which occur in the uterus itself, by which a more or less intimate organic union is established between the maternal parent and the offspring. The history of these differences belongs to the account of the structure and formation of the placenta, which will be given hereafter. At this place it will be sufficient to state that, while in some animals, as the pachydermata and cetacea, the connection between the ovum and uterus

Fig. 515



is reduced to its simplest form, and consists in little more than the implantation of comparatively simple and diffused chorionic villi in minute recesses of the vascular lining membrane of the uterus; in others there is a greater or less degree of deeper interpenetration of

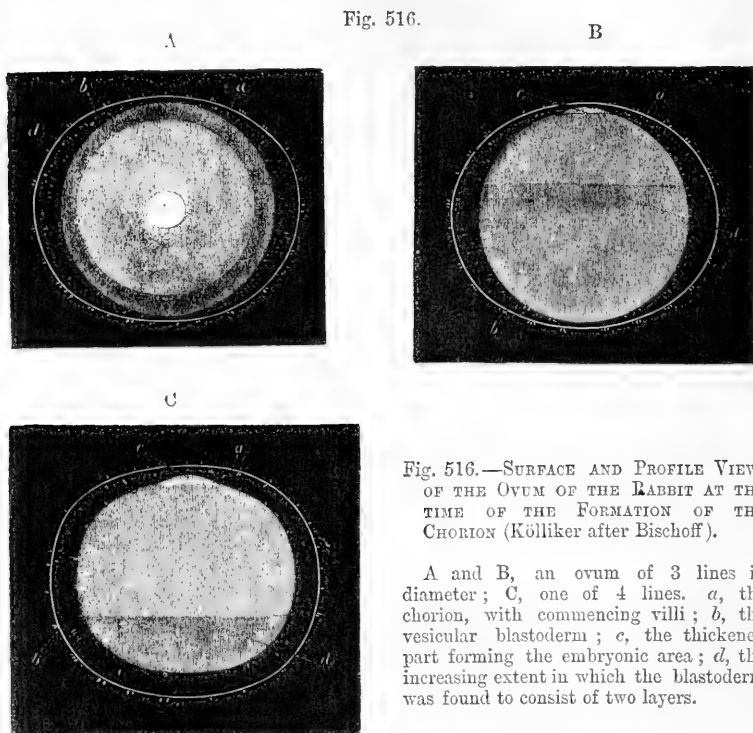


Fig. 516.—SURFACE AND PROFILE VIEWS OF THE OVUM OF THE RABBIT AT THE TIME OF THE FORMATION OF THE CHORION (Kölliker after Bischoff).

A and B, an ovum of 3 lines in diameter; C, one of 4 lines. *a*, the chorion, with commencing villi; *b*, the vesicular blastoderm; *c*, the thickened part forming the embryonic area; *d*, the increasing extent in which the blastoderm was found to consist of two layers.

the more highly developed and complex villi with a vascular structure formed from the uterine lining membrane, and which, from its being in whole or in part separated along with the ovum from the uterus in certain animals at the period of birth, has received the name of *decidua*.

**Origin of the Chorion.**—The manner in which the permanent chorion is first formed has not yet been fully ascertained. The deposit of an albuminous layer on the external surface of the zona pellucida of the rabbit, which takes place in the course of the descent of the ovum through the Fallopian tube, naturally led to the supposition that the chorion might be derived from some external deposit or uterine secretion of this nature; but the fact that a similar deposit from without has not been observed to occur in other animals, and that the albuminous coat in the rabbit very soon thins away like the zona itself, and gives place to other structures, has caused this view to be abandoned. Nor is it probable that the chorion proceeds mainly, as held by some, from a development of the vitelline membrane. For when the rapid expansion of the ovum occurs shortly after its arrival in the cavity of the uterus, the zona pellucida becomes proportionally dilated, and is reduced to an extreme degree of thinness, so that at this period it is liable to be



ruptured with the slightest force, and there is thus caused great difficulty in the examination of the ovum. After a few days the external covering of the ovum, which was previously smooth on its surface, becomes covered with slight projections, which gradually rise in the form of simple villi, and these, according to Bischoff, have at first the same homogeneous structure as the zona originally presented. But according to Kölliker it may be doubted whether these villi are at first entirely homogeneous, and, at all events, he has ascertained that in a very early stage of their formation in the human ovum, as in the ovum of from fifteen to eighteen days, described by Coste, and which Kölliker had an opportunity of examining microscopically, the simple villi consist of hollow tubular processes, which are entirely composed of nucleated cells, similar to those of the upper layer of the blastoderm. It is, therefore, most probable that according to the view first suggested by Reichert, the villous chorion of the mammal's ovum is a product of the development of the blastoderm, and is formed in fact by the extension of its outer layer, now termed epiblast.

Fig. 517.—FRONT AND SIDE VIEWS OF AN EARLY HUMAN OVUM FOUR TIMES THE NATURAL SIZE (from Reichert).

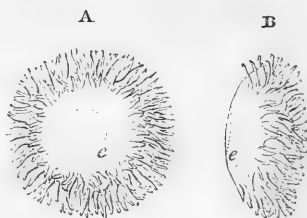
This ovum is supposed to be of thirteen days after impregnation. The surface bare of villi is that next the wall of the uterus, showing at *c*, the opacity produced by the thickened embryonic disc. The villi covered chiefly the marginal parts of the surface.

**Villi of the Chorion.**—A large part of the external surface of the ovum is in the earlier stages beset with villi, and these villi acquire vascularity by the extension into them of the blood-vessels of the allantoic membrane from within. In subsequent stages, however, the form and extent of the development of the villi are subject to great variety in different animals, according to the peculiar form which is assumed in each tribe by the organic connection established in uterogestation between the uterus and the ovum.

In the human species the villi appear to become vascular at a very early period, as ascertained by Kölliker in an ovum of between three and four weeks, in which he found that, while a delicate loop of blood-vessels penetrated into each of the villi, the internal part of the villus, which, as before stated, was previously a hollow cellular tube, was now filled with a fibrous connective tissue bearing the simple blood-vessels, and of a structure precisely similar to that of the outer layer of the allantois. It is therefore extremely probable that the primitive zona of homogeneous structure, after being thinned out to great tenuity by the continued expansion of the ovum, disappears entirely, and is replaced by a cellular membranous structure derived from the upper layer of the blastoderm, while the deeper fibro-vascular part proceeds from the outer layer of the allantois; and from this it necessarily follows that the chorion is no original component of the ovum, but an acquired or newly-formed structure developed from a union of epiblastic and mesoblastic elements.

**Endochorion or Vascular layer of the Allantois.**—The separation of the outer vascular layer of the allantois from the deeper layer (hypoblast)

Fig. 517.



which contains the fluid, is sufficiently obvious in many animals, as, for example, in the sheep or pig. But in the human subject, assuming that the vascular elements of the chorion are derived from the allantois as in animals, which there is no reason to doubt, it has been found difficult to determine the exact manner in which they first pass into the villi, in consequence of the very early time and extreme rapidity of the development of the allantois. But notwithstanding the observations previously mentioned of a nonvascular pediculated vesicle in relation with the allantois, passing from the umbilicus of the embryo into the space between the amnion and chorion; yet, in the great majority of instances, so rapid is the expansion of the membrane, that even in ova of from three to four weeks old it has been found impossible to trace more than the connection of the pedicle of the allantois through the urachus with the genito-urinary sinus; and in all the cases which have been observed, already the umbilical vessels are found detached from the deeper membrane, and passing widely over the whole interior of the chorion to penetrate everywhere into its villi. We are led thus to suppose that by the early and rapid expansion of the outer layer, or by some other mode of development of its fibrous and vascular elements, the blood-vessels of the human allantois have been brought into combination with the cellular layer of the chorion, and have penetrated everywhere into its villi, into the whole of which blood-vessels and fibrous elements may at first be traced. According to this view it is to be understood that while the vascular layer of the allantois may thus become widely diffused, the vesicular or deeper layer may have only a comparatively restricted range of development.

#### UTEROGESTATION: PLACENTATION.

**Incapsulation of the Ovum in the Decidua.**—The further history of the chorion may be best given along with that of the structures by which the ovum is fixed in the uterus, and organic union established between it and the maternal system. This union is effected by the close interpenetration of the vascular villi covering the surface of the chorion with a soft and spongy layer of substance, which is the product of a rapid enlargement or a sort of hypertrophy of the lining membrane of the uterus. To the latter substance the names of *decidua* and *calua* are given, from the circumstance that it is separated from the uterus at birth along with the fœtus and its membranes. Not only is the ovum from an early period completely imbedded in a covering of decidua, but there takes place at a somewhat later period of uterogestation, in a limited area of one side, a greater enlargement of the vascular chorionic villi, and in close combination with, and surrounding these villi, a corresponding increased development of the decidual substance, by which there is produced the large discoid mass of complex structure, named the *placenta* (or uterine cake), through which the nourishment of the fœtus and the aëration of its blood are mainly carried on during the latter three-fourths of the period of uterogestation.

This placenta continues to increase in size with the fœtus and its membranes, and as pregnancy advances, considerable changes take place in the relations of some of these parts, for the fuller comprehension of which it will be necessary to state the successive steps by which the ovum becomes fixed in the uterine decidua, or *incapsulated*, and the manner in which the development of the chorion, decidua, and placenta proceeds.

**Earliest Observed Human Ova.**—In two distinct cases of young

unimpregnated women who died at the time of the invasion of the menstrual flow, Mr. H. Letheby detected an ovum covered by the granular cells in the first part of the Fallopian tube, on the same side on which a ruptured follicle was found in the ovary (Trans. Roy. Soc. Lond. 1852, p. 7). But the fecundated human ovum has not yet been traced in the course of its descent in the Fallopian tube, nor has it, indeed, been seen in a satisfactory manner previous to the time when it is already imbedded in the uterine decidua. The history of the most authentic cases of the earliest ova observed in this state leads to the conclusion that the fecundated human ovum does not reach the cavity of the uterus before the seventh or eighth day after its escape from the ovary; and that already by the twelfth or thirteenth day, if not even sooner, it has acquired a chorion covered with villi, and has become imbedded in the decidua.

The human ovum, like that of mammals generally, probably undergoes very little enlargement during its descent through the tube and the occurrence of segmentation, and its diameter on arriving in the cavity of the uterus does not probably surpass one hundredth, or at most one eightieth of an inch. A very rapid expansion, however, of the whole ovum no doubt occurs immediately after its entrance into the uterus, in the same manner as observed in a number of mammals, so that within two or three days, its size may have increased to ten or twelve times its original diameter. Having at first only the zona pellucida for its external envelope (or primitive chorion), and being nearly smooth on the surface, it soon acquires, by a process previously described, its new chorion, on which are formed the permanent villi; and by the time when it has become incapsulated, according to Reichert's observations in the recently published very careful description of an ovum which was probably of the thirteenth or fourteenth day after impregnation, it has a diameter of nearly one-fourth of an inch, and is beset with villi over a considerable part, but not the whole of its surface (see fig. 517).

Several other examples of incapsulated ova of nearly the same period have been observed, as by Von Baer, Velpeau, Wharton Jones, Coste, and Allen Thomson; but in all these, with the exception of one observed by Velpeau, and supposed to be of the tenth day, or earlier, the whole surface of the ovum was already uniformly covered with short thick set chorionic villi.

The ova observed by Velpeau and Wharton Jones were like that described by Reichert of a period previous to the formation of an embryo, and may be stated as probably of from ten to fourteen days old. (Velpeau, "Ovologie Humaine," Paris, 1833; Wharton Jones in "Trans. Roy. Soc. of Lond.," 1837, p. 339; Reichert, "Besch. einer Frühzeit. Menschl. Frucht, &c.," Berlin, 1873.) Those of Von Baer, Pockels, Coste, and Allen Thomson are of the period immediately following, or from fourteen to eighteen days after impregnation. (Von Baer, "Entwickelungsgeschichte," p. 270; Pockels in "Oken's Isis," 1825; Coste, "Hist. Gén. et Partic. du Développement," 1847; Allen Thomson, "Contrib. to the Hist., &c., of the Human Ovum before the Third Week after Conception," in "Edin. Med. and Surg. Journ." No. 140.)

**Formation of Decidua.**—Before the arrival of the ovum in the uterus, the lining membrane of that cavity undoubtedly undergoes a preparatory change, by which the formation of the decidua is commenced, and this change, in its first stages, or up to the time of the

arrival of the ovum in the uterus, corresponds closely with that which takes place at every successive menstrual period in the uterine membrane. This process consists essentially in a thickening or hypertrophy of the lining membrane, and is mainly due to an extremely rapid proliferation of the subepithelial cells and fibro-cellular tissue, and an increased development of the blood-vessels and glands.

Fig. 518.

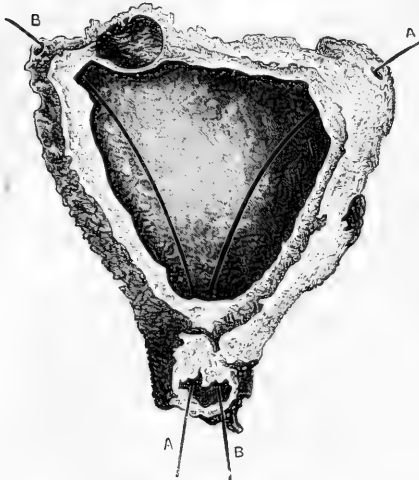


Fig. 518.—THE DECIDUA OPENED AND VIEWED FROM BEFORE (after W. Hunter).

This is a representation of the thickened membrane of the uterus thrown off as the product of abortion at a very early period of gestation. A and B mark superiorly the passage of two bristles through the openings from the Fallopian tubes into the cavity of the uterus (cavity of the decidua), and inferiorly the exit of the bristles at the os uteri. In these three situations the torn edges are seen where the decidua has been separated from the continuous part of the mucous membrane. At *o*, where an ovum has probably been lodged, the inner part of the decidua is made to bulge towards the cavity of the uterus, and begins to form decidua reflexa.

The formation of a complete decidua within the uterus has been observed in several cases in which, although the ovum was not discovered, or had not yet arrived in the uterus, there was reason to believe impregnation had occurred six or eight days previously. (Von Baer, E. H. Weber.) And a similar condition has been observed in several examples of extra-uterine pregnancy (Hunter and others); from which it appears that the earlier changes connected with the formation of the decidua are independent of the presence of the ovum in the uterus.

When the ovum has been recently imbedded in the decidua, it forms a swelling or projection of the surface within the uterine cavity, on an opening into which the villous chorion is found surrounded by the substance of the decidua or thickened mucous membrane; but the covering of this substance which passes over the free surface of the ovum, or that which is towards the uterine cavity, is thinner and simpler in its structure than at the place of attachment of the ovum and in other parts of the uterine surface.

The most projecting part or summit of the swelling formed by the imbedded ovum more especially is somewhat different from the rest, and indicates, by a sort of cicatricial mark, a place where the substance of the decidua, as it gradually covered in the ovum, may be supposed to have finally closed.

The decidual thickening of the mucous membrane affects nearly equally the whole of the lining of the uterine cavity, but towards the

os internum, and the openings of the Fallopian tubes, the thickening gradually decreases, and the membrane assumes the unaltered condition which is maintained in these passages.

By the fifth or sixth week, when the ovum has reached a diameter of

Fig. 519.

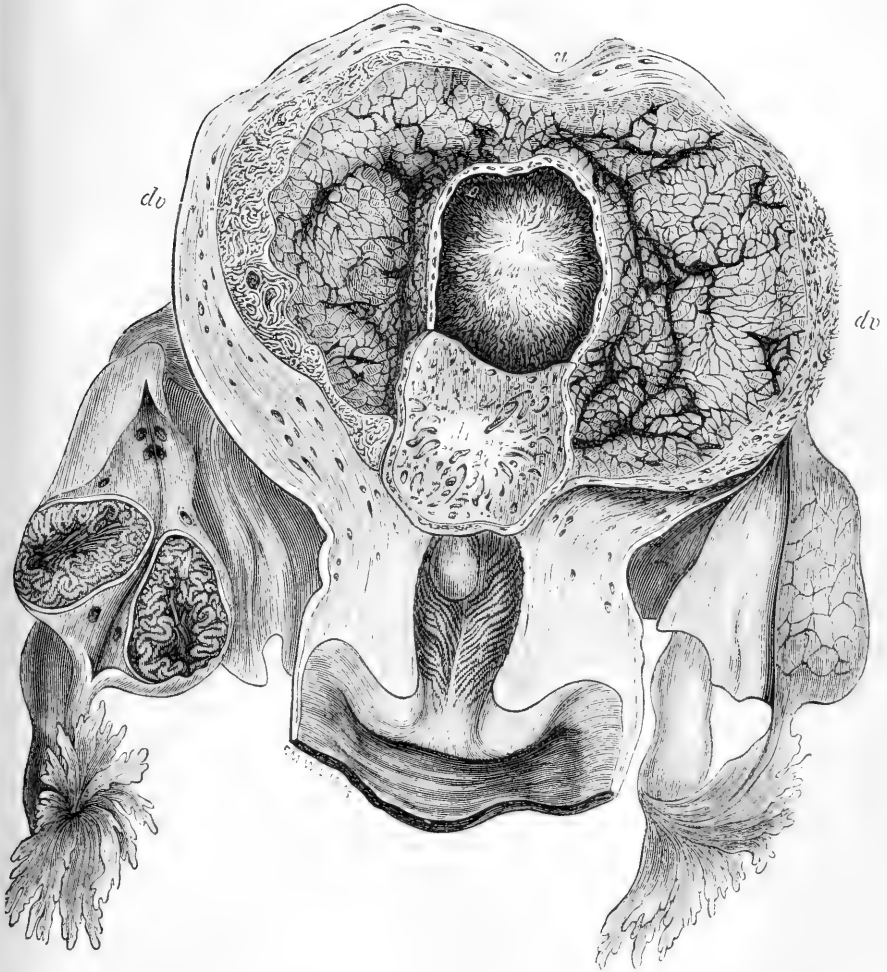


Fig. 519.—VIEW OF THE INTERIOR OF THE HUMAN GRAVID UTERUS AT THE TWENTY-FIFTH DAY (from Farre after Coste).

*u*, uterine wall; *o*, villi of the chorion of the ovum; *dv*, decidua vera and enlarged uterine glands; *dr*, decidua reflexa, divided round the margin of the ovum, and turned down so as to expose its pitted surface, which has been removed from the ovum. The right ovary is divided, and shows in section the plicated condition of the early corpus luteum.

Fig. 520.

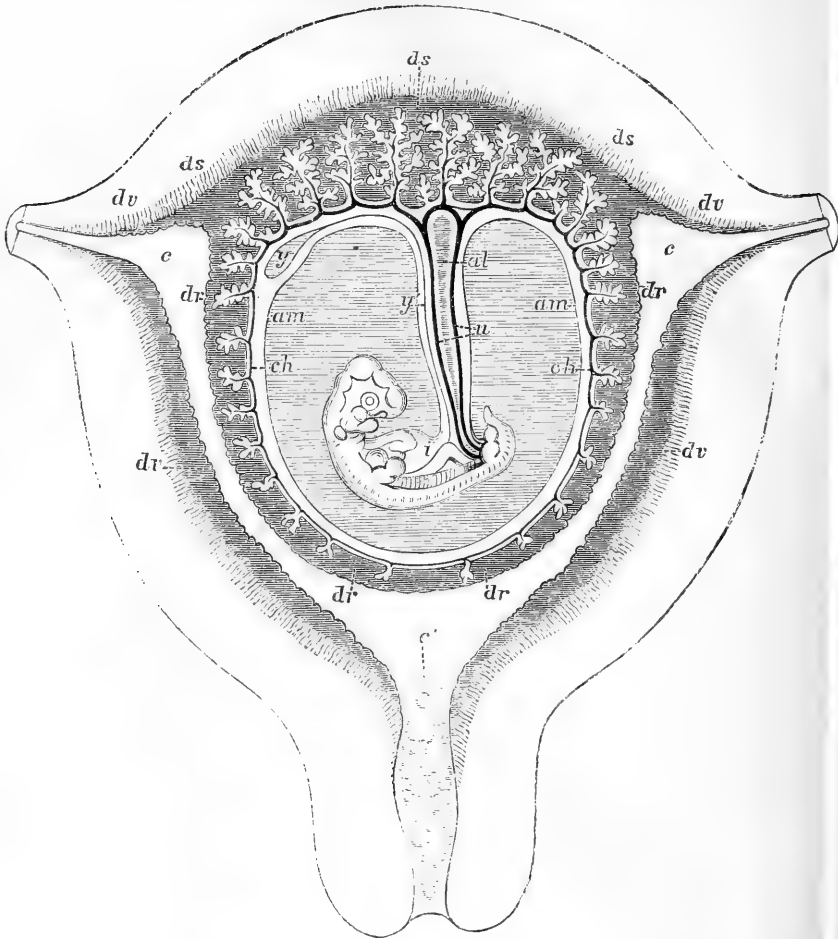


Fig. 520.—DIAGRAMMATIC VIEW OF A TRANSVERSE SECTION OF THE UTERUS AT THE SEVENTH OR EIGHTH WEEK OF PREGNANCY.

*c, c, c'*, the cavity of the uterus which becomes the cavity of the decidua, opening at *c, c*, the cornua, into the Fallopian tubes, and at *c'*, into the cavity of the cervix, which is closed by a plug of mucus; *dv*, decidua vera; the flat shade indicates the thickened subepithelial structure, the radiated lines the glandular tubes between this and the muscular wall; *dr*, decidua reflexa with the sparser villi imbedded in its substance; *ds*, decidua scrotina, involving the more developed chorionic villi of the commencing placenta, and forming also between these and the muscular wall a layer outside which the glandular tubes are represented; *ch*, chorion, with its villi; *u*, umbilical vessels of the fetus passing into these, and in the umbilical cord; *al*, remains of the allantoic pedicle; *am*, amnion; *y*, umbilical vesicle; *y'*, its duct, connected with *i*, the intestine of the embryo. The placenta is shown as if it were situated at the fundus, but may be supposed to be on the posterior wall of the uterus.

from an inch to an inch and a half, and the uterus has nearly doubled the size which it presents in the unimpregnated state, the swelling formed by the ovum and decidua projects strongly like a tumour within the uterine cavity. The membrane of the other parts of the uterus has also undergone progressive increase in its thickness by decidual hypertrophy, so that, having become, as it were, too wide for the capacity of the cavity, it is thrown into a number of grooves enclosing irregular folds and mammillary projections, but still exhibiting throughout the peculiar features of the mucous lining membrane.

On the side of the ovum which is towards the uterine wall, there is also a layer of decidua, in which the villi of the chorion are imbedded. At this place, from the sixth to the eighth week, these villi begin to be more thickly set and of larger size, and to undergo a more complex ramification than on the other sides; and as at the same time there is a corresponding increase in the decidual substance, these villi become more and more closely involved in it, and there is thus established the commencement of that more intimate combination of foetal villi and decidual substance, which by its progressive development in the two or three following weeks, gives rise to the formation of the placenta.

By the changes now described there has become apparent the distinction of the three portions of decidua usually recognised by authors, viz., *decidua vera*, *decidua reflexa*, and *decidua serotina*. The first of these is that portion of the altered membrane which lines the general cavity of the uterus in every part except that occupied by the attachment of the ovum; the decidua reflexa is that which covers the ovum as it projects into the uterine cavity, and which is continuous with the decidua vera at the base of the swelling.

The name of *decidua serotina* has been somewhat variously employed by authors; but may, in the meantime, be most suitably applied to the whole of the decidual substance intervening between the ovum and the uterus, and which may include, therefore, both that which is concerned in the formation of the placenta, and the distinct layer of decidual substance which at a later period is found covering the uterine surface of the placenta.

The cavity of the decidua, which intervenes between the decidua vera and decidua reflexa, and which subsists during the first half of the period of pregnancy, is obviously the same as the original uterine cavity, and, so long as it remains open, naturally communicates with the Fallopian tubes at the upper angles, and the canal of the cervix at the lower. In the last three months of pregnancy, however, this cavity is completely obliterated by the union of the decidua vera and reflexa into one layer over the whole of their extent, so that when afterwards much extended and reduced to a comparatively thin and irregular stratum of substance, they are at birth thrown off as one membrane along with the other envelopes of the foetus.

As the human ovum has never been observed in the progress of its incapsulation, the exact manner in which this occurs is still involved in doubt. From the various observations, however, already referred to on early ova which have undergone recent incapsulation, and the knowledge of what occurs in animals, it may be conjectured, as first suggested by Sharpey (Baly's transl. of "Müller's Physiology," 1842, p. 1580) that the minute ovum when it arrives in the uterus may be sunk or imbedded in the soft or spongy substance of the mucous membrane, and

that when it subsequently enlarges it carries with it, or there is formed round it a covering of the membrane, the substance of which is at the same time undergoing a rapid decidual development, and that this substance continuing to grow with the ovum and expanding with it, constitutes the decidua reflexa. The entire similarity of the structure of the decidua reflexa at its base with that of the decidua vera is in favour of the view that it owes its origin to a similar mode of production.

The formation of the decidua is, as has already been stated, to be attributed mainly to a great increase in the development of the sub-epithelial tissue. Its substance, accordingly, consists in great measure of the cells, round and spindle-shaped, and cell-fibres which belong to that tissue; but these are mingled with much larger irregularly-formed multi-nuclear cells, which increase in number as pregnancy advances, and which are peculiarly characteristic of the structure of the outer layers of the decidua.

The blood-vessels and the glands of the mucous membrane also undergo great enlargement and modification. The whole of the decidua vera and the basilar part of the reflexa are at first penetrated by blood-vessels derived from those of the uterus, more especially in the latter part of the second and first half of the third months, when the decidual structure may be considered as having reached its highest degree of development. After this time the blood-vessels of the decidua reflexa, and later those of the whole lining decidua of the uterus, except in the immediate vicinity of the placenta, shrink and ultimately disappear, so that the united decidua becomes in the end wholly non-vascular. The same retrograde process, or atrophy and disappearance, occurs in the blood-vessels of the chorionic villi by which the decidua reflexa is penetrated, and, although the villi themselves never entirely disappear, but may be traced even in the advanced stages of pregnancy as sparse and shrivelled irregular arborescent processes, the blood-vessels very soon begin to shrink and disappear from all the villi which do not form part of the placental structure.

The uterine glands also become enlarged during the development of the decidua, being both elongated in their deeper convoluted portions, which are directed towards the muscular wall of the uterus, and undergoing a peculiar change not yet fully understood, in the parts next their openings on the inner surface. Over the surface of the whole decidua vera, as it lines the uterine cavity, and also on the decidua reflexa, except at its most projecting part, a number of irregular pits are visible to the naked eye, which are frequently so numerous as to give the membrane a reticulated or sieve-like appearance (cups of Montgomery). These pits are really the uterine glands enlarged and altered soon after the commencement of pregnancy, as first clearly shown by Sharpey (Müller's Physiology by Baly, 1842, p. 1579), and the fact has since been observed by others (Kölliker, Coste). The villi embedded in the decidua do not, however, occupy the cavities of these pits, but so far as yet ascertained, are rather sunk in the inter-glandular hypertrophied substance of the decidua between them (Schröder van der Kolk, Kölliker, and Priestley. See the lectures by the latter "On the Development of the Gravid Uterus," 1860, p. 24). Upon the more exact relation of the villi to the uterine glands in the placenta, further remarks will be made hereafter.



From what has been previously stated, it will be seen that there is at first a general union or interpenetration of the villi of the chorion with the vascular decidua, the more extended part of this union taking place in the decidua reflexa, and the remainder in that portion of the decidua which is interposed between the ovum and the uterus, and which has been already referred to as decidua serotina, but which might from its relation to the formation of the placenta with propriety be named *decidua placentalis*. Already in the latter half of the second month of pregnancy, the villi on the uterine side of the chorion become larger and more ramified than those which run into the decidua reflexa; and

Fig. 521.

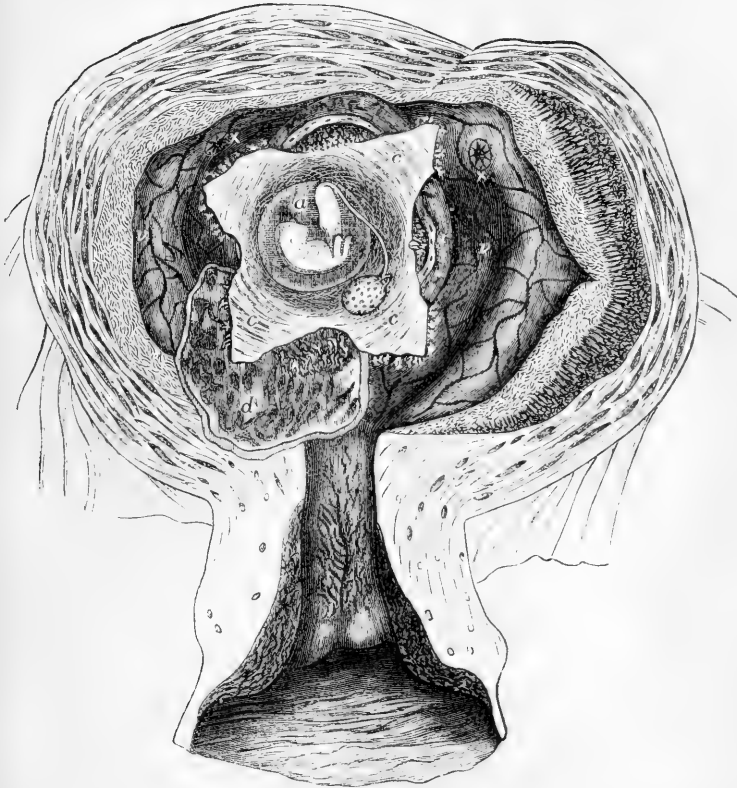


Fig. 521.—VIEW OF THE DISSECTION OF THE PREGNANT UTERUS OF FORTY DAYS AFTER CONCEPTION (from Leishman after Coste).

*a*, the embryo shown within the amnion; *c*, the chorion opened, the umbilical vesicle seen lying between it and the amnion; *d*, deep surface of decidua reflexa where it has been turned back from the ovum; *r, r*, remainder of the decidua reflexa projecting from the uterine surface; *v*, decidua vera, of which the glandular structure is shown in the cut edges; *x x*, openings of the Fallopian tubes seen within the uterus. In the uterine wall the distinction is shown between the outer muscular part with the wide uterine vessels, and the glandular and decidual internal parts.

as these latter, while they still continue to grow to some extent, do not increase in number, or in the complication of their ramifications, they gradually become more sparse, thin, and elongated, and lose their vascularity.

An active process of increase meanwhile is going on in the villi placed on the uterine side of the ovum, by which, while they become larger and longer, and penetrate more deeply into the uterine decidua, they also become more minutely and extensively ramified. Changes at the same time occur in the disposition of the decidua placentalis, by which it receives into its substance, and is more and more intimately interlocked with the developing chorionic villi. In the earlier stages, as up to the eighth or ninth week, the foetal and maternal structures may be separated by the withdrawal of the villi from the recesses of the decidua in which they are sunk; but by the middle of the third month, this becomes no longer possible in consequence of the closer combination or interlocking of the two structures; in the remaining half of the third month the union becomes more intimate, and by the middle of the fourth month the completion of the placenta is effected by the continued increase in size and modification of the structure of the maternal and foetal elements.

**Structure of the Placenta.**—At the time when the placenta has attained its characteristic form and peculiar structure, or after the fourth month of pregnancy, it forms a large discoid or lenticular mass interposed in a limited space between the foetal membranes and the uterus. It presents a foetal and a uterine surface, the former having implanted into it, usually near the middle, the umbilical cord, which carries to the placenta the umbilical arteries and veins of the foetus, and is covered by a tubular prolongation of the amnion, passing over it from that membrane where it lines the placenta to the abdominal integument of the foetus. The placenta continues to increase in size with the foetus, and when it has attained its full dimensions, it has a width of from seven to eight inches, and a thickness of about one inch and a quarter. But towards the circumference it rapidly thins, where it becomes continuous with the chorion and decidua. The foetal surface is covered by the chorion and amnion, and presents the larger divisions of the umbilical vessels before they dip into the substance. The uterine surface shows a subdivision into a number of large lobes, sometimes called cotyledons, which are covered with a layer of decidua (*d. serotina*) passing over the whole of this surface, and sending septal prolongations into the placenta between the lobes, which in some places run almost as far as the foetal surface.

The more uniform substance of the placenta (parenchyma) within these lobes, consists, on the one hand, of highly-developed and complicated tufts of foetal villi, which adhere to the chorion by vascular stems of considerable size and strength, and subdivide again and again into very complex ramifications; and on the other, of certain dilated vascular spaces continuous with the uterine vessels, the outlines of which follow closely the ramifications of the villi throughout every inflection of their surface. These spaces are doubtless to be regarded as belonging to the maternal system, but their exact nature it is very difficult to determine in the fully formed condition. They probably originally possess walls of their own, and are contained in a bounding substance of uterine or decidual tissue; but this has become so reduced in thickness, or so

closely united with, and so nearly assimilated in its structure to the villi, that it has been found difficult to follow it with certainty, and its existence has even by many been entirely denied. The relations of these two parts of the placenta, as ascertained by the observation of their gradual development in the growth of the placenta, and their comparative anatomy in animals, will be referred to hereafter.

The whole of the placental mass, together with the layer of decidua on its external or uterine surface, and the united decidua vera and reflexa are separated at birth along with the fœtus and its membranes.

Fig. 522.

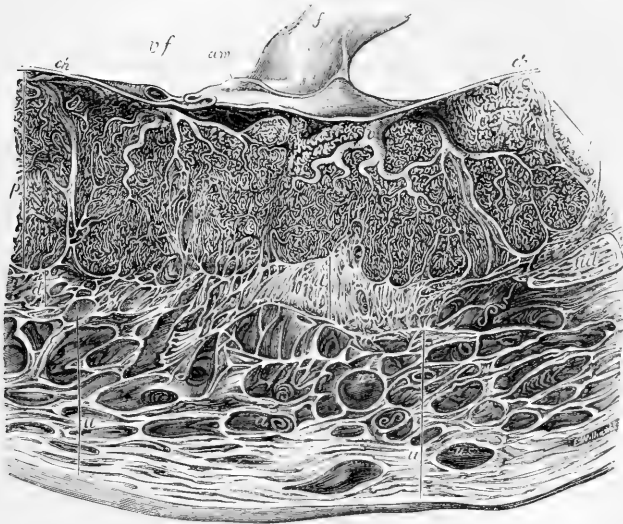


Fig. 522.—VERTICAL SECTION THROUGH THE MIDDLE PART OF THE PLACENTA AND THE UTERINE WALL (from Faure after Wagner).

The preparation was from a woman who died in the thirtieth week of gestation: the fœtes *u, u*, run through the wall of the uterus to the outer surface of the placenta; *d*, the decidua serotina; *p*, the tufts of fœtal vascular villi, of which two larger divisions are separated by decidual septa, as at *dp*; *f*, the placental end of the umbilical cord; *am*, the amnion; *ch*, the chorion; *vf*, divided fœtal blood-vessels; *v*, stems of vascular villi; *us*, uterine sinuses or veins; *a, a*, coiled arteries passing into the placenta.

**Circulation of blood in the placenta.**—The existence of a distinct circulation of blood in the fœtal and in the maternal vessels of the placenta, discovered by the Hunters, has long been placed beyond doubt by the experimental investigations of all those who have injected the two sets of vessels with sufficient care and success. The nature of the distribution of the vessels is very different in the two parts of the placenta. In the tufts of fœtal villi, the umbilical arteries and veins, possessed of distinct coats, undergo gradual subdivision by ramification into smaller and smaller tubes, until they at last reach capillary minuteness, and the terminal capillaries run in long and tortuous loops which

pass from one extreme branch of the villi to another, within the fibrous core of which they are situated, and Schröder van der Kolk has described also a finer superficial network of capillaries distributed below the epithelial covering of the stems and larger branches of the villi. By artificial injections fluids can be made to pass with perfect precision from the umbilical arteries through the capillaries of the villi into the veins, or in the reverse direction from the veins into the arteries. Nor does there ever occur, except from visible accidental rupture of the vessels, either extravasation of the injected material into the intervening tissue, nor any escape into the maternal sinuses.

Fig. 523.




Fig. 523.—SMALL PORTION OF PLACENTA SHOWING THE FETAL VILLI SLIGHTLY MAGNIFIED (from Leishman after Weber).

The uterine blood-passages, on the other hand, are of the nature of irregular spaces, into which the maternal blood is poured directly by numerous small coiled arteries which, as shown by the Hunters, pierce

the external decidua at the uterine surface of the placenta, and open into these blood-spaces without the intervention of any capillary sub-

Fig. 524.




Fig. 524.—CHORIONIC VILLUS FROM THE PLACENTA AT THE TWELFTH WEEK. ENLARGED 180 DIAMETERS (from Leishman after Ecker).

From *a* to *b*, the epithelial covering is left entire; from *a* to *a'* it has been removed and the fibrous core with the capillary blood-vessels is shown.

division. The result of artificial injection of the blood-vessels in the pregnant uterus equally demonstrates the nature of the circulation in the maternal part of the placenta, for it is easy to show by this method, that a fluid thrown into the uterine arteries fills at once all the maternal blood-spaces of the placenta, surrounding everywhere the chorionic or fetal villi, and returns thence into the uterine veins by a number of slanting venous channels, the *utero-placental sinuses*, provided with delicate coats, which issue from the placenta at its

uterine surface by piercing the decidua serotina, and which are most numerous towards the circumference of the organ, where they are in communication with the so-called circular vein or circular sinus previously referred to. Some of these veins may even be traced for some distance into the placenta, in the septa of decidual substance, which are pro-

longed from the external decidua serotina between the lobes. (For an excellent account of the evidence in favour of the foregoing views, supported by original observations, see Professor Turner's observations on the "Structure of the Human Placenta," in *Proceed. Roy. Soc. of Edin., May, 1872*, and in *Journ. of Anat., vol. vii., p. 120.*)

**Farther Consideration of the Structure of the Placenta.**—Two doubtful points respecting the structure of the placenta still require consideration, viz., 1st, the extent to which uterine tissue is included in or penetrates into, or remains as a constituent of the maternal part; and 2nd, the relation of the interpenetration of the fetal villi and the uterine decidua to the glandular or other structures of the uterus.

In regard to the first of these points, the views of anatomists still differ greatly; for, on the one hand, some hold that there is no vestige of uterine tissue left in connection with the maternal blood-spaces, at all events in the deeper two-thirds of the thickness of the placenta, and that consequently the maternal blood circulating in the placenta is in direct contact with the epithelial covering of the foetal villi; while others are inclined to regard that epithelial covering, or some part of the structure which appears to belong to the foetal villi, as really containing some of the elements of the decidua.

Goodsir, indeed, described a double cellular covering of the placental villi, regarding the external layer as of uterine, and the internal as of foetal origin. But later anatomists have not succeeded in confirming these observations, and it does not appear certain that there is more than one obvious layer of cells over the surface of the foetal villi. If, therefore, we assume the existence of a layer of uterine cells in the fully formed placenta, we are reduced to the necessity of supposing that it has either replaced that of the chorionic villi, or has become closely incorporated with it (Kölliker).

The observation of the gradual penetration of the decidua by the villi in the earlier stages of placental formation, the possibility of separating the foetal and maternal structures from each other during a certain time, and the undoubted presence both of decidual tissue and of uterine blood-vessels possessed of walls of their own in the commencement,—all supply convincing proof that uterine elements of structure have originally existed in the placenta, and have contributed to its formation along with those derived from the foetus; but the condition of the uterine elements in the more advanced stages of placental growth, if they really then exist, still requires further investigation.

The actual enlargement of the uterine capillaries of the decidua into the form of vascular spaces has been traced by Virchow (*Archiv*, vol. iii. p. 450), and Priestley has observed the capillary form of the maternal vessels surrounding the villi in a product of abortion of the 8th week (*Lectures on the Development of the Gravid Uterus*, 1860, p. 62). Some anatomists, indeed, as Schröder Van der Kolk, affirm that they have been able to detect the remains of a vascular wall in connection with the blood-spaces of some parts of the placenta (*Waarnemingen over het Maaksel van de Menschelijke Placenta*: Amsterdam, 1861), so that it may with reason be surmised that the change which takes place in the structure of the parts forming the human placenta, in the course of the fourth month, is mainly of the nature of a rapid thinning and absorption of the elements of the decidual tissue and vascular walls.

The view that the placenta originally consists of uterine as well as foetal elements combined receives the fullest confirmation from the study of the comparative anatomy of the various forms of simple placental structures in animals, as, in the *diffuse* placenta of the pachydermata, solipeds, cetacea and some other animals, and in the *cotyledonous* placenta of most ruminants; in both of which only the foetal part of the placental structure undergoes separation from the uterus at birth,—constituting the *non-deciduate* form of placentation; and in the various forms of more complete union of the foetal and maternal elements, which occur in the *zonal* placenta of the carnivora, and the *discoid* of the rodentia, in which more or less of the maternal structure derived from decidual formation comes away with the foetal product at birth. But in all forms of placentation of

animals, with the exception of the Simiac, in which the structure probably agrees closely with the human, the elements of uterine structure are very clearly present, and the uterine blood-vessels may be recognised as such, not being dilated into wide sinuses or lacunæ, but retaining more or less the capillary form of distribution; although in some instances the capillaries have undergone considerable dilatation, and seem to be passing into the condition of venous sinuses. (For a very instructive view of the structure of the placenta in these various animals and their bearing upon the nature of the placental structure in general, the reader is referred to Professor Turner's Lectures on the Structure of the Diffused, the Polycotyledonous and the Zonary forms of Placenta, as published in the *Journal of Anatomy and Physiology*, vol. x., p. 127, Oct. 1875, and separately, 1876. There may also be consulted Von Baer's *Entwicklungsgeschichte*. 1839, and Eschricht. *De organis quæ Respirationi et Nutritioni Fœtus Mammalium inserviunt*, Hafniæ, 1837.)

*Relation of the Uterine Glands to the Placental structure.*—It has long been known that in the placentation of various mammals the uterine glands undergo an increased development, and it has been supposed that they enter into structural and functional relation with the foetal villi; but more precise knowledge is still wanting as to whether, and to what extent this relation is of the nature of an actual penetration of the cavities of developed and dilated glands by the chorionic villi. It was shown by Dr. Sharpey (*Müller's Physiology by Baly*, vol. ii. p. 1574) that the decidua which enters into the formation of the zonular placenta of the dog, and doubtless of other carnivora, consists of a hypertrophical part of the uterine mucous membrane of corresponding figure, in which the main ducts of the largely developed glands become dilated at their orifices into utricular saccules or pouches, that hollow membranous processes containing foetal vessels rise from the chorion, from among the smaller vascular villi, and apply their flattened summits to the widened mouths of the gland ducts, and enter a short way within the saccules; while these receptacles are filled with a whitish semi-fluid secretion and are lined with an epithelium, which also covers the intruded part of the foetal process. As pregnancy advances, the chorionic and decidual structures are further interlocked, and the arrangement becomes more intricate. Decidual, that is, maternal blood-vessels are abundantly distributed round the villi of the chorion, which they closely cover. These vessels are larger than ordinary capillaries; they are unsupported by decidual stroma, and are separated along with the rest of the placenta in parturition.

The observations of Sharpey appeared to receive confirmation from the investigations of E. H. Weber (*Zusätze zur Lehre vom Baue, &c., der Geschlechtsorgane*, 1846,) and Bischoff (*Entwick. des Hundeeies*, 1845,), and by many these observations have been held to prove satisfactorily a connection between the glands and placental formation. But Dr. Sharpey has expressed himself cautiously on this general question, and more recent observations tend rather to throw doubts on the penetration of the uterine glands by the villi of the chorion.

More especially the observations of Ercolani (*Mem. of the Acad. of Bologna*, 1868 and 1870) and of Turner (*loc. cit.*) seem to show that it is possible that the saccules described by Sharpey may be formed in the uterine decidua of the carnivora independently of the glands; and they are disposed to think that these saccules are produced rather in the interglandular tissue. From an examination of the whole evidence on this point and an investigation of the structure and formation of the placenta in different animals, contained in the lectures previously quoted, Turner has ascertained that in the diffused form of placenta the uterine glands open in the sow into feebly vascular intervals between the vascular crypts in which the foetal chorionic fringes are sunk, and not into these crypts themselves; that in the mare the glands open on elevated ridges between the vascular crypts which receive the foetal villi, and only in the Cetacea (*Orca gladiator*) did he find gland apertures in some of the placental crypts. Again, the maternal cotyledons of the ruminants are destitute of utricular glands, and these are confined to the sunk intercotyledonous part of the uterine membrane. In the zonal placenta of the carnivora, as previously stated, Turner failed to trace the uterine glands into the recesses of the decidua which receive the prolongations of the chorionic plates and villi, constituting the foetal portion of the placenta; and

he differs therefore from Sharpey in regarding the crypts as of new formation and independent of the glands. He is thus led to the general conclusion that in no kinds of placenta do the uterine glands form an essential part of the placental structure, and that the uterine crypts which receive the foetal processes are essentially interglandular in their origin. Nevertheless Turner recognises the existence in all placentas of uterine structural elements of a cellular nature, which he regards as descendants of the epithelial or subepithelial tissue of the uterine mucous membrane, and to which he attributes, as others have done, glandular functions in the preparation of the matter which is absorbed as nourishment by the blood-vessels of the foetal villi. Further observations will be required to determine in how far these views admit of application to the structure of the fully formed human placenta. (See also Turner's Memoir on the Placentation of Seals. Trans. Roy. Soc. of Edinburgh. Vol. xxvii., 1875.)

With respect also to the relation of the uterine glands to the penetration of the decidua by the villi in the formation of the human placenta, further observations are still required. As previously stated, anatomists have failed to trace the villi into the dilated parts of the enlarged glands, and Kölliker after a careful examination of the whole subject, comes to the conclusion (Lectures, p. 162) that the villi in becoming involved in the decidua have no permanent connection with the glands. He affirms indeed that the glands soon shrink over the whole extent of the decidua, beginning to do so as early as in the second month of pregnancy, and have in great measure disappeared before the chorionic villi are fully connected with the uterine membrane. Reichert, however, in his recent description of an early human ovum affirms that commencing villi actually enter the mouths of uterine glands, and he has given a diagrammatic representation of the prolongation of the tubes of the uterine glands through the decidua to the surface of the membrane, and the small marginal villi of the ovum as actually within terminal portions of the glands, the cavities of which have undergone some degree of ramification. Further observations will, however, be necessary for the confirmation of a statement so much at variance with the results of most other observers.

**General conclusion.**—In recapitulation of the preceding description it may be stated that the human placenta is an organ which is formed by the combination of two different structural elements; of which one is derived from the fetus or its membranes, and the other from the uterus. The foetal part consists of the developed vascular villi of the chorion, continues to grow and extend itself with the foetus during the whole of uterogestation, and is the seat of a complete circulation of the foetal blood through the capillary ramifications of the umbilical arteries, veins, and capillaries. The uterine element of the placenta originates in a part of the decidua, which is produced by increased growth and transformation of the lining membrane of the uterus and its blood-vessels. With the hypertrophied structure so produced the villi of the foetal chorion at first interpenetrate, so that in the earlier stages of placental formation the uterine and foetal elements are for a time separable, and may still be distinguished from each other, at the period even when they have become more intimately united. But in the progress of development the uterine elements are so much modified, and finally so completely attenuated or removed, that they almost entirely disappear; and as along with them the walls of the blood-vessels are either thinned out to the last degree, or are entirely absorbed, there remain only the vascular spaces through which the maternal blood flows. A doubt, however, may still exist as to whether these spaces are, or are not, entirely deprived of any uterine enclosure.

The maternal blood is introduced into these spaces directly by the small coiled uterine arteries, without capillary intervention, and after

moving through the whole of the placental spaces in contact with or in closest proximity to the foetal villi, it is returned by numerous veins through the outer decidua serotina into the vascular channels of the uterus. This blood is essentially arterial in its qualities, and may be supposed to perform a double function, viz., 1. to exert an aërating effect on the blood of the fetus through the tissue of the villi and the walls of their minute vessels, and 2. to supply for absorption by the foetal vessels the new materials required in the continued nourishment of the foetus.

The continuity of the decidua vera and decidua reflexa with the decidua serotina, and of all three with the whole thickness of the placenta at its margin, sufficiently demonstrates the actual connection of the maternal elements in these several structures, and the existence of that connection is fully confirmed by tracing the steps of the primary formation and subsequent development of the two sets of placental elements, by which are ascertained the actual presence of both in the commencement, and the gradual modification and disappearance of the maternal part. The view thus arrived at receives further support from the result of the observation of the varieties of form and structure presented by the placental organisation in different animals.

**Separation at Birth and Restoration of the Mucous Membrane of the Uterus.**—In the act of birth the whole decidual structures which have been formed in human uterogestation are separated from the uterus along with all those belonging to the ovum, and the placentation is thus said to be completely deciduate. Thus in parturition, from the effect of the contraction of the uterine walls and the abdominal muscles, after the usual rupture of the foetal membranes and the discharge of the amniotic fluid, the foetus is first expelled: the placenta is next detached and pressed downwards, carrying with it the layer of serotina by which it is covered on its uterine surface, and along with it necessarily are broken through the coiled arteries and the slanting veins; the membranes of the ovum follow, consisting of the amnion and chorion, together with the shrunken covering of decidua which in the last stage of pregnancy remains from the union of decidua reflexa with decidua vera matted together into one, which is finally peeled off the whole of the interior of the uterus.

The uterus having now contracted and its cavity being greatly reduced in size, there remains, probably, on the uterine surface a part of the sub-epithelial or decidual structure of the mucous membrane, in irregular shreds rather than in one continuous layer, and in the deeper part are imbedded the convoluted uterine glands extending outwards into the layer of fibres formed by the muscularis mucosæ. These remains of decidua, with the clots of blood resulting from the rupture of the vessels, are gradually cast off with the lochia, a discharge which is at first of a mixed character, but gradually becomes more and more composed of corpuscles similar to the white blood globules, and this is succeeded by the closure and contraction of the vessels, the prolongation of the gland tubes to the surface, the formation of a complete ciliated epithelial lining to the cavity, and the complete restoration of the natural structure of the whole membrane.



## II. DEVELOPMENT OF PARTICULAR SYSTEMS AND ORGANS OF THE BODY.

### THE SKELETON AND ORGANS OF VOLUNTARY MOTION.

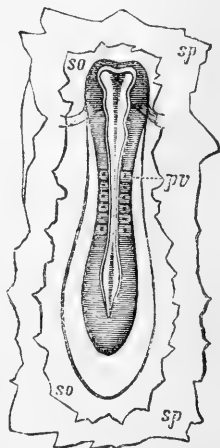
The morphological development of the skeleton and organs of voluntary motion is closely in accordance with the general plan of development which belongs to the whole vertebrate body. The first steps are connected with the formation of the strictly axial part, consisting of the enclosing walls of the cranio-vertebral cavity for containing the rudiments of the brain and spinal marrow, and for the issue of the successive pairs of nerves arising from them. These are succeeded by the formation of the walls of the great visceral cavities of the head and trunk, in which the facial and costal arches are to be distinguished; and lastly, the appendicular parts, or the limbs and limb-arches, are developed. The permanent forms of these parts are only produced in the process of ossification; but the rudiments of most of them are already to be distinguished in the masses of cartilage or formative tissue which precede the ossifying change.

As the mode of ossification of the several bones has been described in the osteological part of the work, and the histological view of the process of formation of bone has been given in the part on General Anatomy, the morphological view of the development will alone be referred to in this place, in which will be included the more important phenomena of the preparation of the matrix or formative material for the various parts of the skeleton.

Fig. 525.—EMBRYO OF THE DOG SEEN FROM ABOVE, WITH A PORTION OF THE BLASTODERM ATTACHED.

Fig. 525.

The medullary canal is not yet closed, but shows the dilatation at the cephalic extremity with a partial division into the three primary cerebral vesicles; the posterior extremity shows a rhomboidal enlargement. The cephalic fold crosses below the middle cerebral vesicle. Six primordial vertebral divisions are visible; *so*, the upper division of the blastoderm; *sp*, the lower division.



#### 1. VERTEBRAL COLUMN AND TRUNK.

**Relation of Vertebral Rudiments to the Notochord.**—It has already been shown (General Phenomena of Development, p. 692), that all the parts of the skeleton owe their primitive formative material to mesoblastic elements, and that the bodies and arches of the vertebræ, and the adjacent part of the cranial walls are formed from continuous blastodermic substance lying below and around the primitive medullary canal. A part also of

the basis of the cranium has this in common with the vertebral axis, that its formative substance surrounds the notochord, extending forward from the column of the vertebral bodies into the occipito-sphenoid part of the cranial basis, which is there composed of the formative substance termed the *investing mass* of Rathke.

It is to be remembered, however, that closely as the formative tissue

of the bone elements appear to surround the notochord, that structure does not itself, nor by its sheath, contribute to the formation of the vertebral or basi-cranial bones, but merely lies within them; and the formative material, out of which the bones are produced, is derived from mesoblastic substance which passes inwards from the primordial vertebral plates, and envelopes the chorda external to its sheath. The formation of the notochord, therefore, precedes that of the formative bone-elements which afterwards envelope it, and the remains of the notochord, unaffected directly by any ossifying change, are found in the interior of the commencing bones, and may be traced even for a long time throughout the whole length of the column of the bodies of the vertebræ.

This important fact was first demonstrated by H. Müller, of Wurtzburg, who showed further that the notochord did not pass through the anterior arch of the atlas, but was traceable directly from the body of the axis vertebra through its odontoid process, and thence into the basi-occipital and basi-sphenoid bones, reaching as far as the pituitary fossa. (Heinrich Müller, "Ub. d. Vorkommen von Resten des Chorda Dorsalis b. Menschen nach der Geburt," in "Zeitsch. für Rat. Med.," von Henle u. Pfeifer, 1858, b. ii. See also Gegenbaur, "Untersuch. ub. Vergleich. Anat. Das Kopfskelet der Selachier," Leipzig, 1872. W. Müller, "Bau der Chorda Dorsalis," in "Jenasch. Zeitsch." b. vi. E. Dursy, "Zur Entwick. des Kopfes," 1869, and Mihalkovics, "On the Chorda and Pituitary Body," in "Archiv für Mikroskop. Anat.," b. xi., 1875.)

It may be mentioned further, as the result of H. Müller's observations, that though in general the chorda passes through the middle of the vertebral bodies, the position was found subject to variation in the caudal portion of the column, where it sometimes passed above, and at other times below, the vertebral bodies.

The notochord itself has been generally held to be produced from an intruded central column of mesoblastic cells, and this seems to be the mode of origin in birds; but it may be doubtful whether it is the same in all animals. In sharks Balfour finds that there is no median column derived from the mesoblast, and attributes the origin of the notochord to the hypoblast (Quart. Journ. of Microscop. Sc., Oct. 1874). The same origin is ascribed to it in mammals by Hensen, who finds that the notochord is late of being formed in the rabbit,—an observation confirmed by Kölliker: Mihalkovics, on the other hand, is inclined to refer it in all animals to the epiblast. However this may be, the tendency of recent research appears to be to show that the notochord may be more nearly allied to epithelial structures than to cartilage with which it has generally been previously associated. It is at all events important to note that it is in many respects different from the parts ascertained to proceed from the mesoblast, that it never combines with their elements, and that there is no penetration of its substance by connective tissue or blood-vessels, as happens in all other parts derived from the mesoblast.

The interesting observations of Kowalevsky on the existence of a chorda dorsalis in Ascidia (Mém. de l'Acad. de St. Petersburg, tom. x. and xi., 1867 and 1868), would appear to show that this structure, and the type of development which accompanies it, are not confined to vertebrate animals, and that in them the notochord may present more of a merely vestigial character than constitute an important element in the formation of the skeleton. The constancy of its position and relations, however, is an important fact regarding its history.

The notochord does not undergo transverse segmentation in the same manner as the protovertebral plate does. It remains undivided to the last, but in the course of vertebral ossification it shows alternate diminutions and enlargements of its diameter, corresponding in number and position with the vertebral divisions. One of these enlargements is found between the odontoid process and the basi-occipital bone, and

another has been observed by Mihalkovics in the interval between the basi-occipital and the basi-sphenoid bones or their cartilaginous matrices.

Fig. 526.—VIEW FROM ABOVE OF THE EMBRYO-CHICK IN THE FIRST HALF OF THE SECOND DAY.

1, 2, the three primary encephalic vesicles; in front and to the sides the cephalic fold; crossing at 2 the fovea cardiaca; 3, the caudal extremity of the medullary canal dilated into a rhomboid form; 4, 4, six primordial vertebral divisions.

In front of this last swelling, the chorda is bent down below the base of the skull, and tapering to a fine filament, ends or is lost in the floor of the pituitary fossa. The enlargements now mentioned have some interest in connection with the question of the vertebral constitution of the skull.

**Segmentation of the Protovertebræ.**—The transverse vertebrate segmentation which occurs in the primary vertebral plates affects only that part of these plates which is formed of mesoblast. It begins at a very early period, as already stated, even before the close of the primary medullary canal, in the form of one or two, or it may be three short transverse transparent lines which separate a corresponding number of dark or condensed quadrilateral masses of the primitive vertebral plates. These quadrilateral masses, the so-called *primordial vertebræ* (Urwirbel of the Germans) (fig. 526, 4, 4), do not, however, correspond merely to the vertebræ of the skeleton, nor are they directly converted into their rudiments, but they are rather divisions equivalent

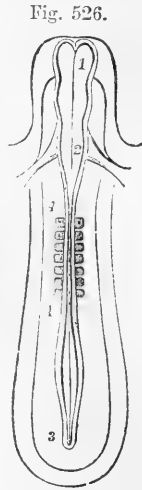


Fig. 526.

Fig. 527.—CERVICAL PART OF THE PRIMITIVE VERTEBRAL COLUMN AND ADJACENT PARTS OF AN EMBRYO OF THE SIXTH DAY, SHOWING THE DIVISION OF THE PRIMITIVE VERTEBRAL SEGMENTS (from Kölliker after Remak).

1, 1, chorda dorsalis in its sheath, pointed at its upper end; 2, points by three lines to the original intervals of the primitive vertebræ; 3, in a similar manner indicates the places of new division into permanent bodies of vertebræ; c indicates the body of the first cervical vertebra; in this and the next the primitive division has disappeared, as also in the two lowest represented, viz., d and the one above; in those intermediate the line of division is shown: 4, points in three places to the vertebral arches; and 5, similarly to three commencing ganglia of the spinal nerves; the dotted segments outside these parts are the muscular plates.

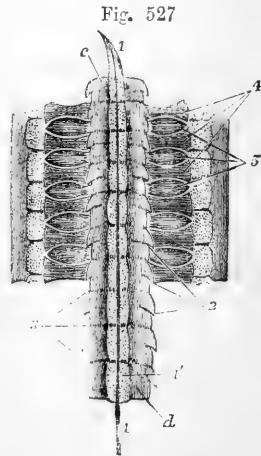


Fig. 527

in number and position to the vertebral segments of the body (somatomes of Goodsir); each one comprising superficially a segment of the muscular plate, and more deeply a pair of intervertebral ganglia and nerves, as well as the parts of the skeleton which lie before and behind them.

The more obvious protovertebral segmentation does not extend into

the mesoblastic tissue beyond the commencement of the basis of the cranium, the mass of blastema which there surrounds the prolongation of

Fig. 528.

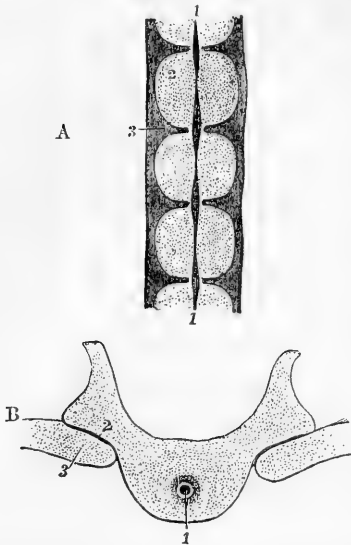


Fig. 528.—SECTIONS OF THE VERTEBRAL COLUMN OF A HUMAN FÆTUS OF EIGHT WEEKS (from Kölliker).

A, transverse longitudinal section of several vertebræ. 1, 1, chorda dorsalis, its remains thicker opposite the intervertebral discs; 2, is placed on one of the bodies of the permanent vertebræ; 3, on one of the intervertebral discs.

B, transverse horizontal section through a part of one dorsal vertebra. 1, remains of the chorda dorsalis in the middle of the body; 2, arch of the vertebra; 3, head of a rib.

the notochord (the *investing mass* of Rathke) remaining one and undivided, or being devoid at least of the marked cleavage which occurs in the strictly vertebral part.

It is from this protovertebral plate on each side, whether in its entire primitive condition, or in its later and divided state, that the material is derived for the formation of the

bodies and laminae of the vertebræ and the muscles which cover them. This is effected by the rapid increase of the mesoblast, and by the extension of that structure beyond the immediate confines of the vertebral laminae in an inward and downward direction, so as to throw a quantity of new mesoblastic material round the notochord, and inwards and upwards, so as to pass in between the primary medullary canal and the enveloping layer of epiblast.

*The muscular plate.*—Shortly after this extension of the mesoblast in the two directions before mentioned, another separation, or rather differentiation, is observed to take place in the direction of its length, in the formation along the dorsal surface, and below the epiblast, of a series of circumscribed plates which form the foundation of the erector muscles of the spine, and the great dorsal muscles of the trunk. These constitute together the *muscular*, or rather the *musculo-cutaneous plate*, for it appears also to include the formative rudiment of the true skin.

There is thus deposited the formative material for the vertebral bodies, the vertebral arches, and the muscles which immediately surround them, together with the general integument.

Meanwhile the vertebral segmentation goes on progressing from before backwards, extending through the dorsal, lumbar, sacral and coccygeal vertebræ, till the process is complete; but this is accompanied by other changes having reference to the separation of the nerve-roots and ganglia from their formative tissue, and the development of the elements of the permanent vertebræ.

In the outer portion of each protovertebral mass a transverse partition arises which separates the anterior part, as ganglion and nerve root, from

the posterior, as matrix or forerunner of the bone and other structures which belong to the vertebral column. Each nerve then comes thus to be placed in front of the future permanent vertebra with the proto-

Fig. 529.

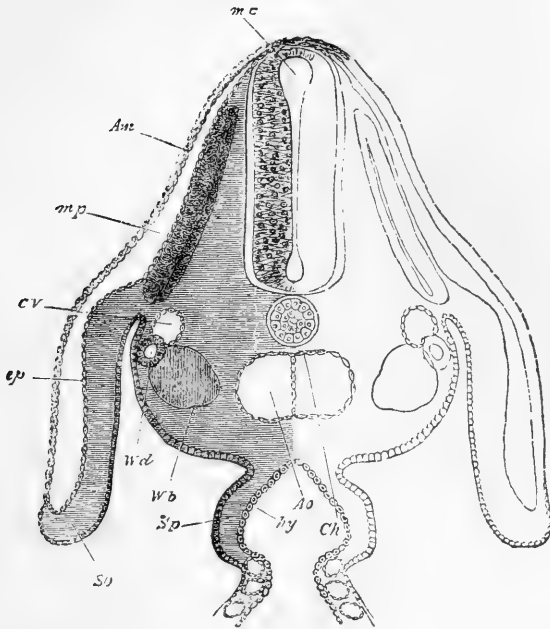


Fig. 529.—TRANSVERSE SECTION THROUGH THE DORSAL REGION OF AN EMBRYO-CHICK, END OF THIRD DAY (from Foster and Balfour).

*Am*, amnion; *m p*, muscle plate; *c v*, cardinal vein; *Ao*, dorsal aorta at the point where its two roots begin to join; *Ch*, notochord; *Wd*, Wolfian duct; *Wb*, commencement of formation of Wolfian body; *ep*, epiblast; *so*, somatopleure; *hy*, hypoblast. The section passes through the place where the alimentary canal (*hy*) communicates with the yolk-sac.

vertebral division of which it was originally connected. In the inner or central part of the primordial vertebræ a different kind of change occurs, first, by the amalgamation or fusion of the protovertebral masses, and subsequently by their subdivision in such a manner that the intervertebral disc arises on a level with or opposite the centre of each protovertebral mass, and the blastema, out of which a permanent vertebral body is formed, is made up by the union of two parts, an anterior and a posterior, the first of these being derived from the hinder part of the preceding protovertebral mass of the same number, the other part being supplied by the anterior section of the protovertebral mass immediately following.

This is a somewhat complicated change; and the more difficult to be followed that it would appear that the original division between the protovertebral masses disappears previous to a new segmentation taking place. Thus it results that, as respects the centrum or body part, the posterior half of one protovertebra is

thrown into connection with the anterior half of the one next following, and thus each permanent body is formed from parts of two protovertebral masses; while in respect to the arches, each one proceeds from the hinder segment of the anterior of the two protovertebrae concerned, the spinal ganglion and root being thrown into connection with the hinder part of the permanent vertebra immediately in front of the protovertebra of which they originally formed a part.

**Formation of Vertebral Matrices.**—While the material for the vertebral bodies is laid down round the notochord, a further extension of mesoblastic substance from the primordial vertebral plates takes place at the sides and round the medullary cavity for the matrix of the vertebral arches, and in due course, by differentiation of the formative cells, chondrification of the substance occurs in the form of the strips which constitute the first rudiments of the vertebral arches, and the accompanying transverse and other processes. The first ossification of these bones is from cartilage, but doubtless in them, as in other bones, much of the subsequent growth and extension of the bone substance proceeds from sub-periosteal deposit. It is also to be remarked that in some bones originating in membrane, cartilage may subsequently contribute to the growth and extension of the bone, as appears to occur in the lower jaw and clavicle.

The chondrification of the formative matrix of the bones in the human embryo takes place chiefly during the fifth and sixth weeks of foetal life, and in the seventh and eighth, ossification has begun in several of the long bones. But even before this time an ossific deposit shows itself in the fibrous matrix of the clavicle and lower jaw. By the ninth week the greater number of the bones have begun to ossify.

The formation of cartilages for the arches of the vertebræ begins first in those of the dorsal region, and spreads from these forwards into the cervical vertebræ and basis of the skull, and backwards\* into the lumbar and sacral vertebræ: but the extension of the matrix upwards ceases in the lower sacral and coccygeal region where the arches are deficient.

A small cartilaginous band forms the matrix of the subcentral portion or anterior arch of the atlas vertebra, quite distinct from that of the body of the axis, and out of the line of prolongation of the notochord.

In the lateral plates the cartilaginous matrices of the ribs are formed in connection with those of the transverse processes, and in the vertebral part of the ribs themselves ossification is comparatively early; but a considerable part remains unossified in the sternal portion, or costal cartilages, in connection with their special use in the mechanism of the respiratory movements.

Certain portions of the transverse parts of the cervical and lumbar vertebræ are undoubtedly homologous with ribs; but we give the name only to those costal bars which are separately articulated to the vertebræ, and the first of the vertebræ with which a rib reaching the sternum is articulated is reckoned as dorsal. Among the thoracic ribs a certain number, as elsewhere stated, of the cartilaginous matrices behind the first, are in the commencement united together at their ventral extre-

\* Here and elsewhere, unless otherwise explained, the terms used to indicate position apply to the primitive prone position of the embryo as it lies in the blastoderm, the dorsal aspect upwards and the ventral downwards.

mities into a strip of cartilage on each side, and thus the matrix of the sternum is at first cleft in two behind the pre-sternal portion. Subsequent fusion of these two lateral strips unites them into one; and the transverse division of the bone only appears from the result of ossification in successive distinct centres. This fact possesses an interest in connection with the tendency of the meso-sternum and xiphi-sternum to divide and to produce various degrees of the malformation termed *fissura sterni*.

In the lumbar region there is reason also to look upon part of the transverse processes as representing costal elements, but it is only in cases of abnormal formation that they are found distinct from the rest of the vertebra. (See the Descriptive Anatomy, Vol. I., p. 22.)

The sacrum is peculiar in presenting, thrust in and compressed between its strictly vertebral elements and the iliac bone with which it is united, several bony pieces which may be regarded as interposed ribs. The ossification of two of these occurs as early as the fifth or sixth month of foetal life.

## 2. THE HEAD.

The head of the embryo consists at first, as already stated, of the cranial part alone, the face, nose, and mouth being absent. Below the cranium, and extending as far forward as the point of junction of the anterior with the middle encephalic vesicle, is situated the pharyngeal portion of the primitive alimentary canal, closed in anteriorly by the inflection of the blastodermic layers. It is at this place that subsequently the opening of the alimentary canal to the exterior takes place in what constitutes ultimately the isthmus of the fauces; and in front of this the buccal cavity, not yet existing, is afterwards formed.

In the progressive development of the head the principal changes by which its fundamental parts come into shape may be enumerated shortly as follows, *viz.*, *First*, increase of deposit and textural differentiation of the mesoblastic substance for the formation of the cranial walls in their basilar, lateral, and upper portions; *second*, the interpolation of the sense-capsules as connected with the formation of the rudiments of the nose, eye, and ear; *third*, the development of the cerebral hemispheres and other parts of the brain from the three primary encephalic vesicles; *fourth*, the occurrence of the several cranial inflections; and *fifth*, the new formation of outgrowths for the development of the parts of the face.

**1. The Cranium.**—The basal portion of the cranium consists primarily of two fundamental parts. Of these the posterior is distinguished by the presence of the prolongation of the notochord within it as far forward as the part of the skull which afterwards becomes the pituitary fossa. This portion, which may be named *occipito-sphenoid*, is originally formed by the undivided investing mass of Rathke, which surrounds the anterior extremity of the notochord, and contains the matrix of the future basi-occipital and basi-sphenoid cartilages. By its later extension to the sides, it forms the matrix of the exoccipitals and the periotic mass of cartilage which surrounds the primary auditory vesicles. The main part extends forward below the posterior and middle primary encephalic vesicles, ending at the pituitary fossa.

The anterior portion of the basis cranii may be called *spheno-ethmoid*, as containing the matrix of the pre-sphenoid, and the ethmoid

cartilages. It is mainly produced in connection with the trabeculae cranii, which contain between their separated limbs the pituitary fossa. This part of the cranial basis contains no prolongation of the noto-

Fig. 530.

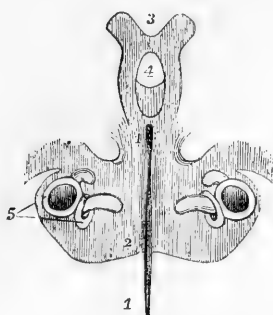


Fig. 530.—THE LOWER OR CARTILAGINOUS PART OF THE CRANIUM OF A CHICK OF THE SIXTH DAY (from Huxley).

1, 1, chorda dorsalis ; 2, the shaded portion here and forwards is the cartilage of the base of the skull ; at 2 the occipital part ; at 3 the prolongations of cartilage into the anterior part of the skull called *trabeculae cranii* ; 4, the pituitary space ; 5, parts of the labyrinth.

chord ; it lies below the anterior encephalic vesicle (thalamencephalon), and becomes greatly modified in connection with the expansion of the cerebral hemispheres and primary ocular vesicles, and the development of the nasal fossae and mouth, together with the other parts of the face.

The primary parts of the three principal sense organs, it may here be stated, the nose, eye, and ear, formed in connection respectively with the cerebral hemispheres, the thalamencephalon, and the third primary vesicle, are interpolated between the rudimentary parts of the head as follows, viz., 1. The nose between the frontal, intermaxillary and ethmoid ; the eye between the frontal, sphenoid, ethmoid and maxillary ; and the ear between the basi-occipital, exoccipital and alisphenoid.

While the base of the cranium, to the extent already mentioned, is

Fig. 531.

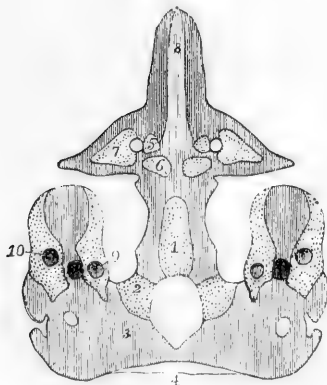


Fig. 531.—VIEW FROM BELOW OF THE CARTILAGINOUS BASE OF THE CRANIUM WITH ITS OSSIFIC CENTRES IN A HUMAN FŒTUS OF ABOUT FIVE MONTHS (from Huxley, slightly altered).

The bone is dotted to distinguish it from the cartilage, which is shaded with lines. 1, the basilar part, 2, the condyloid or lateral parts, and 3, 4, the tabular or superior part of the occipital surrounding the foramen magnum ; 5, centres of the pre-sphenoid on the inside of the optic foramen ; 6, centres of the post-sphenoid ; 7, centres of the lesser wings or orbito-sphenoid ; 8, septal cartilage of the nose ; 9 & 10, parts of the labyrinth.

cartilaginous in its origin, the lateral and upper walls are chiefly of membranous formation, as in the squama occipitis, the squamo-zygomatic of the temporal, the parietal and the frontal bones.

The trabeculae stretch forward to the anterior extremity of the head, and maintain the foremost place as the seat of the nasal cartilages and external apertures of the nose. Behind these the coalesced trabeculae form a narrow ethmo-vomerine cartilage, the nasal septum, round the

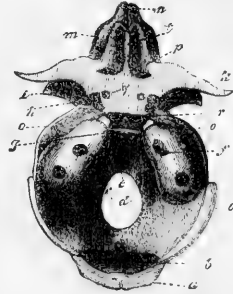


back of which the vomer is formed as a bony splent covering ; while in the hinder lyre-shaped interval of the separated trabeculæ is placed the infundibulum in connection with the pituitary body.

Fig. 532.—BASILAR PART OF THE PRIMORDIAL CRANIUM OF A HUMAN FÆTUS OF THREE MONTHS SEEN FROM ABOVE (from Kölliker).

*a*, upper half of the squama occipitis ; *b*, lower half of the same ; *c*, cartilaginous plate extending into it ; *d*, (in the foramen magnum) the exoccipital ; *e*, basi-occipital ; *f*, petrous, with the meatus auditorius internus ; *g*, dorsum sellæ, with two nuclei belonging to the basi-sphenoid bone ; *h*, nuclei in the anterior clinoid processes ; *i*, great wing nearly entirely ossified ; *k*, small wings ; *l*, crista galli ; *m*, cribrethmoid ; *n*, cartilaginous nose ; *o*, strip of cartilage between the sphenoid and the parietal ; *p*, osseous plate between the lesser wings and the cribriform plate.

Fig. 532.



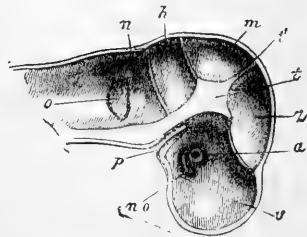
From the side of the presphenoid cartilage the matrix of the orbito-sphenoids or lesser wings, containing the optic foramina, is developed ; and from the sides of the basi-sphenoid proceeds the matrix of the greater wings, which are also cartilaginous in their origin.

In the periotic or cartilaginous rudiment of the temporal bone three centres of formation are distinguished by Huxley, viz., 1. *Opisthotic*, or that surrounding the fenestra rotunda and cochlea ; 2, *pröotic*, or that which encloses the superior semicircular canal ; and 3, *epiotic*, or that which surrounds the posterior semicircular canal and extends into the mastoid portion. They soon unite into one so as to form the petro-mastoid bone.

Fig. 533.—LONGITUDINAL SECTION THROUGH THE HEAD OF AN EMBRYO OF FOUR WEEKS (from Kölliker).  $\frac{10}{1}$

*v*, anterior encephalic vesicle, cerebral portion ; *z*, interbrain ; *m*, midbrain ; *h*, cerebellum ; *n*, medulla oblongata ; *no* and *a*, optic vesicle ; *o*, auditory depression ; *t*, centre of basi-cranial flexure ; *t'*, lateral and hinder parts of tentorium ; *p*, the fold of epiblast which forms the hypophysis cerebri.

Fig. 533.



The styloid process and the auditory ossicles are of cartilaginous origin.

The squamo-zygomatic and tympanic are produced from membrane.

**The Cranial Flexures.**—The earliest and the most important of the cranial flexures is that which takes place at the anterior extremity of the notochord and in the region of the mid-brain or middle encephalic vesicle. Here, as previously stated, the notochord extends into the substance of the basis of the cranium as it is prolonged forwards in the line of the vertebral bodies. At this place the medullary tube, and the substance forming the wall of the cranium especially, undergoes a sudden bending downwards and forwards, so as to cause the projection of the thickened cranial base in a marked manner upwards. This coincides with the place where the investing mass and the trabe-

culæ meet, and where inferiorly the pituitary body, and superiorly the infundibulum are afterwards formed. The investing mass of blastema, in which the anterior extremity of the notochord is enclosed, and the notochord itself, terminate here behind the pituitary fossa, or what afterwards becomes that part, in a place corresponding to the dorsum sellæ of human anatomy. Above and behind this, the middle cerebral vesicle forms the most prominent part of the cranium, which remains a characteristic feature of this part of the embryo head for a considerable time.

Another early flexure of the cranium accompanies the development of the cerebellum from the third primary vesicle, a cleft now appearing behind and below the rudimentary cerebellum, in the region of the fourth ventricle, and above the medulla oblongata, and this flexure is necessarily attended with a convexity forwards, or another flexure in the place of the pons Varolii.

Fig. 534.

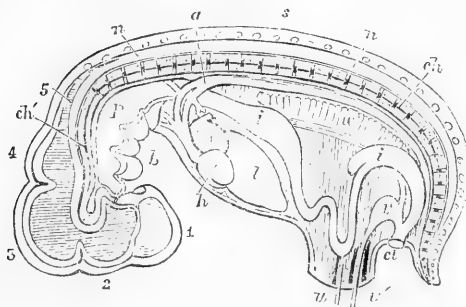


Fig. 534. — LONGITUDINAL SECTION OF THE HUMAN EMBRYO AT THE SIXTH OR SEVENTH WEEK.

1, cerebral hemispheres  
 2, vesicle of the third ventricle ; 3, mid-brain ; 4, cerebellum ; 5, medulla oblongata ; *ch*, notochord passing up through the bodies of the vertebræ into the basis cranii and terminating in the head between the infundibulum and the sac of the hypophysis cerebri ; *s*, the vertebral spines ; *n*, the spinal cord ; *p*, the pharynx ; *h*, the heart ; *l*, the liver ; *i*, the stomach and intestine ; *cl*, the cloaca ; *v*, the urinary bladder and pedicle of the allantois ; *u*, *u'*, the umbilicus containing the vitello-intestinal duct, urachus and vessels ; between *i*, and *i*, superiorly, the Wolffian body is shown.

The great cranial flexure thus marks the division between the strictly basi-cranial, or occipito-sphenoidal, and the basi-facial, or sphenothmoidal part, the chorda terminating between those two portions of the cranial base, with a conical and sharp point. Here the chorda is itself bent downwards and forwards, and terminates in a spot which corresponds to the post-sphenoid body, or dorsum sellæ. According to Mihalkovics, who has recently investigated the subject with care (see *Archiv für Mikroskop. Anat.*, vol. xi., 1875,) in connection with the formation of the pituitary gland in mammals and birds, the chorda tapers off to a fine point in front of this spot, but presents a slight swelling just at the place of the future occipito-sphenoidal suture.

The formation of the mouth, and its opening by the fauces into the pharyngeal or first part of the primitive alimentary canal, are phenomena of development intimately connected with the formation of the central part of the cranium and sella turcica, but they are also associated with the development of the face, which is next to be considered.

**Formation of the Mouth and Hypophysis cerebri.**—Along with the changes which accompany the formation of the principal cranial flexure, is

associated in a remarkable manner the origin of a body (the pituitary gland or hypophysis cerebri) the nature and uses of which in the adult are entirely

Fig. 535.

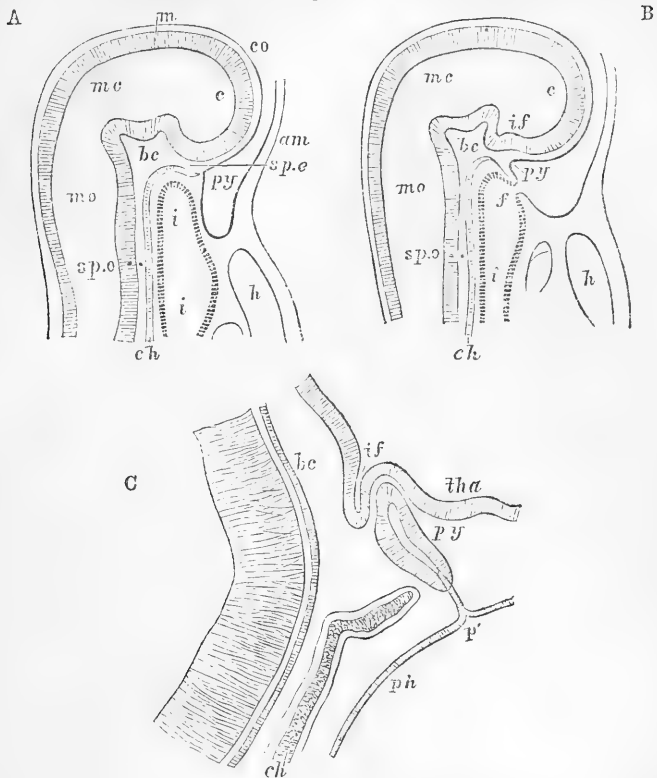


Fig. 535.—VERTICAL SECTION OF THE HEAD IN EARLY EMBRYOES OF THE RABBIT. MAGNIFIED (from Mihalkovics).

- A. From an embryo of five millimetres long.  
 B. From an embryo of six millimetres long.  
 C. Vertical section of the anterior end of the notochord and pituitary body, &c., from an embryo sixteen millimetres long.

In A, the faucial opening is still closed; in B, it is formed; *c*, anterior cerebral vesicle; *mc*, meso-cerebrum; *mo*, medulla oblongata; *co*, corneous layer; *m*, medullary layer; *if*, infundibulum; *am*, amnion; *spe*, speno-ethmoidal, *bc*, central (dorsum sellæ), and *spo*, speno-occipital parts of the basis cranii; *h*, heart; *f*, anterior extremity of primitive alimentary canal and opening (later) of the fauces; *i*, cephalic portion of primitive intestine; *tha*, thalamus; *p'*, closed opening of the involuted part of the pituitary body (*py*); *ch*, notochord; *ph*, pharynx.

unknown, but the constancy of whose presence, and the uniformity of its connections in the whole series of vertebrate animals, points to some important morphological relation.

The general nature of this body, in its joint connection with the infundibulum of the brain on the one hand, and a diverticulum of the alimentary canal on the other, was first pointed out by Rathke (Müller's Archiv, 1838, p. 482), although he afterwards abandoned the view there set forth. It was, however, fully confirmed by others; and, among recent observers, we owe more especially to William Müller an

elaborate investigation of the whole subject (Jenaische Zeitschr., vol. vi., 1871), who traced most carefully the nervous and diverticular elements in their development, and their union with mesoblastic elements in the formation of the gland. Goette next ascertained that the diverticulum from below is connected with the buccal cavity and epiblast, and not with the pharynx and hypoblast, as was previously supposed (Archiv für Mikroskop. Anat., vol. ix., p. 397). The observations of Mihalkovics on Mammals complete the history of this point in development, and will be mainly employed in the following description.

The formation of this body may be shortly described as consisting in the meeting and combination of two outgrowths from very different fundamental parts; one cerebral or medullary from above, and the other corneous or epiblastic (glandular), from below, in a recess of the cranial basis which afterwards becomes the pituitary fossa (fig. 535, *B*, *if*, *py*). The cerebral outgrowth, the posterior of the two parts, takes place by the formation of a pointed projection downwards of a portion of the lower medullary wall of the vesicle of the third ventricle, and its firm adhesion to the base of the cranium. This is the commencement of the infundibulum. Meanwhile, a little in front of the same place, there is projected upwards from below a part of the basilar surface of the cranium, so as to form a deep recess lined by the corneous layer from the back and upper part of the future mouth. This recess is the commencement of the hypophysis or pituitary body in its glandular portion, which is not, as has been supposed, a recess from the pharynx, seeing that it is in front of the opening which is afterwards formed for the fauces. The depressed and sharpened out anterior part of the notochord is directed downwards and forwards, while the sac of the hypophysis is carried upwards and backwards, and, according to Mihalkovics, the attenuated end of the chorda soon disappears from between the infundibulum and the hypophysis, previous to the occurrence of the intimate union which follows between these two bodies. The anterior extremity of the chorda, therefore, is lost in the floor of the pituitary fossa, and the swollen or dilated portion of the chorda which succeeds, and which comes then to form the apparent termination, occupies the interval between the basi-occipital and the basi-sphenoidal cartilages. The chorda traced back from this point, presents another swelling at the junction of the basi-occipital cartilage with that of the odontoid process, into which last it passes. The third swelling of the chorda lies between the odontoid cartilage, and that of the body of the axis vertebra.

Fig. 536.

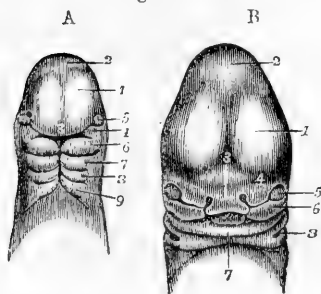


Fig. 536.—CRANIUM AND FACE OF THE HUMAN EMBRYO SEEN FROM BEFORE (from Ecker).

A, from an embryo of about three weeks: 1, anterior cerebral vesicles and cerebral hemispheres; 2, interbrain; 3, middle or fronto-nasal process; 4, superior maxillary plate; 5, the eye; 6, inferior maxillary or mandibular plate (first postoral); 7, second plate; 8, third; 9, fourth, and behind each of these four plates their respective pharyngeal clefts. B, from an embryo of five weeks: 1, 2, 3, and 5, the same as in A; 4, the external nasal or lateral frontal process; 6, the superior maxillary plate; 7, the mandibular; x, the tongue; 8, the first

pharyngeal cleft, which becomes the meatus auditorius externus.

The base of the skull, therefore, consists of two parts, one the posterior, in which the chorda is imbedded, and corresponding to the future basi-occipital and basi-sphenoidal parts, the other in front of this, into which the chorda does not penetrate, the speno-ethmoidal, and which, according to the researches of Parker and Gegenbaur, is of a later formation, and is more immediately related to the development of the face.

The flask-like outgrowth of the buccal epiblast which gives rise to the hypophysis cerebri, is now gradually shut off from the corneous layer and cavity of the mouth, first by the constriction, and subsequently by the closure of its place of communication. There remains however, for a considerable time, a longish

Fig. 537. — OUTLINE PLAN VIEW OF THE UPPER PART OF THE BODY OF AN EMBRYO PIG, TWO-THIRDS OF AN INCH IN LENGTH. MAGNIFIED SEVEN DIAMETERS (from Parker).

Fig. 537.

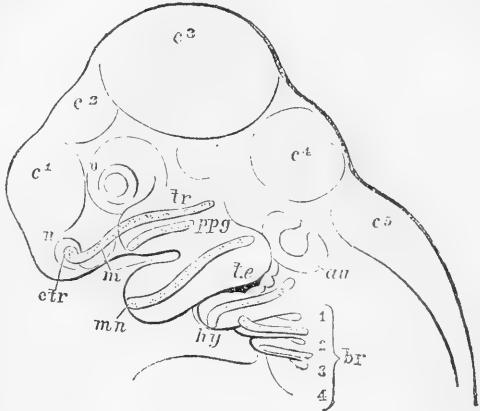
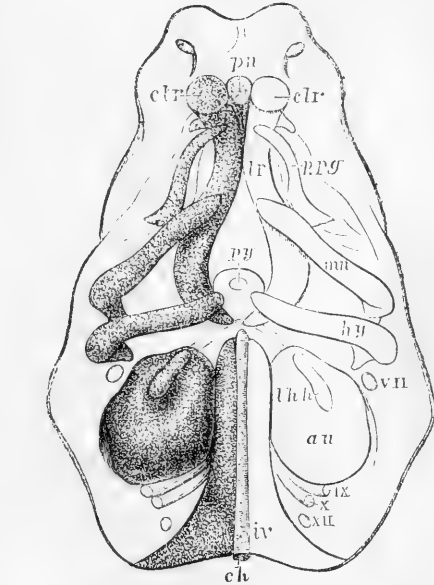


Fig. 538. — PLAN OF THE SKULL, &c., OF THE SAME EMBRYO SEEN FROM BELOW. MAGNIFIED TEN DIAMETERS (from Parker).

Fig. 538.



In this and the preceding figure the letters, where present, indicate the following parts :—

*c*<sup>1</sup> to *c*<sup>5</sup>, the five primary divisions of the brain; *a*, the eye; *n*, the nose; *m*, the mouth; *tr*, cartilage of the trabeculae; *ctr*, cornua trabecularum; *pn*, prenasal cartilage; *ppg*, pterygo-palatine cartilage; *mn*, the mandibular arch with Meckel's cartilage; *te*, first visceral cleft which becomes the tympano-eustachian passage; *au*, the auditory vesicle; *hy*, the cerato-hyoid arch; *br*, the branchial bars and clefts, 1 to 4; *thh*, the thyro-hyoid; *py*, the pituitary fossa; *ch*, the notochord in the cranial basis, surrounded by the investing mass (*iv*); *vii*, facial nerve; *ix*, glosso-pharyngeal; *x*, pneumogastric; *xii*, hypoglossal nerve.

thread of union between the two (fig. 535, *C*, *p'*). The epithelium of the enclosed portion subsequently undergoes development into glandular coeca and cell-cords, and its internal cavity becomes gradually obliterated. This forms the anterior part or lobe of the pituitary body. The posterior part owes its origin to the combination with mesoblastic tissue of a widened extension of the infundibular process of the brain, which is thrust in between the sac of the pituitary body and the dorsum sellae. The nervous structure of this posterior lobe afterwards disappears in the higher animals, but in the lower it retains its place as a part of the brain.

**2. Subcranial, Facial, or Pharyngeal Plates or Arches.**—In man, and all vertebrates, there are developed below and on the sides of the cranial part of the head, a series of processes or bars in pairs, which contribute to the formation of the subcranial structures constituting the face and jaws, and the hyoid and other parts intervening between the head and trunk. These bars first received attention

Fig. 539.

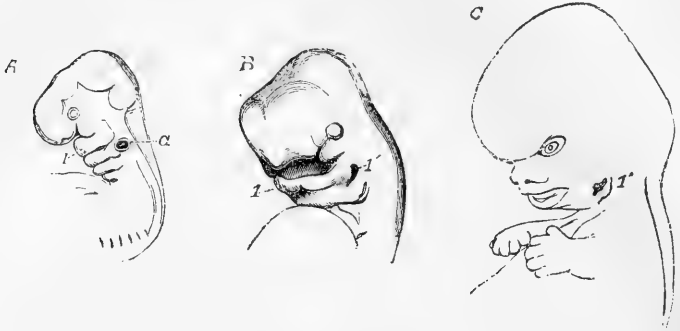


Fig. 539.—OUTLINES SHOWING THE EARLY CHANGES IN THE FORM OF THE HEAD OF THE HUMAN EMBRYO.

*A*, profile view of the head and fore part of the body of an embryo of about four weeks (from nature,  $\frac{1}{2}$ ): the five primary divisions of the brain are shown, together with the primary olfactory and optic depressions, and *a*, the auditory vesicle; 1, marks the mandibular plate, and behind this are seen the three following plates with the corresponding pharyngeal clefts. *B*, from an embryo of about six weeks (from Ecker,  $\frac{2}{3}$ ): the cerebral hemispheres have become enlarged and begin to spread laterally; 1, the lower jaw; 1', the first pharyngeal cleft, now widening at the dorsal end, where it forms the meatus externus; the second cleft is still visible, but the third and fourth clefts are closed and the corresponding plates have nearly disappeared. *C*, from a human foetus of nine weeks (from nature,  $\frac{3}{4}$ ): the features of the face are now roughly formed; the first pharyngeal cleft is now undergoing conversion into the meatus, and the auricle is beginning to rise at its outer border.

from their discovery by Rathke in 1826, published in the *Isis* of that year, and were named by him the **branchial arches**, from the relation which some of them bear to the gill bars of branchiate vertebrates. Their nature and transformations were fully investigated by Reichert in 1837 (*Müller's Archiv*, 1837). From later researches it appears that other processes, with somewhat similar relations to the cranium, occurring further forward, may be associated with those described as branchial by Rathke, and it will be expedient therefore to describe the whole of the subcranial outgrowths together at this place. In this the views of Huxley and Parker will be chiefly followed. (See "On the Structure and Development of the Skull in the Pig," by W. K. Parker, in *Trans. Roy. Soc.* 1873, p. 289; Huxley, in *Elements of Compar. Anat.*, 1864, and *Manual of Compar. Anat.*, 1871; also Gegenbaur, *Das Kopfskelet*, &c., 1872).

According to these views the parts of the head situated in front of and above the future mouth, are formed from two pairs of plates, which may thence be called *preoral*, in one pair of which the bars are the same with the *trabeculae cranii* of Rathke surrounding the pituitary gland, and are the basis of formation of the pre-sphenoid, ethmoid, nasal, and pre-maxillary portions of the skull, while in the other pair, consisting in each of a deeper and a superficial part, the bars form the foundation

of the pterygo-palatine wall of the nose and mouth, and the superior maxillary bone. The nasal pits or primary nasal depressions, which extend themselves afterwards into the nasal fossæ, and remain permanently open to the exterior, are formed by a depression of the surface of the epiblast in the anterior prolongation of the head as constituted by the ends of the trabeculæ, and the harder structures of the septum and walls of the nasal cavities, as well as the turbinated structures on which the olfactory nerves are distributed, are all derived from the anterior parts of these trabeculæ ;—a mesial union giving rise to the nasal septum, while lateral parts circling round the nasal pits, form the alar enclosures of these depressions (see figs. 537 and 538).

The second preoral subcranial plates have received the name **pterygo-palatine** from the nature of their deeper connection with the bar in which the pterygoid and palate-bones are afterwards formed. These enclose the posterior nasal apertures, and advancing from the two sides, at last meet each other in the palate, and in front meet the pre-maxillary process to complete the palate and upper jaw.

But these are only the deeper parts of the structure out of which the upper jaw is formed, there being on the surface of the head, and behind the depression of the eye on each side, a bulging process known as the **superior maxillary process**, in which the upper jaw and malar bone are formed, and which has externally the appearance of bending round the angle of the mouth in continuity with the mandibular or inferior maxillary.

The formation of the superficial parts of the face, as seen from before, may be described as follows, viz. :—In the middle, there descends in what now forms the region of the forehead, a mesial portion, the **fronto-nasal plate**, which forms the integument of the nose, as far as the inside of the nostrils, and the columella of the nose, together with the mesial part or lunula of the upper lip, that is, all the part lying inside the depression of the nostrils. On the outside of these depressions, a short lappet surrounds the orifice of the nostrils, as wings forming the **external nasal processes**. It is towards the outside of these last plates that the ocular depression is situated, that depression being thus interposed between the lateral or external nasal plate, and the maxillary plate, and forming the fissure which has been called the **ocular fissure**, but which afterwards becomes more strictly the lachrymal in its anterior part (see figs. 536 and 539).

The great **buccal aperture** now passes across the face, having the middle and external nasal with the superior maxillary plates above and in front, and the inferior maxillary plates below and behind. It will be remembered, however, that the cavity of the mouth is thrown forward by the outward development of the subcranial plates, which deepen more and more the buccal cavity as they grow outwards from the primitive cranium.

The **POSTORAL** pairs of pharyngeal visceral plates are four in number ; the first being that already mentioned as following immediately behind the mouth, and forming the **mandibular** or **inferior maxillary**.

At an early period of fetal life in the human fœtus, and in that of all vertebrates, plates of this description are found, but in the lower vertebrates a greater number exists than in the higher. The number of four pairs belongs to man in common with all the non-branchiate vertebrates. Behind each of these plates there are formed from within,

in the course of development, clefts which penetrate the wall of the pharynx ; these clefts, or so-called branchial apertures, running completely through the wall of the pharynx and the external wall of the body of the embryo (see figs. 537 and 538).

The **auditory pit**, or primary depression from the epiblastic surface which forms the rudiment of the labyrinth of the ear, is situated immediately above the upper or proximal end of the two first postoral plates, and consequently on a level with the first postoral cleft. And this proximity of position is connected with the intimate relation in which two sets of parts stand to each other : for the part called the first branchial cleft is afterwards converted into the external and middle passages of the ear, (meatus, tympanum, and Eustachian canal), the membrana tympani being at a later period thrown across the passage. It forms thus the tympano-eustachian cleft or canal. The tympanic bone is of membranous origin and is formed round the first cleft. The external auricle is of integumental origin, and is formed in the second postoral bar posteriorly and externally to the aperture of the first cleft.

The second postoral cleft is the first true water passage, or the first of those which serves as a gill aperture in branchiate vertebrates, and which may in the lower classes be increased to a greater number.

Although the description of some of the changes which the several pharyngeal plates or branchial arches undergo in the further process of development, belongs to a different part of the subject, yet it may be useful to describe shortly the more important of them in this place.

In the first or **mandibular arch** a strong cartilaginous bar is formed known as the *cartilage of Meckel*, on the exterior of which, but not in its own substance, throughout a considerable part of its distal length, the lower jaw-bone is afterwards developed. The proximal part next the cranium, which comes later to be connected with the auditory capsule, becomes in mammalia the malleus, in birds and reptiles chiefly the os quadratum. (See figures in connection with development of the ear.)

In the second or **hyoid arch** are developed the styloid process, the stylo-hyoid ligament, the lesser or upper cornua of the hyoid bone, the series of parts which connect them with the basis of the skull, being united like the first to the auditory capsule: but the proximal part of this arch would appear also to have the incus formed in it, and to be connected with the stapes and stapedius muscle.

The third arch is the **thyro-hyoid**, and is related to the formation of the lower or great cornua, and the body of the hyoid bone. It corresponds with the first true branchial arch of amphibia and fishes, in which animals the clefts and bars behind this arch become more numerous than in the higher vertebrata.

The **fourth arch**, which has no special name, but might be called *sub-hyoid* or *cervical*, does not seem to form the basis of any particular organ, but is situated exactly at that part of the body which becomes elongated as the neck,—a part which may be considered as absent in the fœtus, and the formation of which by a simple process of elongation gives rise to some peculiar features in the anatomy of the parts composing it.

**Relations of Cranial Nerves.**—The rudiments of four cranial nerves, besides the optic and auditory afterwards to be referred to, are found at a very early period in connection with the plates now under consideration, and the following is the relation in which, according to Parker, they stand to these plates in all vertebrate animals. These nerves are the



fifth pair or trigeminus, the facial, the glosso-pharyngeal, and the pneumo-gastric. The two first are situated in front, and the two latter behind the auditory sac. These nerves all divide or fork above a visceral cleft, one division going to the posterior face of the arch in front of the cleft, the other to the anterior face of the arch behind it.

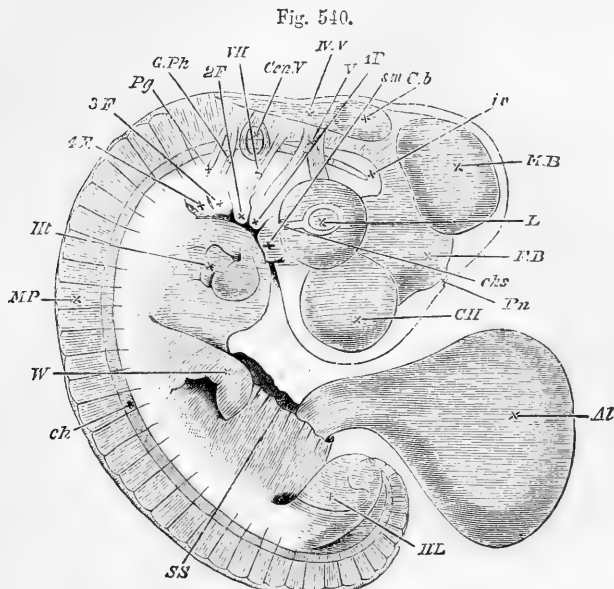


Fig. 540.—EMBRYO OF THE CHICK AT THE END OF THE FOURTH DAY (from Foster and Balfour).

The amnion has been removed; *Al*, allantois; *CH*, cerebral hemispheres; *FB*, thalamencephalon, with *Pn*, the pineal gland projecting from its summit; *MB*, mid-brain; *Cb*, cerebellum; *IV*, *V*, fourth ventricle; *L*, lens; *chs*, choroid slit; *Cen V*, auditory vesicle; *sm*, superior maxillary process; *1F*, *2F*, &c., first, second, third and fourth visceral folds; *V*, fifth nerve in two divisions, one to the eye, and the other to the first visceral arch; *VII*, seventh nerve passing to the second visceral arch; *Gph*, glosso-pharyngeal nerve passing to the third visceral arch; *Pg*, pneumo-gastric nerve passing to the fourth arch; *IV*, investing mass; *ch*, notochord; *Ht*, the heart; *MP*, muscle plates; *W*, wing; *HL*, hind limb.

The orbito-nasal and the palatine divisions of the trigeminus belong to the trabecular arch, the former above, the latter below the optic nerve. Of the other division, one part (the superior maxillary nerve) follows the palato-pterygoid arch, the other (inferior maxillary nerve) accompanies the mandibular arch.

The facial nerve (portio dura of seventh pair) divides above the tympano-eustachian passage, its anterior part (chorda tympani) going to the posterior side of the mandibular arch, and its posterior part (descending branch of facial) to the outer or anterior side of the hyoid arch.

The glosso-pharyngeal nerve, by a similar division, goes by its inner or anterior branch (lingual) to the inner or posterior side of the hyoid arch, and by its other division (pharyngeal) to the front of the first branchial or thyro-hyoid arch.

In the higher animals the pneumo-gastric nerve shows no close relation to the clefts, but in branchiate vertebrates it is continued past the gills, and sends forked branches to the gill arches in front and behind each of the clefts.

### 3. ORIGIN AND FORMATION OF THE LIMBS.

The close connection of the limb-arches with certain vertebral segments of the trunk has been previously referred to in the morphological remarks, given under the description of the bones and muscles in the first volume; and although the vertebral homology of the parts of the limb proper is not so apparent, at least in the proximal segments, yet in the quinquifid division of the more remote parts, in the preaxial and postaxial arrangement of these divisions, and in their relation to the nerves and some other circumstances, we can scarcely fail to perceive some very near relationship between the structure of the limb as a whole, and a certain number of the vertebral segments of the trunk.

Fig. 541.

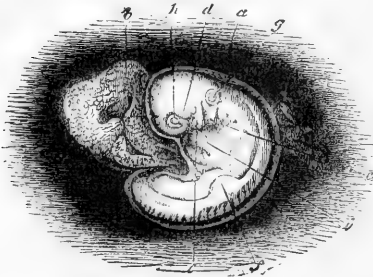


Fig. 541.—HUMAN EMBRYO OF ABOUT FOUR WEEKS (from Kölliker, after A. Thomson).  $\frac{5}{1}$

*f*, the anterior limb rising as a semi-circular plate from the lateral ridge. (The figure is elsewhere described.)

The limbs do not exist from the earliest time of the formation of the cranio-vertebral part of the trunk, but only begin to be formed when the development of the axial part of the body has

made some advance, as in the first half of the fourth day of incubation in the chick, and at the commencement of the fourth week in the human embryo.

They first make their appearance as two pairs of buds from the side of the vertebral part of the trunk, in the form of flattish lateral elevations with curved free margins projecting from the exterior of the body, outside the thickened ridge (sometimes called the *Wolffian ridge*) where the division of the mesoblast into somatopleure and splanchnopleure take place, and near the outer margins of the muscular plates. The anterior pair of limbs appears earlier than the posterior, and for a long time is always more advanced in the development of its parts.

The place of formation of the anterior and posterior limbs does not vary to any great extent throughout the vertebrate animals,—and this fact may be looked upon as one of the most marked features of vertebrate organisation.

The thickened plate which forms the commencing limb, by its increased growth, projects still more from the side, so as to take the form of a flattened lappet with a semicircular free margin; presenting then two surfaces which may be named dorsal and ventral with reference to their correspondence to the like surfaces of the trunk, constituting respectively the primitive extensor and flexor surfaces of the limb; while the anterior margin of the semicircular lappet corresponds to the preaxial and the posterior margin to the postaxial borders of the future limbs.

The whole thickness of the somatopleure division of the mesoblast is involved in this primary limb-bud, and it is of course also covered with the epiblast or cuticular layer, in the substance of which there is considerable increase of thickness at the most prominent part of the margin.

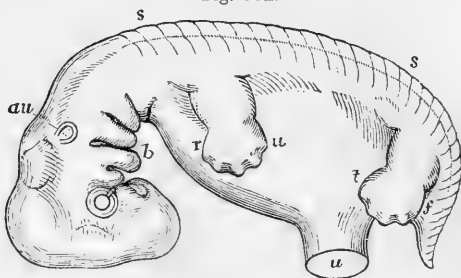
As the limb-buds increase in size, the lateral limb-plate, or Wolffian ridge, which is at first very prominent in its whole length, becomes less, and gradually flattens down into the more even surface of the wall of the trunk.

The part of the limb which appears first, corresponds more immediately with the hand or foot than with the other divisions of the limb. Along with this, however, at a very early period there is an indication of the formation of the limb-girdles as folds passing off from the side

Fig. 542. — DIAGRAMMATIC OUTLINE OF THE PROFILE VIEW OF THE HUMAN EMBRYO OF ABOUT SEVEN WEEKS, TO SHOW THE PRIMITIVE RELATIONS OF THE LIMBS TO THE TRUNK. (Allen Thomson.) †

*r*, the radial (preaxial), and *u*, the ulnar (postaxial) border of the hand and forearm; *t*, the tibial (preaxial), and *f*, the fibular (postaxial) border of the foot and lower leg. (The foot is represented at a somewhat more advanced stage than the rest of the embryo).

Fig. 542.



of the trunk. As the projection of the limb increases from the side of the body, the distal or terminal segment becomes slightly notched off from the part next the trunk. This terminal part, forming nearly three-fourths of a somewhat circular flattened plate, contains the rudiments of the hand or foot. The next change which takes place is in the division of the proximal part, or rather the preaxial border and ventral surface, by a notch which separates the fore-arm and lower leg from the upper arm and thigh at the elbow and knee joint respectively. In the third stage the notched division of the free lateral curved margin, with intermediate slightly tubercular projections of the substance, shows the commencement of digital development, in which it soon becomes apparent that the pollex and hallux occupy the preaxial position in their respective limbs, and are followed by the series of other fingers to the fifth, which is placed on the postaxial border. From these it is easy to trace, by reference to the simple original position of the limbs, the preaxial position afterwards held by the radius in the one and the tibia in the other, and the postaxial position of the ulna or fibula. In the meantime the internal differentiation of texture takes place, by which is brought out the more complete distinction of the segments of the limbs, and the various component parts of each, which gradually appear in the cartilages for the bones, muscular plates extended from the general muscular sheath of the trunk, prolongation of the cutaneous layer of the integument, the formation of nerves, blood-vessels, &c., the consideration of all which belongs to the history of more advanced development.

In order also to complete the history of the formation of the limbs, it is necessary to take account of the changes of attitude the anterior and posterior respectively undergo, as compared with the primary embryonic position. In this the elbow comes first to be turned outwards and then directed backwards, bringing the flexor surface of the upper arm forwards, while the position of the flexor surface of the fore-arm and hand, though generally and naturally inwards, may, by supination, be brought forwards, and by pronation backwards, the latter being the permanent position given to the manus in most animals. In the hinder limb, again, the thigh is turned inwards, so that in the higher animals the flexor surface looks backwards, and in all animals the lower division of the limb is turned inwards and the sole of the foot downwards, so that the extensor surface and dorsum look forwards. (See vol. i., p. 122.)

#### 4. DEVELOPMENT OF THE MUSCLES.

The muscles of the trunk derive their origin from the muscular plates previously referred to as being separated by differentiation of the

Fig. 543.

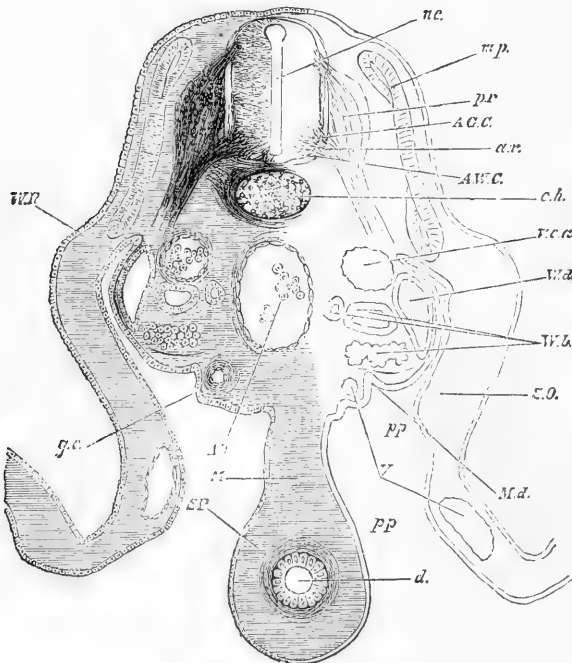


Fig. 543.—SECTION THROUGH THE LUMBAR REGION OF AN EMBRYO-CHICK OF FOUR DAYS (from Foster and Balfour).

*nc*, neural canal ; *pr*, posterior root and ganglion of a spinal nerve ; *ar*, anterior root ; *mp*, muscle-plate ; *ch*, notochord ; *WR*, Wolffian ridge ; *AO*, aorta ; *Vca*, cardinal vein ; *Wd*, Wolffian duct ; *Wb*, Wolffian body with glomeruli ; *ge*, germinal epithelium ; *Md*, depression forming the commencement of the Müllerian duct ; *d*, alimentary canal ; *M*, mesentery ; *SO*, somatopleure ; *SP*, splanchnopleure ; *V*, blood-vessels ; *pp*, pleuro-peritoneal space.

formative cells in the outer or superficial part of the protovertebral masses. Some difference of opinion exists, however, among embryologists, as to how far the hypaxial (hyposkeletal of Huxley) as well as the epaxial muscles, proceed from this source alone, or whether only the latter are traceable to the muscular plate formed by the protovertebral differentiation, and the hypaxial may be supposed to proceed from a deeper source.

Recent observations seem to show that a downward extension of the mesoblast from the protovertebræ may also give rise to the hypaxial muscles.

Being developed from the segmented protovertebral elements, the muscular plate shows at first the same division into segments, which are separated for a time by intermuscular septa (myotomes) as occurs during life in a considerable number of them in fishes and amphibia.

The formation of the longer muscles of the trunk proceeds from the disappearance of the septa, and the longitudinal union of the fasciculi of successive myotomes. In the trunk the direction of these remains for the most part chiefly longitudinal, but those connected with the limb-girdles change their direction with the development of the limb.

The formation of the muscles of the limbs themselves has not been traced in detail. The greater number of these muscles appear rather to arise independently in the blastodermic tissue of the limb-bud, than to be prolonged from the sheets of trunk-muscles (Kölliker).

The facial muscles and the platysma, belong to the subcutaneous system, and are developed along with the skin.

The diaphragm is at first wanting. It arises soon after the formation of the lungs, from two parts which spring from above and the sides, and which divide the pleural and peritoneal cavities, which were previously in one, from each other.

The muscles begin to be formed in the human embryo in the sixth and seventh week.

**Formation of the Joints.**—With regard to the formation of the joints, very little is known. It would appear that the cavities of the synovial joints are not yet formed at the time when chondrification has taken place in the matrix of the bones. It is therefore by a secondary process of solution of continuity that these cavities are produced. The articular cartilages remain as the coverings of the opposed surfaces of the bones, and the various ligamentous and other parts belonging to the joints arise by processes of textural differentiation which it is unnecessary to particularise here.

**Distinction of Bones according to their Cartilaginous or Membranous Origin.**—There is here appended for the assistance of the reader a note of the distinction as regards their origin from cartilage or fibrous membrane of the several permanent bones of the skeleton.

1. *Bones arising from Cartilage* :—

a. *In the Head.*

Basi-occipital, ex-occipital, and part of the supra-occipital or squama occipitis.

The whole sphenoid except the cornua sphenoidalia.

The petro-mastoid or petrotic portion of the temporal bone.

The mes-ethmoid and ethmo-turbinal.

The pterygo-palatine.

The malleus (quadrate of animals) with Meckel's cartilage.

The incus and stapes, with the stylo-hyoid.

The thyro-hyoid.

*b. In the Trunk.*

The bodies, arches, and processes of the vertebræ.

The ribs and sternum.

*c. In the Limbs.*

The scapula and coracoid. The clavicle in part, and all the other bones of the upper limbs (excepting sesamoid).

The ilium, ischium, and pubis, and all the other bones of the lower limbs, including the patella, but excepting sesamoid of toe.

2. *Bones arising from Fibrous Membrane:—**a. In the Head.*

Part of the squama occipitis.

The frontal.

The parietal.

The squamo-zygomatic and tympanic of the temporal.

The nasal and lachrymal.

The maxillaries and pre-maxillaries.

The vomer and cornua sphenoidal.

The inferior or maxillo-turbinal.

The malar or jugal.

The inferior maxillary or mandibular.

*b. In the Trunk.* None.*c. In the Limbs.*

The clavicle in part.

(The marsupial bone of animals.)

The smaller sesamoid bones of tendons.

## DEVELOPMENT OF THE NERVOUS SYSTEM.

**The Cerebro-spinal Centre.**—From what has been previously stated it will have been seen that the rudiment of the cerebro-spinal

Fig. 544.

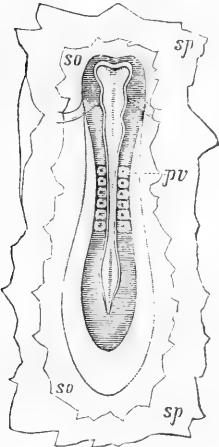


Fig. 545.

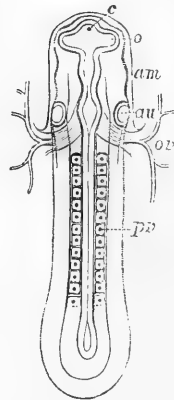


Fig. 544.—EMBRYO OF THE DOG SEEN FROM ABOVE, WITH A PORTION OF THE BLASTODERM ATTACHED (from Bischoff).

The medullary canal, not yet closed, shows at the cephalic extremity a partial division into the three primary cerebral vesicles; and at the posterior extremity a rhomboidal enlargement. Six proto-vertebral divisions are visible; *so*, the upper division of the blastoderm, *sp*, the lower division.

Fig. 545.—EMBRYO OF THE DOG MORE ADVANCED, SEEN FROM ABOVE (after Bischoff).

The medullary canal is now closed in; *c*, the anterior encephalic vesicle; *o*, the primitive optic vesicle in communication with the anterior encephalic; *au*, the primitive auditory vesicle opposite the third encephalic vesicle; *am*, the cephalic fold of the amnion enclosing the anterior third of the embryo; *ov*, the omphalo-mesenteric vein entering the heart posteriorly; *pv*, the proto-vertebral divisions, now become numerous.

nervous centre is formed more immediately from the thickened medullary plates of the involuted epiblast, the ridges of which, rising from the surface of the blastoderm, become united dorsally along the middle line into a hollow medullary tube of a cylindrical form. This tube becomes dilated at its anterior or cephalic extremity, and this dilated portion becomes divided by two partial constrictions into the three primary cerebral or encephalic vesicles, which, as representing fundamental portions of the brain, have been termed the fore-brain, mid-brain and hind-brain. The spinal portion retains its more uniform cylindrical shape, excepting towards the caudal extremity, where it is longer of

Fig. 546.

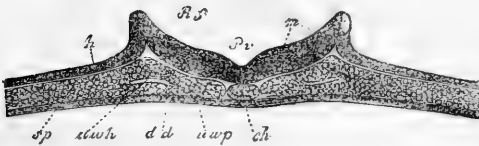


Fig. 546.—TRANSVERSE SECTION THROUGH THE EMBRYO OF THE CHICK, AND BLASTODERM AT THE END OF THE FIRST DAY. MAGNIFIED FROM 90 TO 100 TIMES (from Kölliker).

*h*, epiblast; *dd*, hypoblast; *sp*, mesoblast; *Pv*, medullary groove; *m*, medullary plates;

*wch*, commencement of division of mesoblast into its upper and lower laminae; between *Rf* and *h* the dorsal laminae or ridges which by their approximation close in the medullary canal.

closing, and forms for a time a flat open rhomboidal dilatation. The continuous cavity enclosed within the primitive medullary tube is the same with that which, variously modified, afterwards constitutes the central ventricles of the brain and canal of the spinal cord.

The formative cells composing the medullary substance are at first spherical, but they afterwards become elongated and spindle-shaped, and increase rapidly by multiplication. They represent at first the

Fig. 547.

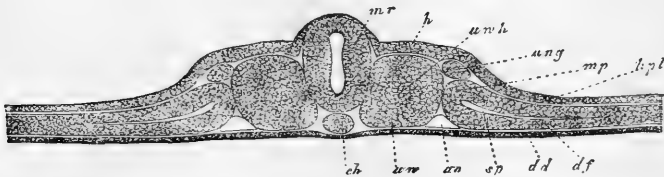


Fig. 547.—TRANSVERSE SECTION OF THE EMBRYO CHICK ON THE SECOND DAY. MAGNIFIED FROM 90 TO 100 TIMES (from Kölliker).

The explanation of the letters is in part the same as in the foregoing figure. *mr*, the medullary tube now closed along the dorsal line and covered in by continuous epiblast; *wch*, hollow of the proto-vertebral mass; *mp*, mesoblast external to the protovertebræ dividing into *hpl*, somatopleure, and *df*, splanchnopleure; *ao*, one of the primitive aortas; *ung*, intermediate mass connected with the origin of the Wolffian body.

grey substance, or the nerve-cells and non-medullated fibres. The cylindrical cells which, from the first, line the whole canal, remain permanently in the part of it which forms the central canal of the spinal marrow, and frequently present the ciliated structure.

#### THE SPINAL MARROW.

The internal grey substance of the spinal marrow is first formed; the white substance is produced later on the exterior. The sides acquire considerable increased thickness, while the dorsal and ventral parts remain comparatively thin, so that the cavity assumes the appearance in section of a slit, which becomes gradually narrower as the lateral thickening increases; and at last the opposite surfaces uniting in the middle divide the primary central canal into an anterior or lower and posterior or upper part (see figs. 547 and 548).

The lower of these divisions becomes the permanent central canal, the upper or dorsal is afterwards so far obliterated that it is filled with a septum of connective tissue belonging to the pia mater, and becomes the posterior fissure of the cord (in human anatomy). (Lockhart Clarke, Phil. Trans. 1862.)

In birds and mammals there is no distinction to be seen at first between the outer or corneous layer of the involuted epiblast and the cells which by their increase more immediately constitute the medullary plates. In batrachia, however, the dark colour of the corneous layer shows it to be distinct from the more strictly nervous layers. In osseous fishes there is no medullary groove or canal at first, but an involution of a solid column of cells, which is subsequently hollowed out for the formation of a ventricular cavity.

The masses of grey matter first formed in the spinal marrow correspond chiefly to the anterior columns; these are succeeded by lateral masses or columns, and somewhat later by small posterior columns. There are at first no commissures except by the passage of the deepest

Fig. 548.

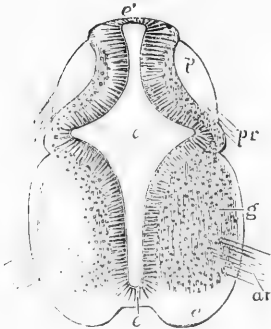


Fig. 548.—TRANSVERSE SECTION OF THE CERVICAL PART OF THE SPINAL CORD OF A HUMAN EMBRYO OF SIX WEEKS (from Kölliker). <sup>35</sup>

This and the following figure are only sketched, the white matter and a part of the grey not being shaded in. *c*, central canal; *e*, its epithelial lining, at *e* (inferiorly), the part which becomes the anterior commissure; at *e'* (superiorly), the original place of closure of the canal; *a*, the white substance of the anterior columns, beginning to be separated from the grey matter of the interior, and extending round into the lateral column, where it is crossed by the line from *g*, which points to the grey substance; *p*, posterior column; *ar*, anterior roots; *pr*, posterior roots.

layer of cells across the middle line, but the fibres from the roots of the nerves when formed are traceable into the grey substance of their respective anterior and posterior columns.

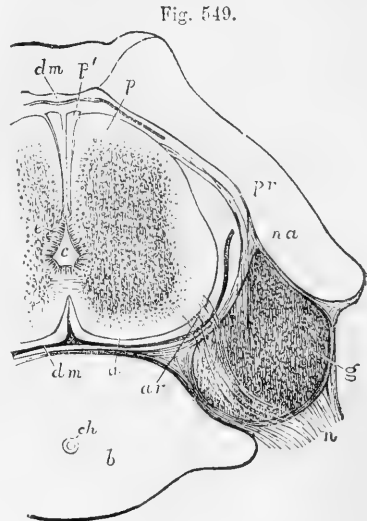
The white substance is formed external to or on the surface of the deeper grey substance; but it is not yet determined whether it is



developed out of the cells composing the grey matter or from separate blastema to which the mesoblast may in part contribute. It is combined with connective tissue elements, and its structure is different from that of the grey substance, which is undoubtedly produced by multiplication and differentiation of the involutioned epi-blastic cells.

Fig. 549.—TRANSVERSE SECTION OF HALF THE CARTILAGINOUS VERTEBRAL COLUMN AND THE SPINAL CORD IN THE CERVICAL PART OF A HUMAN EMBRYO OF FROM NINE TO TEN WEEKS (from Kölliker)  $\frac{12}{1}$

*c*, central canal lined with epithelium ; *a*, anterior column ; *p*, posterior column ; *p'*, band of Goll ; *g*, ganglion of the posterior root ; *pr*, posterior root ; *ar*, anterior root passing over the ganglion ; *dm*, dura-matral sheath, omitted near *pr*, to show the posterior roots ; *b*, body of the vertebra ; *ch*, chorda dorsalis ; *na*, neural arch of the vertebra.



On the fifth and sixth days in the chick, according to Foster and Balfour, the white columns increase rapidly in size, and the anterior median fissure begins to be formed between the anterior columns by their swelling outwards and leaving its interval between them. It is at first wide and shallow, and soon receives a lining of vascular connective tissue or pia mater. The commissures are now also formed ; the anterior grey commissure first, then the posterior grey, and somewhat later the anterior white commissure.

In the further increase of the anterior and lateral white columns as they thicken, they become more united together on each side, so that they can only be arbitrarily distinguished ; the fibres of the roots of the nerves are traced through them into the grey matter ; the cornua of grey matter become more and more developed, and the fissures between the white columns deepen, while the connective tissue or pia-matral septa run more completely inwards through the white substance.

Angular cells with radiating processes make their appearance in the grey matter, and the nerve-fibres both of the grey and white matter become more distinct.

The cylindrical cells lining the central canal retain their distinctness, and they are more completely separated from the grey matter by the delicate tissue of the ependyma. Throughout the greater part of the spinal marrow the dorsal part of the primary medullary hollow is obliterated to form the fissure, but in the sacral region of birds it opens out in the rhomboidal sinus, and in the filum terminale of the human spinal marrow the whole primary medullary cavity remains.

THE SPINAL CORD has been found by Kölliker already in the form of a cylinder in the cervical region of an embryo four weeks old. Un-united borders have been seen by Tiedemann in the ninth week towards the lower end of the cord, the perfect closing of the furrow being delayed in that part, which is slightly

enlarged, and presents a longitudinal median slit, analogous to the rhomboidal sinus in birds.

The *anterior fissure* of the cord is developed very early, and contains even at first a process of the pia mater.

Fig. 550.

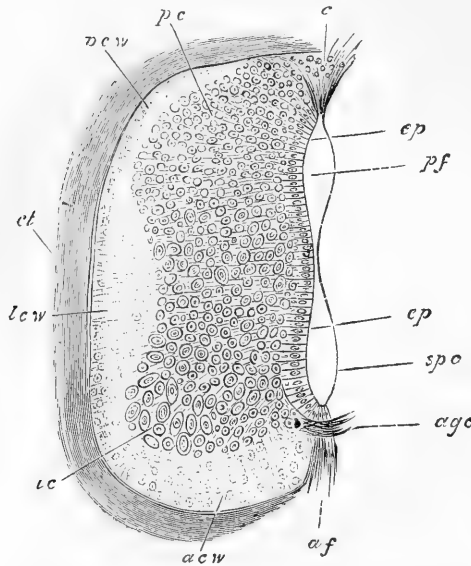


Fig. 550.—TRANSVERSE SECTION OF HALF OF THE SPINAL CORD OF THE CHICK OF SEVEN DAYS (from Foster and Balfour). MAGNIFIED.

*pcw*, posterior, *lcw*, lateral, and *acw*, anterior white columns; *pc*, posterior cornu of grey matter with small cells; *ac*, anterior grey cornu with large cells; *ep*, epithelium of the canal; *c*, the upper part now open and filled with tissue in the posterior fissure; *spc*, the lower division of the primitive medullary cavity, which remains as the permanent canal; *af*, anterior fissure left between the projecting anterior columns; *age*, anterior grey commissure.

The *cervical* and *lumbar enlargements*, opposite the attachments of the brachial and crural nerves, appear at the end of the third month: in these situations the central canal, at that time not

filled up, is somewhat larger than elsewhere (see figs. 556 and 558).

At first the cord occupies the whole length of the vertebral canal, so that there is no *cauda equina*. In the fourth month the vertebrae begin to grow more rapidly than the cord, so that the latter seems as it were to have been retracted within the canal, and the elongation of the roots of the nerves which gives rise to the *cauda equina* is commenced. At the ninth month, the lower end of the cord is opposite the third lumbar vertebra. (Kölliker, *Entwicklungsgeschichte*; Lockhart Clark in the *Phil. Trans.* 1862; Bidder und Kupfer, *Untersuch. üb. d. Rückenmark*, Leipz., 1857. Foster and Balfour, *Elements of Embryology*.)

Till lately it was believed that the roots and ganglia of the spinal nerves are at first distinct from the medullary substance of the cord, and that they originate by differentiation of cells in the mesoblastic substance of the protovertebral plate. But recent observations, to be more particularly referred to hereafter, have shown that they arise in part at least in close connection with the spinal cord itself.

#### THE BRAIN OR ENCEPHALON.

1.—*General phenomena of development as ascertained in birds and mammals.*—A reference has previously been made to the simple form in which the brain at first presents itself in the anterior dilated portion of the primitive medullary tube, and its partial division into the three primary cerebral vesicles. This is placed within simple cranial walls formed by the cephalic inflection of the blastoderm, without face or

any other parts ; so that the head of the embryo consists at first of no more than the wider part of the medullary tube and the simple enclosing wall.

Fig. 551.

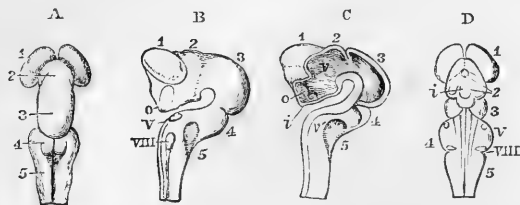


Fig. 551.—FOUR VIEWS OF THE BRAIN OF AN EMBRYO-KITTEN IN THE STAGE OF FIRST DIVISION INTO THE FIVE CEREBRAL RUDIMENTS, MAGNIFIED THREE DIAMETERS (from Reichert).

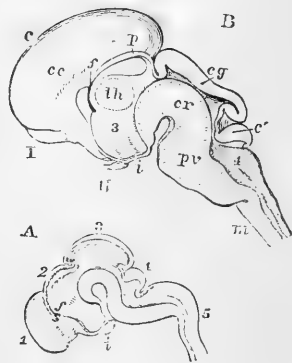
A, from above ; B, from the side ; C, vertical section showing the interior ; D, from below.

1, Cerebral hemisphere, prosencephalon ; 2, thalamencephalon ; 3, mesencephalon, still single ; 4, cerebellum, epencephalon ; 5, myelencephalon, medulla oblongata ; o, optic nerves ; V, fifth pair ; VIII, eighth pair or glossopharyngeal and pneumogastric ; i, infundibulum ; v, v', general ventricular cavity, opening at v, into the lateral ventricle by the foramen of Monro.

In the base of this wall, it will be remembered that the notochord extends forward beneath the posterior and middle of the vesicles, and occupies, therefore, the part of the cranium corresponding to the occipito-sphenoidal basis, while the trabeculæ cranii, developed forwards

Fig. 552.—VERTICAL SECTIONS OF EMBRYONIC BRAINS IN TWO STAGES OF TRANSITION FROM THE RUDIMENTARY CONDITION, MAGNIFIED THREE DIAMETERS (from Reichert).

Fig. 552.



A, Brain of the embryo pig in commencing state of transition. 1, Right cerebral hemisphere ; 2, thalamencephalon and position of the pineal gland ; 3, midbrain, with a large cavity ; f, foramen of Monro ; i, infundibulum ; 4, cerebellum ; 5, medulla oblongata.

B, Brain of the embryo of the cat more advanced. c, Cerebral hemisphere passing backwards so as to cover the other parts in succession ; I, olfactory bulb ; II, optic nerve ; th, thalamus opticus ; f, foramen of Monro ; cc, corpus callosum ; p, pineal gland ; i, infundibulum ; cg, corpora quadrigemina, not yet divided ; 3, third ventricle ; cr, crura cerebri, the aqueduct of Sylvius, now reduced in width ; c', cerebellum ; 4, fourth ventricle ; pv, Pons Varolii ; m, medulla oblongata.

from below the anterior vesicle, are prolonged in the anterior or sphenothmoidal part. The latter cerebral rudiment, therefore, which corresponds to the thalami optici and third ventricle, and which may with Huxley be conveniently called *thalamencephalon*, is at first the foremost part of the brain, and the region of the pituitary fossa lying below it is the foremost part of the cranial basis. The manner in which the development of the trabeculæ and other elements of the face modifies the

form of this region of the head has already been adverted to, and need not be repeated here.

As regards the earliest phenomena of development in the brain itself, there are three changes which mainly tend to modify its form in the most marked degree, viz., 1st, the development from the anterior vesicle on each side of the primitive ocular vesicle; 2nd, the expansion from another part, somewhat later, of the vesicles of the cerebral hemispheres; and 3rd, the formation in the forepart of the posterior encephalic vesicle of a new cerebral rudiment corresponding to the cerebellum.

Fig. 553.

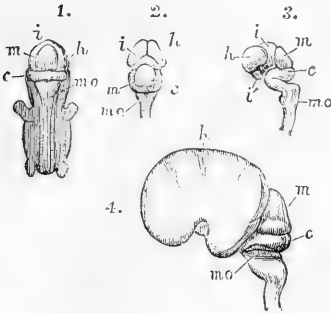


Fig. 553.—SKETCHES OF THE PRIMITIVE PARTS OF THE HUMAN BRAIN (from Kölliker).

1, 2, and 3 are from the human embryo of about seven weeks. 1, view of the whole embryo from behind, the brain and spinal cord exposed; 2, the posterior, and 3, the lateral view of the brain removed from the body; *h*, the cerebral hemisphere (prosencephalon); *i*, the thalamencephalon; *i'*, the infundibulum at the lower part of the same; *m*, the middle primary vesicle (mesencephalon); *c*, the cerebellum (epencephalon); *m o*, the medulla oblongata. Figure 3 shows also the several curves which take place in the development of the parts from the primitive medullary tube. In 4, a lateral view is given of the brain of a human embryo of three months: the enlargement of the cerebral

hemisphere has covered in the optic thalami, leaving the tubercula quadrigemina, *m*, apparent.

The formation of the primitive ocular vesicles, by an evolution of the lateral wall of the primitive medullary tube, gives to the first vesicle and the adjacent part of the head a much greater lateral width; but the cranial wall, though pushed out by the enlarging ocular vesicles, does not follow closely the inflection of their surfaces. As the subsequent contraction of the stalk of the ocular vesicles progresses, these vesicles are thrown more backwards and downwards by the change next to be described.

This is the evolution or expansion of the wall of the anterior encephalic vesicle into the two cerebral hemispheres, which takes place in front and at each side, so that the vesicles of the right and left hemispheres are from the first separate and distinct. As these vesicles become dilated, the cranial wall undergoes a corresponding expansion in the forepart of the head, and the vesicle of the thalamencephalon, which was at first the foremost part of the embryo-head, is thrown downwards and backwards into a deeper position.

The middle encephalic vesicle, increasing greatly in size, takes the most prominent part of the head superiorly, both from its own greater relative magnitude, and from the sudden bend which the head now takes below this vesicle in the great cranial curvature.

The formation of the cerebellum begins by a thickening in the upper and lateral walls of the part of the posterior primitive vesicle which is next to the midbrain, and is accompanied by a deep inflection of the medullary tube between it and the remaining part of the vesicle which forms the medulla oblongata.

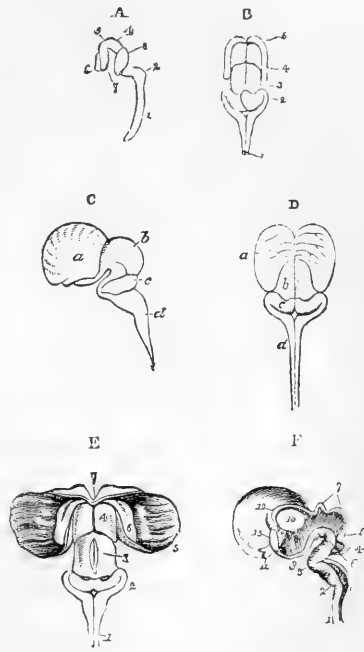
There are thus distinguished the rudiments of five fundamental constituents of the brain, under which it will be found convenient to bring the notice of the development of the several parts forming the full grown organ, and which may in this association be shortly enumerated as follows, viz. :—

1. The cerebral hemispheres, with their ventricular hollows or lateral ventricles, the corpora striata, and the olfactory lobes,—a set of parts to which, as a whole, the name of *procerebrum* or *prosencephalon* may be given.

Fig. 554.—SKETCHES OF THE EARLY FORM OF THE PARTS OF THE CEREBRO-SPINAL AXIS IN THE HUMAN EMBRYO (after Tiedemann).

A, at the seventh week, lateral view ; 1, spinal cord ; 2, medulla oblongata ; 3, cerebellum ; 4, mesencephalon ; 5, 6, 7, cerebrum. B, at the ninth week, posterior view ; 1, medulla oblongata ; 2, cerebellum ; 3, mesencephalon ; 4, 5, thalami optici and cerebral hemispheres. C and D, lateral and posterior views of the brain of the human embryo at twelve weeks. *a*, cerebrum ; *b*, corpora quadrigemina ; *c*, cerebellum ; *d*, medulla oblongata ; the thalami are now covered by the enlarged hemispheres. E, posterior view of the same brain dissected to show the deeper parts. 1, medulla oblongata ; 2, cerebellum ; 3, corpora quadrigemina ; 4, thalami optici ; 5, the hemisphere turned aside ; 6, the corpus striatum embedded in the hemisphere ; 7, the commencement of the corpus callosum. F, the inner side of the right half of the same brain separated by a vertical median section, showing the central or ventricular cavity. 1, 2, the spinal cord and medulla oblongata, still hollow ; 3, bend at which the pons Varolii is formed ; 4, cerebellum ; 5, lamina (superior cerebellar peduncles) passing up to the corpora quadrigemina ; 6, crura cerebri ; 7, corpora quadrigemina, still hollow ; 8, third ventricle ; 9, infundibulum ; 10, thalamus, now solid ; 11, optic nerve ; 12, aperture leading into the lateral ventricle ; 13, commencing corpus callosum.

Fig. 554.



2. The *thalamencephalon* with its cavity or third ventricle, the primary ocular pedicles, and the infundibulum.

3. The *mesencephalon*, which is the same with the original middle vesicle, and comprises the corpora quadrigemina and crura cerebri with its contracted internal hollow, the *iter a tertio ad quartum ventriculum* of human anatomy.

4. The next part in succession is the *cerebellum*, along with which is included the pons Varolii and the fourth ventricle.

5. The hinder part, which passes into the spinal marrow, is the medulla oblongata, with the continuation of the medullary cavity in the fourth ventricle and into the central spinal canal.

In these five fundamental parts or rudiments of the brain, arising out

of very simple modifications of the primitive medullary tube, it is mainly by an increased thickening of the medullary wall in some of the parts, and the relative thinning, or even the removal of the substance in others, that the changes accompanying the formation of the cerebral masses are effected, while as a consequence of these and other modifications of form, the several parts of the internal cavity or ventricles of the brain acquire the different degrees of expansion and contraction, or the comparatively closed or open condition which they exhibit in after life. Thus the cerebral hemispheres, and corpora striata are the main masses formed by the lateral thickening and expansion of the medullary walls of the procerebrum, while the corpus callosum and fornix are formed later by a deeper median development in connection with these parts: the thalami optici are the most solid parts of the lower and lateral region of the second rudiment, while in the upper wall the pineal gland, and in the lower the infundibulum with the hypophysis cerebri, are added: the corpora quadrigemina are thickenings of the upper wall of the third rudiment, while the crura cerebri arise by increased deposit in its lower part; the cerebellum is a large deposit in the upper wall of the fourth rudiment, while the pons Varolii is a thickening of its lower wall; and the parts composing the medulla oblongata are principally formed by increased deposit in the lower and lateral wall of the fifth rudiment.

Thus, also, the lateral ventricles are two lateral expansions of the forepart of the original ventricular cavity which follow the dilatation of the vesicles of the right and left cerebral hemispheres, and communicate with the central or third ventricle by the common foramen of Monro. The central or third ventricle, originally the foremost part of the medullary hollow, is narrowed on the sides by the increased development of the thalami optici, while inferiorly it is prolonged and projects downwards as infundibulum into the pituitary fossa; and above the wall of this ventricle comes to be opened up by the thinning away of its medullary substance, excepting at the place where it is crossed by the pineal gland. The continuation backwards of the original ventricular hollow, greatly narrowed by the ultimate thickening of the substance of the corpora quadrigemina and crura cerebri, forms the aque-

Fig. 555.

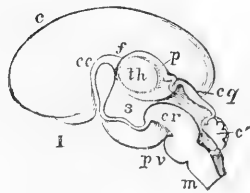


Fig. 555.—VERTICAL SECTION OF THE BRAIN OF A HUMAN EMBRYO OF FOURTEEN WEEKS, MAGNIFIED THREE DIAMETERS (from Reichert).

*c*, cerebral hemisphere; *cc*, corpus callosum beginning to pass back, *f*, foramen of Monro; *p*, membrane over the third ventricle and the pineal gland; *th*, thalamus opticus; *3*, third ventricle; *I*, olfactory bulb; *cq*, corpora quadrigemina, mesencephalon; *cr*, crura cerebri, and above them the aqueduct of Sylvius still wide; *c'*, cerebellum, and below it the fourth ventricle; *pv*, Pons Varolii; *m*, medulla oblongata.

duct of Sylvius, or the iter a tertio ad quartum ventriculum, and is succeeded by the more expanded cavity of the fourth ventricle, lying between the cerebellum and the lower wall. The upper wall of the latter cavity undergoes great thinning, like that of the third ventricle, so as to be reduced in the part before the cerebellum to the valve of Vieussens,

and in the part behind it to be covered only by membrane, and to present an opening from the cavity into the posterior sub-arachnoid space.

From what has before been said of the relation of the fundamental parts of the brain to the basis of the skull, it will be seen that the cerebral development is intimately connected also with the great cranial flexure which occurs at the pituitary fossa; for while the infundibular prolongation of the thalamencephalon projects down into this fossa, and the lamina terminalis rises in front in the position of the original foremost part of the encephalon, certain parts of the brain may be considered as situated posterior to this point, viz., the mesencephalon with crura cerebri, cerebellum with pons Varolii, and medulla oblongata, while the cerebral hemispheres, with the corpora striata, corpus callosum, and fornix, notwithstanding their enormous proportional development, may be considered as formed by forward expansion, and as situated in front of this turning point. But though the connections of the cerebral hemispheres with the rest of the brain may thus be considered as anterior to the cranial centre, and while in their earlier stages, and still of small size, they are actually placed as in the lowest Vertebrates, entirely in front of it, yet by the later great proportional development in the higher animals, and especially in man, the cerebral hemispheres come to progress backwards, and successively to cover superiorly the thalami, corpora quadrigemina, the cerebellum, and the medulla oblongata.

The connection of the several parts of the brain, with the five fundamental parts respectively, may be stated in the following tabular form :

|                                 |                     |                                                                                                                      |
|---------------------------------|---------------------|----------------------------------------------------------------------------------------------------------------------|
| I. Anterior primary Vesicle.    | 1. Prosencephalon.* | { Cerebral Hemispheres, Corpora Striata, Corpus Callosum, Fornix, Lateral Ventricles, Olfactory bulb (Rhincephalon). |
|                                 |                     | 2. Thalamencephalon. (Diencephalon.)                                                                                 |
| II. Middle primary Vesicle,     | 3. Mesencephalon.   | { Corpora Quadrigemina, Crura Cerebri, Aqueduct of Sylvius, Optic nerve (secondarily).                               |
| III. Posterior primary Vesicle. | 4. Epencephalon.    | { Cerebellum, Pons Varolii, anterior part of the Fourth Ventricle.                                                   |
|                                 | 5. Metencephalon.   | { Medulla Oblongata, Fourth Ventricle, Auditory nerve.                                                               |

The changes which take place in the growth of the brain were first elaborately described by Tiedemann; they have been investigated by Von Baer, Bischoff, Remak, Reichert, Kölliker, and others. (Tiedemann, "Anatomie und Bildungsgeschichte des Gehirns," Nürnberg, 1816; Reichert, "Bau des Menschlichen Gehirns," Leipzig, 1859, 1861; F. Schmidt, "Beiträge z. Entwick. des Gehirns," in "Zeitschr. f. Wissen. Zool.," 1862; Kölliker, "Entwicklungsgeschichte," 1861.)

**FARTHER DEVELOPMENT OF THE BRAIN IN MAN AND MAMMALS.**

The medulla oblongata is not completely closed in above by nervous matter. The open part of the medullary tube constitutes the floor of the *fourth ventricle*, which communicates below with the canal of the spinal cord at the place where the calamus scriptorius is eventually formed, and opens posteriorly into the subarachnoid space.

\* This and the four following terms are adopted as applicable to the principal secondary divisions of the primordial medullary tube, and as corresponding to the commonly received names of the German embryologists, viz., Vorderhirn, Zwischenhirn, Mittelhirn, Hinterhirn, and Nachhirn; or their less used English translations, viz., forebrain, interbrain (tweenbrain), midbrain, hindbrain, and afterbrain.

The three constituent parts of the medulla oblongata begin to be distinguished about the third month; first the *restiform* bodies, which are connected with the commencing cerebellum, and afterwards the anterior pyramids and olives. The *anterior pyramids* become prominent on the surface and distinctly defined in the fifth month; and by this time also their decussation is evident. The *olivary fasciculi* are early distinguishable, but the proper *olivary body*, or tubercle, does not appear till about the sixth month. The *fasciolar cinerea* of the fourth ventricle can be seen at the fourth or fifth month, but the *white stria* not until after birth.

**Cerebellum.**—In the human embryo the cerebellum exists at the end of the second month, as a delicate medullary lamina, forming an arch behind the corpora quadrigemina across the widely open primitive medullary tube.

According to Bischoff, the cerebellum does not commence, as was previously supposed, by two lateral plates which grow up and meet each other in the middle line; but a continuous deposit of nervous substance takes place across this part

Fig. 556.

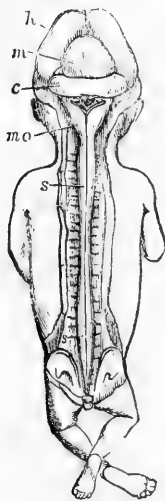


Fig. 556.—BRAIN AND SPINAL CORD EXPOSED FROM BEHIND IN A FŒTUS OF THREE MONTHS (from Kolliker).

*h*, the hemispheres; *m*, the mesencephalic vesicle or corpora quadrigemina, *c*, the cerebellum; below this are the medulla oblongata, *mo*, and fourth ventricle, with remains of the membrana obturatoria. The spinal cord, *s*, extends to the lower end of the sacral canal and presents the brachial and crural enlargements.

of the medullary tube, and closes it in at once. This layer of nervous matter, which is soon connected with the corpora restiformia, or inferior peduncles, increases gradually up to the fourth month, at which time there may be seen on its under surface the commencing *corpus dentatum*. In the fifth month a division into five *lobes* has taken place; at the sixth, these lobes send out *folia*, which are at first simple, but afterwards become subdivided. Moreover, the *hemispheres* of the cerebellum are now relatively larger than its median portion, or *worm*. In the seventh month the organ is more complete, and the *glocculus* and *posterior verum*, with the other parts of the inferior vermiform process, are now distinguishable, except the *amygdalæ*, which are later in their appearance.

Of the *peduncles* of the cerebellum, the *inferior* pair (corpora restiformia) are the first seen—viz., about the third month; the *middle* peduncles are perceptible in the fourth month; and at the fifth, the *superior* peduncles and the Vieussenian valve. The *pons Varolii* is formed, as it were, by the fibres from the hemispheres of the cerebellum embracing the pyramidal and olivary fasciculi of the medulla oblongata. According to Baer, the bend which takes place at this part of the encephalon thrusts down a mass of nervous substance before any fibres can be seen; and in this substance transverse fibres, continuous with those of the cerebellum, are afterwards developed. From its relation to the cerebellar hemispheres the pons keeps pace with them in its growth; and, in conformity with this relation, its transverse fibres are few, or entirely wanting, in those animals in which there is a corresponding deficiency or absence of the lateral parts of the cerebellum.

**Parts connected with the Mesencephalon.**—The *corpora quadrigemina* are formed in the upper part of the middle cephalic vesicle; the hollow in the interior of which communicates with those of the first and third vesicles. The corpora quadrigemina, in the early condition of the human embryo, are of great proportionate volume, in harmony with what is seen in the lower vertebrata; but subsequently they do not grow so fast as the anterior parts of the encephalon, and are therefore soon overlaid by the cerebral hemispheres, which



at the sixth month cover them in completely. Moreover, they become gradually solid by the deposition of matter within them; and as, in the meantime, the *cerebral peduncles* are increasing rapidly in size in the floor of this

Fig. 557.—BRAIN OF THE HUMAN EMBRYO OF THREE MONTHS. NATURAL SIZE (from Kölliker).

In 1 the view is from above, the upper part of the cerebral hemispheres and mesencephalon having been removed. *f*, fore-part of the divided wall of the hemisphere; *f'*, hind part of the same turned in which becomes the hippocampus; *cs*, corpus striatum; *th*, thalamus opticus.

In 2 the lower surface is represented; *to*, tractus opticus; and in front of this the olfactory bulbs and tracts; *cm*, single mass of the corpora mammillaria not yet divided; *p*, pons Varolii. The cerebellum and medulla oblongata are seen behind and to the sides in both figures.

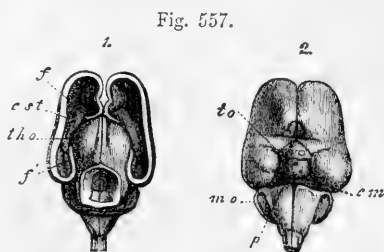


Fig. 557.

middle cephalic vesicle, the cavity in its interior is quickly filled up, with the exception of the narrow passage named the *Sylvian aqueduct*. The fillet is dis-

Fig. 558.—BRAIN AND SPINAL CORD OF A FŒTUS OF FOUR MONTHS, SEEN FROM BEHIND (from Kölliker).

*h*, hemispheres of the cerebrum; *m*, corpora quadrigemina or mesencephalon; *t*, cerebellum; *mo*, medulla oblongata, the fourth ventricle being overlapped by the cerebellum; *ss*, the spinal cord with its brachial and crural enlargements.

tinguishable in the fourth month. The corpora quadrigemina of the two sides are not marked off from each other by a vertical median groove until about the sixth month; and the transverse depression separating the anterior and posterior pairs is first seen about the seventh month of intra-uterine life.

**Thalamencephalon.**—From the sides of this vesicle, as has already been described, the optic vesicles are formed, and from its forepart on the two sides the vesicles of the cerebral hemispheres are developed. Reichert first pointed out that there is left between the *hemisphere-vesicles* of opposite sides a wedge-shaped interval, which forms the third ventricle. He points out that the terminal extremity (lamina terminalis) of the cerebrospinal tube is at the tip of this wedge, and is placed immediately in front of the optic commissure, at the lamina cinerea; and that therefore the infundibulum is not that extremity, as had been previously supposed by Baer, but is an expansion of the vesicle downwards.

The formation of the pituitary body has already been described. The infundibulum of the thalamencephalon becomes connected with it superiorly, and seems for a time even to form a part of it.

The *pineal gland*, according to Baer, is developed from the back part of the thalami, where those bodies continue joined together; but it is suggested by Bischoff that its development may be rather connected with the pia mater. It was not seen by Tiedemann until the fourth month in the human fœtus; subsequently its growth is very slow; and it at first contains no gritty deposit: this, however, was found by Sömmerring at birth.

Fig. 558



The two *optic thalami*, formed from the posterior and outer part of the anterior vesicle, consist at first of a single hollow sac of nervous matter, the cavity of which communicates on each side in front with the anterior of the commencing

Fig. 559.

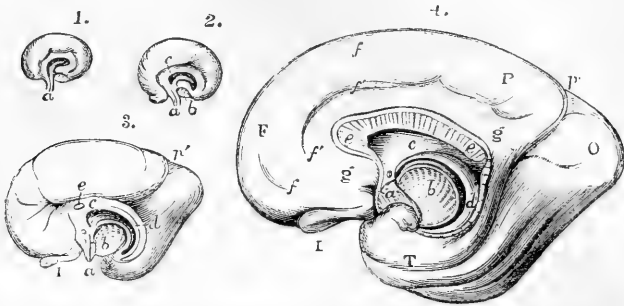


Fig. 559.—SEMIDIAGRAMMATIC VIEWS OF THE INNER SURFACE OF THE RIGHT CEREBRAL HEMISPHERE OF THE FETAL BRAIN AT VARIOUS STAGES OF DEVELOPMENT (from Schmidt).

1, 2, and 3, are from foetuses of the respective ages of eight, ten, and sixteen weeks ; 4, from a foetus of six months. *a*, lamina terminalis or part of the first primary vesicle which adheres to the sella turcica ; *b*, section of the cerebral peduncle as it passes into the thalamus and corpus striatum ; the arched line which surrounds this bounds the great cerebral fissure ; *c*, anterior part of the fornix and the septum lucidum ; *d*, inner part of the arch of the cerebrum, afterwards the hippocampus major and posterior part of the fornix ; *e*, corpus callosum very short in 3, elongated backwards in 4 ; in 4, *f*, the superior marginal convolution ; *f'*, fronto-parietal fissure ; *g*, gyrus fornicatus ; *p'*, the internal vertical fissure descending to meet the fissure of the hippocampus ; I, olfactory bulb ; F, P, O, T, frontal, parietal, occipital and temporal lobes.

cerebral hemispheres, and behind with that of the middle cephalic vesicle (corpora quadrigemina). Soon, however, by increased deposit taking place in

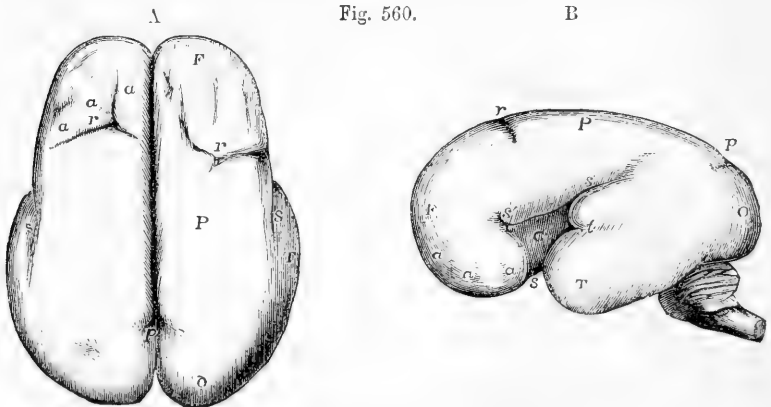


Fig. 560.

Fig. 560.—THE SURFACE OF THE FETAL BRAIN AT SIX MONTHS (from R. Wagner).

This figure is intended to show the commencement of the formation of the principal fissures and convolutions.  $\Delta$ , from above ; B, from the left side. F, frontal lobe ; P, parietal ; O, occipital ; T, temporal ; *a*, *a*, *a*, slight appearance of the several frontal convolutions ; *s*, the Sylvian fissure ; *s'*, its anterior division ; within it, C, the central lobe or convolutions of the island ; *r*, fissure of Rolando ; *p*, the vertical fissure (external part).

their interior behind, below, and at the sides, the thalami become solid, and at the same time a cleft or fissure appears between them above, and penetrates down to the internal cavity, which continues open at the back part opposite the entrance of the Sylvian aqueduct. This cleft or fissure is the *third ventricle*. Behind, the two thalami continue united by the *posterior commissure*, which is distinguishable about the end of the third month, and also by the *peduncles of the pineal gland*. The *soft commissure* probably exists from an early period, although it could not be detected by Tiedemann until the ninth month.

At an early period the *optic tracts* may be recognised as hollow prolongations from the outer part of the wall of the thalami while they are still vesicular. At the fourth month these tracts are distinctly formed. They subsequently are prolonged backwards into connection with the corpora quadrigemina.

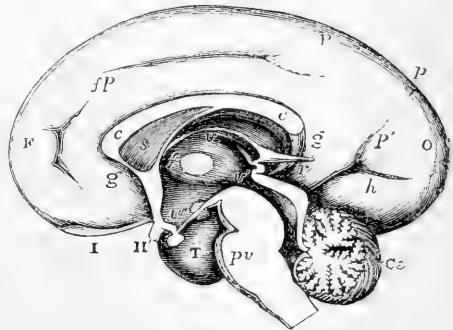
**Prosencephalon.**—Each *hemisphere-vesicle* becomes divisible into two parts: one of these is the part which from the interior appears as the corpus striatum, and from the exterior as the island of Reil, or central lobe; the other forms the expanded or covering portion of the hemisphere, and is designated by Reichert the *mantle*. The aperture existing at the constricted neck of the hemisphere-vesicle, Schmidt and Reichert have recognised as the foramen of Monro.

The *corpora striata*, it will be observed, have a different origin from the optic thalami; for, while the latter are formed by thickening of the circumferential wall of a part of the first cerebral vesicle, and thus correspond in their origin with all the parts of the encephalon behind them, which are likewise derived from portions of the cerebro-spinal tube, the corpora striata appear as thickenings of the floor of the hemisphere-vesicles, which are lateral off-shoots from the original cerebro-spinal tube. On this account, Reichert considers the brain primarily divisible into the stem, which comprises the whole encephalon forwards to the tænia semicircularis, and the hemisphere-vesicles, which include the corpora striata and hemispheres.

Fig. 561.—VIEW OF THE INNER SURFACE OF THE RIGHT HALF OF THE FETAL BRAIN OF ABOUT SIX MONTHS (from Reichert).

F, frontal lobe; P, parietal; O, occipital; T, temporal; I, olfactory bulb; II, right optic nerve; *fp*, fronto-parietal fissure; *p*, vertical fissure; *p'*, internal vertical fissure; *h*, hippocampal fissure; *g*, gyrus formicatus; *c*, *c*, corpus callosum; *s*, septum lucidum; *f*, placed between the middle commissure and the foramen of Monro; *v*, in the upper part of the third ventricle immediately below the velum interpositum and fornix; *v'*, in the back part of the third ventricle below the pineal gland, and pointing by a line to the aqueduct of Sylvius; *v''*, in the lower part of the third ventricle above the infundibulum; *r*, recessus pinealis passing backwards from the tela choroidea; *pv*, pons Varolii; *Ce*, cerebellum.

Fig. 561.



The cerebral hemispheres enlarging, and having their walls increased in thickness, form, during the fourth month (Tiedemann), two smooth shell-like lamellæ, which include the cavities afterwards named the *lateral ventricles*, and the parts contained within them. Following out the subsequent changes affecting the exterior of the cerebral hemispheres, it is found that about the fourth month the first traces of some of the *convolutions* appear, the intermediate *sulci* commencing only as very slight depressions on the hitherto smooth surface. Though the hemispheres continue to grow quickly upwards and backwards, the *convolutions* at first become distinct by comparatively slow degrees; but towards

the seventh and eighth months they are developed with great rapidity, and at the beginning of the last month of intra-uterine life, all the principal ones are marked out.

The *Sylvian fissure*, which afterwards separates the anterior from the middle lobe of each hemisphere, begins as a depression or cleft between them about the fourth month, and, after the great longitudinal, is the first of the fissures to make its appearance. It is followed by the fissure of Rolando, and the vertical or parieto-occipital fissure, and somewhat later by the internal fronto-parietal fissure. After this, the various subordinate fissures dividing the convolutions gradually make their appearance. By the end of the third month the hemispheres have extended so far backwards as to cover the thalami; at the fourth they reach the corpora quadrigemina; at the sixth they cover those bodies and great part of the cerebellum, beyond which they project still further backwards by the end of the seventh month.

During the growth of the hemisphere the aperture of the foramen of Monro is extended backwards; the arched margin of this opening is curved downwards at its extremities, and forms anteriorly the fornix, and posteriorly the corpus fimbriatum and hippocampus major; above the margin a part of the wall of each hemisphere comes into contact with its fellow, and in the lower part forms the septum lucidum, while above this the hemispheres are united by the development of the great commissure, the corpus callosum.

The *corpus callosum* is described by Tiedemann as being first seen about the end of the third month, as a narrow vertical band, extending across between the forepart of the two hemispheres, and subsequently growing backwards. With this view the observations of Schmidt coincide. Reichert, however, maintains that the commissural structure seen at the forepart of the hemispheres is the anterior white commissure, and that the corpus callosum appears in its whole extent at once.

The *corpora albicantia* at first form a single mass: so also do the *anterior pillars* of the fornix, which are distinguished before the posterior pillars. The *posterior pillars* are not seen until the fourth or fifth month. At that period the *hippocampus minor* is also discernible.

#### DEVELOPMENT OF THE NERVES.

**Spinal Nerves.**—Very little is yet known as to the mode of origin of the nerves. In their peripheral extension the great majority of them seem to arise more immediately from mesoblastic formative elements, and the manner in which this takes place has been adverted to in the General Anatomy at p. 161. The ganglia and roots of the spinal nerves are first seen to make their appearance in some very close association with the protovertebral segments. In this the ganglion comes to be distinguishable as a mass by itself, and the anterior and posterior roots follow, with their junction in the part forming the nerve-trunk beyond the ganglion. But according to recent observations by Balfour in Elasmobranch fishes (*Scyllium* and *Torpedo*), it would appear that both the anterior and posterior roots may arise in these animals in a closer connection with the nervous centre than was previously believed, and as independent outgrowths from the involuted epiblast of the neural canal. The posterior roots are the first to appear, and commence by an outgrowth at the summit (dorsal median groove) of the neural canal, and gradually pass outwards from thence to reach their permanent place of origin in a posterior lateral furrow. A subsequent division of the nerve rudiment takes place into root, ganglion, and a part of the nerve beyond.

The anterior roots spring by an outgrowth from the antero-lateral angles of the cord, one for each muscular plate nearly in the place

which they permanently occupy, and after they have attained some size they unite with the posterior roots beyond the ganglion.

But although the roots of the nerves may thus be traced in their commencement to elements of epiblastic nature, it is probable that their sheaths and blood-vessels arise from mesoblastic tissue introduced later into them. The ganglia are at first of proportionally very large size, causing even a considerable part of the projections on the surface of the body, as in the human embryo of from four to seven weeks, which are usually attributed to the vertebrate segmentation (Kölliker). The union of the roots with the grey matter soon becomes apparent, being most obvious in the anterior roots.

The nerves, like the other elementary parts, are at first composed entirely of cells, but fibres are soon formed by transformation of the cells. On the sixth day in the chick, Foster and Balfour found the fibres developed, but were unable to trace them into connection with the ganglionic cells, but at a later period the connection was observed by Lockhart Clarke to be formed.

The very early development of the trunks of the nerves of the limbs, and their progress outwards into the first part of the commencing limb, were observed and figured by Remak.

**Cranial Nerves.**—The optic nerve and the retina, arise from epiblast by an extension of the primary medullary wall of the brain, as already described, and may therefore, in some sort, be regarded as an extension of the brain itself. The olfactory tract and bulb are still more to be looked upon as constituent parts of the cerebrum; but the manner in which the peripheral olfactory nerves which pass through the cribriform plate into the nose are formed has not been yet observed.

Among the other cranial nerves there are four important ones of which the rudiments are seen to be formed at an early period; taking their origin as has been supposed in the mesoblastic wall of the cranial cavity, and extending thence into the facial or visceral plates. These are the fifth pair or trifacial, the facial or portio dura of the seventh pair, the glosso-pharyngeal and the pneumogastric nerves. The two first of these are situated in front, and the two last behind the otic vesicle and tympano-eustachian passage; and according to Parker each of these nerves forks or divides into two above one of the visceral clefts. Thus the fifth pair gives its naso-maxillary division in front, and its infero-maxillary division behind the oral cleft; the facial gives its vidian or superior petrosal before and its descending part behind the tympano-eustachian passage; the glosso-pharyngeal has its lingual and pharyngeal branches divided by the first branchial cleft, and in animals the pneumo-gastric is similarly divided at the second and succeeding clefts.

The third, fourth and sixth pairs of nerves are of subordinate importance, and may be considered as related, the two first to the fifth pair, and the last to the facial nerve. Their peripheral parts are developed in connection with the muscles of the eyeball, but the mode of the formation of their roots in connection with the nervous centres has not been ascertained.

The hypoglossal nerve, although it passes through the exoccipital bone in man, may be compared to a spinal nerve, and probably takes its origin much in the same manner.

**The Sympathetic Nerves.**—Remak observed the development of the great sympathetic nerves from the lateral plates in loops or arches

connecting them with the spinal nerves; while the great sympathetic itself consisted at first of a chain of rounded masses representing the ganglia, connected together, but so closely set that scarcely any intervening nervous cord was at first perceptible. He also observed the separate formation in the mesentery of birds of the large visceral nerve which he discovered in these animals. The gangliated cord of the sympathetic has been described and figured by Kölliker in the human foetus of eight or ten lines long. The peripheral sympathetic nerves are also formed at a very early period, and are perceptible in a foetus of three months. In the hinder part of the abdomen their origin appears to be intimately connected in some way with the formation of the suprarenal bodies.

#### DEVELOPMENT OF THE EYE.

The embryonic structures forming the eyeball and its contents may be considered as proceeding from three sources, viz., 1st, by evolution or expansion from the medullary wall of the first encephalic vesicle (thalamencephalon), giving rise to the retina, in its nervous and pigmental structure and optic nerve; 2nd, by involution or depression and development of a part of the cuticular epiblast, forming the foundation of the lens and the epithelium of the conjunctiva; and 3rd, by the intrusion of mesoblastic elements between and around the other parts, so as to furnish the materials out of which are formed the general coverings of the eyeball, cornea and sclerotic, the fibrous and vascular choroid, the ciliary apparatus and iris, the capsule of the lens and the capsulo-pupillary membrane, the vitreous humour, and all the fibrous and vascular parts of the organ.

The very early formation of the primary optic vesicles by the expansion of the lower and anterior parts of the wall of the anterior primary encephalic vesicle has already been described, and the manner in which each of these vesicles forms a hollow pediculated chamber communicating by its stalk with the general ventricular cavity of the primitive brain. The first important change which the primary optic vesicles undergo is connected with the depression of the rudimentary lens from

Fig. 562.

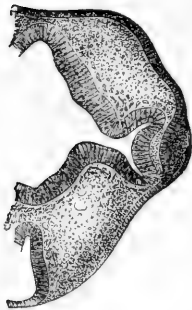


Fig. 562.—SECTION OF THE HEAD THROUGH THE PRIMITIVE OPTIC CAPSULE OF ONE SIDE IN AN EMBRYO-CALF OF 9 MM. LONG, MAGNIFIED (from Julius Arnold).

To the right is seen the optic capsule with its contracted pedicle and its outer wall depressed by the thickening of the corneous layer which forms the commencement of the formation of the lens. The optic stalk is in communication with the thalamencephalon. Mesoblast is seen between the optic capsule and the lens rudiment.

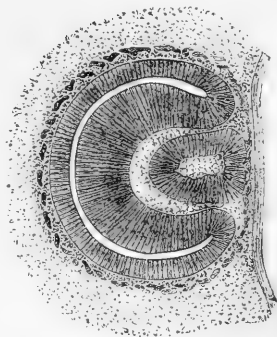
without, and consists in a doubling back or inwards of the medullary wall of each vesicle, so as to form a depression or *cup* at its lower and anterior part, into which the commencing lens in part sinks. This depression has been called the secondary optic vesicle, or the *optic cup* (Foster and Balfour). From a very early period the outer fold of this cup undergoes a much greater thickening by the rapid development of its

cellular constituents than the inner or that towards the brain, and from this, as well as the increase of the inward folding, the original cavity of the primary optic vesicle becomes in a great measure obliterated or narrowed, and the outer and inner folds are closely approximated, while the stalk or pedicle becomes proportionally much diminished. The continued increase of cellular development in the outer fold of this cup leads to the formation of the various elements composing the retina; while in the thinner inner fold only pigment cells are formed. The transition at the bend from the thick nervous part to

Fig. 563.—SECTION THROUGH THE EYE OF AN EMBRYO-CALF OF TWELVE MM., OR HALF AN INCH, LONG, MAGNIFIED (from Julius Arnold).

Fig. 563.

The lens follicle is now closed in and detached from the corneous layer, and its cavity contains loose cells which are the remains of the superficial corneous cells. The optic vesicle or capsule is now completely doubled back, so as to present towards the lens side the secondary ocular capsule or cup; its outer wall now much thickened by the commencement of the development of retina. Mesoblastic tissue is seen to have passed in from the periphery between the optic capsule and the lens, as well as in front of the lens. The commencement of a vascular circle is shown round the exterior of the ocular capsule, and extending also between the lens follicle and the cuticle.

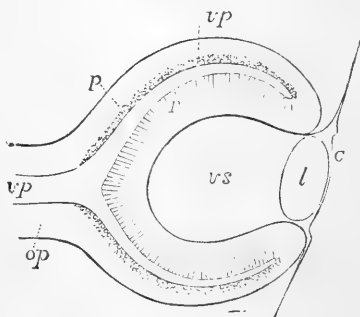


the thin pigmental part is quite sudden, and as soon as pigment cells begin to be developed, a very marked distinction is perceptible between it and the nervous structure of the retina. These cells were formerly regarded as a part of the choroid membrane, but they are now looked upon as belonging rather to the retina,—a view which is supported by the mode of development now described.

Fig. 564.—DIAGRAMMATIC SKETCH OF A VERTICAL LONGITUDINAL SECTION THROUGH THE EYEBALL OF A HUMAN FŒTUS OF FOUR WEEKS (after Kölliker).  $\frac{100}{1}$

Fig. 564.

The section is a little to the side so as to avoid passing through the ocular cleft. *c*, the cuticle, where it becomes later the cornea; *l*, the lens; *op*, optic nerve formed by the pedicle of the primary optic vesicle; *vp*, primary medullary cavity of the optic vesicle; *p*, the pigment-layer of the outer wall; *r*, the inner wall forming the retina; *vs*, secondary optic vesicle containing the rudiment of the vitreous humour.



The fold which produces the optic cup proceeds from above downwards, and when the lens is formed it seems as if it enclosed the lens but left for a time an aperture or depression below. This is the *choroidal fold* or fissure, which may easily be distinguished in the embryo-head after pigment has been deposited, from the circumstance that the pigment is absent from the cleft, which thus appears for a

time as a broad white line, particularly obvious in the embryo bird, running from the circumference in upon the lens.

The lens is developed in the part of the cuticle opposite to the most projecting part of the primary optic vesicle, or at the place where this vesicle comes in contact with the surface of the head. In this situation there is seen from a very early period a thickening of the epiblast, which seems to reside chiefly in its deeper layer of cells, and in birds and mammals it would appear that an actual involution of the cuticle takes place, so that first an open follicle and next an enclosed ball of cuticle is formed. Although, however, both the corneous and the deeper layer (sensory of Stricker) of the cuticle are enclosed, it is only the cells of the deeper layer which undergo development into the fibres of the lens. The ball of the lens separating from the external cuticle, which passes freely over the surface, a cavity filled with loose cells, the remains of cells of the corneous layer, exists for a time within the lens ball. Then the cells of the hinder or inner wall are seen to rise from the bottom by their elongation, and thus a rapid growth of fibres from that side of the ball takes place, while the anterior or outer wall undergoes no similar change, but retains its simply cellular structure. Figures 565, and 566, show sufficiently clearly the manner in which the fibres thus developed from cells rise from the bottom of the lens ball and come to constitute the solid part of the lens.

The optic cup receives the enlarging lens in its anterior and lower opening, and the reflected margins of the cup closely embrace the margin of the lens; but there is a considerable space intervening between the lens and the hollow of the optic cup (or secondary ocular vesicle), which comes to be occupied by the vitreous humour. Into this space connective tissue and blood-vessels developed from mesoblastic

Fig. 565.

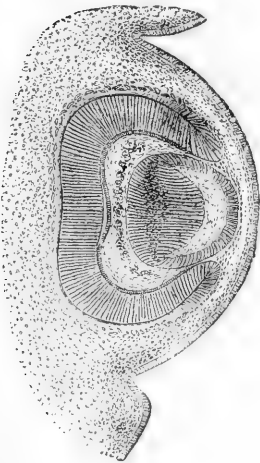


Fig. 565.—SECTION OF THE EYE IN AN EMBRYO-CALF OF 18 MM. LONG, MAGNIFIED (from Julius Arnold).

The posterior or inner wall of the lens follicle is now much thickened by the elongation of its fibres, each of which presents a nucleus, and the whole causing a bulging of the posterior wall. The outer layer of the lens capsule consists of columnar cells. The cavity of the lens follicle is still visible, but is now widened and flattened. Two layers of mesoblastic tissue are now visible between the lens and the cuticle, viz., a deeper vascular layer and a superficial non-vascular one containing nuclei. The secondary optic capsule is now occupied by connective tissue nuclei and numerous blood-vessels. The retinal section of the primitive ocular vesicle is now thicker. Pigment begins to appear in the choroidal section, and numerous blood-vessels surround the whole exterior.

elements are projected from below, so as to furnish the materials for the formation of the vitreous humour and the blood-vessels which pass through it to the lens, and also to surround the lens with vascular and fibrous elements, out of which are produced the *capsulo-pupillary membrane*, and probably also the capsule of the lens. It results from the



observations of Lieberkühn that in mammals the fold which produces the ocular cup or secondary vesicle runs back into the stalk so as to fold in the optic nerve for a considerable space, and by the simultaneous intrusion of mesoblastic tissue, thus to lead to the introduction of the central blood-vessels of the retina within the nerve. But in birds, according to the same observer, no such infolding of the stalk occurs, so that in them the vessels are excluded from the nerve. The malformation termed coloboma iridis is to be attributed to a persistence of the choroidal cleft or fold, and the pecten of birds, close to the optic nerve, with the vascular fold farther forwards, and the falciform fold of the eyes of fishes are to be regarded as fibro-vascular structures formed by original projection through the same fold.

The **further development** of the parts of the eye may be briefly stated as follows :—

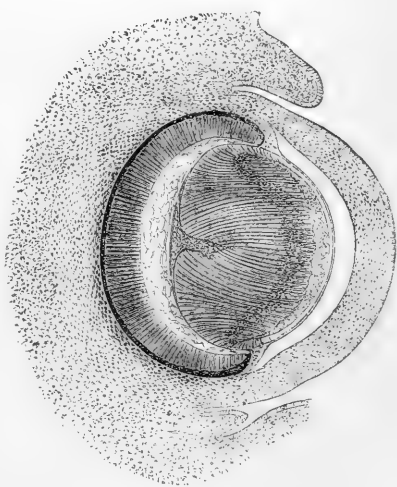
The expansion of the ocular cup continuing to proceed, the chamber for the vitreous humour enlarges, and that structure gradually comes to occupy its space between the retina and the lens.

The marked distinction between the nervous and the pigmental portions of the primitive ocular vesicle goes on increasing by the continued deposit of pigment in the latter, and its proportional thinning, and by the great addition to the thickness and the textural differentiation of the substance of the former. Thus the cells in the retinal or nervous portion, by their rapid multiplication, soon become several layers thick ; certain parts of these cells assume the spindle shape, and exhibit elongation into fibres, while others retain the nuclear form, and thus there is foreshadowed the division into the fibrous, ganglionic, and nuclear layers of the retina. On the exterior a limiting membrane

Fig. 566.—SECTION OF THE EYE OF AN EMBRYO-CALF OF 30 MM. LONG, MAGNIFIED (from Julius Arnold).

The cavity of the lens is much reduced in size from the increased development of fibres from behind. The intersection space begins to be formed posteriorly, and the zone of nuclei is thrown forward. The cornea is now formed, covered externally by the cuticular epithelium, and with the separation of the aqueous chamber internally. Close to the lens is the capsulo-pupillary membrane, which is continuous with the vascular structure occupying the secondary ocular capsule or cavity for the vitreous humour, and with the choroid membrane round the margin of the ocular capsule, where iris and ciliary processes will afterwards be formed. The layer of pigment is now more developed, and the tissue of the sclerotic is begun to be formed. The eyelids are beginning to project as folds of the skin.

Fig. 566.



makes its appearance, and in connexion with it the rudiments of the cells composing the layer of rods and cones. The space between the

retinal and pigmental layers rapidly contracts, and finally the rods and cones are closely united with the layer of pigment cells.

The optic nerve, as already described, is at first connected by its origin with the vesicle of the third ventricle or thalamencephalon, and for a time it retains its original hollow form. But as the cerebral hemispheres are developed forwards, the eye and the optic nerve are thrown backwards and downwards, and a new connection is established between the optic nerve (or tract) and the vesicle of the midbrain (mesencephalon): the rudiment of the optic commissure is at the same time formed by the median approximation of the stalks and the growth of one over the other. Each stalk then becomes more and more solid by the development of nerve fibres along with the intruded connective tissue which forms the sheath substance of the nerve.

**Lens.**—The development of fibres from the hinder wall of the primitive lens-follicle continuing to take place, the cavity of the follicle is first greatly narrowed and then completely filled up by the lengthening fibres, and the lens takes more and more of its full spherical shape. The new fibres continue to be formed towards the margin of the lens; each fibre retaining its nucleus, so as to produce the *nuclear zone* which runs through the whole lens. This zone is at first situated far back in the lens while the fibres are still short, but as they elongate, its place is advanced, so that it comes to be situated considerably in front of the equatorial plane of the lens. It is most distinct towards the margin where the fibres are newly formed. The anterior wall of the lens-follicle remains as a simple cellular layer. The greater number of the fibres now follow the general curve of the surface of the lens, presenting therefore their concavity towards its centre, but the curvature gradually diminishing in those nearest the middle, where they are straight or nearly so. Only the external short and recently formed fibres present a concavity towards the exterior. The intersecting stars of the anterior and posterior poles of the lens now make their appearance by the collection of cells in the peculiarly shaped triradiate space in these two situations, and the ends of the fibres are now traceable to the edges of these spaces, so that the fibres gradually take the arrangement round the poles of the lens which belongs to the adult.

Fig. 567.

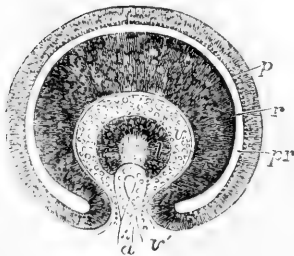


Fig. 567.—TRANSVERSE VERTICAL SECTION OF THE EYEBALL OF A HUMAN EMBRYO OF FOUR WEEKS (from Kölliker).  $\frac{1}{100}$

The anterior half of the section is represented. *pr*, the remains of the cavity of the primary optic vesicle; *p*, the inflected part of the outer layer, forming the retinal pigment; *r*, the thickened inner part giving rise to the columnar and other structures of the retina; *v*, the commencing vitreous humour within the secondary optic vesicle; *v'*, the ocular cleft through which the loop of the central blood-vessel, *a*, projects from below; *l*, the lens with a central cavity.

The capsule of the lens, according to Lieberkühn's and Julius Arnold's most recent observations, owes its origin to the thin innermost pellicle of mesoblast which is introduced at an early period of development between the lens and the secondary ocular vesicle.

**Cornea.**—There is at first no aqueous chamber in the eye, and even after the solution of continuity which gives rise to this space has occurred, the cavity is not dilated with fluid, till near the time of birth. Even then it is very shallow and the lens is placed very near to the cornea. The formation of the cornea is due to a differentiation of the tissue in the layer of mesoblast which is introduced from the neighbouring wall of the head, between the primitive lens-follicle and the corneous epiblast, the cavity of the aqueous humour arising by the separation of the corneous part from a layer of the mesoblastic tissue lying within it. The latter gives rise to the anterior part of the vascular capsulo-pupillary membrane, while a still deeper lamina closely embracing the lens, remaining non-vascular, is converted into the lens capsule. Along with the latter is also formed the suspensory ligament of the lens.

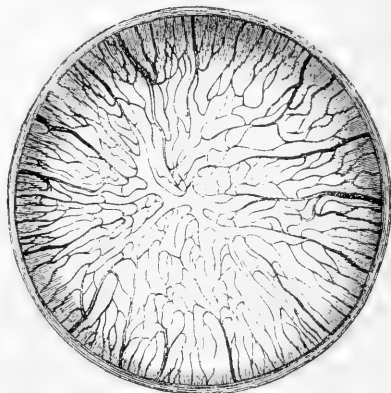
**Vitreous humour.**—The enlargement of the space for the vitreous humour progressing, the cells of the mesoblast which form its foundation become stellated and very sparse from the effusion of a large quantity of fluid, and the hyaloid membrane surrounding this structure takes its origin from the same mesoblastic elements.

**Choroid and other membranes.**—The mesoblastic substance which surrounds the ocular vesicle externally is the source of a number of

Fig. 568.—BLOOD-VESSELS OF THE CAPSULO-PUPILLARY MEMBRANE OF A NEW-BORN KITTEN, MAGNIFIED (FROM KÖLLIKER).

Fig. 568.

The drawing is taken from a preparation injected by Tiersch, and shows in the central part the convergence of the net-work of vessels in the pupillary membrane.



important parts. Among these may be mentioned first the choroid membrane, the cellular (*membrana fusca*), fibrous, and vascular layers of which are developed out of the deeper division of the mesoblastic substance, and to the same source may be traced in a later stage of development the ciliary processes, ciliary muscle and iris; while the zonula ciliaris may be regarded as a part of the deeper mesoblastic tissue connected with the formation of the hyaloid membrane and *membrana capsulo-pupillaris*. The folds of the ciliary processes gradually increasing, encroach upon the space outside the margin of the lens and indent the zonula ciliaris and canal of Petit.

The sclerotic coat is due to a process of differentiation occurring in the outer layer of the enveloping mesoblastic tissue, which occurs considerably later than those which bring the choroid and the cornea into existence, but there is from the first continuity between the corneal tissue and that of the sclerotic coat.

The **capsulo-pupillary membrane**, already referred to, may be looked upon as at first a complete fibro-vascular investment of the lens, which owes its origin

to the deepest part of the intruded mesoblast. The vessels of this membrane are supplied by a branch of the central artery of the retina, which passes forwards in the axis of the globe, and breaks up at the back of the lens into a brush of rapidly subdividing twigs. The forepart of this tunic, adherent to the pupillary margin of the iris, forms the *pupillary membrane* by which the aperture of the pupil is closed in the middle periods of foetal life. In the human subject, the whole tunic, together with the artery which supplies it, becomes atrophied, and is lost sight of before birth, but in some animals it remains apparent for a few days after birth. According to Kölliker, the anterior chamber expands only a short time before birth by the intervention of the aqueous humour between the iris and cornea.

The *eyelids* make their appearance as folds of integument, subsequently to the formation of the globe. When they have met together in front of the eye, their edges become closely glued together; and they again open before birth.

The *lacrimal canal* may be regarded as a persistently open part of the fissure between the lateral frontal process and maxillary lobe of the embryo.

The first discovery of the mode of development of the eye as it is now generally understood was made by Huschke in 1832, and was published in Meckel's Archiv for that year. In addition to the various systematic works on Development previously quoted, the reader is referred to the following, viz., Lieberkühn, *Über das Auge des Wirbelthier-embryo*, 1872; and Julius Arnold, *Beitrag zur Entwick. des Auges*, Heidelberg, 1874.

#### DEVELOPMENT OF THE EAR.

The first origin of the organ of hearing as an involuted follicle from the superficial epiblast of the head, constituting the primary auditory

Fig. 569.

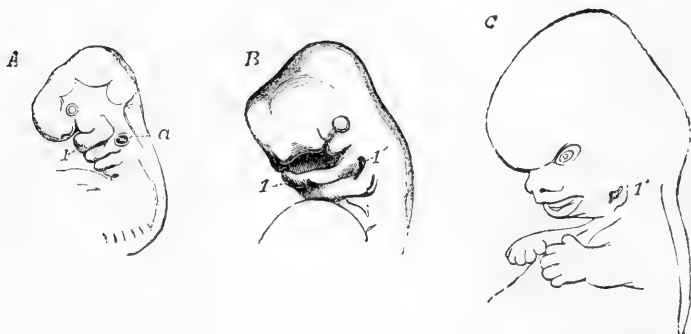


Fig. 569.—OUTLINES SHOWING THE FORMATION OF THE EXTERNAL EAR IN THE FŒTUS.

A, head and upper part of the body of a human fœtus of about four weeks (from nature).  $\frac{3}{4}$  Four branchial plates (the first, forming the lower jaw, is marked 1), and four clefts are shown; the auditory vesicle (*a*), though closed, is visible from the transparency of the parts, and is placed behind the second branchial plate.

B, the same parts in a human fœtus of about six weeks (from Ecker).  $\frac{5}{8}$  The third and fourth plates have nearly disappeared, and the third and fourth clefts are closed; the second is nearly closed; but the first (1') is somewhat widened posteriorly in connection with the formation of the meatus externus.

C, human fœtus of about nine weeks (from nature).  $\frac{3}{4}$  The first branchial cleft is more dilated, and has altered its form along with the integument behind it in connection with the formation of the meatus externus and the auricle.

or otic vesicles, has already been shortly described. From numerous observations there is now no doubt that both in birds and mammals

Fig. 570.

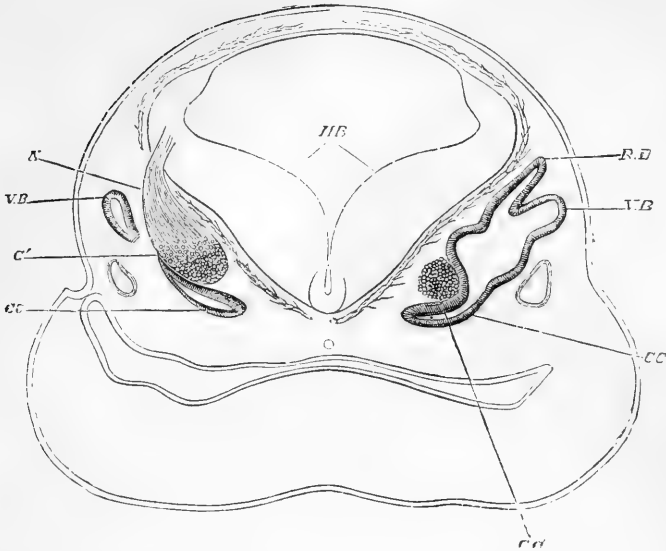


Fig. 570.—TRANSVERSE AND SLIGHTLY OBLIQUE SECTION OF THE HEAD OF A FETAL SHEEP, IN THE REGION OF THE HIND BRAIN (from Foster and Balfour after Boettcher).

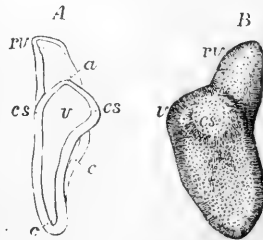
HB, inner surface of the thickened walls of the hind brain ; RL, recessus vestibuli ; VB, commencing vertical semicircular canal ; CC, canalis cochleae, with the cavity of the primitive otic vesicle. On the left side parts only of these structures are seen ; GC, cochlear ganglion of the right side ; on the left side, G', the ganglion, and N, the auditory nerve connected with the hind brain.

the otic vesicle forms at first for a time a follicle open to the surface, and that it has therefore no original connection with the nervous centre. Its position is at the side of the medulla oblongata, and in a place opposite to the interval between the first and second postoral visceral arches. The outer opening of the follicle very soon contracts

Fig. 571.—LABYRINTH OF THE HUMAN FŒTUS OF FOUR WEEKS, MAGNIFIED (from Kölliker).

A, from behind ; B, from before ; *v*, the vestibule ; *rv*, recessus vestibuli, giving rise later to the aqueduct ; *cs*, commencement of the semicircular canals ; *a*, upper dilatation, belonging perhaps to another semicircular canal ; *c*, cochlea.

Fig. 571.



and becomes entirely closed. The follicle sinks down towards the basis of the cranium, and becomes imbedded in the formative mesoblastic tissue lying between the basi-occipital and alisphenoid matrices, undergoing chondrification and ossification at a very early period, as has been already described under the development of the head.

There are therefore to be distinguished from an early period a part corresponding to the internal membranous labyrinth proceeding from

Fig. 572.

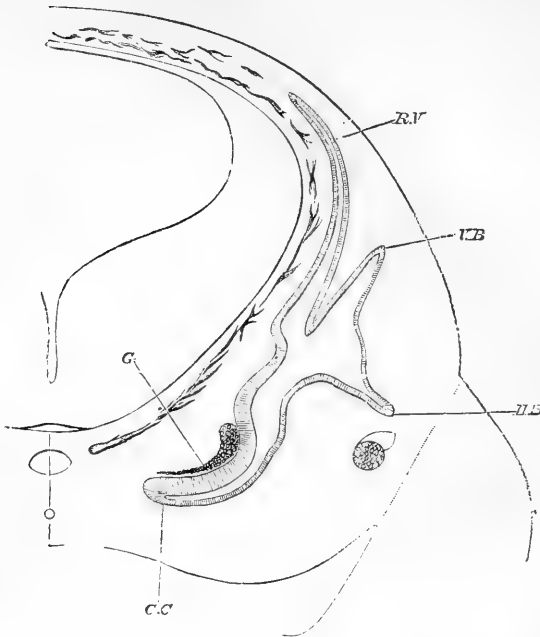


Fig. 572.—TRANSVERSE SECTION OF THE HEAD OF A FETAL SHEEP OF FOUR-FIFTHS OF AN INCH IN LENGTH (from Foster and Balfour after Boettcher).

RV, recessus vestibuli; VB, vertical semicircular canal; CC, cochlear canal; G, cochlear ganglion; HB, horizontal canal.

Fig. 573.

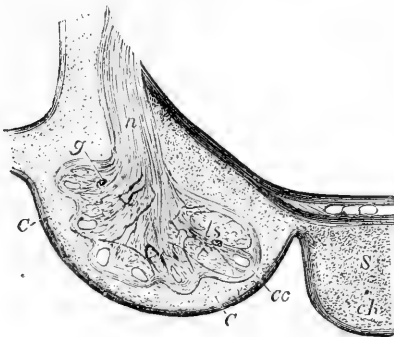


Fig. 573.—TRANSVERSE SECTION OF THE COCHLEA IN A FETAL CALF, MAGNIFIED (from Kölliker).

C, the wall of the cochlea, still cartilaginous; cc, canalis cochleæ; ls, placed in the tissue occupying the place of the scala vestibuli, indicates the lamina spiralis; n, the central cochlear nerve; g, the place of the spiral ganglion; S, the body of the sphenoid; ch, remains of chorda dorsalis.

the epiblast, and an outer cartilaginous or bony and fibrous wall, together with other adventitious structures arising in the mesoblast.

**Labyrinth.**—In the development of the primary otic vesicle after it becomes completely closed, a series of very remarkable changes by extension of its cavity in different directions gives rise to the formation of the different parts of the labyrinth. The first complication which

the vesicle exhibits is by the extension of a process upwards and backwards, which remains permanent in the lower vertebrata, but in mammals is obliterated, its vestiges remaining in the aqueduct of the vestibule. The semicircular canals next appear as elongated elevations of the surface of the primary vesicle: the middle portion of each elevation becomes separated from the rest of the vesicle by bending in of

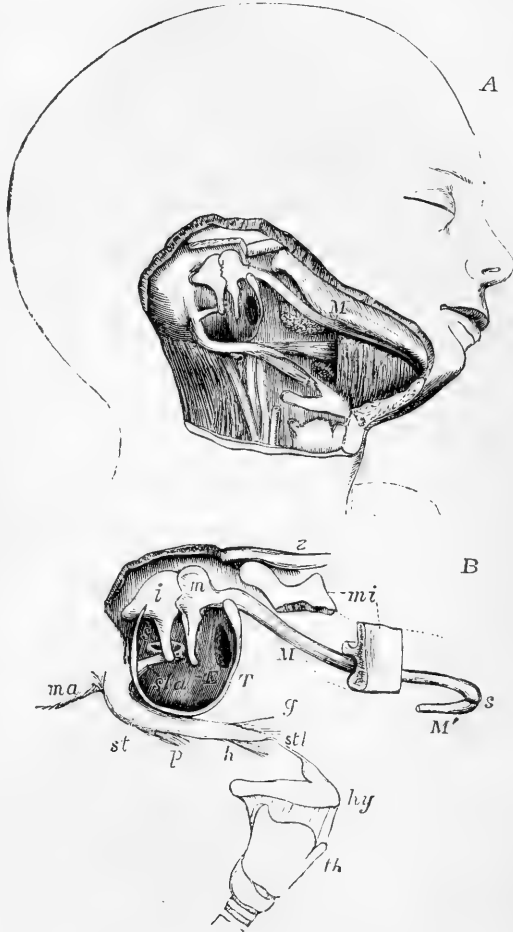
Fig. 574.

Fig. 574.—VIEWS OF THE CARTILAGE OF MECKEL AND PARTS CONNECTED WITH THE FIRST AND SECOND BRANCHIAL PLATES.

A (after Kölliker), head of a fœtus of about eighteen weeks, showing the cartilage of Meckel in connection with the malleus and the surrounding parts.

M, placed upon the lower jaw indicates the cartilage of Meckel of the right side.

B (from nature). An enlarged sketch explanatory of the above view; *z*, the zygomatic arch; *ma*, the mastoid process; *mi*, portions of the lower jaw of which the parts near the angle and the symphysis have been removed; M, the cartilage of Meckel of the right side; M', a small part of that of the left side, joining the left cartilage at *s*, the symphysis; T, the tympanic ring; *m*, the malleus; *i*, the incus; *s*, the stapes; *sta*, the stapedius muscle; *st*, the styloid process; *p, h, g*, the stylo-pharyngeus, stylo-hyoid, and stylo-glossus muscles; *stl*, stylo-hyoid ligament attached to the lesser cornu of the hyoid bone; *hy*, the hyoid bone; *th*, thyroid cartilage.



its walls under it, and thus the elevation is converted into a tube open at each end, which subsequently becomes elongated and acquires an ampullar dilatation. The cartilage which forms the osseous labyrinth is continuous with that of the rest of the primordial cranium. The cartilaginous walls of the cavity are united by connective tissue to the vesicle; this connective tissue, according to Kölliker, becomes divided into three layers, of which the outer forms the lining periosteum, the

inner forms the external walls of the membranous labyrinth, while the intervening layer swells up into gelatinous tissue, the meshes of which become wider and wider, till at last the space is left which ultimately contains the perilymph.

The cochlea appears at first as a prolongation downwards from the auditory vesicle, but afterwards becomes tilted forwards. This prolongation of the auditory vesicle is the rudimentary canalis membranacea. Close to it is placed the cochlear nerve, with a gangliform extremity. The canal becomes elongated in a spiral direction, and the ganglion, which is elongated with it, becomes the ganglion spirale. Between the canal and the cartilaginous wall which afterwards surrounds it a large amount of connective tissue intervenes, and in this tissue the cavities of the scala vestibuli and scala tympani gradually appear at a later period, precisely as does the space for the perilymph, in the vestibule. The modiolus and spiral lamina, according to Kölliker, are ossified without intervention of cartilage. Within the canalis membranacea Kölliker finds in the embryo a continuous epithelial lining, thin on the membrane of Reissner and on the outer wall, but forming a thick elevation in the position of the rods of Corti, and a larger elevation more internally, filling up the sulcus spiralis. On the surface of this latter elevation he has observed a transparent body, the membrane of Corti.

The auditory nerve is said to be developed, separately from both the brain and the labyrinth, in the intermediate mesoblastic wall of the head; the canal termed meatus auditorius internus being left in the bones round it and the facial nerve. The auditory nerve becomes secondarily connected with the medulla oblongata in a manner not yet ascertained, and its fibres are extended into relation with the delicate terminal structures formed in the membranous labyrinth.

**Middle and External Cavities of the Ear.**—It has been already explained that the external meatus, the tympanic cavity, and the Eustachian tube, are formed in the posterior or upper part of the first postoral visceral cleft, which remains permanently open as the tympano-eustachian passage, except at the place where it is interrupted by the formation of the membrana tympani; and also that the malleus is formed in the first visceral plate from the proximal part of Meckel's cartilage, and the incus, stapes, and stapedius muscle and the styloid process probably in the second plate. It is pointed out by Kölliker that during the whole period of foetal life the tympanic cavity is occupied by connective tissue, in which the ossicles are imbedded; and that only after respiration has been established this tissue recedes before an expansion of the mucous membrane.

The **pinna** is gradually developed on the posterior margin of the first visceral cleft. It is deserving of notice that congenital malformation of the external ear, with occlusion of the meatus and greater or less imperfection of the tympanic apparatus, are observed in connection with abnormal development of the deeper parts of the first and second visceral plates and the intermediate cleft; while cases have been observed of the persistence in the neck of the adult of one or more of the branchial clefts situated behind the first. (Allen Thomson, *Proceed. Roy. Soc. of Edin.* 1844, and *Edin. Journ. of Med. Sc.* 1847.)

#### DEVELOPMENT OF THE NOSE.

The organ of smelling, as was first pointed out by V. Baer, owes its origin, like the primary auditory vesicle and the crystalline lens of the eye, to a depression of the integument, or what may be more precisely designated as epiblast. This depression, the primary olfactory groove, is at first encircled by a uniform wall, and is unconnected with the



mouth. This stage has been observed by Kölliker in the human embryo of four weeks. The olfactory groove is enclosed in the anterior extremity of the nasal cartilages prolonged forward from the trabeculæ cranii (Parker). Soon, however, by the unequal growth of the surrounding parts, the groove so formed, descending from above, passes into the mouth. Thus the middle frontal process is isolated between the grooves of opposite sides, while the lateral frontal process separates the nostril from the eye. The maxillary lobes, growing forwards from behind the eyes, complete the boundaries of the nostrils, which then open into the fore part of the mouth. Kölliker observed this stage in the latter half of the second month. The palate subsequently grows inwards to the middle line, as has been elsewhere stated, and separates the nasal from the buccal cavity; leaving only the small communication of the incisor foramen. Meanwhile, with the growth of the face, the

Fig. 575.

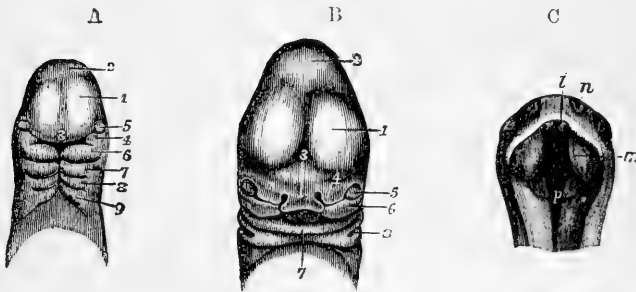


Fig. 575.—VIEWS OF THE HEAD OF HUMAN EMBRYOES, ILLUSTRATING THE DEVELOPMENT OF THE NOSE.

A, Head of an embryo of three weeks (from Ecker).  $\frac{1}{2}$  1, anterior cerebral vesicle; 2, middle vesicle; 3, nasal or middle frontal process; 4, superior maxillary process; 5, eye; 6, inferior maxillary process or first visceral plate, and below it the first cleft; 7, 8, and 9, second, third, and fourth plates and clefts.

B, Head of an embryo of about five weeks (from Ecker).  $\frac{1}{2}$  1, 2, 3, and 5, the same parts as in A; 4, the external nasal or lateral frontal process, inside which is the nasal groove; 6, the superior maxillary process; 7, the inferior maxilla; x, the tongue seen within the mouth; 8, the first visceral cleft which becomes the outer part of the meatus auditorius externus and tympano-eustachian passage.

C, View of the head of an embryo of eight weeks seen from below, the lower jaw having been removed (from Kölliker).  $\frac{1}{2}$

n, the external nasal apertures; i, premaxillary or incisor process, and to the outer side of this the internal nasal aperture; m, one of the palatal processes of the upper jaw, which, advancing inwards from the sides, form the partition between the mouth and nose; p, common cavity of the nose, mouth, and pharynx.

nasal fossæ deepen, and the turbinated bones make their appearance as processes from their walls. The ethmo-turbinal cartilages are at first simple, but rapidly extend themselves to take the more or less complex shape which they present in different animals or in man.

Observations are still wanting to determine whether the olfactory nerves are developed from the bulbs, and have thus a cerebral origin, or are separately

formed from peripheral blastema like all other nerves, with the exception of the optic.

#### DEVELOPMENT OF THE ALIMENTARY CANAL AND ORGANS ARISING FROM THE HYPOBLAST.

The whole alimentary canal, from the fauces to the anus, together with the rudiments of certain organs associated with it in their commencement, viz., the thyroid gland, lungs, trachea and larynx, the liver, and pancreas, as well as the allantois, owe their origin more immediately to inflexions of the hypoblast layer of the germinal membrane, which supplies the epithelial lining of their principal cavities; but in all these organs parts of their structure are supplemented, and some other organs, such as the mesentery and spleen, are wholly formed from the mesoblast, whence proceed the vascular, fibrous, and parenchymatous elements, and also the serous coverings of the organs, where these exist.

#### ALIMENTARY CANAL.

The primary digestive cavity of birds and mammals, as it extends from one end of the embryo to the other below the vertebral axis, presents at first a manifest division into three parts. One of these, occupying the part of the embryo which is enclosed by the cephalic fold, and which may be named the foregut, comprises the rudiments of the pharynx and gullet, the stomach and duodenum. The posterior division, which is comparatively short, occupies the caudal fold of the embryo, and corresponds mainly to the lower part of the colon and rectum. Both of these parts have from the first a tubular form, and are closed respectively by the inflexion of the whole blastodermic layers at the anterior and posterior extremities of the body. The middle division has primarily the form of a long and wide groove, lying close below the corresponding part of the vertebral bodies, leading at its opposite ends into the cephalic and caudal portions of the gut, and is freely open throughout on its ventral aspect into the cavity of the yolk-sac, with the blastodermic walls of which, as formerly described, the constituents of the intestinal walls are directly continuous (see fig. 576).

The mouth, as elsewhere explained, is no part of the primitive alimentary canal, but is formed by involution of parts of the face, and receives, therefore, its lining membrane from epiblast. It is separated for a time from the pharynx, which is the foremost part of the primitive alimentary canal, by the reflection of the layers of the blastoderm, and the communication which is later established between the mouth and pharynx at the posterior arch of the fauces, is due to a solution of continuity in these layers, which occurs in the chick on the fourth day of incubation, and has been traced at a corresponding period of development in several mammals. The aperture has at first the form of a vertical slit, which widens later as it becomes the opening from the pharynx into the common cavity of the nose and mouth. The diverticulum of the pituitary gland, it will be remembered, occupying the place which becomes the top of the permanent pharynx, is formed in connection with the epiblastic or buccal, and not the hypoblastic or pharyngeal division of the alimentary passage (see fig. 535, A and B, *py*).

The hypoblastic layer of the germinal membrane, from which is derived the epithelial lining of the whole alimentary canal and pas-

sages communicating with it, is at first extremely thin and simple, and is composed of flat cells; but as soon as this layer comes to form a part of the inflected alimentary tube, its character is completely altered, its cells become cylindrical, and it attains a great proportional thickness, which it preserves for a considerable time.

Fig. 576.—EARLY FORM OF THE ALIMENTARY CANAL (from Kölliker after Bischoff).

In A a front view, and in B an antero-posterior section are represented.

*a*, four pharyngeal or visceral plates; *b*, the pharynx; *c, c*, the commencing lungs; *d*, the stomach; *f, f*, the diverticula connected with the formation of the liver; *g*, the yolk-sac into which the middle intestinal groove opens; *h*, the posterior part of the intestine.

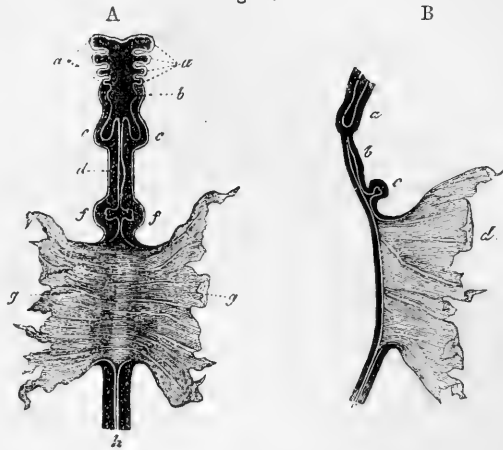


Fig. 576.

The outer surface of the inflected hypoblast of the alimentary tube is more or less in contact with the splanchnopleure division of the mesoblast. In the head no marked separation of the splanchnopleure and somatopleure divisions of the mesoblast takes place, but the elements of the former are no doubt combined with the hypoblast in the walls of the pharynx, and the formation of the tympano-eustachian and following pharyngeal clefts is therefore due to the perforation of both epiblastic and hypoblastic layers with intervening mesoblastic tissue, just as occurs in the formation of the opening of the fauces. But in the thorax and abdomen, the primitive alimentary canal is brought into relation with the pleuro-peritoneal cavity, and receives in various parts a serous investment from the lining membrane which becomes developed in that space. In the thorax the right and left cavities remain distinct as the two pleuræ, while a central portion is separated for the formation of the pericardium, and thus the gullet, as well as the lungs, is brought into relation with the pleuræ, and receives partial covering from them. The formation of the diaphragm, which does not at first exist, and which grows down from the vertebral column as a partition between the thorax and abdomen, leads to the ultimate separation of the peritoneum from the pleuræ. Some examples of diaphragmatic hernia may be considered as arising from the persistence of the original connection between the two cavities. In the abdomen, also, the right and left peritoneal cavities are at first distinct, but when the intestine assumes a tubular form, the right and left cavities are thrown into one across the middle plane of the body.

As the development of the alimentary canal proceeds, the middle open part shortens, more and more of it being converted into the tubular intestine, and at last, as before explained, there remains only

the narrow opening by which the gradually lengthening ductus vitello-intestinalis leads into the umbilical vesicle. The middle part of the intestinal canal has, when first produced, more or less the form of a straight tube lying close to the vertebral column; but as it increases

Fig. 577.

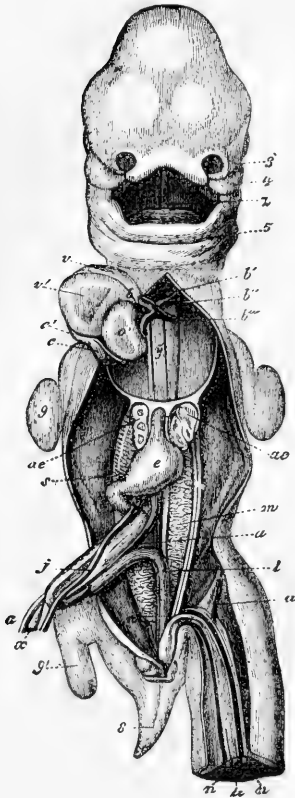


Fig. 577.—HUMAN EMBRYO OF THIRTY-FIVE DAYS SEEN FROM BEFORE (from Kölliker after Coste).

3, left external nasal process; 4, superior maxillary process; 5, lower maxillary process; z, tongue; b, aortic bulb; b', first permanent aortic arch, which becomes ascending aorta; b'', second aortic arch; b''', third aortic arch or ductus Botalli; y, the developing pulmonary arteries; c, the superior cava and right azygos vein; c', the common venous sinus of the heart; c'', the common stem of the left vena cava and left azygos; o', left auricle of the heart; v, right v', left ventricle; a, e, lungs; j, left omphalo-mesenteric vein; s, continuation of the same behind the pylorus, which becomes afterwards the vena portæ; x, vitello-intestinal duct; a', right omphalo-mesenteric artery; m, Wolffian body; i, rectum; n, umbilical artery; u, umbilical vein; 8, tail; 9, anterior, 9', posterior limb. The liver has been removed.

in length, it is thrown into the shape of a loop bent downwards to the umbilicus,—a change which is accompanied by the formation of the mesentery. The latter structure is undoubtedly entirely due to splanchnopleure mesoblastic elements, which, extending themselves between the proto-vertebral masses and the elongating gut, become developed into the vascular and other parts of the mesentery, as was long ago shown by Von Baer. But the mesoblast, also, by its splanchnopleure division, furnishes the contractile fibrous, vascular, and connective

tissue elements of the intestinal walls. The extent to which the glandular elements of the alimentary canal are supplied by the hypoblast, to which their origin was entirely attributed by Remak, or furnished rather by mesoblast from the protovertebral mass, as held by Schenk, is not yet determined.

As development proceeds in the forepart of the alimentary canal, a change in its form manifests itself, by which one part, becoming dilated, forms the commencement of the stomach, while the others remain of smaller diameter as gullet and duodenum; and in connection with different parts of these the rudiments begin to appear of the lungs, liver, and pancreas.

When the tubular parts of the gut have attained to some length, a change of position gradually accompanies their further development. While the œsophageal part remains comparatively straight, the dilated

portion of the tube which forms the stomach turns over on its right side, so that the border, which is connected to the vertebral column by the membranous fold (or true mesogastrium) comes to be turned to the left,—the position of the tube being still vertical, like the stomach of some animals. By degrees it becomes more dilated, chiefly on what is now the left border but subsequently becomes the great curvature, and assumes first an oblique and finally a transverse position, carrying with

Fig. 578.

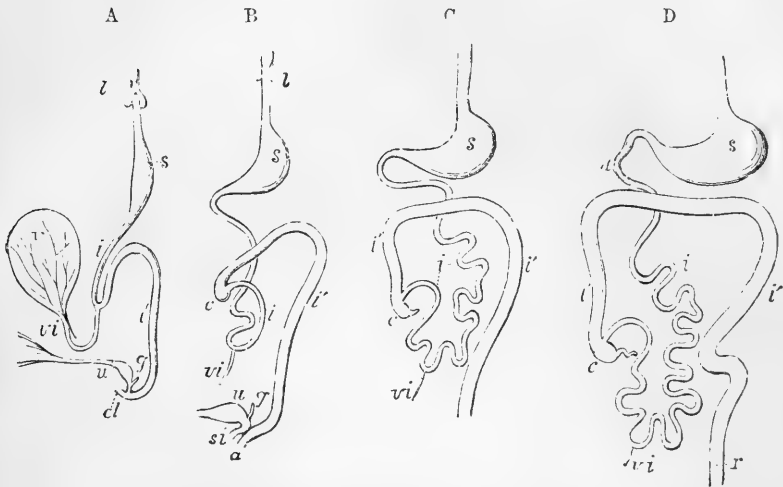


Fig. 578.—OUTLINE OF THE FORM AND POSITION OF THE ALIMENTARY CANAL IN SUCCESSIVE STAGES OF ITS DEVELOPMENT.

A, alimentary canal, &c., in an embryo of five weeks ; B, at eight weeks ; C, at ten weeks ; D, at twelve weeks ; *l*, the primitive lungs connected with the pharynx ; *s*, the stomach ; *d*, duodenum ; *i*, the small intestine ; *i'*, the large ; *c*, the caecum and vermiform appendage ; *r*, the rectum ; *cl*, in A, the cloaca ; *a*, in B, the anus distinct from *s i*, the sinus uro-genitalis ; *v*, the yolk-sac ; *vi*, the vitello-intestinal duct ; *u*, the urinary bladder and urachus leading to the allantois ; *g*, the genital ducts. In B, and C, the thickness of the colon is erroneously represented as greater than that of the ileum.

it the mesogastrium, from which the great omentum is afterwards produced. A slight indication of the pylorus is seen at the third month. Upon the surface of the part of the canal which immediately succeeds the stomach, and which forms the duodenum, the rudiments of the liver, pancreas, and spleen are simultaneously deposited, in the manner to be stated in the description of the development of these organs.

The place of transition from the small to the large intestine, which is soon indicated by the protrusion of the caecum, is at a point just below the apex or middle of the simple loop already mentioned, as accompanying the first elongation of the tubular gut. As the *small* intestine grows, the part below the duodenum forms a coil which at first lies in the commencing umbilical cord, but retires again into the abdomen about the twelfth week ; afterwards it continues to elongate, and its convolutions become more and more numerous.

The *large* intestine is at first less in calibre than the small. In the early embryo there is at first no cæcum. This part of the bowel gradually grows out from the rest, and in the first instance forms a tube of uniform calibre, without any appearance of the vermiform appendix: subsequently the lower part of the tube ceases to grow in the same proportion, and becomes the appendix, whilst the upper portion continues to be developed with the rest of the intestine. The cæcum now appears as a protrusion a little below the apex of the bend in the primitive intestinal tube, and, together with the commencing colon, and the coil of small intestine, is at first lodged in the wide part of the umbilical cord which is next the body of the embryo. The ileo-cæcal valve appears at the commencement of the third month. When the coils of intestine and cæcum have retired from the umbilicus into the abdomen, the colon is at first entirely to the left of the convolutions of the small intestines, but subsequently the first part of the large intestine, together with the meso-colon, crosses over the upper part of the small intestine, at the junction of the duodenum and jejunum. The cæcum and transverse colon are then found just below the liver; finally, the cæcum descends to the right iliac fossa, and at the fourth or fifth month the parts are in the same position as in the adult. At first, villous processes or folds of various lengths are formed throughout the whole canal. After a time these disappear in the stomach and large intestine, but remain persistent in the intermediate portions of the tube. According to Meckel, the villous processes are formed from larger folds, which become serrated at the edge, and divided into separate villi.

The formation of the hinder part of the gut is complicated with the development of the allantois, which arises as a projection or outgrowth of the hypoblast and mesoblast from the lower wall of its terminal portion. This part rapidly buds out in the pleuro-peritoneal space, having from a very early period a rich network of the branches of the umbilical vessels in its outer layer. The anal or cloacal portion remains behind the allantoid pedicle, and by the fifth day in the chick the whole of the tissues which close the terminal fold thin rapidly away, and become perforated so as to form the primitive anal, or rather the cloacal opening. The separation of the permanent anus from the urogenital orifice is the result of a later process of development.

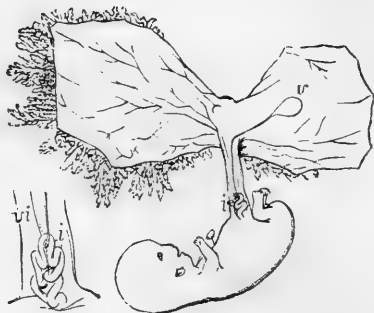
The mode of development of the alimentary canal explains, in some measure, the complicated folds of the peritoneum. The stomach being originally more nearly in the line of the alimentary canal and mesial in position, the small omentum and gastro-phrenic ligament are originally parts of a mesial fold with the free edge directed forwards, which afterwards forms the anterior boundary of the foramen of Winslow. Thus the anterior wall of the sac of the omentum, as far as the great curvature of the stomach, may be considered as formed by the right side of a mesial fold, while the peritoneum in front of the stomach belongs to the left side of the same, and a sac of the omentum is a natural consequence of the version and disproportionate growth of the tube between the duodenum and the cardiac orifice of the stomach. It is obvious that the view of the omental sac, according to which its posterior layers are held to return to the duodenum and posterior wall of the body before proceeding to form the transverse meso-colon (p. 484) is more consistent with the phenomena of development now described,

than that which would make them directly enclose the colon. On the other hand, the further elongation of the omental sac and the whole disposition of the peritoneum, with respect to the colon, must be regarded as having taken place after the assumption by the great intestine of its permanent position.

Fig. 579.—SKETCH OF THE HUMAN EMBRYO OF THE TENTH WEEK, SHOWING THE COIL OF INTESTINE IN THE UMBILICAL CORD. (A. T.)

The amnion and villous chorion have been opened and the embryo drawn aside from them; *v*, the umbilical vesicle or yolk-sac placed between the amnion and chorion, and connected with the coil of intestine, *i*, by a small or almost linear tube; the figure at the side represents the first part of the umbilical cord magnified; *i*, coil of intestine; *v i*, vitello-intestinal duct, alongside of which are seen omphalo-mesenteric blood-vessels.

Fig. 579.



The occurrence of umbilical hernia in its various degrees may be referred to the persistence of one or other of the foetal conditions in which a greater or less portion of the intestinal canal is contained in the umbilical cord; and it has been shown that the most common form of abnormal diverticula from the small intestine is connected with the original opening of the ductus vitello-intestinalis into the ileum.

#### DEVELOPMENT OF THE LIVER, PANCREAS, AND SPLEEN.

**The Liver.**—The liver is one of the earliest formed abdominal organs. It consists at first, according to most observers, of two solid masses in connection with the lower surface of the duodenal portion of the alimentary canal. Schenk, however (Lehrbuch, p. 93), states that the blastemic mass of the liver is single. A hollow cavity soon appears within the mass, which is the commencement of the main excretory duct (ductus choledochus communis). This cavity is lined by hypoblastic epithelium; and, according to the commonly received view, is produced as a diverticulum of the hypoblast of the intestine. Through the mass, but at first unconnected with its substance, there passes the main stem of the veins from the umbilical vesicle and allantois (umbilical vein or meatus venosus).

In the rudimentary mass composing the liver there are soon observed a number of solid cylinders of blastemic cells which branch out from the hypoblast into the mesoblast, and as these come to unite together by their ends, they at last form a network of solid cords with which the hypoblastic diverticula are connected. In the meantime blood-vessels are developed in the mesoblast lying between the cylinders, which vessels become united as branches with the umbilical vein passing through the liver. Hollow processes also extend themselves from the hypoblastic diverticula and stretch into the solid cylinders of the hepatic parenchyma; but the greater part of this remains solid for a time, consisting of reticulated strings of cells between which there is nothing but blood-vessels.

According to some embryologists, as Schenk, the hypoblast forms no

more than the lining epithelium of the bile-ducts and gall-bladder, and the hepatic or glandular cells are entirely derived from mesoblast; but, according to Foster and Balfour, following Remak and the earlier observers, the cellular elements of the gland are stated to derive their origin from the hypoblast, and the mesoblast is mainly converted into blood-vessels and the fibrous tissue of the ducts.

Fig. 580.

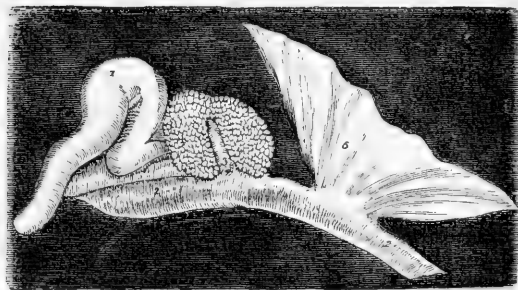


Fig. 580. — EARLY CONDITION OF THE LIVER IN THE CHICK ON THE THIRD DAY OF INCUBATION (from J. Müller.)  $\frac{10}{1}$

1, the heart as a simple curved tube; 2, 2, the intestinal tube; 3, conical protrusion of the coat of the commencing intestine, on which the blastema of the liver (4) is formed; 4, portion of the layers of the germinal membrane, passing into the yolk-sac.

The gall bladder is formed by extension from the wall of the main duct.

The blood-vessels formed in the liver become branches of the main vein, which passes through the cellular mass. These are distinguishable as an anterior and posterior set, the arrangement of which is such that the blood flows from stem to branches in the anterior, and from branches to stem in the posterior. Thus the distinction is established between portal and hepatic veins (see the Development of the Veins).

The solid cylinders of the blastema represent the hepatic lobular tissue, the hollow processes the hepatic ducts; but the origin of the finest ducts is not known. Perhaps each cellular cylinder may be looked upon as a collection of hepatic cells, in the centre of which is the minute duct, according to the view now taken of the structure of the adult liver (Foster and Balfour).

The gall-bladder is at first tubular, and then has a rounded form. The alveoli in its interior appear about the sixth month. At the seventh month it first contains bile. In the fœtus its direction is more horizontal than in the adult.

The following are the principal peculiarities in the liver of the fœtus:—

*Size.*—In the human fœtus, at the fifth or sixth week, the liver is so large that it is said to constitute one-half of the weight of the whole body. This proportion gradually decreases as development advances, until at the full period the relative weight of the fœtal liver to that of the body is as 1 to 18.

In early fœtal life, the right and left lobes of the liver are of equal, or nearly equal, size. Later, the right preponderates, but not to such an extent as after birth. Immediately before birth the relative weight of the left lobe to the right is nearly as 1 to 1.6.

*Position.*—In consequence of the nearly equal size of the two lobes, the position of the fœtal liver in the abdomen is more symmetrical than in the adult.



In the very young fœtus it occupies nearly the whole of the abdominal cavity; at the full period it still descends an inch and a half below the margin of the thorax, overlaps the spleen on the left side, and reaches nearly down to the crest of the ilium on the right.

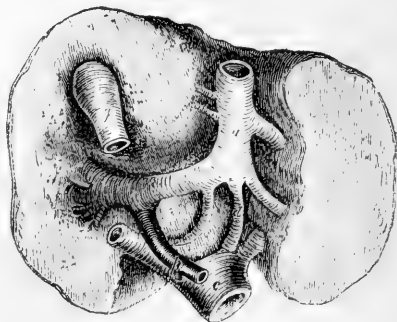
*Form, Colour, &c.*—The fetal liver is considerably thicker in proportion from above downwards than that of the adult. It is generally of a darker hue. Its consistence and specific gravity are both less than in the adult.

During fœtal life, the umbilical vein runs from the umbilicus along the free margin of the suspensory ligament towards the anterior border and under surface of the liver, beneath which it is lodged in the umbilical fissure, and proceeds as far as the transverse fissure. Here it divides into *two* branches; one of these, the smaller of the two, continues onward in the same direction, and joins the vena cava; this is the *ductus venosus*, which occupies the posterior part of the longitudinal fissure, and gives to it the name of the fossa of the ductus venosus. The other and larger branch (the trunk of the umbilical vein) turns to the right along the transverse or portal fissure, and ends in the vena portæ, which, proceeding from the veins of the digestive organs, is in the fœtus comparatively of small dimensions. The umbilical vein, as it lies in the umbilical fissure, and before it joins the vena portæ, gives off large lateral branches, which pass directly into the right and left lobes of the liver. It also sends a few smaller branches to the square lobe and to the lobe of Spigelius.

Fig. 581.

FIG. 581.—UNDER SURFACE OF THE FŒTAL LIVER, WITH ITS GREAT BLOOD-VESSELS, AT THE FULL PERIOD.

*a*, the umbilical vein, lying in the umbilical fissure, and turning to the right side, at the transverse fissure (*o*), to join the vena portæ (*p*): the branch marked *d*, named the ductus venosus, continues straight on to join the vena cava inferior (*c*): some branches of the umbilical vein pass from *a* into the substance of the liver; *g*, the gall-bladder.



The blood which leaves the liver by the hepatic veins, and is carried into the heart along with that of the vena cava inferior, consists of the following parts, viz.; 1. That of the umbilical vein, which passes on directly by the ductus venosus; 2, that portion of the blood which is distributed to the liver by branches proceeding immediately from the trunk of the umbilical vein; and 3, the blood from the digestive organs of the fœtus arriving by the vena portæ.

After birth the umbilical vein becomes obliterated from the umbilicus up to the point of its giving off branches to the liver. The ductus venosus is also obliterated, but the veins which were given as branches from the umbilical vein to the liver remain in communication with and appear as branches of the left division of the portal vein.

**The Pancreas.**—This organ takes its origin in a mass of mesoblastic tissue, which thickens the wall of the duodenum close to the place where the rudiment of the liver is first seen, but placed more to the left side. This mass may be seen on the third day in the chick. There is, however, also a diverticulum from the primary wall of the intestine or hypoblast. The same doubt prevails, as in regard to the

liver, with respect to the exact share of the hypoblastic and mesoblastic elements in the formation of the glandular cells. The main duct and its branches undoubtedly owe their origin to diverticula proceeding from the intestinal hypoblast, and the epithelial lining of the ducts is doubtless derived from that source. By those who consider that the glandular cells also arise from the hypoblast, solid processes of that layer are described as stretching into the mass of mesoblast. Into these the diverticular cavities subsequently extend in more than one main division. The blood-vessels and the connective tissue of the gland are undoubtedly due to the mesoblastic elements, and these are very soon combined with the parts proceeding from hypoblast.

**The Spleen.**—This organ appears soon after the pancreas as a thickening of the mesogastrium, and is therefore entirely mesoblastic in its origin. (Peremeschko, Vienna Acad., 1867, and W. Müller in Stricker's *Histol.*) The gradual formation of the trabecular structure from one set of cells and of the blood-vessels and cellular elements of the organ from the blastemic substance has been traced. The pulp is formed in connection with the veins, and the arteries are formed along with the Malpighian corpuscles. The spleen is closely related to the pancreas in its origin, but it is later of being formed and contains no hypoblastic elements. In the human foetus of about twelve weeks its shape can be recognised, but the Malpighian bodies are not visible till the middle of foetal life.

**Lymphatic Glands.**—The development of the mesenteric lymphatic glands has been observed by Sertoli in mammals. (Vienna Acad., 1866.) The blastema from which they are produced is imbedded in the mesentery, and is therefore entirely mesoblastic. The gradual differentiation of the blastema gives rise in succession to the lymph spaces, the trabeculae and the lymph cells, and the distinction follows between inferent and efferent lymphatic vessels. The development of lymphatic vessels has been described in the *General Anatomy*, p. 191.

**The Thymus and Thyroid Glands.**—The development of these bodies has been described in an earlier part of this volume, pp. 297 and 299. The thymus gland proceeds entirely from mesoblastic tissue; but, according to the researches of W. Müller (*Jenaisch. Zeitsch.*, 1871), it would appear that the thyroid body arises at first as a diverticulum from the pharynx, and it therefore contains some hypoblastic elements.

#### DEVELOPMENT OF THE LUNGS AND TRACHEA.

The lungs first appear as two small protrusions upon the front of the oesophageal portion of the alimentary canal, completely hid by the rudimentary heart and liver. These primitive protrusions or tubercles are visible in the chick on the third day of incubation, and in the embryos of mammalia and of man at a corresponding stage of advancement. Their internal cavities communicate with the oesophagus, and are lined by a prolongation of the hypoblast. At a later period they are connected with the oesophagus by means of a long pedicle, which ultimately forms the trachea, whilst the bronchia and air-cells are developed by the progressive ramification of the internal cavity in the form of caecal tubes, after the manner of the ducts of glands.

The diverticulum of hypoblast is surrounded by a mass of mesoblastic cells, so that the pulmonary parenchyma, like that of the glands,

owes its origin to both hypoblastic and mesoblastic elements. The substance of the mesoblast, thickening round the primary diverticula, becomes penetrated by secondary diverticula formed from the hypoblast processes; these are succeeded by tertiary branches which develop the bronchia, and ultimately have the air-cells formed as their terminations. The formative process consists essentially in the budding of hypoblastic into mesoblastic substance; the hypoblast furnishing the lining epithelium of the tubes, and the mesoblast the other tissues, such as muscular fibres, cartilage, blood-vessels, elastic tissue, &c.

In the formation of the trachea and bronchi the wall of the primitive œsophagus is projected downwards (or forwards), and by the gradual folding in of the sides a second median tube is separated from the primitive alimentary canal. This new tube grows out at its hinder end so as to bulge at the two sides, and thus the commencement of a right and left bronchus is formed. The subsequent division of the diverticular hollow goes on by budding of the hypoblast from within into the masses of pulmonary blastema. The division into larger lobes externally, three in the right and two in the left lung, may be seen at a very early period in the human fœtus. As the bronchial subdivision extends within the lungs, a tubercular or coarsely granular appearance is seen over the outer surface, as observed by Kölliker in the human fœtus in the latter half of the second month. This is produced by the primitive air-cells placed at the extremities of ramified tubes, which occupy the whole of the interior of the organ: the ramification of the bronchial twigs and multiplication of air-cells goes on increasing, and this to such an extent that the air-cells in the fifth month are only half the size of those which are found in the fourth month.

Fig. 582.—SKETCH ILLUSTRATING THE DEVELOPMENT OF THE RESPIRATORY ORGANS (from Rathke).

A, œsophagus of a chick, on the fourth day of incubation, with the rudimentary lung of the left side, seen laterally; 1, the front, and 2, the back of the œsophagus; 3, rudimentary lung protruding from that tube; 4, stomach. B, the same seen in front, so as to show both lungs. C, tongue and respiratory organs of embryo of the horse; 1, tongue; 2, larynx; 3, trachea; 4, lungs seen from behind.

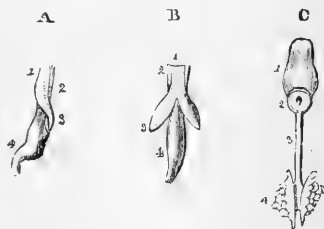


Fig. 582.

In birds the principal air-sacs, three in number, are formed in direct connection with the lung in the course of its early development, and the rudiments of these sacs may be seen at an early period, as bulging constituent parts of the rudimentary lungs.

**Pleuraë.**—Each lung receives a covering externally from the lining membrane of the common pleuro-peritoneal cavity of its own side. This is at first only on the outer side; but, as the lungs enlarge, a fissure separates their solid substance from the outer wall of the œsophagus, and the pleura is carried round the lung-mass so as to encircle the gradually narrowing root of each lung. The two pleuraë remain separated by the mediastinum and heart.

**Pulmonary Vessels.**—The blood-vessels of the lungs which arise in the mesoblastic tissue seem to be of comparatively late formation,

penetrating into the mesoblast only on the twelfth day in the chick. The pulmonary arteries are developed in mammals in connection with the fifth branchial arch of the left side, but the manner in which they become connected with the vessels formed in the lung-substance, and the manner in which a union is established between the pulmonary veins and the left auricle have not yet been ascertained.

#### DEVELOPMENT OF THE HEART AND BLOOD-VESSELS.

In the account of the general phenomena of development the establishment of the first circulation of blood, by the simultaneous formation of the simple heart and of the first blood-vessels and blood in the body of the embryo and in the vascular area of the blastoderm, has already been described, and in the General Anatomy (p. 180) an account has

Fig. 583.

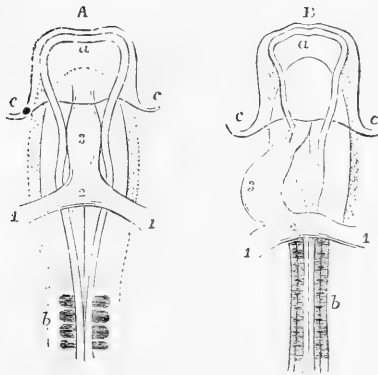


Fig. 583.—OUTLINES OF THE ANTERIOR HALF OF THE EMBRYO CHICK VIEWED FROM BELOW, SHOWING THE HEART IN ITS EARLIEST STAGES OF FORMATION (after Remak). <sup>20</sup><sub>1</sub>

A, Embryo of about 20 to 30 hours; B, of about 36 to 40 hours; a, anterior cerebral vesicle; b, proto-vertebral segments; c, amniotic fold; 1, 1, primitive omphalo-mesenteric veins entering the heart posteriorly; 2, their union in the auricle of the heart; 3, the middle part of the tube corresponding to the ventricle; 4 (in B) the arterial bulb.

been given of the histological changes occurring in the first development of the blood-vessels and blood.

#### DEVELOPMENT OF THE HEART.

**Origin of the Heart—Simple Tubular Form.**—The heart takes its origin in the form of an elongated sac or dilated tube in the substance of a thickening of the splanchno-pleure layer of the mesoblast, in the ventral aspect of the cephalic portion of the primitive alimentary canal, immediately in front of the fovea cardiaca. Doubts have existed as to the exact mode of production of the cavity of the organ, but the observations of Afanasieff and Klein, and especially those of Foster and Balfour, appear to show that the substance in which the first rudiments of the heart arise is produced by a thickening of the lower wall of the mesoblastic layer of the primitive intestine, and that the cavity is formed by a solution of continuity or liquefaction of this substance in such a manner that, while the outer cells constitute the foundation of the commencing fibrous walls, a deep set of cells very soon or from the first arrange themselves in the form of an endo-vascular lining of the cavity. The organ has at first the form of an elongated sac or dilated tube of symmetrical shape, widening out behind into two lateral orifices, each of which is connected with an omphalo-mesenteric vein of its own side bringing the nascent blood back from the vascular area, while the anterior part of the rudimental heart leads into two arterial

vessels, one of which arches over each side of the primitive pharynx and turns backwards below the proto-vertebræ to form one of the two primitive aortic tubes. From each of these last the omphalo-mesenteric arteries pass off into the vascular area.

According to recent observations by Kölliker and by Hensen (*loc. cit.*) a still earlier condition of the heart has been perceived in the embryo of mammals, in which there are two separate tubes hollowed out of the lateral parts of the cephalic fold. Each of these tubes is connected with a vein or entering vessel posteriorly, and an artery or out-going vessel anteriorly: these slowly come together and unite by fusion in the middle, in a limited space at first, and then more and more till the single tubular heart results. Each tube is in relation with the pleuroperitoneal cavity of its own side, and when the median fusion takes place the union of these two becomes the pericardium.

Fig. 584.

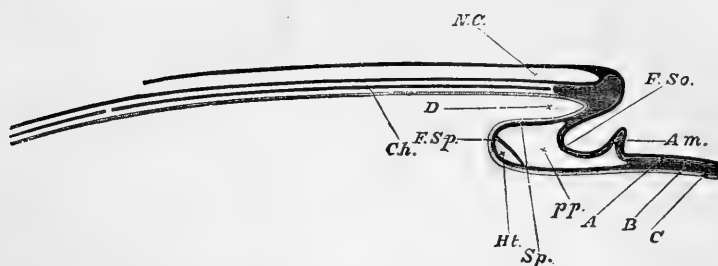


Fig. 584.—DIAGRAMMATIC LONGITUDINAL SECTION THROUGH THE AXIS OF AN EMBRYO.

The section is supposed to be made at a time when the head-fold has commenced, but the tail-fold has not yet appeared. *A*, epiblast; *B*, mesoblast; *C*, hypoblast; *FSo*, fold of the somatopleure; *Sp*, and *FSp*, fold of the splanchnopleure; *Am*, commencing (head) fold of the amnion; *NC*, neural canal, closed in front, but still open behind; *Ch*, notochord, in front uncleft mesoblast in the base of the cranium; *D*, the commencing foregut, or alimentary canal; *Ht*, heart; *pp*, pleuro-peritoneal cavity.

The rudimental heart in the form now described, exists in the chick at the thirty-sixth hour of incubation, and already, while still consisting of formative cells not differing greatly from those composing the other parts of the mesoblast, begins to exhibit motions of alternating systole and diastole, by slow contractions which begin behind and pass forward to the anterior extremity of the tube; and a small quantity of imperfectly formed blood is propelled through the cavity.

The elongation which the tubular heart now undergoes causes it to lose the symmetrical form; and its middle part now becomes detached from the lower side of the alimentary canal, and projects downwards (or forwards in the body) with an inclination to the right side of the embryo.

The heart is now found to be surrounded on the ventral aspect by a median cavity, which is a part of the pleuro-peritoneal space intervening between the wall of the heart as splanchnopleure, and the somatopleure forming the thoracic wall. This cavity becomes the pericardial sac.

As the development of the tubular heart progresses, the bend

increases, and the venous is doubled back upon the arterial end. The tube also becomes divided by two slight constrictions into three

Fig. 585.

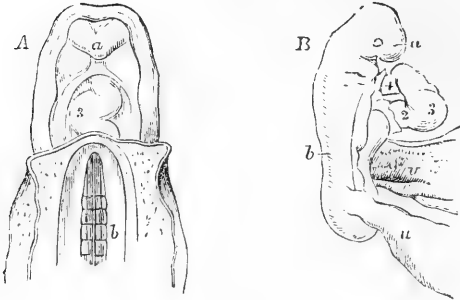


Fig. 585.—HUMAN EMBRYOS AT DIFFERENT EARLY STAGES OF DEVELOPMENT, SHOWING THE HEART IN ITS TUBULAR CONDITION.

A, upper half of the body of a human embryo of three weeks, viewed from the abdominal side (from Coste); *a*, frontal plate; *b*, protovertebrae, on which the primitive aortae are lying; 3, the middle of the tube of the heart, below it the place of entrance of the great veins, above it the aortic bulb.

B, lateral view of a human embryo more advanced than that

last referred to, and somewhat imperfectly developed (from A. Thomson); *a*, the frontal part of the head; *b*, the vertebral column; *v*, the wide communication of the umbilical vesicle or yolk-sac with the intestine; *u*, communication with the allantois or urachus; 2, auricular part of the heart connected with the veins posteriorly; 3, ventricular part of the bent tube; 4, the aortic bulb; near the extremities of the tube the divided pericardium is seen.

portions, of which that originally posterior and receiving the veins is the widest, and constitutes the primitive auricle; the middle one, next

Fig. 586.

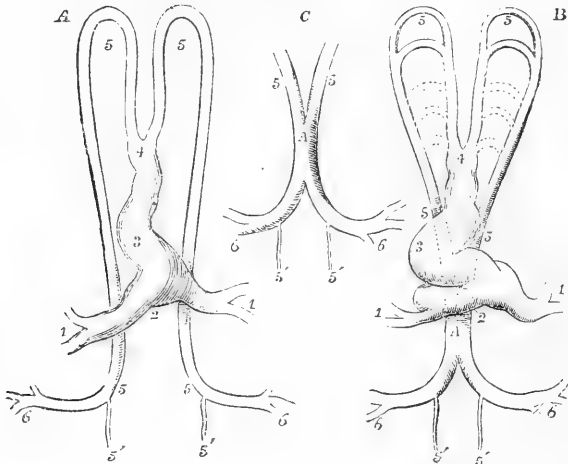


Fig. 586.—DIAGRAMMATIC OUTLINES OF THE HEART AND FIRST ARTERIAL VESSELS OF THE EMBRYO, AS SEEN FROM THE ABDOMINAL SURFACE.

A, at a period corresponding to the 36th or 38th hour of incubation in the chick; B, and C, at the 48th hour of incubation; 1, 1, primitive veins; 2, auricular part of the heart; 3, ventricular part; 4, aortic bulb; 5, 5, the primitive aortic arches, and their continuation as descending aorta; these vessels are still separate in their whole extent in A, but at a later period, as shown more fully in C, have coalesced into one tube in a part of the dorsal region; in B, below the upper 5, the second aortic arch is formed, and

farther down the dotted lines indicate the position of the succeeding arches to the number of five in all; 5', 5', the continuation of the main vessels in the body of the embryo; 6, 6, the omphalo-mesenteric arteries passing out of the body of the embryo into the vascular area of the germinal membrane.

in width and most strongly bent upon itself, becomes the ventricular portion; and the third, situated anteriorly and retaining most the simple tubular form, is the arterial or aortic bulb. This tubular stage of the rudimental heart has been observed in the human embryo by Coste and Allen Thomson (see fig. 585, A and B).

**Division into Single Auricle, Ventricle, and Arterial Bulb.**—

By a continued increase of the inflection of the heart-tube, a change in the relative position of the several parts is effected, so that the auricular cavity comes to be placed above or behind (dorsally) and to the left of the ventricular part, the veins being carried forwards along with it, while the arterial bulb is attached by its extremity in front to the neck of the embryo immediately behind the lower visceral plates. There is as yet only a single passage through the heart, but the distinction of the auricular and ventricular cavities becomes more apparent, both by an increase in the diameter of each, and by the constriction which separates them, and by the much greater thickness acquired by the walls of the ventricular and bulbous parts as compared with the auricular portion.

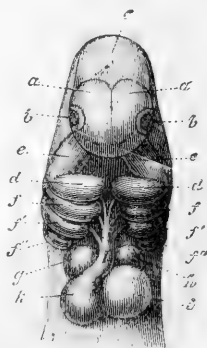
The three parts of the heart have now the appearance of being very closely twisted together. The ventricular part becomes considerably wider transversely, and the auricular part shows two projecting pouches, one on each side of the arterial bulb, which are the first indications of the future auricular appendages. At the same time the constriction between the auricular and ventricular parts increases considerably, and the constricted part elongating produces what has been called the *canalis auricularis*.

**Division of the Cavities. Ventricles.**—The next series of changes in the developing heart consists in the division of each original single cavity of the ventricle, auricle, and arterial bulb into two compart-

Fig. 587.—HEAD OF THE EMBRYO OF THE DOG WITH THE HEART SEEN FROM BELOW (from Kölliker, after Bischoff). MAGNIFIED.

*a*, cerebral hemispheres; *b*, eyes; *c*, midbrain; *d*, inferior maxillary plates; *e*, superior maxillary processes; *f*, *f'*, *f''*, second, third, and fourth branchial or visceral plates; *g*, right, *h*, left auricle of the heart; *k*, right, *i*, left ventricle; *l*, aortic or arterial bulb, with three pairs of aortic or vascular arches protruding from it.

Fig. 587.



ments, so as to form the right and left ventricles and auricles, and the stems of the pulmonary artery and aorta. The first of these changes occurs in the ventricular portion, and is to be seen in progress on the fourth day in the chick, and the sixth and seventh week in the human embryo. The ventricular chamber of the heart, increasing considerably in breadth, that part of it which ultimately becomes the apex of the heart is thrown towards the left side, and in most mammals, and

especially in the human embryo, a blunt cleft or depression appears between this and the right part of the ventricle, which causes an external division into two portions corresponding to the future right and left ventricles; and if the interior of the ventricular cavity be examined at this time, there is perceived a crescentic partition rising from the anterior or lower border of the right wall and projecting into the cavity, at first narrow and placed opposite the external notch, but gradually growing more and more towards the auriculo-ventricular aperture. As development progresses the external division becomes more or less effaced, when the apex of the heart formed by the left ventricle becomes more pointed, and the whole heart takes more of the conical form which belongs to its more advanced condition; but the depression is still perceptible as the interventricular groove of the adult heart, which, as is well known, varies considerably in depth in different cases. In some animals, as the rabbit, the temporary external division of the ventricles is greater than in the human embryo, while in others, as in ruminants, there is very little of the external notching, and in them, as in birds, the heart very early assumes the conical form. The dugong presents a remarkable example of the persistence of the complete external separation of the ventricles, and there appears to be a tendency to the occasional occurrence of the same in the seal.

The internal septum of the ventricles continuing to rise between the right and left divisions of the cavity, reaches at last the base where it is placed in relation with both the auriculo-ventricular orifice and the root of the arterial bulb; but at this place there remains for a time a communication over the still free border of the septum between the right and left ventricles, which is interesting, as this is the seat of the abnormal communication between the right and left ventricles in almost all cases of malformation of the heart presenting that condition.

**Division of the Auricles.**—Although the auricular cavity presents externally some appearance of being divided into two at a period antecedent to the partition of the ventricles, in consequence of the formation of the right and left auricular appendages before mentioned, the internal division of the cavity does not take place till some time later, as on the fifth and sixth days in the chick, and in the eighth week in the human embryo. The auricular septum commences as an internal fold proceeding from the anterior wall of the common cavity, and starting from the septum of the ventricles, it grows backwards towards the entrance of the common vein or sinus, but stops short of it some distance. For a time, therefore, the veins enter the back part of the auricular cavity in common. It is proper to explain, however, that, by the time at which the auricular septum is forming, the venous sinus has been modified so as to produce three veins entering the auricle at its back part. Of these, two correspond with the right superior cava and the inferior cava veins, and the third to the left superior cava and connected with what afterwards becomes the coronary sinus. For a time, all the three vessels open so as to communicate freely with the whole auricular cavity. But changes now occur which cause the left superior cava and the inferior cava to be directed towards the left side, while the right superior cava is placed more immediately in connection with the right part of the auricular cavity.

The auricular septum, in extending itself backwards, is not completed, but leaves an oval deficiency in its lower and middle part, as the

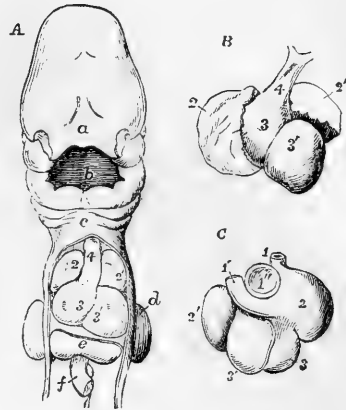


*foramen ovale*, and the inferior cava opens immediately behind this. Some time later in the human embryo, or in the course of the tenth or eleventh weeks, two new folds make their appearance in the auricles posteriorly. One of these constituting the *Eustachian valve*, of a

Fig. 588.—SHOWS THE POSITION AND FORM OF THE HEART IN THE HUMAN EMBRYO FROM THE FOURTH TO THE SIXTH WEEK.

A, upper half of the body of a human embryo of nearly four weeks old (from Kölliker after Coste); B and C, anterior and posterior views of the heart of a human embryo of six weeks (from Kölliker after Ecker); *a*, frontal lappet; *b*, mouth; *c*, below the lower jaw and in front of the second and third branchial arches; *d*, upper limb; *e*, liver; *f*, intestine cut short; 1, superior vena cava; 1', left superior cava or brachio-cephalic connected with the coronary vein; 1'', opening of the inferior vena cava; 2, 2', right and left auricles; 3, 3', right and left ventricles; 4, aortic bulb.

Fig. 588.



crenate form, is placed to the right of the entrance of the inferior vena cava, and in the angle between it and the orifice of the left superior cava (or great coronary sinus), and besides separating these two veins, and thus throwing the opening of the left superior cava into communication with the right auricle, this fold, as it runs forward into the annulus ovalis or border of the anterior auricular septum, has the effect of deepening the entrance of the inferior cava into a groove which lies close to the foramen ovale, and directs the blood entering by that vessel through the passage into the left auricle.

The other fold referred to advances from the posterior wall of the common auricle to meet the anterior auricular septum, but yet to the left of the border of the foramen ovale. To this border, however, it adheres as it grows forwards, and thus gradually fills up the floor of the fossa ovalis. Up to the middle of foetal life, this posterior septum being incomplete, there is a direct passage from right to left through the foramen; but, after that period, the fold in question, having advanced beyond the anterior border of the annulus ovalis and lying to the left, it does not adhere to this or the fore part of the annulus, but leaves a passage between, and appears as a crescentic fold in the left auricle, which, as it passes beyond the annulus, constitutes a very perfect valve against the return of blood from the left into the right auricle.

**Division of the Arterial Bulb.**—The third important change occurring in the heart belongs to the arterial bulb, by which there are developed from this tube the first parts or main stems of the pulmonary artery and the aorta. Within the thick walls of this arterial tube there is at first only a single cylindrical cavity, continued from the originally single ventricle; but, a short time after the partition of the ventricular cavity has commenced, or in the seventh week of the human embryo, a division of the bulb by an independent process begins to

take place. This consists in the projection inwards of a lateral fold of the wall on the two sides, affecting, however, only the inner and middle coats, and not perceptible externally; so as to divide the cavity of the bulb into two channels, which may be described as respectively anterior and posterior, but which from the spiral direction taken by the folds are somewhat twisted on each other, so that the channel which at the ventricular end is placed anteriorly becomes connected with the right ventricle and forms the pulmonary stem, and that which is placed posteriorly becomes connected with the left ventricle and forms the commencement of the aorta. In the distant portion of the bulb, however, the pulmonary channel is situated to the left and posteriorly, and the aortic channel is to the right and most forwards, and at this end these channels are respectively connected with different aortic arches, giving rise to the permanent pulmonic and systemic vessels in the manner afterwards described.

It is further to be noted that the partition of the bulb begins at the remote extremity, and progresses towards the ventricles. There is a time, therefore, during which the ventricular septum, and the septum of the bulb, advancing towards each other, are incomplete and disunited; and from the difference in their direction it is obvious that there must

Fig. 589.

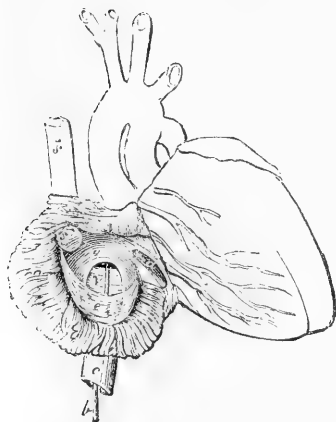


Fig. 590.

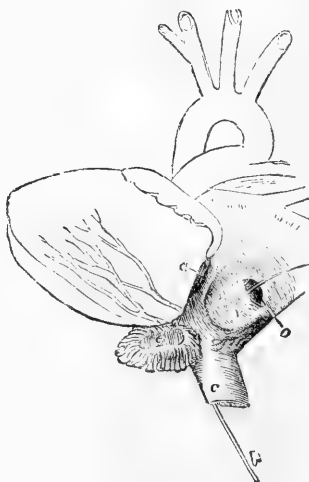

Fig. 589.—VIEW OF THE FRONT AND RIGHT SIDE OF THE FETAL HEART, AT FOUR MONTHS, THE RIGHT AURICLE BEING LAID OPEN (from Kilian).

*a*, the right auriculo-ventricular opening; *b*, a probe passed up the vena cava inferior and through the fossa ovalis and foramen ovale into the left auricle; *c*, vena cava inferior; *c*, Eustachian valve; *v*, valve of the foramen ovale; *s'*, vena cava superior.

Fig. 590.—VIEW OF THE POSTERIOR AND LEFT SURFACE OF THE HEART OF A FETUS OF FOUR MONTHS, THE LEFT AURICLE BEING OPENED (from Kilian).

*a*, left auriculo-ventricular orifice; *c*, inferior vena cava, through which a probe *b*, is passed from below, and thence by the foramen ovale into the left auricle; *e*, left auricular appendage laid open; *o*, valve of the foramen ovale seen to be attached to the left side of the annulus ovalis of the septum.

be a peculiar twist of one or both, in order that they may finally unite so as to become continuous.

The completion of the partition of the aortic and pulmonary stems is afterwards effected by the progress of the division from within outwards through the external walls of the tubes; but the two vessels remain united externally by a common envelope of pericardium.

The remarkable cases sometimes observed of abnormal transposition of the two great arterial stems from their natural connection with their respective ventricles may be explained by reference to the history of the development of the parts of the heart before given.

**Formation of the Valves.**—The formation of the auriculo-ventricular and semilunar valves begins during the time of the changes previously described by the projection of thick folds from the inner wall of the heart. In the case of the semilunar valves the trifold division is early perceived, but the cavities or sinuses within the valves are late of being developed. In the auriculo-ventricular valves there is at first an entire or annular projecting fold of the inner substance round the orifice, and this becomes gradually divided into segments, and the chordæ tendineæ are gradually produced by perforation of the valve plate. (See Tonge in *Proceed. Roy. Soc.*, 1868.)

The manner in which the pulmonary veins, which are formed separately in the lungs, come to be connected with the left auricle has not yet been ascertained.

No further important changes occur in the internal structure of the heart, but there are some which affect the external form and thickness of its walls. In early foetal life the size of the heart bears a considerably greater proportion to that of the body than at a later period. At birth it is still proportionally large. For some time the auricular portion remains more voluminous than the ventricular, but in the latter half of foetal life the permanent proportion is more nearly established. The walls of both ventricles are also thicker than in after life, and it is especially deserving of notice that the wall of the right is up to near the time of birth quite as thick as that of the left,—a peculiarity which may be connected with the office of the right ventricle to propel the blood of the foetus through the extended course of the ductus arteriosus, the descending aorta and the placental circulation.

#### DEVELOPMENT OF THE BLOOD-VESSELS.

**The Principal Arteries. The Aorta.**—The most interesting part of this history is that relating to the development of the aorta and the larger vessels arising from it. The double condition of the main trunk of the aorta has already been referred to as existing in the chick up to near the end of the second day. About the fortieth hour the median fusion or coalescence of the two vessels begins to take place in the dorsal region, by their external union, at first in a very limited space, and very soon afterwards by the formation of a perforation through their united walls. The union of the two vessels which begins in the dorsal region extends itself backwards towards the lumbar vertebræ, and when it reaches the place where the omphalo-mesenteric arteries pass out on each side, these vessels, each of which was originally the continuation merely of one of the aortæ, appear now as branches of a single and median aorta. The iliac vessels are the next large vessels formed

from the hinder part of the aorta. The first vessels belonging to these trunks are not, however, those of the lower limbs, for these are not yet

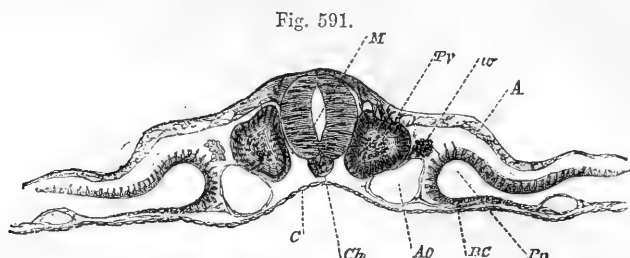


Fig. 591.—TRANSVERSE SECTION THROUGH THE DORSAL REGION OF AN EMBRYO-CHICK OF THE SECOND DAY (from Foster and Balfour, after His).

*M*, medullary canal; *Pv*, proto-vertebral column; *w*, rudiment of Wolffian duct in the intermediate mass; *Ch*, notochord; *Ao*, one of the two aortas; *A*, epiblast; *C*, hypoblast; *BC*, splanchnopleure; *Pp*, pleuroperitoneal space.

formed; but the umbilical or hypogastric arteries, developed at a very early period in connection with the allantois, and subsequently attain-

Fig. 592.

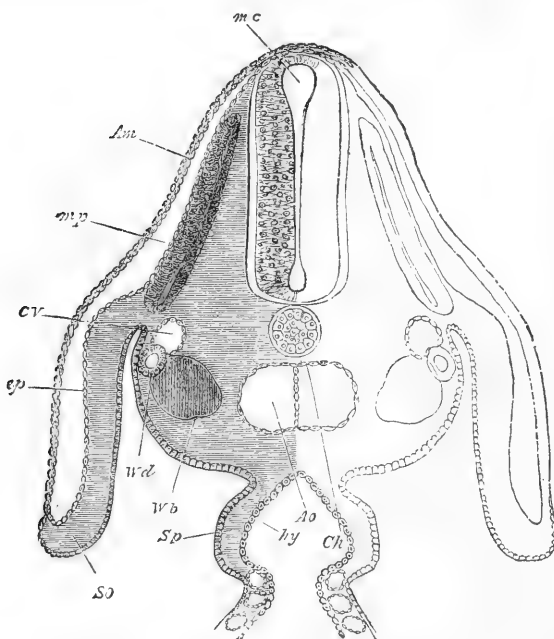


Fig. 592.—TRANSVERSE SECTION THROUGH THE DORSAL REGION OF AN EMBRYO CHICK, END OF THIRD DAY (from Foster and Balfour).

*Am*, amnion; *m p*, muscle plate; *CV*, cardinal vein; *Ao*, dorsal aorta at the point where its two roots begin to join; *Ch*, notochord (the line does not quite reach it); *Wd*, Wolffian duct; *Wb*, commencement of formation of Wolffian body; *ep*, epiblast; *so*, somatopleure; *Sp*, splanchnopleure; *hy*, hypoblast. The section passes through the place where the alimentary canal (*hy*) communicates with the yolk-sac.

ing to a large size along with the growth of the placenta. As the limbs are formed, arteries are developed in them, and these are branches of the main aorta ; but they are for a long time comparatively small, while the umbilical arteries speedily attain a large size, so that, even up to the conclusion of fetal life, they appear to form the principal part of the two large vessels into which the aorta divides at its lower extremity. The middle sacral artery may be looked upon as the continuation of the median stem of the aorta, and probably originates from a double vessel in the same manner as the aorta itself.

The double state of the main aorta when first formed in the foetus was discovered by Serres, and described by him in his 4th Memoir on Transcendental Anatomy (*Annal. des Scien. Nat.*, 1830), but was doubted by Von Baer, as Serres's observations did not show the relation of the primitive trunks of the aorta to the pharyngeal vascular arches. The fact of the original double condition was, however, placed beyond doubt by Allen Thomson (*Edin. New Philos. Journal*, 1830) by the method of tranverse sections, then first employed as a means of embryological investigation, and the process of median union was traced in full detail. The relation of this process to the occurrence of a permanent double canal in the aorta as a malformation, as described by Vrolik, Schröder van der Kolk and Cruveilhier, and observed in at least one case by Allen Thomson, has already been referred to in vol. i., p. 350.

According to Serres, the vertebral arteries within the cranium are originally separate, and the basilar artery results from their mesial union or fusion in the same manner as occurs in the aorta, and the median union of the anterior cerebral arteries in the forepart of the Circle of Willis is another example of the same process. It seems probable that the internal cross band observed by John Davy in the interior of the basilar artery (*Researches Physiol. and Anatom.*, 1839, p. 301) may be a remains of the septum or united walls of the two vertebral arteries.

**Aortic or Branchial Arches.**—The two primitive arterial arches which lead into the dorsal aorta from the arterial bulb of the rudimentary heart, at the time of the establishment of the first circulation, are the most anterior of a series of five pairs of vascular arches which are developed in succession round this part of the pharynx ; and which, since their discovery by Rathke in 1825 (*Oken's Isis*, 1825) have been regarded with much interest, as corresponding with those vessels which are the seat of development of the subdivided blood-vessels of the gills in fishes and amphibia. These vascular arches thus exhibit in the amniota, along with the branchial or pharyngeal clefts and visceral plates, a typical resemblance to the structure of gills, although no full development of these respiratory organs occurs in such animals, but they furnish by their various transformations the basis of formation of the permanent pulmonary and aortic stems and the main vessels to which they give rise.

The form and position of the primitive aortic arches, up to the time of their transformation into permanent vessels, is nearly the same in reptiles, birds and mammals ; and the main differences in the seat and distribution of the large permanent vessels are to be traced to changes in the openness and extent of growth of the several arches. The five pairs of arches do not all co-exist at the same time, for they are developed in succession from before backwards, and by the third day of incubation, or by the corresponding period of the fourth week in the human embryo, when the posterior arches have been formed, already a part of the anterior arches, beginning with the first one, has become

obliterated. Each of the first four branchial arches occupies a place in the substance of the pharyngeal or visceral plates, and in front of one of the pharyngeal clefts. The first or anterior is therefore situated in the inferior maxillary plate, and in front of the tympano-Eustachian, or first pharyngeal cleft; and the fifth arterial arch is placed behind the fourth pharyngeal cleft, and in the substance of the neck, in which there is no distinct bar or plate in the higher animals, but which is the seat of a developed branchial bar in some aquatic animals.

The vessels forming the arterial arches are given off on each side in succession from two short canals, into which the primitive arterial bulb divides immediately in front of the place where it joins the neck. These may be named the lower (ventral) or anterior aortic roots; and similarly, when they have passed round the wall of the pharynx, the branchial arches unite in succession into a vessel on each side, thus forming the upper (dorsal) or posterior aortic roots.

On the third and fourth days in the chick, and from the fourth to the sixth week in the human embryo, there are still three complete pairs of arterial arches passing round the pharynx, and connected both before and behind with the anterior and posterior aortic roots previously mentioned. The transformations of these arches were in part traced by Von Baer and various other observers, but the fuller knowledge of their changes is due to the later researches of Rathke (Mem. of

Fig. 593.

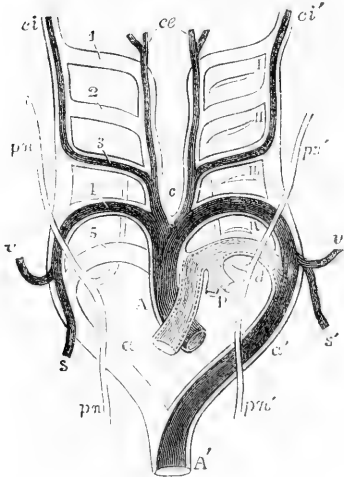


Fig. 593.—DIAGRAM OF THE AORTIC OR BRANCHIAL VASCULAR ARCHES OF THE MAMMAL, WITH THEIR TRANSFORMATIONS GIVING RISE TO THE PERMANENT ARTERIAL VESSELS (according to Rathke, slightly altered).

A, P, primitive arterial stem or aortic bulb, now divided into A, the ascending part of the aortic arch, and P, the pulmonary root; a, the right; a', the left aortic root; A', the descending aorta. On the right side, 1, 2, 3, 4, 5, indicate the five branchial primitive arterial arches; on the left side, I, II, III, IV, the four branchial clefts, which, for the sake of clearness, have been omitted on the right side. It will be observed, that while the fourth and fifth pairs of arches rise from the part of the aortic bulb or stem, which is at first undivided, the first, second, and third pairs are branches above c, of a secondary stem on each side. The permanent systemic vessels are represented in deep shade, the pulmonary arteries lighter; the parts of the primitive arches, which have only a

temporary existence, are drawn in outline only. c, placed between the permanent common carotid arteries; ce, the external carotid arteries; ci, ci', the right and left internal carotid arteries; s, the right subclavian rising from the right aortic root beyond the fifth arch; s', the left subclavian rising from the left aortic root opposite the fourth arch; P, the pulmonary arteries rising together from the left fifth arch; d, the outer or back part of the left fifth arch, forming the ductus arteriosus; pπ, pπ', the right and left pneumogastric nerves, descending in front of the aortic arches, with their recurrent branches represented diagrammatically as passing behind, with a view to illustrate the relations of these nerves respectively to the right subclavian artery (s) and the arch of the aorta and ductus arteriosus (d).

Vienna Acad., 1857), and although some points are still left in doubt, their history may now be given from these observations, and the supplemental illustration derived from the investigation of the various examples of congenital malformation, the greater number of which are manifestly related to variations in the natural mode of transformation. This will be explained by reference to the diagram in fig. 593.

From these researches it appears that the permanent vessels owe their formation to the persistence of certain of the foetal arches or parts of them, while other arches or portions of them become obliterated and disappear. Thus it is ascertained that in mammals the main aortic arch, which in the adult passes to the left of the trachea and gullet, is formed by the persistence of the fourth embryonic arterial arch of the left side, which not only remains patent, and becomes connected with the aortic stem of the arterial bulb, but keeps pace by its increased width and the development of its walls with the rate of growth in the other parts of the body, so that it soon surpasses all the rest of the arches in its width of calibre and thickness of its walls. In birds, however, the permanent aortic arch passes to the right of the trachea and gullet, and it is formed by the persistence of the fourth embryonic arch of the right side; while, in all reptiles, as there are two permanent aortic arches, it is by the persistence of both the right and left foetal arches that the two aortas are produced, the right being that which is most directly connected with the systemic or left ventricle.

The pulmonary arteries of mammals would appear by Rathke's observations to be developed in connection with only one foetal arterial arch, viz., the fifth of the left side, from the middle part of which they appear as branches, and the whole fifth arch of the right side undergoes rapid atrophy and ultimate obliteration. The first part of the left fifth arch, becoming the common pulmonary artery, is connected with that division of the arterial bulb which is separated as the pulmonary stem; but the remote part of this arch also remains fully patent, and undergoing equally with the rest of it full development, continues to lead into the *left* root of the aorta as ductus arteriosus Botalli, which serves to convey the blood from the right ventricle of the foetal heart into the descending aorta, but becomes obliterated at the time of birth.

This duct is therefore in mammals due to a persistent condition of the fifth left branchial arch. But, in birds and reptiles, it appears that the process of transformation is somewhat different, for in them the right and left pulmonary arteries (excepting in those serpents in which there is only one lung developed) are formed in connection with the respective right and left fifth branchial arches, and there are thus two ductus arteriosi during foetal life, the short one of the right side corresponding to that which is *left* in mammals, and the longer one of the left side passing round the pharynx into the left aortic root. Both of these arches are obliterated at the time of the exclusion of the bird from the egg; but in some reptiles the ductus arteriosi remain permanently open during life.

The subclavian and vertebral arteries were shown by Rathke to spring from the posterior aortic roots at a place between the junction of the fourth and fifth arches. In mammals, the vessels on the left side are from the first in direct connection with the aortic root at the place

which they permanently occupy ; but upon the right side, as the fourth arch and the aortic root are obliterated posteriorly, the passage for blood from the aortic stem into the subclavian trunk is formed by the persistence of the forepart of the fourth right arch as far as the place where it meets the origin of the subclavian and vertebral arteries.

The common carotid trunks, occupying the region which afterwards becomes the neck, but which is at first absent or extremely short, are formed by the anterior divisions of the aortic roots ; while the external carotid artery is due to the persistence of a channel in the continuation of each anterior aortic root, and the internal carotid artery arises from the persistence of the crossing third arch and the upper part of the posterior aortic root.

Thus it falls out that, in man and a certain number of mammals, an innominate artery is formed on the right side by the union of the first part of the fourth right aortic arch leading into the right subclavian, and the right anterior aortic root which forms the common carotid ; while, on the left side, the carotid and subclavian vessels rise separately from the permanent aortic arch in consequence of the distance lying between them in the original foetal condition.

It does not come within the scope of this chapter to describe the further steps of development of these vessels, nor to enter into an explanation of the manner in which abnormal position of the arch of the aorta and its branches, or of the pulmonary arteries, may be supposed to arise. For further information on this subject the reader is referred to the short account of the varieties given in the description of the blood-vessels in the first volume of this work, as well as to the third volume of Henle's *Handbuch*, and to the special works of Tiedemann and Richard Quain on the Arteries.

#### DEVELOPMENT OF THE GREAT VEINS.

In the early embryo, before the development of the allantois, a right and a left omphalo-mesenteric vein bring back the blood from the walls of the umbilical vesicle, and unite to form a short trunk, the *meatus venosus*, which is continued into the auricular extremity of the rudimentary heart.

In the first commencement of the placental circulation, or in the fourth week of foetal life, two umbilical veins are seen coming from the placenta, and uniting to form a short trunk, which opens into the common omphalo-mesenteric vein. Very soon the right omphalo-mesenteric vein and right umbilical vein disappear. In connection with the common trunk of the umbilical and omphalo-mesenteric veins, two sets of vessels make their appearance in the young liver. Those furthest from the heart, named *venæ hepaticæ advehentes*, become the right and left divisions of the portal vein ; the others are the hepatic veins, *venæ hepaticæ revehentes*. The portion of vessel intervening between those two sets of veins forms the *ductus venosus*, and the part above the hepatic vein, being subsequently joined by the ascending vena cava, forms the upper extremity of that vein. Into the remaining or left omphalo-mesenteric vein, open the mesenteric and splenic veins. The part above the latter forms the trunk of the portal vein ; and the portion of vessel between the union of this with the umbilical vein and the origin of the *venæ hepaticæ advehentes* is so altered that the portal trunk opens into the commencement of the right vena advehens.

At the time of the commencement of the placental circulation, two short transverse venous trunks, the *ducts of Cuvier*, open, one on each side, into the auricle of the heart. Each is formed by the union of a superior and an inferior vein, named the primitive jugular and the cardinal.

The *primitive jugular* vein receives the blood from the cranial cavity by channels in front of the ear, which are subsequently obliterated : in the greater



part of its extent it becomes the external jugular vein ; and near its lower end it receives small branches, which grow to be the external jugular and subclavian

Fig. 594. — DIAGRAMS ILLUSTRATING THE DEVELOPMENT OF THE GREAT VEINS (after Kölliker).

A, plan of the principal veins of the fœtus of about four weeks, or soon after the first formation of the vessels of the liver and the vena cava inferior.

B, veins of the liver at a somewhat earlier period.

C, principal veins of the fœtus at the time of the first establishment of the placental circulation.

D, veins of the liver at the same period.

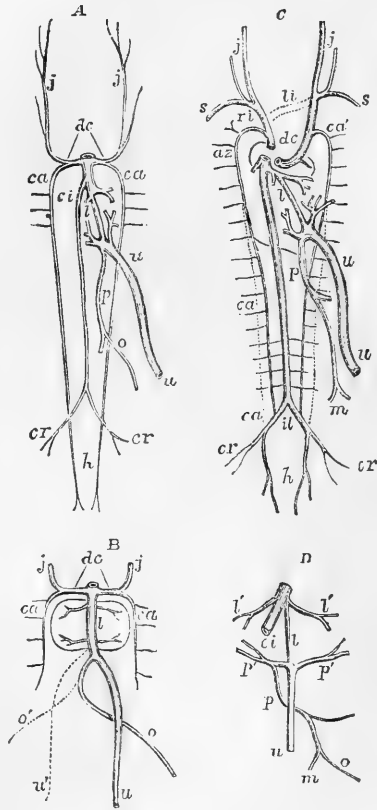
*dc*, the right and left ducts of Cuvier ; *ca*, the right and left cardinal veins ; *j, j*, the jugular veins ; *s*, the subclavian veins ; *az*, the azygos vein ; *u*, the umbilical or left umbilical vein ; *u'*, in B, the temporary right umbilical vein ; *o*, the omphalo-mesenteric vein ; *o'*, the right omphalo-mesenteric vein ; *m*, the mesenteric veins ; *p*, the portal vein ; *p', p'*, the venæ adheventes ; *l*, the ductus venosus ; *l', l'*, the hepatic veins ; *ci*, vena cava inferior ; *il*, the division of the vena cava inferior into common iliac veins ; *cr*, the external iliac or crural veins ; *h*, the hypogastric or internal iliac veins, in the line of continuation of the primitive cardinal veins.

In C, *li*, in dotted lines, the transverse branch of communication between the jugular veins which forms the left innominate vein ; *ri*, the right innominate vein ; *ca'*, the remains of the left cardinal vein by which the superior intercostal veins fall into the left innominate vein ; above *p*, the obliquely crossing vein by which the hemiazygos joins the azygos vein.

veins. The *cardinal veins* are the primitive vessels which return the blood from the Wolffian bodies, the vertebral column, and the parietes of the trunk. The inferior vena cava is a vessel of later development, which opens into the trunk of the umbilical and omphalo-mesenteric veins, above the venæ hepaticæ revehentes. The iliac veins, which unite to form the inferior vena cava, communicate with the cardinal veins. The inferior extremities of the cardinal veins are persistent as the internal iliac veins. Above the iliac veins the cardinal veins are obliterated in a considerable part of their course ; their upper portions then become continuous with two new vessels, the *posterior vertebral veins* of Rathke, which receive the lumbar and intercostal twigs.

As development proceeds, the direction of the ducts of Cuvier is altered by the descent of the heart from the cervical into the thoracic region, and becomes continuous with that of the primitive jugular veins. A communicating branch makes its appearance, directed transversely from the junction of the left subclavian and jugular veins, downwards, and across the middle line to the right jugular ; and further down in the dorsal region between the posterior vertebral veins a communicating branch passes obliquely across the middle line from right

Fig. 594.



to left. The communicating branch between the primitive jugular veins is converted into the left innominate vein. The portion of vessel between the right subclavian vein and the termination of the communicating branch becomes

Fig. 595.

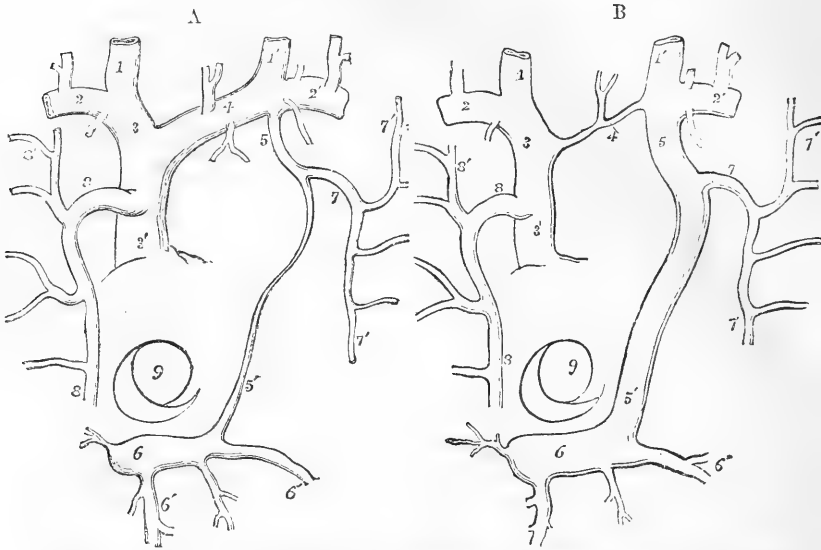


Fig. 595.—A and B.—DIAGRAMMATIC OUTLINES OF THE VESTIGE OF THE LEFT SUPERIOR CAVA AND OF A CASE OF ITS PERSISTENCE (sketched after Marshall).  $\frac{1}{3}$

A, brachio-cephalic veins with the superior intercostal, azygos, and principal cardiac veins.

B, the same in a case of persistence of the left superior cava, showing its communication with the sinus of the coronary vein. The views are supposed to be from before, the parts of the heart being removed or seen through.

1, 1', the internal jugular veins; 2, 2', subclavian veins; 3, right innominate; 3', right or regular superior cava; 4, in A, the left innominate; in B, the transverse or communicating vein between the right and left superior venæ cavæ; 5, in A, the opening of the superior intercostal vein into the innominate; 5', vestige of the left superior cava or duct of Cuvier; 5', in B, the left vena cava superior abnormally persistent, along with a contracted condition of 4, the communicating vein; 6, the sinus of the coronary vein; 6', branches of the coronary veins; 7, the superior intercostal trunk of the left side, or left cardinal vein; 8, the principal azygos or right cardinal vein; 7', 8', some of the upper intercostal veins; 9, the opening of the inferior vena cava, with the Eustachian valve.

the right innominate vein. The portion of the primitive jugular vein below the communicating vein, together with the right duct of Cuvier, forms the vena cava superior, while the cardinal vein opening into it is the extremity of the great vena azygos. On the left side, the portion of the primitive jugular vein placed below the communicating branch, and the cardinal and posterior vertebral veins, together with the cross branch between the two posterior vertebral veins, are converted into the left superior intercostal and left superior and inferior azygos veins. The variability in the adult arrangement of these vessels depends on the various extent to which the originally continuous vessels are developed or atrophied at one point or another. The left duct of Cuvier is obliterated, except at its lower end, which always remains pervious as the coronary sinus. Even in the adult, traces of the existence of this vessel can always be recognised in the form of a fibrous band, or sometimes even a narrow vein, which descends

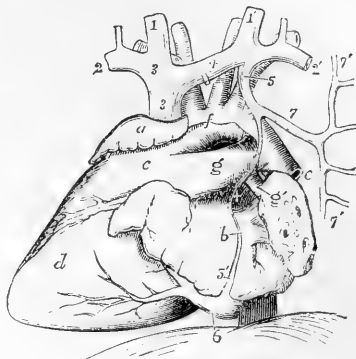
obliquely on the left auricle; and in front of the root of the left lung there remains a small fold of the serous membrane of the pericardium, the *vestigial* fold of the pericardium, so named by Marshall, to whom is due the first full elucidation of the nature and relations of the left primitive vena cava.

The left duct of Cuvier has been observed persistent as a small vessel in the adult. Less frequently a right and left innominate vein open separately into the right auricle, an arrangement which is also met with in birds and in certain mammals, and which results from the vessels of the left side being developed similarly to those of the right, while the cross branch remains small or absent. (Quain on the Arteries, plate 58, figs. 9 and 10.)

Fig. 596.—VIEW OF THE FŒTAL HEART AND GREAT VESSELS, FROM THE LEFT SIDE, TO SHOW THE VESTIGE OF THE LEFT SUPERIOR CAVA VEIN IN SITU. (This figure is planned after one of Marshall's, and slightly altered according to an original dissection.)

*a*, right auricle; *b*, left auricle and pulmonary veins; *c*, the conus arteriosus of the right ventricle; *d*, the left ventricle; *e*, descending aorta; +, vestigial fold of the pericardium; *f*, arch of the aorta, with a part of the pericardium remaining superiorly; *g*, main pulmonary artery and ductus arteriosus; *g'*, left pulmonary artery; 1, 1', right and left internal jugular veins; 2, 2', subclavian veins; 3, 3', right innominate and superior vena cava; 4, left innominate or communicating vein; 5, 5', remains of the left superior cava and duct of Cuvier, passing at + in the vestigial fold of the pericardium, joining the coronary sinus, 6, below, and receiving above the superior intercostal vein, 7; 7', 7', the upper and lower intercostal vein, joining into one.

Fig. 596.



A case is recorded by Gruber, in which the left vena azygos opened into the coronary sinus, and was met by a small vein descending from the union of the subclavian and jugular. (Reichert and Dubois, *Reymond's Archiv*, 1864, p. 729.) In this case, the jugular veins had been developed in the usual manner, while the left vena azygos continued to pour its blood into the duct of Cuvier.

(Consult Kölliker, *Entwicklungsgeschichte*, p. 414, et seq.; J. Marshall on the Development of the great Anterior Veins in Man and Mammalia, in *Phil. Trans.*, part i., 1850; and Wenzel Gruber, *Über die Sinus Communis und die Valvulæ der Venæ Cardiacæ, &c.*, in *Mém. de l'Acad. imper. des Scien. de St. Petersbourg*, 1864; and in *Virchow's Archiv*, Jan. 1865.)

#### PECULIARITIES OF THE FŒTAL ORGANS OF CIRCULATION.

It may be useful here to recapitulate shortly the peculiarities of structure existing in the advanced stage of the formation of the foetal organs of circulation with reference to their influence in determining the course of the blood during intra-uterine life, and the changes which occur in them in consequence of the establishment of pulmonary respiration at birth.

The so-called **foramen ovale** retains the form of a free oval opening in the septum auricularum up to the fourth month, but in the course of that month and the next there takes place the growth from below and on the left side of a flat plate or curtain, which advancing upwards fills up the floor of the fossa ovalis, adheres to its left borders as far as its anterior part, and then becoming free and passing beyond the anterior

border of the fossa, converts the aperture into an oblique passage or slit over the valvular margin of the fold, so that in the last three and a half months the arrangement is completed, by which blood may readily pass from the right into the left auricle, but not in a contrary direction.

The **Eustachian Valve** constitutes a crescentic fold of the lining structure of the heart, which is situated to the right of the opening of the inferior vena cava and fossa ovalis, deepens that fossa, and directs the blood entering it from the inferior cava towards the opening of the foramen ovale; while it throws the opening of the great coronary vein into connection with the right auricle, into which the superior vena cava also opens.

The formation at an early period of fœtal life of the transverse vein of the neck uniting the left with the right brachio-cephalic veins, carries the whole of the blood returning from the head and neck, together with that from the main azygos, into the stream entering the heart by the superior cava.

The **ductus arteriosus** passes from the main pulmonary artery into the aorta, at the hollow part of the arch, a short distance beyond the place of origin of the left subclavian artery. It is nearly of the same width with the pulmonary stem, while the right and left pulmonary arteries are of comparatively small size, so long as the lungs have not been expanded by air in respiration.

**Umbilical Vessels.**—Besides the usual branches of the descending aorta intended to supply the abdominal viscera and the lower limbs, two large vessels, named hypogastric or *umbilical arteries*, are prolonged from the common iliaes, and passing out of the abdomen, proceed along the umbilical cord, coiling round

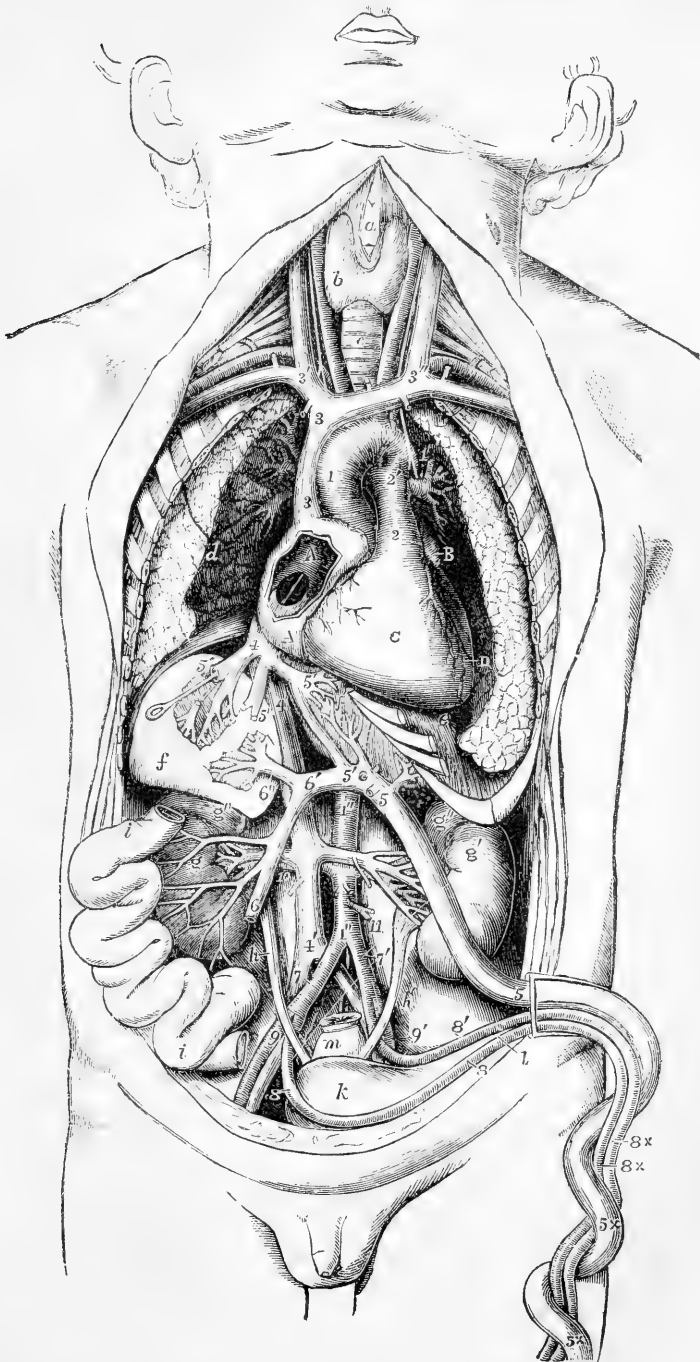
Fig. 597.—SEMI-DIAGRAMMATIC VIEW OF THE ORGANS OF CIRCULATION IN THE FŒTUS FROM BEFORE (from Luschka, modified, and from Nature). §

*a*, front of the thyroid cartilage; *b*, right side of the thyroid body; *c*, trachea; *d*, surface of the right lung turned outwards from the heart; *e*, diaphragm below the apex of the heart; *f*, right lobe of the liver, dissected to show ramifications of the portal and hepatic veins; *f'*, the middle part and left lobe of the liver in the same manner, showing branches of the umbilical veins and ductus venosus; *g*, right, *g'*, left kidney; *g''*, suprarenal bodies; *h*, right, *h'*, left ureter; *i*, portion of the small intestine turned towards the side, to show the veins from it going to the portal vein; *k*, urinary bladder; *l*, is placed below the umbilicus, which is turned towards the left of the fœtus, and points by a line to the urachus; *m*, rectum, divided and tied at its upper part.

*A*, *A*, right auricle of the heart opened to show the foramen ovale: a probe, introduced through the large divided right hepatic vein and vena cava inferior, is seen passing through the fossa ovalis into the left auricle: at the lower part of the fossa ovalis is seen the Eustachian valve, to the right and inferiorly the auriculo-ventricular orifice; *B*, the left auricular appendix; *C*, the surface of the right ventricle; *D*, placed on the inner surface of the left lung, points to the left ventricle.

1, ascending part of the arch of the aorta; 1', back part beyond the ductus arteriosus; 1'', abdominal aorta; 2, stem of the pulmonary artery; 2', the place of division into right and left pulmonary arteries and root of the ductus arteriosus: the left pneumo-gastric nerve is seen descending over the arch of the aorta; 3, superior vena cava; 3', right, 3'', left innominate vein; 4, stem of the inferior vena cava, between the junction of the hepatic vein and the right auricle; 4', continuation of the vena cava inferior below; 5, umbilical vein within the body of the fœtus; 5 ×, without the body, in the umbilical cord; 5', 5'', ductus venosus; between 5 and 5', the direct branches of the umbilical vein to the liver; 5'', 5''', hepatic veins, through one of which a probe is passed into the fossa ovalis and through the foramen ovale; 6, vena portæ; 6', its left branch joining the umbilical vein; 6'', its right branch; 7, placed on the right iliac vein, points to the right common iliac artery; 7', left common iliac artery; 8, right, 8', left umbilical arteries coming from the internal iliac arteries; 8 ×, umbilical arteries without the body, in the umbilical cord; 9, 9', external iliac arteries; 10, placed below the right renal vessels; 11, inferior mesenteric artery, above the root of which are seen the two spermatic arteries.

Fig. 597.



the umbilical vein to reach the placenta. The commencement of each of these vessels afterwards forms the trunk of the corresponding internal iliac artery, but, from their size, they might be regarded in the fœtus as the continuations of the common iliac arteries into which the aorta divides. From the placenta the blood is returned by the umbilical vein, which, after entering the abdomen, communicates by one branch with the portal vein of the liver, and is continued by another, named *ductus venosus*, into one of the hepatic veins, through which it joins the main stem of the vena cava inferior.

**Course of the Blood in the Fœtus.**—The right auricle of the fœtal heart receives its blood from the two venæ cavæ and the coronary vein. The blood brought by the superior cava is simply the venous blood returned from the head and upper half of the body; whilst the inferior cava, which is considerably larger than the superior, conveys not only the blood from the lower half of the body, but also that which is returned from the placenta through the umbilical vein. This latter stream of blood reaches the vena cava inferior, partly by a direct passage—the *ductus venosus*, and partly by the hepatic veins, which bring to the vena cava inferior all the blood circulating through the liver, whether derived from the supply of placental blood entering by the umbilical vein, or proceeding from the vena portæ or hepatic artery.

The blood of the superior vena cava, descending in front and to the right of the Eustachian valve, and mixed with a small portion of that from the inferior cava, passes on into the right ventricle, and is thence propelled into the trunk of the pulmonary artery. A small part of it is then distributed through the branches of that vessel to the lungs, and returns by the pulmonary veins to the left auricle; but, as these vessels remain comparatively undilated up to the time of birth, by far the larger part passes through the *ductus arteriosus* into the dorsal aorta, entering that vessel beyond the place of origin of the arteries of the head and upper limbs, and, mixed perhaps with a small quantity of the blood flowing into the aorta from the left ventricle, is distributed in part to the lower half of the body and the viscera, and in part is conveyed along the umbilical arteries to the placenta. From these several organs it is returned by the vena cava inferior, the venæ portæ, and the umbilical vein: and, as already noticed, reaches the right auricle through the trunk of the inferior cava.

Of the blood entering the heart by the inferior vena cava, only a small part is mingled with that of the superior cava, so as to pass into the right ventricle; by far the larger portion, directed by the Eustachian valve through the foramen ovale, flows from the right into the left auricle, and thence, together with the small quantity of blood returned from the lungs by the pulmonary veins, passes into the left ventricle, from whence it is sent into the arch of the aorta, to be distributed almost entirely to the head and upper limbs. A small portion of it, may, however, flow on into the descending aorta, and join the fuller stream of blood from the *ductus arteriosus*. From the upper half of the body the blood is returned by the branches of the superior cava to the right auricle, from which its course into the right ventricle and pulmonary trunk has been already traced.

There is probably a considerable difference in the early and more advanced stages of foetal life, in the distribution of the stream of blood entering the heart by the vena cava inferior. In the early stages, a large part of the current being directed into the left, but in the three last months, and as the fœtus approaches maturity, more and more of the blood of the inferior cava joins the stream from the superior cava; and, indeed, the course of the blood, and the relative position of the veins, as well as other original peculiarities of the fœtal heart, become gradually altered, in preparation, as it were, for the important changes which take place at birth. It seems also probable that very little of the blood propelled from the left ventricle passes into the descending aorta beyond the *ductus arteriosus* during those months of foetal life in which the peculiarities of the circulation are most complete.

From the preceding account of the course of the blood in the fœtus, it will be seen that, whilst the modified blood from the placenta is principally conveyed to the upper or cephalic half of the fetus, the lower half of the body is chiefly supplied with the blood which has already circulated through the head and upper

limbs. The larger portion of the blood, however, which passes into the descending aorta, is sent out of the body to the placenta. This duty is principally performed by the right ventricle, which after birth is charged with an office somewhat analogous, in having to propel the blood through the lungs. But the passage of the blood through the vessels of the umbilical cord and placenta is longer and subject to greater resistance than that of the pulmonary circulation, and the right ventricle of the fœtus, although probably aided by the left in the placental circulation, also takes a large share in the systemic through the lower half of the body; and this, perhaps, may be the reason why the wall of the right equals in thickness that of the left ventricle in the fœtus.

Sabatier was the first to call attention particularly to the action of the Eustachian valve in separating the currents of blood entering the right auricle by the superior and inferior venæ cavæ. (*Traité d'Anat.*, vol. ii., p. 224.) This separation, as well as that occurring between the currents passing through the aortic arch and the ductus arteriosus into the descending aorta, were illustrated experimentally by John Reid. (See art. "Heart," in *Cyclop. of Anat. and Physiol.*, and *Edin. Med. and Surg. Journal*, 1835.) A striking confirmation of the extent to which the last mentioned division of the two currents of the fœtal blood may take place, without disturbance of the circulation up to the time of birth, is afforded by the examples of malformation in which a complete obliteration has existed in the aortic trunk immediately before the place of the union of the ductus arteriosus with the posterior part of the aortic arch.

#### CHANGES IN THE CIRCULATION AT BIRTH.

The changes which occur in the organs of circulation and respiration at birth, and lead to the establishment of their permanent condition, are more immediately determined by the inflation of the lungs with air in the first respiration, the consequent rapid dilatation of the pulmonary blood-vessels with a greater quantity of blood, and the interruption to the passage of blood through the placental circulation. These changes are speedily accompanied by shrinking and obliteration of the ductus arteriosus, in the space between the division of the right and left pulmonary arteries and its junction with the aorta, and of the umbilical arteries from the hypogastric trunk to the place of their issue from the body by the umbilical cord;—by the cessation of the passage of blood through the foramen ovale, and somewhat later by the closure of that foramen, and by the obliteration of the umbilical vein as far as its entrance into the liver, and of the ductus venosus within that organ.

The process of obliteration of the arteries appears to depend at first mainly on the contraction of the coats, but this is very soon followed by a considerable thickening of their substance, reducing rapidly their internal passage to a minute tube, and leading in a short time to final closure, even although the vessel may not present externally any considerable diminution of its diameter. It commences at once, and is perceptible after a few respirations have occurred. It makes rapid progress upon the first and second days, and by the third or fourth days the passage through the umbilical arteries is usually completely interrupted. The ductus arteriosus is rarely found open after the eighth or tenth day, and by three weeks it has in almost all instances become completely impervious.

The process of closure in the veins is slower, there not being the same thickening or contraction of their coats; but they remain empty of blood and collapsed, and by the sixth or seventh day, are generally closed.

Although blood ceases at once to pass through the foramen ovale from the moment of birth, or as soon as the left auricle becomes filled with the blood returning from the lungs, and the pressure within the two auricles is equalised, yet the actual closure of the foramen is more tardy than any of the other changes now referred to. It is gradually effected by the union of the forepart of the valvular fold forming the floor of the fossa ovalis with the margin of the annulus on the left side; but the crescentic margin is generally perceptible in the left auricle as a free border beyond the place of union and not unfrequently the union remains incomplete, so that a probe may be passed through the reduced aperture. In many cases a wider aperture remains for more or less of the first year of infancy, and in certain instances there is such a failure of the union of the valve as to allow of the continued passage of venous blood, especially when the circulation is disturbed by over-exertion, from the right to the left auricle, as occurs in the malformation attending the morbus cœruleus.

#### DEVELOPMENT OF THE GENITAL AND URINARY ORGANS.

The development of the permanent genital and urinary organs in

Fig. 598.

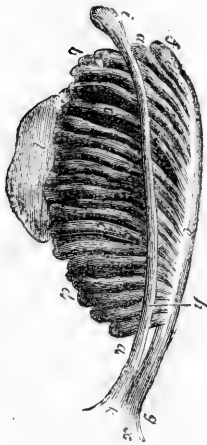

Fig. 598.—ENLARGED VIEW FROM BEFORE OF THE LEFT WOLFFIAN BODY BEFORE THE ESTABLISHMENT OF THE DISTINCTION OF SEX (from Farre after Kobelt).

*a, a, b, d*, tubular structure of the Wolffian body; *c*, Wolffian duct; *f*, its upper extremity; *g*, its termination in *x*, the uro-genital sinus; *h*, the duct of Müller; *i*, its upper still closed extremity; *k*, its lower end terminating in the uro-genital sinus; *l*, the mass of blastema for the reproductive organ, ovary or testicle.

birds and mammals, is preceded by the formation of a temporary glandular organ with which the principal parts of both these sets of organs are in their origin connected. These bodies are named the Wolffian bodies, after their discoverer, C. F. Wolff. From this close association of these organs, it becomes necessary to describe their development together.

#### PRIMARY FORMATION OF THE URO-GENITAL SYSTEM.

**Wolffian bodies.**—The Wolffian bodies occupy a considerable space in the abdominal cavity of birds and mammals from an early period of foetal life, extending at first from the fifth or sixth protovertebral segments to near the caudal extremity, in the form of two reddish prominent ridges, one on each side of the primitive intestine, and below the protovertebral columns and primitive aortæ. They are thickest in the middle of their length, and taper somewhat at their upper and lower extremities. They consist, when fully formed, of short slightly convoluted tubes running transversely, connected on the inner side with vascular glomeruli, very similar to the Malpighian corpuscles of the permanent kidneys, and leading along the outer border into a tube named the

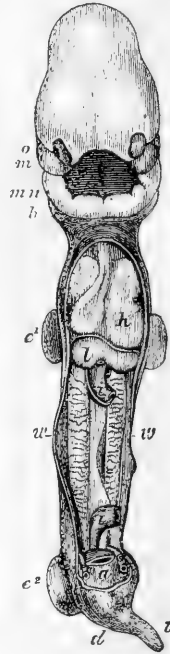


Wolffian duct, which terminates on each side in the cloaca. The Malpighian glomeruli were first discovered by Rathke, who pointed out

Fig. 599.—HUMAN EMBRYO OF FROM 25 TO 28 DAYS, VIEWED FROM BEFORE, THE THORAX AND ABDOMEN OPENED (from K ulliker after Coste).

Fig. 599.

*o*, the eye; *m*, the maxillary plate; *mn*, the inferior maxillary plate; *b*, the second postoral plate; *h*, the heart; *w*, Wolffian bodies and ducts on their outer borders; *l*, the liver; *e*<sup>1</sup>, the upper and *e*<sup>2</sup>, the lower limbs; *a*, the allantoid pedicle, and on each side of it the umbilical arteries; *i, i*, the upper and lower parts of the intestine of which the middle parts with the vitello-intestinal duct have been removed, leaving the mesentery stretched between.



their vascular structure, and their vessels derived from neighbouring branches of the aorta. The ducts of the Wolffian bodies are found to contain a whitish fluid, and the bodies are believed to perform the glandular office of kidneys during a part of foetal life in the higher vertebrata, and they have accordingly received the name of *primordial kidneys*, a designation which is quite appropriate, as it appears that in fishes and amphibia, they remain as the whole in some, and a part in others, of the permanent kidneys.

In the human foetus they begin to be formed along with the allantois, at a very early period, probably before the third week, as they are already very apparent in the fourth. They have attained their full size by the sixth week, and in the seventh and eighth are rapidly diminishing in size, in connection with the changes which accompany the development of the genital organs and the permanent kidneys.

Fig. 600.

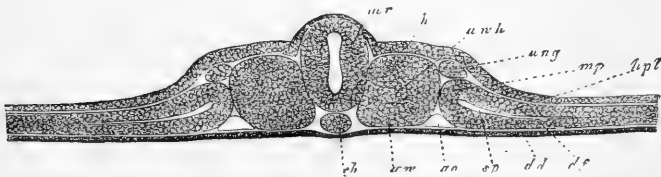


Fig. 600.—TRANSVERSE SECTION THROUGH THE EMBRYO OF THE CHICK AND BLASTODERM ON THE SECOND DAY (from K ulliker).

*d d*, hypoblast; *ch*, chorda dorsalis; *u w*, primordial vertebr e; *m r*, medullary plates; *h*, cornaceous layer or epiblast; *u w h*, cavity of the primordial vertebral mass; *m p*, mesoblast dividing at *s p* into *h p l*, somatopleure, and *d f*, splanchnopleure; *u n g*, Wolffian duct, beginning in the intermediate cell-mass.

As development advances the Wolffian bodies rapidly become proportionally shorter and thicker: they shrink towards the lower part of the abdominal cavity, and soon become almost entirely wasted. By

the middle of the third month only traces of them are visible in the human embryo.

**First origin of the Wolffian bodies.**—Difference of opinion has for some time existed among embryologists as to the exact source of

Fig. 601.

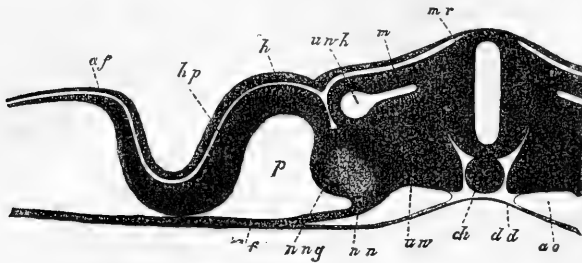


Fig. 601.—TRANSVERSE SECTION THROUGH THE ABDOMINAL REGION OF THE CHICK ON THE THIRD DAY (from Kölliker).

The explanation of the letters is the same as that in the previous figure.

the rudiments of the uro-genital system, but it now appears to be fully ascertained by the concurrence of a variety of observers, more especially of Waldeyer, Schenk, and Balfour, that the Wolffian duct, which is the first part formed, and the formative substance of the Wolffian tubes

Fig. 602.

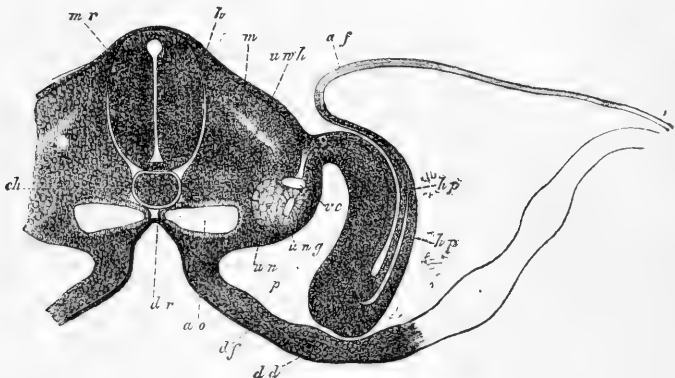


Fig. 602.—TRANSVERSE SECTION OF THE EMBRYO-CHICK OF THE THIRD DAY (from Kölliker).

*mr*, medullary canal and medulla of the spinal cord; *cn*, notochord; *uwh*, primordial vertebral mass; *m*, muscle-plate; *dr* and *df*, groove of the primitive intestine as formed by the hypoblast and splanchnopleure; *ao*, one of the two aortæ; *un*, Wolffian body; *ung*, Wolffian duct; *vc*, vena cardinalis; *h*, epiblast; *hp*, somatopleure and its reflection into the amnion; *p*, the pleuro-peritoneal space.

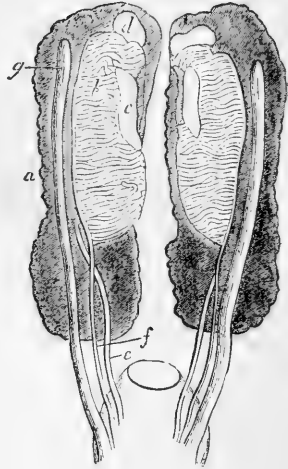
and glomeruli, proceed from the mesoblast, and as these form the foundation of the principal urinary and genital organs, it follows that this

system as a whole has its foundation in the mesoblastic layer. In birds and mammals the duct, which is first formed, appears in its commencement as a solid cord in the upper part of a group of cells, projecting below the epiblast, in the interval between the protovertebral mass and

Fig. 603.—KIDNEYS, WOLFFIAN BODIES, WOLFFIAN AND MÜLLERIAN DUCTS OF A FETAL BIRD. MAGNIFIED (after J. Müller).

*a*, kidney; *b*, tubular part of Wolffian body; *c*, the ovary; *d*, suprarenal body; *e*, ureter; *f*, Wolffian duct; *g*, duct of Müller.

Fig. 603.



the united somatopleure and splanchnopleure of the mesoblast, and thence called the *intermediate cell mass* (fig. 600, *ung*). This cord becomes hollow, and gradually changes its place by sinking downwards in the cellular mass in which it is imbedded, towards the pleuro-peritoneal cavity, while the tubular and glomerular structures of the Wolffian body are developed as diverticula from the duct in connection with the neighbouring cellular blastema.

The intermediate cell-mass now forms a considerable projection to the outside of the mesentery, which occupies a median position (figs. 602 and 604), and the epithelium on its surface exhibits a considerable thickening in two places, first, along the inner side, where it becomes columnar, and forms an opaque whitish ridge, the *germ epithelium*, the seat of after formation of the primitive ovigerms; and second, along the outer side in a line inside the seat of the Wolffian duct, where, by a process of grooved involution, there is gradually formed the duct named *Müllerian*, after its discoverer, Johannes Müller. It is now fully ascertained that both the Wolffian and Müllerian ducts are constantly present in all embryos of birds and mammals, whatever the sex they may be destined afterwards to assume; but the respective ducts have a different sexual destination, for the duct of Müller becomes converted into the oviduct of the female, while in the male the Wolffian duct forms the vas deferens, or main seminal duct of the testicle; and while vestiges of the duct of Müller are perceptible in the developed male, remains of the Wolffian duct are almost always present in the female in a manner afterwards to be described.

The *permanent kidneys* of birds and mammals take their origin in connection with the Wolffian duct and formative substance deposited near the Wolffian bodies. Their first rudiments consist in a diverticulum from the upper or dorsal aspect of the Wolffian duct near its posterior extremity, which constitutes the commencement of the ureter; and from this the tubular and glandular parts of the kidney are formed by extension into the neighbouring mass of blastema at a period somewhat later than that of the development of the Wolffian body itself.

The researches of Waldeyer and others have shown that the *productive glands* of the generative organs in the two sexes, ovary and testis, arise from nearly the same part of the intermediate cell mass, but in

a manner somewhat different. Both are mainly produced in the substance which lies along the inner border of the blastemic mass already referred to, and which may therefore be named the *common reproductive blastema*; but with this important difference between them, that in the

Fig. 604.

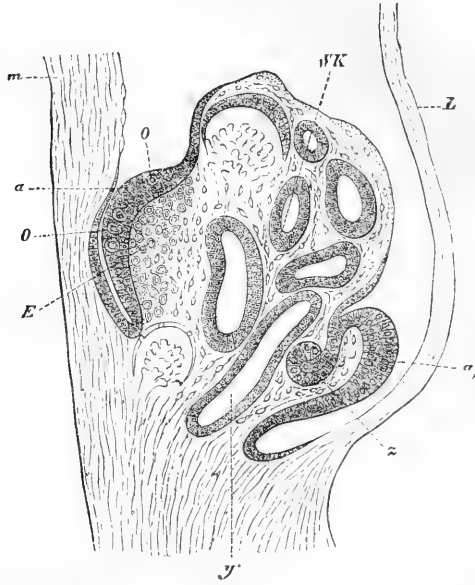


Fig. 604.—TRANSVERSE SECTION OF THE WOLFFIAN BODY AND RUDIMENT OF THE OVARY AND THE DUCT OF MÜLLER IN AN EMBRYO CHICK AT THE END OF THE FOURTH DAY (from Waldeyer).

WK, Wolffian body; y, section of the Wolffian duct; a, germ epithelium with, o, o, cells enlarging into ovigerms; a', epithelium near the place of involution of Müller's duct, z; E, stroma of the ovary; m, mesentery; L, lateral wall of the abdomen.

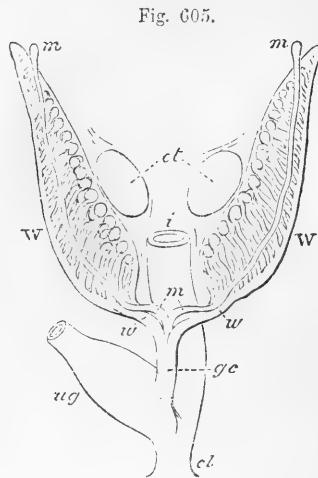
female the primitive ova originate more immediately from the cells of the surface in the *germ epithelium*, and become afterwards imbedded as Graafian follicles in the deeper substance of the mass which forms a stroma round the ova; while the glandular substance of the testicle is apparently developed within the cell mass, without any direct concurrence of the superficial or germ epithelium,—which, though at first existing in male as well as in female embryos, and even exhibiting some tendency to the enlargement of some cells as ovigerms (Waldeyer), soon becomes atrophied and reduced in thickness in the male as the structure of the testicle becomes developed.

The **ducts of Müller** open at their anterior extremities into the pleuro-peritoneal cavity by the orifice which ultimately becomes the infundibulum and fimbriated ostium abdominale; and, as their lining membrane has originally been formed by an involution of the epithelium (germ-epithelium) of that cavity, it follows that the lining membranes of the female passages (Fallopian tubes and uterus) which in their later development assume the characters of mucous membrane, and are de-

scribed as such, have in reality the same origin as the lining membrane of the pleuro-peritoneal cavity.

Fig. 605.—DIAGRAMMATIC OUTLINE OF THE WOLFFIAN BODIES IN THEIR RELATIONS TO THE RUDIMENTS OF THE REPRODUCTIVE ORGANS (A. T.).

*ot*, seat of origin of the ovaries or testes; *W*, Wolffian bodies; *w, w*, Wolffian ducts; *m, m*, Müllerian ducts; *gc*, genital cord; *ug*, sinus urogenitalis; *i*, intestine; *cl*, cloaca.



These ducts at first unite with the Wolffian ducts on each side separately, but later they become separated from them and conjoined at their lower or posterior extremity, and in the development of the female type the uterus results

from the further growth of this median or united part, while in the male sex the prostatic vesicle and gland may be looked upon as its nearest representative, and other partial vestiges of the female passages are to be found in the human species and in various degrees in different mammals.

The **Wolffian duct**, as has already been stated, becomes the vas deferens of the testicle, while the secreting part of the gland, comprising the tubuli seminiferi and the rete testis, are developed in the reproductive blastema of the intermediate cell mass. The union of these two parts of the male organs through the coni vasculosi and the epididymis is brought about by the development of the efferent vessels in the upper part, or what may appropriately be termed the sexual part of the Wolffian body, as this structure has been shown by Banks and others to differ from the lower and larger part of the organ by the absence of the vascular tufts or glomerular arrangement in connection with its tubes. The convoluted tubes forming the efferent vessels, which from the time of their first production are in communication with the upper part of the Wolffian duct, become subsequently connected with the vessels of the rete testis, and thus the original Wolffian duct becomes in its upper part the tube of the epididymis, and in its lower the main excretory duct or vas deferens of the testis.

**Homologies of the Wolffian body:**—An interesting view of the correspondence of the urino-genital organs in different animals is presented by the recent observations of embryologists on the formation of the Wolffian bodies. It was ascertained by His, Bornhaupt, Rosenberg and Goette, that in the lower vertebrates a second body similar to the Wolffian was formed later in connection with its main duct; and the researches of Balfour and Semper have shown that in the selachians the permanent kidneys, which had long been believed to be the same

with the Wolffian bodies, consist in reality of two sets of tubular organs, of which one corresponds to the Wolffian bodies of the embryos of the amniota, while the other tubular body, already referred to as being of later formation and as connected with the main Wolffian duct, corresponds to the permanent kidneys of the higher animals. Balfour

Fig. 606.

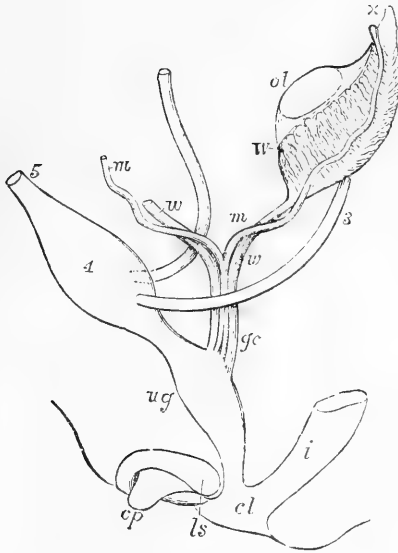


Fig. 606.—DIAGRAM OF THE PRIMITIVE URO-GENITAL ORGANS IN THE EMBRYO PREVIOUS TO SEXUAL DISTINCTION.

The parts are shown chiefly in profile, but the Müllerian and Wolffian ducts are seen from the front. 3, ureter; 4, urinary bladder; 5, urachus; *ol*, the mass of blastema from which ovary or testicle is afterwards formed; *W*, left Wolffian body; *x*, part at the apex from which the coni vasculosi are afterwards developed; *w*, *w*, right and left Wolffian ducts; *m*, *m*, right and left Müllerian ducts uniting together and with the Wolffian ducts in *gc*, the genital cord; *ug*, sinus urogenitalis; *i*, lower part of the intestine; *cl*, common opening of the intestine and urogenital sinus; *cp*, elevation which becomes clitoris or penis; *ls*, ridge from which the labia majora or scrotum are formed.

has also ascertained (*Jour. of Anat. and Physiol.*, vol. x., 1875) that in the selachians both the ducts are found which exist in the amniota, viz., both the Wolffian and the Müllerian ducts, but that they arise in a somewhat different manner from that by which they are produced in birds and mammals, inasmuch as in the selachians the duct of Müller arises by the formation of a septal partition which divides the original duct through a considerable part of its length into two canals: one of these, the Müllerian duct, is in communication with the pleuro-peritoneal cavity in front, and opens into the cloaca behind as a separate tube; the other corresponding with the Wolffian, besides being the excretory duct of the primordial kidneys, becomes the vas deferens of the testicle. In the selachians, therefore, the permanent kidneys consist of two parts, of which one, the anterior, is homologous with the temporary kidneys or Wolffian bodies, while the other, or posterior part, corresponds with the permanent kidneys of birds and mammals.

Balfour and Semper have made further the interesting discovery that the transverse tubes of the two parts of the primordial kidney of the lower animals correspond in number and position with the vertebral segments of the region of the embryo in which they are situated,—a fact of great interest in vertebrate morphology, and, according to the authors, leading also to important views of the morphological correspondence of the organs in question with similar organs in the anne-

lida. The tubes of the kidneys in the lower vertebrata are therefore named *segmental tubes*, and their common duct (Wolffian), the *segmental duct*. In the amniota, however, the same correspondence between vertebrate segments and Wolffian body tubes no longer exists.

**The External Organs.**—The existence in the embryo at first of a single outlet or cloaca, for the urogenital passages and the alimentary canal in common, has already been referred to. This condition of the

Fig. 607.—DEVELOPMENT OF THE EXTERNAL SEXUAL ORGANS IN THE MALE AND FEMALE FROM THE INDIFFERENT TYPE (from Ecker).

A, the external sexual organs in an embryo of about nine weeks, in which external sexual distinction is not yet established, and the cloaca still exists; B, the same in an embryo somewhat more advanced, and in which, without marked sexual distinction, the anus is now separated from the urogenital aperture; C, the same in an embryo of about ten weeks, showing the female type; D, the same in a male embryo somewhat more advanced. Throughout the figures the following indications are employed; *pc*, common blastema of penis or clitoris; to the right of these letters in A, the umbilical cord; *p*, penis; *c*, clitoris; *cl*, cloaca; *ug*, urogenital opening; *a*, anus; *ls*, cutaneous elevation which becomes labium or scrotum; *l*, labium; *s*, scrotum; *co*, caudal or coccygeal elevation.

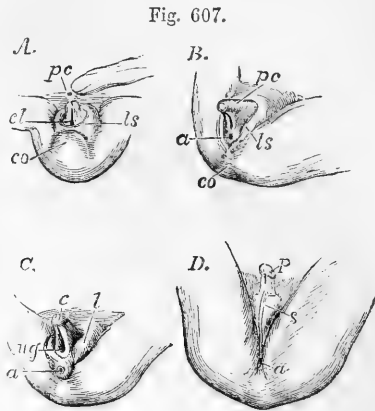


Fig. 607.

parts connected with the surface continues even beyond the time when the sexual distinction has begun to become manifest in the deeper organs, as up to the seventh day in the chick and the end of the eighth week in the human foetus. Previous to this time the cloaca presents itself in the form of a wide cavity, into the middle of which the intestine descends on the dorsal aspect. The pedicle of the allantois opens by a deep groove or recess anteriorly or on the ventral aspect, and on each side there is a widening, into which, in succession from the ventral to the dorsal aspect, open the Müllerian and Wolffian ducts and the ureters. The external opening has the form of a vertical slit wider above and below, and is situated in a raised portion of the common integument, from which all the other parts retire more and more within the cavity of the pelvis as it gradually deepens.

The first change which takes place in the rudiments of the external organs, and which is common to all embryos, and therefore to both sexes, consists in the advance from the sides and behind of the partition which separates the intestinal portion from the rest, thus throwing the urogenital ducts into connection with a wide ventral part of the lower aperture, *urogenital sinus*, while the intestine is left in communication with the narrower dorsal section. The anus, strictly so called, now appears as the opening of the alimentary canal, and in front of it the urogenital aperture forms a narrow vertical slit wider behind than before, and leading into the urogenital sinus.

In front of the last-named aperture there now rises a well-marked prominence of the integument, the rudiment of the still indifferent

organ representing the *clitoris* or *penis*. Into this prominence the urogenital groove runs forward, and surrounding the prominence in front, and continued downwards on each side of the urogenital opening, there is a raised ridge of integument, which is the foundation of the future *labia majora* in the female, and of the two halves of the *scrotum* in the male.

The description of the later changes which occur in these parts in the development of fuller sexual differences will be given hereafter. Here it will be sufficient to state their general nature. In embryos which are assuming the male type, the common eminence becomes gradually longer, more cylindrical and deeply grooved along its lower surface. The lateral ridges of the urogenital opening become united from behind forwards along the middle line, and this union is gradually continued into the ridges of the groove below the penis, so as to enclose a canal which becomes the urethra with its tegumental and spongy vascular coverings, and to form below this the scrotum, in which the raphe is the remains of the median union of the integument.

In female embryos, on the other hand, the cylindrical eminence remains comparatively small, and the groove along its lower surface widens into two folds, forming the *labia minora* or *nymphae*; while the larger lateral integumental folds, retaining their prominence and remaining separate, constitute the labia majora. The groove is not closed, but widened and shortened so as to become the vulva, while more deeply the sinus urogenitalis shortens itself considerably so as to form the limited *atrium vaginae*, into which open the urethra from the urinary bladder and the now united lower portion of Müller's ducts forming the vagina.

From the previous statement, it appears that both the urinary and the reproductive organs take their origin in symmetrical pairs from the intermediate cell-masses of the mesoblast, which are situated to the outside at first, and subsequently below, the protovertebral columns. The earliest formed of these organs are the Wolffian bodies, by which the others are all intimately connected together in their development, so as to form one great system. It further appears that, while the urinary organs are developed in an entirely similar manner in all embryos, there are in the sexual organs certain departures from the common type by which the peculiarities of the male and female are established. The general plan of development of these organs having been previously described, the history of the process will now be completed by an account of the further changes which they undergo.

#### FURTHER HISTORY OF THE DEVELOPMENT OF THE UROGENITAL ORGANS.

**The Kidneys and their Ducts.**—These organs are developed together from a mass of formative cells situated posteriorly on the dorsal aspect of the Wolffian bodies, their first hollows being formed as diverticula from the Wolffian duct.

The formative blastema of the kidney, as observed by Rathke in the foetal calf, soon contains a series of club-shaped bodies which have their larger ends free and turned outwards, and their smaller ends or pedicles directed inwards towards the future hilus, where they are blended together. As the organ grows these bodies increase in number, and finally, becoming hollow, form the *uriniferous tubes*. At first, short, wide, and dilated at their extremities, the tubuli soon become elongated, narrow, and flexuous, occupying the whole mass of the kidney, which then appears to consist of cortical substance only. At a subsequent period, the tubuli nearest



the hilus become straighter, and thus form the medullary substance. The tubuli, as shown by Valentin, are absolutely, as well as relatively, wider in the early stages of formation of the kidney. The Malpighian corpuscles have been seen by Rathke in a sheep's embryo, the kidneys of which measured only two and a half lines in length. Kölliker observed the kidneys already formed in the human embryo of between six and seven weeks, the ureter being hollow, and communicating with dilated cavities within the rest of the blastema. At eight weeks they had assumed their characteristic reniform shape, and about the tenth week they are distinctly lobulated. The separate lobules, generally about fifteen in number, gradually coalesce in the manner already described; but at birth, indications of the original lobulated condition of the kidney are still visible on the surface, and the entire organ is more globular in its general figure than in the adult. The kidneys are then also situated lower down than in after-life.

In the advanced foetus and in the new-born infant, the kidneys are relatively larger than in the adult, the weight of both glands, compared with that of the body, being, according to Meckel, about one to eighty at birth.

**The Suprarenal Bodies.**—These organs have their origin in a mass of blastema, placed in front of and between the kidneys and the Wolffian bodies. They appear to originate in a single mass, and afterwards to become divided. Kölliker has also observed them in close connection with the substance in which the large sympathetic plexus of the abdomen is produced, but it is not ascertained that they have a common origin.

In the human embryo the suprarenal bodies are at the seventh or eighth week larger than the kidneys, and quite conceal them, but after that time their relative size diminishes, so that at about the tenth or twelfth week they are smaller than the kidneys. At six months, according to Meckel, the proportion of the suprarenal bodies to the kidneys is as 2 to 5; at birth the proportion between them is 1 to 3, whilst in the adult it is about 1 to 22. They diminish much in aged persons, and are sometimes scarcely to be recognised.

**The Urinary Bladder and Urachus.**—It has elsewhere been stated that in the human embryo the vesicular part of the allantois extending beyond the umbilicus is closed at a very early period. Its pedicle, however, remains in communication with the urogenital sinus, and receives the ureters from the developing kidneys. The lower part of the pedicle undergoes a gradual dilatation to form the *urinary bladder*, while at the connection of this part with the urogenital sinus a constriction occurs in the part which gives rise to the urethra. This in the female opens at once into the original urogenital sinus, but in the male the passage is continued onwards through the penis by the median union of the parts below that organ.

The part of the allantois situated above or in front of the bladder within the abdomen remains very much narrowed as the *urachus*, a tapering process of the upper extremity of the bladder into which at first the internal cavity is prolonged, but which later consists only of the muscular and fibrous coats. This process may for a time be traced for a short distance within the umbilical cord, but at an early period all vestiges of its farther prolongation disappear.

**Genital Cord.**—In both sexes, as was first fully shown by Tiersch and Leuckart in 1852, the two Wolffian ducts become united by surrounding substances into one cord behind the lower part of the urinary bladder; but retaining internally their separate passages until they reach the sinus urogenitalis. With this cord the Müllerian ducts are incorporated posteriorly, so that at one time there are four passages through the whole of the genital cord. The Müllerian ducts next coalesce into one at some little distance from their lower ends, and this fusion, progressing upwards and downwards for a considerable space, a

single median cavity is produced which lies between the still separate canals of the Wolffian ducts. A large accumulation of tissue in its walls gives to the genital cord great thickness as compared with the neighbour-

Fig. 608.

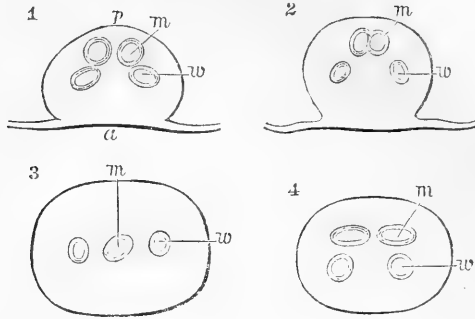


Fig. 608.—TRANSVERSE SECTIONS OF THE GENITAL CORD IN A FEMALE CALF EMBRYO. MAGNIFIED 14 DIAMETERS (from Kölliker).

1, near the upper end ; 2 and 3, near the middle ; 4, at the lower end ;  $\alpha$ , anterior,  $p$ , posterior aspect ;  $m$ , Müllerian ducts, united or separate ;  $w$ , Wolffian ducts.

ing parts of the ducts where they emerge from its enclosure. The lower part of the united Müllerian ducts thus comes afterwards to form the foundation of the vagina and lower part of the uterus in the female, and the corresponding prostatic vesicle with its occasional accompaniments, or the uterus masculinus of the male.

REPRODUCTIVE ORGANS.

In the farther history of the development of the genital organs it will be expedient to consider them in the two sexes in succession under

Fig. 609.

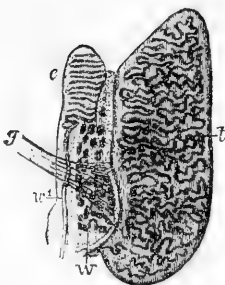


Fig. 609.—INTERNAL GENITAL ORGANS OF A MALE HUMAN EMBRYO OF  $3\frac{1}{2}$  INCHES LONG (from Waldeyer).

$t$ , body of the testicle with seminal canals formed ;  $c$ , epididymis, or upper part of Wolffian body ;  $w$ , Wolffian body, lower part, becoming paradidymis or organ of Giraldès ;  $w'$ , Wolffian duct, becoming vas deferens ;  $g$ , gubernaculum.

the three heads of 1st, the productive organs ; 2nd, the conducting passages ; and 3rd, the external organs.

**Reproductive Glands.**—It has already been explained that although the male and female productive organs take their origin from a mass of blastema which is on the whole identical in the two sexes, yet there are such differences in the development of

the essential parts of the respective structures of the ovary and testicle as almost to warrant the conclusion that these organs are from the first in some measure distinct.

The distinction of sex begins to be perceptible in the internal organs of the human embryo in the seventh week, and becomes more apparent in the eighth. The reproductive gland is from the first connected with the Wolffian body, of which its blastema seems to be actually a part ; and it remains attached to it, or after its disappearance to the structure which occupies its place, by a fold of the peritoneal membrane, constituting the mesorchium or mesovarium. Upper and lower bands fix the Wolffian body ; the upper passing to the diaphragm may be named the diaphragmatic ; the lower running down towards the groin from the Wolffian duct, contains muscular fibres and constitutes the future gubernaculum testis and round ligament of the uterus.

**The Testicle.**—In male embryos at the tenth week already seminal canals are visible, being at first, according to Kölliker, entirely composed of cells, but by the eleventh and twelfth weeks the tubes have become somewhat smaller, longer, and are now branched and possess a membrana propria. There is also by the end of the third month a commencement of lobular division, and the body of the testis is now covered with a condensed layer of fibrous tissue which forms the tunica albuginea.

In connection with the development of the spermatic filaments or spermatozoa, the essential part of the male reproductive element, previously referred to at p. 448 of this volume, it may here further be stated that renewed researches by Neumann (*Archiv für Microsc. Anat.*, vol. xi., p. 292), appear to show that the doubts thrown by Sertoli and Merckel on the statements of V. Ebner are not well founded, that there really exist within the seminal ducts protoplasmic columns stretching from within the wall of the tube into its cavity, and that the spermatic filaments are produced in connection with the inner ends of the columns as branched lobes, amounting in general to ten or twelve in number, in which the heads lie outwards imbedded in the protoplasmic stalk, and the filaments or tails are directed inwards towards the central lumen of the tube. Each stalk, or *spermatoblast*, as Neumann proposes to name it, possesses a large clear nucleus with nucleolus, and previous to the formation of the heads there are nuclei corresponding in number to them, which do not, however, appear to arise directly from division of the main nucleus of the stalk, but rather to be formed as free nuclei in the protoplasm. Each spermatozoon consists of three parts, which are most easily distinguished in those which have not reached their stage of full development. These parts are, 1st, the head, or, as it may from its form in some animals be called, the hook ; 2nd, the body or middle part, forming a slight thickening, and frequently of a vesicular appearance ; and 3rd, the filament or tail. The first of these proceeds more immediately from a nucleus, the second is the remains of the protoplasmic covering of a spermatoblastic lobe, the third is a ciliated production from the last. The bases of the spermatoblasts are attached to the inner surface of the fibrous coat of the seminal canals, to which they furnish a complete lining, being set closely upon it like a layer of hexagonal plates. The stalks rise as tapering processes from these plates, and in the intervals between the stalks, necessarily largest towards the periphery, there is a number of opaque granular spherical cells, the exact nature of which is not ascertained, but which it is conjectured may be the source of new spermatoblasts.

An interesting view is presented by Neumann of the analogy of these spermatoblasts of the seminal tubes with the much elongated ciliated cells which are found in the canals of the *coni vasculosi* and tube of the epididymis, in accordance with which it may be held that the spermatic filaments are a peculiar form of ciliary structure, developed from protoplasmic elements of a cellular nature, but which undergo a peculiar modification in connection with the special destination of the spermatozoa.

**The Ovary.**—Considered as a glandular organ the ovary differs from other glands by the absence from it of excretory ducts, and by the

Fig. 610.

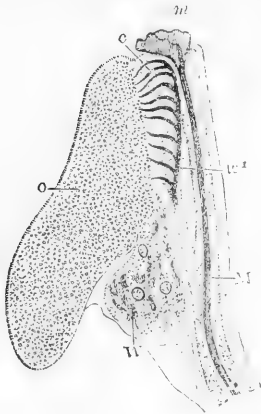


Fig. 610.—INTERNAL ORGANS OF A FEMALE HUMAN FŒTUS OF  $3\frac{1}{2}$  INCHES LONG. MAGNIFIED (from Waldeyer).

*o*, the ovary full of primordial ova; *c*, tubes of the upper part of the Wolffian body forming the epooophoron (parovarium of Kobelt); *W*, the lower part of the Wolffian body forming the parooophoron of His and Waldeyer; *W'*, the Wolffian duct; *M*, the Müllerian duct; *m*, its upper fimbriated opening.

separation of its conducting passages from the glandular or productive part of its structure. Like the testicle it begins to manifest its peculiar characteristics by the seventh or eighth week, when the germ-epithelium has attained considerable thickness, and forms a decided prominence on the mesial side of the Wolffian body. The farther de-

velopment of the glandular part of the organ consists mainly in the formation of ovigerms and ova, and the implantation of these in Graafian follicles by a peculiar combination or intermixture of the superficial germinal cells with the deeper blastema which forms the stroma of the organ.

In a former part of this volume, under Ovary, p. 478, the development of the primordial ova from a certain number of the cells of the germ-epithelium and their enclosure in Graafian follicles by the growing stroma of the ovary have been described according to the most recent observations of Waldeyer, Kölliker and J. Foulis. The publication of the very careful researches of the last observer enables us to add some important details to the previous description.

Figure 611, copied from some of Foulis's plates (Trans. Roy. Soc., Edin., 1875) will best show what from these observations appears to be the most probable view of the mode of development of ova in the human ovary. At *e*, fig. 611, B, is seen a portion of the germ-epithelium, and at *e'*, one of the cells undergoing enlargement and conversion into an ovigerms or primordial ovum. Of this the outer protoplasm becomes the yolk, and the nucleus the germinal vesicle with its nucleolus or macula. At *o*, a single ovigerms, and at *o'*, clusters of ovigerms in various stages of development have sunk into the ovarian stroma, and are being surrounded collectively and individually by the growth of the connective tissue of the ovarian stroma advancing from below. Some of the ovigerms in the clusters are more advanced than the rest, and in these, as also in the isolated ovigerms represented in C, a covering of altered connective tissue corpuscles is seen to be forming round the yolk protoplasm. This is the origin of the cells of the tunica granulosa, which Foulis has shown are not produced, as Waldeyer believed, from germ-epithelial cells, but from the interstitial connective tissue of the deeper ovarian stroma. In A, *o, o*, the cell fibres of the stroma (*n, n*) are seen surrounding several individual ova, so as to furnish the first elements of the wall of the Graafian follicles enveloping the ova, and covering immediately the granular cells. In D, representing an ovum somewhat farther advanced, the enlarged yolk-protoplasm and the germinal vesicle are shown entire, with a fragment of the granular cell covering and fibro-cellular wall of the Graafian follicle; but the zona pellucida is not yet perceptible.

The further steps in the formation of the ovum, as ascertained by the observations of Foulis, consist mainly in the enlargement of the mass of yolk protoplasm, the formation of a certain quantity of albuminous and fatty granules in combination with it (deutoplasm of Edw. van Beneden); and the formation externally of the zona pellucida or yolk-membrane by a consolidation of the outer

Fig 611.

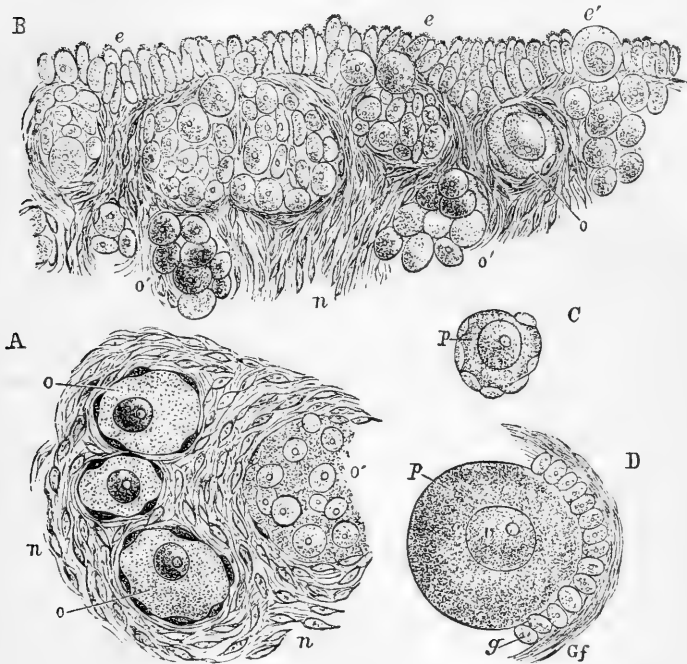


Fig. 611.—VIEWS OF THE FORMATION OF OVA AND GRAAFIAN FOLLICLES IN THE OVARY (from Foulis).

A, small portion of the ovary of a human fetus of  $3\frac{1}{2}$  months, showing primordial ova imbedded in the stroma; *o*, larger primordial ova; *o'* cluster of earlier ova; *n*, fusiform corpuscles of the stroma. B, portion of the ovary near the surface in a human fetus of  $7\frac{1}{2}$  months, showing the manner of inclusion of the germ epithelium corpuscles in groups in the ovarian stroma; *e*, germ epithelium; *e'*, one of the cells enlarging into a primordial ovum before sinking into the stroma; *o*, a larger cell imbedded, becoming an ovum; *o'*, groups of ovigerms or germ cells which have been surrounded by the stroma. C, young ovum from the same ovary, isolated; *p*, yolk protoplasm. D, ovum more advanced, enclosed in condensed stroma, which begins to form a Graafian follicle; *p*, yolk protoplasm; *v*, germinal vesicle with macula; *g*, the fusiform corpuscles now converted into the granular cells; *Gf*, condensed stroma forming the wall of the Graafian follicle.

layer of the yolk substance. And here it may be remarked that the recent observations of Oellacher and Balfour on the radiated structure of the yolk protoplasm may explain in some degree, or be connected with the linear radiated marking-of the zona pellucida.

Such is the number of ova formed in the manner now described, that in the human fetus of six to seven months the whole substance appears to consist of them and their newly formed Graafian follicles, by which

each primordial ovum is closely embraced. A uniform layer of such ova of nearly equal size is especially to be found towards the surface ; but in the two later months of foetal life some of the ova and follicles advance to a farther stage of development, and increase in size, and this advance is invariably accompanied by a change of position of these ova to a deeper stratum of the ovary. The most advanced of the ova, therefore, are situated deepest in this the earlier stages of the ovarian development. It is different, however, when some years after birth, and still more towards the age of puberty, a few of the Graafian follicles expand to a great extent, and ultimately when mature reach the diameter of about a quarter of an inch, for then the expanding Graafian follicle gradually approaches the surface of the ovary, or perhaps rather, during the rapid expansion of the follicle, the ovarian stroma gives way by absorption between the follicle and the surface.

As the Graafian follicle expands with the slightly enlarging ovum, the thickness of the layers of condensed connective tissue or stroma round the ovum increases, and thus there are gradually formed the layers which have been described as the follicular walls, while blood-vessels penetrate into them so as to form the vascular network of the covering. Within the follicle the granular cells multiply so as to form several layers lining the whole follicle and closely covering the ovum. As yet there is no space between the ovum and wall of the follicle except that which is occupied by the granular cells, and for a long time the follicle is not larger than to enable it to enclose the ovum ; but in the more advanced stages a proportionally great enlargement of the follicle takes place, in consequence of the separation of two layers of the granular cells, so as to form a space in which fluid accumulates, and thus one or more layers of cells are left lining the expanded follicle and constituting its tunica granulosa, while those covering the ovum, which is now thrown to one side of the follicle, form the investment known as the discus proligerus, which appears as a reflected portion of the tunica granulosa (see figs. 335 and 336, pp. 473 and 475).

As connected with the difference in the seat and mode of development of the essential parts of the male and female productive organs, the important question presents itself of the possibility or reality of the simultaneous coexistence in any cases of malformation of ovaries and testes on one or both sides of the body in the same individual. From what has been stated above, the possibility of such coexistence may perhaps be theoretically admitted. On this subject the reader may consult an interesting account by Dr. C. L. Heppner of St. Petersburg (Reichert's and Dubois Reymond's Archiv for 1870, p. 679), of a hermaphroditic child which lived two months after birth, in which, along with a considerable amount of the better known conditions of approximation or mingling of the sexual characters, it appeared that two organs coexisted, in one of which, agreeing in all respects with the ovary, primordial ova in Graafian follicles were observed, and in another of a distinctly rounded form and compact structure, and so far corresponding to the testicle and unlike any of the other known vestigial organs, branched and coiled tubes, filled with cells in a manner exactly the same as those of the seminal canals, were ascertained by microscopic observation to exist. The parovarium (epididymis or coni vasculosi) also existed.

**The genital passages.**—The existence of two sets of tubes between the internal productive organs and the external parts has already been adverted to as a feature common to both sexes. The female organs contrast with the male in the large development of one of these tubes, viz.,

the Müllerian ducts into their passages, and in the abortive disappearance of the greater part of the Wolffian ducts; while in the male the ducts of Müller suffer in a great measure the abortive retrogradation, and the seminal conducting tubes are produced out of canals formed within special parts of the Wolffian body and the whole of the Wolffian duct. But as in all embryos of whatever sex both sets of tubes are originally present, while a different one of the original tubes becomes developed into the respective permanent conducting passages, vestiges of the other original tubes are invariably present in various degrees in both sexes.

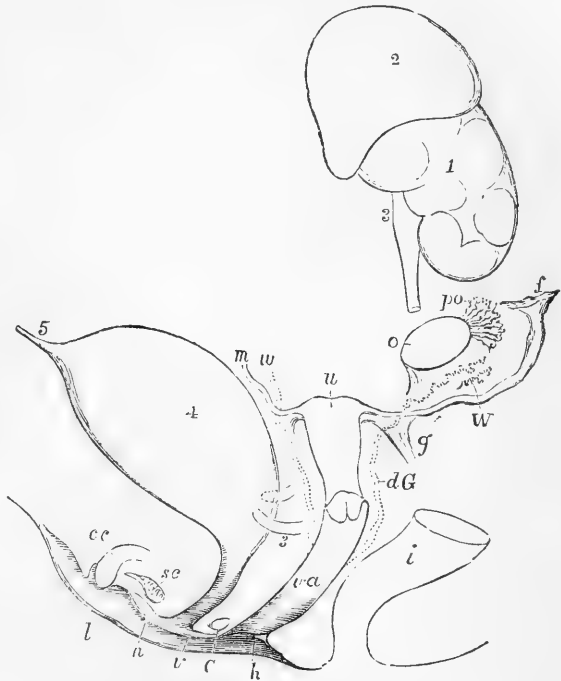
**The Female passages.**—In the female, the vagina, uterus, and Fallopian tubes are formed out of the Müllerian ducts. That portion of the ducts in which they become fused together is developed into the vagina, the cervix, and part of the body of the uterus; and the pecu-

Fig. 612. — DIAGRAM OF THE FEMALE TYPE OF SEXUAL ORGANS.

This and figure 615 represent diagrammatically a state of the parts not actually visible at one time; but they are intended to illustrate the general type in the two sexes, and more particularly the relation of the two conducting tubes to the development of one as the natural passage in either sex, and to the natural occurrence of vestiges of the other tube, as well as to the persistence of the whole or parts of both tubes in occasional instances of hermaphroditic nature.

1, the left kidney; 2, suprarenal body; 3, ureter, of which a part is removed to show the parts passing within it; 4, urinary bladder; 5, urachus; *o*, the left ovary nearly in the place of its original formation; *po*, parovarium, epoophoron of Waldeyer; *W*, scattered remains of Wolffian tubes near it, paroophoron of Waldeyer; *dG*, remains of the left Wolffian duct, such as give rise to the duct of Gaertner, represented by dotted lines; that of the right side cut short is marked *w*; *f*, the abdominal opening of the left Fallopian tube; *u*, the upper part of the body of the uterus, presenting a slight appearance of division into cornua; the Fallopian tube of the right side cut short is marked *m*; *g*, round ligament, corresponding to gubernaculum; *i*, lower part of the intestine; *va*, vagina; *h*, situation of the hymen; *C*, gland of Bartholin (Cowper's gland), and immediately above it the urethra; *cc*, corpus cavernosum clitoridis; *sc*, vascular bulb or corpus spongiosum; *n*, nymphæ; *l*, labium; *v*, vulva.

Fig. 612.



liarity of the mode of fusion accounts for the occurrence, as a rare anomaly, not only of double uterus, but of duplicity of the vagina, coincident with communication between two lateral halves of the uterus. The next following part of the Müllerian duct, constitutes in animals with horned uteri, the cornu of the uterus; but in the human subject it remains comparatively short, entering into the formation of the upper part of the organ. The remaining upper portion of the Müllerian duct constitutes the Fallopian tube—becoming at first open and subsequently fringed at a short distance from its upper extremity.

The pediculated hydatid of the fimbriated extremity (Hydatid of Morgagni) appears to be the remains of the original upper end of the Müllerian tube. The additional or accessory fimbriæ and openings referred to at p. 471, and by Henle in his *Handbuch*, vol. ii., p. 470, may admit of explanation on the supposition of the duct of Müller having remained open at these places.

In the human embryo of the third month the uterus is two-horned, and it is by a subsequent median fusion and consolidation that the triangular body of the entire organ is produced. The cornua uteri, therefore, of the human uterus correspond with the separate cornua of the divided uterus in animals, and this explains the occasional malformation consisting in the greater or less division of the uterine cavity and vagina into two passages. There is no distinction in the

Fig. 613.

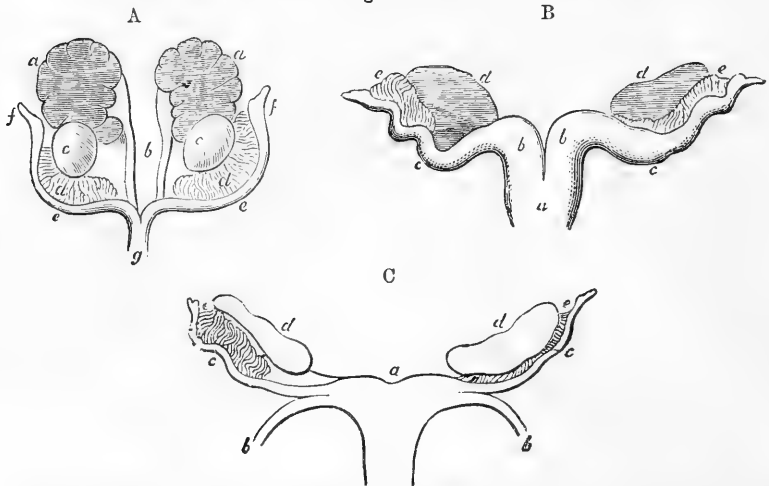


Fig. 613.—FEMALE GENITAL ORGANS OF THE EMBRYO WITH THE REMAINS OF THE WOLFFIAN BODIES (after J. Müller).

A, from a foetal sheep; *a*, the kidneys; *b*, the ureters; *c*, the ovaries; *d*, remains of Wolffian bodies; *e*, Fallopian tubes; *f*, their abdominal openings; *g*, their union in the body of the uterus. B, more advanced from a foetal deer; *a*, body of the uterus; *b*, cornua; *c*, tubes; *d*, ovaries; *e*, remains of Wolffian bodies. C, still more advanced from the human foetus of three months; *a*, the body of the uterus; *b*, the round ligament; *c*, the Fallopian tubes; *d*, the ovaries; *e*, remains of the Wolffian bodies.

human foetus in the third and fourth month between the vagina and uterus. In the fifth and sixth months the os uteri begins to be formed, and the neck is subsequently gradually distinguished. Thickening succeeds in the walls of the uterine portion; but this takes place first in the cervix, which up to the time of birth is much larger and thicker than the body of the uterus (Kölliker).

In the meantime the Wolffian bodies undergo a partial atrophy, and their ducts



become more or less obliterated and abortive in different parts. The most constant vestige of the Wolffian bodies in the female is the now well-known body of Rosenmüller or Parovarium of Kobelt (Rosenmüller, *Quædam de Ovarii Embry. Human., Lipsiæ. 1802*; Kobelt, *der Nebeneierstock des Weibes. Heidelberg, 1847*), which has already been described at p. 480 of this volume, the *epoophoron* of Waldeyer, and which, being produced out of the same elements as the epididymis of the male, presents a remarkable resemblance to that body. The canal uniting the radiating tubes (coni vasculosi) of this organ is also usually persistent, but ceases at a short distance below. In the sow and several ruminants, however, the subdivided upper tubular part or epoophoron has disappeared, and the main tube (middle part of the Wolffian duct) remains in the *duct of Gaertner*, a strong, slightly undulated tube, which is traceable, first free in the broad ligament

Fig. 614.

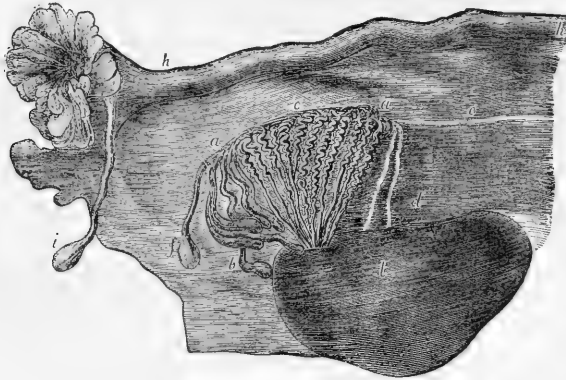


Fig. 614.—ADULT OVARY, PAROVARIIUM AND FALLOPIAN TUBE (from Farre, after Kobelt).

*a, a*, Epoophoron (parovarium) formed from the upper part of the Wolffian body; *b*, remains of the uppermost tubes sometimes forming hydatids; *c*, middle set of tubes; *d*, some lower atrophied tubes; *e*, atrophied remains of the Wolffian duct; *f*, the terminal bulb or hydatid; *h*, the Fallopian tube, originally the duct of Müller; *i*, hydatid attached to the extremity; *l*, the ovary.

of the uterus, and lower down becoming incorporated with the wall of the uterus and vagina, upon which last it is lost.

**The Male Passages.**—The conversion of the Wolffian duct into the vas deferens of the testicle was first demonstrated in animals by Rathke, in correction of the views of J. Müller (*Meckel's Archiv, 1832*), and was further proved and illustrated by H. Meckel and Bidder (*H. Meckel, Zur Morphol. der Harn und Geschlechts-Organen der Wirbelthiere, Halle, 1848*; Bidder, *Male Organs in the Amphibia, Dorpat, 1846*). Kölliker showed that a similar process occurs in the human embryo, and that a communication established between the seminal tubes of the testicle (*rete testis*) and some of the upper tubes of the Wolffian body gave rise to the epididymis.

The observations of Cleland and Banks first pointed out clearly the difference between the structure of the upper nonglomerular, or simply tubular part of the Wolffian body, and that of the lower and glomerular, or primordial-kidney part.

In the male, the Müllerian ducts are destined to undergo little development and are of no physiological importance, while the ducts of the Wolffian bodies, and probably also some part of their glandular substance, form the principal part of the excretory apparatus of the testicle. The united portion of the Müllerian ducts remains as the vesicula prostatica, which accordingly not only corresponds with the uterus, as was shown by Weber, but likewise, as pointed out by Leuckart, contains as much of the vagina as is represented in the male. In some animals the vesicula prostatica is prolonged into cornua and tubes; but in the human subject the whole of the ununited parts of the Müllerian ducts disappear, excepting, as suggested by Kobelt, their upper extremities, which seem to be the source of the hydatids of Morgagni. The excretory duct of the Wolffian body, from the base of that body to its orifice, is converted into vas deferens and ejaculatory duct, the vesicula seminalis being formed as a diverticulum from its lower part (Waldeyer).

With respect to the formation of the epididymis, it appears certain that the larger convoluted seminal tube, which forms the body and globus minor of the epididymis, arises by a change or adaptation of that part of the Wolffian duct which runs along the outer side of the organ. The vas aberrans or vasa aber-

Fig. 615.

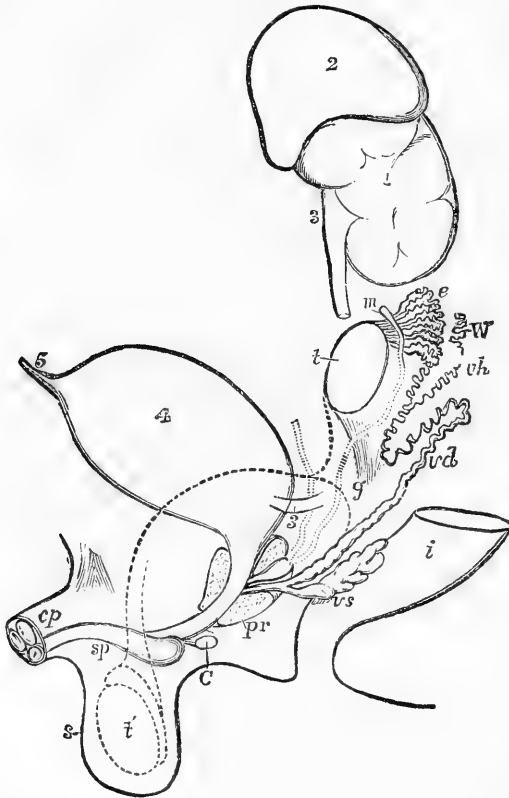


Fig. 615.—DIAGRAM OF THE MALE TYPE OF SEXUAL ORGANS.

1, 2, 3, 4, and 5, as in figure 612; *t*, testicle in the place of its original formation; *e*, caput epididymis; *v d*, vas deferens; *W*, scattered remains of the Wolffian body, constituting the organ of Giraldès, or the paradidymis of Waldeyer; *v h*, vas aberrans; *m*, Müllerian duct, the upper part of which remains as the hydatid of Morgagni, the lower part, represented by a dotted line descending to the prostatic vesicle, constitutes the cornu and tube of the uterus masculinus; *g*, the gubernaculum; *v s*, the vesicula seminalis; *p r*, the prostate gland; *C*, Cowper's gland of one side; *c p*, corpora cavernosa penis cut short; *s p*, corpus spongiosum urethrae; *s*, scrotum; *t*, together with the dotted lines above, indicates the direction in which the testicle and epididymis change place in their descent from the abdomen into the scrotum.

rantia of Haller appear to be the remains also, in a more highly convoluted form, of one or more of the tubes of the Wolffian body still adhering to the excretory duct of the organ, and their communication with the main tube of the epi-

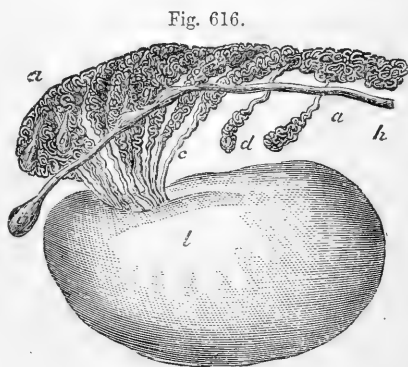
dymis receives an explanation from that circumstance. As to the *coni vasculosi* in the upper part of the epididymis, it has been customary to regard them as produced by a transformation of the tubes and duct in the upper part of the Wolffian body, according to the views most fully given by Kobelt; but, according to the more recent observations of Banks, the origin of the *coni vasculosi* is most probably due to a process of development occurring in a new structure or mass of blastema which had been previously observed by Cleland, and which is formed in connection with the upper end of the Wolffian body, and close to the Müllerian duct. Within this blastema Cleland showed that the tubes of the efferent seminal vessels and the *coni vasculosi*, together with the tube which connects them, are formed anew, while the tubes of the lower primordial-kidney part of the Wolffian body are undergoing an atrophic degeneration. This has been confirmed by the detailed observations of Banks, who has further shown the continuity of their uniting tube with the Wolffian excretory duct.

According to this view, the *caput epididymis* must be regarded, not simply as a conversion of the upper part of the Wolffian body, but rather as a new formation, or superinduced development of tubes in blastema connected with it.

The *coni vasculosi*, so formed, become connected with the body of the testicle by means of a short straight cord, which is afterwards subdivided into the *vasa efferentia*. The peritoneal elevation descending from the testis towards the lower extremity of the Wolffian body, is the upper part of the *plica gubernatrix*, and becomes shortened as the testicle descends to meet the lower end of the epididymis; the peritoneal elevation which passes down into the scrotum, and is continuous with the other, is the more important part of the *plica gubernatrix*, connected with the *gubernaculum testis*. The spermatic artery is originally a branch of one of those which go to the Wolffian body, and ascend from the surface of the Wolffian body to the upper part of the testis, along the ligaments connecting them; but, as the testis descends, the artery lies entirely above it, and the secreting substance of the Wolffian body remains adherent to it; and hence it is that the organ of Giraldès, which consists of persistent Wolffian tubules, is found in a position superior to the epididymis. (For a fuller account of this subject the reader is referred to Banks "On the Wolffian Bodies," Edin 1864.)

Fig. 616.—VIEW FROM BEFORE OF THE ADULT TESTIS AND EPIDIDY- MIS (from Farre, after Kobelt).

*a, a*, convoluted tubes in the head of the epididymis developed from the upper part of the Wolffian body; *b* and *f*, hydatids in the head of the epididymis; *c*, *coni vasculosi*; *d*, *vasa aberrantia*; *h*, remains of the duct of Müller with *i*, the hydatid of Morgagni at its upper end; *l*, body of the testis.



#### The Descent of the Testicles.

—The testicles, which are originally situated in the abdominal cavity, pass down into the scrotum before birth. The testicle enters the internal inguinal ring in the seventh month of foetal life: by the end of the eighth month it has usually descended into the scrotum, and, a little time before birth, the narrow neck of the peritoneal pouch, by which it previously communicated with the general peritoneal cavity, becomes closed, and the process of peritoneum, now entirely shut off from the abdominal cavity, remains as an independent serous sac. The peritoneal pouch, or *processus vaginalis*, which passes down into the scrotum, precedes the testis by some time in its descent, and into its posterior part there projects a considerable columnar elevation

already alluded to, which is filled with soft tissue, and is termed *plica gubernatrix*. There is likewise a fibrous structure attached inferiorly to the lower part of the scrotum, and surrounding the peritoneal pouch above, which may be distinguished as the *gubernacular cord*, both this and the *plica gubernatrix* being included in the general term *gubernaculum testis* (J. Hunter). The gubernacular cord consists of fibres which pass downwards from the sub-peritoneal fascia, others which pass upwards from the superficial fascia and integument, and others again which pass both upwards and downwards from the internal oblique muscle and the aponeurosis of the external oblique; it exhibits, therefore, a fusion of the layers of the abdominal wall. Superiorly, it surrounds the processus vaginalis, without penetrating the *plica gubernatrix*; and the processus vaginalis, as it grows, pushes its way down through the gubernacular cord and disperses its fibres. By the time that the testis enters the internal abdominal ring, the processus vaginalis has reached a considerable way into the scrotum; and, as the testis follows, the *plica gubernatrix* becomes shorter, till it at last disappears; but it cannot be said that the shortening of the *plica* is the cause of the descent of the testicle, and much less that (as has been held by some) the muscular fibres of the gubernacular cord are the agents which effect this change of position. The arched fibres of the cremaster muscle make their appearance on the surface of the processus vaginalis as it descends, while its other fibres are those which descend in the gubernacular cord. (See, for a further account of this process, and the various views which have been held with regard to the descent of the testicles, Cleland, "Mechanism of the Gubernaculum Testis." Edinburgh, 1856.)

**The External Organs.**—In the human embryo, as in that of animals, the external organs are up to a certain time entirely of the same form in both sexes; and the several organs which afterwards distinguish the male and female externally take their origin respectively from common masses of blastema of precisely similar structure and connections. The common cloaca exists till after the fifth week, and the genital eminence from which the clitoris or penis is formed makes its appearance in the course of the fifth and sixth weeks in front of and within the common orifice. In the course of the seventh and eighth weeks the common orifice is seen to become divided into two parts, viz., the longer slit of the genito-urinary aperture anteriorly, and the narrower and more rounded anal aperture posteriorly: but the exact manner in which the separation of these two apertures takes place has not yet been accurately traced. It is intimately connected with the formation of the urogenital cord as an independent structure, and is probably mainly effected by the advance from the sides and posteriorly of septal bands which separate the lower part of the intestine. Somewhat later, or in the ninth and tenth weeks, a transverse integumental band completes the division between the anal and the urogenital orifices, which band forms the whole of the so-called perineum of the female, and the part of the perineal integument in the male which is situated behind the scrotum; the raphé being most obvious in the male sex.

The cutaneous folds, or circular genital ridge, which are afterwards converted into mons Veneris, labia majora, and scrotum, as well as the lips of the urogenital furrow, which are converted into the nymphæ of the female and unite as integument below the penis in the male, are both of early formation and at first precisely the same in all embryos. In this condition, which continues until the eleventh or twelfth week, the parts appear alike in both sexes, and resemble very much the more advanced female organs. The rudiments of *Bartholin's* or *Cowper's glands* are, it is said, seen at an early period, near the root of the rudimentary clitoris or penis, on each side of the genito-urinary passage.

In the female, the two lateral cutaneous folds enlarge, so as to cover the clitoris and form the *labia majora*. The clitoris itself remains relatively smaller, and the groove on its under surface less and less marked, owing to the opening out, and subsequent extension backwards, of its margins to form the *nymphæ*. The vascular bulbs remain distinct and separate, except at one point where they run together in the glans clitoridis. The *hymen* begins to appear about the fifth month as a fold of the lining membrane at the opening of the genital passage.

into the urogenital sinus. Within the vestibule, which is the shortened but widened remains of the urogenital sinus, the urethral orifice is seen, the urethra itself undergoing considerable elongation.

In the male, on the contrary, the *penis* continues to enlarge, and the margins of the groove along its under surface gradually unite from the primitive urethral orifice behind, as far forwards as the glans, so as to complete the long canal of the male *urethra*, which is therefore a prolongation of the urogenital sinus. This is accomplished about the fifteenth week. When this union remains incomplete, the abnormal condition named *hypospadias* is produced. In the meantime the *prepuce* is formed, and, moreover, the lateral cutaneous folds also unite from behind forwards, along the middle line or *raphé*, and thus complete the *scrotum*, into which the testicles descend in the course of the eighth month of foetal life.

The corpora cavernosa, which are at first separate, become united in their distal portions in both sexes; but the corpus spongiosum urethrae which is also originally divided in all embryos, and in the female remains so in the greater part of its extent, becomes enlarged in the male in the glans penis, and its two parts united mesially both above and below the urethra, so as to enclose the whole of that tube from the bulb forwards to the glans.

#### TYPE OF DEVELOPMENT AND ABNORMAL FORMS OF THE GENITAL ORGANS.

The type of development of the genital organs may be stated to differ in the several parts of the system in the two sexes as follows, viz. :—

- 1st. It is single and homological in the external organs.
- 2nd. It is double and heterological in the middle organs or passages.
- 3rd. It is partially double and heterological in the productive organs.

Accordingly the congenital malformations of the reproductive organs admit of being distributed under the following divisions :—

1st. Abnormal forms attributable to deficient, redundant, or abnormal modes of development of one or more of the external organs in either sex, producing an approach to the form of the other sex.

2nd. Forms referrible to deficient, redundant, or abnormal modes of development of one or other of the two sets of sexual passages, viz., of the Wolffian or Müllerian ducts, so as to lead to the greater or less predominance of sexual characters in a part or the whole of these passages inconsistent with those prevailing in other parts of the system, or to the coexistence of both sets of passages in whole or in part.

3rd. Extremely rare forms referrible to the possible coexistence of the productive parts of testicles and ovaries in the same individual, usually combined with more or less of the foregoing kinds of malformation.

Upon the subject of these malformations the reader may consult the learned and able article *Hermaphroditism* by Sir James Y. Simpson in the *Cyclop. of Anat. and Physiol.*

Upon the subject of malformations in general the following works are recommended, viz. :—

Isid. Geoff. St. Hilaire, *Hist. Gén. et Partic. des Anomalies de l'Organisation*, &c., 3 tom. Paris, 1832—6; Cruveilhier, *Anat. Pathol.*, &c., Paris, 1830—42. Otto, *Sexcentorum Monstrorum desc. Anat.* Vratisl., 1841; Th. L. W. Bischoff, *Ueber Missbildungen*, &c., in R. Wagner's *Handwörterbuch der Physiol.*, 1843; Wm. Vrolik, *Tab. ad illustr. Embryol. Hom. et Mammal. tam Natur. quam Abnormem*, Amstel., 1849, and the article "*Teratology*" by the same author in *Todd's Cyclop. of Anat. and Physiol.*; Aug. Förster, *Die Missbildungen des Menschen*, &c., Jena, 1861; as also the systematic works of Rokitsanski and others on *Pathological Anatomy*.

The following tabular scheme of the CORRESPONDING PARTS of the genito-urinary organs in the two sexes, and of their relation to the FORMATIVE RUDIMENTS of the common embryonic type, may be useful in

fixing attention on the more important points of the foregoing description, and indicating more clearly the homologies of the parts:—

| FEMALE PERMANENT.                                                           | COMMON EMBRYONAL.                              | MALE PERMANENT.                                                                                 |
|-----------------------------------------------------------------------------|------------------------------------------------|-------------------------------------------------------------------------------------------------|
| <b>I.—COMMON BLASTEMA OF REPRODUCTIVE GLANDS.</b>                           |                                                |                                                                                                 |
| <b>Ovary.</b><br>Furnishes the <b>ovigerms</b> and remains on the surface.  | 1. Germ-epithelium covering ..                 | <b>Body of Testicle.</b><br>Disappears, and is replaced by serous covering of tunica vaginalis. |
| Forms <b>stroma</b> of the ovary and the Graafian follicles.                | 2. Deeper blastema .....                       | Forms glandular <b>seminal tubes</b> of the testis.                                             |
| <b>II.—WOLFFIAN BODIES.</b>                                                 |                                                |                                                                                                 |
| Transverse tubes of <b>epoophoron</b> or organ of Rosenmüller (Parovarium). | 1. Upper tubular non-glomerular part.          | <b>Vasa efferentia</b> and conivasculosi of the epididymis.                                     |
| <b>Paroophoron</b> (Wald.) .....                                            | 2. Lower glomerular part (primordial kidneys). | <b>Paradidymis</b> (Wald.), organ of Giralde's, and vasa aberrantia.                            |
| <b>Round ligament of the uterus</b> ..                                      | 3. Ligament of the Wolffian body.              | <b>Gubernaculum testis.</b>                                                                     |
| <b>III.—WOLFFIAN DUCTS.</b>                                                 |                                                |                                                                                                 |
| Tube of the Epoophoron .....                                                | 1. Upper and middle parts ....                 | Convolutcd tube of the <b>epididymis</b> .                                                      |
| <b>Ducts of Gaertner</b> , in cow and pig                                   | 2. Lower part .....                            | <b>Vas deferens</b> and vesiculæ seminales.                                                     |
| <b>IV.—MULLERIAN DUCTS.</b>                                                 |                                                |                                                                                                 |
| <b>Fimbriated abdominal opening</b> and terminal and occasional hydatis     | 1. Upper extremity .....                       | <b>Hydatid of Morgagni.</b>                                                                     |
| <b>Fallopian tubes</b> .....                                                | 2. Middle part .....                           | Occasional tubular prolongations of uterus masculinus.                                          |
| <b>Vagina and uterus</b> .....                                              | 3. Lower single or median part                 | <b>Uterus masculinus</b> (vesicula prostatica).                                                 |
| <b>V.—GENITAL CORD AND SINUS UROGENITALIS.</b>                              |                                                |                                                                                                 |
| Tissue uniting female urethra and vagina.                                   | 1. Substance surrounding genital cord.         | <b>Prostate gland.</b> Muscular and glandular tissue.                                           |
| <b>Female urethra</b> .....                                                 | 2. Upper part of cavity or urinary pedicle.    | Upper part of <b>prostatic portion</b> of the <b>urethra</b> .                                  |
| <b>Ostium vaginæ. Hymen</b> .....                                           | 3. Confluence of urinary and genital parts.    | <b>Verumontanum.</b>                                                                            |
| <b>Vestibule</b> .....                                                      | 4. Lower part .....                            | Lower part of <b>prostatic portion</b> and membranous part of <b>urethra</b> .                  |
| <b>Glands of Bartholin</b> .....                                            | 5. Common blastema .....                       | <b>Cowper's Glands.</b>                                                                         |
| <b>VI.—EXTERNAL ORGANS.</b>                                                 |                                                |                                                                                                 |
| I.—Vascular parts.                                                          |                                                |                                                                                                 |
| <b>Crura and corpus clitoridis</b> .....                                    | a. Corpora cavernosa .....                     | <b>Crura and corpus penis.</b>                                                                  |
| <b>Glans clitoridis and vascular bulbs</b> (separate)                       | b. Corpora spongiosa .....                     | <b>Glans penis</b> and spongy body of urethra (united).                                         |
| 2. Integumental parts.                                                      |                                                |                                                                                                 |
| <b>Preputium clitoridis</b> .....                                           | a. On genital eminence .....                   | <b>Preputium penis.</b>                                                                         |
| <b>Integumental folds of nymphæ</b> (separate).                             | b. Lips of genital furrow .....                | <b>Integument and raphé</b> below penis.                                                        |
| <b>Labia majora</b> (separate) .....                                        | c. Genital ridges (lateral) .....              | <b>Scrotum and raphé</b> (united).                                                              |
| <b>Perineum of female</b> , with raphé ..                                   | d. Transverse interanogenital band.            | <b>Perineum</b> of male behind scrotum, with raphé.                                             |

## INDEX TO VOLUME II.



- ABDOMEN** (*abdo*, I hide) regions and viscera of, 346  
**Absorbents**, 37, 183. *See* LYMPHATICS.  
**Acerculus** (dim. of *accrucus*, a heap) cerebri, 549  
**Acid-albumin**, 30  
**Acids**, organic, in muscle, 122  
     in nerve-tissue, 160  
**Adenoid** (*ἄδην*, a gland; *εἶδος*, form) tissue, 69  
**Adipose** (*adeps*, fat) tissue, 59. *See* FAT.  
**Adventitia capillaris**, 178  
**Agminated glands** (*agmen*, a troop), 210, 365  
**Air-cells**, 275. *See* LUNGS.  
**Air-tubes**, 274  
**Ala vespertilionis**, 467  
**Albinos**, pigment wanting in, 52  
**Albumen**, 3  
     of blood, 30  
**Albuminoid substances**, 30  
**Alimentary canal**, 300  
     abdominal portion of, 346  
     development of, 698, 774  
**Alkali-albumin**, 30  
**Allantois** (*ἄλλᾶς*, gen. *ἄλλᾶντος*, a sausage), 704  
     vascular layer of, 709  
**Alveoli** (*alveolus*, a small hollow vessel) of glands, 236  
     lungs, 275, 276  
     lymphatic glands, 193  
     mucous membrane, 209  
     salivary, 339  
     of stomach, 353  
**Amnion** (*ἄμνιον*), 703  
**Amœboid** (*amœba*; *εἶδος*, form) movements in cells, 12  
**Ampullæ** (*ampulla*, a flask or bottle) of semicircular canals, 642, 646  
     of Fallopian tube, 471  
     mammary gland, 487  
     vas deferens, 450  
**Amygdalæ** (*amygdala*, an almond), 335  
     of cerebellum, 518  
**Anastomosis** (*ανά*, through; *στόμα*, a mouth), 165, 172  
**Anatomy**, general, 1  
     special, of the viscera, 239  
**Anfractuosities** (*anfractus*, a winding), 523  
**Annulus ovalis** (oval ring), 244  
**Antihelix** (*ἀντί*, opposite; *heliæ*), 628  
**Antitragus** (*ἀντί*, opposite; *tragus*), 627  
**Antrum pylori**, 349  
**Anus**, 379  
     development of, 778  
**Aorta** (probably allied to *ἀρτάω*, I suspend, and *ἀορτήρ*, a belt or strap to hang anything to, from its apparently suspending the heart), development of, 791  
     orifice of, 251, 255  
**Aortic arches**, 793  
     valve, 251  
**Apertura scalæ vestibuli**, 641  
**Aponeurosis** (*ἀπό*, from; *νεῦρον*, a string or tendon), 63  
**Appendices epiploicæ**, 371  
**Appendix cæci vermiformis**, 374  
     vesicæ, 425  
**Aqueduct** (*aqueductus*, an aqueduct) of cochlea, 644  
     of Sylvius, 552  
     of vestibule, 641  
**Aqueous humour**, 626  
**Arachnoid** (*ἀράχνη*, a spider or spider's web; *εἶδος*, shape) membrane, 519  
     peculiarity of, 197  
**Arbor vitæ** (from resemblance of the shrub so-called) of cerebellum, 519  
     uterinus, 464  
**AREOLAR TISSUE**, 53  
     composition and properties of, 58  
     development of, 70  
     fibres of, 54  
     regeneration of, 69  
     structure of, 56  
     vessels and nerves of, 58  
**Arteria centralis retinæ**, 618  
     thyroidea ima, 297  
**ARTERIES**, general anatomy of, 165  
     anastomoses of, 165  
     coats of, 167  
     contractility of, 171  
     development of, 791  
     distribution of, 164  
     epithelium of, 167

- ARTERIES—continued.**  
 muscular tissue of, 169  
 nerves of, 170  
 physical properties of, 166  
 sheath of, 166  
 small, 178  
 structure of, 166  
 tortuosity of, 165  
 vessels of, 170
- ARTERIES OR ARTERY, auditory, in-**  
 ternal, 662  
 bronchial, 278  
 ciliary, 603, 604  
 deferent, 453  
 hepatic, 384, 388, 390  
 pulmonary, development of, 795  
   distribution of, 278  
   orifice of, 247, 255  
   portion at root of lung, 273  
 renal, 410  
 spermatic, 453  
 splenic, 399. *See also the various organs and tissues for arteries belonging to them.*
- Arytenoid (*ἀρύταινα*, a pitcher or ladle; *ἔδος*, shape) cartilages, 280, 282
- Aryteno-epiglottidean folds, 285
- Assimilating property, 5
- Atrium (a court before a house) of auricles of heart, 244, 248  
 of vagina, 812
- Auditory canal, external, 630  
 hairs, 650  
 nerve. *See NERVE, AUDITORY.*  
 pit and vesicle, 740, 768
- Auricle (*auricula*, the outer ear) of ear, 626
- Auricles of heart. *See HEART.*
- Auriculo-ventricular. *See HEART.*
- Azotised (*azote*, nitrogen) substances, 3
- BARTHOLIN'S glands, 458**
- Basement membrane of glands, 232, 234, 236  
 of mucous membrane, 206  
 of skin, 214
- Basilar membrane, 652, 655
- Basis in cerebral peduncle, 555
- Bicuspid (*bis*, twice; *cuspis*, the point of a weapon) teeth, 302, 303
- Bile-duct, common, 385  
 ducts, aberrant, 394  
   commencement of, 391  
   structure of, 393
- Bladder, gall. *See Gall-Bladder.*
- BLADDER, urinary, 419**  
 coats of, 423  
 development of, 814  
 female, peculiarities of, 420, 422  
 ligaments of, 420, 421, 422  
 sacculated and fasciculated, 425  
 structure of, 423  
 urethral orifice of, 423  
 vessels and nerves of, 426
- Blastide (*βλαστός*, a germ), 679
- Blastoderm (*βλαστός*, a germ; *δέρμα* skin), 675, 680, 681  
 discovery of elements of, 685  
 layers of, 683  
 of mammals, 688  
 relation to development, 683  
 vesicular, 682
- BLOOD, 18**  
 arterial and venous, 33  
 chemical composition of, 23, 32  
 coagulation of, 34  
 colouring principles of, 25  
 corpuscles. *See CORPUSCLES.*  
 hepatic, 34  
 liquor or plasma of, 24, 28  
 occasional constituents of, 23  
 physical and organic constitution of, 18  
 portal, 34  
 renal, 34  
 splenic, 400
- BLOOD-VESSELS, General Anatomy, 163**  
 development of, 180, 784  
*See the several organs and tissues, for blood-vessels belonging to them.*
- BONE, General Anatomy of, 79**  
 chemical composition of, 80  
 compact and cancellated, 81, 82  
 formation and growth of, 94  
 lymphatics of, 93  
 marrow of, 91  
 nerves of, 93  
 periosteum of, 91  
 physical properties of, 80  
 regeneration of, 107  
 structure of, 81  
 vessels of, 92
- Bone-earth phosphates, 8
- Bones, cartilaginous or membranous, origin of, 745
- Bones of ear, 635  
 development of, 740
- Brachia (arms) in cerebrum, 551
- BRAIN. See CEREBRUM AND ENCEPHALON.**  
 development of, 750
- Branchial (*βράγχια*, gills) arches, 793
- Breast. *See MAMMARY GLAND.*
- Bronchi (*βρόγχος*, the windpipe), 265  
 development of, 783  
 position at root of lungs, 273  
 structure of, 268  
 vessels and nerves of, 278
- Bronchia (*βρόγχος*, the windpipe), 274
- Bruch, membrane of, 601
- Brunner's glands, 363
- Buccal (*bucca*, the mouth), glands of, 301
- Buffy coat of blood, 24, 35
- Bulb, arterial, 787  
 division of, 789
- Bulbi vestibuli, 459
- CADAVERIC rigidity, 125**
- Cæcum (*i.e.*, *intestinum cæcum*, the blind gut), 374



- Cæcum**—*continued*.  
 development of, 778
- Calamus scriptorius** (a writing pen), 506
- Calcar avis** (a bird's spur), 542
- Calcification of teeth**, 323
- Calices** (*calix, κάλιξ*) of kidney, 404
- Canal of cochlea**, 652  
 spiral, 643  
 of epididymis, 449  
 of Huguier, 632  
 of Nuck, 443, 467  
 of Petit, 621  
 of Recklinghausen, 594  
 of Schlemm, 595  
 of Wirsung, 396
- Canaliculi in bone**, 85  
 in cement of teeth, 312
- Canalis auricularis**, 787  
 centralis modioli, 644  
 membranaceus, 645, 652  
 reuniens, 646, 653  
 spiralis modioli, 644, 662
- Cancelli** (lattice-work) of bone, 82
- Canine teeth**, 302, 303, 306
- Canthi** (*κάνθος*, the corner of the eye), 583
- Capillaries, biliary**, 392
- Capillary** (*capillus*, a hair) blood-vessels, 163, 175  
 development of, 180  
 structure of, 177  
 lymphatics, 184
- Capsulæ atrabiliarie**, 413
- Capsule of Glisson**, 386
- Capsulo-pupillary membrane**, 764, 767
- Caput cæcum coli**, 374  
 cornu posterioris, 496, 509  
 gallinaginis (woodcock's head), 438
- Carbonic acid in blood**, 25
- Carnin** (*caro*, flesh), 122
- CARTILAGE** (*cartilago*, gristle), General  
 Anatomy of, 72  
 articular, 72  
 chemical composition of, 75  
 costal, 75  
 elastic, 78  
 hyaline, 72  
 development of, 76  
 ossified at end of bones, 90  
 temporary, 72  
 varieties of, 72  
 yellow, 78
- Cartilagine alarum nasi**, 666  
 laterales nasi, 665  
 minores vel sesamoideæ, 666
- Cartilago triticea** (wheat-shaped cartilage), 284
- Caruncula** (dim. from *caro*, flesh) lachrymalis, 583
- Carunculæ myrtiformes**, 458
- Casein** (*caseus*, cheese), 3  
 formation from albumen, 30
- Cauda equina** (horse's tail), 490  
 development of, 750
- Cavernous tissue**, 180
- CELLS, animal**, 8  
 changes in, 11  
 endogenous formation of, 14  
 function of, in growth of textures, 15  
 migratory, 12  
 movements of, 12  
 multiplication of, 13  
 production of, 9  
 in relation to each other, 14  
 vegetable, 7  
*See also various Organs and Tissues.*
- Cellular tissue**, 53. *See AREOLAR TISSUE.*
- Cement of teeth**, 307, 312  
 development of, 320
- Centrum ovale**, 537
- CEREBELLUM** (dim. of *cerebrum*, the brain), 515  
 arteries of, 576  
 development of, 753, 756  
 fissures of, 516  
 folia of, 516  
 grey matter of, 520  
 hemispheres of, 525  
 internal structure of, 518  
 lobes of, 517. *See Lobes.*  
 middle crus of, 511  
 minute structure of, 520  
 peduncles of, 516, 552  
 development of, 757  
 position of, 502  
 weight of, 581
- Cerebrin** (*cerebrum*, the brain), 159
- CEREBRO-SPINAL axis or centre, General**  
 Anatomy of, 125  
 development of, 691, 695, 746  
 Special Anatomy of, 489  
 fluid, 575  
 nerves. *See NERVES.*
- CEREBRUM** (the brain), 522  
 arteries of, 576  
 base of, 533  
 convolutions of, 523. *See Convolutions.*  
 commissures of, 537  
 development of, 750  
 exterior of, 522  
 fibres of, peduncular, 554  
 transverse or commissural, 556  
 longitudinal or collateral, 556  
 Foville's views on, 557  
 fissures of, 523, 544. *See Fissures.*  
 grey matter of, 558  
 hemispheres of, 522  
 internal parts of, 537  
 internal structure of, 553  
 lobes of, 523. *See Lobes.*  
 measurements of, 580, 581  
 peduncles or crura of, 533, 563  
 development of, 757  
 ventricles of, 539, 543, 546  
 weight of, 577  
 white matter of, 553
- Cerumen** (*cera*, wax), 631
- Cheeks**, 300

- Chemical composition of human body, 3  
of tissues. *See* the several tissues
- Chiasma (χιάσμα, I mark with the letter X; crossing or decussation), 536
- Choanæ narium, 342
- Cholesterine (χολή, bile; στέαρ, fat), in red corpuscles of blood, 25  
in nerve-tissue, 160
- Cholin, 159
- Chondrin (χόνδρος, cartilage), 3, 75.
- Chorda dorsalis, 692
- Chordæ tendineæ, 247, 251
- Chorion (χόριον, the investing membrane of the fœtus), 706  
origin of, 708
- Choroid (χόριον, the chorion or investing membrane of the fœtus; εἶδος, shape) plexuses, 545  
of fourth ventricle, 513  
of lateral ventricles, 541  
of third ventricle, 546  
coat of eye, 598  
development of, 767
- Choroidal fold or fissure, 763
- Chyle (χῆλος, juice), 37  
coagulation of, 39  
constitution of, 39  
corpuscles, formation of, 40
- Cicatricula, 674
- Cilia (cilium, an eyelash), eyelashes, 585  
vibratile, 46
- Ciliary motion, 48  
cause of, 50  
processes, 601
- Cineritious (cinis, ashes) substance of nervous system, 126, 553
- Circulation of blood, 163  
changes in, at birth, 803  
fœtal, 799  
in the placenta, 719
- Circulus articuli vasculosus, 75, 203  
major and minor, 603  
venosus of nipple, 488
- Clastrum (that which shuts off), 549, 564
- Clitoris (κλείτορις, perhaps from κλείω, I enclose), 456  
development of, 811, 824  
erector muscles of, 457  
vessels and nerves of, 459
- Cloacal (cloaca, a sewer) aperture, 699, 778
- Coagulation (coagulum, a clot). *See* BLOOD, CHYLE, AND LYMPH.
- Cochlea (κόχλος, a shell-fish with a spiral shell), 643  
development of, 772  
membranous, 651  
nerves of, 662  
vessels of, 662
- Collar of crus, 552
- Colliculus bulbi urethræ, 435  
nervi optici, 607  
seminalis, 438
- Colloid (κόλλα, glue; εἶδος, shape) substances, 4
- Colon (κῶλον, originally limb, the great gut), 376  
development of, 778  
position of, 348, 376
- Columella cochleæ, 644
- Column, posterior vesicular, 499
- Columnæ Bertini, 404  
carneæ (fleshy columns), 247, 250  
recti, 379  
rugarum, 460
- Comes (a companion; pl. *comites*), 172
- Commissure (*com*, together; *mitto*, I send) cerebral, anterior, 546, 556  
great, 537  
middle or grey, 546, 563  
posterior, 546, 556  
optic, 536  
of spinal cord, 493, 496, 500
- Conarium (*conus*, the fruit of the fir), 549
- Concha (κόγχη, a shell), 626
- Conglobate (*con*, together; *globus*, a ball) glands, 191, 210
- Conglomerate (*con*, together; *glomerum*, I gather in a round heap) glands, 236
- Coni vasculosi, 449  
development of, 823
- Conjunctiva, 583, 585
- Connective tissue, 52  
cells and cell-spaces of, 57  
relation of lymphatics to, 186  
development of, 70  
homogeneous, 70  
jelly-like, 68  
retiform, 69  
in brain and spinal cord, 136
- Contractility, vital, 5. *See* also the various tissues.
- Conus arteriosus, 246, 247  
medullaris, 491
- Convulsions (*con*, together; *volvo*, I roll) of cerebrum, 523  
angular, 529  
of corpus callosum, 532  
development of, 759  
frontal, 526, 527  
hippocampal, 532  
of island of Reil, 525, 530  
marginal, 532  
occipital, 524  
occipito-temporal, 532  
orbital, 527  
parietal, 528  
straight, 537  
supramarginal, 528  
temporo-sphenoidal, 530  
uncinate, 532
- Corium (skin), 213  
blood-vessels and lymphatics of, 216  
chemical composition of, 217  
development of, 217

- Corium**—*continued*.  
 nerves of, 216  
 structure of, 213  
 of mucous membrane, 206
- Cornea** (*corneus*, horny), 592  
 development of, 767  
 opaca, 589  
 nerves and vessels of, 597
- Cornicula laryngis**, 280, 282
- Cornu Ammonis**, 541
- Corona glandis**, 430  
 radiata, 555
- Corpora albicantia**, 535  
 development of, 760
- Corpora Arantii**, 252
- Corpora cavernosa clitoridis**, 457  
 penis, 430, 431
- Corpora geniculata**, 551
- Corpora mammillaria**, 535
- Corpora quadrigemina**, 551  
 development of, 756  
 grey matter of, 563
- Corpora striata**, 541, 557  
 development of, 750  
 grey matter of, 563
- Corpus callosum**, 523, 537  
 development of, 760  
 peduncles of, 536, 538
- Corpus ciliare**, 504
- Corpus dentatum of cerebellum**, 519, 522  
 of olivary body, 504
- Corpus fimbriatum**, 542, 544
- Corpus Highmorianum**, 446
- Corpus luteum**, 474
- Corpus spongiosum urethræ**, 430, 435
- Corpuscles of blood**, red, 19  
 chemical composition of, 25  
 formation of, 40, 42  
 proportion of, in blood, 27  
 shape and size of, 19  
 structure of, 20  
 pale, 23  
 of chyle, 39  
 formation of, 40  
 concentric, of Hassall, 298  
 of connective tissue, 57  
 corneal, 594  
 of lymph, 38  
 formation of, 40  
 osseous, 84  
 of thymus gland, 298
- Corpuscula tactus**, 148
- Corti**, organ of, 657
- Cowper's glands**, 440  
 development of, 824, 826
- Cranium**, development of, 732
- Crassamentum** (*crassus*, thick) of blood, 19
- Creatin and creatinin** (*κρέας*, flesh), 31  
 in muscle, 122  
 in nerve-tissue, 160
- Cremasteric** (*κρεμάω*, I suspend) layer of scrotum, 442
- Crico-arytenoid joints**, 284  
 ligaments, 285
- Crico-arytenoid**—*continued*.  
 muscles, 289
- Cricoid** (*κρίκος*, a ring; *ἔδος*, shape) cartilage, 280, 281
- Crico-thyroid joints**, 284  
 membrane, 284
- Crista acustica**, 647, 649  
 urethræ, 438  
 vestibuli, 641
- Crotchet**, 532
- Cruorin**, 25
- Crura cerebelli**, 516  
 cerebri, 533  
 grey matter of, 563  
 of clitoris, 457  
 of fornix, 543, 544  
 of penis, 431
- Crusta of cerebral peduncle**, 555, 556, 557
- Crusta petrosa**, 307, 312  
 formation of, 320
- Crypt** (*κρύπτω*, I conceal), 234  
 multilocular, 234
- Crypts of Lieberkühn**, 209, 363, 373
- Cryptorchismus** (*κρύπτω*, I conceal; *ἄρχις*, a testicle), 443
- Crystalloid substances**, 4
- Cumulus**, 476
- Cuneiform** (*cuneus*, a wedge; *forma*, shape) cartilage, 283
- Cupola**, 643
- Cuspidate** (*cuspis*, the point of a weapon) teeth, 303
- Cuticle** (dim. *cutis*, the skin), 42, 211  
 development of, 213  
 nutritive changes in, 16  
 of enamel, 312
- Cutis vera** (true skin), 213. *See* Corium and SKIN.
- Cystic** (*κύστις*, a bladder) duct, 385, 394
- Cytogenous** (*κύτος*, a cell; *γεννάω*, I produce) connective tissue, 69
- DARTOS** (*δάρτος*; the skin of scrotum; *δέρω*, I flay), 441  
 fibres of, 119
- Decidua** (*deciduus*, falling off; *i.e.*, *membrana*) cavity of, 715  
 formation of, 711  
 incapsulation of ovum in, 710  
 penetration by villi, 717  
 placentalis, 717  
 reflexa, serotina, and vera, 715
- Decussation** (*decusso*, I cut cross-wise) of pyramids, 504
- Dens sapientiæ** (wisdom tooth), 305
- Dental arches**, 301  
 grooves, 313, 315  
 pulp, 307, 317  
 sacs, 316, 321  
 sheath, 309  
*See also* TEETH.
- Dentine** (*dens*, a tooth), 307  
 development of, 318  
 of repair, 325  
 secondary, 324

- Derma (*δέρμα*, skin), 213  
 Descemet's membrane, 595  
 Development of the fœtus and its organs, 673  
     of the several organs and tissues.  
     *See* under these.  
 Dialysis (*διά*, apart; *λύω*, I loosen), 4  
 Diencephalon (*διά*, between; *ἐγκέφαλον*, the brain), 755  
 Digestion, organs of, 300  
 Diploe (*διπλός*, double), 81  
 Discus proligerus (*proles*, progeny; *gero*, I bear), 476  
 Disdiaclasses (*δῖς*, twice; *διακλάω*, I break), 14  
 Diverticulum (from *diverto*, I turn aside)  
     of ileum, 371  
 Duct, or ducts, of Bartholin, 339  
     of Bellini, 406  
     biliary. *See* Bile-Ducts.  
     of Cuvier, 242, 796  
     of Gärtner, 821  
     of glands in general, 237  
     of Rivinus, 338  
     *See* also the various glands, &c.,  
     for their ducts.  
 Ductus ad nasum, 588  
     arteriosus, 795, 800  
     closure of, 803  
     cochlearis, 652  
     communis choledochus, 385  
     venosus, 796  
     fissure or fossa of, 382  
     vitello-intestinalis, 699  
 Duodenum (*duodeni*, twelve; from being  
     twelve finger-breadths in length),  
     357, 369  
     position of, 347  
 Dura mater, 569  
     relation to cerebro-spinal nerves,  
     145  
 Duverney, glands of, 458  
  
 EAR, anatomy of, 626  
     development of, 733, 740, 768  
     external, 626  
     internal, 641. | *See* LABYRINTH.  
     middle, 631. *See* TYMPANUM.  
 Ear-wax, 744  
 Ectoderm (*ἐκτός*, without; *δέρμα*, skin),  
     683  
 Ejaculatory ducts, 453  
 Elastic tissue, 66  
     in arteries, 168, 169, 179  
     in lymphatics, 186  
     in veins, 173  
 Electricity, manifestation of by muscles,  
     123  
 Elementary organisms, 8, *note*  
 Elements, structural, of human body, 2  
 Embryo, axial rudiment of, 691  
     development of, 689, *et seq.*  
     inflections of walls of, 694  
 Embryo-cells, formation of, 9  
  
 Embryology (*ἐμβρυον*, an embryo; *λόγος*,  
     discourse), 673  
 Eminentia collateralis, 542  
     papillaris, 634  
     pyramidalis, 641  
     teres, 511  
 Emotion, a stimulus of muscular action,  
     124  
 Enamel germ, 313  
     membrane, 320  
     organ, 320  
     of teeth, 307, 311  
     formation of, 319  
 Encephalic vesicles, 695, 750  
 ENCEPHALON (*ἐν*, in; *κεφαλή*, the head),  
     502  
     development of, 750  
     size and weight of, 577  
     *See* CEREBRUM, CEREBELLUM,  
     MEDULLA, and PONS.  
 End-bulbs of nerves, 147, 216  
 Endocardium (*ἐνδον*, within; *καρδία*, the  
     heart), 261  
 Endochorion (*ἐνδον*, within; *χόριον*, the  
     investing membrane of the petus),  
     709  
 Endoderm (*ἐνδον*, within; *δέρμα*, skin), 683  
 Endogenous (*ἐνδον*, within; *γεννάω*, I pro-  
     duce) formation of cells, 14  
 Endolymph (*ἐνδον*, within; *λυμφία*,  
     water), 645  
 Endolymphangial nodules, 198  
 Endosteum (*ἐνδον*, within; *ὀστέον*, bone), 91  
 Endothelium (*ἐνδον*, within; *θηλή*, pa-  
     pilla), 43, *note*  
 End-plates, motorial, 154  
 Epencephalon (*ἐπί*, on; *ἐγκέφαλον*, the  
     brain), 755  
 Ependyma (*ἐπί*, on; *ἐνδύμα*, clothing)  
     ventriculorum, 540  
 Epiblast (*ἐπί*, on; *βλαστός*, a germ), 683,  
     684  
 Epidermis (*ἐπί*, on; *δέρμα*, the skin), 42,  
     211  
 Epididymis (*ἐπί*, on; *δίδυμος*, a testicle),  
     445  
     canal of, 449  
     development of, 821, 822  
     relation to Wolffian body, 826  
 Epigastric (*ἐπί*, on; *γαστήρ*, the stomach)  
     region, 347  
 Epiglottis (*ἐπί*, on; *glottis*), 283  
     tubercle or cushion of, 286  
 Epiotic (*ἐπί*, on; *ὄψ*, gen. *ὠπός*, the ear)  
     centre of temporal bone, 733  
 Epithelioid (*epithelium*; *εἶδος*, form) cells,  
     43, *note*  
 EPITHELIUM (*ἐπί*, on; *θηλή*, papilla), 42  
     ciliated, 45, 46  
     columnar, 44  
     cylinder, 44  
     nerve-filaments in, 43  
     nutrition of, 16  
     pavement, 44  
     scaly, 44

- EPITHELIUM—*continued*.  
   spheroidal, 44  
   tessellated, 44  
   transitional, 44  
   of organs. *See* the various organs.
- Epoochoron (ἐπί, on; ὠόν, an egg; φορέω, I bear) relation to Wolffian body, 481, 821
- Erectile tissue, general characters of, 180
- Ergot (Fr. a spur), 542
- Eustachian tube, 634  
   development of, 772  
   valve, 245, 246  
   development of, 789, 800
- Excretion, 231
- EYE, anatomy of, 583  
   appendages of, 583  
   development of, 762  
   globe of, 588
- Eyelashes, 585
- Eyelids, 583  
   development of, 768
- Eye-teeth, 303
- FACE, development of, 738
- Facial plates or arches, 738
- Falciform (*falx*, a sickle or scythe; *forma*, shape) ligament of liver, 383
- Fallopian tubes, 470  
   development of, 819
- False membrane, 200
- Falx cerebelli, 571  
   cerebri, 523, 571
- Fascia (a band), 63  
   cremasteric, 442  
   dentata, 544  
   infundibuliform, 442  
   intercolumnar, 442  
   propria, 442  
   spermatie, 442  
   transversalis, 442
- Fasciæ, structure and use of, 63
- Fasciculi graciles (slender fascicles), 505, 509  
   teretes (round fascicles), 506, 509
- Fasciculus, olivary, 505, 509  
   uncinatus (hook-shaped fascicle), 557
- Fasciola cinerea, 545
- FAT, 59  
   absorption of by intestinal villi, 362  
   chemical composition of, 60  
   deposition of in cells, 11  
   development of, 62  
   distribution of, 59  
   in muscular tissue, 122  
   uses of, 61
- Fatty matters, 3
- Fatty compounds in blood, 31
- Fauces (the throat), 300
- Fecundation of the ovum, 675
- Fenestra (a window or opening) ovalis, 633  
   rotunda, 633
- Fenestrated or perforated membrane, 168
- Fibra primitiva (primitive band), 127
- Fibræ arciformes, 506
- Fibrin (*fibra*, a fibre) of blood, 19  
   action of in coagulation, 35, 36  
   origin of, 28  
   of chyle, 39  
   of lymph, 38
- Fibrinogenous substance or Fibrinogen (*fibrin*; γεννάω, I produce), 29, 31, 36
- Fibrinoplastic substance or fibrinoplastin (*fibrin*; πλάσσω, I form), 29
- Fibro-cartilage, 72, 78
- Fibro-serous membrane, 196
- Fibrous cone, 555
- Fibrous tissue, 63  
   chemical composition of, 65  
   distribution of, 63  
   lymphatics of, 66  
   nerves of, 66  
   physical properties of, 63  
   regeneration of, 66
- Filamentous tissue, 53
- Fillet, 509, 556  
   of corpus callosum, 556
- Filum terminale of spinal cord, 489, 492, 500
- Fimbriæ (fringes) of Fallopian tube, 470
- Fissura palpebrarum, 583
- Fissure or fissures of cerebellum, 517  
   of cerebrum, calcarine, 531  
   calloso-marginal, 531  
   collateral, 532  
   dentate, 532  
   frontal, 527  
   hippocampal, 532  
   intraparietal, 527  
   occipital, 531  
   parieto-occipital, 526, 531  
   of Rolando, 525  
   of Sylvius, 524  
   temporo-sphenoidal, 550  
   of liver, 381, 382  
   of lungs, 270  
   of medulla oblongata, 503  
   ocular, in embryo, 739  
   of Santorini, 628  
   of spinal cord, 492
- Flesh, chemical composition of, 25
- Flexures of colon, 376  
   cranial, in embryo, 733
- Flocculus (dim. of *floccus*, a lock of wool), 518
- Fœtus, development of, 673
- Follicle (*folliculus*, dim. of *follicis*, a bag), 234
- Follicles, teeth, 315
- Follicular glands, 210
- Foramen cæcum of medulla oblongata, 504  
   of tongue, 327  
   commune anterius of brain, 544
- of Monro, 544

- Foramen—*continued*.  
 ovale of heart, 789  
 closure of, 799  
 vestige of, 244, 249  
 of Winslow, 482
- Foramina of Thebesius, 246
- Force, nervous, 6
- Forces, physical, probable relation of vital action to, 5
- Foreskin, 431
- Formic acid, 3  
 in nerve-tissue, 160
- Fornix (an arch or vault), 541, 543  
 bulbs of, 535  
 development of, 760  
 fibres of, 556
- Fornix conjunctivæ, 586
- Fossa of antihelix, 628  
 ductus venosi, 382  
 of gall-bladder, 382  
 of helix, 628  
 innominata, 628  
 navicularis of urethra, 439  
 vulva, 456  
 ovalis of heart, 244  
 scaphoidea (boat-shaped fossa), 628  
 triangularis, 628  
 of vena cava, 382
- Fourchette (a fork), 456
- Fovea anterior of fourth ventricle, 513  
 centralis, 607, 616  
 hemielliptica, 641  
 hemispherica, 641  
 ovalis, 244
- Foville's researches on fibres of cerebrum, 557
- Fræna (pl. of *frænum*, a bridle) of ileo-cæcal valve, 375  
 of lips, 300  
 synovial, 202
- Frænulum (dim. of *frænum*, a bridle)  
 cerebri, 552  
 pudendi, 456
- Frænulum epiglottidis, 327  
 linguæ, 325  
 of prepuce, 430
- Funiculus (dim. of *funis*, a cord) of nerve, 140
- Furrowed band, 518
- GALACTOPHOROUS (*γάλα*, milk; *φορέω*, I carry) ducts, 487
- Gall-bladder, 385  
 development of, 780  
 structure of, 394  
 varieties of, 386
- GANGLIA, General Anatomy of, 125, 136  
 structure of, 136  
 connection of nerve-fibres with, 137  
 on arteries, 171  
 cerebral, anterior, 547  
 posterior, 549
- Ganglion, basal optic, 536  
 of habenula, 531  
 spirale, 662
- Ganglion-cells, 132  
 connection of nerves with, 137
- Ganglion-corpuscles, 132  
 nerves, 126, 157
- Ganglionic layer of retina, 608
- Gastric (*γαστήρ*, the stomach) glands  
 353
- Gastro-colic (*γαστήρ*, the stomach; *κῶλον*, the colon) omentum, 485
- Gastro-phrenic (*γαστήρ*, the stomach; *φρήν*, the diaphragm) ligament, 482
- Gastro-pneumonic (*γαστήρ*, the stomach; *πνεύμων*, the lungs) mucous membrane, 204
- Gastro-splenic (*γαστήρ*, the stomach; *σπλήν*, the spleen) ligament or omentum, 482, 484
- Gelatin, 3, 58  
 from muscle, 122
- Gelatinous nerve-fibres, 131
- Genital cord, 814  
 nerve-corpuscles, 148  
 passages, development of, 818
- Genito-urinary mucous membrane, 204
- Genito-urinary organs, abnormal forms of, 825  
 corresponding embryonal and permanent parts of, 826  
 female, development of, 819  
 male, development of, 815, 821  
 primary formation of, 804  
 type of development of, 826  
*See also* Reproductive Organs and Urinary Organs.
- Genu (a knee) of corpus callosum, 538  
 of optic tract, 552
- Germ-epithelium of ovary, 472, 476, 807
- Germinal matter, 10  
 pole, 674  
 spot, 9, 476, 673  
 vesicle, 9, 476, 673  
 disappearance of, 674
- Giant-cells, 106
- Gingivæ (gums), 301
- Giraldès, organ of, 451, 826
- GLANDS (*glands*, an acorn), Secreting,  
 General Anatomy of, 231  
 acini of, 236  
 ducts of, 237  
 envelope of, 237  
 follicles of, 234  
 formation of, 233  
 forms of, 234  
 lacunæ of, 234  
 lobules of, 235  
 parenchyma of, 237  
 reservoirs of, 237
- Glands, ductless, General Anatomy of, 238
- Glands, lymphatic. *See* LYMPHATIC GLANDS.
- Glandula lacrymalis inferior, 587  
 socia parotidis, 336
- Glandulæ Pacchioni, 575  
 ceruminosæ, 631  
 solitariae of the intestine, 364

- Glans (an acorn) clitoridis, 457  
 penis, 430  
 Glisson's capsule, 386  
 Globin, 26  
 Globulin, 3, 31  
 Globus major and minor of the epididymis, 445  
 Glomerulus (dim. of *glomus*, a clue of thread) of kidney, 409  
 Glosso-epiglottic (γλωσσο-, the tongue; *epiglottis*) folds or frenula, 327  
 Glottis (γλωττις, a tongue), 286  
 Glycogen (γλυκύς, sweet; γεννάω, I produce), 3  
 in liver, 380  
 in muscle, 122  
 Goblet-cells, 211  
 Goitre, 297  
 Graafian follicles, 473, 816  
 Granule layer of cerebellum, 521  
 Granules (*granum*, a grain), in blood, 23  
 in nerve-substance, 135  
 Grey fibres of nerves, 131  
 Gristle, 72  
 Growth, 16  
 Gubernaculum (*guberno*, I steer or guide) testis, 824  
 Gullet, 343  
 Gums, 301  
 Gustatory (*gusto*, I taste) cells, 328  
 Gyri (γυρός, a ring) of brain, 523  
 Gyrus, angular, 529  
 fornicatus (arched convolution), 532, 556
- HEMATIN (αίμα, blood), 27  
 Hæmatoin, 27  
 Hæmin (αίμα, blood), 27  
 Hæmoglobin, 3, 25  
 crystals of, 26  
 Hair, 219  
 chemical nature of, 226  
 cuticle of, 220, 222  
 development of, 224  
 distribution of, 226  
 ending of nerve-fibres in, 225  
 follicles of, 221  
 growth of, 226  
 medulla or pith of, 220  
 muscular fibres of, 223  
 regeneration of, 225  
 root of, 220  
 stem of, 219  
 Hair-cells in ear, 658, 659  
 Halitus (breath) of blood, 34  
 Hamulus (dim. of *hamus*, a hook) of cochlea, 644  
 Haversian canals, 82  
 folds and fringes, 200, 203  
 lamellæ, 84  
 spaces, 84  
 Head, development of, 731  
 HEART, 242  
 action of, 163
- HEART—continued.  
 apex of, 255  
 atria of, 244, 248  
 auricles of, 244  
 capacity of, 263  
 development of, 788  
 fibres of, 256  
 left, 248  
 right, 244  
 septum of, 244  
 position of, 253  
 auriculae or auricular appendages of, 244, 248, 253  
 bone of, 255  
 cavities of, 163, 244  
 development of, 696, 784  
 fibro-cartilage of, 255  
 fibrous rings of, 255  
 tissue of, 255  
 in fœtus, 272  
 furrows of, 243  
 lining membrane of, 261  
 lymphatics of, 260  
 margins or borders of, 243  
 muscular tissue of, 119, 256  
 nerves of, 261  
 orifices of, aortic, 251  
 auriculo-ventricular, left, 248, 250, 255  
 right, 246, 247  
 of coronary and cardiac veins 246  
 positions of, 255  
 of pulmonary artery, 247  
 veins, 248  
 size of, 263  
 of venæ cavæ, 245  
 position of, 242, 253  
 serous coat, external, 240  
 size and weight of, 262  
 structure of, 255  
 valves of, auriculo-ventricular, left, 250  
 right, 247  
 development of, 79  
 mitral or bicuspid, 250  
 sigmoid, or semilunar, left, 251  
 right, 248  
 tricuspid, 247  
 veins of, 246  
 ventricles, capacity of, 263  
 development of, 787  
 fibres of, 257  
 left, 249  
 position of, 255  
 right, 246  
 septum of, 246  
 Helicine (ἑλιξ, a spiral) arteries, 434  
 Helicotrema (ἑλιξ, a spiral; τρήμα, a hole), 643  
 Helix (ἑλιξ, a spiral), 627  
 Hepatic (ἥπαρ, the liver) artery, 384, 388, 390  
 cells, 391  
 duct, 385

- Hepatic—*continued*.  
vein, 384, 388
- Hepato-cystic (*ήπαρ*, the liver; *κύστις*, a bladder) ducts, 386
- Hepato-gastric (*ήπαρ*, the liver; *γαστήρ*, the throat) omentum, 484
- Hilus (or *hilum*, the mark or scar on a bean) of kidney, 403  
of lymphatic glands, 193  
of ovary, 471  
of spleen, 397  
of suprarenal capsules, 414
- Hilus-stroma, 193
- Hippocampus (*ίπποκάμπος*, from *ίππος*, a horse, and *κάμπτω*, I bend, a fish with a coiled tail) major, 541  
minor, 542
- Hippuric (*ίππος*, a horse; *οὔρον*, urine) acid, 3, 31
- Holoblastic (*όλος*, whole; *βλαστός*, a germ) ovum of mammals, 674
- Horny matter, 3
- Hyaline (*υάλος*, glass) cartilage, 72  
coat of hair-follicle, 221
- Hyaloid (*υάλος*, glass; *είδος*, shape) membrane, 620
- Hydatids of Morgagni, 446, 820
- Hymen (*ύμην*, a membrane), 457  
development of, 824
- Hyoid arch in embryo, 740
- Hypoblast (*ύπό*, under; *βλαστός*, a germ), 683, 684  
development of organs from, 774
- Hypochondriac (*ύπό*, under; *χόνδρος*, cartilage) regions, 347, 348
- Hypogastric (*ύπό*, under; *γαστήρ*, the stomach) region, 347
- Hypophysis (*ύπό*, under; *φύω*, I grow) cerebri, 535, 734
- Hypospadias (*ύπό*, under; *σπάω*, I draw out), 825
- Hypoxanthin (*ύπό*, under; *ξανθός*, yellow), 3, 31  
in nerve-tissue, 160
- ILEO-CÆCAL or ileo-colic valve, 375
- Ileum (*είλέω*, I roll), 357, 370. *See* INTESTINE, SMALL.  
diverticula of, 371  
position of, 348
- Iliac region, 347, 348
- Impressio coli on liver, 383  
renalis on liver, 383
- Incisor teeth, 300, 306  
eruption of, 320, 323
- Incisura intertragica, 627
- Incus (an anvil), 636
- Infundibula (funnels) of kidney, 404
- Infundibulum of heart, 246  
lungs, 276
- Inguinal (*ινγυεν*, the groin) canal, 440
- Injection, natural method of, 392
- Inosinic acid, 3, 122
- Inosit, 3
- Inosit—*continued*.  
in muscle, 122  
in nerve-tissue, 160
- Interalveolar lymphatics, 279
- Intercellular substance, 15
- Interpeduncular space, 534
- INTESTINE, large, 371  
areolar or submucous coat of, 372  
development of, 778  
divisions of, 371, 374  
glands of, 373  
length and extent of, 371  
mucous membrane of, 373  
muscular coat of, 371  
position of, 347, 348  
serous coat of, 371  
structure of, 371  
vessels and nerves of, 374
- INTESTINE, small, 357  
areolar or submucous coat of, 358  
development of, 777  
divisions of, 357, 369  
glands of, 363  
length and extent of, 357  
mucous membrane of, 359  
muscular coat of, 358  
movements of, 358  
position of, 347, 348  
serous coat of, 358  
structure of, 358  
vessels and nerves of, 367  
villi of, 360
- Intraembryonic phenomena of development, 691
- Iris (*ίρις*, a rainbow), 601  
muscular tissue of, 602  
pigment of, 603  
pillars of, 595  
structure of, 602  
vessels and nerves of, 603
- Iron in blood, 32
- Irritability, 5  
muscular, 123  
duration after death, 124
- Island of Reil, 525, 530
- Isotropic substance in muscle, 113
- Isthmus of Fallopian tube, 471  
faucium, 300  
of thyroid body, 295  
uteri, 464  
Viussenii, 245
- Ivory of teeth, 307. *See* DENTINE.
- JACOB'S membrane, 608
- Jejunum (*jejunus*, empty), 357, 370  
position of, 348
- Joints, formation of in embryo, 745
- KERATIN (*κέρας*, horn), 3, 213
- KIDNEYS, 402  
blood-vessels of, 410  
connections of, 402  
cortical substance of, 403, 404  
development of, 807, 812



KIDNEYS—*continued.*

- excretory apparatus of, 404
- fibrous coat of, 403
- form of, 402
- horseshoe, 403
- intertubular stroma of, 413
- lymphatics of, 413
- medullary substance of, 403
- nerves of, 413
- papillæ of, 403
- pelvis of, 404
- position of, 402
- primordial, 699, 805
- size and weight of, 402
- structure of, obvious, 403
- tubules of, 405
- varieties of, 403
- Kreatin (*κρέας*, flesh) and Kreatinin. *See*  
Creatin and Creatinin.

## LABIA majora, 456

development of, 824

minora, 457

Labial (labium, the lip) glands, 301

Labyrinth (*λαβύρινθος*, a maze, from its  
complex structure), osseous, 641

development of, 770

membranous, 645

Lachrymal apparatus, 587

development of, 768

canals, 587

gland, 587

sac, 588

LACTEALS (*lac*, milk) General Anatomy  
of, 37

plexuses of, in intestine, 367

relation to villi, 362

Lactic acid, 3

in nerve-tissue, 160

Lacuna magna, 440

Lacunæ in bone, 84

formation of, 103

in crusta petrosa, 312

Lamellæ of bone, 83

structure of, 86

Lamina cinerea (grey layer), 536, 562

cribrosa (a plate perforated like a  
sieve) of sclerotic, 590

elastic, of cornea, 594

fusca, 600

reticular, 658

spiralis ossea, 644

suprachoroidea, 600

Lanugo (wool or down), 225

LARYNX (*λάρυγξ*, the larynx), 280

aperture of, 285

cartilages of, 280

formation and growth of, 294

interior of, 285

ligaments and joints of, 283

mucous membrane of, 293

muscles of, 288

action of, 292

nerves of, 294

LARYNX—*continued.*

pouches of, 287, 288

ventricles or sinuses of, 285, 287,  
288

vessels of, 294

Lecithin, 3, 25

in nerve-tissue, 159

Lemniscus, 556

Lens (a lentil) crystalline, 622

capsule of, 625

changes in by age, 625

development of, 764

Leucin (*λευκός*, white), 3, 32

in nerve-tissue, 160

Leucocytes (*λευκός*, white; *κύτος*, a cell),  
198, 212

Lienculi (little spleens), 398

Life, application of the term, 4

Ligamenta lata, 467

subflava, 67

Ligaments of bones of ear, 637

central or terminal of spinal cord  
489, 492, 500

ciliary, 601

costo-colic, 376

cranio-pharyngeal, 343

hyo-epiglottic, 283

palpebral, 584

peritoneal, 348

pleuro-colic, 376

pubo-prostatic, 428

spiral, 652, 657

suspensory, of crystalline lens, 620  
of penis, 431

thyro-arytenoid, 284

thyro-epiglottic, 283

thyro-hyoid, 283

Ligamentum denticulatum, 575

latum pulmonis, 268

nucha, 67

pectinatum iridis, 595

spirale, 657

suspensorium (of bladder), 423

teres uteri, 467

Ligula, 506

Limbs, development of, 699, 742

Limbus of spiral lamina, 653

luteus of the retina, 606

Line-salts in bone, 80

Linea splendens, 572

Lips, 300

Liquor Cotunnii, 641

Morgagni, 625

sanguinis, 19, 24, 28

Littre, glands of, 459

LIVER, 380

accessory, 386

borders of, 383

changes in, after birth,

coats of, 386

congestion of, 390

development of, 779

ducts of, 385. *See* Bile-ducts.

excretory apparatus of, 384

fissures of, 381, 382

LIVER—*continued*.

- fossæ of, 381, 382
- hæmopoietic (*αἷμα*, blood; *ποιέω*, I make), function of, 41
- ligaments of, 383
- lobes of, 381, 382
- lobules of, 386
- lymphatics of, 393
- nerves of, 384
- position of, 374, 383
- size and weight of, 380
- specific gravity of, 380
- structure of, 386
- surfaces of, 381
- varieties in, 386
- vessels of, 388

## Lobes of cerebellum, 517

- biventral, 518
- central, 517
- quadrate, 517
- slender, 518
- subpeduncular, 518

## of cerebrum, 523

- central, 530
- frontal, 526
- occipital, 529
- parietal, 527
- temporo-sphenoidal, 530

*See also various organs.*

## Lobule of ear, 627

## Lobuli testis, 447

## Lobules of cerebrum, cuneate, 532

- parietal, 528
- quadrate, 532

## Lobulus caudatus, 382

- quadratus, 382
- Spigelii, 382

## Locus cœruleus, 513

- niger, 555, 563
- perforatus anticus, 536
- perforatus posticus, 535

## Luette vesicale (Fr., uvula of the bladder), 423

## Lumbar region, 347, 348

## LUNGS, 269

- capacity of, 271
- changes at birth in, 272
- colour of, 271
- coverings of, 268, 273
- development of, 782
- form of, 269
- lobes of, 270
- lobules of, 274, 276
- lymphatics of, 279
- nerves of, 279
- roots of, 273
- specific gravity of, 272
- structure of, 273
- surfaces and borders of, 269
- texture of, 271
- vessels of, 278

Lunula (dim. *luna*) of nails, 217

- of valves of heart, 252

LYMPH (*lymp̄ha*, water), 37

- chemical composition of, 39

LYMPH—*continued*.

- coagulation of, 38
- corpuscles or globules of, 38
- formation of, 40

## Lymph-channel, 194

## Lymph-sinus, 194

## LYMPHATIC system, General Anatomy of, 183

- glands, 191
  - development of, 782
  - function of, 196
  - structure of, 192

## hearts, 190

## nodules, 198

## vessels, 37, 183

- afferent and efferent, 192
- contractility of, 186
- coats of, 186
- development of, 191
- distribution of, 183
- lacteal. *See* LACTEALS.
- orifices of, 188
- origin of, 183
  - lacunar, 185
  - plexiform, 183
- relation to connective tissue, 186
- structure of, 186
- terminations of, 190
- valves of, 188
- vessels of, 186
- of various organs and tissues.
  - See the organs and tissues.*

Lymphoid (*lymp̄ha*; *εἶδος*, shape) cords, 193

## glands, 210

- in intestine, 365, 373

## tissue, 208, 238

## Lyra, 544

## MACULA germinativa (germinal spot), 476, 673

- lutea (yellow spot), 606, 616

## Malleus (a hammer), 635

## ligaments of, 637

Mammary (*mamma*, the breast) glands, 486

- difference according to sex, 488
- varieties of, 488
- vessels and nerves of, 488

## Mammilla, 486

## Mandibular arch in embryo, 740

## Mantle of hemisphere-vesicle, 759

## Margo acutus and obtusus of heart, 243

## Mastoid cells, 634

## Matrix of cartilage, 72

- formation of, 77
- of cerebrum, 559
- of elastic cartilage, 78
- of fibro-cartilage, 79
- of nails, 218

## Matrix (uterus), 462

## Maxillary bones, formation of, 739

## Meatus auditorius externus, 630

## of nose, 667

## urinary in females, 457, 459

- Meckel's cartilage, 740, 771  
 Mediastinum (*medius*, the middle; *sto*, I stand), 239, 268  
   testis, 446  
 MEDULLA OBLONGATA, 502, 503  
   columns of, 504  
   development of, 753, 755  
   fibres of, longitudinal, 509  
     transverse, 506  
   fissures of, 503  
   grey matter of, 508  
   nerve-nuclei in, 510  
   origin of nerves from, 507  
 Medulla spinalis. *See* SPINAL CORD.  
 Medullary canal of bone, formation of, 103  
   centre of cerebellum, 521  
   sheath of nerve-fibre, 128  
   spaces, 100  
   substance of cerebrum, 553  
     of lymphatic glands, 193  
 Meibomian glands, 585  
 Membrana adamantinæ, 320  
   eboris, 307  
   fusca, 589, 767  
   limitans, 608, 615, 616  
   nictitans, 583  
   preformativa, 319  
   propria of glands, 236  
     of mucous membranes, 206  
     of skin, 214  
   pupillaris, 603  
   tympani, 632  
     secondary, 634  
 Membranes of the brain and spinal cord, 569  
   fetal, 700  
   mucous, serous, &c. *See* MUCOUS and SEROUS MEMBRANES, &c.  
 Meninges (*μήνιγξ*, a membrane), 569  
 Meroblastic (*μέρος*, a part; *βλαστός*, germ) ovum, 674, 677  
 Mesencephalon (*μέσος*, middle; *ἐγκέφαλον*, the brain), 753, 755  
   development of parts connected with, 756  
 Mesentery (*μέσος*, middle; *ἔντερον*, intestine), 348, 370  
 Mesoblast (*μέσος*, middle; *βλαστός*, germ), 683  
   cleavage of, 693  
   parts formed from, 684  
 Mesocæcum (*μέσος*, middle; *cæcum*), 348, 374, 481  
 Mesocephalon (*μέσος*, middle; *κεφαλή*, the head), 511  
 Mesocolon (*μέσος*, middle; *κῶλον*, the colon), 368, 376, 481  
 Mesogastrium (*μέσος*, middle; *γαστήρ*, the stomach), 777  
 Mesorchium (*μέσος*, middle; *ὄρχις*, a testicle), 442, 815  
 Mesorectum (*μέσος*, middle; *rectum*), 348, 378  
 Mesovarium (*μέσος*, middle; *ovarium*), 815  
 Metabolic (*μεταβάλλω*, I change) force, 5  
 Metencephalon (*μετά*, behind; *ἐγκέφαλον*, the brain), 755  
 Methæmoglobin, 26  
 Meynert's description of the brain, 564  
 Milk-teeth, 301, 306  
 Mitral (*μίτρα*, a mitre) valve, 250  
 Modiolus (the nave of a wheel), 643, 644  
 Molar glands, 301  
 Molar (*mola*, a mill) teeth, permanent, 304  
   eruption of, 323  
     temporary, 306, 321  
 Monoplasts (*μόνος*, single; *πλάσσω*, I form), 8  
 Mons Veneris, 456  
 Morsus diaboli (devil's bite), 470  
 Mouth, 300  
   formation of, 734, 774  
 Mucilaginous glands, 201  
 Mucin, 3, 25 *note*, 68, 210  
 MUCOUS MEMBRANE, General Anatomy of, 204  
   attachment of, 205  
   basement membrane of, 206  
   connective tissue of, 207  
   corium of, 206  
   divisions of, 204  
   epithelium of, *See* EPITHELIUM.  
   fibro-vascular layer of, 206  
   folds and valves of, 205  
   glands of, 209, *See* GLANDS.  
   lymphatics of, 207  
   lymphoid tissue of, 208  
   muscular tissue of, 208  
   nerves of, 156, 207, 210  
   papillæ of, 208  
   physical properties of, 205  
   regeneration of, 211  
   secretion of, 210  
   sensibility of, 210  
   structure of, 206  
   vessels of, 207  
   villi of, 209  
 Mucous tissue, 68  
 Mucus, 210  
 Müllerian duct, 807, 808, 819  
   parts formed from, 825  
   fibres in retina, 615  
 Multicuspidate (*multus*, many; *cuspis*, a point) teeth, 305  
 Muscle-rods, 112  
 Muscles, arytenoideus obliquus, 291  
   aryteno-epiglottidean, 291  
   arytenoid, 291  
   ciliaris Riolani, 584  
   ciliary, 601  
   compressor urethræ, 439  
   cremaster, 442  
   crico-arytenoid, lateral, 290  
     posterior, 289  
   crico-thyroid, 289  
   detrusor of bladder, 424  
   dilatator pupillæ, 602  
   erectores clitoridis, 457

Muscles—*continued*.

- kerato-cricoid*, 290  
*laxator tympani*, 638  
*levator glandulae thyroideae*, 296  
 prostatae, 429  
*lingualis*, 331  
*noto-glossus* (*νωτος*, a back; *γλωσσα*, the tongue), 331  
*perpendicularis externus* of tongue, 332  
 of pinna of ear, 629  
*sphincter*. See SPHINCTER.  
*stapedius*, 638  
*tensor tympani*, 638  
*thyro-arytenoid*, 290  
*thyro-epiglottidean*, 292  
 Muscular contractility or irritability, 107, 123  
   duration of, after death, 124  
   current, 123  
   plate in embryo, 730  
   rigidity, 125  
   sense, 123  
 MUSCULAR TISSUE, General Anatomy of, 107  
   involuntary, 118  
     development of, 120  
     of heart, 119  
   voluntary, 108  
     blood-vessels of, 116  
     changes in contraction, 114  
     cleavage into discs, 111  
     corpuscles of, 115  
     cross stripes of, 110  
     development of, 120, 744  
     fasciculi of, 109  
     fibres of, 110  
       length and ending of, 115  
     fibrils of, 111  
     growth of, 120  
     interstitial granules of, 115  
     lacerti of, 108  
     lymphatics of, 117  
     nerves of, 117, 156  
       termination in, 153  
     nuclei of, 115  
     optical appearance of, 112  
     physical properties of, 122  
     sensibility of, 123  
     sheath of, 108  
 Muscularis mucosae, 208, 355, 359, 373  
 Musculi papillares, 247, 250  
   pectinati, 244, 248  
 Myeloplagues (*μυελός*, marrow; *plaques*), 92, 105  
 Myolemma (*μῦς*, a muscle; *λέμμα*, a husk, or rind), 111  
 Myosin (*μῦς*, a muscle), 31  
   in muscular tissue, 122

## NAILS, 217

- development of, 219  
 growth of, 219  
 matrix of, 218  
 reproduction of, 219

NAILS—*continued*.

structure of, 218

- Nares (nostrils), anterior, 664  
 posterior, 665  
 Nasal (*nasus*, the nose), duct, 588  
 Nasmith's membrane, 312  
 Nates (buttocks) in cerebrum, 551  
 Negro, cause of colour in skin of, 51  
 NERVE or NERVES, auditory, arrangement of membranes on, 145  
   cochlear division of, 662  
   origin of, from cerebrum, 568  
     in medulla oblongata, 507, 510  
   vestibular division of, 647  
 CEREBRO-SPINAL, General Anatomy of, 125, 140  
   branching and conjunction of, 141  
   compound or moto-sensory, 160  
   construction of, 140  
   development of, 161  
   differences of, 156  
   fibres of. See NERVE-FIBRES.  
   lymphatics of, 141  
   origins or roots of, 143, 501  
   relation of sympathetic to, 157  
   re-union and regeneration of, 162  
   sheath of, 140  
   simple, 161  
   terminations of, 145  
     in end-bulbs, 147  
     in muscle, 153  
     in networks or terminal plexuses, 146  
     in Pacinian bodies, 149  
     in tactile corpuscles or touch-bodies, 148  
   vaso-motorial, 161  
   vessels of, 141  
 ciliary, 604  
 cranial, development of, 740, 761  
   origins of, in medulla oblongata, 507, 510  
     from cerebrum, 565  
 facial, in embryo, 741  
   origin of, from cerebrum, 568  
     in medulla oblongata, 507, 511  
 fifth, membranes of, 145  
   in embryo, 741  
   origin of, 567  
     of sensory portion of, 514  
 fourth, or trochlear, origin of, 567  
 glosso-pharyngeal, in embryo, 741  
   origin of, from cerebrum, 568  
     in medulla oblongata, 507, 511  
 hypoglossal, origin of, from brain, 569  
   in medulla oblongata, 507, 510

NERVE—*continued.*

- of Lancisi, 537  
 olfactory, membranes of, 145  
   deep connections of, 566  
   distribution of, 671  
   structure of, in cranium, 562  
 optic, membranes of, 145  
   deep connections of, 567  
   distribution in retina, 608  
   origin of, 536  
 pneumogastric or vagus, in embryo,  
   742  
   origin from cerebrum, 569  
   from medulla oblongata,  
     507, 510  
 sixth, origin from cerebrum, 567  
   in medulla oblongata, 507,  
     511  
 spinal, development of, 760  
   origin of, from spinal cord, 501  
 spinal accessory, origin from cere-  
 brum, 569  
   in medulla oblongata, 507,  
     510  
 sympathetic, 156  
   development of, 761  
   relation to cerebro-spinal nerves,  
     157  
   structure of, 157  
 third or oculo-motor, origin of,  
   567  
 Nerve-cells, 132  
   of cerebellum, 520  
   of cerebrum, 559  
   in ganglia, 137  
   connection with fibres, 144  
   development of, 161  
   of spinal cord, 497  
 Nerve-eminence, 154  
 Nerve-fibres, 125  
   afferent or centripetal, 125, 160  
   connection with cells, 144  
   development of, 161  
   efferent or centrifugal, 125, 160  
   grey, non-medullated, or gelatinous,  
     131  
   white or medullated, 126  
     axis-cylinder of, 127, 128  
     course of, 131  
     sheaths of, 128  
     varicose, 130  
     white substance of, 128  
   arrangement and terminations of  
     *See* NERVES, CEREBRO-SPINAL;  
     and NERVOUS SUBSTANCE.  
 NERVOUS SUBSTANCE, structural ele-  
 ments of, 126  
   of cerebellum, 518, 520  
   of cerebrum, 553  
   chemical composition of, 159  
   development of, 161  
   functions of, 125  
   of medulla oblongata, 509  
   of pons Varolii, 511  
   of spinal cord, 494, 497

NERVOUS SUBSTANCE—*continued.*

- of sympathetic, 156  
 vital properties of, 160  
 NERVOUS SYSTEM, General Anatomy of,  
   125  
   Descriptive Anatomy of central  
   organs of, 489  
 Neurilemma (*νεῦρον*, a nerve; *λέμμα*, a  
 peel or skin), 141  
   peculiarities of, 145  
   of spinal cord, 572  
   of sympathetic nerve, 157  
 Neurin (*νεῦρον*, a nerve), 3, 25, 159  
 Neuroglia (*νεῦρον*, a nerve; *γλία*, glue),  
   136, 497, 559  
 Nipple, 486  
 Nitrogen in blood, 25  
 Nitrogenous and non-nitrogenous sub-  
 stances, 3  
 Nodes of Ranvier, 129  
 Nodule (*nodulus*, from *nodus*, a knot)  
   of cerebellum, 518  
 Nodus Arantii, 252  
 Nose, 664  
   cartilages of, 665  
   development of, 739, 772  
   fossæ or cavities of, 667  
   mucous membrane of, 668  
   olfactory region of, 669  
 Notochord (*νῶτος*, the back: *χορδή*, a  
 string), 692, 726  
 Nuclei (*nucleus*, a kernel) of blood-cor-  
 puscles, 22  
   of cartilage-cells, 72  
   of cells, 7, 8, 10  
   of colourless blood-corpuscles, 23  
   of connective tissue-corpuscles, 57  
   division of, 14  
   of epithelial cells, 45  
   of fat-cells, 60  
   of nerves in medulla oblongata,  
     510  
   in fourth ventricle, 513  
 Nucleolus (dim. of *nucleus*), 7, 10  
 Nucleus (kernel) of caudatus, 548, 564  
   lenticularis, 548, 564  
   olivary, 504, 505  
   of roof of fourth ventricle, 552  
   tæniæformis (tape-shaped nucleus),  
     564  
   of tegmentum, 563  
 Nutrition of textures, 16  
   office of vessels in, 17  
   relation to secretion, 231  
   use of fat in, 61  
 Nymphæ, 457  
   development of, 825  
 ODONTOBLASTS (*ὀδοῦς*, gen. *ὀδόντος*, a tooth,  
*βλαστὸς*, a germ), 307, 320  
 Odoriferous matters in blood, 32  
 Œsophagus (*οἶω* or *οἶσω*, obs. = *φέρω*, I  
 bear; *φαγεῖν*, to eat), 343  
   coats of, 344

- Œsophagus**—*continued*.  
 glands of, 345  
 vessels and nerves of, 346  
**Olein** (*oleum*, oil), 60  
**Olfactory cells**, 670  
 mucous membrane, 669  
 nerve, 671  
 tract and bulb, 536  
   grey matter of, 562  
   origin of, 566  
**Olivary** (*oliva*, an olive) bodies, 504  
   development of, 756  
   superior, 514  
   fasciculus, 505, 509  
   nucleus, 504, 505  
**Omenta**, 348, 482  
**Omentum** (the caul) gastro-splenic, 397  
   great or gastro-colic, 485  
   lesser or hepato-gastric, 484  
**Operculum** (covering or lid) in cerebrum,  
   525, 531  
**Opisthotic** (*ὀπισθεν*, behind; *ὄς*, gen.  
*ὠτός*, the ear) centre, 733  
**Optic commissure**, 536  
   nerve, origin of, 567  
   membranes of, 145  
   thalamus, 549  
   development of, 758  
   grey matter of, 563  
   tract, 533  
   development of, 759  
   vesicles, 752, 762  
**Ora serrata** (serrated border), 605  
**Organising force**, 5  
**Organon adamantinæ**, 320  
**Os** (bone) cordis, 255  
**Os orbiculare seu lenticulare**, 636  
   tincæ (tench's mouth), 463  
   uteri externum, 463  
   uteri internum, 463  
**Ossæous tissue**, 79. *See* BONE.  
**Ossicula auditûs**, 635  
**Ossification**, 94  
   in cartilage, 97  
   in membrane, 94  
**Osteoblasts** (*ὀστέον*, a bone; *βλαστός*, a  
   germ), 97, 105  
**Osteoclasts** (*ὀστέον*, a bone; *κλάω*, I  
   break), 105  
**Osteodentine** (*ὀστέον*, a bone; *δενς*, a  
   tooth), 324  
**Osteogen** (*ὀστέον*, a bone; *γεννάω*, I pro-  
   duce), 96  
**Ostium of Fallopiian tube**, 471  
   uteri, 464  
**Otoliths** (*ὄς*, gen. *ὠτός*, an ear; *λίθος*, a  
   stone), 651  
**OVARIES** (*ovum*, an egg), 471  
   development of, 479, 816, 826  
   ligaments of, 467, 472  
   nerves of, 480  
   situation of, 471  
   structure of, 472  
   vessels of, 480  
   vula Nabothi, 465  
**Ovum**, 476, 673  
   fecundation of, 675  
   formation of, 478, 816  
   incapsulation of, in decidua, 710  
   production of cells in, 9  
   segmentation of, 676  
   structure of unfecundated, 673  
**Oxalic acid**, 3  
**Oxygen in blood**, 25  
  
**PACINIAN BODIES**, 147, 149  
   distribution of, 149  
   end of nerve-fibres in, 151  
   function of, 153  
   in skin, 216  
   structure of, 150  
**Palate**, 333, 334  
   glands of, 335  
**Palmitin**, 60  
**Palmæ plicatæ**, 464  
**Palpebræ** (*παλπεβρα*, an eyelid), 583  
**PANCREAS** (*πᾶν*, all; *κρέας*, flesh), 394  
   development of, 781  
   duct of, 396  
   head and tail of, 394  
   lesser, 395  
   position of, 347, 395  
   size and weight of, 394  
   structure of, 396  
   varieties of, 396  
   vessels and nerves of, 396  
**Panniculus adiposus**, 59, 213  
**Papilla foliata**, 328  
   lachrymalis, 583, 587  
**Papillæ dental**, 314, 317  
   of skin, 215, 216  
   of tongue, 327. *See* Tongue.  
**Paradidymis** (*παρά*, near; *δίδυμος*, testes),  
   481  
**Paraglobulin**, 25, 30, 36  
**Parenchymal** (*παρέγχυμα*, interstitial in-  
   fusion) tissue, 54  
**Parepididymis** (*παρά*, near; *epididymis*),  
   451, 481  
**PAROTID GLAND** (*παρά*, near; *ὄς*, gen.  
*ὠτός*, the ear), 335  
   accessory, 336  
   duct of, 337  
   position of, 335  
   vessels and nerves of, 337  
**Parovarium** (*παρά*, near; *ovarium*, ovary),  
   480, 481  
   origin of, 821, 826  
**Pars ciliaris retinae**, 605  
   intermedia of vulva, 459  
**Pelvic cavity**, 346  
**Penis**, 430  
   development of, 812, 825  
   form and attachments of, 430  
   glans of, 430  
   integument of, 431  
   ligament, suspensory, of, 431  
   lymphatics of, 436  
   nerves of, 431, 436

- Penis—*continued*.  
 vessels of, 431, 434, 435  
 Pepsin (πέπτω, 1 digest), 3  
 Peptic cells and glands, 354  
 Pepton (πέπτω, 1 digest), 30  
 Perforated space, anterior, 536, 563  
 posterior, 535, 562  
 Pericardium (περί, about; καρδιά, the heart), 239  
 vestigial fold of, 242  
 Perichondrium (περί, about; χόνδρος, cartilage), 72  
 Perilymph (περί, about; *lymph*a, water), 641  
 Perilymphangial (περί, about; *lymph*η; *ἀγγεῖων*, a vessel) nodules, 198  
 Perimysium (περί, around; μῦς, a muscle), 108  
 Perinaeum, development of, 824  
 Perineurium (περί, about; νεῦρον, a nerve), 141  
 Periosteum (περί, about; ὀστέον, a bone), 91  
 Peristaltic (περιστέλλω, 1 constrict or narrow) movement of the intestines, 358  
 PERITONEUM (περί, about; τεῖνω, 1 stretch), 348, 481  
 continuity of, traced, 481  
 formation of folds of, 778  
 Perivascular canals, 572  
 lymphatics, 183  
 of spleen, 401  
 Pes accessorius, 542  
 hippocampi, 541  
 Peyer's glands, 365  
 PHARYNX (φάρυγξ), 341  
 attachments of, 342  
 development of, 774  
 mucous membrane and glands of, 343  
 Physical properties of tissues, 2. *See* also under each tissue.  
 Pia mater, 571  
 Pigment, 3, 51  
 chemical composition of, 52  
 deposition of in cells, 11  
 use of, 52  
 Pigment-cells, movements in, 12  
 Pigment-molecules, movements of, 51  
 Pineal body or gland, 549  
 development of, 757  
 Pinna (a feather), 626  
 development of, 772  
 ligaments of, 628  
 muscles of, 629  
 nerves and vessels of, 630  
 structure of, 628  
 Pit of the stomach, 347, 350  
 Pituitary (πίτυια, phlegm or mucus) body, 535  
 development of, 734  
 membrane of nose, 668  
 Placenta (πλακοῦς, gen. πλακοῦντος, a flat cake), 710  
 circulation in, 719  
 Placenta—*continued*.  
 separation of, 724  
 structure of, 718, 723  
 Placentation, 710  
 Plasma (πλάσσω, 1 form) of blood, 19, 24, 88  
 salts in, 32  
 of chyle, 39  
 of lymph, 38  
 Plastic (πλάσσω, 1 form) force, 5  
 changes in cells, 11  
 Plates, subcranial, facial, or pharyngeal, in embryo, 738  
 Pleurae (πλευρά, a rib or side), 268  
 development of, 783  
 nerves of, 894  
 structure of, 269  
 Pleuro-peritoneal cavity, 685  
 Plexus, choroid. *See* Choroid Plexus.  
 Plexus of absorbent vessels, 183  
 interlaminar, 367  
 of nerves, 142  
 Auerbach's, 368  
 Meissner's, 368  
 myenteric (μῦς, muscle; *ἐντερον*, intestine), 368  
 tympanic, 640  
 of veins, hæmorrhoidal, 379  
 pampiniform (*pampini*us, a tendril: *forma*, shape), 454  
 vaginal, 462  
 Plica gubernatrix (guiding fold), 825, 826  
 semilunaris (semilunar fold) of eyelid, 583  
 Plicæ semilunares, 481  
 Pomum Adami (Adam's apple), 280, 294  
 Pons hepatis, 382  
 Pons Varolii (bridge of Varolius), 502, 511  
 development of, 756  
 grey matter of, 512  
 Portal canals, 388  
 fissure of liver, 382  
 vein, 384, 388  
 Portio dura, 568  
 mollis, 145, 568  
 Porus opticus (optic pore), 607  
 Postoral (*post*, behind: *os*, the mouth) pharyngeal visceral plates, 739  
 Premolar teeth, 303  
 Preoral (*præ*, before: *os*, the mouth) pharyngeal visceral plates, 738  
 Prepuce (*præputium*, foreskin), 431  
 development of, 825  
 Primordial (*primus*, first: *ordior*, 1 begin) kidney, 805  
 vertebrae, 720  
 Procerebrum (*pro*, fore; *cerebrum*, the brain), 753  
 Process, external nasal in embryo, 739  
 superior maxillary, 739  
 vermiform, 515  
 Processus a cerebello ad cerebrum, 551, 552, 556

- Processus—*continued*.  
 a cerebello ad testes, 516  
 arciformes, 506  
 brevis vel obtusus, 636  
 cuneatus (wedge-shaped process), 509  
 gracilis, 636  
 lenticularis, 636  
 vaginalis peritonei, 442, 823  
 Projection-systems of Meynert, 565  
 Promontory of tympanum, 633  
 Proötic (πρὸ, before: οὖς, gen. ὠτός, the ear) centre, 733  
 Proencephalon (πρός, before; ἐγκέφαλον, the brain), 753, 755  
 PROSTATE (πρό, before; ἴσθημι, I place)  
 GLAND, 427  
 anterior, 440  
 development of, 814, 826  
 fluid of, 430  
 levator muscle of, 429  
 position and characters of, 427  
 structure of, 429  
 vesicle of, 438  
 vessels and nerves of, 430  
 Protagon (πρῶτος, first; ἄγω, I lead), 3, 25  
 in nerve-tissue, 159  
 Proteids (*protein*; εἶδος, form), 33  
 Protein (πρῶτος, first) bodies, 30  
 Protoplasm (πρῶτος, first; πλάσσω, I form) of animal cells, 10, 15  
 contractility of, 12  
 of vegetable cells, 7  
 Protoplast, 8, 15  
 Protovertebræ (πρῶτος, first; vertebra), 693  
 segmentation of, 728  
 Proximate constituents of the body, 3  
 Pseudostomata (ψευδής, false; στόμα, a mouth), 198  
 Pterygo-palatine plates, 789  
 Pulmonary artery. *See* ARTERY.  
 veins. *See* VEINS.  
 vesicles, 275  
 Pulvinar, 549  
 Punctum lacrymale, 583, 587  
 Pupil of eye, 601, 602  
 Pupillary membrane, 603, 768  
 Purkinje, cells of, 521  
 Pyloric glands, 354  
 Pylorus (πυλωρός, a gate-keeper), 349, 356  
 Pyramid in cerebellum, 518  
 of thyroid body, 295  
 in tympanum, 634  
 Pyramids of medulla oblongata, anterior, 504  
 development of, 756  
 posterior, 505  
 of kidney, Ferrein's, 406  
 Malpighi's, 403  
 RACEMOSE (*racemus*, a cluster of grapes)  
 glands, 234  
 Ranvier's nodes, 129  
 Raphe (ράφή, a seam; from ράπτω, I sew)  
 of corpus callosum, 537  
 of medulla oblongata, 506, 510  
 pons Varolii, 512  
 scrotum, 441  
 tongue, 326  
 Recto-uterine folds, 467  
 Recto-vesical folds, 422  
 pouch, 421, 481  
 Rectum (*intestinum rectum*, the straight intestine), 376  
 mucous membrane of, 379  
 position and course of, 377  
 structure of, 378  
 vessels and nerves of, 379  
 Regeneration of textures, 16. *See* also the various tissues.  
 Reissner's membrane, 656  
 Renes succenturiati, 413  
 Reproductive organs, female, 456  
 male, 427  
 development of, 699, 814  
 Respiration, organs of, 263  
 Restiform (*restis*, a cord; *forma*, shape)  
 bodies, 505  
 development of, 756  
 Rete mirabile, 166  
 mucosum, 212  
 vasculosum testis, 448  
 Reticular tissue, 53, 69  
 Reticulum (dim. of *rete*, a net) of nervous tissue, 69, 136  
 Retina (*rete*, a net), 605  
 ciliary part of, 617  
 development of, 763, 765  
 layers of, 608  
 bacillary, 612  
 ganglionic, 608  
 molecular, inner, 609  
 outer, 610  
 of nerve-fibres, 608  
 nuclear, inner, 609  
 outer, 611  
 pigmentary, 615  
 of rods and cones, 612  
 microscopic structure of, 607  
 sustentacular tissue of, 615  
 vessels of, 618  
 Retinacula (restraining bands) of ileo-caecal valve, 375  
 Rigor mortis, 125  
 Rima (cleft) of glottidis, 285, 286, 288  
 of pendulum, 456  
 Rods of Corti in ear, 658  
 of retina, 727  
 Root-sheath of hair, 222  
 Rosenmüller, organ of, 481, 826  
 Rostrum (a beak) of corpus callosum, 538  
 Rugæ (wrinkles) of mucous membrane, 205  
 of stomach, 353  
 vagina, 460  
 SACCULAR (*sacculus*, a little bag) glands, 234



- Sacculæ of vestibule, 646  
 Sacculi of larynx, 287  
 Sacculus, vesical, 425  
 Salivary cells, 339  
 Salivary glands, 335  
   structure of, 339  
   vessels and nerves of, 341  
 Salivin, 3  
 Salts of blood, 32  
   in muscular tissue, 122  
   in nerve-tissue, 160  
 Santorini, cartilages of, 282  
 Sarcolemma (σάρξ, flesh ; λέμμα, a husk),  
   111  
 Sarkin, 3, 31  
   in muscle, 122  
 Satellite (*satelles*, an attendant) veins,  
   172  
 Scalæ (*scala*, a stair), of cochlea, 643,  
   644  
 Scarf-skin, 211  
 Schneiderian membrane, 668  
 Schreger's lines, 308  
 Sclerotic (σκληρός, hard) coat, 589  
   development of, 767  
   structure of, 591  
 Scrobiculus (a small pit) cordis, 347, 350  
 Scrotum (a hide), 441  
   development of, 825  
 Sebaceous (*sebum*, suet) glands, 229  
 Secreting apparatus, 233  
   cells, 232  
   fringes, 233  
   glands, 231  
   membrane, 233  
 SECRETION (*secerno*, I separate), 231  
   cell-agency in, 232  
 Segmentation of protovertebra, 728  
   of yolk or germ, 9, 676  
   partial, 681  
   secondary, 681  
 Semen, 454  
 Semicircular canals, 641  
   membranous, 646  
 Semilunar valves, 248, 251  
 Seminal granules, 454  
   ducts, 454  
   tubes, 447  
   vesicles, 451  
 Semipenniform muscles, 109  
 Sense, muscular, 123  
 Senses, organs of, 583  
   development of, 695  
 Sensibility, 6  
 Sensory terminal organs, 147  
 Septula renum, 404  
 Septum (a partition, from *sepio*, I hedge  
   in) of heart, 244, 246. *See* HEART.  
   lucidum, 540, 543  
   of medulla oblongata, 506  
   nasi, 665  
   pectiniforme (comb-like partition),  
     432  
   of pons Varolii, 512  
   posticum of spinal cord, 574  
 Septum—*continued*.  
   scroti, 442  
   of tongue, 333  
   transversum of semicircular canals,  
     647, 649  
 Serosity, 30  
 SEROUS MEMBRANES, General Anatomy  
   of, 196  
   apertures in, 198  
   epithelioid lining of, 197  
   fluid of, 199  
   form and arrangement of, 196  
   inflammation of, 200  
   lymphatics opening on, 180  
   lymphatics of, 198  
   nerves of, 199  
   reparation of, 200  
   structure and properties of, 197  
   vessels of, 198  
 Serum of blood, 19, 30  
   of chyle, 39  
   lymph, 38  
 Sesamoid fibro-cartilages, 79  
 Sigmoid (S, a form of the letter σίγμα ;  
   εἶδος, shape) flexure of colon, 376  
   valves, aortic, 251  
   pulmonary, 248  
 Sinus (a hollow) circularis iridis, 595  
   coronary, of heart, 246  
   pocularis (cup-like sinus), 438  
   prostatic, 438  
   uro-genital, 811  
   venosus, 244, 248  
   of vestibule, 645  
 Sinuses of veins, 174  
   of Valsalva, 252  
 Skeleton, development of, 725  
 SKIN, General Anatomy of, 211  
   chemical composition of, 213, 217  
   functions of, 230  
   glands of, 226  
   filaments, 454  
   lymphatics of, 216  
   Malpighian layer of, 212  
   nerves of, 156  
   reproduction of, 230  
   vessels of, 216  
   vital properties of, 230  
 Smegma preputii, 955  
 Somato-pleural (σῶμα, a body ; πλευρά,  
   side) elements, 685, 693  
 Solitary glands, 210  
   of small intestine, 364  
 Space, perforated, anterior, 539  
   posterior, 536  
 Spectrum analysis of blood, 27  
 Spermatic cells, 447  
 Spermatic cord, coverings of, 441  
   vessels and nerves  
     of, 444  
   structure of, 440  
 Spermatic fascia, 442  
   filaments, 454  
 Spermatoblast (σπέρμα, seed ; βλαστός, a  
   germ), 815

- Spermatozoa (*σπέρμα*, seed; *ζῶον*, an animal), 454
- Sphincter (*σφίγγω*, I bind) of anus, internal, 380  
of bladder, 425  
of larynx, 293  
of pupil, 602  
vaginæ, 461  
vesicæ, 425
- SPINAL CORD, Descriptive Anatomy of, 489  
central canal of, 496, 500  
ligament of, 492  
columns of, 494  
commissures of, 493, 496, 500  
connective tissue of, 497  
development of, 746  
fibres of, 509  
enlargement in, 491  
external form of, 489  
fissures of, 492  
grey matter of, 496, 497  
internal structure of, 494  
ligaments of, 489  
membranes of, 489, 570, 572  
minute structure of, 497  
origin of nerves from, 501  
size of, 491  
terminal filament of, 489, 492, 500  
white substance of, 495, 497
- Splanchno-pleural (*σπλάγχνα*, entrails; *πλευρά*, a side) elements, 685, 693
- SPLEEN (*σπλήν*), 397  
accessory, 398  
blood-vessels of, 399  
coats of, 398  
corpuscles of, 399  
development of, 782  
hilus or fissure of, 397  
lymphatics of, 401  
nerves of, 401  
position of, 348, 397  
pulp of, 399  
size and weight of, 397  
structure of, 398
- Splenuci (little spleen), 398
- Splenic artery, 399  
flexure of colon, 376
- Stapes (a stirrup), 636
- Stearin (*στέαρ*, tallow), 60
- Stellulæ of Verheyen, 412
- Stenson's duct, 337
- Stigma in ovary, 474
- STOMACH, 349  
areolar coat of, 352  
changes in colour, after death, 352  
connections of, 349  
development of, 776  
dimensions of, 349  
epithelium of, 353  
fundus of, 349  
glands of, 353, 354  
lymphatics of, 356  
lymphoid accumulations in, 355
- Stomach—*continued*.  
mucous membrane of, 352  
muscular coat of, 350  
nerves of, 356  
position of, 347, 349  
pylorus, 349, 356  
rugæ of, 353  
shape of, 349  
structure of, 350  
tubules of, 353  
vessels of, 355
- Stomata (*στόμα*, a mouth), in serous membranes, 189, 198
- Stria terminalis, 549
- Striæ longitudinales, 537  
medullares, 506
- Stroma (*στρώμα*, a bed), of lymphatic glands, 193  
intertubular, of kidney, 413  
of ovaries, 473  
of suprarenal bodies, 415
- Structural elements of the body, 2
- Subarachnoid space, 573
- Subarantal or pharyngeal arches, 738
- Subhyoid or cervical arch, 740
- Sublingual gland, 335, 338
- Sublobular veins of liver, 387
- Submaxillary gland, 335, 337
- Submucous tissue, 53, 205
- Subserous tissue, 53, 197, 273
- Substantia cinerea gelatinosa, 496, 498
- Sudoriferous glands, 226  
contents of, 228  
development of, 228
- Sugar in blood, 32  
in human body, 3  
in muscle, 122
- Sulci (furrows) in brain, 523
- Suleus, auriculo-ventricular, 243, 255
- SUPRARENAL BODIES OR CAPSULES, 413  
accessory, 416  
cortical part of, 415  
development of, 813  
fibrous investment of, 415  
forms and position of, 413  
function of, 417  
lymphatics of, 416  
medullary part of, 415  
nerves of, 416  
size and weight of, 414  
structure of, 414  
vessels of, 416
- Sustentaculum lienis (support of the spleen), 376
- Sweat-glands, 226
- Sympathetic nerve. *See* NERVE, SYMPATHETIC.
- Synovia, 204
- Synovial bursæ, 201  
capsules, 200  
folds or fringes, 200  
membranes, 200  
development of, 204  
nerves of, 204

- Synovial membranes, structure of, 202  
     vessels of, 203  
     sheaths, 201  
 Syntonin (*σύν*, together; *τείνω*, I stretch),  
     3, 30  
     in muscle, 121  
 Systems, organic, 1
- TACTILE (*tactus*, touch) corpuscles, 147,  
     148  
     papillæ, 216  
     sensitivity, 230  
 Tænia (*τανία*, a band or ribbon) hippo-  
     campi, 542, 544  
     semicircularis, 541, 549  
 Tapetum (a carpet), 556  
 Tarsal (*tarsus*, the cartilage supporting  
     the eye) cartilages, 584  
 Taste-buds in tongue, 328  
 Tectorial membrane, 658, 661  
 TEETH, 301  
     arrangement in jaws, 301  
     changes in jaw during growth of,  
         323  
     characters of, general, 301  
     follicular stage of, 315  
         formation of, 313  
     hard tissues of, 307  
         formation of, 318  
     permanent, 302  
         calcification of, 323  
         cavities of reserve of, 321, 323  
         development of, 321  
         eruption of, 323  
     pulp of, 306  
     sacs of, 316  
     structure of, 306  
     temporary, 301, 306  
         development of, 313  
         eruption of, 320  
         shedding of, 322  
 Tegmentum of crura cerebri, 555  
 Tela chorioidea (the choroid web), 545  
 Tendons (*τενω*, I stretch), 63  
     connection with muscles, 115  
 Tentorium (a tent, from *tendo*, I stretch),  
     571  
 TESTES (testicles), 440, 445  
     capsule of, 446  
     connective tissue of, 237  
     coverings of, 440  
     descent of, 823  
     development of, 815  
     excretory duct of, 450  
     secretion of, 455  
     situation and character of, 445  
     structure of, 445  
         minute, 447  
     (in cerebrum), 551  
     muliebres, 471  
 TEXTURES in general, 1  
     chemical composition of, 3  
     development of, 6  
     enumeration of, 1
- TEXTURES—*continued*.  
     nutrition and regeneration of, 16  
     physical properties of, 2  
     vital properties of, 4  
 Thalamus opticus (optic couch). *See*  
     Optic thalamus  
 Thalamencephalon (*thalamus*; *ἐγκέφαλον*,  
     the brain), 751, 753, 755  
     parts formed from, 757  
 Theca (sheath) of spinal cord, 489, 570  
 Thoracic duct, 37, 190  
     viscera, 239  
 THYMUS GLAND, 297  
     development and growth of, 290,  
         782  
     lobes of, 298  
     lymphatics of, 299  
     position of, 297  
     structure of, 298  
     vessels and nerves of, 299  
 Thyro-hyoid arch, 740  
     membrane, 283  
 THYROID (*θυρεός*, a shield; *εἶδος*, shape)  
     BODY OF GLAND, 295  
     development of, 297, 782  
     fluid of, 296  
     lobes of, 295  
     pathological changes in, 297  
     structure of, 296  
     vessels and nerves of, 297  
 Thyroid cartilage, 280  
 Tomentum (flock of wool, hair, &c.) cere-  
     bri, 572  
 TONGUE, 325  
     dorsum of, 326  
     frænum of, 325  
     glands of, 330  
     mucous membrane of, 325  
     muscles of, 331  
     nerves of, 333  
     papillæ of, circumvallate, 327  
         conical and filiform, 329  
         fungiform, 327, 329  
         secondary, 329  
     raphe of, 326  
     septum of, 333  
     vessels of, 333  
 Tonicity (*τόνος*, tension) of arteries, 171  
 Tonsils, 335  
 Touch-bodies, 148  
 Trabeculæ (dim. from *trabs*, a beam) of  
     corpus cavernosum, 433  
     cranii, 738  
     of lymphatic glands, 193  
     of spleen, 398  
 Trabs cerebri (corpus callosum), 537  
 TRACHEA (*arteria trachea*, the rough  
     artery; *τραχύς*, rough), 263  
     cartilages of, 266  
     changes in, after-birth, 272  
     development of, 782  
     elastic tissue of, 267  
     glands of, 267  
     mucous membrane of, 267  
     muscular fibres of, 266

- TRACHEA—*continued*.  
 situation of, 263  
 structure of, 266  
 vessels and nerves of, 267
- Tract, olfactory. *See* OLFATORY.  
 optic. *See* OPTIC.
- Tractus intermedio-lateralis, 499  
 spiralis foraminulentus, 662
- Tragus (*τράγος*, a goat), 627  
 muscle of, 629
- Trapezium in pons Varolii, 511
- Tricuspid (*tres*, three; *cuspis*, the point of a weapon) valve, 247
- Trigone (triangle, from *τρεῖς*, three; *γωνία*, an angle) of bladder, 423
- Triolein, 60
- Tripalmitin, 60
- Triploblastic (*τριπλόος*, triple; *βλαστός*, germ) ovum, 683
- Tristearin, 60
- Tuber annulare, 511  
 cinereum, 535  
 cochleæ, 633  
 olfactorium, 537, 562
- Tubercle, grey, of Rolando, 510  
 laminated, 518  
 of Lower, 245
- Tubercula quadrigemina, 551
- Tuberculum pharyngeum, 343
- Tubular glands, 209  
 nerve-fibres, 126
- Tubules, dentinal, 307, 308
- Tubuli seminiferi, 447  
 of stomach, 353  
 uriniferi, 405
- Tunica adventitia of arteries, 170  
 albuginea of testicle, 446  
 of ovary, 472  
 choroidea, 598  
 chorio-capillaris, 600  
 granulosa of Graafian follicle, 475  
 propria of labyrinth, 649  
 of spleen, 398  
 Ruyschiana, 600  
 vaginalis, 443  
 oculi, 589  
 vasculosa testis, 447
- Tutamina oculi (defences of the eye), 583
- TYMPANUM (*τύμπανον*, a drum) or middle ear, 631  
 development of, 772  
 ligaments and muscles of, 637  
 membrane of, 632  
 lining, 639  
 vessels and nerves of, 640  
 walls of, 633, 634
- Tyrosin, 3  
 in blood, 32
- Tyson's glands, 431
- UMBILICAL (*umbilicus*, the navel) fissure of liver, 382  
 region, 347  
 contents of, 348  
 vessels, 800
- Urachus (*ὄρον*, urine; *ἔχω*, I hold), 814
- Urea, 3  
 in blood, 31
- URETERS (*ὀυρέω*, I pass urine), 417  
 development of, 813  
 orifices of, 423  
 structure of, 418  
 varieties of, 418  
 vessels and nerves of, 418
- URETHRA (*ὄρον*, urine), 427  
 female, 459  
 glands of, 460  
 mucous membrane of, 460  
 orifice, 457, 459  
 male, 436  
 bulb of, 435  
 crest of, 438  
 development of, 825  
 fossa navicularis of, 439  
 glands and lacunæ of, 439  
 length of, 436  
 mucous membrane of, 439  
 orifice of, external, 439  
 internal, 423  
 portion of, membranous, 438  
 bulbous, 439  
 prostatic, 436  
 spongy, 439
- Uric acid, 3  
 in blood, 31  
 in nerve-tissue, 160
- Urinary bladder, 419. *See* BLADDER.  
 organs, 402  
 development of, 699, 804  
 vesicle, 704
- Uriniferous tubes, 405  
 development of, 812
- Utero-gestation, 710
- UTERUS (womb), 462  
 blood-vessels of, 467  
 cavity of, 464  
 cervix, or neck, 463  
 changes in, 468  
 from age, 469  
 in gestation, 121, 468, 711  
 in menstruation, 211, 468  
 development of, 819, 826  
 fundus of, 463  
 glands of, 466  
 in formation of decidua, 716  
 relation of, to placenta, 722  
 ligaments of, 467  
 malformations of, 470  
 mucous membrane of, 465  
 changes in, 711  
 separation of, 724  
 muscular tissue of, 464  
 nerves of, 468  
 os, or mouth of, external, 463  
 internal, 464  
 position of, 462  
 structure of, 464
- Utricle (*utrículus*, a small bag) of male urethra, 438  
 of vestibule of the ear, 645

Uvea (*uva*, a cluster of grapes), 603  
 Uvula (dim. of *uva*) of bladder, 423  
     of cerebellum, 518

VACUOLES in pale corpuscles, 23

VAGINA (sheath), 460  
     development of, 819, 826  
     glands of, 461  
     orifice of, 457  
     sphincter of, 461  
     vessels and nerves of, 462

Vagina cellulosa (cellular sheath) of  
     nerves, 141 note

Vaginal arteries of liver, 390  
     synovial membranes, 201  
     veins of liver, 389

Vallecula of cerebellum, 516, 518

Valve or valves of Bauhin, 375  
     of foramen ovale, 789, 799  
     of heart. *See* HEART.  
     ileo-cæcal, or ileo-colic, 375  
     of Kerkring, 359  
     of lachrymal sac and canals, 588  
     of lymphatics, 188  
     of Tulpus, 375  
     of veins, 174  
     of Vieussens, 552

Valvulæ conniventes, 205, 359

Varicose nerve-fibres, 129, 130

Vas aberrans of testis, 451, 822  
     deferens, 449, 450  
     development of, 822, 826  
     spirale (spiral vessel), 656

Vasa afferentia and efferentia of lymphatic  
     glands, 192  
     efferentia of testis, 448  
         development of, 823, 826  
     lactea, 844  
     recta of kidney, 412  
         of testis, 448  
     vasorum, arteries, 170  
         veins, 174  
         lymphatics, 176  
     vorticosa, 599

Vascular glands, 238  
     system, development of, 696

Vaso-motorial nerves, 161

VEINS, General Anatomy of, 172  
     anastomoses of, 172  
     coats of, 173  
     contractility of, 174  
     development of, 796  
     distribution of, 172  
     formation of, 163  
     peculiarities of, 173  
     pulsation in, 174  
     satellite, 172  
     structure of, 172  
     vital properties of, 174

Veins, bronchial, 279  
     cardiac, openings of, 246  
     cardinal, 797  
     central, of liver, 387  
     coronary, of heart, 246

VOL. II.

Veins—*continued.*  
     of Galen, 546  
     hepatic, 384, 388  
     innominate, development of, 798  
     interlobular, 388  
     intralobular, 317, 388  
     jugular, primitive, 796, 798  
     laryngeal, 294  
     omphalo-mesenteric, 796  
     portal, 384, 388  
     pulmonary, distribution of, 278  
         opening of, 248  
     renal, blood of, 34  
     sublobular, 387, 388  
     umbilical, 802  
         closure of, 803  
     vaginal, in liver, 389  
     vertebral, posterior, 797

Velum medullare arterius, 552  
     interpositum of brain, 541, 545  
     pendulum, palati 334  
     posterior medullary, 518

Vena portæ, 384, 388

Venæ cavæ, openings of, 280  
     cordis minimæ, 246  
     hepaticæ advehentes and revehentes,  
         726

Ventricles (*ventriculus*, dim. of *venter*, a  
     belly), cerebral, of Arantius, 506  
     fifth, 543  
     fourth, 512  
         floor of, 506, 512  
         lining membrane of, 513  
     lateral, 539  
     of septum, or Sylvian, 543  
     third, 546  
     of heart. *See* HEART.  
     of larynx, 285, 287, 288

Vermicular motion (*vermiculus*, dim. of  
     *vermis*, a worm), 358

Vertebræ, formation of, 692, 725  
     primordial, 728

Verumontanum (*veru*, ridge), 438

Vesica urinaria, 419. *See* BLADDER,  
     URINARY.

Vesicula prostatica, 438

Vesico-uterine folds, 467

Vesiculæ seminales, 451  
     development of, 822, 826

Vessels. *See* ARTERIES, CAPILLARIES,  
     and VEINS

Vestibule, aortic, 253  
     of ear, 641  
         membranous, 645  
     of vulva, 457

Vibrissæ, 665

Villi (*villus*, shaggy hair), 209  
     of chorion, 709  
     of small intestine, 359, 360

Vis nervosa, 6

Vital affinity, 5  
     capacity of lung, 271  
     properties of textures, 4. *See* each  
         tissue

Vitality, 4

- Vitelline (*vitellus*, yolk) membrane, 476,  
     673  
 Vitellus, 476, 673  
 Vitreous (*vitrum*, glass) body, 619  
     development of, 764, 767  
 Vocal cords, false, 285, 287  
     true, 284, 287  
 Voice, organ of, 280  
 Voluntary muscles, 108  
 VULVA, 456  
     erectile tissue of, 458  
     glands of, 458  
     mucous membrane of, 458  
     nerves of, 459  
     vessels of, 459  
 WHARTON'S duct, 337  
     jelly, 69  
 Windpipe, 263  
 Wisdom tooth, 305  
 Wolffian bodies, 480, 699, 804, 826  
     homologies of, 809  
     origin of, 806  
     duct, 809, 826  
 Womb, 462. *See* UTERUS.  
 Wrisberg, cartilages of, 283  
 YELLOW cartilage, 72, 78  
     fibres of areolar tissue, 55  
     tissue, 66  
 Yolk, 476, 673  
     segmentation of, 9, 676  
 Yolk-sac, 700  
 ZONA glomerulosa, 415  
     pectinata, 763  
     pellucida, 476, 478, 673  
     reticularis, 415  
 Zones, abdominal, 346  
 Zonula of Zinn, 620

THE END.


















SMITHSONIAN INSTITUTION LIBRARIES



3 9088 00563 8937