


COLUMBIA LIBRARIES OFFSITE

HEALTH SCIENCES STANDARD



HX00017531

RECAP



HEALTH
SCIENCES
LIBRARY

Digitized by the Internet Archive
in 2010 with funding from
Open Knowledge Commons

QUAIN'S
ELEMENTS OF ANATOMY

EDITED BY

EDWARD ALBERT SCHÄFER, F.R.S.

PROFESSOR OF PHYSIOLOGY AND HISTOLOGY IN UNIVERSITY COLLEGE, LONDON.

AND

GEORGE DANCER THANE,

PROFESSOR OF ANATOMY IN UNIVERSITY COLLEGE, LONDON.

IN THREE VOLUMES.

VOL. III.—PART III.

ORGANS OF THE SENSES.

BY PROFESSOR SCHÄFER.

ILLUSTRATED BY 178 ENGRAVINGS.

Tenth Edition.

LONDON:
LONGMANS, GREEN, AND CO.
AND NEW YORK: 15 EAST 16th STREET.

1894.

LONDON:
BRADBURY, AGNEW, & CO. LD., PRINTERS, WHITEFRIARS.

CONTENTS OF PART III.

ORGANS OF THE SENSES.

	PAGE		PAGE
THE EYE	1	THE MIDDLE EAR OR TYMPANUM	80
THE EYELIDS AND CONJUNCTIVA	1	Membrana Tympani	81
Eyelids	1	Eustachian Tube	86
Meibomian Glands	3	Auditory Ossicles	89
Conjunctiva	4	Ligaments	92
Vessels	5	Muscles	93
Nerves	7	Movements	95
THE LACHRYMAL APPARATUS	7	Lining Membrane	95
Lachrymal Gland	7	Recesses	96
Lachrymal Canals	8	Vessels and Nerves	97
Lachrymal Sac	9	THE INTERNAL EAR OR LABYRINTH	98
Nasal Duct	9	Osseous Labyrinth	99
THE GLOBE OF THE EYE	10	Vestibule	99
Sclerotic Coat	13	Semicircular Canals	100
Cornea	17	Cochlea	101
Membrane of Bowman	19	Membranous Labyrinth	104
Membrane of Descemet	19	Utricule	104
Vessels and Nerves of Cornea	22	Sacculæ	105
Vascular Coat	23	Membranous Semicircular Canals	105
Choroid Coat	23	Branches of the Eighth Nerve	108
Ciliary Muscle	30	Vessels	109
Iris	31	Structure of Utricule, Sacculæ and Semicircular Canals	109
Muscular Tissue of Iris	32	Ampullæ	110
Vessels of Iris	33	Membranous Cochlea	112
Nerves of Vascular Coat	34	Limbus	115
Retina	35	Basilar Membrane	116
Retinal Layers	38	Membrane of Reissner	118
Rods and Cones	47	Spiral Ligament	119
Müllerian Fibres	50	Organ of Corti	119
Structure of Macula Lutea and Fovea		Rods of Corti	120
Centralis	52	Hair Cells and Cells of Deiters	121
Structure of Ora Serrata and Pars Ciliaris	54	Lamina Reticularis	122
Vessels of Retina	55	Tectorial Membrane	123
Interconnection of Retinal Elements	56	Nerves of Cochlea	124
Vitreous Body	58	Vessels of Cochlea	126
Suspensory Apparatus of Lens	59	Development of Organ of Corti	126
Lens	63	Measurements of Cochlea	127
Lens-Capsule	65	THE NOSE	130
Changes in Lens with Age	66	Cartilages	131
Aqueous Humour and its Chamber	66	Nasal Fossæ	133
THE EAR	71	Mucous Membrane	139
THE EXTERNAL EAR	71	Olfactory Mucous Membrane	140
Pinna	71	Olfactory Cells	141
Ligaments	74	Olfactory Nerve	142
Muscles	75	Organ of Jacobson	143
Vessels	76	Vessels of Nasal Fossæ	144
Nerves	76	THE ORGANS OF TASTE	148
External Auditory Canal	76	Gustatory Cells	150
Vessels and Nerves	79	ARRANGEMENT OF SENSORY CELLS AND NERVE FIBRES IN THE DIFFERENT ORGANS	152
State in the Infant	79		

ORGANS OF THE SENSES.



IN this Part will be described the organs of sight, hearing, and smell, and also the taste buds which are found on the tongue and other parts endowed with the sense of taste. The terminations of sensory nerves in the skin and elsewhere have already been described in Vol. I., Part 2, and will only be briefly alluded to in reviewing the whole subject of the ending of nerves of special sense.

THE EYE.

The organ of vision, strictly speaking, consists only of the ball or globe of the

CORRIGENDA.

Page 16, line 14 from top, for "(p. 25)" read "(p. 24)."

„ 44, footnote 1, for "vos" read "iós."

„ 59, title of fig. 68, for "HUMOURS" read "HUMOUR."

„ 80, line 13 from bottom, for "auditus" read "aditus."

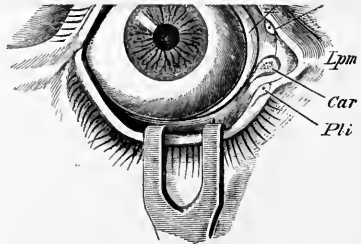
„ 147, line 2 from top, for "Uber" read "Ueber."

line 9 from top, for "nebenhöhle" read "Nebenhöhle."

line 5 from bottom, for "vergleichend-anatome" read "vergleichend-anatomische."

line 2 from bottom, for "pathologisch" read "pathologische."

The upper lid is larger and more moveable than the lower, all the transparent part of the globe being covered by it when the eye is closed; it is chiefly by the elevation of this lid that the eye is opened, the movement being effected by a muscle (*levator palpebræ*) devoted exclusively to this purpose. At the outer and inner angles (*canthi*) of the eye the eyelids are united. The interval between the angles varies



in different individuals, averaging about 28mm. (Fuchs), and, according to its extent, gives the appearance of a larger or a smaller eye, the size of the globe being nearly the same in all. The greater part of the edge of each eyelid is flattened and angular, but towards the inner canthus it is rounded off for a short space, at the same time that it changes its direction, so that a rounded bay is here left between the two eyelids; this bay has been termed the lacrimal reservoir (*lacus lacrimonalis*); at this point there is seen on each lid a slight elevation (*papilla lacrimonalis*),—the apex of which is pierced by the aperture (*punctum*) of a small canal (*canaliculus lacrimonalis*) which serves to convey away the fluid which moistens the conjunctiva (fig. 1, *Pls*, *Pls*). (See also figs. 9, 10, and 11.)

In the greater part of their extent the lids are applied to the surface of the eyeball; but at the inner canthus, at the lacrimal lake, there intervenes a vertical fold

ORGANS OF THE SENSES.

In this Part will be described the organs of sight, hearing, and smell, and also the taste buds which are found on the tongue and other parts endowed with the sense of taste. The terminations of sensory nerves in the skin and elsewhere have already been described in Vol. I., Part 2, and will only be briefly alluded to in reviewing the whole subject of the ending of nerves of special sense.

THE EYE.

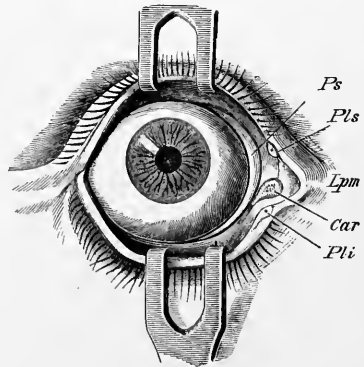
The organ of vision, strictly speaking, consists only of the ball or globe of the eye; but connected with the eyeball externally are muscles, nerves, and blood-vessels, elsewhere described, as well as other parts specially destined for its protection (*tutamina oculi*), of which an account will first be given.

THE EYELIDS AND CONJUNCTIVA.

The eyelids (*palpebræ*) are moveable folds of integument, strengthened towards their margins by a thin lamina of dense fibrous tissue (*tarsus*). They are about 3mm. thick near their free edge. A mucous membrane (*conjunctiva*) lines their inner surface, and is reflected thence on the front of the eyeball. The line of reflection is termed the *fornix conjunctivæ*.

Fig. 1.—FRONT VIEW OF THE RIGHT EYE, WITH THE EYELIDS DRAWN APART BY BLUNT HOOKS. (Merkel.)

Ps, plica semilunaris; *Pls*, *Pli*, punctum lacrimale sup. et inf.; *Car*, caruncula lacrimalis; *Lpm*, interna tarsal ligament.



The upper lid is larger and more moveable than the lower, all the transparent part of the globe being covered by it when the eye is closed; it is chiefly by the elevation of this lid that the eye is opened, the movement being effected by a muscle (*levator palpebræ*) devoted exclusively to this purpose. At the outer and inner angles (*canthi*) of the eye the eyelids are united. The interval between the angles varies in different individuals, averaging about 28mm. (Fuchs), and, according to its extent, gives the appearance of a larger or a smaller eye, the size of the globe being nearly the same in all. The greater part of the edge of each eyelid is flattened and angular, but towards the inner canthus it is rounded off for a short space, at the same time that it changes its direction, so that a rounded bay is here left between the two eyelids; this bay has been termed the lachrymal reservoir (*lacus lacrimalis*); at this point there is seen on each lid a slight elevation (*papilla lacrimalis*),—the apex of which is pierced by the aperture (*punctum*) of a small canal (*canaliculus lacrimalis*) which serves to convey away the fluid which moistens the conjunctiva (fig. 1, *Pli*, *Pls*). (See also figs. 9, 10, and 11.)

In the greater part of their extent the lids are applied to the surface of the eyeball; but at the inner canthus, at the lachrymal lake, there intervenes a vertical fold

of conjunctiva, the *plica semilunaris* (fig. 1, *Ps*), which rests on the eyeball ; whilst occupying the recess of the angle at the border of this fold, is a spongy-looking reddish elevation (*caruncula lacrimalis*, *Car*) formed by a small isolated portion of skin containing a few large modified sweat glands, as well as a group of sebaceous glands which open into the follicles of very fine hairs. There is further found in it a small amount of plain muscular tissue (H. Müller), as well as some cross-striated muscular fibres. A few plain muscular fibres are also to be found in the plica semilunaris.

The plica semilunaris is the rudiment of the third eyelid (*membrana nictitans*) found in many animals ; and in some animals, and occasionally in man, the caruncula lacrimalis retains its connection with the skin at the inner canthus. The muscular tissue of the nictitating membrane of animals, and presumably, therefore, of the semilunar fold of man, receives its nerve supply through the cervical sympathetic. In many animals, and occasionally in man (in the negro constantly, according to Giacomini), the plica semilunaris contains a plate of hyaline cartilage.

Structure of the lids.—The skin covering the eyelids is thin and delicate, and covered with fine downy hairs (fig. 2, *i*, *i*). These are provided with sebaceous follicles ; small sweat-glands are also present. At the line of the eyelashes the skin joins the conjunctival mucous membrane which lines the inner surface of the lids. The cutis vera contains a number of ramified pigment cells, and pigment is also frequently found in the Malpighian layer of the epidermis, especially near the inner angle of the lids. Beneath the skin is a quantity of very loose connective tissue, entirely free from fat and containing the fasciculi of the orbicularis palpebrarum muscle (*b*), and beneath the mucous membrane on the posterior surface is the lamina of dense connective tissue before mentioned, and known as the tarsus (*e*), or from its consistence, the tarsal cartilage, which thins off near the attached margin of the eyelid into the palpebral fascia connecting it with the margin of the orbit. In the tarsi are imbedded the Meibomian glands (*f*). In the upper eyelid there is, in addition, the insertion of the levator palpebræ superioris, attached to the upper or anterior surface of the tarsus by fibrous tissue and smooth muscular tissue (see below) and further sending a well-marked flat tendinous expansion, the bundles of which pass between the bundles of the orbicularis palpebrarum muscle, and are attached to the skin of the middle of the eyelid (fig. 6). There is nothing corresponding to this in the lower lid, but the inferior rectus and oblique muscles send strands of fibrous tissue forwards to be attached to the tarsus and palpebral ligament.

The *orbicularis muscle* is attached to the skin by loose subcutaneous connective tissue, but glides loosely on the tarsal cartilages. A marginal fasciculus lies within the line of the eyelashes, separated by the bulbs of the lashes from the other fibres, and constituting the *ciliary bundle* or muscle of Riolan (*b'*). The fibres of the orbicularis are very small and pale in colour. Its attachments have already been described in Vol. II., Part 2.

The *tarsi* (*tarsal cartilages*) are two thin elongated plates formed of dense connective tissue, without any intermixture of cartilage-cells. They are placed one in each lid, to which they give shape and firmness. The upper one, the larger, is half oval in form, being broader near the centre and narrowing towards the angles of the lids. The lower is thinner, much narrower, and more nearly of a uniform breadth throughout. Their free edges, which are straight, are thicker than any other part. At the inner canthus they are fixed to the nasal process of the superior maxillary bone by the internal tarsal slip ; and at the outer angle are attached to the malar bone by a fibrous band termed the outer tarsal ligament (Vol. II., p. 281). Groups of fat-cells are found in the tarsus both near its attached border and scattered over its anterior surface (Merkel).

The *palpebral fascia* (*septum orbitale*) is a fibrous membrane placed beneath the orbicularis muscle, attached on the one hand to the margin of the orbit, and on the other prolonged towards the attached border of each tarsus. In the lower lid its tissue is continuous with that of the tarsus, but in the upper lid it blends with the tendon of the levator palpebræ. The membrane is thicker at the outer part of the orbit, where it forms the lateral (outer) palpebral or tarsal ligament (figs. 4, 12). The mesial (internal) palpebral ligament, to which the fibres of the orbicularis palpebrarum are attached (see Vol. II. p. 281), is not formed from the general palpebral fascia, but lies altogether in front of it (fig. 4). The palpebral fascia

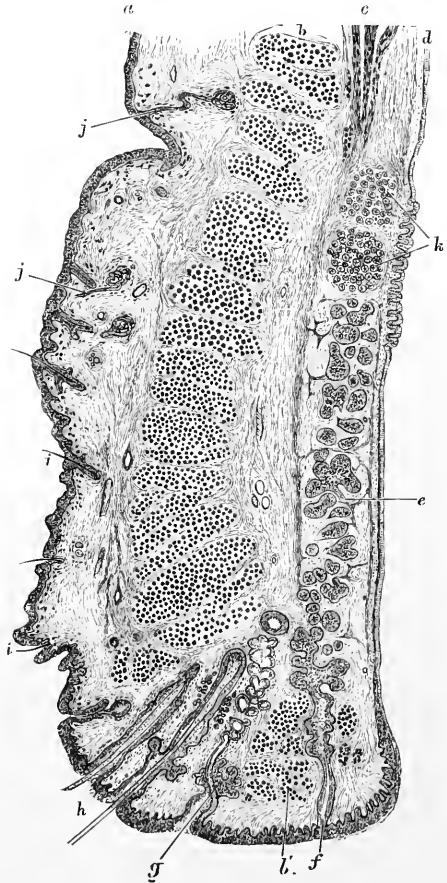
Fig. 2.—VERTICAL SECTION THROUGH THE UPPER EYELID, HUMAN (after Waldeyer). Magnified.

a, skin; *b*, orbicularis; *b'*, ciliary bundle; *c*, involuntary muscle of eyelid; *d*, conjunctiva; *e*, tarsus; *f*, Meibomian gland; *g*, sebaceous gland near eyelashes, with modified sweat-gland opening with it; *h*, eyelashes; *i*, small hairs in outer skin; *j*, sweat-glands; *k*, posterior tarsal glands.

extends downwards from the crista lacrimalis posterior, between the osseous boundary of the nasal duct and the origin of the inferior oblique muscle, to reach the lower border of the orbit (Merkel).

The palpebral fascia thus acts as a kind of fibrous septum between the cutaneous and the conjunctival parts of the eyelid at its attached border: it was therefore termed the *septum orbitale* by Henle. It is perforated above the internal tarsal ligament by the termination of the ophthalmic artery, with a considerable anastomotic vein between the superior ophthalmic and the angular, and its attachment to the supra-orbital margin is interrupted internal to the centre by the passage of the supra-orbital nerve (in one or two pieces) with the accompanying artery.

On the ocular surface of each lid are seen parallel vertical rows of what, seen through the conjunctival mucous membrane, look like yellow granules. There are twenty to thirty of these rows in the lower lid, somewhat more in the upper lid; they are the *Meibomian* or *tarsal glands* (fig. 3). These are long sebaceous glands, imbedded in the tarsi; and they open on the free margin of the lids by minute orifices, generally one for each. The glands consist of nearly straight tubes, closed at the end, with numerous small caecal appendages projecting from the sides. Sometimes, however, they are not straight, but are bent round at the blind end, as is shown in some of those represented in fig. 3. The mouths of the tubes are lined by stratified epithelium continuous with that of the skin; but the ducts and the glandular recesses have a lining of cubical epithelium filled with the fatty



secretion. According to Colosanti the glands have a basement membrane, and a muscular layer outside this : he further describes a network of fine nervous fibrils amongst the epithelium-cells.

A layer of unstriped muscular tissue is contained in each eyelid (H. Müller) : that of the upper (fig. 2, *c* ; fig. 13) arising from the under surface of the levator palpebræ, that of the lower from the neighbourhood of the inferior oblique muscle, and each being inserted near the attached margin of the tarsus. According to Henle, some of the fibres have a transverse course.¹

The *eyelashes* (*cilia*) are strong short curved hairs, arranged in two or more rows along the margin of the lids, at the line of union between the skin and the conjunctiva. The upper lashes are more numerous and longer than the lower ; they

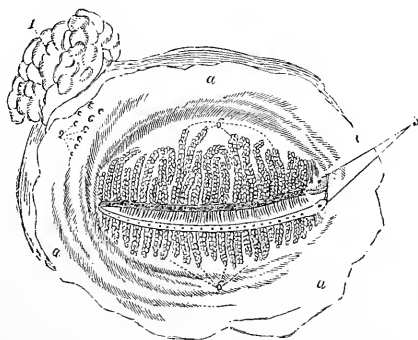


Fig. 3.—MEIBOMIAN GLANDS OF THE LEFT EYELIDS AS SEEN FROM BEHIND.

a, a, palpebral conjunctiva ; 1, lachrymal gland ; 2, openings of seven or eight of its ducts ; 3, upper and lower puncta lacrimalia ; 6, 6, ends of the upper and lower Meibomian glands, of which the openings are indicated along the margins of the eyelids.

are curved in an opposite direction in the two lids : so that their convexities are directed towards one another. The extremity of the lid, in which the follicles of the eyelashes are set, is composed of a dense fibrous tissue, somewhat similar

in nature to that of the tarsus, with which it is, in fact, in the upper lid continuous (Merkel). The hair follicles are of some length (1·5 to 2·5 mm.), penetrating obliquely from the outer edge of the lid nearly to the tarsi.

Near the inner canthus the hairs are weaker and more scattered. Immediately within the eyelashes, between them and the ciliary bundle of the orbicularis, is a row of large modified sweat glands (*glands of Moll*), which sometimes open into the mouths of large sebaceous glands (fig. 2, *g*) (not the Meibomian).

The *conjunctiva* consists of the palpebral part (*conjunctiva palpebrarum*), with which may be included the plica semilunaris and caruncula, and of the ocular part (*conjunctiva bulbi*), in which may be distinguished the sclerotic and corneal portions : each of these parts has distinctive characters. The epithelium of the conjunctiva varies somewhat at different parts ; that of the eyelids is columnar, with smaller cells between the fixed ends of the columnar cells. Near the skin and cornea it shades off into the stratified epithelium which covers these parts.

The *palpebral portion* of the conjunctiva is thicker and more vascular than the rest of the membrane, and is freely supplied with nerves. Through the puncta lacrimalia and canaliculi, it is continuous with the lining membrane of the lachrymal sac. Although closely united to the tarsi, it exhibits, nevertheless, numerous small creases or folds, which are visible with a lens. A layer of small racemose or tubulo-racemose glands (*posterior tarsal*) is found on the ocular surface of the lids, immediately under the conjunctiva, and beyond the blind ends of the

¹ It may be mentioned in this place that H. Müller also described a layer of unstriped muscle bridging over the speno-maxillary fissure, corresponding to a more largely developed layer found in the extensive aponeurotic part of the orbital wall of various mammalia (H. Müller, Würzburg Sitzungsab., 1858 ; Turner, Nat. Hist. Rev., 1862). These involuntary muscles receive their nerves through the cervical sympathetic ; the speno-maxillary muscle, when contracted, causes the globe of the eye to project more from the orbit.

Meibomian glands (fig. 2, *k*). Their minute ducts open near the line of reflection of the conjunctiva upon the globe of the eye.

Harderian gland.—All animals which possess a well-developed *membrana nictitans* have also, situated at the mesial angle of the eye, a special gland, the duct of which opens beneath the third eyelid. The gland has a racemose structure, and secretes a mucus-like fluid, thus differing from the serous-secreting lachrymal. It is not found in primates, unless in an extremely vestigial form.

The ocular portion.—The conjunctiva changes its character at the line of reflection from the eyelids, becoming thinner and being loosely connected to the sclerotic coat of the eyeball by submucous tissue. But over the cornea it consists only of a prolongation of the epithelium, which is closely adherent to the anterior layers of the cornea, in connection with which it will be described.

Blood-vessels.—The blood is supplied to the eyelids mainly by the internal and external palpebral arteries; the former being derived from the ophthalmic artery

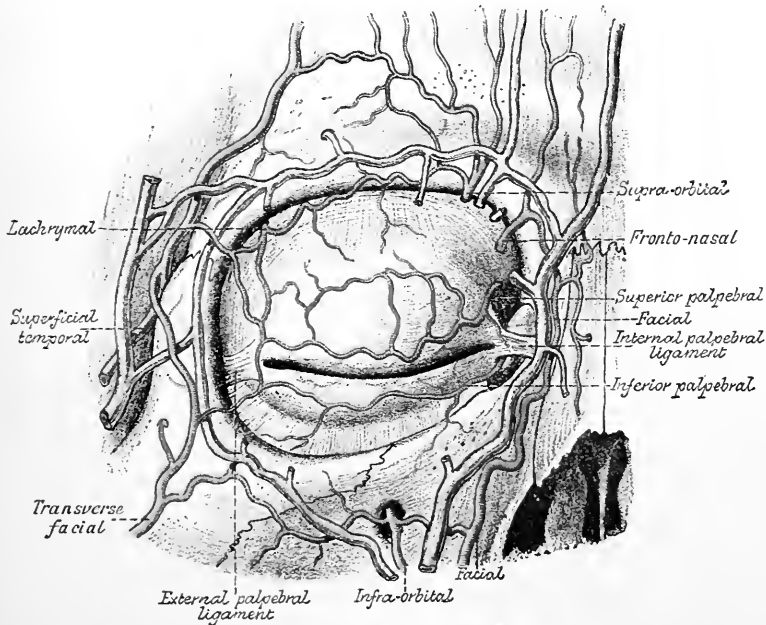
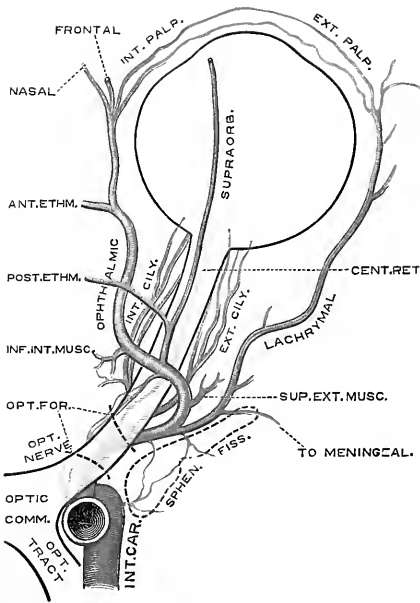


Fig. 4.—DISSECTION SHOWING THE ARTERIES AND VEINS OF THE EYELIDS. (Alter Testut.)

and the latter from its branch, the lachrymal. The *internal palpebral* are usually the larger, and consist of two vessels, a superior and an inferior, one for each lid, which they reach by piercing the palpebral fascia, one a little above and the other just below the mesial palpebral ligament (fig. 4). In the eyelid each vessel runs with a tortuous course near the free border between the tarsus and the bundles of the orbicularis, forming the so-called *tarsal arches*. At the outer side they anastomose with the *external palpebrals*, which are derived from the lachrymal. The superficial temporal and transverse facial also send branches to join this anastomotic chain at the outer part of the orbit.

In the upper eyelid there is a secondary arterial arch formed by a branch of the superior palpebral, and running just in front of the upper or attached end of the tarsus, between the tendon of the levator palpebrae and the plain muscular sheet which passes from it to join the tarsus. Sometimes there is a similar secondary arch



in the lower lid. The two arches in the upper lid are joined here and there by small anastomotic arteries. Branches pass in each lid from the tarsal arches, 1, for-

Fig. 5.—PLAN OF THE OPHTHALMIC ARTERY, SHOWING THE TYPICAL MODE OF ORIGIN OF ITS BRANCHES. (G. D. T. after Meyer.)

wards to supply the orbicularis muscle, and the integumental structures ; 2, backwards into the tarsus to supply the Meibomian glands ; and 3, backwards around the upper and lower edges of the tarsus to supply the conjunctiva palpebrarum. The *veins* of the eyelids are disposed in two series or networks. The one, *post-tarsal*, receives branches from the conjunctiva and a few from the Meibomian glands ; its blood passes for the most part into the ophthalmic vein. The other, or *pre-tarsal*, receives

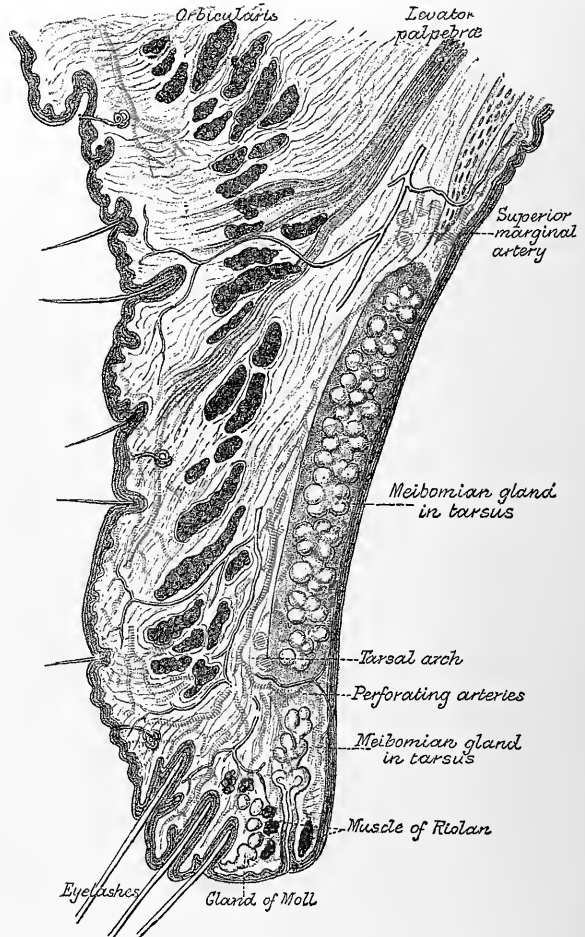
branches from the Meibomian glands and from the orbicularis and integument, below which it forms a tortuous venous plexus, with large and irregular meshes.

Fig. 6.—SECTION OF THE UPPER EYELID, WITH THE ARTERIES INJECTED. (Modified from Merkel.)

The course of the nervous twigs is also shown.

The blood from this plexus passes externally into the superficial temporal and internally into the facial vein.

Lymphatics.—There are two networks of lymphatic vessels in each eyelid, one in front of, the other behind the tarsus. The former receives lymph from the integumental and muscular structures of the lid, the latter from the Meibomian glands and conjunctiva. The networks are connected by vessels which pierce the tarsi, but less freely in the lower than in the upper eyelid. The efferent lymphatics find their way mesially along the



facial vein and its tributaries towards the submaxillary lymphatic glands, laterally into the pre-auricular and parotid lymphatic glands.

Nerves.—The levator palpebræ is supplied by the upper branch of the third nerve, the orbicularis palpebrarum by the upper branches of the facial nerve; the plain muscular tissue of the lids, like that of the orbit generally, by branches of the sympathetic.

The sensory nerves come from branches of the fifth. The upper lid is mainly supplied by the frontal and supra-orbital, the lower lid mainly by the infra-orbital branches, but at the inner or nasal part the supra- and infra-trochlear branches of the ophthalmic division come to the surface, and assist in supplying the lids and the adjacent lachrymal apparatus, whilst laterally the lachrymal branch of the

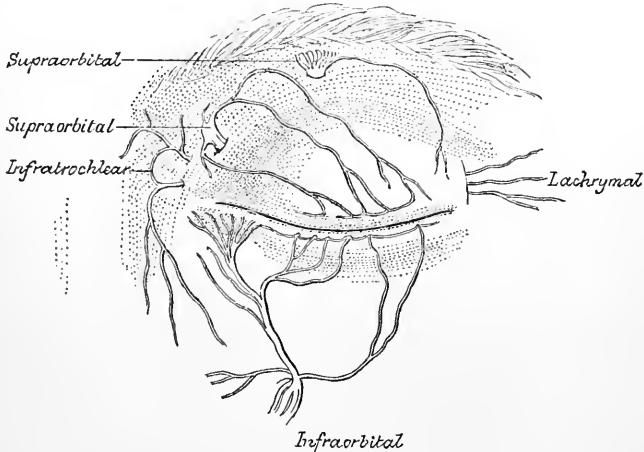


Fig. 7.—NERVES OF THE EYELIDS. LEFT EYE. (From Merkel.)

ophthalmic sends ramifications to the skin over the external angular process, some of which may pass into the upper eyelid (fig. 7).

The principal nerves run in front of the tarsi between these and the fibres of the orbicularis (fig. 6). From here their branches pass forwards to the skin and backwards, piercing the tarsi, to the Meibomian glands and conjunctiva. Near the edge of each eyelid, between the tarsus, the orbicularis, and the muscle of Riolan, is an anastomotic chain of nerve-fibres, the *marginal plexus* of Mises, from which nerves are supplied to the surrounding parts and to the hair-follicles of the eyelashes.

THE LACHRYMAL APPARATUS.

The parts which constitute the lachrymal apparatus are the following, viz. :—The gland by which the tears are secreted; the two canals which collect the fluid near the inner canthus, and the sac with the nasal duct continued from it, through which the tears pass into the inferior meatus of the nose.

The **lachrymal gland** (fig. 3, 1), an oblong flattened body, about the size of a small almond, is placed in the upper and outer part of the orbit, a little behind the anterior margin. The upper convex surface of the gland is lodged in a slight depression in the orbital plate of the frontal bone, to the periosteum of which it is united by fibrous bands; the lower surface is adapted to the convexity of the eyeball, and is in contact with the upper and the outer recti muscles. The fore part of the gland, separated from the rest by a thin layer of fascia, and sometimes described as a distinct gland (*glandula lacrymalis inferior* of Rosenmüller), is

closely adherent to the back of the upper eyelid, and is covered on the ocular surface merely by the conjunctiva; its lobules are small and separate, with minute ducts, some opening separately, others joining the ducts from the principal gland, which are also very small. The number from both divisions of the gland seldom exceeds twelve. After running obliquely under the mucous membrane, and separating at the same time from each other, they open in a row at the fornix conjunctivæ, by separate orifices, at its upper outer part.

Structure.—The lachrymal gland is a compound tubulo-racemose gland resembling the serous salivary glands in general structure. Its alveoli are bounded

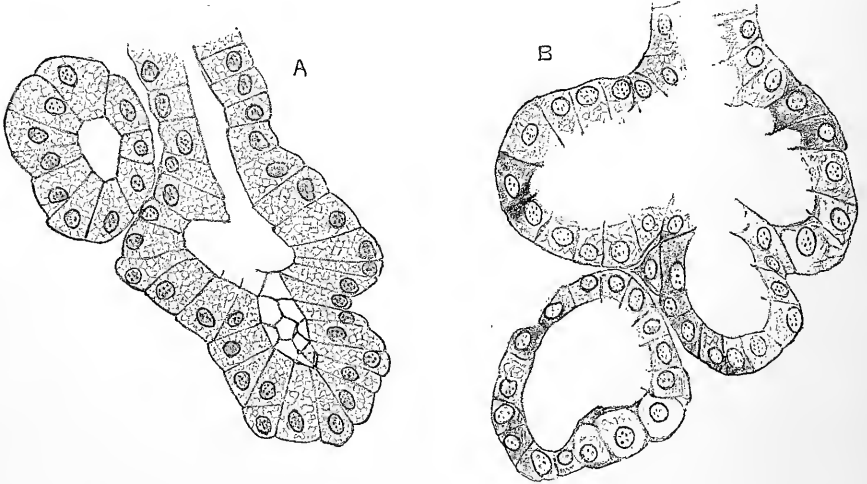


Fig. 8.—ALVEOLI OF THE LACHRYMAL GLAND OF THE DOG: A, FROM A GLAND IN THE RESTING STATE; B, FROM ANOTHER GLAND WHICH HAD BEEN SECRETING FOR THREE HOURS PREVIOUSLY. (E. A. S.) Highly magnified.

The glands were hardened in chromic and osmic solution. In A the cells are filled with the materials of secretion; in B, these are mostly discharged, and the cells are shrunken and vacuolated.

by a basement membrane formed of ramified flattened cells; and the secreting cells exhibit changes in the different states of rest and activity of the gland similar to

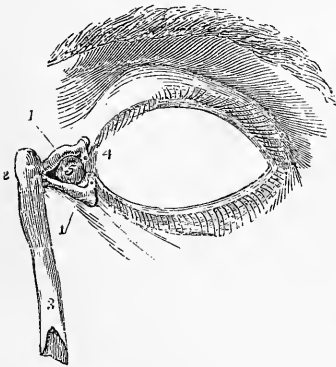


Fig. 9.—FRONT OF THE LEFT EYELIDS WITH THE LACHRYMAL CANALS AND NASAL DUCT EXPOSED.

1, 1, upper and lower lachrymal canals, showing towards the eyelids the narrow bent portions and the puncta lacrimalia; 2, lachrymal sac; 3, the lower part of the nasal duct; 4, plica semilunaris; 5, caruncula lacrimalis.

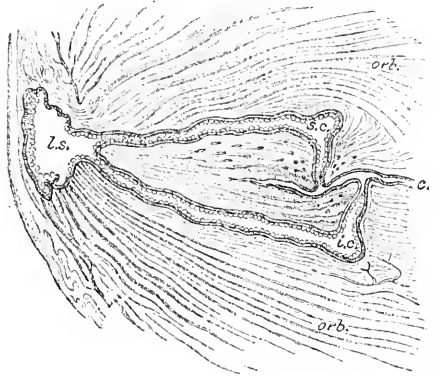
those seen in most other glands (see fig. 8 and Vol. I., Part 2, p. 396). No rod-like structure has been noticed in the epithelium of the ducts. The arteries of the gland are derived from the lachrymal, and the veins pass into the ophthalmic vein. The nerves come from the lachrymal branch of the ophthalmic and from the sympathetic.

Lachrymal canals.—These commence as already mentioned by a minute aperture (*punctum*) on the margin of each lid, near the inner angle (figs. 9, 10 and 11). The upper punctum is slightly smaller and is situated rather more mesially than the lower one. The upper canal is rather the smaller and longer of the two; it first ascends for 2 mm. from the punctum; then makes a sudden bend, and

is directed inwards and slightly downwards for 6 to 7 mm. to join the lachrymal sac (fig. 11). The lower canal descends from the corresponding punctum and then takes a nearly horizontal course inwards. Both canals are smallest at the punctum,

Fig. 10.—SECTION OF THE EYELIDS, PASSING ALONG THE LACHRYMAL CANALS. (Gerlach.) Magnified.

c., inner canthus of eye; s.c., i.e., superior and inferior canals respectively; l.s., lachrymal sac; orb., fibres of orbicularis muscle.



and here they are a little wider at the mouth than at the base of the papilla lacrimalis, where they only measure 0.1 mm. in diameter; they then become enlarged and present a further enlargement at the bend, where each has a marked dilatation, enlarging to 1 mm. diameter or more (fig. 10). The bend is sharper in the embryo than in later life.

From this the horizontal limb passes off

as a nearly cylindrical tube of about 0.6 mm. diameter, gradually narrowing to half that size. A part of the orbicularis palpebrarum (*pars lacrimalis, tensor tarsi*) runs parallel to the horizontal limbs, which are embraced by some of the muscular fibres, and when the orbicularis contracts the canals may be compressed by these fibres (Merkel). The canals either unite near their end, or they open separately, but close together, into a diverticulum of the nasal sac which is known as the *sinus of Maier*.

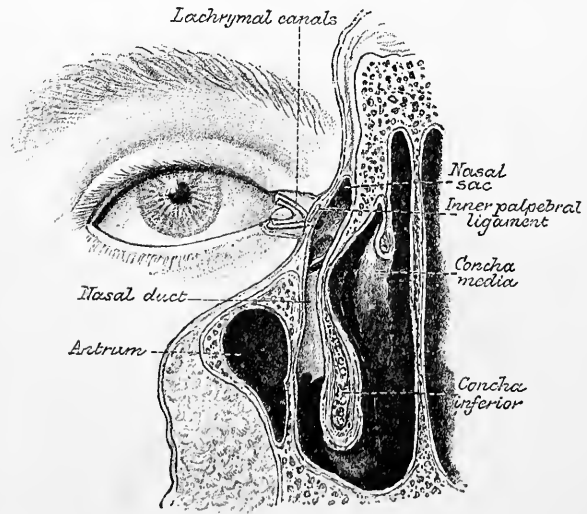
Fig. 11.—SECTION SHOWING THE COURSE AND RELATIONS OF THE NASAL SAC AND DUCT. (E. A. S., slightly modified from Merkel.)

The mucous membrane in the canaliculi is lined by a stratified scaly epithelium set on a corium rich in elastic fibres.

The **lachrymal sac** and **nasal duct** constitute together the passage by which the tears are conveyed from the lachrymal canals to the cavity of the nose.

The *lachrymal sac* (fig. 9,

2; fig. 11), the slightly dilated upper or orbital portion of the passage, is situated at the side of the nose, near the inner canthus of the eye, and lies embedded in a deep groove in the lachrymal and superior maxillary bones, from which it is separated by a thin layer of the orbital periosteum. When distended with tears it forms a distinct swelling here at the side of the nose. It is about 15 mm. long, and about 5 or 6 mm. wide, and is sometimes narrower below where it passes into the nasal duct. Its



upper end is closed and rounded, forming a cul-de-sac; the lower end gradually narrows into the nasal duct. On the outer side, and a little in front, it receives the lachrymal canals; and here it is placed behind the internal tarsal ligament, and some of the inner fibres of the orbicular muscle of the lids; while on its orbital surface is the tensor tarsi muscle. The *nasal duct*, very variable in length (12 to 24 mm.), and 3 or 4 mm. wide, grooving the upper maxilla, descends to the fore part of the lower meatus of the nose, the osseous canal being completed by the lachrymal and lower turbinate bones. Both sac and duct are composed of fibrous and elastic tissues, adhering closely to the bones above mentioned, and strengthened in the case of the lachrymal sac by a fibrous process sent from the internal tarsal ligament, which crosses it a little above its middle. The inner surface is lined by a mucous membrane, which is continuous through the canaliculi with the conjunctiva, and through the nasal duct with the mucous membrane of the nose.

At the opening into the nose the lining membrane is often arranged so as to form an imperfect valve (Hasner). Other valvular folds have been often noticed and described, but they appear to be less constant. The nasal duct is rather narrower in the middle than at either end; its direction is not quite vertical, but inclined slightly backwards. Its direction is indicated by a line joining the mesial canthus of the eyelids with the anterior edge of the first molar of the upper jaw (Testut). The lower orifice of the nasal duct is very variable in position, but is usually from 30 to 35 mm. behind the posterior margin of the anterior nasal opening (Arlt). It may open by a simple round orifice close under the inferior turbinate, or by an oblique or slit-like orifice or groove in the mucous membrane somewhat lower. In rare cases two lower openings have been described. This condition is always present in some animals (*e.g.*, dog).

The nasal sac and duct are lined by a columnar epithelium, which may be ciliated here and there, but does not appear to be covered everywhere with cilia as is the case on the adjacent mucous membrane of the nose. The lower part of the nasal duct has numerous glands similar to those in the nasal meatus into which it opens. The arteries come from the nasal and inferior palpebral. The veins are very large and numerous on the nasal duct (as in the adjacent nasal mucous membrane). The nerves are derived from the infratrochlear branch of the nasal division of the ophthalmic.

THE GLOBE OF THE EYE.

The globe or ball of the eye is supported by a quantity of fat and loose connective tissue in the fore part of the orbital cavity, somewhat nearer its lateral and inferior walls than its mesial and superior. The recti and obliqui muscles closely surround the greater part of the eyeball, and are capable of changing its position within certain limits: the lids, with the plica semilunaris and caruncle, are in contact with its covering of conjunctiva in front; and behind it receives the thick stem of the optic nerve.

The eyeball is composed of segments of two spheres, of which the anterior is the smaller and more prominent; the segment of the larger posterior opaque sphere corresponds with the limit of the sclerotic coat, and that of the smaller sphere with the cornea. The junction of the two is marked by a broad shallow groove which has been named *sulcus sclerae*.

The eyeball measures nearly an inch (24.5 mm.) across from side to side, but slightly less from before back (24 mm.), and still less from above down (23.5). It weighs about 7 grammes, and has a volume of about 6.5 cubic centimetres.

Except when directed towards near objects, the axes of the eyes are nearly parallel; the optic nerves, on the contrary, diverge considerably. Each nerve enters the corresponding eye about 2 to 3 mm. to the inner or nasal side of the axis of the eyeball.

The eyeball consists of three concentric coats, and of certain fluid and solid parts enclosed by them. The coats are (1) an external fibrous covering, forming the *sclerotic (tunica sclera)* and *cornea*, (2) a middle vascular, pigmented, and in part also muscular membrane, the *choroid* and *iris (tunica uvea)*, and (3) an internal nervous and epithelial stratum, the *retina*. The enclosed refracting media, three in number, are the *aqueous humour*, the *vitreous body*, and the *lens*.

Around the posterior two-thirds of the eyeball there is a tunic of fascia, *tunica vaginalis oculi*, or *capsule of Tenon*, which is perforated by the tendons of the recti

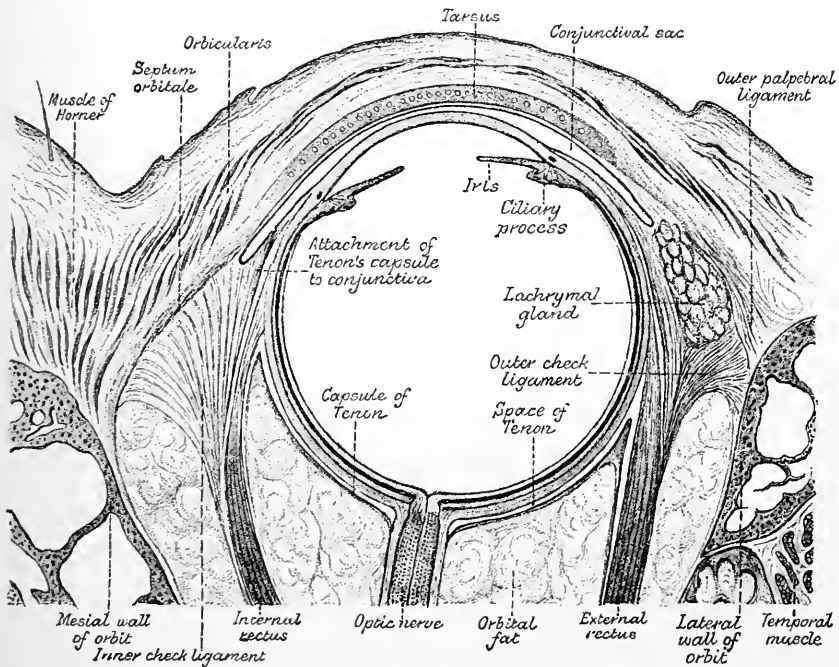


Fig. 12.—HORIZONTAL SECTION OF ORBIT. (After Gerlach.) Magnified.

and obliqui muscles, along which it sends sheaths which blend with the perimysium of the muscles (figs. 12 and 13). It is connected with the sclerotic by delicate connective tissue (*adventitia oculi*, Lockwood), except posteriorly, at the entrance of the ciliary vessels and nerves, where it blends with the sclerotic. Anteriorly the capsule of Tenon is continued into the conjunctiva. This capsule is lined by flattened endothelial cells, and encloses a lymph-space, which separates the eyeball from the orbital fat. It is strengthened just behind the places where the recti muscles perforate it, by bands of fibrous tissue (figs. 12 and 13,) and it is attached on either side to the malar and lachrymal bones by elastic ligamentous structures, which also receive fibrous slips from the internal and external recti. These structures serve as check-ligaments (fig. 12) to these muscles. They are stated by Sappey to contain plain muscular fibres. Fibrous slips also pass from the sheaths of the superior and inferior rectus, and are attached to the conjunctiva palpebrarum and

to the connective tissue of the eyelid (fig. 13). Below and in front of the anterior end of the inferior rectus the capsule is strengthened by a band of fibrous tissue, which is stretched like a sling from one side of the orbit to the other, and is inserted at its ends to the lachrymal and malar bones. This band—the *ligamentum*

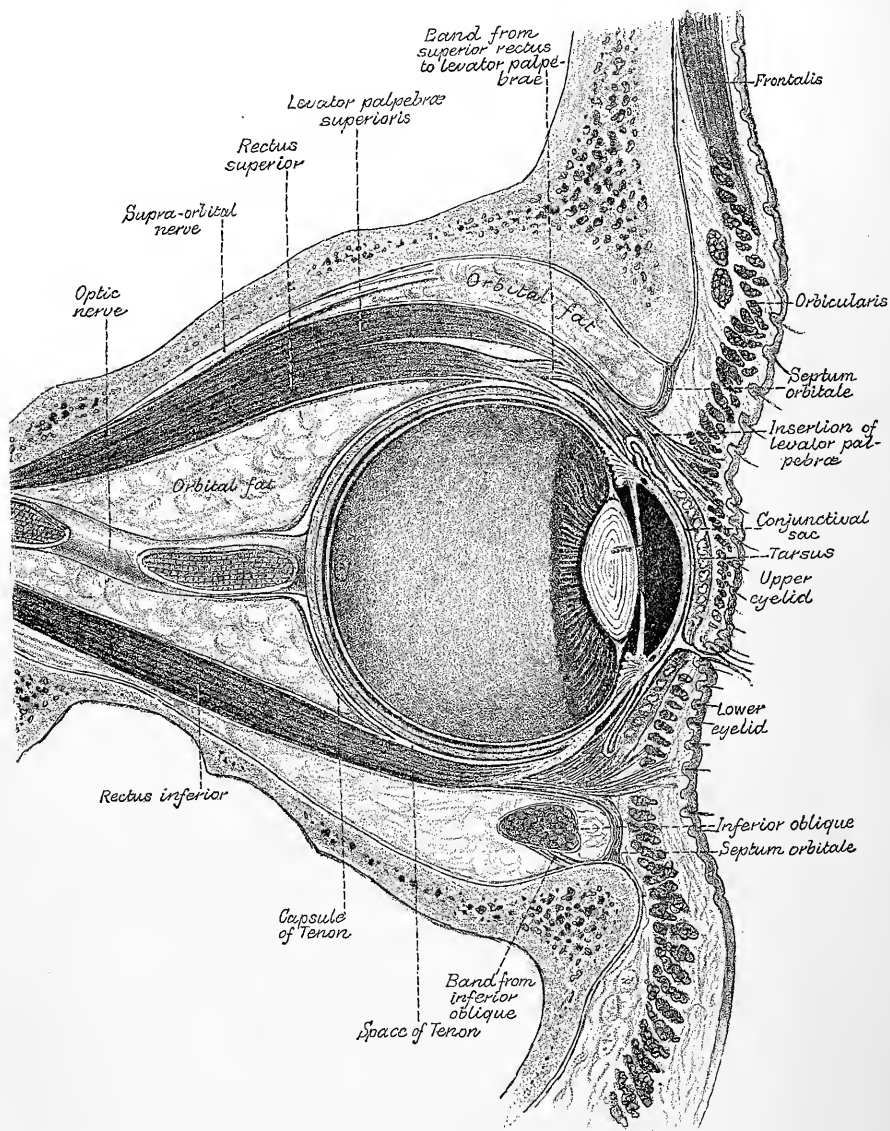


Fig. 13.—SAGITTAL SECTION THROUGH THE MIDDLE OF THE GLOBE OF THE EYE WITHIN THE ORBIT. (E. A. S., from a figure by Merkel, enlarged and modified.)

suspensorium oculi of Lockwood—serves to aid in maintaining the eye in position ; it is joined anteriorly with the tarsus of the lower lid (see fig. 13). Lastly, another band passes from the anterior border of the sheath of the inferior oblique muscle forwards, downwards, and outwards, to be attached to the lateral part of the lower border of the orbit (fig. 13). For further details regarding these structures consult

Lockwood, *Journal of Anatomy and Physiology*, 1885; Merkel, *Handbuch der topograph. Anatomie*; and Testut, *Traité d'Anatomie*. See also Vol. II., p. 292

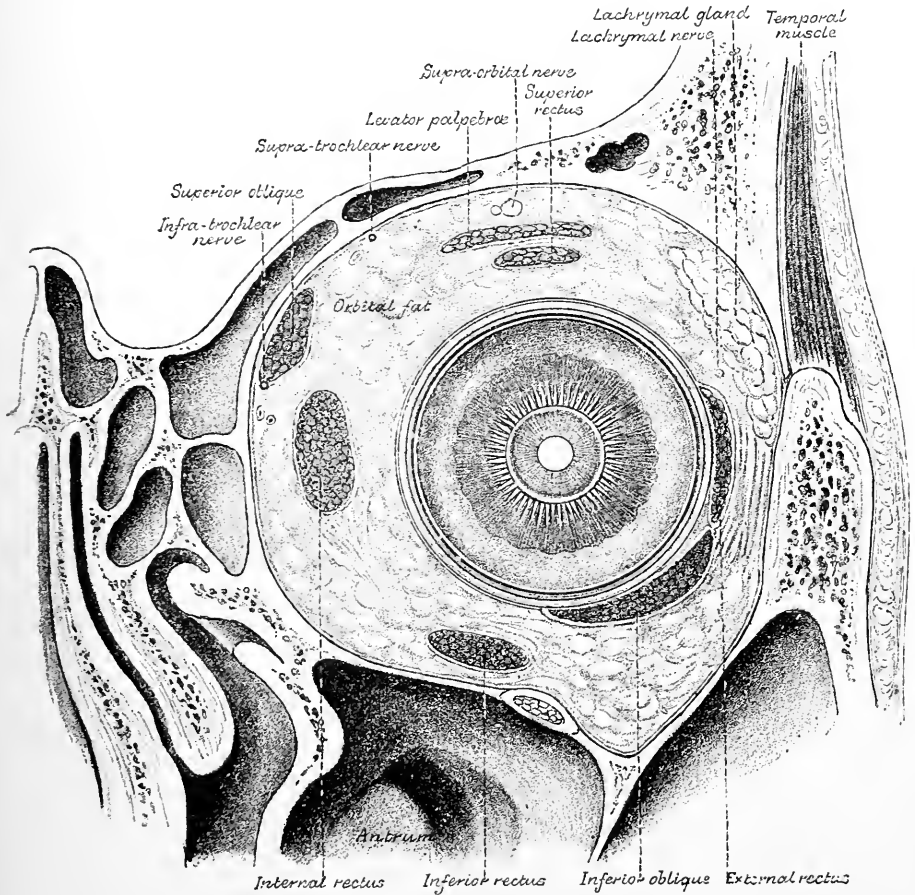


Fig. 14.—CORONAL SECTION THROUGH THE RIGHT EYE AND ORBIT.
(E. A. S., from a figure by Merkel, enlarged and modified.)

THE SCLEROTIC COAT.

The **sclerotic coat**, the tunic of the eye on which the maintenance of the form of the organ chiefly depends, is a strong, opaque, fibrous structure. It extends over the greater part of the eye-ball (fig. 15) joining in front with the cornea. The outer surface is white and smooth, except where the tendons of the recti and obliqui muscles are inserted into it. In the child the eyeball has a bluish white colour, from the fact that the dark pigment of the choroid shows through the sclerotic coat (which is thinner in the child). The inner surface is brown, and rough from the presence of a delicate pigmented connective tissue (*lamina fusca*), which is united by fine threads with the choroid coat. These filaments traverse a lymphatic space through which branches of the ciliary vessels and nerves also pass obliquely. The sclerotic is thickest at the back part of the eye, at the entrance of the optic nerve, where it is nearly 1 mm. thick, and thinnest (0.4 mm.) at about 6 mm. from the cornea: near the junction with the latter, it is again

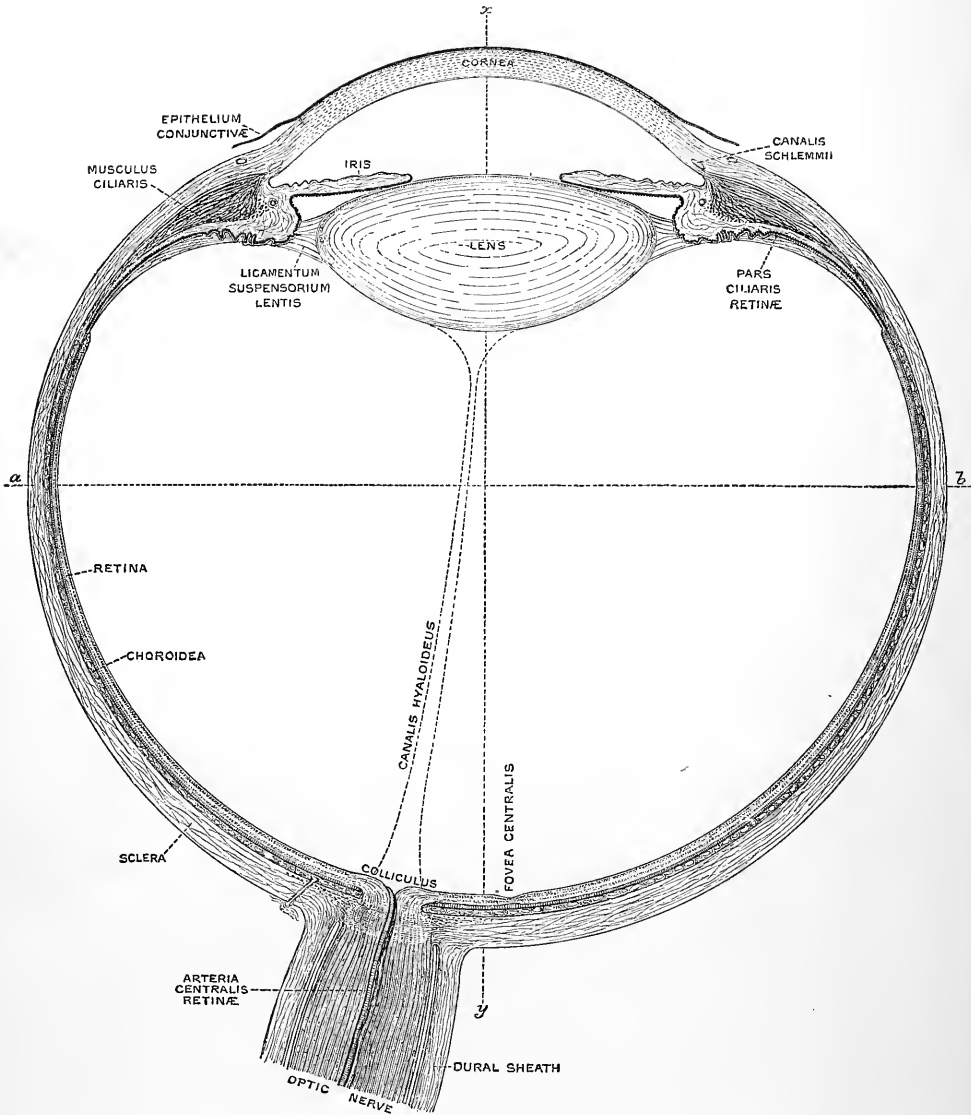


Fig. 15.—DIAGRAM OF THE RIGHT ADULT HUMAN EYE, DIVIDED NEARLY HORIZONTALLY THROUGH THE MIDDLE. (E. A. S.) Magnified five times.

The line *a b* passes through the equator, *x y* through the visual axis of the eye.

The figure has been drawn, as far as possible, to scale, the following being taken as the average measurements of the parts of the adult eye in millimeters:—

Transverse diameter of the eyeball	24·5
Vertical diameter	23·5
Antero-posterior diameter	24·0
Greatest thickness of the sclerotic, choroid, and retina together	1·4
Greatest thickness of the sclerotic posteriorly	0·8
Thickness of the sclerotic at the equator	0·4
Thickness of the cornea in the centre	0·8
Distance from the middle of the anterior surface of the cornea to the front of the lens	3·4
Antero-posterior diameter of the lens	4·0

Transverse ditto	9.1
Greatest thickness of the ciliary body	1.1
Thickness of the iris	0.4
Length of the radius of curvature of the anterior surface of the cornea	7.8
Radius of the posterior surface of the sclerotic	12.5
Radius of curvature of the anterior surface of the lens	10.0
Radius of the posterior surface	6.0
Distance of the middle of the posterior surface of the lens from the middle of the retina	15.0
Distance between the centre of the spot of entrance of the optic nerve and the middle of the fovea centralis retinae	3.5

somewhat thickened owing to the attachment and spreading over it of the tendons of the ocular muscles. The optic nerve pierces this coat about 2.5 to 3 mm. in-

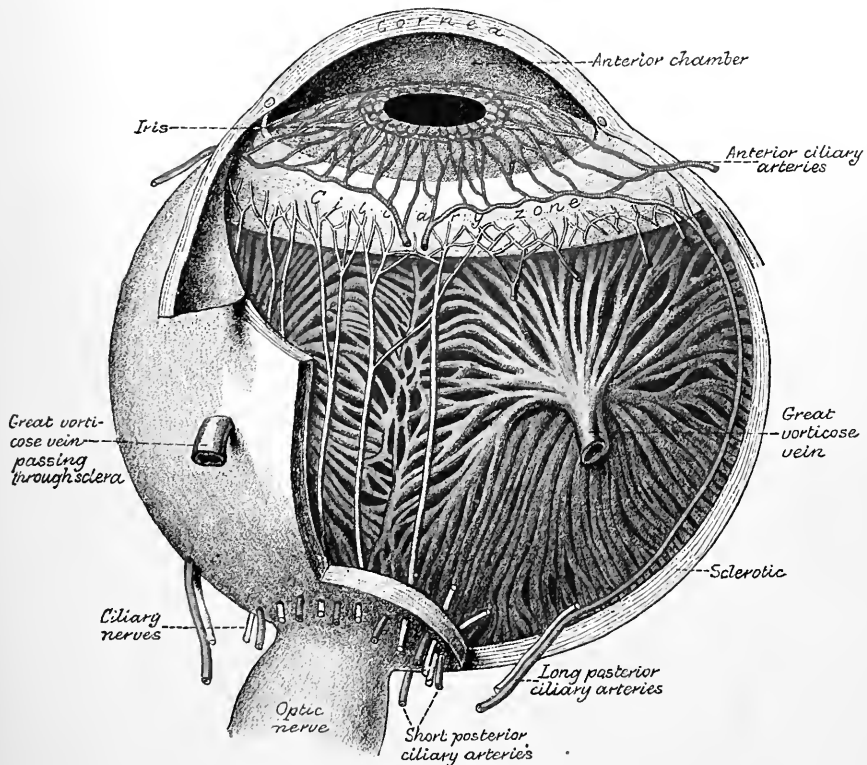


Fig. 16.—DIAGRAM SHOWING THE PRINCIPAL NERVES AND BLOOD-VESSELS OF THE EYEBALL. (Testut.)

ternal to the posterior pole of the eyeball, and about 1 mm. below a horizontal plane passing through the poles; the opening is somewhat smaller at the inner than at the outer surface of the coat. The outer fibrous sheath of the nerve blends with the sclerotic at the margin of the aperture: in consequence of this arrangement, when the nerve is cut off close to the eyeball, the funiculi seem to enter by a group of pores; and to the part of the sclerotic thus perforated the name of *lamina cribrosa* is given. Around this cribrous opening are smaller apertures for the posterior ciliary arteries and the ciliary nerves. These are disposed in the manner shown in the accompanying diagram (fig. 16). Nearer the equator of the globe the sclerotic is pierced by four apertures which transmit veins (*venæ vorticosæ*).

Structure of the sclerotic.—The sclerotic coat is formed of bundles of connective-tissue fibres, and yields gelatine on boiling. Its white fibres are combined with fine elastic elements, and amongst them lie numerous connective-tissue corpuscles lodged in cell-spaces, but not by any means so regularly arranged as in the cornea. Some of the cells are pigmented. The bundles are disposed in layers both longitudinally and transversely, the longitudinal arrangement being most marked behind and at the surfaces, the transverse or circular near the corneal margin. The layers communicate at intervals so as not to be separable for any distance.

Both externally and internally the sclerotic is covered with flattened endothelial cells, which are reflected over the muscles, vessels, nerves, and connecting bands of tissue which pass from it to the capsule of Tenon and the choroid coat respectively. The lamina fusca resembles in structure the lamina suprachoroidea of the choroid coat (p. 25).

The anterior zone of the sclerotic from about the line of attachment of the tendons of the recti muscles forwards to the cornea, is covered by the conjunctiva

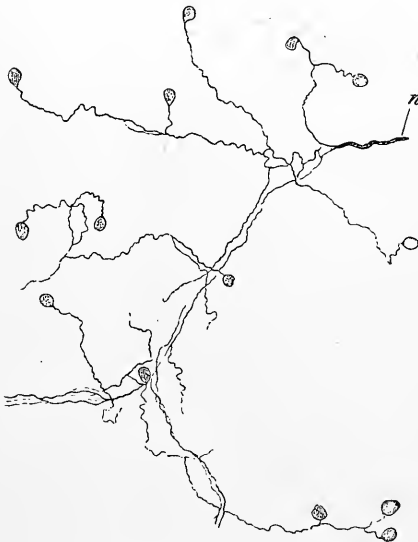

Fig. 17. —TERMINATION IN END-BULBS OF THE NERVES OF THE CONJUNCTIVA. (Longworth.)

which is reflected on to the globe from the eyelids, and which is connected with the sclerotic by loose areolar (subconjunctival) tissue. This part of the conjunctiva is formed of somewhat dense connective tissue covered by a stratified epithelium of some thickness. It is a fairly vascular membrane, and contains a network of lymphatics, which begin at the edge of the cornea by tapering capillaries. Its nerves are mostly medullated: some pass towards the cornea, others end in the membrane itself, many in end-bulbs (W. Krause).

A few blood-vessels derived from the short ciliary and the anterior ciliary arteries, permeate the fibrous texture in the form of a network of capillaries with very wide meshes. Those from the anterior ciliary emerge from under the tendons of the recti muscles, dividing into branches as they pass towards the margin of the cornea. Before reaching this, however, they dip into the substance of the sclerotic, and they here take on a radial disposition in the thickness of that coat. Other vessels derived from the posterior ciliary arteries form a wide-meshed network at the surface of the sclerotic in its posterior three-fourths, and like those from the anterior ciliary communicate freely with deeper vessels in the substance of the membrane. At the posterior part of the sclerotic its vessels are continuous with those of the dural sheath of the optic nerve. Around this nerve the scleral branches of the posterior ciliary arteries form an arterial circle (*circulus Zinnii*), which gives branches to the optic nerve and choroid as well as to the sclerotic. The vessels of the conjunctival membrane, which are derived from the palpebral and lachrymal arteries, are readily distinguishable from those of the subjacent sclerotic by their more tortuous course, and by the fact that they shift upon the globe when the conjunctiva is pulled upon. Near the edge of the cornea they communicate with

the episcleral vessels derived from the anterior ciliary. Veins corresponding with the arteries run in and beneath the conjunctiva, and there is a well-marked episcleral plexus of veins behind the junction of the cornea and sclerotic. The veins convey their blood to the anterior ciliary and the vorticosae veins of the choroid. The sclerotic receives fibres from the ciliary nerves, but it is not certainly known how they terminate.

Hannover described the sclerotic as being traversed in its thickness, opposite the fovea centralis of the retina, by a strand of fibrous tissue, which unites the laminae as it passes through them (*funiculus sclerae*). According to Schwalbe the strand thus described is merely connective tissue which accompanies the most lateral group of posterior ciliary arteries as they pierce the sclerotic.

THE CORNEA.

The **cornea**, the transparent fore part of the external coat, admits light into the interior of the eyeball. It is nearly circular in shape, but is slightly wider in the transverse than in the vertical direction (about 12 mm. and 11 mm. diameter respectively); its arc extends to about one-sixth of the circumference of the whole globe. The cornea has a curvature of a smaller radius than the sclerotic: the degree of its curve varies, however, in different persons, and at different periods of life in the same person, being more prominent in youth than in advanced age. It is also normally a trifle more curved in the vertical than in the horizontal plane. Its thickness is in general nearly the same throughout, viz., 0·8 mm., excepting towards the periphery, where it becomes somewhat thicker (1·1 mm.) The posterior concave surface exceeds slightly in extent the anterior or convex, in consequence of the latter being encroached on by the superficial part of the sclerotic; the cornea being overlapped by the sclerotic like a watch-glass by the edge of the groove into which it is received (see fig. 15); the tissues of the two are, however, in complete continuity. Around the junction a slight groove is apparent in the surface of the globe (*sulcus sclerae*). The tissue of the cornea readily imbibes water and becomes opaque after death.

STRUCTURE OF THE CORNEA.

The cornea may be described as consisting of three parts—a stratified epithelium in front (fig. 19, 1) continuous with the epithelium of the conjunctiva; a middle part, substantia propria, or cornea proper (3), continuous with the sclerotic, composed of modified connective tissue; and a homogeneous elastic lamella (4), bounding it behind, and itself covered with a simple layer of endothelium cells (5).

Epithelium of the Cornea.—The epithelium covering the front of the cornea is of the stratified kind, the cells being in man six to eight deep (fig. 18). The lowermost cells (*c*) are columnar, with a flattened base, where they rest on the substantia propria, and a rounded apex, upon which a cell of the next layer fits. To the base of each columnar cell is attached a broad, flattened, strongly refracting process, which projects under one of the neighbouring cells (not shown in the figure). Above these columnar cells are two or three layers of polygonal cells, some of the deeper of which (the *fingered cells* of Cleland) have projections from their under surface which fit between the cells below. These polygonal cells (*p*) have well-marked denticulations, which join one another across the intercellular spaces which separate the cells. Quite superficially is a stratum of flattened scaly epithelium cells, which retain their nuclei.

The **proper substance** of the cornea is composed, as before said, of a modified form of connective tissue, all the constituents of which have very nearly the same

index of refraction, so that in the perfectly fresh condition it is difficult, even with the best lenses, to make out any indications of structure. After death, however, and with the assistance of reagents, the cornea may be ascertained to consist of alternating lamellæ of fibrous tissue (about sixty in number, according to Bowman), the planes of which are parallel to the surfaces of the cornea. The fibres composing the lamellæ are nearly straight and have a definite direction in each layer; they cross one another at right angles in the alternate layers (fig. 19, *b, d*). It must, however, be understood that the layers are not individually distinct, but give off frequent offsets to those above and below, so that they cannot readily be stripped away for any distance. The fibrils are collected into roundish bundles, which, as

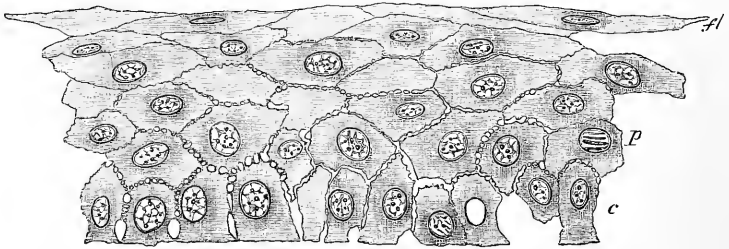


Fig. 18.—VERTICAL SECTION THROUGH THE EPITHELIUM OF THE CORNEA, HUMAN. (E. A. S.)
Highly magnified.

c, deepest columnar cells; *p*, polygonal cells, immediately above them; *f*, flattened cells of the surface.

The section is slightly broken on the right of the figure. The intercellular channels bridged across by processes extending from one cell to another are distinctly seen.

well as the laminae they form, are, as in the connective tissue elsewhere, separated from each other by ground-substance. The latter is in greater abundance between the fibrous strata than elsewhere, and in these parts the cell-spaces of the tissue are found. These cell-spaces, which are readily demonstrated by staining the tissue with nitrate of silver (fig. 20, B), are flattened conformably with the lamellæ, are of an irregularly stellate figure, and freely communicate by their offsets both with others on the same plane and with those above and below. The greater regularity of arrangement which characterises them, as compared with the cell-spaces of connective tissue elsewhere, is dependent on the regularly laminated structure of the cornea.

The corpuscles of the tissue—*corneal corpuscles* (fig. 20, A)—lie within the cell-spaces, corresponding generally with them in form, but without entirely filling them, the room left serving for the passage of lymph and lymph-corpuscles. The protoplasm of the corpuscles is clear, except in the neighbourhood of the nucleus, where it is more granular; the cells send branching processes along the anastomosing canals of the cell-spaces, which join with those of neighbouring corpuscles. In vertical sections the corpuscles appear fusiform (fig. 19, *c*), but horizontal sections show them to be flattened conformably with the surface.

The cell-spaces can be filled with fluid injection by inserting the nozzle of a fine syringe into the tissue, and employing a very low pressure; in this way a network of anastomosing stellate figures is obtained (cell-spaces, Recklinghausen's canals). If, however, the injection-fluid is dense or too forcibly injected, it becomes extravasated in the interstices of the fibril-bundles, the direction of which it takes; and the appearance is produced of minute swollen tubular passages running at right angles to one another in the different layers (Bowman's corneal tubes). This appearance may still more readily be obtained if air is injected into the tissue instead of mercury (the fluid used by Bowman), and it is seen

that the injection always stops at the margin of the cornea, where the tissue becomes closer as it passes into the sclerotic, whereas Recklinghausen's canals are continued into the cell-spaces of the sclerotic.

Frequently in advancing age there occurs a deposit of fatty granules at the margin of the cornea, forming a whitish opaque ring about 1mm. from the corneo-sclerotic junction. This ring is known as the *arcus senilis*.


Fig. 19.—VERTICAL SECTION OF HUMAN CORNEA FROM NEAR THE MARGIN. (Waldeyer.) Magnified.

1, epithelium; 2, anterior homogeneous lamina; 3, substantia propria corneae; 4, posterior homogeneous (elastic) lamina; 5, endothelium of the anterior chamber; *a*, oblique fibres in the anterior layer of the substantia propria; *b*, lamellae the fibres of which are cut across, producing a dotted appearance; *c*, corneal corpuscles appearing fusiform in section; *d*, lamellae the fibres of which are cut longitudinally; *e*, transition to the sclerotic, with more distinct fibrillation, and surmounted by a thicker epithelium; *f*, small blood-vessels cut across near the margin of the cornea.

Membrane of Bowman.—The part of the cornea immediately beneath the anterior epithelium, for a thickness of 0·01 mm. to 0·02 mm., is denser than the rest of the tissue, and entirely free from corpuscles (fig. 18, 2), (*anterior homogeneous lamina, membrane of Bowman*). Although described as a separate formation it appears not

to differ materially in structure from the rest of the corneal substance, fibres from which may be seen passing obliquely towards, and becoming lost within it (fig. 19, *a*). It is thickest in the middle, thinning off gradually towards the edges of the cornea.

The **membrane of Descemet** (fig. 19, 4) (*membrane of Demours, posterior elastic lamina, Bowman*), not very closely united with the fibrous part of the cornea, is transparent and glassy in appearance. It is firm and structureless, but very elastic; and when shreds are removed from it they tend to curl up with the attached surface innermost. It is not readily affected by acids, by boiling in water, or by maceration in alkalis, but under some conditions it can be split up into very fine lamellae. In thickness it varies from 0·006 mm. to 0·012 mm., being thinnest in the middle and thickening towards the margin. Here also there are



apt to develop, in adult age, low papilliform projections on the inner surface of the membrane; with old age these become more marked and the whole membrane becomes thicker, and may measure as much as 0.02 mm. It is lined next the anterior

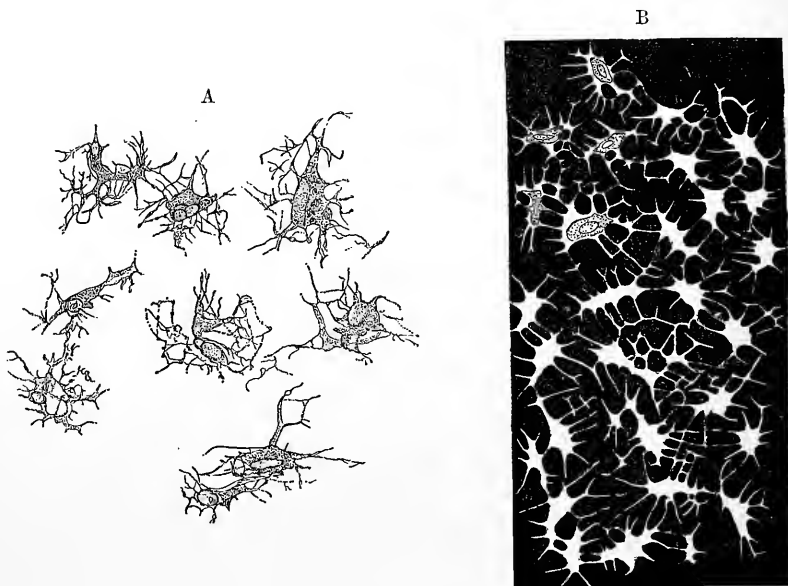


Fig. 20.—A. CORPUSCLES OF THE CORNEA. FROM A PREPARATION TREATED WITH CHLORIDE OF GOLD. (Waldeyer.)
 B. CELL-SPACES OF THE CORNEA. FROM A PREPARATION STAINED WITH NITRATE OF SILVER. (Waldeyer.)

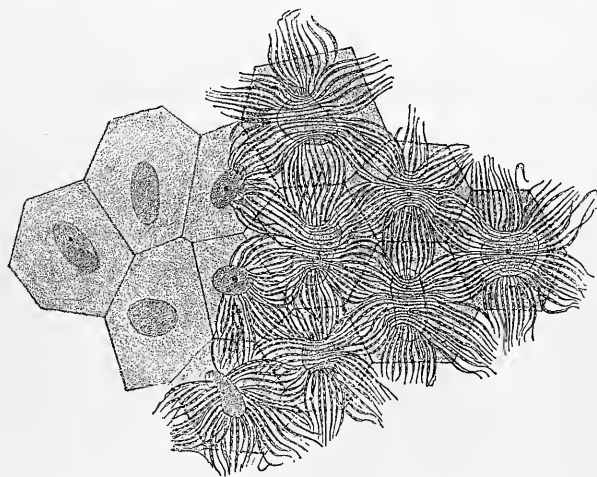


Fig. 21.—CELLS OF ENDOTHELIUM OF BIRD'S CORNEA. (After Smirnow and Nuël.)

chamber with an endothelium (fig. 19, 5), which resembles that on serous membranes, consisting of a single layer of flattened polygonal cells with distinct nuclei. These cells are fibrillar in structure, being traversed by bundles of fine fibrils which pass from cell to cell across the intercellular spaces (fig.

21), and are probably formed by threads of protoplasm, for they undergo rapid alteration, and very soon disappear after death or removal of the globe. (Nuël, Smirnow.)

Near its circumference the membrane breaks up into bundles of fibres, which give attachment to the ciliary muscle (see fig. 22), but a few fine fibres are continued into the substance of the iris, around the angle of the anterior chamber. To these radiating and anastomosing bundles of elastic fibres prolonged from the circum-

ference of Descemet's membrane, the name *ligamentum pectinatum* was given by Hueck. They are sometimes known as the pillars of the iris. The fibres which pass to the iris are very much more marked in the eyes of the sheep and the ox than in the human eye. The bundles of the ligamentum pectinatum are covered with endothelial cells, continued from Descemet's membrane, but these cells do not stretch across the *intervals* between the bundles, so that the cavity of the aqueous chamber is prolonged into, and freely communicates with spaces in the tissue

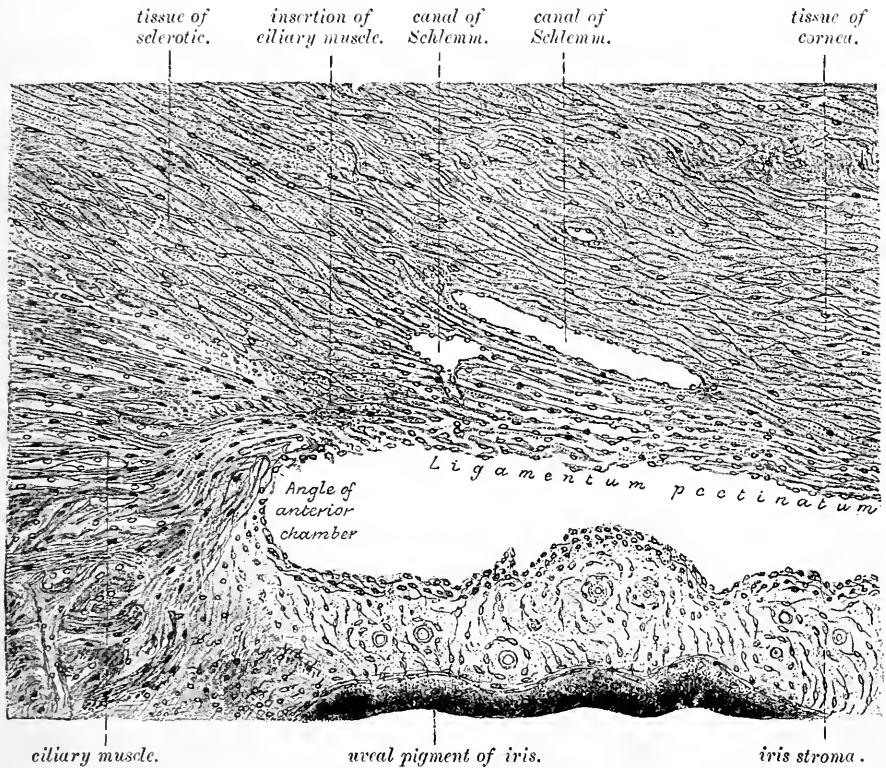


Fig. 22.—SECTION (FROM THE EYE OF A MAN), SHOWING THE RELATIONS OF THE CILIARY MUSCLE TO THE SCLEROTIC, IRIS, AND THE CAVERNOUS SPACES NEAR THE ANGLE OF THE ANTERIOR CHAMBER. (E. A. S.)

The figure, which is copied from a photograph, includes only a small portion of the ciliary muscle, the fibres of which are seen to be converging to a point immediately anterior to the angle of the anterior chamber. Here they are attached through the medium of a tongue of fibrous tissue of the sclerotic (consisting mainly of circular bundles) to the outer part of the ligamentum pectinatum, which forms a loose tissue with open meshes lying between the canal of Schlemm and the anterior chamber. To the right of the figure the fibres of the ligamentum pectinatum are seen to be gradually converging towards the posterior surface of the cornea, and somewhat beyond the part shown in this figure they merge into the membrane of Descemet. The communication of the canal of Schlemm, which is double in this section, with the endothelial-lined spaces in the ligamentum pectinatum, is seen, as also the communications between the last-named spaces and the anterior chamber.

between the bundles (fig. 22). These spaces are much larger and more distinct in some animals than in man, and in them they have received the name of *spaces of Fontana*. A similar, but rather larger space is found immediately in front of the ligamentum pectinatum in the substance of the sclerotic, close to its junction with the cornea. This circular space, which is elliptical in section, is known as the *sinus circularis iridis*, or *canal of Schlemm* (fig. 22, 4).

The canal of Schlemm is often double (fig. 22); it communicates with the spaces between the fibres of the ligamentum pectinatum, and through these with the aqueous chamber of the eye. But, on the other hand, the canal of Schlemm, and the other cavernous spaces in its neighbourhood, are in communication with the *veins* of the anterior part of the sclerotic, and therefore the aqueous chamber must also through them communicate with the veins. In support of this, it was found by Schwalbe that both the spaces and the veins became filled with coloured fluid when this had been injected into the anterior chamber. Why blood does not find its way into the latter during life is not explained, since no valves have as yet been discovered in these veins or spaces: the reason given being, that greater resistance is offered to its passage here than to its return by the ordinary paths.

According to Leber, on the other hand, the results obtained by Schwalbe were due to a diffusible colouring matter having been employed for filling the anterior chamber. Leber affirms that when a non-diffusible one is used it never penetrates into the canal of Schlemm, which is simply a large circular terminal vein, or a collection of two or three plexiform veins uniting at frequent intervals into one trunk. It is admitted, however, that fluid may pass with extreme readiness from the anterior chamber into these veins.

The study of the development of the eye shows that the loose tissue in which the spaces of Fontana occur, as well as the endothelium of Descemet's membrane and the membrane itself, belong to a vascular layer of mesoblast which is continuous with the choroidal layer of the embryonic eye, but which as development proceeds, becomes separated from the vascular layer of the choroidal coat (iris and pupillary membrane), owing to the formation of the anterior chamber; it then comes to form part of the cornea.

Vessels and nerves.—In a state of health the cornea is not provided with blood-vessels, except at the circumference, where the capillaries of the conjunctiva

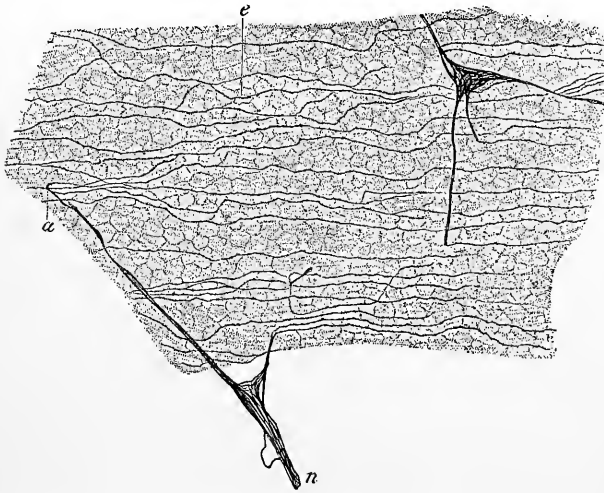


Fig. 23.—CORNEA OF RABBIT, VIEWED ON THE FLAT, SHOWING THE SUBEPITHELIAL PLEXUS; CHLORIDE OF GOLD PREPARATION. (Ranvier.)

n, nerve of fundamental plexus, giving off pencils of fibrils, *a*, to form the subepithelial plexus, *e*.

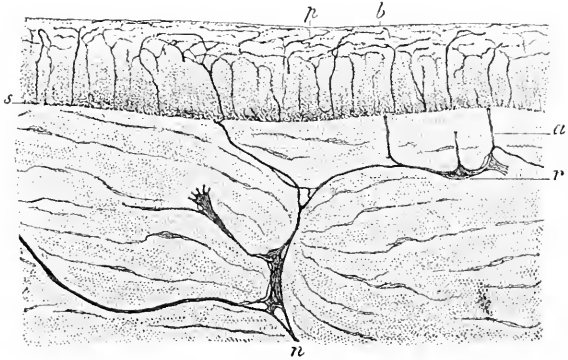
and sclerotic end in loops. Neither are any lymphatic vessels discoverable, unless the channels in which the nerves run, and which are lined with flattened cells and are indirectly in connection with the cell-

spaces, are to be taken as representing them. The *nerves*, on the other hand, are very numerous. Derived from the ciliary nerves, they enter the fore part of the sclerotic, and are from forty to forty-five in number (Waldeyer), forming a plexus which surrounds the margin of the cornea (*plexus annularis*). Continued into the fibrous part of the cornea, partly directly, partly by passing to the adjacent conjunctiva, they retain their medullary sheath for 1 to 2 mm., and then, becoming non-medullated, ramify and form a plexus in the laminated structure, near the anterior surface. From this *fundamental plexus* branches pass obliquely through the anterior homogeneous lamina, where they divide into pencils of fibrils, whose general direction is towards the centre of the cornea, and which join with one another to form a much finer and closer plexus immediately beneath the epithelium. From this *subepithelial plexus* fine, varicose, fibrils pass among the epithelium-cells, and form here a terminal ramification which extends almost to the free surface (figs. 23, 24, and 25).

In addition to the nerves which are destined for the epithelium, others, for the proper substance of the cornea, come off from the primary plexuses, and, after uniting into one or more secondary plexuses, the cords of which are still composite, eventually form, in and among the laminae, a terminal ramification of ultimate fibrils, the meshes of which are much more open than those of the intra-epithelial network (see fig. 25). An actual connection of these nerves with the

Fig. 24.—VERTICAL SECTION OF RABBIT'S CORNEA, CHLORIDE OF GOLD PREPARATION. (Ranvier.)

n, r, parts of fundamental plexus; *a*, vertical branch passing to sub-epithelial plexus, *s*; *p, b*, inter-epithelial ramification.

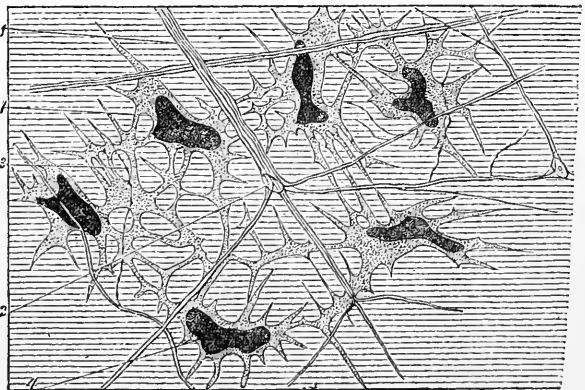


corpuscles of the cornea probably never occurs; although, since the fine nerve-fibrils run in the anastomosing cell-spaces, they come into close connection with the corpuses and their processes, and they have therefore been described by some observers as being actually continuous with the latter.

The larger branches of the nerves are covered with a sheath of flattened cells which, as before mentioned, are in connection with the corpuses of the cornea. At

Fig. 25.—CORPUSCLES AND NERVES IN THE SUBSTANTIA PROPRIA OF THE CORNEA OF THE FROG; CHLORIDE OF GOLD PREPARATION. (Waldeyer.)

1, bundle of fundamental plexus; 2, nucleus; 3, terminal fibril; 4, corneal corpuses.



the points of junction of the plexuses nuclei are frequently seen (fig. 25, 2), but these appear to belong to the ensheathing cells, and are not interpolated in the course of the fibres.

THE VASCULAR COAT.

The vascular coat of the eye (*tunica uvea s. vasculosa*) lies within the corneo-sclerotic coat, and consists of two parts, which are continuous with one another, viz., the choroid and iris. The choroid is applied to the inner surface of the sclerotic, and the retina is firmly attached to its inner surface; the iris is attached only at its circumference, otherwise floating freely in the aqueous humour immediately in front of the lens, with which it comes lightly into contact, and separated from the cornea by the depth of the anterior chamber.

The **choroid coat** (*tunica choroidea*) is a dark brown membrane (black in most animals) lying between the sclerotic and the retina. Anteriorly it is continued into the iris, but before it passes into this it forms a number of radial thickenings named *ciliary*

processes, disposed in a circle and projecting into the anterior part of the vitreous humour. These give attachment to the suspensory ligament of the lens. The choroid coat is thickest behind, where it is pierced by the optic nerve. The outer surface is connected to the sclerotic by loose connective tissue and by vessels and nerves which pass obliquely across a lymph-space which otherwise serves to separate

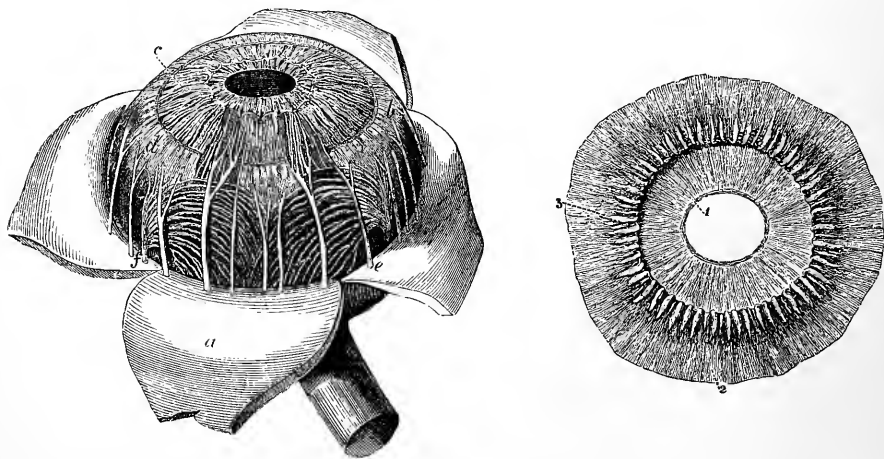


Fig. 26.—CHOROID MEMBRANE AND IRIS EXPOSED BY THE REMOVAL OF THE SCLEROTIC AND CORNEA. (After Zinn.) Twice the natural size.

a, part of the sclerotic thrown back; *b*, ciliary muscle; *c*, iris; *e*, one of the ciliary nerves; *f*, one of the vasa vorticosa or choroidal veins.

Fig. 27.—CILIARY PROCESSES AS SEEN FROM BEHIND. Twice the natural size.

1, posterior surface of the iris, with the sphincter muscle of the pupil; 2, anterior part of the choroid coat; 3, ciliary processes.

the two tunics. The inner surface, which is smooth, is covered by the hexagonal pigmented cells of the retina. These, when the retina is detached, generally remain partly adherent to the choroid, and were formerly described as belonging to that coat, but they are now known to be intimately related, both morphologically and physiologically, to the retina. The ciliary part of the choroid with the ciliary processes is often spoken of as the ciliary body (*corpus ciliare*).

The *ciliary processes* (fig. 27), about seventy in number, are arranged meridionally, and together form a circle. They consist of larger and smaller thickenings without regular alternation. Each of the larger ones, measuring about 2·5 mm. in length and 0·6 mm. in depth, forms a rounded projection at its inner (anterior) end, which is free from the pigment which invests the rest of the structure; but externally they gradually taper, and become lost. The smaller processes are only half as deep as the others, and about one-third as numerous. At and near the inner ends the processes are connected by lateral projections.

Structure of the Choroid.—The choroid consists mainly of blood-vessels united by delicate connective tissue, which contains numerous large ramified and pigmented cells.

Externally the choroid is bounded by a non-vascular membranous layer similar to the *lamina fusca* of the sclerotic, and known as the *lamina suprachoroidea*. This is composed of thin membranes of a homogeneous aspect, but pervaded by networks of fine elastic fibres, and covered by large flat cells. It contains also large flattened pigment-cells dispersed irregularly or arranged in patches, with considerable intervals

free from pigment-cells; and lymphoid cells may occur in it here and there singly or in groups (fig. 28). It is loosely united to the lamina fusca by vessels and bands of connective tissue enclosing pigment-cells, and the two laminae as well as the

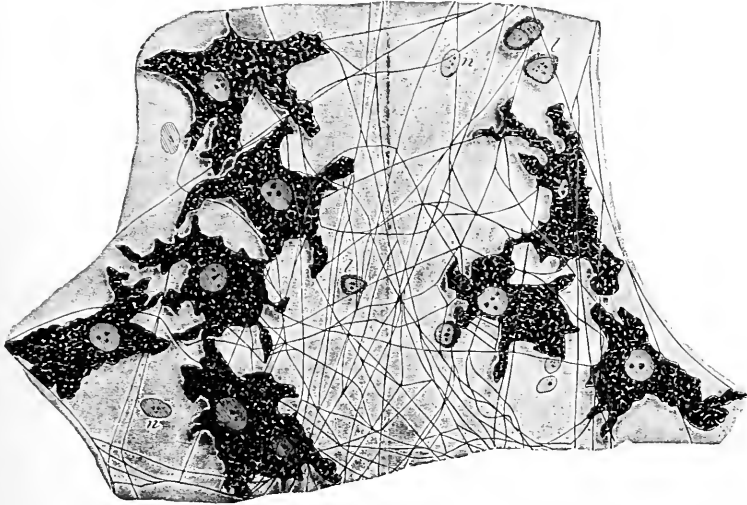


Fig. 28.—A SMALL PORTION OF LAMINA SUPRA-CHOROIDEA. Highly magnified. (E. A. S.)

p, pigment-cells; *f*, elastic fibres; *n*, nuclei of epithelioid cells (the outlines of the cells are not indicated); *l*, lymphoid cells.

uniting structures are coated with endothelium, a lymph-space being thus formed between the sclerotic and choroid. This space communicates, at the places where the vessels and nerves pierce the sclerotic, with that of the capsule of Tenon (Schwalbe).

The **choroid proper** resembles in general structure the lamina suprachoroidea, but contains in addition a very large number of blood-vessels. From a difference in the fineness of these constituent vessels, it resolves itself into two strata, outer and

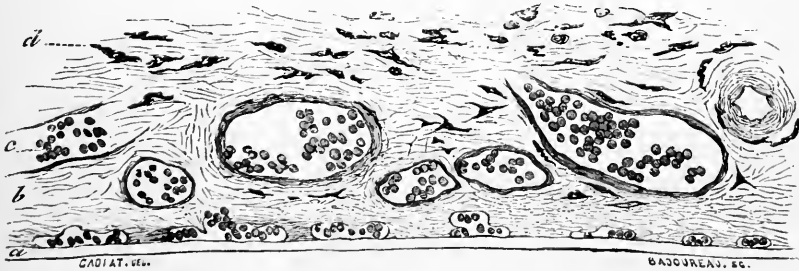


Fig. 29.—SECTION OF CHOROID. (Cadiat.)

a, membrane of Bruch: the chorio-capillaris is just above it; *b*, vascular layer; *c*, vein with blood-corpuscles; *d*, lamina suprachoroidea.

inner; the former containing the larger branches, and the latter the capillary ramifications. A layer of connective tissue containing many elastic fibres which unites the two strata, and is nearly free from pigment, is sometimes described as a third or intermediate part.

Tapetum.—This intermediate layer is markedly fibrous in some mammals, and shines through the layer of choroid and retina in front of it, causing the appearance known as the *tapetum*. In other mammals and in fish the appearance of a tapetum is produced or

enhanced by a layer of iridescent endothelial cells, which becomes formed immediately within the fibrous layer (Sattler).

In the **outer part** of the coat are situated, as just stated, the larger branches of the vessels. The arteries (*short ciliary*) are comparatively large and numerous, and

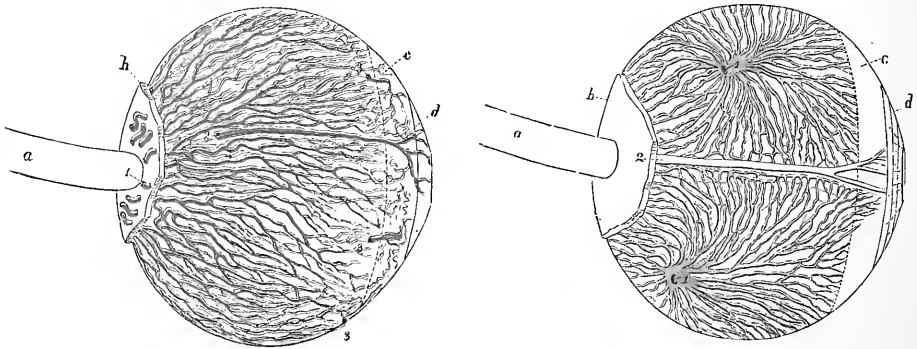


Fig. 30.—LATERAL VIEW OF THE ARTERIES OF THE CHOROID AND IRIS. (From Arnold.)

a, optic nerve; *b*, part of the sclerotic left behind; *c*, region of ciliary muscle; *d*, iris; 1, posterior ciliary arteries piercing the sclerotic and passing along the choroid; 2, one of the long ciliary arteries; 3, anterior ciliary arteries.

Fig. 31.—LATERAL VIEW OF THE VEINS OF THE CHOROID. (From Arnold.)

1, 1, two trunks of the *venæ vorticosæ* at the place where they leave the choroid and pierce the sclerotic coat. The other lettering as in fig. 30.

piercing the sclerotic close to the optic nerve (figs. 30 and 32), divide into branches which are directed at first forwards but soon bend obliquely inwards to end in the capillary layer; whilst the veins external to the arteries are disposed in curves (*vasa*

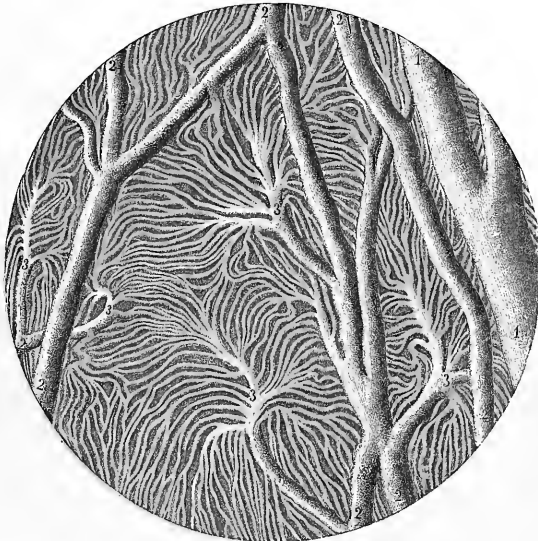


Fig. 32.—INJECTED BLOOD-VESSELS OF THE CHOROID COAT (from Sappey). 30 diameters.

1, one of the larger veins; 2, small communicating vessels; 3, branches dividing into the smallest vessels.

vorticosa) as they converge to four or five principal trunks (fig. 31, 1, *f*; fig. 26), which pierce the sclerotic about half way between the margin of the cornea and the entrance of the optic nerve. In the intervals between the vessels are elongated and stellate pigment-cells. The veins, like those of the pia mater, have no muscular tissue; they are enclosed by an adventitious sheath, between which and the endothelium, which forms the wall of the vein, is a lymph-space (*perivascular sheath*). The arteries have, besides the ordinary circular muscular fibres, strands of longitudinally disposed plain muscular tissue in their adventitia. As the *venæ vorticosæ* pass through the sclerotic they are ensheathed by a prolongation of suprachoroidal tissue (Fuchs).

The **inner part** of the choroid coat (*tunica Ruyschiana s. chorio-capillaris*, fig. 29) is formed mainly by the capillaries of the choroidal vessels. From the ends of the arteries the capillaries radiate and form meshes which are closer than in almost any other texture, being especially fine at the back of the eyeball, near the yellow spot. The network reaches as far forwards as the ora serrata, where its meshes become elongated, and join those of the ciliary processes.

The capillaries are embedded in a soft almost homogeneous tissue, and are stated to be enclosed within extensions of the perivascular lymph-spaces of the choroidal veins.

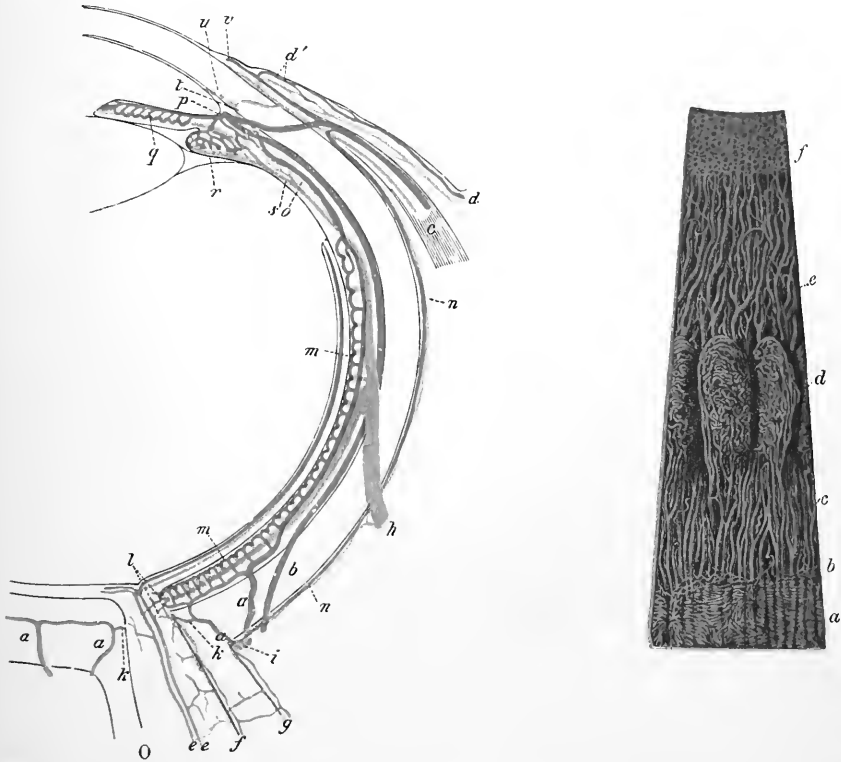


Fig. 33.—DIAGRAMMATIC REPRESENTATION OF THE COURSE OF THE VESSELS IN THE EYE. HORIZONTAL SECTION. (Leber.) ARTERIES AND CAPILLARIES RED; VEINS BLUE.

O, entrance of optic nerve; *a*, short posterior ciliary arteries; *a'*, branch to the optic nerve; *b*, long posterior ciliary arteries; *c*, anterior ciliary vessels; *d*, posterior conjunctival vessels; *d'*, anterior conjunctival vessels; *e*, central vessels of the retina; *f*, vessels of the inner sheath of the optic nerve; *g*, vessels of the outer sheath; *h*, vorticosæ vein; *i*, short posterior ciliary vein; *l*, anastomosis of choroidal vessels with those of optic nerve; *m*, chorio-capillaris; *n*, episcleral vessels; *o*, recurrent artery of the choroid; *p*, circulus iridis major (in section); *q*, vessels of iris; *r*, vessels of ciliary process; *s*, branch from ciliary muscle to vorticosæ vein; *t*, branch from ciliary muscle to anterior ciliary vein; *u*, canal of Schlemm; *v*, capillary loop at margin of cornea.

Fig. 34.—VESSELS OF THE CHOROID, CILIARY PROCESSES, AND IRIS OF A CHILD. (Arnold.) Magnified 10 times.

a, capillary network of the posterior part of the choroid, ending at *b*, the ora serrata; *c*, arteries of the corona ciliaris, supplying the ciliary processes, *d*, and passing into the iris, *e*; *f*, the capillary network close to the pupillary margin of the iris.

The veins begin by the convergence of the choroidal capillaries in a whorl-like manner (fig. 32) to form venous tributaries, which themselves converge again in a similar manner to form the large whorled veins or *venæ vorticosæ*, by which the blood is conveyed away from the choroid coat.

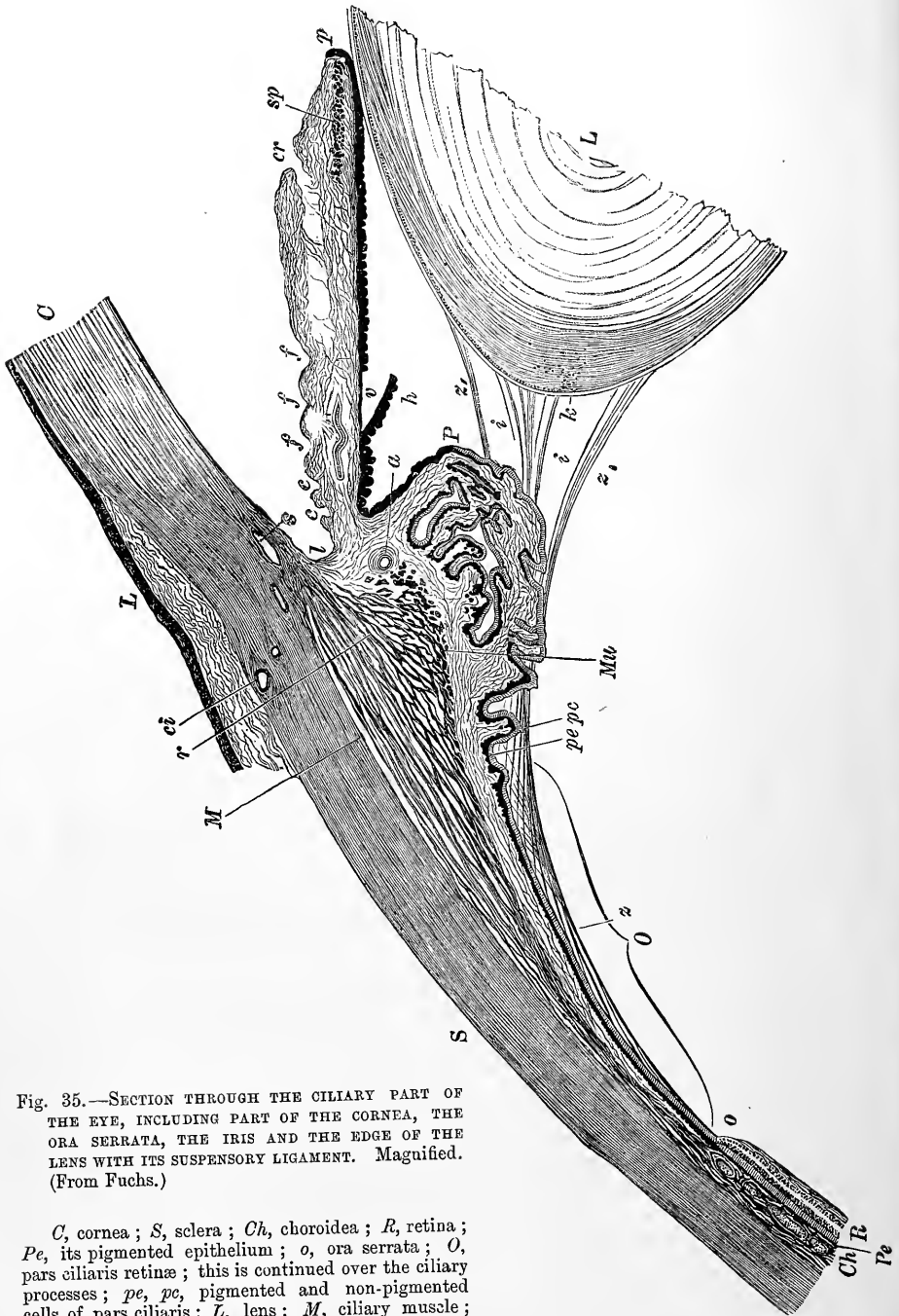


Fig. 35.—SECTION THROUGH THE CILIARY PART OF THE EYE, INCLUDING PART OF THE CORNEA, THE ORA SERRATA, THE IRIS AND THE EDGE OF THE LENS WITH ITS SUSPENSORY LIGAMENT. Magnified. (From Fuchs.)

C, cornea; *S*, sclera; *Ch*, choroidea; *R*, retina; *Pe*, its pigmented epithelium; *o*, ora serrata; *O*, pars ciliaris retinae; this is continued over the ciliary processes; *pe*, *pc*, pigmented and non-pigmented cells of pars ciliaris; *L*, lens; *M*, ciliary muscle; *r*, its radiating fibres; *Mu*, circular ciliary muscle; *ci*, anterior ciliary artery; *s*, canal of Schlemm; *z*, origin of ciliary muscle; *e, e, f, f*, folds and depressions in anterior surface of iris; *cr*, a crevice in this surface (? artificial); *sp*, sphincter pupillae; *p*, edge of pupil; *P*, most prominent part of ciliary process; *h*, pigment behind iris (pars iridica retinae), detached at *V*; *a*, bloodvessel; *z*, zonula of Zinn; *z', z'*, its continuation on the suspensory ligament; *i, i*, spaces between the fibres of the suspensory ligament; *k*, capsule of lens.

On the inner surface of the tunica Ruyschiana is a structureless or finely fibrillated transparent membrane, the *membrane of Bruch* (fig. 29, *a*), which lies next to the pigmentary layer of the retina, and, especially anteriorly in the region of the ciliary processes, presents on its outer surface numerous microscopic reticulations. It tends to become thickened as age advances.

The **ciliary processes** (*corpus ciliare*) have the same structure as the rest of the choroid; but the capillary plexus of the vessels is less fine, and has meshes with chiefly a longitudinal direction: and the ramified cells, fewer in number, are devoid of pigment towards the free extremities of the folds. The ciliary processes

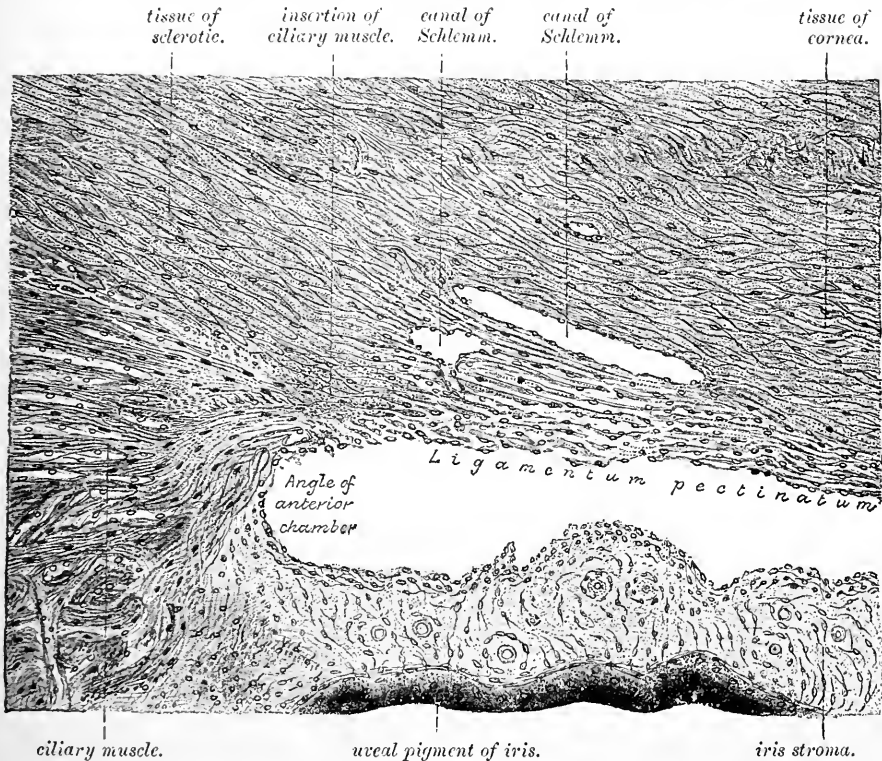


Fig. 36.—SECTION (FROM THE EYE OF A MAN), SHOWING THE RELATIONS OF THE CILIARY MUSCLE TO THE SCLEROTIC, IRIS, AND THE CAVERNOUS SPACES NEAR THE ANGLE OF THE ANTERIOR CHAMBER. (E. A. S.)

The figure (which is copied from a photograph) includes only a small portion of the ciliary muscle, the fibres of which are seen to be converging to a point immediately anterior to the angle of the anterior chamber. Here they are attached through the medium of a tongue of fibrous tissue of the sclerotic (consisting mainly of circular bundles) to the outer part of the ligamentum pectinatum, which forms a loose tissue with open meshes lying between the canal of Schlemm and the anterior chamber. To the right of the figure the fibres of the ligamentum pectinatum are seen to be gradually converging towards the posterior surface of the cornea, and somewhat beyond the part shown in this figure they merge into the membrane of Descemet. The communication of the canal of Schlemm, which is double in this section, with the endothelial-lined spaces in the ligamentum pectinatum is seen, as also the communications between the last named spaces and the anterior chamber.

are penetrated for a certain distance by glandular invaginations of the pigmented epithelium which covers their free surface (Collins). These *ciliary glands* probably assist in the secretion of the aqueous humour.

The *blood-vessels* of the ciliary processes (fig. 34, *d*) are very numerous; they are derived from the anterior ciliary arteries and from the vessels of the fore part of

the choroidal membrane. Several small arterial branches enter the outer part of each ciliary process, at first running parallel to each other and communicating sparingly. As they enter the prominent folded portion, the vessels become tortuous, subdivide minutely, and inosculate frequently. Finally they form short arches or loops, and turn backwards to pour their contents into the radicles of the veins. On the free border of the fold, one artery, larger than the rest, extends the whole length of each ciliary process, and communicates through intervening vessels with a long venous trunk which runs a similar course on the attached surface.

Ciliary muscle.—The anterior part of the choroid, opposite the ciliary processes, is considerably thickened. The thickening is triangular in section, and is produced by a zone of plain muscular tissue, forming the *ciliary muscle* (Bowman) (*tensor choroideæ*, Bruecke). The main part of this muscle arises (figs. 35, 36) by a thin flat expansion from the fore part of the sclerotic close to the cornea, between

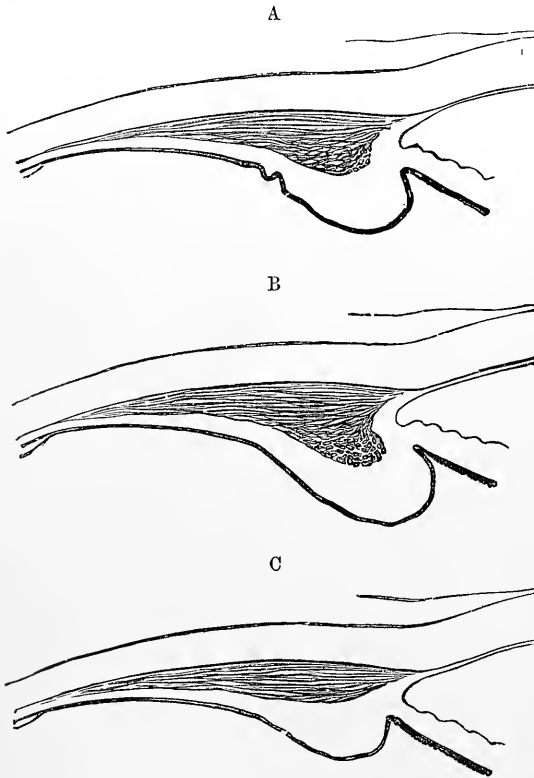


Fig. 37.—DIAGRAMS SHOWING THE COMPARATIVE DEVELOPMENT OF THE CIRCULAR FIBRES OF THE CILIARY MUSCLE IN

A, the normal or emmetropic eye ;
B, the hypermetropic eye ; and
C, the myopic eye. (Fuchs.)

the canal of Schlemm and the anterior chamber, its fibres being attached to the bundles of the ligamentum pectinatum which occupies this position. The muscular fibres, spreading radially (meridionally), are directed backwards (fig. 35, M), to be inserted into the choroid coat opposite to the ciliary processes, and partly further back. At their insertion the fibres pass obliquely and inter-cross so as to form peculiar stellate figures. According to Waldeyer, a small portion (the outermost) is sometimes inserted into the sclerotic coat,¹ but this must be very rare, for the sclerotic always becomes detached with the

greatest ease from this part of the muscle. The radial fibres pass towards the iris into a ring of fibres (fig. 35, *Mu*), which have a circular course around the insertion of the iris. This set forms the *circular ciliary muscle* of H. Müller and is much developed in hypermetropic eyes, but atrophied, or even absent altogether, in myopic (Iwanoff) (fig. 37). It was formerly described as the *ciliary ligament*. In birds the ciliary muscle is composed of cross-stripped muscular fibres. When the ciliary muscle contracts it tends to draw the choroid and ciliary processes forwards and inwards.

¹ This part, if present, is the homologue of an important portion of the ciliary muscle of birds which is known as the Cramptonian muscle.

The suspensory ligament of the lens is thus relaxed and the lens becomes more convex.


The *nerves* of the choroid will be described with those of the iris.

The **iris** is the contractile and coloured membrane which is seen behind the transparent cornea, and gives the tint to the eye. In its centre it is perforated by an aperture—the *pupil*.

At its circumferential border, which is nearly circular, the iris is continuous with the choroid, and by the ligamentum pectinatum, with the cornea: the free inner edge is the boundary of the pupil. The iris measures about 11 mm. across, and, in a state of rest, about 5 mm. from the circumference to the pupil (slightly less on the nasal side): its thickness is about 0.4 mm. The anterior surface, variously coloured in different eyes, is marked by wavy lines converging towards the pupil, near which they join in a series of irregular elevations; and, internal to these, other finer lines pass to the pupil. The appearance is produced by the subjacent blood-vessels. The posterior surface is covered with dark pigment cells (*pars retinalis*), and is marked by a number of fine converging folds or thickenings prolonged from the ciliary processes.

Fig. 33.—CILIARY PROCESSES AS SEEN FROM BEHIND.
(Twice the natural size.)

1, posterior surface of the iris, with the sphincter muscle of the pupil; 2, anterior part of the choroid coat; 3, ciliary processes.



The **pupil** is nearly circular in form, and is usually placed a little to the inner side of the centre of the iris. It is constantly varying in size during life, the variation ranging from 1 mm. to 8 mm. It is habitually wider in young than in old persons.

Structure of the iris.—A delicate connective tissue forms the framework or stroma of the iris (fig. 39). It contains also very numerous vessels and nerves. The endothelial layer of the membrane of Descemet (fig. 36) is continued from the margin of the cornea over the front of the iris; its cells are smaller and more granular than those which cover the membrane of Descemet, but are otherwise similar. Depressions of some size have been described in this anterior surface of the iris (Fuchs, Nuël and Cornil): these have been termed *stomata*, but it is doubtful if they are analogous to the openings of the same name which occur in serous membranes and communicate with subjacent lymphatics. The posterior surface of the iris is covered by a layer of pigmented epithelium two or three cells deep. This is continuous with the (retinal) pigmentary layer covering the ciliary processes, and ends abruptly at the margin of the pupil; it forms what is known as the *pars retinalis iridis* (*pars iridica retine*), as distinguished from the *pars choroidalis* or stroma.

The *stroma* consists of cells and fibres of connective tissue, the latter directed for the most part radially towards the pupil. In the substance of the iris anteriorly and throughout its thickness are variously-shaped ramified pigment cells like those in the choroid. The pigment contained in them is yellow, or of lighter or darker shades of brown, according to the colour of the eye. The colour of the iris depends partly on the pigment in the cells of the *pars retinalis*, partly on that in the stroma cells; in the eye of the infant and in the different shades of blue eye it arises from the black pigment of the posterior surface appearing more or less through the

stroma, which in such cases is only slightly coloured or is colourless; but in the black, brown, and grey eye, the colour is due to the pigment cells scattered through the substance of the stroma itself.

The **muscular tissue of the iris** is disposed as a ring (*sphincter pupillæ*) around the pupil, and as rays (*dilatator pupillæ*) from the sphincter to the circumference.

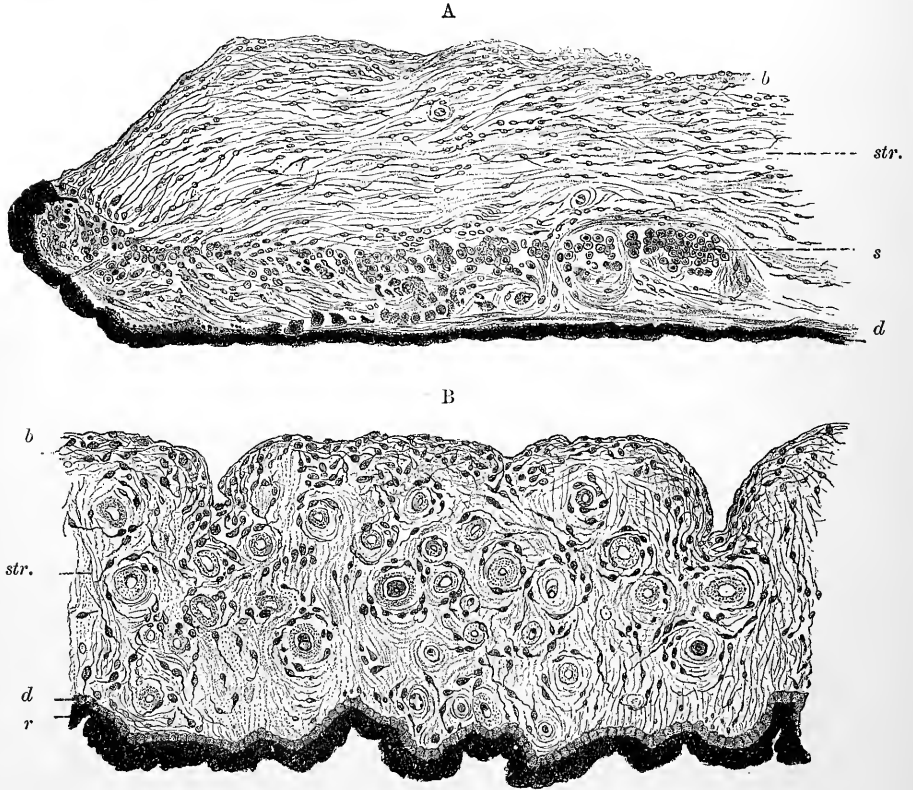


Fig. 39.—TWO SECTIONS OF THE HUMAN IRIS: A, RADIAL; B, TAKEN ACROSS THE RADII (G. Retzius).
HIGHLY MAGNIFIED.

b, basement membrane and endothelium of anterior surface; *str.*, stroma; *s.*, bundles of fibres of sphincter pupillæ, cut across (in A); *d*, layer of dilatator pupillæ; *r*, pigment (*pars iridica retinæ*).

The *sphincter* muscle (fig. 35, *sp*; 39, *s*, and fig. 40, *a*) is a narrow band about 0.5 mm. wide, situated close to the pupil posteriorly and consisting of a number of bundles of plain muscular tissue running concentrically with the margin of the pupil. Here the bundles are closely arranged, but further from the margin they are more separated, and form less complete rings.

The *dilatator* (*b*), less apparent than the sphincter, begins at the ciliary or outer margin of the iris, and its fibres form a continuous membrane close to the posterior surface, converging towards the pupil. Here they bend round and blend with the sphincter, some reaching nearly to its inner margin. At their origin at the ciliary margin, they also arch round and take a somewhat circular direction.

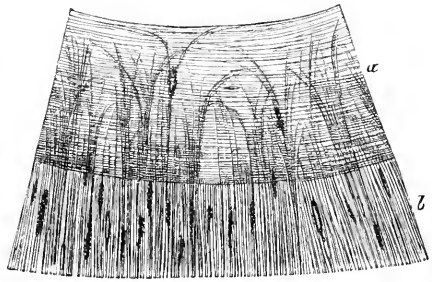
The majority of recent writers on the subject have failed to find evidence of the existence of a distinct layer of dilatator fibres and have consequently denied its existence in man and

mammals. It is admitted, however, to be well developed in birds (where like the intraocular muscular tissue generally it is of the striped variety) and, amongst mammals, in the otter. Other writers have strenuously contended for the existence of a dilatator muscle. I have myself obtained unmistakable evidence of the presence of a thin layer of fibres at the back of the iris, under the pigment-cells, having all the appearance of flat plain muscle-cells. Recently physiological proof of the existence of dilatator fibres has been furnished in the cat and other animals by the experiments of Langley and Anderson.

The choroidal part of the iris is often described as being bounded on its anterior and

Fig. 40.—SEGMENT OF THE IRIS, SEEN FROM THE POSTERIOR SURFACE AFTER REMOVAL OF THE UVEAL PIGMENT (Iwanoff).

a, sphincter muscle; *b*, dilatator muscle of the pupil.



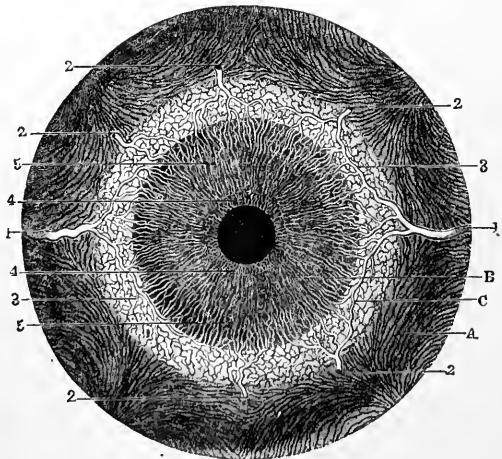
posterior surfaces by special layers, which have been termed the anterior and posterior limiting or hyaline layers. Of these, the anterior layer is merely the superficial part of the general stroma, having the fibres and cells somewhat more closely arranged; and what has usually been described as the posterior is probably the thin muscular sheet of the dilatator pupillae.

There may, however, be a thin membrane corresponding to the membrane of Bruch of the choroid immediately underlying the epithelium of the pars retinalis.

Vessels of the iris (figs. 30 to 34, and fig. 41).—The *long ciliary arteries*, two in number, pierce the sclerotic a little in advance, and one on each side, of the optic nerve. Having gained the interval between the sclerotic and choroid coats, they extend horizontally forwards covered by loose connective tissue to the ciliary muscle. In this course they lie nearly in the horizontal plane of the axis of the eye-ball, the outer vessel being a little above, and the inner one a little below the level of that line. A little behind the attached margin of the iris, each vessel

Fig. 41.—FRONT VIEW OF THE BLOOD-VESSELS OF THE CHOROID COAT AND IRIS FROM BEFORE. (Arnold.) Magnified $2\frac{1}{2}$ times.

A, choroid; B, iris; c, ciliary muscle; 1, 1, long ciliary arteries; 2, 2, five of the anterior ciliary arteries ramifying at the outer margin of the iris; 3, loop of communication between one of the anterior and one of the long ciliary arteries; 4, internal circle and network of the vessels of the iris; 5, external radial network of vessels.



divides into an upper and a lower branch, and these, anastomosing with the corresponding vessels on the opposite side and with the anterior ciliary, form a vascular ring (*circulus major*, fig. 33, *p*, fig. 41, 3) in this situation. From this circle small branches arise to supply the ciliary muscle; whilst others converge towards the pupil, and there, freely communicating by transverse offsets from one to another, form a second circle of anastomosis (*circulus minor*), from which capillaries are continued inwardly and end in small veins.

The *anterior ciliary arteries* (fig. 33, *c*, fig. 41, 2, 2), five or six in number, but smaller than the vessels just described, are supplied from the muscular and lachrymal branches of the ophthalmic artery, and pierce the sclerotic about

2 mm. behind the margin of the cornea ; they divide into branches which supply the ciliary processes, and join the circulus major.

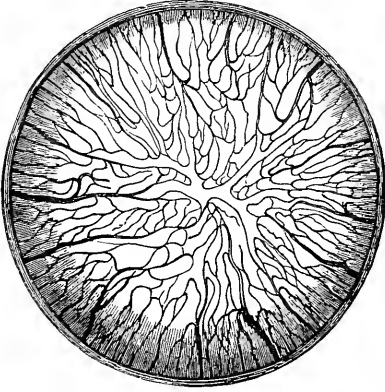


Fig. 42.—PUPILLARY MEMBRANE OF NEW-BORN KITTEN, INJECTED. (Kölliker, from a preparation by Thiersch.) Magnified.

Besides these special arteries, numerous minute vessels enter the iris from the ciliary processes.

The *veins of the iris* follow closely the arrangement of the arteries just described. The canal of Schlemm communicates with this system of vessels.

Pupillary membrane.—In the foetus the pupil is closed by a thin transparent vascular membrane, the vessels in which are continued from those of the iris and of the capsule of the lens (which is also vascular in the foetus). Near the middle of the pupil the vessels of the membrane loop round, leaving the centre free from vessels. They disappear in the seventh or eighth month of foetal life, becoming obliterated from the centre towards the circumference, and the membrane itself is gradually absorbed in like manner. A few shreds may still remain at birth : sometimes the whole membrane persists.

Nerves of the choroid and iris.—The *ciliary nerves* (fig. 43), about fifteen in number, and derived from the ciliary ganglion and the nasal branch of the

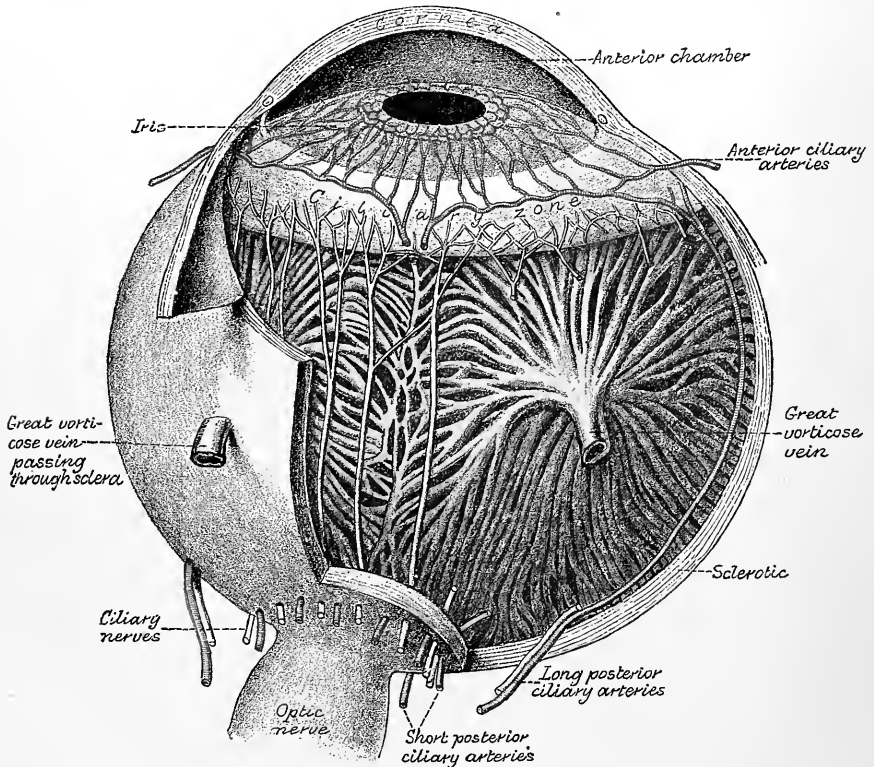


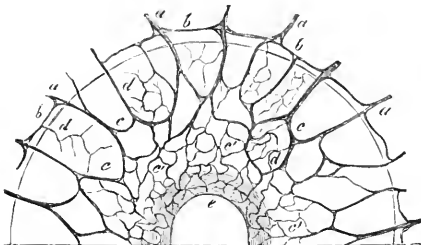
Fig. 43.—DIAGRAM SHOWING THE PRINCIPAL NERVES AND BLOOD-VESSELS OF THE EYEBALL. (Testut.)

ophthalmic division of the fifth nerve, pierce the sclerotic near the entrance of the optic nerve, and come immediately into contact with the choroid. They are some-

what flattened in form, are partly imbedded in grooves on the inner surface of the sclerotic, and communicate occasionally with each other before supplying the cornea and entering the ciliary muscle. When the sclerotic is carefully separated from the subjacent structures, these nerves are seen lying on the surface of the choroid,

Fig. 44.—DISTRIBUTION OF NERVES IN THE IRIS (Kölliker). 50 DIAMETERS.

The preparation was from the eye of an albino rabbit; *a*, smaller branches of the ciliary nerves advancing from the choroid; *b*, loops of union between them at the margin of the iris; *c*, arches of union in the iris; *c'*, finer plexus in the inner part; *e*, sphincter pupillæ muscle.



into which they send branches, and in which they form a gangliated plexus amongst the blood-vessels, the groups

of ganglion-cells being often applied to the walls of the vessels. Within the ciliary muscle the nerves also subdivide minutely, forming here another plexus, which contains a number of medullated fibres, and the cells of which are smaller. A few recurrent branches appear to pass back from it into the choroid coat, but the greater number pass on to the iris (fig. 44, *a*, *a*). In the iris the nerves follow the course of the blood-vessels, dividing into branches, which communicate with one another as far as the pupil, forming a close plexus of fine non-medullated fibres. Their ultimate destination is probably mainly the muscular tissue of the iris and of its vessels.

THE RETINA.

The retina is a delicate membrane, which contains the expanded termination of the optic nerve. It lies within the choroid coat, and rests on the hyaloid membrane of the vitreous humour. It extends forwards nearly to the outer edge of the ciliary processes of the choroid, where it ends in an indented border, named *ora serrata* (fig. 45). From this border there is continued onwards a thin layer of a different structure and containing no nerve-fibres, the *pars ciliaris retinae*, which reaches as far as the tips of the ciliary processes, and there gives place to the double layer of pigment known as the *urea*, which is continued on to the posterior surface of the iris (*pars iridica retinae*). The thickness of the retina diminishes from behind forwards, from 0.5 mm. near the yellow spot to 0.1 mm. at the *ora serrata*. In the fresh eye it is translucent and of a light pink colour, but of a purple-red colour if kept in the dark for a little while before removal. Under the influence of sunlight it is quickly bleached and after death it soon becomes opaque. The colouring matter was discovered by Boll and has been specially investigated by Kühne, who has given it the name of *rhodopsin*. It is absent at the yellow spot and central fovea, and also close to the *ora serrata*. The outer surface of the retina is covered with a layer of hexagonal pigment-cells which send fine offsets between the elements of the next retinal layer: the rhodopsin becomes developed in this layer by the agency of these pigment-cells. When the choroid is detached these offsets are ruptured and the pigment-cells come away with it, so that this layer was formerly described as part of the choroid coat.

The inner surface of the retina is smooth: on it the following objects may be seen. In the axis of the ball is a yellow spot—*macula lutea* (*limbus luteus*, Sömmerring)—which is somewhat elliptical in shape (fig. 45), and about 1 to 2 mm. in diameter: in the centre of this, again, is a slight hollow, *fovea centralis*, 0.2 mm. to 0.4 mm. in diameter (fig. 45), and, as the retina is thinner here than elsewhere,

the pigmentary layer is more clearly visible through it in the dead condition, giving rise to an appearance as of a hole through the tunic. About 3 mm. inside the yellow spot and about 1 mm. below the level of a horizontal line through the posterior pole of the eyeball is a pale, round disc, *porus opticus* (figs. 46 and 47),

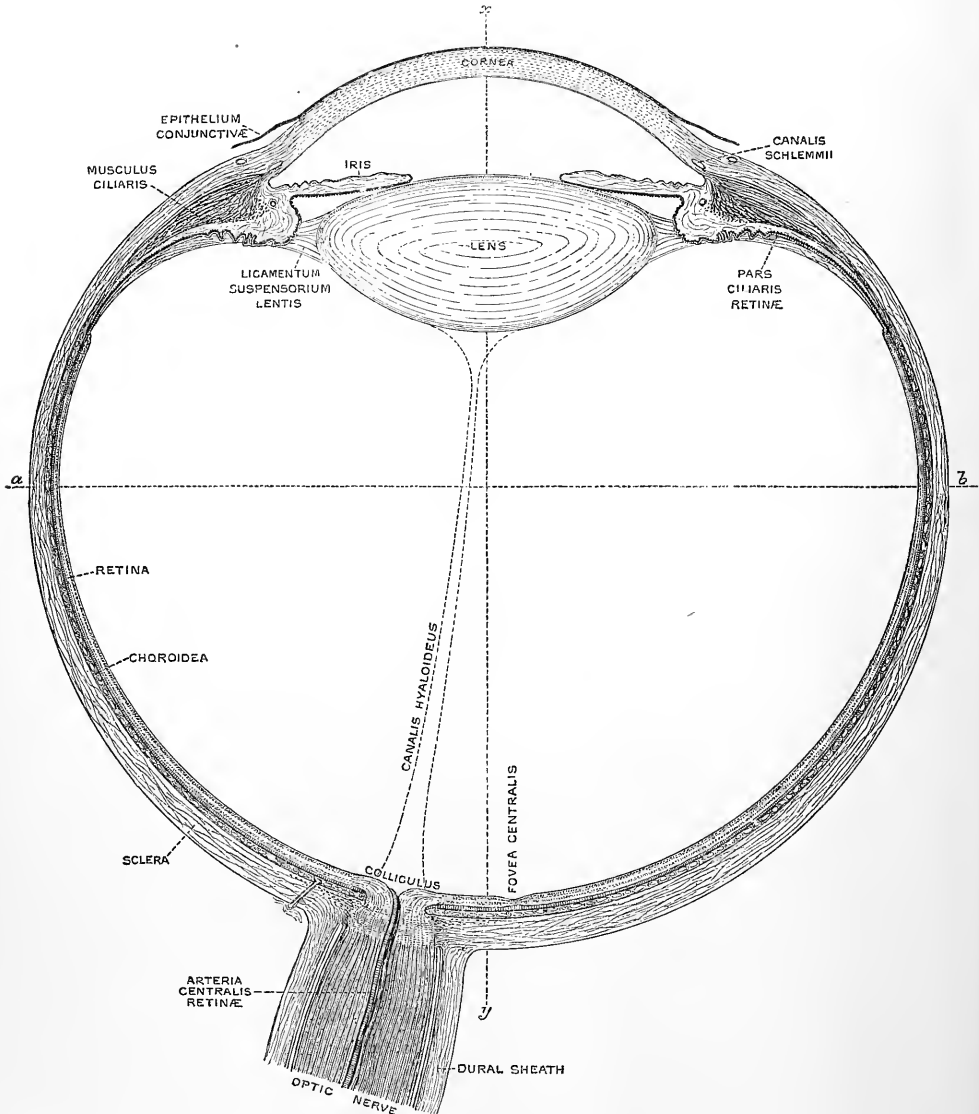


Fig. 45.—RIGHT ADULT HUMAN EYE, DIVIDED HORIZONTALLY THROUGH THE MIDDLE.
(Magnified five times.)

The line *a b* passes through the equator, *x y* through the visual axis of the eye.

where the optic nerve pierces the retina and expands to form its inner layer. The circumference of the disc is slightly elevated to form an eminence (*colliculus nervi optici*) (fig. 45) and in its centre, which often shows a well-marked depression, is the point from which the vessels of the retina branch.

When examined during life by the aid of the ophthalmoscope, the optic disc appears of a light grey tint, contrasting strongly with the red colour of the rest of the field. In the central depression of the disc are remnants of the tissue which, in the fœtus, accom-

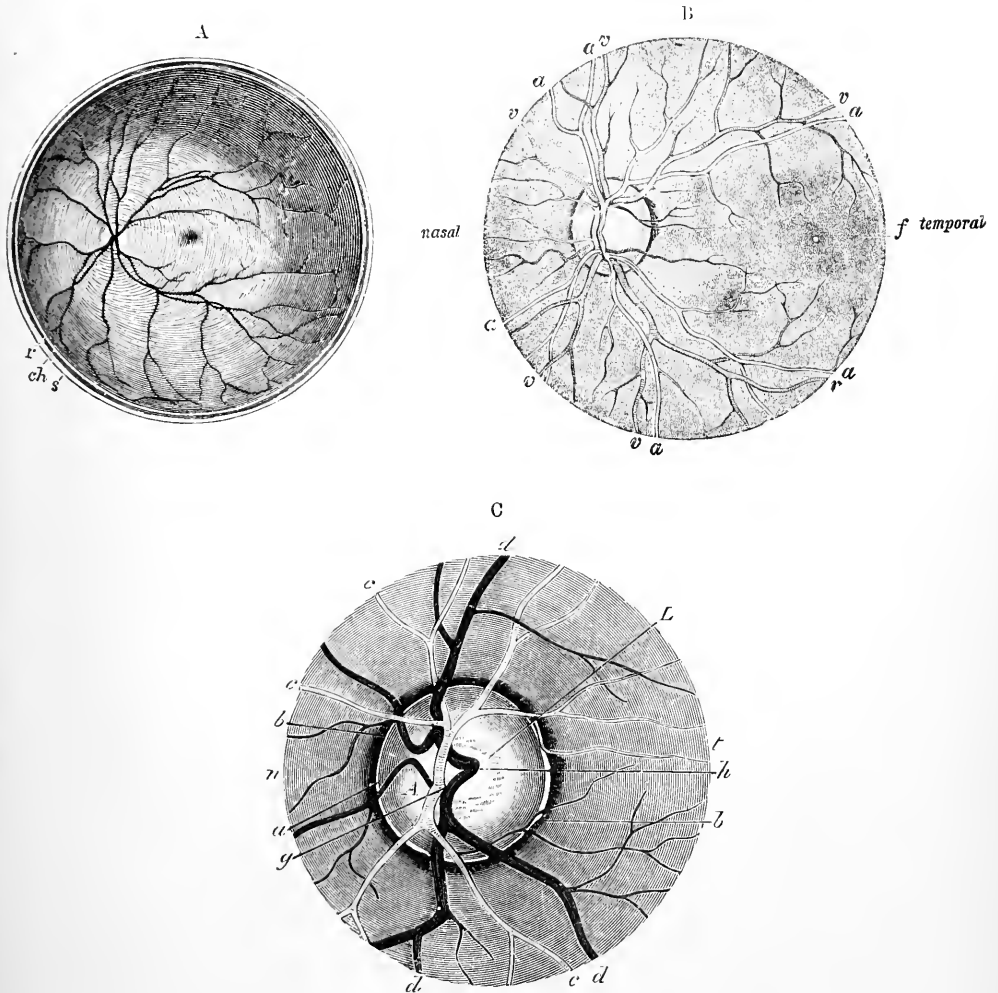


FIG. 46.—VIEWS OF THE POSTERIOR PART OF THE RETINA. Various magnified.

A.—The posterior half of the retina of the left eye, viewed from before. (Heale.) Twice the natural size.

s, cut edge of the sclerotic; ch, choroid; r, retina: in the interior at the middle the macula lutea with the depression of the fovea centralis is represented by a slight oval shade; towards the left side the light spot indicates the colliculus or eminence at the entrance of the optic nerve, from the centre of which the arteria centralis is seen sending its branches into the retina, leaving the part occupied by the macula comparatively free.

B.—Fundus of the eye, as seen with the ophthalmoscope. (Jaeger.) Somewhat magnified.

a, a, arteries; v, v, veins; f, fovea.

C.—The point of entrance of the optic nerve as seen with the ophthalmoscope. (Jaeger.) Magnified still more.

A, optic nerve, passing through the lamina cribrosa, l, which shows through the disc-like expansion of the entering nerve; a, ring of connective tissue; b, choroidal ring; c, branches of the central artery of the retina, g; d, branches of the central vein, h; n, inner or nasal side; t, outer or temporal side.

panied the prolongation of the central artery of the retina along the canal of Stilling (fig. 45) through the vitreous body to the capsule of the lens; in some eyes this tissue can be followed for some distance into the vitreous humour.

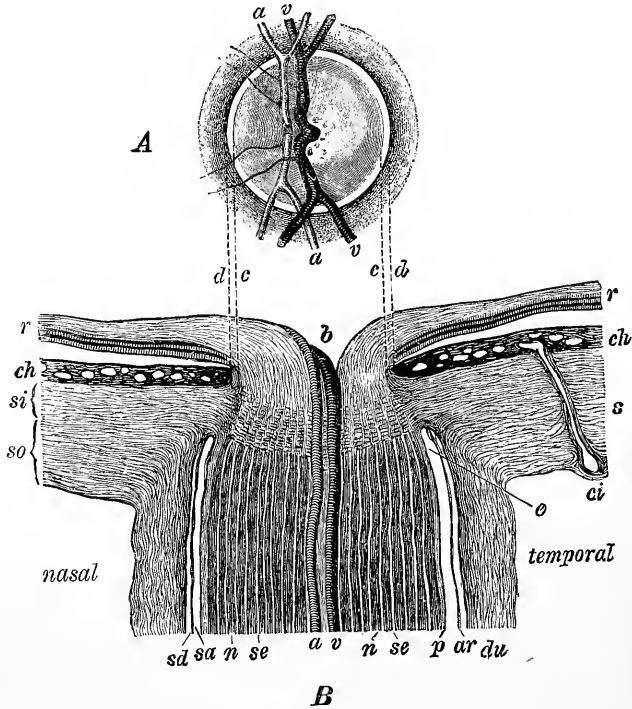


Fig. 47.—SECTION THROUGH THE PLACE OF ENTRANCE OF THE OPTIC NERVE (B), TOGETHER WITH THE OPHTHALMOSCOPIC VIEW OF THE DISC (A), TO SHOW THE CORRESPONDING PARTS OF THE TWO. (Fuchs, after Jaeger.)

c, d, lines of correspondence; *b*, depression in centre of disc; *r*, retina; *ch*, choroid; *si*, *so*, inner and outer parts of the sclerotic coat; *s*; *ci*, a ciliary artery cut longitudinally; *a, v*, central artery and vein; *sd*, subdural space; *sa*, subarachnoid space; *du*, dural sheath; *ar*, arachnoidal sheath of nerve; *p*, pial sheath; *n*, nerve bundles; *se*, septa between them.

MICROSCOPIC STRUCTURE OF THE RETINA.

When vertical sections of the retina, *i.e.*, sections made perpendicularly to its surface, are submitted to microscopic examination, eight distinct strata are recognizable, together with certain fibrous structures which pass vertically through the membrane and connect the several layers.

The following are the designations of the layers, from within outwards:—

1. The layer of nerve-fibres (*stratum opticum*).
2. The layer of nerve-cells (*ganglion nervi optici*).
3. The inner molecular layer (*stratum reticulare internum*).
4. The inner nuclear layer (*stratum granularum internum, ganglion retinae*).
5. The outer molecular layer (*stratum reticulare externum*).
6. The outer nuclear layer (*stratum granularum externum*).
7. The layer of rods and cones (*stratum bacillarum*).
8. The layer of hexagonal pigment cells (*stratum nigrum*).

In addition to these eight strata two very delicate membranes have been described—the one, *membrana limitans interna*, bounding the retina on its inner surface, next to the hyaloid membrane of the vitreous humour; the other, *membrana*

limitans externa, lying between the outer nuclear layer and the layer of rods and cones; but, as will be afterwards explained, these so-called "membranes" are merely the boundary lines of the sustentacular tissue of the retina. The accompanying figure, from Max Schultze, represents diagrammatically the general arrangement of the layers (fig. 48).

The several layers of the retina will first be considered successively as they are met with from within out, after which the sustentacular fibres or fibres of Müller, which traverse several of the layers, and the connection of the nervous elements

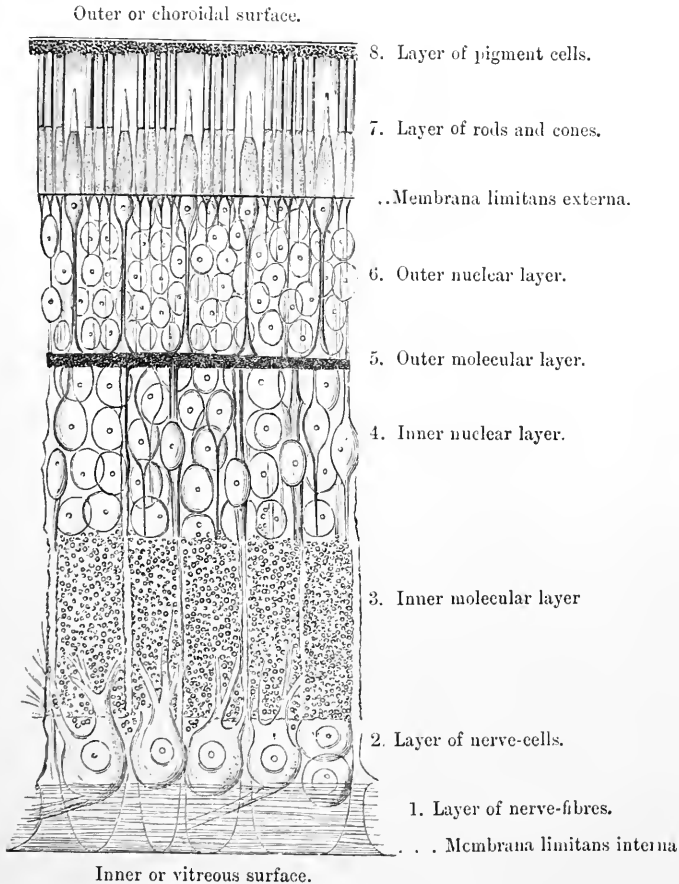


Fig. 48. — DIAGRAMMATIC SECTION OF THE HUMAN RETINA (Schultze).

throughout the retina with one another will be described. Finally an account will be given of those parts of the retina which present points of difference from the rest, especially the central fovea, and the ciliary part.

1. **Layer of nerve-fibres.**—The optic nerve passes at the *porus opticus* directly through the thickness of the retina to reach its inner surface (fig. 47) on which it spreads out in the form of a membrane which extends to the *ora serrata*. Its fibres, which are destitute of a primitive sheath and vary much in size, but are mostly small, lose their medullary sheath on reaching the retina, consisting there normally of axis-cylinder only (Bowman). In rare cases some of them may retain their medullary sheath for a short distance. They are collected

into small bundles, which, compressed laterally, intercommunicate and form a delicate web with narrow elongated meshes (fig. 49). At the yellow spot this layer is almost wanting, and indeed it ceases at the central fovea, but elsewhere it forms a continuous stratum, gradually diminishing in thickness in front, interrupted only by the enlarged ends of the fibres of Müller to be afterwards described (fig. 48, 1). The nerve-bundles, as well as the cells of the next layer, are partially supported by neuroglia-cells (spider-cells). Most of the fibres are continuous with the axis-cylinder processes of the cells of the next layer (fig. 50, 1.), but some are continued through the second and third layers, and end by ramifying either in the inner molecular layer or amongst the elements of the fourth layer (inner granules), the terminations being frequently somewhat knobbed or enlarged (fig. 50, 1., *m*).

2. **Ganglionic layer.**—Immediately external to the nerve-fibre layer is a stratum of nerve-cells (fig. 48, 2), having in the fresh condition a pellucid aspect. The cells vary much in size and in figure, some being spheroidal, others more pyriform. Each cell has a single unbranched nerve-fibre process extending obliquely

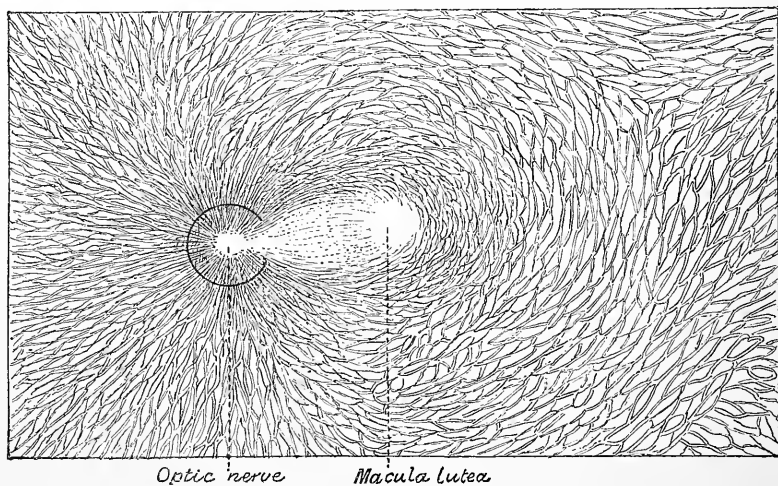


Fig. 49.—MAGNIFIED VIEW OF THE INNERMOST LAYER OF THE RETINA, SHOWING THE BUNDLES OF OPTIC NERVE FIBRES RADIATING FROM THE PAPILLA. (Merkel.)

from its rounded inner extremity amongst the fibres of the preceding layer, with one of which it is continuous. From the opposite end of the cell, which is frequently imbedded in the substance of the succeeding layer, one, two, or more much thicker protoplasmic processes extend outwards for a variable distance into that stratum, and branch in its substance (fig. 50, v., VI., VII.). The branching occurs at different levels for different cells, the smaller cells as a rule having the terminal ramification of their protoplasmic processes nearer the ganglionic layer, the larger ones nearer the inner nuclear layer. The arborisations are mostly flattened conformably with the retinal strata, and in sections of retina produce the appearance of coarse lines in the molecular stratum. The number of nerve-cells and consequently the thickness of the ganglionic layer in the different regions of the retina varies largely. Over the greater part of the retina they form a single stratum, but in the neighbourhood of the yellow spot they are placed two or three deep. At the spot itself (fig. 60, 2) they are very thickly set; the cells are also smaller here. Towards the ora serrata, on the other hand, there is but a single stratum, and that frequently incomplete.

The ganglion-cells of the retina may be classed into those the protoplasmic or peripheral processes of which ramify in a diffuse manner in the inner molecular layer, and those the protoplasmic processes of which are ramified horizontally in one or more of the strata of that layer, where they interlace with similar ramifications from the cells of the inner nuclear layer. The diffusely ramifying cells (fig. 50, VII., *i*) are usually small and with slender processes, and this is also the case with some of the cells with stratified processes (fig. 50, VI., *a*; VI., *c*), but many of the latter are larger, sometimes very large (giant cells), and with comparatively coarse processes.

The cells with stratified processes are classified by R. y Cajal according to the stratum of the inner molecular layer in which these processes ramify. Some ramify, however, in two, and even in more layers (bi- and multi-stratified). Three types of the stratified cells can usually be distinguished. They may be termed *first*, *second*, and *third*, or from their relative size, *large*, *medium*, and *small*, and some of each type appear to belong, as regards the distribution of their arborescence, to each stratum of the inner molecular layer.

First type.—Those of the large type have a thick axis-cylinder process and one, two, or more coarse protoplasmic processes, varying in vertical extent in different cells according to the stratum of the inner molecular layer for which they are destined. Their terminal arborescences extend over a considerable area, and are open in nature. The largest cells of this type (giant cells) send their processes to the outer strata of the molecular layer (fig. 53, VII., *a*, *c*, *e*); processes to the inner strata come from cells of the same type but of smaller size.

Second type.—The ganglion-cells of this type (fig. 50, VI., VII., *f*, *g*, *h*) vary in size of cell-body, but are usually smaller than those of the first type, and of pyriform shape, the stalk of the pear being directed outwards for a variable distance in the molecular layer according to the position within this of the terminal arborescence. The latter is composed of moderately fine varicose filaments which form a compact, closely interwoven ramification, occupying some thickness of the molecular layer, the arborescence being less flattened out than is the case with those from many of the cells of the first and third types.

Third type.—This is represented by cells usually pyriform with small cell-bodies and correspondingly fine moderately arborescent processes, which may radiate from the end of a straight outwardly directed stalk, as in the case of those which ramify in the outer strata of the molecular layer (fig. 50, VI., *a*), or may spring in a similar radiating manner from the body of the cell itself, as with those ramifying in the inner strata (fig. 50, VII., *b*).

3. Inner molecular or inner plexiform layer, neurospongium.—Next in order to the ganglionic layer comes a comparatively thick stratum of a granular-looking substance, which as preparations treated by the methods of Ehrlich or of Golgi show, is mainly made up of the arborescent terminations of the processes of the cells in the layers which bound it internally and externally. A few branched cells, apparently of nervous nature, occur within the layer (fig. 50, III.); these are probably allied to the amacrine cells of the layer next to be described. The interlaced arborisations of the ganglion-cells, amacrine cells, and bipolars form within it definite strata which, according to R. y Cajal, are altogether five in number. There are a few blood-vessels in this layer, and the fibres of Müller pass through it as fine vertical filaments with delicate lateral offsets.

4. Inner nuclear layer.—This is composed of a number of closely-packed cells, which are frequently known collectively as the "inner granules," but are of several distinct kinds. Some are bipolar nerve-cells, and it is the presence of these which has led to the name *ganglion retinæ* being applied to this layer. They occupy the bulk of the stratum and send processes inwards and outwards into the respective molecular layers. Others are multipolar nerve-cells, the processes of which ramify in the molecular layers; they form incomplete strata close to and partly imbedded in the molecular layers. Others, again, are nucleated enlargements belonging to the fibres of Müller. The structure and arrangements of each of these elements must be separately considered.

a. Bipolar-cells.—These, by far the most numerous, are round or oval clear cells (fig. 50, I., III.; fig. 51, 4), prolonged at either end into a fibre.

Of the processes or fibres which proceed from these cells, the inner one, or that extending into the inner molecular layer, is finer than the other, is always unbranched until reaching that layer, and often exhibits varicosities similar to those on nerve-

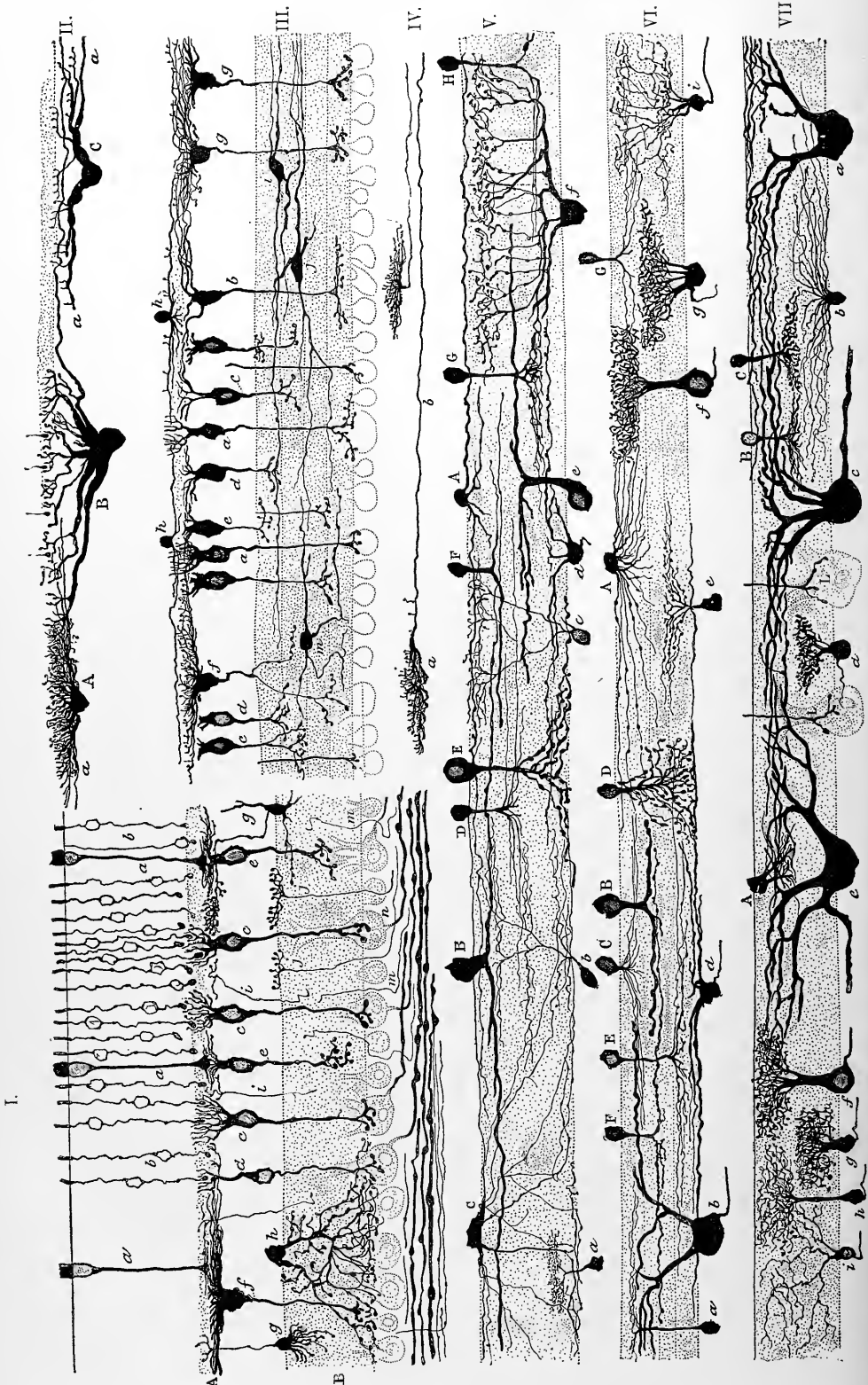


Fig. 50.

fibrils. It is regarded as the axis-cylinder process of the cell, and extends usually to the inner part of the internal molecular layer, within which it ends in a terminal ramification of varicose fibrils which is frequently in close proximity to the outer surface of one or more of the ganglion-cells of the layer. The outer prolongation or process of the bipolar cell is not varicose, is usually thicker than the inner one, and in some cases passes undivided into the next layer, in others divides before reaching it. Having arrived at the outer molecular layer it breaks up into an arborisation within this layer, which is interlaced with arborisations of fibres belonging to the horizontal cells presently to be described, and with the terminations of the rod- and cone-elements of the bacillary layer. It has been shown by R. y Cajal that the bipolars are of at least two kinds, distinguishable by the character of the terminal arborescence of the outwardly-directed protoplasmic

Fig. 50.—ELEMENTS OF THE RETINA OF MAMMALS DISPLAYED BY THE CHROMATE OF SILVER METHOD OF GOLGI. (Cajal.)

I. Section of the dog's retina. *a*, cone-fibre; *b*, rod-fibre and nucleus; *c*, *d*, bipolar cells (inner granules) with vertical ramification of outer processes destined to receive the enlarged ends of rod-fibres; *e*, bipolars with flattened ramification for ends of cone-fibres; *f*, giant bipolar with flattened ramification; *g*, cell sending a neuron or nerve-fibre process to the outer molecular layer; *h*, amacrine cell with diffuse arborisation in inner molecular layer; *i*, nerve fibrils passing to outer molecular layer; *j*, centrifugal fibres passing from nerve-fibre layer to inner molecular layer; *m*, nerve-fibril passing into inner molecular layer; *n*, ganglionic cells.

II. Horizontal or basal cells of the outer molecular layer of the dog's retina. A, small cell with dense arborisation; B, large cell, lying in inner nuclear layer but with its processes branching in the outer molecular; *a*, its horizontal neuron; C, medium sized cell of the same character.

III. Cells from the retina of the ox. *a*, rod-bipolars with vertical arborisation; *b*, *c*, *d*, *e*, cone-bipolars with horizontal ramification; *f*, *g*, bipolars with very extensive horizontal ramification of outer process; *h*, cells lying on the outer surface of the outer molecular layer, and ramifying within it; *i*, *j*, *m*, amacrine cells within the substance of the inner molecular layer.

IV. Neurons or axis-cylinder processes belonging to horizontal cells of the outer molecular layer, one of them, *b*, ending in a close ramification at *a*.

V. Nervous elements connected with the inner molecular layer of the ox's retina. A, amacrine cell, with long processes ramifying in the outermost stratum; B, large amacrine with thick processes ramifying in second stratum; C, flattened amacrine with long and fine processes ramifying mainly in the first and fifth strata; D, amacrine with radiating tuft of fibrils destined for third stratum; E, large amacrine, with processes ramifying in fifth stratum; F, small amacrine, branching in second stratum; G, H, other amacrones destined for fourth stratum; *a*, small ganglion-cell sending its processes to fourth stratum; *b*, a small ganglion-cell with ramifications in three strata; *c*, a small cell ramifying ultimately in first stratum; *d*, a medium sized ganglion-cell ramifying in fourth stratum; *e*, giant cell, branching in third stratum; *f*, a bi-stratified cell ramifying in second and fourth strata.

VI. Amacrones and ganglion-cells from the dog. A, amacrine with radiating tuft; B, large amacrine passing to third stratum; C and G, small amacrones with radiations in second stratum; F, small amacrine passing to third stratum; D, amacrine with diffuse arborisation; E, amacrine belonging to fourth stratum; *a*, *d*, *e*, *g*, small ganglion-cells, ramifying in various strata; *b*, *f*, large ganglion-cells, showing two different characters of arborisation; *i*, bi-stratified cell.

VII. Amacrones and ganglion-cells from the dog. A, B, C, small amacrones ramifying in middle of molecular layer; *b*, *d*, *g*, *h*, *i*, small ganglion-cells showing various kinds of arborisation; *f*, a larger cell, similar in character to *g*, but with longer branch; *a*, *c*, *e*, giant cells with thick branches ramifying in the first, second, and third layers; L, L, ends of bipolars branching over ganglion-cells.

process, and by the position in the internal molecular layer in which the axis-cylinder process terminates. In one kind this arborescence is composed of a dendritic tuft of vertical fibrils, somewhat varicose and enclosing amongst them the end-knobs of several (3 to 20) of the rod-fibres of the bacillary layer; and the axis-cylinder process ends in a varicose ramification over a body of a cell of the ganglionic layer. These may be termed, therefore, the *rod-bipolars*, or bipolars with vertical arborescence (fig. 50, 1, *c*; 111., *a*). In the other kind (*cone-bipolars*) this terminal arborescence is horizontal (fig. 50, 1, *e*; 111., *b*, *c*, *d*, *e*), and abuts against or interlaces with the ramified foot of one or more cone-fibres, and the axis-cylinder process usually extends to a less depth of the internal molecular layer, and is not constant in position as is that of the rod-bipolar; the axis-cylinder process of either kind may give off short collaterals in traversing the inner molecular layer. Some of

the cone-bipolars have their horizontal arborescence extending over a large area of the outer molecular layer (fig. 50, I., f, III., f, g), and probably come into contact with a considerable number of cone-feet.

In birds, reptiles, and amphibia some of the bipolar cells—probably corresponding to those described above as cone-bipolars—give off from their arborescence within the outer molecular layer an unbranched irregularly varicose fibril as far as and just beyond the membrana limitans externa (*fibril* of Landolt), where it usually ends in a clavate enlargement (fig. 51, E). According to Cajal it is absent in mammals and teleosteans.

The relative length of the inner and outer process of the bipolars naturally differs according to the position of the individual cell in the nuclear layer; if the cell is near the inner molecular layer the outer process will have a longer course to reach the outer molecular layer, and, conversely, if the cell is near the latter. At and near the central fovea these processes or fibres of the inner nuclear layer have a

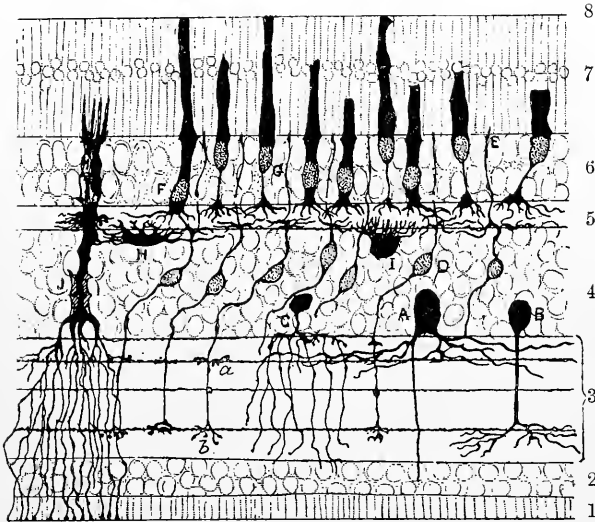


Fig. 51.—SECTION OF BIRD'S RETINA, PREPARED BY GOLGI'S METHOD. (R. y Cajal.)

A, B, large spongioblasts of inner nuclear layer; C, smaller spongioblast of the same layer; D, small bipolar cells with one process, *a*, *b*, ending in terminal ramifications in the inner molecular layer, and the other process ending partly in a flattened ramification in the outer molecular layer and partly in a filament which ends at the external limiting membrane in an enlarged extremity (at E); F, G, rod and cone nuclei; H, I, cells with ramifications in the outer molecular layer; J, fibre of Müller.

markedly oblique direction, in other parts of the retina they run nearly vertically to the surfaces.

In the frog and lizard it is common to find bipolars amongst the outer granules as well as in their ordinary position in the inner nuclear layer. Such cells are spoken of as displaced bipolars.

b. Spongioblasts (of inner molecular layer) of W. Müller: amacrine¹ cells of Cajal.—These, which are placed in the inner part of the inner nuclear layer, form an almost complete stratum, which is termed by Cajal the layer of amacrine cells. As this name implies, it has not hitherto proved possible to demonstrate the existence of an axis-cylinder process in these cells (which are nevertheless regarded by Cajal as nerve-cells²), but they possess, on the other hand, extensively ramified protoplasmic processes which are wholly included within the inner molecular layer, and mostly form horizontal arborisations in the several strata of that layer. There are several kinds of these cells, which differ amongst one another much in the

¹ *a*, privative; *μακρός*, long; *ινος*, fibre.

² In birds, reptiles, and amphibia there are a certain number of large cells in this layer which have an undoubted axis-cylinder process extending into the nerve-fibre layer (Dogiel) (see fig. 51, A), but they have not been found in mammals.

same way as do the cells of the ganglion-cell layer, that is to say, partly in the varying size of the cell-body, and the character of the cell-processes, partly in the position of their terminal arborescences within the inner molecular layer.

The varieties of amacrine cells described by Cajal are firstly, those with diffusely ramified processes, their arborescence extending throughout the whole depth of the molecular layer (fig. 50, I., *h*; VI., D), and secondly, those having their terminal arborescences horizontally placed in the several strata of the molecular layer. Of these so-called stratified amacrines there are, as in the case of the ganglion-cells, three principal types—

(1.) Those of the first type (fig. 50, V., B, E; VI., B) have for the most part very large cell-bodies and a thick stalk-like process, sometimes more than one, extending into the inner molecular layer, and ramifying in one or other of its strata over a considerable extent of area, but with comparatively few and relatively coarse processes. A good deal of variation is, however, met with in the character and extent of these processes.

(2.) Those of the second type (fig. 50, V., F, G, H; VI., E, F, G; VII., B, C) have a pyriform cell-body of medium size with a straight stalk passing into the molecular layer, and ending in one of its strata in a moderately extended close interlacement of fibrils.

(3.) The amacrines of the third type (fig. 50, V., D; VI., C) are of small or medium size, usually with a fine stalk-like process passing into the molecular layer. From the lower (inner) end of this process a terminal tuft of very fine radiating fibrils spreads out in one of the strata of the molecular layer, the extent of the arborescence thus formed being often very considerable. When, however, the arborescence is near the inner nuclear layer, the fibrils may come off from the body of the cell (fig. 50, V., VI., A).

c. Spongioblasts of outer molecular layer: horizontal cells of Cajal: basal cells.—

These are flattened or irregularly projecting cells, the bodies of which occupy the outermost part of the inner nuclear layer, whilst their greatly ramified processes extend into and end in the outer molecular layer. The stratum in which they lie is termed by Cajal the layer of horizontal cells; it was previously described by W. Krause as the *membrana fenestrata*.

Two kinds of these cells have been noticed by Cajal in mammals, and by their situation they serve to subdivide the layer into two strata, an inner and an outer.

(1.) The cells in the inner stratum of the layer are large and broadly pyramidal in shape, the base being directed towards the outer molecular layer, and resolving itself into a large number of coarse but rapidly tapering processes which end in small tufts of short varicose vertical fibrils at about the level in the outer molecular layer in which the knobs of the rod-fibres occur. The apex of the pyramid is sometimes truncated, but in other cases can be traced as a thick vertical process down into the inner molecular layer, where it ends in horizontal branches. Each cell has a long axis-cylinder process, which extends for a considerable distance within the outer molecular layer to end in a closely interlaced terminal ramification (fig. 50, II., B, C; IV., *a*).

(2.) Semilunar cells, from the upper (outer) flattened surface of which a thick brush of closely interlacing radiating filaments comes off and passes vertically outwards towards the base of the rod- and cone-fibres (fig. 50, II., A). These also have an axis-cylinder process which passes horizontally and a little upwards to end in the outer part of the outer molecular layer.

5. Outer molecular layer.—The outer molecular layer is much thinner than the inner, but otherwise presents, in vertical sections of hardened retina, a similar granular appearance.

This layer (fig. 50, II.) is largely formed of the processes of the horizontal cells which have just been described, and also of the outwardly directed protoplasmic processes of the bipolars, which ramify within it and interlace with similarly ramifying fibres from the cones, and with the knobbed ends of the rod-fibres.

In some mammals there are cells with widely extending branched processes resting upon the outer surface of the outer molecular layer (fig. 50, III., *h*), much in the same way as some of the amacrine cells rest upon the inner molecular. The outer molecular layer also receives fine axis-cylinder processes which pass into it from the inner molecular (fig. 50, I., *i*), but whence they are derived is not known.

The layers hitherto described contain structures (cells and fibres) which are undoubtedly of nervous nature, and which appear to be developed in the same manner as corresponding structures in the brain. Those next to be described are of epithelial nature, and constitute collectively what is sometimes known as the *epithelium of the retina*, in contradistinction to the more strictly nervous or cerebral part. The outer nuclear and bacillary layers are morphologically but one, being composed of long cells, *visual cells*, which extend through both layers. Each cell is drawn out into a fibre, and furnished with a nucleus in its inner portion (rod- or cone-fibre and its outer granule), and is peculiarly modified both in shape and structure in its external portion (rod or cone proper).

In most vertebrates no blood-vessels penetrate into this epithelial layer, but a remarkable exception is stated by Denissenko to occur in the retina of the eel, in which the retinal capillaries extend nearly to the *limitans externa*.

6. Outer nuclear layer.—This (figs. 48, 50, 52) resembles very closely at first sight, in sections of retina stained with hæmatoxylin or carmine, the inner nuclear

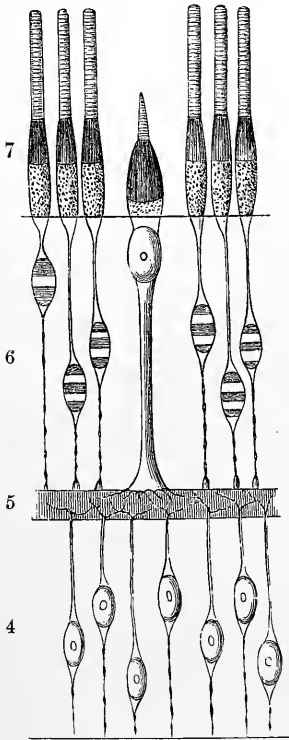


Fig. 52.—DIAGRAM OF SOME OF THE NERVOUS AND EPITHELIAL ELEMENTS OF THE RETINA. (Modified from Schwabe.)

The numbers are the same as in fig. 47.

layer; appearing, like that, to consist of clear, oval or elliptical, nuclear corpuscles (outer granules), from the ends of which delicate fibres are prolonged. These outer granules differ, however, essentially from the inner granules, and may be readily distinguished from them. They are of two kinds, which present well-marked differences, and are known respectively as the rod-granules and cone-granules, accordingly as they are connected with the rods or with the cones of the next retinal layer. Those which are connected with the *rods* are, in most parts of the retina, by far the more numerous, and form the main thickness of the outer nuclear layer. They may be regarded as enlargements or swellings in the course of delicate fibres (rod-fibres), which extend from the inner ends of the rods at the *membrana limitans externa* through the thickness of this layer to the outer molecular layer. The enlargements, of which there is but one to a fibre, situated at any part of its course, are each occupied by an elliptical nucleus, and, in the fresh condition, exhibit a remarkable cross-stripped appearance (Henle), the strongly refracting substance which mainly composes the enlargement being interrupted by bands or

disks of a clearer, less refracting material, usually two in number, one on each side of the middle line (fig. 52), but occasionally single and median (see the left-hand one in fig. 52). The rod-fibres are of extreme fineness, and exhibit minute varicosities in their course: each is directly continuous at the outer end with one of the rods, but at the inner end terminate in a somewhat larger varicosity (*end-knob*). These end-knobs lie in the outer part of the outer molecular layer, and are embedded in the tufts of which the terminal arborisations of the rod-bipolars are formed. In amphibia and birds (but not in nocturnal birds) fine fibrils radiate from these end-knobs (fig. 51), but in mammals and teleosteans these fibrils are absent (Cajal).

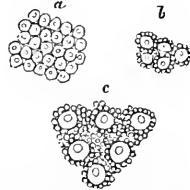
Those outer granules which are connected with the *cones* are, in most parts of the retina, much fewer in number than the rod-granules, from which they are dis-

tinguished by their shape, which is somewhat pyriform, by the absence of transverse striation, and by their position—for they occupy the part of the outer nuclear layer nearest the *membrana limitans externa*,¹ and the larger end of each is thus in close proximity to the base of the corresponding cone (fig. 48), with which it is directly connected, or there is at most a short, comparatively thick stalk uniting the two (see fig. 52). At the macula lutea, however, where only cone-granules are met with, many of them are further removed from the limiting membrane, and the stalk is then longer (fig. 60). The nucleus of each cone-granule, which, as in the case of the rod-granules, occupies almost all the enlargement, is spheroidal, and contains a distinct nucleolus. The cone-fibre is very much thicker than the rod-fibre above described, and is itself finely striated or fibrillated. It passes from the smaller end of the pear-shaped enlargement straight through the outer nuclear layer to reach the outer molecular layer, upon which it rests by a somewhat pyramidal base (*cone-foot*), from which ramifications may be traced into the substance of the molecular layer where they interlace with the ramifications of the peripheral processes of the cone-bipolars (see above) (fig. 52).

7. The layer of rods and cones.—The elements which compose this layer are, as their name implies, of two kinds, those of the one kind—the *rods*—having an

Fig. 53.—OUTER SURFACE OF THE COLUMNAR LAYER OF THE RETINA (Kölliker). 350 DIAMETERS.

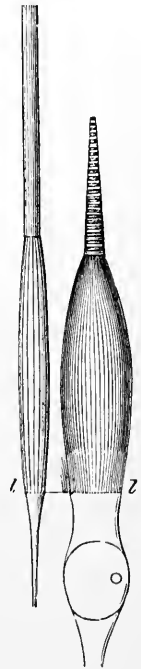
a, part within the macula lutea, where only cones are present; *b*, part near the macula, where a single row of rods intervenes between the cones; *c*, from a part of the retina midway between the macula and the ora serrata, showing the preponderance of the rods.



elongated cylindrical form (about 0.060 mm. long and 0.002 mm. diameter); the *cones*, on the other hand, being shorter (0.035 mm.), much thicker (0.006 mm.), bulged at the inner end or base, and terminated externally by a finer tapering portion. Both rods and cones are closely set in a palisade-like manner over the whole extent of the retina between the *membrana limitans externa* and the pigimentary layer (fig. 48, 7). Except at the macula lutea, where only cones are met with, the rods far exceed the cones in number. Their relative number and arrangement is well exhibited when the layer is viewed from the outer surface, as in fig. 53, where *a* represents a portion of the layer from the macula lutea; *b*, from the immediate neighbourhood of the latter; and *c*, from the peripheral part of the retina.

Fig. 54.—A ROD AND A CONE FROM THE HUMAN RETINA (Max Schultze). (Highly magnified.)

In the rod the longitudinal striation of both the outer and inner segments is shown; in the cone the transverse striation of the outer segment and the longitudinal of the inner segment; *l*, *limitans externa*.

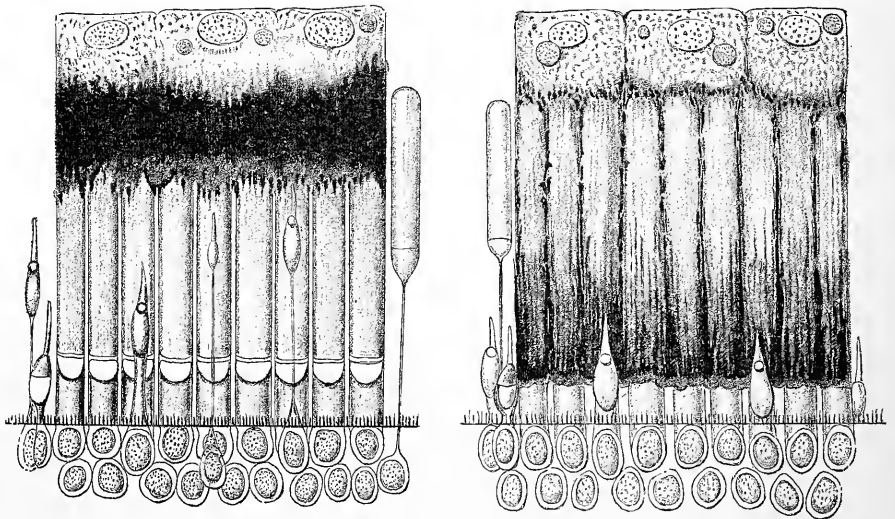


The total number of cones in the human retina has been calculated to exceed three millions; and of rods many times this number. It may be of interest here to note that the number of fibres in each optic nerve is about half a million (Salzer).

The rods and the cones, although differing thus in shape and size, agree in many points of structure. Thus, each consists of two distinct segments—an inner and an outer; the division between the two occurring, in the case of the rods, about the middle of their length (in man); in the cones at the junction of the finer tapering

¹ In Teleostei the cone-nuclei lie outside the *limitans externa*.

end-piece with the basal part; consequently, the outer and inner segments of the rods are nearly similar in size and shape, the inner being, however, slightly bulged, whereas the inner segment of each cone far exceeds the outer one in size, the latter appearing merely as an appendage of the inner segment (fig. 54). The two segments both of the rods and cones exhibit well-marked differences in their chemical and optical characters, as well as in the structural appearances which may be observed in them. Thus, while in both the outer segment is doubly refracting in its action upon light, the inner is, on the contrary, singly refracting: the inner becomes stained by carmine, iodine, and other colouring fluids, whilst the outer remains uncoloured by these reagents, but is stained greenish-brown by osmic acid. The outer segment in both shows a tendency to break up into a number of minute superposed disks. The inner segment of each is distinguishable into two parts—



Figs. 55 and 56.—SECTIONS OF FROG'S RETINA SHOWING THE ACTION OF LIGHT UPON THE PIGMENT CELLS, AND UPON THE RODS AND CONES. (v. Genderein-Stort.)

Fig. 55, from a frog which had been kept in the dark for some hours before death.

Fig. 56, from a frog which had been exposed to light just before being killed.

Three pigment cells are shown in each section. In Fig. 55, the pigment is collected towards the nucleated part of the cell, in Fig. 56 it extends nearly to the bases of the rods. In Fig. 55 the rods, outer segments, were coloured red (the detached one green), in Fig. 56 they had become bleached. In Fig. 55, the cones, which in the frog are much smaller than the rods, are mostly elongated, in Fig. 56 they are all contracted.

an outer part, composed, according to Max Schultze, of fine fibrils, and an inner part, homogeneous, or finely granular, and, at the *membrana limitans externa*, directly continued into a rod or cone-fibre, the disposition of which in the outer nuclear layer has been already described.

In the **outer segments** of the *rods* there can be detected, by the aid of a powerful microscope, besides a delicate transverse striation (fig. 52), corresponding to the superposed disks of which, as above mentioned, they appear to be formed, also fine longitudinal markings which are due to slight linear grooves by which they are marked in their whole extent. The ends of the segments are rounded and project into the pigmentary layer. The purplish-red colour of the retina before mentioned (p. 35), resides entirely in the outer segments of the rods (Boll, Kühne). A few of the rods are, however, at least in some animals, of a green colour. The outer segments of the *cones* taper gradually to a blunt point, and do not exhibit

superficial groovings, but the transverse markings are somewhat more evident than in the rods (figs. 52, 54). There is a delicate covering of neurokeratin investing the outer segments of both rods and cones, and this is somewhat more pronounced on the cones, so that a post-mortem separation into disks does not take place so readily as in the rods. From their behaviour to staining reagents and the readiness with which they become altered after removal from the body, it has been conjectured that the outer segment contains materials similar in chemical nature to those composing the myelin of the medullary sheath of nerve-fibres.

In the **inner segments**, the proportion which the fibrillated part bears to the homogeneous basal part differs in the rods and cones. In the *rods* the fibrils usually occupy only the outer third of the inner segment (fig. 52), ceasing abruptly at its junction with the middle third; in the *cones*, on the other hand, they occupy about the outer two-thirds of the segment, only the part nearest the *membrana limitans* remaining free from fibrils. The fibrils in question are for the most part straight and parallel, and strongly refracting. Sometimes, in the cones, instead of this outer part of the inner segment being fibrillated, it appears

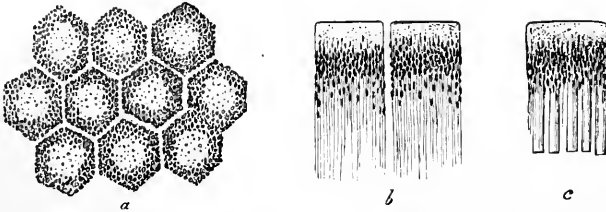


Fig. 57.—PIGMENTED EPITHELIUM OF THE HUMAN RETINA (Max Schultze). HIGHLY MAGNIFIED.

a, cells seen from the outer surface with clear lines of intercellular substance between; *b*, two cells in profile with fine offsets extending inwards; *c*, a cell still in connection with the outer ends of the rods.

homogeneous, but is nevertheless well marked off from the inner part by its strong refractivity.

This condition of a part of the inner segment of the cones is much better marked in other mammals and in the lower vertebrata, where there occurs a distinct strongly refracting body, situated in the middle or outer part of the segment, and known from its shape as the "ellipsoid," a name which is also extended to include the fibrillated part of the cone in the human retina. In reptiles an oval body, coloured red by iodine, takes the place of the ellipsoid (Merkel). In lower vertebrata, as well as in most other mammals, the fibrils are absent from the inner segments of the rods also, a peculiar, strongly refracting, lenticular body ("rod-ellipsoid") being met with at their outer part, corresponding to the ellipsoid of the cones. Further, in birds, reptiles, and amphibia, in ganoid fishes and in marsupials (but not in other mammals), there is found in the extreme outer part of the inner segment of each cone a minute globular body, apparently of a fatty nature, which in some is clear and colourless, but in many cones is brightly coloured of a tint varying in different cones from red to green—red and yellow being the most common. Blue and violet are not met with, but by the action of iodine the colours of all become changed to blue. Sometimes the whole inner segment is found to be slightly tinted of the same colour as the "oil-globule." In birds there are two kinds of cone: in the one kind, the cone-fibre passes straight down to the outer molecular layer; in the second kind, obliquely. In all vertebrates below mammals, double- or twin-cones are here and there met with; these usually have, the one a straight the other an oblique cone-fibre. Numerous other differences and peculiarities are found in animals: thus in birds and reptiles the cones are more numerous than the rods; in many reptiles (*e.g.*, lizard) only cones are met with; while in some fishes (sharks and rays), in most nocturnal mammals, and in the owl, the cones are either altogether absent or are but few and rudimentary (M. Schultze). This statement has, however, been denied by W. Krause so far as nocturnal mammals are concerned. In the size of the elements there is also much variation: the rods being very large in amphibia, and especially long in fishes. In the frog there are three

kinds of rods, one kind having a long outer segment of the usual red colour (when not exposed to light), whilst in the others the inner segment is lengthened and either fine or of the usual thickness, whilst the outer segment is short and of a green colour. The rod-fibre is straight in the red variety and in those of the green kind with the larger inner segments, but oblique in the green rods, with finer inner segments.

In the frog the cones were observed by Engelmann to shorten on exposure to light and to lengthen in the dark (figs. 55, 56). This change occurs through the nervous system, for it will take place equally well if the head of the animal be kept in the dark and only the skin of the trunk and limbs exposed to the action of light.

8. **The pigmentary layer.**—This layer, which bounds the retina externally, and was formerly described with the choroid coat, consists of a single stratum of hexagonal epithelium cells separated from one another by a perceptible amount of clear intercellular substance (fig. 57). The outer surface of each cell—that which is turned towards the choroid—is smooth and flattened, or slightly convex, and the part of the cell near this surface is devoid of pigment, and contains the nucleus (figs. 55, 56); the inner boundary, on the other hand, is not well marked, for the substance of the cell, which here is loaded with pigment, is prolonged into fine, straight, filamentous processes (fig. 57, *b*), which extend for a certain distance between and amongst the outer segments of the rods and cones—indeed the outer parts of the rods may be said to be altogether imbedded in the pigment-cells (*c*).

The pigment-cells are not everywhere quite regularly hexagonal, but here and there cells are found, singly or in patches, which are larger or smaller than the rest, and of a more rounded or of an irregularly angular shape.

The pigment granules, which are in the form of minute crystals, are placed for the most part, both in the cells and cell-processes, with their long axes at right angles to the surface of the retina. The distribution of the pigment granules within the cells varies during life and immediately after removal of the eye according as the retina has been shaded from the light or exposed to its influence. In the former case the pigment is mainly accumulated in the body of the cell (or at least its inner zone), and is withdrawn to a great extent from between the rods; but after exposure to light, a large amount of pigment is found between the rods, and some of the granules may even extend as far as the external limiting membrane (fig. 56). This has the effect of causing the pigmentary layer to adhere more firmly to the rest of the retina than when the pigment granules are accumulated in the body of the pigment-cell. The pigment appears to have *inter alius* the function of renewing the colour (visual purple) of the outer segments of the rods after these have become bleached from exposure to the light. This renewal of the colour will take place for a short time after the death of the animal, or the excision of the eye (Kühne).

In some animals, *e.g.*, frog, coloured oil-droplets and particles of a highly refracting myelin-like substance (myeloid granules, Kühne) occur in the non-pigmented portion of the cells, which are further covered next to the choroid by a clear homogeneous cuticular layer.

The intervals between the rods and cones are only partially filled by the processes of the hexagonal pigment-cells; the remaining part appears to be occupied by a clear substance, which, according to Henle and H. Müller, is of a soft elastic consistence during life and in the fresh condition, but soon liquefies after death; but according to Schwalbe, is normally liquid. In the embryo, between the hexagonal pigment and the remainder of the retina, there is a distinct cleft filled with fluid (remains of cavity of primary optic vesicle), homologous with the ventricular cavities of the brain, with which it is originally in continuity.

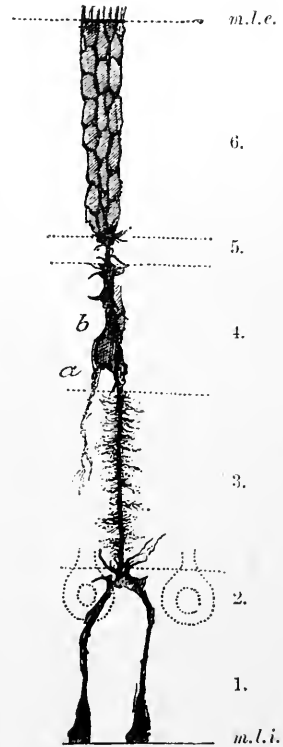
The sustentacular tissue of the retina: Müllerian or radial fibres.—

In addition to the elements which belong specially to the layers above described, there are certain other structures which are common to nearly all the layers, passing through the thickness of the retina from the inner almost to the outer surface, and, although not actually of the nature of connective tissue, serving the same kind of purpose, namely to bind together and support the more delicate nervous structures of the membrane. These *sustentacular fibres* or *fibres of Müller* (figs. 48, 58), commence at the inner surface of the retina by a broad conical hollow base or foot, which may be forked (fig. 58), and often contains a spheroidal body, staining with hamatoxylin (pseudo-nucleus). The bases of

Fig. 58.—A FIBRE OF MÜLLER FROM THE DOG'S RETINA. SHOWN BY GOLGI'S METHOD. (R. y Cajal.) Highly magnified.

1, nerve-fibre layer; 2, ganglionic layer; 3, inner molecular layer; 4, inner nuclear layer; 5, outer molecular layer; 6, outer nuclear layer; *m.l.e.*, membrana limitans externa; *m.l.i.*, membrana limitans interna; *b*, nucleus of the fibre; *a*, process extending from nucleated part into inner molecular layer.

adjoining fibres are united together at their edges (fig. 59), so as to give, in vertical sections of the retina, the appearance of a distinct boundary line (fig. 48); this has been named *membrana limitans interna*, but, as may be inferred from the above description, it is in no way a continuous or independent membrane. The Müllerian fibres pass through the nerve- and ganglionic layers, either with a smooth contour, or with but two or three well-marked lateral projections from which fine lamellar processes extend amongst the elements of these layers: gradually diminishing in size they then traverse the inner molecular layer. In the mammalian retina the fibres may be marked by slight projections in passing through this layer. In the inner nuclear layer they again give off delicate flattened processes from their sides, which pass round the inner granules and serve to support them. Moreover, each Müllerian fibre is here characterised by the presence of a clear oval or elliptical nucleus (already mentioned in the description of the inner nuclear layer), containing a nucleolus, and situated at one side of, and in close adherence to the fibre to which it belongs (fig. 58, *b*). On reaching the outer nuclear layer (after passing through the outer molecular) the fibres of Müller break up into fibrils and thin lamellae, and in this form they pass outwards through the layer, between the outer granules and the rod- and cone-fibres, enclosing these structures, filling up the intervals between the granules and forming partial sheaths for them. At the level of the bases or central ends of the cones and rods, the numerous offsets terminate along a definite line which marks the boundary between the outer nuclear layer and the layer of rods and cones, and has been termed *membrana limitans externa*. This also, like the *m. l. interna*, is in no way a continuous membrane, nor is it isolable from the Müllerian fibres; indeed, numerous fine fibrillar offsets of these pass a short distance beyond the so-called limiting membrane, and closely invest the bases of the inner segments of the rods and cones.



The Müllerian fibres exhibit a fine striation. They swell up and become

indistinct on treatment with acetic acid and dilute alkalis, but much more slowly than connective tissue fibrils; moreover, they are not dissolved by boiling in water. They are much less developed in the central and posterior part of the retina than in the peripheral and anterior part; towards the ora serrata they are very distinct and closely set.

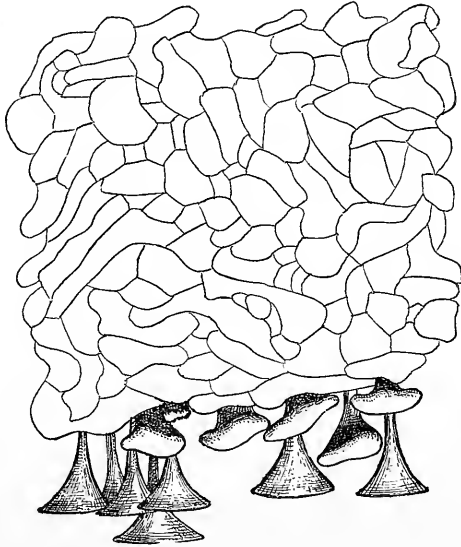


Fig. 59.—INTERNAL LIMITING MEMBRANE OF THE RETINA TREATED WITH SILVER NITRATE, SHOWING THE OUTLINES OF THE BASES OF THE MÜLLERIAN FIBRES. (Retzius.)

At the lower part of the figure some of these fibres are seen separated.

Structure of the macula lutea and fovea centralis (fig. 60).—The peculiarities in structure which these present have partly been incidentally noticed in the preceding description of the retinal layers. In the fovea no rods are met with, and the cones, especially their inner segments, are much longer and narrower than elsewhere. All the other layers are much thinned, but towards the margin of the fovea they rapidly increase in thickness, and in the rest of the macula lutea most of them are thicker than at any other part of the retina. The ganglionic layer (fig. 60, 2) is especially thickened at the edge of the fovea, the cells being from six to eight deep. They are smaller here than nearer the centre of the fovea. The nerve-fibre layer (1) gradually thins and disappears as a distinct layer near the edge of the fovea as the fibres join the central ends of the ganglion-cells. The opposite end of each ganglion-cell is directed vertically towards the inner nuclear layer. The bipolar inner granules are somewhat obliquely disposed. They are smaller than the outer granules and, as elsewhere, much smaller than the ganglion-cells. At the centre of the fovea they are but thinly scattered, and the inner and outer molecular layers appear to join between them. At the middle of the fovea the retina is very thin, consisting here mainly of the cone-cells (*i.e.*, cones with their nucleated fibres) and pigmentary layer, but a few of the inner granules are also present, and one or two isolated nerve-cells (perhaps amacrine cells) may also be seen very near to the centre. According to the figures and description given by M. Schultze the membrana limitans externa is also cupped in at this place, and the cones, both inner and outer segments, are considerably longer than elsewhere, so that

the line of pigment remains level. Hulke figured the limitans externa as plane, and others (*e.g.*, Merkel, Kuhnt, Schwalbe) have formally denied this cupping of the *m. limitans externa*. Undoubtedly, however, it exists and may, as a glance at fig. 60 will render evident, be as deep as that of the limitans interna or true fovea, from which for purposes of description it may be distinguished by the name of *fovea externa*. On the other hand, the inner segments of the cones are not longer here than elsewhere, but are if anything somewhat shorter than at the edge of the fovea, but this is more than compensated for by the greater length of their outer segments. The cones are also more slender in the very middle of the fovea than elsewhere, here measuring not more than 0.002mm., whereas at the edge of the fovea they are double this in diameter. The outer nuclear layer (fig. 60, 6) of the macula lutea is

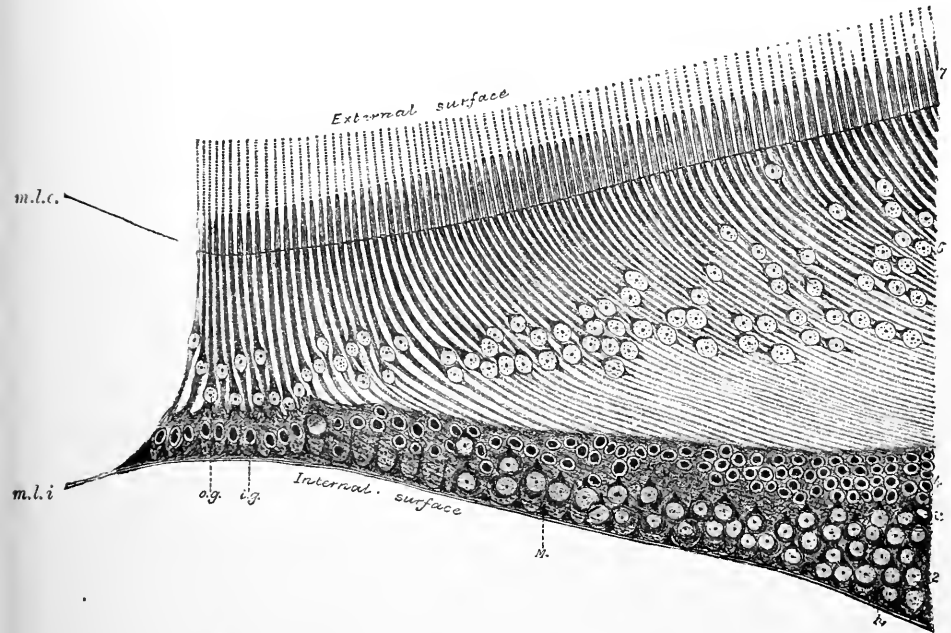


Fig. 60.—DIAGRAM OF A SECTION THROUGH THE FOVEA CENTRALIS. (The outlines of this figure have been traced from a photograph.) Magnified 350 diameters. (From a preparation by C. H. Golding-Bird.)

2, ganglionic layer; 4, inner nuclear; 6, outer nuclear layer, the cone-fibres forming the so-called external fibrous layer; 7, cones; *m.l.e.*, membrana limitans externa; *m.l.i.*, membrana limitans interna.

occupied in the greater part of its thickness by the very long and obliquely disposed cone-fibres; the nuclei are only two or three deep, and take up a comparatively small portion of the layer, which was termed the *outer fibrous layer* by Henle. Over most of the yellow spot the cone-nuclei are placed close up to the limitans externa, but a short distance from the middle of the fovea they begin to be removed from the limitans, and at the centre of the fovea they are close to the outer molecular layer. The cells of the pigmentary layer are smaller but deeper (0.01mm. \times 0.016mm.) and more strongly pigmented in the macula lutea than in the rest of the retina. The hyaloid membrane of the vitreous humour is very thin over the centre of the fovea. The choroid coat is thickened opposite the fovea, the thickening being due to an accumulation of capillary blood-vessels, which here occupy not only their usual position but also that of the layer of larger blood-vessels, and even encroach on the lamina suprachoroidea (Nuël).

The yellow tint of the macula is absent at the centre of the fovea : it is said to be due to a diffuse colouring matter which is seated in the interstices between the elements of the four or five inner layers. The yellow colour of this part of the retina is peculiar to Primates : in man it develops after birth. A corresponding area is found however in all mammals, characterized by a lack of dark pigment in the pigmentary layer, while in some mammals (Chievitz) as well as in birds, reptiles and amphibia (H. Müller, Hulke, W. Krause), a fovea has been described within such a central area. In some birds two foveæ are present, one being near the ora serrata : in some cases several foveæ are found (Chievitz). The central area is always characterized by containing relatively smaller visual cells. The occurrence and relative development of the central area and fovea in vertebrata has been specially investigated by Chievitz (see Bibliography).

Structure of the ora serrata and pars ciliaris retinae.—At the line of the *ora serrata* the numerous complex layers of the retina disappear, and in front of it, the retina is represented merely by a single stratum of elongated columnar cells with the pigmentary layer external to it (*pars ciliaris retinae*). The transition is, in man, somewhat abrupt, all the changes being met within a zone of about 0.1 mm. in breadth. The layer of rods and cones (fig. 61, *g*) first disappears as a complete layer, the cones continuing rather further than the rods, but being imperfectly formed and lacking the outer segments ; the nerve- and ganglionic layers, which were already very thin and incomplete, cease altogether at the ora, the inner.




Fig. 61.—VERTICAL SECTION THROUGH THE CHOROID AND RETINA NEAR THE ORA SERRATA (Kölliker). 60 DIAMETERS.

a, hyaloid membrane ; *b*, limiting membrane and nervous layer of the retina ; *c*, ganglionic and inner molecular layers with closely set Müllerian fibres ; *d*, inner nuclear ; *e*, outer molecular ; *f*, outer nuclear layer ; *g*, columnar layer ; *h*, pigment ; *i, k*, choroid ; *l*, part of one of the ciliary processes ; *m*, pars ciliaris of the retina. (The recess shown at *a'* is not constant.)

Fig. 62.—A SMALL PORTION OF THE CILIARY PART OF THE RETINA (Kölliker). 350 DIAMETERS.
A, human ; B, from the ox ; 1, pigment-cells ; 2, columnar cells.

molecular layer (*c*), which is now largely occupied by Müllerian fibres, retains its thickness up to a certain point, and then abruptly terminates (*a'*), as do also the nuclear layers, outer and inner (*f, d*). The columnar cells of the pars ciliaris, which appear directly to continue these layers of the retina, are at first of considerable length, but become gradually shorter anteriorly ; they are finely striated (fig. 62, 2), and each cell has a clear oval nucleus at the outer part of the cell, near the pigmentary layer. The inner end may be rounded, pointed, square, or even branched ; the sides of the cells, too, are sometimes uneven.

This double layer of cells is continued as before said over and between the ciliary processes to join the uveal layer upon the posterior surface of the iris (*pars iridica retinae*). On the ciliary processes, and especially their anterior aspect, glandular depressions of the epithelium occur which may be solid or may be provided with a

lumen like true tubular glands (E. T. Collins). The function of these *ciliary glands* is not certainly known, but they are believed to take part in the secretion of the aqueous humour.

Vessels of the Retina.—A single artery (*arteria centralis retinae*) passes between the bundles of fibres of the optic nerve to the inner surface of the retina at the middle of the papilla optici (fig. 64). It enters the nerve about 15—20 mm. from the globe of the eye, being accompanied by the corresponding vein and giving off small branches to supply the central part of the nerve. Emerging at the papilla oculi the vessels divide into branches (fig. 63), usually two, one above, the other below (*superior and inferior papillary branches*), each of these again almost immediately dividing into two branches which arch out towards

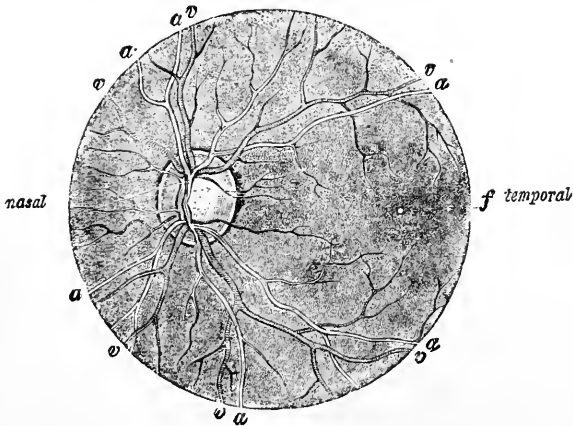


Fig. 63.—RETINA AS SEEN WITH THE OPHTHALMOSCOPE. (Jaeger.)
a, a, branches of central artery; v, v., branches of central vein; f, fovea.

the sides (*superior and inferior nasal and temporal branches*); the outer ones are somewhat the larger, and as they bend round the macula lutea they send numerous fine branches into it which end, a short distance from the centre of the fovea, in capillary loops. The macula is also supplied by small vessels which pass directly to it from the papilla. The middle of the fovea centralis has no blood-vessels. The main branches of the vessels pass forwards in the nerve-fibre and ganglionic layers, dividing dichotomously as they proceed, and giving off fine offsets to the substance of the retina, where they form two capillary networks, the one in the nerve- and ganglionic layer, the other in the inner nuclear layer. The capillaries of the former are mainly connected with the arteries, and those of the latter with the veins, the communication between the two networks being effected by vertically and obliquely coursing capillaries which traverse the inner molecular layer. No vessels penetrate the outer molecular layer (His, Hesse), so that the outer retinal layers are entirely destitute of blood-vessels. The retinal arteries have no anastomoses, thus resembling those of the grey matter of the brain.

The vascular system of the retina is nowhere in direct communication with the choroidal vessels. Near the entrance of the optic nerve, however, it comes into communication with some offsets from the posterior ciliary in the sclerotic coat, and the choroidal vessels also send branches to join the long-meshed network in the optic

nerve furnished by the central artery. The arteries of the retina have the usual coats, but the veins resemble capillaries in structure, their walls consisting of a single layer of endothelial cells without any muscular tissue. Outside the endothelial layer is a space (perivascular lymphatic space, His) both in the veins and capillaries, bounded externally by a second endothelial layer (forming the wall of the lymphatic space). Outside this again is found, in the case of the veins, a layer composed of a peculiar retiform tissue. These perivascular lymphatic spaces are in communication

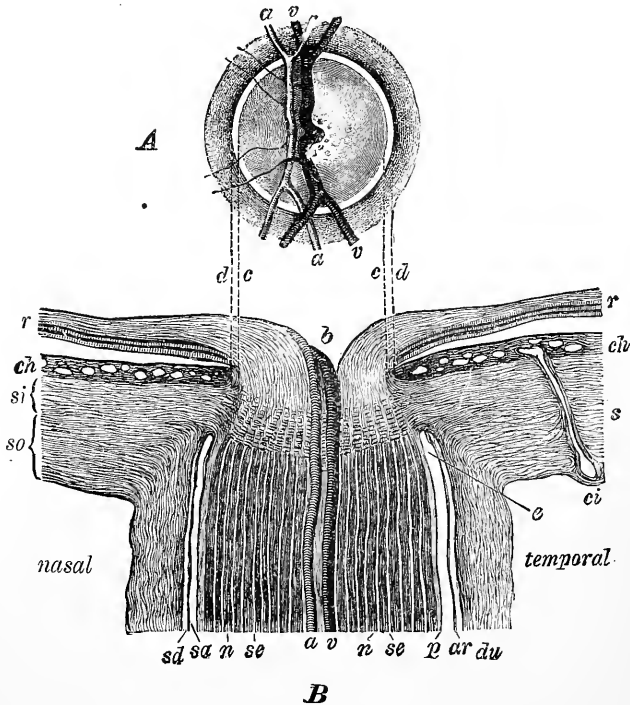


Fig. 64.—SECTION THROUGH THE PLACE OF ENTRANCE OF THE OPTIC NERVE (B), TOGETHER WITH THE OPHTHALMOSCOPIC VIEW OF THE DISK (A), TO SHOW THE CORRESPONDING PARTS OF THE TWO. (Fuchs, after Jaeger.)

c, d, lines of correspondence; *b*, depression in centre of disk; *r*, retina; *ch*, choroid; *si, so*, inner and outer parts of the sclerotic coat; *s*; *ci*, a ciliary artery cut longitudinally; *a, v*, central artery and vein; *s, d*, subdural space; *sa*, subarachnoid space; *du*, dural sheath; *ar*, arachnoidal sheath of nerve; *p*, pial sheath; *n*, nerve bundles; *se*, septa between them.

with the lymphatic spaces of the optic nerve, and may be filled by injecting coloured fluid under the sheath which that nerve derives from the pia mater. Other lymph-spaces also become injected by the same process, viz., the interstices between the nerve-bundles which radiate from the papilla optici, the capillary space between the limitans interna and the hyaloid membrane of the vitreous humour, and finally even the irregular interstice between the pigmentary layer and the layer of rods and cones (Schwalbe). With one or two exceptions (Chelonia, eel) no vertebrates below mammals have blood-vessels in the retina: even in some mammals the distribution is restricted to the posterior part of the eye and to the nerve-fibre layer.

Interconnection of the retinal elements.—It is only comparatively recently, by the aid of the method of Ehrlich (staining *intra vitam* with methyl-blue) and that of Golgi (chromate of silver impregnation), that histologists have been able

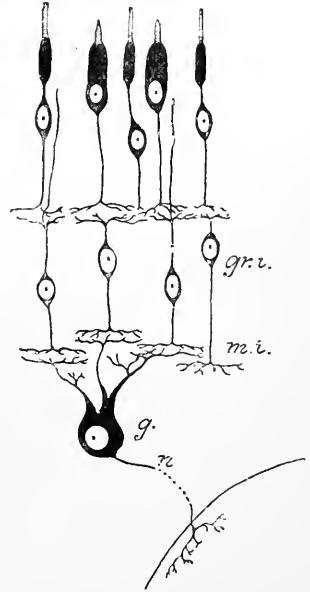
definitely to trace the course and connections of the fibres which pass from and to the several retinal elements. The most fruitful applications of Golgi's method have been made by Ramón y Cajal, following up investigations by Dogiel, which were made by Ehrlich's method; it is the account given by the first-named observer which will here in the main be followed.

In the first place, it would appear that there is no direct anatomical continuity between the elements of the several layers, with the exception of some of the nerve-fibres of the first layer and the ganglionic cells immediately outside them. As with other parts of the nervous system (see Part I. of this volume) the nerve-elements of the retina are anatomically isolated units, merely coming into connection with one another by the interlacement of their arborescent processes. These interlacements occur in two places, viz., in the two molecular layers. In the

Fig. 65.—DIAGRAM SHOWING THE MODE OF CONCATENATION OF THE VISUAL NERVOUS ELEMENTS IN THE VERTEBRATE TYPE.

outer molecular layer is found the interlacement by which the rod- and cone-elements are brought into connection with the inner granules. In the inner molecular layer there is a series of interlacements running mainly in planes parallel to the surfaces of the layer, and serving to bring the elements of the inner nuclear layers into connection with those of the ganglionic layer. Finally, some of the nerve-fibres of the first or innermost layer ramify directly in the molecular layer or pass through this layer and ramify amongst the inner granules (figs. 50, 51, 64).

The retina, therefore, is essentially formed by a number of nerve-cell chains, the elements of which are arranged in three series from without in. The first of these is formed by the rod- or cone-element. One end of this element abuts against or is imbedded in a pigment-cell, the other end interlaces by the terminal arborisation of the rod- or cone-fibre within the outer molecular layer, with the peripheral arborisations of the next elements. The latter are the bipolar inner granules (fig. 65, *gr.i.*). These, by the peripheral process just mentioned, interlock with the arborisations of the rod- and cone-fibres and in some animals also send the fibres of Landolt as far as the membrana limitans externa. By their central processes they ramify within the inner molecular layer (*m.i.*) and interlace with the peripheral processes of the ganglion-cells (*g*). The last-named form the third of the concatenated elements. Their peripheral processes spread out in the inner molecular layer, and are connected with the central processes of the inner granules in the manner just stated. Their central process (*n*) is an axis-cylinder of one of the fibres of the optic nerve, and its terminal ramification is to be found in the grey matter of the superior corpora quadrigemina, or of the lateral geniculate bodies. The functions of the other cell elements in the retina, such as the horizontal cells, which ramify in the outer molecular layer, and the amacrine-cells of Cajal, which are distributed in the inner molecular layer, are still quite obscure.



THE VITREOUS BODY.

The vitreous body occupies the greater portion of the eyeball. It is quite pellucid in aspect, and of a soft gelatinous consistence. Sub-globular in form, it fills about four-fifths of the ball, and serves as a support for the delicate retina, but it may be readily separated from the latter, except behind, at the entrance of the optic nerve, where the connection is closer, the retinal vessels having here entered it in foetal life. At the fore part it is hollowed out (*fossa patellaris*) for the reception of the lens and its capsule, to which it is closely adherent. The vitreous humour contains 98.5 % of water. The solids are chiefly salts and extractives, with a trace of proteid and nucleoalbumin.

The surface of the vitreous humour is covered everywhere by a thin glassy membrane, named *hyaloid*, which lies between it and the retina. In the last edition

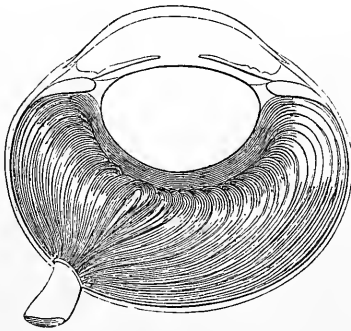


Fig. 66.—HORIZONTAL SECTION OF THE HORSE'S EYE HARDENED IN CHROMIC ACID (after Hannover).

The vitreous humour appears concentrically and meridionally striated throughout its whole depth.

of this work it was stated that, according to the most recent observations, there is no binding membrane between the vitreous humour and the lens capsule, but it has been shown by Anderson Stuart that the older view regarding this subject is more correct, for after removal of the lens within its capsule it is still possible to demonstrate the existence of a delicate glassy membrane over the *fossa patellaris* in the front of the vitreous humour, and this can be none other than a continuation of part of the hyaloid membrane. No vessels enter the vitreous humour in the adult, and its nutrition must, therefore, be dependent on the surrounding vascular structures, viz., the retina and the ciliary processes.

Although in the fresh state, apparently structureless, or at least presenting under the microscope but faint traces of fibres and a few cells—the so-called corpuscles of the vitreous




Fig. 67.—TRANSVERSE SECTION OF HUMAN EYE HARDENED IN CHROMIC ACID, SHOWING RADIAL STRIATION OF THE VITREOUS BODY (after Hannover).

humour to which we shall immediately recur,—yet in preparations hardened in weak chromic acid, or acted upon in certain other ways, it is possible to make out a more or less distinct lamellation of the vitreous body, especially in its peripheral part, that, namely, nearest the retina; which part in the human eye has a somewhat firmer consistence than the more central portion. From the appearances (figs. 66, 67) which have been obtained by such modes of preparation it has been conjectured by various observers that at least in this part the vitreous substance is divided into compartments by a number of delicate membranes arranged concentrically and parallel to the surface; but the existence of such membranous partitions has not been conclusively demonstrated. That, however, the vitreous substance does in some way consist of a firmer material—either in the shape of continuous membranes, or, as H. Virchow states, in the form of a network of fibres—enclosing in its meshes the more fluid portion, is shown by the fact that if either the whole or a piece of the vitreous humour be thrown upon a filter, a small proportion always remains upon the latter; although by far the larger part drains away, and may be collected as a clear watery fluid.

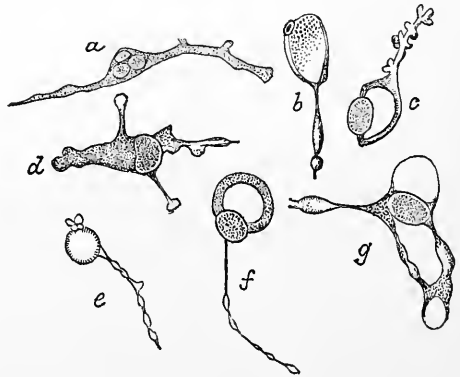
In addition to the above-mentioned concentric striation, a radial marking has also been observed in sections of vitreous humour made transversely to the axis of the eyeball, but whether there is any pre-existent structure to account for it is not known. It is conceivable that these appearances may be merely produced by the manner in which the albuminous substance has undergone coagulation by the reagent employed.

It has also been shown by Iwanhoff, Younan and A. Stuart that the periphery of the vitreous humour near the ciliary body, is considerably strengthened and rendered more consistent by the presence of an accumulation of fibres which encircle this part of the posterior chamber of the eye, and are believed to aid in supporting the ciliary body and the attachment of the suspensory ligament of the lens to that body. The fibrous structure in question appears to be continuous with the fibres of the zonula of Zinn (see below), which here strengthen the hyaloid membrane.

There further exists, nearly but not quite in the axis of the eye, a definite structure in the shape of a distinct canal, about 2 mm. in diameter, filled with fluid and extending from the *papilla optici* to the back of the lens-capsule, where it apparently terminates blindly (fig. 69). This is the *canalis hyaloideus* or *canal of Stilling*. It is best shown in the fresh eye, and may be also injected by forcing a coloured solution under the pia-matral sheath of the optic nerve (Schwalbe). The canal widens somewhat towards its posterior part; its wall is composed of an extremely delicate homogeneous membrane. It represents the place of passage of an offset from the central artery of the retina to the capsule of the lens in the fœtus, and from it lymph may pass into the lymphatic spaces of the optic nerve behind, and perhaps in front round the edge of the lens into the canal of Petit.

Fig. 68.—CELLS OF VITREOUS HUMOURS.
(Schwalbe.)

a and *d*, without vacuoles; *b*, *c*, *e*, *f*, *g*, vacuolated.



Scattered about throughout the substance of the vitreous humour are a variable number of corpuscles, for the most part possessed of amœboid movement. Some of these cells are remarkable for the very large vacuoles which they contain, and which distend the body of the corpuscle, pushing the nucleus to one side; the cell-processes are often peculiar in possessing numerous little secondary bud-like swellings, or they may present a varicose appearance, like strings of pearls.

Suspensory apparatus of the lens.—The hyaloid membrane invests, as before mentioned, the whole of the vitreous humour. As the ora serrata it is apparently split into two layers, one, which must be regarded as the hyaloid membrane proper, being that which has been already mentioned as demonstrable over the anterior surface of the vitreous humour. The other layer into which the hyaloid appears to split adheres to the pars ciliaris retina so closely that when removed it generally shows some of the pigmented cells of that structure adhering to its outer surface. It forms a fibrous structure much firmer in consistence than the true hyaloid, and extends over the ciliary body inwards to be attached to the capsule of the lens, for which it forms a suspensory apparatus, known as the *zonula of Zinn*, or *zonula ciliaris* (fig. 70, *z*). Its free part, which stretches from the ciliary body to the lens capsule, is termed the *suspensory ligament of the lens*. The posterior part, or hyaloid proper, is exceedingly thin and delicate, and is readily thrown into folds when detached. Under the microscope it presents no

appearance of structure ; but, flattened against its inner surface, are generally to be seen a number of granular nucleated corpuscles (leucocytes) which exhibit amoeboid movements. The zonula, on the other hand, is composed of or at least con-

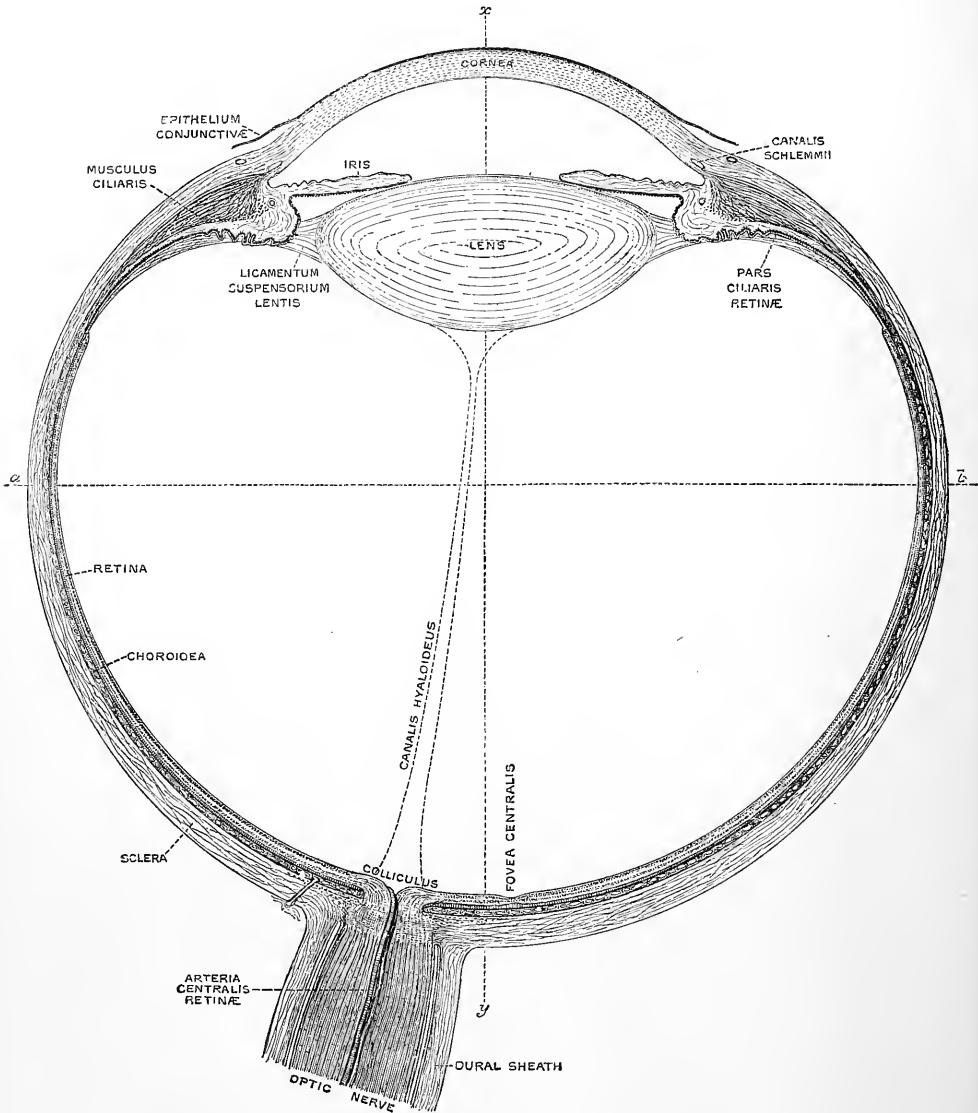


Fig. 69.—RIGHT ADULT HUMAN EYE, DIVIDED HORIZONTALLY THROUGH THE MIDDLE.
(E. A. S.) Magnified 5 times.

The line *a b* passes through the equator, *x y* through the visual axis of the eye.

tains radiating meridional fibres, stiff in appearance but possessed of considerable elasticity ; they commence opposite the ora serrata, and are firmly adherent here to the pars ciliaris retinæ. Over the ciliary body the adhesion, as just stated, is firm to the elevations of that body (ciliary processes), so that when the zonula is torn away

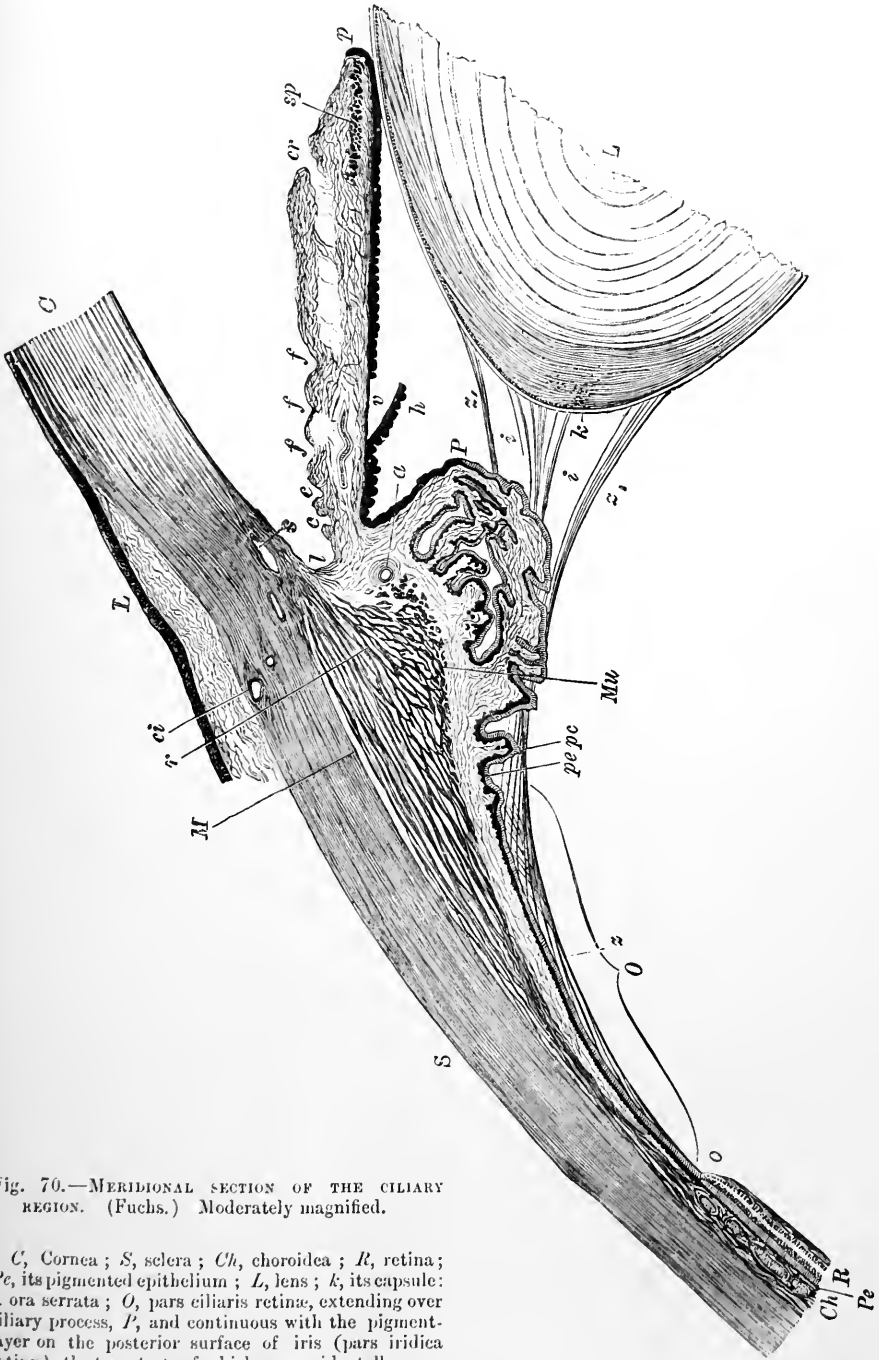


Fig. 70.—MERIDIONAL SECTION OF THE CILIARY REGION. (Fuchs.) Moderately magnified.

C, Cornea; *S*, sclera; *Ch*, chorioidea; *R*, retina; *Pe*, its pigmented epithelium; *L*, lens; *k*, its capsule: *o*, ora serrata; *O*, pars ciliaris retinae, extending over ciliary process, *P*, and continuous with the pigment-layer on the posterior surface of iris (pars iridica retinae), the two strata of which are accidentally separated at *r*, *h*; *pc*, *pc*, pigmented and columnar layers of pars ciliaris; *z*, zonule of Zinn, continuous over and between the ciliary processes with the fibres of the suspensory ligament of the lens, *z'*, *i*, which are attached to the lens capsule; *M*, meridional fibres of the ciliary muscle; *r*, radiating or interlacing fibres of the same; *Mu*, Müllerian or circular fibres of the same; *S*, canal of Schlemm; *I*, iris-corner; *c*, *c*, *f*, *f*, folds in anterior surface of iris; *p*, edge of pupil; *sp*, sphincter pupillae; *ci*, anterior ciliary artery; *a*, circular artery in ciliary body; *gl*, glandular depressions in ciliary body.

the pigment is often detached from these processes. Over the intervals between the ciliary processes the zonula is, however, less closely applied to the pars ciliaris retinae, so that a series of pouches, narrowing posteriorly and widening anteriorly, where they communicate with the posterior chamber, become left between zonula and ciliary body (*recesses of the posterior chamber*, Kuhnt). It is into these recesses that the ciliary glands (see p. 55) open. The recesses are occupied by aqueous humour, and traversed by fibres belonging to the zonula of Zinn, which serve to attach the outer surface of that membrane to this portion of the pars ciliaris retinae: they are also partly subdivided by small subsidiary folds of the ciliary body which project into the recesses. Opposite the most prominent part of the ciliary body the zonula gives off bundles of fibres which pass meridionally inwards towards the margin of the lens, some reaching and extending a short distance over its anterior surface, others just reaching its posterior surface, and others again occupying intermediate positions at the margin (fig. 70). They are all firmly cemented to the lens-capsule. Those which pass anteriorly originate mainly from the part of the zonula which lies in the intervals between the ciliary processes: they form a radially fibrous mem-

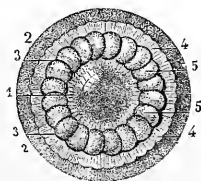


Fig. 71.—VIEW FROM BEFORE OF THE CANAL OF PETIT INFLATED (from Sappey).

The anterior parts of the sclerotic, choroid, iris and cornea having been removed, the remaining parts are viewed from before, and the canal of Petit has been inflated with air through an artificial opening. 1, front of the lens; 2, vitreous body; 3, outer border of the canal of Petit; 4, outer part of the zonule of Zinn; 5, appearance of sacculated dilatations of the canal of Petit.

branous layer, but it is not quite complete, for coloured injection can be easily made to pass from the interstices between the lens capsule and the ciliary body into the aqueous humour and *vice versa*. The clefts in it are fine enough, however, to retain air if blown into this interstice: if this be done after removal of the whole vitreous body (a removal which can be easily effected in an eye which has been left for a day or two at the ordinary atmospheric temperature), the interstices which correspond with the eminences of the ciliary processes are most distended, and the appearance of a sacculated canal (*canal of Petit*), encircling the lens, is produced as in fig. 71.

The canal which is thus artificially produced is bounded behind by the part of the hyaloid membrane which covers the front of the vitreous humour, and in front by the imperfect membrane above alluded to as formed by the fibres of the zonula which are passing to the anterior surface of the lens margin. Since these fibres spring most abundantly from the part of the zonula which is opposite the intervals between the ciliary processes, the membrane is as it were tied down at those intervals and can only be distended between them; hence the sacculated aspect of the so-called canal.

Berger states that in the foetus the anterior free surface of the zonula is covered with a layer of endothelial cells which disappears by birth.

As just stated, in addition to this anterior membranous prolongation of the zonula, other fibres, more scattered in their disposition, pass at intervals across to the periphery of the lens, some being attached to the extreme edge, others coming into continuity with the posterior capsule, and others again occupying intermediate positions (fig. 70). Those which pass to the posterior surface of the lens capsule and to the extreme edge of the lens are stated to come for the most part from the part of the zonula which overlies and is adherent to the most prominent portion of the ciliary body, and these fibres therefore partially cross in direction those which are coming from the depressions and passing to the anterior surface.

THE LENS.

The lens (*lens crystallina*) is a transparent solid body, of a doubly convex shape, with the circumference rounded off. It is completely enclosed by a transparent, highly elastic membrane known as the *capsule of the lens*. The anterior surface is in

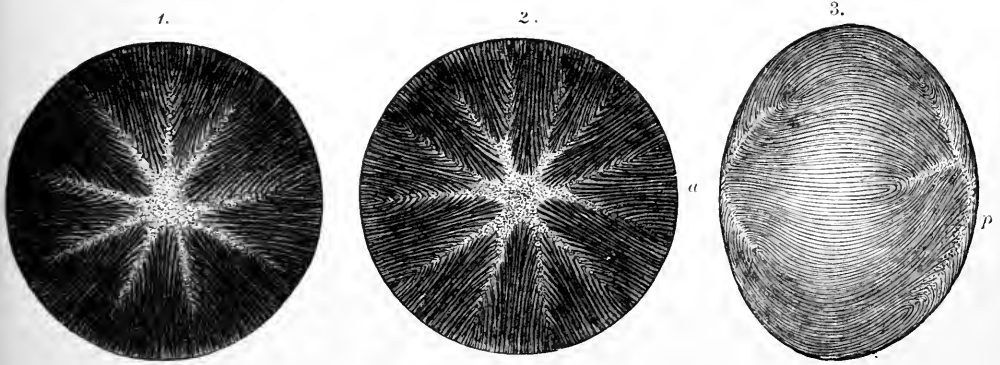


Fig. 72.—1, FRONT VIEW ; 2, HIND VIEW ; 3, LATERAL VIEW OF THE FIBROUS STRUCTURE OF THE ADULT LENS (after Arnold). $\frac{1}{2}$

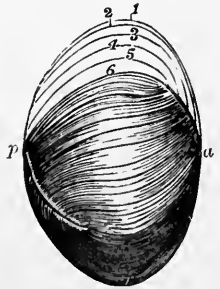
a, anterior ; *p*, posterior pole. The direction of the superficial fibres is indicated by the curved lines.

contact with the iris towards the pupil, receding from it slightly at the circumference ; the posterior is embedded in the vitreous humour. Around the circumference is the zonula. The capsule is strongest anteriorly (anterior capsule) and thinnest over the

Fig. 73.—DIAGRAM TO ILLUSTRATE THE COURSE OF THE FIBRES IN THE FETAL CRYSTALLINE LENS. (Allen Thomson.)

a, anterior ; *p*, posterior pole.

posterior surface of the lens (posterior capsule). Chemically the lens-capsule yields neither elastin nor gelatin, but appears similar in composition to the sarcolemma of muscle and the membranæ propriæ of glands. An indistinct fibrous and lamellar structure has been described in it. The convexity of the lens is not alike on the two surfaces, being greater behind ; moreover, the curvature is less at the centre than towards the margin. When in its natural position it measures about 8mm. to 9mm. across, and about 4mm. from before backwards. The radius of curvature during life of the anterior surface varies with the condition of accommodation from about 10mm. when the eye is accommodated for distant vision, to 6mm. when accommodated to the near point of distinct vision. That of the posterior surface is about 6mm. in distant vision and a little less in near vision. In a fresh lens, divested of its capsule, the outer portion is soft and easily detached ; the succeeding layers are of a firmer consistence ; and in the centre the substance becomes much harder, constituting the so-called "nucleus." On the anterior and posterior surfaces are faint white lines directed from the poles towards the circumference ; these in the



adult are somewhat variable and numerous on the surfaces (fig. 72), but in the foetal lens throughout, and towards the centre of the lens in the adult, they are three in number, diverging from each other like rays at equal angles of 120° (fig. 73). The lines which converge to the opposite poles have an alternating position. Thus of those seen on the posterior surface of the foetal lens, one is directed vertically upwards, and the other two downwards and to either side, whereas those on the anterior surface are directed one directly downwards and the other two upwards and to the sides. These lines are the edges of planes or septa within the lens diverging from the axis, and receiving the ends of the lens-fibres, which here abut against one

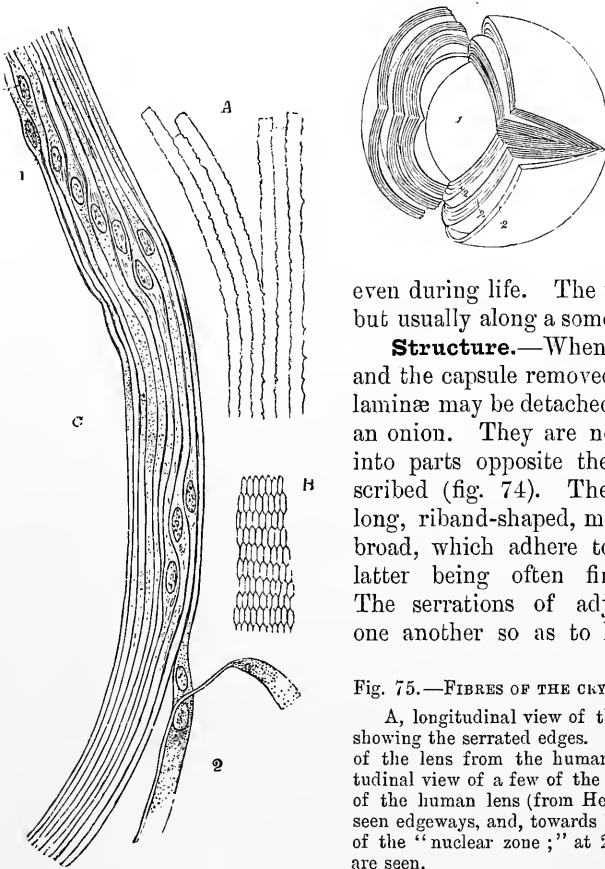


Fig. 74.—LAMINATED STRUCTURE OF THE CRYSTALLINE LENS, SHOWN AFTER HARDENING IN ALCOHOL (Arnold). $\frac{4}{5}$
1, nucleus; 2, 2, lamellæ.

another. As Tweedy has pointed out, they may be seen, by the aid of the ophthalmoscope,

even during life. The rays seldom meet at a point, but usually along a somewhat irregular area.

Structure.—When the lens has been hardened and the capsule removed, a succession of concentric laminae may be detached from it like the coats from an onion. They are not continuous, but separate into parts opposite the radiating lines above described (fig. 74). The laminae are composed of long, riband-shaped, microscopic fibres, 0.005mm. broad, which adhere together by their edges, the latter being often finely serrated (fig. 75, A). The serrations of adjacent fibres abut against one another so as to leave as in other epithelial

Fig. 75.—FIBRES OF THE CRYSTALLINE LENS. 350 DIAMETERS.

A, longitudinal view of the fibres of the lens from the ox, showing the serrated edges. B, transverse section of the fibres of the lens from the human eye (from Kölliker). C, longitudinal view of a few of the fibres from the equatorial region of the human lens (from Henle). Most of the fibres in C are seen edgewise, and, towards 1, present the swellings and nuclei of the "nuclear zone;" at 2, the flattened sides of two fibres are seen.

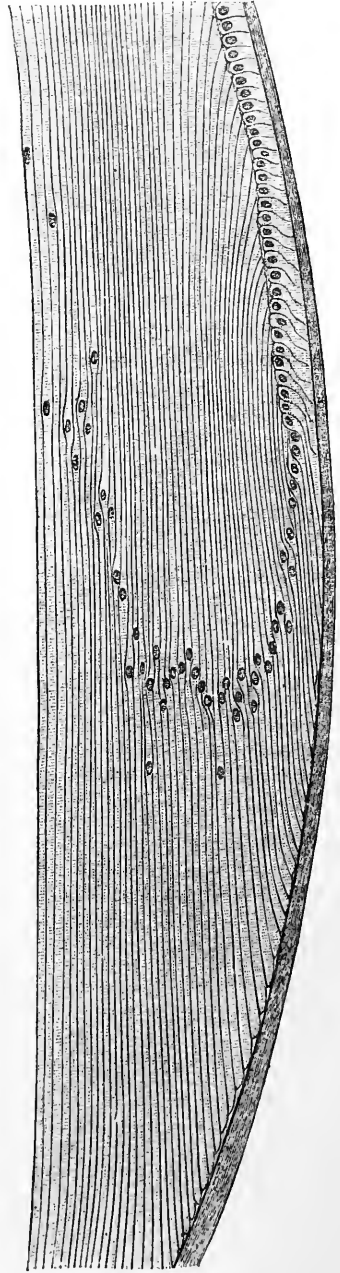
structures fine interfibrillar or intercellular channels for the passage of fluid. The lens-fibres pass in a curved direction from the intersecting planes of the anterior half of the lens to those of the posterior half, or *vice versa*: in this course no fibre passes from one pole to the other, but those fibres which begin near the pole or centre of one surface, terminate near the marginal part of a plane on the opposite surface, and conversely; the intervening fibres passing to their corresponding places between. The arrangement will be better understood by a reference to fig. 73, where the course of the fibres in the foetal lens is diagrammatically indicated.

The lens-fibres, as the history of their development shows, are to be looked upon as greatly elongated cells. In the young state each has a clear oval nucleus, but in

the fully-formed lens the nuclei have disappeared from the fibres which form the more internal parts of the lens, and only remain in the more superficial layers.

Fig. 76. — SECTION THROUGH THE MARGIN OF THE LENS, SHOWING THE TRANSITION OF THE EPITHELIUM INTO THE LENS-FIBRES (Babuchin).

Here they are found, not quite in the middle of each fibre, but slightly nearer the anterior end, their situation nearly corresponding in adjacent fibres, and they form by their juxtaposition the so-called "nuclear zone" around the lens. The superficial fibres further differ from the more deeply seated ones in being softer and larger, and in possessing a plain, unserrated margin. The extremities of all the fibres are softer and more readily acted on by reagents than the middle parts, and the axial or more internal part of a fibre more so than the external, but the transition is gradual from one to the other, and there is no definite membrane enclosing each fibre. The lens-fibres when cut across are seen to be six-sided prisms (fig. 75 B). By reason of this shape they fit very exactly the one to the other with but little interfibrillar cementing substance between. This is met with in rather larger quantity in the intersecting planes between the ends of the fibres.



Thin and Ewart have shown that with certain methods of treatment the superficial lens-fibres show indications of being composed of a number of regular segments separated by sharply marked lines of intersegmental substance (Journal of Anatomy, 1876).

The **capsule** of the lens is a transparent structureless membrane; somewhat brittle and elastic in character, and when ruptured the edges roll outwards. The fore part of the capsule, from about 2.5 mm. from the circumference, where the anterior part of the suspensory ligament joins it, is much thicker than the back: at the posterior pole of the lens the capsule is very thin indeed. In the adult, it, like the lens itself, is entirely non-vascular, but in the foetus there is a network of vessels in the superficial part of the capsule, supplied by the terminal branch of the central artery of the retina, which passes from the optic papilla through the canal of Stilling in the vitreous humour to reach the back of the capsule, where it divides into radiating branches. After forming a fine network, these turn round the margin of the lens and extend forwards to become continuous with the vessels in the pupillary membrane and iris (fig. 42, p. 34).

Epithelium of the capsule.—At the back of the lens the fibres are directly in contact with the inner surface of the capsule, but in front they are separated from the latter by a single layer of cubical, polygonal, nucleated cells, which covers the whole anterior surface underneath the capsule. Towards the edge or equator of the lens the appearance and character of these cells undergo a change: they first gradually take on a columnar form, and then, becoming more and more elongated, present every transition to the nucleated lens-fibres of the superficial layers, into which they are directly continuous (see fig. 76).

After death a small quantity of fluid (liquor Morgagni) frequently collects between the back of the lens and the capsule: it appears to be derived from the lens-fibres. There is no epithelium in this situation as in front.

Changes in the lens with age.—In the *fœtus*, the lens is nearly spherical (fig. 77, *a*): it has a slightly reddish colour, is not perfectly transparent, and is softer and more readily broken down than at a more advanced age.



Fig. 77.—SIDE VIEW OF THE LENS AT DIFFERENT AGES.

a, at birth with the deepest convexity; *b*, in adult life with medium convexity; *c*, in old age with considerable flattening of the curvatures.

In the *adult*, the anterior surface of the lens is distinctly less convex than the posterior (fig. 77, *b*); and the substance of the lens is firmer, colourless, and transparent.

In *old age*, it is more flattened on both surfaces (*c*); it assumes a yellowish or amber tinge, and is apt to lose its transparency and gradually to increase in toughness and specific gravity.

AQUEOUS HUMOUR AND ITS CHAMBER.

The aqueous humour fills the space in the fore part of the eyeball, between the capsule of the lens with its suspensory ligament and the cornea. The iris, resting in part upon the lens, divides the aqueous chamber partially into two, named respectively the anterior and posterior chambers. This subdivision is incomplete in the adult, but in the *fœtus* before the seventh month it is completed by the *membrana pupillaris*, which, by its union with the margin of the pupil, closes the aperture of communication between the two chambers.

The *anterior chamber* is limited in front by the cornea and behind by the iris, while opposite the pupil it is bounded by the front of the lens and its capsule.

The *posterior chamber* lies behind the iris. It is continuous through clefts in the anterior part of the suspensory ligament of the lens with the triangular space intervening between the margin of the lens, the anterior surface of the vitreous humour and the ciliary body (canal of Petit), and it sends prolongations or pouches between the zonula and the *pars ciliaris retinæ*, as has already been described (p. 62). The aqueous humour is a clear watery fluid, in which a few leucocytes can sometimes be found. It is probably secreted mainly by the epithelium of the ciliary body and its glands, and by the epithelium covering the posterior surface of the iris. It finds exit through the clefts of the *ligamentum pectinatum iridis*, into the spaces of Fontana and thence into the canal of Schlemm and the venous system of that region, and in part into lymph-spaces in the iris, and thence to the perichoroideal lymph-space.

RECENT LITERATURE OF THE EYE.

- Alexander, A.**, *Ueber die Lymphcapillaren der Chorioidea*, Archiv für Anatomie u. Phys., Anat. Abt., 1889.
- Anderson, R. J.**, *The lens in an albino rat*, Monthly Int. Journal of Anatomy and Physiology, x., 1893.
- Angelucci, R.**, *Ricerche istol. contr. epitelio retinico dei vertebrati*, Atti d. R. accad. dei Lincei, 1877.
- Arnstein u. Agabow.** *Die Innervation des Ciliarkörpers*, Anat. Anzeiger, 1893.
- Baquis, Elia**, *La retina della faina*, Anatomischer Anzeiger, Jahrg. v., 1890.
- Barabaschew, P.**, *Beitrag zur Anatomie der Linse*, Archiv für Ophthalmologie, xxxviii., 1892.
- Barrett, J. W.**, *The distribution of blood-vessels in the retina of mammals*, Journ. of Physiology, vol. vii., 1886.
- Bayer, J.**, *Bildliche Darstellung des gesunden und kranken Auges unserer Haustiere*, Wien, 1890.
- Beauregard**, *Etude du corps vitré*, Journal de l'Anat., 1880.
- Behrends, G. J.**, *Beiträge zur Kenntniss der Entwicklung des Nervus opticus und des Glaskörpers bei Säugethieren*, Erlangen, 1888.
- Berger, Emile**, *Anatomie normale et pathologique de l'œil*, Paris.
- Boden, J. S., and Sprawson, F. C.**, *The pigment cells of the retina*, Quarterly Journal of Microscopical Science, xxxiii. 1892.
- Brand, Emil**, *Die Nervenendigungen in der Hornhaut*, Archiv für Augenheilkunde, Band xix. 1888; (Translation in Archives of Ophthalmology, New York, vol. xviii.).
- Canfield, W. B.**, *Vergl. anatom. Studien ü. d. Accommodations-apparat des Vogelauges*, Arch. f. mikr. Anat., xxviii., 1886.
- Chiewitz, J. H.**, *Entwicklung der Fovea centralis retinae; Die Area centralis retinae*, Verhandlungen der anatom. Gesellschaft auf der 2. u. 3. Versammlungen, Anatom. Anzeiger, ii. and iii. 1888, 1889; *Untersuchungen über die Area centralis retinae*, Arch. f. Anat. u. Physiol., Anat. Abtlg. 1889; *Ueber das Vorkommen der Area centralis retinae in den vier höheren Wirbeltierklassen*, Archiv für Anatomie und Physiologie, Anatomische Abteilung, 1891; *Untersuchungen über die Entwicklung der Area und Fovea centralis retinae*, Arch. f. Anat. u. Physiol., Anat. Abtlg.; *Die Area und Fovea centralis retinae beim menschlichen Fetus*, Internationale Monatschrift für Anatomie und Physiologie, Band iv., 1887.
- Ciaccio, G. V.**, *Di una novissima e notevole particolarità di struttura osservata nella cornea di un cavallo*, Memorie della r. accademia delle scienze di Bologna, v. 1891.
- Cirincione, G.**, *Sulla struttura delle vie lacrimali dell'uomo*, La riforma medica, vi. 1890.
- Claeys, G.**, *De la région ciliaire de la rétine et de la zonule de Zinn*, Archives de biologie, tome viii., 1888.
- Collins, E. T.**, *The glands of the ciliary body in the human eye*, Transactions of the Ophthalmological Society of the United Kingdom, London, 1890—91; *On the development and abnormalities of the zonule of Zinn*, R. London Ophth. Hosp. Reports, xiii., 1891.
- Collins, W. J.**, *The composition of the human lens in health and in cataract, and its bearing upon operations for the latter*, Illustrated Medical News, 1889.
- Colucci, Cesare**, *Alterazioni nella retina d. rana in seguito alla recisione del nervo ottico*, Riforma medica, 1890.
- Cuccati, G.**, *Contributo all' anat. microsc. della retina del buco e del cavallo*, Mem. d. r. accad. d. sci. di Bologna, 1886; *Sur la structure rayonnée du segment externe des bâtonnets de la rétine*, Arch. ital. de biol., vii. 1886.
- Czermak, Wilh.**, *Beitrag zur Kenntniss der sog. cilio-retinalen Gefässe*, Wiener klinische Wochenschrift, 1888.
- Debierre, Ch.**, *Sur le muscle de l'iris de l'homme*, Comptes rendus de la société de Biologie, v. 1888.
- Dimmer, F.**, *Die ophthalmoskopischen Lichtreflexe des Netzhaut nebst Beiträgen z. normal. Anat. der Netzhaut*, Wien.
- Dogiel, Alexander**, *Ueber die nervösen Elemente in der Netzhaut der Amphibien u. Vogel*, Anat. Anzeiger, iii.; *Ueber das Verhalten der nervösen Elemente in der Retina der Ganoiden, Reptilien, Vögel und Säugethiere*, Anatom. Anzeiger, iii., 1888; *Die Nervenendkörperchen in der Cornea und Conjunctiva bulbi des Menschen*, Archiv für mikroskopische Anatomie, xxxvii., 1891; *Ueber die nervösen Elemente in der Retina des Menschen*, Archiv für mikroskopische Anatomie, xxxviii., 1891; xl., 1892.
- Dogiel, J.**, *Neue Untersuch. ü. d. pupillenerweiternden Muskeln, etc.*, Arch. f. mikr. Anat., xxvii. 1886; *Neuroglia der Retina des Menschen*, Arch. f. mikr. Anat., 1893.
- Dostojewsky, A.**, *Ueber d. Bau des Corpus ciliare u. der Iris von Säugethieren*, Arch. f. mikr. Anat., xxviii. 1886.
- Dubois, Raphael, et Renaut, J.**, *Sur la continuité de l'épithélium pigmenté de la rétine avec les segments externes des cônes et des bâtonnets, et la valeur morphologique de cette disposition chez les vertébrés*, Comptes rendus hebdom. de l'académie des sciences de Paris, tome cix. 1889.
- Engelmann, T. W.**, *Uc. Bewegungen der Zapfen u. Pigmentzellen unter d. Einfluss des Lichtes u. des Nervensystems*, Pflüger's Archiv, Bd. xxxv., 1885.
- Ewing, A. E.**, *Ueber ein Bauverhältniss des Irisumfanges beim Menschen*, Archiv für Ophthalmologie, Bd. xxxiv. 1888.
- Falchi, F.**, *Sur l'histogénèse de la rétine et du nerf optique*, Archives italiennes de biologie, tome ix.; *Ueber die Histogenese der Retina und des Nervus opticus*, Archiv für Ophthalm., xxxiv. 1888.

- Fick, Eugen**, *Untersuchungen über die Pigmentwanderung in der Netzhaut des Frosches*, Archiv für Ophthalmologie, xxxvii., 1891.
- Fridenberg, Percy**, *Ueber die Sternfigur der Krystall-Linse*, Strassburg, Inaug. Diss. 1891.
- v. Garnier, R.**, *Ueber den normalen und pathologischen Zustand der Zonula Zinnii*, Archiv für Augenheilkunde, xxiv. 1891.
- Geberg, A.**, *Ue. Nerven der Vogel-iris*, Monthly Intern. Journ. of Anat., Vol. i.
- v. Gendren-Stort**, *Mouvements des éléments de la rétine sous l'influence de la lumière*, Archives néerland. des sci. méd., 1887; *Ueber Form- und Ortsveränderungen der Netzhaut-Elemente unter Einfluss von Licht und Dunkel*, Archiv für Ophthalmologie, Band xxxiii., 1888.
- Gifford, H.**, *Uc. d. Lymphströme des Auges*, Arch. f. Augenheilkunde, xvi. 1886; *Further experiments, &c.*, Arch. of ophthalm., 1892, and Arch. f. Augenheilk., xxvi., 1893.
- Golding-Bird, C. H.**, and **Schäfer, E. A.**, *On the structure of the foeca centralis*, Proc. Physiol. Soc., Journal of Physiol., 1894, and Int. Monthly Journal of Anat. and Physiol., 1894.
- Gottschau**, *Ueber die Entwickl. der Säugethierlinse*, Tagebl. d. 59. Versamml. deutsch. Naturf. u. Aerzte, 1886.
- Gradenigo**, *Ue. d. Einfluss des Lichtes u. d. Wärme an der Retina des Frosches*, Allgem. Wiener Med. Zeitung, 1885.
- Grossmann**, *De l'ossification dans l'œil*, Archives d'ophthalmologie, tome ix. 1889.
- Gruenhagen, A.**, *Ueber die Muskulatur und die Bruch'sche Membran der Iris*, Anat. Anz., iii., 1888.
- Gunn, R. Marcus**, *Researches at the St. Andrews marine laboratory on the embryology of the retina of Teleosteans*, The Annals and Magazine of Natural History, series vi., vol. ii., 1888; *On the nature of light-percipient organs and of light- and colour-perception*, The Royal London Ophthalmic Hospital Reports, 1888; *Congenital malformations of the eyeball and its appendages*, Ophth. Review, viii. 1889; *Growth of new lens-fibres, &c.*, Trans. of the Ophthal. Soc., vol. viii., 1889: Article "Eye" in Morris' Anatomy, 1892.
- Gutmann, G.**, *Ueber die Lymphbahnen der Cornea*, Archiv für mikroskop. Anatomie, xxxii. 1888.
- Haase, F.**, *Ueber den Canalis Petiti des Menschen*, Inaug.-Dissert., Rostock, 1889.
- Hache, E.**, *Sur la structure et la signification du corps vitré*, Compt. rend., cv. 1887; *Sur l'hyaloïde et la zone de Zinn*, Compt. rend. de la soc. de biol., 1889.
- Haensell, P.**, *Recherches sur le corps vitré*, Paris, 1886.
- Hannover, A.**, *On a spongy formation between the sclerotic and choroid coat in new-born children*, The Lancet, 1886, vol. ii.
- Heitzmann, C.**, *The minute structure of the cornea*, The Microscope, Trenton, 1890.
- Hirschberg, J.**, *Blutgefässneubildung im Glaskörper, vor dem Sehnerveneintritt*, Centralblatt für praktische Augenheilkunde, Jahrg. 13, 1889.
- Hosch, F.**, *Ehrlich's Methyleneblaumethode u. ihre Anwendung auf das Auge*, Arch. f. Ophth., Bd. xxxvii., 1891.
- Jessop, W. H.**, *The intra-ocular muscles of mammals and birds*, Abstract of Hunterian lectures, Ophthalmic Review, vol. vi.
- Johnson, G. Lindsay**, *Bemerkungen über die Macula lutea*, Archiv für Augenheilkunde, xxv, 1892; *Observations on the Macula lutea*, Arch. Ophth., New York, 1892.
- Keibel, Franz**, *Zur Entwicklung des Glaskörpers*, Arch. f. Anat. u. Phys., Anatom. Abt., 1886.
- Kirschbaumer, Rosa**, *Ueber Altersveränderungen der Uvea*, Ophthalmologen-Congress, Heidelberg, August, 1888 (Arch. f. Ophthalmologie); *Ueber Altersveränderungen der Uvea*, Archiv für Ophthalmologie, xxxviii., 1892.
- Kohl, C.**, *Rudimentäre Wirbelthieraugen*, Biblioth. Zool., 1893.
- Kollock**, *The eye of the negro*, Trans. Amer. Ophthalm. Assoc., 1892.
- Korányi, A.**, *Beitr. zur Entwicklung der Krystalllinse*, Intern. Monthly Journal of Anatomy and Physiology, iii. 1886.
- Krause, W.**, *Die Retina*, Internationale Monatsschrift für Anatomie. A series of papers (from 1886 onwards) on the comparative structure of the Retina in the vertebrate classes.
- Kühnt**, *Ueber die Fovea centralis*, Sitzungsh. d. ophth. Gesellsch., 1881; *Histologische Studien an der menschlichen Netzhaut*, Jenaische Zeitschrift für Naturwissenschaft, xxiv. 1889.
- Landolt**, *Beiträge zur Anatomie vom Frosch, Salamander u. Triton*, Arch. f. mikr. Anat., vii, 1871.
- Lang**, *The ciliary processes and the suspensory ligament*, Ophthalmolog. Review, December, 1888.
- Lang and Barrett**, *The refractive character of the eyes of mammalia*, Ophth. Hospital Reports, xi. 1886.
- Lange, Otto**, *Topographische Anatomie des menschlichen Orbitalinhalts*, Braunschweig, 1887.
- Langer, Fritz**, *Beitrag zur normalen Anatomie des menschlichen Auges, "Ist man berechtigt, den Perichorioidalraum und den Tenon'schen Raum als Lymphräume aufzufassen?"* Sitzungsber. der Kais. Akad. d. Wiss. in Wien., Bd. xcix., Abt. iii. 1890.
- Lennox, R.**, *Beobacht. ü. d. Histologie der Netzhaut, &c.*, Arch. f. Ophthalm., xxxii. 1886; *Development of the crystalline lens*, Brooklyn Medical Journal, vol. iii. 1889.
- Loewenthal, N.**, *Uc. d. Harder'sche Drüse des Igels*, Anat. Anz. vii., 1892; *Beitr. z. Kenntn. d. Harder'sche Drüse bei d. Säugethiereu*, Ibid.
- Martin, Paul**, *Entwicklung der Netzhaut bei der Katze*, Zeitschrift für vergleichende Augenheilkunde, vii. 1891.
- Matthiessen, S.**, *Die neueren Fortschritte in unserer Kenntniss von dem optischen Bau des Auges der Wirbeltiere*, Beiträge zur Psychologie und Physiologie der Sinnesorgane, Hermann von Helmholtz als Festgruss zu seinem 70. Geburtstag gewidmet, 1891.

- Mayerhausen**, *Der gefäßtose Bezirk der menschlichen Retina*, Arch. f. Ophthalm., xxix., 1883.
- Merian, Karl**, *Versuche über die Lymphwege des Auges*, Archiv für Anatomie und Physiologie, Anatomische Abteilung, 1891.
- Merkel, Fr.**, *Handbuch d. topograph. Anat.*, 1885.
- Merkel, Fr., und Orr, Andrew W.**, *Das Auge des Neugeborenen an einem schematischen Durchschnitt erläutert*, Anatomische Hefte, i., 1892.
- Meyer, E.**, *De la forme de l'hémisphère antérieure de l'œil déterminée par la mensuration des courbes de la cornée et de la sclérotique*, Revue générale d'ophtalmologie, année viii., 1889.
- Michel, J.**, *Ueber die Ausstrahlungsweise der Opticusfasern, etc.*, Ludwig-Festschrift, 1874.
- Morf, J.**, *Exper. Beitr. zur Lehre von den Abflusswegen der vorderen Augenkammer*, Dissert. Zurich, 1888.
- Motais**, *Recherches sur l'anat. humaine et l'anat. comparée de l'appareil moteur de l'œil*, Arch. d'ophtalmologie, vi., 1886.
- Musgrave, James**, *The blood-vessels of the retina*, The Journal of Anatomy and Physiology, 1892.
- Nicati, W.**, *Sur la disposition et le fonctionnement normal et pathologique d'un véritable appareil glandulaire dans l'œil des mammifères*, Comptes rendus hebdom. de l'Académie des sciences, tome cviii. 1889; *Note sur la disposition et le fonctionnement normal d'un appareil glandulaire dans l'œil des mammifères*, Recueil d'ophtalmologie, 1889; *Physiol. et pathol. de la glande des procès ciliaires*, Compt. rend. d. l. soc. de biol., 1889; *La glande de l'humeur aqueuse, glande des procès ciliaires ou glande urée*, Archives d'ophtalmologie, tome x. 1890.
- Nuel, J. P.**, *De l'endothélium de la chambre antérieure*, Archives d'ophtalmologie, x., 1890; *De la vascularisation de la choroïde et de la nutrition de la rétine principalement au niveau de la foca centralis*, Archives d'ophtalmologie, xii. 1892.
- Nuel, J. P., et Cornil, F.**, *De l'endothélium de la chambre antérieure de l'œil, particulièrement de celui de la cornée*, Archives de Biologie, tome x. 1890.
- Paget, Stephen**, *Congenital pigmentation of the sclerotic*, Brit. Med. Journ., 1887.
- Peltesohn, N.**, *Zur Morphologie der Papilla optica*, Centralblatt für praktische Augenheilkunde, xii. 1888.
- Pollock, C. F.**, *The normal and pathological histology of the human eye and eyelids*, London, 1886.
- Pröbsting, A.**, *Ein Beitrag zur feineren Anatomie des Lides u. der Conjunctiva des Menschen u. des Affen*, Zeitschr. f. vergleich. Augenheilkunde, iv. 1886.
- Ramón y Cajal, S.**, *Sur la morphologie et les connexions des éléments de la rétine des oiseaux*, Anatomische Anzeiger, Jahrg. iv. 1889; *Estructura de la retina de las aves*, Revista trimestral de Histologia, &c., año i.; *La retina de los batrachios y reptiles*, Trabajos del laboratorio histol. de Barcelona, 1891; *La retina de los Teleosteos, &c.*, Madrid, 1892; *La rétine des vertébrés*, La Cellule, ix., 1893 [contains a general account of the whole subject, including the author's previous observations].
- Rampoldi, R.**, *Sull'anatomia della regione interna della retina dei mammiferi*, Annali di ottalmologia, xvii. 1888.
- Ranvier**, *Traité technique d'histologie*, 1889.
- Retterer, Ed.**, *Note sur la structure de l'iris chez les mammifères*, Comptes rendus de la Société de biologie, tome v. 1888.
- Rieke, A.**, *Ueber Formen und Entwicklung der Pigmentzellen der Chorioïdea*, Archiv für Ophthalmologie, xxxvii., 1891.
- Ritter, C.**, *Studien über die Stäbchenschicht der Vögel*, Internationale Monatsschrift für Anatomie und Physiologie, viii. 1891; *Zur Histologie der Zapfen der Fischretina*, Internationale Monatsschrift für Anatomie und Physiologie, viii. 1891.
- Rochon-Durigneaud**, *Recherches sur l'angle de la chambre antérieure et du canal de Schlemm*, Paris, 1892; and Arch. d'ophtalm., xiii., 1893.
- Rudloff, P.**, *Ueber eine Eigenthümlichkeit der äusseren Körner*, Arch. f. Anat. u. Phys., Anat. Abth., 1886.
- Rumschewitsch, Conrad**, *Ueber die Anastomosen der hinteren Ciliargefässe mit denen des Opticus und der Retina*, Klinische Monatsblätter für Augenheilkunde, Jahrg. xxvii. 1889; *Zur Morphographie der Papilla nervi optici*, Centralblatt für praktische Augenheilkunde, xiii. 1889.
- Samuelsohn**, *Zur Topographie d. Faserverlaufs im menschlichen Sehnerven*, Centralbl. f. d. med. Wissensch., 1880.
- Sardemann, E.**, *Beiträge zur Anatomie der Thränen-drüse*, Berichte der naturforschenden Gesellschaft zu Freiburg i. B., Band iii. 1888.
- Schaper, A.**, *Zur Histologie der menschlichen Retina*, A. f. mikr. Anat., Bd. xli., 1893.
- Scherl, J.**, *Unters. ü. d. Pigment des Auges*, Arch. f. Ophth., Bd. xxxix., 1893.
- Schiefferdecker, P.**, *Studien zur vergleichenden Histologie der Retina*, Arch. f. mikr. Anat., Bd. xxviii., 1886.
- Schloesser**, *Ueber die Lymphbahnen der Linse*, Münchener medicinische Wochenschrift, Jahrg. xxxvi., 1889.
- Schoen**, *Zonula u. Grenzhanf des Glaskörpers*, Arch. f. Ophth., xxxii. 1886; *Die Konkavität des vorderen Zonablattes nach vorn*, Archiv für Augenheilkunde, Band xxi. 1889-90.
- Schwalbe, G.**, *Lehrbuch der Anatomie der Sinnesorgane*, Erlangen, 1887.
- Smith, Priestley**, *On the size of the cornea in relation to age, sex, refraction and primary glaucoma*, The Lancet, 1889, also Brit. Med. Journ., 1889; *On the escape of fluid from the aqueous and vitreous chambers*, Ophth. Review, 1888.

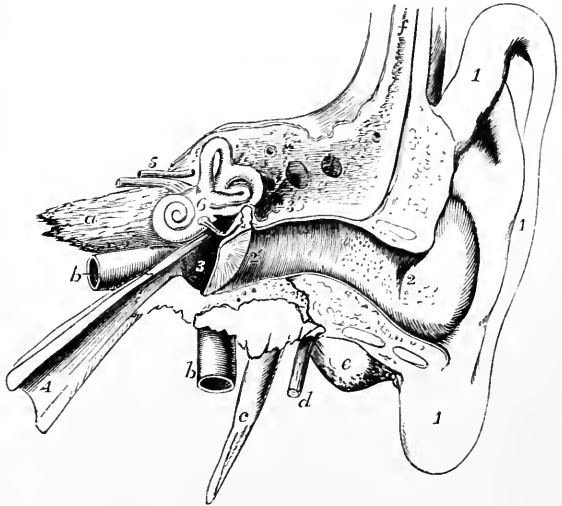
- Solger**, *Schnitte durch die normale Netzhaut*, Verhandlungen der anatom. Gesellschaft, Anat. Anz., iv. 1889.
- Staderini, Carlo**, *Ueber die Abflusswege des Humor aqueus*, Archiv für Ophthalmologie, xxxvii., 1891.
- Stieda, Ludwig**, *Ueber die Caruncula lacrymalis des Menschen*, Archiv für mikroskopische Anatomie, Band xxxvi., 1890.
- Stöhr, Philipp**, *Ueber die Netzhaut*, Sitzungsberichte der physikalisch-medizin. Gesellschaft zu Würzburg, Jahrg. 1888.
- Straub, M.**, *Notiz über das Ligamentum pectinatum und die Endigung der Membrana Descemeti*, Archiv f. Ophthalmologie, Band xxxiii., 1888; *Die Lymphbahnen der Hornhaut*, Archiv für Anatomie und Physiologie, Anat. Abt., 1887; *Beitr. zur Kenntniss des Glaskörpergewebes*, Arch. f. Ophthalm., Band xxxiv., 1888; *Ueber das Gleichgewicht der Gewebs- u. Flüssigkeitsspannungen im Auge*, Ibid., Bd. xxxv., 1889.
- Stuart, T. P. Anderson**. *On a membrane lining the fossa patellaris of the corpus vitreum*, Proceedings of the Royal Society, xlix., 1891; *On the connexion between the suspensory ligament of the crystalline lens and the lens capsule*, Proceedings of the Royal Society, xlix., 1891; *A mode of demonstrating the gross structure of the eye-ball*, Journal of Anat. and Physiol., 1891.
- Tartuferi, F.**, *Sull'anatomia della retina*, Archivio per le scienze mediche, anno xi., 1887; *Sull'anatomia della retina*, Internationale Monatsschrift für Anatomie und Physiologie, Band iv., 1887; *Sulla strato dei granuli interni della retina*, Giornale della r. accademia di medicina di Torino, vol. 1.
- Topolanski, A.**, *Ueber den Bau der Zonula und Umgebung nebst Bemerkungen über das albinotische Auge*, Archiv für Ophthalmologie, xxxvii., 1891.
- Ucke, Alexander**, *Zur Entwicklung des Pigmentepithels der Retina*, Inaug.-Diss., Dorpat, 1891.
- Ulrich, Richard**, *Neue Untersuchungen über die Lymphströmung im Auge*, Archiv für Augenheilkunde, Band xx., 1889.
- Virchow, Hans**, *Ueber d. Glaskörpergewebe u. s. w.*, Ber. der ophthalm. Gesellschaft, 1885; *Ue. d. Form u. Falten des Corpus ciliare*, Morph. Jahrb., xi., 1885; *Ue. d. verschiedenen Formen d. Ligam. pect. iridis*, Arch. f. Anat. u. Phys., Phys. Abth., 1885; *Ueber Augengefäße der Carnivoren*, Verhandl. der physiol. Gesellschaft zu Berlin, Jahrg. 1887.
- Voll, Adam**, *Ueber die Entwicklung der Membrana vasculosa retina*, Festschrift für A. v Koelliker, gewidmet vom anat. Institut zu Würzburg, 1892.
- Vossius**, *Ein Fall von beidenseitigen centralen Skotom, &c.*, Arch. f. Ophthalm., xxviii., 1883.
- Weiss**, *Anatomie der Eintrittsstelle der Sehnerven*, Münchener medicinische Wochenschrift, 1889.
- Wertheim, Th.**, *Ueber die Zahl der Scheinheiten im mittleren Teile der Netzhaut*, Archiv für Ophthalmologie, Bd. xxxiii., 1888.
- Wicherkiewicz, B.**, *Beiträge zur Kenntniss der persistierenden Pupillarmembran*, Archiv für Ophthalmologie, Band xxxiv., 1888.
- Würdinger**, *Ue. d. vergl. Anatomie des Ciliarmuskels*, Zeitschr. f. vergl. Augenheilkunde, 1886.
- Zaluskowski, K.**, *Bemerkungen über den Bau der Bindehaut*, Archiv für mikroskopische Anatomie, Band xxx.
- Ziem**, *Ueber das Schwellgewebe des Auges*, Archiv für pathologische Anatomie, 1891.

THE EAR.

THE organ of hearing is divisible into three parts; the external ear (fig. 78, 1, 2), the tympanum or middle ear (3), and the labyrinth or internal ear (6). The

Fig. 78.—DIAGRAMMATIC VIEW FROM BEFORE OF THE PARTS COMPOSING THE ORGAN OF HEARING OF THE LEFT SIDE (after Arnold).

The temporal bone of the left side, with the accompanying soft parts, has been detached from the head, and a section has been carried obliquely through it so as to remove the front of the meatus externus, half the tympanic membrane, and the upper and anterior wall of the tympanum and Eustachian tube. The meatus internus has also been opened, and the bony labyrinth exposed by the removal of the surrounding parts of the petrous bone. 1, the pinna and lobule; 2 to 2', meatus externus; 2', membrana tympani; 3, cavity of the tympanum; above 3, the chain of small bones; 3', opening into the mastoid cells; 4, Eustachian tube; 5, meatus internus, containing the facial (uppermost) and auditory nerves; 6, placed on the vestibule of the labyrinth above the fenestra ovalis; a, apex of the petrous bone; b, internal carotid artery; c, styloid process; d, facial nerve issuing from the stylo-mastoid foramen; e, mastoid process; f, squamous part of the bone.



first two of these are to be considered as accessories to the third, which is the portion of the organ to which the fibres of the eighth or auditory nerve are distributed.

THE EXTERNAL EAR.

In the external ear are included the *pinna*—the part of the outer ear which projects from the side of the head—and the *meatus* or passage which leads thence to the tympanum, and which is closed at its inner extremity by a membrane interposed between it and the middle ear.

THE PINNA.

The general form of the pinna or auricle, as seen from the outside, is concave, to fit it for collecting and concentrating the undulations of sound, but it is thrown into various elevations and hollows, to which distinct names have been given (fig. 79). The largest and deepest concavity is called the *concha*; it surrounds the entrance to the meatus, and is interrupted at its upper and anterior part by a ridge, which is the beginning of the helix. In front of the concha, and projecting backwards over the meatus, is a conical prominence, the *tragus* (fig. 79), covered usually with hairs. Its upper part sometimes forms a rounded prominence (*tuberculum supratragicum*, His). Behind the tragus, and separated from it by a deep notch, is another smaller elevation, the *antitragus*. Below the antitragus, and forming the lower end of the auricle, is the *lobule*, which is devoid of the firmness and elasticity that characterise the rest of the pinna. The thinner and larger portion of

the pinna is bounded by a prominent and incurved margin, the *helix*, which, springing above and rather within the tragus, from the hollow of the concha, surrounds the upper and posterior margin of the auricle, and gradually loses itself in the back part of the lobule. Within the helix is another curved ridge, the *anthelex*, which, beginning below at the antitragus, sweeps round the hollow of the concha, forming the posterior boundary of that concavity, diverging above it into two ridges. Between the helix and the anthelex is a narrow curved groove, the *fossa of the helix* (*fossa scaphoidea*); and in the fork of the anthelex is a somewhat triangular depression, the *fossa of the anthelex* (*fossa triangularis*).

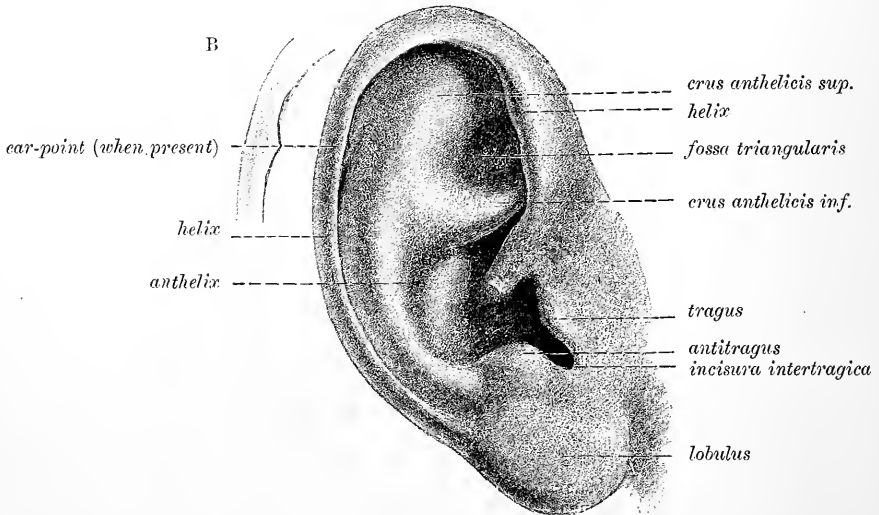


Fig. 79.—OUTER SURFACE OF THE RIGHT AURICLE. (After Arnold.)

Ear-point; Tubercle of Darwin.—Slight projections are occasionally observed in the human subject at the margin of the helix. One of these to which Darwin's attention was drawn by Mr. Woolner, the sculptor, is of interest as representing the much more distinct pointed extremity met with in the expanded ears of quadrupeds (Darwin, "The Descent of Man"). The point in question is represented in the sketch given in fig. 79 B. It is constant in the embryo of about the 6th month, where it presents a relative extent of development which is permanent in certain monkeys (Schwalbe).

Considerable variation is met with in the size and shape of the pinna,¹ in its amount of projection from the side of the head, in the extent of folding which it exhibits, and in the size of the lobule, and this is not only in individuals of different races, but even in those belonging to the same family. Attempts have been made to use these variations as a basis of classification in criminal anthropology, but with results of very doubtful value. The lobule is usually regarded as a human characteristic, but it is sometimes found fairly well developed in anthropoids, and is often very little developed in man.

Structure.—The pinna consists mainly of yellow fibro-cartilage and integument, with a certain amount of adipose tissue. It has several ligaments and small muscles of minor importance.

The *skin* covering it is thin, closely adherent to the cartilage, especially on the concave aspect, and is covered with hairs which are provided with large sebaceous follicles. It also contains sweat glands on the convex aspect, but few or none on

¹ The relation of the transverse to the longitudinal measurement of the pinna is known as the ear-index $\left(\frac{T \times 100}{L}\right)$ and is employed in anthropometry.

the concave side. In the external auditory meatus these reappear in a modified form as the ceruminous glands. The hairs of the pinna are most numerous and longest on the tragus and antitragus. The hairs on the margin and convex aspect of the ear are arranged with a general tendency to point towards the tubercle of Darwin, where the converging series may even form a distinct tuft, thus furnishing an additional argument in favour of the view regarding the meaning of that prominence which was taken by Darwin.

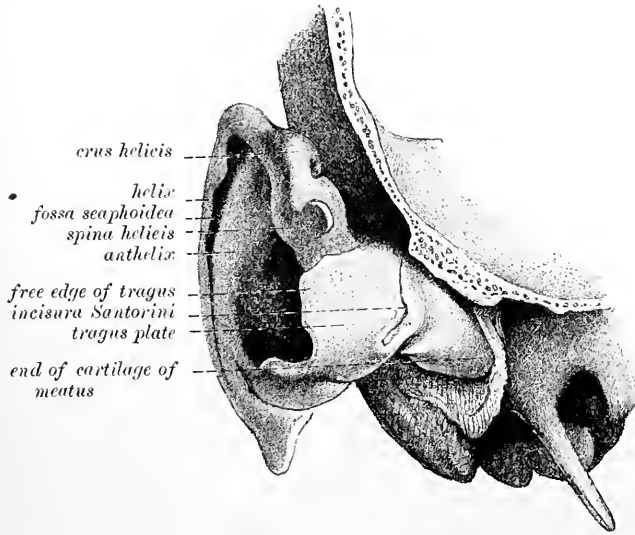


Fig. 80.—EAR-CARTILAGE, ANTERIOR ASPECT. (Arnold.)

The *cartilage* (figs. 80 to 82) forms a plate 1 mm. to 3 mm. thick, with all the inequalities already described as apparent on the outer surface of the pinna, and on its

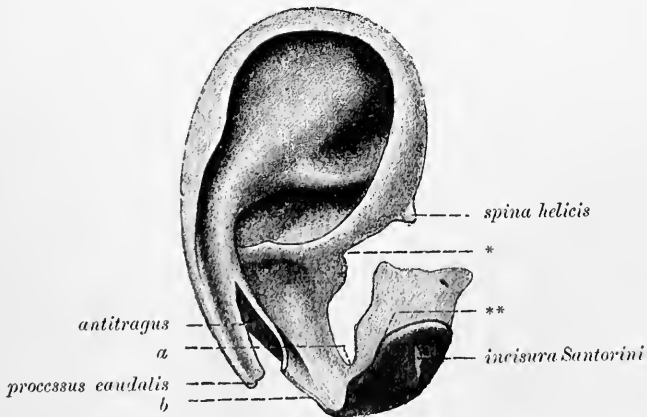


Fig. 81.—EAR-CARTILAGE, LATERAL ASPECT. (Schwalbe.)

In the natural position of the parts the corner of the tragus plate ** fits into the angle marked * at the anterior part of the helix. Between *a* and *b*, the isthmus separating the auricle-cartilage from the cartilage of the meatus.

cranial surface having prominences the reverse of the concha and the fossa of the helix, while between these is a depression in the situation of the anthelix. The cartilage is not confined to the pinna, but enters likewise into the construction of the outer part of the external auditory canal. When dissected from other structures, it is

seen to be attached by fibrous tissue to the rough and prominent margin of the external auditory meatus of the temporal bone. The tubular part is cleft in front between the tragus and fore-part of the helix inwards to the bone, the deficiency being filled with fibrous membrane. The whole cartilage may be looked upon as an elongated plate, the lower part of which is folded round in front so as to bring it nearly into contact with the upper part. There is no cartilage in the lobule except at its base, where the caudal process of the ear-cartilage passes into it: otherwise it contains only fat and tough connective tissue.

Behind the prominence of cartilage which forms the antitragus is a deep notch, separating it from the helix. Behind and below this the ear-cartilage forms a tail-like process descending towards the lobule (*caudal process*). At the fore part of the pinna, opposite the first bend of the helix, is a small conical projection of the cartilage, called the *spine of the helix*, to which the anterior ligament is attached. Behind this process is a short vertical slit in the helix; and on the surface of the tragus is a similar but somewhat longer fissure. A deep fissure (*incisura terminalis*, Schwalbe) passes back between the commencement of the helix and the tube of the ear, and

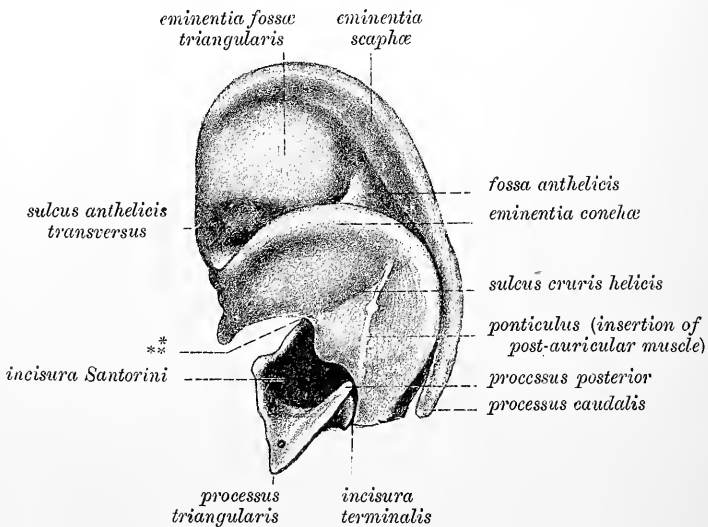


Fig. 82.—EAR-CARTILAGE, MESIAL ASPECT. (Schwalbe.)

another passing outwards and backwards from the deep end of the longitudinal cleft separates the part forming the tragus from the rest of the tube, so that the tube is continuous with the pinna only by means of a narrow isthmus. Other irregular gaps or fissures partially divide the cartilaginous tube transversely. These deficiencies are termed *fissures of Santorini*. They are usually two in number. These and the other named recesses and prominences of the ear-cartilage are shown in the accompanying figures, and do not require to be further described. The substance of the cartilage is very pliable, and is covered by a firm fibrous perichondrium. Near its attachment to the bone it becomes hyaline.

Ligaments.—Of the *ligaments of the pinna*, the most important are two, which assist in attaching it to the side of the head. The *anterior* ligament, broad and strong, extends from the spine of the helix to the root of the zygoma. The *posterior* ligament fixes the back of the auricle (opposite the concha) to the outer surface of the mastoid process of the temporal bone. A few fibres attach the tragus also to the root of the zygoma. Ligamentous fibres are likewise placed across the fissures and intervals left in the cartilage (*intrinsic ligaments*).

Muscles.—Of the muscles of the pinna, those which are attached by one end to the side of the head, and move the pinna as a whole, have been already described (Vol. II.): there remain to be examined several smaller muscles, composed of thin layers of pale-looking fibres, which extend from one part of the pinna to another, and may be named the special muscles of the organ. Six such small muscles are distinguished: four being placed on the outer and two on the inner or deep surface of the pinna.

The *smaller muscle of the helix* (fig. 83, 1) is a small bundle of oblique fibres, lying over, and firmly attached to, that portion of the helix which springs from the bottom of the concha. Like the other of these muscles, its fibres are, in part, attached to the skin.

The *greater muscle of the helix* (2) lies vertically along the anterior margin of the pinna. By its lower end it is attached to the spine of the helix; and above, its fibres terminate opposite the point at which the ridge of the helix turns backwards. The anterior auricular muscle is sometimes continued partly into this muscle.

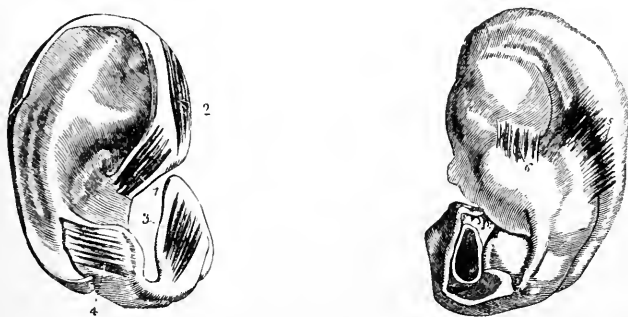


Fig. 83, A and B.—OUTER AND INNER SURFACES OF THE RIGHT PINNA, EXPOSED TO SHOW THE SMALL MUSCLES (from Arnold).

1, musculus heliis minor; 2, m. heliis major; 3, tragicus; 4, antitragicus; 5, musculus transversus auriculæ; 6, musculus obliquus auriculæ.

The *muscle of the tragus* (3) is a flat bundle of short fibres covering the outer surface of the tragus: its direction is nearly vertical. Occasionally a slender bundle of muscular fibres is seen prolonging this muscle across the cleft in the cartilage between the tragus and fore part of the helix to be attached to the spine of the helix (*m. pyramidalis*, Jung). Another muscle (*dilatator conchæ*, Theile) of less constant occurrence lies upon the anterior face of the tragus, bridging over the greater fissure of Santorini, which is there present.

The *muscle of the antitragus* (4) is placed obliquely over the antitragus and behind the lower part of the anthelix. It is fixed at one end to the antitragus, from which point its fibres ascend somewhat to be inserted into the caudate process of the helix, above and behind the lobule.

The *transverse muscle* (5) lies on the inner or cranial surface of the pinna, and consists of radiating fibres which extend from the back of the concha to the prominence which corresponds with the groove of the helix.

The *oblique muscle* (Tod) (6) consists of a few fibres stretching from the back of the concha to the convexity directly above it, across the back of the inferior branch of the anthelix, and near the fibres of the transverse muscle.

The muscles of the tragus and antitragus tend to contract the entrance to the meatus when stimulated by electricity (Duchenne), the muscles of the helix having a contrary tendency. They are none of them under the influence of the will, but it is possible they may act slightly in a reflex manner. All the ear-muscles are supplied by the facial nerve.

Vessels of the pinna (fig. 84).—The auricular branch of the *posterior auricular artery*, a branch from the external carotid, is distributed chiefly on the mesial surface, but some of its branches turn over the folded margin to reach the external surface of the helix : others pierce the cartilage and ramify on the external surface of the anthelix, concha and lobule. Besides this artery, the auricle receives the *anterior auricular* branches from the superficial temporal. These chiefly supply the anterior part of the lobule, the tragus, and the anterior part of the helix.

The *veins* for the most part accompany the arteries. They join the posterior auricular and temporal veins, but some enter the mastoid emissary vein of the lateral sinus (see Vol. II., p. 526). The *lymphatics* of the pinna pass partly forwards from the concha to join a gland in front of the tragus ; partly downwards and backwards from the upper and posterior part of the pinna towards the mastoid glands ; and partly downwards from the lobule towards the parotid lymphatic glands.

Nerves.—The *great auricular nerve*, from the cervical plexus, supplies the integument of the greater part of the inner surface of the auricle, and sends small filaments with the posterior auricular artery to the outer surface of the lobule and

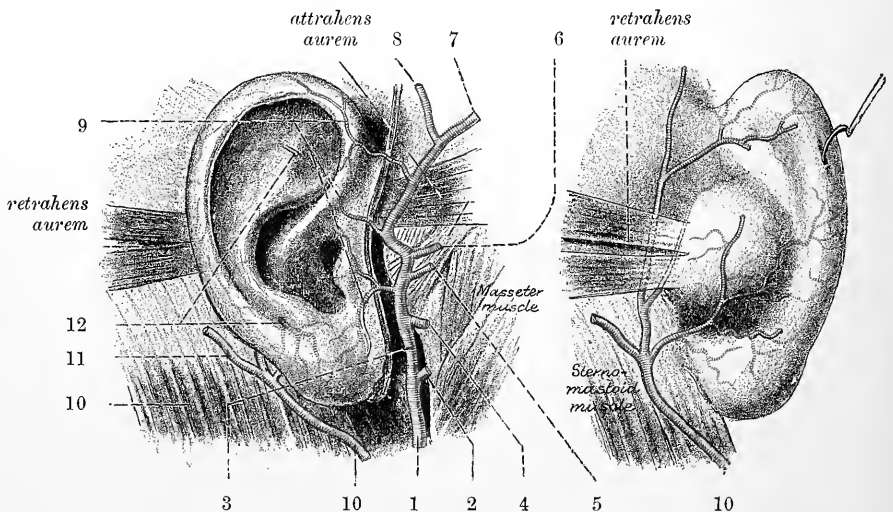


Fig. 84.—ARTERIES SUPPLYING THE AURICLE. (Testut.)

1, external carotid ; 2, internal maxillary ; 3, superficial temporal ; 4, transverse facial ; 5, middle temporal ; 6, orbital branch of temporal ; 7, anterior terminal branch ; 8, posterior terminal branch ; 9, anterior auricular branches ; 10, posterior auricular artery ; 11, its mastoid branch ; 12, perforating branches.

the part of the ear above it. The auricular branch of the *posterior auricular nerve*, derived from the facial, after communicating with the *auricular branch of the pneumogastric*, ramifies on the back of the ear, supplying the small muscles. The *auriculo-temporal* branch of the third division of the fifth nerve gives filaments chiefly to the outer surface of the pinna. A branch of the *small occipital* supplies the upper part of the inner surface. Filaments from the temporal branches of the facial supply the external muscles.

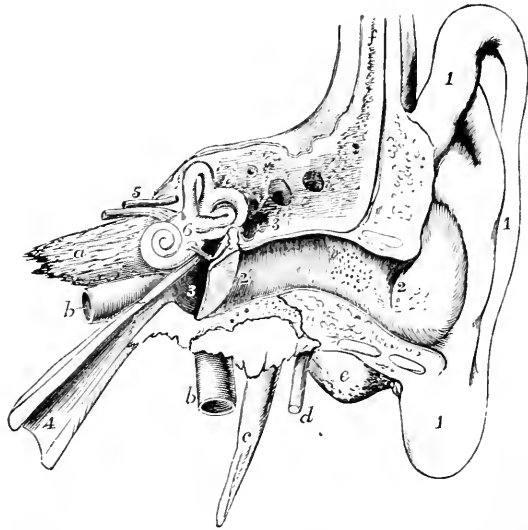
THE EXTERNAL AUDITORY CANAL.

The external auditory canal, *meatus auditorius externus* (85, 2, 2), extends from the bottom of the concha to the membrane of the tympanum and serves to convey the vibrations of sound to the middle chamber of the ear. The canal is

about 25 mm. long, but the superior and posterior boundaries are considerably shorter than the inferior and anterior. If the part of the concha which is bounded anteriorly and externally by the tragus is reckoned in with the canal,

Fig. 85.—DIAGRAMMATIC VIEW FROM BEFORE OF THE PARTS COMPOSING THE ORGAN OF HEARING OF THE LEFT SIDE. (After Arnold.)

The temporal bone of the left side, with the accompanying soft parts, has been detached from the head, and a section has been carried obliquely through it so as to remove the front of the meatus externus, half the tympanic membrane, and the upper and anterior wall of the tympanum and Eustachian tube. The meatus internus has also been opened, and the bony labyrinth exposed by the removal of the surrounding parts of the petrous bone. 1, the pinna and lobe; 2 to 2', meatus externus; 2', membrana tympani; 3, cavity of the tympanum; above 3, the chain of small bones; 3', opening into the mastoid cells; 4, Eustachian tube; 5, meatus internus, containing the facial (uppermost) and auditory nerves; 6, placed on the vestibule of the labyrinth above the fenestra ovalis; *a*, apex of the petrous bone; *b*, internal carotid artery; *c*, styloid process; *d*, facial nerve issuing from the stylo-mastoid foramen; *e*, mastoid process; *f*, squamous part of the bone.



its length must be given as considerably more (35 mm). In its inward course it is inclined at first somewhat forwards and very slightly ascends (external portion): it then turns pretty sharply backwards and is nearly horizontal (middle portion), and

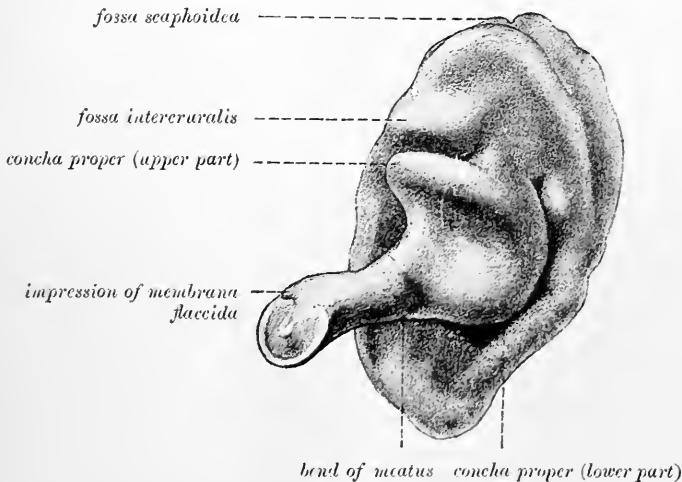
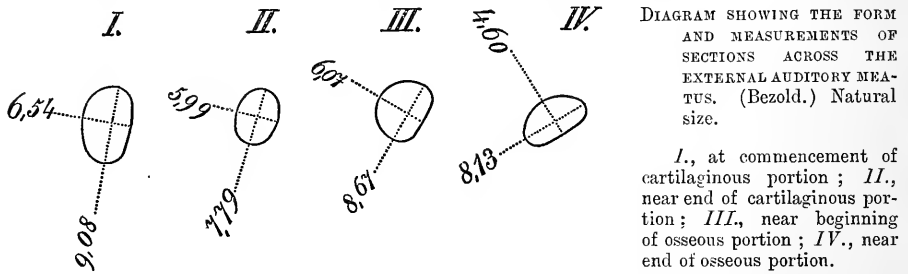


Fig. 86.—CAST OF THE EXTERNAL AUDITORY MEATUS. (Bezold.)

is finally directed slightly forwards and decidedly downwards (internal portion) (fig. 85). The calibre of the passage is smallest in the osseous part of the canal a few millimeters from the membrana tympani: it is also somewhat contracted near the end of the cartilaginous portion. Its form and dimensions have been studied by v. Bezold, chiefly by means of casts of the cavity: the results of the transverse

measurements at certain points are given in the accompanying diagram. At the inner extremity the tube is terminated by the membrana tympani, which is placed obliquely, being inclined downwards, forwards, and towards the median plane; and thus, as shown in fig. 85, the floor of the meatus is longer than its roof.



Structure.—The wall of the meatus is composed partly of cartilage, and partly of bone, and is lined by a prolongation of the skin.

The *cartilaginous* part occupies somewhat less than half the length of the passage. It is formed, as already mentioned, by an inflection of the deep part of the cartilage of the pinna, but the cartilage does not form a complete boundary; the tube being deficient at the upper and posterior part where it is completed by fibrous membrane.

The *osseous portion* is a little longer and on the whole rather narrower than the cartilaginous part. At its inner end is a narrow groove (*sulcus tympanicus*), which

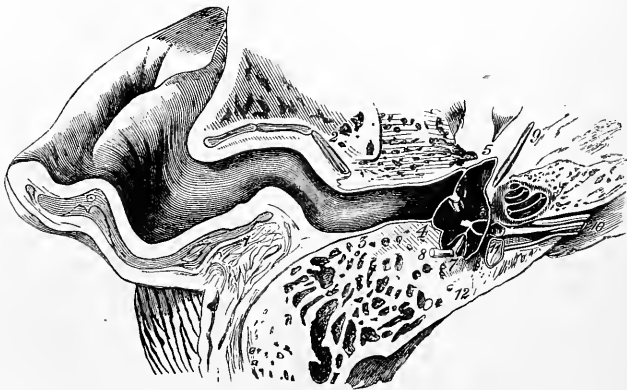


Fig. 87.—VIEW OF THE LOWER HALF OF THE AURICLE AND MEATUS IN THE LEFT EAR, DIVIDED BY A NEARLY HORIZONTAL SECTION (after Rüdinger).

1, posterior wall; 2, anterior wall of the cartilaginous meatus; 3, posterior wall of the bony meatus; 4 to 5, membrane of the tympanum, with the handle of the malleus cut; 6, stapes, to the right of 6, section of the cochlea; 7, stapedius muscle; 8, section of facial nerve; 9, tensor tympani muscle; 10, branches of the auditory nerve to the cochlea, saccule, and utricle, 11.

extends round the sides and floor of the meatus, but is deficient above; into this the margin of the membrana tympani is inserted.

The *skin* of the meatus is continuous with that covering the pinna, but is very thin in the osseous part, especially at the bottom of the passage. Here it adheres very closely to the periosteum, and has no hairs or glands, but is provided with vascular papillæ (ridges, according to Kaufmann). At the end of the tube the skin is prolonged over the surface of the membrana tympani, forming the outer layer of that structure. Towards the outer part of the roof of the osseous portion and throughout the cartilaginous portion the skin possesses fine hairs and sebaceous

glands; and in the thick subdermic tissue are small oval convoluted tubular glands of a brownish-yellow colour, agreeing in form and structure with the sweat glands, but larger in part or entirely, and in sufficient number at some parts, especially where cartilage is deficient, to form an almost complete layer in the subcutaneous tissue. The cerumen or ear-wax is secreted by these glands (*glandulae ceruminosae*), and their fine ducts may be seen to perforate the skin of the meatus close to or into the mouths of the hair follicles. According to Schwalbe the fatty part of the ear-wax is formed by the sebaceous glands. This may be partly the case, but the secretion of the ceruminous glands is certainly also of a fatty nature (fig. 88).

Vessels and nerves.—The external auditory meatus is supplied with arteries from the *posterior auricular*, *internal maxillary*, and *temporal* arteries. The principal

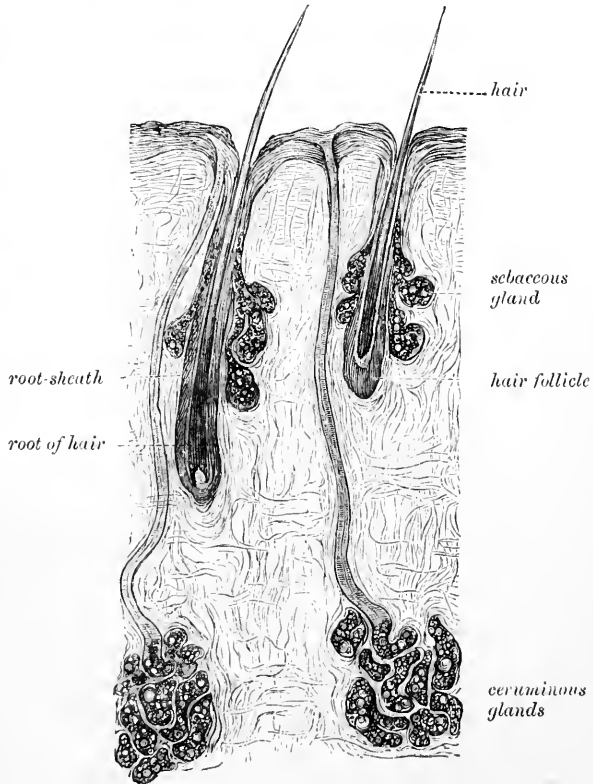
Fig. 88.—SECTION OF SKIN OF AUDITORY MEATUS, INCLUDING TWO CERUMINOUS GLANDS. (Grüber.) •

branches of the arteries course along the upper and back wall of the canal. The veins and lymphatics take the same course on leaving the meatus as do the corresponding vessels of the pinna. The nerves are derived from the auriculo-temporal branch of the fifth and the auricular branch of the vagus. The latter supplies the skin of the osseous part of the canal and that which covers the lower part of the tympanic membrane.

State in the infant.

—The auditory passage is only in part formed of bone and cartilage in the infant. The osseous part is formed at birth by a small ring of bone (tympanic bone) which is deficient antero-

superiorly, where it is completed by uniting with the squamous portion of the temporal bone, and this part of the temporal overhangs the meatus and constitutes the chief part of its superior boundary. The floor is mainly formed by fibrous tissue which unites the tympanic ring of bone with the fibro-cartilage of the pinna and external part of the meatus. This is the *fibrous tympanic plate* of Symington, and into it the tympanic bone gradually grows after birth. This growth takes place chiefly from two points (Zuckermandl) outwards into the fibrous plate in question and usually in such a manner that a gap is left for some time in the antero-inferior part of the bony meatus which sometimes persists throughout life. The membrane of the drum is more inclined away from the vertical in the foetus and new-born infant than in the adult, being in fact in the same plane as the roof and overlying the fibrous floor of the inner part of the



meatus. The meatus of the foetus is for the most part closed by apposition of its upper and lower walls, but towards the end of fetal life it becomes occupied with epithelial scales and ear-wax. The cartilage of the external ear and meatus appears to be formed in two or three pieces, the fissures of Santorini marking the junctions of these component portions (Bürkner).

THE MIDDLE EAR OR TYMPANUM.

The tympanum or drum, the middle chamber of the ear, is a narrow irregular cavity in the substance of the temporal bone, placed between the membrane occluding the inner end of the external auditory canal and the outer bony wall of the

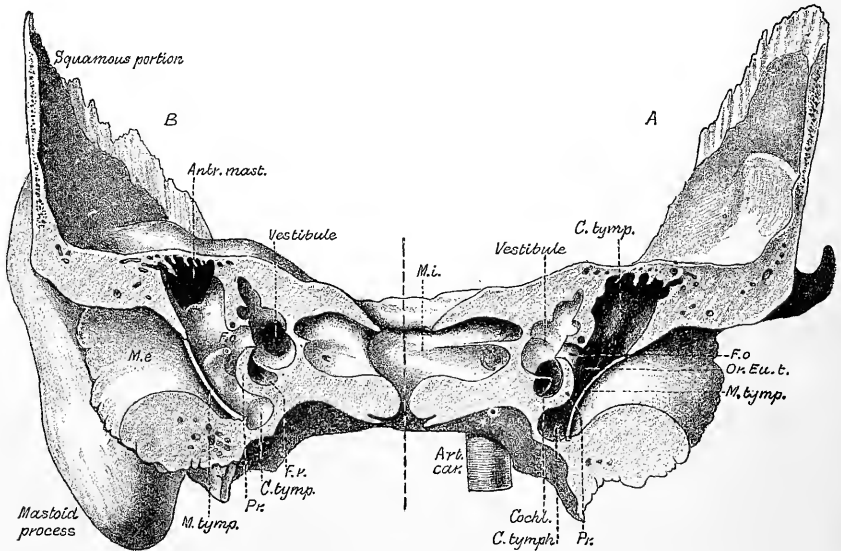


Fig. 89.—THE RIGHT TEMPORAL BONE SAWN IN A CORONAL PLANE THROUGH THE TYMPANUM, VESTIBULE, AND AUDITORY MEATUS, THE POSTERIOR PART OF THE SAWN BONE HAVING BEEN TURNED ROUND SO AS TO DISPLAY BOTH SURFACES OF THE SECTION. Natural size. (Testut.)

A, Anterior aspect; B, posterior aspect.

labyrinth. Its width between these boundaries varies from about 2 mm. to 4 mm., being narrowest opposite the middle of the membrane, and narrower below and in front than above and behind. It measures about 15 mm. from above down and about the same from before back.

The vertical measurement includes the so-called *recessus epitympanicus* or *auditus ad antrum*, which lodges the head of the malleus and the greater part of the incus: this, by Bezold and some other authors is excluded from the tympanum proper, which without it measures about 9 mm. In other words, the entrance to the mastoid antrum and mastoid cells is about 9 mm. above the bottom of the tympanic cavity. The orifice of the Eustachian tube is about 4 mm. above the lowest part of the floor.

The tympanum contains a chain of small bones (by means of which the vibrations communicated from without to the membrana tympani are conveyed across the cavity to the internal ear) and also certain minute muscles and ligaments, which belong to the bones referred to, as well as nerves, some of which end within the cavity, whilst others merely pass through it to other parts. The cavity is otherwise filled with air, for it communicates with the atmosphere through the Eustachian tube, which leads into the pharynx. The bony walls of the cavity are by no means

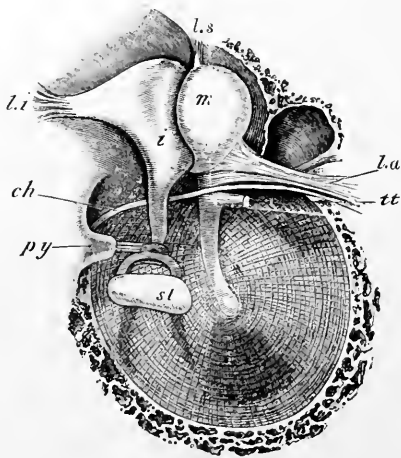
everywhere smooth, but marked in many situations with depressions, some deeper others shallower, which are lined by a prolongation of the mucous membrane of the cavity and also contain air. These depressions are known as the *tympanic cells*. A roof and floor, an outer and inner wall, and an anterior and posterior boundary are commonly described.

The **roof** of the tympanum is formed by a thin plate of bone (*tegmen tympani*), which may be easily broken through so as to obtain a view of the tympanic cavity from above: it is situated on the upper anterior surface of the petrous portion of the temporal bone near the angle of union with the squamous portion, the petro-squamous fissure passing just external to it. The *tegmen tympani* also roofs over the canal of the Eustachian tube and tensor *tympani* muscle. It is not unfrequently partly deficient (compare Vol. II., p. 42). The **floor** is narrow, in consequence of the outer and inner boundaries being inclined towards each other. It passes without any sharp demarcation into the anterior and posterior boundaries. It is separated by a thin plate of bone, which in rare cases is found to be incomplete, from the lateral part of the jugular fossa, and exhibits a small aperture through which the tympanic nerve reaches the inner wall.

The **outer wall** is formed, to a small extent, by bone, but mainly by the membrane (*membrana tympani*) already mentioned as closing the inner end of the

Fig. 90.—VIEW OF THE LEFT MEMBRANA TYMPANI AND AUDITORY OSSICLES FROM THE INNER SIDE, AND SOMEWHAT FROM ABOVE (E. A. S.).

m, malleus; *i*, incus; *st*, stapes; *py*, pyramid from which the tendon of the stapedius muscle is seen emerging; *tt*, tendon of the tensor *tympani* cut short near its insertion; *la*, anterior ligament of the malleus: the *processus gracilis* is concealed by the lower fibres of this ligament; *ls*, superior ligament of the malleus; *li*, ligament of the incus; *ch*, chorda *tympani* nerve passing across the outer wall of the tympanum.



external auditory meatus. Immediately in front of the ring of bone into which the *membrana tympani* is inserted, is the inner extremity of the fissure of Glaser (*petro-tympanic fissure*). Close to the inner end of this fissure is the opening of a small canal (*iter chordæ anterioris*), through which the chorda *tympani* nerve passes out from the tympanum. The margin of the tympanic ring is interrupted above by a notch (*incisura Rivini*) which is bounded in front and behind by prominent angles, the *anterior and posterior tympanic spines*. The outer wall of the recessus epitympanicus is formed by the thickened part of the squamosal which lies behind the root of the zygoma: it may contain, according to Kirchner, cells communicating with those of the mastoid process. This recess overhangs the inner end of the external auditory meatus.

The **membrana tympani** is an ellipsoidal disc, the longer axis of which is directed from behind and above, forwards and downwards, and is about 10 mm. in length: the shorter axis being about 9 mm. It is nearly as large at birth as in the adult. It is inserted into the groove already noticed at the end of the meatus externus, and so obliquely that the membrane inclines towards the anterior and lower part of the canal at an angle of about 55° (fig. 102). It is said to be more vertical in musicians and more horizontal in the congenitally deaf. In the foetus and even at or near birth it is as already stated nearly horizontal. The handle of the malleus,

one of the small bones of the tympanum, descends in contact with the inner surface of the membrane, covered by mucous membrane, to a little below the centre, where it is firmly fixed; and, as this process of the bone is directed inwards, the outer surface of the membrane is thereby depressed in a conical form (fig. 102).

The membrana tympani is about 0.1 mm. thick, but at its insertion into the sulcus tympanicus it becomes thickened and firmly attached to the bone by a considerable accumulation of fibres (*annulus fibrosus*), and this thickened margin is prolonged from the spines of the tympanic ring as two ligamentous bands which pass to the short process of the malleus, constituting the so-called *anterior and posterior tympano-malleolar folds or ligaments* (fig. 92), and forming the lower boundary of the membrana flaccida (see below). Covering it externally is a prolongation of the skin of the external meatus; internally is a prolongation of the mucous membrane lining the cavity of the tympanum; and between the two is the proper substance of the membrane, composed of fibrous tissue. The greater number of the fibres radiate from the attachment of the handle of the malleus (fig. 91), but there are also circular fibres (fig. 90) which are situated within or mesially to the radial, and near the circumference of the membrane, form a dense, almost ligamentous thickening. Besides these two sets of fibres there are others met with, especially

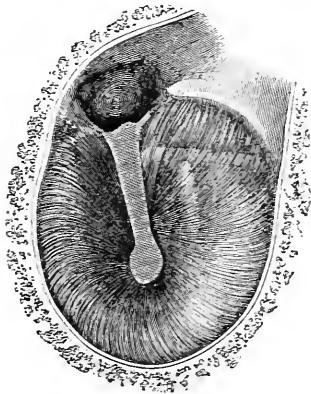


Fig. 91.—VIEW OF THE OUTER SURFACE OF THE LEFT MEMBRANA TYMPANI, AFTER REMOVAL OF THE CUTANEOUS LAYER (E. A. S.) †

The handle of the malleus is distinctly seen, and the long process of the incus appears as a faint light band parallel with and a little behind the handle of the malleus. The other light band nearly at right angles to the malleus is caused by the chorda tympani nerve. The notch of Rivinus is seen above the handle of the malleus.

in the posterior half of the membrane, which are irregularly disposed and form at places prominent fibrous bands in and upon the mesial surface of the membrane (covered of course by the mucous membrane), and even extend here and there across part of the cavity of the tympanum. At the insertion of the malleus the membrane, especially its integumental layer, is thickened. The fibrous tunica propria here becomes continuous with the periosteum of the malleus, but along the line of contact of the bone with the membrane there is generally a streak of cartilage forming the actual uniting tissue: a similar thin layer of cartilage may also be found along the opposite (free) border of the manubrium mallei, and also forming a complete cap to the end of the manubrium. In the thickening of the integumental layer above mentioned vessels and nerves to the membrane are seen in section. The epidermal layer is stratified, as elsewhere in the external auditory meatus: it is also somewhat thickened along the malleolar line, and here small papillæ of the cutis project into it. The radial fibres are not straight, but are slightly bowed outwards, so that between the most depressed point or *umbo*, and the attached border, the membrane is slightly convex outwardly. This shape is maintained by the annular fibres.

At the upper and anterior part, the annular fibres stretch, as just related, across the mouth of a small notch in the bony ring to which the membrane is attached (notch of Rivinus). The notch is occupied by a lax membrane (*membrana flaccida*, Shrapnell) (fig. 92), consisting of loose connective tissue, with vessels and nerves, and covered by skin and mucous membrane. It occasionally happens that a fissure or perforation is to be detected at this place.

The membrane is supplied with blood-vessels, but they are chiefly confined to the

skin and mucous membrane covering the surfaces: a few are, however, found in the proper fibrous membrane, and form a communication between the two systems on the surfaces. Those of the skin are mostly supplied by a small artery, derived from the deep auricular branch of the internal maxillary, which passes from above parallel to and along the handle of the malleus. The nerves for the most part accompany the blood-vessels, first supplying these and then forming a plexus both in the cutis and in the mucosa. They are derived, for the upper and greater part of the membrane, from the auriculo-temporal; for the lowermost part, according to Sappey, from the auricular branch of the vagus. For the mucosa they come from the plexus tympanicus. Lymphatic vessels are, according to Kessel, tolerably abundant in all three layers.

The **inner wall** of the tympanum (fig. 93, A & B), which separates it from the internal ear, is very uneven. Near its upper part is an ovoid, or nearly kidney-

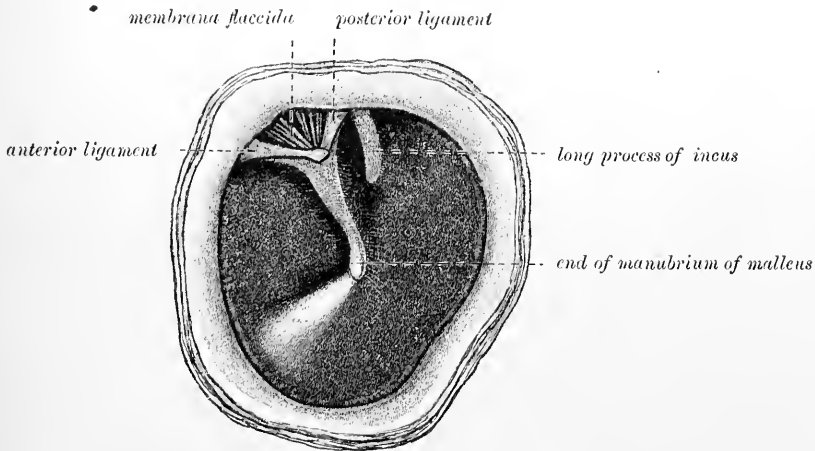


Fig. 92.—MEMBRANA TYMPANI, AS SEEN WITH THE OTOSCOPE. (Hensman.)

shaped opening—*fenestra ovalis*, which leads into the cavity of the vestibule. This opening, which is elongated from before backwards, with a slight inclination downwards in front, is occupied in the recent state by the base of the stapes and the annular ligament connected with that plate of bone. It measures 3 mm. by $1\frac{1}{2}$ mm., and lies at the bottom of a depression (*fossula ovalis*), which is bounded by the bony prominences immediately to be mentioned. Above the fenestra ovalis, and between it and the roof of the tympanum, a ridge indicates the position of the aqueduct of Fallopius (*aF'*), as it passes backwards, containing the facial nerve. Below is a larger and more rounded elevation, caused by the projection outwards of the first turn of the cochlea, and named the *promontory*, or *tuber cochleae*; its surface is marked by grooves, in which lie the nerves of the tympanic plexus.

Below and behind the promontory, and somewhat hidden by it, is another aperture named *fenestra rotunda*, 1.5 mm. to 2 mm. in diameter, which lies within a funnel-shaped depression (*fossula rotunda*). In the macerated and dried bone the fenestra rotunda opens into the scala tympani of the cochlea; but, in the recent state, it is closed by a thin membrane.

The membrane closing the fenestra rotunda—*secondary membrane of the tympanum* (Scarpa)—is rather concave towards the tympanic cavity and convex to the scala tympani, and, like the membrana tympani, is composed of three structures, the middle being fibrous, and the outer and inner derived from the membranes lining the cavities between which it interposed, viz., the tympanum and the cochlea. The

membrane is not quite circular but is prolonged superiorly and posteriorly into a somewhat triangular extension, which lies parallel and close to the lamina spiralis cochleæ, and forms an angle with the principal part of the membrane; the latter looks somewhat backwards and downwards, as well as outwards.

Another fossa is seen on the inner wall, behind the promontory and between the fossula ovalis and fossula rotunda, from each of which it is separated by a bony prominence, while behind it is the base of the pyramid (see below). This fossa, which has been named the *sinus tympani*, is about 4 mm. in diameter and 3 mm.

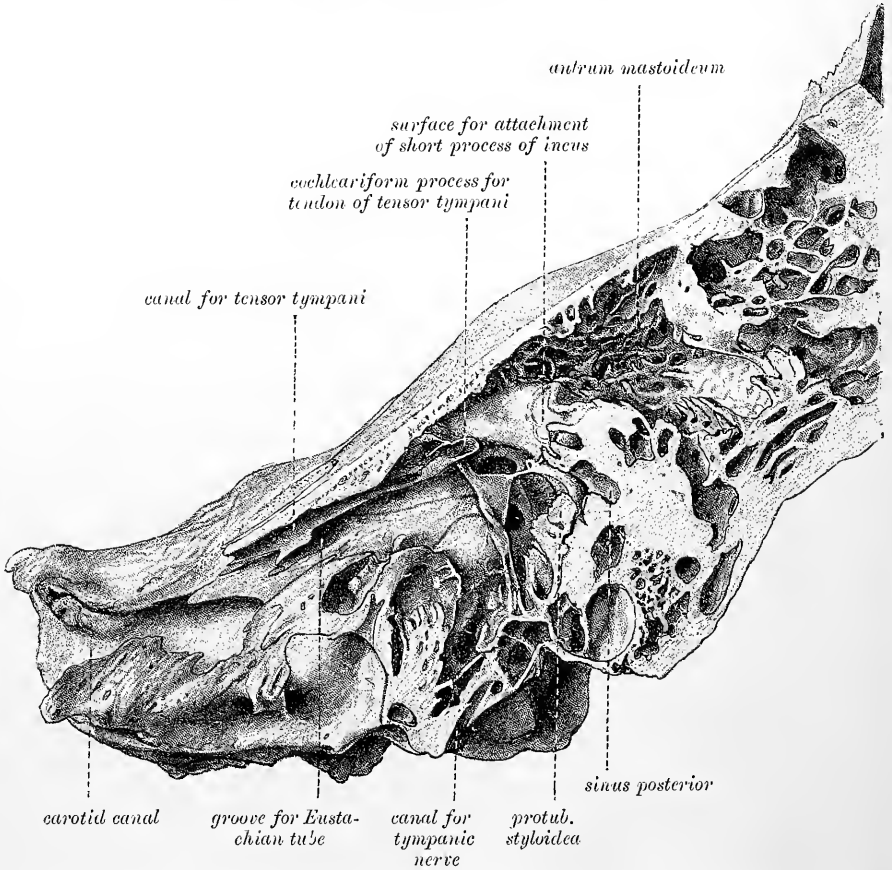


Fig. 93 A.—SECTION OF THE RIGHT PETROUS BONE PASSING THROUGH THE MIDDLE OF THE TYMPANIC CAVITY SO AS TO EXPOSE THE INNER WALL OF THAT CAVITY AND TO EXHIBIT ITS CONNEXION WITH NEIGHBOURING SPACES WITHIN THE BONE. (E. A. S.) About twice the natural size.

deep. The ampulla of the posterior semicircular canal lies close to its floor, and it is marked by one or two small apertures for vessels (Steinbrügge).

The **posterior wall** of the tympanum has at its upper part a large opening which leads into a considerable air-space (*antrum mastoideum*, figs. 93, A and B) behind and above the proper tympanic cavity. From this antrum numerous irregular cavities, the *mastoid cells*, pass into the substance of the mastoid portion of the temporal bone. These cells communicate for the most part freely with one another, and are lined by a thin mucous membrane continuous with that of the tympanum. In the foetus and new-born child the mastoid cells are not developed (corresponding with the slight development of the mastoid process), but the antrum mastoideum is formed at birth. The petroso-squamosal fissure passes through the antrum. The

mastoid cells are very variable in development : when large they approach close to the free surface of the bone, and may come into proximity with the lateral sinus, when small there is a considerable thickness of bone between them and the surface. Sometimes they are undeveloped, and their place is occupied by spongy bony substance (diplöe). At the lower margin of the orifice of the antrum is a depressed surface for the attachment of the lower ligament of the incus.

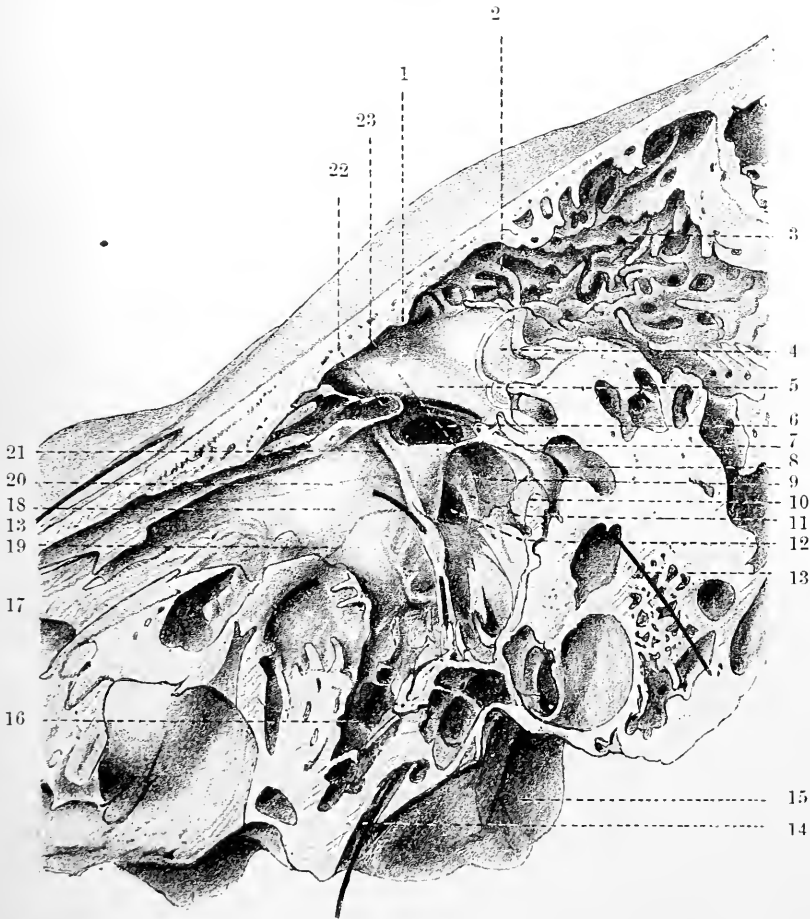


Fig. 93 B.—PART OF THE SECTION SHOWN IN FIG. 93 A, MORE MAGNIFIED, SHOWING THE VARIOUS NAMED PARTS IN AND CONNECTED WITH THE INNER WALL OF THE TYMPANUM. (E. A. S.)

1, tympanic crest ; 2, entrance to mastoid cells ; 3, mastoid antrum ; 4, prominence due to external semicircular canal ; 5, prominence over aqueduct of Fallopius (a bristle, 13, 13, has been passed through this canal) ; 6, fenestra ovalis ; 7, pyramid ; 8, posterior sinus ; 9, sinus tympani ; 10, styloid protuberance ; 11, subiculum promontorii ; 12, fenestra rotunda ; 14, bristle passed through the canal for the tympanic nerve ; 15, jugular fossa ; 16, tympanic cells ; 17, canal for Eustachian tube ; 18, promontory ; 19, 20, 21, grooves for nerves on promontory emerging from the end of the canal for the tympanic nerve, 19 being for the carotico-tympanic, 20 for the small deep petrosal, and 21 for the small superficial petrosal ; 22, trochlear end of the canal for the tensor tympani muscle ; 23, bridge of bone uniting the promontory with the pyramid.

Below the orifice of the antrum and behind the fenestra ovalis is a small conical eminence (1 m. to 1.5 m. high), called the *pyramid*, or *eminencia papillaris* (fig. 90, *py* ; fig. 93, 7). Its apex is pierced by a foramen, through which the tendon of the stapedius muscle emerges. The muscle is contained within a canal

which when traced back is found to turn downwards in the posterior wall of the tympanum, sometimes opening at the base of the cranium by a small aperture just in front of the stylo-mastoid foramen, and connected at one or two places with the descending part of the aqueduct of Fallopius. A small bony spiculum often connects the end of the pyramid with the upper part of the promontory (see fig. 93 B, 23).

Anterior boundary. Canal for the tensor tympani.—The anterior extremity of the tympanum is narrowed by the gradual descent of the roof, and is continued into the inner orifice of the Eustachian tube (fig. 85). Above the commencement of this is the small (2 mm. diameter) canal which lodges the tensor tympani muscle. This canal, which is lined by a fibrous membrane, is about half an inch (12 mm.) long, and it opens immediately in front

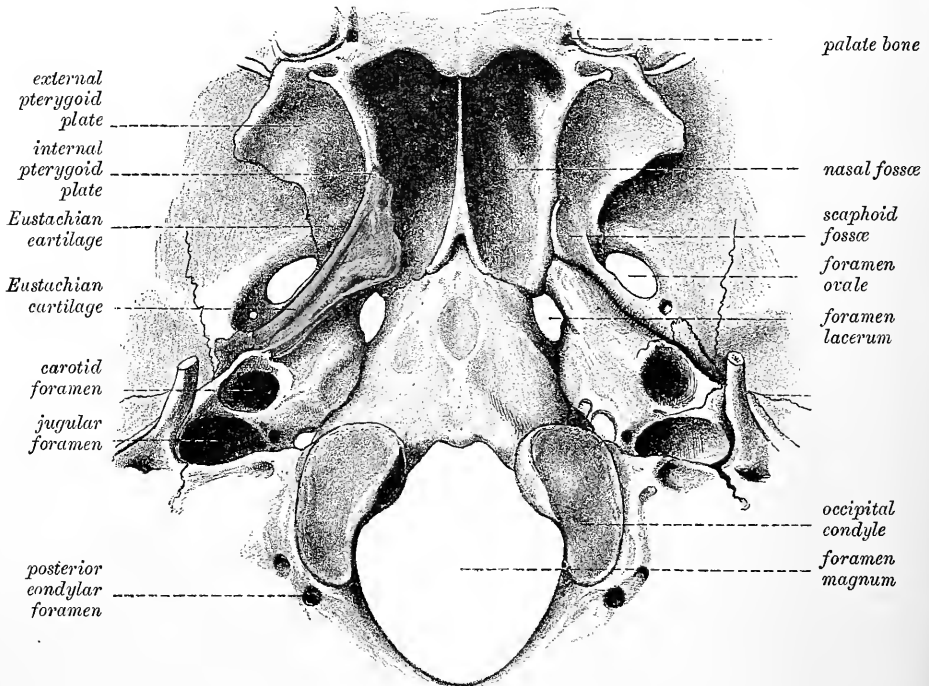


Fig. 94.—BASE OF THE SKULL, SHOWING THE POSITION OF THE EUSTACHIAN CARTILAGE.
(Modified from Testut.) (E. A. S.)

of the fenestra ovalis, surrounded by the expanded and everted end of the cochleariform process, which separates it from the Eustachian canal. The bony septum between the two canals is often incomplete, so that in the macerated bone they may appear as a single large canal partly subdivided by a thin osseous partition.

In the recent state the fibrous sheath of the tendon is expanded over the end of the canal, so as to impart to it a conical shape (see fig. 101, *tt*).

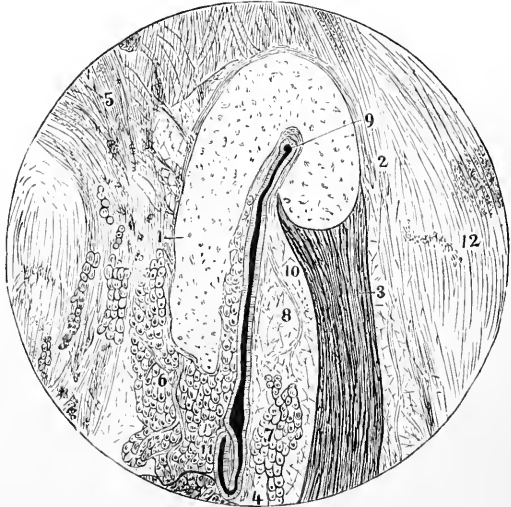
The **Eustachian tube** (*salpinx*) (fig. 85, 4) is a canal about 36 mm. (1·5 inches) long and from 2 mm. to 4 or 5 mm. diameter, bounded partly by bone, partly by cartilage and fibrous membrane, which leads from the cavity of the tympanum to the upper part of the pharynx. From the opening into the tympanum (*ostium tympanicum*) it is directed forwards and inwards, at an angle of about 45 degrees with the sagittal plane, with an inclination of about 30 degrees downwards from the horizontal; the downward inclination is slightly greater in the

cartilaginous part than in the osseous. The posterior or *osseous* division of the tube, about half an inch long, is placed at the angle of junction of the petrous portion of the temporal bone with the squamous portion. It is funnel shaped, diminishing somewhat rapidly in size from behind forwards, to the junction with the cartilaginous part; here the tube is narrowest (*isthmus tube*). The carotid canal lies mesially to the osseous portion of the tube, and is occasionally found to communicate with it owing to deficiencies in the bony septum between them.

The mucous membrane lining the osseous portion of the tube is thin and closely attached to the bone except along the floor of the canal, where it is separated from the periosteum by a venous plexus. It is lined by ciliated epithelium, and has no glands opening into it. The *anterior* part of the tube, about an inch in length, is formed of a triangular piece of elastic fibro-cartilage, the edges of which are slightly curled round towards each other, leaving an interval at the under and outer side, in which the wall of the canal is completed by dense but pliable fibrous membrane (*fascia salpingo-pharyngea*), and by a muscular band connected with the tensor palati and termed by

Fig. 95.—SECTION ACROSS THE CARTILAGINOUS PART OF THE EUSTACHIAN TUBE. (Rüdinger.)

1, 2, bent cartilaginous plate; 3, musc. dilatator tube; to the left of 4, part of the attachment of the levator palati muscle; 5, tissue uniting the tube to the base of the skull; 6, and 7, mucous glands; 8, 10, fat; 9 to 11, lumen of the tube; 12, connective tissue on the lateral aspect of the tube.



Rüdinger the *dilatator tube*. The cartilaginous plate is hook-shaped in transverse section (fig. 95), the larger part of the plate being on the mesial side, and only a small part on the lateral border. The cartilage is largest near the ostium pharyngeum, where it measures 12 mm. from above down, and is 7 mm. thick. It here occupies the whole mesial wall of the tube, but gradually diminishes in size as it approaches the bony canal. It is often partially or entirely broken up by fissures, or there may be accessory pieces of cartilage in various situations in the wall of the tube. The cartilaginous part of the tube is trumpet-shaped, being narrow behind, and gradually expanding to a greater width in front (fig. 94); the anterior part is compressed from side to side, and is fixed to the inner pterygoid plate of the sphenoid bone. The anterior opening (*ostium pharyngeum*) is of a compressed oval, somewhat triangular form, and is placed obliquely at the side and upper part of the pharynx, into which its prominent margin projects behind the lower turbinate process of the nose and above the level of the hard palate (fig. 96). The aperture is bounded above and posteriorly by a projection, which is caused by the end of the curved plate of cartilage (covered, of course, by mucous membrane), which separates it behind from a longitudinal depression of the pharyngeal wall, known as the *lateral recess of the pharynx* or fossa of Rosenmüller. The projection in question is continued into the salpingo-pharyngeal fold. Below it is limited by a thickening, increased when the levator palati contracts, continued from a fold (salpingo-palatine), which also assists in forming the anterior boundary of the orifice. The opening is placed

relatively to the palate somewhat lower in the child than in the adult. Through this aperture the mucous membrane of the pharynx is continuous with that which lines the tympanum, and under certain conditions air passes into and out of that cavity. Mucous glands open on the inner surface of the cartilaginous part of the tube; they are most numerous near the pharyngeal orifice. There is also a

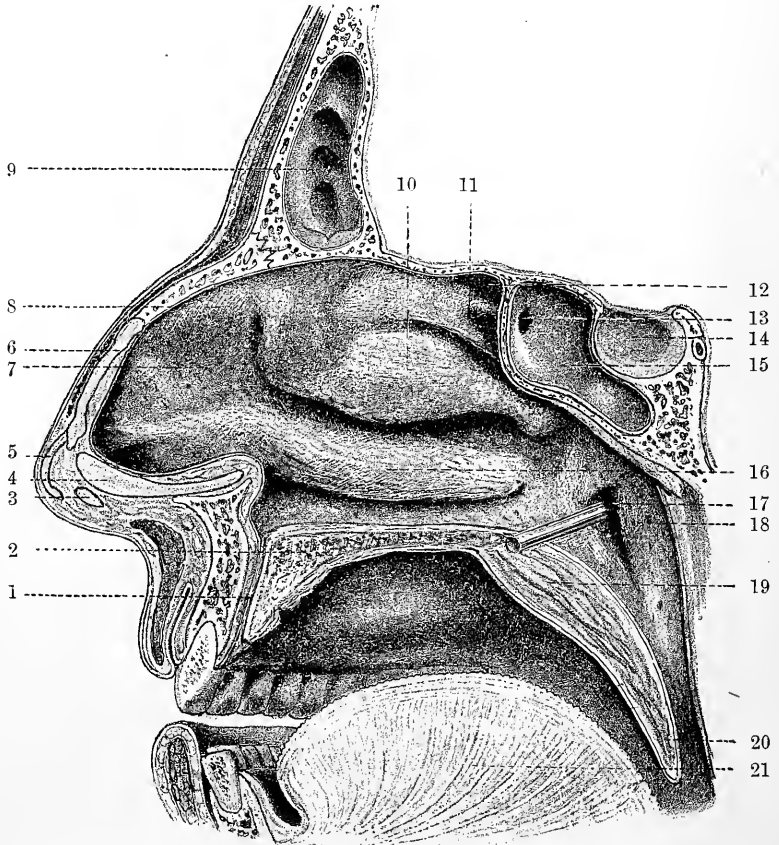


Fig. 96.—VIEW OF THE RIGHT NASAL FOSSA AS SEEN IN A SECTION THROUGH THE SKULL TAKEN JUST TO THE RIGHT OF THE SEPTUM. (E. A. S.)

1, incisor canal; 2, bone of hard palate; 3, 4, 5, parts of the cartilage of the aperture; 6, cartilage of the septum; 7, atrium leading to middle meatus; 8, agger nasi; 9, frontal sinus; 10, inferior ethmoidal concha; 11, superior ethmoidal concha; 12, sphenoid-ethmoidal recess; 13, entrance to sphenoidal sinus; 14, pituitary fossa; 15, sphenoidal sinus; 16, inferior turbinal; 17, rod passed into Eustachian tube; 18, salpingo-pharyngeal fold, immediately behind this is the lateral recess of the pharynx, not specially indicated in the drawing; 19, soft palate; 20, uvula; 21, tongue.

considerable amount of lymphoid tissue especially in young subjects, and near the pharyngeal end of the tube.

Vessels and Nerves.—The *arteries* of the tube are derived on the one hand from the pharyngeal branch of the external carotid, and on the other from the middle meningeal and vidian branches of the internal maxillary. The *nerves* arise from the tympanic plexus and pharyngeal twigs of the vidian nerve.

Muscles.—Besides the middle part of the tensor palati muscle, which takes origin along the whole length of the lateral plate of the hooked cartilage of the tube (fig. 95), the levator palati also has an attachment to the commencement of the

lateral plate, and from the adjacent membranous part of the floor of the tube, parallel to which its fibres course towards their insertion into the soft palate. When the muscle contracts the membranous floor of the tube is tightened, and is also raised near the ostium pharyngeum by the thickening of the muscular fibres which run just below it, and this helps to open the lower orifice during swallowing.

Lastly, some muscular bundles, forming the salpingo-pharyngeus of Santorini, arise from the lower and fore part of the mesial plate of cartilage, and passing down immediately beneath the mucous membrane, join the palato-pharyngens (Vol. II., p. 308). This muscle tends to drag the mesial plate backwards and downwards, and thus assists in opening the tube during deglutition.

The anterior wall of the tympanum, below the orifice of the Eustachian tube, is formed by a bony plate forming part of the petrous portion of the temporal bone, which is hollowed out by air-cells, and here separates the tympanic cavity from the vertical part of the carotid canal. Rarely there are one or more deficiencies in this wall.

SMALL BONES OF THE EAR.—Three small bones (*ossicula auditûs*) are contained in the upper part of the tympanum: of these, the outermost (*malleus*) is attached to the *membrana tympani*; the innermost (*stapes*) is fixed in the *fenestra ovalis*; and the third (*incus*), placed between the other two, is connected to them by articular surfaces. They form together an angular and jointed connecting rod between the *membrana tympani* and the *fenestra ovalis*.

The **malleus** or hammer-bone (fig. 97), (18 mm. to 19 mm. long, weight 24 milligr.), consists of an upper thicker portion, with a tapering lower portion, and

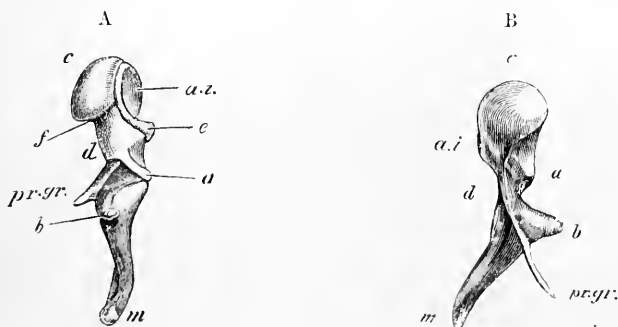


Fig. 97 A.—THE LEFT MALLEUS OF THE ADULT VIEWED FROM THE OUTER SIDE. Magnified four times. (After Helmholtz.)

c, capitulum; *a i*, grooved articular surface for the incus; *e*, its prominent lower margin; *d*, cervix, *m*, end of the manubrium; *b*, processus brevis; *pr.gr.*, processus gracilis, here represented only by a short stump, the rest of the process having been converted into ligament; *a*, ridge to which the external ligament is attached.

Fig. 97 B.—LEFT MALLEUS OF A CHILD VIEWED FROM BEFORE. Magnified four times. (E. A. S.)

The lettering is the same as in the previous figure. The processus gracilis is here complete. The angle which the manubrium forms with the rest of the bone is seen in this view.

two processes. The upper end is formed by the rounded *head* (*capitulum*) (*c*), on the posterior surface of which is an elliptical depressed surface (*a.i*) with prominent margins, which passes obliquely downwards and inwards, and serves for articulation with the incus. The articular surface shows two principal facets, nearly at right angles to one another. They are separated by a constriction and by an obliquely crossing crest or edge. These facets look respectively, the upper and larger one backwards, the lower one inwards; and each principal facet is subdivided

by a longitudinal groove into secondary facets. The inferior margin of the articular surface is very prominent opposite the constriction, and forms here, in fact, the lower end of the ridge above mentioned (*spur of the malleus*). Below the head is a constricted *neck* (*d*); and beneath this another slight enlargement of the bone, to which the processes are attached. The *handle* (*manubrium*) (*m*), the lower tapering point of the malleus, is slightly twisted, and is compressed from before backwards to near its point, where it is flattened laterally. It forms a rounded obtuse angle with the head of the bone (fig. 97 B), and passes downwards with an inclination forwards and inwards, on the inner side of the *membrana tympani*, to which it is closely attached both by its periosteal covering and also by a layer of cartilage extending its whole length, and especially marked at the attachment of the *processus brevis*. The point of insertion of the tendon of the *tensor tympani* muscle is sometimes marked by a slight projection on the inner side of the *manubrium* near its upper end. The *long process* (*processus gracilis* vel *Folianus*) (fig. 97 B, *pr. gr.*) is a very slender spiculum of bone, which in the adult is usually converted, except a small stump, into ligamentous tissue, and even where it still exists as bone is often broken off in its removal from the tympanum; it projects at nearly a right angle from the front of the neck of the malleus, and extends thence obliquely downwards and forwards to the Glaserian fissure. Its end is flattened and expanded, and is connected by ligamentous fibres or bone to the sides of the fissure. In the foetus this process is directly continued into Meckel's cartilage (see Vol. I, Part I, p. 168). The *short process* (*processus brevis* vel *obtusus*) (*b*) is a low conical eminence situated at the root of the *manubrium*, beneath the *cervix*, and projecting outwards towards the upper part of the *membrana tympani*, to which it is attached.

The **incus** (fig. 98), as its name implies, has been compared to an anvil; but it resembles perhaps more nearly a tooth with two fangs widely separated. It consists

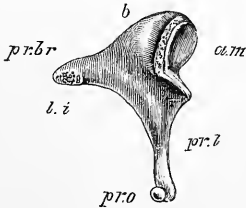


Fig. 98.—LEFT INCUS, VIEWED FROM THE INNER SIDE AND SOMEWHAT FROM BEFORE. Magnified four times. (G. D. Thane.)

b, body; *a. m.*, ridged articular surface for the malleus; *pr. br.*, *processus brevis*; *l. i.*, rough surface near its extremity for the attachment of the ligament of the incus; *pr. l.*, *processus longus*, terminating below in a small projection which comes off from it at a right angle, and is capped by a convex tubercle, *processus lenticularis*, *pr. o.*, for articulation with the stapes.

of a body and two processes. The *body* has a deep saddle-shaped articular surface in front (*a. m.*), which fits over the articular surface on the head of the malleus, and which consists, like that of the malleus, of two chief facets, each subdivided to form two secondary facets. The lower margin of the articulation is excavated to receive the spur-like prominence of the malleus, and in front of this excavation is very prominent, where it also forms a spur, against which that of the malleus catches in inward movements of the *manubrium*. The *shorter process* (*crus breve*) (*pr. br.*) of the incus projects backwards. Its extremity is tipped with cartilage, and is moveably articulated by ligamentous fibres with the posterior and partly with the outer wall of the tympanum near the entrance to the mastoid cells. The place where the ligamentous fibres are attached to the wall of the tympanum is somewhat depressed, and has a covering of cartilage. The *long process* (*crus longum*) (*pr. l.*) tapers rather more gradually, and passes downwards and inwards parallel to the handle of the malleus, and about $1\frac{1}{2}$ mm. mesial to and behind it. At its extremity it is bent inwards at an angle which varies considerably in different bones, and is suddenly narrowed into a short neck; and upon this is set a flattened tubercle (*processus orbicularis* seu *lenticularis*) (*pr. o.*), tipped with cartilage. This tubercle, which articulates with the head of the stapes, was formerly, under the name

of *os orbiculare* seu *lenticulare*, described as a separate bone, which indeed it originally is in the fœtus up to the sixth month.

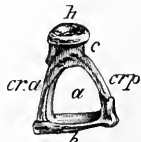
The length of the short process is about 3 to 3½ mm., of the long process about 4½ mm. The weight of the incus is very nearly the same as that of the malleus (Blake).

At the joints between the incus and malleus on the one hand and the incus and stapes on the other the articular surfaces are tipped with cartilage and enclosed by a synovial membrane. Rüdinger describes both in this joint and in the articulation of the incus with the stapes an interarticular fibro-cartilage which subdivides the joint into two parts; but according to Brunner neither are synovial joints but are symphyses, the articular cartilages being united by fibrous tissue. At all events the existence of an interarticular cartilage at the joint between incus and stapes is doubtful, although most authorities admit its presence at the joint between the malleus and incus. Some anatomists describe a synovial joint at the articulation of the short process of the incus with the bone at the entrance to the mastoid cells.

The **stapes** (figs. 99, 100), the third and innermost bone of the ear, is in shape remarkably like a stirrup, and is composed of a head, a base, and two crura. The whole bone measures 3 to 4 mm. in length and about 2½ mm. in breadth. Its weight is from 2 to 4 milligrams. The *head* (*h*) is directed outwards, and has on its end a slight depression, covered with cartilage, which articulates with the lenticular process of the incus. The *base* (*b*) is a plate of bone fitting into

Fig. 99.—LEFT STAPES, VIEWED FROM BELOW. Magnified four times. (E. A. S.)

h, outer extremity or head of the bone, with a shallow concavity for articulation with the orbicular process of the incus; *c*, constricted part or cervix. This is not always so well-marked as in the present specimen. *cr a*, anterior crus; *cr p*, posterior crus; *b*, base; *a*, arch of the stapes. The bony groove which bounds the arch is shown in front and below; above and behind it is concealed from view.



the fenestra ovalis, but not quite closely, so that a slight amount of movement is allowed. Its form is irregularly oval, the upper margin being curved, while the lower is nearly straight (fig. 90, *st*). Its border is encircled by hyaline cartilage, which also covers its vestibular surface. The margin of the fenestra ovalis has also a covering of the same tissue (Toynbee), and the opposed cartilaginous surfaces are closely connected by a network of elastic fibres passing between them, and forming an especially dense ligamentous band near the tympanic and vestibular cavities (Rüdinger). The crura of the stapes diverge from a constricted part (*neck*, fig. 99, *c*) of the bone, situated close to the head, and are attached to the outer surface of the base near its extremities. The anterior crus (*cr. a*) is the shorter and straighter of the two. The crura, with the base of the stapes, encircle a small triangle or arched space (*a*), across which in the recent state a thin membrane is stretched. A shallow groove runs round the opposed surfaces of the arch, and into this the membrane is received.

The formation and morphological relations of the auditory ossicles have already been noticed in the Embryology (Vol. I., p. 167, *et seq.*). Suffice it here to recall the fact that the incus and malleus are originally laid down as one piece of cartilage, which is continued forwards as Meckel's cartilage along the first visceral arch, and that the stapes is formed by ossification in cartilage which develops around an artery (stapedial or mandibular—Fraser, Salensky), which arises from the internal carotid, and passing into the tympanum through the wall of the carotid canal, ascends over the promontory and anastomoses with branches of the stylo-mastoid, middle meningeal, and ascending pharyngeal arteries. In rare instances this artery remains, but it has usually disappeared before birth. In some animals (Cheiroptera, Insectivora, Rodentia) it persists in the adult. In these cartilaginous foundations of the auditory ossicles the formation of the individual bones occurs in the following manner: the separation and articulation between the malleus and incus appears in the third month of embryonic life; the cartilaginous continuity between the malleus and Meckel's cartilage disappears somewhat later, and its place is taken partly by ligamentous tissue (forming the

anterior ligament of the malleus and the accessory mesial ligament of the mandibular articulation) and partly by a thin slip of membrane bone which develops in the perichondrium, and becomes the *processus gracilis* of the malleus. Besides this the malleus has two ossification centres, one in the head, the other in the manubrium, which appear at the end of the third or the beginning of the fourth month. About the same time an ossification centre appears in the body of the incus, and from this the whole of the bone is formed, except the

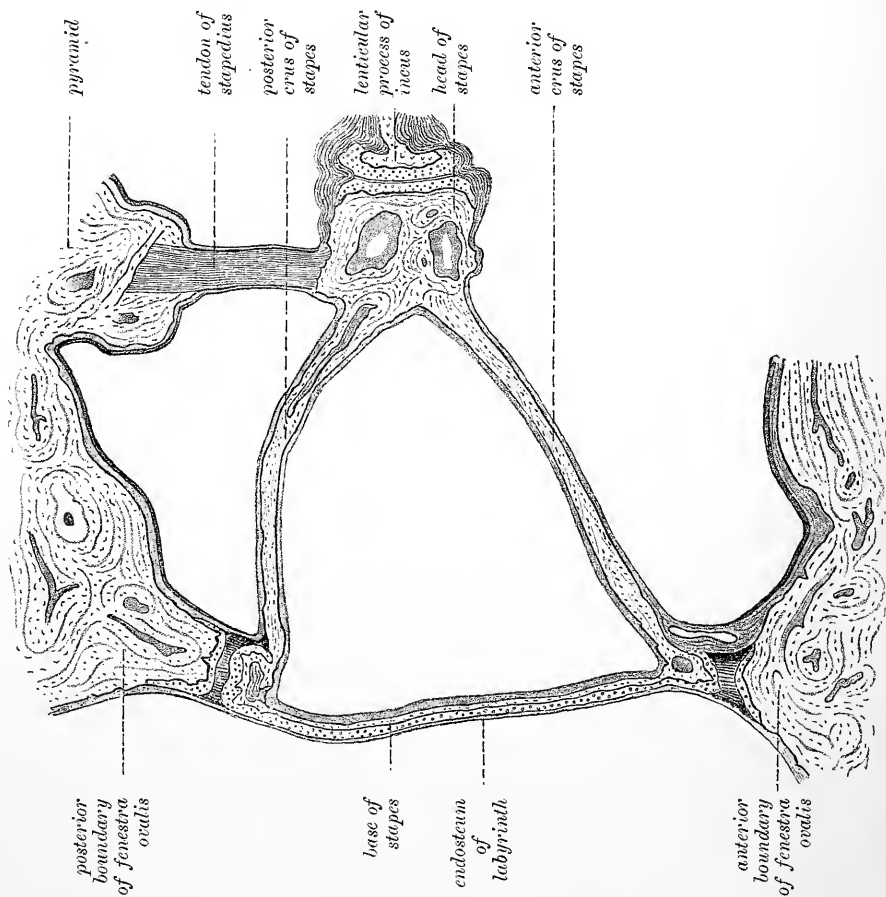


Fig. 100.—SECTION THROUGH STAPES AND FENESTRA OVALIS. (Brunner.)

lenticular process, which appears as an epiphysis. The stapes ossifies somewhat later than the other ossicles, and from four centres—one for the head, one for each crus, and one for the base.

Ligaments.—In the articulations of the small bones of the ear with one another the connection is strengthened by ligamentous fibres.

Their attachment to the walls of the tympanum is effected chiefly by the following ligaments, as well as by the reflections of the mucous membrane lining that cavity.

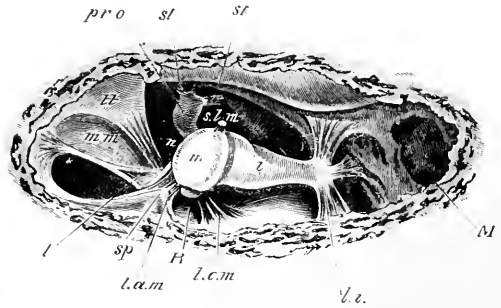
The *anterior ligament of the malleus* (figs. 90, *l. a.*, and 101, *l. a. m.*) is a comparatively strong and broad band of fibres, which connects the base of the *processus gracilis* and the anterior part of the malleus above this process with the anterior wall of the tympanum close to the Glaserian fissure. The part of the ligament which passes out of the Glaserian fissure was long thought to be muscular (*laxator tympani auct.*), but most observers agree in denying the

existence of muscular tissue in this situation. Many of the fibres of the anterior ligament take origin from a bony prominence which projects from the margin of the external meatus into the tympanum, and forms the anterior boundary of the notch of Rivinus. This prominence is known as the anterior spinous process of the tympanum (*spina tympanica anterior*) (fig. 101, *sp*) to distinguish it from another smaller bony prominence or spine at the posterior extremity of the notch (see p. 81).

Accessory anterior ligament.—A comparatively stout sheath surrounds the tendon of the tensor tympani as it passes from the end of the cochleariform process to the malleus, and a flat ligamentous band with a thickened margin (fig. 101, *l*), which lies along the anterior border of this sheath, stretching between the anterior wall of the tympanum and the upper

Fig. 101.—VIEW OF THE CAVITY OF THE TYMPANUM, OPENED FROM ABOVE. (Magnified four times.) (E. A. S.)

m, head of the malleus; *sp*, *spina tympanica anterior*; *l. a. m*, anterior ligament of the malleus; *l. e. m*, external ligament of the malleus; *R*, gap between the two ligaments leading to the *membrana flaccida* and notch of Rivinus; *i*, body of the incus; *l. i*, posterior ligament of the incus; *pr. o*, *processus orbicularis* of the incus seen in the depth of the cavity, articulated with the head of the stapes, *st*; *st'*, tendon of the stapedius muscle emerging from the pyramid; *t*, tendon of the tensor tympani, emerging from the conical end of its canal; *l*, thickened edge of a flattened band of ligamentous fibres which lies in the fold of the mucous membrane, *m. m.*, and assists in fixing the malleus; *s. l. m*, superior ligament of the malleus, cut short; *n*, chorda tympani nerve.



part of the manubrium and neck of the malleus, may be regarded as assisting in the fixation of the malleus anteriorly. Toyne described the sheath in question as acting as an accessory ligament (tensor ligament).

The *external ligament of the malleus* (fig. 101, *l. e. m.*), is a fan-shaped ligamentous structure, the fibres of which arise from the margin of the notch of Rivinus, and converge to the short process and adjacent part of the malleus.

The posterior bundle of fibres of this ligament, together with the anterior bundle of the anterior ligament are termed by Helmholtz the "axis-ligament of the malleus," since they are attached nearly in the axis of rotation of that bone.

The *superior ligament of the malleus* (figs. 101, 102, *s. l. m.*) consists of a small bundle of fibres, which passes downwards and outwards from the roof of the tympanum to the head of the malleus, and serves to check the outward movements of the manubrium and *membrana tympani*.

Inferior ligament of the malleus.—A small bundle of ligamentous fibres is occasionally found passing from near the extremity of the handle of the malleus upwards and backwards behind the long process of the incus, to be attached to the outer wall of the tympanum. This ligament assists the external ligament in resisting a too violent action of the tensor tympani muscle, and it serves also to restrict any rotating action which that muscle may tend to exert upon the malleus.

The *ligament of the incus* (figs. 90, 101, *l. i.*) extends from near the point of the short crus backwards towards the posterior wall of the tympanum, but some of its fibres spread also outwards and inwards. It is attached below the entrance to the mastoid cells.

Muscles.—There are only two well-determined muscles of the tympanum. Sömmerring described four, and some authors have mentioned a larger number; but

their descriptions have not been confirmed by later research. Of the two muscles generally recognised, one is attached to the malleus, and the other to the stapes.

The **tensor tympani** is the larger of these muscles. It consists of a tapering fleshy part, about half an inch in length, and a slender tendon. The muscular fibres arise from the cartilaginous end of the Eustachian tube and the adjoining surface of the sphenoid bone, and from the sides of the canal in which the muscle lies and in which it is conducted backwards to the cavity of the tympanum. Immediately in front of the fenestra ovalis the tendon of the muscle bends at nearly a right angle over the end of the processus cochleariformis as round a pulley, and, contained in a fibrous sheath, passes outwards, to be inserted into the inner part of

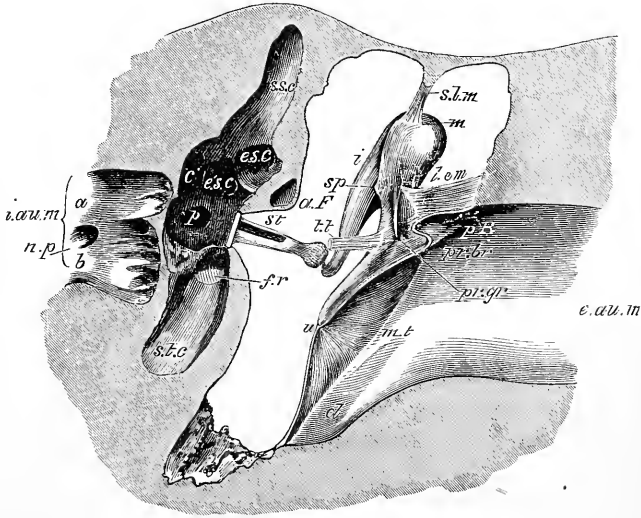


Fig. 102.—PROFILE VIEW OF THE LEFT MEMBRANA TYMPANI AND AUDITORY OSSICLES FROM BEFORE AND SOMEWHAT FROM ABOVE. Magnified four times. (E. A. S.)

The anterior half of the membrane has been cut away by an oblique slice. *m*, head of the malleus; *sp*, spur-like projection of the lower border of its articular surface; *pr. br.*, its short process; *pr. gr.*, root of processus gracilis, cut; *s.l.m.*, suspensory ligament of the malleus; *l.e.m.*, its external ligament; *t.t.*, tendon of the tensor tympani, cut; *i*, incus, its long process; *st*, stapes in fenestra ovalis; *e.a.u.m.*, external auditory meatus; *p.R.*, notch of Rivinus; *m.t.*, membrana tympani; *u*, its most depressed point or umbo; *d*, declivity at the extremity of the external meatus; *i.a.u.m.*, internal auditory meatus; *a* and *b*, its upper and lower divisions for the corresponding parts of the auditory nerve; *n.p.*, canal for the nerve to the ampulla of the posterior semicircular canal; *s.s.c.*, ampullary end of the superior canal; *p*, ampullary opening of the posterior canal; *c*, common aperture of the superior and posterior canals; *e.s.c.*, ampullary, and *e'.s.c.*, non-ampullary end of the external canal; *s.t.c.*, scala tympani cochleæ; *f.r.*, fenestra rotunda, closed by its membrane; *a.f.*, aqueduct of Fallopius.

the handle of the malleus, close to its root (figs. 101, 102, *tt*). The tensor tympani is supplied by a branch of the fifth pair through the otic ganglion. Its nerve is furnished with a small ganglion (Dastre and Morat).

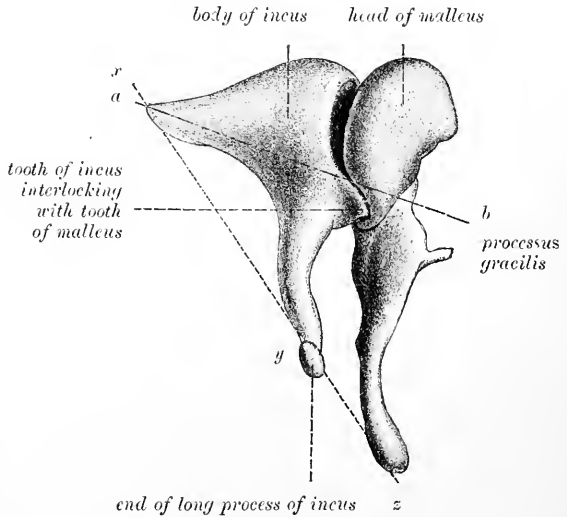
The **stapedius** is a very distinct muscle, but is hidden within the bone, being lodged in a canal in front of the descending part of the aqueductus Fallopii and in the hollow of the pyramid. The tendon issues from the aperture at the apex of that little elevation (fig. 90), and passing forwards, surrounded by a fibrous sheath, is inserted into the neck of the stapes posteriorly, close to the articulation of that bone with the lenticular process of the incus (figs. 90, 101).

A very slender spine of bone has been found occasionally in the tendon of the stapedius in man; and a similar piece of bone, though of a rounder shape, exists constantly in the horse, the ox, and other animals.

Movements of the auditory ossicles.—The malleus and incus move together round an axis extending backwards from the attachment of the malleus by its anterior ligament to the attachment of the short process of the incus posteriorly. The handle of the malleus follows all the movements of the membrana tympani, and when the membrane is impelled inwards, the incus, moving inwards along with the malleus, pushes the stapes inwards towards the internal ear. In this movement the head of the stapes is slightly raised as well as pressed inwards, and the upper margin of its base moves more than the lower. But the cavity of the inner ear is full of liquid; and its walls are unyielding, except at the fenestra rotunda; when, therefore, the stapes is pushed inwards, the secondary membrane of the tympanum, which blocks up the fenestra rotunda, must be bulged outwards. When the membrana tympani returns to its original condition these movements are reversed. That the movement inwards of the incus must closely accompany that of the malleus, is necessitated by the fact that the lower margin of its articular surface has a well

Fig. 103.—FIGURE TO SHOW THE INTERLOCKING OF THE MALLEUS AND INCUS. (Helmholtz.)

The line *a b* indicates the axis of rotation of the two bones, the line *x y z* joins this axis with the two ends of the crank lever which these bones form.



marked projection which catches against the prominent border of the articular surface of the malleus (fig. 102, *sp*, and fig. 103). If, however, in consequence of increase of tension of the air in the tympanum, the malleus should be moved too freely outwards, the incus need not follow that movement to its full extent, but may merely glide over the smooth adjoining surface of the malleus, and thus the danger that there would otherwise be of forcibly dragging out the stapes from the fenestra ovalis is avoided (Helmholtz).

The tensor tympani muscle, being attached near the base of the manubrium of the malleus, draws the whole bone and the membrane inwards, tightening the latter. Its action is opposed by the strong external ligament of the malleus. The tensor tympani exerts but little rotating action upon the malleus. The action of the stapedius muscle is obviously to draw the head of the stapes backwards, in doing which the hinder end of the base of that bone will be pressed against the margin of the fenestra ovalis, while the fore part will be withdrawn from the fenestra.

The lining membrane of the tympanum.—The mucous membrane of the tympanum is continuous with that of the pharynx through the Eustachian tube, and is further prolonged from the tympanum backwards into the mastoid cells. The malleus and incus are invested by the lining membrane of the outer wall of the cavity. The membrane forms also folds extending down from the roof in front of and behind the conjoined heads of the incus and malleus, and another passing down to the chorda tympani nerve or even below it; these folds wholly or partially separate off small pouch-like portions of the tympanic cavity which will be further

noticed below. Another well-marked fold has been already noticed in connection with the tendon of the tensor tympani, and various other smaller folds are met with. They often contain strands of fibrous tissue and sometimes osseous spicules. All these folds are, however, very variable in their development.

The mucous membrane which lines the cartilaginous part of the Eustachian tube resembles much the membrane of the pharynx, with which it is immediately continuous; it is thick and vascular, is covered by ciliated epithelium, and is provided with many simple mucous glands which pour out a thick secretion: in the osseous part of the tube, however, the membrane becomes gradually thinner. In the tympanum and the mastoid cells the mucous membrane is paler, thinner, and less vascular, and secretes a small amount of less viscid, yellowish fluid. According to most observers no glands are normally met with in the tympanum, but Krause has described and figured simple glands in parts, and Tröltzsch describes an acinous gland on the external wall, anteriorly. Between the mucous membrane and the periosteum is a network of fibrous bundles, which are here and there raised above the general surface, causing corresponding projections of the mucous membrane. In various places on the interlacing bundles, peculiar swellings occur of various sizes, which appear to be caused by the superaddition of concentrically arranged fibres upon the smaller bundles, producing an appearance similar to that of miniature Pacinian corpuscles (Politzer, Kessel). The epithelium in the tympanic cavity is in part columnar and ciliated, with small cells between the bases of the ciliated cells, but the promontory, the ossicula, and the membrana, are covered with a simple layer of flattened non-ciliated cells (Kölliker); and a similar non-ciliated epithelium is said to line the mastoid antrum and cells.

Recesses or pouches of the tympanum.—The ossicula, as well as the ligaments which unite them with the wall of the tympanum, and the chorda tympani nerve, are all invested by folds of the lining mucous membrane, which in many cases also pass across the spaces between the several ligaments and bony projections. These uniting folds and the prominences which they cover and connect thus mark off in certain places pouch-like portions of the general cavity. There is a good deal of variation in the extent of development of these folds and pouches, but some are fairly constant in their occurrence, and one pouch in particular, between the heads of the malleus and incus and the external wall is nearly shut off from the rest of the cavity by well marked folds, which pass down from the roof of the tympanum in front of and behind the suspensory ligament of the malleus. This pouch may be termed the *superior external pouch*. Immediately below it and partly separated from it by the anterior and external ligaments of the malleus and a fold of membrane which unites them, is another smaller pouch, described by Prussak, which may be termed the *infero-external*. It is bounded above by the ligaments and folds just mentioned, externally by the membrana flaccida, below and internally by the processus brevis mallei. In front it ends blindly, but behind it opens into the general cavity of the tympanum. This pouch is of considerable importance clinically and pathologically because fluid (*e.g.*, pus) may accumulate in it, especially since its opening into the rest of the posterior pouch is placed somewhat above its floor. It is into this pouch that perforations of the membrana flaccida occur.

The fold which passes down from the roof of the cavity towards the mesial part of the neck of the malleus, and which incloses in or near its free border the chorda tympani nerve, also separates off two pouches, one in front of and the other behind the manubrium mallei, and both bounded externally by the membrana tympani. These pouches are the *anterior* and *posterior pouches* of Tröltzsch. For a detailed description of the various folds and pouches, the student is referred to certain of the memoirs cited in the Bibliography.

In the fœtus the mucous membrane of the tympanum consists of a swollen gelatinous embryonic tissue which fills the cavity, leaving only an irregular cleft between its folds. Towards the end of intrauterine life the membrane becomes gradually thinner and less gelatinous and the cleft enlarges, fluid accumulating within it. After birth this fluid becomes replaced by air, and the mucous membrane speedily acquires the thin fibrous character which it exhibits throughout life.

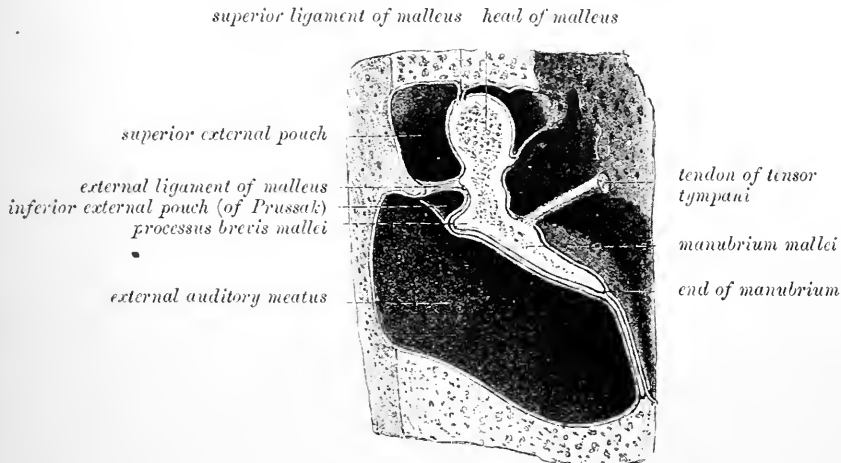


Fig. 104.—SECTION THROUGH THE MALLEUS AND MEMBRANA TYMPANI, SHOWING SOME OF THE POUCHES OR RECESSES OF THE TYMPANIC CAVITY. (After Merkel.)

Vessels and nerves of tympanum.—The **arteries** of the tympanum, though very small, are numerous, and are derived from branches of the external carotid, and from the internal carotid.

The fore part of the cavity is supplied chiefly by the *tympanic branch* of the internal maxillary, which enters by the fissure of Glaser. The back part of the cavity including the mastoid cells, receives its arteries from the *stylo-mastoid branch* of the posterior auricular artery, which is conducted to the tympanum by the aqueduct of Fallopius. These two arteries form by their anastomosis a vascular circle round the margin of the membrana tympani. The smaller arteries of the tympanum are, the *petrosal branch* of the middle meningeal, which enters through the *hiatus Fallopii*, and branches through the bone from the *internal carotid* artery, furnished from that vessel whilst in the carotid canal.

The **veins** of the tympanum empty their contents into the superior petrosal sinus and the temporo-maxillary vein.

Nerves.—The tympanum contains numerous nerves; for, besides those which supply the parts of the middle ear itself, there are several which serve merely to connect nerves of different origin.

The lining membrane of the tympanum is supplied by filaments from the tympanic plexus, which occupies the shallow grooves on the inner wall of the cavity, particularly on the surface of the promontory (fig. 93).

This plexus (fig. 105) is formed by 1st, the *nerve of Jacobson* from the petrosal ganglion of the glosso-pharyngeal; 2nd, the *small deep petrosal nerve*, a filament connecting the nerve of Jacobson with the carotid plexus of the sympathetic; 3rd, a branch which joins the great superficial petrosal nerve; 4th and lastly, the *small superficial petrosal nerve*, passing to the otic ganglion.

Numerous ganglion cells are found both in the uniting cords and also at the points of junction of the plexus.

The nerve of Jacobson or tympanic nerve enters the tympanum by a small foramen near its floor, which forms the upper end of a short canal in the petrous portion of the temporal bone, beginning at the base of the skull between the carotid foramen and the jugular fossa. The nerve connecting it with the carotid plexus is above and in front, and passes through the bone directly from the carotid canal. The branch to the great superficial petrosal nerve is lodged in a canal which opens on the inner wall of the tympanum in front of the fenestra ovalis. The small superficial petrosal nerve also leaves at the fore part of the cavity beneath the canal for the tensor tympani.

The tensor tympani muscle obtains its nerve from the internal pterygoid of the fifth through the otic ganglion; as already mentioned its nerve is provided with a small ganglion. The stapedius receives filaments from the facial nerve.

The *chorda tympani*, arising from the facial near the lower end of the aqueduct of Fallopius, takes a recurrent course to the tympanum, which it enters by an

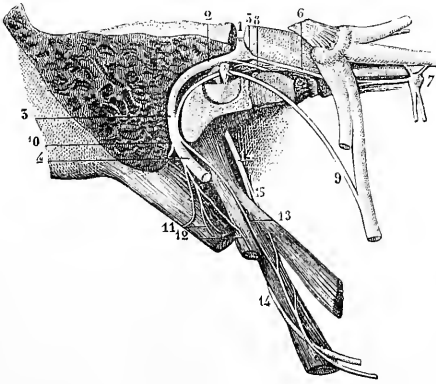


Fig. 105.—THE FACIAL NERVE IN ITS CANAL, WITH ITS CONNECTING BRANCHES, &c. (From Sappey, after Hirschfeld and Leveillé.) $\frac{2}{3}$

The mastoid and a part of the petrous bone have been divided nearly vertically, and the canal of the facial nerve opened in its whole extent from the internal meatus to the stylo-mastoid foramen; the Vidian canal has also been opened from the outer side: 1, facial nerve in the first horizontal part of its course; 2, its second part turning backwards; 3, its vertical portion; 4, the nerve at its exit from the stylo-mastoid foramen; 5, geniculate ganglion; 6, large superficial petrosal nerve; 7, sphenopalatine ganglion; 8, small superficial petrosal nerve; 9, chorda tympani; 10, posterior auricular branch cut short; 11, branch to the digastric muscle; 12, branch to the stylo-hyoid muscle;

13, twig uniting with the glosso-pharyngeal nerve (14 and 15).

aperture in the posterior wall (*iter chordæ posterioris*) just below the level of the pyramid. From this place it passes with a slight curve across the cavity near the outer boundary, and crossing successively the posterior part of the membrana tympani, the handle of the malleus near its neck, and the processus gracilis of the same bone, finally enters a small canal (*iter chordæ anterioris*) in the bone close to the Glaserian fissure (fig. 90, *ch*). It is invested by the fold of the lining membrane already mentioned.

THE INTERNAL EAR, OR LABYRINTH.

The inner, essential part of the organ of hearing, is contained in the petrous portion of the temporal bone. It consists of a complex cavity—the osseous labyrinth—hollowed out of the bone, and containing the membranous labyrinth.

The *osseous labyrinth* is incompletely divided into three parts, named the vestibule, the semicircular canals, and the cochlea. They are lined throughout by a thin periosteal membrane, within which there is a clear fluid named perilymph, or liquor Cotunnii.

The *membranous labyrinth* being distinctly smaller than the bony labyrinth, a space is left between the two, occupied by the perilymph just referred to. The membranous structure is lined throughout by epithelium, and at certain parts receives branches of the auditory nerve. It contains a fluid named the endolymph, and consists of several parts, viz.: the utricle, saccule, semicircular canals, and membranous cochlea.

THE OSSEOUS LABYRINTH.

The **vestibule** forms a central chamber of the labyrinth, which communicates in front with the cochlea, and behind with the semicircular canals. It is irregularly ovoidal in shape, measuring about 5mm. from above down and from before back but slightly less from without inwards.

The outer wall, which separates it from the cavity of the tympanum, is perforated by the fenestra ovalis, which in the recent state is closed by the base of the stapes.

At the fore part of the inner wall is a small round pit, the *fovea hemispherica* (fig. 108, 2 ; fig. 111), pierced with many minute holes, which serve to transmit branches of the auditory nerve from the internal auditory meatus to the sacculle. This fossa is limited behind by a vertical ridge named *crista vestibuli*, the anterior

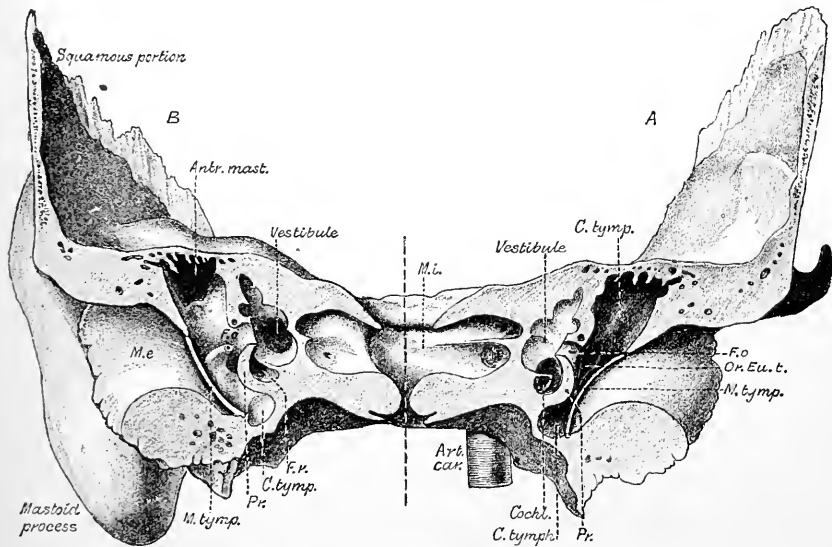


Fig. 106.—THE RIGHT TEMPORAL BONE SAWN ACROSS IN A CORONAL PLANE ; THE CUT PASSING THROUGH THE FENESTRA OVALIS. Natural size. (Testut.)

A, anterior, B, posterior segment, showing the cut surfaces.

m. e., meatus externus ; *m. tymp.*, groove for membrana tympani ; *c. tymp.*, typanic cavity ; *antr. mast.*, antrum mastoideum ; *pr.*, promontory ; *or. Eu. t.*, orifice of Eustachian tube ; *f. o.*, fenestra ovalis ; *f. r.*, fenestra rotunda ; *cochl.*, commencement of cochlea ; *m. i.*, meatus audit. internus ; *art. car.*, carotid artery.

extremity of which has been termed the *pyramid of the vestibule*, and merges on to the roof. The crista passes backwards and downwards and bifurcates behind the fovea hemispherica ; the fork encloses a small fossa, which was termed *recessus cochlearis* by Reichert : it receives the beginning of the ductus cochlearis and is pierced by a number of holes for the passage of nerve-fibres (fig. 111, *fossa cochlearis*). Behind the lower part of the crest is the small oblique groove which deepens into a fine canal, the *aqueduct of the vestibule* (fig. 108, 4). This extends to the posterior surface of the petrous bone and transmits the ductus endolymphaticus (p. 105) and a small vein.

In the roof is an oval depression, placed somewhat transversely, *fovea hemi-elliptica* (fig. 108, 1 ; fig. 111), which is separated by the crest from the hemispherical fossa. The crest and pyramid close to this fossa are pierced with fine holes for the passage of nerve-fibres, those in the crest itself being destined for the utricle : those in the pyramid for the ampullae of the superior and external semicircular canals.

At the back part of the vestibule are five round apertures, leading into the semi-

circular canals: and at the lower and fore part of the cavity is a larger opening, which communicates with the scala vestibuli of the cochlea.

The **semicircular canals** are three tubes, situated above and behind the vestibule, into which they open by five apertures, the contiguous ends of two of the canals being joined. They are unequal in length, but each tube is bent so as to form about two-thirds of an ellipse; and is moreover dilated at one end, the enlargement being known as the *ampulla*. The canals are compressed laterally, and measure 1mm. to 1.5mm. across; but the ampulla has a diameter of about 2mm.

The canals differ from one another in direction, in length, and in position with regard to the vestibule. The *superior semicircular canal* (fig. 108, 3, fig. 109, 5), 19 mm. long, is nearly vertical and lies transversely to the bony axis of the petrous

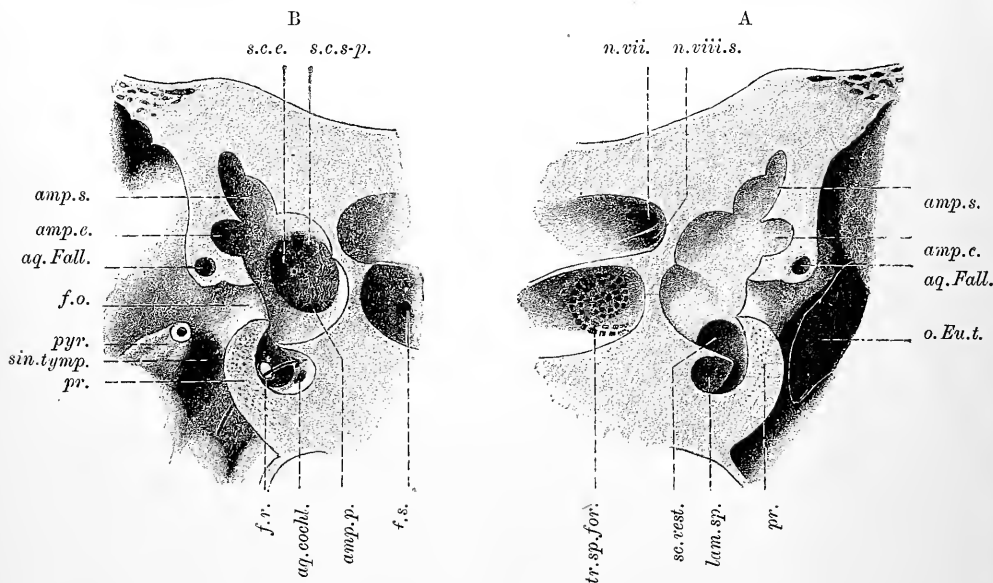


Fig. 107.—PORTIONS OF THE PREVIOUS FIGURE ENLARGED. (Testut.)

A, anterior; B, posterior segment. *amp.e.*, *amp.s.* and *amp.p.*, ampullary orifices of external, superior and posterior semicircular canals; *s.c.e.*, non-ampullary orifice of the external canal; *s.c.s-p.*, conjoint non-ampullary orifice of the superior and posterior canals; *aq.Fall.*, aqueductus Fallopii; *f.o.*, fenestra ovalis; *f.r.*, fenestra rotunda; *aq.cochl.*, aqueductus cochleæ; *sc.vest.*, commencement of scala vestibuli: that of the scala tympani is just below it; *lam.sp.*, spiral lamina; *n.VII.*, orifice for facial nerve; *n.VIII.s.*, orifices for superior or vestibular division of auditory nerve; *tr.sp.for.*, orifices for cochlear nerve; *f.s.*, foramen singulare; *pyr.*, pyramid; *pr.*, promontory; *sin.tymp.*, sinus tympani; *o.Eu.t.*, orifice of osseous Eustachian tube.

bone, forming an angle of about 45° with the coronal plane; it rises higher than any other part of the labyrinth, and its place is indicated by a smooth arched projection on the upper surface of the petrous bone. The ampullary end of this canal is the external and anterior, and opens by a distinct orifice into the upper part of the vestibule (fig. 107, *s*); whilst the opposite extremity joins the non-dilated end of the posterior semicircular canal, and opens by a common aperture with it into the back part of the vestibule (fig. 107, *s.c.s-p.*; fig. 109, 3). The *posterior semicircular canal* (fig. 108, 5, fig. 109, 6), is also nearly vertical, and lies in a plane which is almost parallel with the superior canal of the other side (Crum Brown). The posterior and superior canals of the same side incline towards one another at their inner ends. The posterior is the longest of the three (22 mm.): its ampullary end is at the lower and back part of the vestibule (fig. 107, *amp.p.*); and the opposite end terminates in the common canal above described (*s.c.s-p.*). The

external semicircular canal (fig. 108, 4; fig. 109, 7) arches *horizontally* outwards, and opens by two distinct orifices into the upper and back part of the vestibule (fig. 107, *amp.e.* and *s.c.e.*). The canal is shorter than either of the other two (15 mm.): its ampulla is at the outer end, above the fenestra ovalis.

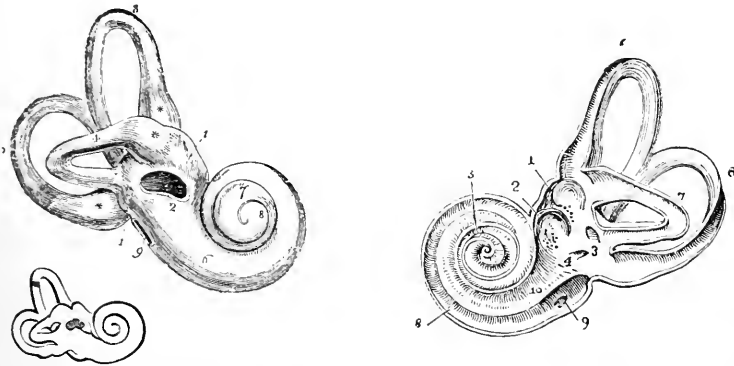


Fig. 108.—RIGHT BONY LABYRINTH, VIEWED FROM THE OUTER SIDE (after Sömmerring). Magnified $2\frac{1}{2}$ times.

The specimen here represented is prepared by separating piecemeal the looser substance of the petrous bone from the dense walls which immediately enclose the labyrinth. 1, the vestibule; 2, fenestra ovalis; 3, superior semicircular canal; 4, horizontal or external canal; 5, posterior canal; * * *, ampullae of the semicircular canals; 6, first turn of the cochlea; 7, second turn; 8, apex; 9, fenestra rotunda. The smaller figure in outline below shows the natural size.

Fig. 109.—VIEW OF THE INTERIOR OF THE LEFT LABYRINTH. (From Sömmerring.) $2\frac{1}{1}$

The bony wall of the labyrinth is removed superiorly and externally. 1, fovea hemi-elliptica; 2, fovea hemispherica; 3, common opening of the superior and posterior semicircular canals; 4, opening of the aqueduct of the vestibule; 5, the superior; 6, the posterior, and 7, the external semicircular canals; 8, spiral tube of the cochlea (scala tympani); 9, opening of the aqueduct of the cochlea; 10, placed on the lamina spiralis in the scala vestibuli.

The **cochlea** (figs. 108 to 116), when cleared of the surrounding less dense bony substance in which it lies embedded, appears in the form of a blunt cone, the base of which is turned towards the internal auditory meatus, whilst the apex is directed

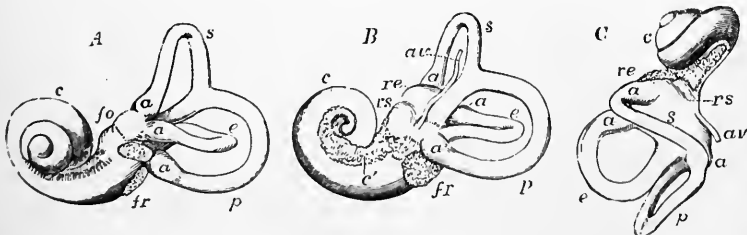


Fig. 110.—VIEWS OF A CAST OF THE INTERIOR OF THE LABYRINTH. (From Henle.) $\frac{2}{1}$

Such casts may easily be made in fusible metal, and give a very correct view of the form of the different parts of the labyrinthine cavity. A, view of the left labyrinth from the outer side; B, the right labyrinth from the inner side; C, the left labyrinth from above; s, the superior, p, the posterior, and e, the external semicircular canals; a, their several ampullae; r e, fovea hemi-elliptica of the vestibule; r s, fovea hemispherica; a v, aqueduct of the vestibule; f o, fenestra ovalis; f r, fenestra rotunda; c, the coiled tube of the cochlea; c', the tractus spiralis foraminulentus.

outwards, with an inclination forwards and downwards, and is close to the canal for the tensor tympani muscle. It measures about 5mm. from base to apex, and 9 mm. in breadth at the base. It consists of a gradually tapering spiral tube, the inner wall of which is formed by a central column, or *modiolus* (fig. 113), around which

it winds. It is partially divided along its whole extent by a spiral lamina, projecting into it from the modiolus. From this osseous spiral lamina membranous structures are in the recent condition stretched across to the outer wall of the tube, and thus completely separate two passages or *scala*, one on each side of the spiral lamina, which communicate one with the other only by a small opening, named *helicotrema*, placed at the apex of the cochlea.

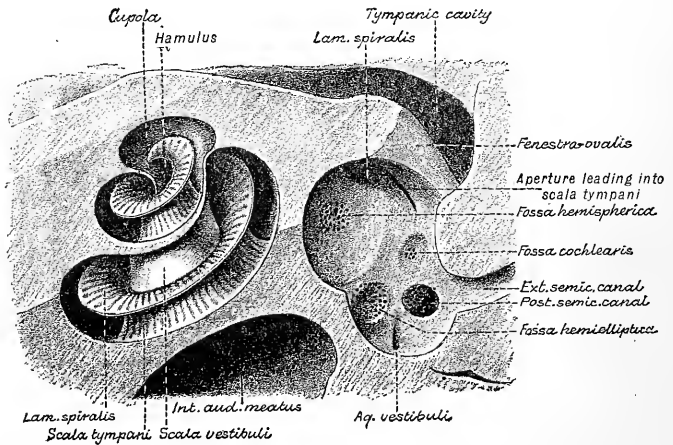


Fig. 111.—THE COCHLEA AND VESTIBULE EXPOSED BY REMOVING THE ROOF OF THE BONY LABYRINTH WITH THE SAW, SO AS TO VIEW THE PARTS FROM ABOVE. Magnified. (Testut.)

That the cochlea is justly to be considered as an elongated tube, coiled spirally on the modiolus, is illustrated by the simple pouch-like form of the rudimentary cochlea of birds (fig. 112) as well as by the history of its development.

The *spiral osseous canal* is about 33mm. long, and about 2mm. in diameter at the commencement, where it is widest. From this point the canal makes nearly $2\frac{3}{4}$ turns round the central pillar (from left to right in the right ear, and in the opposite direction in the left ear, supposing the cochlea viewed from the base), and ends by an arched and closed extremity called the *cupola*, which forms the summit of the

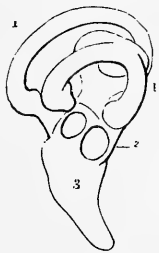

Fig. 112.—OSSEOUS LABYRINTH OF THE BARN OWL (*STRIX FLAMMEA*). (From Breschet.) $\frac{1}{4}$

1, semicircular canals; 2, vestibule; 3, cochlea in the form of a short straight tube.

cochlea. The first coil, having by far the most extensive curve and being the largest portion of the tube, nearly hides the second from view; and, bulging somewhat into the tympanum, forms the round elevation on the inner wall of that cavity called the promontory. The last half-coil is somewhat flattened from above down and its extremity is partly embedded in the coil next below it.

The *modiolus* (*columella cochleæ*), the central pillar or axis of the cochlea, is much the thickest within the first turn of the tube, rapidly diminishing in size in the succeeding parts. Its central part is spongy as far as the last half-coil, and is pierced by many small canals, for the passage of the nerves and vessels to the spiral lamina; one of these canals, larger than the rest, *central canal of the modiolus*, runs from the base through the centre of the modiolus (fig. 114). The base of the modiolus appears in the internal auditory meatus as the fossula cochleæ containing the foramen centrale and the tractus spiralis foraminulentus: the latter transmit-

ting the nerve-fibres of $1\frac{1}{2}$ turns of the cochlear tube, the former being continued into the central canal of the modiolus and transmitting the nerve-fibres for the uppermost turn.

The *osseous spiral lamina* is a thin, flat plate, growing from the modiolus, and

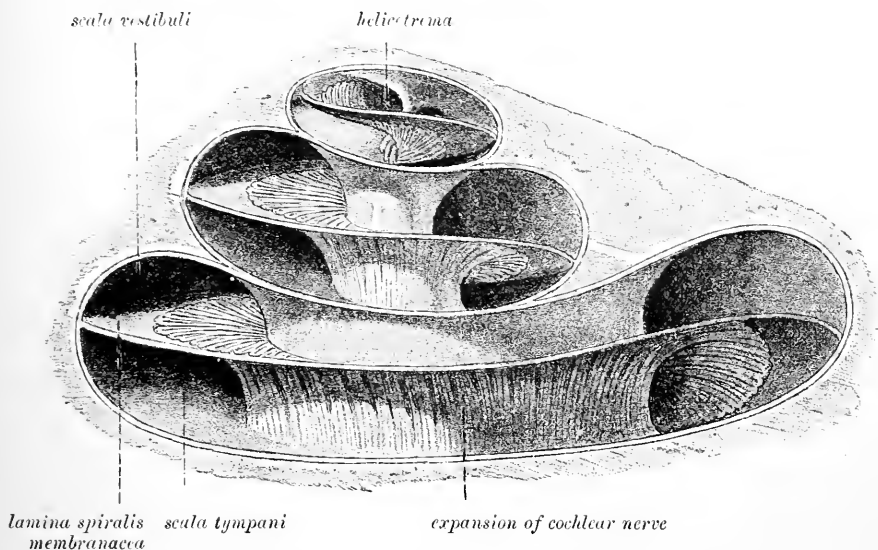


Fig. 113.—DIAGRAMMATIC VIEW OF THE OSSEOUS COCHLEA LAID OPEN. (Arnold.)

projecting into the spiral tube, so as to divide it partly into two. It does not reach farther than about half-way towards the outer wall of the spiral tube. Close to the

scala vestibuli

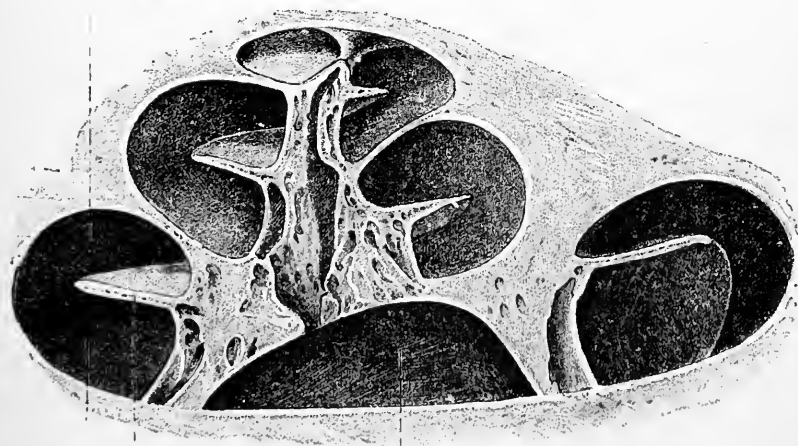


Fig. 114.—VIEW OF THE OSSEOUS COCHLEA DIVIDED THROUGH THE MIDDLE. (Arnold.)

apex of the cochlea, it ends in a hooklike process (*hamulus*), which partly bounds the helicotrema. Opposite the lamina spiralis at the commencement or base of the cochlear tube is another bony lamina (secondary spiral lamina) which nearly meets the spiral lamina, so that there is here only a narrow cleft between the two.

The lamina is dense at its free edge; but nearer the modiolus its internal

structure is more open and spongy, and contains numerous small canals for vessels and nerves, continuous with, but running at right angles to, the canals in the modiolus. Winding round the modiolus, in the base of the spiral lamina, is a small canal, named the *spiral canal of the modiolus*.

The *scala tympani* (fig. 111 ; fig. 113, 3), the portion of the tube on the basal side of the lamina spiralis, commences at the fenestra rotunda, where in the recent state it is separated from the tympanum by the secondary membrane of the tympanum. Close to its commencement is the orifice of a small canal (*aqueductus cochleæ*), which extends downwards and inwards to the lower border of the petrous bone, where it opens into a depression immediately in front of the jugular fossa. It transmits a small vein which joins the inferior petrosal sinus. There is also a communication along the aqueductus cochleæ between the subarachnoid space and the perilymph in the scala tympani. The *scala vestibuli* (figs. 111, 113, 4) is rather narrower than the scala tympani in the first turn of the cochlea, but in the succeeding turns is larger ; it commences from the cavity of the vestibule, and communicates, as already described, with the scala tympani at the apex of the modiolus.

THE MEMBRANOUS LABYRINTH.

Within the osseous labyrinth, and separated in most parts from its lining membrane by the perilymph, membranous structures exist in which the ultimate ramifications of the auditory nerve are spread. In the vestibule and semicircular canals

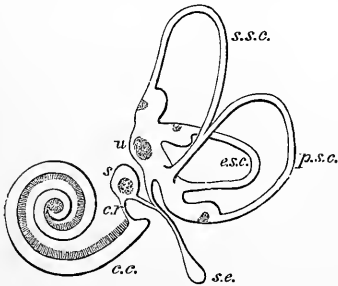


Fig. 115.—PLAN OF THE RIGHT MEMBRANOUS LABYRINTH VIEWED FROM THE MESIAL ASPECT. (E. A. S.)

u, utricle, with its macula and the three semicircular canals with their ampullæ ; *s*, saccule ; *s.e.* saccus endolymphaticus ; *c.r.* canalis reuniens ; *c.c.* canal of the cochlea.

these structures have a general resemblance in form to the complicated cavity in which they are contained. They do not, however, lie loose within the osseous cavity, but along the convex border of the canals, and at the places of entrance of the nerves into the vestibule and ampullæ are fixed to its wall. In the cochlea the membranous structures complete the septum between the *scalæ* already mentioned, and enclose an intermediate passage, the membranous *canal of the cochlea*. As before stated, the liquid contained within the membranous labyrinth is distinguished as *endolymph*.

The cavity which contains the perilymph communicates through the sheath of the auditory nerve with both the subdural and subarachnoid spaces.

Within the osseous vestibule are two membranous sacs, the one of which, termed the *utricle*, is connected with the semicircular canals, whilst the other, the *saccule*, is connected with the cochlea. These two sacs although in close contact do not open directly into one another although they are in indirect communication, in a manner presently to be explained.

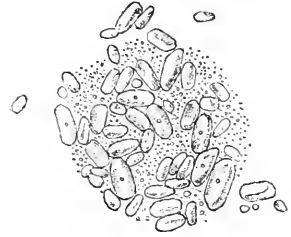The larger of the two sacs, the *common sinus* or *utricle* (fig. 115, *u* ; fig. 116), is of a very irregular oblong form, measuring in all 6 mm. to 7 mm. in length, and averaging 5 mm. in breadth, slightly flattened from behind forwards. It is lodged in the upper and back part of the vestibule, occupying the fovea hemi-elliptica and the space immediately below this. The part which lies in the fovea is termed the *recessus utriculi* (fig. 116, *rec. utr.*). This forms a distinct blind forward projection, some 3 mm. in length, into which, opposite the crista vestibuli, several small branches of the auditory nerve enter from the foramina in the bone ; and here the

wall of the utricule is thickened, the thickening having a concave surface towards the interior of the utricule, and being covered by auditory epithelium (*macula acustica utriculi*). A small mass of calcareous particles (*otoliths* or *otoconia*) lies

Fig. 116.—OTOLITHS. (From Schwalbe.)

within the sac, attached to the macula. These otoliths are crystals of carbonate of lime, rhombic, octahedral, or six-sided, often pointed at their extremities (fig. 118).

The ends of all the membranous semicircular canals open into the utricule in the situations shown in the diagrams, and a fine canal (*canalis utriculo-saccularis*) passes from the antero-mesial wall of the utricule, which joins with another one from the saccule to form the *ductus endo-lymphaticus* (fig. 116, *d.e*) (see below).



The ampullæ of the superior and external canals open into the roof of the recessus utriculi. The part of the utricule where the ampulla of the posterior semicircular canal opens is termed by G. Retzius *sinus posterior*, and the conjoined limbs of the superior and external canals form the *sinus superior* of that author. In all vertebrates below mammals the utricule has a second macula acustica in its lower part near the sinus posterior (*macula neglecta* of Retzius).

The smaller vesicle, the **sacculæ** (fig. 115, *s*; fig. 117), is an irregularly oval vesicle about 3 mm. long and nearly 2 mm. broad, and is somewhat flattened from within out. The sacculæ is situated in the lower and fore part of the cavity of the osseous vestibule, close to the opening from the scala vestibuli of the cochlea, and is received into the hollow of the fovea hemispherica, from the bottom of which many branches of nerve enter it, and here there is a similar broad and concave macula in its wall, which is covered by a small mass of otoliths. The upper end of the sacculæ bends round towards the recessus utriculi, with which it comes in contact, without direct communication (fig. 117).

The sacculæ gradually narrows below into a short funnel-shaped duct (1 mm. long, 0.5 mm. wide), the *canalis reuniens* of Hensen (fig. 115, *c. r.*; fig. 117, 19), which passes downwards and outwards to open directly into the epithelial canal of the cochlea a short distance from its blind lower extremity. There is also, as already mentioned, a canal, lined with epithelium, which passes from the posterior wall of the sacculæ along the aqueductus vestibuli to end blindly in a dilated extremity (*sacculus endo-lymphaticus*, fig. 115, *s.e.*) on the posterior surface of the petrous bone just below the orifice of the aqueduct and lying in the tissue of the dura mater (Cotugno). This canal is joined near its origin by a minute tube from the utricule (fig. 117, 7), so that in this way the cavity of the sacculæ is brought into communication with that of the utricule (Boettcher).

The **membranous semicircular canals** are from one-third to one-fifth the diameter of the osseous tubes in which they are lodged, and are dilated into ampullæ within the ampullary enlargements of those tubes. In section they are oval or somewhat elliptical (fig. 119). The ampullæ measure from 2 mm. to 2.5 mm. in length; they are thicker and less translucent than the rest of the canals, and nearly fill their bony cases, the (membranous) ampullæ being nearly three times the diameter of the canals. That part of each which is towards the concavity of the semicircle of the canal is free; whilst the opposite portion is fixed to the wall of the bony canal; in the ampulla this part is flattened and receives branches of nerves and blood-vessels, and on its inner surface is a transverse projection (*septum transversum*) which partly divides the cavity into two, and broadens out somewhat at either end. The most prominent part of the septum, which is surmounted by the auditory

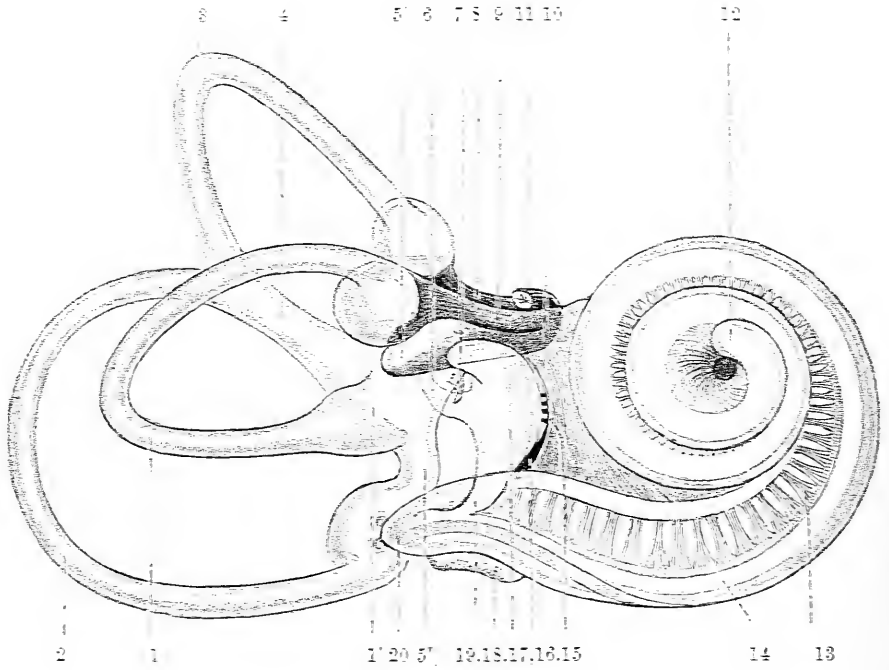


Fig. 117.

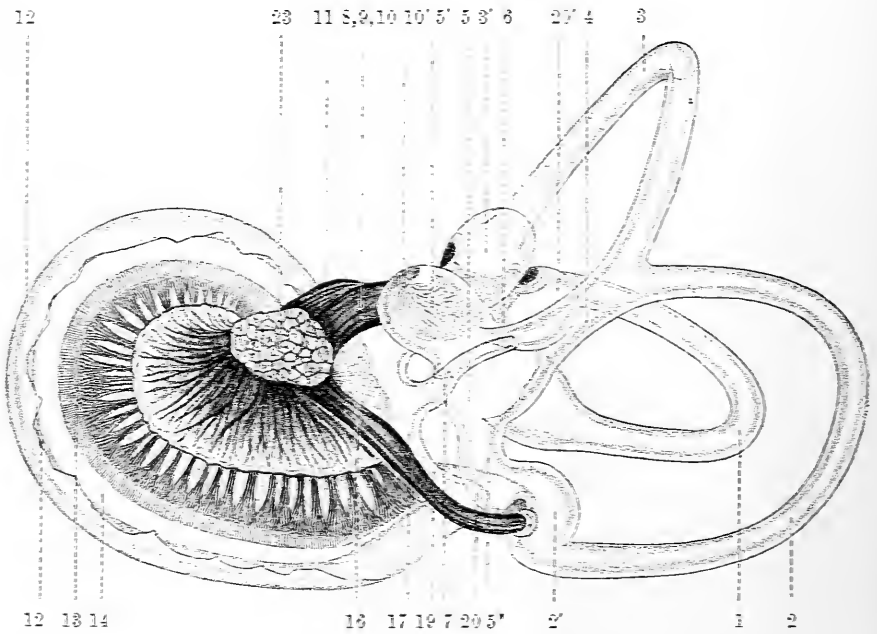


Fig. 118.

Fig. 117.—RIGHT HUMAN MEMBRANOUS LABYRINTH, REMOVED FROM ITS BONY ENCLOSURE, AND VIEWED FROM THE ANTERO-LATERAL ASPECT. (G. Retzius.)

Fig. 118.—THE SAME FROM THE POSTERO-MESIAL ASPECT. (G. Retzius.)

1, external semicircular canal: 1', its ampulla: 2, posterior canal: 2', its ampulla: 3, superior canal: 3', its ampulla: 4, conjoined limb of superior and posterior canals: sinus utriculi superior: 5, utricle: 5', recessus utriculi: 5'', sinus utriculi posterior: 6, ductus endolymphaticus: 7, canalis utriculo-saccularis: 8, nerve to ampulla of superior canal: 9, nerve to ampulla of external canal: 10, nerve to recessus utriculi (in fig. 117, the three branches appear conjoined): 10', ending of nerve in recessus utriculi: 11, facial nerve: 12, lagena cochleæ: 13, nerve of cochlea within spiral lamina: 14, basilar membrane: 15, nerve fibres to macula of saccule: 16, nerve to ampulla of posterior canal: 17, saccule: 18, secondary membrane of tympanum: 19, canalis reuniens: 20, blind ending of cochlear canal in vestibule: 21, outer wall of cochlea: 22, spiral ligament: 23, section of the seventh and eighth nerves within internal auditory meatus (the separation between them is not apparent in the section).

epithelium, is termed the *crista acustica*. Seen from above (*i.e.*, through the roof of the ampulla), the septum is somewhat fiddle-shaped, the ends being broader than

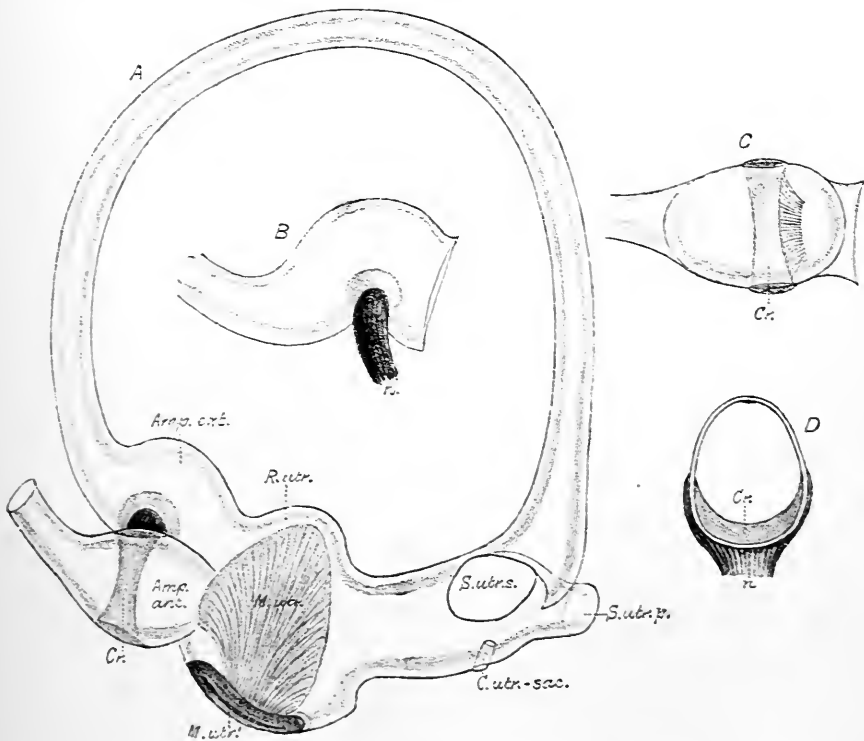


Fig. 119.—VIEWS OF THE EXTERNAL SEMICIRCULAR CANAL, HUMAN. Magnified. (G. Retzius.)

A, The whole of the external canal attached to the utricle, the anterior and posterior canals having been cut away. *Amp.ext.*, ampulla of the external canal: *Amp.ant.*, ampulla of the anterior canal: *Cr.*, crista acustica of the same: *R.utr.*, recessus utriculi: *S.utr.s.*, sinus utriculi superior, cut short: *S.utr.p.*, sinus utriculi posterior, ditto: *C.utr.sac.*, canalis utriculo-saccularis: *M.utr.*, fibres passing to macula recessus utriculi: *M.utr'*, the same passing round the wall of the utricle.

B, Lateral view of the external ampulla; *n*, nerve bundle entering crista.

C, View of external ampulla, showing the free surface of the crista acustica, *Cr.*

D, Transverse sectional view of the external ampulla, showing the transverse extent of the crista, *Cr.*; *n*, nerve fibres.

the middle; and beyond each rounded end of the crista is a crescent-shaped edge (covered by columnar epithelium) which has been termed *planum semilunatum* (fig. 119, C. D.).

Branches of the eighth nerve.—Within the internal auditory meatus the eighth nerve divides into two branches, which, broken up into minute filaments, pass through perforations in the plate of bone which separates the meatus from the internal ear, and are distributed respectively to the cochlea and vestibule. In both branches, as well as in the trunk, there are numerous nerve-cells. The *superior division* (fig. 118, 8, 9, 10), which is at first also anterior in position (*ramus anterior* of Retzius), and is separated by a crest of bone from the other division below it, gives off three branches, which proceed respectively to the utricle and the ampullæ of the superior and external semicircular canals, entering the vestibular cavity in a group

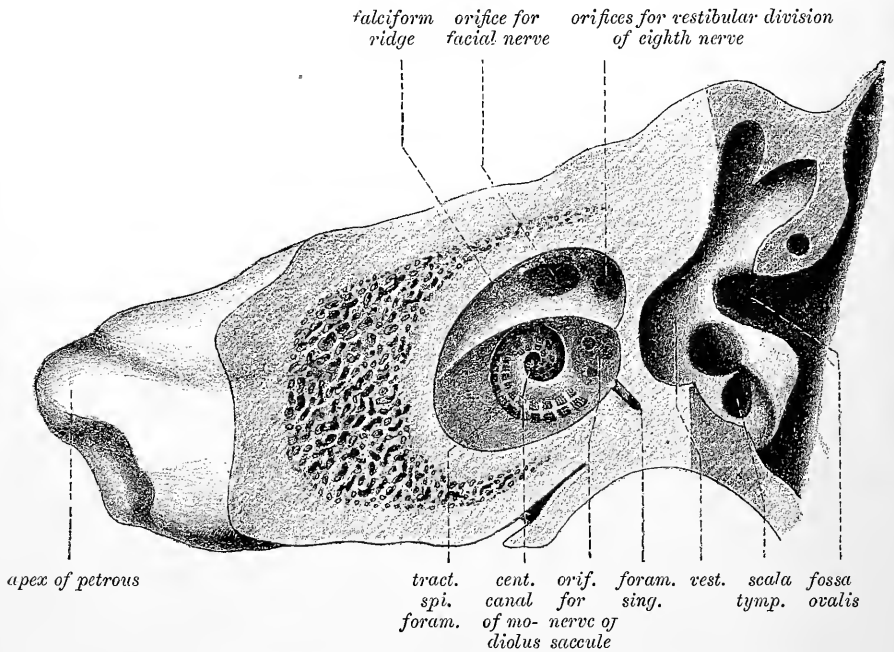


Fig. 120.—THE PETROSAL SAWN THROUGH IN TWO PLANES, SO AS TO SHOW THE EXTREMITY OF THE INTERNAL AUDITORY MEATUS AND THE VESTIBULE. (Testut.)

along the crista vestibuli. This superior division has a ganglion upon it whilst still within the internal auditory meatus (*ganglion of Scarpa*) and the ganglion-cells also extend for some distance along the branches within the canals in the bone. The *inferior division* on the other hand (*ramus posterior* of Retzius) (*l*), which is at first behind as well as below the vestibular division, gives off, besides the cochlear branch which enters the cochlea by the tractus foraminulentus, a branch for the saccule—which enters the vestibule by a small group of foramina, opening at the bottom of the fovea hemispherica—and a branch for the posterior semicircular canal; this is long and slender, and traverses a small passage in the bone (*foramen singulare*) behind the foramina for the nerve of the saccule. The part of the inferior division which gives the branches to the saccule and posterior canal is distinguished by Schwalbe as the *ramus medius*. The branch to the saccule also has a ganglion upon it within the meatus and that to the posterior semicircular canal a ganglion near its ending in the ampulla (*ganglion of Corti*), whereas the

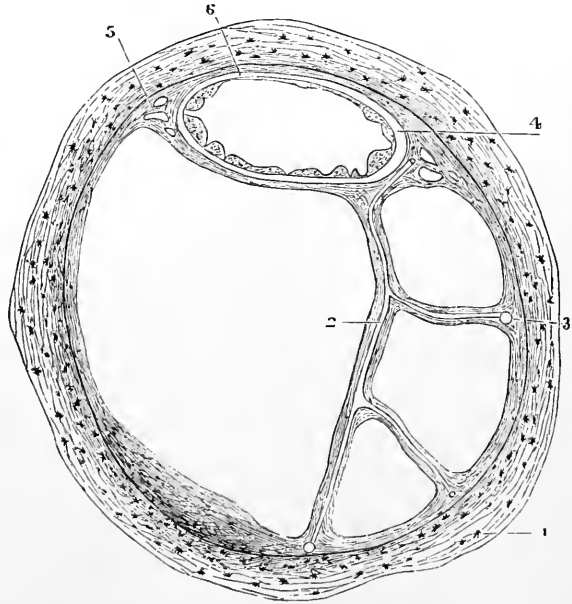
ganglion of the cochlear branch lies within the modiolus, at the base of the spiral lamina (*ganglion spirale*). All the cells of these several ganglia are bipolar. The nerves of the ampullæ enter the flattened or least prominent side of the ampullæ, where they each form a forked swelling, which corresponds with the crista acustica, in the interior of the dilatation.

Vessels of the labyrinth.—The *internal auditory artery*, a branch of the basilar, accompanies the auditory nerve in the internal auditory meatus, and divides into branches for the vestibule and cochlea. Those of the vestibule supply the membranous labyrinth and the endosteum, and small vessels ensheathed by fibrous tissue pass across the cavity containing the perilymph. The blood is chiefly collected into the internal auditory veins which accompany the artery and open into the inferior petrosal sinus, but some is conveyed to the inferior petrosal sinus by fine veins in the aqueductus vestibuli and aqueductus cochleæ. Small arterial branches from the vessels of the dura mater and also from the stylo-mastoid artery, and from vessels of the middle ear, supply the bony walls of the labyrinth, but do not appear to anastomose with the arteries of the membranous labyrinth.

Structure of the utricle, saccule, and semicircular canals.—Three layers can be distinguished in the membranous walls of the semicircular canals, an

Fig. 121.—SECTION OF ONE OF THE HUMAN SEMICIRCULAR CANALS. (Rüdinger.) Magnified.

1, osseous wall; 2, fibrous bands with included blood-vessels, united at 3 with the periosteum; 4, membranous canal with its three layers; 5, short fibrous bands (with intervening spaces) uniting the membranous canal firmly to the periosteum; 6, union of its outermost layer with the periosteum.



outer fibrous stratum, an inner epithelial lining, and between the two a tunica propria. These layers are not of equal thickness throughout, for along the side which is in contact with and supported by the bone (fig. 122, 6), they are thinner than at the rest of the circumference, where

they lie free and are bathed by the perilymph. The difference in thickness affects the fibrous layer and the tunica propria only, for the epithelium forms throughout a lining of simple flattened cells.

The *fibrous layer* (fig. 122, 1), which contains some irregular pigment-cells, is apparently composed of ordinary fibrous tissue, similar to that of the periosteum, with which it becomes continuous at the parts where the two structures are in contact. It is especially developed at the ends of the oval section, whence well-marked bands of fibrous tissue pass to the periosteum (fig. 122, 7). More delicate bands of fibrous tissue traverse the perilymph to become connected with the periosteum of the opposite wall of the canal (fig. 121, 2). Both along these bands and also more directly from the contiguous periosteum, numerous small blood-vessels pass into the

fibrous layer and there break up into a coarse capillary network, the branches of which do not, in man, pass into the tunica propria.

The *tunica propria* is a clear membranous structure continuous around the whole tube, although thinning off very much opposite the part where the membranous canal is in contact with the bone (fig. 122, 5). Externally it is not very distinctly marked off from the fibrous coat: internally it has a number of papilliform eminences (fig. 122, 6,) which project into the interior of the canal except at the thinnest part (Rüdinger).

The *epithelial lining* takes the form of a complete layer of flattened cells, which in the human semicircular canals are of the same nature throughout, except along

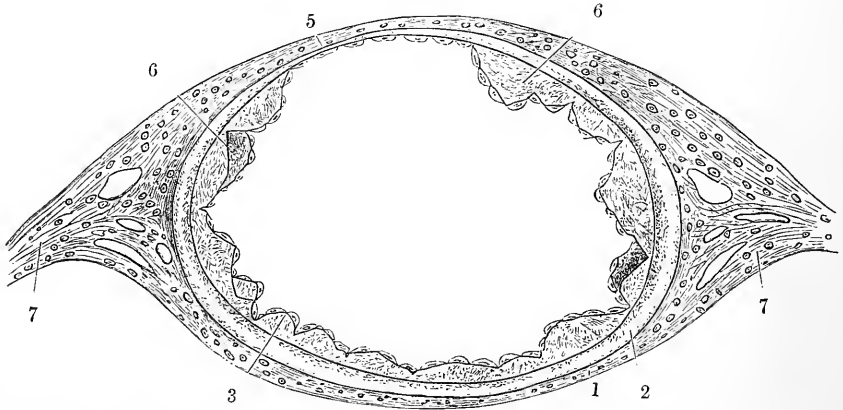


Fig. 122.—SECTION OF MEMBRANOUS SEMICIRCULAR CANAL, MUCH MAGNIFIED. (Rüdinger.)

1, outer fibrous layer; 2, tunica propria; 3, 6, papilliform projections with epithelial covering; 5, fixed side of the canal, with very thin tunica propria without papillae; 7, fibrous bands passing to periosteum.

the outer part of the lumen, where there is a longitudinal tract of cells which are more elongated than the rest. This line is sometimes termed the raphe of the canal.

In many of the lower animals—birds and fishes—some of these lining cells are columnar, while in one species of fish (*Salmo hucho*), as described by Rüdinger, a tract along the whole length of each canal becomes developed into two rows of rounded cells, from each of which a long filament extends to the wall of the canal in a direction transverse to the axis.

The *ampullæ*, as well as the saccule and utricle, agree generally in structure with the semicircular canals: but at the part where they are connected with the osseous wall the fibrous outer layer is looser, and the tunica propria is much thickened, and in the ampullæ projects into the cavity as the *septum transversum* surmounted by the *crista acustica*, before mentioned (fig. 119). Through the substance of this thickening the nerve-fibres pass to the edge of the ridge, and over it the epithelium is of an elongated columnar form (figs. 123 to 126), and is surmounted by long, conical, gradually tapering filaments (auditory hairs (*h*),), which project stiffly into the cavity, and are about 0.03 mm. in length. These hairs are borne by the columnar epithelium-cells (fig. 126), a single hair projecting from each cell, but under the influence of reagents they are apt to become broken near the base, and thus split up into fine fibrils which appear as a bunch of cilium-like filaments attached to the free border of the cell. The columnar cells, or *hair-cells*, do not extend down to the basement membrane, but terminate short of this in a

rounded extremity. They are surrounded by the branching axis-cylinders of the nerve-fibres which penetrate into the epithelium; the medullary sheath disappears

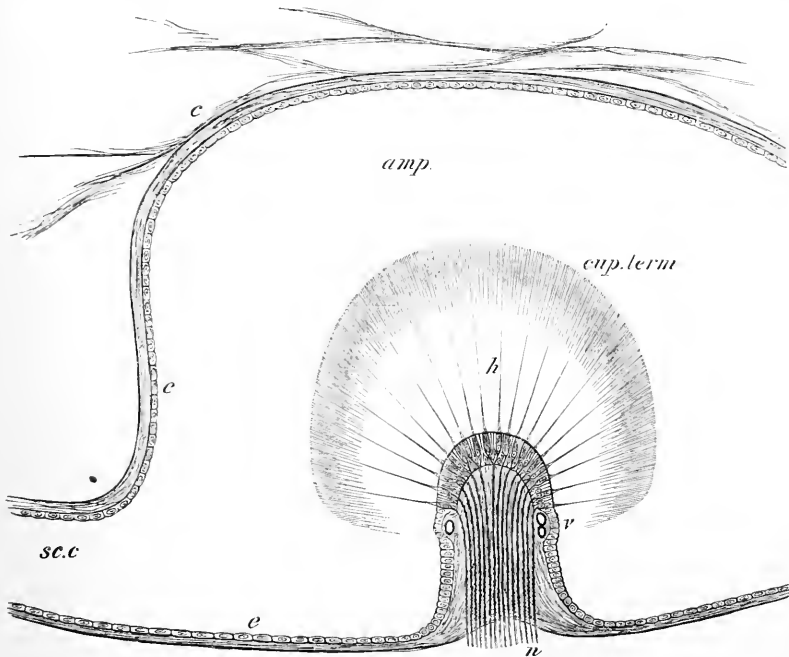


Fig. 123.—LONGITUDINAL SECTION OF AN AMPULLA THROUGH THE CRISTA ACUSTICA.
SEMI-DIAGRAMMATIC (E.A.S.).

amp, cavity of the ampulla; *sc. c*, semicircular canal opening out of it; *e*, connective tissue attached to the wall of the membranous ampulla and traversing the perilymph; *e e*, flattened epithelium of ampulla; *h*, auditory hairs projecting from the columnar cells of the auditory epithelium into the cupula, *cup. term.*; *v*, limit of the auditory epithelium on the crista; *n*, nerve-fibres entering the base of the crista and passing into the columnar cells.

as the fibres enter the epithelial layer, and the axis-cylinders ramify amongst the cells, but there does not appear to be any actual continuity between the terminal arborizations of the nerve fibres (fig. 125) and the hair-cells.

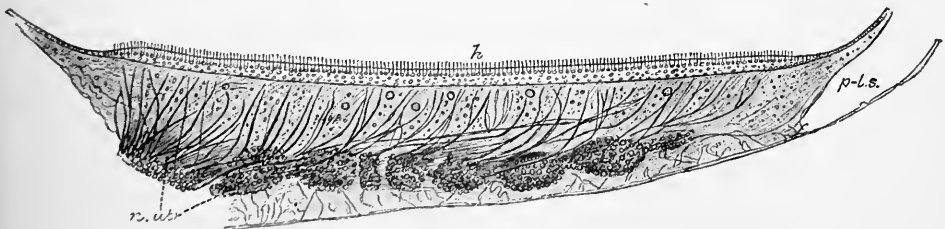


Fig. 124.—SECTION OF THE MACULA ACUSTICA OF THE RECESSUS UTRICULI, HUMAN.
(G. Retzius.) Magnified.

n. utr., bundles of the utricular branch of the eighth nerve; *h*, hair-cells; *p.l.s.*, perilymphatic space.

Between and beneath the columnar cells other cells are met with of a different character. They take the form of long and comparatively rigid fibres (*fibre-cells* of Retzius) which extend through the whole thickness of the epithelium, and are provided at one part of their course with a nucleated enlargement. This is always

placed below the columnar cells, and in many it is close to the central end of the fibre. The fibres, which are probably sustentacular in function, like the fibres

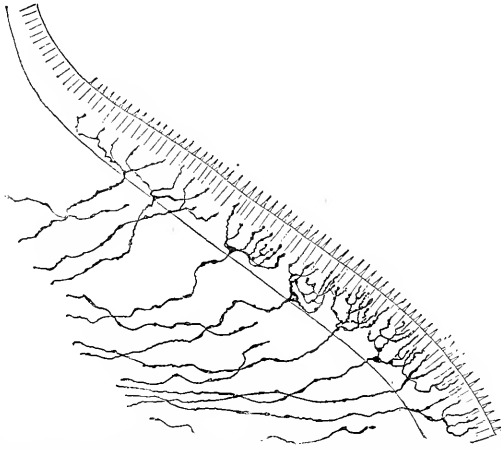


Fig. 125.—NERVE TERMINATIONS IN MACULA ACUSTICA, SHOWN BY GOLGI'S METHOD. (G. Retzius.)

of Müller in the retina and the cells of Deiters in the cochlea, expand slightly as they approach the free surface, and appear to become attached to a cuticular structure which encloses the ends of the hair-cells and is thus comparable to the reticular lamina of the cochlea (Urban Pritchard). On the other hand the fibres are set by their central ends upon a limiting membrane which bounds the epithelium next to the tunica

propria, and which appears in section as a fine but well-marked line.

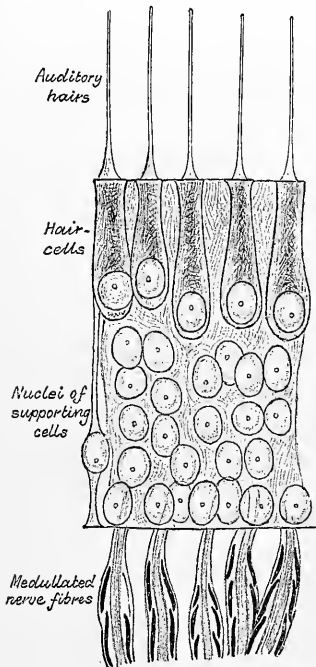


Fig. 126.—SECTION OF EPITHELIUM OF AMPULLA OF LACERTA VIRIDIS. (G. Retzius.) Magnified.

The limit of the auditory epithelium at the sides of the crest is sometimes marked, at least in the human ampullæ, by a prominent vessel (fig. 123, *v*).

The auditory hairs were first noticed by Max Schultze, who described them as being connected with the elongated cells and not with those of a columnar shape. Their true relations were pointed out by Retzius, and in this matter my own observations, in the fish and in man, coincide with his. When the cells are isolated after preservation in osmic acid, the separated columnar cells are alone surmounted by auditory hairs, whereas the elongated intermediate cells are not provided with auditory filaments. It is worthy of note that the auditory hairs do not in sections made from hardened specimens appear to project freely into the endolymph of the ampulla, but into a soft material which takes a dome-like shape (*cupula terminalis*, Lang), and appears to possess an indistinctly fibrillar structure. If this material is pre-existent (and not merely, as some have supposed, produced by a swelling and alteration of the auditory hairs after death), it is not possible to imagine that the hairs can be set in vibration singly, but whatever movements are communicated to the endolymph, must affect the whole cupula and all the hairs embedded in it.

The foregoing description of the characters of the epithelium and mode of nerve-distribution in the cristæ acusticæ of the ampullæ, is equally applicable to the maculæ acusticæ of the saccule and utricle. The nerves which are supplied to the maculæ seem, however, to spread out more than those to the ampullæ. The auditory hairs are somewhat shorter than those of the ampullæ. As before mentioned, both saccule and utricle contain in their cavity and lying in contact with the nerve-epithelium a little mass of otoliths, which, however, do not float free in the fluid, but appear imbedded in a soft matrix which is perhaps enclosed in a delicate cuticular investment. Otoliths are also found scattered here and there in the ampullæ and semicircular canals.

The **membranous cochlea**, which occupies the spirally-wound tube of the osseous cochlea consists like this of about two and three-quarter turns, which

may be termed respectively the *basal*, *middle*, and *apical*, the last-named being incomplete. The total length of the tube is about 35 mm. In structure it resembles the membranous semicircular canals just described in consisting of a tube, lined by epithelium and containing endolymph, partly surrounded by a clear space containing perilymph, but it differs from them both in shape and in the modifications presented by its epithelial lining. In macerated specimens, the two parts into which the osseous tube of the cochlea is divided are, it will be remembered, only imperfectly separated by the osseous spiral lamina which projects from the columella; but in the fresh specimen the tube is separated completely into three distinct parts by means of two membranes, which extend along its whole length (figs. 127 to 129). In the first place the lamina spiralis is directly prolonged by a comparatively strong, well-marked membrane, the *basilar membrane*, which stretches straight across to the outer wall of the cochlea, and is here connected to an inward

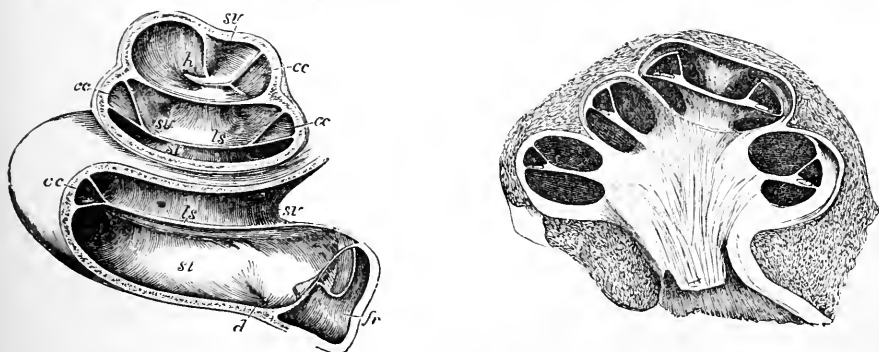


Fig. 127.—LEFT COCHLEA OF A CHILD SOME WEEKS OLD (Reichert). ♀

The drawing was taken from a specimen which had been preserved in alcohol, and was afterwards dried; a section is made so as to show the lamina spiralis, scalæ, and cochlear canal in each of the three coils: the membranous spiral lamina is preserved, but the appearances connected with the organ of Corti, &c., have been lost from drying. *fr*, fossula of the fenestra rotunda. The secondary membrane of the tympanum is seen at the bottom of the fossula attached below to a bony projection of the lower wall (crista semilunaris, to the right of *d*); *st*, scala tympani; *sv*, scala vestibuli. In the lowermost turn the scala tympani is seen to be the larger: in the higher turns the proportions are reversed; *ls*, lamina spiralis; *h*, hamulus; *cc*, canalis cochlearis; *d*, opening of the aqueductus cochlearis.

Fig. 128.—VERTICAL SECTION OF THE COCHLEA OF A FŒTAL CALF (Kölliker). ♀

In this specimen the external wall was ossified, but the modiolus and spiral lamina was still cartilaginous; the section shows in each part of the cochlear tube the two scalæ with the intermediate canalis cochlearis and lamina spiralis.

projection of the lining periosteum and sub-periosteal tissue known as the *spiral ligament*. The basilar membrane thus helps to complete the upper¹ limit of the scala tympani but does not, properly speaking, enter into the lower boundary of the scala vestibuli, for a second, much more delicate membrane, known as the membrane of Reissner, passes from the upper part of the lamina a little distance from its end, and stretches obliquely upwards and outwards, also to become connected with the lining periosteum. The oblique direction of the membrane of Reissner causes a triangular space to be shut off between it and the basilar membrane, which is bounded externally by the outer osseous wall of the cochlea lined by periosteum; and this space, extending throughout the whole length of the osseous tube, and lined throughout by an epithelium variously modified in different parts, is known distinctively as *the canal of the cochlea*, *canalis membranaceus*,

¹ To avoid repetition it may here be stated that for convenience sake the cochlea is considered in the present description as having its larger part or base lowermost, and the domed extremity uppermost, although of course this is far from being the relative position of the parts whilst within the body. Moreover, parts nearer the columella are spoken of as *inner*; parts nearer the external wall as *outer*.

or *ductus cochlearis* (fig. 127, *cc* ; figs. 128, 129). It terminates in a blind extremity at the apex (*lagena*),¹ and another at the base. That at the apex, extending

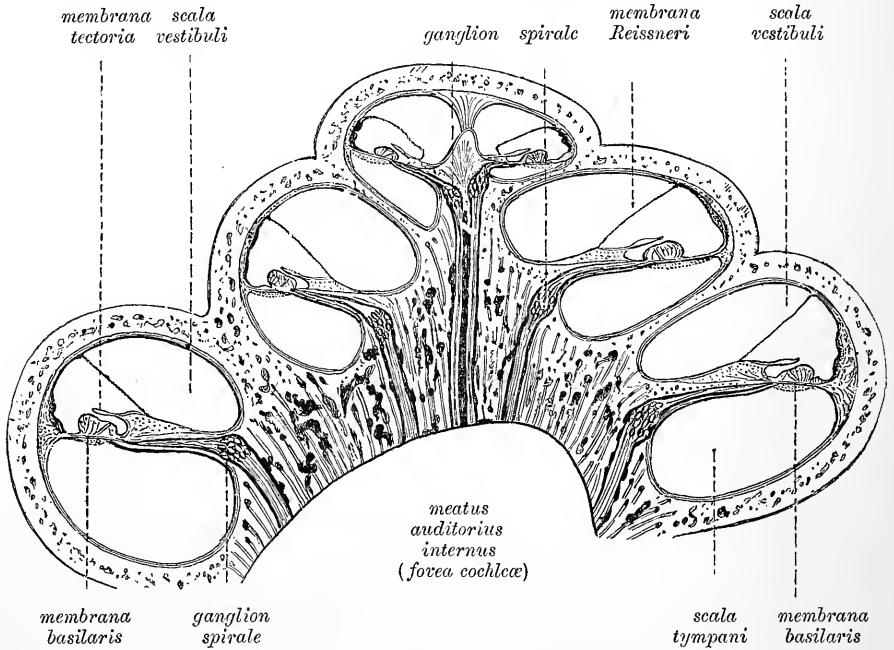


Fig. 129.—SECTION THROUGH THE MIDDLE OF THE COCHLEA, DIAGRAMMATIC. (E. A. S.)

beyond the hamulus, is fixed to the wall of the cupola, and partly bounds the helicotrema ; that at the base fits into the angle at the commencement of the osseous

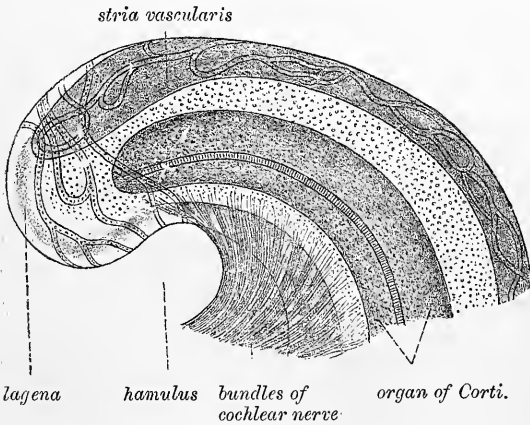


Fig. 130.—APEX OF COCHLEAR CANAL. (Retzius.)

spiral lamina in front of the floor of the vestibule. Near to this blind extremity the canal of the cochlea receives a small canal, lined with epithelium, *canalis reuniens* (Hensen), which is continued from the saccule of the vestibule like a neck of a flask, and enters the canal of the cochlea abruptly nearly at a right angle (figs. 117, 118, 19). The cavity of the canal of the

cochlea is thus rendered continuous with that of the saccule. The structures which are found upon the *floor* of this spirally-wound triangular canal of the cochlea claim more particular attention, for it is to them that the branches of the cochlear nerve are distributed, and upon them the function of the cochlea as a part of the auditory apparatus appears more especially dependent.

¹ In monotremes and in birds, reptiles, amphibia, and fishes, there is a specially modified patch of auditory epithelium at the lagena, similar to the maculæ of utricle and saccule, and provided with otoliths. In fishes this is the only nerve-terminal apparatus in the cochlea, which is also otherwise quite rudimentary.

The floor itself of the cochlear canal is formed of a narrow portion of the spiral lamina external to the membrane of Reissner, and of the basilar membrane. In the macerated specimen this part of the lamina thins off gradually to a fine edge like the blade of a knife, but in the recent condition (fig. 129) it retains its thickness for some distance (or even exhibits a slight increase), and then abruptly terminates with a border which in section is C-shaped, with the lower limb of the C (*labium tympanicum*) much more prolonged and tapering than the upper (*labium vestibulare*). The lower limb is in fact the section of the end of the osseous lamina, together with a thin membranous layer which covers it, and which is directly prolonged into the basilar membrane. This membrane, as well as the whole thickened upper part of the edge of the spiral lamina, not being ossified, disappears in the process of maceration. The thickened part (fig. 131, *l*), with its somewhat

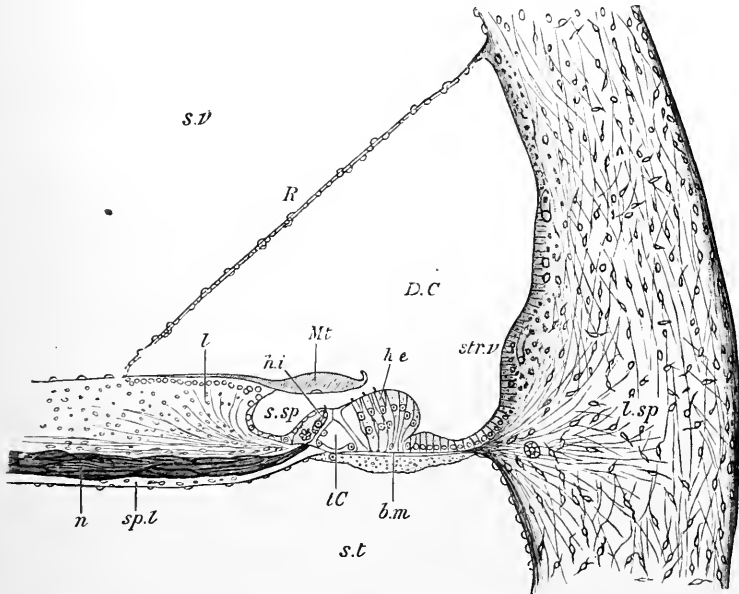


Fig. 131.—SECTION ACROSS THE BASAL TURN OF THE HUMAN COCHLEA. (G. Retzius.) Magnified.

D.C., ductus cochleæ; *s.v.*, scala vestibuli; *s.t.*, scala tympani; *R*, membrana Reissneri; *Mt*, membrana tectoria; *b.m.*, membrana basilaris; *str.v.*, stria vascularis; *l.sp.*, ligamentum spirale; *l*, limbus; *s.sp.*, sulcus spiralis; *t.C.*, tunnel of Corti; *n*, nerve fibres; *s.p.l.*, spiral lamina.

overhanging, crest-like edge, is known as the *limbus* of the spiral lamina, and the groove which it overhangs, and which in section is represented by the bay of the C, is known as the *spiral groove* (fig. 131, *s.sp.*).

The tissue of which the *limbus* is composed seems to be a peculiar form of connective tissue. Towards the under and inner part there are numerous corpuscles, and the texture is fibrous, but above and near the crest few or no connective tissue corpuscles are met with, but the tissue has a columnar aspect with somewhat regularly-arranged nuclei. The fibrillated tissue is prolonged, as just intimated, beyond the osseous lamina, into the basilar membrane. Near its termination, close to the junction with the basilar membrane, it is perforated with a number of regularly-arranged, elongated apertures (fig. 132, *p*), about 4,000 in number, which serve for the transmission of bundles of the nerve-fibres. The latter, in their course from the spiral ganglion to the auditory epithelium, are lodged, as far as this, in canals in the lower osseous part of the spiral lamina. Their arrangement will be afterwards more fully described.

When the limbus is viewed from above, the vestibular edge is seen to present a succession of tooth-like projections (fig. 132, *Cr*), about 7,000 in number altogether, which give it a jagged aspect. These projections are continued as flattened eminences a short distance on the upper surface of the limbus, which is, therefore, not smooth, at least near the edge, but marked in this way with eminences and intervening furrows. Nearer the line of origin of the membrane of Reissner, it becomes smoother, and here, too, its epithelial covering, which is directly continuous with that of the under surface of Reissner's membrane, is evenly distributed; whereas at the crest itself the epithelial cells are columnar in the furrows, but flattened out over the teeth, so as to be invisible here with ordinary methods of preparation. Their outlines can, however, according to G. Retzius, be brought to view by the employment of the silver method. Immediately below the overhanging projections, the epithelium again forms a well-defined layer of cubical or short columnar cells which lines the spiral groove, and is continuous externally with the specialized cells, presently to be described as forming the organ of Corti.

The **basilar membrane** stretches, as before mentioned, straight between the osseous lamina and the spiral ligament, and separates the canal of the cochlea from the

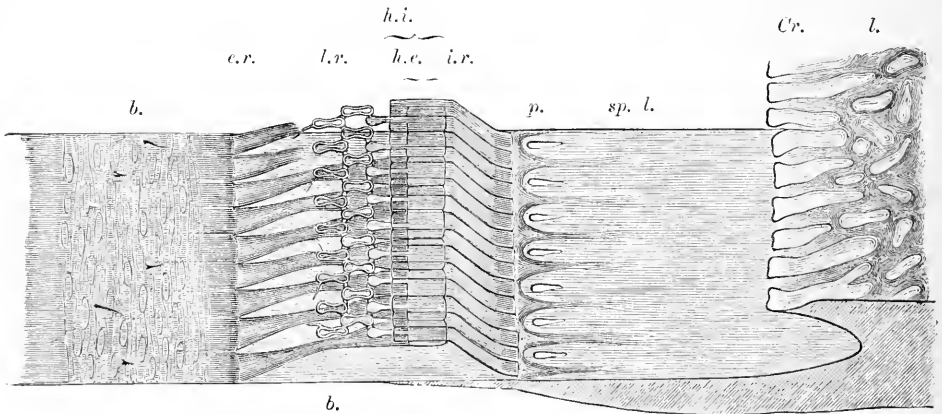


Fig. 132.—SEMI-DIAGRAMMATIC VIEW OF PART OF THE BASILAR MEMBRANE AND TUNNEL OF CORTI OF THE RABBIT, FROM ABOVE AND THE SIDE. Much magnified. (E.A.S.)

l, limbus; *Cr*, labium vestibulare or crest of limbus with tooth-like projections; *b*, basilar membrane; *sp. l.*, spiral lamina with *p*, perforations for transmission of nerve fibres. In the lower half of the part of the spiral lamina here represented the nerve fibres are left, and are supposed to be seen through the upper layer of that lamina, converging to three of the perforations; below, in the section of the lamina, they are shown occupying a canal, or cleft, in the osseous substance; *i. r.*, fifteen of the inner rods of Corti; *h. i.*, their flattened heads seen from above; *e. r.*, nine outer rods of Corti; *h. e.*, their heads, with the phalangeal processes extending outward from them and forming, with the two rows of phalanges, the lamina reticularis, *l. r.* On the left of the figure the connective tissue fibres and nuclei of the undermost layer of the basilar membrane are seen through the upper layers. Portions of the basilar processes of the outer hair-cells remain attached here and there to the membrane at this part.

scala tympani. It increases in breadth, at first rapidly but afterwards more gradually, from the base to the apex of the cochlea, while the breadth of the osseous spiral lamina diminishes. At the lowest part of the cochlea, where this membrane occupies the narrow cleft between the lamina spiralis ossea and the lamina secundaria, the breadth is only about 0.041 mm.; but towards the apex of the cochlea it increases at the expense of the bony lamina, until, near the helicotrema, the membranous part is left almost unsupported by any plate of bone, measuring as much as 0.495 mm., or about twelve times as much as at the base (Hensen). The *average* measurements given by Retzius are, for the first or basal turn 0.21 mm.; for the middle turn 0.34 mm.; and for the apical turn 0.36 mm. Its total breadth averages, according

To go opposite p. 116.]

In the description of fig. 132 the words "In the lower half — in the osseous substance," are to be omitted ; and in the last line of the description the words "cells of Deiters" are to be substituted for "outer hair-cells."



to Retzius, 33.5 mm. The basilar membrane is usually described as showing two zones, viz., the *zona arcuata*, which is the part upon which the rods of Corti stand, and the *zona pectinata*, extending from the feet of the outer rods to the spiral liga-

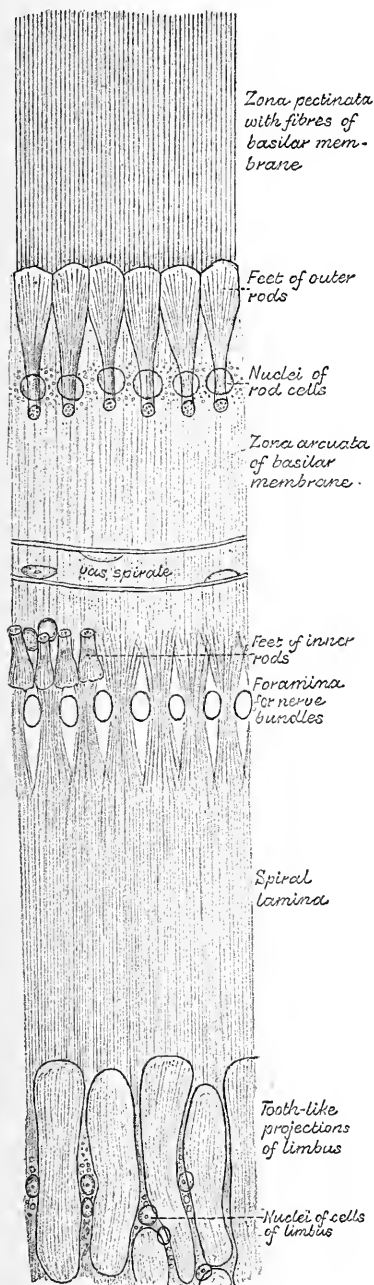


Fig. 133.—BASILAR MEMBRANE AND LIMBUS VIEWED FROM ABOVE. Magnified. (G. Retzius.)

ment, the latter zone being somewhat thicker and much more distinctly fibrous. The proper substance of the membrane appears to be formed of a homogeneous ground-substance containing nuclei embedded in it here and there, and having straight fibres (running radially from the spiral lamina to the external spiral ligament) embedded in it, so that the membrane, especially its outer part, presents a marked striation when viewed on the surface (fig. 133). Externally, at its attachment to the spiral ligament, it breaks up into diverging fibres, which spread into that projection. In a section of the membrane across the direction of its fibres the latter appear as fine points enclosed by the homogeneous



Fig. 134.—TANGENTIAL SECTION ACROSS THE ZONA PECTINATA OF THE BASILAR MEMBRANE OF THE GUINEA-PIG. (Schwalbe.) Highly magnified.

ground-substance (fig. 134). In chemical nature they resemble elastic fibres but are rather less resistant to alkalis and most other reagents. It has been calculated by Retzius that there are altogether as many as 24,000 of these fibres in the human *membrana basilaris*, but they do not all run singly, some being grouped together. On the upper surface of the membrane is the epithelium which forms the organ of Corti, continued laterally by a single layer of cells (fig. 131): a delicate cuticular layer which is seen in section is perhaps formed by this epithelium. On the under surface the membrane is covered by a layer of connective tissue (often described as part of the membrane), the fibres of which have a direction parallel with the spiral, and across that of the fibres of the membrane proper. There are numerous intermixed spindle-shaped corpuscles in this tissue, which is in continuity with the lining periosteum of the *scala tympani* (fig. 134). Small blood-vessels

are found in it, but as a rule extending only over the inner part of the membrane. They are usually terminated by a rather larger longitudinally running vessel, situated opposite the outer rods of Corti, and known as the *vas spirale* (fig. 136).

The **membrane of Reissner** (fig. 129, 131, *R*), separates the scala vestibuli from the canal of the cochlea. It is composed of an exceedingly delicate layer of connective tissue continuous with the lining periosteum of the scala vestibuli, and is covered on the surface, which is turned to the cochlear canal with a simple pavement epithelium which is in continuity below with the epithelium of the limbus and above with that lining the outer wall of the canal. The cells have each a circular flattened nucleus, and not unfrequently contain fat-droplets. The vestibular side of the membrane of Reissner is quite smooth, and is covered with an epithelial layer of flattened connective-tissue cells, distinguishable from the epithelial cells on the other side by their greater delicacy of outline, and their larger size. A few blood-capillaries are continued into the adjacent part of the membrane from the neighbouring periosteum.

Outer wall of the cochlear canal.—The periosteum which lines the scala vestibuli and scala tympani, consists of ordinary connective tissue. There is no con-

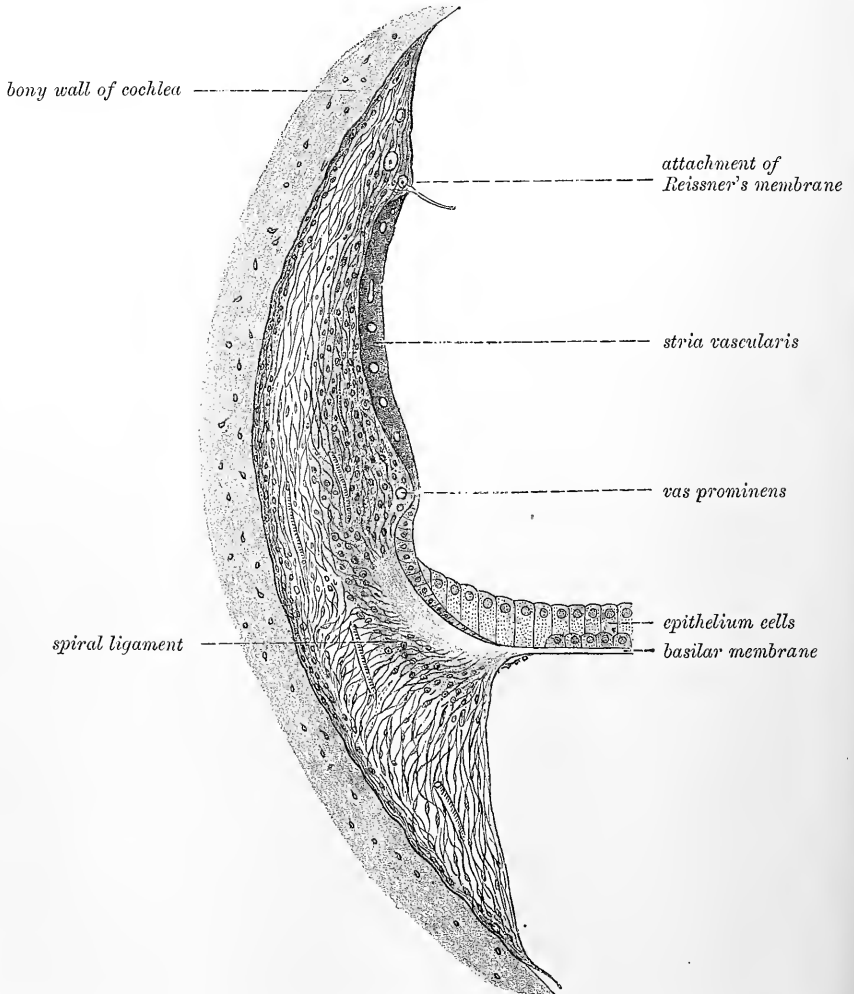


Fig. 135.—SECTION SHOWING THE STRUCTURE OF THE LIGAMENTUM SPIRALE AND ADJACENT PARTS, FROM THE GUINEA-PIG'S COCHLEA. (Schwalbe.) ¹³⁹/₁

tinuous lining of flattened cells on the free surface, such as covers the surface of serous membranes. On the other hand the periosteum which bounds the canal of

the cochlea externally, is much thickened by a development of retiform connective tissue, and is covered by the epithelium of that tube, which here forms a single layer of columnar cells, which contain pigment, and are prolonged by forked or arborescent processes into the subjacent connective tissue. There is usually a slight inward projection a little above the spiral ligament, containing a prominent blood-vessel (figs. 131, 135). In the tract between this prominence and the membrane of Reissner, the substance of the periosteum is also frequently pigmented, and from containing large and numerous blood-vessels, the capillary loops of which may even project between the bases of the epithelium-cells, is termed *stria vascularis*. Immediately beneath the epithelium of the outer wall is a basement membrane, through which, in section, the cell-processes above mentioned may be seen passing from the epithelium into the subjacent connective tissue.

The **spiral ligament** (fig. 131 *l.sp.*, fig. 135) appears in section as a triangular prominence attached to the outer wall of the cochlea, with the basilar membrane prolonged from its apex. It is composed of a retiform connective tissue, many of the cells of which have an elongated shape and radiate from the point of attachment of the basilar membrane. They have been considered by some to be muscular, but there is no distinct proof of their contractile nature.

Organ of Corti.—The epithelium which covers the basilar membrane includes

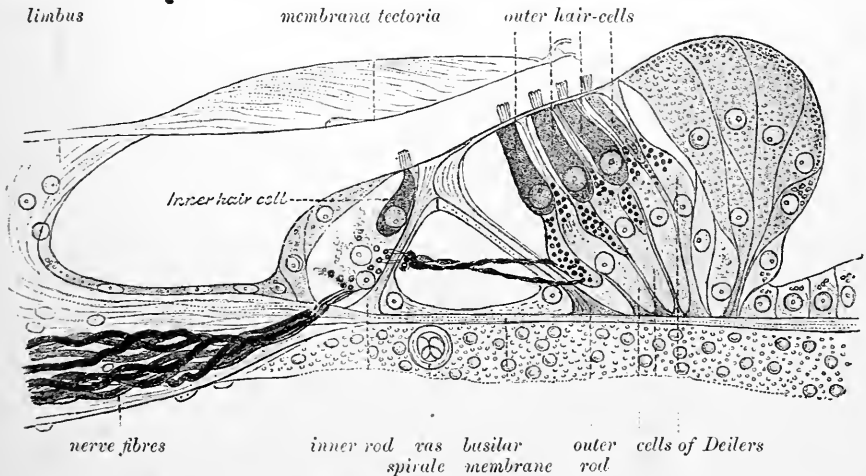


Fig. 136.—SECTION THROUGH THE ORGAN OF CORTI OF THE MIDDLE TURN OF THE HUMAN COCHLEA. (G. Retzius.) Highly magnified.

the highly-specialised structures which are known by the name of the **organ of Corti** (fig. 136). The central part of this apparatus is formed by two sets of stiff, rod-like bodies—the inner and outer rods of Corti (fig. 132)—which stand upon the basilar membrane, the outer series (*e.r.*), at some little distance from the inner (*i.r.*), and are inclined towards each other, coming in contact above. In this way each pair of rods forms a pointed arch with slanting sides (fig. 137), and since the rods of each series are in lateral juxtaposition, the double row of inclined columns forms a tunnel (fig. 132) along the whole extent of the cochlear canal.

On the inner side of the inner series of rods is a row of epithelial cells (fig. 136), which are surmounted by a brush of fine, short, stiff hairlets, and external to the outer rods are three or four successive rows of similar but more elongated cells. These cells are termed respectively the *inner* and *outer hair-cells*. The hairlets of the outer hair-cells project through apertures in a curiously formed cuticular membrane, termed the *reticular lamina* (fig. 132, *l.r.*, 140), which covers this part of

the organ of Corti like a wire net. The hairlets of the inner hair-cells are $1\frac{1}{2}$ times as long as those on the outer hair-cells (Retzius). On either side of the two sets of hair-cells, the epithelium, becoming gradually shorter, passes continuously into the simple layer of cubical cells which is found in the spiral groove and on the lateral part of the basilar membrane.

The whole organ is further covered by a thick, fibrillated membrane—the *tectorial membrane* (fig. 131, *Mt*)—which is attached at one edge to the upper surface of the limbus, falls over the crest, and rests on the rods of Corti and the hair-cells, thus converting the spiral groove into a canal. It will be necessary to describe more minutely these several parts of the organ of Corti.

Rods of Corti.—The inner and outer rods of Corti differ from one another in shape, although agreeing, for the most part, as regards the details of their structure.

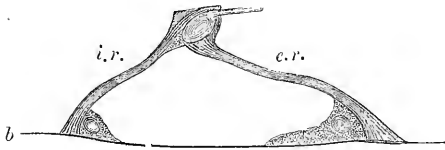


Fig. 137.—A PAIR OF RODS OF CORTI, FROM THE RABBIT'S COCHLEA, SIDE VIEW. (E.A.S.) Highly magnified.

b b, basilar membrane; *i.r.*, inner rod; *e.r.*, outer rod. The nucleated protoplasmic masses at the feet are also shown.

Each inner rod may be best compared in shape to a human ulna, the upper end of the rod being pretty accurately represented by the upper extremity of that bone, the

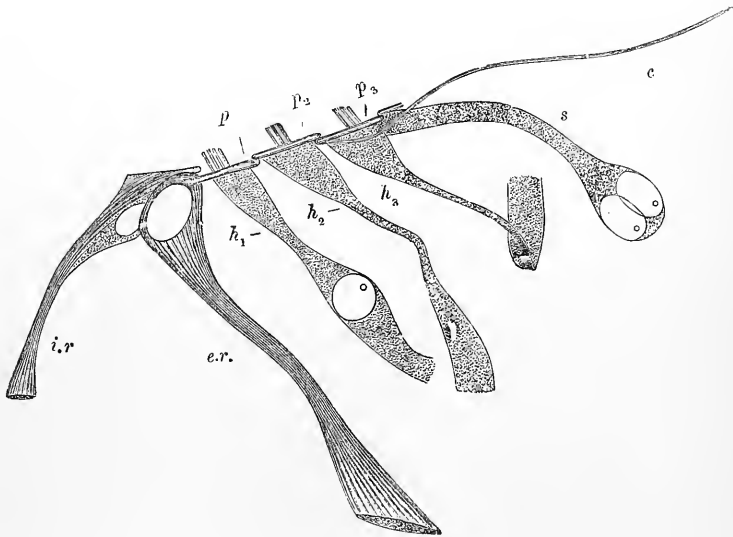


Fig. 138.—TEASED PREPARATION SHOWING AN INNER AND AN OUTER ROD IN CONNECTION WITH THREE HAIR-CELLS, AND PART OF THE LAMINA RETICULARIS (FROM THE GUINEA-PIG). (E.A.S.) Very highly magnified.

i.r., inner rod; *e.r.*, outer rod; *h₁*, *h₂*, *h₃*, hair-cells of first, second, and third rows respectively. They appear, especially the second and third, narrow in the middle, the thin edge of the ribbon-shaped cell being here seen, but below have become accidentally twisted so that the flattened side is brought into view. A nucleus is visible in *h₁*, but none is seen in *h₂*, *h₃*, probably owing to its being contained in the part of the cell the edge of which is turned towards the observer. The lower ends of all three have become broken in the preparation of the specimen; *s*, one of the succeeding epithelial cells (cell of Hensen); *c*, cuticular thread attached to lamina reticularis, belonging to a cell of Deiters; *p*, phalangeal process of outer rod; *p₁*, *p₂*, *p₃*, phalanges of lamina reticularis seen in section.

shape of the olecranon and coronoid processes, as well as the concave articular surface between, being readily recognisable. The upper end of each of the outer rods, on the

other hand, somewhat resembles the outline of a swan's head; the rounded part, which represents the back of the head, fitting into the concave surface on the head of the corresponding inner rod or rods, while the part which represents the bill projects outwards and is connected with the reticular lamina, aiding to form the first series of rings for the transmission of the auditory hairlets. Both inner and outer rods are more slender about the middle of their length and expand again below, so as to rest upon the basilar membrane by a somewhat widened foot. They are distinctly striated throughout their length (fig. 138).

In the head of the outer rod is an oval part free from fibres, and staining with carmine more deeply than the remainder of the rod (pseudo-nucleus). A similar, but smaller clear body, staining deeply with carmine, is seen in the head of the inner rod, and the substance of the rod in its neighbourhood has a somewhat granular appearance (fig. 138).

The inner rods are more numerous than the outer;¹ they are also more closely set and touch one another along their whole length, whereas the outer rods are only in contact laterally by their heads; finally the outer rods are in all parts longer than the inner, and in the upper turns of the cochlea considerably so.

How the two sets of rods are jointed together is not very clear. It is certain that the individual rods have little, if any, independent movement; they are securely fixed below to the basilar membrane, and the heads of adjacent rods are in close contact.

Basilar cells.—In connection with both inner and outer rods, there is seen a protoplasmic cell occupying the angle which the rod makes with the plane of the basilar membrane (figs. 136, 137). Sometimes these cells extend along the membrane until they come into contact, and they may, especially in young subjects, be seen to rise up and partly envelope each rod. They are usually regarded as the cells by and from which the rods have been formed.

Hair-cells and cells of Deiters.—The *inner hair-cells*, some 3,500 in number in all, are closely applied against two or three of the corresponding rods, the cells being considerably larger in diameter than the rods. Seen from above they are oval and marked by a curved line, which is the line along which the hairlets are attached (fig. 140, *i.h.*) They are very like somewhat short, columnar epithelium-cells, and are prolonged below into a process (which may be branched) by which they are connected with the upper surface of the spiral lamina. Beneath them, and extending also under the gradually decreasing columnar epithelium of the spiral groove, is a layer of protoplasmic cells with large round nuclei, amongst which fine nerve-fibres appear to run in a spiral direction. Around the top of each inner hair-cell is a sort of ring of cuticular substance, which is connected with slight projections on the flattened heads of the inner rods, and perhaps represents the reticular lamina in this place.

The *outer hair-cells* are peculiar in shape. They are cylindrical at the upper end, where they fit into the rings of the reticular lamina and bear the hairlets, but lower down they are flattened from within out, so that, in profile, they look narrow, but broader when seen on the flat (fig. 138). These cells end below with a rounded extremity (fig. 136), extending about as far as to the narrowing part of Deiters' cells. The hairlets, as with the inner cells, are about 20 in number on each cell, and spring also from a curved line on the upper surface of the cell. Beneath the hair-cells and resting by a broad base upon the basilar membrane, certain other cells are found which are known as the *cells of Deiters* (fig. 136). These, which are of a cylindrical-

¹ According to Retzius there are altogether in the human cochlea about 5,600 of the inner rods and nearly 4,000 of the outer ones.

conical shape, rest by their bases upon the basilar membrane, and each one encloses in its substance a cuticular filament which is fixed below to that membrane. This filament is prolonged above in the tapering apex of the cell, between the hair-cells and in close contact with one of them, and is attached above to, or rather expands to form, one of the so-called phalanges of the reticular lamina: it is known as the *phalangeal process* of Deiters' cell. This cuticular filament may probably be regarded as the equivalent of the rod of Corti, the cell of Deiters to which it belongs being looked upon as representing the protoplasmic cell which lies at the foot of each rod of Corti, and in the young subject encloses the rod.

Hensen has described a clear oval capsule with a spiral fibre wound around it, occupying the part of the hair-cell next to the free extremity.

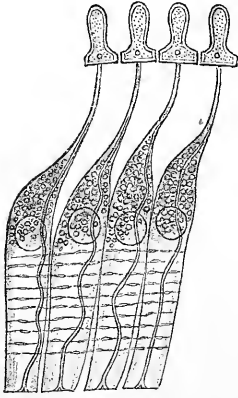


Fig. 139.—FOUR CELLS OF DEITERS, FROM THE RABBIT. (Modified from G. Retzius.) Highly magnified.

The phalangeal processes are shown, each expanding to form a phalanx of the reticular lamina. The varicose lines are spirally running nerve-fibrils.

In most animals there are three series of outer hair-cells, but in man there are four series except in the lowermost turn (fig. 136, *h*) and even five and six in the upper turns of the cochlea (Pritchard); but where they are more numerous they tend to be somewhat irregularly placed and intermittent. There are about 12,000 outer hair-cells and 20 hairlets to each cell in the human cochlea (Retzius). The columnar cells outside the hair-cells are much elongated and obliquely disposed, but become gradually shorter and more vertical as they pass into the simple cubical epithelium on the outer part of the basilar membrane.

Spaces filled with endolymph are seen both in the inner and outer hair-cell region and communicate between the rods of Corti with the tunnel-space. The largest of these secondary spaces lies between the outer rods and the first row of outer hair-cells (Nuel). (See fig. 136.)

The cells which immediately succeed the hair-cells form in some animals a distinct swelling or arch outside the hair-cell region, from which and from the basilar membrane they may be separated by a considerable space occupied by endolymph. In the guinea-pig they contain a considerable number of fat globules in the upper turns of the cochlea. They are sometimes known as the "cells of Hensen," whilst those which follow them and rest on the lateral half of the basilar membrane have been termed "cells of Claudius."

Lamina reticularis (figs. 132, 140).—The net-like membrane which overlies the outer hair-cell region of the organ of Corti is composed of at least two rows of elongated fiddle-shaped structures termed "phalanges" which are united to one another and to the phalangeal processes of the outer rods in such a manner as to leave between them oblong apertures through which the free ends of the hair-cells with their semicircular rows of auditory hairs project. The phalanges, although they seem like rings, are in reality thin plates with thickened margins, and are to all appearance of a cuticular nature: the most external row of phalanges is in continuity with a cuticular tissue which lies between the external epithelium cells. Attached to the phalanges below are the phalangeal processes of the cells of Deiters (fig. 139). The lamina varies in extent with the number of rows of hair-cells. Where there are four or more of these, a corresponding increase in the number of rows of cells of Deiters and of phalanges is observed. The phalanges serve to isolate the hair-bearing ends of the auditory cells.

The **tectorial membrane** is the last special structure which remains to be described in connection with the organ of Corti. It arises, as before stated, on the limbus, not far from the line of origin of Reissner's membrane (fig. 131). It overlies the projecting teeth at the edge of the limbus, and also the epithelium between them: all this part of the membrane is thin and delicate, imperceptibly

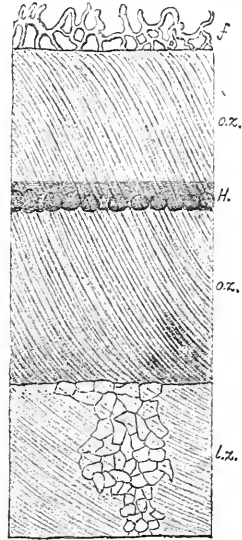
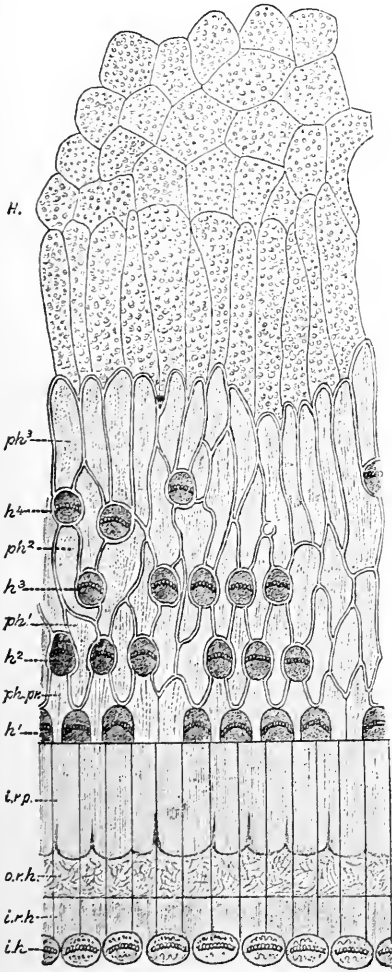


Fig. 140.—VIEW OF A SMALL PART OF THE ORGAN OF CORTI OF THE HUMAN COCHLEA FROM ABOVE, SHOWING THE LAMINA RETICULARIS. Much magnified. (G. Retzius.)

i.h., inner hair-cells, the hairlets being seen in section; *i.r.h.*, heads of inner rods; *o.r.h.*, heads of outer rods; *i.r.p.*, "olecranon" processes of inner rods; *ph.pr.*, phalangeal processes of outer rods; *ph¹, ph², ph³*, first, second, and third series of phalanges; *h¹, h², h³, h⁴*, first, second, third, and fourth series of outer hair-cells; *H.*, cells of Hensen.

Fig. 141.—SURFACE VIEW OF A SMALL PIECE OF THE MEMBRANA TECTORIA OF THE HUMAN COCHLEA. (G. Retzius.)

l.z., limbus-zone of the membrane, showing markings caused by the cells covering the limbus; *o.z.*, *o.z.*, outer zone, showing a well-marked fibrous structure; *H.*, stria described by Hensen in the middle of the outer zone; *f.*, reticular free border.

shading off towards the inner edge of attachment. As the membrane projects over the crest of the limbus, it swells out below into a pad-like projection (fig. 136) which covers in and partly fills up the spiral groove, and rests below upon the rods of Corti and contiguous structures. Towards its external edge the membrane again thins out, and overlies the outer hair-cell region as a delicate film presenting a somewhat reticular appearance, as if impressed by or moulded on the subjacent structures. The thickened part of the membrane is distinctly fibrous in appearance (the fibrillation extending obliquely from within out) (fig. 141), and after immersion in weak solutions of omic acid, chromic acid, or bichromate of potash, it appears to possess considerable toughness and elasticity. From its position the hairlets borne by the hair-cells must necessarily be in contact with the under surface of this

membrane. In its situation relative to the auditory epithelium it corresponds to the otolithic accumulations of the maculæ.

Nerves of the cochlea.—The branch of the auditory nerve which goes to the cochlea is given off in common with those to the saccule and the posterior ampulla.

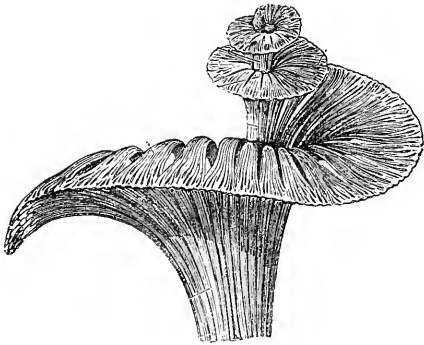


Fig. 142.—GENERAL VIEW OF THE MODE OF DISTRIBUTION OF THE COCHLEAR NERVE, ALL THE OTHER PARTS HAVING BEEN REMOVED. (Arnold.)

It is shorter, flatter, and broader than any of the other branches. It perforates the bone by groups of minute foramina at the bottom of the internal meatus, below the opening of the Fallopiian aqueduct. These groups are arranged in a shallow spiral furrow (tractus spiralis foraminulentus) in the centre of the base of the cochlea; and they lead into small bony canals, which first follow the direction of the axis of the

cochlea, through the modiolus, and then radiate outwards, between the plates of the the bony spiral lamina (fig. 129). In the centre of the spiral tract is a larger foramen which leads to the central canal of the modiolus. Through this foramen and canal the

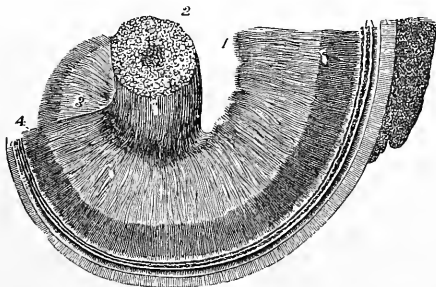


Fig. 143.—DISTRIBUTION OF THE COCHLEAR NERVES IN THE SPIRAL LAMINA. (After Henle.)

This figure shows part of the modiolus and spiral lamina, viewed from the base, showing the plexiform arrangement of the cochlear nerves; 1, filaments of the nerve issuing from the tractus spiralis foraminulentus; 2, branches of the nerve entering the central canal of the modiolus; 3, wide plexus in the bony lamina spiralis; 4, close plexus at its border.

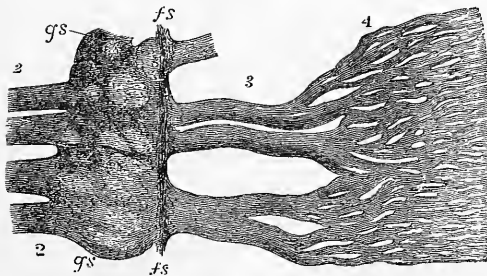


Fig. 144.—PART OF THE NERVES EXTRACTED AND MORE HIGHLY MAGNIFIED.

2, twigs of the nerve from the modiolus close to the lamina spiralis ossea; *gs*, spiral ganglion; *fs*, nerve-fibres running spirally along the outer part of the ganglionic swelling 3, wide plexus; 4, close plexus of nerve-fibres as in fig. 143.

occupy the smaller foramina and bent canals. Near the root of the spiral lamina the nerve-fibres pass outwards through a spirally wound ganglionic cord (*ganglion spirale*), situated in the special bony canal (*spiral canal of the modiolus*) already mentioned. The cells of this ganglion are bipolar and each nerve-fibre appears to have one of the cells interpolated in its course. From the outer side of the ganglion, the fibres, having resumed their medullary sheath, pass onwards with a plexiform arrangement, at first in distinct but anastomosing cords (fig. 144, 3),

filaments for the last half-turn of the spiral lamina are conducted; whilst the first two turns are supplied by the filaments which

contained in separate canals in the bony lamina, but afterwards spreading out into a stratum of intermingling fibres, to be again gathered up, near the edge

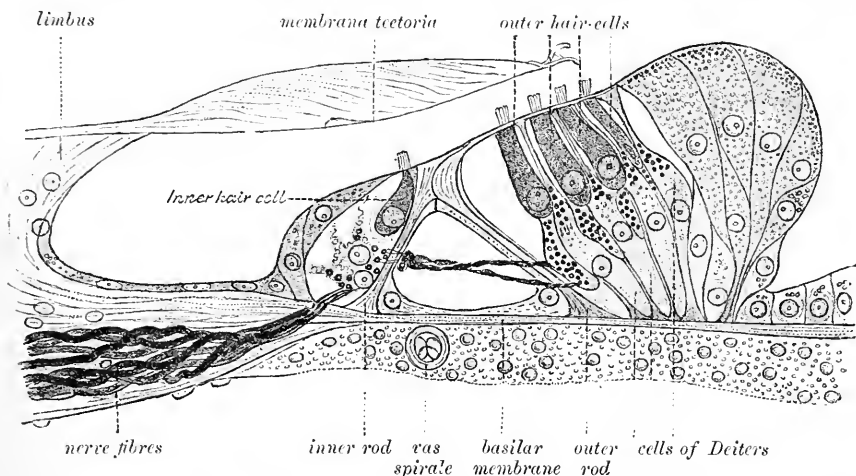


Fig. 145.—SECTION THROUGH THE ORGAN OF CORTI OF THE MIDDLE TURN OF THE HUMAN COCHLEA. (G. Retzius.) Highly magnified.

of the osseous lamina, into conical bundles which turn abruptly upwards, and passing through the elongated apertures previously described (p. 112 and fig. 132, *p*),

Fig. 146.—ENDING OF NERVE-FIBRES IN THE COCHLEA, SHOWN BY GOLGI'S METHOD. (G. Retzius.) Much magnified.

g, a cell of the spiral ganglion; *i.h.*, inner hair-cells; *o.h.*, outer hair-cells, with the nerve-fibres running spirally between the cells.



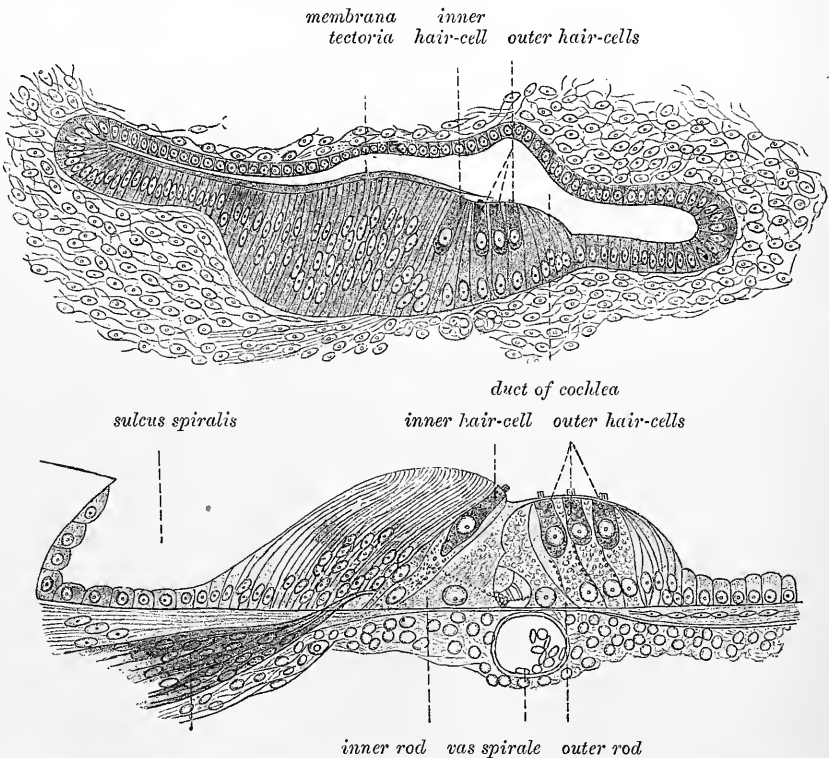
lose their medullary sheath, and enter the epithelium in the region of the inner hair-cells (fig. 145). Some of the nerve-fibres appear to end here by ramifying with a spiral course amongst the bases of the inner hair-cells, but others are continued as fine threads between the inner rods, and form a second spiral band close to the outer side of these and in contact with the protoplasmic cell which ensheaths them. Other fibres may be seen in sections to pass across the tunnel of Corti between the rods and to enter the region of the outer hair-cells. Here the fibres, which now again branch and alter their direction, run spirally parallel with the successive series of hair-cells. They rest against the corresponding cells of Deiters, and in man form a bunch of spirally-running fibres immediately below the expanded part of each hair-cell (fig. 145). They form, therefore, altogether five or six spiral strands of fibrils, which lie between the epithelium-cells of the organ

of Corti. In most animals they are less grouped together and more distributed along the length of each cell of Deiters (fig. 139), but with the same spiral arrangement and in the same relative position.

Vessels of the cochlea.—The branches of the internal auditory artery to the cochlea, twelve or fourteen in number, arising at the bottom of the internal auditory meatus, traverse small canals in the modiolus and bony lamina spiralis, and also pass to the outer wall of the cochlea, forming at the root of the septum, between the turns of the cochlear tube a spirally-arranged glomerulus-like arterial plexus, which sends vessels to the subjacent stria vascularis and to the periosteum lining the adjacent scalæ (Schwalbe). From this plexus offshoots are distributed in the form of a fine network on the periosteum, but the vessels do not anastomose across the membrana basilaris. The bony cochlea also receives through the fenestra rotunda a twig from the stylomastoid branch of the occipital artery.

The veins of the cochlea issue from the grooves of the cochlear axis, and join the veins of the vestibule and semicircular canals at the base of the modiolus. A small sinus-like vein passes through the aqueductus cochleæ, from the lowermost turn of the cochlear tube, and joins the commencement of the internal jugular vein.

Development of the organ of Corti.—The organ of Corti is at first composed of columnar epithelium-cells forming part of the layer of epithelium which



Figs. 147 and 148.—TWO STAGES IN THE DEVELOPMENT OF THE ORGAN OF CORTI OF THE CAT. (G. Retzius.)

† In the preparation represented in fig. 147 the hair-cells are differentiated; in that shown in fig. 148 the rods of Corti are also beginning to be formed, and the nerve-fibres have reached the organ of Corti, and are already running spirally below the hair-cells.

lines the whole of the membranous labyrinth. After a time certain of these cells begin to be differentiated and become distinguishable from the rest as the inner and

outer hair-cells. Subsequently the rods of Corti become formed by a transformation of the protoplasm of other of these columnar cells, and the cells of Deiters also begin to appear. In the meantime the epithelium of the vascular stria which was at first similar to that of the rest of the canal becomes pigmented and vascularized, and the remaining epithelium of the cochlear canal is also gradually acquiring the form and character by which its various parts are distinguished.

The membrana tectoria appears to be formed as a cuticular deposit or secretion from the epithelial cells of the limbus, upon which, even at a comparatively early stage of development, it may be seen to lie.

Measurements of some of the parts of the cochlea.—The following numbers (from Retzius) show the average dimensions of various parts of the human cochlea, and represent the size in micromillimeters.

Cochlear canal, breadth, basal turn	0.45
" " " middle "	0.77
" " " apical "	0.80
" " " extreme length	35.00
Reissner's membrane, breadth, basal turn	0.81
" " " middle "	0.88
" " " apical "	0.85
Limbus laminae spiralis, breadth, basal turn	0.24
" " " " middle "	0.23
" " " " apical "	0.22
Rods of Corti, space between attachment of feet, basal turn	0.048
" " " " " " " middle "	0.081
" " " " " " " apical "	0.09
" " " " " " " height of arch, basal turn	0.028
" " " " " " " middle "	0.045
" " " " " " " apical "	0.049
" " " " " " " length of inner rods	0.048—0.07
" " " " " " " length of outer rods	0.06—0.1
Hair-cells, length of inner	0.018—0.024
" " " " " " " length of outer	0.03—0.04
" " " " " " " length of hairlets	0.005
Membrana tectoria, breadth	0.28—0.34
" " " " " " " extreme thickness	0.025
Basilar membrane, breadth from habenula perforata to lig. spirale, basal turn	0.21
" " " " " " " " " middle "	0.34
" " " " " " " " " apical "	0.36
" " " " " " " " " breadth from habenula perforata to feet of outer rods, basal turn	0.075
" " " " " " " " " " " " middle "	0.12
" " " " " " " " " " " " apical "	0.126

RECENT LITERATURE OF THE EAR.

- Altzheimer, A.**, *Ueber die Ohrschmalzdrüsen*, Würzburg, 1888.
- Ayers, Howard**, *Die Membrana tectoria—was sie ist, und die Membrana basilaris—was sie verrichtet*, Anatomischer Anzeiger, vi. 1891; *Ueber das peripherische Verhalten der Gehörnerven*, Anat. Anz., 1893.
- Baginsky, G.**, *Zur Entwickl. der Gehörschnecke*, Arch. f. mikr. Anat., xxviii. 1886.
- Barth, A.**, *Beiträge zur Anatomie des Ohres*, Zeitschrift für Ohrenheilkunde, Band xvii.; *Ueber die Darstellung des häutigen Labyrinthes*, Archiv für Anatomie und Physiologie, Physiol. Abt., Jahrg. 1889; *Beitrag zur Anatomie der Schnecke*, Anatomischer Anzeiger, iv. 1889.

- Beauregard, H.**, *Recherches sur l'appareil auditif chez les mammifères*, Journal de l'anat., 1893.
- Bertelli, D.**, *Contribuzione à la structure de la couche moyenne de la membrane tympanique chez le cobaye*, Archives italiennes de biologie, xvi, 1891.
- Binder, Das Morelsche Ohr**, Eine psychiatriisch-anthropologische Studie, Archiv für Psychiatrie, Band xx.
- Bistrzycki, A., und von Kostanecki, K.**, *Das Gewicht menschlicher Gehörknöchelchen*, Monatsschrift für Ohrenheilkunde, xxv, 1891.
- Boettcher, Rückblicke auf die neueren Untersuchungen ü. d. Bau der Schnecke, im Anschluss an eigene Beobachtungen**, Arch. f. Ohrenheilkunde, xxiv, 1886.
- Bryant, W. S.**, *Observations on the topography of the normal human tympanum*, Arch. Otol., New York, 1890.
- Bulle, Hermann**, *Beiträge zur Anatomie des Ohres*, Archiv für mikroskop. Anatomie, Band xxix.
- Bürkner, Kurd**, *Atlas von Beleuchtungsbildern des Trommelfells*, 1890.
- Chiarugi, G.**, *Il tubercolo di Darwin e la direzione dei peli nel padiglione dell'orecchio umano*, Bollett. d. r. acc. d. fisioerit. di Siena, anno vi, 1888.
- Coggi, Alexander**, *Ueber die sog. Kalksäckchen an den Spinalganglien des Frosches und ihre Beziehungen zum Ductus endolymphaticus*, Anatomischer Anzeiger, v, 1890.
- Draispul, Zur Entwicklungsgeschichte des Hammer-Ambos-Gelenkes; Ueber die Membrana propria des Trommelfelles**, Verhandlungen des x. internationalen medicinischen Kongresses zu Berlin, 1890.
- Dreyfuss, Beitr. z. Entwicklungsgesch. des Mittelohres u. des Trommelfelles**, Morph. Arbeiten, Bd. ii., 1893.
- Eichler, Oswald**, *Anatomische Untersuchungen über die Wege des Blutstromes im menschlichen Ohrlabrynth*, Abhandl. d. math.-phys. Kl. d. kgl. Sächs. Ges. d. Wiss., No. v, 1892.
- Ellis, H. H.**, *The ear in criminals*, The Lancet, 1890.
- Engelmann, Th. W.**, *Ueber die Function der Otolithen*, Zoolog. Anzeiger, Jahrg. x., Nr. 258.
- Fick, A.**, *Betrachtungen über den Mechanismus des Paukenfells*, Archiv für Ohrenheilkunde, Band xxiv.; and Würzb. Verhandl. xx, 1886.
- Fischer, Ferdinand**, *Ueber das Epithel und die Drüsen der Ohrtrumpete und Paukenhöhle*, Inaug.-Dissert., Rostock, 1889.
- Gradenigo, Die Entwicklung der Ohrmuschel beim Menschen und bei den Säugethieren**, Zeitschrift für Ohrenheilkunde, Band xix.; *Die Formentwicklung der Ohrmuschel mit Rücksicht auf die Morphologie und Teratologie derselben*, Centralblatt für die medicin. Wissenschaften, 1888; *Beitrag zur Morphologie des Annelix der menschlichen Ohrmuschel*, Zeitschrift für Ohrenheilkunde, Band xxi., 1891; *A contribution to the morphology of the human auricle*, New York, 1891; *Missbildungen der Ohrmuschel*, Arch. f. Ohrenheilkunde, Bd. xxxiv., 1893.
- Hasse, C.**, *Ue. d. Gefäße in d. lamina spiralis membranacea des Gehörorganes*, Anat. Anzeiger, i, 1886.
- His, Wilhelm**, *Zur Anatomie des Ohrläppchens*, Archiv f. Anat. u. Physiol., Anat. Abtlg., 1889.
- Kaiser, Otto**, *Das Epithel der Cristae und Maculae acusticae*, Archiv für Ohrenheilkunde, xxii., 1891.
- Katz, L.**, *Beitrag zur Frage über die Verbindung der Corti'schen und Deiter'schen Zellen des Corti'schen Organes und deren Gestalt*, Monatsschrift für Ohrenheilkunde, Jahrg. 1888; *Ueber die Epithelgebilde des Corti'schen Organes*, Archiv für Ohrenheilkunde, Band xxvii.; *Ueber die Endigung des Nervus Cochleae im Corti'schen Organ*, Zeitschrift für Ohrenheilkunde, Band xxix, 1889-90; *Histologisches ueber den Schneckenkanal, speziell die Stria vascularis, mit Demonstration mikroskopische Präparate*, Verhandlungen des x. internationalen medicinischen Kongresses zu Berlin, 1890; and Archiv für Ohrenheilkunde, Band xxxi., 1890; *Ueber einige Streitpunkte in der Histologie des Gehörganges*, Verhandlungen des x. internat. medic. Kongresses, Berlin, 1890; *Mikrophotographischer Atlas der normalen und pathologischen Anatomie des Ohres*, Berlin, 1891, 1892.
- Kirchner, W.**, *Ueber Divertikelbildung in der Tuba Eustachii des Menschen*, Festschrift zu von Kölliker's 70. Geburtstage.
- Kostanecki, C.**, *Die pharyngeale Tubenmündung und ihr Verhältniss zum Nasenrachenraum*, Archiv für mikroskopische Anatomie, Band xxix.
- Larsen, P. C.**, *Ein anatomisch-physiologischer Beitrag zur Lehre von den Ossicula auditus*, Anatomischer Anzeiger, v, 1890.
- Lenhossék, M.**, *Die Nervenendigungen im Gehörorgans*, Verhandl. d. anat. Gesellschaft, Anat. Anz., viii., 1893; *Die Nervenendigungen in den Maculae u. Cristae acusticae*, Anat. Hefte. ix., 1893.
- Linsmayer, L.**, *Ein Fall von Verknöcherung der Ohrmuscheln*, Wiener klinische Wochenschrift, 1889.
- Niemack, J.**, *Maculae u. Cristae acusticae mit Ehrlich's Methyltenblaumethode*, Anatom. Hefte, 1892.
- Prénant, A.**, *Recherches sur la paroi externe du limaçon des mammifères et spécialement sur la strie vasculaire*, Internationale Monatsschrift für Anatomie und Physiologie, ix, 1892.
- Randall, B. A., and Morse, H. L.**, *Photographic illustrations of the anatomy of the human ear, together with pathological conditions of the drum membrane and descriptive text*, Philadelphia, 1887.
- Rauber, Ueber d. Bau des Gehörlabyrinthes**, Sitzungsab. d. naturf. Gesellsch. z. Leipzig, xii, 1886.
- Retzius, G.**, *Das Gehörorgan der Wirbelthiere*, Stockholm, 1884; and in Biolog. Unters., vols. iii. & v., 1892 & 1893.

Rüdinger, N., *Über die Abflusskanäle der Endolymphe des inneren Ohres*, Sitzungsber. d. k. bayer. Akad., 1887; *Zur Anatomie und Entwicklung des inneren Ohres*, Monatsschrift für Ohrenheilkunde, xxii. 1888; *Über die Beziehung der Neuroepithelstellen der beiden Säckchen zu den Schall-leitungsweegen im Labyrinth*, Münchener medicin. Wochenschrift, xxxv. 1888; *Zur Entwicklung der häutigen Bogengänge des inneren Ohres*, Sitzungsberichte der mathem.-physikal. Klasse der k. b. Akademie der Wissensch. zu München, 1888; *Über die Deckmembran der Maculae acusticae der Säckchen des häutigen Labyrinths*, Sitzungsberichte der Gesellschaft für Morphologie u. Physiologie in München, v. 1889.

Schaeffer, O., *Ueb. d. foetale Ohrentwicklung, &c.*, Arch. f. Anthrop., xxi., 1892.

Schwalbe, G., *Ein Beitrag zur Kenntniss d. Circulationsverhältnisse in der Gehörschnecke*, Ludwig-Festschrift, 1886; *Lehrbuch der Anatomie der Sinnesorgane*, Erlangen, 1887; *Über die vergleichende Anatomie u. Entwicklungsgeschichte des Ohrknorpels*, Deutsche medicinische Wochenschrift, Jahrg. xv. 1889; *Inwiefern ist die menschliche Ohrmuschel ein rudimentäres Organ?* Archiv f. Anatomie u. Physiol., Anatom. Abt., 1889; *Das Darwin'sche Spitzohr, &c.*, Anat. Anzeiger, iv., 1889; and Arch. f. Psychiatrie, xxi., 1889; *Über Auricularhöcker bei Reptilien, ein Beitrag zur Phylogenie des äusseren Ohres*, Anatomischer Anzeiger, vi. 1891; *Beiträge zur Anthropologie des Ohres*, Festschrift f. Virchow, Bd. i.

Schroeder, J. K., *Unters. ü. d. Blutgefäss-system des äusseren Ohres*, Jena, 1893.

Siebenmann, Friedrich, *Die Korrosions-Anatomie des knöchernen Labyrinths des menschlichen Ohres*, Wiesbaden.

Steinbrügge, H., *On the Cupula-formations in the human labyrinth*, Arch. of Otolgy, New York, xvi. 1887; *Über d. Verhalten d. menschl. Ductus cochlearis im Verhofblindsack*, Anat. Hefte, 1893.

Symington, J., *The external auditory meatus in the child*, Journal of Anatomy, xix., 1885; *Demonstration of auditory air-passages*, Journal of Anatomy, vol. xxiii. 1888.

Tartaroff, Dimitry, *Über die Muskeln der Ohrmuschel und einige Besonderheiten des Ohrknorpels*, Archiv für Anatomie u. Physiologie, Anatom. Abt., 1887.

Voltolini, U. d. *Gehörzähne der Schnecke des Menschen u. der Säugethiere u. deren Gefässe*, Arch. f. path. Anat., Bl. civ., 1886.

Zuckerkandl, E., *Beitr. zur vergl. Anatomie d. Ohrtrompete*, Arch. f. Ohrenheilkunde, xxiii. 1886.

THE NOSE.

THE nose is the special organ of the sense of smell. It has also other functions to fulfil:—for, communicating freely with the cavities of the mouth and lungs, it is concerned in respiration, voice, and taste; and by means of its muscles it assists in expression.

The nose forms a prominence composed of bone and hyaline cartilage with certain muscles, and a general covering of integument. At its lower extremity or base the nostrils (anterior nares) open downwards. Its upper end is the *root*, the rounded or flattened ridge along its middle is termed the *dorsum*, and this ends below in the *point* of the nose. The upper or bony part of the dorsum is often spoken of as the *bridge*; it frequently forms an angle with the cartilaginous part (aquiline type). The root springs from below the glabella of the frontal bone, with which it usually forms a more or less marked angle, so that the nose appears to spring from a well-marked groove: if this groove is absent, and the line of the dorsum is continuous with the plane of the forehead, the Grecian type of nose is produced. The sides of the nose, which form an open angle (*naso-facial angle*) with the general anterior surface of the face, diverge from the dorsum at an increasing angle as we trace them down from the root; the nose is therefore broadest below at the nostrils. This lowest part of the lateral wall is slightly bulged outwards, and is separated from the rest by a slight groove; it is known as the *ala* of the nose, and is mobile, its form being capable of alteration by the action of certain muscles, which thereby dilate or contract the nostrils. A median partition (*septum nasi*) divides the interior of the nose into two approximately equal parts, the *right and left nasal fossæ*. These open above and behind into the pharynx by the posterior nares (choanæ), and below on to the exterior by the anterior nares. The septum is composed of bone and cartilage in the greater part of its extent, but at its lower end it is formed only of integument and connective tissue (*septum mobile*, or *columna nasi*). This part of the septum forms the mesial boundary or separation between the anterior nares; in the rest of their extent they are bounded by the curved free margin of the alæ.

From the development and complexity of the nasal fossæ and olfactory lobes of the cerebrum mammals are divided by Turner into the three subdivisions of *macrosmatics*, including rodents, carnivora, marsupials, and most mammals; *microsmatics*, including man and most primates, monotremes, and some cetacea; and *anosmatics*, including certain cetacea (*e.g.*, porpoise).

The nasal fossæ communicate with hollows in the neighbouring bones (ethmoid, sphenoid, frontal, and superior maxillary). The skin of the nose is studded, particularly in the grooves of the alæ or outer walls of the nostrils, with numerous small openings, which lead to sebaceous follicles. Within the margin of the nostrils are a number of short, stiff, and slightly curved hairs—*vibrissæ*—which grow from the inner surface of the alæ and septum nasi.

As is well known the nose presents great variety in size and shape in different individuals. Into most of these it is unnecessary here to enter, but there is one kind of variation which is of considerable anthropological importance, *viz.*, the extent of lateral expansion of the anterior nares as compared with the

total length of the organ. This relationship is expressed by the cephalometric nasal index ($\frac{\text{greatest breadth} \times 100}{\text{length measured vertically}}$). It is found that in the white races of mankind the nasal index is below 70; in the black races (African, Australasian) it is 85 and upwards; in the yellow races (Asiatic, American-Indians, Eskimo) from 70 to 85 (Topinard).

The blood-vessels of the outer nose are branches of the ophthalmic and facial. The lymphatics pass to the submaxillary lymphatic glands. The sensory nerves are branches of the first and second divisions of the fifth, and the motor nerves are derived from the facial. All of these have been already noticed in previous parts of this work.

CARTILAGES OF THE NOSE.

These are the chief support of the outer part of the organ. They occupy the triangular interval seen in front of the nasal cavity in the dried skull (anterior

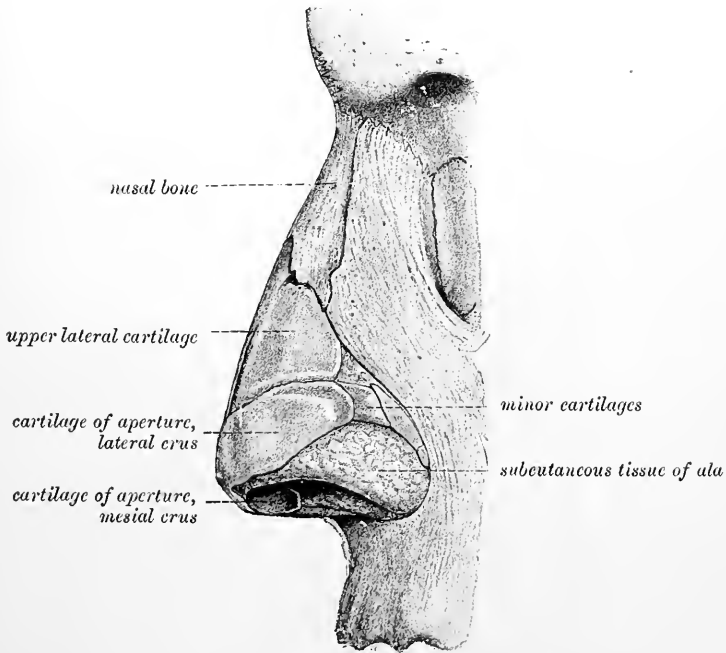


Fig. 149.—LATERAL VIEW OF THE CARTILAGES OF THE NOSE. (Modified from Arnold.)

nasal aperture), and assist in forming the septum between the nasal fossæ. There are two large cartilages, one on each side, partly enclosing the aperture of the anterior nares, and known as the *cartilages of the aperture* or *lower lateral cartilages*, and one winged median cartilage which forms part of the septum nasi, and spreads externally and superiorly into two large flattened expansions which are commonly known as the *upper lateral cartilages*, and may conveniently be described separately, although part of the cartilage of the septum.

The *upper lateral cartilages* (figs. 149 and 150) are situated in the middle part of the projecting portion of the nose, immediately below the free margin of the nasal bones. Each is flattened and triangular in shape, with one surface looking outwards, and the other inwards towards the nasal cavity. The anterior margin,

thicker than the posterior, is united with the edge of the cartilage of the septum above, but is separated therefrom by a small fissure below. The posterior edge is closely attached to the free margins of the upper maxilla and of the nasal bone, and the inferior margin is connected by fibrous membrane with the lower lateral

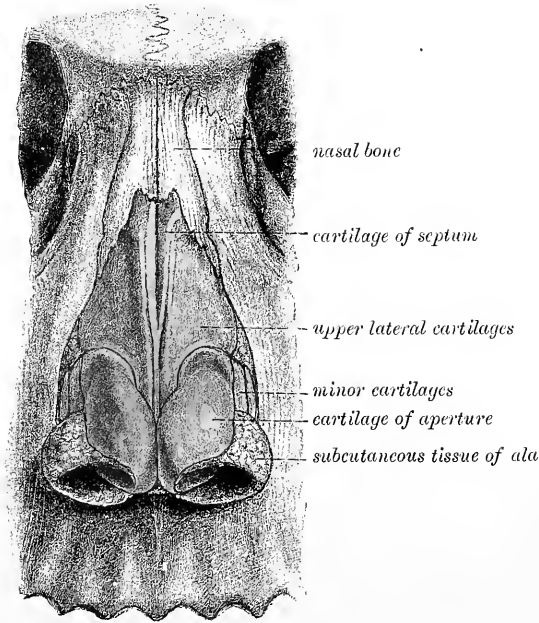


Fig. 150.—FRONT VIEW OF THE CARTILAGES OF THE NOSE. (Modified from Arnold.)

cartilage; and there are often small portions of cartilage (*cartilagine epactiles*) lying in the fibrous tissue in this situation.

The *lower lateral cartilages* or *cartilages of the aperture* (figs. 149, 150, 151) are thinner than the preceding, below which they are placed, and are characterised by their peculiar curved form. Each consists of an elongated plate, so bent upon itself as to pass in front and on each side of the nostril to which it belongs, and by this arrangement serve to keep it open. The outer portion is somewhat oval and flattened, or irregularly convex externally. Behind, it is

attached to the margin of the upper maxilla by tough fibrous membrane, enclosed in which there is usually to be met with either a prolongation backwards of the posterior angle of the cartilage, or two or three separate cartilaginous nodules (*cartilag. minores vel quadratæ*) (figs. 149, 150); above, it is fixed, also by fibrous membrane, to the upper lateral cartilage, and to the lower and fore part of the

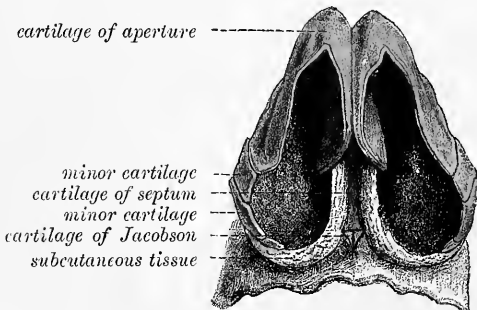


Fig. 151.—VIEW OF THE CARTILAGES OF THE NOSE FROM BELOW. (Modified from Arnold.)

cartilage of the septum. Towards the middle line it is curved backwards (fig. 151), bounding a deep median groove, at the bottom of which it meets with its fellow of the opposite side, and continues to pass backwards, lying in the upper part of the *columna nasi*, below the

level of the cartilage of the septum. This inner part of the cartilage of the aperture is thick and narrow, curls outwards, and ends in a free rounded margin which projects outwards. The ala of the nose, like the lobule of the ear, is formed of thickened skin with subjacent tissue, and is unsupported by cartilage.

The *cartilage of the septum* (fig. 152) is quadrilateral in form, and is thicker at the edges than near the centre. It is placed nearly vertically in the median plane of the nose, but often with an inclination to one or other side, and completes, at the

fore part. the separation between the nasal fossæ. The anterior margin of the cartilage, thickest above, is firmly attached to the back of the nasal bones near their line of junction ; and below this it lies successively between the upper and the lower lateral cartilages, united with the former, which constitute its alæ, and connected loosely by fibrous tissue with the latter. The posterior margin is fixed to the lower and fore part of the central plate of the ethmoid bone (*e*) ; and the lower margin is received into the groove of the vomer (*v*), and rests anteriorly on the incisur crest of the superior maxillæ.

This cartilage is the persistent anterior extremity of the primordial cartilaginous

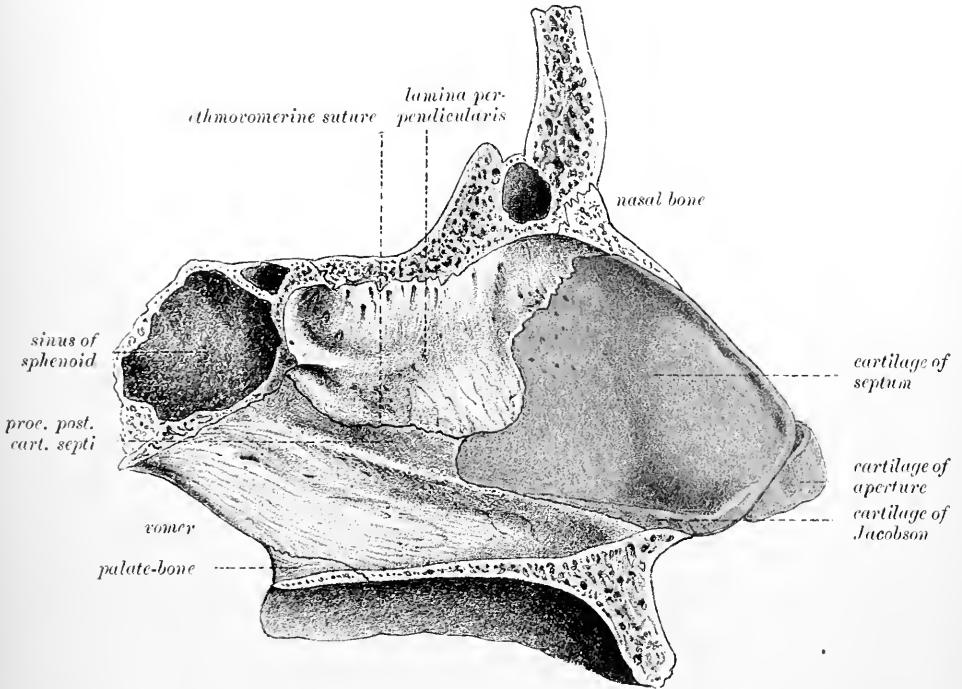


Fig. 152.--OSSEOUS AND CARTILAGINOUS SEPTUM OF THE NOSE, SEEN FROM THE SIDE. (Arnold.)

cranium. In young subjects it is prolonged back to the body of the pre-sphenoid bone ; and in many adults an irregular thin band remains between the vomer and the central plate of the ethmoid (*processus posterior s. sphenoidalis*, fig. 152). The *vomerine cartilages* (Huschke) or *cartilages of Jacobson*, are two small longitudinal strips of cartilage which lie along the lower border of the cartilage of the septum, attached to the vomer. They are not always distinct from the cartilage of the septum and are relatively better developed in the embryo and in many of the lower mammals conformably with the greater extent of development of the organ of Jacobson (see p. 143), which, in some animals, they partly enclose.

NASAL FOSSÆ.

The nasal fossæ are, as already stated, the cavities which occupy the interior of the nose and effect a communication between the exterior and the pharynx. They have been described in Vol. II. as they exist in the skeleton, but they are much narrower in the living condition owing to the thickness and vascularity of the lining membrane, which also covers over many of the apertures seen in the macerated

bone. These differences are well exemplified by comparing fig. 153, which represents the lateral wall of the left nasal fossa in the macerated condition with fig. 154, which shows the right nasal fossa as it appears when still covered by mucous membrane. In (coronal) section each nasal fossa is irregularly triangular in shape, the apex of the triangle being formed by the roof of the fossa, and the base by the floor. Towards the apex the triangle is quite narrow, but about halfway towards its base, *i.e.*, immediately below the free edge of the middle turbinal (see below), each fossa expands, so that this lower part is nearly quadrilateral in coronal section (fig. 156); this is the *respiratory part*: the upper narrow part is the *olfactory part* of the fossa or *olfactory cleft*. The mesial wall and floor of each fossa is smooth, but the lateral wall is complicated by a series of lamellar

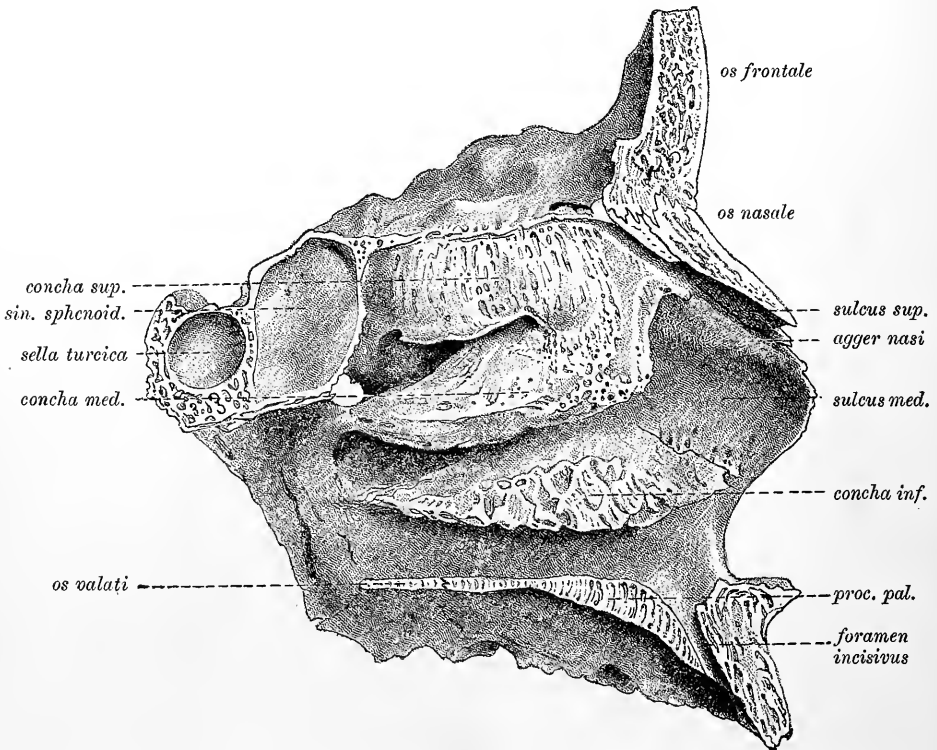


Fig. 153.—VIEW OF THE LATERAL WALL OF THE LEFT NASAL FOSSA AS IT APPEARS IN THE MACERATED SKELETON. (Modified from Arnold.)

prominences running in a sagittal direction and projecting into the cavity; these prominences, which are formed by the turbinate processes of the ethmoid bone and by the inferior turbinate bone covered by mucous membrane, may be termed the *turbinate bodies*, or simply *turbinals* (*conchæ*).

The following are the average dimensions of the nasal fossæ (Thane):—

Greatest vertical measurement (at fore part of cribriform plate)	44 mm.
Greatest sagittal measurement (along floor, from posterior margin of hard palate to anterior extremity of roof)	73 mm.
Sagittal measurement of osseous part of floor	44 mm.
Least sagittal measurement (close below cribriform plate)	35 mm.
Greatest coronal measurement (near floor)	16 mm.
Least coronal measurement (near roof)	2.5 mm.

The turbinals on the lateral wall of each fossa are usually described as three in number, viz., two on the lateral mass of the ethmoid, which are known as the superior and middle turbinals (superior and inferior ethmoidal conchæ), and one, the inferior turbinal, on the superior maxillary bone (maxillary concha). Each concha overhangs and partially separates from the general cavity of the fossa a groove-like space, which is known as the corresponding *meatus* (*superior, middle, or*

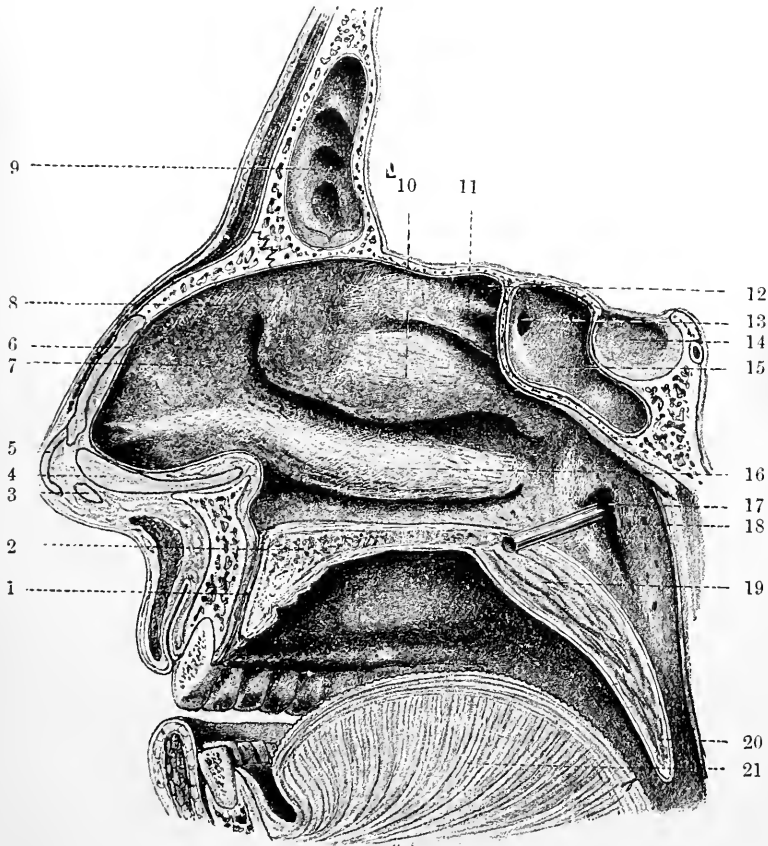


Fig. 154.—VIEW OF THE RIGHT NASAL FOSSA AS SEEN IN A SECTION THROUGH THE SKULL, TAKEN JUST TO THE RIGHT OF THE SEPTUM. (E. A. S.)

1, incisor canal; 2, bone of hard palate; 3 and 4, parts of the mesial crus of the cartilage of the aperture; 5, anterior part of the same cartilage; 6, cartilage of the septum; 7, groove leading to middle meatus; 8, agger nasi; 9, frontal sinus; 10, inferior ethmoidal concha; 11, superior ethmoidal concha; 12, recess of upper meatus above superior concha; 13, entrance to sphenoidal sinus; 14, pituitary fossa; 15, sphenoidal sinus; 16, inferior turbinal (maxillary concha); 17, rod passed into Eustachian tube; 18, salpingo-pharyngeal fold: immediately behind this is the lateral recess of the pharynx, not specially indicated in the drawing; 19, soft palate; 20, uvula; 21, tongue.

inferior, as the case may be). The groove of the *superior meatus* between the superior and middle conchæ is also termed the *ethmoidal fissure*. This meatus is relatively small, corresponding with the small size and extent of its overhanging concha: into it the *posterior ethmoidal cells* open by one or two apertures (fig. 155).

The middle turbinal or concha is large, and overhangs a correspondingly large *middle meatus*, which can only be properly seen on cutting away the concha (fig. 155). It is then found that the meatus extends under the anterior part of the turbinal into a gradually narrowing funnel-shaped diverticulum (*infundibulum*) which leads

directly upwards into the *frontal sinus*, and that the lateral wall of this meatus is further marked by a deep curvilinear depression (*hiatus semilunaris*, Zuckerkandl), extending from behind and below upwards and forwards towards the infundibulum. Into the deepest part of this depression the *anterior ethmoidal cells* and the *maxillary antrum* open, often by a common orifice; sometimes the antrum has a second orifice rather lower down in the hiatus. Immediately above and behind the hiatus semi-

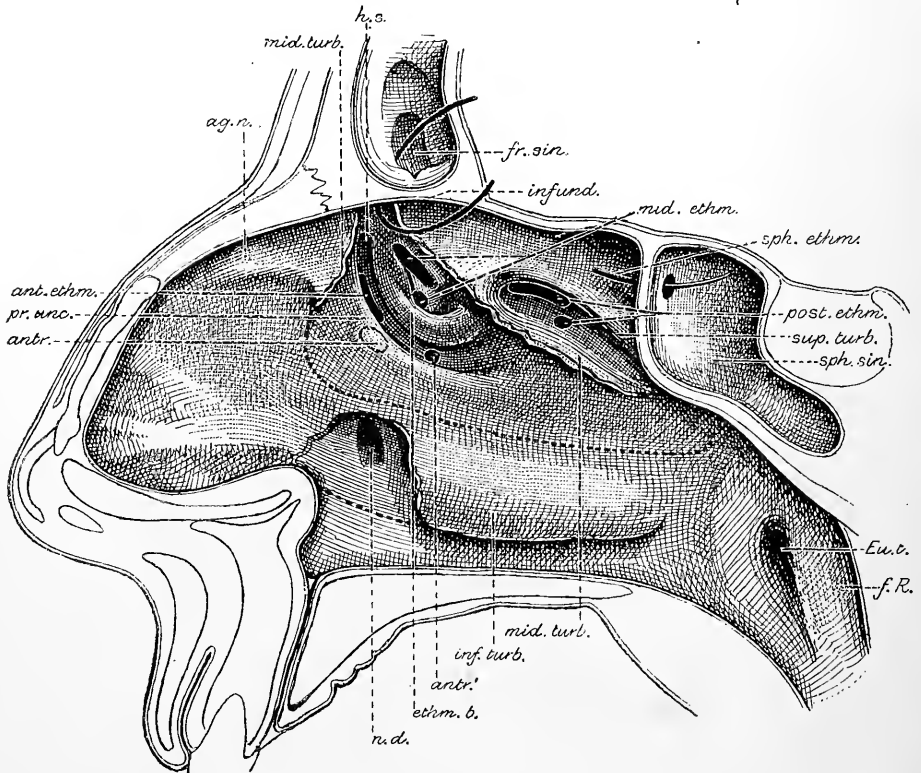


Fig. 155.—SKETCH SHOWING THE POSITION OF THE ORIFICES OF THE AIR-CELLS, AND OF OTHER PASSAGES LEADING INTO THE NASAL FOSSE (E. A. S.).

The middle and inferior turbinals are cut away as much as is necessary to expose the orifices.

sph. ethm., probe passed from the sphenoidal recess into the sphenoidal sinus, *sph. sin.*; *post. ethm.*, apertures of the posterior ethmoidal cells beneath the superior ethmoidal concha; *mid. ethm.*, apertures of the middle ethmoidal cells beneath the middle (inferior ethmoidal) concha, and just above the ethmoidal bulla, *ethm. b.*; *ant. ethm.*, aperture of the anterior ethmoidal cells in the hiatus semilunaris, *h. s.*, immediately below the ethmoidal bulla; *antr.*, aperture of the maxillary antrum also in the hiatus, and close to those of the anterior ethmoidal cells but concealed by the uncinat process, *pr. unc.*; *antr.'*, an accessory orifice to the antrum, sometimes present in the lower part of the hiatus semilunaris; *infund.*, infundibulum leading to the aperture of the frontal sinus, *fr. sin.* (through which a probe is passed); *n. d.*, orifice of nasal duct, beneath the inferior turbinal; *ag. n.*, agger nasi; *Eut.*, Eustachian tube; *f. R.*, lateral recess of pharynx (fossa of Rosenmüller).

lunaris and below the attachment of the concha is an oval prominence of the lateral wall which is often very strongly marked. This is the *ethmoidal bulla* of Zuckerkandl, and above or upon it are the apertures of the *middle ethmoidal cells* (fig. 155).

The ethmoidal bulla has been held to be a rudiment of an additional ethmoidal concha which is well developed in macrosomatic mammals; but this opinion, although it seemed a probable one, is not supported by the most recent researches.

Zuckerkandl has shown that there is frequently present, especially in the foetus and child, a second ethmoidal fissure parallel to and above the principal fissure. This second fissure separates off the lower part of the superior ethmoidal concha as a *middle ethmoidal concha*.

There may also be found a third parallel fissure above the second fissure, effecting a further separation of the upper concha, so that in these cases there are four distinct conchæ on the ethmoid bone alone, viz., *suprema*, *superior*, *media*, and *inferior* (besides the lowermost or maxillary concha). This condition represents one which is met with in macrostomatic mammals in a much more developed form. The most common condition, however, in man, according to Zuckerkandl, is that with three ethmoidal conchæ, but the middle one, when present, is frequently hidden beneath the superior concha, and thus often escapes observation. Hence the usual description of the ethmoidal conchæ as superior and inferior only, the inferior being the one which is spoken of above as the middle turbinal.

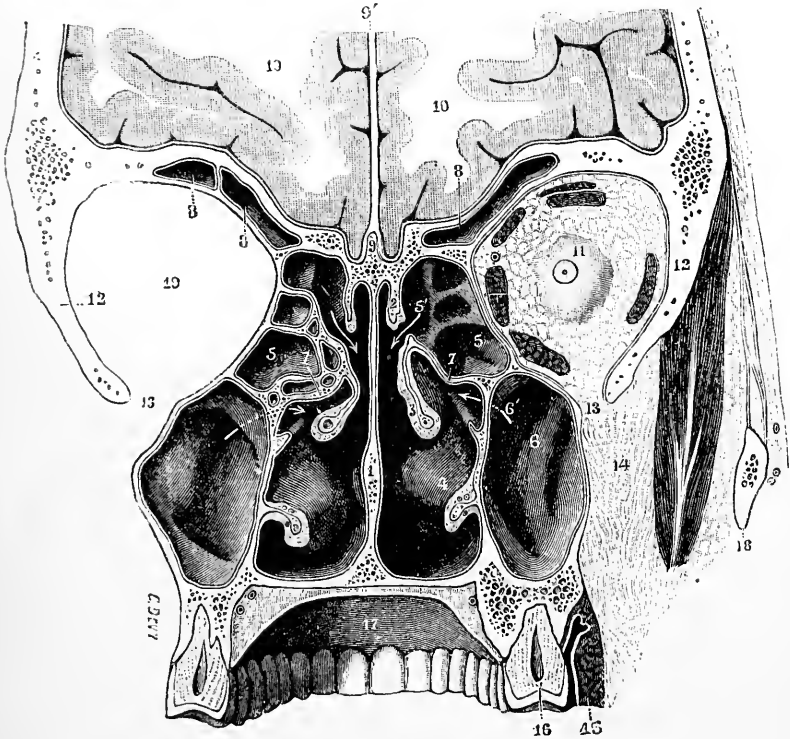


Fig. 156.—CORONAL SECTION OF THE NASAL FOSSÆ SEEN FROM BEHIND. THE SECTION PASSES THROUGH THE LAST MOLAR TEETH. (Testut.)

1, septum nasi; 2, superior turbinal; 3, middle turbinal; 4, inferior turbinal; 5, posterior ethmoidal cells opening at 5' (on the right side) into the superior meatus; 6, maxillary antrum, opening at 6' into the middle meatus: the head of the arrow is in the hiatus semilunaris; 7, bulla ethmoidalis; 8, frontal sinuses; 9, crista galli; 9', falx cerebri; 10, cerebral hemispheres; 11, right orbit containing the globe of the eye (surrounded by orbital fat) and its muscles; 12, great wing of sphenoid; 13, spheno-maxillary fissure; 14, fatty tissue of zygomatic fossa; 15, buccinator muscle; 16, last molar tooth; 17, vault of palate; 18, zygoma; 19, left orbit.

Besides the ethmoidal fissures which separate the conchæ from one another, the superior turbinal is often marked by a distinct groove at its posterior part, which leads backwards into the spheno-ethmoidal recess (fig. 154).

The superior and middle turbinals are conjoined in front and may be said to spring from the cribriform plate, through which pass the branches of the olfactory nerve. Their free edges slope downwards and backwards, that of the middle turbinal gradually becoming nearly horizontal. The lower margins of both, covered by thick mucous membrane, are free and overhang respectively the superior and middle meatus; the middle turbinal has also a nearly vertical free border anteriorly, which, together with the adjoining part of the concha, forms an operculum covering the corresponding part of the middle meatus, and concealing

the bulla ethmoidalis, the hiatus semilunaris, and the apertures of the air-cells which open into this meatus.

The middle meatus, which lies beneath the middle turbinal, is roughly triangular in shape, with the base of the triangle directed forwards. It expands in front of the middle turbinal into a nearly smooth-walled chamber which communicates through the vestibule with the anterior nares; this chamber is known as the *atrium* of the middle meatus. On the outer wall above the atrium a low ridge (figs. 154, 155) may usually be detected passing downwards and forwards from the anterior attachment of the middle turbinal. This ridge (*agger nasi* of H. Meyer), which is seen also in the macerated bone (fig. 153), is the rudiment of a well-developed turbinal (*nasoturbinal*), which is met with in most mammals (Schwalbe). It is usually better marked in the fœtus and new-born child, in which it is seen to be continued below and behind into the uncinatè process of the ethmoid, which forms the lower and anterior boundary of the hiatus semilunaris (Seydel). The groove above the *agger nasi* leads to the olfactory part of the nose, and is termed *sulcus olfactorius*.

In the lower meatus, which lies between the inferior turbinal and the floor of the fossa, is the inferior orifice of the nasal duct which is defended by one or two folds of membrane: when there are two, the folds are often adapted so accurately together as to prevent air from passing up from the cavity of the nose to the lachrymal sac.

The *roof* of the nasal fossa is divided into three parts, viz.: *nasal*, in front; *ethmoidal*, in the middle, and *sphenoidal*, behind, corresponding with the bones of the same name. The roof is at the front formed only by the conjunction of the septum and lateral walls, and is quite narrow, but it is broader near the choanæ. Above and behind the upper turbinal is a diverticulum of the nasal fossa, the *spheno-ethmoidal recess*, which communicates posteriorly with the sphenoidal sinus (fig. 154). The *floor* of the fossa is broader than the roof. In it in front is the incisor foramen, but this is in the recent state generally closed (fig. 154). Sometimes, however, a narrow funnel-shaped tube of mucous membrane (*nasopalatine canal*, *canal of Stensen*, or *canalis incisivus*) passes obliquely downwards from each nasal fossa for a short distance towards the front of the hard palate. Vesalius, Stensen, and Santorini believed that these tubes of membrane opened generally into the roof of the mouth by small apertures close behind the central incisor teeth. Haller, Scarpa, and Jacobson found the canals in man usually closed, and often difficult of detection, and these statements have been confirmed by most modern investigators. The canal is a remnant of the wide communication between the nasal and buccal cavities found at an early period of foetal life, being in man usually obliterated, at least in its lower part, before birth, although persistent in many animals. It is long represented below by a solid column of epithelium cells continuous with the epithelium of the palate, and above by a narrow tube lined with ciliated epithelium, opening into the floor of the nasal fossa but closed below.

The part of the inferior meatus which lies behind the incisor canal, together with the space immediately behind the posterior end of the superior and middle turbinals as far back as the orifice of the Eustachian tube, belongs to the primitive buccal cavity of the fœtus, having become separated from the permanent mouth by the growth of the palate (see Vol. I., p. 97). It is known as the naso-pharyngeal part (*ductus naso-pharyngeus*), and its mucous membrane is marked off behind from that of the pharynx by a prominence which is termed the *naso-pharyngeal fold*.

The anterior and lowermost part of the nasal cavity is termed the *vestibule* (fig. 157). This is bounded laterally by and corresponds in extent with the ala and the cartilage of the aperture. It is lined by skin and is furnished with hairs and with sebaceous and sudoriferous glands. The hairs are large and numerous just within the orifice of the anterior nares (*vibrissæ*), but over the rest of the vestibule

they are small and thinly scattered, and both the hairs and glands are absent near the posterior limit of the vestibule, which is marked off by a curved prominence (*limen vestibuli*) from the nasal fossæ proper. At this line the stratified epithelium of the vestibule passes into the ciliated epithelium of the fossæ, and the cutaneous glands are replaced by compound mucous glands. At the front of the vestibule, enclosed by the curved cartilage of the aperture, is a shallow *cul-de-sac* known as the *ventricle of the nares*.

MUCOUS MEMBRANE.

The pituitary or Schneiderian membrane, which lines the cavities of the nose, is a highly vascular mucous membrane, inseparably united with the periosteum and perichondrium over which it lies. It is continuous with the skin through the nostrils; with the mucous membrane of the pharynx through the posterior nares; with the conjunctiva through the nasal duct and lachrymal canaliculi; and with the lining membrane of the several sinuses which communicate with the nasal fossæ.

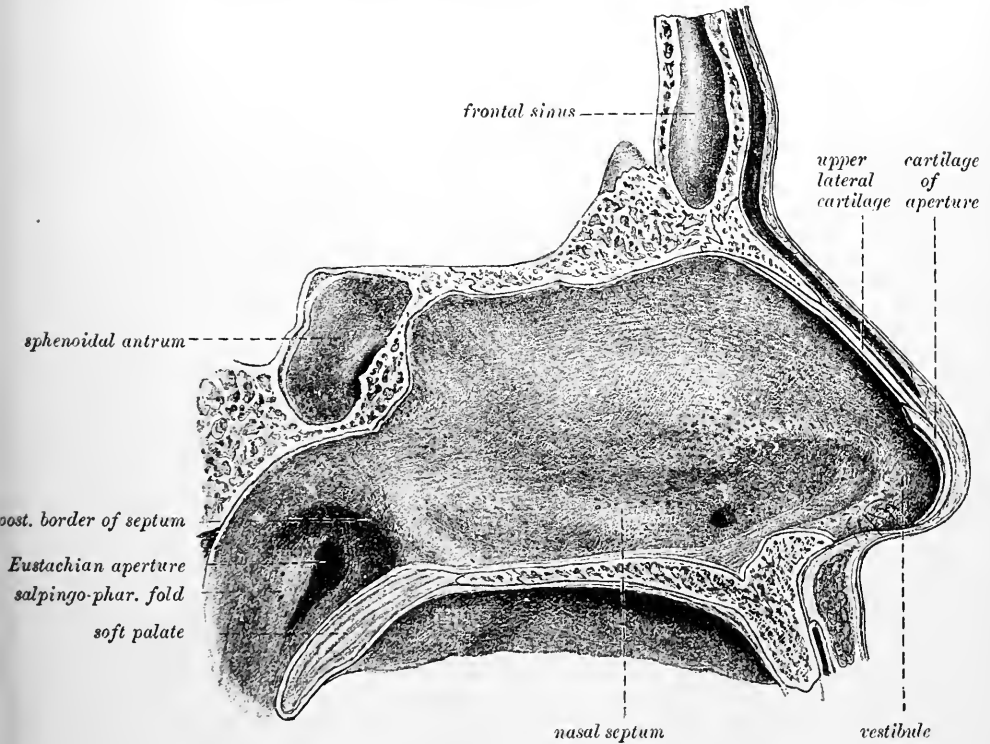


Fig. 157.—VIEW OF THE SEPTUM NASI FROM THE RIGHT SIDE.

The pituitary membrane, however, varies much in thickness and vascularity in different parts. It is thickest and most vascular over the turbinate bones (particularly the inferior) and on the septum nasi it is also very thick and spongy; but in the intervals between the turbinate bones, and over the floor of the nasal fossæ, it is considerably thinner. In the maxillary, frontal, and sphenoidal sinuses, and in the ethmoidal cells, the lining mucous membrane is very thin and pale, and contrasts strongly with that which lines the nasal fossæ.

The character of the epithelium varies in different parts, and by this, in a general way, three regions of the nasal fossæ may be distinguished. Thus, the region of the external nostrils (the vestibule) is lined with stratified squamous epithelium;

and the remainder is divisible into two parts, viz., the upper or olfactory region in which the epithelium is non-ciliated and columnar, and the lower or respiratory region in which, as also in the sinuses, it is ciliated and columnar. The membrane in the respiratory part covers the middle and inferior turbinals and all the lower portions of the fossæ, and is studded with racemose glands, which open by orifices apparent on the surface. They are most numerous about the middle and hinder parts of the nasal fossæ, and are largest at the back of the septum near the floor of the nasal cavity. Glands which are much smaller and less numerous are stated to open into the several cavities which communicate with the nasal fossæ, but many observers have failed to find them. Besides the glands the mucous membrane of the fossæ contains a variable amount of lymphoid tissue, occasionally accumulated into "nodules." In some parts large venous plexuses are found, encircled, as well as the alveoli of the glands amongst which they lie, by bundles of plain muscular fibres (Klein), thus forming a sort of cavernous tissue.

Olfactory mucous membrane.—The olfactory region, or that in which the olfactory nerve is distributed, includes in man only the uppermost part of the fossæ

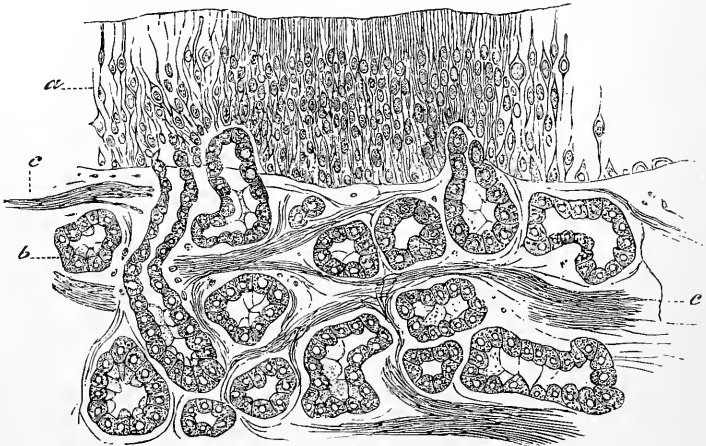


Fig. 158.—SECTION OF THE OLFACTORY MUCOUS MEMBRANE. (Cadiat.)
a, epithelium ; b, glands of Bowman ; c, nerve-bundles.

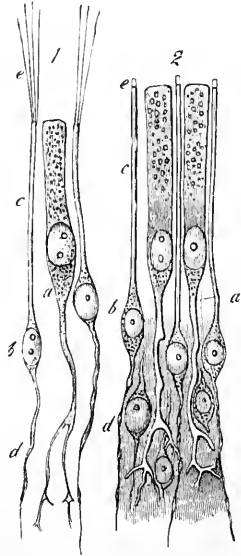
(superior turbinal and corresponding part of the septum). It is extremely vascular, a close plexus of large capillary vessels being found under the lining membrane throughout its whole extent. Its mucous membrane is covered by a very thick non-ciliated epithelium, and it is more delicate in consistence than that of the ciliated region, being indeed soft and pulpy. It has a distinct yellow colour in man (*locus luteus*); brown in some animals; the colour may extend however beyond the true olfactory part of the mucous membrane. The glands of this region (*glands of Bowman*) are numerous, and are of a more simple structure than those in the lower part of the fossæ. They open by fine ducts lined with flattened cells which extend to the surface between the olfactory epithelium cells (fig. 158). In the mucous membrane itself, the gland-tube is somewhat convoluted and enlarged, and it may have one or two branches. It is limited throughout by a basement membrane, and lined and almost filled with columnar or polyhedral secreting cells. These are of the "serous" type in man, but in some mammals there are "mucous" cells intermingled with the serous (Paulsen). The gland-cells contain yellowish brown pigment. In man the gland-ducts frequently open into a small sub-epithelial receptacle lined with flattened epithelium, from which a fine tube passes to the surface between the epithelium cells. Occasionally the opening

is into a ciliated crypt. Here and there the epithelium of the surface, as shown by Max Schultze, is ciliated and not olfactory; where this is the case, the ordinary racemose glands are found (Klein). On the other hand, Bowman's glands are not entirely confined to the olfactory mucous membrane, but may extend a short distance beyond it into the respiratory part of the fossa.

The columnar cells on the surface of the olfactory mucous membrane (fig. 159, *a*) are prolonged at their deep extremities into a process which is generally somewhat

Fig. 159.—CELLS OF THE OLFACTORY REGION. (M. Schultze.)
Highly magnified.

1, from the frog; 2, from man; *a*, epithelial cell, extending deeply into a ramified process; *b*, olfactory cells; *c*, their peripheral processes; *e*, their extremities, seen in 1 to be prolonged into fine hairs; *d*, their central filaments.



branched towards its deeper end. The nuclei of these cells are oval in shape and lie all at about the same level (*zone of oral nuclei*), *i.e.*, in the deeper part of the columnar portion of each cell. The protoplasm of the columnar cells contains granules of yellowish-brown pigment. Amongst the branching central ends of these columnar cells there are a large number of peculiar spindle-shaped cells (fig. 159, *b*), each consisting of a large, clear, nearly spherical, nucleus surrounded by a relatively small amount of granular protoplasm. From each cell proceeds a superficial and a deep process. The superficial process (*c*) is a cylindrical or slightly tapering thread passing directly to the surface, and terminating abruptly at about the same level as the free surface of the epithelial cells between which it lies, or a little beyond; the deep process (*d*) is more slender, and passes vertically inwards. This last usually presents a beaded appearance similar to that observed in fine nerve-

Fig. 160.—AN OLFACTORY CELL, HUMAN. (v. Brunn.)

n, central process prolonged as an olfactory nerve fibril; *b*, body of cell with nucleus; *p*, peripheral process passing towards free surface; *c*, knob-like clear termination of peripheral process; *h*, bunch of olfactory hairs.



filaments. These cells were termed by Max Schultze, *olfactory cells*, to distinguish them from the columnar epithelium cells, which are much fewer in number, and which are entirely surrounded with the fine rod-like peripheral processes of the smaller cells. The nucleated bodies of the olfactory cells are several rows deep, and form a layer of considerable thickness beneath the columnar cells (*zone of round nuclei*).

In the rabbit and guinea-pig Klein, in confirmation of a statement by Sidky, describes a lowermost layer of conical vertical cells resting by their bases upon the membrana propria.

The total thickness of the olfactory epithelium in man is 0.06 mm., whereas in macrosomatic mammals it is 0.1 mm. or more (v. Brunn).

The olfactory (but not the columnar) cells are said to project through apertures in a cuticular lamina which bounds the mucous membrane superficially (*external limiting membrane*, v. Brunn). The existence of this cuticle has been, however, called in question by other observers.

The peripheral process of the olfactory cell was observed by Schultze to be

surmounted by a short projection (fig. 159, 2, *e*); according to v. Brunn, this appears in well-preserved specimens to be surmounted by a bunch of fine short hairlets, which are termed the *olfactory hairs* (fig. 160). Long and fine hair-like processes have long been known to exist on the olfactory cells of amphibia, reptiles, and birds (fig. 159, 1, *e*).

In amphibia and fishes the olfactory cells are grouped together in the form of bud-like organs resembling the taste-buds of the tongue.

It has been shown by various observers, by aid of the methyl-blue and silver-chromate methods, that the fine varicose central processes of these cells are directly continuous with the fibres of the olfactory nerve, and terminate centrally by

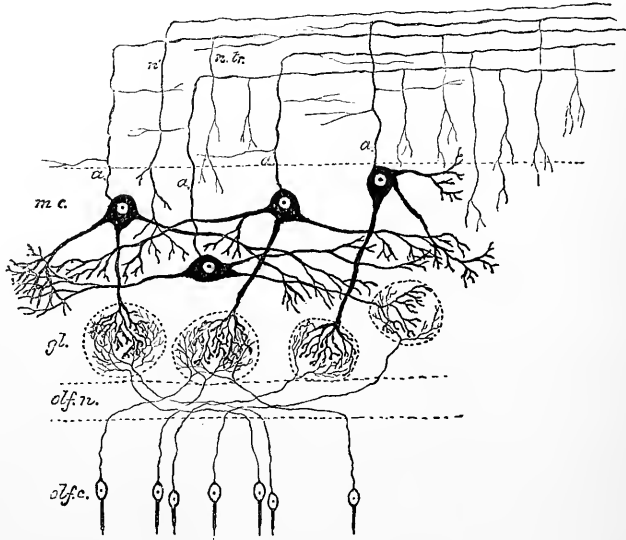


Fig. 161.—DIAGRAM OF THE CONNECTIONS OF CELLS AND FIBRES IN THE OLFACTORY BULB.
(E. A. S.)

olf.c., cells of the olfactory mucous membrane; *olf.n.*, deepest layer of the bulb composed of the olfactory nerve-fibres, which are prolonged from the olfactory cells; *gl.*, olfactory glomeruli, containing arborisations of the olfactory nerve-fibres and of the dendrons of the mitral cells; *m.c.*, mitral cells; *a*, their axis-cylinder processes passing towards the nerve-fibre layer, *n.tr.*, of the bulb to become continuous with fibres of the olfactory tract: these axis-cylinder processes are seen to give off collaterals, some of which pass again into the deeper layers of the bulb; *n'*, a nerve-fibre from the olfactory tract ramifying in the grey matter of the bulb.

dendritic ramifications in the glomeruli of the olfactory bulb (see fig. 161, and Vol. III., Part 1, p. 175).

Olfactory Nerve.—The filaments of this nerve, lodged at first in grooves on the surface of the bones, enter the substance of the Schneiderian membrane obliquely. The nerves of the septum (fig. 162) are rather larger than those of the outer wall of the nasal fossæ; they extend over the upper third of the septum, becoming very indistinct as they descend. The nerves of the outer wall (fig. 163) are divided into two groups—the posterior being distributed over the surface of the upper turbinal, and the anterior over the anterior part of the olfactory groove. In the embryo the extent of distribution of the olfactory nerves is relatively greater, but it becomes more limited as development proceeds, and ultimately the actual distribution of olfactory nerve-fibres, to judge by the character of the epithelium covering the membrane, becomes limited to a relatively small tract embracing little but the superior turbinal and a corresponding extent of the septum (v. Brunn).

The nerves ramify so as to form flattened tufts, the filaments of which, spreading out laterally and communicating freely with similar offsets on each side, form a close plexus, with elongated and narrow meshes.

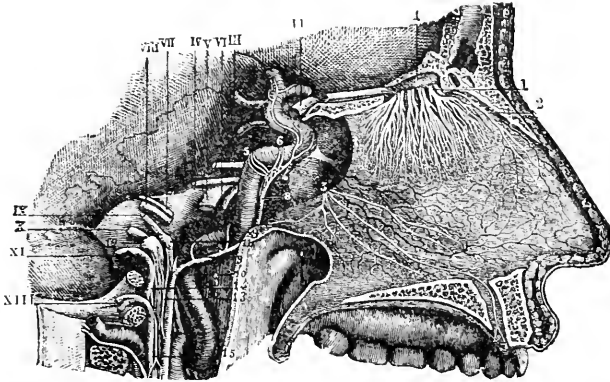


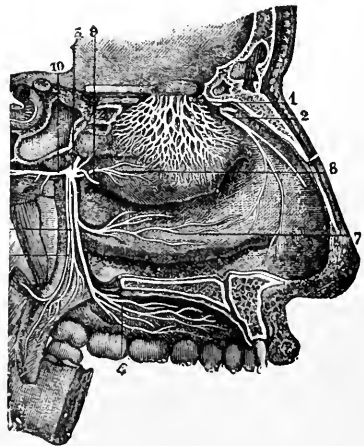
Fig. 162.—NERVES OF THE SEPTUM NASI, SEEN FROM THE RIGHT SIDE. (From Sappey, after Hirschfeld and Leveillé.) $\frac{3}{3}$

1, the olfactory bulb; 1, the olfactory nerves passing through the foramina of the cribriform plate, and descending to be distributed on the septum; 2, the internal or septal twig of the nasal branch of the ophthalmic nerve; 3, naso-palatine nerves.

In their structure the olfactory nerve-fibres differ much from the ordinary dark-bordered fibres of the cerebral and spinal nerves: they possess no medullary

Fig. 163.—NERVES OF THE OUTER WALL OF THE NASAL FOSSÆ. (From Sappey, after Hirschfeld and Leveillé.) $\frac{3}{3}$

1, network of the branches of the olfactory nerve, descending upon the region of the superior and middle turbinated bones; 2, external twig of the nasal nerve; 3, spheno-palatine ganglion; 4, ramification of the large palatine nerve; 5, small, and 6, external palatine nerves; 7, branch to the region of the inferior turbinated bone; 8, branch to the region of the superior and middle turbinated bones; 9, naso-palatine branch to the septum cut short.



sheath, but are axis-cylinders provided with a distinct nucleated sheath, much more distinct than that of the fibres of Remak and with nuclei at less frequent intervals (fig. 164).

The greater part of the mucous membrane of the nasal fossæ is provided also with nerves of common sensibility, derived from branches of the fifth pair: the distribution of these has already been described. They appear to end amongst the epithelium cells in arborisations which have been noticed by several observers in preparations made by the silver chromate method.

The Organ of Jacobson.—In the anterior and lower part of the nasal septum a small aperture may sometimes be seen opening obliquely on to the surface of the mucous membrane slightly above and in front of the orifice of the nasopalatine canal (see fig. 157). This aperture leads into a minute canal which passes backwards for a short distance along the septum to terminate blindly a few millimeters from the orifice. The canal, which is lined with epithelium continuous with that of the

nasal cavity and has numerous glands opening into it, is the homologue of a much more extensively developed tubular organ which opens in a similar position in many quadrupeds, and is encircled by a special curved plate of cartilage which lies below the septal cartilage on either side and is known as the cartilage of Jacobson. This is only represented in man by a narrow shred of cartilage (the vomerine cartilage of Huschke), which lies wholly below the rudimentary organ of Jacobson. In the rabbit and guinea-pig as shown by Klein, and probably in other animals in which the organ is in a well-developed condition, the epithelium which lines the inner or mesial side of the canal is much thicker than that on the outer side. It is throughout similar in structure to that lining the olfactory part of the Schneiderian membrane. Moreover it receives considerable branches of the olfactory nerve, and in these animals is no doubt of high functional importance as an accessory to the proper organ of smell. In man the epithelium on the mesial wall of the canal is thick like the olfactory epithelium, but contains no true olfactory cells. Most of the cells are of the columnar (sustentacular) type, and although there are some more slender spindle-cells between these, probably homologous with the olfactory cells, they do not reach the surface, nor are they connected with nerve-fibres. Moreover, calcareous concretions are frequent amongst the epithelium cells, so that it is highly probable that the function of the organ in man is entirely in abeyance. In

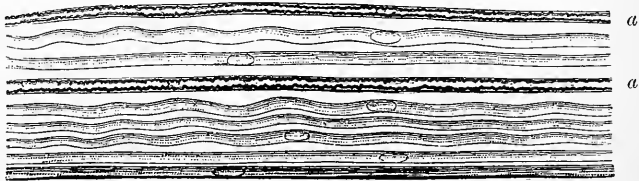


Fig. 164.—NERVE-FIBRES FROM THE OLFACTORY MUCOUS MEMBRANE. (Max Schultze.)
Magnified between 400 and 500 diameters.

From a branch of the olfactory nerve of the sheep; at *a, a*, two dark-bordered or medullated fibres, from the fifth pair, associated with the pale olfactory fibres.

the embryo, up to eight weeks this epithelium is relatively far better developed, but after this time it appears to undergo retrograde changes.

Blood-vessels and lymphatics of the nasal fossæ.—The *spheno-palatine branch of the internal maxillary artery* enters the cavity by the spheno-palatine foramen and divides into external branches (*posterior nasal*) to the meatuses and turbinals, sending offsets also to the ethmoidal cells and to the maxillary and frontal sinuses, and an internal branch (*naso-palatine artery of the septum*) along the septum to the incisor foramen. The branches of the naso-palatine communicate freely with the anterior and posterior ethmoidal of the ophthalmic.

The *descending palatine branch of the internal maxillary artery* gives small offsets to the hinder part of the inferior turbinal and meatus.

The *anterior ethmoidal branch of the ophthalmic artery* enters the cavity with the nasal nerve and is distributed to the mucous membrane of the fore part of the septum and outer wall.

The *posterior ethmoidal branch* of the same artery sends small twigs to the posterior ethmoidal cells, to the roof, and to the upper part of the septum.

Lastly a branch from the superior coronary of the facial and the *lateral nasal artery* supply the part near the anterior nares. The several arteries anastomose freely together in the mucous membrane, and are distributed to three sets of capillaries, viz., a periosteal, glandular, and sub-epithelial.

The *veins* form a dense plexus in the mucous membrane, those in the deeper parts of the membrane being especially large and closely arranged so as almost to approach the structure of a cavernous tissue. This is most largely developed over the whole lower turbinal, the lower and hinder border of the middle turbinal, and the hinder end of the upper turbinal as well as on the lower and hinder part of the septum. A similar dense venous plexus, continuous with that of the nasal fossæ, extends around the nasal duct, as far upwards as the lachrymal sac. The trunks leaving the cavity accompany the arteries, the *spheno-palatine vein* emptying

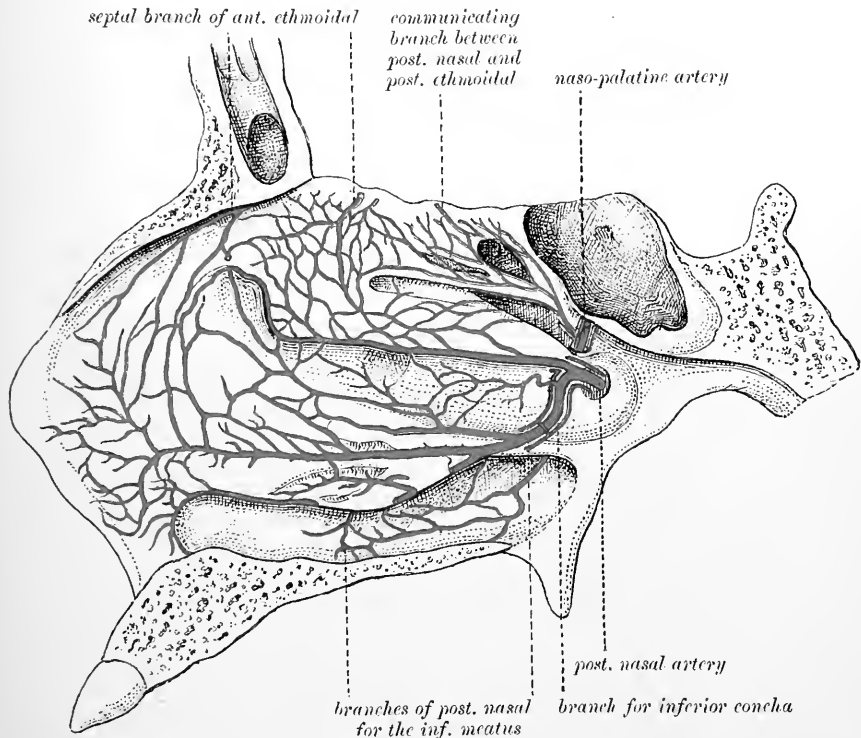


Fig. 165.—ARTERIAL SUPPLY TO THE MUCOUS MEMBRANE OF THE LATERAL WALL OF THE NASAL FOSSA. (After Zuckerkandl.)

itself into the pterygoid plexus; the *ethmoidal veins* joining the ophthalmic vein and the veins of the dura mater, and also sending a branch to join the veins of the orbital part of the frontal lobe of the brain (Zuckerkandl), and small veins passing out at the margin of the nares to join the venous plexus of the upper lip. Some small veins also pierce the nasal bone and the ascending process of the superior maxilla to join the commencement of the facial vein.

The *lymphatics* are abundant and large. They form a close plexus in the mucous membrane, the branches extending almost to the surface, and a more open plexus of valved vessels nearer the bone. These are in communication with the lymphatic spaces which enclose the branches of the olfactory nerve, and these spaces again communicate with the subdural and subarachnoid spaces of the cranium, so that the lymphatics of the nasal mucous membrane can be injected from the cranial

cavity (Schwalbe, Key and Retzius). Lymphatic nodules are here and there present in the mucous membrane.

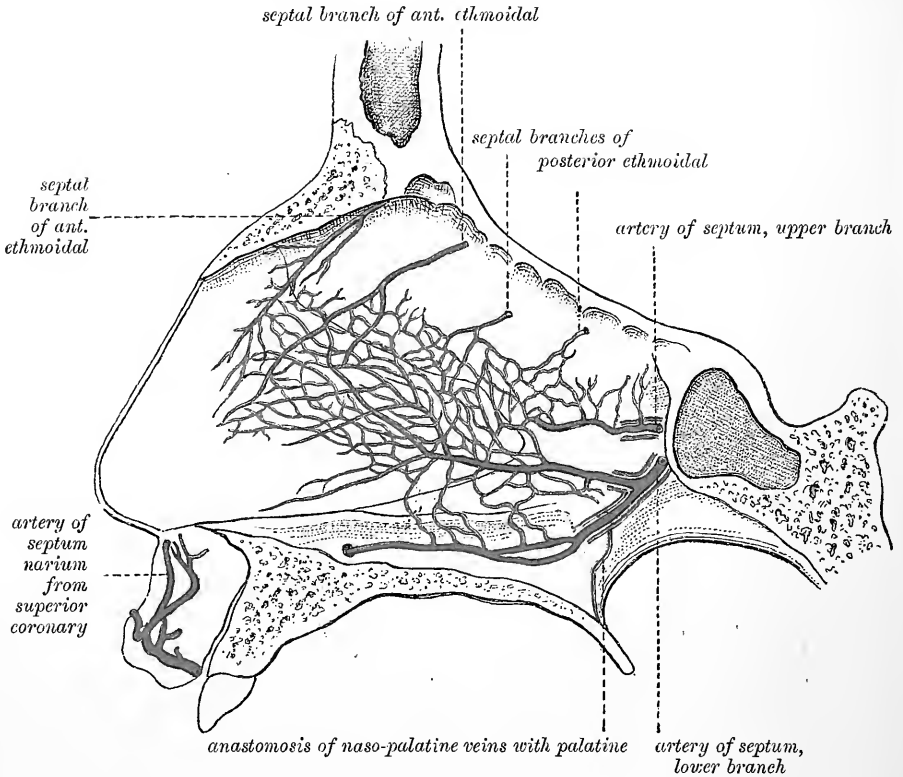


Fig. 166.—ARTERIAL SUPPLY TO THE SEPTUM NASI. (After Zuckerkandl.)

RECENT LITERATURE OF THE OLFACTORY ORGAN.

- Allen, Harrison**, *The anatomy of the nasal chambers*, The New York Med. Journ., 1889.
- Beard, J.**, *Morphological Studies*, No. 4, *The nose and Jacobson's organ*, Zoologische Jahrbücher, Abt. f. Anatomie, Band iii., 1889.
- Bovier-Lapierre, Emile**, *De la vascularité de l'épithélium olfactif*, Comptes rendus hebdom. de la Société de biologie, 1888.
- v. Brunn**, *Ueber die Ausbreitung der menschlichen Riechschleimhaut*, Rostocker Zeitung, 1891; *Die Nervenendigung im Riechepithel*, Rostocker Zeitung, 1891; *Beitr. zur mikr. Anat. der Nasenhöhle*, Arch. f. mikr. Anat., Bd. xxxix., 1892; *Die Endigungen d. Olfactoriusfasern im Jacobson'schen Organe des Schafes*, Arch. f. mikr. Anat. xxxix., 1892.
- Cajal, R. y**, *Termin. del nervio olfact. en la mucosa nasal*, Barcelona, 1889; *Origen y termin. d. l. fibras nerviosas olfatorias*, Gac. med., Catalona, 1890.
- Cozzolino, V.**, *Deviazioni del setto nasale*, etc., Il Morgagni, xxviii., 1886.
- Disse, J.**, *Die Ausbildung der Nasenhöhle nach der Geburt*, Archiv f. Anatomie u. Phys., Anatom. Abt., 1889.
- Fränkel, B.**, *Gefrierdurchschnitt zur Anatomie der Nasenhöhle*, Berlin, 1890.
- van Gehuchten, A.**, *Contributions à l'étude de la muqueuse olfactive chez les mammifères*, La Cellule, vi., 1890.
- Grassi, B., und Castronovo, A.**, *Beitrag zur Kenntniss des Geruchsorgans des Hundes*, Archiv für mikroskopische Anatomie, xxxiv., 1889.
- Hartmann, A.**, *Atlas der normalen und pathologischen Anatomie der Nase*, Berlin, 1891.
- Herzfeld, J.**, *Beiträge zur Anatomie des Schwellkörpers der Nasenschleimhaut*, Archiv für mikroskopische Anatomie, xxxiv., 1889.
- Herzfeld, P.**, *Ueber das Jacobson'sche Organ des Menschen u. der Säugethiere*, Zool. Jahrb., iii., 1888.

- Hovorka, O.**, *Die äussere Nase. Eine anatomisch-anthropologische Studie*, Wien, 1893.
- Hubert, K. W.**, *Über die Verkrümmungen der Nasenschleimwand*, Diss., Heidelberg, 1886.
- Kaufmann**, *Über die Bedeutung der Riech- und Epithelialzellen der Regio olfactoria*, Mittheilungen aus dem embryolog. Institute der k. k. Universität. Wien, 1887.
- Keibel, F.**, *Zur Entwicklungsgesch. u. vergleichend. Anat. der Nase, etc.*, Anat. Anz., 1893.
- Klein, E.**, *The Organ of Jacobson*, Quarterly Journ. of Microsc. Science, 1881.
- v. Lenhossék, M.**, *Die Nervenprünge und Endigungen im Jacobson'schen Organ des Kaninchens*, Anatomischer Anzeiger, 1892.
- Löwe, L.**, *Zur Anatomie der Nase und Nebenhöhle*, Leipzig, 1883.
- Lustig, A.**, *Des cellules épithéliales dans la région olfactive des embryons*, Archives italiennes de Biologie, tome x., 1888.
- Merkel, F.**, *Jacobson'sches Organ u. Papilla palatina*, Anat. Hefte, i., 1892.
- Moreno, J.**, *Sobre las terminaciones nerviosas periféricas en la mucosa olfatoria de los Peces*, Anales d. sociedad espan. d. histor. natur., tomo xvii.
- Onodi, A.**, *Die Nasenhöhle u. ihre Nebenhöhlen*, Wien, 1893.
- Pilliet, A. H.**, *Note sur le tissu érectile des fosses nasales*, Bulletins de la société anatomique de Paris, 1891.
- Pogojeff, L.**, *Ueber die feinere Struktur des Geruchsorgans des Neunauges*, Archiv für mikroskopische Anatomie, xxxi.
- Preobraschensky, S. S.**, *Zur Kenntniss des Baues der Regio olfactoria*, Wiener klinische Wochenschrift, iv., 1891.
- Retzius, G.**, *Biol. Untersuchungen*, iii., Stockholm, 1889.
- Röse, C.**, *Ueber das rudimentäre Jacobson'sche Organ der Crocodil u. des Menschen*, Anat. Anz., 1893.
- Roux, Déviation de la cloison du nez, Revue méd. de la Suisse romande, vi., 1886.**
- Schmidt, M.**, *Die seitliche Divertikel des Nasenrachenraumes*, Arch. f. Laryngol. u. Rhinol. i., 1893.
- Seydel, Otto**, *Ueber die Nasenhöhle der höheren Säugethiere und des Menschen*, Morphologisches Jahrbuch, xvii., 1891.
- Spurgat, F.**, *Die regelmässige Formen der Nasenknorpel des Menschen*, Sc., Anat. Anzeiger, viii., 1893.
- Suchannek, Hermann**, *Beitrag zur Frage der Specificität der Zellen in der tierischen und menschlichen Riechschleimhaut*, Anatomischer Anzeiger, 1891; *Beiträge zur feineren normalen Anatomie des menschlichen Geruchsorgans*, Archiv für mikroskopische Anatomie, xxxvi., 1890; *Beiträge zur normalen und pathologischen Histologie der Nasenschleimhaut*, Anatom. Anzeiger, vii. 1892, and in Arch. f. Ohrenheilkunde, xxxiv., 1893.
- Zuckerkindl, E.**, *Das periphere Geruchsorgan der Säugethiere. Eine vergleichend-anatomische Studie*, Stuttgart; *Ueber d. Circulationsapparat in der Nasenschleimhaut*, Wiener Denkschriften, xlix., 1885; *Das adenoide Gewebe der Nasenschleimhaut*, Medic. Jahrb., Neue Folge, i., 1886; *Die Siebbeinmuskeln des Menschen*, Anatom. Anzeiger, vii. 1892; *Normale und pathologisch Anatomie der Nasenhöhle und ihrer pneumatischen Anknüpfungen*, 1892.

THE ORGANS OF TASTE.

THE gustatory organs are represented by certain patches or groups of peculiarly modified epithelium cells which are lodged in the thickness of the stratified epithelium of certain parts of the tongue and pharynx. These groups of cells have in mammals a bud-like arrangement and have therefore been termed *taste-buds*. They occur in man at the sides of the papillæ vallatæ of the tongue, forming a zone around the papillæ and also upon the opposed wall of the vallum. They are also found on

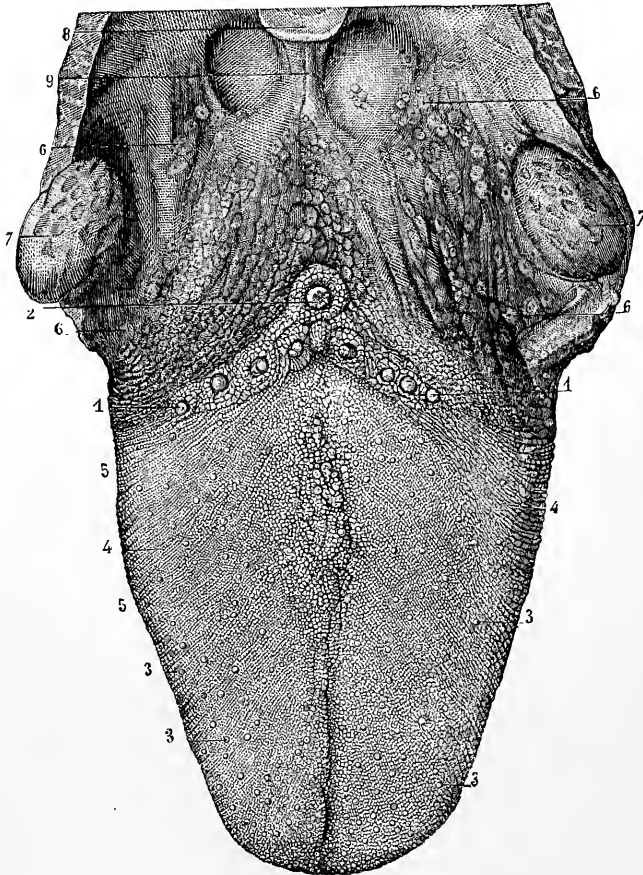


Fig. 167.—PAPILLARY SURFACE OF THE TONGUE, WITH THE FAUCES AND TONSILS. (Sappey.)

1, 2, circumvallate papillæ; 3, fungiform papillæ; 4, 5, filiform and conical papillæ; 6, glands and glandular recesses; 7, tonsils; 8, tip of the epiglottis; 9, frænum epiglottidis.

the fungiform papillæ of the back and sides of the tongue, extending to the lip, and here and there in the epithelium covering the general surface of the same parts of that organ. They are especially numerous over a small area just in front of the anterior pillar of the fauces (*fimbria linguae*). This area usually displays four or five longitudinal folds or elevations of the mucous membrane and appears to represent a much better defined oval laminated structure which is found in a similar situation in the tongue of some mammals (*e.g.*, rabbit), and which is known as the

papilla foliata (fig. 169). Taste-buds are also found over the anterior surface of the soft palate, and are very numerous over the posterior surface of the epiglottis.

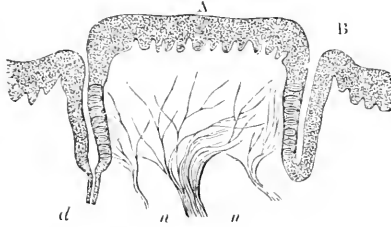


Fig. 168.—VERTICAL SECTION OF CIRCUMVALLATE PAPILLA, FROM THE CALF. (Engelmann.) $\frac{1}{5}$

A, papilla; B, vallum; n, bundles of nerve-fibres entering papilla; d, duct of a serous gland opening into fossa around papilla.

According to W. Krause they follow the distribution of the glosso-pharyngeal nerve.

Flask-shaped organs similar to taste-buds were discovered by Leydig in fishes in

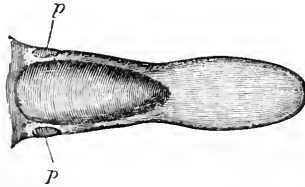


Fig. 169.—VIEW FROM ABOVE OF THE RABBIT'S TONGUE SHOWING THE PAPILLE FOLIATE. (E. A. S.)

certain parts of the skin, and they also occur in the mucous membrane of the mouth and throat in those animals. In amphibia the taste-organs take the form of patches

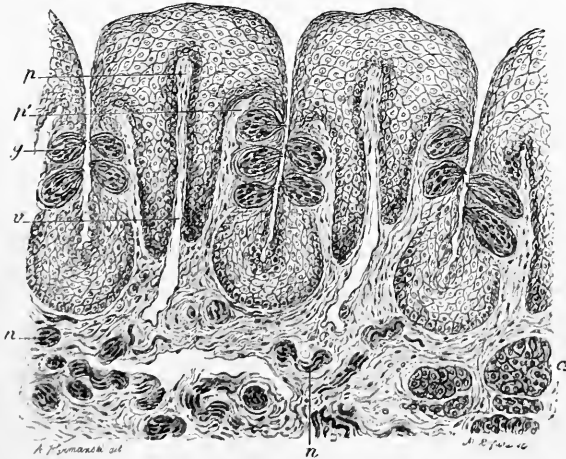


Fig. 170.—VERTICAL SECTION OF A FOLIATE PAPILLA OF THE RABBIT, PASSING ACROSS THE FOLIA. (Ranvier.)

p, central lamina of folium; v, vein; p', lateral lamina of folium; y, taste-bud; n, sections of nerve-bundles; a, serous gland.

of modified epithelium-cells set on the surface of certain papillæ of the tongue. The structure of the taste-buds is most easily studied in sections of the papilla foliata of the rabbit (figs. 170, 171).

Taste-buds have been compared in general form and appearance to the leaf-buds of a plant. They are flask-shaped bodies, the base of the flask resting upon the corium of the mucous membrane and the apex projecting towards the free surface of the epithelium, and emerging between the ordinary flattened surface-

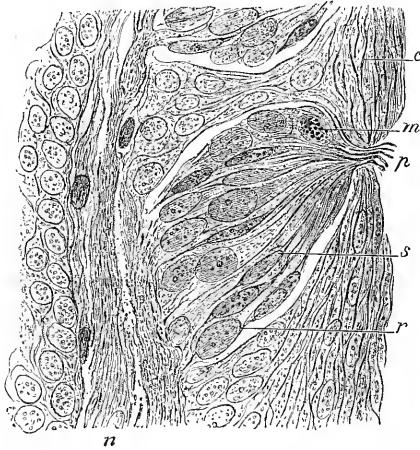


Fig. 171.—SECTION THROUGH ONE OF THE TASTE-BUDS OF THE PAPILLA FOLIATA OF THE RABBIT. (Ranvier.) Highly magnified.

p, gustatory pore ; *s*, gustatory cell ; *r*, sustentacular cell ; *m*, leucocyte containing granules ; *c*, superficial epithelium cells ; *n*, nerve-fibres.

cells of the stratified epithelium. The cells of the stratified epithelium are adapted and applied to the outer surface of the taste-bud and form a sort of adventitious capsule for it. The most superficial cells may even be perforated to allow of the access of the apex of the taste-bud to the free surface. In any case the apex does not quite reach the surface, but is approached from the surface by a small opening, the *gustatory pore*. Into this a bunch of fine hairlets, prolonged from the gustatory cells of the taste-bud, is seen to project.

Every taste-bud contains two kinds of cells termed respectively the *sustentacular* and the *gustatory* cells. The **sustentacular cells** (fig. 172, *b*) are long and spindle-shaped, tapering to either end. They form a complete envelope to the taste-bud, being fitted together like the staves of a barrel : these surface cells are flattened from within out. Other sustentacular cells lie within the taste-bud amongst the gustatory cells, extending from apex to base of the taste-bud.

The **gustatory cells** (fig. 172, *a*) closely resemble in general appearance the olfactory cells of Max Schultze (see p. 141). From the nucleated body of the cell

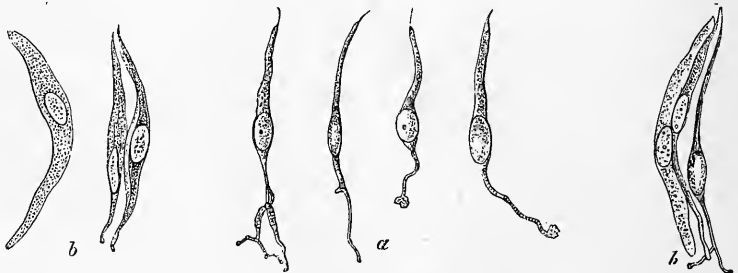


Fig. 172.—CELLS FROM TASTE-BUDS OF RABBIT. (Engelmann.) $\frac{100}{\lambda}$
a, four gustatory cells ; *b*, two gustatory and one sustentacular cell ; *c*, three sustentacular cells.

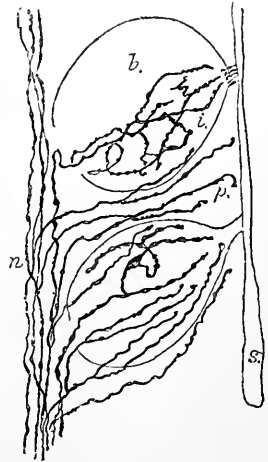
which is somewhat bulged, two processes extend. One, the peripheral, is nearly straight, and passes to the gustatory pore where it ends in a cilium-like projection, the *taste-hair*. The other process, the central one, passes towards the base of the flask: it may be fine and varicose, and is often bifurcated or even further branched, and, according to G. Retzius and Lenhossék, it ends in a free extremity or extremities, and not, as was formerly thought, in continuity with the nerve-fibrils which pass to the taste-bud.

Each taste-bud receives a small bundle of nerve-fibres, derived, at least in the case of those of the papillæ vallatæ, from the glosso-pharyngeal nerve. The nerve-

Fig. 173.—ENDING OF NERVE FIBRES IN AND AROUND TASTE-BUDS OF RABBIT: GOLGI PREPARATION. (G. Retzius.)

fibres lose their medullary sheath as they enter the organ and are continued as axis-cylinders which end by ramifying amongst the gustatory cells (*intrabulbar ramification*, fig. 173, *i*) without, as has been just stated, coming into actual continuity with these cells. A number of nerve-fibrils also pass into the enclosing capsule of stratified epithelium and end by ramifying between the cells of that epithelium (*peribulbar ramification*, fig. 173, *p*). These peribulbar nerves are believed to be nerves of general sensibility and not gustatory.

Section of the glosso-pharyngeal nerves in young animals is followed by atrophy of the taste-buds after some time. The taste-buds of the anterior part of the tongue appear to be supplied by the chorda tympani nerve.



RECENT LITERATURE OF THE GUSTATORY ORGANS.

- Arnstein, C.**, *Die Nervenendigungen in den Schmeckbechern der Säuger.*, Arch. f. mikr. Anat., xxxi., 1893.
- Drasch, O.**, *Untersuchungen über die Papillæ foliate und circumvallatæ der Kaninchen und Feldhasen*, Leipzig, 1887.
- Gmelin**, *Zur Morphologie der Papilla vallata und foliata*, Archiv für mikroskopische Anatomie, xl., 1892.
- Hermann, Friedrich**, *Studien über den feineren Bau des Geschmacksorgans*, Erlangen, 1887; *Sitzungsberichte der math.-physik. Klasse d. k. b. Akad. d. Wissensch.*, München, 1888.
- Hönigschmied, J.**, *Kleine Beiträge, betreffend die Anordnung der Geschmacksknospen bei den Säugethieren*, Zeitschrift für wissenschaftl. Zoologie, Band xlvii., 1888.
- Lenhossék, M. v.**, *Der feinere Bau u. d. Nervenendigungen der Geschmacksknospen*, Anat. Anzeiger, viii. 1893.
- Niemack, J.**, *Der nervöse Apparat in den Endscheiben der Frosch-zunge*, Anat. Hefte, 1892.
- Tuckerman, Frederick**, *Note on the papilla foliata and other taste areas of the pig*, Anatom. Anzeiger, iii., 1888; *Anatomy of the papilla foliata of the human infant*, Journ. of Anat., vol. xxii., 1888; *Observations on the structure of the gustatory organs of the bat*, Journal of Morphology, 1888; *On the gustatory organs of some Edentata*, Internationale Monatsschrift für Anatomie und Physiologie, Band vii., 1890; *The development of the gustatory organs in Man*, Journal of Anatomy, 1889; *Americ. Journal of Psychology*, vol. iii., 1890; *On the gustatory organs of some of the Mammalia*, Journal of Morphology, vol. iv., 1890; *Observations on some mammalian taste-organs*, Journ. of Anat. and Physiol., 1891.

COMPARISON OF THE MODES OF ARRANGEMENT OF SENSORY CELLS AND NERVE FIBRES IN THE DIFFERENT ORGANS OF SPECIAL SENSE.

All the organs of special sense contain specially modified cells or the processes of such cells, the so-called nerve-epithelium cells or sense-epithelium cells which serve to receive the physical impressions upon which the sensation depends, and to transmute these impressions into nerve-impulses which are then conducted by nerve-fibres to a nerve-centre. The skin appears at first sight to present an exception to this general rule, but the ganglion-cells on the posterior roots, which send their peripheral processes in the form of nerve-fibres to end by ramifying in the skin, either in a special tactile organ or between the cells of the

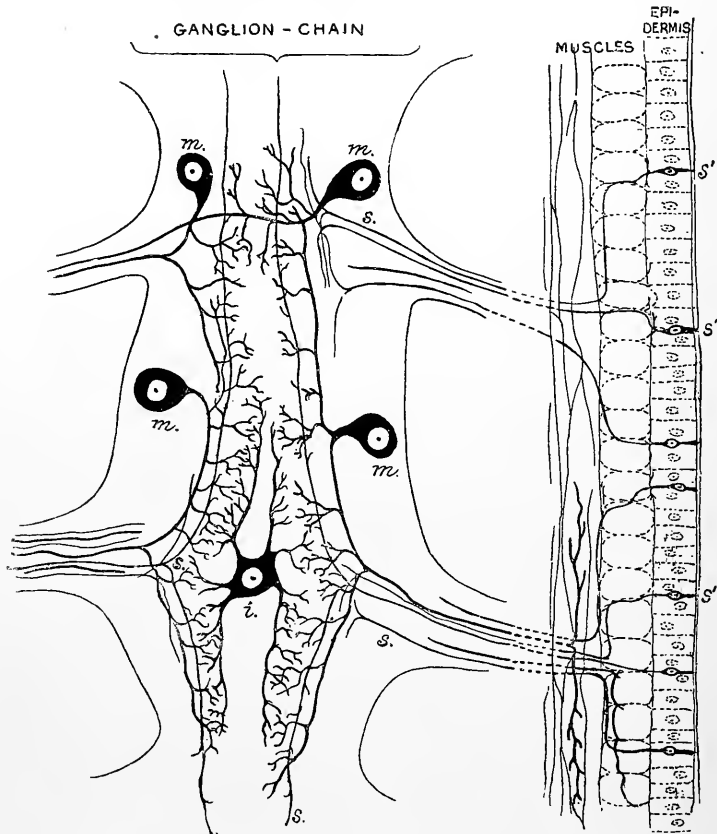


Fig. 174.—DIAGRAM OF THE NERVOUS SYSTEM OF THE EARTHWORM. (E. A. S., after Lenhossék and Retzius.)

m, motor cells; *s*, sensory fibres emanating from *s'*, sensory cells in the epidermis; *i*, median intercalated cell.

epidermis, do in fact represent the sense-epithelium cells such as we find in the olfactory organ and in the retina of the eye. This becomes plain from a comparison of the arrangements of the sensory nerves of Annelids with those of Vertebrates. Thus in the earthworm (*Lumbricus*) the whole epidermis is pervaded by cells (fig. 174, *s'*) which resemble in nearly every particular the olfactory cells of Vertebrates. They are spindle-shaped cells, having two processes, one unbranched and extending straight to the free surface, the other branching, and with one of its branches prolonged as a nerve-fibre to the central nervous system and ending in a forked termination which comes into relation with branches of the nerve-cells there present. As in the olfactory organ the sense-cells are supported by columnar epithelium cells which are not connected with the nerve centre. In other Annelids (*e.g.*, *Nereis*) the sense-cells are no longer situated between the other cells of the epidermis, but occupy a deeper position and send their peripheral process, which is still unbranched, to penetrate between the cells of the epidermis, and thus to reach the surface, whilst the central process

is prolonged towards the central nervous system, where it terminates as in *Lumbricus* (fig. 175). Here, in *Nereis*, the body of the sense-cell, which, since it gives origin to a nerve-fibre or fibres, may be termed the sensory nerve-cell, is beginning to move away from the periphery. In Vertebrata, the only essential difference is that the same cell is further removed from the periphery, and is nearer the central nervous system, viz., in the ganglion of the posterior root. In all vertebrate embryos and in some Vertebrata throughout life, the sensory nerve-cell is a spindle-shaped cell, with a peripheral process extending as the sensory nerve-fibre towards the integument, and a central process, passing by the posterior root into the grey matter of the nerve-centre. In most Vertebrata, the spindle-shaped bipolar character of these sensory nerve-cells becomes lost, owing to the fact that as development proceeds the two processes shift towards one another at their attachment to the cell and ultimately come off from it by a common stem, but this is a mere secondary modification and does not affect the validity of the comparison. In most other sense organs, the sensory cells remain at or near the periphery, and the most important differences between them consist in the relative extent of development of the centrally directed prolongation. In the auditory organ (fig. 176), which is an involuted portion of the integumental surface, the sense-cells are represented by the hair-cells of the maculae and of the organ of Corti. Here a central process is absent, and the connection with the central nervous system is effected by the endings of the auditory nerve enveloping the cell-bodies by a close terminal ramification. These hair-cells of the auditory organ are not in the same category of sensory cells with the

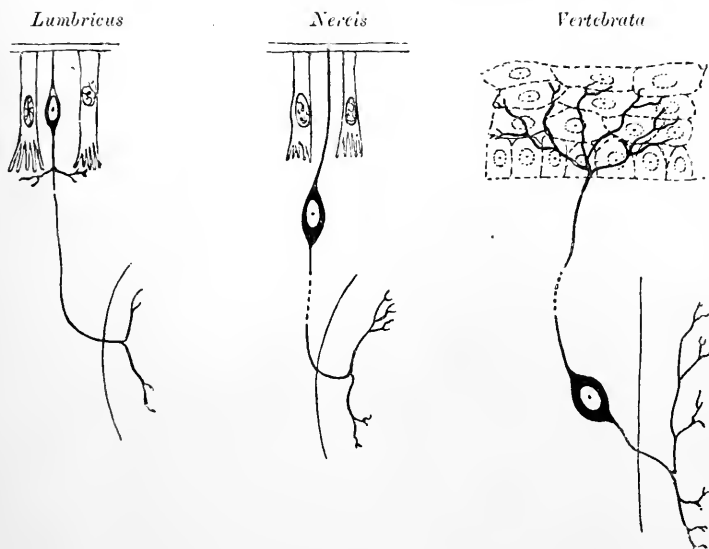


Fig. 175.—DIAGRAMS SHOWING THE RELATIVE POSITION OF THE SENSORY CELL IN LUMBRICUS, NEREIS, AND VERTEBRATA. (After G. Retzius.)

olfactory cells of the nasal membrane or the visual cells of the retina. For they are destitute of a central or nerve-fibre process, and it may be doubted whether they transmute the auditory vibrations into nervous impulses. On the other hand the manner in which the terminations of the auditory nerve-fibres surround or abut against the enlarged deeper ends of these cells suggests the possibility of a mechanical excitation of the nerve-terminations by a direct transmission of the vibrations of the endolymph through the cells in question. If this view be taken, viz., that the hair-cells of the auditory organ are not true nerve-epithelium cells, but only ordinary epithelium cells somewhat modified for the transmission of mechanical impulses, then it will follow that the terminal sensory cells are to be looked for in the cells of the spiral ganglion of the cochlea and in the cells in the vestibular branch of the auditory nerve. These are bipolar cells having a peripheral process ending as we have seen in contact with the hair-cells, and a central process (auditory nerve fibre) ramifying in the grey matter of the nerve-centre. There will thus be a close analogy as regards nerve-ending between the auditory and tactile organs. With regard to the gustatory organ our knowledge is still imperfect. It has usually been supposed hitherto that the central processes of the gustatory cells are prolonged into nerve-fibres, and if this were the case, these cells would come into the same category with the olfactory cells of the nasal mucous membrane. But according to the most recent observa-

tions the central process of the gustatory cell is not continuous with a fibre of the glosso-pharyngeal nerve, and the connection of the gustatory cells with the fibres of that nerve is

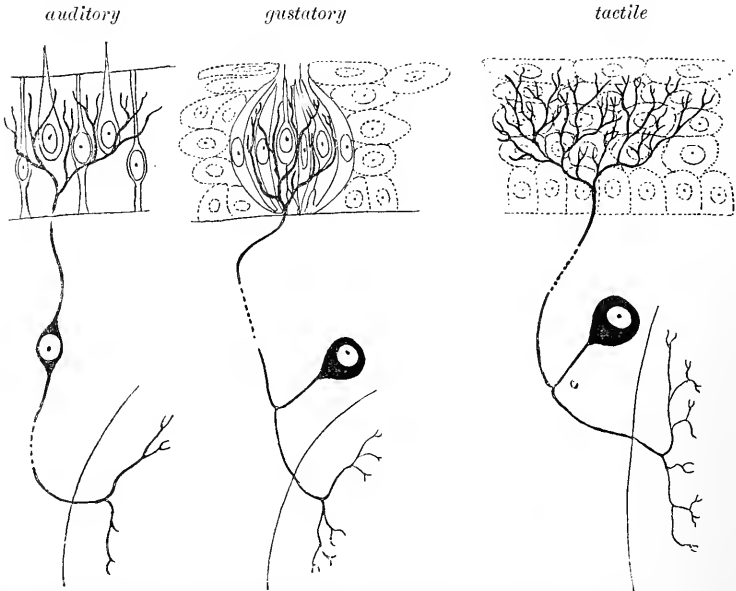


Fig. 176.—DIAGRAM SHOWING THE MODE OF TERMINATION OF SENSORY NERVE FIBRES IN THE AUDITORY, GUSTATORY, AND TACTILE STRUCTURES OF VERTEBRATA. (After G. Retzius.)

indirect and not by continuity. If this is so, the arrangement in the gustatory organ would appear to be somewhat similar to that which obtains in the general integument and in the auditory organ (fig. 176).

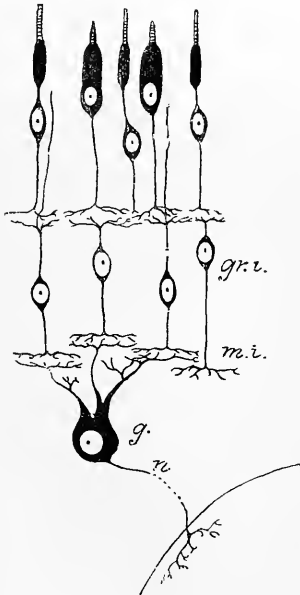


Fig. 177.—DIAGRAM OF THE CONNEXIONS OF THE RETINAL ELEMENTS. (After G. Retzius.)

gr.i., inner granules; *m.i.*, inner molecular layer; *g.*, ganglion cell; *n.*, its nerve fibre process or neuron ramifying in the nerve centre.

The retina of the eye, as its development shows, is rather to be regarded as an extension of the central nervous system than a peripheral organ. It is composed of nerve-elements (nerve-cells) which are arranged in three tiers (fig. 177). Those which are placed most peripherally are the visual cells or rod- and cone-cells, which resemble the general type of sensory cells in consisting of a nucleated enlargement or cell-body (outer granule) with a specially modified peripheral process (rod or cone), and a centrally directed ramified (nerve-fibre) process (rod- or cone-fibre). In the case of the cone-elements the peripheral process has been shown to be contractile, since it shortens under the excitation of light (see p. 50). It is usually believed that in these peripheral processes the nerve-impulses are produced and that the impulses are thence conducted centrally by the central or nerve-fibre process (rod- or cone-fibre), and by it transmitted to the next tier of cells. The second tier of nervous elements is afforded by the layer of inner granules. Here there are bipolar nerve-cells, the peripheral processes of which interlace with the central processes of the rod- and cone-cells, but one peripheral fibre (fibre of Landolt) extends in most vertebrates beyond the rest and comes to lie between the bodies of the rod- and cone-cells. The central processes of the bipolars interlace with the peripheral processes of the cells of the next tier.

Lastly, the third tier of nervous elements is formed by the ganglion-cells of the retina whose peripheral dendritic processes interlace with the central processes of the inner granules and whose centrally directed processes are fibres of the nerve and have their central optic terminations in the grey matter of the general nerve-centres.

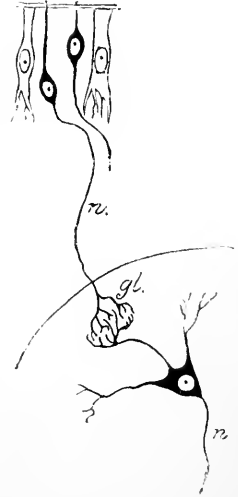The comparison of the elements of the retina with those of the other sense organs is not easy. If we compare the retina with the olfactory organ, we are at a loss to say whether we are to place the rod- and cone-cells along with the olfactory cells, as in making this comparison is most frequently done, or whether we should not rather look upon the bipolar inner granules as the homologues of those elements. In the latter case we should be led to suppose that the nervous impulses originate in the peripheral process of the inner granules.

Fig. 178.—DIAGRAM OF THE ARRANGEMENT OF THE SENSORY NERVE-FIBRES IN THE OLFACTORY ORGAN AND BULB. (After G. Retzius.)

being there set up by a stimulation received from the rod- and cone-cells. And it is further open to us to suppose this stimulation to be a mechanical one caused by the contraction of the rod- and cone-elements under the influence of light. If on the other hand we regard the rod- and cone-elements as representing the olfactory cells, there appears to be no structure in the olfactory apparatus homologous with the tier of inner granules of the retina. A comparison of the retina with the remaining sense-organs is also easier on the assumption that the inner granules represent the actual sensory cells in which nervous impulses originate in response to stimulation set up through the rod- and cone-elements.

The connections of the olfactory cells (fig. 178) more nearly resemble the primitive arrangement of sensory structures which occurs in *Lumbricus*, than is the case in any other of the sense organs. For here, as in the epidermis of *Lumbricus*, the sensory nerve-cells are at the free surface, lying between and supported by columnar epithelium cells. And the sensory nerve-fibres are a direct prolongation of the fixed ends of the olfactory cells, passing to the nerve centre and there becoming interlaced with the processes of the nerve-cells of the centre. The nature of the olfactory excitation, whether mechanical, chemical, or otherwise, is not known, but whatever it be, we must assume that its result is to set up nervous impulses within the olfactory cells, and that these impulses are then propagated along the fibres of the olfactory nerve to the olfactory bulb: where, within the olfactory glomeruli, they are somehow transmitted to the dendritic processes of the mitral cells, through the nerve-fibre processes of which they are again passed on to other parts of the brain.

It will therefore be seen that all the sense-organs have this in common, viz., a bipolar sensory nerve-cell having (1) a peripheral process extending towards the surface and penetrating between more or less modified epithelium-cells which cover that surface, and (2) a central process which is in all cases recognizable as a nerve-fibre and the terminal ramification of which interlaces with ramifications of nerve-cells within a nerve-centre. The chief differences occur in the greater or less special modification of the epithelium-cells between which the peripheral processes penetrate, such modification being very considerable in the visual organ, less in the auditory and gustatory organs, very slight in the olfactory organ, and absent in the case of the general integument.



INDEX AND GLOSSARY TO VOL. III., PT. III.

ADITUS ad antrum (approach to antrum), 80
 Adventitia oculi, 11
 Agger (mound) nasi, 138
 Ala (wing) of nose, 130, 132
 Amaerine (α priv. μακρός, long; ἴς, ἴνος, fibre)
 cells, 41, 44, 52, 57
 Amphibia, retinal cells of, 44
 end-knobs of retina of, 46
 lagenae of, 114
 olfactory cells of, 142
 rods and cones of, 49
 taste-organs of, 149
 Ampulla (flask-shaped vessel) of semicircular
 canals, 100, 105, 108, 110
 Anderson, on dilatator iridis, 33
 Angle, of eye, 1
 naso-facial, 130
 Annelids, sensory cells and nerves of, 152
 Annular ligament, 83
 Annulus fibrosus, 82
 Ansmatics (α priv. δσμάομαι, smell), 130
 Anterior chamber of eye, 21, 22, 66
 homogeneous lamina of cornea, 19
 hyaline layer of iris, 33
 limiting layer of iris, 33
 Anthelix (*ἀντι*, opposite to; helix), 72
 Antitragus, 71
 muscle of, 75
 Antrum (cave), mastoid, 80, 84
 maxillary, 136, 139
 Aqueduct of cochlea, 104
 Fallopian, 83
 vestibule, 99, 105
 Aqueous humour (*humor*, liquid), 11, 55, 66
 Arch, tarsal, 5
 Arcus senilis, 19
 Area centralis retinae, 54
 Arteria centralis retinae, 38, 55, 59, 65
 Arteries or Artery, auditory, internal, 109
 auricular, 76, 79, 83
 central of retina, 38, 55, 59, 65
 of choroid coat, 36, 55
 ciliary, 13, 15, 16, 26, 29, 33
 of cochlea, 126
 of conjunctiva, 5, 16
 of cornea, 22
 ethmoidal, 144
 of Eustachian tube, 88
 of eyelids, 5
 of external auditory canal, 79
 of iris, 33
 of labyrinth, 109
 of lens, 65
 of lachrymal gland, 8
 mandibular, 91
 of membrana tympani, 82
 nasal, 144
 of nasal duct, 10
 fossae, 144
 naso-palatine, 144
 of nose, 131

Arteries—*continued*.
 of optic nerve, 16, 55
 palatine, 144
 palpebral, 5, 16
 papillary, 55
 of pinna, 76
 of retina, 36, 55
 of sclerotic coat, 16, 55
 of septum nasi, 144
 spheno-palatine, 144
 stapedial, 91
 of tympanic membrane, 97
 of tympanum, 97
 Atrium (hall) of middle meatus, 138
 Auditory artery, internal, 109
 canal, external. *See* CANAL.
 epithelium, 105
 hairs, 110, 112
 meatus, external. *See* CANAL.
 internal, 102, 124
 nerve, 99, 104, 108, 124, 152
 ossicles, 89, 96
 movements of, 95
 Auricle, 71
 Auricular artery, 76, 79, 83
 nerve, 76, 79, 83
 Auriculo-temporal nerve, 76, 79, 83
 Axis of eye, 11
 Axis-ligament of malleus, 93

BACILLARY layer of retina, 38, 46
 Ball of eye. *See* GLOBE.
 Basal cells, 45
 Basilar membrane, 113, 116, 119, 127
 cells, 121
 Berger on zonula of Zinn, 62
 v. Bezold on external auditory canal, 77
 Bibliography. *See* LITERATURE.
 Bipolar cells, 41, 45, 52, 109, 124, 153, 154, 155
 Birds, bipolar cells of retina of, 44
 ciliary muscle of, 30
 cochlea of, 102
 dilatator iridis of, 33
 end-knobs of retina of, 46
 epithelium of semicircular canals of, 110
 fovea centralis of, 54
 lagenae of, 114
 olfactory cells of, 142
 retinal cones of, 49
 Blood-vessels. *See* ARTERIES; VEINS.
 Body, ciliary, 15, 29, 62, 66
 vitreous, 11, 38, 58
 Bones or bone, small, of ear, 89
 of stapedius muscle, 94
 tympanic, 79
 Bowman, corneal tubes of, 18
 glands of, 140
 membrane of, 19
 Bruch, membrane of, 29
 v. Brunn, on olfactory cells, 142

- Brunner, on articulations of auditory ossicles, 91
 Bulla (boss) ethmoidalis, 136
 Bundle, ciliary, 2
- CAJAL, on amacrine cells, 45
 bipolar cells of retina, 43
 gauglionic layer of retina, 41
 horizontal cells, 15
- Canal or canals, carotid, 87, 89
 central, of modioli, 102, 124
 of chorda tympani, 98
 of cochlea, 113, 118, 127
 Eustachian, 86
 external auditory, 76, 81
 of infant, 79
 nerves of, 79
 structure of, 78
 vessels of, 79
 of Jacobson's nerve, 98
 lachrymal, 7, 8, 10
 membranous of cochlea, 104
 membranous semicircular, 105
 nasopalatine, 138
 of Petit, 59, 62, 66
 of Recklinghausen, 18
 of Schlemm, 21, 34, 66
 semicircular, 98, 99, 100, 105, 109
 spiral of cochlea, 102
 of modioli, 104, 124
 of Stensen, 138
 of Stilling, 38, 59
 of tensor tympani muscle, 86, 94
- Canaliculus lacrimalis, 1
 Canalis hyaloideus, 59
 incisivus, 138
 membranaceus, 113
 reuniens, 105, 114
 utriculo-saccularis, 105
- Canthus (tire of wheel), 1
 Capitulum (dim. of *caput*, head) of malleus, 89
 Capsule of lens, 34, 59, 62, 63, 65
 of Tenon, 11
- Carotid canal, 87, 89
 Cartilage of Eustachian tube, 87
 of external auditory canal, 78, 80
 of Jacobson, 133, 144
 lateral, of nose, 131
 of nasal aperture, 131, 132
 of Meckel, 90, 91
 of pinna, 73, 80
 of septum nasi, 132
 tarsal, 2. *See also* TARSUS.
 vomarine, 133, 144
- Cartilagine epactiles (*ἐπακτές*, intercalary), 132
 minores vel quadratæ, 132
- Caruncula (dim. of *caro*, flesh) lacrimalis, 2, 10
 Cat, dilatator iridis of, 33
 Caudal process, 74
 Cells, basilar, 121
 of Claudius, 122
 of Deiters, 121, 127
 ethmoidal, 135, 136, 139
 ganglionic, 150, 153
 of Hensen, 122
 mastoid, 84, 96
 nerve-epithelium, 152
 olfactory, 141, 154
 sense-epithelium, 152
 tympanic, 81
 visual, 46, 154
- Central artery of retina, 38, 55, 59
 canal of modioli, 102, 124
 Cerumen (*cera aurium*, wax of ears), 79
 Ceruminous glands, 73, 79
 Chamber, anterior, of eye, 21, 22, 66
 posterior of eye, 66
 Chievitz, on fovea centralis, 54
 Choanæ (*χοάνη*, funnel), 130
 Chorda (string) tympani nerve, 81, 96, 98, 151
 Choroid (correctly chorioid, from *χόριον*, mem-
 brane) coat, 11, 13, 14, 16, 23, 30, 53
 structure of, 24
 nerves of, 34
 Cilia (*cilium*, eyelid, eyelash), 4
 Ciliary arteries, 26, 29, 33
 body, 15, 24, 29, 62, 66
 bundle, 2
 glands, 29, 55, 62, 66
 ligament, 30
 muscle, 20, 30
 circular, 30
 nerves, 13, 15, 16, 26, 29, 55
 processes, 23, 24, 29, 54, 60
 vessels, 13, 15, 16, 26, 29, 55
 Circular ciliary muscle, 30
 Circulus major, 33, 34
 minor, 33
 Zinnii, 16
 Claudius, cells of, 122
 Cleft, olfactory, 134
 Coat, choroid, 11, 13, 14, 16, 23, 30, 53
 sclerotic, 11, 13, 14, 30
 vascular, of eye, 23
 Cochlea (snail), 83, 98, 101, 108
 canal of, 113, 118, 127
 measurements of, 127
 membranous, 98, 104, 112
 vessels of, 126
 Cochlear nerve, 108, 114, 124
 Cochleariform (*cochleare*, spoon; *forma*, shape)
 process, 86, 94
 Collienus (dim. of *collis*, hill) nervi optici, 36
 Colosanti, on Meibomian glands, 4
 Columella (dim. of *columna*, pillar) cochleæ, 102
 Columna nasi, 130, 132
 Comparison of different sensory nerves and cells,
 152
 Concha (mussel shell) of ear, 71
 Conchæ, ethmoidal, 135, 136
 Cone-bipolar cells, 43
 Cone-fibre, 46, 53, 57, 154
 Cone-foot, 47
 Cone-granules, 46
 Cones of retina, 46, 47, 50, 52, 54, 57, 154
 Conjunctiva (*conjungit palpebras eum oculo*), 1,
 4, 10, 11
 arteries of, 16
 bulbi, 4, 16
 palpebrarum, 4, 11
 veins of, 17
 Cornea (*corneus*, horny), 11, 13, 14, 17
 structure of, 17
 vessels and nerves of, 22
 Corneal corpuscles, 18, 23
 tubes, 18
 Corpus ciliare, 15, 24, 29, 62, 66
 Corpuscles of cornea, 18, 23
 vitreous body, 59
 Crista (crest) acustica, 107, 110
 vestibuli, 99
 Crura (*eris*, leg) of incus, 90
 of stapes, 91

Crystalline lens. *See* LENS.

Cupola, 102

Cupula (vault) terminalis, 112

DARWIN, tubercle of, 72

Deiters, cells of, 121, 127

Demours, membrane of, 19

Denissenko, on retina of eel, 46

Descemet, membrane of, 19, 22

Diameters of cornea, 17

of eyeball, 14

Dilatator conchæ, 75

pupillæ, 32

tubæ, 87

Dimensions. *See* MEASUREMENTS.

Disc, optic, 38

Divisions of auditory nerve, 108

Dog, orifice of nasal duct of, 10

Dogiel, on spongioblasts, 44

Drum of ear, 80

Duct, nasal, 7, 9, 138, 145

Ductus cochlearis, 113

endolymphaticus, 99, 105

naso-pharyngeus, 138

EAR, 71

external, 71

index of, 72

internal, 98

literature of, 127

middle, 80

ossicles of, 89

Ear-point, 72

Earthworm, sensory cells and nerves of, 152

Eel, vessels of retina of, 46

Eighth nerve. *See* AUDITORY NERVE.

Elastic lamina, posterior, 17, 19

Ellipsoid, 49

Eminentia papillaris, 85

End-bulbs of conjunctival nerves, 16

End-knob, 46

Endolymph, 98, 104, 113, 152

Endothelium of cornea, 17, 20, 22

lamina suprachoroidea, 25

ligamentum pectinatum, 21

sclerotic coat, 16

Tenon's capsule, 11

zonula of Zinn, 62

Epiglottis, 149

Episcleral (*ἐπί*, upon; sclerotic) plexus of veins,

17

Epithelium, of ampullæ, 110

auditory, 105

of conjunctiva, 16

of cornea, 17, 22

of Eustachian tube, 87, 96

of iris, 31, 66

of lens capsule, 66

of limbus, 116

of mastoid cells, 96

of membrane of Reissner, 118

of membranous cochlea, 113

of nasal fossæ, 139

nerve —, 152

olfactory, 140, 141

of organ of Corti, 117, 119, 126

of organ of Jacobson, 144

of retina, 46, 50, 54

of semicircular canals, 109, 110

Epithelium—*continued*.

sense —, 152

of tympanum, 96

Ethmoidal arteries, 144

bullæ, 136

cells, 135, 136, 139

conchæ, 135, 136

fissure, 135, 136

Eustachian canal, 86

cartilage, 87, 96

tube, 80, 81, 86, 94, 96

muscles of, 88

vessels and nerves of, 88

Ewart, on lens fibres, 65

External auditory canal. *See* CANAL.

ear, 71

palpebral arteries, 5

Eye, 1

axes of, 11

chambers of, 21, 22, 66

choroid coat of, 23

coverings of, 1

globe of, 10

lens of, 63

literature of, 67

measurements of, 14, 17, 63

retina of, 35

sclerotic coat of, 13

suspensory ligament of, 12

vitreous humour of, 58

Eyelashes, 4

Eyelids, 1, 2, 10

lymphatics of, 6

nerves of, 7

smooth muscle of, 4

structure of, 2

vessels of, 5

FALLOPIUS, aqueduct of, 83

Fascia (band), palpebral, 2, 3

salpingo-pharyngea, 87

Fat, orbital, 10, 11

Fenestra (window) ovalis, 83, 91, 95, 99

rotunda, 83, 95, 104

Fibre-cells, 111

Fibres of lens, 64

of Müller, 39, 41, 50, 54

radial, 50

Fibril of Landolt, 44, 57, 154

Fibrous tympanic plate, 79

Fimbria (fringe) linguæ, 148

Fingered cells, 17

Fishes, epithelium of semicircular canals of,

110

lagena of, 114

olfactory cells of, 142

rods and cones of, 49

taste-organs of, 149

Fissure, ethmoidal, 135, 136

of Glaser, 81, 90

petroso-squamosal, 84

petro-tympanic, 81

Fissures of Santorini, 74, 80

Fold, naso-pharyngeal, 138

salpingo-palatine, 87

salpingo-pharyngeal, 87

Folds, tympano-malleolar, 82

Fontana, spaces of, 21, 66

Foramen centrale, 102

incisor, 138

single (solitary), 108

- Fornix (arch, vault) conjunctivæ, 1, 8
 Fossa (ditch) of anhelix, 72
 of helix, 72
 nasal, 130, 133
 mucous membrane of, 139
 patellaris (*patella*, small dish), 58
 of Rosenmüller, 87
 scaphoidea, 72
 triangularis, 72
 Fossula (dim. of *fossa*) cochleæ, 102
 ovalis, 83
 rotunda, 83
 Fovea (pit) centralis retinæ, 15, 35, 40, 44, 52, 55
 externa, 53
 hemielliptica, 99, 104
 hemispherica, 99, 105, 108
 Frog, bipolar cells of retina of, 44
 retinal cones of, 50
 retinal rods of, 49
 Frontal sinus, 136, 139
 Fundamental nerve-plexus of cornea, 22
 Fungiform papillæ, 148
 Funiculus (dim. of *fumis*, cord) scleræ, 17
- GANGLION of Corti, 108
 nervi optici, 38, 40, 57
 of nerve of tensor tympani, 94, 98
 retinæ, 38, 41, 154
 of Scarpa, 108
 spirale, 109, 124, 152
 Ganglionic layer of retina, 40, 52, 54, 57
 Ganoidei, retinal cones of, 49
 Giacomini on plica semilunaris of negro, 2
 Giant-cells of retina, 41
 Glands of Bowman, 140
 ceruminous, 73, 79
 ciliary, 29, 55, 62, 66
 Harderian, 5
 lacrimal, 7, 8
 inferior, 7
 Meibomian, 2, 3
 of Moll, 4
 of nasal duct, 10
 tarsal, 3
 posterior, 4
 of tympanum, 96
 Glandula lacrimalis inferior, 7
 Glandulæ ceruminosæ, 79
 Glaser, fissure of, 81, 90
 Globe of eye, 1, 10
 diameters of, 14, 15
 dimensions of, 1, 10, 14
 Glomeruli, olfactory, 142
 Granules, inner, 41, 52, 57, 154
 myeloid, 50
 outer, 46, 52, 154
 pigment, of retina, 50
 Groove, spiral, 115
 Guinea-pig, cells of Hensen of, 122
 olfactory epithelium of, 141
 organ of Jacobson of, 144
 Gustatory cells, 150, 153
 organs, 148
 literature of, 151
 pore, 150
- HAINS, auditory, 110, 112
 olfactory, 142
 Hair-cells, 110, 119, 121, 127, 152
- Hamulus (small hook), 103
 Handle of malleus, 82, 90
 Hannover on funiculus scleræ, 17
 Harderian gland, 5
 Helicotrema (Ἑλιξ, spiral; πρήμα, hole), 102
 Helix, 72
 muscles of, 75
 spine of, 74
 Henle on bacillary layer of retina, 50
 on smooth muscle of eyelid, 4
 Hensen, cells of, 122
 on hair-cells, 122
 Hexagonal cells of retina, 24, 35, 38, 50
 Hiatus (opening, from *hio*, open) Fallopii, 97
 semilunaris, 136, 138
 Homogeneous lamina of cornea, 19
 Horizontal cells, 45, 57
 Humour (*humor*, liquid) aqueous, 11, 54, 66
 vitreous, 11, 38
 Hyaline layers of iris, 33
 Hyaloid membrane, 53, 58, 59
- INCISOR foramen, 138
 Incisura (notch) Rivini, 81, 82
 terminalis, 74
 Incus (anvil), 80, 89, 90, 91, 95
 ligaments of, 85, 93
 Index, of ear, 72
 nasal, 131
 Infundibulum (funnel), 135
 Internal auditory meatus, 102, 124
 ear, 71, 98
 palpebral artery, 5
 Intrabulbar nerves, 151
 Intrinsic ligaments of pinna, 74
 muscles of pinna, 75
 Iris (rainbow), 11, 15, 20, 23, 31
 muscular tissue of, 32
 nerves of, 34
 pillars of, 21
 vessels of, 33
 Isthmus tubæ, 87
 Iter chordæ anterioris, 84, 98
 posterioris, 98
- JACOBSON, cartilages of, 133, 144
 nerve of, 97
 organ of, 133, 143
- KRAUSE on glands of tympanum, 96
- LABIUM tympanicum, 115
 vestibulare, 115
 Labyrinth, 71, 98
 membranous, 98, 104
 osseous, 98, 99
 Lacrymal (*lacrima*, tear) apparatus, 7
 canals, 7, 8, 10
 gland, 7, 8
 inferior, 7
 reservoir, 1
 sac, 7, 9
 Lacus (reservoir) lacrimalis, 1
 Lagena (flagon), 114

- Lamellæ (dim. of *lamina*, plate) of cornea, 18
 Lamina, anterior homogeneous, of cornea, 19
 eribrosa (*cribrum*, sieve), 15
 fusca (dark), 13, 16
 posterior elastic, of cornea, 17, 19
 reticularis, 119, 121, 122
 spiralis, 102, 103, 113, 124
 secondary, 103
 suprachoroidea, 24, 53
 Laminae of lens, 64
 Landolt, fibril of, 44, 57, 154
 Langley on dilatator iridis, 33
 Lateral recess of pharynx, 87
 sinus, 85
 Laxator tympani muscle, 92
 Layer, of horizontal cells, 45
 outer fibrous, of retina, 53
 Layers of retina, 38, 52, 54, 56
 Leber on canal of Schlemm, 22
 Lenhossék on gustatory cells, 151
 Lens, 11, 14, 31, 63
 capsule of, 34, 59, 62, 63, 65
 changes with age of, 66
 fibres of, 64
 structure of, 64
 suspensory ligament of, 59
 Levator palati muscle, 88
 palpebræ muscle, 1, 2, 3
 Leydig on taste-organs of fishes, 149
 Lid of eye. *See* EYELID.
 Ligaments or ligament, annular, 83
 of auditory ossicles, 92
 of capsule of Tenon, 11
 ciliary, 30
 of incus, 85, 93
 of malleus, 92
 palpebral, 2, 3
 of pinna, 74
 spiral, 113, 117, 119
 suspensory of eye, 12
 of lens, 24, 31, 59
 tarsal, 2, 3, 10
 tympano-malleolar, 82
 Ligamentum pectinatum (*pecten*, comb), 21,
 30, 66
 suspensorium oculi, 12
 Limbus (sill, border) luteus, 35
 of spiral lamina, 115, 127
 Limen (threshold) vestibuli, 139
 Limiting layers of iris, 33
 Liquor Cotunnii, 98
 Morgagni, 66
 Literature of ear, 127
 of eye, 67
 of gustatory organs, 151
 of nose, 146
 Lobule, 71, 74
 Lockwood on capsule of Tenon, 12
 Locus luteus, 140
 Long ciliary arteries, 33
 Lumbricus, sensory cells and nerves of, 152
 Lymphatics of conjunctiva, 16
 of cornea, 22
 of external auditory canal, 76, 81
 of eyelid, 6
 of nasal fossæ, 145
 of nose, 131
 of pinna, 76
 of tympanic membrane, 83
 Lymph-spaces of olfactory nerves, 145
 of optic nerve, 56, 59
 perichoroidal, 13, 25, 66
 Lymph-spaces—*continued*.
 perivascular, 26, 56
 of retina, 56
 of Tenon's capsule, 11, 25
 Lizard, bipolar cells of retina of, 44
 MACROSMATICS (*μακρός*, large; *ὀσμάματα*, smell),
 130, 137, 141
 Macula (spot) acustica utriculi, 105, 112
 lutea (yellow), 35, 40, 47, 52, 55
 neglecta, 105
 Maier, sinus of, 9
 Malleus (hammer), 80, 81, 82, 89, 91, 92, 94,
 95, 98
 ligaments of, 92
 Mammals, end-knobs of retina of, 46
 rod-ellipsoid of, 49
 Mandibular artery, 91
 Manubrium (handle) mallei, 82, 90
 Marginal fasciculus, 2
 plexus, 7
 Marsupials, retinal cones of, 49
 Mastoid antrum, 80, 84
 cells, 84, 96
 Maxillary antrum, 136, 139
 concha, 135
 Measurements of coats of eye, 14
 of cochlea, 127
 of cornea, 14, 17
 of globe of eye, 14
 of lens, 63
 of nasal fossæ, 134
 of tympanum, 80
 Meatus (passage), auditory, external. *See* CANAL.
 internal, 102, 124
 of nose, 135, 138
 Meckel, cartilage of, 90, 91
 Meibomian glands, 2, 3
 Membrana fenestrata, 45
 flaccida, 82, 96
 limitans of pituitary membrane, 141
 of retina, 38, 51, 52
 nictitans (*nicto*, wink), 2
 tympani, 78, 79, 81, 90, 93, 95, 96, 98
 Membrane, basilar, 113, 116, 119, 127
 of Bowman, 19
 of Bruch, 29
 of Denours, 19
 of Descemet, 19, 22
 hyaloid, 53, 58, 59
 papillary, 34, 66
 pituitary, 139
 of Reissner, 113, 118, 127
 Schneiderian, 139
 secondary, of tympanum, 83, 95, 104
 tectorial, 120, 123, 127
 Membranous cochlea, 98, 104, 112
 labyrinth, 98, 104
 semicircular canals, 105
 Microsmatics (*μικρός*, little; *ὀσμάματα*, smell),
 130
 Middle ear, 71, 80
 Modiolus (navel of wheel), 101, 102, 124
 Molecular layer, inner, 38, 41, 43, 44, 52, 54, 57
 outer, 38, 43, 45, 47, 52, 57
 Moll, glands of, 4
 Monotremes, lagena of, 114
 Müller on bacillary layer, 50
 fibres of, 39, 41, 50, 54
 on spheno-maxillary muscle, 4

- Muscles or Muscle, of antitragus, 75
 ciliary, 20, 30
 circular, 30
 dilatator conchæ, 75
 pupillæ, 32
 tubæ, 87
 of Eustachian tube, 88
 of eyelid, 2, 3, 4, 9, 10
 of helix, 75
 laxator tympani, 92
 levator palati, 88
 of pinna, 75
 pyramidalis, 75
 of Riolan, 2
 salpingo-pharyngeus, 89
 smooth, of iris, 32
 of capsule of Tenon, 11
 spheno-maxillary, 4
 sphincter pupillæ, 32
 stapedius, 85, 94, 95, 98
 tensor choroideæ, 30
 tensor palati, 87, 88
 tensor tarsi, 9, 10
 tensor tympani, 81, 86, 93, 94, 95, 98
 of tragus, 75
 transverse, of pinna, 75
 of tympanum, 93
 Myeloid granules, 50
- NARES, anterior and posterior, 130
 ventricle of, 139
- Nasal arteries, 144
 duct, 7, 9, 10, 138, 145
 fossæ, 130, 133
 measurements of, 134
 mucous membrane of, 134
 vessels of, 144
 index, 131
- Naso-facial angle, 130
 Naso-palatine artery, 144
 canal, 138
- Naso-pharyngeal fold, 138
 Naso-turbinal, 138
 Negro, plica semilunaris of, 2
- Nereis, sensory cells and nerves of, 152
 Nerve-epithelium cells, 151
 Nerve-fibre layer of retina, 38, 52, 54, 57
- Nerves or nerve, auditory, 99, 104, 108, 124, 152
 auricular, 76
 chorda tympani, 81, 96, 98, 151
 of choroid, 31, 34
 ciliary, 13, 15, 17, 22, 34
 of cochlea, 108, 114, 124
 of conjunctiva, 16
 of cornea, 22
 of Eustachian tube, 88
 of external auditory canal, 79
 of eyelid, 7
 intrabulbar, 151
 of iris, 34
 of Jacobson, 97
 of lachrymal gland, 8
 of nasal duct, 10
 fossæ, 143
 of nose, 131
 olfactory, 140, 142
 optic, 10, 11, 15, 16, 35, 39, 47, 55, 56, 57
 peribulbar, 151
 petrosal, 97
 of pinna, 76
 of retina, 39
- Nerves—*continued*.
 of sacculæ, 108
 of sclerotic, 17
 of taste-buds, 151
 of tympanum, 81, 83, 97
- Neuroglia-cells, 40
 Neurospongium, 41
- Nose, 130
 cartilages of, 131
 literature of, 146
 septum of, 130, 142, 145
 vessels and nerves of, 131
- Notch of Rivinus, 81, 82, 93
- Nuclear layer, inner, 38, 41, 54, 57
 outer, 38, 46, 53, 54
 zone of lens, 65
- Nucleus of lens, 63
- OBLIQUE muscle of pinna, 75
- Ocular conjunctiva, 5
 Oil-globule of retinal cones, 49
- Olfactory cells, 141, 154
 cleft, 134
 epithelium, 140, 141
 glomeruli, 142
 hairs, 142
 mucous membrane, 140
 nerves, 140, 142
 organs, 131
 literature of, 146
- Optic disc, 38
 nerve, 10, 11, 15, 16, 35, 47, 55, 56, 57
 papilla, 55, 59
 vesicle, primary, 50
- Ora serrata (notched edge), 35, 54
- Orbicularis palpebrarum muscle, 2, 3, 9, 10
- Organ of Corti, 119, 126
 of Jacobson, 133, 143
- Os orbiculare s. lenticulare, 91
- Osseous labyrinth, 98, 99
- Ossicula auditus, 89, 96
 movements of, 95
- Ostium (entrance) pharyngeum, 87
 tympanicum, 86
- Otoconia (*ὄττος*, *ἄττος*, ear; *κόκκα*, dust), 105
- Otoliths (*ὄττος*; *λίθος*, stone), 105, 112
- Otter, dilatator iridis of, 33
- Outer fibrous layer of retina, 53
- Ox, ligamentum pectinatum of, 21
- PALATE, soft, 149
- Palatine artery, 144
- Palpebræ (eyelids), 1
- Palpebral arteries, 5, 16
 conjunctiva, 4
 fascia, 2, 3
 ligament, 2, 3
- Papilla (nipple) foliata, 149
 fungiform, 148
 lacrimalis, 1, 9
 optici, 55, 59
 vallatæ (*vallum*, rampart), 148
- Papillary arteries, 55
- Pars choroidealis iridis, 31
 ciliaris retinæ, 35, 54, 60
 iridica retinæ, 31, 35, 54
 lacrimalis, 9
 retinalis iridis, 31
- Peribulbar nerves, 151

- Perilymph, 98, 104, 113
 Perivascular lymph-space, 26, 56
 Petit, canal of, 59, 62, 66
 Petrosal artery, 97
 nerves, 97
 Petroso-squamosal fissure, 84
 Petro-tympanic fissure, 81
 Phalangeal process, 122
 Phalanges, 122
 Pharynx, 148
 lateral recess of, 87
 Pigment granules, 50
 Pigmentary layer of retina, 38, 50, 52, 53, 54
 Pillars of iris, 21
 Pinna, 71
 ligaments of, 74
 muscles of, 75
 nerves of, 76
 structure of, 72
 vessels of, 76
 Pituitary (*pituita*, phlegm or mucus) membrane, 139
 Planum semilunatum, 108
 Plate, fibrous tympanic, 79
 Plexiform layer of retina, 41
 Plexus annularis, 22
 episcleral venous, 17
 fundamental nervous, of cornea, 22
 marginal, 7
 subepithelial nervous, of cornea, 22
 tympanic, 83, 97
 venous, of nasal fossæ, 140, 145
 Plica (fold) semilunaris, 2, 10
 Pore, gustatory, 150
 Porus (passage) opticus, 36
 Post-tarsal veins, 6
 Posterior chamber of eye, 66
 elastic lamina, 19
 hyaline layer of iris, 33
 limiting layer of iris, 33
 tarsal glands, 4
 Pouches of tympanum, 96
 Pretarsal veins, 6
 Primary optic vesicle, 50
 Process, caudal, 74
 phalangeal, 122
 Processes, ciliary, 23, 24, 29, 54, 60
 of incus, 90
 of malleus, 90
 Processus brevis, 90
 cochleariformis, 86, 94
 Folianus, 90
 gracilis (slender), 90, 92
 lenticularis (dim. of *lens*), 90
 obtusus, 90
 orbicularis, 90
 sphenoidalalis, 133
 Promontory, 83, 96, 102
 Pseudo-nucleus, 51, 121
 Punctum (small hole) lacrimale, 1, 8
 Pupil (*pupa*, small image; referring to reflected image seen on looking into eye), 31
 dilator muscle of, 32
 sphincter muscle of, 32
 Pupillary membrane, 34, 66
 Purple, visual, 35, 48, 50
 Pyramid of tympanum, 85, 94
 of vestibule, 99
 RABBIT, olfactory epithelium of, 141
 organ of Jacobson of, 144
 papilla foliata of, 149
 Radial fibres, 50
 Radii of eyeball, 15
 of lens, 63
 Rami of auditory nerve, 108
 Raphe (*ραφή*, seam) of semicircular canal, 110
 Recess, lateral of pharynx, 87
 spheno-ethmoidal, 138
 Recesses of posterior chamber, 62
 of tympanum, 96
 Recessus cochlearis, 99
 epitympanicus, 80, 81
 utriculi, 104
 Recklinghausen, canals of, 18
 Reissner, membrane of, 113, 118, 127
 Reptiles, bipolar cells of retina of, 44
 ellipsoid of, 49
 lagna of, 114
 olfactory cells of, 142
 retinal cones of, 49
 Reticular lamina, 119, 121, 122
 Retina (*rete*, net), 11, 14, 35, 154
 epithelium of, 46
 hexagonal cells of, 24, 35
 intercommunications of elements of, 56
 layers of, 38, 52
 lymph-spaces of, 56
 structure of, 38
 sustentacular tissue of, 50
 Retzius on gustatory cells, 151
 Rhodopsin (*ροδοψιν*, rose; *ὄψις*, appearance), 35, 48
 Riolan, muscle of, 2
 Rivinus, notch of, 81, 82, 93
 Rod-bipolar cells, 43
 -ellipsoid, 49
 -fibre, 46, 57, 154
 -granules, 46
 Rods of Corti, 119, 120, 127
 Rods, retinal, 46, 47, 50, 52, 54, 57, 154
 Rosenmüller, fossa of, 87
 Rüdinger on articulation of auditory ossicles, 91
 SAC, lachrymal, 7, 9
 Sacculæ, 98, 104, 105, 109, 112, 114
 nerve of, 108
 Saccus endolymphaticus, 105
 Salpingo-palatine fold, 87
 Salpingo-pharyngeal fold, 87
 Salpingo-pharyngeus muscle, 89
 Salpinx (*σαλπιγξ*, trumpet), 86
 Santorini, fissures of, 74, 80
 Sappey on ligament of Tenon's capsule, 11
 Scala (staircase) tympani, 83, 102, 104
 vestibuli, 99, 102, 104
 Searna, ganglion of, 108
 Schlemm, canal of, 21, 34, 66
 Schneiderian membrane, 139
 Schultz on fovea centralis, 52
 Schwalbe on bacillary layer, 50
 on canal of Schlemm, 22
 on funiculus scleræ, 17
 Sclerotic (*σκληρός*, tough) coat, 11, 13, 16, 21, 30
 Semicircular canals, 98, 99, 100, 105, 109
 Sense-epithelium cells, 151

- Septum mobile, 130
 nasi, 130, 142, 145
 artery of, 144
 cartilage of, 132
 orbitale, 3
 transversum of ampullæ, 105, 110
- Sheath, perivascular, 26, 55
- Sheep, ligamentum pectinatum of, 21
- Sinus (hollow, bay) circulus iridis, 21
 frontal, 136, 139
 lateral, 85
 of Maier, 9
 of membranous labyrinth, 104
 sphenoidal, 139
 tympanic, 84
 of utricle, 105
- Spaces of Fontana, 21, 66
- Spheno-ethmoidal recess, 138
- Sphenoidal sinus, 139
- Spheno-maxillary muscle, 4
- Spheno-palatine artery, 144
- Sphincter (σφύγγω, bind) pupillæ, 32
- Spider-cells, 40
- Spina tympanica, 93
- Spine of helix, 74
- Spines, tympanic, 81, 82, 93
- Spiral canal of cochlea, 102
 of modiolus, 104, 124
 ganglion, 109, 124, 152
 groove, 115
 lamina of cochlea, 102, 103, 124
 ligament, 113, 117, 119
- Spongioblasts, 44, 45
- Spot, yellow, 35, 40
- Spur of malleus, 90
- Stapedial artery, 91
- Stapedius muscle, 85, 94, 95, 98
 bone of, 94
- Stapes (stirrup), 83, 89, 91, 94, 95
- Stensen, canal of, 138
- Stilling, canal of, 38, 59
- Stomata (στόμα, mouth) of iris, 31
- Stratum bacillarum (*bacillum*, small staff) 8,
 46, 47, 54
 granularum externum, 38, 46, 52, 53, 54
 internum, 38, 41, 52, 54, 57
 of horizontal cells, 45
 nigrum, 38, 50, 52, 53, 54
 opticum, 38, 52, 54
 reticulare internum, 38, 41, 43, 44, 52, 54,
 57
 externum, 38, 43, 45, 47, 52, 57
- Stria (flute of column) vascularis, 119
- Stroma iridis, 31
- Stuart, on hyaloid membrane, 58
- Substantia propria of cornea, 17
- Sulcus (furrow) olfactorius, 138
 scleræ, 10, 17
 spiralis, 115
 tympanicus, 78
- Suspensory ligament of eye, 12
 of lens, 24, 31, 59
- Sustentacular cells of taste-buds, 150
 fibres of ampullary epithelium,
 112
 tissue of retina, 50
- TAPETUM, 25
- Tarsal arches, 5
 cartilage, 1, 2, 12
 glands, 3
- Tarsal—*continued*.
 ligament, 2, 3, 10
 posterior, 4
- Tarsus (*ταρσός*, wing), 1, 2, 12
- Taste-buds, 148, 149, 150
- Taste-hair, 151
- Taste-organs, 148
 literature of, 151
- Tectorial (*tectorium*, cover) membrane, 120, 123,
 127
- Tegmen (cover) tympani, 81
- Teleostei, cone-fibres of, 47
 end-knobs of retina of, 46
- Tenon, capsule of, 11
- Tensor choroideæ, 30
 palati, 87, 88
 tarsi, 9, 10
 tympani, 81, 86, 93, 94, 95, 98
- Thin on lens-fibres, 65
- Tongue, 148
- Tractus spiralis foraminulentus, 102, 108, 124
- Tragus, 71
 muscle of, 75
- Transverse muscle of pinna, 75
- Tube, Eustachian, 80, 81, 86, 94, 96
 muscles of, 88
 vessels and nerves of, 88
- Tuber cochleæ, 83
- Tubercle of Darwin, 72
- Tuberculum supratragicum, 71
- Tubes, corneal, 18
- Tunica choroideæ, 23
 propria of semicircular canals, 110
 Ruyschiana s. chorio-capillaris, 27
 sclera, 11
 uvea s. vasculosa, 11, 23
 vaginalis oculi, 11
- Tunnel of Corti, 119, 125
- Turbinate bodies or Turbinals (*turbo*, whirl,
 twist), 134, 137, 142, 145
- Turner on olfactory organs of mammals, 130
- Tutamina (*tutamen*, means of protection)
 oculi, 1
- Tympanic artery, 97
 bone, 79
 cells, 81
 membrane, 78, 79, 81, 90, 93, 95,
 96, 98
 nerve, 81
 plate, fibrous, 79
 plexus, 83, 97
 spines, 81, 82, 93
 sulcus, 78
- Tympano-malleolar folds, 82
 ligaments, 82
- Tympanum (drum), 71, 80. *See also* TYM-
 PANIC.
 glands of, 96
 mucous membrane of, 95
 muscles of, 93
 nerves of, 97
 recesses or pouches of, 96
 secondary membrane of, 83, 104
 vessels of, 97
- UMBO (boss of shield), 82
- Utricle, 98, 99, 104, 108, 109, 112
- Uvea (Lat. rendering of *παγοειδής χιτώνας* = *tunica*
uviformis, choroid and iris together being
 compared to the skin of a grape, *uva*), 35

- Vas spirale, 117
 Vasa vorticiosa (whorled), 26
 Vascular coat of eye, 23
 Veins of choroid coat, 26
 of ciliary processes, 30
 of cochlea, 125
 of cornea, 22
 of eyelids, 6
 of external auditory canal 79
 of iris, 34
 of labyrinth, 109
 of lachrymal gland, 8
 of nasal duct, 10
 fossæ, 145
 of pinna, 76
 post-tarsal, 6
 pretarsal, 6
 of retina, 55
 of sclerotic coat, 17
 of tympanum, 97
 Venæ vorticiosæ, 15
 Ventricle of nares, 139
 Vertebrates, sensory cells and fibres of, 152
 Vesicle, primary optic, 50
 Vessels. *See* ARTERIES, VEINS, LYMPHATICS.
 Vestibule, aqueduct of, 99
 Vestibule—*continued.*
 of labyrinth, 83, 98, 99
 of nasal fossæ, 138
 Vibrissæ, 130, 138
 Visual cells, 46, 154
 purple, 35, 48, 50
 Vitreous body or humour (*humor liquid*), 11,
 38, 58
 Vomarine cartilage, 133, 144

 Wax of ear, 79, 80

 YELLOW spot, 35, 40, 47, 52, 55

 ZINN, zonula (dim. of *zona*, belt) of, 59
 Zona arcuata, 117
 pectinata, 117
 Zone, nuclear, of lens, 65
 of oval nuclei, 141
 of round nuclei, 141
 Zonula ciliaris, 59
 of Zinn, 59
 Zuckerkaudl on ethmoidal fissures, 136

END OF PART III.



A LIST OF WORKS ON
MEDICINE, SURGERY
AND
GENERAL SCIENCE,

PUBLISHED BY

LONGMANS, GREEN & CO.,

39, PATERNOSTER ROW, LONDON.

15, EAST 16th ST., NEW YORK.

Medical and Surgical Works.

ASHBY. NOTES ON PHYSIOLOGY FOR THE USE OF STUDENTS PREPARING FOR EXAMINATION. By HENRY ASHBY, M.D. Lond., F.R.C.P., Physician to the General Hospital for Sick Children, Manchester; formerly Demonstrator of Physiology, Liverpool School of Medicine. Sixth Edition, thoroughly revised. With 141 Illustrations. Fcap. 8vo, price 5s.

ASHBY AND WRIGHT. THE DISEASES OF CHILDREN, MEDICAL AND SURGICAL. By HENRY ASHBY, M.D. Lond., F.R.C.P., Physician to the General Hospital for Sick Children, Manchester; Lecturer and Examiner in Diseases of Children in the Victoria University; and G. A. WRIGHT, B.A., M.B. Oxon., F.R.C.S. Eng., Assistant Surgeon to the Manchester Royal Infirmary and Surgeon to the Children's Hospital; Examiner in Surgery in the University of Oxford. Enlarged and Improved Edition. With 178 Illustrations. 8vo, price 24s.

BARKER. A SHORT MANUAL OF SURGICAL OPERATIONS, HAVING SPECIAL REFERENCE TO MANY OF THE NEWER PROCEDURES. By ARTHUR E. J. BARKER, F.R.C.S., Surgeon to University College Hospital, Teacher of Practical Surgery at University College, Professor of Surgery and Pathology at the Royal College of Surgeons of England. With 61 Woodcuts in the Text. Crown 8vo, price 12s. 6d.

BENNETT.—*WORKS* by WILLIAM H. BENNETT, F.R.C.S., Surgeon to St. George's Hospital; Member of the Board of Examiners, Royal College of Surgeons of England.

CLINICAL LECTURES ON VARICOSE VEINS OF THE LOWER EXTREMITIES. With 3 Plates. 8vo. 6s.

ON VARICOCELE: A PRACTICAL TREATISE. With 4 Tables and a Diagram. 8vo. 5s.

CLINICAL LECTURES ON ABDOMINAL HERNIA: chiefly in relation to Treatment, including the Radical Cure. With 12 Diagrams in the Text. 8vo. 8s. 6d.

BENTLEY. A TEXT-BOOK OF ORGANIC MATERIA MEDICA.

Comprising a Description of the Vegetable and Animal Drugs of the British Pharmacopœia, with some others in common use. Arranged Systematically and Especially Designed for Students. By ROBERT BENTLEY, M.R.C.S. Eng., F.L.S. With 62 Illustrations on Wood. Crown 8vo, price 7s. 6d.

CLEMOW. THE CHOLERA EPIDEMIC OF 1892 IN THE

RUSSIAN EMPIRE. With Notes upon Treatment and Methods of Disinfection in Cholera, and a short account of the Conference on Cholera held in St. Petersburg in December, 1892. By FRANK CLEMOW, M.D. Edin., Member of the Epidemiological Society of London, &c. Royal 8vo, 5s.

COATS. A MANUAL OF PATHOLOGY. By JOSEPH COATS,

M.D., Pathologist to the Western Infirmary and the Sick Children's Hospital, Glasgow; Lecturer on Pathology in the Western Infirmary; Examiner in Pathology in the University of Glasgow. Second Edition. Revised and mostly Re-written. With 364 Illustrations. 8vo, price 31s. 6d.

COOKE.—WORKS by THOMAS COOKE, F.R.C.S. Eng., B.A., B.Sc.,

M.D. Paris, Senior Assistant Surgeon to the Westminster Hospital.

TABLETS OF ANATOMY. Being a Synopsis of Demonstrations given in the Westminster Hospital Medical School in the years 1871-75. Eighth Thousand, being a selection of the Tablets believed to be most useful to Students generally. Post 4to, price 7s. 6d.

APHORISMS IN APPLIED ANATOMY AND OPERATIVE SURGERY. Including 100 Typical *vivâ voce* Questions on Surface Marking, &c. Crown 8vo, 3s. 6d.

DISSECTION GUIDES. Aiming at Extending and Facilitating such Practical Work in Anatomy as will be specially useful in connection with an ordinary Hospital Curriculum. 8vo, 10s. 6d.

DICKINSON.—WORKS by W. HOWSHIP DICKINSON, M.D.

Cantab., F.R.C.P., Physician to, and Lecturer on Medicine at, St. George's Hospital; Consulting Physician to the Hospital for Sick Children.

ON RENAL AND URINARY AFFECTIONS. Complete in Three Parts, 8vo, with 12 Plates and 122 Woodcuts. Price £3 4s. 6d. cloth.

* * The Parts can also be had separately, each complete in itself, as follows:—

PART I.—*Diabetes*, price 10s. 6d. sewed, 12s. cloth.

„ II.—*Albuminuria*, price £1 sewed, £1 1s. cloth.

„ III.—*Miscellaneous Affections of the Kidneys and Urine*, price £1 10s. sewed, £1 11s. 6d. cloth.

THE TONGUE AS AN INDICATION OF DISEASE; being the Lumleian Lectures delivered at the Royal College of Physicians in March, 1888. 8vo, price 7s. 6d.

THE HARVEIAN ORATION ON HARVEY IN ANCIENT AND MODERN MEDICINE. Crown 8vo, 2s. 6d.

DUANE. THE STUDENT'S DICTIONARY OF MEDICINE AND THE ALLIED SCIENCES. Comprising the Pronunciation, Derivation, and Full Explanation of Medical Terms, together with much Collateral Descriptive Matter, numerous Tables, &c. By ALEXANDER DUANE, M.D., Assistant-Surgeon to the New York Ophthalmic and Aural Institute, Reviser of Medical Terms for "Webster's International Dictionary." 8vo, 21s.

ERICHSEN.—*WORKS* by JOHN ERIC ERICHSEN, F.R.S., LL.D. (Edin.), Hon. M. Ch. and F.R.C.S. (Ireland), Surgeon Extraordinary to H.M. the Queen; President of University College, London; Fellow and Ex-President of the Royal College of Surgeons of England; Emeritus Professor of Surgery in University College; Consulting-Surgeon to University College Hospital, and to many other Medical Charities.

THE SCIENCE AND ART OF SURGERY; A TREATISE ON SURGICAL INJURIES, DISEASES, AND OPERATIONS. Ninth Edition, Edited by Professor BECK, M.S. & M.B. (Lond.), F.R.C.S., Surgeon to University College Hospital, &c. Illustrated by 1025 Engravings on Wood. 2 Vols. 8vo, price 48s.

ON CONCUSSION OF THE SPINE, NERVOUS SHOCKS, and other Obscure Injuries of the Nervous System in their Clinical and Medico-Legal Aspects. Crown 8vo, 10s. 6d.

FRANKLAND. MICRO-ORGANISMS IN WATER, THEIR SIGNIFICANCE, IDENTIFICATION, AND REMOVAL. Together with an Account of the Bacteriological Methods Involved in their Investigation. Specially Designed for the Use of those connected with the Sanitary Aspects of Water Supply. By Professor PERCY FRANKLAND, Ph D., B.Sc. (Lond.), F.R.S., Fellow of the Chemical Society; and Mrs. PERCY FRANKLAND, Joint Author of "Studies on Some New Micro-Organisms Obtained from Air." [In the press.]

GAIRDNER AND COATS. ON THE DISEASES CLASSIFIED by the REGISTRAR-GENERAL as TABES MESENTERICA. LECTURES TO PRACTITIONERS. By W. T. GAIRDNER, M.D., LL.D. On the PATHOLOGY of PHTHISIS PULMONALIS. By JOSEPH COATS, M.D. With 28 Illustrations. 8vo, price 12s. 6d.

GARROD.—*WORKS* by Sir ALFRED BARING GARROD, M.D., F.R.S., &c.; Physician Extraordinary to H.M. the Queen; Consulting Physician to King's College Hospital; late Vice-President of the Royal College of Physicians.

A TREATISE ON GOUT AND RHEUMATIC GOUT (RHEUMATOID ARTHRITIS). Third Edition, thoroughly revised and enlarged; with 6 Plates, comprising 21 Figures (14 Coloured), and 27 Illustrations engraved on Wood. 8vo, price 21s.

THE ESSENTIALS OF MATERIA MEDICA AND THERAPEUTICS. The Thirteenth Edition, revised and edited, under the supervision of the Author, by NESTOR TIRARD, M.D. Lond., F.R.C.P., Professor of Materia Medica and Therapeutics in King's College, London, &c. Crown 8vo, price 12s. 6d.

GRAY. ANATOMY, DESCRIPTIVE AND SURGICAL. By HENRY GRAY, F.R.S., late Lecturer on Anatomy at St. George's Hospital. The Thirteenth Edition, re-edited by T. PICKERING PICK, Surgeon to St. George's Hospital; Member of the Court of Examiners, Royal College of Surgeons of England. With 636 large Woodcut Illustrations, a large proportion of which are Coloured, the Arteries being coloured red, the Veins blue, and the Nerves yellow. The attachments of the muscles to the bones, in the section on Ostology, are also shown in coloured outline. Royal 8vo, price 36s.

HALLIBURTON.—*WORKS* by W. D. HALLIBURTON, M.D., B.Sc., M.R.C.P., Professor of Physiology at King's College, London; Lecturer on Physiology at the London School of Medicine for Women; late Assistant Professor of Physiology at University College, London.

A TEXT-BOOK OF CHEMICAL PHYSIOLOGY AND PATHOLOGY. With 104 Illustrations. 8vo, 28s.

ESSENTIALS OF CHEMICAL PHYSIOLOGY. 8vo, 5s.

* * This is a book suitable for medical students. It treats of the subject in the same way as Prof. SCHÄFER's "Essentials" treats of Histology. It contains a number of elementary and advanced practical lessons, followed in each case by a brief descriptive account of the facts related to the exercises which are intended to be performed by each member of the class.

HASSALL.—*WORKS* by ARTHUR HILL HASSALL, M.D., London.

THE INHALATION TREATMENT OF DISEASES OF THE ORGANS OF RESPIRATION, INCLUDING CONSUMPTION.

With numerous Illustrations. Crown 8vo, price 12s. 6d.

THE NARRATIVE OF A BUSY LIFE: an Autobiography. 8vo, 5s.

HERON. EVIDENCES OF THE COMMUNICABILITY OF CONSUMPTION. By G. A. HERON, M.D. (Glas.), F.R.C.P., Physician to the City of London Hospital for Diseases of the Chest. 8vo, 7s. 6d.

HEWITT. ON SEVERE VOMITING DURING PREGNANCY: a Collection and Analysis of Cases, with Remarks on Treatment. By GRAILY HEWITT, M.D. Lond., F.R.C.P., F.R.S. Ed., Emeritus Professor of Obstetric Medicine, University College; Consulting Obstetric Physician to University College Hospital, &c., &c. 8vo, 6s.

HOLMES. A SYSTEM OF SURGERY, Theoretical and Practical. Edited by TIMOTHY HOLMES, M.A.; and J. W. HULKE, F.R.S., Surgeon to the Middlesex Hospital. Third Edition, in Three Volumes, with Coloured Plates and numerous Illustrations. 3 Vols., royal 8vo, price £4 4s.

LANGTON. ABDOMINAL HERNIA. By JOHN LANGTON, F.R.C.S., Surgeon to St. Bartholomew's Hospital, Senior Surgeon to the City of London Truss Society, Member of the Council and Court of Examiners of the Royal College of Surgeons of England. With numerous Illustrations. [*In the press.*]

LIVEING.—WORKS by ROBERT LIVEING, M.A. & M.D. Cantab., F.R.C.P. Lond., &c., Physician to the Department for Diseases of the Skin at the Middlesex Hospital, &c.

HANDBOOK ON DISEASES OF THE SKIN. With especial reference to Diagnosis and Treatment. Fifth Edition, revised and enlarged. Fcap. 8vo, price 5s.

ELEPHANTIASIS GRÆCORUM, OR TRUE LEPROSY; Being the Goulstonian Lectures for 1873. Cr. 8vo, 4s. 6d.

LONGMORE.—WORKS by Surgeon-General Sir T. LONGMORE, C.B., F.R.C.S., Honorary Surgeon to H.M. Queen Victoria; Professor of Military Surgery in the Army Medical School.

THE ILLUSTRATED OPTICAL MANUAL; OR, HANDBOOK OF INSTRUCTIONS FOR THE GUIDANCE OF SURGEONS IN TESTING QUALITY AND RANGE OF VISION, AND IN DISTINGUISHING AND DEALING WITH OPTICAL DEFECTS IN GENERAL. Illustrated by 74 Drawings and Diagrams by Inspector-General Dr. MACDONALD, R.N., F.R.S., C.B. Fourth Edition. 8vo, price 14s.

GUNSHOT INJURIES. Their History, Characteristic Features, Complications, and General Treatment; with Statistics concerning them as they are met with in Warfare. With 58 Illustrations. 8vo, price 3s. 6d.

MURCHISON.—WORKS by CHARLES MURCHISON, M.D., LL.D., F.R.S., &c., Fellow of the Royal College of Physicians; late Physician and Lecturer on the Principles and Practice of Medicine, St. Thomas's Hospital.

A TREATISE ON THE CONTINUED FEVERS OF GREAT BRITAIN. Edited by W. CAYLEY, M.D., F.R.C.P. With 6 Coloured Plates and Lithographs, 19 Diagrams and 20 Woodcut Illustrations. 8vo, price 25s.

CLINICAL LECTURES ON DISEASES OF THE LIVER, JAUNDICE, AND ABDOMINAL DROPSY; Including the Croonian Lectures on Functional Derangements of the Liver, delivered at the Royal College of Physicians in 1874. Revised by T. LAUDER BRUNTON, M.D. 8vo, price 24s.

NEWMAN. ON THE DISEASES OF THE KIDNEY AMENABLE TO SURGICAL TREATMENT. Lectures to Practitioners. By DAVID NEWMAN, M.D., Surgeon to the Western Infirmary Out-Door Department; Pathologist and Lecturer on Pathology at the Glasgow Royal Infirmary; Examiner in Pathology in the University of Glasgow; Vice-President Glasgow Pathological and Clinical Society. 8vo, price 16s.

OWEN. A MANUAL OF ANATOMY FOR SENIOR STUDENTS. By EDMUND OWEN, M.B., F.R.S.C., Senior Surgeon to the Hospital for Sick Children, Great Ormond Street, Surgeon to St. Mary's Hospital, London, and co-Lecturer on Surgery, late Lecturer on Anatomy in its Medical School. With 210 Illustrations. Crown 8vo, price 12s. 6d.

PAGET.—*WORKS* by Sir JAMES PAGET, Bart., F.R.S., D.C.L. Oxon., LL.D. Cantab., &c., Sergeant-Surgeon to the Queen, Surgeon to the Prince of Wales, Consulting Surgeon to St. Bartholomew's Hospital.

LECTURES ON SURGICAL PATHOLOGY, Delivered at the Royal College of Surgeons of England. Fourth Edition, re-edited by the AUTHOR and W. TURNER, M.B. 8vo, with 131 Woodcuts, price 21s.

CLINICAL LECTURES AND ESSAYS. Edited by F. HOWARD MARS, Assistant-Surgeon to St. Bartholomew's Hospital. Second Edition, revised. 8vo, price 15s.

STUDIES OF OLD CASE-BOOKS. 8vo, 8s. 6d.

POOLE. COOKERY FOR THE DIABETIC. By W. II. and Mrs. POOLE. With Preface by Dr. PAVY. Fcap. 8vo. 2s. 6d.

POORE. ESSAYS ON RURAL HYGIENE. By GEORGE VIVIAN POORE, M.D., F.R.C.P. Crown 8vo, 6s. 6d.

QUAIN. A DICTIONARY OF MEDICINE; Including General Pathology, General Therapeutics, Hygiene, and the Diseases peculiar to Women and Children. By Various Writers. Edited by SIR RICHARD QUAIN, Bart., M.D., F.R.S., Physician Extraordinary to H.M. the Queen, Fellow of the Royal College of Physicians, Consulting Physician to the Hospital for Consumption, Brompton. Seventeenth Thousand; pp. 1,836, with 138 Illustrations engraved on wood. 1 Vol. medium 8vo, price 31s. 6d. cloth. To be had also in Two Volumes, price 34s. cloth.

QUAIN. QUAIN'S (JONES) ELEMENTS OF ANATOMY.

The Tenth Edition. Edited by EDWARD ALBERT SCHÄFER, F.R.S., Professor of Physiology and Histology in University College, London; and GEORGE DANCER THANE, Professor of Anatomy in University College, London. (In three volumes.)

VOL. I., PART I. EMBRYOLOGY. By Professor SCHÄFER. Illustrated by 200 Engravings, many of which are coloured. Royal 8vo, 9s. [*Ready.*]

VOL. I., PART II. GENERAL ANATOMY OR HISTOLOGY. By Professor SCHÄFER. Illustrated by nearly 500 Engravings, many of which are coloured. Royal 8vo, 12s. 6d. [*Ready.*]

VOL. I., PART I. OSTEOLOGY. By Professor THANE. Illustrated by 168 Engravings. Royal 8vo, 9s. [*Ready.*]

VOL. II., PART II. ARTHROLOGY, MYOLOGY, ANGIOLOGY. By Professor THANE. Illustrated by 255 Engravings, many of which are Coloured. Royal 8vo, 18s. [*Ready.*]

VOL. III., PART I. SPINAL CORD AND BRAIN. By Professor SCHÄFER. Illustrated by 139 Engravings. Royal 8vo, 12s. 6d. [*Ready.*]

VOL. III., PART II. PERIPHERAL NERVES & SENSE ORGANS. [*In preparation.*]

VOL. III., PART III. VISCERA. [*In preparation.*]

RICHARDSON. THE ASCLEPIAD. A Book of Original Research in the Science, Art, and Literature of Medicine. By BENJAMIN WARD RICHARDSON, M.D., F.R.S. Published Quarterly, price 2s. 6d. Volumes for 1884, 1885, 1886, 1887, 1888, 1889, 1890, 1891, & 1892. 8vo, price 12s. 6d. each.

SCHÄFER. THE ESSENTIALS OF HISTOLOGY: Descriptive and Practical. For the Use of Students. By E. A. SCHÄFER, F.R.S., Jodrell Professor of Physiology in University College, London; Editor of the Histological Portion of Quain's "Anatomy." Illustrated by more than 300 Figures, many of which are new. Third Edition, Revised and Enlarged. 8vo, 7s. 6d. (Interleaved, 10s)

SCHENK. MANUAL OF BACTERIOLOGY. For Practitioners and Students. With especial reference to Practical Methods. By Dr. S. L. SCHENK, Professor (Extraordinary) in the University of Vienna. Translated from the German, with an Appendix, by W. R. DAWSON, B.A., M.D., Univ. Dub.; late University Travelling Prizeman in Medicine. With 100 Illustrations, some of which are coloured. 8vo, 19s. net.

SEMPLE. ELEMENTS OF MATERIA MEDICA AND THERAPEUTICS. Including the whole of the Remedies of the British Pharmacopœia of 1885 and its Appendix of 1890. With 440 Illustrations. By C. E. ARMAND SEMPLE, B.A., M.B. Camb., L.S.A., M.R.C.P. Lond.; Member of the Court of Examiners, and late Senior Examiner in Arts at Apothecaries' Hall, &c. Crown 8vo, price 10s. 6d.

SISLEY.—WORKS by RICHARD SISLEY, M.D.

EPIDEMIC INFLUENZA. Notes on its Origin and Method of Spread. Royal 8vo, 7s. 6d.

A STUDY OF INFLUENZA, and the Laws of England concerning Infectious Diseases. A Paper read before the Society of Medical Officers of Health, January 18, 1892, with Appendix of Counsel's Opinion, &c. 8vo, 3s. 6d.

SMALE AND COLYER. DISEASES AND INJURIES OF THE TEETH, including Pathology and Treatment: a Manual of Practical Dentistry for Students and Practitioners. By MORTON SMALE, M.R.C.S., L.S.A., L.D.S., Dental Surgeon to St. Mary's Hospital, Dean of the School, Dental Hospital of London, &c.; and J. F. COLYER, L.R.C.P., M.R.C.S., L.D.S., Assistant Dental Surgeon to Charing Cross Hospital, and Assistant Dental Surgeon to the Dental Hospital of London. With 334 Illustrations. Large Crown 8vo, 15s.

SMITH (H. F.). THE HANDBOOK FOR MIDWIVES. By HENRY FLY SMITH, B.A., M.B. Oxon., M.R.C.S. Second Edition. With 41 Woodcuts. Crown 8vo, price 5s.

STEEL.—WORKS by JOHN HENRY STEEL, F.R.C.V.S., F.Z.S., A.V.D., late Professor of Veterinary Science and Principal of Bombay Veterinary College.

A TREATISE ON THE DISEASES OF THE DOG; being a Manual of Canine Pathology. Especially adapted for the use of Veterinary Practitioners and Students. 88 Illustrations. 8vo, 10s. 6d.

A TREATISE ON THE DISEASES OF THE OX; being a Manual of Bovine Pathology specially adapted for the use of Veterinary Practitioners and Students. 2 Plates and 117 Woodcuts. 8vo, 15s.

A TREATISE ON THE DISEASES OF THE SHEEP; being a Manual of Ovine Pathology for the use of Veterinary Practitioners and Students. With Coloured Plate, and 99 Woodcuts. 8vo, 12s.

“STONEHENGE.” THE DOG IN HEALTH AND DISEASE. By “STONEHENGE.” With 84 Wood Engravings. Square crown 8vo, 7s. 6d.

THORNTON. HUMAN PHYSIOLOGY. By JOHN THORNTON, M.A., Author of “Elementary Physiography,” “Advanced Physiography,” &c. With 267 Illustrations, some of which are Coloured. Crown 8vo, 6s.

WALLER. AN INTRODUCTION TO HUMAN PHYSIOLOGY.

By AUGUSTUS D. WALLER, M.D., Lecturer on Physiology at St. Mary's Hospital Medical School, London; late External Examiner at the Victorian University. Second Edition, Revised. With 305 Illustrations. 8vo, 18s.

WILKS AND MOXON. LECTURES ON PATHOLOGICAL

ANATOMY. By SAMUEL WILKS, M.D., F.R.S., Consulting Physician to, and formerly Lecturer on Medicine and Pathology at, Guy's Hospital, and the late WALTER MOXON, M.D., F.R.C.P., Physician to, and some time Lecturer on Pathology at, Guy's Hospital. Third Edition, thoroughly Revised. By SAMUEL WILKS, M.D., LL.D., F.R.S. 8vo, 18s.

WILLIAMS. PULMONARY CONSUMPTION: ITS ETIOLOGY, PATHOLOGY, AND TREATMENT.

With an Analysis of 1,000 Cases to Exemplify its Duration and Modes of Arrest. By C. J. B. WILLIAMS, M.D., LL.D., F.R.S., F.R.C.P., Senior Consulting Physician to the Hospital for Consumption, Brompton; and CHARLES THEODORE WILLIAMS, M.A., M.D. Oxon., F.R.C.P., Senior Physician to the Hospital for Consumption, Brompton. Second Edition, Enlarged and Re-written by Dr. C. THEODORE WILLIAMS. With 4 Coloured Plates and 10 Woodcuts. 8vo, 16s.

YOUATT.—*WORKS* by WILLIAM YOUATT.

THE HORSE. Revised and Enlarged by W. WATSON, M.R.C.V.S. Woodcuts. 8vo, 7s. 6d.

THE DOG. Revised and Enlarged. Woodcuts. 8vo, 6s.

General Scientific Works.

ARNOTT. THE ELEMENTS OF PHYSICS OR NATURAL PHILOSOPHY.

By NEIL ARNOTT, M.D. Edited by A. BAIN, LL.D. and A. S. TAYLOR, M.D., F.R.S. Woodcuts. Crown 8vo, 12s. 6d.

BENNETT AND MURRAY. A HANDBOOK OF CRYPTO-

GAMIC BOTANY. By A. W. BENNETT, M.A., B.Sc., F.L.S., and GEORGE R. MILNE MURRAY, F.L.S. With 378 Illustrations. 8vo, 16s.

CLERKE. THE SYSTEM OF THE STARS.

By AGNES M. CLERKE, Author of "A History of Astronomy during the Nineteenth Century." With 6 Plates and Numerous Illustrations. 8vo, 21s.

CLODD. THE STORY OF CREATION. A Plain Account of Evolution. By EDWARD CLODD, Author of "The Childhood of the World," &c. With 77 Illustrations. Crown 8vo, 3s. 6d.

CROOKES. SELECT METHODS IN CHEMICAL ANALYSIS (chiefly Inorganic). By W. CROOKES, F.R.S., V.P.C.S., Editor of "The Chemical News." Second Edition, re-written and greatly enlarged. Illustrated with 37 Woodcuts. 8vo, 24s.

CULLEY. A HANDBOOK OF PRACTICAL TELEGRAPHY. By R. S. CULLEY, M.I.C.E., late Engineer-in-Chief of Telegraphs to the Post Office. With 135 Woodcuts and 17 Plates, 8vo, 16s.

EARL. THE ELEMENTS OF LABORATORY WORK. A Course of Natural Science for Schools. By A. G. EARL, M.A., F.C.S., late Scholar of Christ College, Cambridge; Science Master at Tonbridge School. With 57 Diagrams and numerous Exercises and Questions. Crown 8vo, 4s. 6d.

GANOT. ELEMENTARY TREATISE ON PHYSICS; Experimental and Applied, for the use of Colleges and Schools. Translated and edited from GANOT's *Eléments de Physique* (with the Author's sanction) by E. ATKINSON, Ph.D., F.C.S., Professor of Experimental Science, Staff College, Sandhurst. Fourteenth Edition, revised and enlarged, with 9 Coloured Plates and 1,028 Woodcuts. Large crown 8vo, 15s.

NATURAL PHILOSOPHY FOR GENERAL READERS AND YOUNG PERSONS; Being a Course of Physics divested of Mathematical Formulæ, and expressed in the language of daily life. Translated from GANOT's *Cours de Physique* (with the Author's sanction) by E. ATKINSON, Ph.D., F.C.S. Seventh Edition, carefully revised; with 37 pages of New Matter, 7 Plates, 569 Woodcuts, and an Appendix of Questions. Crown 8vo, 7s. 6d.

GOODEVE.—*WORKS* by T. M. GOODEVE, M.A., Barrister-at-Law; Professor of Mechanics at the Normal School of Science and the Royal School of Mines.

PRINCIPLES OF MECHANICS. New Edition, re-written and enlarged. With 253 Woodcuts and numerous Examples. Crown 8vo, 6s.

THE ELEMENTS OF MECHANISM. New Edition, re-written and enlarged. With 342 Woodcuts. Crown 8vo, 6s.

A MANUAL OF MECHANICS: an Elementary Text-Book for Students of Applied Mechanics. With 138 Illustrations and Diagrams, and 141 Examples taken from the Science Department Examination Papers, with Answers. Fcp. 8vo, 2s. 6d.

HELMHOLTZ.—*WORKS* by *HERMANN L. F. HELMHOLTZ*,
M.D., Professor of Physics in the University of Berlin.

ON THE SENSATIONS OF TONE AS A PHYSIOLOGICAL BASIS FOR THE THEORY OF MUSIC. Second English Edition; with numerous additional Notes, and a new Additional Appendix, bringing down information to 1885, and specially adapted to the use of Musical Students. By *ALEXANDER J. ELLIS*, B.A., F.R.S., F.S.A., &c., formerly Scholar of Trinity College, Cambridge. With 68 Figures engraved on Wood, and 42 Passages in Musical Notes. Royal 8vo, 28s.

POPULAR LECTURES ON SCIENTIFIC SUBJECTS. With 68 Woodcuts. 2 Vols. crown 8vo, 3s. 6d. each.

HERSCHEL. **OUTLINES OF ASTRONOMY.** By Sir *JOHN F. W. HERSCHEL*, Bart., K.H., &c, Member of the Institute of France. Twelfth Edition, with 9 Plates, and numerous Diagrams. 8vo, 12s.

HUDSON AND GOSSE. **THE ROTIFERA OR 'WHEEL ANIMALCULES.'** By *C. T. HUDSON*, LL.D., and *P. H. GOSSE*, F.R.S. With 30 Coloured and 4 Uncoloured Plates. In 6 Parts. 4to, price 10s. 6d. each; Supplement, 12s. 6d. Complete in Two Volumes, with Supplement, 4to, £4 4s.

* * The Plates in the Supplement contain figures of almost all the Foreign Species, as well as of the British Species, that have been discovered since the original publication of Vols. I. and II.

IRVING. **PHYSICAL AND CHEMICAL STUDIES IN ROCK-METAMORPHISM**, based on the Thesis written for the D.Sc. Degree in the University of London, 1888. By the Rev. *A. IRVING*, D.Sc. Lond., Senior Science Master at Wellington College. 8vo, 5s.

JORDAN. **THE OCEAN: A Treatise on Ocean Currents and Tides and their Causes.** By *WILLIAM LEIGHTON JORDAN*, F.R.G.S. 8vo, 21s.

KOLBE. **A SHORT TEXT-BOOK OF INORGANIC CHEMISTRY.** By Dr. *HERMANN KOLBE*, late Professor of Chemistry in the University of Leipzig. Translated and Edited by *T. S. HUMPHREYS*, Ph.D., B.Sc. (Lond.), late Professor of Chemistry and Physics in the University College of Wales, Aberystwyth. New Edition. Revised by *H. LLOYD-SNAPE*, Ph.D., D.Sc. (Lond.), Professor of Chemistry in the University College of Wales, Aberystwyth. With a Coloured Table of Spectra and 66 Woodcuts. Crown 8vo, 8s. 6d.

LADD.—*WORKS* by *GEORGE T. LADD*, *Professor of Philosophy in Yale University.*

ELEMENTS OF PHYSIOLOGICAL PSYCHOLOGY: A TREATISE OF THE ACTIVITIES AND NATURE OF THE MIND FROM THE PHYSICAL AND EXPERIMENTAL POINT OF VIEW. With 113 Illustrations. 8vo, price 21s.

OUTLINES OF PHYSIOLOGICAL PSYCHOLOGY. With numerous Illustrations. 8vo. 12s.

LARDEN. **ELECTRICITY FOR PUBLIC SCHOOLS AND COLLEGES.** With numerous Questions and Examples with Answers, and 214 Illustrations and Diagrams. By *W. LARDEN*, M.A. Crown 8vo, 6s.

LINDLEY AND MOORE. **THE TREASURY OF BOTANY, OR POPULAR DICTIONARY OF THE VEGETABLE KINGDOM:** with which is incorporated a Glossary of Botanical Terms. Edited by *J. LINDLEY*, M.D., F.R.S., and *T. MOORE*, F.L.S. With 20 Steel Plates, and numerous Woodcuts. 2 Parts, fcp. 8vo, price 12s.

LOUDON. **AN ENCYCLOPÆDIA OF PLANTS.** By *J. C. LOUDON.* Comprising the Specific Character, Description, Culture, History, Application in the Arts, and every other desirable particular respecting all the plants indigenous to, cultivated in, or introduced into, Britain. Corrected by *Mrs. LOUDON.* 8vo, with above 12,000 Woodcuts, price 42s.

MARTIN. **NAVIGATION AND NAUTICAL ASTRONOMY.** Compiled by *Staff-Commander W. R. MARTIN*, R.N., Instructor in Surveying, Navigation, and Compass Adjustment; Lecturer on Meteorology at the Royal Naval College, Greenwich. Sanctioned for use in the Royal Navy by the Lords Commissioners of the Admiralty. Royal 8vo, 18s.

MENDELÉEFF. **THE PRINCIPLES OF CHEMISTRY.** By *D. MENDELÉEFF*, Professor of Chemistry in the University of St. Petersburg. Translated by *GEORGE KAMENSKY*, A.R.S.M. of the Imperial Mint, St. Petersburg, and Edited by *A. J. GREENAWAY*, F.I.C., Sub-Editor of the Journal of the Chemical Society. With 97 Illustrations. 2 Vols. 8vo, 36s.

MEYER. **OUTLINES OF THEORETICAL CHEMISTRY.** By *LOTHAR MEYER*, Professor of Chemistry in the University of Tübingen. Translated by Professors *P. PHILLIPS BEDSON*, D.Sc., and *W. CARLETON WILLIAMS*, B.Sc. 8vo, 9s.

MILLER.—*WORKS* by WILLIAM ALLEN MILLER, M.D., D.C.L.,
LL.D., late Professor of Chemistry in King's College, London.

THE ELEMENTS OF CHEMISTRY, Theoretical and Practical.

PART II. INORGANIC CHEMISTRY. Sixth Edition, revised throughout, with Additions by C. E. GROVES, Fellow of the Chemical Societies of London, Paris, and Berlin. With 376 Woodcuts. 8vo, price 24s.

PART III. ORGANIC CHEMISTRY, or the Chemistry of Carbon Compounds. *Hydrocarbons, Alcohols, Ethers, Aldehydes and Paraffinoid Acids.* Fifth Edition, revised and in great part re-written, by H. E. ARMSTRONG, F.R.S., and C. E. GROVES, F.C.S. 8vo, price 31s. 6d.

MITCHELL. MANUAL OF PRACTICAL ASSAYING. By JOHN MITCHELL, F.C.S. Sixth Edition. Edited by W. CROOKES, F.R.S. With 201 Woodcuts. 8vo, 31s. 6d.

MORGAN. ANIMAL BIOLOGY. An Elementary Text Book. By C. LLOYD MORGAN, Professor of Animal Biology and Geology in University College, Bristol. With numerous Illustrations. Crown 8vo, 8s. 6d.

ODLING. A COURSE OF PRACTICAL CHEMISTRY, Arranged for the use of Medical Students, with express reference to the Three Months' Summer Practice. By WILLIAM ODLING, M.A., F.R.S. With 71 Woodcuts. Crown 8vo, 6s.

OSTWALD. SOLUTIONS. By W. OSTWALD, Professor of Chemistry in the University of Leipzig. Being the Fourth Book, with some additions, of the Second Edition of Ostwald's "Lehrbuch der Allgemeinen Chemie." Translated by M. M. PATTISON MUIR, Professor of Gonville and Caius College, Cambridge. 8vo, 10s. 6d.

PAYEN. INDUSTRIAL CHEMISTRY; A Manual for use in Technical Colleges or Schools, also for Manufacturers and others, based on a Translation of Stohmann and Engler's German Edition of PAYEN'S *Précis de Chimie Industrielle*. Edited and supplemented with Chapters on the Chemistry of the Metals, &c., by B. H. PAUL, Ph.D. With 698 Woodcuts. 8vo, 42s.

REYNOLDS. EXPERIMENTAL CHEMISTRY for Junior Students. By J. EMERSON REYNOLDS, M.D., F.R.S., Professor of Chemistry, Univ. of Dublin. Fcp. 8vo, with numerous Woodcuts.

PART I.—*Introductory*, 1s. 6d.

PART II.—*Non-Metals*, with an Appendix on Systematic Testing for Acids, 2s. 6d.

PART III.—*Metals and Allied Bodies*, 3s. 6d.

PART IV.—*Chemistry of Carbon Compounds*, 4s.

PROCTOR.—WORKS by RICHARD A. PROCTOR.

- OLD AND NEW ASTRO-
NOMY. In 12 Parts. Price 2s. 6d.
each; supplementary section, 1s.;
complete, 36s. cloth.
- LIGHT SCIENCE FOR
LEISURE HOURS; Familiar
Essays on Scientific Subjects,
Natural Phenomena, &c. 3 Vols.
crown 8vo, 5s. each.
- THE ORBS AROUND US; a
Series of Essays on the Moon and
Planets, Meteors, and Comets.
With Chart and Diagrams, crown
8vo, 5s. Cheap Edition, crown
8vo, 3s. 6d.
- OTHER WORLDS THAN
OURS; The Plurality of Worlds
Studied under the Light of Recent
Scientific Researches. With 14
Illustrations, crown 8vo, 5s.
Cheap Edition, crown 8vo, 3s. 6d.
- THE MOON; her Motions, As-
pects, Scenery, and Physical
Condition. With Plates, Charts,
Woodcuts, and Lunar Photo-
graphs, crown 8vo, 5s.
- UNIVERSE OF STARS; Pre-
senting Researches into and New
Views respecting the Constitution
of the Heavens. With 22 Charts
and 22 Diagrams, 8vo. 10s. 6d.
- LARGER STAR ATLAS for
the Library, in 12 Circular Maps,
with Introduction and 2 Index
Pages. Folio, 15s., or Maps
only, 12s. 6d.
- NEW STAR ATLAS for the
Library, the School, and the Ob-
servatory, in 12 Circular Maps
(with 2 Index Plates). Crown
8vo, 5s.
- THE STUDENT'S ATLAS.
In 12 Circular Maps on a Uni-
form Projection and 1 Scale,
with 2 Index Maps. Intended as
a *vade-mecum* for the Student
of History, Travel, Geography,
Geology, and Political Economy.
With a letter-press Introduction
illustrated by several cuts. 5s.
- ELEMENTARY PHYSICAL
GEOGRAPHY. With 33 Maps
and Woodcuts. Fcp. 8vo, 1s. 6d.
- LESSONS IN ELEMENTARY
ASTRONOMY; with Hints for
Young Telescopists. With 47
Woodcuts. Fcp. 8vo, 1s. 6d.
- FIRST STEPS IN GEOME-
TRY: a Series of Hints for the
Solution of Geometrical Prob-
lems; with Notes on Euclid,
useful Working Propositions, and
many Examples. Fcp. 8vo, 3s. 6d.
- EASY LESSONS IN THE
DIFFERENTIAL CALCU-
LUS: indicating from the Outset
the Utility of the Processes called
Differentiation and Integration.
Fcp. 8vo, 2s. 6d.
- THE STARS IN THEIR SEA-
SONS. An Easy Guide to a
Knowledge of the Star Groups, in
12 Large Maps. Imperial 8vo, 5s.
- STAR PRIMER. Showing the
Starry Sky Week by Week, in 24
Hourly Maps. Crown 4to, 2s. 6d.
- ROUGH WAYS MADE
SMOOTH. Familiar Essays
on Scientific Subjects. Crown,
3s. 6d.
- HOW TO PLAY WHIST:
WITH THE LAWS AND ETI-
QUETTE OF WHIST. Crown
8vo, 3s. 6d.
- HOME WHIST: an Easy Guide
to Correct Play. 16mo, 1s.
- OUR PLACE AMONG INFI-
NITIES. A Series of Essays
contrasting our Little Abode in
Space and Time with the Infini-
ties around us. Crown 8vo, 5s.
- STRENGTH AND HAPPY-
NESS. Crown 8vo, 5s.

[Continued.]

PROCTOR.—*WORKS* by **RICHARD A. PROCTOR**—*continued.*

STRENGTH: How to get Strong and keep Strong, with Chapters on Rowing and Swimming, Fat, Age, and the Waist. With 9 Illustrations. Crown 8vo, 2s.

THE EXPANSE OF HEAVEN. Essays on the Wonders of the Firmament. Crown 8vo, 5s. Cheap Edition, crown 8vo, 3s. 6d.

THE GREAT PYRAMID, OBSERVATORY, TOMB, AND TEMPLE. With Illustrations. Crown 8vo, 5s.

PLEASANT WAYS IN SCIENCE. Crown 8vo, 5s. Cheap Edition, crown 8vo, 3s. 6d.

MYTHS AND MARVELS OF ASTRONOMY. Crown 8vo, 5s. Cheap Edition, crown 8vo, 3s. 6d.

CHANCE AND LUCK; a Discussion of the Laws of Luck, Coincidences, Wagers, Lotteries, and the Fallacies of Gambling, &c. Crown 8vo, 2s. boards, 2s. 6d. cloth.

NATURE STUDIES. By GRANT ALLEN, A. WILSON, T. FOSTER, E. CLODD, and R. A. PROCTOR. Crown 8vo, 5s. Cheap Edition, crown 8vo, 3s. 6d.

LEISURE READINGS. By E. CLODD, A. WILSON, T. FOSTER, A. C. RUNYARD, and R. A. PROCTOR. Crown 8vo, 5s.

SCOTT. WEATHER CHARTS AND STORM WARNINGS.

By ROBERT H. SCOTT, M.A., F.R.S. With numerous Illustrations. Crown 8vo, 6s.

SLINGO AND BROOKER. ELECTRICAL ENGINEERING FOR ELECTRIC LIGHT ARTISANS AND STUDENTS.

(Embracing these branches prescribed in the Syllabus issued by the City and Guilds Technical Institute.) By W. SLINGO, Principal of the Telegraphists' School of Science, &c., &c., and A. BROOKER, Instructor on Electrical Engineering at the Telegraphists' School of Science. With 307 Illustrations. Crown 8vo, 10s. 6d.

SMITH. GRAPHICS; OR, THE ART OF CALCULATION BY DRAWING LINES,

applied to Mathematics, Theoretical Mechanics and Engineering, including the Kinetics and Dynamics of Machinery, and the Statics of Machines, Bridges, Roofs, and other Engineering Structures. By ROBERT H. SMITH, Professor of Civil and Mechanical Engineering, Mason Science College, Birmingham.

PART I. Text, with separate Atlas of Plates—Arithmetic, Algebra, Trigonometry, Vector, and Locor Addition, Machine Kinematics, and Statics of Flat and Solid Structures. 8vo, 15s.

THORPE. A DICTIONARY OF APPLIED CHEMISTRY.

By T. E. THORPE, B.Sc. (Vict.), Ph.D., F.R.S., Treas. C.S., Professor of Chemistry in the Royal College of Science, London. Assisted by Eminent Contributors. To be published in 3 vols. 8vo. Vols. I. and II. £2 2s. each, Vol. III. £3 3s.

TYNDALL.—*WORKS* by JOHN TYNDALL, F.R.S., &c.

FRAGMENTS OF SCIENCE. 2 Vols. Crown 8vo, 16s.

NEW FRAGMENTS. Crown 8vo, 10s. 6d.

HEAT A MODE OF MOTION. Crown 8vo, 12s.

SOUND. With 204 Woodcuts. Crown 8vo, 10s. 6d.

RESEARCHES ON DIAMAGNETISM AND MAGNE-CRYSTALLIC ACTION, including the question of Diamagnetic Polarity. Crown 8vo, 12s.

ESSAYS ON THE FLOATING-MATTER OF THE AIR in relation to Putrefaction and Infection. With 24 Woodcuts. Crown 8vo, 7s. 6d.

LECTURES ON LIGHT, delivered in America in 1872 and 1873. With 57 Diagrams. Crown 8vo, 5s.

LESSONS IN ELECTRICITY AT THE ROYAL INSTITUTION, 1875-76. With 58 Woodcuts. Crown 8vo, 2s. 6d.

NOTES OF A COURSE OF SEVEN LECTURES ON ELECTRICAL PHENOMENA AND THEORIES, delivered at the Royal Institution. Crown 8vo, 1s. 6d.

NOTES OF A COURSE OF NINE LECTURES ON LIGHT, delivered at the Royal Institution. Crown 8vo, 1s. 6d.

FARADAY AS A DISCOVERER. Crown 8vo, 3s. 6d.

WATTS' DICTIONARY OF CHEMISTRY. Revised and entirely Re-written by H. FORSTER MORLEY, M.A., D.Sc., Fellow of, and lately Assistant-Professor of Chemistry in, University College, London; and M. M. PATTISON MUIR, M.A., F.R.S.E., Fellow, and Prælector in Chemistry, of Gonville and Caius College, Cambridge. Assisted by Eminent Contributors. To be Published in 4 Vols. 8vo. Vols. I. II. 42s. each. Vol. III. 50s.
[Now ready.]

WEBB. CELESTIAL OBJECTS FOR COMMON TELESCOPES.

By the Rev. T. W. WEBB, M.A., F.R.A.S., Vicar of Hardwick, Herefordshire. Fifth Edition, Revised and greatly Enlarged by the Rev. T. E. ESPIN, M.A., F.R.A.S. (Two Volumes.) Vol. I. now ready. With Portrait and a Reminiscence of the Author, 2 Plates, and numerous Illustrations. Crown 8vo, 6s.

WRIGHT. OPTICAL PROJECTION: A Treatise on the Use of the Lantern in Exhibition and Scientific Demonstration. By LEWIS WRIGHT, Author of "Light: a Course of Experimental Optics." With 232 Illustrations. Crown 8vo, 6s.



COLUMBIA UNIVERSITY



0027666018

