





SRF 430028

74. *crue, J. Anat. of Pinnipedia.*

*(Claude W. Hibbard
Lee R. Dice*

TRANSACTIONS

INDEXED

OF

THE ZOOLOGICAL SOCIETY OF LONDON.

VOL. VIII.—PART 9.

LONDON :

PRINTED FOR THE SOCIETY :

SOLD AT THEIR HOUSE IN HANOVER-SQUARE;

AND BY MESSRS. LONGMANS, GREEN, READER, AND DYER, PATERNOSTER-ROW.

1874.

Price 42s.

PUBLICATIONS OF THE ZOOLOGICAL SOCIETY.

PROCEEDINGS OF THE COMMITTEE OF SCIENCE AND CORRESPONDENCE OF THE ZOOLOGICAL SOCIETY OF LONDON.

Svo. 2 vols.

	To Fellows.	To the Public.
Part I. 1830-31. 1 vol. Svo.	Price 4s. 6d. 6s.
„ II. 1832. „	„ 4s. 6d. 6s.

PROCEEDINGS OF THE ZOOLOGICAL SOCIETY OF LONDON.

Svo. 15 vols. and Index. (First Series.)

		Price to Fellows.	Price to the Public.			Price to Fellows.	Price to the Public.
Part I. 1833. 1 vol. Svo.		4s. 6d.	. . 6s.	Part IX. 1841. 1 vol. Svo.		4s. 6d.	. . 6s.
„ II. 1834. „		4s. 6d.	. . 6s.	„ X. 1842. (out of print.)			
„ III. 1835. „		4s. 6d.	. . 6s.	„ XI. 1843. 1 vol. Svo.		4s. 6d.	. . 6s.
„ IV. 1836. „		4s. 6d.	. . 6s.	„ XII. 1844. „		4s. 6d.	. . 6s.
„ V. 1837. „		4s. 6d.	. . 6s.	„ XIII. 1845. „		4s. 6d.	. . 6s.
„ VI. 1838. „		4s. 6d.	. . 6s.	„ XIV. 1846. „		4s. 6d.	. . 6s.
„ VII. 1839. „		4s. 6d.	. . 6s.	„ XV. 1847. „		4s. 6d.	. . 6s.
„ VIII. 1840. „		4s. 6d.	. . 6s.	Index 1830-47. „		4s. 6d.	. . 6s.

PROCEEDINGS OF THE ZOOLOGICAL SOCIETY OF LONDON.

Svo. 13 vols. and Index. (Second Series.)

		Without Illustrations.			With Illustrations.						
		To Fellows.	To the Public.		To Fellows.	To the Public.					
				Price	£	s.	d.	£	s.	d.	
Part XVI. 1848. 1 vol. Svo.		4s. 6d. 6s.		1	1	0	1	7	6
„ XVII. 1849. „		4s. 6d. 6s.		1	1	0	1	7	6
„ XVIII. 1850. „		4s. 6d. 6s.		1	7	6	1	18	0
„ XIX. 1851. „		4s. 6d. 6s.		0	16	0	1	1	0
„ XX. 1852. „		4s. 6d. 6s.		0	16	0	1	1	0
„ XXI. 1853. „		4s. 6d. 6s.		0	18	0	1	4	0
„ XXII. 1854. „		4s. 6d. 6s.		1	0	0	1	6	0
„ XXIII. 1855. „		4s. 6d. 6s.		1	7	6	1	18	0
„ XXIV. 1856. „		4s. 6d. 6s.		1	1	0	1	7	6
„ XXV. 1857. „		4s. 6d. 6s.		1	1	0	1	7	6
„ XXVI. 1858. „		4s. 6d. 6s.		1	12	0	2	2	0
„ XXVII. 1859. „		4s. 6d. 6s.		1	12	0	2	2	0
„ XXVIII. 1860. „		4s. 6d. 6s.		1	12	0	2	2	0
Index 1848-60. „		4s. 6d. 6s.								

ILLUSTRATIONS TO THE PROCEEDINGS OF THE ZOOLOGICAL SOCIETY OF LONDON. 1848-60. Svo. 6 vols.

	To Fellows.	To the Public.
Mammalia 1 vol., containing 83 Plates	Price 2 8 0 3 3 0
Aves 2 vols., „ 173 „	„ 4 15 0 6 6 0
Reptilia et Pisces 1 vol., „ 43 „	„ 1 3 0 1 10 6
Mollusca 1 vol., „ 51 „	„ 1 3 0 1 10 6
Annulosa et Radiata . . 1 vol., „ 90 „	„ 2 8 0 3 3 0

[Continued on page 3 of Wrapper.]

137
P6M97
P.3
Kel.

(Laud W. Hibba)

XVI. *Researches upon the Anatomy of the Pinnipedia.*—(Part III.) *Descriptive Anatomy of the Sea-lion* (*Otaria jubata*). By JAMES MURIE, M.D., F.L.S., F.G.S., &c., late Prosector to the Society.

Read December 6th, 1870.

[PLATES LXXV.—LXXXII.]

CONTENTS.

I. The Skeleton and Cranial changes, p. 501.	V. Hyolaryngeal and Respiratory Organs, p. 546.
II. The Nervous System, p. 517.	VI. The Digestive System, p. 553.
III. Sensory Apparatus, p. 534.	VII. Urino-generative Organs, p. 567.
IV. The Vascular System, p. 535.	VIII. Description of the Plates, p. 573.

HAVING in the first part of this Memoir treated of the exterior, of the fleshy body, and of the ligaments knitting the osseous frame of the Sea-lion, it follows that I next take the skeleton into consideration. H. M. Ducrotay de Blainville, in his magnificent 'Atlas of Osteography,' has figured the skeleton of our Otary, and that of the Walrus and the Common Seal; but neither of the two former is placed in the peculiar and distinctive attitude these animals assume on land. For this reason I have refigured that of the Sea-lion, and added separate illustrations of each of the carpal and tarsal bones—a decided want in his great work. The series of crania figured by me I shall refer to *en passant*.

I. THE SKELETON AND CRANIAL CHANGES.

1. *The Skull.*

a. *General aspects.*—Seen in profile, the skull of the Society's young or nearly adult ♂ specimen of *Otaria jubata* exhibits a remarkable flattening of the upper cranial surface; the base of the cranium from this view also appears pretty level, and is nearly parallel with the horizontal plane of the vertex. From the nasals anteriorly the skull slopes considerably; and posteriorly the occipital truncation is interrupted by the projecting condyle. In old age, as subsequently to be shown, the skull of this species does not retain the above-mentioned features; but these evidently hold good in a certain stage of growth.

Three segments or regions are readily mapped off in this side-view. The first or naso-maxillary one occupies rather less than a third of the entire length of the cranium, and includes the nasal, the intermaxillary, the maxillary bone, and the teeth as far as the fourth premolar. The anterior or inner margin of the orbit bounds this segment



behind. The second, orbito-frontal or middle region is chiefly formed by the orbit itself. It embraces, moreover, a portion of the vacuity of the temporal fossa, externally is guarded by the malar arch, is bounded above by the frontal bone and supraorbital process, and below and within is defined by the pterygo-palatine wall. Its length is almost an exact third of the long diameter of the cranium.

These two anterior segments or provisional boundaries together comprise the facial region, which here bears a proportion to the entire length of the skull as 6 is to 10. The third, hinder and largest segment, the temporo-occipital, is nearly as deep as it is long, and it thus has a marked rectangular configuration.

The upper cranial surface exhibits even more definitely the three regions just spoken of. That portion containing the brain is broad, and more particularly so at the exoccipitals. The frontals are deeply scooped out opposite the zygomatic arch; and this narrowing contrasts with the prominent postorbital processes. Each malar arch has an external flattened aspect, and only slightly veers inwards anteriorly. At the maxillary bones the skull is narrower; and quite in front these and the premaxillæ form an unevenly rounded muzzle; four bosses (see fig. 1) indicate the relative positions of the outer incisors and canine teeth.

b. *The Cranial Bones.*—Anfractuous low ridges chiefly indicate the occipital elements, which otherwise are more or less coalesced. The basiocciput inferiorly is somewhat oblong in shape, and rather longer from before backwards than across; the foramen magnum is nearly circular in figure. The condyles form, posterior to the opening, an inferior projecting and thickened semilune of bone; but the upper margin of the foramen magnum, composed of the inferior hinder border of the supraoccipital, is thin. A large exoccipital canal¹, or condyloid foramen, pierces the bone just within the articulating surface. The supraoccipital forms a well-defined arch, bounded by a broad moderately raised lambdoidal crest. The surface of the supraocciput is very uneven, being marked mesially by a sharp crest, on either side of which are deep hollows for the nuchal muscles.

The parietals are narrow, flat-topped, and short; suturally they are firmly connected with each other, and interossified with the squamous portion of the temporals. The squamous element of the temporal bone is broad and flat. The mastoidal surface is rather prominently ridged just behind the external auditory meatus, or with a moderate-sized paramastoid process; rearwards it is sunk flat, and joins a narrow, scarcely appreciable paroccipital process. The tympanic bone is fair-sized, but not inflat. It is directed obliquely inwards, backwards, and downwards, ending in a sharp margin; superficially (*i. e.* inferiorly) it is broadly grooved and indented on its inner face. A slight ridge is all that indicates a styloid process; but there is a short tooth-like cusp projecting forwards in front of the tympanic, and overlooking the carotid foramen. The glenoideum is narrow antero-posteriorly, but broad transversely, and moderately

¹ A term proposed by Mr. H. N. Turner, see P. Z. S. 1848, p. 75.

scooped; the jugal extension is a tapering rod. The jugal bone is not very stout, though at its middle high, in an upward angle. Bifurcate in front, it forms a firm union with the maxillary retrovert process.

A considerable part of the face or muzzle is taken up by the intermaxillary, so that, excepting the canine eminence, each maxillary chiefly outflanks the cheeks only. The basal segment of the maxilla rises high, is flatly convex, and of fair breadth. Behind, the canine eminence is deeply and widely grooved, where lie the thick infraorbital nerves and vessels. There is a small but distinct antorbital prominence. The maxillary orbital surface is moderate, and tolerably vertically concave forwards. The palatine region of the maxillary is of fair breadth, and terminates in a long spear-shaped palatine strip guarding the palatine plates of the palate-bones almost to the posterior nares. Each premaxilla is flattish and truncate anteriorly towards the alveolus, and rises therefrom in a narrowing outspread arch enclosing the anterior nares. The narial orifice in front is heart-shaped, $1\frac{1}{2}$ inch deep and $1\frac{1}{4}$ inch at its upper widest part. The upward strip of the premaxilla is inserted between the nasal and maxillary bone as a narrow wedge. The large turbinals are much convoluted and almost occlude the narial passages, but within the maxillary area. The vomer is in great part hidden, and has no connexion with the horizontal palatine plates.

The nasals in some respects are like the premaxillaries in being wide below and narrow above. Each is 1.8 inch long, and about half an inch at widest or below. They are suturally connected nearly their whole length, posteriorly divaricating; the forks fit into the frontal. One half of their outer margin abuts against the maxilla, the remainder in front lies upon the premaxilla.

The frontal bones are peculiar from their length, postorbital processes, and great constriction behind these. Their upper surface is smooth and flat anteriorly, and widely convexly arched behind. Their orbital surfaces are of great length, considerably scooped out, and but moderately deep, a long vacuity existing between them and the maxillo-palatines.

The palatine plates of the palate-bones, as has been noticed by many authors, are uncommonly long and broad—in this case fully $2\frac{1}{2}$ inches in antero-posterior, and above $1\frac{1}{2}$ inch in transverse diameter. Their hinder margins are transversely abrupt, and the posterior nares constricted. Laterally and exteriorly the palatine walls reach high, and present a great pterygo-sphenoidal surface.

The basisphenoid is short, but wide. The pterygoid processes stout, and with a sharp recurved hamular process. The alisphenoids are fair-sized, distinguished by a square boss where they join the postfrontals. There seems, however, to be a large orbital plate: but this is mainly composed of the postfrontal; for the orbito-sphenoidal area is very narrow and small.

c. *The Mandible*.—The two halves of the inferior maxilla have no bony ankylosis, but are united to each other by synchondrosis. This separation is not merely the result of

age; for I find such symphyseal cartilaginous union obtains, not only in the adult specimens of *Otaria jubata*, but even in undoubted old animals of the same species. Each body possesses a shallow curve, the concavity of which looks inwards; and the halves together thus form a tongue-shaped arch, ending in front in the broadish deep symphysis. Immediately beneath the well-marked incisor-fossæ and foramina, the edges of the symphysis pout forwards in a low but distinct median mental crest, some half an inch in vertical depth. Below this the rami gradually diverge from each other, inclining downwards and backwards as they each form a thickened posterior symphyseal angle.

The extreme length of the lower jaw measures 7·25 inches; the greatest diameter (which is at the condyles) is 5·3 inches.

A row of foramina as numerous as the molar teeth on the left side, and less by one on the right, occupy a line trending downwards from the alveolus, opposite the last molar, to below the middle of the bone, and anteriorly vertical between the first and second molar teeth. The most anterior of these is the largest, and may represent the mental foramen of Man; but here, in the Sea-lion, the vascular supply is great, and accordingly supplied with an increased number of nutritious channels. A narrowing and thinning of the bone distinguishes or separates the body from the ramus; this nearly median contraction has the effect of giving the side of the jaw a somewhat long and irregularly bordered figure-of-eight contour. At this narrowest part, just behind the last molar, there is a breadth or vertical depth of 1·2 inch, and a thickness of 0·4. From it the ramus commences, and very gradually widens, its thin coronoid lamina rising at an obtuse angle to the body. The angle, a flattened rhombic plate, is inflect, with a deepish emargination in front. The condyloid neck is compressed antero-posteriorly.

d. *Foramina of Lower Base*¹.—The anterior palatine are fissures of some magnitude. Marked postpalatine foramina do not obtain; but instead a linear series of minute openings reach from opposite each penultimate tooth back to the end of the maxillary splint, in apposition with the lengthened palatal arch. There is an alisphenoid canal perforating longitudinally the base of the pterygoid, and communicating with the sphenoorbital region. A Vidian canal, admitting a fine bristle, can be traced along the inside of the pterygoid root. A fair-sized foramen ovale lies behind and outside the alisphenoid canal; and exterior to it is the postglenoid foramen. Directly posterior to the ovale, and in a somewhat irregular transverse recess, there are close together the lacerum medium, anterior opening of the carotic canal, hiatus Fallopii, and fissura Glasseri—the said recess, moreover, being surmounted posteriorly by the tubercle developed in front of the tympanic. The orifice of the meatus auditorius externus is sunk in a conical hollow between the mastoid eminence and the tympanic bulla, the large stylomastoid foramen being situate close to its rear. Still further back, and more towards the

¹ Compare respectively the interesting researches on this subject in the Carnivora by H. N. Turner, as cited, and Prof. Flower, P. Z. S. 1869, p. 4; also Prof. Owen's pithy descriptive remarks on specimens in the Hunterian Museum.

median line, is the very great horseshoe-shaped jugular vacuity. At its fore border, partially hidden within the bone, is the entrance of the carotid canal, which pursues a course through the tympanic, opening, as aforesaid, at the lacerum medium. A shelf of bone divides the postcarotic foramen from the deeper-placed aquæductus cochleæ. Lastly, to the rear, and a trifle within the jugular fossa, is the basal opening of the anterior condyloid foramen.

e. Interior of the Skull.—As regards peculiarities in the form of this cavity, allusions will be found under the description of the encephalon; here I confine my remarks to the osseous superficies and foramina. Laterally the walls of the calvarium are exceedingly thin—anteriorly, or in the frontal region, excessively thick and cancellous—occipitally equally porous but very moderate in thickness, and with capacious venous channels. The bony tentorial plate, necessarily broken on removal of the vertex, as displayed in fig. 10, is uneven, and pitted with minute and larger-sized foramina. The anfractuositities of the canopy of the skull, and the irregular cerebral-pitting depressions are most unusually well marked; and, moreover, innumerable minute and larger-sized foramina bear evidence of the great vascularity of the osseous structure. The longitudinal venous groove is very deep and well pronounced; and so are the furrows lodging the meningeal arteries &c.

The floor of the cavity (somewhat bluntly boat-shaped) possesses numerous irregularities and vacuities; but the orbito-frontal parietes are smoother and incline to the perpendicular. The olfactory fossæ are narrow, high, and deep, the cribriform plates of the ethmoid assuming the vertical, with a retroverted spinous partition. Immediately behind the latter is a single low-arched perforation for the optic nerves, each nerve escaping into the back of the orbit through the orbito-sphenoid bone, the perforation drilling the median wall (fig. 5). Along the solid mid-basilar plane, successively from before backwards, the noteworthy points are:—adjoining the optic arch a transverse cleft, through non-ossification of præ-sphenoid suture; a full broadish processus olivarius, comparatively deficient in mid clinoid processes; a deeply excavated sella turcica, whose bayed front margin carries relatively large angular postclinoid processes; a scooped basi-sphenoid lodging the pons Varolii; to the rear of this, in the basioccipital, a great lopsided hollow (possibly a vascular recess), chiefly to the left, though shown on the right in the reversed fig. 9.

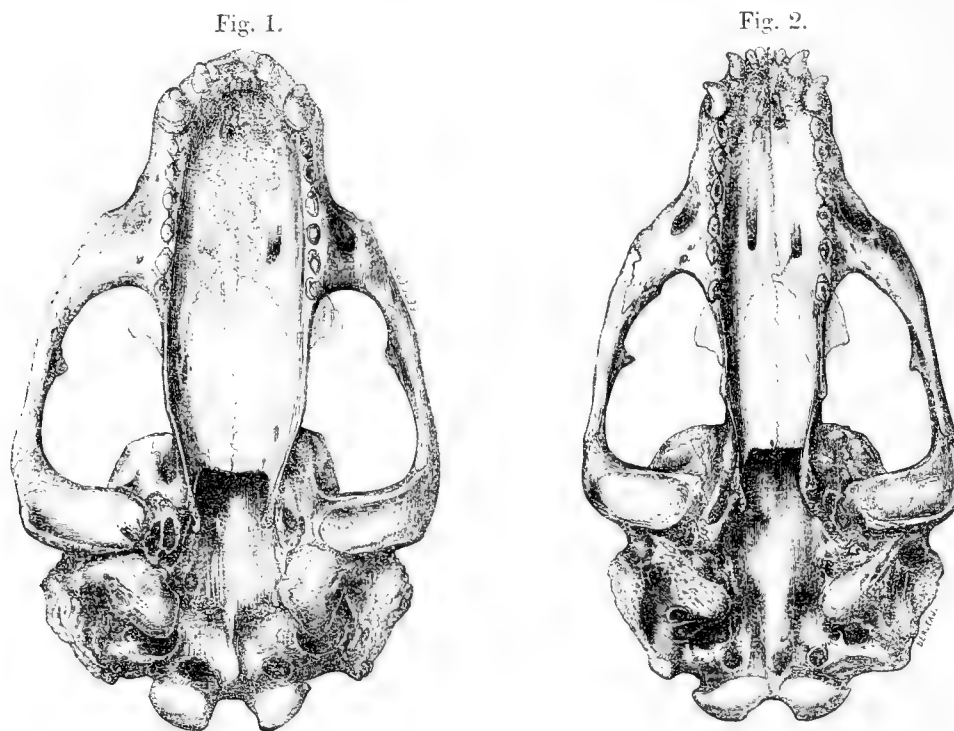
At the sides defined areas correspond to the orbito-parietal and temporal lobes of the cerebrum, whilst that which receives the cerebellum and lateral sinuses is markedly characterized by its depth, prominent nodular periotic, and large jugular orifice.

Of other fissures and visible foramina, that agreeing with the lacerum anterius extends half an inch antero-posteriorly, an outer eaved bony plate partly overriding it; a groove about another half inch leads back and outwards to a large foramen ovale, these and an inner adjoining space (in the fresh subject) being occupied by the Casserian ganglion and fifth-nerve divisions. What apparently answers to the lacerum medium (giving ingress to the internal carotid artery) and the foramen spinosum is a widish perforation and

adjoining minute accessory tiny open fork, situate behind but to the inside of the ovale, and immediately in front of the periotic. The latter nodular bone dominantly projects, a concavity of the cerebellum at the flocculus resting thereon. Anteriorly the aquæductus Fallopii is barely visible in this view; neither is the meatus auditorius internus, which looks towards the median line; and the aquæductus vestibuli similarly occupies a recess on the posterior face. Below the last is the carotid canal, behind the large jugular perforation. An anterior condyloid foramen pierces the corner betwixt basi- and exoccipitals, running nearly vertically towards the jugular groove.

For a description of the longitudinal vertical section of the aged skull, viz. that in Pl. LXXVII. fig. 22, I refer to Prof. Owen's notice in the *Cat. Coll. Surg.*, specimen No. 3971. It is sufficient for my purpose to call attention to the great occipital crest, thickness of frontal, position of ethmoid and turbinals, maxillo-palatine cleft, and osseous tentorium, as all more fully pronounced in character than what obtains in younger skulls which, nevertheless, in other general respects agree.

f. *Sexual differences.*—In a previous communication to this Society, I directed attention to certain visual distinctions extant between the male and female skulls of *Otaria jubata*, and gave figures of the same, hereunder reproduced. I was not then aware that Owen had commented on the same fact, and therefore now append his remarks in a footnote¹.



Palatal views of adult male (fig. 1) and female (fig. 2) skulls of *Otaria jubata*. To scale $\frac{1}{3}$ nat. size.

From P. Z. S. 1869, p. 103.

¹ "It differs from that of the male in its inferior size, but agrees with it in all essential or modifiable characters. The more feeble bite and smaller temporal muscles have not required the elevation of the temporal

They apply to the skull figured by me in Pl. LXXVII. figs. 16, 17, which is that numbered 3968, Cat. Coll. Surg. Besides the points here displayed in palatal views, a comparison of the crania in the accompanying Pl. LXXVII. further bears out statements concerning said differentiations¹.

g. Progressive Cranial changes.—Although writers previously had incidentally adverted to an alteration in the form of the skull with age in some of the Eared Seals, yet no one has so forcibly pointed this out as Dr. Gray². In one of his papers on the *Otariadæ* he justly remarks³:—“The skull of these animals changes so much in form as the animal arrives at adult and old age, that it is not always easy to determine the species by it, unless you have a series of them of different ages and states to compare.” So much do the parietal crest and other osseous prominences shoot forth in the Sea-bear or Great Sea-lion of some travellers (*Otaria jubata*), that between young and old specimens changes as great and characteristic as obtain in the cranium of the Gorilla occur in them.

In tracing the development of the skull of this species of *Otaria*, I have had the advantage of comparing side by side a large number of both sexes and various ages. I tabulated a series of proportional measurements of the relative growth of different regions, but refrain from introducing the table in this place. Instead I have illustrated, in Series Pl. LXXVII., examples of five different stages of the development, to each of which I append remarks. My figures have been drawn to a uniform scale, quarter natural size; I nevertheless subjoin, in inches and tenths, the absolute length, breadth, and height of each, for greater precision.

Crania of <i>Otaria jubata</i> .	1st stage. 15 to 20 days.	2nd stage. Yearling.	3rd stage. ♂ ad. (nearly), ♀ ad.		4th stage. ♂ old.	5th stage. ♂ very old.
Nos. in Cat. Coll. Surg., except sp. 3rd column	3971 c.	3971 B.	Z. S. sp.	3968.	3971 A.	3971 E.
Greatest length, premaxilla to condyle	6·5	8·5	10·6	11·0	12·8	14·3
Greatest breadth	3·9	4·6	6·5	5·8	7·5	9·4
Greatest height, without mandible line cutting } mastoid }	3·6	4·0	4·6	4·7	6·0	8·2

First stage. In the young skull of a few weeks old the brain-region is in prepon-
ridges into a parietal crest, nor any considerable development of the occipital ridge. The boundary of the large mastoid is well shown in this skull, together with the share which the paroccipital takes in this rough muscular ridge external to the petrosal. The middle surface of the basioccipital is less carinate than in the male. The entry of the carotid canal in the petrosal is more distinct from the jugular vacuity. The broad superorbital processes of the frontal are less angular. The canines and external incisors of the upper jaw are smaller in comparison with the molars. The first and second incisors have bifid crowns. The angle of the lower jaw is produced and bent inwards more than in the male.”

¹ I may also refer to a most valuable communication “On the Eared Seals,” by Mr. J. A. Allen, Bull. Mus. Comp. Zool. Camb. U. S. vol. ii. no. 1 (1870-71), wherein the author, with occasionally sweeping criticism, has most adroitly woven together many facts concerning sexual variation and changes of the skull in the North-Pacific species.

² P. Z. S. 1859, p. 360, and Cat. of Seals and Whales in B. M. ³ Ann. & Mag. Nat. Hist. 1868, i. 100.

derance. It occupies about half the total length, the other half being divided betwixt the orbital region and the face proper or maxillo-premaxillary parts. The entire skull is low, broad, and flat on the top. Superiorly, from occiput to nasals, approaches an equal-sided triangle. The breadth of the mid frontals is not only relatively but absolutely a trifle greater than in the aged animal. On the other hand, the prefrontal processes scarcely extrude. The jugals have but slight arching. The occiput is altogether full, flat, and vertical; the condyles project little. Premaxillæ comparatively short and high; speno-orbital vacuity shallow, height proportionally great to length. Palate shallow and short. Basioccipital and sphenoid parts smooth, and all other processes small. Mandible with shallow shelving symphysis; a wide ramal arch; condyle short-necked and low-set.

Second stage. In this cranium, authenticated as a yearling, there is a sensible change of cerebral to facial and prefrontal areas. Maxillæ and premaxillæ begin to lengthen. Mid frontals narrow relatively to increase of prefrontal processes. The brain-region becomes somewhat quadrangular; occiput rougher and begins to shoot backwards. Temporal groove deepens; jugal arch increases. The permanent teeth in place give more character to the mouth; lengthening and deepening of palate obvious; the hamular processes approach. Eminences of speno-occipital and other regions show indications of growth, but are not prominent. Condyles and coronoid processes of lower jaw exhibit a tendency to vertical elevation; mental portion of symphysis inclined to become tuberoso.

Third stage. Face, orbito-frontal, and brain-division now bear more equal proportion; that is, the two former have increased in a greater ratio than the latter. The mid frontals appear more scooped by reason of prefrontal development. By elongation of condyles and concomitant increase of basi- and exoccipitals, the occiput acquires a reverse obliquity to the first stage. The outline of the brain-cavity remains in abeyance, whilst temporal and occipital crests become apparent, though yet moderate. Mastoid and preoccipital eminences acquire a certain prominence. Orbito-jugal arch wider; premaxillæ decidedly elongate. Teeth, especially canines, enlarged. Palatal grooving deepened, the pterygoid processes nearing, hence postnares less open. Muscular impressions on basioccipital well scooped, basiocciput turning upwards behind. Symphysis lengthened; upward tilt of ascending ramus. In this stage sexual distinction becomes evident, although there is still considerable resemblance between them.

Fourth stage. Here the changes become very notable. The excessive growth of the canines of the male produce rounder, fuller premaxillæ. Brain-expansion is arrested. Mid-frontal width retrogrades, while prefrontal progresses. The jugal arch expands, its orbital segment deepens, its post upper angle rises; the maxillary surface of orbit gets fuller. Parieto-occipital crests and processes acquire importance; and this causes the after part of the top of the skull to be elevated and no longer smooth and broad. Moreover on each side, at the fronto-parietal suture, bony projections appear. Arching

of palate and lengthening of pterygoids go on apace. The tympanic bones descend and become laterally compressed, whilst the carotic canal assumes a more vertical direction posteriorly. Meantime the basisphenoid shelves upwards and forwards, the paramastoids roughly bulging out. Growth of the occipital crest alters the back of the skull to a kind of trefoil outline. Increment of the teeth widens the premaxillary region and anterior nares. There is an upturning of the ascending ramus and an inflection of the angle. The bones altogether become more massive and rugose.

Fifth stage. As the skull ripens to old age, particularly in the male, all the characteristic points of the fourth stage are carried out by excessive growth of processes, crests, and other superficial developments of bony lines, spicules, and nodules. The cavity of the eye looks forwards; the space behind for the temporal and masseter muscles enlarging as fleshy bulk preponderates over cerebral character.

It follows that all the aforesaid changes are an exact counterpart of what obtains in the Gorilla. In early youth the brain is functionally predominant. Then the teeth assume importance with a corresponding facial accession. Lastly, whereas brain-increment is apparently arrested, the muscles of mastication, those of the throat and neck, indeed all connected with the head, and therefore involved in the organs of offence and defence, paramountly swell in bulk and strength; nerves and blood-vessels augment proportionally. Thus from the featureless skull is evolved the rugged, immense, and terrible-looking carnivorous cranium peculiar to this and certain other genera of the Eared Seals¹.

2. *Spinal Column and Thorax.*

a. *Vertebræ*.—Restricting myself to the Society's male specimen, its vertebral elements were as follows:—7 cervical, 15 dorsal, 5 lumbar, 4 sacral, and 8 caudal; or a total of 39 pieces.

The cervicals are all large relatively, the largest of the series. The first 5 or 6 dorsal, from their greater spines and transverse processes, also seem large. The remainder of the dorsals decrease in size as regards height and breadth. The lumbar vertebræ appear of moderate size, the three hindermost being rather the stoutest. The 1st sacral is of fair size; the remainder, with the caudal, form a graduated series, none of which are large. The spinal column (46 inches long) does not seem to hinge on any particular vertebra, all being equally movable by the thick cartilaginous intervertebral disks.

The axis is the only cervical with a long spine. The first four retrovert neural spines of the dorsal are longest and subequal; there is no other prominent spine behind. All the inferior processes of the cervical vertebræ, as De Blainville² has depicted, are stout

¹ See Allen, as cited, for the genera *Eumetopias*, *Zalophus*, and *Callorhinus*. Dr. Gray, also, in several communications to the Society's Proceedings, has shown cranial alterations in some rarer forms, since the present memoir was read.

² 'Ostéographie,' plate vii. Atlas, part 2.

but short. The dorsal vertebræ present no striking difference from those of Seals generally. Gradually narrowing, the dorsals merge into the lumbar vertebræ, which are likewise larger, but not specially characterized from other Phocine genera. In computing the presence of four sacral vertebræ, I am guided partly by the nervous distribution and partly by the fact that the said number bears closest resemblance to each other of the series. Together they are distinguished by their raking neural arches and spines, subequal in length, and lying upon each other almost in an imbricated manner. The foremost has the largest body, the modified great flat-surfaced transverse processes forming a sacro-iliac synchondrosis, a facet of the second assisting. The bodies of the 2nd, 3rd, and 4th are carinate, but, nevertheless, have not the depth of the 1st. The pedicles of their transverse processes are uncommonly squat, a retral bar, however, enclosing an intertransverse foramen.

In our adult male animal under consideration, there are eight caudal vertebræ remarkably movable upon each other by the intervention of thick interarticular fibrocartilaginous disks. The vertebræ diminish regularly from the first to the last, which is of very small size, and but incompletely ossified. The first two have each backwardly directed spinous processes. The third has two imperfectly formed thick laminar elevations, but no spine. All three of these vertebræ have well-developed transverse processes. From the fourth to the eighth caudal element there are no spinous or transverse processes, slightly raised elevation of the bone alone representing these structures.

b. *The Ribs*.—Of the fifteen pairs of ribs, the 1st, 2nd, and 3rd are the shortest, then follows the 15th. From the 4th backwards to the 9th and 10th, there is a gradual increase in length, from which they decrease as they go backwards.

The subjoined Table gives the respective costal lengths in the young and adult animals. The measurements in each are from the angle to the costal tip:—

Ribs.	Young.	Adult (Z. S. sp.).	Ribs.	Young.	Adult (Z. S. sp.).
1st	1·5	2·7	9th	6·5	10·0
2nd	2·1	3·5	10th	6·2	10·0
3rd	3·2	5·2	11th	6·2	9·9
4th	4·1	6·8	12th	6·0	9·4
5th	4·7	7·8	13th	5·7	8·6
6th	5·3	8·9	14th	5·2	7·7
7th	5·9	9·1	15th	3·9	6·1
8th	6·1	9·5			

The first rib has a stout roundish straight body, with a very slight antero-posterior compression. The neck, set almost at a right angle to the body of the rib, is thick, and markedly grooved in front and behind. The capitulum is of moderate size; it articulates with the anterior part of the body of the first dorsal vertebra, barely impinging against the intervertebral cartilage. The prominent tubercle, and its articular

facet, together nearly $\frac{1}{2}$ an inch long, in this and the succeeding rib, shoot upwards nearly in the line of the axis of the body itself. Indeed these processes seem almost to form the true termination of the ribs, from which the neck and head proper seem but forked offsets.

The second rib diverges slightly from the pattern of the first, inasmuch as it is rather longer, thinner, and possesses a wider sweep or curvature from the angle to the neck. There is just a perceptible indication of a bending backwards or semi-twist at the angle, but not the same flattening and bulging which obtains in the succeeding ribs. The scalene tuberosity, tolerably well marked in the first rib, is diminished and well-nigh obsolete on the second.

The third, fourth, and fifth ribs are fashioned not unlike each other, and with but slight individual variation. They present different yet scarcely appreciable degrees of curvature and twist, the body altering in such a manner that what was the anterior surface in the first and second ribs becomes in them the outer flattened surface. Their sternal extremities are more compressed and elliptical in outline than the ribs in front or those immediately behind. The angles of the three ribs in question are better indicated than the others in the series, but none have it well pronounced. The fork-like head and elongated tubercle distinctive of the first two ribs undergoes a gradual change in the third, fourth, and fifth. The neck becomes vertically deeper, less constricted, and consequently appears shorter, although not in reality so. The tubercle diminishes in length, and its articular facet acquires a more backward direction. The anterior groove at the angle lessens from the third to the fifth. The enlarged capitulum of each assumes an obliquity of condition, and with a fore-and-aft articulating face abuts upon the posterior surface of the body of the vertebræ in advance and the anterior surface of its own numerical vertebra. From the sixth to the twelfth costal elements there is a very gradual progressive change in the amount of curvature, and in reduction of the tubercle. The differences between the intervening ribs will be best comprehended by comparing, say, the sixth with the twelfth, rather than attempting to describe the next to insensible modifications which the ribs seriatim undergo.

The sixth rib, then, with similitude to the fifth, is long, of moderate breadth and thickness, narrowed and slightly triangular in transverse section about its middle, but flatter and compressed from within outwards, below. It joins the sternal cartilage by a truncated somewhat bulbous end. The outer surface from the angle downwards is plain and smooth, the front and hinder edges gently rounded. The unequal arch of the body is deepest at the angle. The latter is not protuberant but definable, the more readily so as the rib at this part as well as the neck and head is compressed antero-posteriorly. The tubercle is of fair size; the neck and head large, but uniform in diameter. The most notable changes in the twelfth rib are little or no antero-posterior compression, no defined angle, the rib from one end to the other presenting a wide, low, regular arch. The head, neck, and tubercle have decreased in ratio, the division

between them being less pronounced. The rib at the angle has lost the semi-twist possessed by the sixth; but instead there is a more regular spiral, so that the outer surface has a somewhat backward inclination below. The sternal extremity is thinned. Surface within and without body biconvex, with sharp antero-posterior edges.

The 13th, 14th, and 15th ribs have little or no distinction between head, neck, and tubercle; they are elliptical in their long diameter, weak, slightly concave in arch, the free extremities tapering. They all articulate, with but a single vertebral body. The zygapophysial articulating surface is on their inner sides. Instead of a convex angle there is a shallow concavity in its place, which is very slight in the 13th, a little more so in the 14th, and distinct in the 15th.

c. *Sternum*.—De Blainville's representation of this bone ('Atlas,' i. ii. pl. vii.) calls for a few remarks on my part. These refer to the intersternal and superadded cartilaginous elements. As the above authority shows, there are eight sternal bones, the manubrium being prolonged beyond the first rib; but the attached rib-cartilages are nine in number. In these respects the Society's specimen agrees. De Blainville's more aged animal and dry skeleton, however, have misled him—first, in assigning too limited an area for the intersternal cartilages; secondly, in the abutment of the eighth and ninth sternal ribs against the seventh bone instead of behind it on the cartilage; and, thirdly, in the xiphoid cartilage being narrow and straight, instead of spatulate. These omissions, through a defective skeleton, have to some extent been already rectified from the present specimen, by my friend Mr. Parker¹. The manubrium has a flat dorsal and carinate ventral surface, the anterior broader segment terminating in a forwardly projecting blunt cartilage an inch long. The posterior segment is much narrower, stouter, and vertically deeper than the anterior portion. The second, third, fourth, fifth, and sixth meso-sternal elements range about one size, and differ from each other chiefly as regards breadth and thickness. From being round, with bulbous extremities, they gradually alter, becoming broader, thinner, and flatter. The seventh piece is unlike the sixth in having an arched instead of truncate posterior extremity, the rounded edges thus giving greater space to the intersternal cartilage, whereby, as aforesaid, the eighth and ninth sternal ribs join it.

The "metosteon" of the xiphoid precisely resembles one of the phalanges of the manus, but is thinner; the xiphoid cartilage has a short narrow handle, ending in a broad rounded extremity, not quite pyriform, as Parker remarks, and certainly entirely different from De Blainville's figure.

The several bones from the præ- to the xiphosternum measure respectively 2·8, 1·6, 1·4, 1·3, 1·4, 1·5, 1·9, 2·5 inches long. In a young female of the same species which I have had an opportunity of comparing, these bones had the following long diameters

¹ A Monograph of the Structure and Development of the Shoulder-girdle and Sternum in the Vertebrata (Ray Soc. 1867), p. 216, pl. xxx. fig. 7. Witness also fig. 25, pl. lxxii. of pt. ii. of my own memoir.

=2.0, 0.9, 1.0, 0.8, 0.8, 0.95, 1.1, 1.6. Thus these bones present the same relations as regards size in the young and older animal. It is not so, however, with the cartilages, which in the young Otary are each equal to half the length of the bone, but in the adult no more than a third.

The sternal cartilages are thick, long, and flexible; but the last three are shorter than the others, and comparatively free. The first cartilage articulates with the præsternal bony facet. The second, third, and fourth are attached to the middle of the intersternal cartilages. The fifth, sixth, and seventh join the intersternal cartilages more obliquely, and are inserted chiefly into the hinder corners of the 4th, 5th, and 6th sternal bones. The eighth cartilage is fixed to the rounded postero-outer border of the seventh bone; the 9th to the middle of the cartilage.

The cavity of the thorax and abdomen enclosed by the ribs, is long, deep, and narrow, according as the ribs are expanded or otherwise, heart-shaped, =22 inches long. The ribs either stand out or are flattened. This is chiefly permitted by the looseness of the cartilaginous and ligamentous union, also length and flexibility of the sternal cartilages.

3. *Bones of the Extremities.*

a. *Pectoral Limb.—Scapula.* This has not the arched or semilunar shape of the Common Seal, but is a broad irregularly trapezoidal thin bone. It measures in our specimen 6.5 inches from the glenoid head (the cartilage *in situ*) across to the middle vertebral or posterior border, and it is 8 inches in diameter between the superior and inferior angles. The spine is of moderate nearly uniform height, and possesses a downward slant, overarchng very slightly the infraspinous fossa. It is carried onwards to within $\frac{1}{2}$ an inch of the glenoid cavity, whence an acromion process rather broader than the spine itself reaches almost to the articular fossa. In the recent state a ligament converts this acromial arch into a foramen. The glenoidal cavity is shallow and more oval in shape than in *Phoca vitulina*. The neck is very short, broad, and stout. Only a rudiment of the coracoid process is present. The supraspinous fossa occupies the upper three fourths of the bone¹. A slightly raised ridge proceeds from the upper third of the neck backwards and towards the superior angle, dividing the supraspinous fossa into two shallow concavities. The narrower, but deeper, infraspinous fossa has the oblique ridge and groove for the teres major distinctly marked. The space lodging the infraspinatus muscle is hollow, and not convex.

Humerus. Figured in three different views by De Blainville (*op. cit.* pl. viii.), is short, stout, and peculiar-looking from the great development and prominent nature of the deltoid eminence. The greatest length of the bone in a straight line is $6\frac{1}{2}$ inches, being $\frac{1}{4}$ of an inch less than the radius, and $1\frac{3}{4}$ inch shorter than the ulna. The

¹ *Vide* Cuvier, 'Ossemens Fossiles,' tom. v. pt. i. p. 224, and De Blainville, *op. cit.* text, tom. ii. p. 23, Atlas,' vol. ii. pls. iii. & viii.

axis of the three-faced shaft is nearly perpendicular, though at first sight it does not appear so, the deltoid projection giving it outwardly somewhat the contour of the letter S. The latter forms a thick anterior projecting and somewhat laterally compressed plate of bone extending from the root of the unusually greater tuberosity downwards, mesially, four fifths the length of the shaft. Head and neck sessile. Condylod ridges short, but giving great lateral breadth to the lower half of shaft. Inner condyle most marked; eminentia capitata and inner trochlear eminence the reverse. The further positions of the bones of the elbow-joint, and their singular gliding movements upon each other, I discussed when treating of the ligamentous system (consult pt. ii. vol. vii. p. 581).

Ulna and Radius. Throughout the Pinnipedia the ulna is hatchet-shaped, altogether flattened, especially the olecranon (as the blade). Slight modifications distinguish the different families and genera (witness Cuvier and De Blainville's illustrations &c.). In *Otaria jubata* the outer extensor surface of shaft is gently convex in its axes, the inner flexor is concave; distal epiphysis conical. The even-surfaced greater sigmoid notch is almost vertical, with the exception of a small inferior projection (=the coronoid process) upon which the inner knuckle of the humerus plays; and on the radial side of this projection an oblique shallow concavity represents the lesser sigmoid notch. A widish inward scoop separates the humeral articulation from the top of the olecranon process, which latter, thinning, sweeps backwards, terminating in a dependent angular process. The radius has a well-defined neck, short but large and wide shallow head. From the upper third the roundish shaft widens and flattens to its massive lower extremity, $2\frac{1}{2}$ inches broad, with thickness in proportion.

Carpus, Metacarpus, and Phalanges. Of the seven carpal bones the amalgamated scapholunar is the most remarkable, on account of its great size and of its claiming the major share of the articular surface of the first row of bones. It is in opposition with all the bones of the second row, the cuneiform, and radius, in all six; but it plays against these virtually by three faces. The radial is large and convex; the face in contiguity with the os magnum and unciform is somewhat vertically scooped, a mesial ridge defining the province of each bone, whilst the cuneiform impinges against the posterior corner of the latter; lastly, the trapezio-trapezoidal is extensive, rhomboidal-outlined, concave from without inwards, and convex from above downwards. It is this peculiar disposition of the latter, in unison with a certain oblique or excentric movement of the parts, which enables the animal to use its fore flipper on land as a foot; for the proximal carpal row is then raised from the horizontal basal line, as in a great measure is the unciform. Thus the wedged-in magnum, the trapezoides, and the trapezium of the carpals form the base of support; and that also accounts for the singular radial flop with which the manus is laid down in walking. According to the amount of bend of the wrist-joint, so does the cuneiform in a lesser or greater degree come into connexion with the bones. Its postero-outer face receives the pisiform and point of the ulna in a

wide hollow; the inner glides upon the radius; a narrow corner of the anterior impinges against the scapholunar, its remainder articulating with the unciform; and an outer facet partly accommodates the fifth metacarpal as the manus is twisted outwards. The pisiform is a small bean-shaped bone, its free end directed outwards, its attached end lying upon the epiphysis of the ulna and the cuneiform of the four articular surfaces presented by the trapezium; that towards the second metacarpal is a mere corner facet. The trapezoidal is smaller than the trapezium, its palmar surface being very considerably narrowed. It just touches the third metacarpal, besides its ordinary facets for scaphoid, magnum, trapezium, and first metacarpal. The os magnum is the least-sized bone of the distal row, and, reversely from the last, has a narrow dorsal and broader palmar surface. It appears not to come into contact with the second metacarpal, and sinks in obliquely and below the scapholunar. Thus when the manus is planted on the ground the latter bone overrides it in great part. The unciform is about equal to the trapezoides in magnitude. It is surrounded by five bones, the fifth metacarpal more usually constituting its outer boundary.

The metacarpals are of most unequal dimensions, that of the pollex being of inordinate proportions. The lengths from 1st to 5th are as follows:—4·25, 3, 2·3, 2, and 1·9 inch. The first is by far the broadest, thickest, and flattest; the third thinnest and roundest. The fifth differs from the fourth in being a wider bone. The proximal ends of the outer four are enlarged and tuberoso; the width of the innermost (first) subdues its otherwise bulky character.

The phalanges, of normal number, bear a relation to the size of the metacarpals; that is, the innermost is largest and longest, the fifth digit a trifle stronger though shorter than the fourth. The proximal phalanx of the thumb is powerful, its distal one a short flat figure of eight; respectively they are 3·9 and 1·5 inch long. The lengths of the remainder of the series are:—second digit 2·7, 2·2, 1; third digit 1·9, 1·6, 1; fourth digit 1·5, 0·8, 0·3; fifth digit 1·3, 0·3, 0·2 inch. The spatulate cartilages and that extraordinary one of the pollex, which form the digital extremities, I drew attention to and figured in my former anatomical contribution.

b. *Pelvic Limb.—Pelvis.* The long axis of the entire pelvis is almost identical with that of the spinal column, and even in the strange attitude of walking it accords with the lumbo-caudal region¹. Ilio-pubic and ilio-ischial angles cannot be said to obtain. Each innominate bone approaches posteriorly so as to produce a long narrow V-shaped pelvis, and with such variation in the thickness of the bones that the brim is lozenge-shaped. The ischium and pubis are narrow bars uniting in a thin rounded plate the tuberosity, and enclosing a lengthened oval obturator foramen. Their acetabular ends thicken; the acetabulum itself is large but not deep. The ilium is a broader strip of bone, slightly outturned anteriorly, its sacral border inturned, and with moderate sacro-

¹ Cuvier (*l. c.* p. 226) briefly distinguishes between the pelvis of the Earless and Eared Seals, a point which Allen in his paper (*l. c.* p. 27) with justice lays great stress on as characteristic of the two groups.

iliac synchondrosis. Measurements:—Extreme pelvic length 7·3 inches, ilium 3·1, pubis 4·2, as is also ischium to mid-acetabulum; the latter 1·3 long, anterior iliac angles 3·3 apart, mid iliac breadth or depth 1·2, line cutting acetabulum 1·7, mid ischio-pubal 1·3. Diameters of brim—conjugate 4·7, transverse 1·5, oblique 3·3. Diameters of outlet—antero-posterior 1·4, transverse 0·4.

Femur and Patella. The former, at its upper end, has head and trochanteric eminence on a level simulating one another—and neither prominent, from the antero-posterior flattening and breadth of the short shaft. The intercondyloid fossa is shallow, the innermost knuckle largest, and both rather square in figure from being truncate below. Femur is 4 inches long. Patella small, rounded, and with a flat articular surface.

Tibia and Fibula. The straight rodlike fibula usually stands quite behind the tibia; its narrowed shaft is sharply triangular. Head badly defined, smaller end more expanded. The tibia has a forward bend, a somewhat laterally compressed stoutish shaft, and subequally enlarged extremities. The articular end opposed to the femur is smooth and pretty equal-surfaced; but it shelves downwards, backwards, and outwards. This posterior inclination is most serviceable, and, indeed, enables the femur to be bent on the lower limb at a very acute angle without depriving the muscles of their power of action in walking. Moreover, along with unusual freedom of the femur, it contributes to the limb being thrown back and up in a line with the tail as in the act of swimming. There is a short inner malleolus; and the adjoining astragaloid face has double facets. Extreme length of tibia 8·2, of fibula 6·5 inches.

Hind Foot. When the animal is on all fours the tarsal bones, of the normal number, offer perhaps less striking and fewer, but as singular points worthy of notice as the carpus. The entire sole (and not a segment of it) is laid on the ground plantigrade-fashion in walking. Both astragalus and calcaneum are low. Cuvier's words (*l. c.* p. 226), so applicable to *Otaria jubata*, will bear quotation. He says:—"L'astragale des phoques est très-extraordinaire, en ce qu'au lieu d'une poulie plus ou moins creuse dans son milieu il offre à la jambe une poulie convexe formée de deux faces, qui font ensemble un angle saillant comme un toit, et dont l'une répond au tibia, et l'autre, qui est plus grande, au péroné. Cet os n'a pas seulement une apophyse en avant pour le scaphoïde, mais il en a une autre en arrière terminée par une tubérosité et formant une sorte de talon interne, de manière qu'en voyant l'astragale isolé on croiroit que c'est le calcaneum." I may note more particularly of the present specimen that the horizontally ovoid fibular facet looks backwards and inwards, and there is a certain amount of the same obliquity apparent in its tibial concavo-convex facet. These dispositions concurrently adapt themselves to the peculiarities of tibia and fibula. The plantar surface of the os calcis is roughened and moderately convex; the short calcaneal process seems to have an inward tilt. It is not altogether, as Cuvier observes, that the calcaneum is placed outside the astragalus, but rather that the two bones have a

constricted X-position to one another, or together are semirotated, lying slanting inwards on their short axes. These anomalies have a most important bearing, inasmuch as mechanism for swimming and diving are concerned: and they well explain, religated with musculo-tendinous¹ accessories, how it is that the hind foot acts like a pivot on the heel when walking or running. It is in fact an adjustment of instrument for terraqueous locomotion. The awkward pedal defect colloquially known as "flat-footed" in man is a kind of first stage towards the Otary's condition, though through ligamentous rather than osseous conformation in his case. The Earless Seal's incapacity to use the hind foot on land depends more on the different proportion of femur to leg-bones, and lowered attachment of tegumentary caudal expansion, than to absolute difference in the construction of the bones forming the ankle-joint. In the Sea-lion the cuboid, naviculare, and entocuneiform are each fair-sized, the meso- and ectocuneiform small and very much laterally compressed, particularly the latter, which is indeed a diminutive bone.

With respect to the metatarsals, the hallucial is longest and strongest, the fifth a shade less, the three intermediate much slenderer and a trifle shorter. Not taking into account apical cartilages, the bones of the digits terminate somewhat subequally—the first, however, being shortest, the fifth next, and the third by a grade the longest. It results that the three middle digits have altogether the longest phalangeal bones: but the proximal phalanx of the hallux is in itself decidedly the longer and stouter bone compared with the proximal of the other digits. The second, third, and fourth ungual projections are best marked.

II. THE NERVOUS SYSTEM.

1. *Remarks on the Extraction of the Brain and Membranes.*

THE strong fibrous pericranium having been divided, the bone of the cranial vault was carefully sawn through in a nearly horizontal line, extending on each side from the upper arch of the foramen magnum forwards, close to the postfrontal prominence. At the latter part the saw was again used vertically and transversely, so as to cut the anterior points of the horseshoe-shaped horizontal incision. When the calvarium had thus been loosened in its osseous circumference, it still remained firmly fixed by the bony tentorial lamella. This latter was then broken through by manœuvring in a wriggling manner backwards and upwards, and the brain-pan removed. The great difference between the thick osseous protection afforded to the cerebral mass above, and the thin side walls, became strikingly evident on the calvarium being raised (see figs. 9 and 10). It would appear as if the powerful temporal and masseter muscles, besides being massive fleshy engines of mastication, must also, with their fatty and

¹ For corroborative testimony refer to the various paragraphs in pts. i. & ii. of these researches, on the Walrus and Sea-Lion.

cutaneous coverings, act as buffers to the delicate temporal walls, which, in some places, do not exceed a line in thickness. Thus, while the brain is provided against lateral concussions, the very utmost limit is given it as regards breadth, and this without diminishing the space necessary for the muscular apparatus, or increasing the width of the hinder portion of the head, which altogether is comparatively narrow and elongate.

On the dura mater being longitudinally divided and laterally reflected, a sketch was made of the brain *in situ*. In this way the upper convolutions, sulci, and general relation of parts previously to change of position were secured. After this the brain and a small portion of the upper part of the cord were carefully removed in the usual way, then weighed with the membranes, and preserved in spirit.

The dura mater of the base being left within the cranium, and the calvarium replaced, an accurate model of the interior was obtained by filling the cavity with plastic material. From this a mould was formed, and, lastly, a plaster of Paris cast derived therefrom. As is well known, the recent brain immediately on removal alters in shape; and still more so, as Marshall¹ has accurately noted, does the preserved encephalon change remarkably in the relations of its parts. A photograph could not conveniently be taken at the moment. The figures here given, therefore (figs. 38, 39, & 40), of the lateral, upper, and basal views, are rigorously measured outlines, by my friend and artist Mr. Berjeau and myself, of the intercranial cast, filled in their details from the shrunken brain, corrected by the sketches made of the organ in its fresh condition. If not perfect counterparts, the figures will be found close approximations to the natural aspect of each view in question. The longitudinal and horizontal sections (Pl. LXXIX. figs. 44, 45) are from the preserved hardened brain, very slightly modified by reference to a similarly divided soft intracranial model.

It is but proper for me to express my sense of obligations to recent workers on cerebral anatomy, among whom more particularly may be mentioned Leuret², Gratiolet³, Dareste⁴, Owen⁵, Huxley⁶, Flower⁷, Marshall⁸, Turner⁹, and Rolleston¹⁰.

2. *The Dura and Pia Mater.*

The most external fibrous cerebral envelope, the dura mater, is firm and of moderate thickness. Its upper surface is very irregularly indented, corresponding as it does to the greatly convoluted brain, and more particularly to the unequally hollowed and ridged bony vault. Minute vascular channels exist plentifully over the greater part of

¹ Nat. Hist. Review, 1861, p. 298.

² Anat. Comp. d. Syst. Nerv. Paris, 1839-57.

³ Mém. sur les Plis céréb. de l'Homme &c.

⁴ Ann. Sc. Nat. 4th ser. iii. 1855, p. 73.

⁵ Trans. Zool. Soc. vol. i. 1833, "Cheetah;" and his 'Anat. of Verteb.' vol. iii. &c.

⁶ Brain of *Ateles*, P. Z. S. 1861, p. 259: his Hunterian Lectures, &c.

⁷ Phil. Trans. 1852, p. 185. Trans. & Proc. Zool. Soc., various papers.

⁸ Phil. Trans. 1865, p. 501.

⁹ Proc. Roy. Soc. Edinb. 1865-66, vol. v. p. 578, &c.

¹⁰ Nat. Hist. Review, 1861, p. 201.

the superficies, especially at its hinder portion. The venous sinuses are prominent, and fit into the remarkably deep grooves already mentioned in the description of the interior of the cranium. There is a considerable thickening of the dura mater as it passes out of the foramen magnum backwards towards the spinal canal. Vascularity also distinguishes the pia mater, otherwise of an ordinary character.

3. *The Brain.*

a. *Its outward aspects and dimensions.*—The general characteristic feature of the brain of *Otaria*, looked at on its upper surface, is its comparative squareness—in this respect differing from the more common ovoid form of mammals generally, as well as from the somewhat circular contour which it assumes in *Phoca* and particularly in Cetaceans. This quadrilateral configuration is chiefly produced by the abrupt truncation of the frontal and occipital lobes respectively, their outer corners being considerably angular, or but very moderately rounded. The lateral margins are deeply indented about their middles; and the fronto-parietal portions are less prominent than the temporo-occipital ones; nevertheless they, on the whole, still lend something to the general quadrilinear aspect of the entire encephalon. Notwithstanding what has been said, each cerebral hemisphere superiorly presents a reniform outline, the deeply indented Sylvian fissure being equivalent to the hilus, and the straight-edged longitudinal fissure to the dorsum. The olfactory bulbs are large, and mesially project considerably forwards. The posterior lobes of the cerebrum are tolerably equal in dimensions: the left may be slightly longer than the right; but this was not clearly appreciable by measurement, though appearing so to the eye.

Unlike some of the so-called higher forms of Carnivora, the posterior cerebral lobes all but overlap the cerebellum laterally, as Huxley has recorded is also the case in the allied genus *Trichechus*. The actual amount of backward projection of the outer cerebellar lobes is little more than 0·1 inch. Mesially, however, the superior vermiform and superior posterior lobes of the cerebellum are more exposed, have a triangular form 1·1 inch long and 1·3 inch broad, and reach slightly further back than the external lobes.

The cerebral convolutions are numerous and well developed, giving this upper surface quite a sinuous appearance. There is a certain amount of asymmetry between the halves; but this shall be described hereafter. The brain is highest behind, or at the junction of the occipital with the parietal lobes; and from this it inclines downwards and forwards, as also more steeply outwards.

Measured from the anterior extremity of the olfactory lobe backwards in a straight line to the most projecting part of the cerebellum, the total length is 4·6 inches. The diameter across the parietal lobes is 3·2 inches. The extreme longitudinal axis of each moiety of the cerebrum is 4 inches. The greatest transverse diameter of the brain, which is about the middle of the occipital lobes, is also about 4 inches. Thus the length of

each hemisphere exactly corresponds to the breadth of both, taken at the hinder half of the brain. And although the frontal half is, as shown, somewhat narrower, yet the above measurements bring out what is the impression at first sight conveyed to the eye—namely, that the brain altogether approximates to an equal-sided figure.

The lateral aspects are as remarkable as the superior one, and more clearly demonstrate the infracerebral position of the cerebellum. In this view the entire brain possesses somewhat of an oval shape, the anterior portion of the frontal cerebral lobe narrowing rather angularly, while the rounded, bulbous olfactory surface projects beyond; and together they have considerable vertical depth. Each occipital lobe tapers backwards with a semicircular outline, the inferior border being the straighter of the two. The temporal lobe is broad, tolerably vertical, or only inclined moderately forward; in front of it a wide and deep depression exists, the Sylvian fissure with its marginal convolution. As in the upper view, the hemispherical segment behind the aforesaid depression or constriction is seen, when viewed sideways, to be decidedly convex, the most protuberant point being the upper part of the temporal lobe; but on the contrary the anterior or frontal segment is remarkably flat and perpendicular. A vacuity corresponding to the osseous elevation of the periotic occurs behind the temporal lobe and cerebellum, partially exposing the pons Varolii.

The contour of the base of the brain agrees pretty well with its upper surface. The olfactory lobes are broadish and bulbous in front, narrower at their middles, and widen and flatten behind, as they divide in an arched manner into the short inner and longer external roots. The anterior segment, or orbital region, is flat.

The Sylvian fissures are deep; and behind them the temporal lobes form a well-marked arch, the keystone of which is the roots of the optic nerves. The optic commissure is large and long, the nerves not separating from their single investing sheath till they arrive at the foramen opticum.

The accompanying table represents a series of measurements of the Cerebrum and Cerebellum, *corrected by the intracranial cast*, with the ratios of the same. They correspond to what obtains in the (European) human brain, taking the latter as a standard of comparison in units—namely that given by Marshall, Phil. Trans. p. 554. I reserve comparisons and other remarks on the brain of the Pinnipedia for a future occasion, restricting this part of my researches to anatomical description.

Cerebrum.

(*Otaria jubata* ♂.)

	Dimensions in inches.	Ratio.
<i>a.</i> Greatest breadth (viz. at the temporo-occipital lobes)	4·0	0·58
<i>b.</i> Ditto length, antero-posteriorly	3·8	0·80
<i>c.</i> Ditto height ditto ditto	2·9	0·64
<i>d.</i> Length (or oblique height) of the orbital surface	1·4	0·60

	Dimensions in inches.	Ratio.
<i>e.</i> Greatest vertical depth of the fronto-parietal lobe (<i>i.e.</i> in a line cutting the postero-parietal gyrus)	2·4	0·68
* Ditto diameter at the frontal lobes (the point)	2·4	—
** Ditto diameter at the posterior ascending parietal lobes	3·1	—
<i>f.</i> Length from the front of the middle lobe to hinder end of brain	2·5	0·52
<i>g.</i> Cerebral radius, occipital	2·4	0·73
<i>h.</i> Ditto, frontal	3·0	0·70
<i>i.</i> Ditto, temporo-parietal	2·6	0·66
<i>j.</i> Ditto, vertical	2·6	0·56
<i>k.</i> Projection of the cerebrum <i>beyond</i> the <i>cerebellum</i> does not obtain.		

Cerebellum.

<i>l.</i> The greatest breadth	3·9	1·08
<i>m.</i> Ditto, length	1·5	0·62
<i>n.</i> Ditto, depth	1·8	1·28

Measurements of several parts of the brain taken *from the preserved specimen*, with the ratios as in the preceding Table.

Medulla oblongata.

<i>o.</i> Greatest breadth	0·85	0·12
----------------------------	------	------

Corpus callosum.

<i>p.</i> Length (in a straight line)	1·5	0·48
<i>q.</i> Average thickness	0·17	0·39

Corpus striatum.

<i>r.</i> Length of the visible part	0·65	0·72
<i>s.</i> Width of ditto	0·4	0·80

Optic thalamus.

<i>t.</i> Length of the visible part	1·1	0·84
<i>u.</i> Width of ditto	0·4	0·80

Pons Varolii.

<i>v.</i> From the upper to the lower border	1·05	1·05
<i>w.</i> Thickness	0·8	0·50

b. The Cerebral Lobes.—Of the five lobes of the cerebrum which most modern anatomists recognize in the mammalian brain generally, four are tolerably well defined in *Otaria*—the fifth or central lobe being much less so, if at all distinct. The frontal lobes are short, but of moderate breadth and height; their orbital surfaces

possess considerable vertical depth, and incline obliquely downwards, with an aspect corresponding to that of the orbital plates. The parietal lobes are long from before backwards, and broad from below upwards, or are of considerable height. The Sylvian fissure gives them a sharp and deep line of demarcation behind and at their outer margin; but in front they blend with the frontal lobes. Each temporal lobe, as seen on the base of the brain, has a long-elliptical form; viewed laterally it appears shorter, but of medium thickness. The occipital lobes sweep round the truncated posterior hemispheres. Thus they have great proportional breadth, but, on the other hand, are shallow from above downwards, the cerebellum occupying much of the vertically deep occipital region.

c. *Clefts and sulci of Cerebrum, outer face.*—In general pattern these and the gyri offer agreement with what obtains in the Common Seal (*Phoca vitulina*) as depicted by MM. Leuret and Gratiolet¹. What may be considered distinctive between the Otariadæ and Phocidæ I shall not stop to inquire. In the nomenclature I follow as much as possible that applied to the human cerebrum, with only incidental comment on the counterpart of the smoother-brained Carnivora, *e. g.* Felidæ. My descriptions refer only to the right cerebral half of my specimen, unless where otherwise expressed. With regard to the great longitudinal fissure or intercerebral cleft, it is of moderate depth, the opposite lips approximating rather closely for the anterior half, but divaricating widely behind, thus exposing the vermiform process or middle lobe of the cerebellum. On gently separating the central hemispheres the corpus callosum becomes visible; but the corpora quadrigemina are hidden by the anterior rostrum of the cerebellum (=incisura cerebelli anterior).

Orbito-frontal fissures.—The inferior surface of the frontal lobe or supraorbital region is grooved by three parallel longitudinal sulci, which trend slightly inwards anteriorly. The outermost is shortest; the innermost lodges the external root of the olfactory nerve. On the upper and outer surface of the same lobe the sulci are more irregular. The so-called crucial sulci of Carnivora² are appreciable, though relatively neither long nor deep. From each hemisphere they converge rearwards and together form a V-shaped figure, placed quite at the fore extremities of the great marginal convolutions. The presence of infero-frontal sulci is indicated by a couple of short transverse and oblique indents, situate outside and above the supraorbital angle. Curved midorbital sulci are better marked and in part continuous below and exteriorly with the antero-parietal fissure. The supraorbital are broken, somewhat radiate grooves, located in proximity and at right angles to the fore end of the great marginal gyri.

Spheno-parietal fissures.—The well-defined Sylvian fissure forms a notable landmark equally on the base and outer superficies. It ascends vertically or with only a slightly

¹ Anat. Comp. Syst. Nerv. pl. II.

² Consult Leuret, "*Phoca*," *l. c.* p. 392; Owen, "*Cheetah*," *l. c.*; and Flower, "*Proteles*," P. Z. S. 1869, p. 480.

retrovert obliquity, the upper end nestling in a fork beneath the lobule of the supra-marginal convolution, which latter band-like gyrus forms its anterior lip. There appears, moreover, to be an additional long straight sulcus derived from the upright Sylvian cleft. It strikes backwards and upwards, at an acute angle, starting about an inch above the brain's base. The relations of this to the temporal sulci &c. I shall presently have occasion to refer to, but take this occasion of mentioning that M. Gratiolet¹, in the Green Monkey, and Prof. Turner², in the Chimpanzee, both record an occasional backward offshoot from the primary Sylvian fissure.

The latter anatomist has besides specially called attention, and given the name intra-parietal³, to a sinuous fissure of considerable length, which forms a line of demarcation betwixt the postparietal gyrus and the supramarginal with its lobule. A sulcus corresponding to this, and bearing identical relations to the said convolutions, can readily be traced in the brain of *Otaria*. It here springs just in front of the anterior or supramarginal lip of the Sylvian fissure, quite at the spheno-parietal base. Thence ascending laterally, it accompanies and bounds anteriorly and superiorly the much inflected supramarginal gyrus, its lobule, and the angular gyrus towards the upper temporal projection. Both in advance and to the rear of the lobule it exhibits secondary spurred grooves; one of these with a semilunar sweep cuts into the turn of the ascending portion of the postparietal convolution. Posteriorly the intraparietal fissure ceases at a bridge connecting the angular gyrus with the postparietal lobule; but virtually it seems to go on to the supraoccipital region, in connexion with a sulcus equivalent to an external perpendicular fissure.

At its commencement below, on the lateral aspect of the spheno-parietal lobule, the fissure of Rolando holds rather an indefinite position towards the intra- and antero-parietal sulci; but about halfway up its windings are more easily followed. It first ascends perpendicularly, but in an *f*-shaped direction, to the fronto-parietal eminence. Thence, wheeling backwards, it constitutes a longitudinal midhemispherical fissure. The latter traverses the vertex to the occipital region; and what with an accessory frontal furrow in communication with an antero-parietal fissure, that of Rolando may be said to stretch the entire length of the summit in a second lengthened *f*-shaped manner, with subsidiary curt incisions.

Though the representative of the antero-parietal fissure is better distinguished at its spheno-orbital or subfrontal origin, yet as it mounts to the lateral and upper aspects of the hemisphere its actual course is only recognized by snatches. It appears, however, by linear and stellate depressions, to wind round between the fronto-parietal areas, somewhat beyond the middle and top of the hemisphere.

Temporo-occipital fissures.—On its inferior or basal aspect the temporal lobe is clearly furrowed by three main sulci. On its exterior these continue to run nearly

¹ Mém. Plis cérébraux, p. 29.

² P. R. S. Edinb. vol. v. 1866, p. 583.

³ Turner, *l. c.* p. 581; Brain of Common Seal, *l. c.* vol. ii. p. 392.

parallel and equidistant from each other, being divided by single folds. Their course is only moderately sinuous, and throughout follows the long axis of the lobe—that is, have considerable upward tilt. Besides these a fourth sulcus, not ordinarily visible below, is met with laterally behind, or close to the occipital border. These fissures undoubtedly represent the three temporal ones recognized in man and the primates. The foremost, and possibly the one behind that, may be considered equivalent to the parallel or antero-temporal. The third or second and third may be regarded as mid-temporal; and they both merge into, and become continuous with, what I have described as the long limb of the Sylvian fissure. The fourth sulcus divides the post-temporal from the inferior occipital gyrus; it sweeps well round towards the upper back part of the hemisphere. As regards other occipital sulci I did not take accurate note.

d. *Convolution of the outer face.*—Frontal.—Under these come those situated below, or the orbital series. They are simple folds lengthwise to the long axis of the brain, and three in number, viz. external, middle, and internal. The inferior frontal gyrus almost appears to be a continuation upwards of the external orbital. It chiefly forms the outer front lower angle of the hemisphere, and comprises a somewhat vertical and transverse loop-shaped fold. The midfrontal stage has similarly an upright and bent division. The suprafrontal tier lies alongside the margin of the hemispherical fissure, constituting a zigzag convolution, which appears to go back well nigh to the middle of the brain. Both mid- and suprafrontal gyri are in continuity; and each posteriorly joins the recurrent longitudinal folds of the first ascending parietal convolution. The short hammer-shaped crucial gyrus crops forwards on the inner anterior aspect of the suprafrontal convolution.

Parietal gyri.—Three in number, each possessing an ascending plication, as obvious a longitudinally directed one, and folds which have a lobular character terminating towards the posterior summit of the hemisphere. The antero-parietal begins about the spheno-parietal region, where no clear line of demarcation separates it from the second ascending plication. At the outer fronto-parietal prominence separation becomes clearer, the antero-parietal passing upwards behind the midfrontal, and, as above stated, becomes involved with the latter and the suprafrontal gyri. At the suprafrontal prominence a double fold wends backwards; and this, the antero-parietal convolution in proximity to the great marginal gyrus, continues rearwards to the internal perpendicular fissure, in front of which it forms a kind of lobule indented by one or two secondary short sulci.

The postparietal convolution, as it rises from the base, is a single broad smooth fold which, on the side of the lobe behind the infero-frontal gyrus, has a forward knee-like bend. It then sweeps obliquely towards the Sylvian fissure, goes upward and parallel to this; and where the supramarginal gyrus turns, it again bends anteriorly. Here, gaining the upper surface, it wheels backwards, presenting a broad mass and subsidiary grooves above the supramarginal lobule; thence it continues to the occipital region,

and forms a curved lobule, which joins that of the antero-parietal at the internal perpendicular fissure. It, moreover, is in continuity with the extremity of the angular gyrus.

The third ascending parietal appears as a band sunk within the Sylvian fissure, and constitutes the anterior lip of the latter, or becomes what in man has been termed supramarginal. Its upper loop embraces the top of the upright Sylvian fissure, a descending wedge-shaped turn serving as a division between the latter sulcus and its long posterior branch. The continuation of the supramarginal gyrus and lobule is equivalent to the angular convolution, which bounded above by the intraparietal fissure, below by the 2nd Sylvian parallel fissure and temporal lobes, strikes obliquely upwards to the summit of the occipital region. A lobular expansion is manifest outside that of the postparietal, a narrow bridge connecting these, and another joining it to the posttemporal convolution.

Temporal and occipital gyri.—The anterotemporal is an inversely U-shaped fold. Its short upper limb sinks into the middle of the Sylvian fissure; the longer lower limb curves forwards below the lobe, and partly bounds the Sylvian cleft behind. The middle temporal gyrus is a single sinuous S-shaped fold which above abruptly ends or dips into the post-Sylvian fissure. The posttemporal convolution goes parallel to the latter as far as the post-Sylvian sulcus, meantime exhibiting greater tortuosity. Above the mid-temporal it doubles or is transformed into a lobule which stretches up to the supra-occipital region and is there connected with the occipital gyri. As above mentioned, a narrow bridge unites the posttemporal to the angular gyrus, and breaks the upward continuity of the post-Sylvian fissure.

An infraoccipital gyrus of a simple band-like character is well marked behind the posttemporal. Mid- and supraoccipital convolutions are less easily defined, or are represented by those post upper and inner strips which overhang the cerebellum and outwardly blend with the lobular terminations of the posttemporal and angular gyri.

e. *Sulci and Gyri of the inner face.*—The great marginal convolution extends to about opposite the middle of the corpus callosum, has but moderate depth, and is broken into several lozenge-shaped folds by short secondary sulci. The calloso-marginal fissure is interrupted thrice by upward intrusive folds; nevertheless it can be followed to nearly above the splenium. The convolution of the corpus callosum presents a lower straightish plication and upper diverticula. A posterior downward loop rounds the corpus callosum, forming a callosal lobule in proximity to the upward fold of the uncinata gyrus. A second loop above and in front of that mentioned reaches forwards and lies subjacent to a third and horizontal loop, representative of a quadrilateral lobule. This is bounded behind by a somewhat forward, shelving, internal, perpendicular fissure, which dips into a fold or ridge leading to the relatively large internal occipital lobule. The latter lobule has a rounded exterior border approaching close to the occipital edge, a marginal occipital sulcus intervening, which sulcus has communication in front with the internal perpendicular fissure. Inferiorly the internal

occipital lobule divides the rearmost gyrus, bending round a backward spur of the collateral sulcus to blend with the lower occipital and temporal convolutions. The anterior division of the lobule proceeds by an inflexion to the calcarine gyrus. The collateral sulcus is deep and somewhat X-figured. Its two posterior furrows embrace the lower post-segment of the occipital lobule; its two anterior similarly enclasp the posteriorly directed calcarine loop, but have a more horizontal plane; and the lowermost is the longer. The calcarine sulcus is L-shaped: the lower backward limb courses between the calcarine and uncinata gyri; the upright limb is prolonged between the representatives of the uncinata, the internal occipital, and the callosal lobule. It meets the internal perpendicular fissure above, where a triradiate arrangement of the sulci obtains. What coincides with the calcarine gyrus is a prolongation of the extremity of the lower anterior limb of the occipital lobule. This fold, at first with a slight anterior bend, turns horizontally backwards, and again curves forwards in a parallel line below—that is, forms a loop becoming without division, or is continuous with the uncinata gyrus. This latter convolution widens somewhat in front, and sends up and round the cerebral crus the fold agreeing with the uncinata lobule. A well-defined dentate sulcus runs between the crus and the fore border of the dentate lobule. The upper border of the latter gyrus is in proximity to the duplicature of the callosal lobule, whilst a narrow wedge or horn slants upon the splenial knee of the corpus callosum.

f. *Folds and Furrows, left half of the Cerebrum.*—I intimated there being a certain amount of asymmetry on the two sides of the brain; and fig. 38 partially displays that want of harmony in the furrows and ridges. With regard to the outer face of the left hemisphere, the more prominent and characteristic gyri and fissures as described on the right segment also obtain, the variations depending on minor duplications and incisions. For example, the Sylvian fissure has its perpendicular and oblique posteriorly directed one; but the latter divaricates at the angular and posttemporal lobules and mounts towards the occiput, forming an island or separated fold of that between the external perpendicular fissures. Again, the mid-temporal gyrus seems to have a second division, or, rather, the anterior V-shaped knuckle of the posttemporal constitutes a descending isthmus alongside, and rivals the mid-temporal in size. The mid-frontal gyri are less sulcated; but the superofrontal has fully more indents and superficial sculpturing, rather than clearly defined induplications of gyrus. The lobule of the supramarginal convolution is fuller, the first vertical sulcus above and behind being insulated, the second deepened and, as it were, taking the place of the first. The anteroparietal gyrus has imperfect continuity with the postparietal at its commencement; but the great *longitudinal f*-shaped fissure of Rolando clearly separates them above, as on the right half. The suprafrontal has a well-marked duplicature or loop where it joins the anteroparietal at the great marginal gyrus. The anteroparietal presents behind a trifurcate arrow-headed wedge; and instead of a single continuous loop with outward turn to the internal perpendicular fissure, two longitudinal but obliquely directed folds connect it with the termination of postparietal and angular gyri.

What for convenience of description I have termed lobules of the antero-, post-parietal, angular, and posttemporal gyri on the right face thus notably differ. Moreover it becomes a moot point whether in the area in question parts of these so-called lobules are not of a verity representatives of "plis de passage" of the French, "connecting" or "annectant" gyri of English authors, as found in man and monkeys. In MM. Leuret and Gratiolet's grouping of mammals according to brain-convolutions, they give the Seal a high place, and separate it from the Carnivora by the Edentata, Marsupialia, and Ruminantia. But some of the Ursidæ lead towards the Pinnipedia in their gyral condition; so that the series from the smoother, simpler-brained Felidæ is really less interrupted than their arrangement would warrant¹.

g. Interior structures.—On removing a horizontal section, about half an inch in thickness at deepest, from the upper face of the left hemisphere, the so-called *centrum ovale minus* of Vicq d'Azyr was exposed. The white matter of the brain here presented an elongated and transversely narrowed surface, deeply indented externally by the sulci and convolutions, and somewhat less so internally by the fold bordering the interhemispherical fissure. In the preserved brain in which the section above described was made, the central substance was not pure white, but of a pale yellow hue, while the cortical grey matter had a fawn tinge, shading in some places insensibly into the yellowish centre. The darkness of the white matter, though in part due to the brain having been soaked in spirit, was not entirely so produced; for in the fresh condition I observed that the variation between the central and cortical substance was less marked than in a human subject of the Caucasian variety. The layer of grey matter had a relative depth of $\frac{2}{30}$ of an inch; and, excepting a limited area, there was little appreciable deviation between the different regions.

A second, deeper horizontal slice laid open the lateral ventricle. This cavity, compared with the size of the brain, is large, and has a very marked *f*-shape. Its total length in a straight line is 2.2 inches; but measured curvilinearly, the body of the lateral ventricle is 1.1 inch long, the anterior cornu 0.6, and the posterior cornu 0.9 inch. As regards the relative position of the extremities of the lateral ventricle to those of the hemisphere, the posterior cornu approaches within 0.7 inch of the occipital lobe, the anterior cornu 0.8 inch from the anterior end of the frontal lobe. Thus the ventricle is situated nearly equidistant between the front and back of the cerebrum.

The anterior cornu has an obtusely rounded boundary in front, and is a fossa of moderate depth. The corpus striatum is smooth-surfaced and slightly convex; it measures in the opened ventricle 0.65 inch antero-posteriorly, and 0.4 inch transversely. Proceeding from the foramen of Monro, the choroid plexus, as usual, traverses the lateral ventricle in an oblique direction, externally and behind dipping into the descend-

¹ The most admirable investigation of Prof. Gervais, "Mém. sur les Formes Céréb. propres aux Carniv. Viv. et Foss.," *Nouv. Archiv.* tom. vi. 1870, is well worthy of reference. Coming late to hand, I could not avail myself of its contents as I could have desired.

ing cornu. The *tænia semicircularis* is hidden by the choroid plexus; but when the latter is raised it appears to be well-developed though flat. That portion of the thalamus opticus which is exposed in the lateral ventricle has a very elongated and acutely pointed diamond-shape, its greatest length being 1.1 inch, and the extreme breadth 0.4 inch. Its outer posterior border is the highest part, from which the surface gently shallows inwards and forwards.

In the horizontally opened ventricle, the middle or descending cornu is hidden. But on a vertical and transverse section being made behind the thalamus, through the temporal lobe, or the same parts opened up as is shown in fig. 46, the middle cornu is observed to curve downwards perpendicularly, then forwards and inwards to the tip of the temporal lobe. This remarkably vertical descending cornu has a depth or length of 1.25 inch. The hippocampus major which forms the anterior wall is of considerable size. Its surface, at the vertical upper portion, is flattened behind, and with a narrow and compressed outer margin; but as it extends inwards and forwards it becomes altogether more equally rounded and convex. Superficially it is smooth, and devoid of a pes hippocampi. The corpus fimbriatum and the continuation of the choroid plexus, both of fair size, lie in the deep sulcus in front, and are in great part concealed by the outstanding body of the hippocampus major. The posterior cornu stretches backwards and outwards with a very regular sweeping arch, and goes well back into the occipital lobe, terminating in a shallow tapering extremity. The eminentia collateralis is not distinctly defined; but what appears to represent the outwardly bulging hippocampus minor has a length of 0.7 inch, and at widest is 0.3 to 0.4 broad.

In the section under consideration, I measured the cerebrum, after the manner of Mr. Flower, with a view to compare the dimensions of the anterior and posterior regions. It yielded the following results: the front or anterior median region from the point of junction of the hippocampi is equal to 2.1 inches, whilst the posterior region from the same point is 1.55 inch long. This gives a proportion of 100 to 74.

In the longitudinal, median, vertical section of the brain, the divided corpus callosum is observed to occupy a nearly horizontal position slightly inclining downwards in front, or with a very little tendency to a flattened arch. Relatively to the size of this median face of the hemisphere it appears to be long and tolerably uniform in depth. The rounded anterior genu possesses no special increment, as obtains in the Primates, but is rather indented behind. The splenium or posterior fold, continuous with the fornix, is likewise deficient in breadth, and turns abruptly at right angles downwards. The extreme length of the corpus callosum in the preserved brain is 1.5 inch, its greatest thickness 0.2 inch, and its least thickness 0.1 inch. The anterior commissure is remarkable on account of its diminutive size, having a circumference no greater than a pin's head. The pineal gland, on the other hand, is relatively large; the corpora quadrigemina intermediate as respects their volume.

h. *Basal Parts and Cerebellum*.—A portion of the great marginal convolution appears between the outer and inner olfactory roots. The locus perforatus is narrow; the corpora albicantia full but not unusually prominent. The pituitary body was not removed with the brain; but I noted its dimension as being moderate.

The pons Varolii has a somewhat elliptical outline, and seems not particularly elevated; but the large roots of the 5th nerves may help to mask its real prominence. Otherwise it is thick or deep, and, indeed, within a trifle as large as that in the brain of the Bushwoman so ably described by Mr. Marshall (*l. c.* p. 523). The medulla oblongata likewise is proportionally very wide, having a breadth absolutely as great as in the human brain above exemplified. Its pyramidal bodies are well-marked though low.

Among the distinguishing peculiarities of the cerebellum of *Otaria jubata* are its great breadth and depth to its length, the fact that it is well nigh overlapped by the cerebral hemispheres behind, and the presence of a deepish excavation below and exterior to the flocculus. The entire organ on its three faces, upper, lower, and posterior, presents a semilunar contour. Its lateral hemispheres from behind are abruptly truncate; its base unequal but most pronounced rearwards; its top lightly arched, shelving sharply downwards and forwards. Hidden as it were under the eave of the cerebral mass, it ordinarily does not appear massive; yet its proportional, and, in fact, actual size is very considerable. Compared with that of two races of man tabulated and treated of by the above author, it exhibits deficiency in length, surpasses in greatest depth, and is intermediate between that of the European and Bushwoman in breadth. In proportion, therefore, to magnitude of the entire brain, the Otary's cerebellum is exceptionally preponderant in volume. The superior vermiform process is long, narrow, and well-defined; portions of it and the upper posterior lobes are uncovered by the cerebrum, as heretofore mentioned. The tonsil or amygdaloid lobe bears a narrow, compressed character. The pneumogastric lobe or flocculus is circumscribed, and, although raised much higher than the last, is not remarkably prominent or free. A most singular appearance of this lower basal aspect of the cerebellum is a large oval depression or hollow, which fits upon the periotic eminence on the posterior fossa of the interior of the cranium. This causes the anterior inferior and partly middle cerebellar lobe to be sunk, while from the flocculus backwards and outwards, with sweeping semilunar turn, a steeply raised bank, including a portion of the middle and post-inferior lobes, abruptly guards the rear of the base of the cerebellum. The said horn-like ridge widens outwards, or is pyriform; and from its projecting bulbous contour both exteriorly and posteriorly the massive breadth of cerebellum accrues, in spite of the very perpendicular superficies of the hinder face. These peculiarities in shape are simply adaptations to the osseous case, and to the still more remarkable provision made for the great venous blood-channels situated in the region in question.

i. *Weight of the Brain*.—My memorandum of the weight of the fresh brain and its membranes having been mislaid, I endeavoured to make good in part the omission

when the specimen had been soaked and hardened in spirit, although I did not attempt to follow out the relations of cerebrum to cerebellum, pons, &c. The organ, minus its membranes, in its preserved condition, altogether weighed 9.45 ounces. If, as Mr. Marshall avers, the loss of weight in specimens of brains preserved in spirit averages $\frac{7}{24}$ of their original weight (*l. c.* p. 506), this loss would, moreover, require to be added. We may estimate the deficiency in this instance as somewhere about 2.75 ounces. The latter, therefore, added to the former amount, yields a total brain mass=12.20 ounces.

As recorded by me in a former section of this memoir (Pt. ii., p. 534), the weight of the entire carcass of the animal was 159 lbs. From these data, then, it follows that the ratio of the weight of the brain of the nearly adult male Sea-lion (*O. jubata*) to that of its body is as 1 to 208. Such a calculation is virtually but an approximation to the truth; still less can it be held up as a standard of relation in the species, though in other ways it may serve a useful purpose.

4. *The Nerves. Main Branches of Head and Limbs.*

a. *Cranio-facial.*—As in most of the Carnivora, the olfactory bulbs of *Otaria* are large. Seen from below, they are two elongate-pyriform, partially constricted bodies, in close apposition, and projecting more than $\frac{1}{2}$ inch beyond the frontal lobes. In the lateral aspects each bulbous part of the nerve of smell appears as deep as it is protuberant beyond the cerebral extremity; and in this view their anterior truncation, slightly horizontal upper, and more shelving lower border are evident. The two roots of the first nerve are very unequal in length—the inner, which dips into and arises from the inter-hemispherical fissure, being short, and the outer broad, long and curved.

The large optic nerves, after a course from and round the thalamus, pass to the middle of the cerebral base in an almost transverse direction, being there nearly on a level with the inwardly pointed tip of the temporal lobe, and just in front of the tuber cinereum. Mesially they decussate, and form a remarkable long broad flat commissure (1 inch or more), which does not split into the right and left nerves of the eye until within the confluent optic foramina.

The origin of the 5th or trifacial nerve is very large, and, with the Casserian ganglion, which fills the fossa on the side of the basisphenoid, truly massive. Both superior and inferior maxillary divisions are great cords. The most remarkable branches of the former are its infraorbital. These as they pass forwards from the sphenoidal region, constitute a broad and flattened bundle lying upon the palato-maxillary plinth. On emergence from the infraorbital foramen they proceed in thick funiculi chiefly to the muscular structures and roots of the vibrissae of the muzzle. In the face they are covered by the levator muscles of the nose and lips. The inferior maxillary division has both external and internal trunks. The magnitude of the inferior dental branch

as it enters the mandibular canal is noteworthy, in agreement therefore with the vascular supply to the teeth-sockets and lower lip.

The 6th and two branches of the 7th nerve are slender compared with the 5th, and the facial nerve barely as thick as the 3rd at its origin.

The three nerves which together embrace Willis's 8th, spring distinctly separate from the medulla and cord. The pneumogastric is of very considerable calibre beyond its ganglion. Several pharyngo-laryngeal branches are distributed behind the hyoid, the superior laryngeal being of good size. It pierces the constrictor muscles along with the artery at the cleft or angle between the middle and inferior layers. The main trunk of the pneumogastric, as usual, proceeds to the thoracic cavity in company with the carotid artery and jugular vein. Pulmonary, cardiac, and gastric nerves are all remarkable on account of their magnitude, those to the stomach particularly so,—easily accounted for in an animal whose powers of rapid digestion are almost incredible.

b. *In Fore Limb.*—Of the brachial plexus the external cutaneous nerve sends a subdivided branch to the middle third of the belly of the biceps. Another sent off from the same point goes beneath that muscle, and, curving round the great aponeurotic tendon of the cephalo-humeral, pierces both bellies of the brachialis anticus. A nerve apparently connected with the above goes to the inner side, and supplies the lowermost triceps muscular head, and region above the elbow.

The muscular spiral nerve is of great size; at the middle of the humerus it winds round the shaft as usual, but in a very shallow and ill-defined groove. The nervous filaments are here broadly flattened, and lie between the bellies of the second and third triceps muscles. Nervous twigs supply each of these muscles; one, longer than its neighbours, goes down to the olecranon between their fleshy fibres. As the nerve reaches the outer side of the arm, just above the condyloid ridge, it divides and supplies the supinator longus muscle on its outer surface, the extensor carpi radialis covering the nerves. Another large radial branch goes down to the under surface of the pronator radii teres muscle, thence towards the wrist on the pollicial aspect.

The ulnar nerve passes round behind the internal condyle between it and the coronoid process, over the internal lateral ligament, and under cover of the internal anconeus. Below the joint it sends muscular branches to the flexor carpi ulnaris, and twigs to the upper head of the sublimis. The ulnar nerve continues on to the ulnar side of the wrist-joint, and there divides like the ulnar artery to the 5th and 4th digits.

From the median nerve at the middle of the upper arm a twig is sent off, which partly goes to the flexor sublimis and partly to the adjoining muscles. Another lower branch supplies the pronator teres and flexor carpi radialis, piercing their bellies opposite the elbow-joint. Still lower (above the condyle) the anterior interosseus is derived. Then the main nerve, situate externally to the radial artery, continues down the middle of the forearm, sending twigs to the long flexors and ultimately (at the wrist) subdividing like the palmar artery.

c. Of Loins and Hind Limb.—Lumbar plexus. Hidden entirely by the psoas muscle and not lying upon but issuing from behind the quadratus lumborum, the lumbar nerves partly are superimposed and partly dip beneath the iliacus, but, relatively to the sacral nerves, are small.

The external cutaneous nerve sends filaments to the rectus femoris, vastus internus, and crureus, and passes down transversely over the thigh; superficial to the pectineus and adductors longus and magnus it is distributed to the fascia and skin at the middle and inner side of the shaft of the tibia.

The muscular branches of the femoral nerve in the groin are distributed to the crureus, vastus internus, and both divisions of the adductor longus and magnus. The femoral nerve accompanies the artery through the opening in the adductor magnus muscle. With regard to the obturator nerve, I include it with the sacral plexus, to which in this case it more properly belongs.

Sacral Plexus.—This (with junction to lumbo-sacral) is composed of three large trunks, which emerge from as many of the anterior sacral foramina. The first of these trunks immediately on its exit sends off a branch which joins the posterior deep nerves; the main trunk then goes backwards to opposite the next sacral foramen, where it splits into two nearly equal-sized branches: the shorter one (0·2 inch) unites with the second sacral nerve; the longer one forms the obturator nerve, which proceeds under cover of the pelvic fascia to the anterior border of the obturator internus, and pierces it. The second sacral nerve is rather thicker than the first; it unites with the third at the narrow portion of the pelvis, and there forms a thick single trunk, which passes through the great ischiatic notch. From each sacral nerve a small branch is sent inwards and backwards, which communicates through a *ganglion impar* with a twig from the sympathetic sacral nerves. The nerve is continued backwards from the ganglion, and, with the other minute caudal twigs, supplies the muscles and viscera within the pelvis.

As the sacral plexus passes round and out of the great ischiatic foramen (here considerably narrowed) it bears relation to the parts as follows:—From within outwards it lies upon the gemellus inferior, the hinder part of the quadratus femoris, the long adductors and the semimembranosus. Above or dorsally it is covered by the levator caudæ externus, the first and the second portions of the gluteus maximus, the sacro-peronæus muscle, and the broad biceps. The gluteal artery and vein, as usual, accompany the nervous plexus.

The lesser ischiatic nerve comes off at the outer border of the quadratus femoris, after traversing the great sacro-ischiatic notch with the great ischiatic nerve and vessels. It afterwards lies on the semitendinosus and on the surface of the soleus, being covered by the semimembranosus, the sacro-peronæus, and second portion of the biceps. It proceeds as far as the heel.

The external popliteal or peroneal nerve proceeds in a slanting manner outwards and

slightly backwards under the gluteus maximus secundus and upper portion of biceps to the peroneal margin of the soleus, where, dipping between it and the peroneus longus below the head of the fibula, it divides into several branches. The uppermost one, the anterior tibial, pierces the upper origin of the peroneus brevis muscle, and runs on the neck of the fibula in a shallow groove underneath the peroneus longus and the fibular origin of the extensor communis. It there subdivides, sending a twig to the knee-joint and to the extensor longus, a larger one outwards to the head of the tibialis anticus, and another to the extensor hallucis.

The musculo-cutaneous nerve, or long branch of the above, goes down the leg deeply between the peroneus longus and extensor communis digitorum to the ankle-joint, where, just above the outer malleolus, it emerges, and is ultimately distributed to the dorsum of the foot.

The internal popliteal nerve, the continuation of the largest cord, or the great ischiatic, leaves its neighbours at the middle of the fleshy belly of the quadratus femoris, and, pursuing a course backwards and downwards to the middle of the lower leg, divides into a number of branches on the inner or tibial side of the adductor magnus muscle. Thus, from the peculiar position of both the upper and lower part of the hind leg, it does not traverse the popliteal space, but becomes in a manner the posterior tibial, almost in what appears, on cursory inspection, to be the region of the groin, which here, however, is wrenched upwards, and so clothed with muscles as to be with difficulty recognizable. As the internal popliteal reaches the sacro-peronæus muscle it sends a branch subdividing peripherally on the deep surface of the gastrocnemius. Another branch similarly divides and enters the semimembranosus &c.

The posterior tibial nerve, of considerable size, passes downwards beneath the gastrocnemius and upon the surface of the long flexors to the ankle, where its component parts, diverging, form the internal and external plantar nerves. The latter goes beneath the plantaris tendon as it reaches the sole of the foot, and sends muscular twigs to the abductor ossis metacarpi quinti, the abductor and flexor brevis minimi digiti. One branch, furthermore, goes to the outer side of the fourth digit, in company with the digital branch of the external plantar artery; another branch goes between the fourth and fifth digits, splitting into an ulnar twig to the fifth, and a radial twig to the fourth digit, besides twigs to the short palmar muscles and lumbrici. The former (internal plantar) divides into two at the proximal end of the foot, the plantar artery running between. One nerve, the inner one, proceeds to near the distal end of the proximal phalanx, there splitting into two branches, one for the hallux, the other for the tibial side of the second digit. The second division of the internal plantar nerve is more medianly situated, and at the proximal extremity of the metatarsal bones divides—one branch subdividing into the ulnar and radial twigs of the second and third digits, the other branch similarly subdividing into the radial and ulnar twigs respectively of the third and fourth digits.

III. SENSORY APPARATUS.

1. *Organ of Vision. The Eye and its Appendages.*

In treating of the external characters generally, the peculiarities and appearances of the outward portions of the organ of vision have been described in Part ii. It here remains for me to take into consideration the contents of the orbit. The osseous orbital cavity, as has been shown, is deficient in its posterior bony marginal ring. This deficiency as regards the orbital contents, however, is made good by a bridge of fibrous tissue stretching between the postorbital process of the frontal bone and the fronto-orbital spur of the malar bone, the fleshy fibres of the temporal muscle, moreover, materially strengthening this otherwise weak boundary. Circumferentially the eyeball and its muscles are well cushioned with fat; but a small hemispherical separate mass surrounds the optic nerve and middle of the back of the eye. The latter portion doubtless relieves pressure on the optic nerve and vessels during contraction of the choanoid and other ocular muscles.

a. *Eyeball.*—The globe of the eye is of good size in proportion to the body of the animal. It is not perfectly spherical, but slightly wider across than from before backwards, the average diameter being about $1\frac{1}{2}$ inch. The sclerotic is altogether remarkably dense and strong, and, as in the Earless Seals, of very unequal thickness. As in them, the middle portion or zone immediately behind the iris is thinnest, namely about a line deep, while in front, between this and the cornea, it increases to fully more than 0·1 inch. Behind (Pl. LXXIX. fig. 49), the sclerotic bulges in a crescentic manner, both above and below the optic nerve. The portion above the nerve is slightly the longer and thicker of the two, being 1·08 inch thick at its middle, but only 0·1 at the level of the optic nerve¹. To the naked eye or with an inch lens, the sclerotic tunic in the preserved specimens is seen to be composed of an interlacement of fine white glistening fibro-elastic tissue, resembling that of a thick tendon. At its junction with the cornea the network-like arrangement ceases, the cornea itself appearing as a continuation of the outermost of these, but in a compact linear series. The cornea is nearly circular in outline, 1 inch in diameter, and ranging from $\frac{1}{30}$ to $\frac{1}{20}$ of an inch in thickness, the centre being the thinnest portion. It is only moderately convex.

The choroidal portion of the middle tunic is a thin uniform layer, very vascular, and with an abundance of dark pigment, overlain internally by a large iridescent tapetum. As Leydig has observed in Carnivora, the tapetum is composed of irregularly shaped cells and granular matter.

In the live animal the pupil is subject to great variations of size and shape (as illustrated by the previous diagrams); but in the dissected eye it is found to be pyriform, the narrow end below. The so-called sphincter of the pupil is very distinct

¹ See Dr. Lightbody's remarks on these structures in *Mammalia*, *Journal of Anat. Cambridge*, 1867, i. p. 15.

posteriorly, and about $\frac{1}{20}$ of an inch wide. The fibres are not perfectly circular, but are seen to be derived from the radii of the dilator, and as they approach the pupil to interlace and proceed to the edge obliquely. The ciliary muscle is well developed. The venous meshwork constituting the canal of Schlem has considerable volume. The ciliary processes of the iris are between 90 and 100 in number. The crystalline lens, half an inch in diameter, is nearly spherical or with a very limited antero-posterior flattening. The capsule and suspensory ligament are both strong and well developed. The optic nerve pierces the eyeball 0.2 inch below its centre.

b. *Orbital Muscles*.—Of these a retractor, or what may represent the levator palpebræ and tensor tarsi, is a broadish thin sheet in intimate union with the superior rectus; it separates at the fore part of the eyeball, passes over the superior oblique, and then is lost among the circular fibres of the orbicularis palpebrarum. A few of its fasciculi join with the superior oblique and internal rectus. Four recti are present; and, as usual, the obliqui are two in number. The superior one of these is of moderate size, wanting in tendon and pulley, and fleshy almost to its ocular termination. It runs obliquely, as a broad band enclosed anteriorly between the rectus superior and palpebral retractor; it then turns downwards, outwards, and forwards, to be inserted into the middle of the eyeball. At the latter attachment it is overridden by the internal rectus, while it covers a slip of the choanoid muscle. The inferior oblique is thin and narrow, it is fixed into the globes of the eye, $\frac{1}{4}$ of an inch below the superior oblique. The choanoid or retractor oculi muscle is split into four unequal-sized segments. The internal inferior one of these is the most delicate and separated slip. Its insertion is below the inferior oblique muscle, just behind it and the lobes of the Harderian gland. The upper inner slip is slightly thicker than the former; it passes to the back of the globe, and behind the insertion of the superior oblique muscle. The two outer portions are much broader muscular sheets, and together in close approximation cover the globe for a third of its posterior circumference.

IV. THE VASCULAR SYSTEM.

1. *Cardiac Receptacle*.

When the muscular organ of the heart is fully distended, or, say, filled with plaster of Paris, it appears to be of great proportional bulk to the body; more especially both auricles and the right ventricular cavity seem unusually large and protuberant. In the flaccid condition it is only of moderate dimensions, namely $6\frac{1}{2}$ inches in longitudinal, and 5 inches in transverse diameter. The left ventricle measures 5 inches from its root to the apex. The form of the heart as a whole is flat, broad, and obtusely pointed, the apex, indeed, presenting a tendency to bifurcation. The median longitudinal and auricular furrows are shallow. The strong fibrous pericardial investment is attached to the aorta, 2 inches above its root on the right side, but considerably lower on the left.

The right auricle is thin-walled and capacious, the large triangular appendix protruding well forward. There is no internal valve at the opening of the inferior vena cava; but the aperture, nevertheless, may be influenced or diminished in circumference by what appears to be an oblique or spiral band of supernumerary fibres, situate near the orifice in question. The tuberculum Loweri is an unusually thick and deep free crescentic fold, such as must divert the current of the blood returned by the inferior cava. The fossa annulus ovalis is deep, but perfectly closed. The margins of the wide-mouthed coronary vein are thickened by an addition of fibro-elastic tissue; the approximation of which no doubt partially if not entirely closes the opening during contraction of the auricle. Delicate but numerous muscoli pectinati are confined to the auricular appendix; otherwise the internal walls are smooth. The auriculo-ventricular opening has a diameter of $1\frac{1}{2}$ inch. The right anterior segment of the tricuspid valve is by far the largest of the three. Its thick flat columnæ carneæ spring chiefly from the apical portion of both walls of the cavity; and there is moreover a strong broad intertwined transverse band, reaching from the median to the anterior wall at their middles. The pulmonary veins, above eight in number, unite so as to pour the blood by four channels into the left auricle. This cavity is smaller-sized than the right; and the only peculiarity possessed is a small semilunar valvular fold overarching the closed foramen ovale. The lower thickened border of the obliterated foramen also exhibits traces of a similar fold. From these it may be inferred that during the fœtal condition the sanguineous current would be directed downwards into the auricle or even at times checked in its flow. The mitral and semilunar valves present nothing remarkable.

2. Arterial Distribution.

a. Aorta and branches to Neck and Head.

Immediately above its commencement from the left ventricle, and having given off the coronary arteries, the aorta has a circumference of $4\frac{1}{2}$ inches; its calibre continues about the same to the hollow of the arch. From the summit of the vessel and 5 inches distant from its origin, the innominate artery is given off; to the left of this, rather behind, but in close proximity, the left carotid is derived; one tenth of an inch further to the left springs the wider left subclavian artery. Directly beneath this last, at the concavity of the arch towards its front edge, is the ductus arteriosus. Beyond the derivation of the above vessels, where the aorta bends downward, it narrows considerably; and a few inches below, as the thoracic aorta, it is barely over 2 inches in circumference. Thus the arch presents a considerable relative dilatation to its descending trunk, as occurs in other Pinnipedia.

The arteria innominata is 1 inch in length, and about 2 in girth; it splits, as normally is the case in Man, into the right carotid and right subclavian, the latter being about twice as wide as the former. The common carotid artery of the right side of the neck

proceeds forward with a usual course outside the trachea; its subsequent distribution will be included with that of the left side, which it resembles.

Common carotid and branches.—The left common carotid, as thick as a swan's quill, springs, as mentioned, from the middle and back part of the aortic arch, and crossing over the left bronchus continues alongside of the trachea for a distance of 9 inches, when it gives off the superior thyroid. This is a small branch, less than 2 inches long, which curves inwards below the internal jugular vein, opposite the posterior inferior angle of the cricoid cartilage, and splits into three branchlets. One of these runs down the surface of the œsophagus, and sends four short arched twigs to the diminutive thyroid body. The second passes deeply between the thyroid gland and the trachea, supplying the latter. The third divides immediately beyond its origin, a twig entering the upper end of the thyroid gland, another being sent to the outer side of the sterno-thyroid muscle as it lies on the cricoid cartilage. Besides, minute vascular twigs pierce the muscular wall of the œsophagus, and are also freely distributed to the tissues intervening between the latter and the trachea, and also partly to the crico-thyroid and inferior constrictor muscles. The superior laryngeal artery is derived directly from the trunk of the common carotid, and is not a branch of the superior thyroid, as is more usually the case in Man. It leaves the common carotid about 2 inches apart, or anterior to the superior thyroïdal branch, and from the opposite side of the vessel. At its origin the superior laryngeal artery is placed upon the outer aspect of the thyro-hyoid muscle, and, crossing a portion of the inferior constrictor, gains the interspace between that muscle and the middle constrictor, where it accompanies the superior laryngeal nerve. The hindermost of the parotidean arteries is another small offshoot from the common carotid instead of the external carotid. It springs from the inner or lower side of its parent trunk, an inch distant from the superior laryngeal artery, and, running across the middle constrictor muscle, penetrates the parotid gland posteriorly and on its inner surface. The second and anterior parotidean twig is as long but scarcely so large as the posterior one; it is derived from the angle of division of the common into internal and external carotids, as noted below.

External carotid artery and its subdivisions.—The common carotid $\frac{3}{4}$ of an inch beyond the first parotidean twig above described, just below and posterior to the osseous stylo-hyal and stylo-pharyngeus muscle, divides into two main trunks of equal calibre, the external and internal carotid arteries. At the angle where these divaricate several small arterial branches, muscular and glandular, are given off. The former supply the middle constrictor, stylo-pharyngeus and adjoining muscles; the latter is the second parotidean twig mentioned above.

The lingual artery, of moderate thickness, arises about an inch from the commencement of the external carotid, and, pursuing a course parallel with and crossed by the lingual nerve, supplies the tongue from its body to the tip. At first it lies on the superior

constrictor, then on the hyoglossus muscle, giving branches to both. As it traverses the latter it is covered by the styloglossus muscle, then, dipping underneath both, it enters the substance of the tongue, distributing its branches to the genio-hyoglossus, lingualis, &c., while the main trunk of the artery corresponding to the ranine proceeds onwards to the frænum, and inosculates with its fellow of the opposite side.

The trunk of the external carotid beyond its lingual branch continues towards the cranium, and between the tympanic and condyloid eminence divides into several branches near each other. The facial artery traverses the groove of the mandibular angle under cover of the digastric muscle, and loops round the ramus, being freely distributed to the oral muscles. The occipital branch, diverging beneath the sternomastoid muscle near its paramastoid attachment, supplies the occipital parts, overlain, however, by the great sheet of the cephalo-humeral muscle. As to the temporal branch, which is comparatively small, it reaches the surface of the temporalis muscular layers in front of the outer flexible tube of the auditory apparatus. The internal maxillary artery is by far the most important of the ectocarotid divisions. In the emargination beneath the neck of the condyle at the rear of the pterygoid muscles it sends down a large inferior dental branch. The main vessel, thence continuing obliquely forwards and inwards, penetrates the alisphenoid canal at the root of the pterygoid. Anteriorly it pursues a course on the surface of the palatine arch; and then it becomes the superior maxillary accompanying the infraorbital plexus of nerves, its peripheral divisions being distributed to the parts around the mouth, muzzle, and nose. Within the large speno-palatine and orbital space various muscular, superior dental, and nasal derivatives are sent off. The marginal vessels appear to enter the foramen lacerum medium; but they may nevertheless find entrance to the cranial cavity by the interior minute cleft spoken of as representative of foramen spinosum.

Internal carotid artery.—This strikes deeply backwards, and, rounding the internal groove of the tympanic in close relation to the jugular vein, traverses the canal of the periotic, crosses the foramen lacerum medium, lies in the carotid groove, and joins in the circle of Willis.

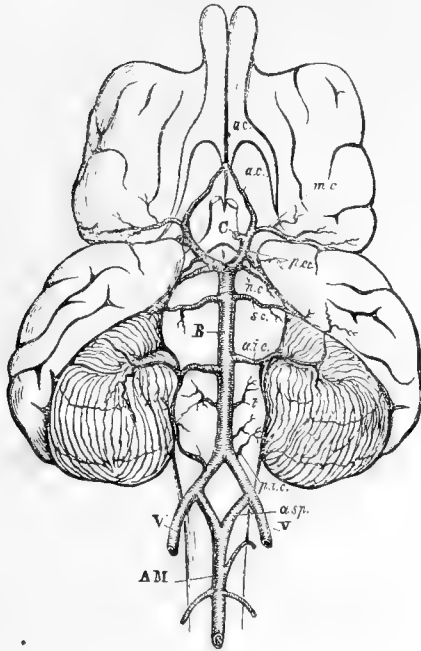
Arteries of the base of the brain.—Within the spinal canal and previous to forming the basilar artery, two large anterior spinal arteries converge backwards into a single vessel of considerable magnitude, which becomes the anterior median artery of the cord.

Much smaller-sized inferior cerebellar arteries are also derived from the front of the vertebral. The basilar artery is about 2 inches long, relatively large, and sends off, almost at right angles, the usual transverse, superior cerebellar and posterior cerebral branches. The two latter are situated rather widely apart. The "circle of Willis" is complete. The posterior communicating branches of the internal carotid are short and wide, with the internal carotid of but moderate size placed in their middle, and not so close to the anterior and middle cerebral as in the human brain.

Subclavian trunks and branches derived therefrom.—The right subclavian artery, on

leaving the innominata and common carotid, arches outwards, and at $1\frac{1}{4}$ inch from these sends off from the upper side its first branch, the vertebral, a vessel of considerable thickness, almost equalling in this respect the common carotid.

Fig. 3.

Diagram of the arteries of the Base of the Brain. *O. jubata*.

C. Internal carotid, severed close to posterior communicating vessel. *B.* Basilar. *V.* Vertebral cut short. *A.M.* Anterior median and *a.sp.* anterior spinal arteries. *a.c.* Anterior cerebral. *m.c.* Middle cerebral. *p.co.* Posterior communicating. *p.c.* Posterior cerebral. *s.c.* superior cerebellar. *a.i.c.* Anterior inferior cerebellar, and *p.i.c.* posterior inferior cerebellar arteries of left side. *t.* Transverse branch.

The vertebral artery proceeds but a short way forwards between the scalenus anticus and longus colli muscles, then enters the foramen of the sixth, and continues within the channel formed by the remaining cervical foramina situated at the roots of their transverse processes. Emerging from the atloid vertebral foramen the artery winds round the root of the superior articular process, and passes through a second foramen in the atlas, which perforates the bone in front of the neural lamina; thence it reaches the interior of the spinal canal, to unite with its fellow of the opposite side.

The left subclavian artery has a calibre as great as the trunk of the innominata. It continues forwards and outwards towards the left, without branching, for 2 inches or rather more; then the internal mammary shoots from its pectoral border. Three quarters of an inch to the left of the internal mammary branch the subclavian trunk divides into three. The largest vascular channel is the continuation of the subclavian into the axillary. The upper smallest branch, but, moreover, relatively a large vessel, is the left vertebral artery, which here, with a rather longer course in the neck than the right vertebral, proceeds onwards to the skull as on the opposite side. The third division is of intermediate size, and springs somewhat from above and behind the subclavian trifurcation. It is equivalent to the thyroid axis, and through large transverse

cervical and suprascapular branches distributes, as on the right side, a copious supply of blood to the great muscles of the neck, and those in front of and around the shoulder.

b. *Arteries of the Pectoral Limb.*

Axillary artery.—The arbitrary divisions of the subclavian trunk and line of demarcation between the axillary and brachial artery, which are useful in a surgical point of view in Man, here lose their significance from the absence of a clavicle and the altered condition of the parts. What may be regarded as the axillary artery is little more than one and a half inch long, though of considerable calibre. Several thoracic branches are distributed to the pectoral muscles and to the glands in the axilla. From a quarter to half an inch beyond where these diverge the main artery bifurcates into two equal-sized divisions—respectively the subscapular and brachial arteries. The former relatively large division gives off the circumflex arteries and many muscular branches.

The subscapular artery pierces the tissues at the root or origin of the subscapularis muscle, and not far from the inner insertion of the episcapularis muscle. After a short course it subdivides into three groups of branches which, respectively, are spread over the surface of the subscapularis muscle, corresponding to the areas of its trifid, fleshy segments. The dorsalis scapulæ, a large branch, proceeds from the subscapular, opposite the neck of the scapula, and goes under the bone between the heads of the dorso-epitrochlear and triceps, giving branches to these muscles near their origin, after which it joins in front the posterior scapular arteries which supply the parts round the joint. The posterior circumflex pierces the posterior margin of the second division of the triceps—namely, between its small tendinous scapular portion and that arising from the outer neck of the humerus. The anterior circumflex is small, and is distributed to the long portion of the episcapularis muscle.

Brachial artery.—Corresponding to the diminished length of the brachial region in *Otaria*, this artery is short; moreover it is relatively small; for the great sanguineous channels supplying the enormous muscular masses of the shoulder are derived higher up than the region in question. The artery is, as usual, accompanied and surrounded by the brachial plexus of nerves and large veins, maintaining a position to the inner side of the median nerve.

The inferior profunda and the anastomatica magna appear to be derived from one offshoot, which comes from the brachial below its middle, and at half an inch distance divides into two. The upper branch, representing the former, pierces the small triceps muscle. The lower and longer branch, equivalent to the latter, also pierces the same division of the triceps; but just above or rather deeper than the internal anconeus, it dips deeply beneath the lower (short) triceps and sends a branchlet to the side of the joint behind the internal condyle, the main artery continuing round and above the olecranon to the external anconeus and neighbouring tissues.

The ulnar artery.—From the main artery below the elbow-joint a short flange proceeds ulnarwise, and at a quarter of an inch distance splits into three. One slants across the ulnar head of the flexor sublimis and goes down the arm as the ulnar artery to the wrist, there splitting into three small digital vessels. These three vessels are distributed to the fifth and fourth digits. The outer one, given off highest, runs along the ulnar side of the fifth digit; the next goes a short way single and then divaricates, one branchlet supplying the radial side of the fifth digit, the other the ulnar side of the fourth digit.

From the short trunk above spoken of the anterior ulnar recurrent diverges upwards toward the joint. The posterior ulnar recurrent is derived immediately below the above, and at an angle from the ulnar. It enters the substance of the flexor carpi ulnaris and the palmaris longus muscle.

Radial artery.—This, the chief continuation of the brachial into the forearm, passes downwards over the biceps and brachialis anticus muscles in front of the inner condyle, and afterwards beneath the pronator radii teres and the flexor carpi radialis. In the forearm it is situated nearly in the middle of the broad radius, superficial to and partly on the ulnar side of the radial head of the conjoined flexor profundus and pollicis. The tendon of the palmaris longus secundus obliquely crosses the artery above the wrist-joint. Dipping beneath the superficial palmar fasciæ, it then, at the proximal end of the metacarpals, splits into three divisions which form the main portion of the palmar arch. The largest pollicial branch crosses the radial side of the second metacarpal and subdivides into two twigs which proceed respectively to the ulnar side of the pollex and radial side of the second digit. The second middle branch similarly subdivides into a couple of twigs, which run along the ulnar side of the second and radial side of the third digit. The third branch comes off the highest of the three, and, subdividing at the proximal end of the proximal phalanx, bifurcates, one twig going to the ulnar side of the third, and the other to the radial side of the fourth digit. This palmar arch is superficial to the nerves.

Below the elbow and in the upper part of the forearm the radial sends off a recurrent branch, chiefly distributed to the muscles on the humerus and radial side of the joint. Other muscular branches are distributed in the forearm.

Interosseous vessels.—Immediately below the derivation of the ulnar the common interosseous artery strikes off and is about half an inch long, it then splits into two branches. One of these, the posterior interosseous artery, dips between the radial and ulnar heads of the deep flexors above the oblique ligament. It is distributed to the pronator teres, extensor ossis metacarpi pollicis, &c. The second branch forms the anterior interosseous artery, from which, an inch below the commencement of the posterior interosseous artery, a muscular offshoot of moderate size diverges radially and goes to the long muscles of the radial side. A small branch, representing the recurrent, goes upwards to the elbow-joint beneath the external lateral ligament.

c. The Visceral Arteries.

Bronchial, œsophageal, and intercostal vessels are duly given off within the thorax. Each and all of these are large; but the latter do not form retia as in Cetacea.

Small phrenic arteries which penetrate the muscular diaphragm come off from the abdominal aorta below and between the crura. About half an inch lower two diminutive branches are also derived, one on either side of the aorta; these go to supply the suprarenal bodies.

The Cœliac axis, the first large trunk, proceeds from the abdominal aorta, half an inch below the last, or about one inch beyond the diaphragm. It has a large calibre, and is one and a half inch long. It ultimately splits into two equal-sized branches, that to the right being the hepatic, and that to the left consisting of a single stem furnishing the gastric, the splenic, and their branches.

The single left branch derivative from the cœliac divaricates at about an inch from its origin. Its right division, that to which the name of gastric or coronary artery is applicable, proceeds along the lesser curvature for two inches or thereabouts, and then divides into a large anterior and as considerable-sized posterior vessel. Each of these pursues nearly the same course, but on opposite sides of the stomach. Their direction is straight, but oblique to the long diameter of the stomach, parallel with and to the cardiac side of the cleft of the lesser curvature. Both the anterior and the posterior coronary or gastric vessels subdivide into twenty or more branches, which are emitted at oblique or right angles on either side; and these again, towards the greater curvature, subdivide into secondary and tertiary dichotomous branchlets. Thus the greater part of the surface of the stomach receives a vascular covering disposed in a series of dichotomous radii, which inosculate at the greater curvature with their fellows of the opposite side, and anastomose with branchlets of the œsophageal and splenic arteries.

The large splenic artery is not tortuous as in Man, but sweeps in a curvilinear manner across the middle of the stomach, from the summit of the lesser to rather beyond the middle or towards the pyloric moiety of the greater curvature. A considerable-sized branch is given off from the top of the stomach; and this, like one of the branches of the gastric, is directed towards the extremity of the viscus and there freely anastomoses with the œsophageal vessels. The vasa brevia belie their name, inasmuch as here they are large long branches, some three or four in number. They proceed beneath the spleen towards the fundus and border of the great curvature, splitting dichotomously like the coronary, and, as before said, inosculating with them. The gastro-epiploica sinistra, or continuation of splenic, as usual, follows the curved outer border of the stomach to the pylorus, and joins the gastro-epiploica dextra.

The hepatic trunk, one and a half inch from its derivation, sends off its hepatic branch. This lies on the surface of enlargement of the vena cava, and beneath the pancreas; as it reaches the Spigelian lobe of the liver it splits into two main divisions, that

to the left being slightly the larger one. The right hepatic division, three quarters of an inch from its origin, subdivides into two. One branch, directed outwards, supplies the first and second lobules to the right of the liver; the other strikes more upwards and slightly to the left, being distributed to the third hepatic segment, viz. the right moiety of the cystic lobe. The left hepatic division is longer and straighter than the right, and furnishes several branchlets. About an inch and a half from its origin one or two small twigs are sent to the Spigelian lobe and what represents the transverse fissure. An inch beyond these a branchlet goes upwards, which gives offshoots to the minute lobule(* fig.72) and to the IV. or left half of the cystic lobe. The main left hepatic division proceeds onwards for above two inches, and splits into several terminal segments distributed to the V. and VI. lobes, or left half of the liver.

The cystic artery is a very long and narrow branch. It accompanies the cystic duct as far as the neck of the gall-bladder, where it penetrates the coats of that reservoir. In its course it lies to the left of the duct, and is superficial to the pancreas and hepatic artery. The arteries of the liver, excepting the cystic branch, have a position beneath the gall-ducts and above the veins and hepatic plexus of nerves. I observed a peculiarity in the first portion of the hepatic artery previous to its dividing into right and left branches. This consisted in its possessing a median septum, apparently produced by a splitting of the inner coat. I could not well satisfy myself, however, whether this might not have been the result of injection rather than a natural condition.

The gastro-duodenal branch of the hepatic is of good size. About one inch from its commencement it gives short offshoots to the pancreas and first part of the small intestine, the latter distant two inches from the pylorus. Thence continuing beneath the duodenum it runs along the outer pyloric border of the stomach as the gastro-epiploica dextra, inosculating in the ordinary manner with the sinistral epiploic extremity of the splenic.

The superior mesenteric artery springs from the abdominal aorta one and a quarter inch below the cœliac axis, has a calibre equal to that vessel, and indeed is relatively little inferior in size to the aorta itself, where they are divergent. In forming the mesenteric arch it is enclosed and hidden within a double, long, narrow, continuous strip of lymphatics, the mesenteric glands. The so-called vasa intestini tenuis are derived from the trunk of the mesenteric by about twenty very short but wide branches, which divide and subdivide into primary, secondary, and tertiary forks, ultimately ramifying on the intestinal surface. Of the named branches of the superior mesenteric artery the ileo-colic is well marked and of moderate size.

The renal arteries, derived posteriorly, strike off opposite one another and at right angles to the aorta. They are each 2 inches long.

The spermatic vessels and the inferior mesenteric trunk spring separately and to the rear of the preceding. Sigmoid and hæmorrhoidal branches of the latter obtain in well-defined arches; and lymphatic glands lie towards the main vessel.

d. *Arteries of the Pelvic Limb.*

The distribution of these in most respects resembles what obtains in *Phoca*, slightly modified to correspond with the altered relations of the fleshy parts, agreeing therefore more closely with *Trichechus*, where also caudo-calcaneal bands knit the heel well towards the spinal termination. The continuation of the abdominal aorta upon the inferior aspect of the tail, arteria sacra media, is noteworthy chiefly on account of a plexus vasculosus coccygeus or so-called coccygeal gland. This structure is represented in the Otary by an elongated somewhat cylindrical, yellowish, glandular-looking body, almost an inch long and 0.2 broad. It is situate between the converging long median tendons of the pubo- and ilio-coccygeal muscles, and is covered in part by the junctional raphé of the levator ani.

External iliac and tributaries.—The epigastric is a large artery, which underlying the external and internal oblique muscles upon the surface of the transversalis and outside the rectus, traverses the abdominal parietes and forms a free inosculation with the equally capacious internal mammary.

The femoral artery, of very moderate calibre, on leaving the ilium, crosses outwards almost at a right angle from it, and in this way traverses the groin to the inner and here posterior edge of the femur. The artery, with its companion vein and nerves, have the following relations before penetrating the adductor magnus muscle. The psoas tendon is superficial to it; the rectus femoris and sartorius lie anteriorly, the pectineus behind. These altogether form an elongated triangular space, the artery crossing this diagonally from before backwards. Deeply the vessel lies on the tendon of the iliacus, and then passes over the the adductor longus. At the lower third of the shaft of the femur it goes through a small opening in the upper border of the adductor magnus and reaches the posterior surface of the bone.

The popliteal artery is very short, and, as usual, lies in the popliteal space; but its relations nevertheless are different, as the hamstring muscles are shifted downwards and do not approach the knee-joint, while the gastrocnemius has but one inner broad head of origin. On the inner side, then, it is enclosed superficially by the adductor magnus, and deeply by the gastrocnemius, these two muscles stretching from the condyloid ridge of the femur to the head of the tibia. On the outer side is the remarkably low insertion of the obturator externus, the upper portion of the biceps femoris, and the soleus. Having reached the inner side of the head of the fibula, the popliteal divides into anterior and posterior tibial arteries.

This last-mentioned vessel rests on the popliteus and tibialis posticus, the long hallucial and digital flexor muscles in part covering it to the turn of the heel. The internal plantar artery appears to be that which furnishes the digital branchlets, or what here represents the plantar arch. It results that the distribution of the plantar is uncommonly like that of the palmar vessels. The innermost artery runs alongside the hallux

to the distal end of the metatarsal, splits, and supplies the adjoining sides of the first and second toe. At the proximal end of the second metatarsal, what in *Otaria* is equivalent to the external plantar in Man, springs from it, then a little way on again divides, a third outer branch coming off still further on. These three bifurcate and give twigs to the second and third, the third and fourth, and the fourth and fifth toes respectively. The outside of the fifth toe receives a separate twig derived from the peroneal near the calcaneum.

Internal Iliac.—Its divisions within the pelvis were not noted with sufficient exactness. One artery, however, has very unusual relations, if, as seems the case, it is the homologue of the sciatic and its derivative *comes nervi ischiadici*. This vessel, of considerable calibre, accompanies the sacral plexus through the sciatic foramen, and afterwards follows the course of and bears relations similar to the lesser sciatic nerve, already described. It yields branches to the large lymphatic gland in the tibio-caudal space, to the semitendinosus, membranosus, sacro-peronæus, and other muscles of the back of the leg, and proceeds on to the outer ankle.

3. *The Venous Blood-channels.*

The veins derived from the interior of the cranium, the head, face, tongue, and fauces, combining, form the external and internal jugulars. Small veins come from the thyroid gland, the omohyoid, and neighbouring parts below the cricoid cartilage; these unite into a common vein, which joins the internal jugular opposite the lower posterior extremity of the thyroid gland.

The recurrent venous channels from the hind limbs and pelvis forming the posterior vena cava are of great calibre, and particularly so after receiving the renal veins. These latter emulgent veins are of unequal length, the left being the longer of the two: compared with the kidney itself, they are of inordinate capacity.

The portal vein, on reaching the flat portion of the liver or bridge connecting the Spigelian and right lobes, divides into two great main trunks. The short one of these supplies the right or I lobe. The other, which is set at a wide angle from the last, proceeds upwards and to the left, sending off wide branches and smaller divisions to the several large lobes, viz. II, III, IV, V. Each branch is accompanied by a derivative twig from the hepatic artery; the veins, however, are by very far the larger.

By far the most remarkable point in connexion with the venous system is the enlargement of the posterior vena cava or great hepatic sinuses so admirably depicted by Barkow¹ in the Common Seal, *Phoca vitulina*, and similar to those of the Walrus. It is in fact but a simple expansion of the vena cava within the precincts of the liver, and

¹ Professor Barkow's magnificent illustrations of the vascular system contain several devoted to *Phoca vitulina*, *P. annellata*, and *Halichoerus griseus*; but a comparison with these is beyond the limits of the present paper. 'Die Blutgefässe, &c.' Breslau: see plates x. to xiii. and xxix.

in this case occupying a volume, one might almost say, greater than the glandular hepatic organ itself. As I have shown in *Trichechus*, there is a mid septum interiorly, with a free opening, however, between; and each sac has diverticular pouches in communication with the various segments of the much divided liver. The capacity of the two chambers is such that, on being injected, I was utterly astonished and confounded as to where the material was being sent to. Subjoined is the memorandum taken when at work; and the drawings, figs. 48 and 72, supplant lengthened description.

“Hepatic sinuses 14 inches across in a straight line; that of the right side alone is 8 inches, interspace 1 inch; hence left, above, 5 inches long. There is a deep and wide fissure behind; and each from this view is semilunar or stomach-shaped, the cardiac and pyloric curvatures being represented by the veins that enter the different lobes of the segmented liver. In front, *i. e.* below, there is scarcely any fissure; but a strong white fibrous band, an inch broad, runs up the middle, being derived from, or a duplication of the abdominal surface of the diaphragm. Circumference of right half when distended 11 inches, the left being half an inch less.”

The *hepatic plexus of nerves* lies beneath the portal trunks; and twigs of these ramify around the vein while being sent to the numerous hepatic lobes. Minute branches of nerves are also derived from the hepatic plexus, which accompany the bile-ducts, and lie superficial to the portal vein, and even to the arterial trunks.

Fig. 4.

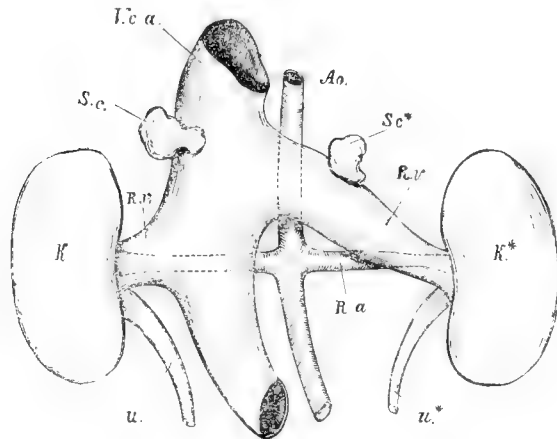


Diagram of the Renal Vessels, &c.

K, K*. Kidneys. u, u*. Ureters, cut short. Ao. Aorta. R.a. Left renal artery; the dotted line shows position of the right, behind cava. R.v, R.v. Renal veins. V.c.a. Vena cava ascendens. Sc, Sc*. Suprarenal capsules or Glands.

V. HYOLARYNGEAL AND PULMONARY SYSTEMS.

1. Components of *Hyoid and Larynx*.

a. *Hyoid arch*.—This arch is built up of nine osseous and four cartilaginous elements. A taper pointed cartilage 0.4 inch long articulates the arch with the tympanohyal of the skull. The stylohyals united with these cartilages are subcompressed, digit-shaped bones, each 1.2 inch long, and with a knobbed extremity distad from the skull. These

stylohyals are connected by fibro-cartilage to separate osseous elements, the epihyals; each of the latter bones is longer than the stylohyal, *i. e.* 1.4 inch, somewhat stouter, dilated at both extremities and laterally compressed in the middle. Another fibro-cartilaginous synovial hinge-joint passes between the epihyal and the much stouter, equally lengthened adjoining bone. This, the ceratohyal, is subtriangular on transverse section, a broad surface or border being ventrally situate, and the angular edge deeply placed. The end of each bone which lies in apposition with the basihyal is enlarged and slightly depressed or grooved internally. The single basihyal, 2.1 inch in length, is developed as a stout bar of solid bone, with wide flattened extremities, possessing a superior and inferior or anterior and posterior broad facets; with these the ceratohyals articulate above, and the thyrohyals below. The middle or body of the basihyal is somewhat narrower than the extremities, and is compressed in an opposite direction to the ends. Each thyrohyal is knobbed at its basihyal end, and tapers to a narrow cartilaginous point at the thyroid extremity. It is subcompressed laterally, slightly bent or arched forwards, roughened or with a median prominence in front, and rather sharper-edged behind. Length 2.2 inches. At their narrowed cartilaginous tip is a free triangular nodule of cartilage 0.4 inch long, the so-called *cartilago triticea*. This is connected by strong fibrous tissue to the thyrohyal and is also attached by the lateral thyrohyoid ligament to the superior or anterior cornua of the thyroid cartilage.

b. *Cartilages of the Larynx*.—Thyroid Cartilage. The two alæ as they approach together in front are deeply incised anteriorly and posteriorly (or above and below), leaving only a narrow but nevertheless thick and strong septum of communication (*pomum Adami*). The anterior notch is an inch deep, the posterior no more than half that. Each lamella is somewhat rhomboid in form, the superficial and deep borders (anterior and posterior in Man) being convex, the anterior somewhat and posterior (upper and lower) decidedly concave. There is no prominent oblique line or ridge; but on the lateral surface and near the middle of the posterior (inferior) concavity is a large-sized roughened tuberosity to which the arytenoid and thyro-arytenoid muscles are attached. The posterior (inferior) cornu is half an inch long, ending in a rigid thickened pointed extremity; the posterior crico-arytenoid muscle being fixed thereon. The anterior (superior) cornu is much smaller, thinner, and elastic. Internally, the surface of the thyroid lamella is perfectly smooth. The connecting bridge between the alæ, much stouter than they, is smooth externally, but has an elevated cartilaginous median papilla within, from which the vocal cords arise. Measured from the septal junction to the deep free margin, each thyroid lamella is $2\frac{1}{2}$ inches; from the summit to the cricoid end 2 inches, the distance between the extremities of the cornua being nearly the same. At the narrowest part, between the anterior and posterior convexity, it is $1\frac{1}{4}$ inch in diameter.

The cricoid cartilage forms a solid ring some 6 inches in external circumference.

Behind it is 2 inches in extreme (antero-posterior) depth; in front, or superficially, which is the narrowest part, it is 0·9 inch; the diameter from the ventral to the vertebral superficies is 2 inches. The elevated smooth ventral aspect is, as noted, moderately deep and with biconcave margins. The œsophageal surface has a raised mesial line, with lateral, wide, shallow excavations between it and the thyroid cartilages, the posterior crico-arytenoid muscles completely filling these depressions. Where the arytenoid cartilages are attached the cricoid on each side is very much thickened and projects in a rounded manner, leaving a median deep cleft or notch, which is filled with fibro-fatty tissue. The tracheal end of this same œsophageal surface has a thin spatulate cartilaginous plate 0·3 inch long, and fully as much broad at its widest part. On each side of this the borders are incised semilunarly, and form a slight angle posterior to (or beneath) the thyro-cricoid articulation.

Each pyramidal or trihedral, but round-margined arytenoid cartilage is of the following dimensions—0·7 inch in extreme height, an inch in basal width, and 0·6 inch in thickness, or from the internal to the external surface. Its crico-articulating facet is large, shallow, and with a synovial membrane. The inner mesially connecting spur is the thinnest and most elastic portion, and possesses a rounded recurved point to which the interarytenoid ligament is fixed. The true and false vocal cords have a firm and strong bond of union. The posterior crico-arytenoid ligament loosely but powerfully connects the cartilages in the interval.

Fixed to the summit of the arytenoid cartilage by a close, movable, but not synovial joint, is a smaller and softer V-shaped cartilaginous body, which, as a whole, includes the cartilages of Santorini and Wrisberg.

c. Laryngeal Membranes and Ligaments.—The thyro-hyoid membrane, or middle thyro-hyoid ligament, forms a strong, wide, and very elastic connecting bridge between the basihyal, thyrohyals, and thyroid cartilage. It contains in its centre, or midway between the basihyal and the fore part of the thyroid shield, a firm, well-developed, cartilaginous nodule. This nodule of cartilage has a short figure-of-8 shape, smooth on the ventral surface, and rougher or somewhat carinate anteriorly on its deep aspect. It is 0·8 inch long, and 0·5 broad at its anterior segment. It is deeply imbedded in the fat and fibrous tissue at the root of the epiglottis; and between the latter and its internal projecting anterior point there passes a strong fibro-elastic band—the *hyo-epiglottic ligament*.

The lateral thyro-hyoid ligaments are two narrow bands of fibro- and yellow elastic tissue, which pass between the tip of the thyrohyals and each cartilago triticea to the short anterior cornua of the thyroid cartilage.

The crico-thyroid membrane, divisible by human anatomists into a mesial and two lateral crico-thyroid ligaments, is, in *Otaria*, a well-developed strong fibro-elastic structure, the median portion containing abundance of yellow elastic tissue, which is thickened and forms a projecting ridge. The lateral portions of the crico-thyroid membrane,

from the great size and thickness of the thyro-arytenoidei muscles, are partially excluded from the formation of the true vocal cords.

The capsular ligaments encircling the synovial articulation between the posterior (inferior) cornua of the thyroid and the postlateral facet of the cricoid cartilage are short, and limit considerably the motion of the joint. The crico-arytenoid ligaments, on the contrary, are wide, loose, and permit great freedom of motion of the arytenoid cartilages, especially in an antero-posterior direction. The more elastic and resilient cartilages of Santorini and Wrisberg do not possess any definite articulation or ligaments, but pass indefinitely the one into the other by cartilaginous union. There is, moreover, a small but strong ligamentous union uniting the inner points of the arytenoid cartilages (interarytenoid ligament), and a less distinct, by reason of the intermixture of muscular and fatty tissue, posterior crico-arytenoid ligament or connecting membrane.

The superior thyro-arytenoid ligaments, or false vocal cords, are so much interwoven with the submucous tissues, fat, and muscular fibres of the thyro-arytenoideus secundus as to prevent their special dissection. The true vocal cords or inferior thyro-arytenoid ligaments, however, are much better expressed. They pass in the usual manner from the elevation behind the junction of the thyroid aë backwards to the inward or anterior projection of the arytenoid cartilages and adjoining portions of the cornicula laryngis.

The upper end of the trachea is firmly lashed all round the interior of the cricoid cartilage by a very strong membrane, which, however, from its elastic nature, allows of a certain amount of up and down movement.

d. *Muscles of the Os hyoïdes and Larynx.*—The most superficial layer, in this case long massive muscles connected with the hyoïdean region—to wit, the omo-hyoid, sterno-hyoid, and sterno-thyroid, forming a great part of the thickness of the neck and being involved with the structures at their origins, have consequently been described in Part II.

Thyro-hyoid.—The direction of the fibres of this muscle are at an obtuse angle inwards from those of the sterno-thyroid; therefore there is a clear line of demarcation between them. The thyro-hyoid is of considerable thickness, 2 inches long by 1 broad, and trapezoidal in shape. It rests upon the fibres of the inferior constrictor muscle, outer ala of the thyroid cartilage and the thyro-hyoid membrane; and it is itself covered by the omo-hyoid muscle. Its origin is the curved line and prominence of the thyroid cartilage, and its insertion the inferior (posterior) border of the osseous thyrohyal and the thyro-hyoid membrane. On the right side a slip of the inferior constrictor was observed to pass across the thyro-hyoid just behind its middle.

In *Otaria jubata* the Crico-thyroid is represented by a large and broad plane of muscle, as a whole, quadrilateral in shape, though rather irregular in outline. It comes from nearly the whole outer moiety of the cricoid cartilage, and covers the crico-thyroid

membrane. The two crico-thyroid muscles converge medianly in front, but leave a triangular interval exposing the crico-thyroid membrane behind.

Posterior crico-arytenoid.—This is of considerable size and thickness. It covers the posterior surface of the cricoid cartilage, with the exception of the spatular appendix. The fibres expanding outwards and forwards from the above origin are inserted into the outer protuberance of the arytenoid cartilage. As in Man, the outermost fibres are nearly vertical, and the upper or anterior ones nearly transverse to the antero-posterior axis of the larynx. The posterior margin of the thyroid cartilage partially hides the outside curved edge of the posterior crico-arytenoideus. This muscle is a retractor of the arytenoid cartilage and dilater of the glottis.

Lateral crico-arytenoid.—A short, triangular-shaped muscle lying outside inferiorly, but in close connexion with the last mentioned. It occupies the space anterior to and below the crico-thyroid joint, and is fastened to the prominent protuberant angle of the arytenoid cartilage. The action of this pair of muscles is to drag downward the arytenoid cartilage, and close the posterior lip of the glottis. No *ceratocricoid* slip of Merkel was observed.

Thyro-arytenoid.—Divisible in this species of Eared Seal into at least two well-defined bundles:—(a) The larger inferior one is a strong broad plane of muscular fibres which arise from the front and middle of the interior junction of the thyroid alæ. Passing towards the arytenoid cartilage the fleshy fibres are inserted in front of (or below) the arytenoid protuberance. A few of the fibres run over the surface of the arytenoid muscle. (b) The superior smaller division in some respects may represent the so-called aryteno-epiglottidean muscle of human anatomy. This portion commences partly by fascia and partly by muscular fibres from the interior of the thyroid cartilage in front of the laryngeal pouch. Splitting so as to lie on either side of the sac and again uniting, the muscle is finally inserted into the arytenoid cartilage and cartilage of Santorini, anterior, however, to the arytenoid muscle. The superficial division of the thyro-arytenoid in great part covers this second segment. Concerning the function of the foregoing, the large inferior planes (a) of both sides drag forwards the arytenoid cartilages, and therefore approximate the true vocal cords. The superior divisions (b), fixed more behind the arytenoid cartilages, compress the laryngeal sacculus; but they possibly also drag forwards the Santorine cartilages and close the aperture of the glottis.

The arytenoidei muscles do not decussate obliquely and pass right across as they do in Man. In the larynx of *Otaria* the arytenoid is thick, short, and alone fills the cavity of each arytenoid cartilage.

Appertaining to the hyoid and thyroid region, I may in this place institute record of a thick fleshy muscle, somewhat of a long parallelogram in figure, and situated immediately beneath the posterior end of the hyoglossus and anterior portion of the superior constrictor when the parts are in natural position. The muscle in question has attachments to, and bridges or connects the cerato- and thyrohyal bony segments,

posteriorly impinging on what appears to represent a stylo-pharyngeus. In some of its aspects it agrees with the interhyoideus or hyokeratic and partly hyo-epiglottic muscle of Cetaceans.

2. *Vocal Passages, Respiratory Organs, and Glands.*

a. *Cavities of Larynx and Trachea.*—Figures 57 and 59 are devoted to an exposition of the interior of the larynx, showing it from above and in section. To these the following description specially applies. The free surface of the epiglottis is smooth, thick, short and heart-shaped, the posterior median depression rising into an elongated fold within the rima. The superior aperture of the larynx, 1 inch long, has a trefoil outline, the hinder longitudinal limb being the longest. The fissure is bounded laterally by two smooth rounded elastic eminences (fatty cushions surmounting the cartilages of Santorini), and continuously behind by the projecting, clothed portion of the arytenoid cartilages. Two elastic, membranous aryteno-epiglottic folds connect the epiglottis with the rearward rounded prominences; and outside these are wide and moderately deep reticular pouches. Behind and surrounding the parts in question are the inner longitudinal wavy plications of the pharynx and œsophagus. The laryngeal cavity itself is of moderate capacity. The ventricles anteriorly are well defined, but leave an open passage behind, which surface is dotted with mucous glands. Between the false and true vocal cords the narrow elliptical slit of the ventricle, which is directed obliquely backwards towards the pomum Adami, leads into a small flask-shaped sacculus or laryngeal pouch having a reversed direction, or towards the epiglottis. Besides a general converging of fatty tissue, the neck of the sacculus is surrounded by fibres of the thyro-arytenoidei, as above described. The smoother surface of the lower larynx is tumid to the cricoid, where it is slightly wider, diminishing gradually to the trachea. Before dissecting the intrinsic muscles and structures of the larynx, I examined and made diagrammatic outlines of the superior aperture in three different stages of tension, purposely comparing the same with the designs given by Czermak of the laryngoscopic appearances in the living human being. Consult fig. 58, where (1) a reduction shows that ordinarily the fissure is relatively narrower forwards than in man; when more opened (2), and even when forcibly distended (3), a similar condition is exhibited. In other respects the aperture, as a whole, presents considerable resemblances, whatsoever may be said of the widely different powers of vocalization, betwixt *Homo* and *Otaria*. As regards voice, this male animal had no soprano notes. Its more usual cry commenced with a liquid but guttural and tremulous tone, increasing in volume and terminating by a loud and deep-bass roar or growl. At other times, when pleased, or fondling with the keeper, Lecote, a shorter subdued grunting whine was emitted. Lastly, a quicker, shorter, and sharper-sounding call was issued, apparently as a note of surprise or intimation of apparent danger. What has been compared to the bleating of a sheep, by voyagers and others, in the young and female Eared Seals, is doubtless the above tremulous cry

given forth by a weaker and more metallic voice than is possessed by the adult male Sea-lion.

In the trachea the uppermost cartilaginous rings are wide and subequal; they do not meet behind, the interspace being occupied by membrane. Moreover a dense layer of fibro-elastic tissue unites the trachea to the gullet, and, passing over both, ensheaths the thyroid gland and the vessels and nerves distributed thereabouts. This strong membranous investment or layer of deep cervical fascia appears to contain much yellow elastic-fibre in its composition, and while surrounding the trachea tends powerfully to bring the cartilaginous rings together, a needful provision to the remarkable flexible neck of the creature.

b. *Lungs*.—The lungs have great capacity, and when inflated are unusually long in shape. In this respect they correspond to the form of the very mobile thoracic walls. As has been previously mentioned, the Sea-lion alters remarkably in the rotundity, length, depth, and flatness of its body, according as the animal walks on all fours, swims, or lolls on the ground. This plasticity of the chest is due chiefly to the loose manner in which the ribs are articulated to the bodies of the vertebræ, and also to the amount of intervertebral, costal, and sternal cartilages present, all more or less acted upon by the large thoracic muscles.

The right lung rises slightly highest in the chest. It is divided into four lobes, or is composed of three considerable-sized lobes and the so-called *lobulus impar*, in this case tolerably free. The upper or anterior lobe is of a trihedral form, and rather flattened at the edges; the lower angle descending and covering the right side of the root of the heart. Its lower margin is slightly concave at the posterior third, allowing the bronchus and the second lobe to fit into the hollow. This upper or anterior lobe has a separate or third bronchial division, which is derived from the usual right bronchus 6 inches below the bifurcation of the trachea. The second or middle lobe of the right lung is long, narrow and spatulate. The third inferior (posterior) lobe is the thickest and slightly larger than the anterior or first lobe; it is triangular in shape. The fourth, or *lobus impar*, is derived from the cardiac side of the root of the last, but receives a separate extension of the right bronchus, so that it forms an individual lobe. Single and pedunculate at the base, it divides distally in a trefoil manner, each spur being three-sided.

The left lung is composed of three main lobes: the first one is deeply cleft at its uppermost corner. The second, middle, smaller one is attached to the lower end of the first; it is short, narrow, flat and broad at the free extremity. The third lobe is the largest of all; it is triangular, the upper margin being slightly concave. The sternal free margins of all the lobes of both lungs have an irregular somewhat crenated border; this is most notable in the middle, spatulate lobes.

c. *Glands in proximity to Air-passages*.—The thyroid bodies, relatively to the size of the animal, are small. They are situated widely apart, without any connecting isthmus,

upon the sides of the trachea close behind (below) the cricoid cartilage and immediately adjoining the œsophagus. Each gland is of a narrow elongated form, about $1\frac{3}{4}$ inch in length, and 0·4 inch wide at its broadest part; it extends from the first to the sixth tracheal ring. Anteriorly what may be considered the head or broader end is roundish, or well defined; but posteriorly the gland mingles with the thick layer of yellow elastic and fibrous tissue (deep cervical fascia), which encompasses the trachea and connects it with the œsophagus as well as with the vessels of the neck. The surface of the thyroid body is smooth, and of a yellowish or orange colour; section demonstrates its substance to be compact, with only a few vascular channels on its œsophageal side. There is no fibroid or muscular band representing a levator thyroideæ.

As regards thymus gland, no remnant of this foetal organism was noticed.

VI. THE DIGESTIVE SYSTEM.

1. *Parts and Organs within the Mouth.*

a. *The Teeth and Palate.*—In this male animal the dentition presented the normal number accorded to the adult of *Otaria*, the formula being

$$I. \frac{3-3}{2-2}, C. \frac{1-1}{1-1}, Pm. \frac{4-4}{4-4}, M. \frac{2-2}{1-1} = 36.$$

The hard palate is as usual covered by firm periosteum, and by a lining of mucous membrane of a pale tint; but these are only of moderate thickness. The openings of the anterior palatine canals are two long slits placed nearly behind the incisor teeth. They have an antero-posterior direction 0·15 inch apart in front, and diverge slightly from before backwards. The front portion of the palate to as far back as the anterior premolars is tolerably smooth. From between the premolars backwards to about opposite the hindermost molars, there is a series of transverse ridges. These elevations are low, and somewhat flat on their summits. The most of them do not traverse entirely the palate from one side to the other, but are irregularly interrupted in the median line. Each half slants inwards and backwards in such a manner that if continuous they would form a series of low arches, the convexity of which is directed backwards. The interspaces or hollows are less than half the breadth of the raised portions of membrane; and the median longitudinal one is somewhat wider than the transverse ones, especially as it meets these. Behind the teeth the surface of the palate is smooth.

b. *Lingual Organ superficially considered.*—The tongue in *Otaria jubata* is a thick fleshy body, which dorsally at the root is greatly arched both transversely and longitudinally, and becomes somewhat flatter towards the narrower anterior bifid extremity. Looked at laterally, when it has been removed from the mouth, it presents an elongated wedge-shape, with roundish margins. A marked lateral row of large papillæ defines the smooth under surface from the opposite upper roughened dorsum. As seen above,

the tip, fully an inch broad, has a central incision 0·2 inch deep; and this divides the extremity into two rounded halves, which are roughened by a multitude of strong, erect, warty papillæ. A median longitudinal shallow furrow, the raphe, runs backwards from the cleft for $1\frac{1}{2}$ inch, behind which the dorsum becomes very convex (as noted above).

The whole of the upper surface of the tongue has a very roughened rasp-like aspect, but not the retroverted acicular spines which obtain in some Felines, *e. g.* the Lion and the Cat. The papillæ differ considerably at the tip, the middle, and the root of the tongue. The margins and upper surface of the bifid tip are covered with short, semierect, conical, and triangularly flattened soft papillæ. They are longest and most numerous at the free edge, where they form a kind of brush. On the dorsum and raphe they are shorter and overlap each other less. These representatives of the human filiform papillæ, at the sides and summit of the dorsum, insensibly alter into uniform, flat, and broadish fungiform papillæ. Laterally they are closely set together in a tessellated manner, but are rather more open towards the middle line. The summits of nearly all of them appear rounded, but they nevertheless contain a small central depression. The wide horseshoe-shaped root is overlaid with larger circumvallate papillæ; these are irregular in contour, many elongate, others roundish; but all are granular and deeply pitted superficially. Behind the tongue there is a long deep cleft, the soft wrinkled faucial tract presently to be described.

c. Faucial folds, Tonsils, and Oral Glands.—When the mouth and fauces are examined in the live animal, the anterior pillars of the fauces, uvular curtain, and retracted root of tongue so close the faucial aperture as to hide the textures between the proper base of the tongue and the epiglottis. Even in the dead animal with opened mouth, when the parts remain *in situ*, there is a difficulty in making an accurate examination of these posterior structures, because of the peculiarly long and narrow postpalatine formation.

When, however, the parts have been carefully removed *en masse* from the skull, their configuration and relation are more easily made out. Figure 52 (in Plate LXXX.) represents the tongue and anterior two thirds of the isthmus faucium thus exposed. The raised floor of the postfaucial tract already spoken of is deeply divided medianly, the cleft or sulcus reaching from the root of the tongue to the *velum palati*, viz. a distance of $2\frac{1}{2}$ inches. On each side of the groove there is a long transversely arched ridge, the apparent continuation of the forks of the tongue's root. These are covered by loose rugose mucous folds, which at intervals are studded with elongated soft filiform papillæ. Anteriorly the papillæ are short and small, but posteriorly, near the *velum palati*, of considerable size and length. In fact, the latter are so distributed as to give the subuvular parts quite a rough shaggy aspect. The intervening longitudinal cleft is smoother than the side ridges; but, nevertheless, filiform papillæ are not wholly absent. The lining membrane of the postbuccal envelope, as it spreads upwards or overarches

the root of the tongue, possesses plications which correspond to the curve; and these partially interdigitate with one another.

The keystone or summit of the said arch, the backward continuation of the fibromucous membrane of the hard palate to the velum, is moderately smooth, but dotted with puncta, the orifices of the very numerous palatine muciparous glands. The extension of this membrane becomes the duplicature of the uvula and posterior pillars of the fauces. The anterior palatine arch and faucial pillars are considerably in advance of the posterior, and equidistant between the uvula and proper root of the tongue.

The so-called anterior pillars of the fauces are moderately prominent bulgings, with a middle indentation running backwards to a recess lodging the tonsils.

Tonsils.—These amygdaloid bodies correspond very well in shape and size with what they have been likened to, almonds—their free edge and narrow end looking upwards and forwards. The resemblance to the fruit in question is further heightened by their surface being wrinkled and pitted, similar to the sculpturing of its outer husk or shell. There is a deep sulcus above, which runs round in front to the anterior lower third; the faucial membrane thus constitutes a semilunar fold. In the hollow between the tonsils and fold there is a trabecular arrangement of the membrane connecting them, forming a series of interstices or deep pits.

The velum pendulum palati, or soft palate, is a thick fold composed of mucous membrane, glandular and connective tissues, with an unusual quantity of strong fleshy muscular fibre. During the contracted state the thick, fleshy velum forms a complete partition between the pharyngeal cavity around the aperture of the glottis and the faucial one in front. The mucous membrane is studded laterally with muciparous apertures, which follow the attached base of the posterior pillars. The pendulous uvulæ are divided by a deep median incision. Each uvula is rounded, its free margin running outwards, backwards, and then downwards, as the posterior pillars of the fauces, to the front of the epiglottis; a fossa, however, exists between the two latter parts.

The parotid and submaxillary glands in their diminutive development offer resemblances to the Seal tribe generally. In this *Otary* the parotid obtains as a small flat subtriangular body situated below the tympanic region, sunk in a recess partially covered by the cranial end of the sternomastoid muscle. The submaxillary gland is rounder in form, but of nearly the same size as the parotid. It lies lower than the preceding, more behind the angle of the mandible, and upon the surface of the digastric muscle. Below the jaw and tongue, and in the concavity between the latter and inner normal surface, there is a long but irregular chain of flattened glandular substance, the sublingual gland. Through its substance the lengthened duct of the submaxillary passes; and both secretions find exit in the mouth, near the frænum linguæ.

d. *Muscles of the Tongue and Palate.*—Mylo-hyoid. Possessing strong coarse fascicular bundles of fibres, this broad and somewhat extensive sheet of muscle is attached to the ramal groove. The muscles of the opposite sides approach and freely inter-

mingle with each other in the middle line of the inframandibular region, rather forming a continuous whole and tolerably thick layer than thinning into a median longitudinal raphe. Anteriorly the fibres curve forwards; and centrally, about the middle, they have a transverse direction, while posteriorly they bend inwards and backwards. The latter are not inserted upon the basihyal of the os hyoides, but rather superficial to it, being fixed by strong tendinous fascia to the fibres of the sterno-hyoid, omo-hyoid, and hyoglossus muscles. Thus, as regards their action, the fibres of the mylo-hyoid are continuous with those derived from the sternum, and therefore must act inversely as a long lever, according as they act from the fixed point at either end. It follows also that they have an increased power of compressing the tongue and fauces during deglutition.

Together the genio-hyoidei form a thick tongue-shaped muscular mass arising anteriorly from the concavity of the mandibular symphysis, posteriorly spreading out and thinning as they are inserted in a continuous arched manner into the whole front of the basihyals and root of thyrohyals. Although divisible into two lateral equal-sized muscles, the fibres of the genio-hyoids are closely bound together, and, like the mylo-hyoidei, present scarcely any raphe. The fibres of each genio-hyoid at its insertion run outside into those of the middle constrictor of the pharynx, and likewise, with only a very indefinite fibrous division, join those of the sterno- and omo-hyoid. The genio-hyoids, from their great strength, must act very powerfully in drawing forwards the hyoidean apparatus, and also greatly assist the closure and grasping movement of the upper pharyngeal constrictor. Their outer insertions compress or bring together the thyrohyals. It may further be remarked that, when examined deeply, each genio-hyoid is seen to be composed of what might be considered two parts. The middle appears as a long strong muscle with straight fibres inserted into the basihyal and sterno-hyoid muscle. Outside this, behind and superficially, a thin layer diverges to be partially inserted into the root of the thyrohyal and to intermingle with the omo-hyoid and middle constrictor.

The massive genio-hyoglossi may be considered an azygos plane of muscular fibres originating at the symphyseal cleft, and, therefrom assuming a fan-shape, are directed upwards and forwards to the tip of the tongue. Medianly they become vertical, and posteriorly gain the horizontal line; inferiorly the horizontal fibres of the genio-hyoglossi are flattened or slightly scooped out to receive the thick genio-hyoid muscles.

The fibres of the anterior three fourths of each muscle do not ascend to the substance of the tongue. The remaining fibres are mainly inserted upon, and partly go to the inferior wall or basis of the pharynx. Those that go backwards are inserted into the upper surface of the basihyal and side of the ceratohyal.

Hyoglossus.—This muscle is large and tolerably thick, broad behind and narrow wedge-shaped in front, also convex below and concave or deeply scooped out above, so as to fit into the prominent ceratohyals. Its origin is from the ceratohyal, thyrohyal, and posterior root of the basihyal; its outer corner of origin from the thyrohyal is

furthest back and partly covered by the middle constrictor. As it reaches the root of the tongue and narrows, it likewise becomes vertically deeper and laterally compressed, and proceeds along the genio-hyoglossus to the tip of the tongue; previously to which the styloglossus ensheaths it.

Arising from the anterior and outer side of the stylohyal the thin layer of muscular fibres of the styloglossus passes forwards and downwards obliquely, and, wrapping round the anterior half of the thicker hyoglossus, goes on with it towards the tip of the tongue. The long flattened irregular-shaped sublingual gland lies on the surface of this muscle. Representatives of the levator palati and circumflex or extensor palati are present. These were not made out precisely before cutting away the tongue and pharynx. The remnants of both appeared large; the latter muscle must be rather strong, if the long deeply-grooved hamular process be indicative of a large tendon to it.

Azygos uvulæ.—This so-called pair of muscles are very long, narrow, but strong fleshy bands. They arise (close together) from the hinder edge and under surface of the palatine plates, and, proceeding backwards deeply within the tissues of the soft palate, diverge, one to each division of the uvula, being expanded inferiorly.

The palato-pharyngeus is a strong broad fleshy layer, with a postpalatine origin. The fibres as they go backwards diverge outwards and go round to the back of the pharynx, mingling partly with the superior constrictor, and partly covering the œsophageal membrane itself. A salpingo-pharyngeus was not differentiated, if it existed. The presence of a stylo-pharyngeus, however, was better attested, viz. a longish band starting anteriorly from the tympanohyal cartilaginous apex. Directed rearwards deeply between the superior and middle constrictors, and becoming broader, it is fastened to the nodular cartilage at the posterior end of the thyrohyal and to the anterior cornu of the thyroid cartilage. The fibres of the palato-glossus are intimately united with the neighbouring muscles. They pass inwards and downwards from the narial opening to the genio-hyoglossus.

2. *Deglutitive Apparatus.*

a. *Pharynx and fleshy appurtenances.*—The pharyngeal cavity comprehended behind the velum is capacious, but under the influence of powerful constrictors; at the same time it is so very distensible that, in the relaxed condition of the parts, many of the folds and rugæ are readily obliterated. Its whole interior mucous coat is remarkably glandular, and particularly so at the sides of the postnarial opening. A foreshortened view of the region under consideration is shown in Pl. LXXX. fig. 57; it may be described as follows:—The posterior pillar of the fauces projects on the side of the wall in front of the epiglottis; the lingual surface has numerous wrinkled folds, some of which may be considered to represent the frænula or glosso-epiglottidean ligaments of Man. From the surface of this part a number of long conical papillæ project; these are distributed rather widely apart. The epiglottis and superior aperture of the glottis

form the floor of the cavity (these have been described along with the organs of voice); but on either side of them are several longitudinal elastic folds of membrane (aryteno-epiglottidean folds) connecting the root of the epiglottis with the wavy plications of the œsophageal portion of the pharynx.

Inferior constrictor.—Under this head I shall describe what represents the above in human anatomy; but here it may conveniently be subdivided into two portions, although the fibres of these in the median line closely intermingle with one another. 1. The crico-pharyngeal portion springs as a narrow strong muscular band from the posterior hinder (inferior) angle of the cricoid cartilage, close to and somewhat overlapping the margin of the crico-thyroid muscle. Its fibres curve slightly forwards and round the œsophagus, mingling, as already hinted, with the second portion. 2. The thyro-pharyngeal portion is much the broader, and consequently stronger, of the two. Its origin is from the surface of the thyroid cartilage between its oblique line and upper posterior œsophageal border; whence the fibres are directed in an arched manner, meeting their fellows from the opposite side, and with scarcely any median fibrous raphe. The anterior median fibres curve in an angular manner forwards, considerably overlapping those of the middle constrictor.

Middle constrictor.—Like the last, this is an expanded, tolerably thick, fleshy layer, the fibres of which are coarse and present clefts such as might suggest separation of portions, as in the preceding; moreover its points of attachment are more numerous than in that muscle. Its most posterior origin is a superficial slip which overlaps the thyro-hyoid muscle. Fibres joining this slip come deeply from the thyro-hyoid ligament immediately adjoining the superior laryngeal nerve; this portion arches towards the middle line. The broader portion in advance of this arises from the thyro-hyal nearly its whole length. This attachment has fibres in conjunction with the thyro-hyoid muscle which it overlaps; in the same way it overrides and commingles with the origin of the hyoglossus, and in turn itself is overlapped by the outwardly expanded posterior fibres of the genio-hyoid, which, indeed, intimately mix with it. On the right side a further narrow slip arose from the thyrohyal. From these several sources the fibres proceed round to meet their fellows of the opposite side. Posteriorly they are arched considerably, so that part of the muscle passes under the inferior constrictor, the hinder border being convex. About the middle they are nearly transverse, and in front present a concavity forwards, the centre being attached to the skull.

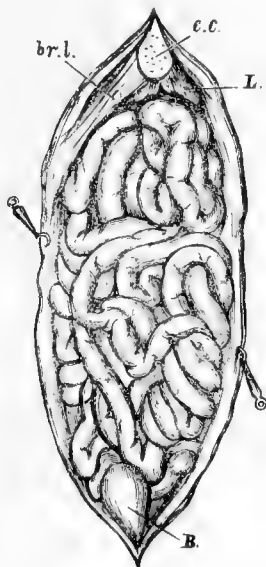
The superior constrictor underlies the fore part of the latter muscle, and is altogether very much weaker.

3. *Alimentary Canal.*

a. *Relative positions of the Abdominal Viscera.*—A longitudinal median incision having been made into the abdomen from the ensiform cartilage to the pubis, the contained viscera were found disposed in the undernoted condition. The Liver, which occupies

both the right and left hypochondriac regions, was not seen to descend or come posteriorly further than the ensiform cartilage. This viscus was equally divided into right and left moieties by the falciform ligament and the remains of the foetal vessels. The stomach was barely visible, being situated deeply in the left hypochondriac region, and almost entirely hidden by the liver. The great omentum, in the present instance perfectly devoid of fat, thin and quite transparent, did not, as is most commonly the case in Carnivora, cover the intestines; but was partially sunk among the folds of the gut. Nearly the whole visible contents of the abdomen seemed to be occupied by the small intestines; only a small portion of the rectum peered out behind them and towards the right iliac region. The empty and contracted urinary bladder extended forwards no great distance beyond the symphysis pubis. The cæcum, firmly attached to the mesentery, lay towards the right side of the spine and between the ensiform cartilage and pubes, being rather towards the former. From the cæcum the great intestine runs backwards to the iliac region, forms a loop and returns forwards again; then, with only a partial transverse fold, reaches the left of the spine, lying at this part behind the unusually loose kidney. Above the superior fundus of the bladder its rectal fold directs itself towards the median line, and passes into the pelvis, at first rather to the right side of the bladder.

Fig. 5.



Reduced sketch of the position of the abdominal viscera, as seen when opened.

e.c. Ensiform cartilage. *L.* Liver. *br.l.* The broad ligament. *B.* Urinary bladder.

[Compare with corresponding view in the Walrus, *Trans. Zool. Soc.* vol. vii. pl. 55. fig. 20.]

b. *The Œsophagus.*—Taking this wide tube as commencing at the lower border of the inferior constrictor muscle, it measures from this to the cardiac orifice of the stomach $22\frac{1}{2}$ inches in length. In the contracted condition its mucous membrane is tough and elastic, and thrown into very numerous interlacing and strongly ridged, pale-coloured, longitudinal plicæ. The submucous areolar tissue is plentiful, and the muscular coat very strong and thick.

The thick, well-developed muscular coat of the œsophagus of *Otaria* afforded me ample opportunity of testing whether its composition was similar or otherwise to what Dr. Rutherford¹ has described in the gullet of the Sheep, Ox, and Dog. According to him, layers of fibres cross obliquely like the letter X, but are not continuous spiral fibres from pharynx to stomach—rather decussating in evenly distributed bundles or loops, which form short parallelograms crossing three times. Thus, while strength and rapidity of transmission in either direction is gained, the tube retains a more or less uniform thickness of wall. I find, therefore, after tracing the fibres with great caution, in the hardened and distended gullet of this Seal, that they perfectly correspond with the structural conditions extant in the Ruminants and Carnivore examined by him. Indeed it becomes evident, on consideration, that the diverse direction and interdigitating of the fleshy fibres of the three massive constrictors of the pharynx are, with some modification, modelled after the same fashion. Those fibres at the opposite extremity of the tube, near the cardiac orifice, are thicker than at the middle of the gullet, and they pass on to the stomach, tending to form the so-called constrictor or oblique bands of the cardiac end of the stomach. The deep layer of fibres has the greater obliquity of the two.

Cuvier's² and Meckel's³ observations (unnoticed by Rutherford), though indefinite as regards the length and continuity of the spiral fibres, show at least there is a common type of structure prevalent among several orders of Mammalia, quite irrespective of ruminating-power.

c. The Stomach and Omenta.—The gastric viscus presents an enormous pear-shaped figure, with the neck or pyloric extremity bent sharply round. The œsophagus enters the stomach quite at the left and upper end; consequently the great *cul-de-sac*, or fundus, is short, but widely rounded. It follows also that the great curvature is long, and with a regular convex contour, whilst the lesser curvature is short and acutely angular. The small *cul-de-sac* of the right extremity, or antrum pylori, furthermore, is long, narrow, and directed forwards or upwards towards the diaphragm. The gastric and splenic vessels and nerves pass on to the surface of the stomach, about midway between the sharp angle of the lesser curvature and the cardiac orifice, and pursue their course on the anterior and posterior surfaces, as has been described under the vascular and nervous systems. They are large, and encompass the organ with a complete ramified network.

The size of the stomach of course varies according as it is distended or otherwise; the subjoined measurements therefore, it is to be noted, apply to the empty and flattened organ.

Extreme transverse diameter, median line drawn from the fundus
to the antrum pylori = $13\frac{1}{2}$ inches.

¹ Linn. Soc. Journ. (Zool.) vol. iii. 1865, pp. 53-61, tab. 3.

² Legons, 2nd ed. tome iv. p. 16.

³ Anat. Comp. vol. viii. p. 688.

Depth or diameter between the highest point of the lesser curvature and lowest margin of the great curvature, in a line cutting the spleen	= 10½ inches.
Length or outer circumference, following the curve from the œsophageal to the pyloric orifice	= 31 „
Length of the lesser curvature from the œsophagus to pylorus, following the inflexed margin of the viscus	= 11 „
Depth of the narrowed part of the V-shaped angle of the lesser curvature	about 2 „

In the interior of the stomach the longitudinal folds of the œsophagus stop short, by a sphincter-like ring of mucous membrane sharply defining the cardiac orifice, which is wide and thick-walled. The mucous coat, throughout the entire cavity of the stomach, has a rough, marbled appearance, from the irregular crossing and inter-blending of slightly raised, narrow rugæ. There is a partial septum, formed by a large semilunar fold of membrane, which projects downwards in a line with the angular bend of the lesser curvature. Beyond this, towards the pylorus, the mucous plaits are more pronounced; and close to the pyloric orifice several longitudinal large folds exist; between these, reaching from one to the other, are fine, transverse, honeycomb or narrow elliptical depressions and sinuous plicæ. Although very indistinct, from the folds being low and flat, there is nevertheless a resemblance in the design of the mucous folds to what obtains in the first gastric cavity of the Cetacea, e. g. *Phocæna communis*. In the Lion (*Felis*) the lower part of the œsophagus has transverse circular folds, like *valvulæ conniventes*, whereas in *Otaria* they are longitudinal and thicker. The fundus is better marked (*i. e.* larger) than in *Otaria*, and the walls throughout much thicker. The orifices of the gastric glands in *Otaria* are distinctly seen as minute pinholes, distributed here and there at intervals on the membrane. The pyloric orifice, guarded by a circular fold or valve, is narrow, only admitting the finger, or less than half an inch in diameter.

The lesser omentum, while still comparatively thin, is rather thicker than the great omentum. It is attached to the lower or posterior surface of the left great venous reservoir, and to the right posterior edge of the left lobe of the liver. At this point it is also adherent to the right side of the left lateral ligament, passing on to the œsophageal end of the stomach. Having reached the upper curvature of the stomach, it stretches around and from it to the liver, there forming the dense layer of Glisson's capsule. The great omentum forms a large, but exceedingly delicate, web of membrane, traversed, as usual, by vessels derived from the right and left gastro-epiploic arteries &c. In the present instance there was not a trace of fat in the membrane when the abdomen was opened. It was observed not to cover the intestines and viscera, but to be inter-mixed among the folds of the gut. This possibly may have been an accidental circumstance.

d. *Intestines*.—The small intestines have a nearly uniform calibre throughout their entire course; the average diameter is three quarters of an inch. From the pyloric extremity of the stomach to the ileo-cæcal valve they have a length of 60 feet $2\frac{1}{2}$ inches.

Excepting the curve of the gut as it passes round the head of the pancreas, which may be arbitrarily termed the duodenum, there is no definite change in the character of the internal mucous membrane sufficient to limit the above as it passes on to the so-called jejunum. In like manner, excepting greater frequency of Peyer's patches, no line of demarcation exists between the jejunum and ileum. No valvulæ conniventes are present. The mucous lining of the whole of the small intestines ordinarily appears to the eye as smooth; but looked at more closely, and especially under water, the membrane is seen to be of a velvety or minutely villous character. The villi are arranged in transverse linear folds of a very delicate kind.

At the distance of 22 feet from the pyloric orifice the first Peyer's patch is found. It is 3 inches long and about 0.7 inch broad. Fourteen feet further on another patch of Peyer's glands is met with, which measures 7 inches in length, with a rather greater breadth than the first patch. The third agminated gland is 5 feet 10 inches apart from the second, and like it is broadish, but $5\frac{1}{2}$ inches long. A very considerable interspace then follows, apparently free from these glands. Eleven inches backwards from the ileo-cæcal valve there terminates an extraordinary long and continuous Peyer's gland. This enormous gland, or lengthened group of Peyer's vesicles, measures 4 feet 8 inches from the one extremity to the other. It varies in breadth from 0.5 to 0.8 inch, and in some places the vesicles or pits are more distinct than in others, but throughout its whole extent is well marked.

The caput cæcum coli is a simple, wide, cylindroid diverticulum, half an inch long.

The great intestine has few flexures; and its walls are remarkably free from sacculations. From the ileo-cæcal valve to the anus it measures $59\frac{1}{2}$ inches, including cæcum. The diameter of the greater part of its course is $1\frac{1}{4}$ inch, widening near the rectum to $1\frac{1}{2}$ inch. Mucous, muscular, and serous coats are each and all of considerable thickness. As may be inferred from the absence of sacculations, the longitudinal muscular fibres are not segregated in bands, but form a more or less uniformly distributed outer coat, thickest at the rectal portion, and terminating with the circular fibres in a large sphincter ani internus. The mucous folds are irregular slight elevations and shallow depressions, which only acquire a pronounced character at the lower part of the gut. The surface throughout has a minutely granulated appearance.

From what has been said it follows that the total length of the alimentary tract (that is, from the mouth to anus) is approximately equivalent to 69 feet: of this the œsophagus counts $22\frac{1}{2}$ inches, the stomach 21 inches, and the intestinal tube 65 feet 2 inches.

4. *Alimentary Glands &c.*

a. *Liver*.—As in the Earless Seals, the hepatic organ is divided in a remarkable manner—there being seven or eight very much separated lobes or lobules, and each of these is more or less subdivided into lobules and fissures of an extremely complicated kind. This furrowed and lobular character of the liver is in some respects identical with the condition obtained in the curious Rodent *Capromys furnieri*¹; only in the Sea-lion the superficial sculpturing and segregation into the smaller angular lobules does not proceed quite so far as in the animal compared. In the aberrant form of Lemuroid *Arctocebus calabarensis*² the main lobes of the liver are very much separated by deep incisions, but the surface of the organ is comparatively smooth.

In *Otaria* the root of the liver rests upon the enormously dilated abdominal venous sinuses, and, indeed, on the right side, partly surrounds that vascular reservoir.

What may be described as the first (I) lobule of the right hepatic lobe is, like the other main divisions, tongue-shaped, and only of moderate thickness. Along with the second lobule it is very much separated from the other right lobular divisions; indeed those two of themselves are quite free and placed widely apart. At its root the first lobule is adherent to the vena cava ascendens, and covers a portion of it deeply. In greatest length, upon its diaphragmatic surface, it measures 9 inches; and transversely its widest diameter is $3\frac{1}{2}$ inches. Superficially it possesses few furrows or marginal incisions, as compared with other of the hepatic segments. Those present are chiefly towards the left side, and have a trilobed character. The second, smaller lobule (II), $4\frac{1}{2}$ inches long, situated in front, springs from the root of the first. It is much the narrower of the two, and has an imperfect sagittate outline, the left barb of which is partially adherent, and crosses the base of the first lobule. Fig. 72 shows the second lobe displaced to the right of the first. The third lobule (III), much the largest division of the so-called right lobe, has a sinuous, faintly fissured margin, and comes into contact at the root behind and on the left with the fourth or quadrate lobule. It is thick, measures 10 inches in length, and averages 4 inches in breadth. Both surfaces are more or less irregularly furrowed, the gastric one furthermore having median, somewhat angular, lobulations. A thick broad ligament (L) passes from the left of these to the gall-bladder, which lies in the fissure betwixt the third and fourth lobules. The fourth division of the right lobe (IV), or lobus quadratus (Q), is differently shaped from the preceding, being composed of several pedunculate, unequally fissured parts, joined, however, at the roots and partially adherent and overlapped by the base of the third lobule behind the venous sinus. The suspensory ligament of the liver intervenes between the fourth and fifth lobules, though abdominally they are in contact. The neck of the gall-bladder is placed rather upon the left side of the third lobule; but its fundus passes obliquely to the dorsal surface of the quadrate lobule. Very large subdi-

¹ See Professor Owen's description of the anatomy of that animal, P. Z. S. 1832, p. 70.

² "On the Angwántibo," Professor Huxley, P. Z. S. 1864, p. 330, fig. 10, A, B.

visions of the portal vein run into the substance of both the third and fourth lobules; and these, along with the cystic ligament and a moderate amount of hepatic tissue, bridge together this otherwise separate or bifid cystic lobe. Its quadrate segment, our fourth lobule, is about 2 inches broad and 6 inches in extreme length.

The fifth lobule, counting from the right (v), or right moiety of the left lobe, is large, thick, and almost completely severed from its fellow moiety on the left. From its root to its narrowed free point is 11 inches long; and it varies from 3 to $3\frac{1}{2}$ inches in breadth. Marginally it is fissured, but not deeply, whilst its upper and lower surfaces are throughout very much grooved and ridged longitudinally. The furthest segment to the left, or sixth lobule (vi), is less tapering than the above, and rather smaller, namely 8 by $4\frac{1}{2}$ inches in diameter, though equally thick. Dorsally it is smoother than the fifth lobule, but ventrally is much sculptured like it; the left compartment of the venous sinus runs well into its substance.

At the root or middle of this much segmented liver, where the blood-vessels and hepatic ducts split into divisional branches, there are several leaf-like, almost separate, minor lobules. These, together, represent or are homologous with the Spigelian lobe (S), and, numerically considered, count as the seventh hepatic lobule (vii). From them there issues an hepatic duct (no. 4). They lie upon the venous reservoir, slightly to the right of its median constriction, merge into a flat hepatic piece still further on the right, and are themselves partially covered by the hepatic vessels, ducts, and Glisson's capsule. A flat, broad bridge of union (viii), connecting the otherwise separate first, second, third, and seventh lobules, runs outwards from the two latter towards the two former. It is tolerably smooth, and firmly adherent throughout to the vena cava. From its position, and being in some respects an appendage to the lobus Spigelius, as likewise its being situate between the here indefinite transverse fissure, cystic lobe, and divisions to the right of that, it appears to be homologous with the so-called lobus caudatus of Man (C).

Guided partly by the determination of both the above-mentioned anatomists on diverse Mammalian forms, and partly by a fresh consideration of the corresponding component parts in the human liver—the same organ in the Eared Seal, though greatly segmented, may be said to possess perfectly homologous constituents. That is to say, there is a right, a left, a quadrate, a Spigelian, and a caudate lobe,—each of the two former being cut into segments, the right lobe of human anatomy possessing what Owen has aptly termed a cystic lobe or division. Taking the broad ligament *suspensorium* hepatis as the line of demarcation, the four divisions to the right of it and above the enlarged venous sinus would together be equivalent to the right lobe of human anatomy. If, however, the parts be read contrariwise, what are here separate portions, have coalesced in those animals wherein the hepatic organ is simpler in conformation.

b. *Hepatic Ducts, Ligaments, and Gall-bladder.*—The very separate condition of the numerous lobes of the liver influences the distribution of the hepatic ducts. A branch

(No. 1) of considerable calibre, and 2·3 inches long, emerges from the innermost protuberant angle of the sixth lobe, and passes towards the right side, in what represents the transverse fissure of human anatomy. A very short, narrow branch (2), 0·3 inch in length comes from the diminutive and almost free lobule lying at the root of the cystic lobe, and joins the above-mentioned duct. These continue together about 0·2 inch, when a third duct pours its contents into the above conjoined one. This third branch (3) issues from the sinistral portion of the cystic lobe, is an inch long, and of equal diameter to that already spoken of as coming from the left lobe. A fourth adjunct carries the secreted bile from the irregularly shaped, nearly free lobule lying upon the immense vena cava. This branch (4) rolls round the hepatic artery, and crosses it from the left towards the right, terminating in the common tube formed by the three ducts already described, and about half an inch from them. At about the same distance further on a fifth branch (5), that sent off by the right moiety or lobule of the cleft cystic lobe, adds its contents to the united main trunk. This channel veers to the right and passes underneath the cystic duct, but without here joining it. 1·8 inch from where it received its last or fifth branch, it unites at a wide angle with a single capacious branch (6) coming from the right. This sixth division is the product of two branches—one, the wider, issuing from the right lobe, and the other the narrower, from the adjoining lobule. After the junction of the large trunk from the right side with that from the left, the single wide hepatic duct (*hd*), still keeping to the right of the cystic duct, runs parallel with it for half an inch, then joins to form the ductus communis choledochus (*dch*).

The gall-bladder is an elongated, slender-necked, pyriform sac. When distended it is 3·8 inches long and 1·8 inch in diameter at widest. It lies in the deep cleft or fissure separating the cystic lobe into a right and a left division. A ligament passing across the gall-bladder, about its middle, connects and binds it with the third and fourth hepatic lobules. The cystic duct itself is 3·2 inches long, and the ductus communis choledochus 2·3 inches. This last, the common bile-duct, externally appears to terminate in the intestine on its upper surface, about two and a half inches distant from the pyloric orifice. There, however, it only pierces the outer fibro-serous wall, but does not penetrate the mucous coat for two inches further on, where it opens in a semi-lunar slit-shaped manner. The reservoir, or expansion, is increased by an additional *cul-de-sac* extending backwards underneath the channel of ingress for almost half an inch.

The broad ligament, or suspensory peritoneal fold, as it proceeds from the diaphragm towards the liver, is attached to the immensely distended vena cava of the left side; it continues towards the incision dividing the third from the fourth lobe. The round ligament, as usual situated at the anterior margin of the broad ligament, enters what may represent the longitudinal fissure, namely that to the left of the cystic lobe, or cleft between the third and fourth lobes, where it joins the vena cava. In the present instance

this remnant of the foetal circulation was obliterated close to the vein, at the point where a cross branch was sent to the third and another to the fourth lobe. The right lateral ligament is attached to a small portion of the upper surface of the right or first lobe, and near to its outer border. Posteriorly it joins the coronary ligament. The left lateral ligament, thicker than the right, comes from the diaphragm, close to the cardiac orifice of the stomach, and goes to the upper edge of the left lobe. The left end of the gastro-hepatic omentum joins at right angles on its right face, whence the left lateral ligament is continued onwards to the lower and inferior surface of the left capacious vena cava. The coronary ligament, traced from right to left, is attached to the posterior surface of the enlarged right vena cava, and passes along, between the vein and the diaphragm, to where the ascending vena cava penetrates the diaphragm. Opposite the right lobe of the liver it is joined at right angles with the right lateral ligament. Around and behind the right surface of the left venous reservoir the coronary ligament joins the left lateral ligament.

c. Spleen, Mesenteric Glands, and Pancreas.—The spleen is a flat, elongated, tongue-shaped organ, which lies behind and across the stomach, rather to the cardiac side of its middle. Its upper end has a rounded head and a beak-like process, which last is directed towards the left extremity of the stomach. The middle of the spleen is slightly the broadest part; the lower end is attenuated. The edges are smooth, and there are only two shallow emarginations—one below and to the right side, the other on the opposite border and about the middle. In the undistended state the spleen is fourteen inches long and varies from one to three inches broad. It is attached to the posterior wall of the stomach by a duplicature of the gastro-splenic omentum, which is from an inch and a half to two inches broad, and runs down for two thirds the length of the spleen in the central line. Within this omental fold some seven branches of the splenic artery and of the vein are conveyed to the gland in question; these divide into branches to the right and left sides as soon as they reach its surface, so that there is little or no hilus lienis. The internal structure of the spleen is of the usual trabecular character, and extraordinarily dilatible. Some enlarged lymphatic glands were observed on its attached or gastric side; but no accessory splenules existed, such as Owen¹ found in the Common Seal.

The mesenteric glands lie upon the anterior and the posterior surface of the main trunks of the superior mesenteric artery and vein. In all there are some six or seven of these glands; but they appear to form a continuous chain on either side of the vessels spoken of. In front they are above six inches long. The upper part, close to the root of the said vessels and below the duodenal flexure of the intestine, is an inch broad; but they lessen in size, and retain a nodulated character as they follow the course of the vessels downwards; and near the iliac flexure of the intestine the lowermost gland forms a sharp turn or bend upwards and backwards. Behind they possess

¹ P. Z. S. 1850, p. 152.

the same form, but without the lower curvature, which is replaced by a separate small kidney-shaped gland.

The surface of the mesenteric glands is traversed by innumerable parallel close-set white lines. These are chiefly lacteal vessels, but they also have nervous filaments intermingled. Some of these lacteals appear to cross the gland entirely and pass up towards the pancreas; but the greater number are derived from the mesenteric glands, and they follow the course of the arteries and veins.

Pancreas.—Whilst injecting the vessels of the abdomen with a composition chiefly of size and colouring-matter, it was observed that the pancreas became very much distended, but did not acquire the red tinge of the material employed. This was caused by an infiltration of the uncoloured fluid into the tissues of this organ, whereas the thicker colour was retained in the vessels. As a consequence the dimensions, relations, &c. of the gland were altered, so that no approximation to the truth can be offered.

VII. THE URINO-GENERATIVE SYSTEM.

1. *The Renal Viscera.*

a. *Suprarenal Capsules.*—These bodies have a position not uncommon among Carnivorous families—that is, in their non-adherence to the upper ends of the kidneys, but lying to their inner side and considerably apart from them. In the species of *Otaria* under consideration the suprarenal glands differ individually in shape and in their precise situation; but they agree in both being flattened, smooth-surfaced, and moderate-sized. The right suprarenal body is somewhat tongue-shaped, its right end, however, being expanded downwards so that the lower or posterior border is slightly concave. Its left end is continuous with and partly lies upon the very much dilated ascending vena cava. The left suprarenal gland is smaller-sized and trihedral in contour. Its inner border rests upon the left emulgent or renal vein, the narrower outer extremity pointing to the left kidney. From this latter it is distant $1\frac{1}{2}$ inch, being somewhat nearer to the abdominal aorta and ascending vena cava than to the kidney itself. When divided, the interior of each suprarenal capsule appears to consist of a uniform, soft, finely glandular substance of a pale yellowish hue. There is no central cavity, nor division into cortical and medullary parts, as is the case in Man and some Mammals.

b. *Kidneys.*—The most marked feature, as regards the position of these secreting glands in the Sea-lion, is their comparative looseness or partial freedom. Thus they are not firmly bound down by a closely adherent investment of fascia to the posterior wall of the iliac region, as occurs in many Mammals; but as in the Seals generally, and to some extent also in certain other families of the Carnivora, they are somewhat free or loosely pedunculate. Both kidneys are nearly uniform in size, 4·7 inches long and averaging 2·3 inches broad. Each is of an elongate, slightly

flattened, oval form, rather blunted, however, at the extremities; the hilus, as the kidney lies *in situ*, appears shallow, and has a somewhat forward or ventral direction. The two kidneys are situated almost on a level with each other, near the middle of the loins. The renal arteries, as has been mentioned, enter the hilus at right angles, while the emulgent veins of enormous calibre leave it more obliquely, and pass rather forwards; the ureters, most deeply situate, diverge at an opposite angle from the veins.

The capsular tunic is a strong, firm, fibrous membrane, pierced and ramified by numerous small vessels, chiefly arterial, but not possessing an external network of large veins as obtains in *Phoca vitulina* &c. Covered by its capsule, each kidney has a roughened aspect, indicating lobulation, but this by no means prominent. When the capsule is removed, the superficial renal lobulations become more manifest, the furrows and ridges, however, still being shallow and imperfectly defined.

As in feline animals generally, the external cortical substance of the kidney, when injected, presents a peculiar and rather beautiful arborescent vascular tracery. This dendritic appearance, shown in fig. 71, is due to the ramification of minute veins upon the surface of each renule; the arterial capillaries are not so distinct and not so numerous, but they nevertheless form an intervening complementary set of ramifications.

If a longitudinal section is made a little to one side of the median line, as fig. 70, Pl. LXXXI. illustrates, the kidney there is seen to be composed of between fifty and sixty lobules or renules of an irregular pentagonal and hexagonal figure, and varying in size from 0·2 to 0·5 or 0·6 of an inch. Each renule, though closely adherent to its neighbour, is clearly defined into its three renal constituents. In the middle and widest space are the fine and straight tubuli uriniferi, which radiate outwards; these are surrounded by a narrow arterial ring of short radiant vessels in which here and there puncta indicate the Malpighian corpuscles. Lastly, bounding the arterial ring circumferentially, is a rather broader venous band, which is common to the several adjoining lobules, and, as mentioned, has an arborescent cortical configuration. Each renule manifests its independent structure in the uriniferous tubules terminating in a papilla, projecting into a central cavity, which in the section in question is only displayed in some of the lobules. The cavities communicate with widish infundibular tubes, which convey the urine to the pelvis of the kidney, the latter being deeper on section than its outward appearance warrants. The renal artery, as it reaches the hilus, divides into several branches, which again subdivide into the lesser ramifications. The veins return the blood, in channels parallel with these, to the very wide emulgent vessel.

Previously to making the above-described section, I forced successfully into the kidney a fine injection of three different colours, viz. red into the artery, blue into the vein, and yellow into the ureter. By this method the structures were well differentiated. A whole kidney thus manipulated is now preserved in the Hunterian Collection; and a half of the other has been mounted by Mr. J. W. Clark, and is now deposited in the Zoological Museum of Cambridge.

c. *The Ureters and Bladder*.—As the former leave the kidneys they present a wide dilatation; but they narrow considerably at a short distance from their origin, and then, retaining the diameter of a goose-quill, enter the base of the urinary bladder a little way behind the neck, an inch apart from each other. Having penetrated the serous and muscular coats of the bladder, they continue within its walls for about three quarters of an inch, and, converging, open by narrow apertures, 0·2 inch separate, at the uvula vesicæ, immediately posterior to the prostatic portion of the urethra.

The urinary bladder is elongated and pyriform, the neck, however, being short. The serous, muscular, and mucous coats are of but moderate thickness. Of its ligaments I noted that the remains of urachus and hypogastric arteries obtain below the tip of the fundus. At the neck, just behind the prostate, a distinct strong median band of glistening tissue represents the anterior ligament. The lateral ligaments, broad and thin, reach from the neck to the fundus; and, furthermore, there is present an anterior vesical fascial layer.

2. *The Organs of Generation.*

a. *Urethra and Penis*.—The prostatic portion of the urethra is fully an inch long and narrow; the mucous membrane, thrown into narrow longitudinal folds, has the median inferior one most elevated. The caput gallinaginis or veru montanum is distinctly marked, though of small size, and is situated anterior to the middle of the prostate gland. On either side are slight depressions, the prostatic sinuses, in which minute puncta indicate the orifices of the said gland. The membranous portion of the urethra is slightly wider and more dilatable than the prostatic portion; but its mucous folds resemble the latter. Its length is fully two inches.

The penis, which is enclosed in a loose subcutaneous sheath, measures in the contracted condition about eight and a half inches from its symphyseal root to the tip of the glans. It lies adherent along the median line of the abdomen, the external opening being eight inches distant from the anus. The suspensory ligaments are two short fibro-tendinous cords attached to the pubic arch, and inserted on each side of the upper surface of the middle of the enlarged bulb. The strong crura, firmly fixed to both sides of the ischial arch, swell out as they go to form the deep enlarged bulb of the corpora cavernosa. The bulb, with its investing muscles, measures $1\frac{1}{4}$ inch in vertical depth, and rather over that in length. Beyond the bulb the conjoined corpora cavernosa, or body of the penis, is round, and about the thickness of one's little finger; this diameter is continued to the proximal end of the bone, a distance of between two and three inches. From this point the united cavernous body diminishes considerably, and is partially lost in the fibro-vascular membrane investing the os penis.

There is no prominent corpus spongiosum, the urethral canal passing beneath the cavernous bodies, being embraced and almost hidden by them. It opens as the meatus urinarius at the front and lower end of the glans, immediately below the bone. The

preputial fold of skin continuous with the sheath is dark-coloured and much wrinkled, both circularly and longitudinally, the latter cuticular furrows being remarkably small. The prepuce is attached $1\frac{1}{2}$ inch behind the urethral orifice. The glans penis at its thinner hinder end has dark-coloured mucous membrane; but the bulbous terminal front is more florid. The truncate extremity of the glans is oval, the long diameter vertical, and the lower end the narrowest part. The somewhat prominent distal end of the bone is covered by a layer of mucous membrane, between which and the outer glans there is a shallow furrow.

The os penis, a strong bone, is altogether 4 inches long, but in the present example of *Otaria* angularly bent; suffice it to say that in other examples of the genus the os penis is more or less straight. The posterior extremity of the bone is thickest, the remainder forwards to the glans penis roundish, and about 0.2 inch in diameter. At the distal end it terminates abruptly in a vertically extended and laterally compressed truncation.

Strange to relate, the animal during life had the misfortune to sustain a fracture of the penis, though the exact nature of the injury was only revealed after death. Either just before or immediately after the *Otaria* came into the possession of the Society it was observed that the point of the penis protruded continuously through the membranous sheath which usually encloses it. With this constant supposed partial erection the glans and foreskin were inflamed and in a raw state. The tumidity &c. of the parts suggested the probability of phymosis; and it was proposed to alleviate the malady by topical treatment, or operation if need were. Neither, however, was very feasible; and as the swelling gradually subsided, no further active measures were taken. Time brought about a cessation of all bad symptoms; but the glans penis was never afterwards withdrawn within the sheath. At last it became leather-like and callous from the continual rubbings it was subjected to as the animal walked and scrambled about in its rough gravelly enclosure. On dissection of the body it was discovered that the os penis was broken exactly in its middle. The bones had firmly united in the form of an arch or obtuse angle; that portion of the external limb of the arch within the glans could necessarily never be withdrawn within the sheath. In the delineation of the organs of generation (Pl. LXXXII. fig. 73) this most remarkable piece of nature's surgery is shown, the asterisk pointing to the apex of the angle or seat of fracture. In the figure in question the relative positions of the bladder, urethra, and penis are, of course, altered from that which they had in the living animal; notwithstanding, the amount of bending in the bone is thoroughly appreciable.

b. *Muscles of the Genitals and Anus.*—The retractors of the penis are two long, narrow, riband-like muscles, which have origin among the fleshy fasciculi of the internal sphincter and levator ani muscles anterior to the rectum. The retractors pursue a parallel course along and under the surface of the penis, and are inserted into the tissues connected with the prepuce.

The membranous portion of the urethra has a thin layer of transversely striped mus-

cular fibres covering the whole length of its exterior. This is the true compressor urethræ; and, as far as my dissection enables me to judge, the muscular sheet in question comprehends what, in human anatomy, have been respectively termed the *circular fibres* of Santorini, or *stratum internum circulare* of J. Müller, the *constrictor urethræ*, and the *levator prostatae*. The compressor urethræ, then, in *Otaria jubata* embraces the membranous portion of the urethra in such a way that it appears to surround the parts spirally. The fibres posteriorly are partially continuous with those of what has been named by some anatomists the "*sphincter vesicæ*." They are very sparse over the prostate, however, and, on reaching the membranous portion of the urethra, apparently divide into two thick symmetrical halves, which have a direction downwards and forwards towards the anus and pubes. These fleshy moieties may be taken as the equivalent of Guthrie's muscle in the human being, which would seem to be but the continuation forwards of the outer oblique fibres of the bladder, Pettigrew's figure-of-8 loops. In front and below, a laterally compressed band of fibres goes towards, and joins, through the rectovesical fascia, the levator ani muscle. This portion seems to represent the "levator prostatae" of Santorini, Albinus, and Soemmering, and to be the fibres known as Wilson's muscle. Some few fibres, again, extend upwards to the symphysis pubis; these are analogous to the constrictor urethræ of some human anatomists, and may be what has been described as the ascending portion and origin of Wilson's muscle.

The bulbo-cavernosus muscle is made up of strong fibres, which curve round the bulb as in other Carnivora &c. The erectors of the penis have origin from the ischial tuberosities; and each, as a thick carneous mass curvilinear in figure, is inserted into the side and postero-inferior surface of the enlarged crus penis.

The sphincter ani internus is strong and broad. It powerfully constricts the lower part of the rectum and anus for an inch or more. The circular fibres join those of the transversus perinæi, levator ani, and retractores penis. There is also an external sphincter of the anus, which is of considerable size.

Reference and figures of the unusually large and peculiarly inserted levator ani and transversus perinæi muscles are given in Part II.; so that nothing further need be said of them in this place.

c. ♂ *Genital Glands, Scrotum, &c.*—Prostate gland.—Surrounding the urethra for an inch in antero-posterior extent, and of a cylindroid or spindle-shape, is the very moderately raised glandular body of the prostate. Its structure is compact and finely textural, merging almost indefinitely in the fibres of the sphincter vesicæ behind, and equally continuous with the urethral walls in front. The efferent canal and ejaculatory ducts appear to open at the minute orifice of the sinus pocularis an inch in advance of the apertures of the ureters.

There are no vesiculæ seminales; and bodies representing Cowper's glands are absent, or so small as to escape observation.

Testes and surrounding parts.—Enveloped in a strong, but loose, tunica vaginalis, the

testicles occupy the very remarkable ischio-rectal fossæ, and thus, as respects position, differ widely from those of the Earless Seals, whose testes lie in the pubic region, or the groin outside the abdomen. There is, moreover, in this Eared Seal (*Otaria jubata*), as has been mentioned and figured along with the cutaneous parts, an external scrotum; but it is not usually prominent; nor does it generally hang downwards, as in other mammals. Indeed the superficial scrotal tissues are chiefly distinguished from the neighbouring skin by the wrinkling and folds rather than by the dependent nature of the sac.

On slight pressure being applied above this somewhat rudimentary scrotum, the testicles come down or emerge from the ischio-rectal cavity in which ordinarily they are lodged, and, as they pass into the scrotal sac, dilate it considerably. They do not, however, show a tendency to remain down, but are easily replaced or returned to the ischio-rectal hollow already alluded to.

This ischio-rectal fossa, wherein each testicle ordinarily lies, is a narrow elongated cavity, between two and three inches deep, the opening of which is to the outer side of the very limited perinæum. On removal of the integument and a further dissection being made (such as is exhibited in fig. 33, pl. lxxiii., of former memoir), the boundaries and general relations of this cavity are unfolded. These are as follows:—Anteriorly or superficially is a somewhat semilunar-shaped fold of strong fibrous tissue, or proper perineal fascia, which is partly continuous with the dartos or scrotal muscular fibres and those of the transversus perinæi. Externally, above and in connexion with this perineal fascia is the oblique sweeping arch or fleshy plane of the gracilis muscle; beneath or deeply, the great broad semimembranosus; posteriorly and also deeply, or at the bottom of the fossa, the semitendinosus and partly glands and vessels; inwardly or in the median line, the transversus perinæi, root of the penis, circular fibres of sphincter ani, and the rectum itself.

The testis itself and investing vaginal tunic is, moreover, supported by fibres which run towards the perinæum; and other still more delicate fibres proceed outwards and pass on to the superficies of the muscles of the lower tibial region. Some of the transverse layer of fleshy fibres representing transversus perinæi, along with fibrous tissue and fat, constitute a partial protection or anterior wall to this most unusual testicular chamber.

The body of the testicle, including the epididymis, is smooth-surfaced, and of an oval or almond shape, 1·8 inch long and 0·9 inch broad. A strong duplicature of the tunica vaginalis firmly binds down the testicle to the bottom of the pouch; the reflection of this, the tunica albuginea, is of considerable thickness. On a vertical median section of the testis being made, the tunica albuginea is seen to dip between the lobes of the glandular substance. At its back part, where covered by the globus major, it is almost a line in depth; and, in the uninjected condition, at this part it possesses a punctate or trabecular arrangement from the intermingled vascular network, the *rete* or

tunica vasculosa. The glandular lobes of the tubuli seminiferi are small and very numerous, the corpus Highmorianum being centrally well pronounced. The epididymis is nearly of uniform breadth, the globus major having no very marked obtuse head. Structurally to the eye it has a glandular-looking aspect, with irregular transverse, white, glistening septa.

DESCRIPTION OF THE PLATES.

PLATE LXXV.

- Fig. 1. Upper view of the skull of the Society's male specimen of *Otaria jubata*.
 Fig. 2. Basis of the same skull, viewed from below.
 Fig. 3. Front and foreshortened aspect of same, with mandible.
 Fig. 4. Occipital view of the skull, minus the inferior maxilla. Objects here given all about $\frac{2}{3}$ nat. size, and from photographs.

PLATE LXXVI.

- Fig. 5. Profile view of the same male Otary's cranium, with mandible.
 Fig. 6. Portion of its inferior basis cranii, slightly tilted inwards to show certain relations of alisphenoid canal &c.
 Fig. 7. Upper view of the inferior maxillæ.
 Fig. 8. The angle and articular condyle of the left mandible, seen from below.
 Fig. 9. The internal basis of the same skull, opened by a horizontal section made from the squamo-frontal process to the upper ends of the occipital condyles, and vertically cut by an incision 0.3 inch behind the former point.
 Fig. 10. The interior surface of the removed calvarium. Figures each reduced, about two thirds natural size.

In this and the preceding Plate the same lettering is used throughout.

Bones.

<i>Pmx.</i> Premaxilla.	<i>So.</i> Supraoccipital.
<i>Mx.</i> Superior maxilla.	<i>Eo.</i> Exoccipital.
<i>Na.</i> Nasal.	<i>Bo.</i> Basioccipital.
<i>Fr, Fr*.</i> Pre- and postfrontal.	<i>Bs.</i> Basisphenoid.
<i>Pa.</i> Parietal.	<i>Ps.</i> Presphenoid.
<i>Sq.</i> Squamosal.	<i>As.</i> Alisphenoid.
<i>Ju.</i> Jugal or malar.	<i>Ty.</i> Tympanic.
<i>Pl.</i> Palatine.	<i>Ma.</i> Mastoid.
<i>Pt.</i> Pterygoid.	<i>Mn.</i> Mandible.
<i>Vo.</i> Vomer.	

Processes.

<i>ao.</i> Antorbital.	<i>cd.</i> Mandibular condyle.
<i>po.</i> Postorbital.	<i>co.</i> Coronoid.
<i>pf.</i> Postfrontal.	<i>a.</i> Angle of mandible.
<i>c.</i> Condyle.	<i>t.</i> Tentorium.
<i>pmd.</i> Paramastoid.	<i>gl.</i> Glenoideum.
<i>h.</i> Hamular (of pterygoid).	<i>eth.</i> Ethmoidal spine.

Foramina.

<i>ap.</i> Anterior palatine.	<i>vc.</i> Vidian canal.
<i>io.</i> Infraorbital.	<i>pe.</i> Posterior ethmoidal.
<i>als.</i> Alisphenoid.	2. Optic.
<i>ov.</i> Ovale.	<i>la.</i> Lacerum anterior.
<i>ca, ca*.</i> Carotid (canal).	<i>lm.</i> Lacerum medius.
<i>jug.</i> Jugular.	<i>sp.</i> Spinosum.
<i>mae.</i> Meatus auditorius externus.	<i>af.</i> Aquæductus Fallopii.
<i>mai.</i> Meatus auditorius internus.	<i>av.</i> Aquæductus vestibuli.
<i>sm.</i> Stylo-mastoid.	<i>lg.</i> Longitudinal (sinus).
<i>aur.</i> Auricular.	<i>mg.</i> Meningeal groove.
<i>ac.</i> Anterior condyloid.	<i>me.</i> Mental.
<i>ex.</i> Exoccipital.	<i>i.</i> Incisive.
<i>fm.</i> Foramen magnum.	<i>id.</i> Inferior dental.
<i>v.</i> Vascular (bony channels).	

Teeth.

<i>I, \bar{I}.</i> Incisors.	<i>PM, \overline{PM}.</i> Premolars.
<i>C, \bar{C}.</i> Canines.	<i>M, \bar{M}.</i> Molars.

The upper dotted line in fig. 5 denotes where calvarium was sawn through. Compare figs. 9 and 10.

PLATE LXXVII.

Fig. 11. Skeleton of the Zoological Society's male Sea-lion, sketched in the natural attitude of walking, and with dorsum of the sacro-pelvic region slightly turned towards the observer.

Series of skulls of *Otaria jubata*, illustrating progressive growth, reduced to scale one fourth their natural magnitudes:—

Fig. 12. Profile of skull, No. 3971 c, College-of-Surgeons Museum. It is one of two young Seals' crania presented by Captain B. J. Sullivan, R.N., in 1844, and described by him in a letter as "about a fortnight old."

Fig. 13. Upper view of the same specimen.

Fig. 14. Side view of skull, No. 3971 B, College-of-Surgeons Museum, said by donor, Captain Sullivan, to be that of a "yearling."

Fig. 15. Same skull as seen from above.

Fig. 16. Profile of a female skull, No. 3968, Osteol. Cat. Roy. Coll. Surg. Presented by Admiral Beaufort, C.B., F.R.S.

Fig. 17. Upper view of ditto, exhibiting roughening or commencement of occipito-parietal crests.

Fig. 18. Side view of skull of the mounted skeleton, No. 3971 A, Roy. Coll. of Surg. Collection. This with the above crania, figs. 12-14, are each from the Falkland Islands. Attested by Captain Sullivan of H.M. ship 'Philomel,' and referred to in a letter, 21st May 1844, as male of the Hair Seal, Sea-lion, not full grown. *Vide* interleaved Catalogue and Minutes of Museum Committee, 30th August, 1844.

Fig. 19. Upper surface of skull, figured 18: B marks a bullet lodged between the frontal and root of nasal bones.

Fig. 20. Skull of a large and old *Otaria jubata*, from Dungeness Point, S.E. Patagonia, 12th January, 1867. Presented to the Hunterian Museum by the Admiralty, 1868, and in the College Catalogue numbered 3971 E.

Fig. 21. The same skull, minus the mandible, in bird's-eye view, or from above.

The letters *, *a*, *b*, *c*, in figs. 21, 20, 19, & 18, respectively indicate extraneous processes and crest, developed and most marked as age advances.

Fig. 22. A longitudinal mesial section of an aged skull in the College-of-Surgeons Museum (No. 3971, Cat.), to show the interior brain-cavity, ethmoidal bones, &c.: *c*, great occipital crest; *tent*, bony tentorium, separating cerebral and cerebellar areas; *ex*, exoccipital foramen; *pn*, posterior nares. *Fr*, frontal, *Eth*, ethmoid, and *Tb*, turbinal bones.

Fig. 23. Under view of pelvis, last two lumbar, and the sacro-caudal vertebræ of the Zoological Society's male Otary. The parts are united by ligament and the intervertebral cartilages: about $\frac{2}{3}$ nat. size. *L*, lumbar transverse processes; *c*, intervertebral cartilage; *I*, ilium; *S*, sacrum; *P*, pubis.

The separate drawings between figs. 24 and 37 are two views of each of the bones composing the left carpus and tarsus of the male central skeleton, fig. 11.

Fig. 24. Conjoined scapho-lunar bone, as seen from above (*A*) and below (*B*): *d*, upper or dorsal surface; *r*, radial articular face; *tz*, anterior facet, which articulates with the trapezium and trapezoides; *p*, lower or palmar surface; *m*, facet for os magnum; *uc*, unciform facet.

Fig. 25. Cuneiform, (*A*) its postero-outward and (*B*) antero-inner faces: *ag*, upper hinder, and *ag**, lower front angle of the bone; *ul*, ulnar fossa; *m*⁵, facet for fifth metacarpal; *r*, radial facet; *uc*, unciform facet; *d*, narrow upper or dorsal surface.

- Fig. 26. Pisiform bone, (*A*) upper and (*B*) lower surface: *o*, outer extremity; *ul*, ulnar and cuneiform facet.
- Fig. 27. Trapezium, (*A*) upper and (*B*) lower and inner face: *s*, scapho-lunar border; *o*, outer border; *m*¹, first metacarpal facet; *td*, trapezoidal facet; *m*², second metacarpal facet; *p*, palmar surface.
- Fig. 28. Trapezoides: (*A*) inner and anterior faces, (*B*) outer and lower faces. *tp*, facet for trapezium; *m*², second metacarpal facet; *d*, upper or dorsal surface; *p*, palmar surface; *s*, scapho-lunar facet.
- Fig. 29. Os magnum, (*A*) inner and (*B*) outer surface: *d*, dorsal, and *p*, palmar apices; *m*³ and *m*⁴, facets for third and fourth metacarpals; *s*, scapho-lunar ridges; *cb*, cuboidal facet; *td*, trapezoidal facet.
- Fig. 30. Unciform, (*A*) postlateral inner and (*B*) postlateral outer surfaces: *s*, scaphoid facet; *mg*, face partially articulating with os magnum; *m*⁴ fourth metacarpal facet; *c*, cuneiform facet; *m*⁵, fifth metacarpal facet; *d*, dorsal, and *p*, palmar surface.
- Fig. 31. Astragalus, (*A*) upper and (*B*) lower surfaces: *t*, tibial, and *f*, fibular articular faces; *n*, navicular facet; *c*¹, *c*², the two calcaneal facets.
- Fig. 32. Os calcis, (*A*) superior and (*B*) inferior surfaces: *, epiphysis adherent to the posterior extremity of the tuberosity; *a*¹, *a*², the two astragaloid facets; *cb*, cuboidal articular surface.
- Fig. 33. The cuboid: (*A*) upper, outer, and partly anterior and posterior faces; (*B*) inner and inferior faces. *c*, calcaneal end; *m*^{4,5}, distal extremity for fourth and fifth metatarsals; *d*, dorsum; *g*, peroneal groove; *n*, naviculare, and *ec*, ecto-cuneiform facets.
- Fig. 34. Naviculare, (*B*) posterior and (*A*) anterior faces: *d*, dorsum; *a*, astragaloid fossa; *i*, internal angle; *ec*, *mc*, *en*, ecto-, meso-, and entocuneiform facets.
- Fig. 35. Entocuneiform, dorsal (*A*) and plantar (*B*) superficies: *n* and *mc*, facets for naviculare and mesocuneiform; *m*¹ and *m*², articular faces of first and second metatarsals; *d*, dorsum; *g*, groove for peroneus longus.
- Fig. 36. Mesocuneiform, (*A*) internal and (*B*) external faces: *d*, dorsal, and *p*, plantar border; *m*², second metatarsal articular surface; *ec* and *en*, ecto- and entocuneiform facets.
- Fig. 37. Ectocuneiform, (*A*) exterior and (*B*) interior faces: *d* and *p*, dorsal and plantar borders; *m*^{3,4}, articular border for third and fourth metatarsals; *cb*, cuboid facet; *n*, hind border or naviculare facet; *en*, part entocuneiform facet.

PLATE LXXVIII.

- Fig. 38. Upper surface of the brain of the male *Otaria jubata*, about nat. size.
- Fig. 39. Base of the same, with cerebral nerves.
- Fig. 40. Right lateral superficial view of the brain, also nat. size.

Fig. 41. Reduced sketch of a posterior segment of the inner face of the right cerebrum, designed to show the hippocampal sulci.

Fig. 42. An outline representing the same Sea-lion's brain, as seen in front or fore-shortened. Taken from a cast of the interior cavity of the skull, with the dura mater in place.

Fig. 43. Posterior or occipital view of same. Both very much reduced.

The same lettering corresponds in all the figures of this Plate.

Cerebral Lobes.

F. Frontal.
P. Parietal.

T. Temporal.
O. Occipital.

Convolutions.

IO. Internal orbital.
MO. Mid orbital.
EO. External orbital.
IF. Inferofrontal.
MF. Mid frontal.
SF. Superofrontal.
Cr. Crucial.
AP. Anteroparietal (=premier pli ascendant).
PP. Posteroparietal (=second pli ascendant).
SM. Supramarginal.
Ang. Angular.
AT. Anterotemporal (=inframarginal).
M.T. Mid temporal.

PT. Posttemporal.
Oc. Occipital (inferior).
Lob¹. Lobule of anteroparietal.
Lob². Lobule of postparietal.
Lob³. Lobule of supramarginal.
Lob⁴. Lobule of angular.
Lob⁵. Lobule of posttemporal.
Lob⁶. Lobule of internal occipital.
* Fold connecting internal occipital with quadrilateral lobule.
Ma. Great marginal.
Ca. Callosal.
Cl. Callosal lobule.
Ql. Quadrilateral.
U. Uncinate.

Fissures and Sulci.

io. Intorbital.
mo. Mid orbital.
eo. Extorbital.
cs. Crucial.
ap. Anteroparietal.
ro. Rolando.
ipa. Intraparietal.
sy¹. Sylvian (antero-vertical).
sy². Sylvian (postoblique).
at. Anterior temporal (=parallel).

mt. Mid temporal.
ot. Occipito-temporal (=posttemporal).
ep. External perpendicular (faint line pointing to front one).
ip. Internal perpendicular.
cm. Calloso-marginal.
co. Colateral.
calc. Calcarine.
dent. Dentate.

Parts Base and Internal Face.

<i>al.</i> Corpus albicans.	<i>py.</i> Anterior pyramid of medulla oblongata.
<i>pv.</i> Pons Varolii.	<i>f.</i> Fornix.
<i>cc.</i> Corpus callosum.	

Nerves.

1. Olfactory.	6. Abducentes.
1*. Olfactory bulb.	7. Facial and auditory.
2. Optic (at commissure).	8. Glossopharyngeal and pneumogastric.
3. Motores oculorum.	8*. Spinal accessory.
4. Pathetici.	9. Hypoglossal.
5. Trifacial.	<i>ce.</i> Cervical (anterior).

Cerebellum.

<i>h</i> Hollow.	<i>p.</i> Posterior lobe.
<i>fl.</i> Flocculus.	<i>sv.</i> Sup. vermiform process.
<i>to.</i> Tonsil (or amygdala).	<i>ls.</i> Lobus superioris.
<i>a.</i> Anterior lobe.	<i>li.</i> Lobus inferioris.
<i>m.</i> Middle lobe.	

PLATE LXXIX.

Fig. 44. Inner surface of the right half of the same Otary's brain, of natural dimensions: *Ma*, great marginal convolution; *cm*, calloso-marginal sulcus; *Ca*, callosal gyrus; *Cl*, its callosal lobule; *Ql*, quadrilateral lobule; *Io*, internal occipital lobule, more fully shown in fig. 41, and marked *Lob^b*; *, a ridge therefrom partly connecting it with the quadrilateral lobule; *ip*, internal perpendicular fissure; *ocp*, occipital sulcus (see fig. 41); *cc*, corpus callosum; *sp*, splenium; *g*, genu; *f*, fornix; *V⁵*, fifth ventricle; *th*, thalamus opticus; *pi*, pineal gland; *c⁴*, corpora quadrigemina; *V⁴*, fourth ventricle; *acm*, anterior commissure; *av*, arbor vitæ; *al*, corpus albicans; 1, olfactory bulb; 2 and 3, second and third nerves; *pv*, pons Varolii; *ap*, anterior pyramid of medulla oblongata.

Fig. 45. Horizontal section of the left cerebral moiety, exposing the cavity of the lateral ventricle &c.: *ac*, anterior cornu; *cs*, corpus striatum; *cf*, corpus fimbriatum, overlying choroid plexus; *th*, thalamus opticus; *pc*, posterior cornu, the dotted line in front, indicating the middle or descending cornu; *sy*, Sylvian fissure; 1*, olfactory bulb.

Fig. 46. Somewhat enlarged outline of the under surface of the left temporal lobe and neighbouring parts. The middle or descending cornu is opened into, and the

hippocampus major shown. *sy*, Sylvian fissure; *mc*, middle cornu; *hm*, hippocampus major; 2, 3, 4, portions of roots of corresponding nerves.

Fig. 47. Dissections displaying the heart, the great vessels, their divisions, and portions of the lungs.

1, 2, 3, 4, roots of different lobuli of right lung; *tr*, trachea at its bifurcation; a portion of the pulmonary substance is removed to show the bronchial divisions and vessels at lung's root; *ao*, dilated arch of the aorta; *ao**, descending aorta, of diminished calibre; *Pa*, pulmonary artery; *da*, ductus arteriosus; *i*, innominata; *r.s*, *l.s*, right and left subclavians; *r.c*, *l.c*, right and left common carotids; *r.s*, *l.s*, right and left subclavian arteries; *v*, vertebral; *im*, internal mammary; *vc*, vena cava descendens.

Fig. 48. Reduced sketch, exhibiting the semidivided upper or anterior surfaces of the great hepatic venous sinuses, and their relations to the diaphragm, liver, and stomach, as seen on removal of the parts *en masse*.

*Vs*¹, right moiety, and *Vs*², left moiety of the hepatic venous sinus or dilated vena cava ascendens; *D*, diaphragm; *br*, its broad ligament; *r.l*, round ligament; *la*, right lateral ligament; *St*, stomach, hidden in great part by the liver; *G.b*, gall-bladder.

Fig. 49. Vertical antero-posterior section of the contents of the right orbit, made slightly to one side of the median line: *l*, lens; *V*, vitreous chamber; *A*, anterior or aqueous chamber; *c*, conjunctiva; *co*, cornea; *sc*, sclerotic at its thickened hinder part; *ch*, choroid; *r*, retina; *cp*, ciliary processes; *i*, iris; *P*, canal of Petit; *S*, venous sinus or canal of Schlem; *n*, opening of nasal duct; *gl*, gland; *t*, tarsal cartilage; *o*, optic nerve; *a*, artery; *Rs*, *Ri*, superior and inferior rectus; *cho*, choanoid muscle.

Fig. 50. Inner view of the anterior segment of the eyeball, cut crossways. The lettering applies as in the preceding: *sp*, sphincter iridis.

Fig. 51. The vitreous humour with adherent crystalline lens and zonula of Zinn. Seen in front, and about nat. size. The dark pigmental radial processes (*p*) of the ciliary zone are unusually long and prominent.

PLATE LXXX.

Fig. 52. Tongue and fauces of the Sea-lion shown as an anatomical preparation, looking into the throat, but in a three-quarters view.

v, velum palati; *a*, anterior pillars of the fauces; *p*, posterior pillars; *t*, right tonsil; *e*, right postlingual eminence, or postfaucial tract; *g*, mesial groove or cleft.

Fig. 53. Under surface of the tongue, larynx, and portion of the trachea. The superficial layer of muscles &c. are retained on the left side, and a deeper dissection of the several structures brought out on the right.

M.h. Mylo-hyoid.

O.h. Omo-hyoid.

S.h. Sterno-hyoid.

S.th. Sterno-thyroid.

C.th. Crico-thyroid.

Th.h. Thyro-hyoid.

G.h. Genio-hyoid.

S.g. Stylo-glossus.

s.l. Superior laryngeal nerve and artery.

l. Lingual artery and hypoglossal nerve.

g. Gustatory nerve.

T.gl., thyroid gland; *Sgl.*, sublingual gland and duct.

Fig. 54. Side view, deep dissection, of the same regions as in fig. 53, but enlarged.

The lettering agrees, but there is in addition:—*Ghg.*, genio-hyoglossus; *Thy.*, thyroideus; *Ic.*, inferior constrictor; *Mc.*, middle constrictor; *Sph.*, stylo-pharyngeus; *Hg.*, hyoglossus; *oe.*, œsophagus; *v.*, jugular vein; *ca.*, common carotid artery, dividing anteriorly into internal and external carotids, with subsidiary branches; *pn.*, pneumogastric nerve, superior laryngeal, pharyngeal, and lingual derivatives springing and being distributed anteriorly.

Fig. 55. Upper view of the pharyngeal constrictors and the adjoining parts: *il.*, inferior laryngeal nerve; *Sc.*, superior constrictor, in part; *Azu.*, azygos uvulæ uncovered on one side; *Pp.*, palato-pharyngeus; arrow leads into pharynx. Other letters apply as in preceding (fig. 54) and succeeding (fig. 56), in which latter portions of muscles have been removed.

Fig. 56. A deeply dissected side view of the same region as in fig. 55. *He.*, hyo-epiglottic.

Fig. 57. Epiglottis and laryngeal fissure, with part of the pharyngeal membrane of the left side, reflected outwards. Seen from above, and somewhat less than natural dimensions: *Ep.*, epiglottis; *sp.*, fatty prominences, or Santorinian projections; *ae.*, aryteno-epiglottic folds; *p.*, papillæ of the postfaucial floor; *a.*, arytenoid prominences; *ph.*, pharyngeal cavity.

Fig. 58. Reduced diagrams illustrating the outline of the superior aperture of the larynx in three different states of tension: 1, its natural condition; 2, slightly open, or during inhalation (?); 3, fully distended. The black ground marks the longitudinal chink, the light the divaricating loops.

Fig. 59. The interior left half of the larynx as displayed by a mesial longitudinal section through the entire organ, but retaining the epiglottis intact: *ep.*, epiglottis; *s.p.*, fatty projections above the cartilage of Santorini; *T.*, *T**, sections of the thyroid cartilage, the smaller portion being the narrow bridge anteriorly connecting the thyroid alæ; *C.*, cricoid, in front and behind; *tr.*, trachea; *s.*, orifice of laryngeal sac.

Fig. 60. The deep lateral thyro-arytenoid muscles &c. The dotted outline signifies the boundary of the right thyroid ala, which has been removed. *L.c.a.*, lateral crico-arytenoid; *P.c.a.*, posterior crico-arytenoid; *Ar.*, arytenoideus; *Th.a¹*, thyro-arytenoideus, its first or lower portion; *Th.a²*, second or upper portion of the thyro-arytenoideus; *s.*, laryngeal sac or pouch; *ep.*, epiglottis.

- Fig. 61. Hinder view of the larynx and its arytenoideus muscles; the dotted outlines indicating the absent left thyroid cartilaginous moiety. *Ar*, arytenoideus; *P.c.a*, posterior crico-arytenoid.
- Fig. 62. Ventral surfaces, hyoid bones, thyroid and cricoid cartilages, and on opposite half the deep muscles connected therewith. *H*¹ and *Hg*², separate insertions of hyoglossus; *Mc*, fibres of middle constrictor; *Thy*, thyroideus; *Cth*, cricothyroideus.
- Fig. 63. Larynx and hyoidean arch, in profile. *T*, thyroid cartilage; *C*, cricoid; *tr*, trachea; *c.t.l*, crico-thyroid ligament; *l*, lateral thyro-hyoid ligament; *sh*, stylohyal, and *tyh*, tympanohyal, its cartilaginous articulating tip; *eh*, epihyal; *cth*, ceratohyal; *bh*, basihyal; *th*, thyrohyal.
- Fig. 64. View from behind of the hyoidean arch and larynx. *A*, arytenoid cartilage; *S*, cartilage of Santorini; *n*, nodule in thyro-hyoid membrane. Other lettering corresponds with the parts in fig. 63.

PLATE LXXXI.

- Fig. 65. Reduced view of the distended stomach, seen from behind, with the spleen, vessels, and nerves *in situ*:
- æ*, œsophagus, cardiac end; *py*, pyloric end of stomach; *d*, duodenum; *sp*, spleen; *h.a*, hepatic artery cut short; *s.a*, splenic artery; *v.b*, trunk of one of the vasa brevia; *c.a*, cardiac artery; *g.es*, gastric epiploica sinistra as it proceeds to inosculate with the dextral branch. The veins not lettered follow alongside the arteries; *n*, gastric nerve other branches are seen distributed upon the surface of the stomach.
- Fig. 66. A few inches of the Jejunum, with the mesentery attached, and showing the intestinal subdivision and distribution of the superior mesenteric vessels: *a*, artery; *v*, vein.
- Fig. 67. Portions of the ileum and colon, with cæcum coli and ramifications of the ileo-cæcal artery and vein: *cæ*, cæcum; *a*, artery; *v*, vein. The arrows indicate the passage from small to great gut.
- Fig. 68. Small piece of intestine (14 feet from pylorus), cut open to display part of broad elongated Peyer's patch. *Pgl*. Peyer's gland, about nat. size.
- Fig. 69. A portion of the rectum, exhibiting its mucous membrane, of nat. dimen.
- Fig. 70. A longitudinal section of the right kidney, sliced through a little to one side of its middle. Of nat. size. The arteries, veins, and urinary tubes have each different-coloured injection thrown into them. *r.a*, renal artery; *rv*, renal vein; *u*, ureter; * veno-arterial inoscultations.
- Fig. 71. Segment of the cortical surface of the same kidney, showing the arborescent nature of its superficial vascularity. The darker stellate lines indicate chiefly the veins. The undulate marginal periphery exhibits but slight lobulation.

PLATE LXXXII.

- Fig. 72. Under surface of the liver, its vessels, and a small piece of the gut. Reduced. *R*, right and *L*, left hepatic moieties. I, II, III, IV, V, VI, VII, VIII, lobes or segments of the liver as described in the text. *C*, caudate, *Q*, quadrate, and *Sp*, Spigelian lobuli; *l*, cystic ligament; *cl*, coronary ligament; *Gb*, gall-bladder; *cd*, cystic duct; *hd*, hepatic duct; 1, 2, 3, 4, 5, 6, branches of same, distributed to the several lobules (see text); *h.a*, hepatic artery; *p.v*, portal vein; *Vc*, vena cava; *VS*¹, *VS*², venous sinuses, right and left, the latter only partially visible; *dch*, ductus communis choledochus, an arrow showing its tunnel within wall of duodenum (*duo*) to its orifice at *o*.
- Fig. 73. Urino-generative parts, displayed as a preparation. *B*, bladder; *uh*, remnant of the urachus; *u*, ureter; *la*, lateral ligament; *a.l*, portion of the anterior ligament of the bladder; *v.d*, the termination of the vasa deferentia; *P*, prostate; *c.u*, compressor urethræ; *I.c*, ischio-cavernosus, its bony insertion cut through; *B.c*, bulbo-cavernosus; *R.p*, retractores penis; *sph*, sphincter ani; *R*, portion of rectum; *c*, left crus; *s.l*, suspensory ligament; *a.v*, dorsal artery and vein of the penis; *c.s*, dark line representing the corpus spongiosum; *os*, os penis, posteriorly defined by a dotted line; *, the bent part where fractured; *f*, frænum; *g*, glans.
- Fig. 74. Point of the penis. Front view, about nat. size. *os**, truncate termination of os penis; *g*, glans; *m.u*, meatus urinarius.
- Fig. 75. Neck of bladder, prostatic and membranous portions of urethra, opened from above. *B*, bladder; *u*, orifices of ureters; *e.d*, ejaculatory duct; *P*, prostate in section; *c.c*, corpus cavernosum.
- Fig. 76. Testicle in section and its sac. *t.v*, tunica vaginalis; *g.m*, globus major; *r.v*, rete vasculosum.

LIST OF THE PAPERS CONTAINED IN VOL. VIII.

	Page		Page
ALLMAN, Professor G. J., F.R.S.		Researches upon the Anatomy of the Pinnipedia. Part III. Descriptive Anatomy of the Sea-lion (<i>Otaria jubata</i>)	501
Report on the Hydroida collected during the Expeditions of H.M.S. 'Porcupine'	469	OWEN, Professor, C.B., F.R.S., F.L.S., F.Z.S., &c.	
ANDERSON, Professor JOHN, M.D., C.M.Z.S.		On Dinornis (Part XVII.): containing a Description of the Sternum and Pelvis, with an attempted Restoration, of <i>Aptornis defossor</i> , Ow.	119
On the Osteology and Dentition of <i>Hylomys</i>	453	On Dinornis (Part XVIII.): containing a Description of the Pelvis and Bones of the Leg of <i>Dinornis gravis</i>	361
DUNCAN, Professor P. MARTIN, M.B. (Lond.), F.R.S., F.G.S.		On Dinornis (Part XIX.): containing a Description of a Femur indicative of a new Genus of large Wingless Bird (<i>Dromornis australis</i> , Owen) from a post-tertiary deposit in Queensland, Australia	381
A Description of the Madreporaria dredged up during the Expeditions of H.M.S. 'Porcupine' in 1869 and 1870	303	On the Osteology of the Marsupialia (Part III.). Modifications of the Skeleton in the Species of <i>Phascolomys</i>	345
FLOWER, WILLIAM HENRY, F.R.S., V.P.Z.S., Hunterian Professor of Comparative Anatomy, and Conservator of the Museum of the Royal College of Surgeons.		On the Osteology of the Marsupialia (Part IV.). Bones of the Trunk and Limbs, <i>Phascolomys</i>	483
On Risso's Dolphin (<i>Grampus griseus</i> , Cuv.)	1	WALDEN, ARTHUR VISCOUNT, F.R.S., P.Z.S. &c.	
On the Recent Ziphioid Whales, with a Description of the Skeleton of <i>Berardius arnouxi</i>	203	A List of the Birds known to inhabit the Island of Celebes	23
MIVART, St. GEORGE, F.R.S., F.L.S., F.Z.S.		Appendix to a List of Birds known to inhabit the Island of Celebes	109
On the Axial Skeleton of the Ostrich (<i>Struthio camelus</i>)	385		
MURIE, JAMES, M.D., F.L.S., F.G.S., &c.			
On the Form and Structure of the Manatee (<i>Manatus americanus</i>)	127		
On the Organization of the Caaing Whale (<i>Globiocephalus melas</i>)	235		

INDEX OF SPECIES, ETC., IN VOL. VIII.

- Accipiter cruentus*, 34.
 — *hyogaster*, 34.
 — *rufitorques*, 34.
Acridotheres cinereus, 77, 108.
 — *fuscus*, 77.
 — *javanicus*, 77.
Acrocephalus arundinaceus, 64.
 — *brunnescens*, 64.
 — *magnirostris*, 64.
 — *orientalis*, 64.
Actitis glareola, 96.
 — *hypoleucos*, 96.
Ægialites curonicus, 89, 90.
 — *hiaticula*, 89, 90.
 — *dubius*, 89.
 — *minutus*, 89, 90.
 — *peronii*, 90, 108.
Æthopyga flavostriata, 71.
Aglaophenia dromaius, 471, 475, 476, 480.
 — *elongata*, 471, 476, 481.
 — *myriophyllum*, 471.
 — *tubulifera*, 476.
Alcedo asiatica, 45.
 — *collaris*, 44.
 — *diops*, 44.
 — *meninting*, 45.
 — *minor moluccensis*, 45.
 — *moluccensis*, 45.
 Allman, G. J. Report on the Hydroida collected during the Expeditions of H.M.S. 'Porcupine,' 469.
Amphihelia atlantica, 307, 324, 326.
 — *miocenica*, 307, 323, 324.
 — *oculata*, 305, 307, 322, 324, 325, 326, 337, 338, 339, 340, 342.
 — *ornata*, 307, 324, 326.
 — *ramea*, 305, 307, 324, 326, 337, 338, 339, 340, 342, 343.
Amphihelia sculpta, 307, 323.
 — *venusta*, 323.
Anas gracilis, 102.
 — *querquedula*, 102.
 Anderson, John. On the osteology and dentition of *Hylomys*, 453.
Antennularia antennina, 471.
Anthreptes malaccensis, 70.
Anthus arboreus, 117.
Aodon, 209.
Apiaster philippensis major, 42.
Aporosa, 306, 309–332.
Apteryx australis, 363.
Aptornis defossor. On *Dinornis* (Part XVII.): containing a description of the sternum and pelvis, with an attempted restoration of, by Prof. Owen. 119.
 — —, comparison of the sternum and femur of, with *Tribonyx ventralis*, *Ocydromus australis*, *Notornis*, *Aptornis otidiformis*, &c., 119–122.
 — —, comparison of sternum of, with *Cnemidornis*, 122.
 — —, ilium of, 124.
 — —, pelvis of, 122, 125.
 — —, sternum of, 119, 120.
 — —, vertebræ of, 122–124.
 — *otidiformis*, 119–124.
Aquila audax, 380.
Arachnechthra flavigastra, 71.
 — *frenata*, 71.
Arachnothera longirostra, 70.
Arctocebus calabarensis, 563.
Ardea alba, 99.
 — *caledonica*, 100.
 — *fusca*, 98.
 — *gardeni*, 100.
 — *garzetta*, 99.

- Ardea goliath*, 98.
 — *insignis*, 98.
 — *lepida*, 99.
 — *leucocephala*, 101.
 — *maculata*, 100.
 — *melanophis*, 99.
 — *melanoptera*, 99.
 — *melanotis*, 99.
 — *modesta*, 99.
 — *nebulosa*, 99.
 — *nigripes*, 99.
 — *prasinoscetes*, 98.
 — *rectirostris*, 98.
 — *sumatrana*, 98.
 — *typhon*, 98.
Ardeola grayi, 98.
 — *leucoptera*, 98, 99.
 — *malaccensis*, 98, 99.
 — *speciosa*, 98.
Ardeomega nobilis, 98.
Ardetta cinnamomea, 99.
 — *sinensis*, 99.
Artamides bicolor, 70.
Artamus leucogaster, 67.
 — *leucopygialis*, 67.
 — *leucorhynchus*, 67, 68.
 — *melaleucus*, 67.
 — *mentalis*, 67.
 — *monachus*, 67, 107, 113.
 — *papuensis*, 67.
Astroridae, 307, 327-332.
Astur barbatus, 37.
Athene borneensis, 40, 41.
 — *florensis*, 41.
 — *japonica*, 41.
 — *malaccensis*, 41.
 — *ochracea*, 38.
 — *punctulata*, 38.
 Avifauna, list of species to be added to the Celebean,
 114.
Balæna mysticetus, 265, 268.
Balaenoptera carolineæ, 236.
 — *musculus*, 236, 266, 268, 276, 286, 298,
 299.
 — *rostrata*, 235-237, 248, 263-265, 273-
 276.
 — *sibbaldii*, 236, 237, 239, 271.
Balanophyllia britannica, 334.
Balanophyllia cellulosa, 308, 333, 337, 339, 344.
 — *gaditana*, 308, 333, 337, 339.
 — *jeffreysia*, 334.
 — *socialis*, 308, 333, 337, 338, 342.
Basileornis celebensis, 77.
 — *corythæix*, 77.
Bathyecyathus atlanticus, 306, 318, 337, 339, 343.
 — *chilensis*, 318.
 — *sowerbyi*, 318.
Baza magnirostris, 36.
 — *reinwardtii*, 36.
Berardius arnouci. On the recent Ziphioid Whales,
 with a description of the skeleton of, by W. H.
 Flower, 203.
 — —. Preliminary notice of a Ziphioid
 Whale, probably *Berardius arnouci*, stranded
 on the 16th of December, 1868, on the sea-
 beach, near New Brighton, Canterbury, New
 Zealand, by Julius Haast, 214.
 — —, antero-posterior length of the bodies of
 the thoracic, lumbar, and caudal vertebræ of,
 228.
 — —, caudal vertebræ of, 228.
 — —, cervical vertebræ of, 224; dimensions of,
 226.
 — —, description of the skeleton of, 217-
 233.
 — —, dimensions of, 212.
 — —, dimensions of the bones of the right
 pectoral limb of, 231.
 — —, history of, 212.
 — —, hyoid bones of, 223.
 — —, lumbar vertebræ of, 227.
 — —, pectoral limb of, 230.
 — —, pelvic bones of, 232.
 — —, ribs of, 229.
 — —, skull of, 217-223; dimensions of, 221.
 — —, sternum of, 229.
 — —, teeth of, 222.
 — —, thoracic vertebræ of, 226.
 — —, vertebral column of, 223.
 — *hectori*, 211.
 Birds, table of Indian genera of, found in Celebes, 24.
 —, table showing the Australian genera of, found
 in Celebes, 25.
 —, table showing the genera of, represented in
 Celebes which likewise occur both within and
 beyond the limits of the Indian region, 25.

- Birds, table showing the genera of, found in Celebes which are also common to the Indian and Australian regions, 25.
- , table showing the principal Austro-Malayan or Papuan genera of, which do not occur in Celebes, 29.
- , table showing the principal Indian genera of, which are wanting in Celebes, 27.
- Brachyurus celebensis*, 62.
- *forsteni*, 62.
- Broderipus celebensis*, 112.
- *coronatus*, 60, 112.
- *frontalis*, 61.
- Buceros cassidia*, 47.
- *corrugatus*, 51.
- *exaratus*, 47, 107.
- *sulcatus*, 51.
- Budytes viridis*, 65.
- Buphus bacchus*, 98.
- Butalis hypogrammica*, 66.
- Buteo pygmaeus*, 37.
- *pyrrhogenys*, 37.
- Butorides chloriceps*, 101.
- *javanica*, 100.
- Caaing Whale (*Globiocephalus melas*), on the Organization of the, by J. Murie, 235.
- — (see *Globiocephalus melas*).
- Cacatua æquatorialis*, 30, 31.
- *sulphurea*, 30, 31.
- Caccabis rufa*, 101.
- Cacomantis assimilis*, 54.
- *borneensis*, 54.
- *bronzinus*, 54.
- *castaneiventris*, 54.
- *dumetorum*, 54.
- *fasciolatus*, 55.
- *flabelliformis*, 54.
- *infaustus*, 54.
- *infuscatus*, 55.
- *insperatus*, 54.
- *lanccolatus*, 53-55.
- *merulinus*, 54, 55.
- *pallidus*, 54.
- *passerinus*, 54, 55.
- *pravatus*, 55.
- *pyrogaster*, 54.
- *rufovittatus*, 55.
- *sepulchralis*, 54, 116.
- Cacomantis simus*, 54, 55.
- *sonnerati*, 55.
- *tenuirostris*, 54.
- *threnodes*, 54.
- *tymbonomus*, 54.
- Callialcyon rufa*, 44.
- Caloenas nicobarica*, 86.
- Calornis affinis*, 79.
- *amboinensis*, 80, 81.
- *aromatica*, 82.
- *cantaroides*, 80, 81.
- *chalybea*, 79, 81.
- *crassirostris*, 80, 81.
- *curvirostra*, 82.
- *gularis*, 80.
- *kittlitzii*, 80.
- *metallica*, 79-81, 107.
- *mysolensis*, 80.
- *neglecta*, 79, 80, 81, 113.
- *nitida*, 80.
- *obscura*, 79, 80.
- *psittacea*, 82.
- *purpurascens*, 80, 81.
- *virescens*, 80.
- *viridescens*, 80.
- Calycella fastigiata*, 471.
- Campephaga nigra*, 69.
- Caprimulgus affinis*, 114.
- *arundinaceus*, 115.
- *binotatus*, 115.
- *europæus*, 114.
- *macrourus*, 115.
- *monticolor*, 115.
- Capromys fourrieri*, 563.
- Carpophaga luctuosa*, 84.
- *paulina*, 83.
- Caryophyllia abyssorum*, 306, 310, 311, 315, 337, 339, 340.
- *africana*, 313.
- *arcuata*, 306, 310, 313, 317, 337, 339, 342.
- *berteriana*, 314, 317.
- *borealis*, 305, 306, 309, 312, 338, 340, 343.
- *calveri*, 306, 310, 311, 312, 316, 337, 339.
- *clavus*, 305, 306, 310, 311, 337, 338, 339, 340, 343, 344.
- *corniformis*, 317.
- *cyathus*, 306, 310, 313, 337.

- Caryophyllia cylindracea*, 306, 310, 311, 314, 315, 337, 339, 340.
 — *elongata*, 306, 311, 340, 344.
 — *epithecata*, 306, 312, 344.
 — *exserta*, 306, 312, 343.
 — *formosa*, 317.
 — *inskipi*, 306, 310, 311, 316, 337, 339.
 — *ornata*, 314.
 — *pourtalsi*, 306, 310, 311, 317, 337, 339, 341.
 — *sequenzæ*, 306, 310, 314, 337, 338, 342.
 — *smithii*, 305, 306, 309, 312, 340, 344.
 — *vermiformis*, 306, 310, 311, 316, 337, 339, 341.
Casuarius bennettii, 124.
Ceblepyris fimbriatus, 69.
 — *lugubris*, 69.
 Celebes. A list of birds known to inhabit the Island of, by Arthur, Viscount Walden, 23.
 —. An appendix to a list of birds known to inhabit the Island of, by Arthur, Viscount Walden, 109.
Centrococyx affinis, 56–60, 112.
 — *bengalensis*, 59, 60.
 — *dimidiatus*, 59.
 — *javanensis*, 58, 60.
 — *medius*, 58, 60.
 — *moluccensis*, 59, 60.
 — *rectunguis*, 60.
 — *viridis*, 58.
Centropus affinis, 60.
 — *aterallbus*, 56.
 — *bengalensis*, 57.
 — *bicolor*, 55.
 — *bornensis*, 57.
 — *bubutus*, 57.
 — *chlororhynchus*, 57.
 — *dimidiatus*, 57.
 — *curycercus*, 57.
 — *javanensis*, 57, 112.
 — *lepidus*, 57, 58, 60.
 — *lignator*, 57, 59.
 — *medius*, 56, 57.
 — *melanopus*, 56.
 — *molkenboeri*, 58.
 — *moluccensis*, 57.
 — *nigrifrons*, 56.
 — *phasianus*, 57.
 — *philippensis*, 58.
 — *pumilus*, 58, 60.
Centropus pygmæus, 59.
 — *rectunguis*, 56, 57.
 — *rufinus*, 59.
 — *rufipennis*, 56, 57.
 — *viridis*, 57, 59.
Ceratocyathus armatus, 306, 310, 314.
Ceycopsis fallax, 45, 112.
Chætura celebensis, 46.
 — *gigantea*, 46.
Chalcophaps hombroni, 86.
 — *indica*, 86, 114.
 — *stephani*, 85, 86, 114.
Chalcostetha porphyrolema, 71.
Charadrius alexandrinus, 89.
 — *euronicus*, 89.
 — *fulvus*, 88.
 — *giganteus*, 91.
 — *intermedius*, 89.
 — *magnirostris*, 91.
 — *minor*, 89.
 — *minutus*, 89.
 — *philippinus*, 89.
 — *pusillus*, 89.
Charitornis albertinae, 76, 77.
Circus approximans, 38.
 — *assimilis*, 37, 38, 380.
 — *gouldi*, 38.
 — *gardenii*, 37, 38.
 — *macropterus*, 38.
Cisticola cursitans, 64, 65.
 — *grayi*, 117.
 — *lineocapilla*, 65.
 — *schauincola*, 64.
Cittura cyanotis, 44.
 — *sanghirensis*, 44.
Cladocarpus formosus, 471, 478, 481.
Climacteris leucophaea, 106.
Collocalia concolor, 46.
 — *esculenta*, 46.
 — *fuciphaga*, 46.
 — *hypoleuca*, 46.
Columba caeca, 83.
 — *diademata*, 83.
 — *hypogastra*, 83.
 — *monacha*, 83.
 — *viridis*, 81.
Coracias papuensis, 43.
 — *temminckii*, 43.

- Corvus advena*, 74, 75.
 — *balicassius*, 70.
 — *caledonicus*, 74, 75.
 — *corone*, 74.
 — *dauricus*, 75.
 — *enca*, 74, 113.
 — *validus*, 74, 113.
 — (*Physocorax*) *moneduloides*, 74.
Corydalla gustavi, 117.
Corydonix maculatus, 59.
 — *pyrrhopterus*, 58.
Cranorrhinus cassidiæ, 47-49.
Criniger aureus, 109.
Cuculus canoroides, 116.
 — *canorus*, 115, 116.
 — *flavus*, 54.
 — *himalayanus*, 116.
 — *micropterus*, 116.
 — *præsagus*, 51.
 — *pyrrhocephalus*, 52.
 — *saturatus*, 116.
 — *sumatranus*, 53.
 — *tolu*, 58.
Cuncuma leucogaster, 35.
Cuspidella grandis, 471.
Cyathaxonidae, 308, 335.
Cyornis banyunas, 117.
 — *rufigula*, 66, 107.
Dacelo cyanocephalus, 43.
 — *monachus*, 43.
Dasyurus macrurus, 496.
Delphinorhynchus, 209.
 — *micropterus*, 210.
Delphinus acutus, 20.
 — *aries*, 16.
 — *bidentatus*, 209.
 — *butskode*, 209.
 — *densirostris*, 209.
 — *edentatus*, 209.
 — *epiodon*, 209.
 — *globiceps*, 20.
 — *grœnlandicus*, 209.
 — *griseus*, 17-19.
 — *heavisidii*, 20.
 — *melas*, 235.
 — *micropterus*, 209, 210.
 — *nesarnak*, 237.
 — *obscurus*, 20.
Delphinus phocæna, 264, 268.
 — *risso*, 16.
 — *sowerbensis*, 209.
 — *sowerbyi*, 210.
 — *tursio*, 266, 287.
 — (*Heterodon*) *sowerbensis*, 210.
 — (*Phocæna*) *rissoanus*, 16, 18, 19.
Demicretta asha, 100.
 — *sacra*, 100.
Dendrocygna gouldi, 103.
 — *guttata*, 102.
 — *guttulata*, 102.
 — *vagans*, 102.
Dendrophyllia cornigera, 308, 334, 337, 339.
Dermophyllum costatum, 307, 321, 322.
 — *crista-galli*, 305, 307, 321, 337, 339, 340, 341.
 — *cumingi*, 307, 321.
 — *dianthus*, 321.
 — *stokesi*, 322.
Dicaeum celebicum, 72.
 — *leclancherii*, 72.
Dicrurus atroceruleus, 106.
 — *bimaënsis*, 106.
 — *leucops*, 70.
 — *pectoralis*, 70.
Didelphys ursina, 345.
Dinornis (Part XVII.). Containing a description of the sternum and pelvis, with an attempted restoration of *Aptornis defossor*, Ow., by Prof. Owen, 119.
 — (Part XVIII.). Containing a description of the pelvis and bones of the leg of *Dinornis gravis*, by Prof. Owen, 361.
 — (Part XIX.). Containing a description of a femur indicative of a new genus of large wingless bird (*Dromornis australis*, Owen), from a post-tertiary deposit in Queensland, Australia, by Prof. Owen, 381.
 — *altus*, 375.
 — *casuarinus*, 362, 366, 368, 369, 375, 376.
 — —; dimensions of the femur, tibia, and metatarsus of, 371.
 — *crassus*, 362-365, 373, 375-377.
 — —, dimensions of the femur, tibia, and metatarsus of, 371, 373.
 — *curtus*, 375.
 — —, dimensions of the femur, tibia, and metatarsus of, 371.
 — *didiformis*, 369, 372, 375.

- Dinornis didiformis*, dimensions of the femur, tibia, and metatarsus of, 371, 372.
 — *dromioides*, 372, 375.
 — —, dimensions of the femur, tibia, and metatarsus of, 371.
 — *elephantopus*, 365, 375–377.
 — —, dimensions of the femur, tibia, and metatarsus of, 371, 373.
 — *geranooides*, 372, 375, 377.
 — —, dimensions of the femur, tibia, and metatarsus of, 371.
 — *giganteus*, 361, 366, 368, 369, 375, 376.
 — —, dimensions of the femur, tibia, and metatarsus of, 371, 374.
 — *gracilis*, 375.
 — —, dimensions of the femur, tibia, and metatarsus of, 371, 372.
 — *gravis*. On *Dinornis* (Part XVIII.), containing a description of the pelvis and bones of the leg of, by Prof. Owen, 361.
 — —, dimensions of the femur, tibia, and metatarsus of, 371, 372.
 — —, femur of, 366, 379.
 — —, metatarsus of, 362, 378.
 — —, pelvis of, 369; dimensions of, 370.
 — —, tibia of, 364, 378.
 — *ingens*, 361, 375, 376.
 — —, dimensions of the femur, tibia, and metatarsus of, 371, 374.
 — *maximus*, 366, 375.
 — —, dimensions of the femur, tibia, and metatarsus of, 371, 375.
 — *rhœdes*, 375–377.
 — —, dimensions of the femur, tibia, and metatarsus of, 371.
 — *robustus*, 365, 375–377.
 — —, dimensions of the femur, tibia, and metatarsus of, 371, 375.
 — *strathioïdes*, 361, 373, 375.
 — —, dimensions of the femur, tibia, and metatarsus of, 371, 374.
 —, table of admeasurements of the bones of the leg of the known species of, 371.
- Diodon*, 209.
Diphasia coronifera, 471, 474, 480.
 — *pinaster*, 470, 471.
Diplodon, 209.
 — *europæus*, 211.
Diplodon gervaisii, 211.
Diplohelia doderleiniana, 307, 324, 327.
 — *meneghiniana*, 307, 324, 327.
 — *profunda*, 307, 324, 326.
 — *sismondiana*, 327.
Diplopteron insigne, 471, 479–481.
Dolichodon, 209.
 Dolphin, Risso's (see *Grampus griseus*).
Dromaius ater, 382.
 — *novæ-hollandiæ*, 366.
Dromornis australis. On *Dinornis* (Part XIX.): containing a description of a femur indicative of a new genus of large wingless bird, from a post-tertiary deposit in Queensland, Australia, by Prof. Owen, 381.
 — —, femur of, compared with *Dinornis elephantopus*, 382–384.
 — —, measurement of femur of, 382.
Drymophila alecto, 107.
 Duncan, P. Martin. A description of the Madreporaria dredged up during the expeditions of H.M.S. 'Porcupine' in 1869 and 1870, 303.
Dysporus sula, 106.
Eeectus mülleri, 31.
Edoliosoma melanolema, 69.
 — *morio*, 69.
Elanus hypoleucos, 30, 36.
 — *intermedius*, 36.
 Emu, the, 382.
Enodes erythrophrys, 78.
Eos cochinsinensis, 107.
Ephialtes leucospila, 39, 40.
 — *magicus*, 39, 40.
 — *menudensis*, 30, 40.
Epiodon australe, 235.
 — *australis*, 208.
 — *desmarestii*, 207.
Erythra phœnicura, 94.
Erythropitta celebensis, 62.
Erythrospiza iogastra, 34.
 — *trinotata*, 33.
Esacus magnirostris, 91.
 — *recurvirostris*, 91.
Eudendrium ramosum, 470, 471.
Eudromia veredus, 88.
Eudynamis melanorhyncha, 53, 112.
Eulabes javanus, 81.
Eurystomus orientalis, 43.

- Eurystomus pacificus*, 43.
Excalfactoria chinensis, 87.
 ——— *minima*, 87.
Falcinellus igneus, 101.
 ——— *peregrinus*, 101.
Falco aldrovandi, 33.
 ——— *columbarius*, 33.
 ——— *cuculoides*, 34.
 ——— *indicus*, 37.
 ——— *javanicus*, 37.
 ——— *poliogenys*, 37.
 ——— *rupicolus*, 33.
Filellum serpens, 470.
Flabellum distinctum, 307, 322, 337, 339, 340.
 ——— *extensum*, 307, 322.
 ——— *laciniatum*, 307, 322, 337, 338.
 Flower, W. H. On the recent Ziphioid Whales, with a description of the skeleton of *Berardius arnouxi*, 203.
 ———. On Risso's Dolphin, *Grampus griseus* (Cuv.), 1.
Fungia symmetrica, 308, 334, 337, 339, 344.
Fungiidae, 308, 334.
Gallinago megala, 98.
Gallinula ardosiacea, 94.
 ——— *chloropus*, 94.
 ——— *frontata*, 93.
 ——— *hamatopus*, 93.
 ——— *orientalis*, 94.
 ——— *tenebrosa*, 93.
Gallus bankiva, 86.
 ——— *ferrugineus*, 87.
Gastornis parisiensis, 366.
Gazzola caledonica, 75.
 ——— *typica*, 74, 75.
Geocichla erythronota, 61, 107, 113.
 ——— *interpres*, 61.
Geopelia striata, 86.
Glareola grallaria, 117.
Globiocephalus affinis, 290.
 ——— *chinensis*, 235, 291.
 ———, comparative table of diagnostic characters of, compared with *Grampus*, 20, 21.
 ——— *edwardsii*, 290.
 ——— *grayi*, 291.
 ——— *indicus*, 291.
 ——— *macrorhynchus*, 291.
 ——— *melas*, 20, 235.
 ——— ———, alimentary canal of, 256-260.
Globiocephalus melas, auditory appendages of, 249-251.
 ——— ———, cavity of the mouth, dental armature, and pharynx of, 252-256.
 ——— ———, external characters of, 238-242.
 ——— ———, eye and its surroundings of, 242.
 ——— ———, fleshy motor agents of body and limbs of, 272-284.
 ——— ———, general observations and history of, 235-237.
 ——— ———, genitalia of, 284.
 ——— ———, glands accessory to alimentation of, 260-262.
 ——— ———, heart of, 266.
 ——— ———, hyoidean and laryngeal structures of, 262-365.
 ——— ———, measurement of the tail of, 241.
 ——— ———, measurements of, 240.
 ——— ———, muscles acting chiefly on the pectoral limb of, 272-276.
 ——— ———, muscles acting on the sterno-costal framework of, 281, 282.
 ——— ———, muscles acting on the trunk and tail of, 276-281.
 ——— ———, muscles connected with neck and head of, 282-284.
 ——— ———, nasal passages of, 242-248.
 ——— ———, nervous centre of, 272.
 ——— ———, on the organization of, 235.
 ——— ———, organs subservient to deglutition and digestion of, 252-262.
 ——— ———, parts related to the senses of, 242-252.
 ——— ———, pelvic bones, ligament, and muscles of, 286-290.
 ——— ———, respiration and machinery involved, 262-266.
 ——— ———, reflections, zoological and physiological, on, 290-293.
 ——— ———, sanguiferous distribution of, 266-272.
 ——— ———, skin, and subcutaneous coverings of, 248, 249.
 ——— ———, tongue of, 251.
 ——— ———, tracheo-pulmonary parts of, 265.
 ——— ———, urino-generative organs and pelvic-appendage homologues of, 284-290.
 ——— ———, vascular channels and reservoirs of, 268-271.

- Globiocephalus propinquus*, 291.
 — *sieboldii*, 291.
 — *svineval*, 235, 239, 264, 282, 290.
Grammaria abietina, 470.
Grampus cuvieri, 15.
 — *griseus*, Risso's Dolphin, by W. H. Flower, 1.
 — —, 235.
 — — and *G. rissoanus*, identity of, 18.
 — —, anterior surface and side view of cervical vertebrae of, 5.
 — —, bones of the pectoral limb of, 10.
 — —, earliest account of, 15.
 — —, carpal bones of, 10.
 — —, carpal bones and the phalanges of the young of, 14.
 — —, chevron bones of, 7.
 — —, coloration of, 3.
 — —, coloration of the young of, 12.
 — —, dimensions of vertebrae of, 5.
 — —, dimensions of the young of, 12.
 — —, fins of the young compared with those of the adult, 12.
 — —, general form of, 2.
 — —, general form of skull of, 8.
 — —, general form of the young of, 12.
 — —, humerus of, 10.
 — —, pelvic bones of, 8.
 — —, periotic and tympanic bones of, 9.
 — —, principal dimensions of, 1.
 — —, principal dimensions of the bones of the pectoral limb of, 11.
 — —, principal dimensions of the skull of, 10.
 — —, scapulae of, 10.
 — —, skeleton of, 4.
 — —, skeleton of young of, 13, 14.
 — —, sternal ribs of, 8.
 — —, sternum of, 8.
 — —, systematic position of, 20.
 — —, teeth of young of, 13.
 — —, vertebrae of, 4.
 — —, vertebrae of young of, 14.
 — —, vertebral ribs of, 7.
 — *richardsonii*, 15, 18.
 — *rissoanus*, 6, 8, 10, 11, 15, 236, 247, 266, 274.
 — —, identity with *G. griseus*, 18.
Graucalus atriceps, 68.
 — *leucopygius*, 68.
 — *personatus*, 68.
Graucalus temminckii, 68, 113, 118.
 Grey-headed Gallinule, 92.
 Grind Whale, 237.
Gujnia annulata, 308, 335, 337, 340, 343.
 Haast, Julius. Preliminary notice of a Ziphioid Whale, probably *Berardius arnuxii*, stranded on the 16th of December, 1868, on the Sea-beach, near New Brighton, Canterbury, New Zealand, 214.
Haleyon chloris, 44.
 — *coromanda*, 44.
 — *diops*, 106.
 — *funebri*, 106.
Haliastur leucosternus, 35.
Halicornaria ramulifera, 471, 477, 481.
Haplophyllia paradoxa, 335.
Hemichelidon griseosticta, 66.
Hemicyathus crassicostratus, 336.
Hemiphaga forsteni, 84.
Herodias alba, 99.
 — *egretta*, 99.
 — *garzetta*, 99.
 — *nigripes*, 99.
Heterodon densirostris, 209.
 — *sowerbensis*, 209.
Hierococcyx crassirostris, 116, 118.
Himantopus intermedius, 91.
 — *leucocephalus*, 91.
Hirundinapus giganteus, 46.
Hirundo brevirostris, 46.
 — *esculenta*, 46.
 — *francica*, 46.
 — *gutturalis*, 65.
 — *javanica*, 66.
 — *panayana*, 65.
 — *rustica*, 65.
 — *unicolor*, 46.
 — *vanicorensis*, 46.
Hydralector gallinaceus, 92.
Hydrallmania falcata, 469, 470.
Hydrochelidon delalandii, 103.
 — *fluviatilis*, 103.
 — *leucoparcia*, 103.
 — *nigra*, 103.
Hydroïda. Report on the, collected during the Expeditions of H.M.S. 'Porcupine,' by G. J. Allman, 469.
Hylomys. On the osteology and dentition of, by John Anderson, 453.

- Hylomys peguensis*, anapophyses of, 462.
 ———, carpus of, 465.
 ———, chevron bones of, 463.
 ———, clavicle of, 464.
 ———, colouring of, 455.
 ———, ears of, 454.
 ———, eye of, 454.
 ———, femur of, 465.
 ———, general form of, 454, 455.
 ———, hypapophyses of, 463.
 ———, hyperapophyses of, 462.
 ———, humerus of, 465.
 ———, innominate bone of, 465.
 ———, limbs of, 454, 455.
 ———, measurements of, 455.
 ———, measurements of the skull of, 461, 462.
 ———, metapophysial processes of, 462.
 ———, præsternum and mesosternum of, 464.
 ———, radius and ulna of, 465.
 ———, scapula of, 463, 464.
 ———, skeleton of, 462–467; measurements of, 466.
 ———, skull of, 455–462.
 ———, snout of, 454.
 ———, spinous processes of, 462.
 ———, tail of, 455.
 ———, teeth of, 459.
 ———, tibia and fibula of, 465.
 ———, transverse processes of, 462.
 ——— *suillus*, 453.
Hyloterpe sulfuriventera, 117.
Hyperoodon gervaisii, 206, 207.
 ——— *rostratus*, 203, 209, 234.
 ——— *semijunctus*, 206.
Hypotaenidia celebensis, 95.
 ——— *philippensis*, 95.
 ——— *striata*, 95.
Hypothymis manadensis, 66.
 ——— *puella*, 66, 107.
Hypotrionchis severus, 33.
Ibis falcinellus, 101.
Inocotis papillosa, 101.
Iotreron melanocephala, 30, 83.
 Javan Hawk, 37.
Kogia, 223.
Lafœa dumosa, 470, 471.
 ——— *fruticosa*, 470, 472.
 ——— *halecioides*, 471, 472, 477, 480.
Lafœidæ, 472.
Lagenorhynchus albifrons, 273.
 ——— *albirostris*, 236, 247, 250, 275, 280, 281, 296, 300.
Lalage aurea, 70, 107.
 ——— *dominica*, 69.
 ——— *leucopygialis*, 69, 108.
 ——— *melanoleuca*, 69.
Lamprotornis cantor, 79.
 ——— *columbianus*, 80.
 ——— *metallica*, 80.
 ——— *minor*, 80, 81.
 ——— *obscura*, 80.
 ——— *pyrrhopogon*, 78.
Lamproteron formosa, 82.
Lanius dominicanus, 67.
 ——— *dubius*, 81.
 ——— *leucogaster*, 67.
 ——— *leucorhynchus*, 67.
 ——— *manillensis*, 67.
 ——— *pacificus*, 80.
 ——— *silens*, 69.
Lasiorhinus m'coyi, 345.
Leptopteryx leucorhynchus, 67.
Leucotreron gularis, 83.
Limnaëtus lanceolatus, 34, 110, 111.
Limosa uropygialis, 97.
Lobipes hyperboreus, 97.
Lophohelia affinis, 308, 331.
 ——— *anthophyllites*, 307, 331.
 ——— *defrancei*, 308, 331.
 ——— *gracilis*, 305, 308, 332, 339, 341.
 ——— *latistella*, 332.
 ——— *prolifera*, 305, 307, 328, 331, 332, 337–342.
 ——— *stoppaniana*, 308, 331.
 ——— *striata*, 332.
 ——— *subcostata*, 307, 331.
Lophospiza griseiceps, 33.
Lophotes reinwardtii, 36.
Loriculus amabilis, 26.
 ——— *exilis*, 32.
 ——— *flosculus*, 27.
 ——— *pusillus*, 27.
 ——— *quadricolor*, 109.
 ——— *sclateri*, 32.
 ——— *stigmatus*, 26, 32.
Lyncornis cerviniceps, 112.
 ——— *macropterus*, 47, 112.
 ——— *macrotis*, 112.
 ——— *temmincki*, 112.

- Macropteryx klecho*, 45.
 — *leucophaea*, 46.
 — *wallacii*, 45.
Macropus rufus, 483.
Macropygia albicapilla, 85.
 — *leptogrammica*, 85, 107.
 — *macassariensis*, 85.
Madrepora oculata, 323.
 — *ramea*, 324.
Madreporaria. A description of the, dredged up during the Expeditions of H.M.S. 'Porcupine' in 1869 and 1870, by P. Martin Duncan, 303.
 —, classification of the species of, 306, 308.
 —, distribution of the species, in the recent and past faunas, of, 337.
 —, tables of the localities, &c. of, 338.
Madreporidæ, 308, 333.
 Manatee (*Manatus americanus*), on the form and structure of, by J. Murie, 127.
Manatus americanus, additional note on, 191-193.
 — —, admeasurements of, 128-130.
 — —, air-passages of, 178, 179.
 — —, alimentary canal of, 169.
 — —, blood-vessels and lymphatic glands of, 175-178.
 — —, cranium and dentition of, 140-143.
 — —, digestive tract of, 164-175.
 — —, exterior aspects and dimensions of, 127-131.
 — —, fatty envelope of, 134, 135.
 — —, general contour of, 127, 128.
 — —, glands concerned in digestion of, 172-175.
 — —, hair and bristles of, 133, 134.
 — —, heart of, 175.
 — —, hyoid and the surrounding pharyngo-glossal fleshy parts of, 179, 180.
 — —, integument, its appendages and sub-jacent textures, of, 131-135.
 — —, interior of the mouth, and tongue of, 164-169.
 — —, limbs, pelvis, and ligaments of, 139, 140.
 — —, muscles of the accessory skeleton of, 156-163.
 — —, muscles of the axial skeleton of, 143-156.
Manatus americanus, muscles connecting the spinal column of: dorsal aspect, 143-145; ventral aspect, 145-148.
 — —, muscles of the costal arches of: thoracic, 151-153; abdominal, 153-156.
 — —, muscles of the dermis of, 163, 164.
 — —, muscles of the hip-girdle of: pelvic and generative, 161-163.
 — —, muscles of the pectoral limb of: dorsal, 158, 159; ventral of, 159-161.
 — —, muscles of the shoulder-girdle of, 156-158.
 — —, muscles of the skull or cephalic segment of: facial or supracranial, 148-151.
 — —, muscular system of, 143-164.
 — —, nervous system of, 180-186.
 — —, nose and nasal passages of, 186, 187.
 — —, ocular and auditory apparatus of, 187, 188.
 — —, organs of circulation of, 175-178.
 — —, parts related to generation (in the female and male) of, 188, 189.
 — —, rank and relations of, 189-191.
 — —, sensory organs of, 186-188.
 — —, skeleton and its ligamentous connexions of, 135-143.
 — —, skin of, 131-133.
 — —, spinal axis of, 135-138.
 — —, spinal ligaments of, 138, 139.
 — —, vocal and respiratory apparatus of, 178-180.
Marca gibberifrons, 102.
 — *punctata*, 102.
Marsupialia, on the osteology of the (Part III.). Modification of the skeleton in the species of *Phascolumys*, by Prof. Owen, 345.
 —, on the osteology of the (Part IV.). Bones of the trunk and limbs of *Phascolumys*, by Prof. Owen, 483.
Megacephalon malco, 87, 88.
 — *rubripes*, 87, 88.
 — *rufipes*, 87.
Megapodius gilberti, 87.
 — *rubripes*, 87.
Melanopeltargus episcopus, 101.
Melanopitta forsteni, 62.
Melias diardi, 53.
Melittophagus minutus, 111.

- Meropogon bullockoides*, 111.
 — *forsteni*, 42, 111, 112.
Merops daudini, 42.
 — *ornatus*, 42.
 — *philippinus*, 42, 112.
 — *viridis*, 42.
Merula solitaria philippensis, 63.
Mesodiodon, 209.
 — *densirostris*, 211.
 — *seychellensis*, 211.
Mesoplodon, 208-212.
 — *densirostris*, 224.
 — *sowerbyensis*, 210.
 — *sowerbyi*, 223, 224, 229, 231.
Micropteron bidens, 210.
Micropterus, 209.
Milvus affinis, 36.
 Mivart, St. George. On the axial skeleton of the Ostrich (*Struthio camelus*), 385.
Monachalcyon monachus, 43.
 — *princeps*, 43.
Monodon monoceros, 278.
Monticola solitaria, 63.
Motacilla flavescens, 65.
Mulleripicus fulvus, 41.
 — *pulverulentus*, 41.
Munia brunneiceps, 73, 108.
 — *molucca*, 73.
 — *nisoria*, 73.
 — *pallida*, 107.
 — *punctularia*, 73.
 — *rubro-nigra*, 73, 74.
 Murie, J. On the form and structure of the Manatee (*Manatus americanus*), 127.
 —. On the organization of the Caaing Whale, *Globiocephalus melas*, 235.
 —. Researches upon the anatomy of the Pinnipedia. Part III. Descriptive anatomy of the Sea-Lion (*Otaria jubata*), 501.
Muscicapa cantatrix, 117.
 — *panayensis*, 79.
 — *rufigastra*, 117.
Myiagra azurea, 66.
 — *rubeculoides*, 66.
Myiastes cinereocapilla, 66.
 — *helianthea*, 66, 107.
Myristicivora bicolor, 84.
 — *luctuosa*, 84.
Myristicivora spilorrhoea, 84.
Myzomela chloroptera, 117.
Nectarinia aspasia, 71.
Nectarophila grayi, 71.
Neopus malayensis, 34.
Neoziphius, 209.
Ninox affinis, 41.
 — *japonicus*, 40.
 — *madagascariensis*, 41.
 — *nipalensis*, 40.
 — *philippensis*, 38, 41.
Nisus cruentus, 34.
 — *trinotatus*, 33.
 — *virgatus rhodogaster*, 33.
Noctua hirsuta japonica, 40.
 — *philippensis*, 38.
Nodus, 209.
Notornis mantelli, 120.
 —, length of femur and sternum of, 119.
Numenius minor, 96.
 — *minutus*, 96.
 — *phaeopus*, 96.
 — *uropygialis*, 96.
 — *viridis*, 101.
Nycticorax caledonicus, 100, 114.
 — *griseus*, 100.
 — *manilensis*, 100.
Octopus, 214.
Oculinidæ, 308, 332.
Ocydromus australis, 120, 124-126.
 — —, length of sternum and femur of, 119.
Œlicnemus grillarius, 91.
 — *magnirostris*, 91.
Onychoprion anæsthetus, 104.
 — *melanauchen*, 104.
Orea gladiator, 20, 237.
Oriolus galbula, 60, 112.
 — *hippocrepis*, 60.
 — *horsfieldii*, 60.
 — *indicus*, 60.
 — *kundoo*, 113.
 — *sinensis*, 78.
Ortygometra cinerea, 94.
 — *quadristrigata*, 94.
Osmotreron bicincta, 114.
 — *griseicauda*, 82.
 — *vernans*, 81, 113.

- Ostrich (*Struthio camelus*), on the axial skeleton of, by St. George Mivart, 385.
 —, the (see *Struthio camelus*).
- Otaria jubata*, descriptive anatomy of, by J. Murie, 501.
 — —, alimentary canal of, 558.
 — —, alimentary glands &c. of, 563-567.
 — —, aorta of, 536.
 — —, arterial distribution of, 536-545.
 — —, arteries of the base of the brain of, 539.
 — —, arteries of the head and neck of, 536.
 — —, arteries of the pectoral limb of, 540.
 — —, arteries of the pelvic limb of, 544.
 — —, bones of the extremities of, 513-517.
 — —, brain of, 519-530; outward aspects and dimensions of, 519-521; cerebrum, 520; the cerebral lobes, 521; clefts and sulci of cerebrum, outer face, 522; convolutions of the outer face, 524; sulci and gyri of the inner face, 525; folds and furrows, left half of the cerebrum, 526; interior structures, 527; basal parts of cerebellum, 528; weight, 529.
 — —, carpus, metacarpus, and phalanges of, 514.
 — —, cartilages of the larynx of, 547.
 — —, cavities of larynx and trachea of, 551.
 — —, components of hyoid and larynx of, 546.
 — —, cranio-facial nerves of, 530.
 — —, deglutitive apparatus of, 557.
 — —, digestive system of, 553-567.
 — —, dura and pia mater of, 518.
 — —, faucial folds, tonsils, and oral glands of, 554.
 — —, femur and patella of, 516.
 — —, genital glands, scrotum, &c. of, 571.
 — —, glands in proximity to air-passages of, 552.
 — —, hepatic ducts, ligaments, and gall-bladder of, 564.
 — —, hind foot of, 516.
 — —, humerus of, 513.
 — —, hyolaryngeal and pulmonary systems of, 546-553.
 — —, intestines of, 562.
 — —, kidneys of, 567.
 — —, laryngeal membranes and ligaments of, 548.
 — —, lingual organs superficially considered of, 553.
 — —, liver of, 563.
- Otaria jubata*, lungs of, 552.
 — —, muscles of the genitals and anus of, 570.
 — —, muscles of the os hyoides and larynx of, 549.
 — —, muscles of the tongue and palate of, 555.
 — —, nerves of, 530-533.
 — —, nerves in fore limb of, 531.
 — —, nerves of the main branches of head and limbs of, 530.
 — —, nerves of loins and hind limb of, 532.
 — —, nervous system of, 517-534.
 — —, œsophagus of, 559.
 — —, organs of generation of, 569-573.
 — —, organs of vision of, 534; eyeball, 534; orbital muscles, 535.
 — —, parts and organs within the mouth of, 553-557.
 — —, pectoral limb of, 513-515.
 — —, pharynx and fleshy appurtenances of, 557.
 — —, pelvic limb of, 515-517.
 — —, pelvis of, 515.
 — —, relative positions of the abdominal viscera of, 558.
 — —, remarks on the extraction of the brain and membranes of, 517.
 — —, renal viscera of, 567.
 — —, ribs of, 510-513.
 — —, scapula of, 513.
 — —, sensory apparatus of, 534.
 — —, skeleton and cranial changes of, 501-517.
 — —, skull of, general aspects, 501; cranial bones, 502; the mandible, 503; foramina of lower base, 504; interior, 505; sexual differences, 506; progressive cranial changes, 507.
 — —, spinal column and thorax of, 509-513.
 — —, spleen, mesenteric glands, and pancreas of, 566.
 — —, sternum of, 512.
 — —, stomach and omenta of, 560.
 — —, teeth and palate of, 553.
 — —, tibia and fibula of, 516.
 — —, ulna and radius of, 514.
 — —, ureters and bladder of, 569.
 — —, urethra and penis of, 569.
 — —, urino-generative system of, 567-573.
 — —, venous blood-channels, 545.
 — —, vertebræ of, 509.
 — —, visceral arteries of, 542.

- Otaria jubata*, vocal passages, respiratory organs, and glands of, 551-553.
- Otus magicus*, 39.
- Owen, Professor. On *Dinornis* (Part XVII.): containing a description of the sternum and pelvis, with an attempted restoration, of *Aptornis defossor*, Ow., 119.
- . On *Dinornis* (Part XVIII.): containing a description of the pelvis and bones of the leg of *Dinornis gravis*, 361.
- . On *Dinornis* (Part XIX.): containing a description of a femur indicative of a new genus of large wingless bird (*Dromornis australis*, Owen) from a post-tertiary deposit in Queensland, Australia, 381.
- . On the osteology of the *Marsupialia* (Part III.). Modification of the skeleton in the species of *Phascolomys*, 345.
- . On the osteology of the *Marsupialia* (Part IV.). Bones of the trunk and limbs, *Phascolomys*, 483.
- Padda oryzivora*, 72.
- Palapteryx ingens*, 373, 374, 376, 377.
- Paracyathus agassizi*, 306, 319, 337, 339, 342.
- *confertus*, 320.
- *crassus*, 319.
- *striatus*, 306, 319, 337, 340, 342.
- Parra cristata*, 92, 93.
- *gallinacea*, 93.
- *indica*, 93.
- Pastor ruficollis*, 78.
- *seneæ*, 78.
- Pelargopsis melanorhyncha*, 45.
- Pelecanopus cristatus*, 105.
- *medius*, 104.
- Perforata*, 306, 333-335.
- Pernis celebensis*, 111.
- *crassirostris*, 36.
- *cristata*, 36.
- *ptilorhyncha*, 36, 111.
- Petaurus (Acrobates) pygmaeus*, 358.
- Petrorhynchus capensis*, 208.
- *mediterraneus*, 207, 209.
- Phalacrocorax melanoleucus*, 106.
- Phalangista gliriformis*, 358.
- Phalaropus australis*, 97.
- Phascolomys*. On the osteology of the *Marsupialia* (Part III.). Modifications of the skeleton in the species of, by Professor Owen, 345.
- Phascolomys*. On the Osteology of the *Marsupialia* (Part IV.). Bones of the trunk and limbs of, by Professor Owen, 483.
- , atlas of, 483, 484.
- , bones of the fore limbs of, 487.
- , bones of the hind limbs of, 494-497.
- , cranial characters of, 345-353.
- , dental characters of, 355-358.
- , femur of, 494.
- , fibula of, 494.
- , humerus of, 488.
- , ilium of, 486.
- , ilium and pubis of, 493.
- , mandibular characters of, 353-355.
- , neck of, 485.
- , pubis of, 493.
- , radius and ulna of, 490.
- , ribs of, 484, 485.
- , sacrum of, 486.
- , scapula of, 487.
- , tail of, 487.
- , tibia of, 494.
- , vertebræ of, 485-487.
- , vertebral column of, 483-487.
- *angasii*, 345.
- *lasiorhinus*, 345.
- *latifrons*, 345-360, 483-491, 494-500.
- *niger*, 345.
- *platyrhinus*, 345-360, 483-491, 494-500.
- *setosus*, 345.
- *vombatus*, 345-360, 483, 485-487.
- Philemon collaris*, 106.
- *inornatus*, 106.
- *moluccensis*, 106.
- Phlogœnas cruenta*, 29.
- *luzonica*, 29.
- *tristigmata*, 85.
- Phoca vitulina*, 522, 568.
- Phocœna communis*, 241, 255, 274, 278, 280, 561.
- *globiceps*, 235.
- *griseus*, 15.
- *risonnus*, 17.
- Phœnicophaës œneicaudus*, 52.
- *calorhynchus*, 52, 53.
- *curvirostris*, 52, 53.
- *erythrognathus*, 52, 53.
- *pyrrhocephalus*, 52, 53.
- Phyllodes laciniatum*, 322.

- Physalus antiquorum*, 266, 286, 298, 299.
Physeter, 208, 219, 220, 223.
 — *bidens*, 210.
 — *macrocephalus*, 272.
Pica albicollis, 75.
Picus fulvigaster, 41.
 — *horsfieldii*, 41.
 — *javensis*, 41.
 — *leucogaster*, 41.
 — *sanguineus*, 42.
 Piked Whale, 255.
 Pilot Whale (see *Globiocephalus melas*).
Pinnipedia, anatomy of, Part III. Descriptive anatomy of the Sea-lion (*Otaria jubata*), by J. Murie, 501.
Pipastes batchianensis, 117.
Pitta melanocephala, 62.
 — *mülleri*, 62.
Pictolophus buffoni, 30.
Pliobothrus symmetricus, 336, 338, 344.
Plotus melanogaster, 106.
 — *novæ-hollandiæ*, 106.
Plumularia catharina, 479.
 — *pennatula*, 477.
 — *pluma*, 476.
 — *setacea*, 476.
Plumulariæ, 475-480.
Podiceps gularis, 105.
 — *minor*, 105.
Polioætus humilis, 35.
Poliornis indicus, 37.
 — *liventer*, 37.
Polophilus lathamii, 59.
Polyphasia merulina, 54.
Pontoporia blainvillii, 235.
Porphyrio cinereus, 94, 95.
 — *indicus*, 92.
 — *neglectus*, 92.
 — *pulverulentus*, 92.
 — *samoënsis*, 92.
 — *smaragdinus*, 92.
Pratincola atrata, 63.
 — *caprata*, 63.
Prioniturus flavicans, 32.
 — *platurus*, 32.
 — *wallacei*, 32.
Prionochilus aureolinbatus, 72.
Psittacus cyanicollis, 107.
Psittacus setarius, 32.
 — *sumatranus*, 31.
Ptilinopus flavicollis, 107.
 — *hyogaster*, 107.
 — *melanocephalus*, 83.
 — *xanthogaster*, 107.
Pyrrhocentor celebensis, 55, 56.
 — *unirufus*, 55, 56.
Querquedula circea, 102.
 — *humeralis*, 102.
Rallina isabellina, 96.
 — *minahasa*, 95.
 — *rosenbergii*, 96.
Rallus aquaticus, 124.
 — *gularis*, 95.
 — *lewini*, 95.
 — *pectoralis*, 95.
 — *quadririgatus*, 95.
 — *superciliaris*, 94.
 — *torquatus*, 95.
Reinwardtæna reinwardti, 85, 107.
Rhinocærus sumatranus, 247.
Rhizotrochus affinis, 307, 323, 337, 339, 343.
 Risso's Dolphin, *Grampus griseus* (Cuv.), by W. H. Flower, 1.
 — — (see *Grampus griseus*).
Rugosa, 306, 335.
Sabinotrochus apertus, 306, 320, 339, 337, 341.
Saiga tartarica, 246.
Sauropatis chloris, 44.
 — *forsteni*, 44.
 — *sancta*, 44.
Scissirostrum dubium, 81.
 — *pagei*, 81.
Scops madagascariensis, 40.
 — *mantis*, 106.
 — *rutilus*, 40.
Scythrops novæ-hollandiæ, 51.
 Sea-Lion (*Otaria jubata*), descriptive anatomy of the, by J. Murie, 501.
 —, the (see *Otaria jubata*).
Sertularella gayi, 469-471, 474, 480.
 — *polyzonias*, 469-471, 474.
 — *robusta*, 471.
Sertularia abietina, 470.
Sertulariæ, 474.
Solenosmilia variabilis, 307, 321, 328, 337, 339, 341, 342.

- Sphenotrochus intermedius*, 305, 306, 320, 337, 341.
 — *milletanus*, 320.
 — *milletianus*, 305.
Spilornis rufipectus, 35.
Spizaetus cirratus, 34.
 — *cirratus*, 35.
 — *crisatellus*, 35.
Sterna affinis, 104.
 — *bengalensis*, 104.
 — *bergii*, 105.
 — *delamotta*, 103.
 — *grisea*, 103.
 — *hybrida*, 103.
 — *panaya*, 104.
 — *panayensis*, 104.
 — *pelecanoides*, 105.
 — *ressa*, 105.
 — *similis*, 103.
 — *sumatrana*, 104.
 — *velox*, 105.
Sternula minuta, 118.
Strepsilas interpres, 91.
Streptocitta albicollis, 75.
 — *caledonica*, 75-77.
 — *torquata*, 76, 77.
Strix hirsuta, 40.
 — *rosenbergi*, 41.
 — *scutulata*, 41.
Struthio camelus. On the axial skeleton of the Ostrich, by St. George Mivart, 385.
 — —, atlas of, 387-390.
 — —, axis of, 390-394.
 — —, catapophyses of, 451.
 — —, caudal vertebræ of, 387, 428-430.
 — —, centra of, 448.
 — —, cervical vertebræ of, 385, 387.
 — —, cervico-dorsal vertebræ of, 385, 386, 407-413.
 — —, coccygeal vertebræ of, 386.
 — —, diapophyses of, 450.
 — —, dorsal vertebræ of, 385, 386, 413-419.
 — —, dorso-lumbar vertebræ of, 385.
 — —, dorsal aspect of lumbar and sacral vertebræ of an immature specimen of, 425.
 — —, hypapophyses of, 451.
 — —, hyperapophyses of, 450.
 — —, ilium of, 436.
Struthio camelus, ischium of, 437.
 — —, lateral aspect of lumbar and sacral vertebræ of an immature specimen of, 422.
 — —, lateral aspect of the vertebræ from the fortieth to the forty-sixth inclusive, in an immature condition of, 427.
 — —, lumbar sacro-caudal vertebræ of, 420.
 — —, lumbar vertebræ of, 387, 421-424.
 — —, metapophyses of, 450.
 — —, neural laminæ of, 449.
 — —, neural spines of, 449.
 — —, parapophyses of, 451.
 — —, paraxial parts of, 450, 451.
 — —, pelvis of, 431-438.
 — —, pelvis of, dorsal aspect, 434.
 — —, pelvis of, lateral aspect, 433.
 — —, pelvis of, lateral aspect of acetabular region of an immature, 437.
 — —, pelvis of, preaxial aspect, 431.
 — —, pelvis of, ventral aspect, 435.
 — —, pleurapophyses of, 451.
 — —, postzygapophyses of, 450.
 — —, presacral part of axial skeleton of, 386.
 — —, presacral vertebræ of, 387-407.
 — —, prezygapophyses of, 449.
 — —, pubis of, 437.
 — —, ribs of, 438-447.
 — —, sacral vertebræ of, 387, 424-426.
 — —, sacro-caudal vertebræ of, 387, 426, 427.
 — —, ventral aspect of lumbar and sacral vertebræ of an immature specimen of, 423.
 — —, vertebræ of, 385-431.
 — —, vertebral parts and processes of, 448-450.
Sturnia albofrontata, 78.
 — *pyrrhogenys*, 78.
Sturnus dauricus, 78.
Stylaster gemmascens, 308, 332, 337, 338, 344.
Sula fiber, 106
Sylvia cysticola, 64.
Tachyspiza soloënsis, 34, 110.
Tantalus castaneus, 101.
 — *falcinellus*, 101.
Tanygnathus albirostris, 31.
 — *mülleri*, 31.
Tanysiptera riedelii, 45, 112.
 Tapir, 246, 247.
Temenuchus dominicanus, 78.

- Teraspiza rhodogastra*, 33, 109, 118.
Tetrao ferrugineus, 87.
 — *perlatus*, 87.
Thalasseus poliocercus, 105.
 — *torresi*, 104.
Thecopsammia socialis, 308, 333.
Thuiaria articulata, 469, 470.
 — *hippuris*, 471, 473, 477, 480.
 — *laxa*, 471-473, 477, 480.
 — *salicornia*, 471, 473, 480.
 — *thuia*, 473.
Thuiaridæ, 472.
Tinnunculus moluccensis, 33.
Todiramphus funebris, 44.
Toria nasica, 82.
 — *nipalensis*, 82.
Totanus calidris, 97.
 — *glottis*, 96.
Treron pulverulenta, 82.
 — *vernans*, 82.
 — *viridis*, 82.
Tribonyx ventralis, 120, 125.
 — —, length of sternum and femur of, 119.
Trichoglossus ornatus, 32.
 — *meyeri*, 32, 107.
Trichostoma bicolor, 62.
 — *celebense*, 62, 113.
Tringa damacensis, 97.
 — *minuta*, 97.
 — *subminuta*, 97.
Turacæna menadensis, 85.
Turbinoliidæ, 306, 307, 309-327.
Turdus avensis, 61.
 — *cantor*, 79.
 — *chalybeus*, 79.
 — *columbinus*, 79.
 — *dominicus*, 69.
 — *eremita*, 63.
 — *insidiator*, 79.
 — *manilla*, 63.
 — *manillensis*, 63.
 — *mauritanus*, 80.
Turdus orientalis, 69.
 — *palmarum*, 80.
 — *philippensis*, 63.
 — *strigatus*, 79.
 — *terat*, 69.
Turnix rufilatus, 87.
Turtur chinensis, 85.
 — *tigrina*, 85.
Typhon robusta, 98.
Ulocyathus arcticus, 307, 322.
Urospiza torquata, 106.
Venilia albertula, 42.
Viralva indica, 103.
Volvocivora melaschistos, 69.
 — *morio*, 69, 108.
 Walden, Arthur, Viscount. A list of birds known to inhabit the Island of Celebes, 23.
 —. Appendix to a list of birds known to inhabit the Island of Celebes, 109.
 Weka, 119, 120.
 Wombat (see *Phascolomys*).
 —, bare-nosed, 346, 350, 351.
Fungipicus kisuki, 42, 111.
 — *temminckii*, 41, 111.
Zapornica nigrolincata, 94.
 Ziphioid Whales, on the recent, with a description of the skeleton of *Berardius arnouxi*, by W. H. Flower, 203.
 — —, dimensions of a large, stranded in Worcester's Bay, 215, 216.
Ziphiorrhynchus cryptodon, 208.
Ziphius australis, 224.
 — *cavirostris*, 206-208, 224.
 — *gervaisii*, 207.
 — *indicus*, 208.
 — *layardii*, 211.
 — *sowerbyi*, 210.
Zonænas radiata, 84.
Zosterops atrifrons, 72, 108.
 — *intermedia*, 72, 108.
 — *nigrifrons*, 72.

END OF VOLUME VIII.

TRANSACTIONS
OF
THE ZOOLOGICAL SOCIETY
OF LONDON.

VOLUME VIII.

LONDON:
PRINTED FOR THE SOCIETY:
SOLD AT THEIR HOUSE IN HANOVER-SQUARE:
AND BY MESSRS. LONGMANS, GREEN, READER, AND DYER, PATERNOSTER-ROW.

1874.

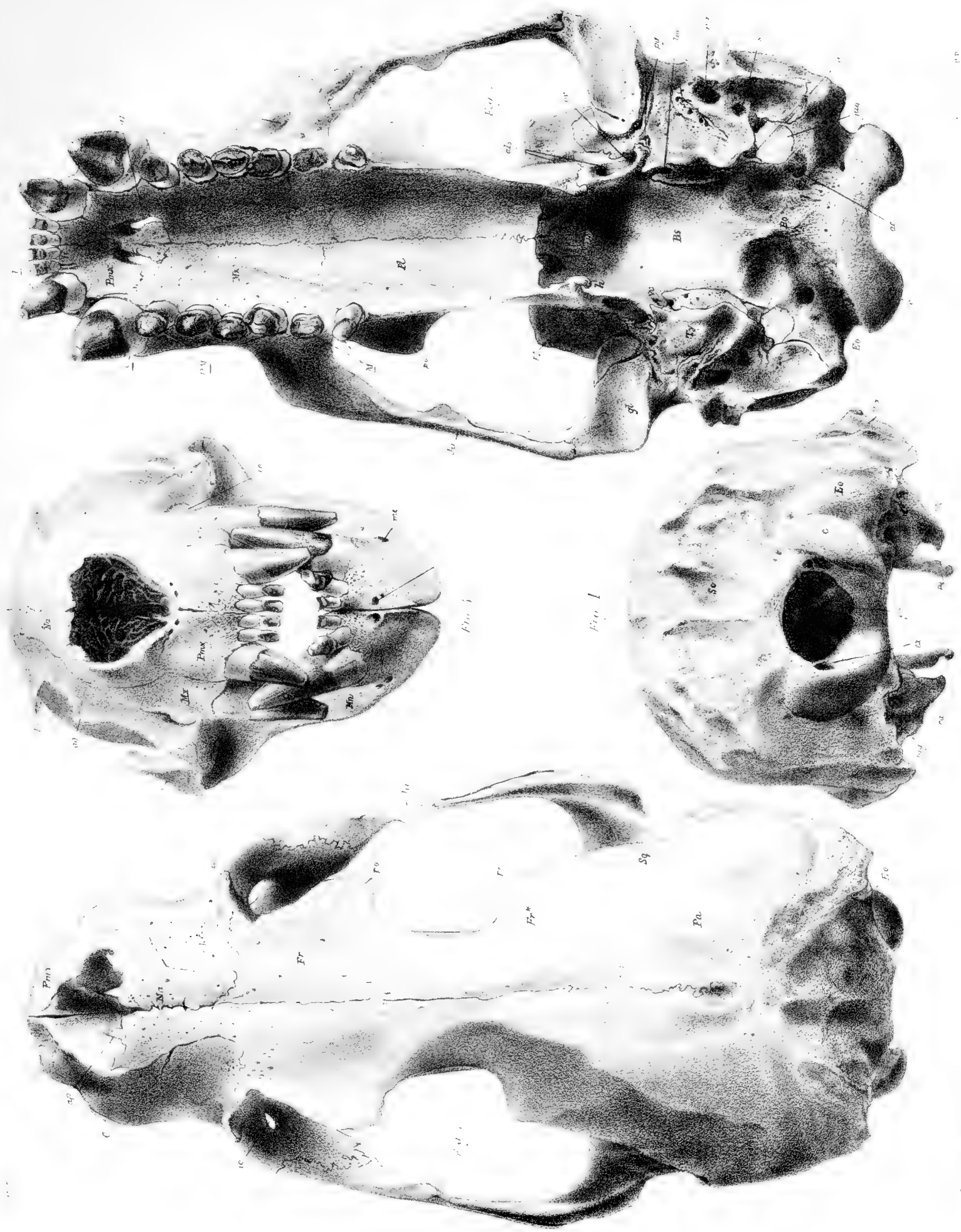
PRINTED BY TAYLOR AND FRANCIS,
RED LION COURT, FLEET STREET.

C O N T E N T S.


- I. *On Risso's Dolphin, Grampus griseus (Cuv.).* By WILLIAM HENRY FLOWER, *F.R.S., F.R.C.S., V.P.Z.S., Hunterian Professor of Comparative Anatomy and Conservator of the Museum of the Royal College of Surgeons of England* page 1
- II. *A List of the Birds known to inhabit the Island of Celebes.* By ARTHUR, Viscount WALDEN, *F.R.S., President of the Society* 23
- III. *Appendix to a List of Birds known to inhabit the Island of Celebes.* By ARTHUR, Viscount WALDEN, *F.R.S., President of the Society* 109
- IV. *On DINORNIS (Part XVII.): containing a Description of the Sternum and Pelvis, with an attempted Restoration, of Aptornis defossor, Ow.* By Professor OWEN, *F.R.S., F.L.S., &c.* 119
- V. *On the Form and Structure of the Manatee (Manatus americanus).* By Dr. JAMES MURIE, *F.L.S., F.G.S., &c., late Prosector to the Zoological Society* . . . 127
- VI. *On the Recent Ziphioid Whales, with a Description of the Skeleton of Berardius arnouxii.* By WILLIAM HENRY FLOWER, *F.R.S., V.P.Z.S., Hunterian Professor of Comparative Anatomy, and Conservator of the Museum of the Royal College of Surgeons of England* 203
- VII. *On the Organization of the Caaing Whale, Globiocephalus melas.* By Dr. JAMES MURIE, *F.L.S., F.G.S., &c.* 235
- VIII. *A Description of the Madreporaria dredged up during the Expeditions of H.M.S. 'Porcupine' in 1869 and 1870.* By Professor P. MARTIN DUNCAN, *M.B. (Lond.), F.R.S., F.G.S., Professor of Geology to King's College, London, &c.* . . . 303
- IX. *On the Osteology of the Marsupialia. (Part III.) Modifications of the Skeleton in the Species of Phascalomys.* By Professor OWEN, *F.R.S., F.Z.S., &c.* . . . 345
- X. *On DINORNIS (Part XVIII.): containing a Description of the Pelvis and Bones of the Leg of Dinornis gravis.* By Professor OWEN, *F.R.S., F.Z.S., &c.* . . . 361

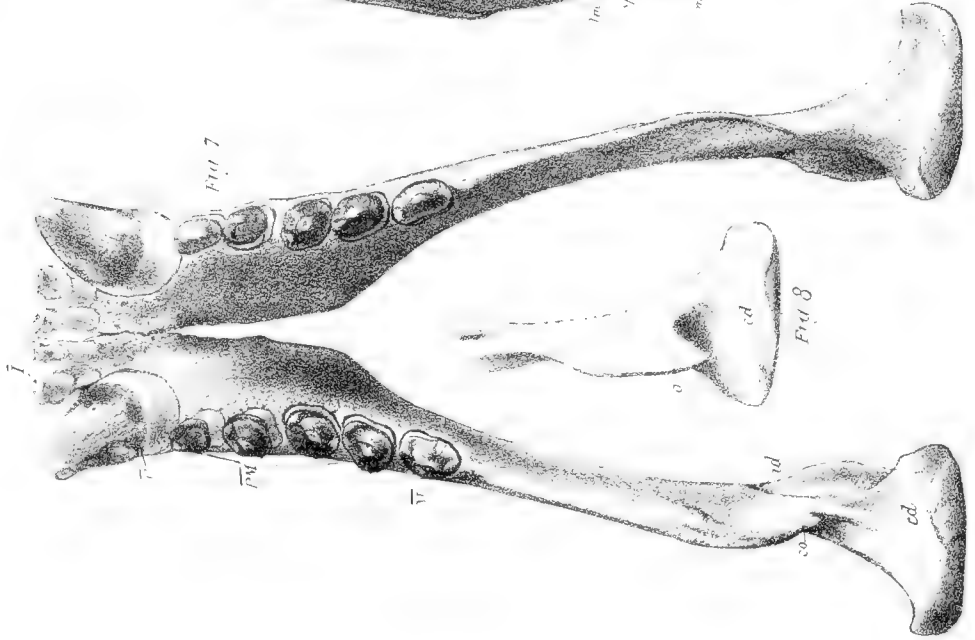
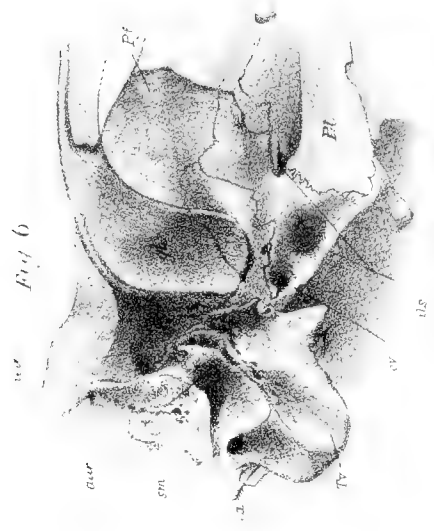
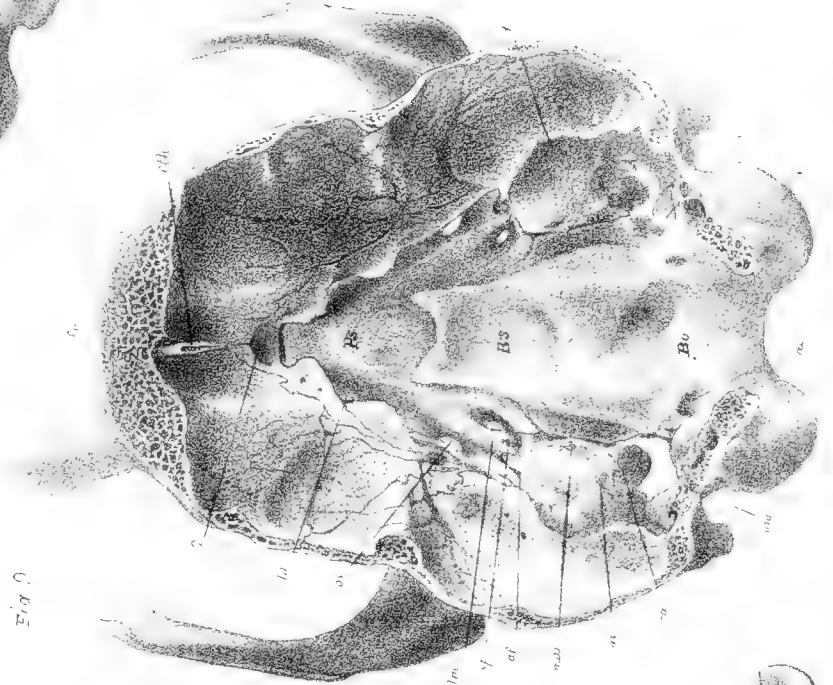
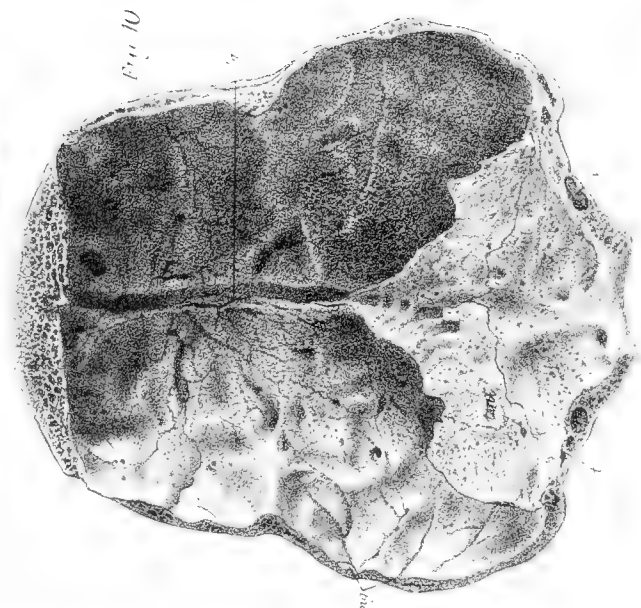
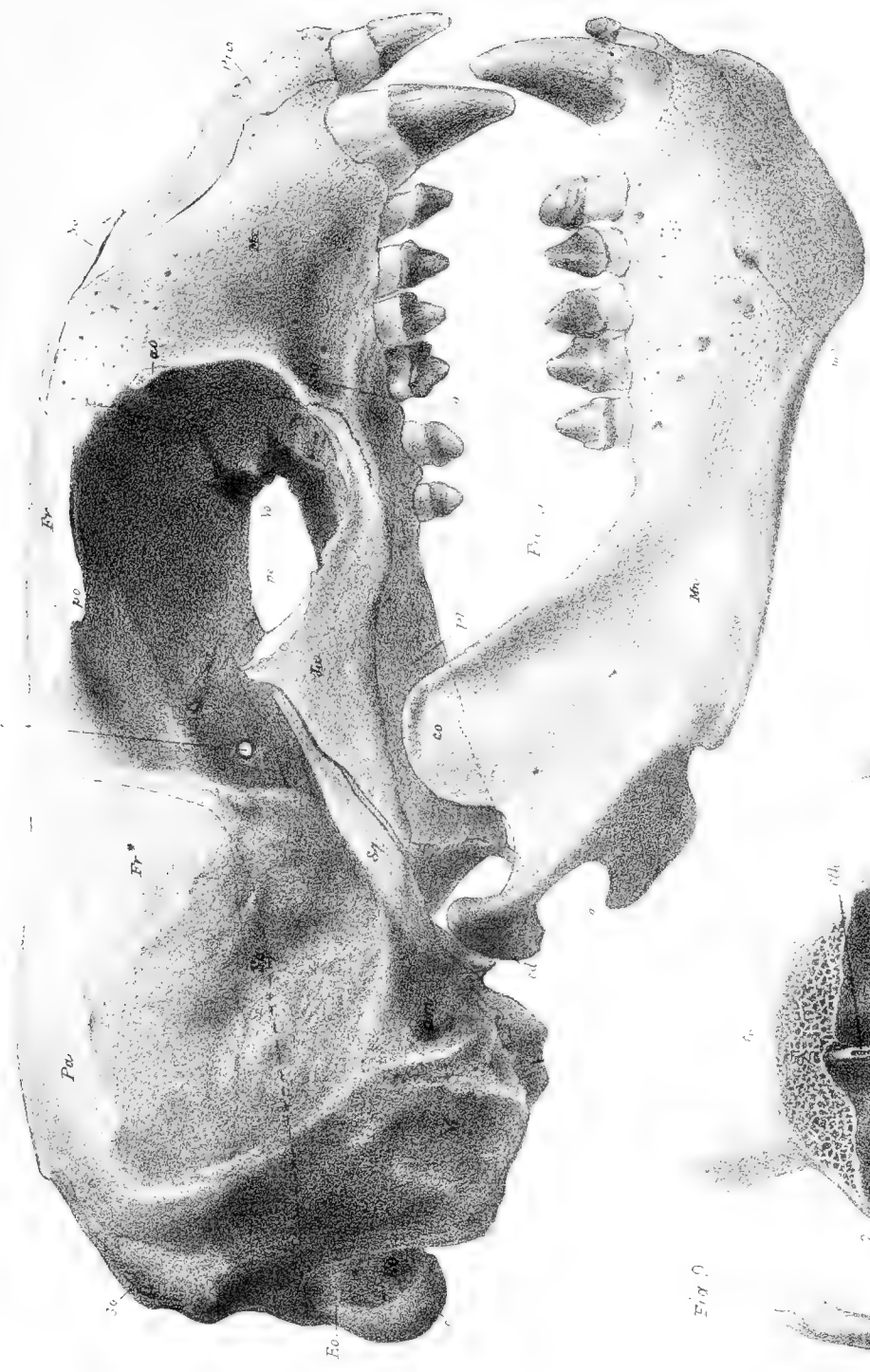- XI. *On DINORNIS (Part XIX.): containing a Description of a Femur indicative of a new Genus of large Wingless Bird (Dromornis australis, Owen) from a post-tertiary deposit in Queensland, Australia.* By PROFESSOR OWEN, F.R.S., F.L.S., &c. . 381
- XII. *On the Axial Skeleton of the Ostrich (Struthio camelus).* By ST. GEORGE MIVART, F.R.S. 385
- XIII. *On the Osteology and Dentition of Hylomys.* By JOHN ANDERSON, M.D., Curator of the Indian Museum, and Professor of Comparative Anatomy in the Medical College, Calcutta 453
- XIV. *Report on the Hydroida collected during the Expeditions of H.M.S. 'Porcupine.'* By PROFESSOR G. J. ALLMAN, F.R.S. 469
- XV. *On the Osteology of the Marsupialia. (Part IV.) Bones of the Trunk and Limbs, Phascalomys.* By PROFESSOR OWEN, C.B., F.R.S., F.Z.S. 483
- XVI. *Researches upon the Anatomy of the Pinnipedia.—Part III. Descriptive Anatomy of the Sea-lion (Otaria jubata).* By Dr. JAMES MURIE, F.L.S., F.G.S., &c., late Prosector to the Society 501


1894



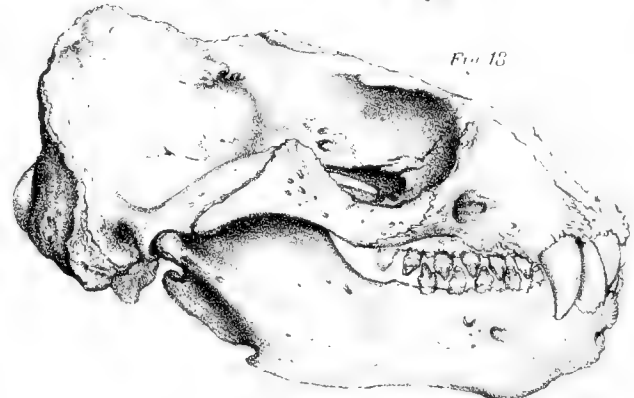
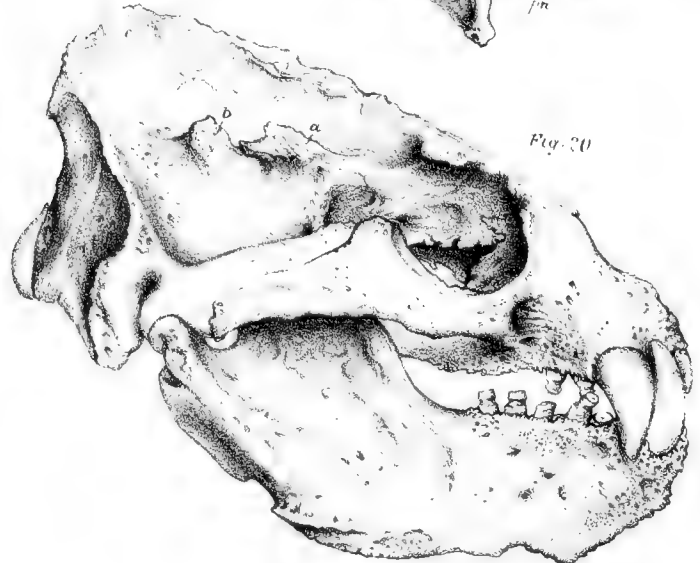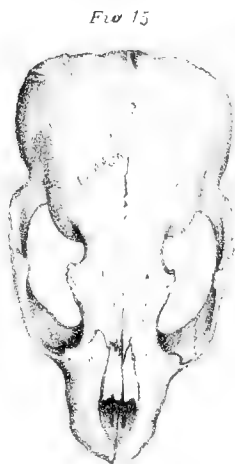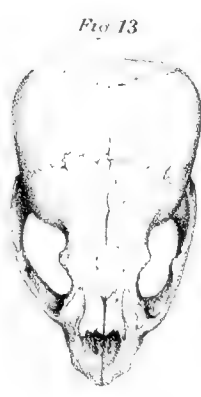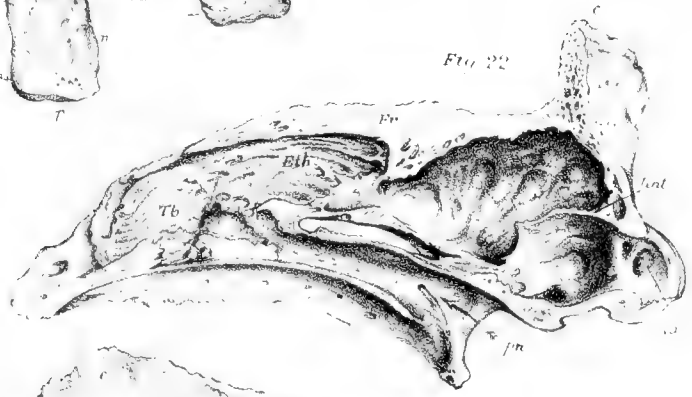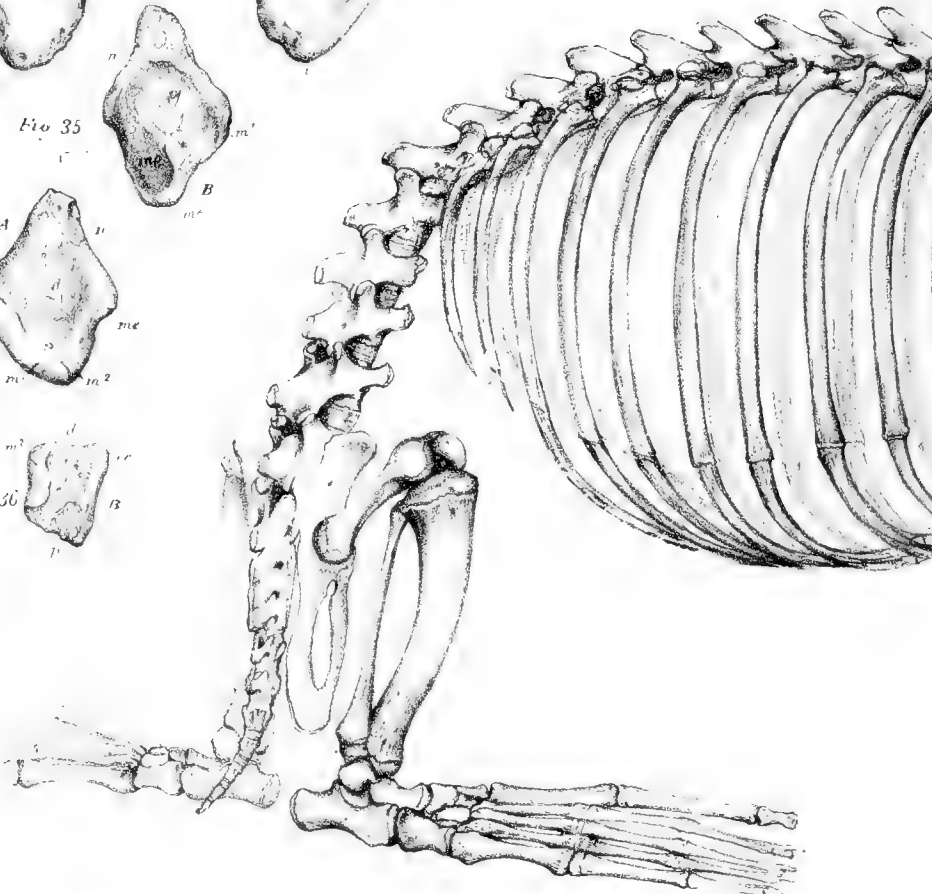
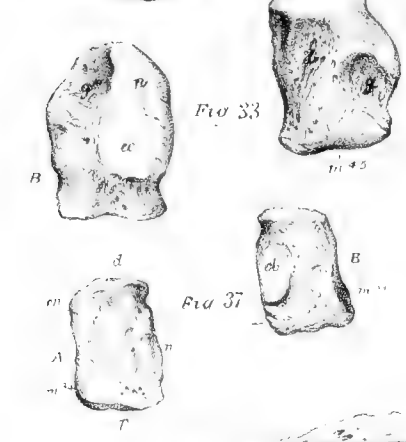
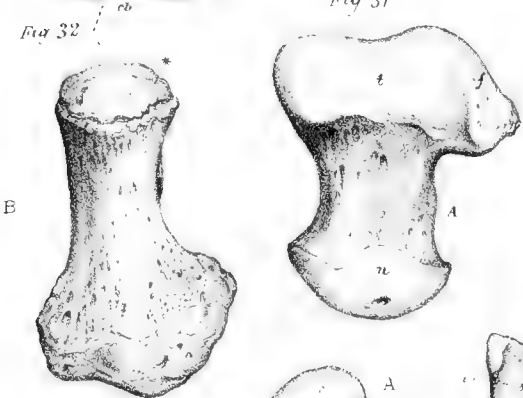
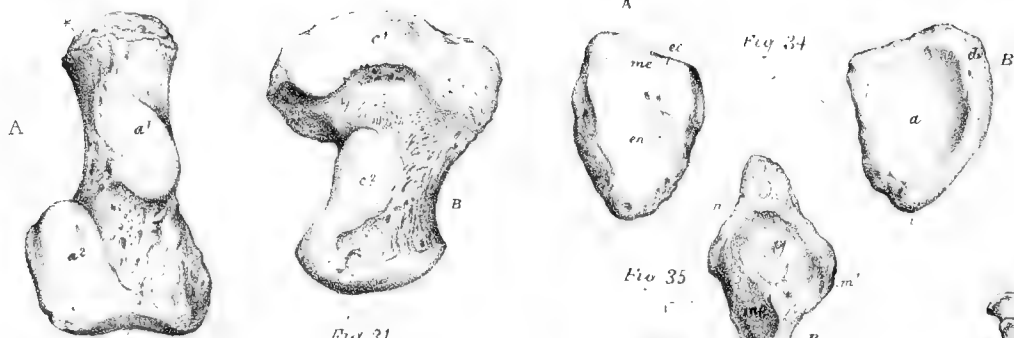
SKULL OF *Myotis* (Plate 1, 1894)

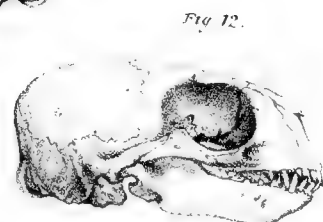
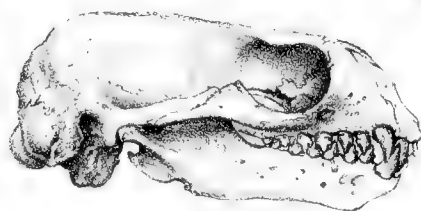
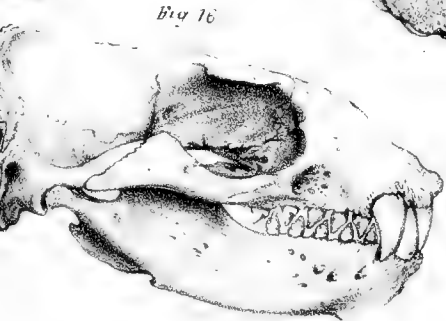
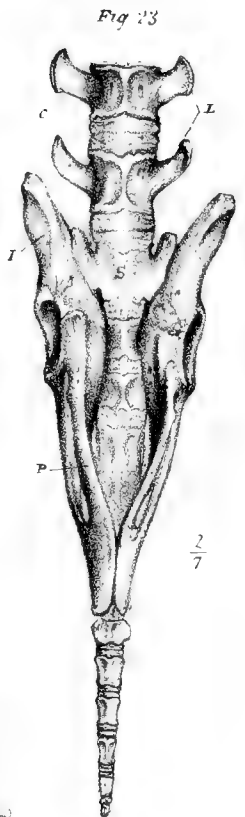
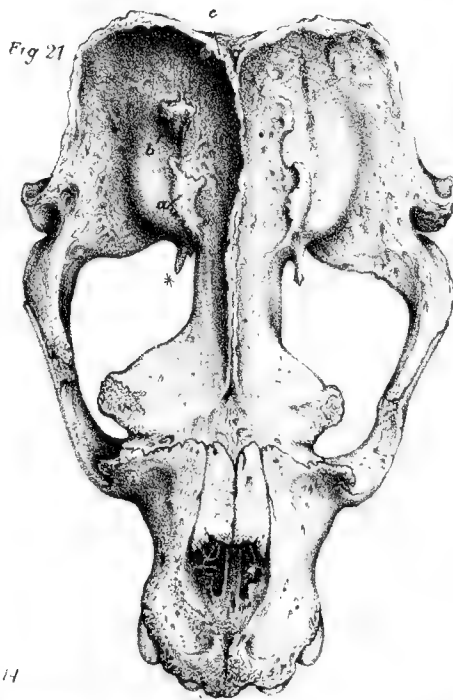
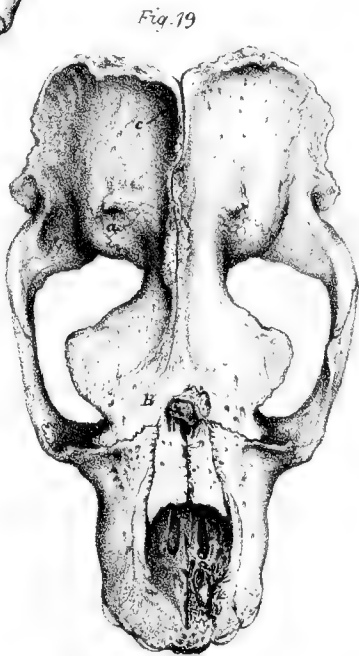
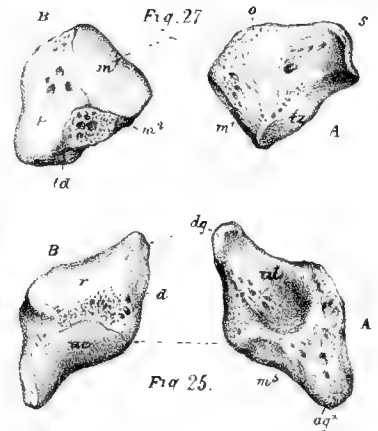
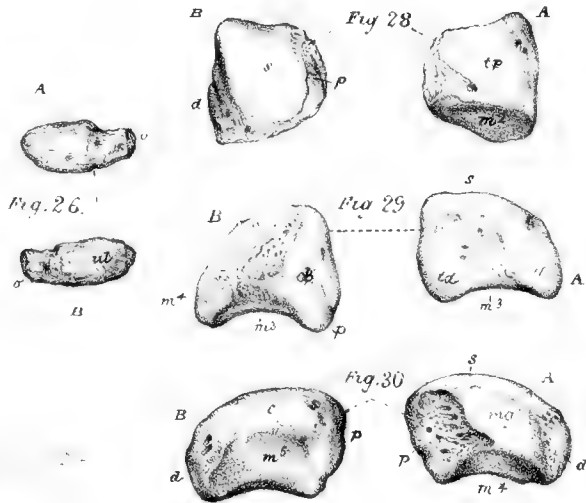
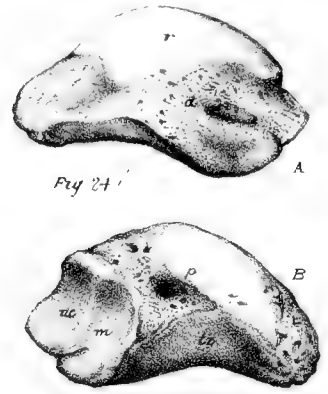
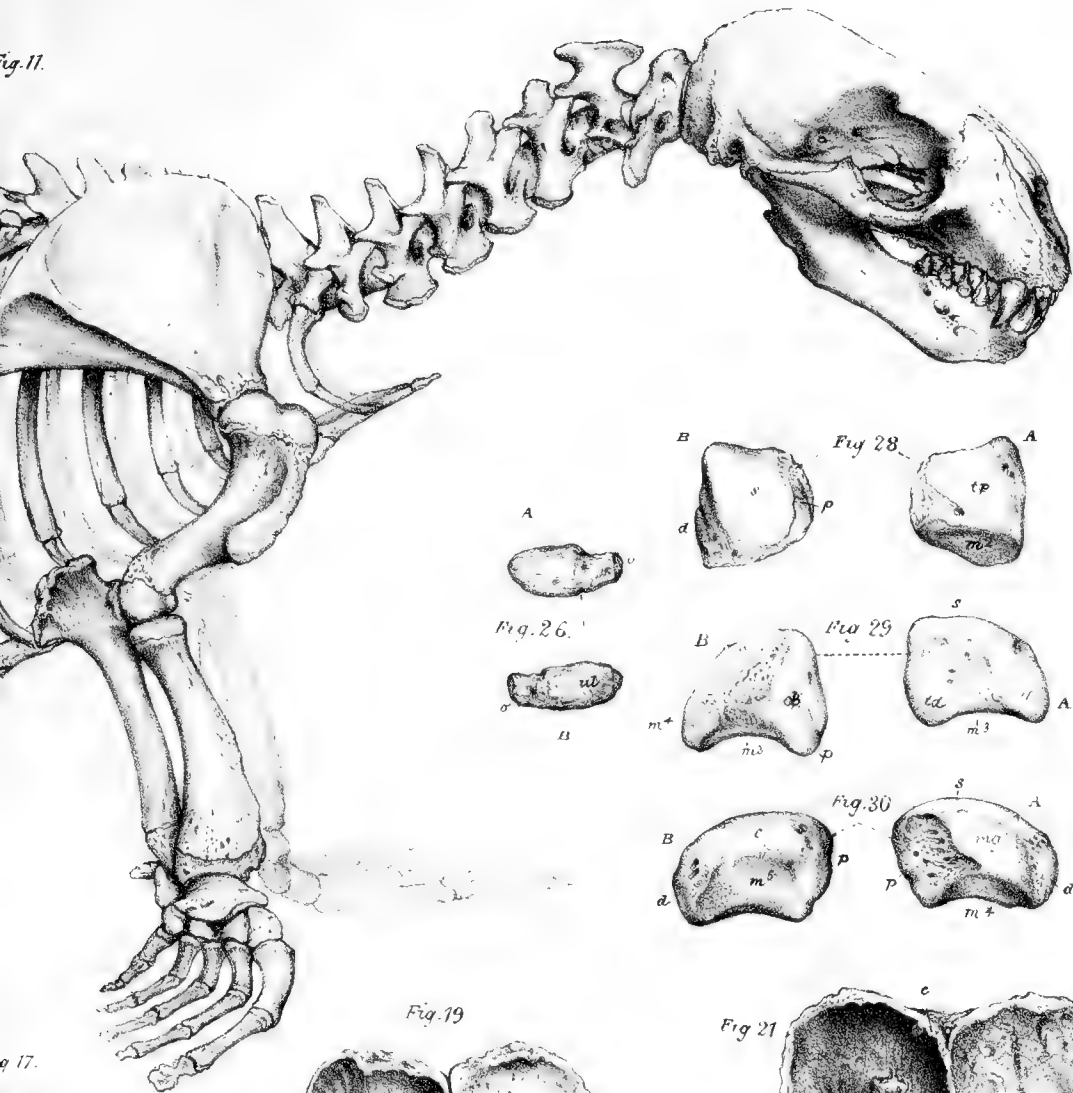





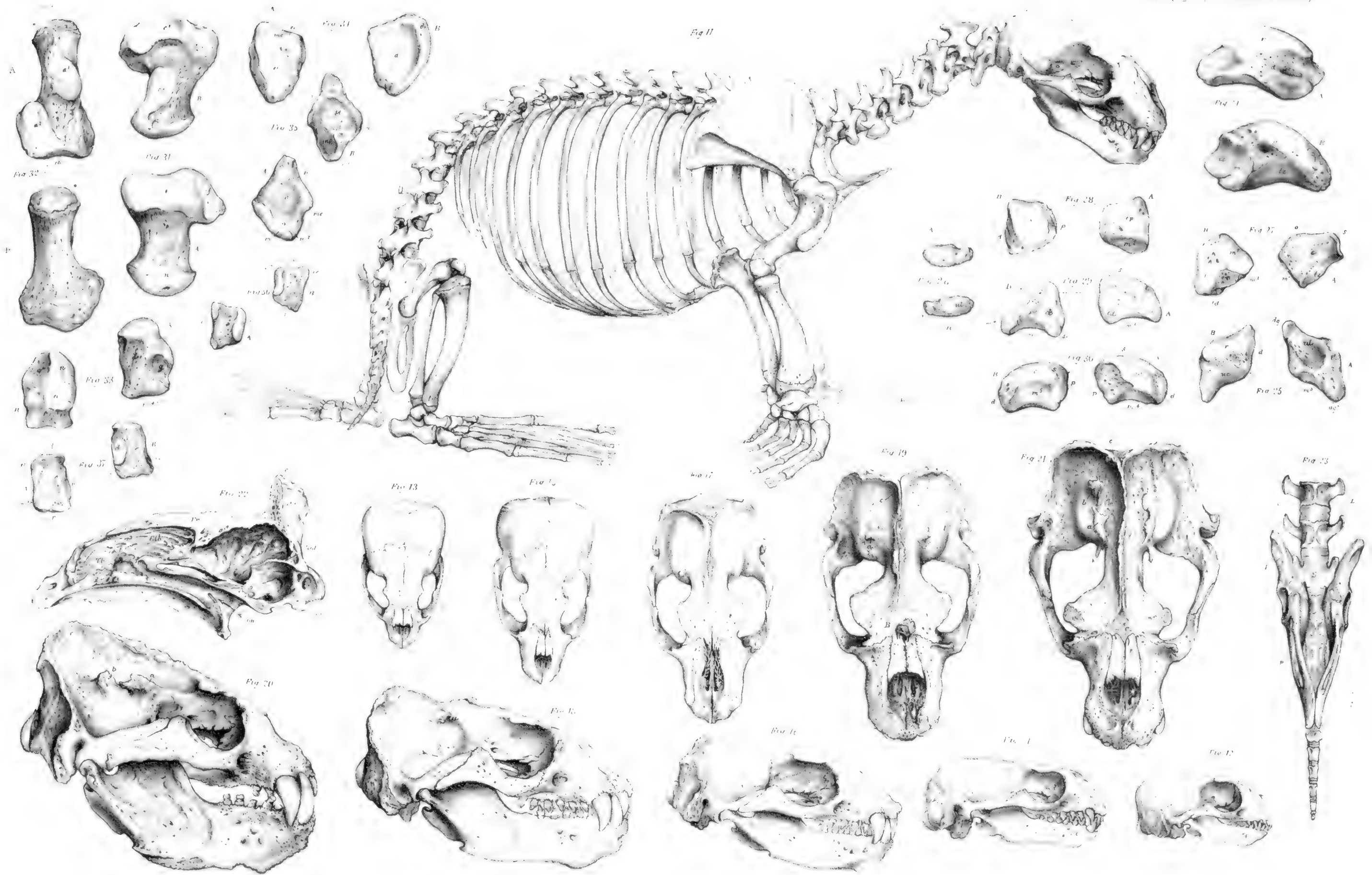


1 Mm.










OSSEA JUBA
SKELETON AND CRANIA AT DIFFERENT AGES



Pl. Anatom. No. 118

Fig 39

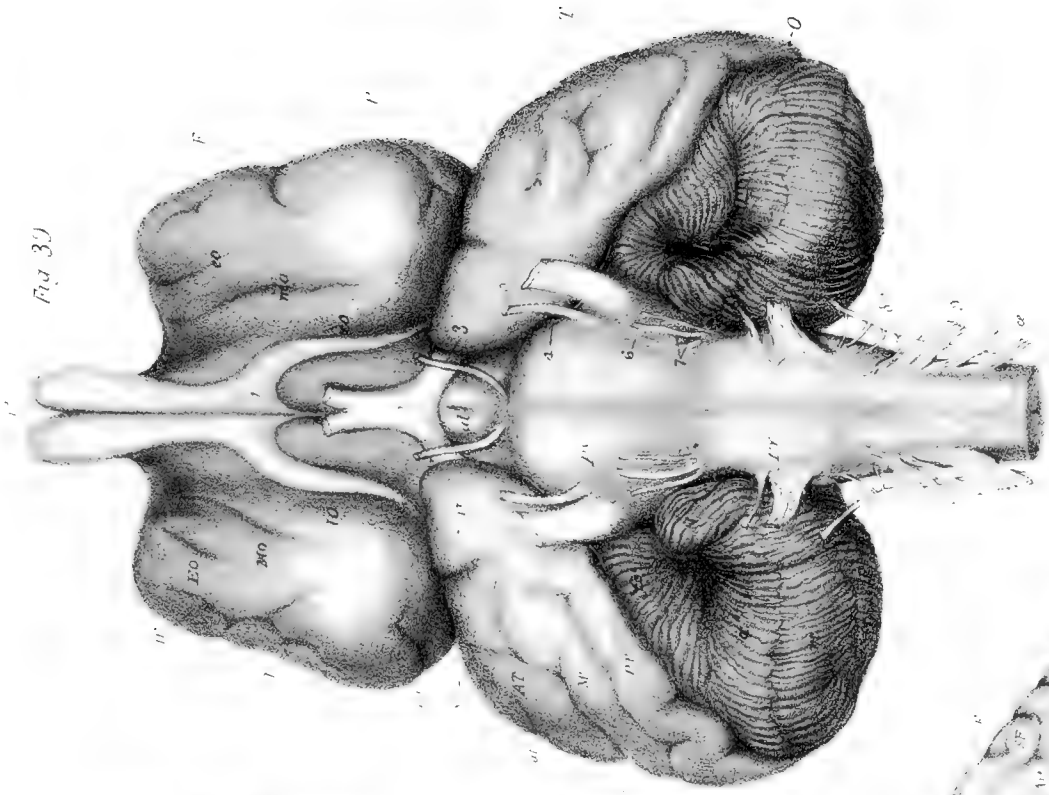


Fig 40

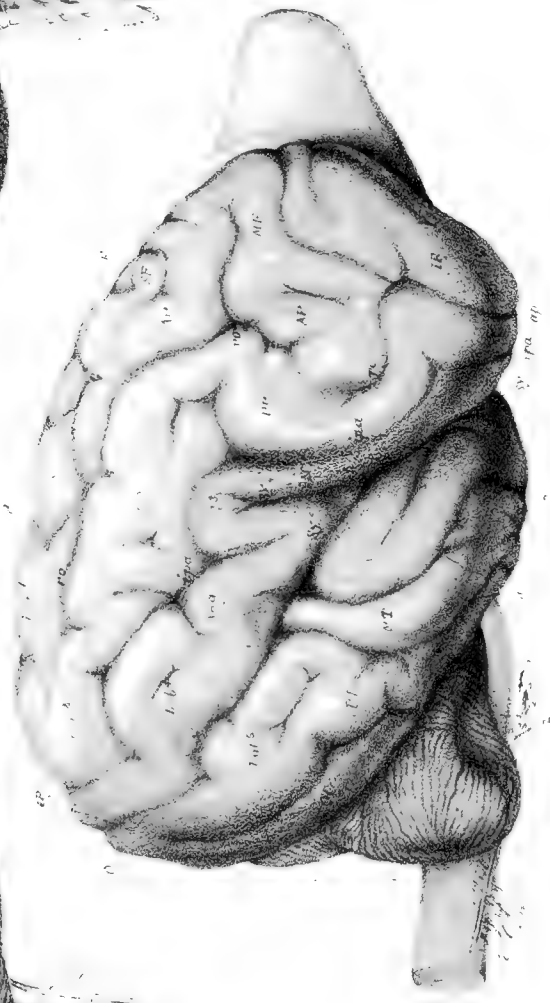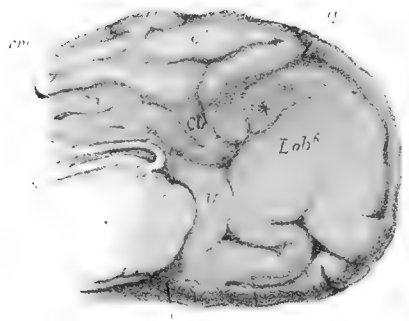
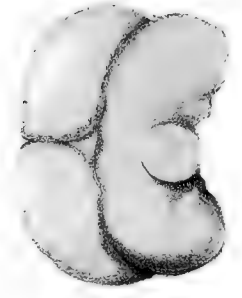
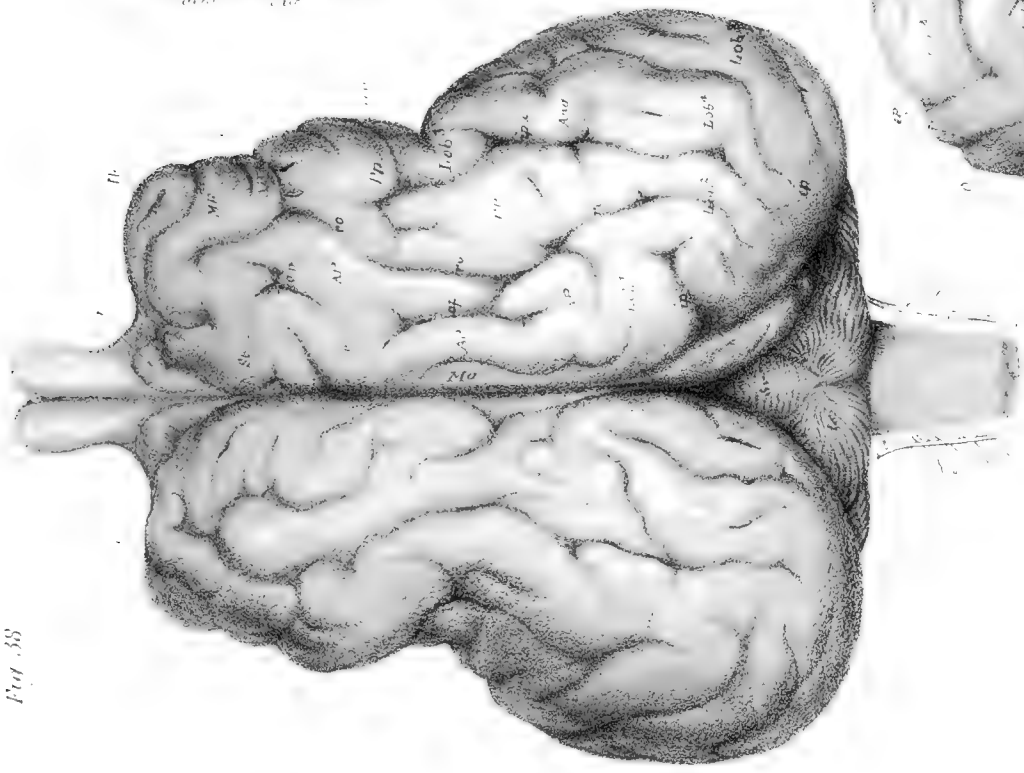


Fig 41

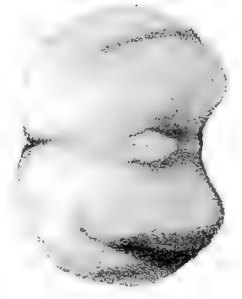

Fig 38






Fig 48

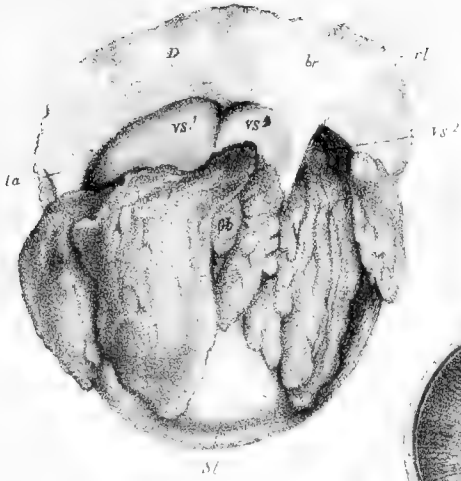

Fig 50

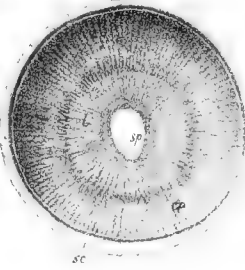


Fig 49

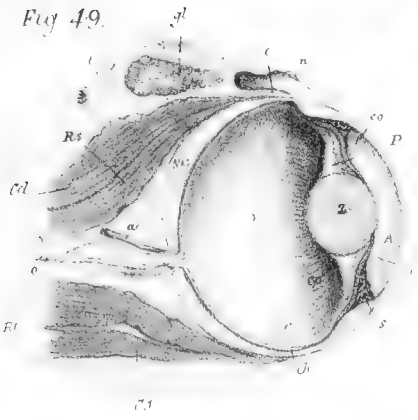


Fig 51

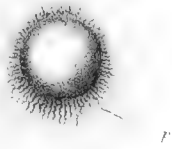


Fig 45

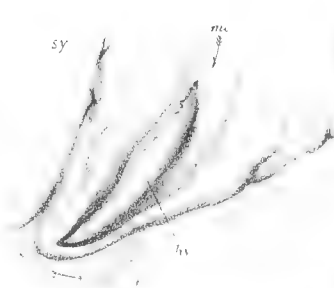
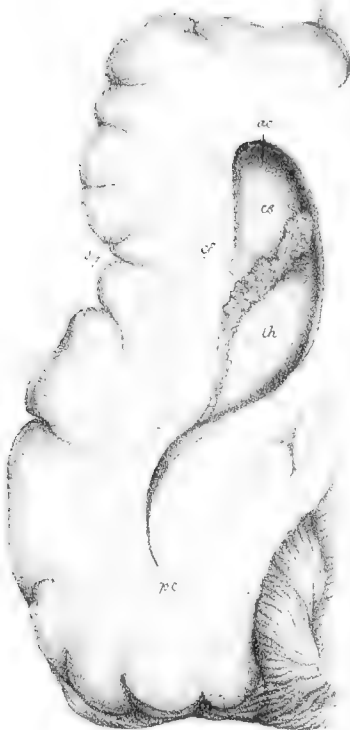

Fig 46

Fig 47

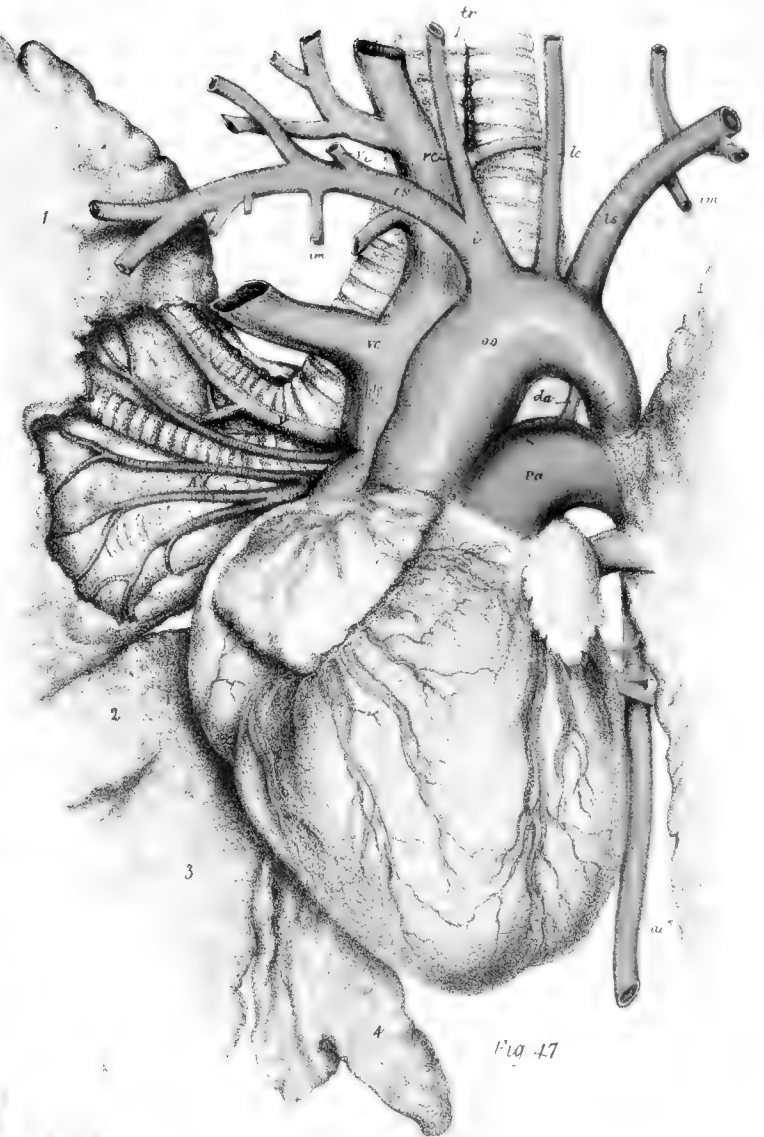
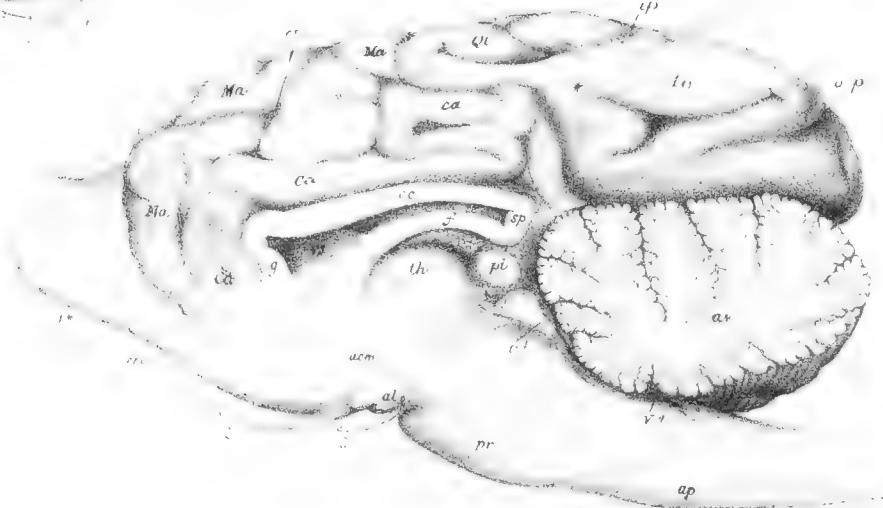


Fig. 44



C Berjeau lith

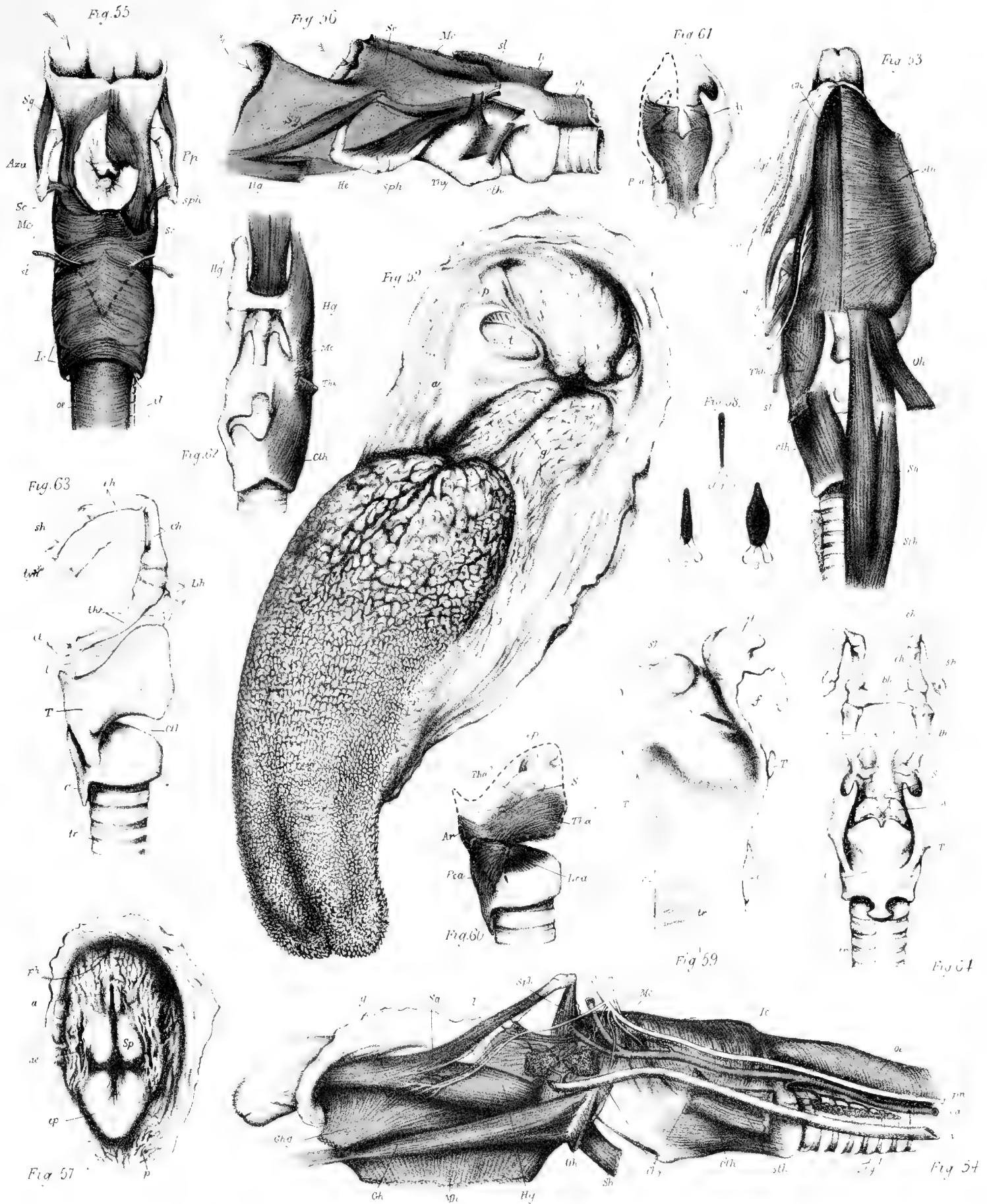
Berjeau & Murie del

SENSORY AND VASCULAR ORGANS.
OTARIA JUBATA

M&N Hanhart imp



I Murie



C Berreau lith

Eberzeau & Murie del

ORGANS OF DECLINATION & VOICE
MARIJA JUBATA

M&N Harriet int

1778. Anatomie des Arbres. S.




Fig. 69

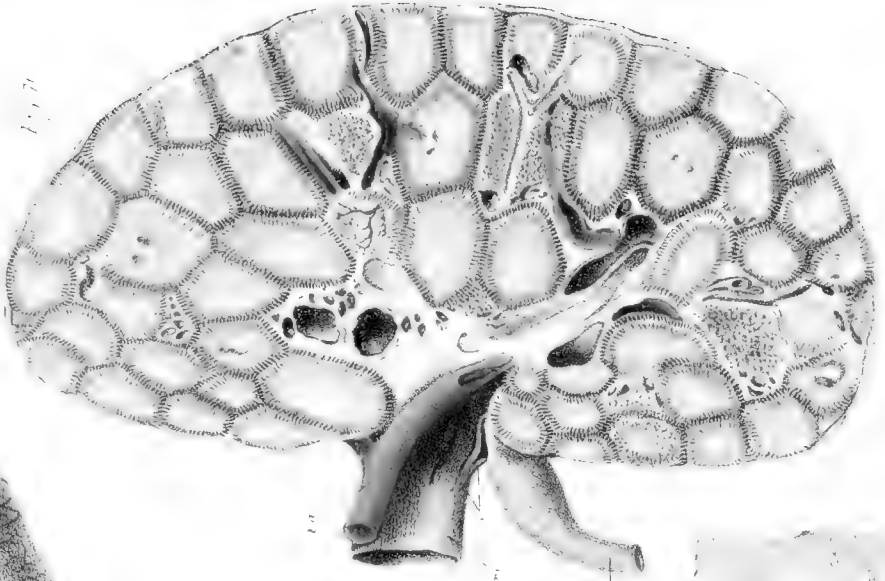


Fig. 70

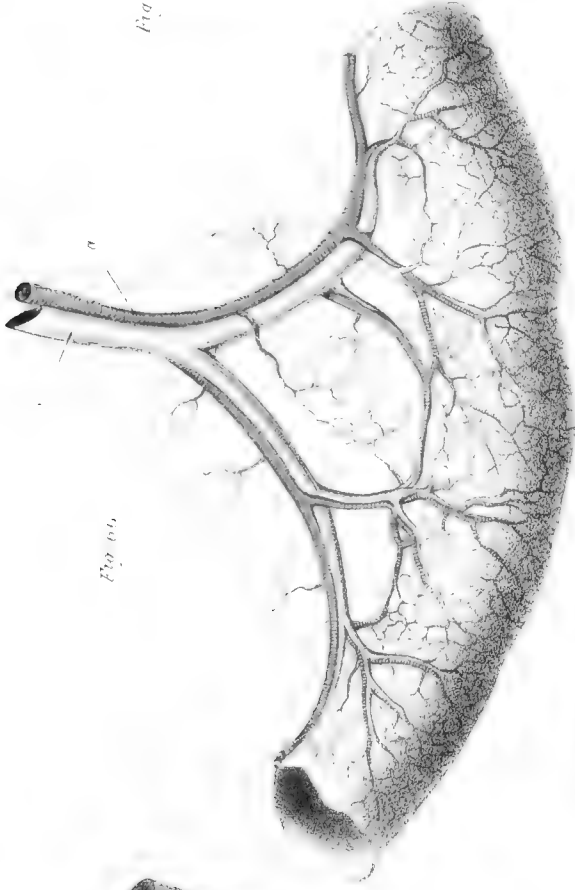


Fig. 71

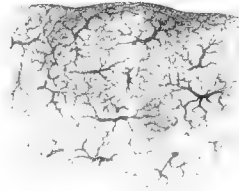


Fig. 72




Fig. 73

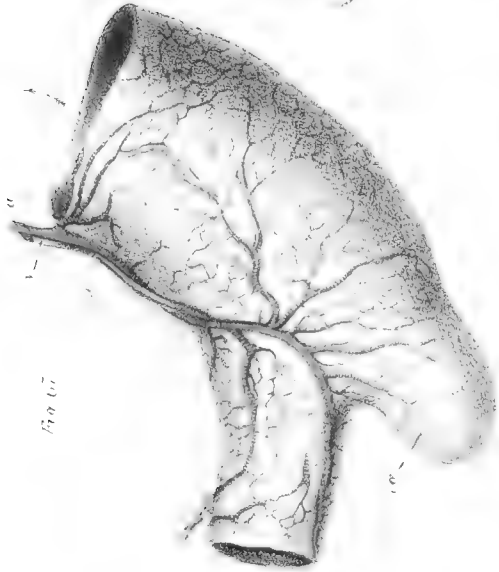

Fig. 74

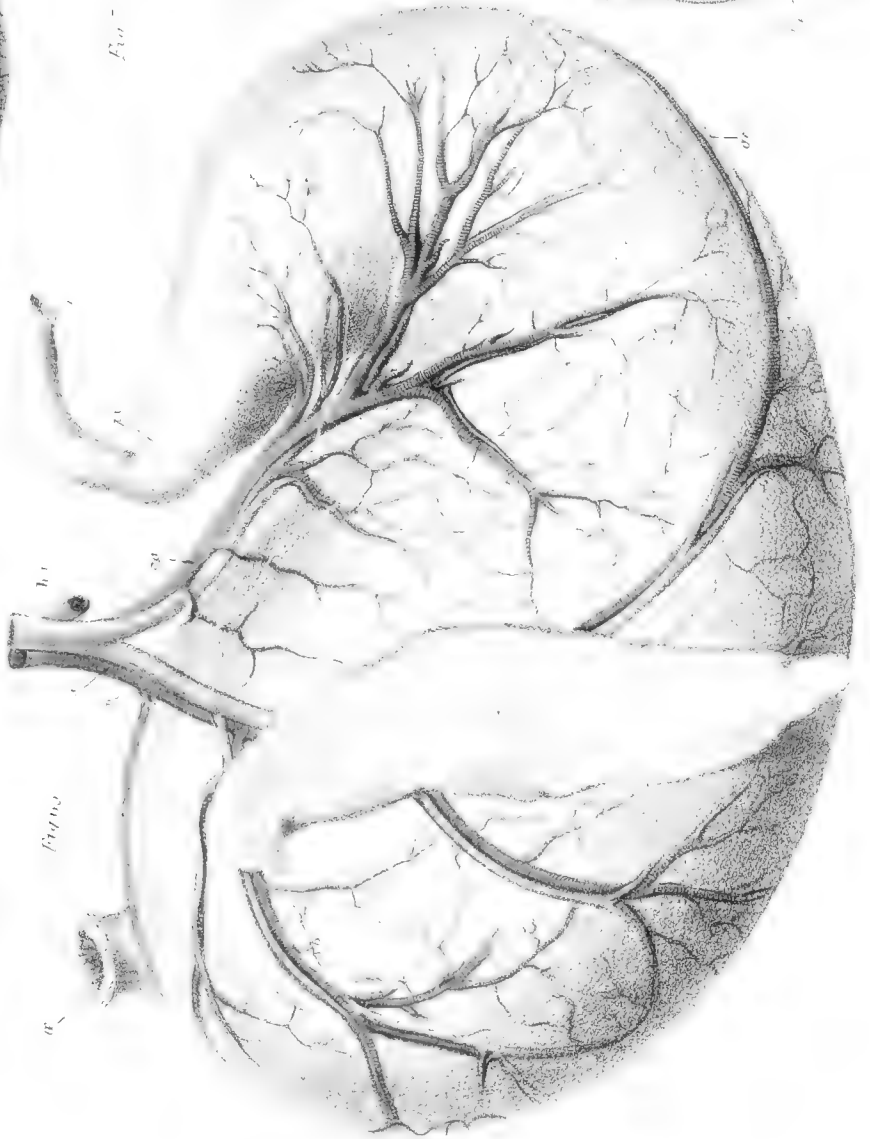


Fig. 75




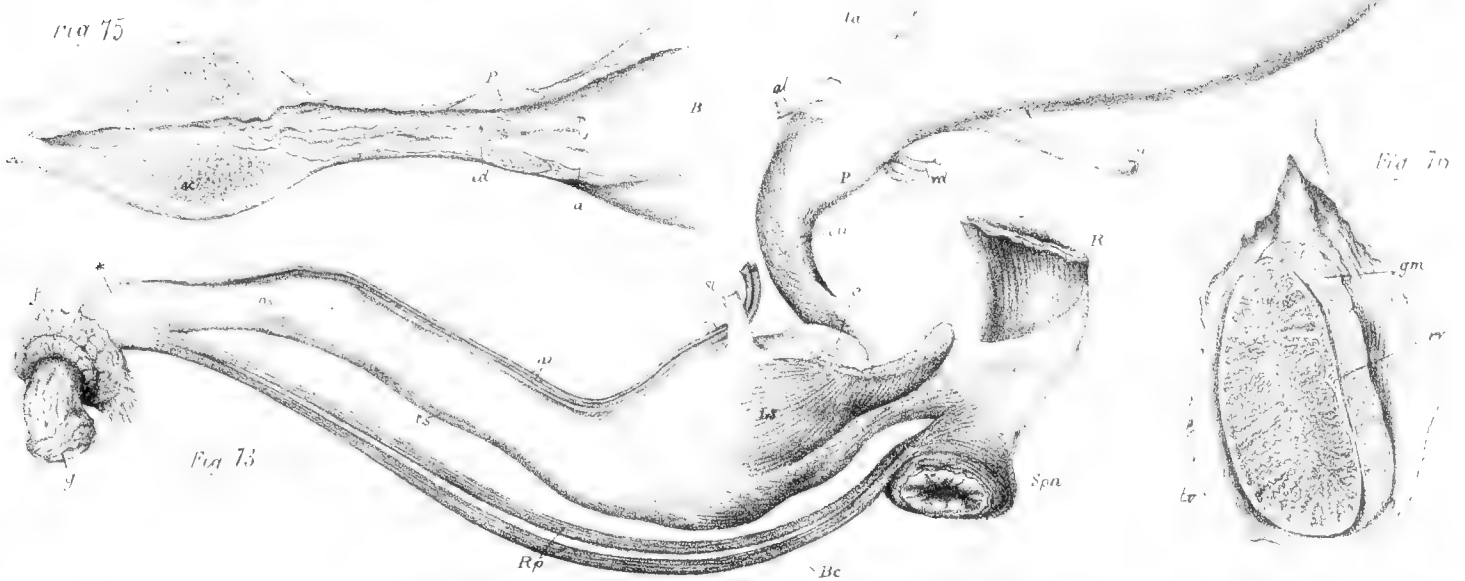
Fig 74

Fig 72

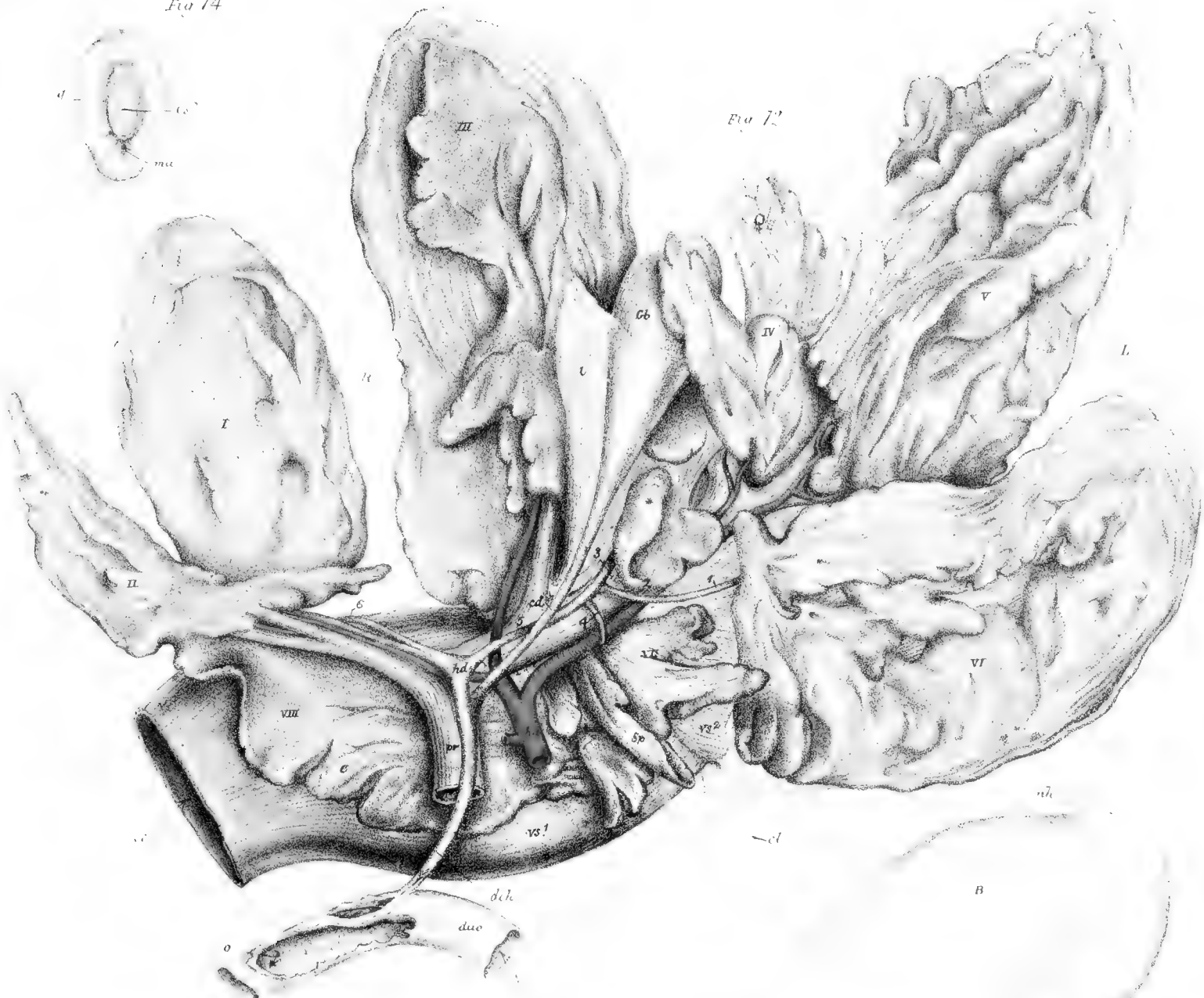

Fig 75

Fig 76



		To Fellows.			To the Public.		
		£	s.	d.	£	s.	d.
VOLUME VI. (1866–1869, containing 91 Plates)	Price	11	5	0	15	0	0
PART 1. (1866)	„	1	7	0	1	16	0
„ 2. (1867)	„	1	7	0	1	16	0
„ 3. (1867)	„	1	7	0	1	16	0
„ 4. (1867)	„	1	7	0	1	16	0
„ 5. (1868)	„	1	7	0	1	16	0
„ 6. (1868)	„	1	7	0	1	16	0
„ 7. (1868)	„	1	16	0	2	8	0
„ 8. (1869)	„	1	7	0	1	16	0
 VOLUME VII. (1869–1872, containing 73 Plates)	Price	8	17	0	11	16	0
PART 1. (1869)	„	1	2	6	1	10	0
„ 2. (1870)	„	1	2	6	1	10	0
„ 3. (1870)	„	1	2	6	1	10	0
„ 4. (1870)	„	1	7	0	1	16	0
„ 5. (1871)	„	1	13	0	2	4	0
„ 6. (1871)	„	1	7	0	1	16	0
„ 7. (1871)	„	1	7	0	1	16	0
„ 8. (1872)	„	1	2	6	1	10	0
 VOLUME VIII. (1872–1874, containing 82 Plates)	Price	9	8	3	12	11	0
PART 1. (1872)	„	0	10	6	0	14	0
„ 2. (1872)	„	1	11	6	2	2	0
„ 3. (1872)	„	1	7	0	1	16	0
„ 4. (1873)	„	0	15	9	1	1	0
„ 5. (1873)	„	0	18	0	1	4	0
„ 6. (1873)	„	0	19	6	1	6	0
„ 7. (1874)	„	0	16	6	1	2	0
„ 8. (1874)	„	0	18	0	1	4	0
„ 9. (1874)	„	1	11	6	2	2	0

The ‘Transactions’ and other publications of the Society may be obtained at the Office (11 Hanover Square, W.), at Messrs. Longmans’, the Society’s publishers (Paternoster Row, E.C.), or through any bookseller.

Fellows, Honorary, Foreign, and Corresponding Members of the Society, who pay a Subscription of £1 1s. before the day of the Anniversary Meeting (April 29th) in each year, are entitled to receive all the Society’s Publications for the year. They are likewise entitled to purchase the Publications of the Society at 25 per cent. less than the price charged for them to the Public. A further reduction of 25 per cent. is made upon purchases of Publications issued prior to 1861, if they exceed the value of five pounds.

P. L. SCLATER,
Secretary.

11 Hanover Square, London, W.
January 1, 1875.

CONTENTS.

- I. *On the Dentition and Osteology of the Maltese fossil Elephants, being a Description of Remains discovered by the Author in Malta between the years 1860 and 1866.*
By A. LEITH ADAMS, M.B., F.R.S., F.G.S. 1

SMITHSONIAN INSTITUTION LIBRARIES



3 9088 00584 9815