


LIBRARY
OF
W. G. SHAW



JOHN A. SEAVERNS

TUFTS UNIVERSITY LIBRARIES



3 9090 013 413 162

Webster Family Library of Veterinary Medicine
Cummings School of Veterinary Medicine at
Tufts University
200 Westboro Road
North Grafton, MA 01536



Wm Shaw

38 Pine St

Phila Pa

ROARING IN HORSES.

ROARING IN HORSES:

ITS

PATHOLOGY AND TREATMENT.

BY

P. J. CADIOT,

PROFESSOR AT THE VETERINARY SCHOOL, ALFORT.

TRANSLATED FROM THE ORIGINAL BY

THOMAS J. WATT DOLLAR,

M.R.C.V.S.G.B., LIC. VET. MED. AND SURG. H.A.S.S.

Illustrated by Eighteen Figures.



NEW YORK: WILLIAM R. JENKINS.
LONDON:

SWAN SONNENSCHNEIN & CO.
PATERNOSTER SQUARE.

1892.

P R E F A C E .

THE great interest that was manifested by the Veterinary Profession and the public generally some two or three years ago on the announcement of a cure for roaring has induced me to translate the following pages.

My acquaintance with the Author enables me to testify to the thoroughly scientific manner in which he has carried on his investigations, and to assure the profession that the present work represents the latest development in operative methods for the alleviation of roaring.

At the same time I wish to express my thanks to Professor P. J. Cadiot, to Monsieur Trasbot, Director of the Veterinary School of Alfort, to Professor Nocard, and the other professors of that institution, as well as to many of the *élèves*, who have rendered me very valuable aid whilst I was among them.

I also desire to thank Messrs. Asselin and Houzeau, publishers, Paris, for the assistance they have afforded me in respect of the plates, etc., for the illustration of this edition.

THOS. J. WATT DOLLAR.

SURGICAL TREATMENT
OF
CHRONIC ROARING.

I.

ROARING PRODUCED BY PARALYSIS OF
THE LARYNX.

THE term "roaring" was given by ancient veterinary writers and practitioners to a symptomatic affection very commonly met with in the horse, and characterised by an unnatural sound—"rattling, snoring, or whistling"—in respiration, which noise is more noticeable or only to be distinguished

during inspiration. The various alterations which tend to create an obstacle to the free circulation of air in the upper (superior) respiratory passages are accompanied by roaring. This is either acute or chronic, according to whether it accompanies a recent illness, when it may be transient; or, on the other hand, if it is the result of a previous illness or injury, it is said to be positive or chronic.

Among the morbid conditions which give rise to chronic roaring, there is one—paralysis of the muscles of the larynx—the extreme frequency of which has been revealed during this century by anatomical and pathological research. These inquiries have established that 95 per cent. of the cases of incurable roaring were due to paralysis of the larynx. Total paralysis is

seldom seen; it is nearly always unilateral, and generally affects the left side. When it follows irritation of the bronchial tubes or lungs, the laryngeal hemiplegia is the result of inflammation of the inferior laryngeal nerve of the same side or pressure on it by the hypertrophied bronchial glands; the diversity of relations of the recurrens as they leave the pneumogastrics fully accounts for the localisation of the laryngeal alterations. When it appears without having been preceded by a bronchial or pulmonary affection, it is due either to hereditary cause or to an accidental injury to the recurrent or pneumogastric nerves.

It is simply necessary to give a glance at the upper part of a larynx affected with hemiplegia to judge of the deformity which that organ has undergone. The orifice,

circumscribed by the epiglottis, the aryteno-epiglottic folds, and the arytenoid cartilages, is shrunk up and rendered manifestly unsymmetrical by the abnormal position occupied by the left arytenoid being lower and nearer the middle line than its fellow. The falling of this cartilage necessarily causes a change of position of the vocal cord attached to its lower edge; it is turned slightly backwards and inwards and therefore towards the opposite vocal cord, producing a very noticeable shortening of the lower part of the glottis (fig. 1). These anatomical alterations, more or less marked according to the duration of the affection, are generally in proportion to the respiratory sound noticed during life. Immediately they exist the action of the larynx becomes very imperfect. The posterior and lateral

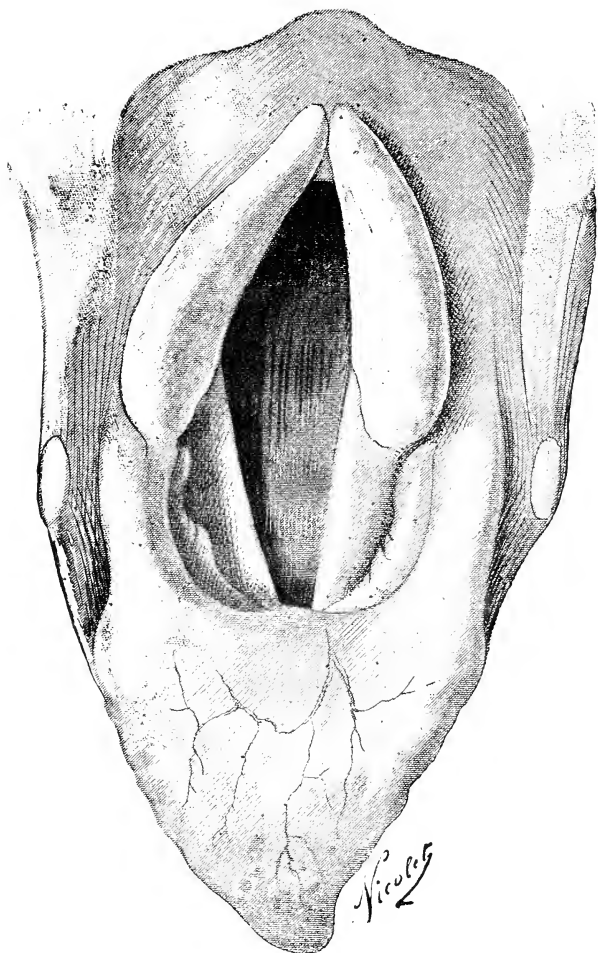


FIG. 1.—Superior orifice of the larynx and glottis of a horse affected with chronic roaring.

crico-arytenoidean, the thyro-arytenoidean and arytenoidean muscles degenerate, and are incapable of accomplishing their physiological work. The transverse dimensions of the superior opening of the larynx are already lessened and are incapable of being extended, and the opening is more reduced during inspiration, especially when the respiratory movements are quickened. As long as the respiration is calm, the air passes the laryngeal passage in silence; but as soon as it is quickened by exercise the left arytenoid, instead of being taken upwards and outwards by the action of the corresponding muscles, is displaced in an inverse direction. Pressed by the air inspired—being carried below and inwards towards the glottis and against the opposite arytenoid cartilage, taking with it the vocal cord, the

opening of the larynx being thus very much reduced,—the respiration becomes insufficient, painful, and noisy.

Such is the mechanism of the production of roaring as connected with paralysis of the larynx. The unnatural sound is produced by the obstacle which opposes the accomplishment of respiration; the arytenoid cartilage and the left vocal cord brought to the middle line become powerless.

In exceptional cases of total paralysis the two arytenoids are carried together in front of the glottis during inspiration, and the vocal cords execute the same movement, thereby considerably reducing the calibre of the upper part of the larynx, and the roaring is heard at its maximum degree.

II.

TREATMENT.

THE knowledge of the causes of roaring accompanying pulmonary affections has given rise to a prophylactic treatment, to which several authors have drawn attention. By the administration of alteratives—notably of iodide of potassium—it has been sought to prevent the compressive and atrophying action of the hypertrophied bronchial glands on the left inferior laryngeal nerve, but the efficacy of the medicine is most uncertain. Perhaps in many cases where no action is manifested, the paralysis of the recurrent is due to the pressure exercised upon it by the inflamed lung or of the extension of the inflammatory process, which in the first

instance was localised in the lungs and pleura, to its own substance. (Günther, Möller, Vaerst.)

As to the therapeutic means used as cures for chronic (definitive) roaring, they have seldom been successful. The preparations of arsenic, iodine and its compounds, mercurials, strychnine, given in pills, injected intravenously or hypodermically, electricity and the actual cautery, have been tried by a great number of veterinarians, and often several of these agents have been successively applied. Whatever has been done has been practically of no avail. If in some cases a transitory amelioration has been effected, and the onward march of the disease retarded, a cure has been the very rare exception, and then only in cases of very short standing.

It had begun to be considered that chronic roaring was an incurable disease, and ought to be classed among those affections where a palliative treatment could alone be looked for; and that the only means in these cases was to perform tracheotomy in order to be able to utilise the animals affected by it. Nevertheless, for a long time the insufficient nature of the remedies in use, as well as the serious inconveniences and the possible accidents which result from tracheotomy, gave rise to the idea of a direct surgical intervention on the deformed part of the larynx. It was sought to do away with the obstacle which prevented free respiration by lowering the arytenoid and changing the position of the vocal cord by excising those organs.

It is to Günther, Professor of the Veterinary

School of Hanover, that we owe the first attempts to that end (1845). This veterinarian, in the first place, resected both vocal cords in a certain number of roarers. No amelioration followed in any of the cases operated upon. He next successively performed ablation of the vocal cord on the paralysed side, partial excision of the arytenoid, total extirpation of the same cartilage, ablation of the vocal cord and the corresponding ventricle, and then fixed the arytenoid to the thyroid. These various operations were no more successful than the first. Several animals rapidly succumbed, and the others roared just as much as before the operation.

These experiments were repeated at Berlin by Gerlach; at Alfort by H. Bouley; at Copenhagen by Stockfleth; and at Turin by

Bassi. Then they were abandoned. Everywhere the results were unfortunate, nil, or doubtful. Of late years the surgical treatment of roaring was re-studied by Möller, Professor of Surgery at the Berlin Veterinary School, who also apparently had finally condemned it; and by Fleming, Chief Veterinary Surgeon of the English Army. These authors have made known methods that have given a certain number of successes. Möller has published his own manner of operating in a memorandum, translated by Hendrickx.* Fleming has explained his in a work where some interesting documents on laryngeal paralysis are to be found.†

* Möller, *Das Kehlkopffleifen der Pferde (Hemiplegia laryngis) und seine operative Behandlung*. Stuttgart, 1888. *Trad. in Annal. de Méd. Vet.*, 1888-9.

† Fleming, *Roaring in Horses*. London, 1889.

After having assured himself no cure could be obtained by excision of the vocal cords, Möller, convinced that the obstacle producing roaring was situated at the upper orifice of the larynx, made a number of experiments with the object of restraining the movements of the arytenoid by ankylosing it to the cricoid or by fixing it to the thyroid.

The first proceeding was to cut through the cricoid and the first two rings of the trachea in the middle line; then, by means of a pointed bistoury, to open the crico-arytenoid articulation by incising the capsular ligament of that joint, the patient being then left alone for some weeks. It was hoped that the arytenoid, ankylosed to the cricoid, would not again fall down from the pressure of inspired air. The greater number of the horses thus operated upon were sensibly

better afterwards, but the roaring never completely ceased in any one case.

Möller then tried another operation which allowed him to fix the arytenoid to the thyroid by means of a ligature, without first opening either the larynx or the trachea. This operation was generally followed by an increase of the roaring. He next tried section of the paralysed posterior crico-arytenoid, by opening the larynx by an incision made at the lower border of the parotid, between the jugular and the external maxillary veins. He thought the resulting cicatrix would shorten the muscle, support and perhaps raise the arytenoid; but the effects of the operation were most uncertain. The roaring continued in nearly every case subjected to the treatment.

These different experiments being very

unfavourable, Möller decided on completely excising the arytenoid cartilage (fig. 2), by which operation he had in 1887-8 cured

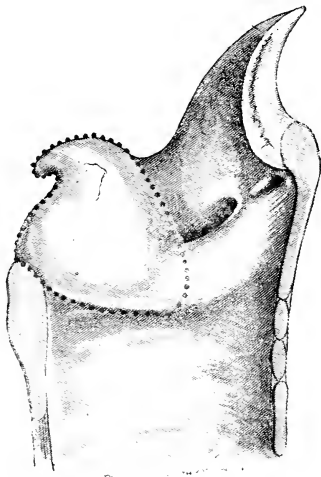


FIG. 2.—Möller's operation. Vertical and antero-posterior section of the larynx.—The dotted line represents the mucous membrane covering the edges of the arytenoid cartilage.

twenty-two cases out of thirty; that is to say, a proportion of 75 per cent. of successes.

The first of Fleming's experiments dates from 1878. "The possibility of curing a

case of roaring," says this Veterinarian, "was suggested to me by the examination of a horse affected with fracture of the thyroid cartilage. To remedy the accident the larynx was opened up, and I was astonished at the impunity with which the interior could be explored. The revelation which this fact afforded determined me to attempt the cure of roaring by a simple and sure operation. The physiology of the horse's larynx and the ease with which it adapts itself to surgical treatment being little known, I had, like those who preceded me in this line of research, to make a variety of experiments."

Fleming successively tried excision of the left vocal cord, the upper part of the arytenoid, ablation of the cord and a very large portion of the cartilage, but with little or no success. He then removed the arytenoid entirely, and

this was sometimes followed by a cure, whilst in other cases it simply reduced the sound. From examination of larynges of horses where

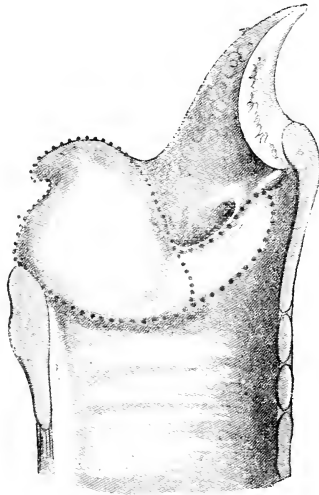


FIG. 3.—Fleming's operation. Section of the larynx.—The dotted lines show the incisions of the mucous membrane in ablation of the arytenoid cartilage and the vocal cord.

the operation had been useless, or only partly successful, he thought that the continued roaring was due to the vocal cord; he had

there a practical demonstration of the part that it took in producing the sound. Consequently to insure a more certain cure he found it necessary to excise the vocal cord as well as the arytenoid cartilage (fig. 3), and says this procedure gave the most satisfactory results.

Therefore, whilst Möller advised excision of the paralysed cartilage only, Fleming recommends extirpation of the arytenoid, as well as the vocal cord. But, although I have not as yet had a long experience in these operations, I have made my choice, and do not in the least hesitate to give my preference in every case to the method established by Möller; it has the advantage of not interfering with the laryngeal mucous membrane, except in a very small degree, and in a regular manner. On the other hand if the

cure is incomplete or not successful at all, the vocal cord has nothing to do with the persistency of the roaring; the cicatricial contraction cannot but hold it in its position or draw it slightly outwards.

III.

ARYTENOTOMY.

To excise the arytenoid cartilage with some certainty of success it is necessary to act



FIG. 4.—Blunt-pointed bistoury.

methodically, and be prepared with certain special instruments.

1. A razor knife or narrow-bladed, probe-pointed bistoury (fig. 4).

2. A pair of curved scissors, the blades of which should be very nearly perpendicular with the handles (fig. 5).

3. A double branched hook, with a spring



FIG. 5.—Bent or curved scissors.

to keep the wound open during the operation (fig. 6).

4. A pair of articulated artery forceps (fig. 7), or a pair of long, strong, anatomical forceps.

5. A tracheotomy tube of the form used

by Trendelenburg for human surgery, and intended to prevent the entrance of foreign bodies into the trachea (fig. 8). It is a long tracheotomy tube, the flattened surface or

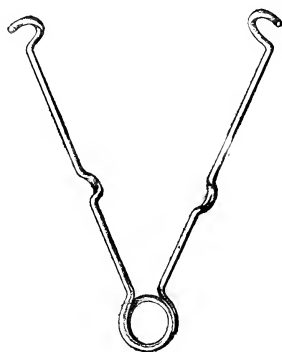

FIG. 6.—Spring hooks.

pavilion of which is provided with a cap to protect the outer orifice of the canula; the tube is surrounded on its external surface with an india-rubber covering which fits very tightly except in the middle, at which point, when in position and in use, it forms a sort

of balloon produced by inflating it, when within the trachea, with air by means of a small india-rubber tube provided with a bellows, which is connected with it by an

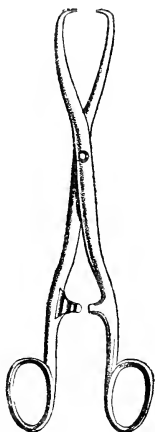


FIG. 7.—Hooked or artery forceps.

opening in the wall of the canula from the inside ; when distended the small india-rubber tube is ligatured at a point outside the canula and the india-rubber ball bellows removed (fig. 9). In place of the above an ordinary

tracheotomy tube may be used, but the canula should be covered with aseptic gauze, fixed by means of two ligatures.

6. A bent needle with the eye close to the point, and provided with a metal handle (fig. 15).

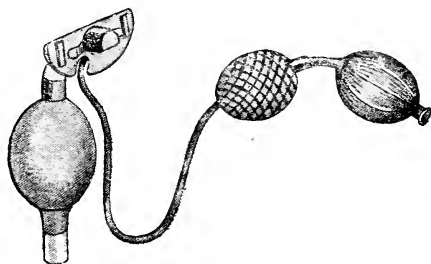


FIG. 8.—Plug or stopper canula with ampullæ or bellows attached.

Beyond these it is necessary to have a pair of long, straight scissors, ordinary curved scissors, anatomical and artery forceps, sponges fixed to the teeth of bolted forceps, needles, two sizes of catgut, and silk or thread, wadding, carbolised gauze (Lister's),

or gauze rendered aseptic with iodoform, and an antiseptic solution.

The animal being anaesthetised* is placed on its back and kept in that position by means of a bar held by two or four assistants. The head being well extended on the neck, the region of the throat is shaved over a surface limited in front by the hyoid, behind by the fourth ring of the trachea, laterally by the branches of the inferior maxillary and the tendon of the sterno-maxillary muscles. The shaved skin is washed with warm water

* As an anaesthetic agent I at first persistently used chloral by intravenous injections (jugular) of one-third or one-sixth strength, but this is subject to very serious accidents. It is much better to use ether, chloral in clysters associated with hypodermic injections of hydrochlorate of morphia, or chloroform, the recent researches of Möller and Guinard having proved that chloroform is not more dangerous to the horse than to man.

and soap, and then with a one per thousand solution of corrosive sublimate.

METHOD OF OPERATING. — *First Phase: Incision of the Skin and Muscles which cover the Larynx.*—The incision of the tissues which cover the lower surface of the larynx should be made on the middle line, and extend from the body of the thyroid to the second or third ring of the trachea. These points can be easily distinguished on examining the region. That done, the skin is divided to the full extent at one cut, the edges being slightly turned back the intersection of the sterno-hyoidean and omoplat-hyoidean muscles is seen. The muscular coat can by that means be cut through exactly in the middle line. The division of the encircling laryngeal connective tissue completes the first part of the operation. There is never much

bleeding, and it is easily stopped by the cold douche. When small arterial branches have been cut in the muscular structure, or in the deep layer of connective tissue (rendered abnormally vascular in consequence of the prior application of blisters or the cautery), it is necessary to twist the injured vessels or to apply bull-dog artery forceps. When the bleeding has ceased the second part of the operation is commenced.

Second Phase: Incision of the Larynx and the two first Rings of the Trachea; Introduction and fixing of the Canula.— This incision may be made in one stroke, from front to back, by plunging the bistoury into the crico-thyroidean ligament behind the body of the thyroid and in the middle line, dividing successively this ligament, the cricoid cartilage, the crico-tracheal ligament, and the

first rings of the trachea.* But by doing so, the operator is liable to injure one of the vocal cords, either during a movement of the patient, incompletely anaesthetised, or by introducing the instrument a little to one side of the middle line, and thus taking an oblique direction. To avoid this accident it is necessary to act in the following way. The bistoury held in a vertical position with the cutting edge behind is passed into the crico-thyroidean ligament immediately in front of the cricoid cartilage, then this cartilage, the crico-tracheal, and the two first rings of the trachea are incised, then the lips of the laryngo-tracheal incision are withdrawn from one another by tenacula, or by spring hooks,

* The incision need only be extended to the first ring of the trachea, provided the canula is not employed, or only used at the moment of dressing the wound.

the incision of the crico-thyroidean membrane is completed from behind forwards, and from within to without by holding the bistoury in the position of a bow reversed. The vocal cords are distinctly seen to turn outwards at the moment of inspiration; and it is at this time that the opportunity should be taken to incise the crico-thyroidean membrane up to the body of the thyroid without damaging the cords. The canula is then introduced into the trachea, and immediately it is in position an assistant, with the aid of the india-rubber ball bellows, moderately distends the elastic balloon attached to the tube. The operator should determine to what extent it is to be filled by passing the index and middle fingers of the left hand into the upper part of the trachea, or by feeling the air reservoir of the bellows. When the

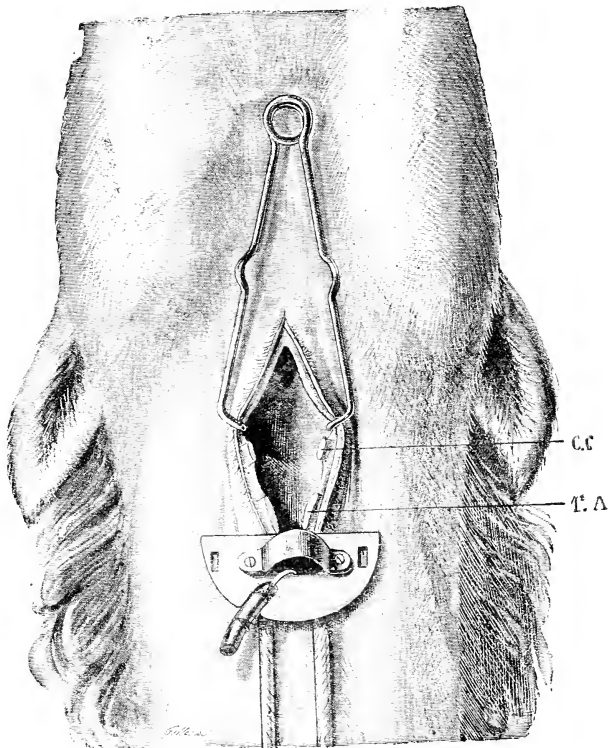


FIG. 9.—Arytenotomy. The second phase of the operation. The crico-thyroid ligament, the cricoid cartilage, the crico-tracheal ligament, and the two first rings of the trachea are cut through. The canula and spring hooks are in position.—CC, cricoid; 1st A, first tracheal ring.

balloon is sufficiently distended a ligature should be applied to the india-rubber tube near the cap of the pavilion of the canula, and the remainder of the small tube with the bellows removed (fig. 9). Even when the balloon is filled to the desired extent, the canula has a tendency to slip towards the larynx; it should therefore be kept in place by a whipcord, a dossil, or a band placed under the pavilion of the tube, and the two ends carried backwards (fig. 9).

Third Phase: Ablation of the Arytenoid Cartilage.—It is sufficiently easy to determine which of the arytenoids is affected with paralysis by a comparative examination of their action, as well as to be able to judge of its degree. In every operation which I have made till now, the paralysis affected the left side; in three cases the two cartilages

were the seat of the malady, but the left always to a greater degree than the other.

Ablation of the arytenoid is divided into the following parts:—(a) Incision of the mucous membrane along the superior and posterior edges of the cartilage; (b) section of the vocal cord, dissection of the cartilage upon its inferior and anterior borders, and its external face; (c) section of the cartilage near its articulation with the cricoid; (d) dissection of the superior surface of the cartilage.

(a) By means of the probe-pointed bistoury and using a slight amount of pressure, the mucous membrane bordering the superior and posterior edges of the arytenoid is incised (fig. 10). The instrument is carried to the opening of the larynx, upon the middle line, then directed from front to back as far as

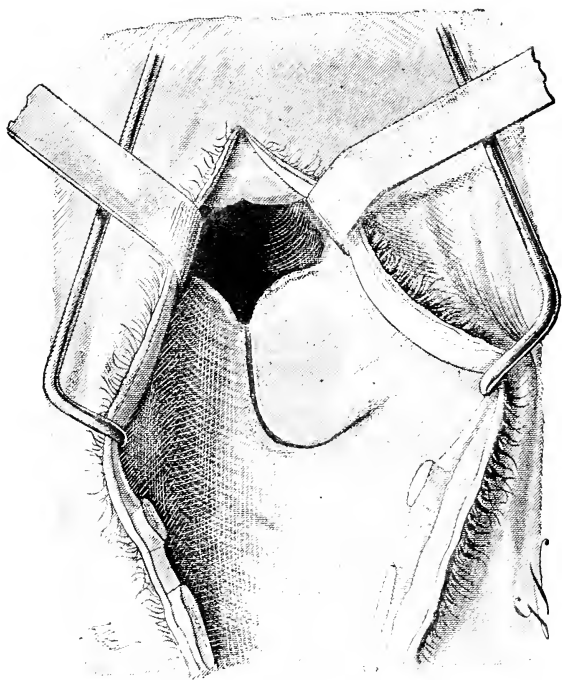


FIG. 10.—*Third Phase: (a)* Incision of the mucous membrane of the superior and posterior edges of the arytenoid. In order to render the demonstration more clear, the incision of the second part is continued in front to the middle portion of the epiglottis, and backwards to the fourth tracheal ring.

the cricoid, then from within outwards and from below upwards to the insertion of the vocal cords. This incision can be made at some distance from the edges of the cartilage, so as to affect the mucous membrane as little as possible, which ought to be entirely divided; if incompletely so at the first attempt, the bistoury must be used anew.

(*b*) With long, well-ground scissors the vocal cord is cut through at its insertion on the arytenoid (fig. 11); then with great precision the cartilage is dissected, from behind forwards, dividing the mucous membrane along the lower edge and the muscular fibres (crico-arytenoidean and thyro-arytenoidean), which are inserted on its external face (fig. 12); then, holding the scissors vertically, the mucous membrane which covers the

anterior edge is detached from above to below.

For the favourable execution of this third part of the operation, the cartilage should be tightly held by double tenacula or long forceps with corrugated points, the lower border and the external face is dissected on turning it towards the middle line; it should be drawn backwards and upwards to divide the mucous membrane from its anterior edge. The only important rule is to hold the points of the scissors always in contact with the cartilage, to glide over it, to damage the mucous membrane as little as possible. The same may be said with respect to the laryngeal ventricle, and the tissues detached from the external face of the arytenoid. If this is carried out there is not the least danger in opening the ventricle. Towards

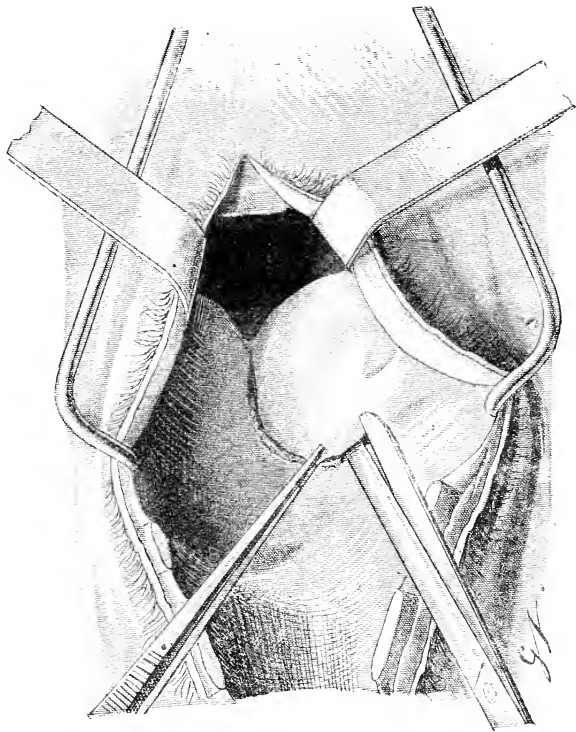


FIG. II.—*Third Phase : (b) Section of the vocal cord.*

the finish of this stage of the third part of the operation, when the fibres of the thyroarytenoid muscle are separated, the laryngeal branch of the thyroid artery is cut (fig. 13, A). The bleeding which results is not formidable, and may be arrested by twisting the vessel, or by applying a pair of articulated forceps to its extremity, which should be held by an assistant; or the operation can be continued without troubling about the matter, but then the operator is constrained in his later movements.

(c) The arytenoid, lifted and held up with a pair of strong forceps or by hooked forceps, is cut away from the outside inwards, near its postero-superior or articular angle, by means of the probe-pointed bistoury. This, held vertically or in a slightly oblique direction below and forwards, is applied to

the external part of the arytenoid immediately in front of the cricoid (fig. 13); and a saw-like movement is made with a certain amount of pressure, always taking care that it does not slip. When the arytenoid is partially ossified (in nearly half the cases) it is necessary to use force. A sensation that the resistance is overcome and that there is a great deal of movement of the cartilage, which is easily displaced in all directions, indicates that the section is complete.

Möller cuts the arytenoid from within outwards, fixing it by applying the index finger of his left hand to its external surface.

(*d*) The upper face of the arytenoid is dissected with the curved scissors, the cartilage is lifted by forceps, and under the posterior portion is passed the extremity of the scissors, the handles of which are held

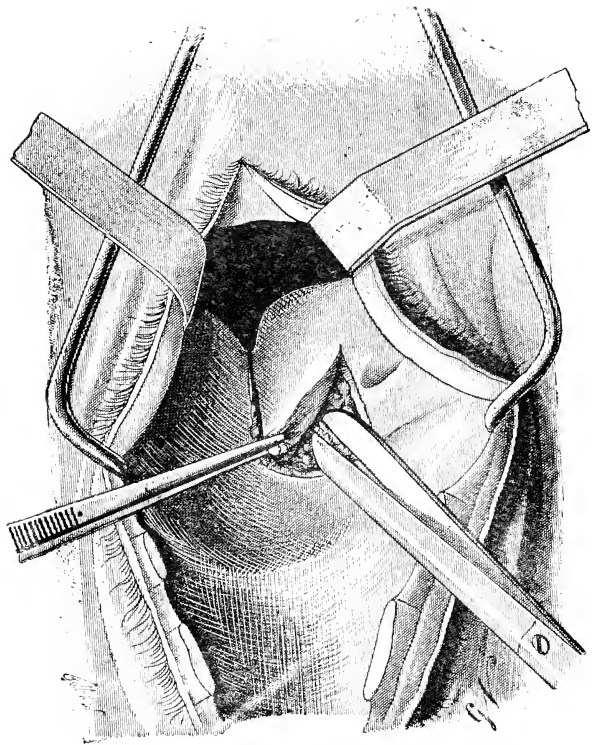


FIG. 12.—*Third Phase: (b)* Dissection of the arytenoid at its inferior edge and exterior surface.

nearly vertically (fig. 14), and by gliding over the superior surface from behind forwards, the fibres of the arytenoid muscle are detached, the last adhesions of the point (bec) with a little care are broken down without interfering with the neighbouring parts. Möller leaves the articular angle of the arytenoid in the wound. It can be easily removed by taking it between the teeth of a pair of long forceps, and making the dissection by means of the ordinary curved scissors.

To perform the section of the arytenoid, and destroy the adhesions of its upper surface (*c, d*), the operator is sometimes troubled by the blood and the pharyngeal mucus that are thrown into the larynx by the movements of deglutition; the seat of the operation must then be kept clean by soft napkins, plugs

of wadding, or small sponges fixed in the teeth of bolted forceps.

When the different stages of the operation, already described, have been properly accomplished, the edges of the wound are strictly defined, and their dimensions are about equal in point of length and breadth.

Advisedly I do not describe excision of the vocal cord; there is no advantage to be gained in practising it, and I have already stated my reasons.

Fourth Phase: Suture.—The anterior and posterior edges of the wound are united by two or three threads of catgut passed by a needle *ad hoc*, solidly attached to its handle. The needle, with a thread of about eighteen inches long attached to it, is passed through the anterior lip of the wound at about one-third of an inch from the middle line; there the

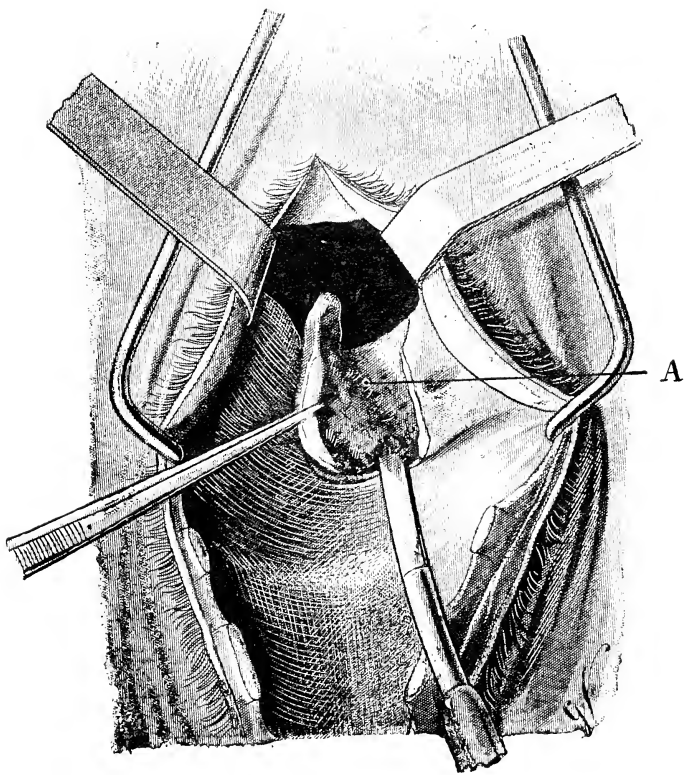


FIG. 13.—*Third Phase*: (c) Section of the arytenoid close to its articular angle. A, Laryngeal branch of the thyroid artery.

mucous membrane is penetrated from front to back and from without to within; then, at a corresponding point, the posterior lip is traversed from front to back and from within to without (fig. 15). One of the ends of the catgut thread is retained at the outside of the posterior lip of the wound, and the other is drawn back with the needle to the outside of the anterior lip; the ends of the thread are then knotted together and drawn sufficiently tight without injuring the mucous tissue. To accomplish this rather delicate part of the operation, the thumb or index finger may be passed into the larynx, and draw gently on each end of the thread; the extremities of the suture are then cut off close to the knot.

The other two sutures are placed in the same manner (fig. 16). When the laryngeal

branch of the thyroid artery has been pressed by an artery forceps, the bleeding is insignificant once the parts are sutured.

DRESSING.—After having removed the blood clots from the larynx it is filled up with layers of wadding, or plugs of wadding and gauze, rendered aseptic by iodoform, provided with strings to prevent them being swallowed. It is advisable to put in some long, flattened plugs at once; the inferior edges of which should be traversed by the muscular sutures. The edges of the external wound are joined together by two sutures superposed at a distance of about one-third of an inch from one another, the first made in the muscular tissue, the other in the skin. For both these silk thread or ordinary thread is used. The skin suture placed in front of the canula ought to be very strong, in order

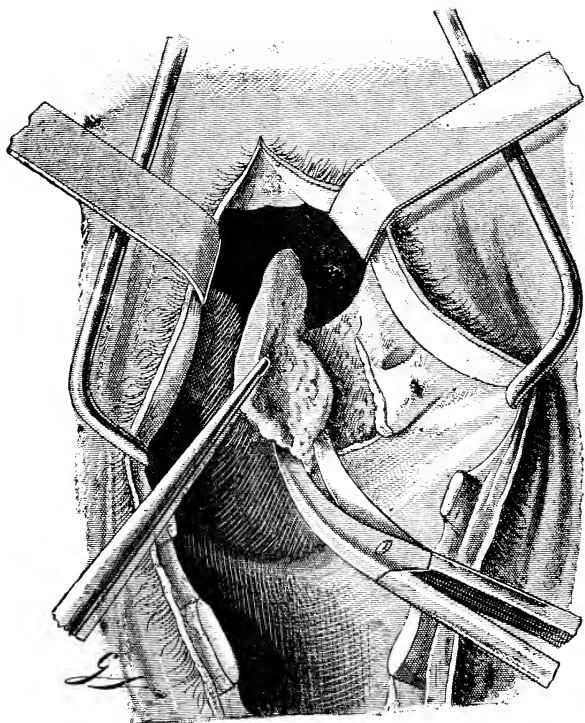


FIG. 14.—*Third Phase: (d)* Excision of the cartilage by the curved scissors.

to prevent displacement ; to this should be further attached linen bands or dossils, and their extremities knotted above the upper part of the neck.*

SUBSEQUENT ATTENTION.—The animal on getting up is placed in a box without bedding, and kept strictly without food for twenty-four hours. Möller, who formulated these instructions, does not now rigorously apply them. For some time past, he has given his patients bedding and water to drink from the first day.

The next day the dressing and the tube

* The principal changes that can be made in the way of rendering this operation more simple are the following :—(1) Make the incision only as far back as the first tracheal ring ; (2) discard the use of the canula ; (3) apply no dressings. The future will determine the efficacy of the means.

are removed. The skin in the neighbourhood of the wound has the scales or crusts cleaned off its surface, the sutures are cut successively and the plugs removed. Then the interior of the larynx is cleansed with a sponge held in the teeth of a forceps, or by the use of balls of wadding rolled round and attached to small sticks, the lips of the wound being meanwhile kept apart by large shouldered hooks (*Écarteurs de Farabœuf*). Finally, having cut the small india-rubber tube, and allowed the air in the balloon to escape, the canula is removed. Very often the distended rubber membrane has already allowed the air to escape by an unseen issue, and sometimes it is found torn.

The regular cicatrisation of the wound is favoured by uniting the subcutaneous muscular tissue to the skin by a few stitches. In

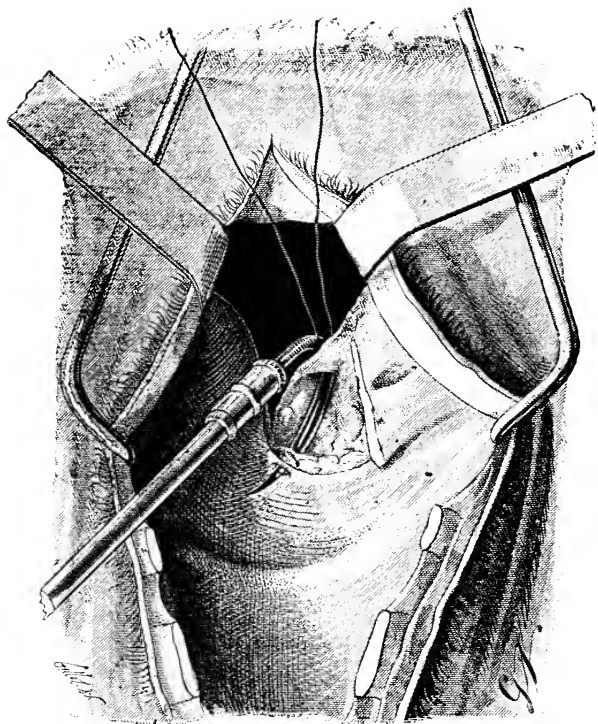


FIG. 15.—*Fourth Phase: Suture.*—Mode of passing the thread. The needle should pass the anterior and posterior lips at a point equidistant from the middle line and close to their free edges. In tracing the posterior lip of the wound, the needle should enter at a point somewhat deeper than indicated in the figure, but so as only to affect the mucous membrane.

order to permit the free action of respiration, the threads of the middle suture of each lip, kept long, are knotted moderately tight to the upper border of the neck. They keep the wound open and prevent the edges touching together during inspiration. The third or fourth day these threads are cut, and the sutures removed.

The further treatment consists in cleaning the outside wound three times daily, with an antiseptic solution (carbolic acid, corrosive sublimate, or cresyl), without in the least interfering with the intra-laryngeal wound, the regular repair of which is the necessary condition of success. Both cicatrise rapidly enough. The first is generally entirely closed by the end of a month.

It has been recommended to give the animal nothing but hay and water for the

first three or four days, but it can be given its ordinary food immediately; the only indication of importance being to place the food and drinking water at a little distance from the ground, in order to let out by the wound any alimentary matter or liquid that may penetrate into the larynx during the first few days.

The febrile reaction produced by the operation is very little noticed, and persists only during a few days. The temperature seldom exceeds 39.5° Cent., or about $103\frac{1}{2}^{\circ}$ Fahr.

The patient ought to be left completely at rest for three or four weeks, and then walked out morning and evening, or put to light work.

The final effect of the operation cannot be determined before the third month. With

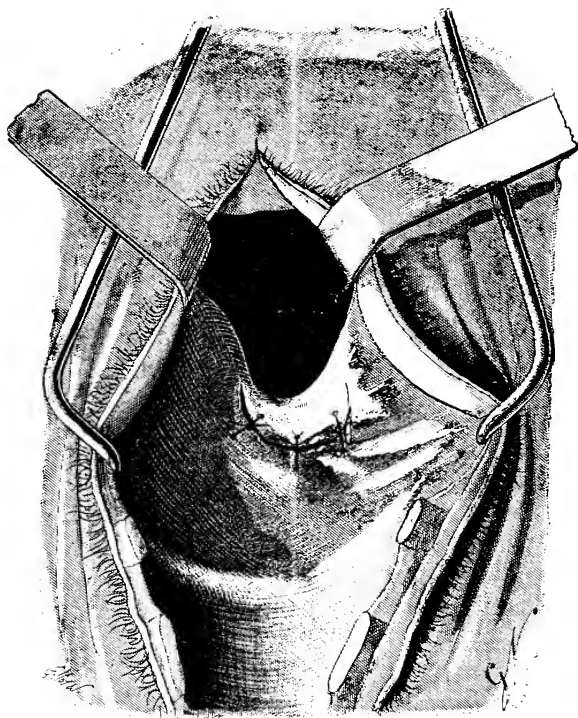


FIG. 16.—Termination of the suture. Position of the three stitches. When the sutures are well put in, the three threads should be nearly parallel with themselves and with the middle line. The first should not have the oblique position indicated in the figure.

the view of assisting the absorption of the new elements which have not become organised, and to avoid as much as possible a protruding cicatrix, I am in the habit of giving, from the second to the fifth week, a daily dose of a quarter to half an ounce of iodide of potassium to my patients in their drinking water.

ACCIDENTS AND COMPLICATIONS.—I. *Wounds of the Mucous Membrane and of the Arytenoid which has been left.*—They result from slips made in carrying out the movements that form the third part of the operation, more especially at the moment of cutting through the cartilage at its articular angle. The mucous membrane may be more or less seriously injured if the animal attempts to lift its head and is not tightly held. In putting in the sutures the remaining arytenoid

may likewise be wounded by the needle. In most cases where the cartilage becomes inflamed, the mucous membrane becomes tumified, hard, and of an enormous thickness, and intense roaring continues.

2. *Incomplete Deglutition of the Dressing.*—

When the plugs or the gauze compresses placed in the larynx are not closely fixed, the animal, by its efforts at deglutition, may cause them to pass into the œsophagus, where they are taken hold of by a contraction of the muscular coat of that tube. The next day, on removing the dressings, the larynx is found empty. The plugs must then be extracted by holding the head extended on the neck, and carefully drawing upon the threads attached to them in a vertical or slightly oblique manner and forwards.

3. *Inflammation of the Lungs by Foreign*

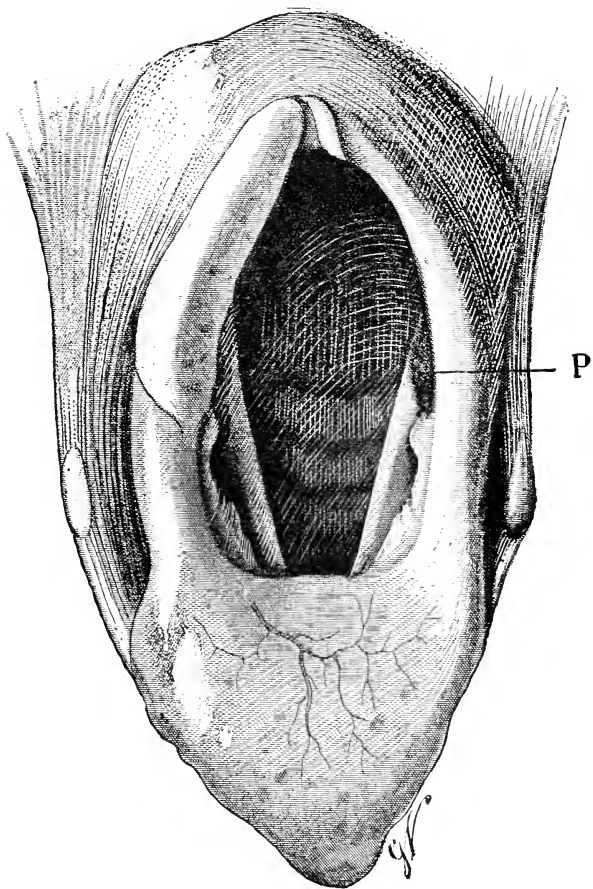


FIG. 17.—Superior opening of the larynx and glottis of a roaring horse that died of pneumonia eighteen days after the operation. The lips of the wound resulting from ablation of the arytenoid were not sutured. P, wound in the act of healing.

Bodies.—It would seem as though this complication ought often to arise considering the opening made in the arytenoidean arch, the incomplete closing of the upper orifice of the larynx, and the possible entry into it for some time of alimentary matter, saliva, or drinking water.

In reality it is very rare, and in those instances where it does occur it is undoubtedly the result of inattention and negligence in taking care of the patient. The great chance of avoiding it is in placing the food and water at a little distance from the ground, and allowing nothing of an irritating nature to pass into the trachea when the wound is being cleansed.

4. *Exuberant Vegetation of the Cicatricial Tissue.*—It is very difficult to inspect the reparative process of the intra-laryngea

wound, and intervene during the development of more or less prominent growths. These, moreover, are not frequent, and there is more harm done than advantage obtained by interfering directly with the reparative tissue. The causes of inflammation of the mucous membrane are the opening of the external wound and the introduction of irritating foreign bodies into the larynx. In consequence it is better to consider these points before meddling.

5. *Deformity of the Incised Cartilaginous Rings at the top of the Trachea.* — This consists in the lateral flattening of the rings, and arises without doubt as a result of the inflammation developed in their substance. The transverse diameter of the trachea may be reduced to the third of an inch. The section of too many of the

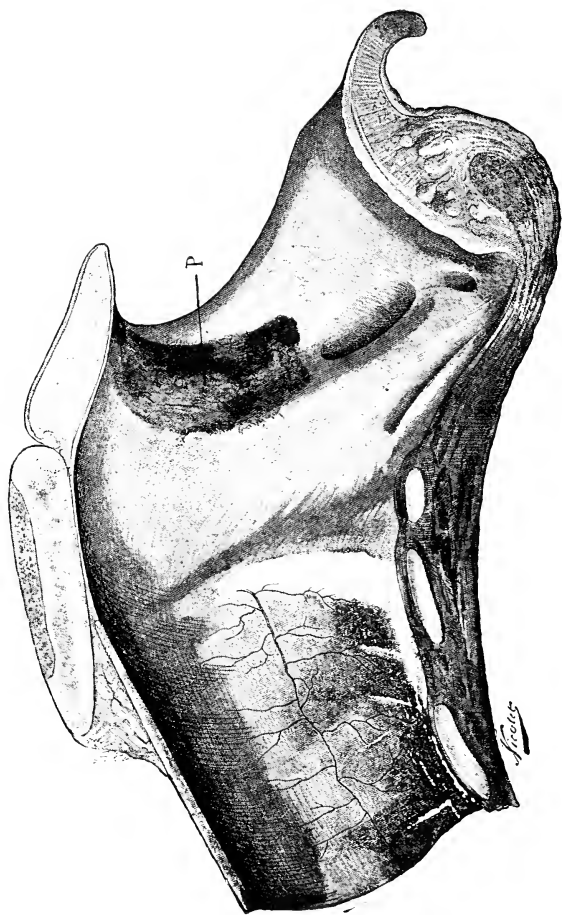


FIG. 18.—Antero-posterior section of the preceding larynx. P, wound.

rings, the separation of their extremities by retaining the canula too long in the trachea, the pressure exercised on the upper part of that conduit, and the extension of inflammation of the mucous membrane to the perichondrium are the causes of this accident. Partial ossification of the incised rings, of the cricoid, and of the thyroid results in every case; but it remains limited to the parts of the cartilages which surround the wound and leads to no deformity of the larynx.

6. *Shrinking of the Trachea at the Point of Application of the Elastic Balloon.*—This follows partial gangrene of the tracheal mucous membrane, and is the result of the pressure exercised on that membrane by the too great distension of the caoutchouc balloon. The fibrous new growth or neoplasm, which follows the casting off of the

dead tissue, rapidly acquires great proportions. The passage of the trachea may be so reduced in six weeks that the finger can only with difficulty be introduced. To prevent this accident the india-rubber ampulla should be but moderately filled, just sufficiently to close the trachea or use the tube surrounded with gauze.

7. *Persistent Cough and Rejection of Alimentary Matter and Drinking Water through the Nasal Cavities.*—These phenomena appear generally about the fourth week. The cough which mostly appears at the beginning, is occasioned by the abnormal irritability of the cicatricial tissues. As for the rejection of food stuffs through the nasal cavities, it results from the irregular cicatrisation of the anterior portion of the arytenoidean wound, producing an interference with the

action of the pharynx at the origin of the œsophagus.


Septicemia and tetanus are also two possible complications when sufficient care is not taken to avoid infection of the wound during and after the operation (instruments, fingers of the operator or his assistants, the articles necessary for dressing the wound, removal of the dressings, and the cleansing of the external wound).

Arytenotomy has been appreciated in various ways by those veterinarians who have practised it. At present I am not entirely decided as to its value, and before judging finally it is necessary to wait the teaching of experience. But, I will say it has given me a very encouraging proportion of successes, and in successful cases the cure of roaring is complete and lasting.

At the Central Veterinary Medical Society of France, sitting in Paris, Monsieur Cadiot, on behalf of M. Labat, Professor of the Toulouse Veterinary School, presented, on May 12th, 1892, the first of a series of notes and the results of six cases of chronic roaring operated on by him under Möller's system.

Out of the six cases, two were radically cured, one having the appearance of being cured was prematurely put to work and relapsed, two cases were much relieved, and the sixth patient died three days after the operation of a complication very much resembling the disease described by Loiset under the name of mechanical bronchitis (bronchorræ asphyxiante).*

* Vide *Recueil de Médecine Vétérinaire d'Alfort*, Series VII., Tome IX., No. 10, 30 Mai, 1892.





Albion Family Library of Veterinary Medicine
Cornell University School of Veterinary Medicine at
Tufts University
200 Northboro Road
North Grafton, MA 01536

