

UC-NRLF




B 4 613 968





~~PALaeONTOLOGY~~

EARTH  
SCIENCEs  
LIBRARY

EARTH  
SCIENCEs  
LIBRARY









*Shew.* STRANGWAYS'  
" "

# Veterinary Anatomy

---

FOURTH EDITION

---

REVISED AND EDITED

BY

I. VAUGHAN, F.I.S., F.Z.S.,

FELLOW OF, AND EXAMINER ON COMPARATIVE ANATOMY TO, THE ROYAL COLLEGE OF  
VETERINARY SURGEONS, LATE LECTURER ON ANATOMY AND ZOOLOGY  
AT THE NEW VETERINARY COLLEGE, EDINBURGH.



NEW YORK  
WILLIAM R. JENKINS  
VETERINARY PUBLISHER AND BOOKSELLER  
851 AND 853 SIXTH AVENUE

---

1904

EARTH  
SCIENCES  
LIBRARY

~~XXXXXXXXXX~~

Cat for Piles lib

Dept of Prof-ssn Camp



SF761  
S7  
1904

EARTH  
SCIENCES  
LIBRARY  
WV

TO

ENGLISH-SPEAKING

VETERINARY STUDENTS,


THIS, THE FOURTH EDITION OF

STRANGWAYS' ANATOMY

IS DEDICATED BY

THE EDITOR.

M774921



## PREFACE TO FOURTH EDITION.

---

THE Third Edition of STRANGWAYS' being exhausted, it is deemed advisable to issue a Fourth.


The work has been very carefully read and considered, with the result that little or no material alteration has been made. The diction has occasionally been improved, and a few alterations and additions made in the nomenclature where such appeared necessary.

Histology has become such a distinct branch of science, that the portions touching on that subject must, in a work like this, be somewhat brief and insufficient; but they have been modified and allowed to remain, as they may not prove altogether worthless.

I trust that this Edition of the work will maintain the reputation acquired by its immediate predecessors.

I. VAUGHAN.

EDINBURGH 29th April, 1892.



## PREFACE TO THE FIRST EDITION.

---

ON the death of Professor Strangeways, there was a very general feeling that his anatomical lectures should be given to the world. Working daily with him during my furlough, and being present at his death-bed, I was solicited to take the matter in hand. His friend, Dr. Call, and I accordingly undertook to re-write and arrange the lectures.

The late Professor Goodsir's detached manuscript on the Myology of the Horse was, after an effectual search, discovered, and considerately placed in my hands by his brother, the Rev. Joseph Taylor Goodsir, F.R.S.E. It is believed this will enhance the value of the work, more especially as Strangeways was not only an ardent admirer of the great anatomist, but he informed me his principal lectures had been perused and approved of by Professor Goodsir.

Strangeways' lectures, although generally very complete and excellent, demanded an entire recasting. In doing so, I adopted Leyh's arrangement, which, with due regard to French and English veterinary anatomy, I selected as the best.

Dr. Call, notwithstanding his many professional engagements, has re-written the Osteology and the Anatomy of the Nervous System, the Eye, and the Ear. The Comparative Osteology, the Ligaments, Muscles, Digestive, Urinary, Sexual, and Respiratory Organs, and the Organs of Circulation, Lymphatics, Skin, and Hoof, have fallen to my lot.

It has been our object to produce what is greatly desiderated—a thorough-going Manual of Anatomy for the veterinary student.

The photo-lithographs, with few exceptions, are selections from Leyh and Lecoq's classical works. To Dr. Morrison Watson, Assistant Demonstrator of Anatomy in Edinburgh University, my thanks are due for his assistance in arranging them during my absence on the Continent.

The Editors cordially thank Mr. Thomas H. Douglas, Photographer, Chamberlain Road, for his handsome gift of the Vignette of his friend, which will be appreciated by all the Professor's former students.

Messrs. Maclachlan & Stewart, the Publishers, deserve every praise for the generous manner in which they have undertaken the publication; and Messrs. Waterston, Hanover Street, for the style of the photo-lithographs.

To Professor Turner of Edinburgh University, and Mr. Joseph Johnston of Montrose, I am indebted for many valuable suggestions.

The work owes no small measure of its completeness to the kindly helping-hand of Dr. John Gray M'Kendrick, Assistant to the Professor of Physiology in the University of Edinburgh, who not only has been of immense service to me in the tedious work of proof correcting, but to whom the Editors are indebted for the complete Index and Glossary which accompanies the work.

The Appendices speak for themselves. The work would have been incomplete without a "dissection manual," and a translation was accordingly made of Chauveau's directions, adopted because they are superior to any I am acquainted with.

The Editors confidently commend the work to the veterinary student, farmer, stockbreeder, and to any and every one interested in domestic animals, inasmuch as the true pathological site of disease is incidentally pointed out *au courant* with the anatomical description. The Dentition Plates of the Horse, Cow, Sheep, and Dog afford a *coup d'œil* which will be a reminder to the

adept, and a useful guide to the veriest tyro in the difficult subject of dentition as an index of age.

It has been our effort to produce the work at the lowest remunerative rate commensurate with the interests of the deceased's family, to whom all benefit directly passes.

Assured that the student will find in these pages a good *quid pro quo* investment, we leave it with him, along with Seneca's advice and the sententious rule given by Sir William Hamilton in an autograph letter—

“Non multa sed multum.”

“Be more anxious to read attentively a few than to read many works.”

J. WILSON JOHNSTON.

KINNABER HOUSE,

24th September, 1869.





## PREFACE TO THE SECOND EDITION.

---

THE proprietor of Strangeways' Anatomy having resolved on issuing a new and revised edition of the work, placed the matter in my hands, with a *carte blanche* to do what I thought most advisable. This I have striven to the best of my ability to do; whether successfully or not, the dictum of future students alone will decide, since for them the work is designed.

Books on Anatomy seem naturally to divide themselves into three classes—the exhaustive work for reference, the practical dissecting manual, and the current text-book. In the veterinary department of Anatomy, the first of these classes is represented by Mr. Fleming's well-known edition of "Chauveau," the second by Mr. Steel's "Outlines of Equine Anatomy," while the third is represented by the works of Percivall and Strangeways.

In the present edition of Strangeways I have separated the matter into headed paragraphs and chapters; the Comparative Anatomy being inserted in sections, each at the end of its proper chapter, and, to avoid error in rapid reference, printed in smaller type. The Introduction is my own, Dr. Strangeways' introductory lecture being by some means omitted from the first edition. Other portions of the work which I have added I need not enumerate here, nor yet certain other portions which have been expunged.

The photo-lithographic illustrations to the first edition, not being part of the copyright, were not forthcoming, but I have

succeeded in procuring electrotype copies of all the original cuts, which were required, from the French edition of Leyh's Anatomy, and so venture to hope that the work has not suffered in that respect; my thanks are due to M. Asselin for this, and also to Messrs. Churchill, and Messrs. Routledge & Co., for the electros kindly supplied by them. An attempt has also been made by Messrs. Banks to reproduce, with certain modifications, the admirable anatomical plates of M. Mégnin. A few minor illustrations have been cut specially for the work.

I have to thank Dr. F. E. Rice, of Springfield, Mass., U.S., for much valuable assistance in indexing, and passing the work through the press; and Mr. J. J. Fraser, of the New Veterinary College, Edinburgh, for assistance in many ways. And I must also acknowledge with thanks some useful suggestions given to me by Mr. Robertson, F.R.C.V.S., of Kelso, and by Principal Williams. Messrs. Bell & Bradfute, the publishers, and Messrs. Lorimer & Gillies, the printers of the work, deserve much thanks for the kind manner in which they have assisted me in a rather tedious undertaking.

I venture to hope that the matter of the book is as correct as can reasonably be expected in a performance of the kind; that the arrangement is such as to prevent confusion, and consequent loss of time to those who may consult it; that the book in its present form may, to some extent, meet the ordinary anatomical requirements of the veterinary curriculum of the present day; and finally, that the student who wishes to go deeper into the subject, may by it be prepared for the consultation of more exhaustive treatises.

I. VAUGHAN.

GAYFIELD HOUSE,  
EDINBURGH, 15th September, 1879.

## PREFACE TO THE THIRD EDITION.

---

IN the present edition, the general plan of the work has not been altered in any way ; and so far from attempting to enlarge or elaborate the matter of the last edition, I have tried, when practicable, rather to reduce or condense it ; for I am of opinion that of all other books, the one designed as a text-book on a scientific subject should be as free as possible from that obtrusive prolixity or *pudding*, which tends to influence in an unsatisfactory way both the patience and pocket of the student. The present edition is a trifle larger than the last, due to the addition of a few small sections which appeared necessary, and to the insertion of a number of extra cuts. The majority of the added illustrations are electrotypes from Franck's edition of Leyh's work, to the publishers of which, Messrs. Shickhardt & Ebner, my acknowledgments are due, as also to Mr. Renshaw, Messrs. Churchill & Co., and Messrs. Macmillan & Co., for various clichés from the works of Milne Edwards, Huxley, and Mivart. The plates will, I think, from an artistic point of view, be found greatly superior to those of the second edition, they having been engraved specially for the present one.

I have received assistance, alike varied and valuable, from Professor Lewis, of Edinburgh, which I beg here to acknowledge, and especially his trouble in drawing up and arranging the article on foetal development—the last in the book. Professor

W. O. Williams has also given me very useful assistance, in reading the sheets, and rearranging the index.

The favourable reception which the last edition received, might be said to promise well for the success of the present edition; and knowing that no pains have been spared either in the revision, the correction, or in the printing of the work, I trust that STRANGWAYS' VETERINARY ANATOMY as thus issued will not suffer in its reputation as a students' text-book.

I. VAUGHAN.

EDINBURGH, 14th October, 1885.

# TABLE OF CONTENTS.

## INTRODUCTION.

	PAGE
<b>ANATOMY,</b> . . . . .	1
Vertebrata, . . . . .	3
Domesticated Mammals, . . . . .	4
Domesticated Aves, . . . . .	5
Descriptive Anatomy, . . . . .	6

## CHAPTER I.

<b>OSTEOLOGY,</b> . . . . .	7
Structure of bone, . . . . .	7
Osseous tissue, . . . . .	9
Classes of bones, . . . . .	12
<b>THE SKELETON,</b> . . . . .	17
Axial Skeleton, . . . . .	21
Vertebræ, . . . . .	21
The Ribs, . . . . .	33
The Sternum, . . . . .	35
General view of the Skull, . . . . .	37
Cranial bones, . . . . .	45
Facial bones, . . . . .	54
<b>APPENDICULAR SKELETON,</b> . . . . .	65
Pectoral arch and limb, . . . . .	66
Pelvic arch, . . . . .	83
Pelvic limb, . . . . .	88
<b>COMPARATIVE OSTEOLOGY,</b> . . . . .	98
Ruminantia, . . . . .	98
Omnivora, . . . . .	105
Carnivora, . . . . .	109
Rodentia, . . . . .	114
Aves, . . . . .	115

## CHAPTER II.

	PAGE
ARTHROLOGY, . . . . .	120
General Anatomy, . . . . .	120
Classes of joints, . . . . .	125
Motion in joints; . . . . .	128
ARTICULATIONS OF THE AXIAL SKELETON, . . . . .	129
Vertebral articulations, . . . . .	129
Articulations of the Skull, . . . . .	134
ARTICULATIONS OF THE APPENDICULAR SKELETON, . . . . .	136
Pectoral limb, . . . . .	136
Pelvis and pelvic limb, . . . . .	143
COMPARATIVE ARTHROLOGY, . . . . .	151

## CHAPTER III.

MYOLOGY, . . . . .	155
Muscular tissue, . . . . .	155
Tendons, . . . . .	158
Fascia, . . . . .	159
Muscular nomenclature, . . . . .	160
Classification of muscles, . . . . .	160
Subcutaneous region, . . . . .	161
The Head, . . . . .	162
The Trunk, . . . . .	178
Pectoral limb, . . . . .	212
Pelvic limb, . . . . .	231
Arrangement of the fasciæ, . . . . .	252
Table of muscular attachments, . . . . .	256
COMPARATIVE MYOLOGY, . . . . .	260

## CHAPTER IV.

SPLANCHNOLOGY, . . . . .	270
Epithelium, . . . . .	270
Mucous membranes, . . . . .	272
Serous membranes, . . . . .	273
Glands, . . . . .	274
DIGESTIVE SYSTEM, . . . . .	275
Alimentary canal, . . . . .	275
Mouth, . . . . .	276
Palate, . . . . .	277
Tongue, . . . . .	280
Salivary glands, . . . . .	285
Teeth, . . . . .	288

	PAGE
<b>DIGESTIVE SYSTEM—continued.</b>	
Pharynx, . . . . .	296
Œsophagus, . . . . .	298
Abdomen, . . . . .	300
Stomach, . . . . .	301
Intestines, . . . . .	304
Accessory organs of digestion, . . . . .	312
Liver, . . . . .	312
Pancreas, . . . . .	318
Spleen, . . . . .	319
Peritoneum, . . . . .	321
<b>RESPIRATORY SYSTEM,</b> . . . . .	323
Nostrils, . . . . .	323
Nasal chambers, . . . . .	325
Larynx, . . . . .	327
Trachea, . . . . .	334
Thyroid and Thymus glands, . . . . .	335
Bronchi, . . . . .	335
Thorax, . . . . .	336
Pleuræ, . . . . .	337
Lungs, . . . . .	337
<b>URINARY SYSTEM,</b> . . . . .	340
Kidneys, . . . . .	340
Ureters, . . . . .	343
Bladder, . . . . .	344
<b>GENERATIVE SYSTEM,</b> . . . . .	345
Male Organs, . . . . .	346
Scrotum, . . . . .	347
Spermatic cord, . . . . .	347
Testicle, . . . . .	348
Vas deferens, . . . . .	350
Prostate gland, . . . . .	351
Cowper's glands, . . . . .	352
Urethra, . . . . .	352
Penis, . . . . .	353
Seminal fluid, . . . . .	356
Female Organs, . . . . .	357
Ovary, . . . . .	357
Fallopian tubes, . . . . .	358
Uterus, . . . . .	359
Vagina, . . . . .	361
Vulva, . . . . .	361
Mammary glands, . . . . .	363
<b>COMPARATIVE SPLANCHNOLOGY,</b> . . . . .	365

## CHAPTER V.

	PAGE
ANGIOLOGY, . . . . .	387
BLOOD-VASCULAR SYSTEM—Blood, . . . . .	387
Heart, . . . . .	388
Pericardium, . . . . .	397
Course of circulation, . . . . .	397
ARTERIES. . . . .	398
Capillaries, . . . . .	400
Pulmonary artery, . . . . .	400
Common aorta, . . . . .	401
Posterior aorta, . . . . .	402
Internal iliac, . . . . .	409
External iliac, . . . . .	411
Anterior aorta, . . . . .	418
Brachial artery, . . . . .	418
Cephalic and Carotid arteries, . . . . .	424
VEINS, . . . . .	433
Pulmonary and Systemic, . . . . .	435
Posterior cava, . . . . .	436
Portal vein, . . . . .	437
Iliac veins, . . . . .	438
Anterior cava, . . . . .	442
Brachial vein, . . . . .	444
Jugular vein, . . . . .	446
LYMPHATIC SYSTEM—Vessels, . . . . .	449
Glands, . . . . .	450
Lymph and Chyle, . . . . .	451
Thoracic duct, . . . . .	451
Lymphatics of posterior region, . . . . .	452
abdominal viscera, . . . . .	454
thoracic viscera, . . . . .	455
thoracic walls, . . . . .	456
anterior region, . . . . .	456
Lymphatic vein, . . . . .	458
COMPARATIVE ANGIOLOGY, . . . . .	458

## CHAPTER VI.

NEUROLOGY, . . . . .	465
Nervous tissue, . . . . .	466
Nerves, . . . . .	467



TABLE OF CONTENTS.

xxi

PAGE

CEREBRO-SPINAL SYSTEM—Meninges, . . . . .	468
Spinal cord, . . . . .	471
Brain, . . . . .	473
Encephalic circulation, . . . . .	485
Cranial nerves, . . . . .	490
Spinal nerves, . . . . .	502
Brachial plexus, . . . . .	508
Lumbo-sacral plexus, . . . . .	511
 SYMPATHETIC SYSTEM—Cephalic portion, . . . . .	 515
Cervical portion, . . . . .	516
Thoracic portion, . . . . .	519
Lumbar portion, . . . . .	521
Sacral portion, . . . . .	521
 COMPARATIVE NEUROLOGY, . . . . .	 522

CHAPTER VII.

ÆSTHESIOLOGY, . . . . .	525
-------------------------	-----

ORGANS OF SPECIAL SENSE.

THE EAR—External ear, . . . . .	525
Middle ear, . . . . .	526
Internal ear, . . . . .	529
THE EYE—Tunics, . . . . .	532
Humours, . . . . .	536
Muscles, . . . . .	537
Appendages, . . . . .	538

ORGANS OF SENSATION.

THE SKIN AND ITS APPENDAGES—Skin, . . . . .	541
Hair, . . . . .	543
Foot—Hoof, . . . . .	544
Soft parts of the foot, . . . . .	549
COMPARATIVE ÆSTHESIOLOGY, . . . . .	552

CHAPTER VIII.

EMBRYOLOGY, . . . . .	556
Ovum after Fecundation, . . . . .	556
Placenta, . . . . .	557
Umbilical cord, . . . . .	558
Fœtal circulation, . . . . .	559
Development of Fœtus, . . . . .	561

## APPENDIX.

	PAGE
I. General directions for dissection, . . . . .	565
II. On a supernumerary oblique muscle of the eyeball, . . . . .	575
III. On a muscle connected with the orbital periosteum, . . . . .	577
INDEX, . . . . .	583

## TABLE OF ILLUSTRATIONS.

PLATE		PAGE
I.	Skeleton of Horse, . . . . . opposite page	21
„	II. Muscles of Horse—superficial layer, . . . . .	161
„	III. Muscles of Horse—deep layer, . . . . .	193
„	IV. Digestive and Urinary Organs of Horse, . . . . .	274
„	V. Heart and chief blood-vessels of Horse, . . . . .	400
„	VI. Nervous System of Horse, . . . . .	503

**FIG.**

1.	Transverse sections through the body of a vertebrate and an invertebrate animal—diagramatic, . . . . .	3
2.	Transverse section of bone, . . . . .	9
3.	Longitudinal section of bone, . . . . .	10
4.	Lacunæ of bone, . . . . .	10
5.	Section of ossifying cartilage, . . . . .	16
6.	Skeleton of Horse, . . . . .	18
7.	Transverse vertebral segment, . . . . .	22
8.	Cervical vertebræ articulated, . . . . .	24
9.	Cervical vertebra . . . . .	25
10.	Skull seen from above, . . . . .	37
11.	Inferior aspect of skull, . . . . .	39
12.	Lateral view of the skull, . . . . .	41
13.	Longitudinal section of the skull, . . . . .	43
14.	Inferior maxilla, . . . . .	62
15.	Bones of the hyoid series, . . . . .	64
16.	Bones of the carpus, . . . . .	72
17.	Bones of the carpus, metacarpus, and digit, . . . . .	73
18.	Development of foot, . . . . .	77
19.	Phalanges disarticulated, . . . . .	79
20.	Lateral aspect of pelvis, . . . . .	85
21.	Posterior aspect of femur, . . . . .	89
22.	Bones of tarsus, . . . . .	94
23.	Bones of tarsus, metatarsus, and digit, . . . . .	96

FIG.	PAGE
24. Posterior aspect of metatarsus, . . . . .	97
25. Skeleton of Ox, . . . . .	99
26. Skull of Ox, . . . . .	100
27. Cardiac bone of Ox, . . . . .	104
28. Skull of Boar, . . . . .	105
29. Skeleton of Hog, . . . . .	106
30. Section of Hog's skull, . . . . .	107
31. Skeleton of Dog, . . . . .	110
32. Bones of Digits compared, . . . . .	113
33. Clavicle of Dog, . . . . .	113
34. Clavicle of Cat, . . . . .	113
35. Os penis of Dog, . . . . .	114
36. Skeleton of Bird, . . . . .	116
37. Sternum of Bird, . . . . .	116
38. Skull of Fowl, . . . . .	117
39. Pectoral arch of Bird, . . . . .	118
40. Pelvis of Bird, . . . . .	118
41. Hyaline cartilage, . . . . .	121
42. White fibrous tissue, . . . . .	123
43. Yellow elastic tissue, . . . . .	123
44. Adipose tissue, . . . . .	124
45. Diarthrodial joint—diagram, . . . . .	127
46. Odontoid and superior coracoid ligaments, . . . . .	131
47. Costo-vertebral articulation—lateral aspect, . . . . .	133
48. Costo-vertebral articulation—superior aspect, . . . . .	133
49. Temporo-maxillary articulation, . . . . .	135
50. Hyoid articulations, . . . . .	135
51. Ligaments of elbow joint, . . . . .	136
52. Ligaments of carpus—anterior, . . . . .	137
53. Deep ligaments of carpus—external, . . . . .	138
54. Deep ligaments of carpus—postero-internal, . . . . .	139
55. Superficial ligaments of carpus—posterior, . . . . .	140
56. Sesamoidean and digital ligaments, . . . . .	141
57. Deep sesamoidean ligaments, . . . . .	141
58. Navicular ligaments, . . . . .	143
59. Sacral and pelvic ligaments, . . . . .	144
60. Sacral and pelvic ligaments—inferior view, . . . . .	144
61. Ligaments of hip joint, . . . . .	145
62. Ligaments of stifle joint, . . . . .	146
63. Ligaments of stifle joint—posterior view, . . . . .	147
64. Ligaments of tarsus—postero-internal view, . . . . .	149
65. Ligaments of tarsus—antero-external view, . . . . .	150
66. Striated muscular fibres and tendon, . . . . .	156
67. Muscular fibrillæ, . . . . .	156
68. Striated muscular fibres, . . . . .	157
69. Non-striated muscular fibres, . . . . .	158

FIG.	PAGE
70. Muscles of head—lateral view, . . . . .	165
71. Muscles of maxillary space, . . . . .	171
72. Muscles of external ear, . . . . .	175
73. Lateral cervical muscles, . . . . .	185
74. Occipito-atlo-axoid muscles, . . . . .	188
75. Pectoral muscles, . . . . .	195
76. Sublumbar and internal femoral muscles, . . . . .	206
77. Diaphragm, . . . . .	209
78. External muscles of anterior limb, . . . . .	213
79. Internal muscles of anterior limb, . . . . .	216
80. Deep muscles of arm, . . . . .	223
81. Flexor muscles of fore-foot, . . . . .	227
82. Section of digit, . . . . .	229
83. Deep muscles of hip, . . . . .	233
84. Muscles of thigh and haunch, . . . . .	240
85. Anterior tibial muscles, . . . . .	246
86. Posterior tibial muscles, . . . . .	250
87. Tendons and ligaments of Ox's extremity, . . . . .	262
88. Epithelial cells, . . . . .	270
89. Ciliated epithelium, . . . . .	271
90. Muscles of tongue, palate, and pharynx, . . . . .	279
91. Parotid and molar glands, . . . . .	285
92. Mouth and salivary glands, . . . . .	286
93. Dentine, . . . . .	289
94. Enamel, . . . . .	290
95. Incisor and canine teeth, . . . . .	292
96. Structure of incisor tooth, . . . . .	292
97. Structure of molar tooth, . . . . .	294
98. Stomach, . . . . .	301
99. Internal aspect of stomach, . . . . .	303
100. The mesenteries, . . . . .	305
101. Section of mucous membrane of intestine, . . . . .	306
102. Chyle magnified, . . . . .	307
103. Cæcum and great colon, . . . . .	309
104. Liver and diaphragm, . . . . .	313
105. Hepatic lobules magnified, . . . . .	316
106. Biliary and pancreatic ducts, . . . . .	317
107. Pancreas, . . . . .	318
108. Spleen, . . . . .	319
109. Relations of abdominal viscera, . . . . .	320
110. Framework of nostril, . . . . .	324
111. Longitudinal section of head, . . . . .	326
112. Epiglottis, . . . . .	329
113. Ligaments of larynx—posterior view, . . . . .	330
114. Ligaments of larynx—anterior view, . . . . .	330
115. Muscles of larynx—lateral view, . . . . .	332

FIG.	PAGE
116. Deep muscles of larynx—lateral view, . . . . .	333
117. Larynx laid open, . . . . .	334
118. Respiratory organs, . . . . .	336
119. Capillaries of lung, . . . . .	339
120. Section of kidney, . . . . .	340
121. Structure of kidney, . . . . .	341
122. Distribution of renal artery, . . . . .	342
123. Male generative organs, . . . . .	346
124. Testicle, . . . . .	348
125. Diagram of structure of testicle, . . . . .	349
126. Bladder and urethra, . . . . .	353
127. Female urino-genital organs, . . . . .	357
128. Female generative organs, . . . . .	360
129. Stomach of Ox, . . . . .	367
130. Stomach of Sheep, . . . . .	368
131. Ruminant stomach opened, . . . . .	369
132. Stomach of Musk Deer, . . . . .	371
133. Mesentery and intestines of Ox, . . . . .	372
134. Cæcum of Ox, . . . . .	372
135. Liver of Ox, . . . . .	373
136. Kidney of Ox, . . . . .	375
137. Section through vagina and bladder of Cow, . . . . .	376
138. Teeth of Hog, . . . . .	377
139. Stomach of Hog, . . . . .	377
140. Cæcum and colon of Hog, . . . . .	378
141. Liver of Hog, . . . . .	379
142. Kidney of Hog, . . . . .	379
143. Teeth of Carnivora, . . . . .	381
144. Stomach of Dog, . . . . .	381
145. Cæcum and colon of Dog, . . . . .	381
146. Stomach, liver, &c., of Dog, . . . . .	382
147. Teeth of Rodent, . . . . .	383
148. Alimentary canal of Bird, . . . . .	385
149. Urino-genital organs of Bird, . . . . .	386
150. Right side of heart—opened, . . . . .	390
151. Left side of heart—opened, . . . . .	393
152. Muscular fibres from heart, . . . . .	395
153. Diagram of circulation, . . . . .	397
154. Heart and large vessels <i>in situ</i> , . . . . .	402
155. Abdominal branches of posterior aorta, . . . . .	405
156. Arteries of cæcum and colon, . . . . .	406
157. Breaking up of posterior aorta, . . . . .	408
158. Distribution of internal iliaes, . . . . .	410
159. Arteries of thigh, . . . . .	413
160. Arteries of leg, . . . . .	415
161. Arteries of neck, . . . . .	419

FIG.	PAGE
162. Arteries of fore-limb, . . . . .	421
163. Arteries of head, . . . . .	428
164. Facial arteries, . . . . .	429
165. Posterior vena cava, . . . . .	436
166. Portal system, . . . . .	438
167. Heart and great veins, . . . . .	443
168. Veins of face and neck, . . . . .	448
169. Section of lymphatic gland, . . . . .	450
170. Lymphathic trunks, . . . . .	452
171. Circulation in Reptile, . . . . .	463
172. Circulation in Fish, . . . . .	464
173. Circulation in Crustacean, . . . . .	464
174. Nerve tissue, . . . . .	466
175. Pacinian body, . . . . .	467
176. Section of spinal cord, . . . . .	472
177. Base of brain, . . . . .	474
178. Brain viewed from above, . . . . .	477
179. Lateral ventricles, . . . . .	481
180. Cavities of brain—diagramatic, . . . . .	483
181. Brain laid open, . . . . .	484
182. Diagramatic section of brain, . . . . .	485
183. Encephalic arteries, . . . . .	486
184. Arteries at base of brain, . . . . .	487
185. Origins of cranial nerves, . . . . .	491
186. Nerves of eye, . . . . .	493
187. Fifth nerve, . . . . .	495
188. Facial nerves, . . . . .	497
189. Posterior nerves of head, . . . . .	501
190. Brachial plexus, . . . . .	509
191. Carpal and metacarpal nerve, . . . . .	510
192. Lumbo-sacral plexus, . . . . .	513
193. Tarsal and metatarsal nerves, . . . . .	514
194. Sympathetic ganglion, . . . . .	515
195. Nerves of thorax, . . . . .	517
196. Abdominal nerves, . . . . .	519
197. Conchal and annular cartilages, . . . . .	526
198. Scutiform cartilage, . . . . .	526
199. Mallets, . . . . .	527
200. Incus, . . . . .	527
201. Stapes, . . . . .	527
202. Tympanum, . . . . .	528
203. Diagram of ear, . . . . .	529
204. Membranous labyrinth, . . . . .	531
205. Diagram of eye, . . . . .	532
206. Globe of eye, . . . . .	533
207. Globe of eye—partly opened, . . . . .	533

FIG.	PAGE
208. Pigment cells, . . . . .	534
209. Iris, . . . . .	535
210. Globe of eye—opened, . . . . .	536
211. Hoof, . . . . .	546
212. Solar aspect of hoof, . . . . .	547
213. Section of horn-tissue, . . . . .	548
214. Sensitive foot—solar aspect, . . . . .	550
215. Sensitive wall, . . . . .	551
216. Fœtus of Cow, . . . . .	558
217. Fœtus of Bitch, . . . . .	559
218. Fœtal circulation, . . . . .	560

---



## INTRODUCTION.

**BIOLOGY**, the comprehensive science which treats of living or organised bodies, is divisible into two parts, the one dealing with the Vegetable, the other with the Animal Kingdom. Animal Anatomy, or Zoötomy, has for its object the investigation of the animal frame, an investigation conducted by mechanically dividing it into its component parts, and studying their form, structure, attachments, and relations. Anatomy may be Comparative, Special, or Transcendental, according to the scope and ultimate object in view. Thus, if more than one species of animal be under consideration, the comparative anatomist takes note of their various deviations and similarities; but, if the investigations be confined to one variety of animal, as in Human Anatomy, the subject then becomes special. When Special Anatomy leads to the thorough investigation of one single variety, for the purpose of comparing other classes with it, the subject of such special study is termed a *type*.

Comparative Anatomy, therefore, is not studied by the indiscriminate comparison of one class with another, but by referring them to certain types or standards. Embracing as it does the structural investigation of the whole animal kingdom, Comparative Anatomy is closely related to the science of Zoology, the latter science aiming especially at the attainment of a scientific method of classification. Transcendental or Philosophical Anatomy seeks for analogies and developmental facts, which may guide the investigator in his search after primary anatomical types. Since the prosecution of such a study must assume a more or less profound knowledge of Comparative Anatomy, this

abstruse branch of the science is merely alluded to here in passing.

If we consider a portion of the animal body with respect to its form, size, relative position, or structure, we are said to consider it *anatomically*; but should we inquire into the use or function of such portion, or seek to know the changes undergone by it while in a living condition, then we are investigating it *physiologically*. Such is a general distinction between the sciences of Anatomy and Physiology; but it will readily be seen that they are to a great extent bound up in one another, since both the sciences must lend their aid to afford a complete description of any given organ or part. The branch treating solely of structure and form is termed MORPHOLOGY. HISTOLOGY, otherwise called General or Minute Anatomy, treats of the intimate structure of the *tissues* or materials of which the various parts of the body are composed. As the tissues present certain characteristics invisible to the naked eye, the microscope is largely employed by the histologist in his investigations. EMBRYOLOGY, from an anatomical point of view, is a science considering the various appearances presented by an animal after each of the many successive stages of its development,—from when it first appears as a mere speck of vitality until it has acquired the general characteristics of a perfect animal.

Anatomy, in all the above-mentioned branches, deals only with normal or healthy material; but should such material be in a diseased condition, the consideration of the changes it has consequently undergone is termed Morbid Anatomy. Surgical Anatomy embraces the description and investigation of such parts of the body as are most liable to be involved in surgical operations. The surgeon, by a competent knowledge of this branch of the subject, is enabled to operate with the maximum of safety and expedition, together with the minimum of pain and inconvenience to the patient.

Anatomy in either of its aspects may be descriptive or practical. In the former, the student relies on books, diagrams, lectures, &c., for his information; in the latter, he verifies descriptions by actual dissection and demonstration of the various structures in question.

Veterinary Anatomy, in the full sense of the word, includes the anatomy of all the domesticated animals, and is, therefore, a branch of the comparative science, and the animal usually

referred to as its type is the Horse, the Anatomy of which animal, or Hippotomy, is primarily considered in this work, while the deviations from the type, which make up the comparative branch of the subject, will be noted in their more important features, as fully as the scope of the work will permit.

## VERTEBRATA.

As all the domesticated animals belong to the sub-kingdom VERTEBRATA, it is of importance to gain a clear idea of the leading characteristics of a vertebrate animal; and, except in one or two of the lowest orders, these are well marked.

The animal kingdom is divided into the sub-kingdoms INVERTEBRATA and VERTEBRATA. As the names would imply, the latter is distinguished from the former by its members possessing a vertebral column, or backbone, which forms, as it were, the axis of the bony framework, supports the head, and is placed dorsally, or in the region of the back, extending from one end of the body to the other. It is pierced throughout the greater part of its extent by a canal called the *neural canal*, which is continuous with a cavity in the head called the *cranium*. These cavities are occupied by centres, from which radiate the large series of nerves termed the *cerebro-spinal system*. Underneath the backbone there is a second series of nerve-centres—those of the *sympathetic system*. Thus in a vertebrate animal there are *two systems of nerves, whose centres are separated by a partition of bone*.

The remaining portion of the animal body may be regarded as a second cavity, or canal, which contains, in addition to the sympathetic system of nerves, the *alimentary* and the *hæmal systems*. The former runs the whole length of the body, being a canal which gives passage to the food; the latter consists of

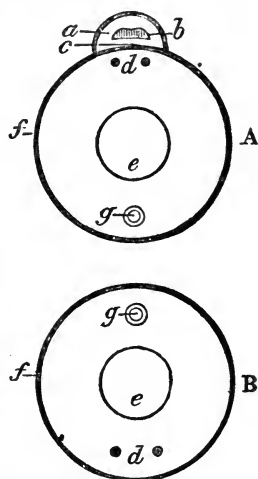


FIG. 1.

A, Diagrammatic transverse section through the body of a vertebrate. B, A similar section through a highly-organised invertebrate animal.

a, Neural Canal; b, Cerebro spinal nerve-centres; c, Notochord; d, Sympathetic nerve-centres; e, Alimentary canal; f, Visceral canal wall; g, Hæmal system.—After NICHOLSON.

a series of tubes. by which the blood passes through the body, both systems being supplied with many accessory organs.

In the higher invertebrate animal we find no backbone, no neural canal, and no cerebro-spinal system of nerves; but the visceral canal exists, and its contents correspond mostly with the structures found in the vertebrate. (See Fig. 1.) The lowest vertebrate animals known—the Lancelet, or *Amphioxus*, and the Lamprey—have no vertebral column, but they possess throughout life a soft, gelatinous structure, the *notochord*, from which, in the higher vertebrates, the column becomes early developed. These may be regarded as exceptional or undeveloped forms.

If we eliminate from the Vertebrata all the classes but the two highest—the MAMMALIA and AVES—we shall further localise our subject, since these two classes contain all the animals which, as a rule, engage the attention of the veterinary anatomist, to whom the first of the two is of by far the greater importance.

#### DOMESTICATED MAMMALS.

It is sufficient to state that the Mammalia are characterised by the females being provided with an apparatus which supplies milk for the nourishment of their young after birth.

The horse, ass, ox, sheep, goat, camel, llama, pig, elephant, dog, cat, and rabbit are the mammalian vertebrates, usually included in the term “domesticated animals.” The first eight of these belong to one of the most important of the natural orders, the *Ungulata*, or hoofed animals. The camel, llama, and elephant, not being domesticated, in the proper sense of the word, in Europe, the scope of the present work will not permit separate sections to be devoted to their description.

#### UNGULATA.

The *Ungulata* which included the *hoofed quadrupeds*, is a very large and important order, divided into two parts. One section, the *Perissodactyla*, includes the animals having an odd number of toes or digits; the other, the *Artiodactyla*, containing those with an even number.

#### PERISSODACTYLA.

*Equidæ* or *Solidungula*.—The horse and ass are referred, in the section *Perissodactyla*, to this family, which includes only the two genera *Equus* and *Asinus*: their most prominent external feature is the possession of only one perfect digit or finger on each extremity. Apparently there is but one clearly defined species in the genus *Equus*, the features presented by the varieties which are

known as "breeds" being, in all probability, due to the prolonged influence of external circumstances, such as locality, treatment, climate and selection. In the Equidæ the stomach is simple and comparatively small.

## ARTIODACTYLA.

*Ruminantia*.—The ox, sheep, goat, camel, and llama belong to this section of ruminating animals, so named from their habit of remasticating their food. They are all cloven-footed, or have two digits. Very generally the skull of the ruminant is provided with a pair of horns; and the ox, sheep, and goat are classed as *Cavicornia*, their horns being hollow, and supported on bony cores. Ruminants are mostly without front teeth in the upper jaw, and their stomach is very large and complex.

*Omnivora*.—The pig is classed in this section. Its teeth are of a mixed order, calculated to deal with many kinds of food, hence the name *Omnivora*. The canine or eye teeth are very prominent, and in the male they project considerably as "tusks," which in the wilder varieties are formidable weapons. The stomach is intermediate in complexity between that of the ruminant and that of the horse. This animal has four digits, two long and two short on each extremity. The nose, or snout, is prominent, and rather cylindrical in form.

## CARNIVORA.

Unlike any of the above-named animals, the dog and cat are placed in this natural order, an order characterised by large canine teeth, and by there being no lateral or grinding motion between the jaws. The anterior extremity is supplied with five, the posterior with four or five digits, which are terminated by sharp or blunt, retractile or non-retractile claws. The stomach is small, and the intestine comparatively short.

## RODENTIA.

This natural order, to which the rabbit belongs, although an extensive order, is sufficiently distinguished by the possession of two large chisel-shaped incisor or front teeth, which are found in each jaw, the canine teeth being altogether wanting.

## DOMESTICATED AVES.

Birds are distinguished from Mammals by their producing their young oviparously, or by hatching the egg outside the body.

They never suckle their young, and have a covering of feathers. Such of these as we have to allude to belong either to the natural order RASORES or to the NATATORES. the former including the terrestrial birds and pigeons, the latter the various aquatic species. distinguished by their *web feet*.

#### DESCRIPTIVE ANATOMY.

*Osteology* is a term applied to that section of descriptive anatomy which treats of the bones. *Arthrology* to the consideration of the joints or modes of union between the bones. while by *Myology* is meant the doctrine of the muscular system. *Splanchnology* treats of the viscera, *Angiology* of the circulatory and absorbent systems. *Neurology* deals with the nervous system. *Æsthesiology* with the organs of sense; while *Embryology*, as before stated. is the consideration of the animal frame at periods preceding its birth. In this work the various departments are discussed in the order here given. The structures which are the subjects of the first three divisions are sometimes classed together as the *Organs of Locomotion*, for bones form the framework of the body and often act as levers; the joints connect the bones, permitting more or less motion between them; while the muscles move the bones, and so produce *motion* of a part of the body—or it may be *locomotion*, or change of situation in the entire frame.

In the study of Comparative Anatomy the terms *analogy* and *homology* are frequently met with. Although these words are not unfrequently used indiscriminately, the following difference should be noted. Organs are said to be *analogous* when, though differing in structure. they perform the same function; but when their functions are different, while. in the broad sense. they correspond in structure or form. they are said to be *homologous*. Thus the middle finger of the human hand is the homologue of the anterior digit of a horse. because they have the same general structure, and relation to the rest of the limb; but as the functions they perform are quite dissimilar. they cannot be termed analogous. Again, the lungs of a mammal are analogous to the gills of a fish. for, though they differ widely in structure, position, and form, and are therefore not homologous, their ultimate use is the same—each of them being an apparatus in which is carried on the process of purifying the blood.

## CHAPTER I.

### OSTEOLOGY.

#### STRUCTURE OF BONE.

BONES are hard, yellowish-white, insensitive bodies, which form the internal or *endoskeleton*. give attachment to soft structures, and are of various sizes, forms, and densities. In the limbs the bones are usually more or less cylindrical, with expanded extremities, and not only effectually support the body, and afford leverage and attachment to the muscles, but, by uniting, form the articulations or joints. Where cavities, such as the cranium, chest and pelvis, enclose viscera requiring protection and support, the bones tend to assume a flat, expanded form.

Living bone is bluish pink, insensitive, and elastic; on exposure to air it becomes diseased, assumes a black or livid hue, and is extremely sensitive and painful; the teeth excepted, it is harder and of a higher specific gravity than any other animal tissue. Consisting as it does of inorganic salts deposited in a basis of animal matter, to the former it owes its density and hardness, to the latter, its elasticity and tenacity—the union rendering the tissue solid and elastic enough to obviate fracture from ordinary causes. Its components are so intimately blended that, to the naked eye, it appears homogeneous, but, by steeping in dilute hydrochloric, or other strong mineral acid, the earthy matter is dissolved, while the tough flexile animal cast is left. Again, if we expose it to the action of heat we get rid of the animal matter, and a white, brittle, earthy, chalky substance is left, retaining its original shape.

The relative proportions of animal and earthy matter vary at different periods of life. In the young, the organic constitutes nearly one-half of the bone; in the adult, it diminishes to about a third, while in old animals it is still less; hence the bones of very old animals are brittle, and more liable to fracture.

The animal and earthy proportions do not vary in the true bone tissue, but there is a gradual filling up of the cavities originally occupied by fat cells, thus condensing the bone. The earthy ingredients consist chiefly of carbonate and phosphate of lime; the animal matter of cartilage and connective tissue, vessels, membranes lining the cancellated structure and medullary cavities, and a quantity of fat. The following is an average analysis of osseous tissue by Von Bibra :—

	Femur of 4-year old Sheep.	Femur of 4-year old Bull.	Femur of 6-year old Horse.	Humerus of 6-year old Cat.
Phosphate of Lime, with trace of } Fluoride Calcium, . . . . }	55.94	54.07	54.37	59.30
Carbonate of Lime, . . . .	12.18	12.71	12.00	10.69
Phosphate of Magnesia, . . . .	1.00	1.42	1.83	1.70
Soluble Salts, . . . .	0.50	0.80	0.70	0.40
	69.62	69.00	68.90	72.09
Cartilage, . . . . .	29.68	29.09	27.99	27.21
Fat, &c., . . . . .	0.70	1.91	3.11	0.70
	30.38	31.00	31.10	27.91
	100.00	100.00	100.00	100.00

In adult bones, as above stated, the proportion of animal matter is about a third, varying in different animals, and in different bones of the same animal. The bones of the young may have too great a proportion of animal matter, when they give way under the superincumbent weight, as in *rachitis*, when, ossification advancing, the animal becomes a cripple. The degree of hardness varies not only with the age, but also with the class of the animal, the bones of birds being white, hard, and brittle, especially those of the wings and legs; the bones of the chamois and its congeners are also very hard and brittle, whereas fish bones are soft and flexible. The bones of some fishes contain a very large proportion of animal matter, and these are known as the *cartilaginous fishes*. In different parts of the same skeleton they vary in hardness, the petrosal bone being the hardest one in the body; the shank bones are also very hard and dense, while the ribs are soft and flexible. The leg bones of a thoroughbred horse are more compact than those of a heavy cart-horse;



the latter are larger, but do not weigh as much in proportion, because the shell, or outer layer, is more expanded and thinner, affording greater surface for muscular attachments. Whereas, in the thorough-bred, a greater density of bone is necessary to withstand the intense concussion of speedy action; therefore the bones are increased in thickness of shell, affording greater strength without apparent increase in size.

## OSSEOUS TISSUE.

In bone tissue there are two modifications of texture, the *compact* and the *cancelled*. The former—hard, dense, and ivory-like—is always situated externally; the latter—porous and spongy—lies within.

Although the compact tissue appears uniformly dense, and destitute of porosity, yet, if we transversely sectate the shaft of a long bone, and examine it under the microscope, by transmitted light, it is found to contain numerous round openings. These are called *Haversian canals*. They transmit blood-vessels, and run in a longitudinal or slightly oblique direction, opening on either the outer or inner surface of the

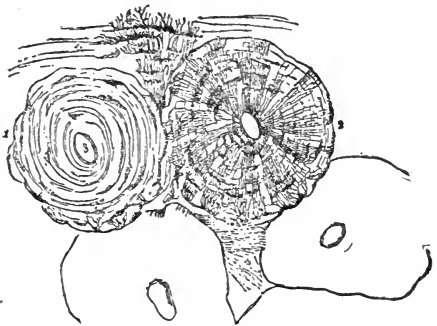


FIG. 2.

Transverse section of compact osseous tissue. An Haversian canal, 3, is seen surrounded by concentric layers, forming an Haversian cylinder, 1. The dark objects between the lamellæ are lacunæ; 2 is a similar cylinder, showing also the canaliculi; 4 4, Portions of the peripheral and interstitial lamellæ.

bone; they also have many transverse branches of communication, which are often of greater diameter than the trunks. These canals are from  $\frac{1}{200}$ th to  $\frac{1}{1000}$ th of an inch in diameter, and surrounded by concentric layers or *lamellæ* of bone, which are shady or opaque, and vary in number from two or three to six, the internal being most distinct, each succeeding one becoming less so. Between them may be seen many dark, irregularly-oval objects—the minute reservoirs or *lacunæ*, containing the *bone-corpuscles*, from which numerous radiating processes occupy the *canaliculi*; the latter are minute canals, which establish a communication between the Haversian canals and the lacunæ. On the external part of the shell of the compact tissue of long bones are several concentric osseous layers, the *peripheral*

or *periosteal lamellæ*, passing completely round the shaft. There is also a corresponding concentric disposition of layers on the inner or medullary surface. Both these systems of lamellæ are in a great measure destitute of Haversian canals, and are supplied with nutritive material by means of lacunæ and canaliculi, disposed as in the compact tissue generally.



FIG. 3.

Longitudinal section of osseous tissue, showing the arrangement of the Haversian canals.

The average diameter of the canaliculi is  $\frac{1}{70000}$ th of an inch. The lacunæ are somewhat oval, and lie with their long diameters, which measure about  $\frac{1}{15000}$ th of an inch, parallel to the lamellæ; their short diameter is about  $\frac{1}{35000}$ th of an inch. The compact tissue is therefore copiously supplied with nutriment by means of minute vessels, which enter from almost every conceivable point.

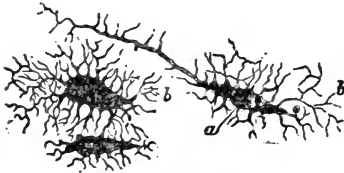


FIG. 4.

Lacunæ highly magnified. *a*, Cavity of lacuna; *b b*, The canaliculi; those of the two lacunæ on the left are seen to join each other.

Each Haversian canal may be considered a vascular longitudinal centre, round which successive concentric layers of bone are arranged, so as to form a dense cylindrical ossicle, a *Haversian System* or *Cylinder*. Series of these are repeated, and united by lamellæ destitute of canals, but with numerous canaliculi and lacunæ, and called the connecting or *interstitial lamellæ*, the entire structure being encircled by the external peripheral lamellæ, thus constituting the compact tissue, and in such a way as to combine strength and density with efficient nutrition, the nutritive material being conveyed by the canals, canaliculi, and lacunæ; the last two only transmit the *fluid* portion of the blood. The canaliculi interlace, and some pass directly through the lamellæ to the central Haversian canal. The lamellæ are in places pierced, and, as it were, pinned together by fibres, or fibrous bundles known as the *perforating fibres of Sharpey*; some of these are derived from the periosteum, and some even appear to be continued from inserted tendons and ligaments.

*Cancellated* or *spongy* tissue is always situated internally. It consists of a large number of fragile bony plates, with spaces between them called the *cancelli*; there are lacunæ and canaliculi, but no Haversian canals, their place being taken by the *cancelli*; in the bones of the cranium this tissue is called the *diploë*.

## COVERING OF BONE.

The external surface of every bone is covered by a tough, fibro-vascular, inelastic membrane, the *periosteum*, excepting where tendons play over the bone, and its articular surfaces upon which there is a layer of cartilage. The *periosteum*, firmly adherent to the bone, contains minute blood-vessels, which are thickly distributed before entering the osseous tissue, and it consists of two layers—an outer one, fibrous and protective, and an inner one, which consists of fine connective tissue, contains bone-producing cells, or *osteoblasts*, and has been termed the *osteogenic membrane*. The inner layer is continued into the Haversian canals, a layer of cells also existing between the canal wall and the contained vessel. It affords support and protection to the bone, and attachment to tendons and ligaments, which frequently become continuous with it. It varies in thickness, being dense and strong on bones nearest the skin, and liable to injury; in the horse, it is well developed on the inner surface of the tibia, and over the anterior surfaces of the metacarpal and metatarsal bones. By its strength it sometimes retains the fragments of a bone in contact after an oblique fracture; in the young, it is thicker and more vascular than in the adult. Blood-vessels which ramify in the *periosteum* pass directly to the bone; the external surface of a bone is always studded with numerous *foramina* through which these enter.

The *periosteum*, owing to its inelasticity, is, when inflamed, the seat of intense pain; and should any part of it be stripped off, there is every probability of the denuded bone dying and exfoliating. It is most vascular near the joints, where it terminates by joining the articular cartilage, or passes to the next bone, but it never covers an articular surface. The internal or medullary cavities are lined by a more delicate vascular membrane, the *endosteum*, or medullary membrane, which is prolonged into the *cancelli* and Haversian canals. It is very thin, consisting of delicate areolar tissue, filaments from which serve to support the marrow, the nutrient or medullary arteries, enter-

ing the bones by the so-called nutrient foramina, being chiefly distributed in it. The periosteum covering the bones of the cranial vault is called the pericranium.

#### CONTENTS OF BONES.

Bones contain Marrow, Connective Tissue, Blood-vessels, Lymphatics, and Nerves.

*Marrow*, as found in the shafts of long bones, is a soft, yellowish adipose or fatty material, which is contained in a delicate layer of connective tissue, and supported by inflective processes of the same. A few cells are found in yellow marrow. Cancellated tissue contains what is termed the red marrow, a substance consisting for the most part of *marrow-cells*, which are round and nucleated, but also containing some smaller objects resembling embryonic blood-corpuscles, and some very large cells. These latter contain numerous nuclei, and they are known as the *giant cells*, otherwise *myeloplaxes*.

The connective tissue lining the medullary canal and cancelli forms the above-mentioned *endosteum*. The large bones of most birds in adult life contain air instead of marrow, but in the bones of a mammal in perfect health there is a considerable quantity of the latter, which becomes diminished in disease.

*Blood-vessels* are numerous in bone tissue; the arteries ramifying in the periosteum gain the Haversian canals, the medullary artery enters by the nutrient foramen, and the arteries of the cancellated tissue pass through foramina situated near the articular surfaces. The veins are numerous, and, according to recent observation, do not generally accompany the arteries, but occupy separate canals; the diploë in the cranial bones contains large dilated veins. *Lymphatics* exist, but little more is as yet known of them than that lymph spaces are found in the Haversian canals. *Nerves* likewise exist in osseous tissue, in its coverings, and also in marrow—accompanying the various blood-vessels.

#### CLASSES OF BONES.

Bones are classed as long, flat, and irregular. *Long* or cylindrical bones are found in the extremities, where they serve as levers, and pillars of support. Descriptively, a long bone is divisible into a centre or *shaft* and *extremities*. The shaft is cylindrical, and consists of a shell of compact tissue of varying thickness, which encloses the cancellated tissue and medullary canal, and is pierced by the medullary or *nutrient*

*foramen*; it is smallest in the centre, expanding towards the extremities, and is circular, oval, or prismoid in form. When a long bone is placed nearly vertically under the body, the internal wall of its shaft is usually the thickest. When obliquely placed, the thick portions of the shaft correspond with the lines which would indicate the direction of pressure produced by the animal's weight. Long bones are never straight; they may be twisted, as is the humerus, and, if bent, are generally convex on their exposed surfaces, the shell being thickest on the concave side.

The extremities of long bones always exceed the shaft in circumference, and are remarkable for the irregularity of their outline; they are expanded and roughened, to afford surface for the attachment of tendons and ligaments, their protuberances also materially increasing the mechanical power of muscles by serving as pulleys over which the tendons play. The extremities are composed of cancellated, with a thin layer of compact, tissue, the cancellated getting gradually less dense towards the centre of the shaft, which is occupied by the medullary canal. While the extremities exceed the shaft in circumference, their weight is not relatively greater—their increase being due to a diffusion and expansion of material, not to an addition of substance. This arrangement lightens and strengthens the bone, besides filling its cavities with an elastic material to resist concussion. The hardest part of a bone is usually the thin portion lying next to the articular surface; it is only found when the bone is fully developed, and it rests upon a series of arches formed by the cancelli: this thin layer is covered with cartilage. Excepting on their articulating surfaces, the extremities of long bones are copiously pierced by foramina, which chiefly transmit blood-vessels to and from the interior.

*Flat or tabular bones* afford extensive surface for muscular attachment, and help to enclose cavities containing important organs. Thus, the cranium protects the brain, the scapula and ribs protect the respiratory organs and heart. Flat bones are composed of two thin expanded plates of compact tissue, rarely quite parallel to each other, and enclosing a cancellated structure between them. The internal is considerably harder than the external plate, but not so thick or tough, the outer being more elastic and less liable to fracture; the connecting cancellated tissue is plentifully supplied with blood-vessels. In the bones of the cranium, the compact plates are called the

tables, and the spongy tissue between, the diploë; the tables also in some facial bones may be widely separated, with air cavities between them.

*Irregular bones* include all which are classed with the foregoing. They are found in the vertebral column, in the skull, and also in the limbs. They usually possess many angles and indentations, with surfaces for articulation and tendinous attachment, and consist of a thin, dense, external case of compact bone enclosing cancellated tissue. In proportion to their size they present a much larger extent of articular surface and greater mechanical strength than any other class.

#### SURFACES OF BONES.

No bone is strictly geometrical in form, although, to a casual observer, some may appear so. The chief irregularities consist of certain eminences and depressions, a knowledge of which is one of the first requisites in the study of osteology. *Eminences* and *depressions* are *articular* or *non-articular*; the former are clothed with cartilage, and assist in the formation of joints.

*Non-articular eminences* exist extensively on the external surfaces of most bones, and receive the attachments of tendons and ligaments. They are of various shapes, sizes, and densities, and frequently named from their real or supposed resemblance to some known object.

The term *process* or *apophysis*, may be generally applied to prominent elevations, but processes so called are not necessarily non-articular, and certain other terms are, rather arbitrarily, applied. A *spine* is an elevation which tends to become pointed; a *tubercle* is a small blunt projection, which, if more developed, would be called a *tuberosity*, while the name *trochanter* is applied to the largest and most prominent of these. A *crest* or *ridge* implies a roughened line or border.

*Non-articular depressions* may serve as channels of transmission, passing completely through a bone or part of a bone, and may bear either of the names *foramen*, *canal*, *aqueduct*, or *meatus*, the first name being the most used; or they may be blind cavities in the surface of the bone, and if roughened for the attachment of tendons or ligaments, the term *fossa* is sometimes applied to them. The terms *notch* and *figure* indicate depressions or grooves, which transmit various structures, and the approximation of two notches in contiguous bones sometimes forms a foramen. When we find a depression leading to two or more foramina it may be termed an *hiatus*.

*Articular eminences.*—A *caput* or *head* is a more or less semi-spherical projection, supported by a roughened and constricted *cervix* or *neck*. An ovoid convexity is called a *condyle*; and often condyles are found in pairs, the articular surfaces of which may be continuous or separated. A *trochlea* is an articular surface presenting a pulley-like appearance.

*Articular depressions.*—A *glenoid* cavity is shallow, and may be cup-like, while a cavity is called *cotyloid* when it is deeper. The term *facet* is often applied to articular surfaces, which may be large, but are not well marked either as elevations or depressions.

The rough irregularities of surface are more distinctly marked in the bones of the horse than in those of most other animals; their size is always proportionally greater in well-bred animals; in heavy, coarsely-bred horses, which possess great strength but little activity, they are smaller in proportion to the absolute size of the bones.

#### DEVELOPMENT OF BONE.

Although the bones of the foal, calf, and young of many other large quadrupeds, possess greater solidity at birth than those of the human infant, yet they all pass through certain progressive stages of development before arriving at that degree of density which they ultimately possess. The tracing of future bone is recognised, about the seventh week of foetal development, in local collections of soft, granular, gelatinous pulp, which becomes gradually flooded with nucleated cells, held together by an opaque, intercellular basis or matrix, which, with the cells equally distributed through it, forms *temporary cartilage*—a material closely resembling in its properties ordinary *gristle*.

The process of *ossification*, or conversion of cartilage into bone, begins at certain fixed points, and gradually spreads; these points are called *ossific centres*, or points of ossification. When this conversion commences, that part of the cartilage about to become ossified is permeated by large channels for the passage of the blood-vessels which convey the bone-earth; and the cells, instead of being equally distributed throughout the matrix, become arranged in parallel groups, and increase in number, those nearest the point of ossification enlarging. Matter, in the form of very minute granules, is now deposited in this column of intercellular or hyaline substance, as well as between each cell.

Ossification of the cell walls ensues, which is followed by the absorption of the osseous matter between the cells, converting what was a row of closed cells into a tube, which is a rudiment-

ary Haversian canal, no trace being left of the nucleus of the original cartilage corpuscle; but there are numerous very minute reddish granules, which almost fill the cavity, and are concerned in the formation of blood-vessels, which now begin to appear. The ossific parietes of the cartilage cells lining the tube, at first thin, enlarge and thicken by successive layers of dense osseous matter, and thus produce the concentric lamellæ, the lamella last formed pushing out the older one, until what was the lining of the tube becomes the external lamella of an Haversian system, while the ossific matter which was deposited in the column of intercellular material, becomes the connecting lamellæ between the Haversian cylinders.

In long bones this ossific process commences in the centre of

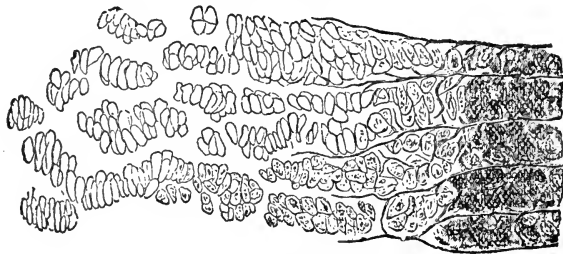


FIG. 5.

Section of ossifying cartilage magnified. On the left the cells are becoming arranged in rows; while to the right, between the rows, the earthy material is being deposited.

the shaft, gradually spreading to the extremities, in which there are separate points of ossification; there are generally three such points, one for the shaft, and one for each extremity, the developing shaft being called the *diaphysis*, the extremities the *epiphyses*. When any process is superadded, as the trochanter of the femur, which possesses a distinct point of ossification, it may be termed an *apophysis*. As ossification commences in the shaft, there are for some time after birth, intervening portions of unossified cartilage, marked by a deep ring in the dried long bones of young animals; they disappear at variable periods, the portions of bone hitherto imperfectly united becoming consolidated into one firm mass. The bone increases in length by growth of the unossified ring, uniting the shaft and epiphysis, until the ring fills up, when growth is completed. Should an epiphysis unite with the diaphysis prematurely, by acceleration of the process of ossification through disease, growth being thus arrested, the bone will be shorter than its fellow. The shaft of a long bone increases in



circumference by deposits of new bone on its external surface, derived not from cartilage, but from membrane—the inner layer of the periosteum, which has been termed the *osteogenic membrane*. In the periosteum there are two layers or strata—an outer, strong and fibrous; an inner, soft, and containing *osteoblastic* cells, which, after undergoing certain changes, produce layers of new bone; the process is termed intramembranous, as opposed to intracartilaginous ossification. This goes on till the bone has reached its full development, when Haversian systems cease to be formed, and then, as a climax, the peripheral lamellæ are formed, and the medullary canal enlarges by internal absorption.

In flat bones, ossification usually radiates from a centre, and is directed by the membrane investing each surface of the bone; some of them possess numerous apophyses. Ossification is completed in some bones much earlier than in others, and at birth those which are required for support and progression are farthest advanced.

The bones of the cranial vault are developed, not from cartilage, but from membrane. In early fœtal life the brain is covered by two membranes, closely united—viz., the pericranium and dura mater; between these, bone becomes developed from radiating ossific centres.

#### THE SKELETON.

The internal framework on which the animal body is built is termed the **ENDOSKELETON**, while the outer casing which determines the shape and appearance of the animal is the **EXOSKELETON**; in some of the lower animals the latter assumes the form of a calcareous case, in others it is scaly, in others again, bony. The exoskeleton of the higher animals consists of the skin and its appended modifications, which will be described in a future section of the work. By the term *skeleton* is generally understood the endoskeleton, or bones of an animal, held in their relative positions, or articulated by wires or screws, in which case all the soft tissues are first removed, and the preparation is termed an *artificial* skeleton: but if those soft structures, which, in the living animal, join the bones together, are allowed to remain, dried, and preserved, then the preparation is a *natural* skeleton.

As the skeleton has two sides or halves, the majority of the bones exist in pairs. There is, however, a central chain of single bones, formed by the back bones or vertebræ and the median

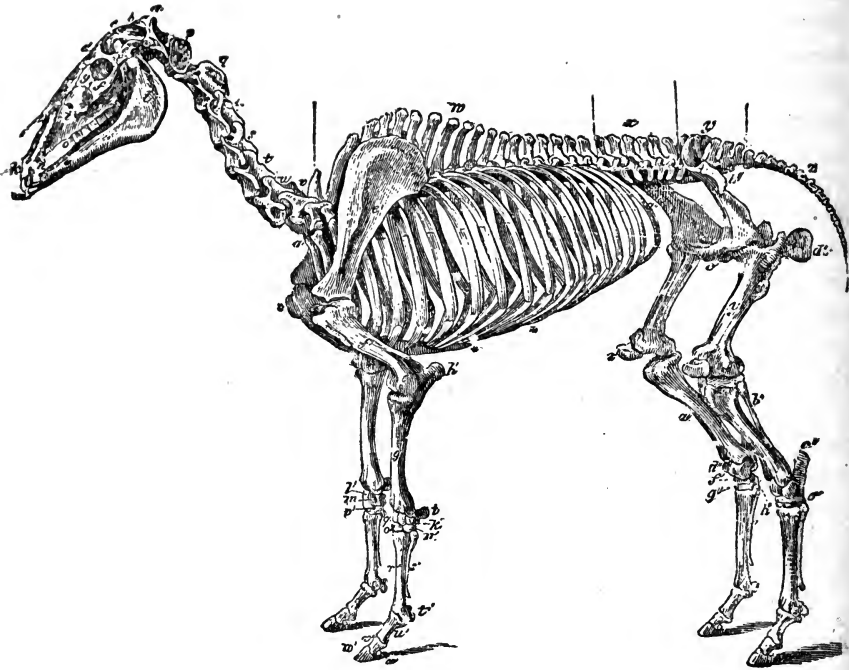


FIG. 6.

## SKELETON OF THE HORSE (SOLIDUNGULA).

## AXIAL SKELETON.

## THE SKULL.

*Cranial Bones.*—*a*, Occipital, 1; *b*, Wormian, 1; *c*, Parietal, 2; *d*, Frontal, 2; *e*, Temporal, 2; Sphenoid, 1; Ethmoid, 1; Auditory ossicles, 3.

*Facial Bones.*—*h*, Nasal, 2; *g*, Lachrymal, 2; *f*, Malar, 2; *i*, Superior maxilla, 2; *k*, Premaxilla, 2; Palatine, 2; Pterygoid, 2; Vomer, 1; Turbinals, 4; *l*, Inferior maxilla, 1; Hyoid (segments), 5. Teeth:—*m*, Incisors, 12; *n*, Canines, 4; *o*, Molars, 24.

*The Trunk.*—*p-v*, Cervical vertebræ, 7; *w*, Dorsal vertebræ, 18; *x*, Lumbar vertebræ, 6; *y*, Sacrum, 1; *z*, Coccygeal vertebræ (variable), 18; *a'a'*, Ribs, 36; \* Sternum (3-7 Sternebræ), 1; † Costal cartilages

## APPENDICULAR SKELETON.

## PECTORAL LIMB.

*♂*, Scapula, 2; *f'*, Humerus, 2; *g'*, Radius, 2; *h'*, Ulna, 2. Carpus:—*i'*, Trapezium, 2; *k'*, Cuneiform, 2; *l'*, Lunar, 2; *m'*, Scaphoid, 2; *n'*, Unciform, 2; *o'*, Magnum, 2; *p'*, Trapezoid, 2; *q'*, Pisiform, 2. Metacarpus:—*r'*, Large bone, 2; *s'*, Small bone, 4. Digit:—*v'*, Proximal phalanges, 2; *u'*, Median phalanges, 2; *w'*, Distal phalanges, 2; *t'*, Large sesamoids, 4; Small sesamoids, 2.

## PELVIC LIMB.

*Pelvis.*—Os Innominatum:—*b'*, Ilium, 2; *d'*, Ischium, 2; *c'*, Pubis, 2.

*The Limb.*—*y'*, Femur, 2; *z'*, Patella, 2; *a''*, Tibia, 2; *b''*, Fibula, 2. Tarsus:—*c''*, Calcaneum, 2; *d''*, Astragalus, 2; *e''*, Cuboid, 2; *f''*, Cuneiforme magnum, 2; *g''*, Cuneiforme medium, 2; *h''*, Cuneiforme parvum, 2. Metatarsus:—Large bone, 2; Small bone, 4. Digit:—Proximal phalanges, 2; Median phalanges, 2; Distal phalanges, 2; Large sesamoids, 4; Small sesamoids, 2.

The Horse's Skeleton, as here considered, consists of 256 parts.

segments of the head, extending the whole length of the framework, and uniting its lateral halves. But even these single bones present the same shape on either side of their central line; hence, if a skeleton were divided longitudinally, exactly in the median plane, the two halves would correspond. This "right and left," or double arrangement of parts, is termed *bilateral symmetry*.

Anatomists differ as to the number of bones composing the skeleton, some enumerating all ossific bodies, including the teeth and sesamoids, which others eliminate; some, again, regard certain cranial bones as single, other authorities as double. It is of little practical importance which view be taken; it will be found that there are about 216 separate bones; or, including the teeth, 256 pieces in the skeleton of the horse.

In speaking of the anatomical position and relation of bones as of other structures, continual reference is made to imaginary lines or planes. The skeleton of the quadruped, as well as that of man, is, in an anatomical sense, viewed from before; but man, being erect, with the long axis of his body in a vertical position, whilst that of the quadruped is horizontal, corresponding organs do not always present themselves to observation from the same point of view. With reference to quadrupeds, imaginary planes are supposed to lie as follows:—A longitudinal median vertical plane descends through the centre of the head, vertebral chain, and trunk, midway between the right and left extremities, to the ground, dividing the body into two exact halves; right and left lateral vertical planes are placed parallel to the former, but external to the body; at right-angles to the above an anterior vertical plane is placed in front, and a posterior vertical one behind: a superior horizontal plane lies above the body, between the anterior and posterior vertical planes; while parallel with the superior is an inferior horizontal plane, placed under the feet. The external surface of an organ or region is that which faces the lateral plane on the side where the organ is situated. The internal surface faces the median plane of the body, the anterior surface the anterior vertical, the posterior surface the posterior vertical plane, while the superior and inferior surfaces are those facing their respective superior and inferior planes. This imaginary index may be applied to any region, as well as to the entire body.

Modifications of these terms are used when it is requisite to point out the precise situation of a structure. For example, take

the anterior limb, and suppose it encompassed by the planes *ut supra*. If we wish to describe the situation of any object on the upper part of its lateral region, the term supero-lateral would be used; if the object were situated at the lower lateral part, then infero-lateral. Similar modifications of terms are, of course, applicable to the anterior and posterior surfaces. Supero-anterior implies the superior part of the anterior region, and antero-superior the anterior part of the superior region. For description, structures are frequently divided into two or more parts; thus we allude to the superior, middle, or inferior third of an object. The end of a structure which is nearest to the vertebral column is often termed the *proximal*, while the remote end is termed the *distal* extremity.


#### DIVISION OF THE SKELETON.

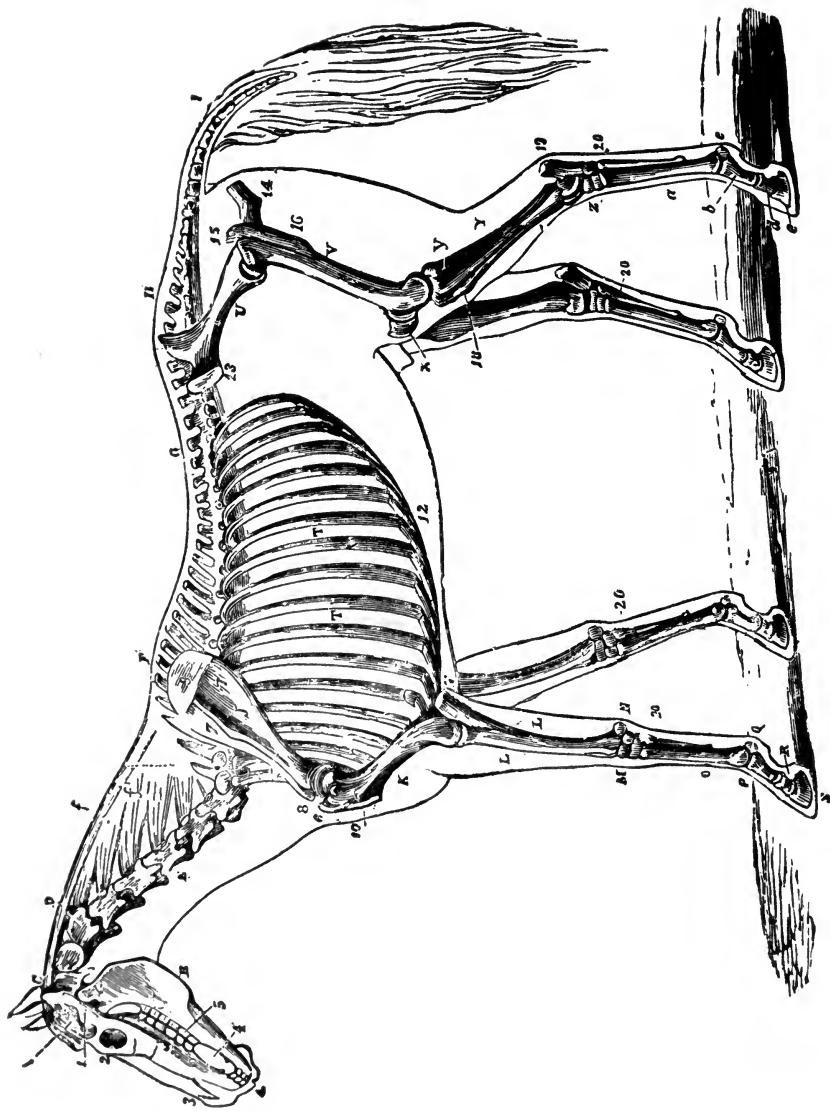
The limbs, with their media of attachment, form the APPENDICULAR SKELETON; while the remaining portion of the structure, consisting of the skull, vertebræ, ribs, and breast-bone, is called the AXIAL SKELETON. By many authorities the skull is regarded as being formed of a number of modified vertebræ, while the ribs and breast-bone, or sternum, are considered parts of complete vertebral segments. Taking this view, the term axial skeleton would be synonymous with vertebral column. In this work we first describe the axial skeleton, dividing it into the vertebral column and the skull, afterwards treating of the appendicular skeleton. The following Table will exhibit this division:—

<i>Axial Skeleton.</i>	
Vertebral Column.	{ Cervical Region. { Dorsal Region. { Ribs. { Sternum. { Lumbar Region. { Sacral Region. { Coccygeal Region.
Skull.	{ Cranium { Face.

#### *Appendicular Skeleton.*

Pectoral Arch and Limb  
Pelvic Arch and Limb.






SKELETON OF HORSE—after Meunier.

## EXPLANATION OF PLATE I.

### SKELETON OF THE HORSE,

*Showing its relation to the contour of the animal, viewed laterally.*

- |                       |   |
|-----------------------|---|
| A. Temporal fossa.    | Z. Tarsus.  |
| B. Inferior maxilla.  | a. Metatarsus.  |
| C. Atlas.             | f. Ligamentum nuchæ, funicular portion. f'. Lamellar portion. |
| D. Dentata.           | 1. Zygoma.  |
| E. Cervical vertebræ. | 2. Orbital fossa.   |
| F. Dorsal do.         | 3. Nasal peak.  |
| G. Lumbar do.         | 4. Incisor teeth.   |
| H. Sacral do.         | 4'. Canine teeth.   |
| I. Coccygeal do.      | 5. Molar teeth.   |
| J. Scapula.           | 6. External humeral trochanter.                               |
| K. Humerus.           | 7. Scapular fossæ.  |
| L. Radius.            | 8. Coracoid apophysis.  |
| L'. Ulna.             | 9. Cartilage of prolongation.                                 |
| M. Carpus.            | 10. Deltoid ridge, and external tuberosity.                   |
| N. Trapezium.         | 11. Olecranon.  |
| O. Metacarpus.        | 12. Costal cartilages.  |
| P, b. Os suffraginis. | 13. Anterior iliac spine.                                     |
| Q, c. Sesamoids.      | 14. Ischium.  |
| R, d. Os coronæ.      | 15. Trochanter major.   |
| S, e. Os pedis.       | 16. Trochanter minor.   |
| T.T. Ribs.            | 18. Anterior tibial tuberosity.                               |
| U. Ilium.             | 19. Calcaneum.  |
| V. Femur.             | 20. Small metacarpal and metatarsal, or splint bones.         |
| X. Patella.           |   |
| Y. Tibia.             |   |
| y. Fibula.            |   |





## AXIAL SKELETON.

## VERTEBRAL COLUMN.

The *vertebral* or *spinal column* may be considered the foundation of the skeleton, from which all other parts proceed. Extending the whole length of the body, it consists of a series of single bones, termed *vertebræ*, firmly united, and it presents a succession of curves; thus, in the horse, the neck, back, and croup are usually curved, while the loins are nearly straight.

The vertebral chain may be divided into five regions, exclusive of the cranial portion, which we regard collectively as the skull. These are the cervical, dorsal, lumbar, sacral, and coccygeal—respectively the regions of the neck, back, loins, croup, and tail; and, while all possess certain points of conformation in common, special peculiarities distinguish the *vertebræ* of any one region from those of another.

*Vertebræ* are either *true* or *false*; true *vertebræ* possess certain *typical* parts, which they retain throughout the life of the animal, and they never, in health, unite by ossification; while false *vertebræ* either do not possess the essential characters of true, or they may become so united.

## TRUE VERTEBRÆ.

A *true vertebra* consists of a body or *centrum*, an arch, called the neural arch, notches, and spinous, transverse, and articular processes. The *body* is the solid block of bone on which all the other parts are built, and which, in quadrupeds, lies below the spinal canal. Its anterior end is convex, and its posterior correspondingly concave, both being discs of compact bone roughened for the attachment of the soft intervertebral substance. Its upper or spinal surface is flattened or slightly concave, its inferior surface being convex, and sometimes terminating in a spinous process or prominent ridge.

The *neural arch* or *ring* rises from the supero-lateral surfaces of the body by two processes of bone termed *pedicles*, from each of which a plate of bone, *the lamina*, expands and passes inwards, the union of the *laminæ* in the median line completing the arch, which encloses the neural canal or spinal foramen.

The *notches* are excavations in the anterior and posterior surfaces of each pedicle, so placed that when the vertebræ are *in situ* the notch in the posterior part of one pedicle corresponds with that in the anterior of the next, the two forming a large opening, called the intervertebral foramen, which leads to the neural canal and gives passage to the spinal nerve and blood-vessels.

Each true vertebra, with the exception of the two anterior cervical ones, has four *oblique* or *articular processes* (*zygapophyses*) on the superior and lateral parts of the arch. The faces of the anterior of these processes are directed upwards and inwards, those of the posterior downwards and outwards; as their name implies, they articulate and form joints with the corresponding processes of contiguous vertebræ. In some of the dorsal and lumbar segments of certain animals, the anterior zygapophyses have processes which project above the level of the articular facets; these are the *mammillary processes* (metapophyses).

The *transverse processes* (*diapophyses*), one on each side, spring from the sides of the body and pedicle, and are projections varying much in size and shape in the different regions. Between the anterior zygapophysis and the metapophysis in some animals there may be another small eminence projecting backwards (*anapophysis*).

The *spinous processes* are superior and inferior. The *superior* or *neural spine* (*neurapophysis*), formed by the union of the laminae, and surmounting the centre of the arch, is sometimes of great size and strength, but varies much in development in the different regions of the same animal. The *inferior* (*hypapophyses*) are for the most part rudimentary, and can scarcely be said to exist, except in the cervical region, where they project from the inferior central line of the bodies.

The centra or bodies of the vertebræ, placed in natural apposition, thus form a central bony column, to which the arches and processes are attached; the arches, with their connecting ligaments, form superiorly a cavity, the *spinal* or *neural canal*,

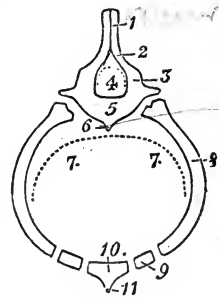


FIG. 7.

Diagrammatic transverse section from the skeleton of a mammalian thorax, showing the chief features of a perfect vertebral segment. 1, Neural spine; 2, Lamina (neurapophysis); 3, Pedicle; 4, Neural arch; 5, centrum; 6, Inferior Spine (hypapophysis); 7 7, Hæmal arch; 8, Rib (pleurapophysis); 9, Costal cartilage (hæmapophysis); 10, Sternebra; 11, Hæmal spine.

which extends from the head to the tail, and contains the spinal cord, with its membranes and blood-vessels; the articular processes strengthen the connections of the vertebræ, while the spinous and transverse processes are levers to which muscles are attached, their development having great influence on the physical conformation and capabilities of the animal. The ribs may be regarded as continuations of the dorsal transverse processes; they form the inferior or hæmal arch of their own region.

## FALSE VERTEBRÆ.

The *false vertebræ* are found in the sacrum, which consists of vertebral segments united by the ossification of their connecting material, and in the coccyx, the skeleton of which consists of rudimentary or imperfectly-developed vertebræ. The sacral segments in the early stages of life are separable, and they present all the characteristics of true vertebræ.

## CERVICAL VERTEBRÆ.

## General Features.

(FIG. 8.)

There are seven cervical vertebræ in all the Mammalia, with the exception of the Three-toed Sloth, which has nine, and one of the Sea-cows, which has six. They are numbered in order from the head, the first receiving the special name of *atlas*, and the second that of *axis* or *vertebra dentata*; these, with the sixth and seventh, differ from the rest, which are essentially alike.

The *centra* or *bodies* of the cervical vertebræ are larger and longer than those of any other true vertebræ, and frequently measure upwards of four inches in length; they are quadrangular in shape, their anterior extremity or head being convex and somewhat heart-shaped, with the apex downwards, while the posterior extremity presents a corresponding cup-like cavity. The flexibility of the neck is partly due to these convexities and cavities, which are more pronounced in the cervical region than in other parts of the cöllum. The *superior surface* is flattened, and presents, close to the pedicle on each side, a distinct furrow, which contains the spinal vein; these lateral furrows are united by

means of a central transverse furrow, and partly covered by a thin bony plate, to which the superior common ligament is attached. The *inferior surface* presents a longitudinal process or ridge, the inferior spinous process, which increases in size as it approaches

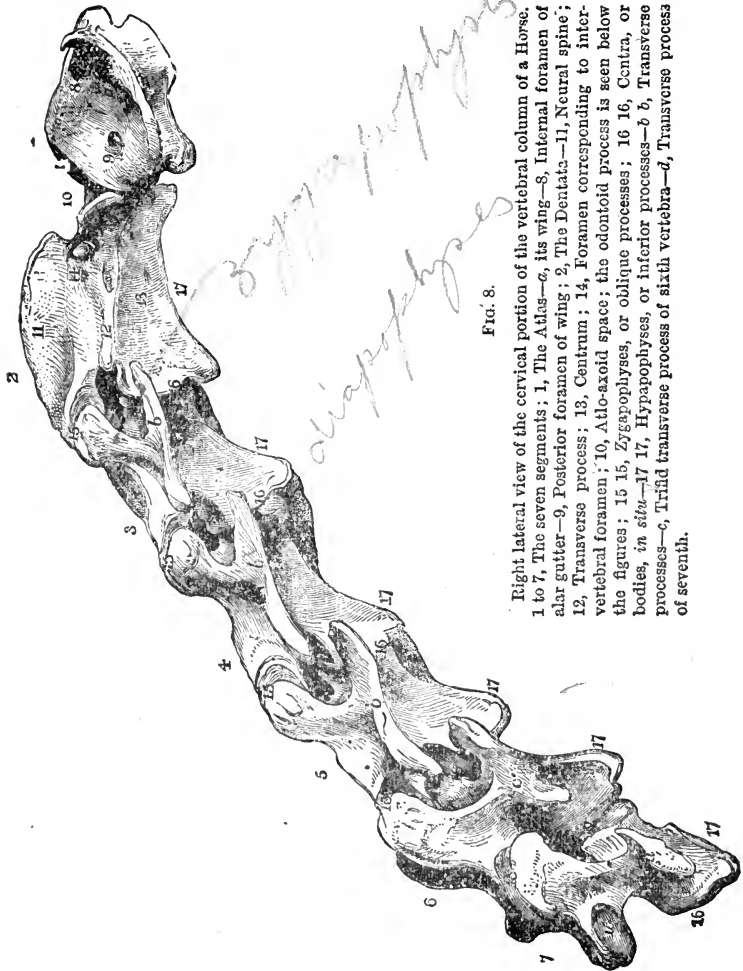


FIG. 8.

Right lateral view of the cervical portion of the vertebral column of a Horse. 1 to 7, The seven segments; 1, The Atlas—*a*, its wing—8, Internal foramen of alar gutter—9, Posterior foramen of wing; 2, The Dentata—11, Neural spine; 12, Transverse process; 13, Centrum; 14, Foramen corresponding to intervertebral foramen; 10, Atlo-axoid space; the odontoid process is seen below the figures; 15 16, Zygapophyses, or oblique processes; 16 16, Centra, or bodies, *in situ*—17 17, Hypapophyses, or inferior processes—*b b*, Transverse processes—*c*, Triad transverse process of sixth vertebra—*d*, Transverse process of seventh.

the posterior end of the bone, where it terminates in a projecting tuberosity, which gives attachment to the longus colli muscle. The *lateral surfaces* of the body, above the inferior spine, are flattened, and somewhat excavated.

The *superior spinous processes* or *neural spines* are mostly rudimentary, and rise from the centre of the quadrilateral space between the oblique processes. They are bifid posteriorly, the ligamentum nuchæ and spinalis colli muscle being attached in the bifurcation.

The *transverse processes*, broad, short, strong, and irregular in shape, pass directly outwards, and divide into two parts—one projecting antero-inferiorly, and the other postero-inferiorly. They increase in size as they extend backwards, and all of them, except the seventh, are pierced by the vertebral foramen, through which pass the vertebral artery and vein. These processes give attachment to the serratus magnus, splenius, longus colli, intransversalis colli, levator humeri, and other muscles acting upon the head and neck.

The *articular processes*, larger than in any other region, have flattened oval articular surfaces; the anterior two look upwards and inwards, while the posterior look downwards and outwards. The articular processes of the posterior five cervical vertebræ give attachment to the complexus major, trachelo mastoideus, and spinalis colli muscles.

The *arches*, stronger than in any other region, enclose the spinal canal, which progressively increases in size in the direction of the dorsal vertebræ, its vertical diameter being the greater. The *notches* of the three posterior cervical vertebræ are also larger than the rest.

Viewed *in situ*, it is seen that the transverse processes of the three central cervical vertebræ are largest and strongest, with the exception of that of the first, and they can be detected under the investing muscles in the living animal; also that the bodies progressively diminish in length, and increase in breadth and depth from the second backwards.

The first, second, sixth, and seventh cervical vertebræ having features peculiar to themselves, require special notice.

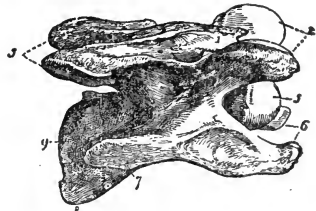


FIG. 9.

Right lateral view of a cervical vertebra of a Horse. 1, Neural spine; 2, Anterior oblique processes; 3, Posterior oblique processes; 4, Concave posterior end of the centrum; 5, Convex anterior end, and 9, Concave posterior end of the centrum; 6, Anterior ends of transverse processes; and 7, Posterior end of right one; 8, Inferior process, or hypapophysis.

## SPECIAL CERVICAL VERTEBRÆ.

*The Atlas.*

The *First cervical vertebra* is called the *Atlas*, because in human anatomy it supports the head; in quadrupeds the head is suspended from it. It presents no well-defined body, but consists of a strong ring of bone, the superior surface of which is convex, with a slight longitudinal elevation in the median line, from which the *alæ* or wings slope downwards and backwards. The wings are large, flat transverse processes, wider than those of any other true vertebra, and they terminate in rough convex margins, which may be plainly felt through the skin in the living animal; they give insertion to portions of the levator humeri, splenius, trachelo mastoideus, and obliquus capitis posticus muscles, and are always largely developed in the carnivora.

Superiorly, each ala exhibits three foramina; the posterior is the largest, and corresponds to the vertebral foramen, giving passage to the anastomotic branch of the occipital artery. The two anterior foramina are joined by a short, deep depression, the alar gutter; the external foramen gives passage to the occipital artery, vein, and nerve, while the internal passes through the ring into the neural canal, representing the intervertebral foramen, and through it pass the cerebro-spinal artery, and the first spinal nerve.

The *inferior surface* of the atlas is convex centrally, and presents posteriorly a short, obtuse eminence, which represents the inferior spine, this is the *tubercle* of the atlas to which the tendon of the longus colli muscle is attached. On each side of the central convexity we find a large concave space limited externally by the ala. The *anterior surface* presents two notches and two articular depressions. The notches are of great size, and contain the superior and inferior suspensory ligaments—one being above, and the other below, the spinal canal. The articular glenoid cavities receive the condyles of the occipital bone, and are each constructed of a superior and an inferior continuous surface; the inferior, representing the convex head of other vertebrae, is concave; while the superior, nearly flat, represents the oblique processes. A prominent bony ridge, to which is inserted the investing or capsular ligament, surrounds the anterior border of the bone. The *posterior surface* presents a somewhat

triangular outline ; its inferior margin is excavated to receive the *odontoid* process of the second vertebra, while the superior is thin, and roughened for ligamentous insertion, and, on each side, a broad slightly convex articular surface represents the posterior oblique processes. This surface is bounded externally by a ridge, which gives insertion to the capsular ligament ; and internally it is separated by a similar ridge from the spinal canal.

The spinal foramen of the atlas is very large, in order that the spinal cord may be preserved from injury during the extensive motions which take place between the head and neck. Its floor is divided by a transverse ridge into two portions, the anterior of which is roughened for the attachment of ligaments, the posterior being smooth for the articulation of the *odontoid* process. Its roof is smooth, and penetrated by two foramina for the passage of an artery and nerves, and its sides have each an excavation in which a venous sinus is lodged ; a foramen from this excavation opens on the inferior surface of the ala, and transmits a vein from the sinus.

The atlas has three articular processes,—two for the occipital condyles, and one for the axis,—all of which form *true* joints, the atlas being the *only* vertebra possessing none but true articulations.

#### *The Dentata.*

The *Second vertebra* is called also the *axis*, because the head rotates upon it, also the *vertebra dentata*, from a process which, in the corresponding human bone, somewhat resembles a tooth in shape, and is called the *odontoid process* ; it is situated on the anterior end of the centrum, projecting forwards into the ring of the atlas, and around it the head and atlas rotate. In the horse the under surface of this process is smooth and rounded, and the upper roughened and excavated, for the attachment of the *odontoid ligaments* ; laterally, it terminates in a broad, oval, somewhat convex surface, which represents the oblique processes, and articulates with the posterior surface of the atlas ; these articular shoulders being bounded by a ridge, to which the capsular ligament is attached.

The *neural spine* of the axis springs from a very strong arch, and is nearly as long as the body, which is longer than that of any other true vertebra ; this spine is convex, and consists of lateral halves, united anteriorly into a strong rough crest,

but bifurcating posteriorly into ridges, which terminate in the oblique processes. The *inferior spine* arises from a notch in the inferior part of the odontoid process; it is broad and rough anteriorly, but contracts into a sharp spine, which terminates in a roughened tubercle posteriorly. The *transverse processes*, the smallest in the cervical region, are single, and project outwards and backwards; they are pierced by very small vertebral foramina. The *spinal canal* is somewhat narrow, and instead of *notches*, there are two oval foramina anteriorly for the passage of the spinal nerves. The posterior parts of the body and arch do not materially differ from those of the other cervical vertebræ.

In the horse the atlas and axis do not approximate above the spinal canal, and there is a considerable space between them, the *atlo-axoid space*, which is covered by soft structures only; and here the operation of "pithing" is easily performed.

#### *The Two Last Segments.*

The *Sixth vertebra* has a much shorter body than those anterior to it, and is destitute of an inferior spine. Its transverse processes consist of three lateral divisions, and its vertebral foramina, notches and spinal canal are of great size.

The *Seventh vertebra*, or *Vertebra prominens*, the shortest of the series, is very strong, and has an elevated neural spine, pointing upwards and forwards, but scarcely the trace of an inferior one. Its oblique processes resemble the four preceding; its transverse processes are small, and have usually no vertebral foramina, while its notches and spinal canal are larger than in any other of the last six cervical vertebræ. On each side of its body, posteriorly, it presents a depression which, with a corresponding depression on the first dorsal centrum, forms a cup for the articulation of the first rib. Altogether it closely resembles in character the first dorsal vertebra.

#### DORSAL VERTEBRÆ.

(PL. I. F.)

These vertebræ, of which there are eighteen or rarely nineteen, always correspond in number with the pairs of ribs, and in the horse form the weight-bearing portion of the column, extending over the whole length of the chest. Their *bodies*, the smallest of the true vertebræ, are short, thick, and somewhat semicircular



in form, each presenting a middle ridge along its under surface, to which the inferior common ligament is attached. The superior surface of the body, which forms the floor of the spinal canal, is flattened and quadrilateral, presenting longitudinal furrows for the spinal vessels, and often a central transverse one, partially covered by a bony plate. The *anterior extremity* presents a slightly convex head, on the superior and lateral aspect of which is a semicircular depression corresponding with another on the posterior extremity of the vertebra in front, so that together they form a cup-shaped cavity for the articulation of a rib, each articulating with *one-half* of the head of the rib. The *posterior extremity* is concave, to articulate with the contiguous bone, and has on each side an articular depression similar to those on the anterior extremity. The *transverse processes*, rising from the sides of the arches, are small; superiorly and anteriorly they are roughened for muscular attachment, and at its posterior inferior part, each presents a flat, smooth facet which articulates with the tubercle of the next anterior rib.

The *neural spines*, larger than in any other region, vary much in size, shape, and direction, the first twelve being directed backwards, the next three nearly upright, and the last three forwards; their length gradually increases to the fifth, which is usually the longest, and then decreases to the fourteenth, which is generally somewhat shorter than those behind it; the first is small and sharp, and the second, which is abruptly bent backwards, is very strong; the summits of the next six or seven are flattened, roughened, and expanded laterally, assuming a bifid appearance, giving greater surface for the attachment of muscles and the great suspensory ligament of the head and neck, the *ligamentum nuchæ*. The lateral surfaces are convex and slightly roughened, the anterior borders being thin and serrated, while the posterior, of the higher spines especially, are broad and concave, becoming cleft as they approach the oblique processes.

The *oblique processes* are small, and their facets are more horizontal than in the cervical region, and closer together. The *pedicles* are short and strong, and, with the exception of the anterior four or five, possess notches on their posterior edges only; backwards, we find these notches become more and more closed in, until posteriorly there are foramina in lieu of notches. The *arch*, and consequently the spinal canal, are small, the laminae passing almost directly inwards from the pedicles.

An ordinary dorsal vertebra has twelve articular surfaces—viz., three anterior and three posterior, as in the cervical, and three at each side; of the latter, two are for the heads of two ribs, and the third for the tubercle of the anterior rib. The depressions for the heads of the ribs are deepest between the anterior vertebræ, and gradually grow shallower, in the two last becoming continuous with the facet on the transverse process. The eighteenth segment, being attached to but one rib on each side, has eight articulating surfaces only.

Viewing the dorsal vertebræ in connection, it is seen that the spines diminish from the fifth backwards, and the vertebræ themselves grow narrower. The first exhibits some of the characters of a cervical vertebra, and the second has a short body, with transverse and anterior oblique processes formed on the same bony projection, and a neural spine, short, convex anteriorly, and more bent than any other in the vertebral chain. The first thirteen form the skeleton of the *withers*, and, when well developed, the height of their spines increases the surface for muscular attachment, and also affords greater leverage.

#### LUMBAR VERTEBRÆ.

(PL. I. G.)

These form the skeleton of the loins, and are shorter in the horse in proportion to his size, than in other animals. Their number is six usually, sometimes five, in the horse, six in the mule, generally five in the ass, and also, it is said in the Arab horse. Their *bodies*, intermediate in length between the cervical and the dorsal, are thick and strong, the three anterior being flattened superiorly and laterally, and possessing a strongly-developed median ridge; the three posterior ones are convex laterally, and flattened above and below. More motion being required in the loins than in the back, the anterior extremities of the centra of the lumbar vertebræ are more convex, and the posterior extremities more concave than those in the dorsal region. The *arches* enclose a large semicircular spinal canal, and with one or two exceptions possess both anterior and posterior notches. The *neural spines* are strong, broad, and flattened laterally; they incline slightly forwards, are about the same length as the posterior dorsal spine, and have sharp anterior and posterior

edges, with rough expanded extremities; they increase slightly in height, and diminish in strength backwards.

The *transverse processes*, longer than the corresponding processes in any other region, are broad and flat with rounded extremities, and extend nearly horizontally from the bodies; the central are the largest, the two first inclining a little backwards, and the three last slightly forward. The last two of these processes articulate with each other by means of facets, and, in advanced age sometimes become united by ossification, the sixth articulating in a similar manner with the sacrum. The *oblique processes* project farther from the arch than those of the dorsal region; the articular facets of the anterior ones are concave and directed inwards, while those of the posterior are convex and directed outwards.

The first four lumbar vertebræ have six, the typical number of articular surfaces, the fifth having in addition one on each posterior border of its transverse processes, and the sixth one on each border, anterior and posterior, of these processes, or ten in all.

### FALSE VERTEBRÆ.

#### THE SACRUM.

(Pl. I. H.)

This, the bone of the croup, is a single, somewhat triangular-shaped bone, consisting of five false vertebræ united, in the young animal by articulation, and in the adult by ossification; it contains the continuation of the spinal canal, forms the roof of the pelvis, and has articular surfaces by which the pelvic arches are attached, and in the horse these are the *only* articular connections between the axial and appendicular skeletons. Its direction varies somewhat according to the breeding of the animal; in lightly-made, highly-bred, and well-formed animals its long axis is usually placed in a nearly horizontal line, while in horses of coarser breed its coccygeal extremity is often considerably lower than the other, thus giving a drooping appearance to the contour of the croup. It presents for consideration superior and inferior surfaces, two lateral borders, and anterior and posterior extremities.

The *superior surface* is irregularly convex, with the flat-topped spines of its vertebral segments running along its centre, decreasing in height, but increasing in breadth as they extend backwards.

In a groove at their base, opposite the interspinous spaces, are the four superior sacral foramina, which give exit to the superior branches of the sacral nerves. An irregularly-elevated ridge, external to the grooves, marks the division between the superior and inferior surfaces of the bone. The *inferior* or *pelvic surface* is smooth and rather concave; at its anterior end is a transverse elevation, the sacral promontory, not very pronounced in the horse, and crossing the bone transversely are four slightly-elevated lines, which show the connections between the original segments. Between these lines, and close to the borders on each side are the four large foramina through which pass the inferior branches of the sacral nerves, and at the anterior end two notches, which correspond with similar notches in the last lumbar vertebra, and form the foramina through which the first sacral nerves find their exit.

The *anterior extremity* or *base* is almost entirely articular; the central part, oval and convex, articulates with the last lumbar vertebra, and above it is the spinal canal surmounted by the articular processes. The lateral parts are the thick expanded transverse processes which terminate in sharpened *extremities*, and contain two broad facets for articulation with those on the last lumbar transverse processes. The *posterior extremity* or *apex* presents the diminished spinal canal in its centre, with the last spinous process above it, and below the flat surface which articulates with the first bone of the coccyx, while the notches and the sacral cornua are on its sides.

The *lateral borders*, anteriorly, are roughened for attachment to the iliac bones under which they lie, and with which they form the sacro-iliac joint; posteriorly, they are roughened for the attachment of the sacro-sciatic ligaments, and terminate in small transverse processes—the sacral cornua.

The sacrum has five articular surfaces on its base, one on each side, and one on its apex. Its spinal canal is somewhat triangular in shape, and decreases much in size posteriorly.

#### THE COCCYX.

(PL. I. I.)

The *coccygeal* or *caudal vertebræ*, are false vertebræ, varying in number from thirteen to twenty. In form, they are the most rudimentary of all the vertebral segments; their centra are

oblong, mostly constricted in the centre, and expanded where they articulate with one another: the four or five anterior ones are slightly flattened above, hollowed longitudinally below, and they possess generally incomplete arches and imperfectly-developed processes. The remaining segments consist merely of centra, which diminish in size posteriorly. There is, therefore, no complete neural canal in the caudal region, only the first two or three vertebræ being sometimes found with their neural arches complete.

## THE THORAX.

The dorsal vertebræ superiorly, the ribs and their cartilages laterally, and the sternum or breast-bone inferiorly, form the skeleton of a large cavity called the *Thorax*.

## THE RIBS.

(PL. I. T. T.)

In the horse the ribs usually number eighteen on each side. They extend in a series of arches of varying curvature from the dorsal vertebræ above, towards the sternum and sides of the abdomen below. Their shape, in a great measure, determines the conformation of the thorax; they protect its contents, and materially aid in its contraction and expansion.

To the distal end of each rib an elongated piece of cartilage is attached, and eight of these connect the eight anterior, termed *sternal* or *true ribs*, with the sternum; the ten posterior ribs, having only an indirect sternal attachment are known as *asternal* or *false ribs*. The ribs pass first outwards and backwards, and then in an arched direction downwards, their cartilages inclining inwards and forwards. They gradually lengthen from the first to the ninth, after which they progressively shorten; their curvature increases from the first, which is nearly straight, to the last, which forms a large segment of a comparatively small circle. The greatest breadth is attained in the fifth, sixth, seventh, and eighth, which, in their middle portions, exhibit the more especial characters of flat bones.

Each rib presents for consideration superior and inferior extremities, and a shaft or body having anterior and posterior borders and external and internal surfaces.

The *superior* or *proximal extremity* consists of a head, a neck, and a tubercle. The head, which rests in a cavity in the vertebræ, is separated by a vertical furrow, in which the interarticular ligament is attached, into two convex articular surfaces—one of which is directed forwards and inwards, and the other backwards and inwards. The *neck* is the constricted portion supporting the head; it is strong and roughened for ligamentous attachment; and has a groove for the intercostal nerves and blood-vessels running across it in front. The *tubercle* is the prominent eminence at the posterior part of the neck; it has a flat, smooth facet, which articulates posteriorly with the transverse process of a vertebra. External to the tubercle is another eminence, the *angle*, where the rib is suddenly bent downwards; the distance between the angle and the head of the rib gradually increases from the third to the last, the first two scarcely possessing angles. In the third and fourth ribs the angles and the tubercles are from one to two inches apart, which distance increases, in a well-formed horse, to nearly five inches in the last. In horses possessing well-rounded chests the costal angles are plainly marked and separated from the vertebræ, so as to form large costal grooves for the dorsal muscles; in flat-sided animals they are indistinct and close to the spinal column, the grooves being consequently narrower.

The *inferior* or *distal extremity* is expanded and constructed of more elastic bone than the proximal extremity; it is quite porous, and joined firmly to its cartilage. The *anterior border* is rough, and excavated along its upper third to give attachment to the intercostal muscles. The *posterior border* is grooved along its upper third for the intercostal muscles, nerves, and blood-vessels; in both borders the distal portion is thinner in the anterior than in the posterior ribs. The *external surface* is convex in every direction; between the head and the angle it is roughened for muscular attachment, and below this point smooth, excepting in a few places, the chief of which, a short distance below the angle, give attachment to muscles. The *internal surface*, concave from above downwards, and convex from side to side, is smooth, and for the greater part covered by the pleura, the membrane lining the thorax.

With the exception of the last, and sometimes the last two on each side, each rib has its cartilage. These cartilages, which contain a large quantity of earthy or bony material, pass obliquely

forwards and inwards; they diminish in thickness from before backwards, but increase in length to the eleventh or twelfth, after which they again grow shorter. Those attached to the true ribs are smallest at their proximal ends, becoming expanded before they articulate with the sternum; those of the false ribs are largest at their proximal ends, and, gradually tapering to fine points below, they pass forwards and downwards, so that, having no inferior articulations, each is overlapped by the succeeding one.

The special ribs are the two first and the last four or five. The first is shorter and straighter than the others, with rough surfaces, rounded borders, and no well-defined posterior groove; its head is irregular in shape, and exceeded in size by the tubercle, and its distal end is flattened and expanded laterally, joining the short thick cartilage, which contains much ossific matter. The second possesses the above-named characters of the first in a less degree. The last four or five are slender; the articular surfaces of their tubercles and the posterior divisions of their heads are usually continuous; their curvature is great; they are broadest immediately behind the tubercle, and their cartilages are remarkably slender and elongated.

Each true rib has four articular surfaces, two on the head, one on the tubercle, and one at the distal end.

#### STERNUM.

The sternum or breast-bone, a comparatively small and short bone in the horse, is single in the adult, and placed in the inferior longitudinal line of the body at the antero-inferior part of the thorax. The anterior portion somewhat resembles the keel and cut-water of a boat; it is elongated and concave above, convex below, with its anterior part flattened laterally, and its posterior part flattened above and below. It is constructed of six, rarely seven, irregularly-formed segments or *sternebrae*, united by cartilage in the young animal, and by partial ossification in the adult; complete ossification seldom or never takes place in this bone. Its anterior end is surmounted by the cariniform cartilage, and its posterior extremity prolonged by the ensiform or xiphoid cartilage.

Its *superior surface* is triangular in outline and concave, the superior sternal ligaments traversing its lateral borders. Its

inferior surface is narrow anteriorly and convex, the centre presenting a prominent ridge coated with cartilage, materially increasing the *lateral* surfaces, which give origin to the pectoral muscles; the sides are flat and irregular, and present between the segments depressions, in which the cartilages of the true ribs articulate, another depression being entirely formed in the first, and an eighth in the last segment. These depressions are oval in shape, and are nearer to each other as they proceed backwards.

The *Cariniform* or *keel-shaped cartilage* presents a convex border looking forwards and upwards, and elevated so as to surmount the articular depressions for the first pair of costal cartilages, to which it is attached by ligaments; laterally it is flattened to increase the surface for muscular attachment; and its inferior border, prolonged over the first segments of the sternum, terminates in the cartilaginous ridge. The prominent convexity which this cartilage forms may often be plainly distinguished in the living animal.

The *Xiphoid* or *Ensiform cartilage* is somewhat heart-shaped, the apex being directed downwards and backwards. Its superior surface, broad and cup-shaped, occupies a space bounded by the cartilages of the false ribs, and supports part of the abdominal viscera. Its inferior surface is convex, and roughened for muscular attachment, and its free borders are thin. It affords attachment for muscles, and for a fibrous cord called the *linea alba*.

The bony framework of the thoracic cavity bears some resemblance to a truncated cone, with its apex or anterior extremity compressed laterally. The anterior aperture is a triangular space, having its apex directed downwards and slightly forwards, formed by the sternum, the first pair of ribs, and the first dorsal vertebra; it gives passage to the œsophagus, trachea, and various important nerves and blood-vessels. The base or posterior aperture is oval in outline, and slopes obliquely downwards and forwards from the vertebræ; it is formed by the last dorsal vertebra, the last pair of ribs, the cartilages of the false ribs, and the Xiphoid cartilage, and its boundary gives attachment to the diaphragm, a large muscular curtain which separates the thorax from the abdomen.



## THE SKULL.

## GENERAL VIEW.

The skull, or skeleton of the head, the most anterior part of the horse's skeleton, articulates with the first cervical vertebra, from which it is suspended by its posterior extremity, its anterior extremity being free. Its position varies with the attitude of the animal; but in our descriptions we shall allude to it as if it were placed in a horizontal position, as in Fig. 12.

In the young animal the skull is composed of a number of bones, all of which, with the exception of the lower jaw, the teeth, the bones of the tongue, and ossicles of the ear, become united by ossification in the adult; excluding the teeth and the internal bones of the ear, there are thirty-eight bones in the skull—six single ones, and the rest pairs.

The skull is divisible into two parts—viz., the *cranium* or *calvarium*, and the *face*. The former is a cavity situated in the supero-posterior region of the skull, and continuous with the spinal canal; it contains the brain and its appendages, and in the horse is comparatively a small cavity, occupying about one-fifth of the skull. The remaining bones of the skull collectively form the face, hence the whole structure is composed of cranial and facial bones. We shall first endeavour to give a general idea of the articulated skull, and afterwards describe separately the bones which compose it.

The bones of the head are in early life united to each other by means of *sutures*, or interposed layers of fibrous material, and after union by ossification, a well-marked line usually indicates

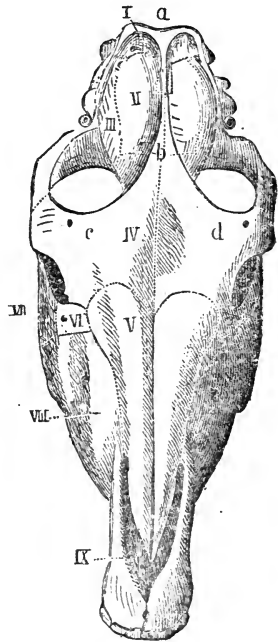


FIG. 10.

Skull of the Horse seen from above  
 I. Occipital bone; II. Parietal bone; III. Squamosal bone; IV. Frontal bone; V. Nasal bone; VI. Lachrymal bone; VII. Maler bone; VIII. Superior Maxilla; IX. Premaxilla. a, Orbital process; b, Parietal crest; c, Occipital crest; d, Supraorbital foramen.

the position of the late suture. One of the principal sutures of the skull is the *longitudinal*, which extends in the median line from the poll to the nasal peak, and marks the division of the skull into two lateral halves.

In shape the skull resembles a quadrangular pyramid, and contains various cavities or chambers. Supposing it to be placed in the horizontal position resting on the lower jaw, we can more easily give a general description of the most important external features if we divide it into the following regions:—Superior, Inferior, Lateral, Anterior, and Posterior:

The *Superior* region is a surface formed by three pairs of bones, called the parietal, frontal, and nasal, each bone being joined to its fellow by a part of the longitudinal suture. The parietal bones are the hindermost of the three, and are convex, forming part of the roof of the cranium or brain cavity, while the frontal or middle pair are flatter, and very broad above the level of the orbits, the region of the forehead. The nasal bones together form a semi-cylinder, and gradually diminish in breadth anteriorly, finally forming the projecting nasal peak. The prominent transverse ridge bounding this region posteriorly is the occipital crest.

The *Inferior* region presents a very irregular surface, bounded below by the inferior maxilla or lower jaw, a bone whose two segments are firmly united anteriorly, but diverge backwards somewhat in the form of a letter V, each terminating superiorly in a convex articular surface, the maxillary condyle, before which is the prominent coronoid process, the lever of the lower jaw. The diverging parts or *rami* of the jaw include a space, appropriately called the maxillary space. We find in the united or anterior portion of this bone the inferior incisor and, in the male, the canine teeth, and in the rami the inferior molars or grinders; the space between the molar and front teeth is called the *diastema* or interdental space, and is always large in herbivorous animals.

If we remove the inferior maxilla, we notice the following objects:—Anteriorly the premaxilla, bearing the upper incisor and partly the canine teeth, and just behind the incisors, in the median line, a small round aperture, the foramen incisivum, while the interdental space and molar teeth are similar to those in the lower jaw. The flattened surface extending from the incisors backwards between the molars is the bony palate, formed chiefly by the superior maxilla, and bounded posteriorly by the *palatine*.

*arch*, which is semi-elliptical in form, and marks the entrance to a large cavity above called the *nasal chamber*; this cavity is in the fresh state, divided into right and left compartments or *fossæ* by a cartilaginous septum.

Between the posterior molars and the palatine arch are the two palatine foramina. Behind, and bounded by the palatine arch, are the entrances to the nasal chamber, right and left, called the *posterior nares*, and the slender median bone stretching from behind forwards in the cavity is the vomer; it indicates the division of the chamber into right and left fossæ. Continuous with the vomer we find an irregular column of bone reaching to the back of the skull; this column consists of three pieces, the pre-sphenoid anteriorly, then the basi-sphenoid, and lastly the basi-occipital bone. These bones are respectively parts of the sphenoid and occipital bones, and they, together with the vomer, are regarded as the centra of the *cranial vertebrae*; and the ossified suture between the last two bones is usually marked by a roughened ridge.

On the posterior edges of the palatine arch are two small sharp projections, the ends of the pterygoid bones, and behind them the rough palatine ridges, the posterior edges of which are formed by the pterygoid processes of the sphenoid bone; outside the base of each of these processes we have the posterior aperture of the *subsphenoidal* or *pterygoid foramen*, which gives passage to an important artery. There are two large, rounded, and may be roughened prominences, the alveolar tuberosities, immediately behind the last molar teeth, and between them and the palatine ridges and pterygoid bones are the smooth staphyline grooves.

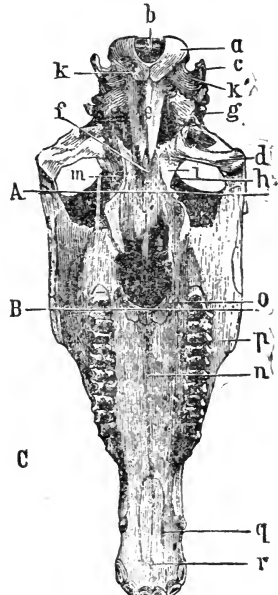


FIG. 11.

Inferior aspect of Horse's skull, the mandible being removed. Above the line *A* is the posterior region or *base*, between *A* and *B* the middle, and below *B* the anterior or nasal region. *a*, Occipital condyle; *b*, Foramen magnum; *c*, Styloid process; *d*, Temporal articular surface; *e*, Basi-occipital, and *f*, Basi-sphenoid bones; *g*, Petrosal bone; *h*, Lili-sphenoid bone; *i*, Temporal bone; *k*, Condyloid foramen; *k'* Condyloid notch; *l*, Foramen lacerum basis cranii; *m*, Pterygoid foramen; *n*, Palatine suture; *o*, Palatine foramen; *p*, Molar teeth; *q*, Incisive opening; *r*, Foramen incisivum.

Outside the palatine ridges there are two very large spaces, the orbito-temporal cavities; each of these is bounded externally by the *zygomatic arch*, a horizontal process composed of parts of the ~~malar~~ and squamosal bones, anteriorly by the alveolar tuberosity, posteriorly by the articular surface of the squamosal bone, with which the inferior maxilla articulates, and internally by the sphenoid and palatine bones. The cavities open each by two large apertures on the lateral aspect of the skull; the posterior portion being called the temporal, the anterior the orbital fossa. In the higher orders of mammals, the *bimana* and *quadrumana*, these two fossæ are completely separated from each other by a bony process or plate. The articular surface of the squamosal bone, above named, terminates posteriorly in a projection called the anterior mastoid process, behind and internal to which is a very irregularly-shaped bone, the petrosal, characterised by the *external auditory meatus*, a bony tube which is directed outwards and upwards, and also by a slender spike, projecting downwards and forwards, called the styloid process; the petrosal bone contains the internal mechanism of the ear, and also gives attachment to the cornu of the *os hyoides*, or bone of the tongue.

Between the petrosal and basi-occipital bones we have a large and very irregularly-shaped aperture, leading into the cranial cavity; this is the *foramen lacerum basis cranii*, and it gives passage to some important nerves and vessels; anteriorly, the foramen lacerum is bounded by a flattened plate, the part of the sphenoid bone called the wing or ali-sphenoid; and on the internal part of the edge of the wing is the carotid notch, through which the endocarotid artery enters the cranium. Posterior to the petrosal bones, two large processes point downwards; these are the occipital styloid processes, which must be distinguished from the small petrosal ones before alluded to. Still farther back we have the *occipital condyles*, by which the head articulates with the atlas; a deep notch, the stylo-condyloid notch, separates each condyle from the styloid process, and at the bottom of the notch on its internal aspect is the condyloid foramen, leading into the cranium.

The *Lateral surfaces* exhibit inferiorly the external face of the rami of the inferior maxilla, and antero-superiorly a triangular space, formed chiefly by the superior maxilla, more or less convex but sometimes hollowed in old animals, and presenting the infra-

orbital foramen in its centre. The zygomatic arch presents externally a well-marked edge or line, which is continued anteriorly by a ridge, called the maxillary spine. A process thrown outwards and downwards by the frontal bone articulates with the zygomatic arch about its middle; it is called the frontal or external orbital arch, and it indicates the division of the cavity within into orbital and temporal fossæ.

The orbital fossa is a conical cavity, the oval entrance of which is circumscribed by the frontal, the lachrymal, malar, and part of the zygomatic process of the squamosal bone; in addition to these, the cavity is formed by the superior maxilla, the palatine, and the anterior wing of the sphenoid, called the orbito-sphenoid

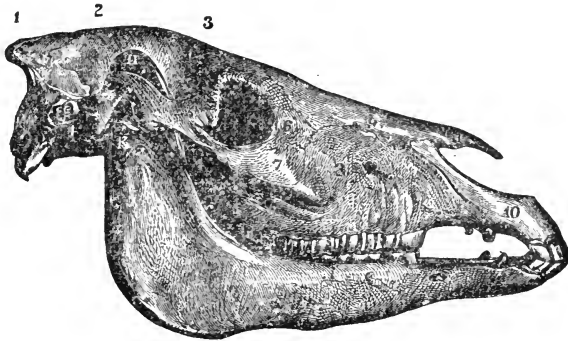


FIG. 12.

Lateral aspect of a Horse's skull. 1, Occipital bone; 2, Parieta bone; 3, Frontal bone; 9, Nasal bone; 11, Nasal peak; 10, Premaxilla; 8, Superior maxilla; 6, Lachrymal bone; 7, Malar bone; 5, Zygomatic process of the squamosal bone; 4, Petrosal bone—*e*, its external meatus; 12, Inferior maxilla; H, Coronoid process of inferior maxilla occupying the temporal fossa; K, Temporo-maxillary articulation; *l*, Molar teeth.

bone. Deep in the fossa anteriorly is a depression, the maxillary hiatus, which leads to the palatine, speno-palatine, and superior dental foramina, and posteriorly another depression, the orbital hiatus, containing the optic, pathetic, lacerated, and round foramina. This cavity contains the eye, the muscles by which it is moved, the lachrymal gland, and all accessories to the organ, together with a large quantity of adipose tissue or fat.

The temporal fossa is incompletely separated from the orbital by the orbital arch, complete separation of these cavities by a wall of bone being found only in man and the quadrumana. It is oval in shape, situated in an oblique direction, from within

outwards, and is bounded internally by a rough line, the parietal crest, and externally by the superior edge of the zygomatic process. It lodges the temporal muscle and the lever process of the lower jaw, and contains many foramina, which lead to a cavity between the bones called the parieto-temporal conduit.

The *Posterior* part or base of the skull presents superiorly the roughened *occipital crest* continued downwards by the sharp mastoid ridges, which again are continuous with ridges on the squamosal bones, and so with the upper edges of the zygomatic arches. Below the crest is a broad, slightly-roughened surface, and below that, in the median line, is the neural canal of the occipital bone, called the *foramen magnum*, bounded laterally by the condyles, which again are flanked by the styloid processes, and separated from them by the stylo-condyloid notches.

The *Anterior* part or apex, formed by the premaxilla and body of the inferior maxilla, contains the incisor teeth, and is more or less rounded in profile, according to the age of the animal. In front, it is surmounted by the external opening of the nasal cavities; this opening, included between the premaxilla and the nasal spine, is divided, in the fresh subject, into two orifices, the *anterior nares*.

#### CAVITIES IN THE SKULL.

The skull contains internally the *cranial cavity*, the *nasal fossæ* or chambers, and the *sinuses*, which are appendages to the latter.

#### CRANIUM.

The Cranium is an extremely irregular ovoid cavity, the walls of which are formed by the frontal, parietal, occipital, temporal, sphenoid, and ethmoid bones. For the purpose of description, it may be regarded as being divisible into a roof, a floor or inferior surface, two lateral surfaces, and two ends.

The *Roof* presents, towards its posterior third, in the median line, the parietal protuberance, or *ossific tentorium*, which, with the two lateral ridges springing from it, and which may be regarded as a part of it, assists in dividing the cranial cavity into two compartments—a posterior one, for the cerebellum, and an anterior, considerably larger, for the cerebrum. Along the median line, from this eminence to the front of the roof runs a groove, the roughened elevated borders of which form a rudi-

mentary crest, to support the membrane which divides the compartment into two lateral sections, one for each hemisphere of the cerebrum. Folds of membrane attached to the protuberance, and lateral ridges, also render the transverse partitioning of the cavity more perfect.

The *Lateral surfaces* are concave, and, like the roof, marked with numerous smooth grooves and impressions. They assist in the division into cerebral and cerebellar compartments by means of the parieto-temporal ridges, which are prolonged obliquely as far as the sphenoid bone, the first portion being formed by the occipital and internal face of the petrosal, and the second by the squamosal bone.

The *Floor* or *inferior surface* is very irregular, and presents, from behind forwards, in the median line, the bones which

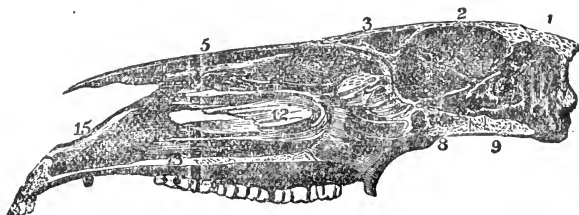


FIG. 13.

Longitudinal section of a Horse's skull. 1, Supraoccipital bone and crest; 2, Parietal bone; 3, Frontal bone; 4, Frontal sinus; 5, Nasal bone; 6, Superior turbinal; 7, Inferior turbinal; 8, Superior maxilla, and 13, its palatine plate; 9, Premaxilla; 10, Palatine bone; 11, Ethmoid bone and volutes; 12, Basi and pre-sphenoid bones; 14, Basi-occipital bone; 15, Petrosal bone. The cranium is the cavity under 1 and 2.

represent the three posterior centra of the cranial vertebræ—viz., the basi-occipital, basi-sphenoid, and pre-sphenoid bones; and laterally we find the foramina lacera basis cranii, the remaining portion of the floor being formed by the ali-sphenoid and orbito-sphenoid bones the former presenting on each side of the centrum two grooves running forwards, and terminating in foramina. On the pre-sphenoid is a transverse slit, the *optic hiatus*, and the raised ledge posterior to it is the olivary process, behind which we find the sella turcica, a depression in the basi-sphenoid bone. Laterally, the bony floor coalesces with the walls so as to form deep ovoid cavities, which receive the mastoid or great lobes of the cerebrum.

The *Posterior end* contains the foramen magnum, by means of which the cavity communicates with the spinal canal.

The *Anterior end* presents the perpendicular crista galli process, in the median line, on each side of which are the ethmoidal fossæ, the cribriform lamellæ of the ethmoid bone forming their anterior boundary.

#### NASAL FOSSÆ.

The Nasal fossæ are two cavities, separated in the fresh state by a cartilaginous septum, which extends from the ethmoid bone to the anterior nares. The framework of these fossæ is formed by the nasal, the superior maxillary, the frontal, and the palatine bones, the whole forming a spacious irregular tube, bounded posteriorly by the ethmoid bone, two turbinated bones being situated in each fossa. The vomer in the median line, gives attachment below to the cartilaginous septum.

#### SINUSES.

These are winding cavities in the bones of the face. They communicate freely with each other and with the nasal fossæ, of which they may be regarded as prolongations. Ordinarily, they number four on each side—viz., the frontal, the maxillary, the sphenoidal, and the ethmoidal.

The *Frontal sinus* is situated inside the inner plate of the orbital fossa, its extremely irregular walls being formed by the frontal, nasal, lachrymal, ethmoid, and superior turbinated bones. It communicates with the maxillary sinus below by means of a large opening through the delicate bony partition between them. A thick vertical plate, often placed more to one side than the other, and always imperforate, separates this sinus from that of the opposite side.

The *Maxillary sinus*, formed below, and before the orbit by the superior maxillary, malar, ethmoid, lachrymal, and inferior turbinated bones is the largest of the sinuses. A ridge which contains the superior dental canal, divides it into two chief compartments—an internal, which is a shallow recess continuous with the sphenoidal, and communicating with the ethmoidal sinus, and an external, divided into two chambers by a transverse plate, which frequently (according to some authorities, always) remains perfect through life, and completely isolates the anterior chamber. The posterior of these chambers is prolonged backwards to the alveolar tuberosity, and has the roots of the two last molar teeth



utting into it. The anterior chamber is subdivided into two parts, the internal of which is prolonged into the inferior turbinal bone, the external, which is the smallest, having an elevation on its floor caused by the root of the fourth molar tooth.

The *Sphenoidal sinus* is a small irregular cavity formed in the sphenoid, ethmoid, and palatine bones. It is subdivided by incomplete partitions into several compartments, especially into an anterior included between the plates of the palatine, and a well-marked posterior one, excavated in the pre-sphenoid bone; the latter is separated from its fellow on the opposite side by a perforated lamella.

The *Ethmoidal sinus*, the smallest of these cavities, is a space included in the volute of the ethmoid bone. It communicates by a small opening with the maxillary sinus.

The sinuses which contain air, and are larger in the adult than in the young animal, are partially divided by imperfect septa, which run across their interior; in the fresh state they are lined with mucous membrane.

## SEPARATE BONES OF THE SKULL.

### CRANIAL BONES.

The bones of the Cranium which we now proceed to describe separately, are the occipital, sphenoid, ethmoid, and Wormian bones, which are single, and the parietal, frontal, and temporal bones, arranged in pairs; the temporal bone is, in the horse, divided into two parts, the squamosal and petrosal bones.

### OCCIPITAL BONE.

(Fig. 10. I.; 12. 1.)

This bone occupies the posterior part of the skull, and is in the young animal divisible at first into four pieces, and afterwards into two, which finally unite to form one bone; it is very irregular, and presents an external and an internal surface and borders.

The *external surface* may be thus described. The upper or supraoccipital portion being very much exposed, is thick and strong; it terminates superiorly in a prominent crest, the *crest of the occiput*, which is convex anteriorly, and gives attachment to the

complexus major muscle, and below it at the back is the *occipital tuberosity*, on each side of which there is a roughened depression for the attachment of the cordiform part of the ligamentum nuchæ. The *occipital* or *mastoid ridge*, continuous with the squamosal bone, descends from the crest on each side, and gives attachment to various muscles. The inferior or suboccipital portion presents a little below the tuberosity, a large, oval hole, the *foramen magnum*, through which pass the spinal cord, the spinal accessory nerves, and the basilar artery; the sides of this foramen, the transverse diameter of which is the larger, are slightly roughened for the attachment of the long odontoid ligaments, and on each side is a large rounded prominence, the *condyle*, which articulates with the atlas. A large process, the *basilar process* (basi-occipital bone), passes forwards from the lower part of the condyles, and forms the floor of the foramen magnum, being flattened and slightly hollowed above, but rounded below, where it gives attachment to the rectus capitis anticus major and minor muscles; it articulates with the sphenoid bone in front, and has a fissure, the *basilar fissure*, running along its under surface, terminating posteriorly in the foramen magnum. Two flattened *styloid* processes extend downwards from the sides of the bone, and give attachment to the obliquus capitis anticus, stylo-maxillaris, and stylo-hyoideus muscles; and between each of these processes and the condyle is a deep notch, the *condyloid* or *stylo-condyloid notch*, at the bottom of which and just in front of the condyle, is the *condyloid foramen* which gives passage to the twelfth nerve.

The *internal* or *cerebral surface* has, in the supraoccipital portion, a vaulted concavity termed the *occipital cupola*, which covers the cerebellum; while the superior surface of the basilar process presents a pit, the *basilar fossa*, in the anterior part of which the pons varolii lies, and in the posterior part the medulla oblongata. The small foramina which enter the basilar process from within the foramen magnum are for the passage of nutrient blood-vessels. The superior border is serrated, and articulates with the parietal and the lateral borders with the petrosal bones.

The occipital bone resembles a vertebra more than any other of the so-called cranial vertebræ; in the young state it separates into an inferior or basi-occipital part, representing the centrum; two lateral exoccipitals, representing the pedicles, laminae, &c.; and above, the supraoccipital portion, corresponding to the

tubercle of the neural spine. The occipital bone articulates with eight bones—the parietals, squamosals, petrosals, sphenoid, and the atlas.

## PARIETAL BONE.

(FIG. 10. II. ; 12. 2.)

These bones are situated at the superior and lateral parts of the cranium, of which they form the walls and part of the roof. The parietal is a large thin bone, possessed of an external and an internal surface, and four borders.

The *external surface* is convex and smooth. On each side of the sagittal suture, formed by the junction of the two parietal bones, there is a curved ridge, to which the temporalis muscle is attached; these ridges together form an angle, the point of which joins the occipital crest. The lateral parts of this surface are roughened, to articulate with the squamosal bone.

The *internal surface* is concave, and marked by numerous grooves and indentations, which correspond with the convolutions of the brain. A groove, termed the *longitudinal groove*, and generally formed by a ridge or crest, runs along the junction of the two bones, and gives lodgment to the longitudinal sinus of the dura mater; this crest terminates posteriorly in a three-sided process, the *parietal protuberance* or *ossific tentorium*, to which, as well as to the crest, is attached the falx cerebri, a part of the dura mater which contains the above-named sinus. In front of this process the longitudinal groove ends in two transverse grooves, which lodge the transverse sinuses of the dura mater, and are continued down to the parieto-temporal conduit, a passage formed between this bone and the temporal.

The *posterior border* of this bone is thick and denticulated, and articulates with the occipital; the *anterior border* is slightly concave and strongly serrated, articulating with the frontal bone; the *internal border* is denticulated, and united to its fellow of the opposite side, forming the sagittal suture; the *external border* is divided by a prominent angle into two parts, the anterior one being thin, and articulating with the squamosal, while the posterior is thicker, and articulates with the petrosal bone, the prominent angle or crest meeting the sphenoid bone.

Sometimes the sagittal suture is interrupted or rendered bifid posteriorly by the insertion of a small bone, generally triangular

in shape, and called the *os triquetrum*, or Wormian bone; the ossific tentorium springs from this bone when present. The parietal bone articulates with its fellow, the occipital, frontal, squamosal, petrosal, and sphenoid—*i.e.*, with six bones, or with seven when the Wormian bone is present.

#### FRONTAL BONE.

(Figs. 10. IV.; 12. and 13. 3.)

This bone is situated at the antero-superior part of the cranium, and the pair constitute the broad, flat part called the forehead; their union in the centre of the forehead forms the *frontal suture*. Each frontal bone is irregular in shape, flat externally, smooth and concave internally, and presents external and internal surfaces and four borders.

The *external surface* is somewhat prominent above and slightly depressed below, and has a lateral process, the *external orbital*, which arches downwards and slightly backwards, and bounds part of the orbital fossa; it articulates with the zygomatic process of the squamosal bone, and is also termed the frontal arch. The foramen piercing the superior part of this process is the supra-orbital, which transmits the artery, vein, and nerve of the same name. The thin plate which extends downwards and backwards from the external lateral border of the bone is the *internal orbital plate* or *process*, divided by a large triangular opening closed, in the articulated state, by the orbital portion of the sphenoid; and the small notch in front of the large one forms, with the sphenoid bone, the internal orbital foramen. The pit or hollow above the larger notch lodges the lachrymal gland; and the small depression at the base of the external orbital process is for the attachment of the greater oblique muscle of the eye. The slightly-depressed part behind the orbital process assists in forming the temporal fossa.

The *internal surface* is irregularly concave, and divided into two unequal parts by a bony septum, the cranial plate, which meets the cribriform plate of the ethmoid bone. The posterior division is smooth, and marked by ridges, which correspond with the convolutions of the brain, the anterior lobe of which it covers; a furrow for the anterior meningeal artery runs upwards from the internal orbital foramen, and close to the ethmoid bone. The continuation of the longitudinal groove of the parietal bone

runs along the median line; and near the inner surface of the orbital plate is a longitudinal notch, the *incisura sphenoidalis*, into which the orbital portion of the sphenoid bone is received. The anterior concavities form the frontal sinus, which is separated from its fellow by a prominence termed the nasal spine, on the posterior part of which is a rounded surface, which joins the crista galli process of the ethmoid bone.

The *posterior border* is divided into two parts, both of which are denticulated, the superior part articulating with the parietal, while the inferior or descending part is overlapped by the squamosal bone. The *anterior border* is pointed at the frontal suture, and articulates partly with the nasal and partly with the lachrymal bone. The *internal border* is straight and triangular, the widest part being at the septum; it joins its fellow. The *outer and inferior border* is very irregular, and articulates with the sphenoid and lachrymal bones. The frontal bone articulates with nine bones:—its fellow, the parietal, squamosal, sphenoid, ethmoid, lachrymal, nasal, palatine, and superior maxillary bones.

## TEMPORAL BONE.

(Fig. 12. 4, 5.)

Situated at the side of the cranium, the temporal bone is divided, in the horse, into two distinct pieces, named the squamosal or squamous temporal and the petrosal or petrous temporal bones.

The SQUAMOSAL BONE (Fig. 10. III.) is irregularly oval, flattened, and slightly curved, with a strong process arching outwards and forwards. It has an external and an internal, or cerebral surface, and a circumferent border.

The *external surface* is rather convex, presenting numerous small foramina, which lead into the parieto-temporal conduit, a cavity between it and the parietal bone. Projecting outwards and forwards from its middle is a long, arched, process, the *zygomatic*, which unites with a similar process of the malar bone to form the zygomatic arch, on which the frontal arch abuts superiorly. Posterior to this abutment is a broad convex surface, which forms the inferior part of the temporal fossa; and projecting upwards from the postero-external part of the fossa is the sharp *zygomatic spine*. The shallow transverse concavity on the inferior face of the zygomatic process is the glenoid cavity, with which the condyle of the lower jaw articulates; and continuous

with this cavity, anteriorly, is an articular ridge, the condyle, which also forms part of the articulation, and posteriorly the *anterior mastoid process*, which limits the motion of the articulation; the opening of the *parieto-temporal conduit* or canal is at the base of the process. Posteriorly, the bone divides, the inferior portion being beaked, and clasping the external auditory meatus of the petrosal bone, and the other extending backwards, to articulate with the occipital, the occipital ridge becoming continuous with the prolongation of the zygomatic spine.

The *internal surface* is divided into two very unequal portions by a deep channel, which forms, with the parietal and petrosal bones, the *temporal* or *parieto-temporal conduit*. The posterior portion articulates with the petrosal bone, while the posterior half of the anterior and larger portion is greatly roughened and bevelled, superiorly, forming with the parietal bone the *squamous suture* of the skull: such of the remaining portion as forms part of the wall of the cranial cavity is marked similarly to the internal surface of the other cranial bones; the remainder articulates with the ali-sphenoid bone.

Thus the squamosal bone articulates with the petrosal, parietal, occipital, frontal, sphenoid, malar, superior and inferior maxillary bones.

The **PETROSAL BONE** is the hardest bone in the skeleton, and is interesting, as it contains the essential part of the organ of hearing. It is a small, thick bone, somewhat pyramidal in shape, the base being turned downwards and a little backwards, and it is placed at the postero-lateral part of the cranium between and below the occipital, parietal, and squamosal bones. It presents four surfaces, a summit, and a base.

The *anterior surface* is divided into two portions, the more external part being roughened, and articulating by harmony with the parietal bone, while the inner and lesser portion is smooth, and forms the posterior part of the cavity for the greater lobe of the cerebrum. The *posterior surface* is triangular and rough: and articulates by harmony with the occipital bone. The *external surface*, also triangular, is divided into two parts, the inner articulating with the squamosal, the outer being interposed between the occipital ridge and the styloid process of the occipital bone. The *internal surface*, which forms the lateral boundary of the cavity for the cerebellum, is slightly concave, and presents several depressions, and anteriorly a large orifice and conduit, the *internal*

*auditory meatus*—a short canal through which the auditory and facial motor nerves pass, and which is divided by a thin plate into two parts, one leading by small foramina to the internal ear, the other being the origin of the *aqueduct of Fallopius*, which, after taking a spiral course through the bone, terminates externally by the stylo-mastoid foramen. A narrow slit, the *aqueduct of the vestibule*; near the meatus, transmits a small vein and artery, and lodges a process of dura mater.

The four surfaces are separated by four borders or angles, two of which deserve notice,—the first, separating the external from the posterior surface, is thick and rough, and forms the *mastoid ridge*, which is continuous with the occipital ridge above, and has the *posterior mastoid process* in front; the *mastoid fissure* runs across this angle, passing upwards under the squamosal bone to terminate in the parieto-temporal conduit. The second, separating the anterior from the internal surface, marks the division between the cavities of the cerebrum and cerebellum, and has a process of dura matter attached.

The *summit* of the bone is pointed, and articulates with the occipital; the *base* is very irregular in outline, and presents a large opening, the *external auditory meatus*, which leads to the middle ear, and is surrounded by an oval rim of bone, which is notched in the middle, and gives attachment to the cartilages of the ear. Below this opening is the *hyoid process*, to which is attached the cornu of the hyoid bone, and between which and the mastoid process is the *stylo-mastoid foramen*, the external opening of the aqueduct of Fallopius. The rounded part immediately below the hyoid process is the *mastoid protuberance* or *auditory bulla*, which is little developed in the horse, containing the mastoid cells; before, and projecting forwards, is the long and slender *styloid process*, which gives attachment to muscles, the *Glaserian fissure* (*styloid foramen*) for the corda tympani nerve being above it, and the opening for the Eustachian tube below and inside. More internally, a well-marked ridge forms the external boundary of the foramen lacerum basis cranii.

The petrosal bone articulates with the occipital, parietal, and squamosal bones, and with the hyoidean cornu.

## SPHENOID.

(FIG. 13. 8.)

This is a single bone situated in the middle and anterior parts of the base of the cranium. between the occipital and ethmoid bones, and transversely between the two frontal and temporal bones. Its shape is generally likened to that of a bird in flight, with its legs and wings extended. In the young state this bone separates readily into two parts. an anterior and a posterior. Anatomically, it may be divided into two centre-pieces, and two pairs of flattened processes or wings. The posterior centre-piece is then termed the basi-sphenoid. articulating behind with the basi-occipital, and before with the other centre, the pre-sphenoid, the two constituting the *body* of the bone. The expanded parts, collectively termed the *wings*, are formed of two plates from the posterior centre called the ali-sphenoid, and two considerably larger ones from the anterior centre, the orbito-sphenoid bones. Although for descriptive purposes it may be sufficient to divide the bone into a body and two wings, still it is well to bear in mind the above divisions and names.

The *body* is semi-cylindroid in form, convex inferiorly, where it is roughened for muscular attachments. and on either side is the long pterygoid process. continuous with the posterior wing. On each side of the body, and winding round to the anterior part of the pterygoid process. is a small groove, the Vidian fissure, which the palatine bone converts anteriorly into the small Vidian canal, through which the nerve of that name passes to join the spheno-palatine ganglion. Above this fissure, and passing through the base of the pterygoid process, is the large *pterygoid foramen*, which bifurcates anteriorly, the larger and inferior branch giving passage to the internal maxillary, while the smaller, which is directed upwards, lodges the anterior deep temporal artery; and in front of the process is a large irregular opening, *the orbital hiatus*, into which various foramina open. Still more anteriorly is the optic foramen; and at the anterior border of the body, a notch, which with the frontal bone, forms the internal orbital foramen, giving passage to branches of the ophthalmic artery and nerve.

The *internal* or *superior surface* is smooth, and presents, in the posterior segment of the body, a shallow fossa, the *pituitary*



*fossa* or *sella turcica*, in which the pituitary gland is lodged; in front of the *sella turcica* is a slight elevation formed by the pre-sphenoid, the *olivary process*, which supports the commissure of the optic nerves. Immediately in front of the olivary process is the *optic hiatus*, a transverse notch which leads to the two optic foramina for the optic nerves; and anteriorly is a sharp central process which articulates with the *crista galli* process of the ethmoid bone. A concavity on each side of the anterior part of the body helps to form the ethmoid fossa, which contains the olfactory bulb.

On each side of the *sella turcica* are two shallow grooves, the internal being the *cavernous fossa*, which contains the cavernous sinus of the brain, and the ophthalmic, third, and sixth nerves; the external, which is the larger and deeper, is the *sphenoidal fossa*, which transmits the superior maxillary division of the fifth nerve. In front of these lateral grooves, and continuous with them, two foramina open into the orbital hiatus, the inner and uppermost being the *foramen lacerum orbitale*, for the alveolar vein, and the third and sixth nerves; the inferior is the *foramen rotundum* for the passage of the superior maxillary division of the fifth nerve; it is joined by the pterygoid foramen. Above these, and passing through the base of the pterygoid process, the *foramen pathelicum* gives passage to the fourth nerve.

The *wings* project outwards and upwards; their internal surfaces are smooth, and help to form the lateral walls of the cranium, the posterior part being hollowed for the mastoid lobes of the cerebrum. The external surface of the wing is slightly convex anteriorly, where it joins the frontal bone to form the orbital fossa, and rough posteriorly, where it articulates with the squamosal bone. The *pterygoid processes* project downwards and forwards, are broad and flat, and articulate with the vomer and palatine bones.

The *posterior border* of the body articulates with the basi-occipital bone. The portion of the wing next to the body bounds anteriorly the *foramen lacerum basis cranii*; in this portion there are two notches, an internal one, the *carotid notch*, which gives passage to the endocarotid artery, and is continued under the body of the bone, and an external, the *inferior maxillary notch*, which transmits the nerve of the same name, a branch of the fifth.

The *anterior face* of the body of the bone presents two deep

cavities separated by a thin bony plate, sometimes perforated, which is continuous with the perpendicular plate of the ethmoid bone; these cavities are the *sphenoidal cells*, and help to form the *sphenoidal sinuses*. The sphenoid bone articulates with thirteen bones—the occipital, ethmoid, and vomer, single bones: and the superior maxilla, frontal, parietal, squamosal, and pterygoid, pairs.

#### ETHMOID.

(FIG. 13. 7.)

The ethmoid, or sieve-like bone, is placed between the frontal and sphenoid bones; it separates the nasal fossæ from the cranium, and consists of a perpendicular plate and two lateral portions.

The perpendicular plate or lamella, continuous with the cartilaginous septum of the nose, is covered, excepting in the cranium, with pituitary membrane; it divides the sphenoidal sinuses, is continuous with the septum dividing the frontal sinuses, and it joins the vomer below. Posteriorly, it forms the *crista galli process*, which projects upwards in front of the cranial cavity, is narrow inferiorly, where it joins the sphenoid, and broad superiorly, where it supports the frontal bone.

The *ethmoid cells* constitute the lateral parts of the bone. These are numerous and very fragile plates of bone rolled up into *conchæ* or *volutes*, which contain the ethmoid sinuses, and are attached to transverse plates. The *cribriform plates*, which are perforated for the passage of the olfactory nerves, separate the cranial from the nasal cavities. The concave posterior parts form the *ethmoidal fossæ*, the most anterior recesses of the cranium, which are, in the fresh state, occupied by the olfactory bulbs. The ethmoid articulates with ten bones—the sphenoid, vomer, two frontals, two palatines, two superior turbinals, and two superior maxillaries.

#### FACIAL BONES.

The facial skeleton consists of two parts, the superior and inferior maxillary, the regions respectively of the upper and lower jaw, each of which supports the passive organs of mastication, the teeth. The upper portion, which is traversed by the nasal cavities, is formed of nineteen distinct bones, one only of which,

the vomer, is single, the remainder—viz., the nasal, superior maxillary, premaxillary, malar, lachrymal, palatine, pterygoid, and turbinal bones being pairs. The lower jaw is a single bone, also called the inferior maxilla or mandible, and it includes between its rami the hyoid bone and its appendices.

## NASAL BONE.

(FIG. 10. V.; 12. 9, 11.)

The nasal bones are situated at the antero-superior part of the face, immediately before the frontal bones, and between them and the lachrymals and superior maxilla. They are long slender bones, flattened from above downwards, somewhat triangular in form, and heart-shaped when together. A nasal bone presents two surfaces, two borders, a base, and an apex.

The *superior* or *external surface* is smooth, convex from one side to the other, and becomes gradually larger posteriorly. The *internal surface* is concave, and forms the roof of the nasal fossa; a vertical ridge, to which the superior turbinal bone is attached, runs along its external border; posteriorly, this ridge bifurcates, and behind and within the bifurcation is a concave surface, which forms the *nasal* or anterior portion of the frontal sinus. Above this ridge the surface is smooth, and forms a gutter, the *superior nasal meatus*, and along the inner border is a slight ridge, which combines with that of the opposite bone to form a groove for the cartilaginous septum nasi.

The *internal border* is straight and dentated, and articulates with its fellow. The *external border* is very thin and waved, dentated in its upper two-thirds to articulate with the lachrymal bone, the superior maxilla, and the posterior part of the premaxilla, the remaining part being free, so as to leave an angular opening, the *naris*, between it and the premaxilla. The *base* or *superior border* is rounded, serrated, and unites with the frontal; the *apex* is sharp and pointed, forming with its fellow the nasal peak.

The nasal bone articulates with the frontal, lachrymal, superior maxillary, premaxillary, and opposing nasal bones, and has the superior turbinal bone attached to its inner surface.

## SUPERIOR MAXILLA.

(FIG. 12. 8; FIG. 13. 14.)

This is situated at the side of the face, and is the largest bone of the upper jaw, very irregular in form, and elongated from before backwards. It presents three surfaces, three borders, and two extremities.

The *external* or *facial surface*, concavo-convex in the adult, and somewhat convex in the young animal, is almost smooth, having an elongated horizontal ridge, the *maxillary spine*, continuous with the zygomatic spine of the malar bone, commencing opposite the third molar tooth, and running along the middle line of the posterior part of the surface. Near the middle of the upper surface is the large infra-orbital foramen, through which the facial division of the fifth nerve and a branch from the superior dental artery pass. The *inferior* or *palatine surface*, slightly hollowed from side to side, consists of a bony plate, the *palatine process*, which forms the greater part of the bony palate, or partition between the nasal fossæ and the mouth; it contains numerous small grooves and foramina, and one deep groove near its outer edge, the *palatine*, which is bounded by the alveolar processes of the molar teeth, and runs the whole length of the bone, giving passage to the palatine artery. The *internal* or *nasal surface* forms the sides and most of the floor of the nasal cavity; it is irregularly concave, smooth, and divided into two concavities by a longitudinal ridge, the *internal maxillary spine*, to which the inferior turbinal bone is attached. At the posterior part of this surface is a large, deep excavation, the *maxillary sinus*, below which is a serrated surface, articulating with the palatine bone, and containing a fissure, which, with a corresponding fissure in the palatine bone, forms the *palatine foramen*. A little anterior to the sinus is the opening of the lachrymal conduit, which is continued by a shallow fissure to the anterior extremity of the bone; along this conduit and fissure passes the lachrymal duct, which conveys the tears from the eye to the nasal chamber.

The *superior border* is thin, convex, and divided into two parts—an anterior, grooved and serrated for the attachment of the external border of the nasal bone, and the inferior part of the premaxilla, and a posterior, which is bevelled to articulate with the lachrymal and malar bones. The *inferior border* is

very thick, and contains six quadrilateral cavities, termed *alveoli*, in which the upper molar teeth are lodged. At the back of the last alveolus is a large rounded eminence, the *alveolar tuberosity*, and in front of the first the border becomes thin and sharp, and forms a portion of the *diastema* or *interdental space*, which separates the molar from the incisor and canine teeth. The *internal border* is serrated to articulate with its fellow of the opposite side, notched anteriorly to form the incisive opening, and it articulates posteriorly with the palatine bone.

The *posterior extremity* is rounded and prominent, forming the *alveolar tuberosity*, in the interior of which the maxillary sinus is prolonged. At the inner side of this eminence is a large deep excavation, which the palatine bone assists to form into the *maxillary hiatus*. This hiatus is situated directly opposite to the orbital hiatus, the sphenomaxillary fissure being the space between them; the hiatus contains three foramina—1st, the *palatine* or *palato-maxillary*, which leads to the palatine groove, for the passage of the palatine artery; 2nd, the *dental*, which enters the maxillary sinus, is continued along the roots of the molar teeth, and divides into two branches—a large short one, which opens at the infra-orbital foramen, and another continued to the roots of the incisor teeth; the 3rd is the *spheno-palatine*, which enters the nasal chamber, and gives passage to the spheno-palatine artery, vein, and nerve. The *anterior extremity* presents in the male a cavity which, with a similar cavity in the premaxilla with which it articulates, forms the alveolus of the canine tooth.

The superior maxilla articulates with its fellow, and with the premaxilla, ethmoid, squamosal, nasal, palatine, malar, lachrymal, and inferior turbinal bones.

## PREMAXILLA.

(FIG. 12. 10.)

This bone, called also the Inter or Anterior maxillary bone, is situated at the anterior extremity of the face, and consists of a broad thick part and two processes which spring from it. The thick part or *base* presents three surfaces—an *external* or *labial*, which is smooth and convex; an *internal*, which is roughened to articulate with its fellow, and has a groove running down it, which, with that of the opposing bone, forms the

*foramen incisivum* for the passage of the palato-labial artery; and an *inferior*, which is smooth, slightly concave, and marked by a continuation of the palatine groove, which terminates in the foramen incisivum. Between the external and inferior surfaces is a very thick curved border, containing anteriorly three alveoli for the incisor teeth, behind which is a sharp portion, which helps to form the interdental space. At the posterior part of the border, in the male animal, there is a cavity which, with that on the anterior extremity of the superior maxilla, forms the alveolus for the canine tooth.

The *processes* are external and internal. The *external*, the largest and longest, is continuous with the base, and flattened from side to side. Its outer surface is convex and smooth, its inner rounded above, and covered by the mucous membrane of the nasal chamber; inferiorly, it is roughened to articulate with the superior maxilla; its posterior extremity is thin, and attached between the superior maxilla and the nasal bone. The *internal* or *palatine process* is a thin flexible plate, which joins its fellow internally by a dentated suture; their superior surface forms part of the floor of the nasal fossæ, and their inferior part, which is smooth, forms part of the hard palate.

The premaxillæ are joined by fibro-cartilage in the young animal and by ossification in the old, the junction forming the *symphysis*; they articulate with each other and with the superior maxilla, nasal bone, and vomer.

#### MALAR BONE.

(FIG. 12. 7.)

The Malar, Zygomatic, or Jugal bone, situated at the antero-inferior part of the orbital fossa, is irregularly triangular in shape, with a broad anterior part, ending in a sharpened posterior point. It presents for consideration three surfaces, a base, and the zygomatic process.

The *external* or *facial surface* is smooth, somewhat convex, and has, inferiorly, a sharp ridge, the *zygomatic ridge*, continued posteriorly by the *zygomatic process*, which meets the process of the same name of the squamosal bone, the two forming the zygomatic arch. The *internal* or *maxillary surface* is irregularly concave, the posterior part helping to enclose the maxillary sinus. The *superior* or *orbital surface* is concave, and forms the antero-

inferior part of the orbital fossa, the border which separates it from the external surface being part of the orbital ridge. The *base* is thin, and articulates with the superior maxilla, and above the base is a serrated border which articulates with the lachrymal bone.

The malar articulates with the superior maxilla, the lachrymal, and squamosal bones.

## LACHRYMAL BONE.

(FIG. 12. 6.)

This is situated at the supero-anterior part of the orbital fossa; it is an irregular bone, very thin and very light, and presents three surfaces and a circumference.

The *external* or *facial surface* is triangular, slightly convex, and bounded, posteriorly, by the orbital ridge, in the middle of which is an eminence, the *lachrymal tubercle*, to which the orbicularis palpebrarum muscle is attached. The *posterior* or *orbital surface*, also triangular, is concave and smooth; it presents near its centre a funnel-shaped cavity, the *lachrymal fossa*, which leads to the lachrymal canal, and gives lodgment to the lachrymal sac. The lesser oblique muscle of the eye is attached in a slight depression at the inner side of this cavity. The *internal surface* is divided by the prominent wall of the lachrymal canal into two concavities, and forms part of the roof of the maxillary sinus. The circumference is very rough, and denticulated for articulating with the frontal, nasal, superior maxillary, and malar bones.

## PALATINE BONE.

(FIG. 13. 11.)

This bone is situated at the posterior part of the palatine plate of the superior maxilla, and forms, with its fellow, the anterior and external boundaries of the posterior nares. It is a long narrow bone, flattened from side to side, and curved inwards anteriorly, to meet the opposite palate bone, where it becomes flattened horizontally. It presents four surfaces and two extremities.

The *external* or *orbital surface* is smooth posteriorly, where it forms part of the orbital fossa, and aids in the formation of the maxillary hiatus, and denticulated anteriorly, where it articulates with the superior maxilla. Infero-posteriorly it presents a

shallow groove, running obliquely downwards and forwards, and terminating in the palatine surface; bounded externally by the alveolar tuberosity of the superior maxilla. it forms the *staphyline groove* for the passage of the staphyline artery and nerve, and the palatine vein. In the centre, also running obliquely downwards and forwards, is a deep groove, which, with a similar groove in the superior maxilla, forms the palatine foramen. The spheno-palatine foramen is in its superior middle. The *inferior* or *palatine surface* is smooth, very narrow, and concave, and forms half of the palatine arch. The *internal* or *nasal surface* is smooth and concave, the anterior portion being narrow, and bent inwards to meet its fellow; the posterior part being broad, and presenting a roughened line, which runs obliquely from above downwards for the attachment of the pterygoid bone. The *superior* or *sphenoidal surface* is deeply excavated, assisting in the formation of the sphenoidal sinus. The sharp ridge between this and the nasal surface is the *palatine crest*, on which the vomer rests.

The *anterior extremity* is flat, and curved inwards to meet the opposing palatine bone and palatine process of the superior maxilla. The *posterior extremity* is very thin and sharp, and presents externally a depression, in which the pterygoid process of the sphenoid bone articulates. The space between the palatine bones is termed the posterior nares, the borders of the opening or *palatine arch* giving attachment to the velum pendulum palati.

The palatine articulates with its fellow, and with the superior maxilla, the vomer, pterygoid, sphenoid, ethmoid, frontal, and inferior turbinal bones.

#### PTERYGOID BONE.

This is a very small elongated bone, flattened from side to side and slightly twisted, situated on the inner side of the pterygoid process of the sphenoid and posterior part of the nasal surface of the palatine bone, and below the posterior part of the vomer. It presents two surfaces and two extremities.

The *external surface* articulates with the palatine and pterygoid process of the sphenoid bone; the *internal surface* is smooth and covered by the pharyngeal mucous membrane; the *posterior extremity* is very slender, and assists in forming the Vidian conduit; the *anterior extremity* possesses a blunt process, the *summit* which is free, directed downwards, and has a groove at its



extremity forming a pulley, round which the tendon of the tensor palati muscle plays.

## VOMER.

This, the only single bone in the superior facial region, is a long bone constructed of two thin plates, with a deep groove between, and extends along the middle line of the floor of the nasal chambers from the sphenoid to the premaxilla. It presents two surfaces, two borders, and two extremities.

The two *lateral surfaces*, narrow anteriorly and wider posteriorly, are smooth, and, in the fresh state, covered by mucous membrane. The *superior border* is deeply grooved for the reception of the cartilaginous septum of the nose; the *inferior border* is sharp and smooth in its posterior half, where it forms the divisor between the posterior nares; the remaining portion is broad, flat, and slightly dentated to articulate with the maxillary bones. The *posterior extremity* is broad from side to side, convex below, and concave above, where it opens out into a crescentic border which embraces the sphenoid, and forms an irregular hiatus between the two bones for the passage of the nerves and blood-vessels which supply the septum. The *anterior extremity* is flat, and rests on the palatine process of the premaxilla.

The vomer articulates with the sphenoid, ethmoid, palatine, pterygoid, superior maxillary, and premaxillary bones.

## TURBINATED BONES.

(FIG. 13. 6, 12.)

These, also called the turbinals, four in number, one superior and one inferior on each side, are found in the nasal chambers, and are irregular bony columns, larger posteriorly than anteriorly, flattened from side to side, and hollowed within, dividing the nasal passages into superior, middle, and inferior meati.

The *superior* or *ethmoidal turbinal* is attached to the ridge on the nasal bone and to the ethmoid, and the *inferior* or *maxillary turbinal* to the ridge on the superior maxilla. They are formed of very delicate and reticulated rolls or convolutions of bone void of periosteum. The *superior* is the larger of the two, and extends from the ethmoid to near the external opening of

the nose ; a transverse plate divides it into two portions, of which the posterior is continuous with the frontal sinus, and the anterior with the nose ; the convolutions of this bone are from below upwards. The *inferior* bone is convoluted from above downwards, and its anterior is continuous with the maxillary sinus.

The use of the turbinals is to augment the surface of the nasal chambers over which the olfactory nerves are distributed, while, by their lightness, they do not add materially to the weight. The *superior meatus* of the nasal fossa is between the upper bone and the roof of the fossa ; the *middle meatus* is between the two bones, and the *inferior meatus* between the lower bone and the floor.

#### INFERIOR MAXILLA.

(FIG. 14.)

This, the Mandible, or lower jaw, is a large, irregular, somewhat V-shaped bone, situated below the upper jaw, and articulating,

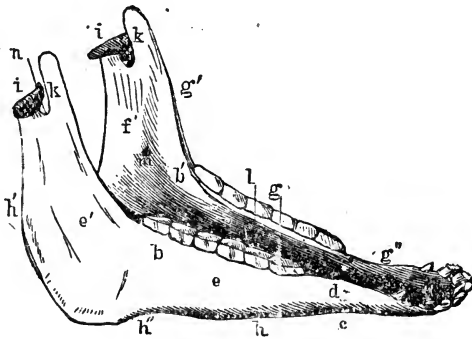


FIG. 14.

Inferior maxilla of Horse—antero-lateral view. *a*, Body ; *b* *b'*, Rami ; *c*, Neck ; *d*, Mental Foramen ; *e*, Buccinator, and *e'*, Masseter surface ; *f* *f'*, Inner Surface of Ramus ; *g*, Molar alveoli ; *g'*, Anterior border ; *g'''*, Bar, bounding diastema ; *h* *h'''*, Posterior border. The angle lies between *h'* and *h'''* ; *i* *i'*, Condyles ; *k* *k'*, Coronoid processes ; *l*, Maxillary space ; *m*, Inferior dental foramen ; *n*, Sigmoid notch.

by means of a true joint, with the glenoid cavities of the squamosal bone. It consists of two symmetrical branches flattened laterally, and deeper posteriorly than anteriorly, the posterior portions being curved upwards ; and the anterior extremities united, thus leaving a triangular space (the maxillary) between. These branches, united in the adult, are separate in the foetus, and

each presents for consideration two surfaces, two borders, and two extremities.

The *external surface* is smooth and rounded anteriorly, growing gradually deeper as it proceeds backwards; the posterior part or curved portion is roughened and excavated for the attachment of the masseter muscle. The *internal surface* is roughened and hollowed posteriorly, for the attachment of the pterygoid muscles, and it presents a large foramen, the *inferior maxillary or dental*, leading to the dental canal, which passes through the bone below the roots of the molar teeth. The anterior part of this surface is smooth and flat, and has a groove for the attachment of the buccal membrane; below the groove, some of the muscles of the tongue are attached.

The *superior border* is straight anteriorly, and concave posteriorly; the first part contains six alveoli for the lower molars, and the second, which terminates in the coronoid process is thin, and roughened for muscular attachment. The *inferior border* is also divided into two portions, a straight and a convex one, separated by a prominent roughened part termed the *angle of the jaw*. The anterior portion is rounded in the young animal, but grows gradually thinner with age owing to the outward growth of the teeth; the posterior border above the angle becomes thinner, and terminates in the condyle.

The *posterior extremity* presents two eminences, a flat, thin, pointed one, the *coronoid process*, anteriorly and a transverse doubly convex one, the *condyle*, posteriorly, the two being separated by a deep notch, the *sigmoid or corono-condyloid*. The *anterior extremities*, joined by the maxillary symphysis, form the *body of the bone*. The *external or labial surface* of the body is convex, and gives attachment to the gums and labial muscles, and has a line down its middle, which marks the division of the foetal bone. The *internal or buccal surface*, less than the external, is smooth and concave; the frænum of the tongue is attached to its posterior part. The *anterior border* is excavated into six alveolar cavities for the incisor teeth; and on each side, farther back, it presents, in the male animal, a cavity for the canine tooth, small or absent in the female. The *neck* is the constricted portion which joins the body to the ramus, and it has a more or less sharp ridge, superiorly; these ridges, or *bars*, occupy the inferior diastema or interdental space. On the outer side of the neck is the *anterior maxillary, mental, or labial foramen*.

the termination of one part of the dental canal which transmits the inferior dental artery and inferior dental division of the fifth pair of nerves.

## OS HYOIDES.

(FIG. 15.)

This is a bone which supports the tongue, the pharynx, and the larynx, and is suspended downwards and forwards between the rami of the lower jaw; it has a fibro-cartilaginous attachment to the hyoid process of the temporal bone. The hyoid series is composed of five distinct pieces—a body, or hyoid-bone proper, two cornua or horns, and two cornicula or lesser horns.

The body bears a striking resemblance to a spur or two-pronged

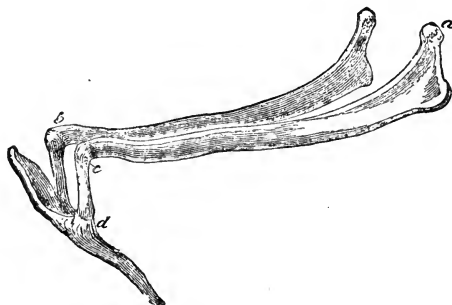


FIG. 15.

Left aspect of the hyoid series of bones. *a*, Proximal end of left cornu; *b*, Distal end of right cornu; *c*, Proximal end of corniculum; *d*, Hyoid bone. The left *heel-process* points downwards and backwards, the *spur process* in the opposite direction.

fork, presenting two lateral or *heel* processes, the *thyro-hyals*, directed backwards and downwards, their free extremities articulating with the thyroid cartilage of the larynx. The two convex articular facets, where these processes join the body, are for the cornicula. Springing from the middle portion, anteriorly, is a long, sharpened process, the *glossohyal* or *spur process*, which is buried in the substance of the tongue.

The cornicula, or *cerato-hyals*, are two short cylindrical pieces, articulating at the inferior extremity with the body, and at the superior with the cornua.

The cornua, or *stylo-hyals*, are long, thin, flattened bones, which extend obliquely backwards and upwards. The anterior extremity of each cornu presents an articulation for the corresponding corni-

culum, while the posterior extremity presents a kind of thickened elbow or curve inferiorly, and terminates superiorly in a rounded extremity, which is united to the temporal bone by a piece of fibro-cartilage. Among mammals the hyoid cornua attain perhaps in the horse the maximum of relative size. Occasionally a rudimentary additional ossicle is found in the cartilage between the cornu and corniculum.

Various muscles connect the hyoid bones with the tongue, larynx, and pharynx. It may be noted here that both the alimentary and respiratory canals pass between the hyoid cornua.

## APPENDICULAR SKELETON.

This division of the skeleton includes the bones which belong to the limbs or extremities, and those which help to join the latter to the trunk, when such bony union exists. The horse, like the majority of mammals, has two pairs of limbs—an anterior, fore, thoracic, or pectoral, and a posterior, hind, or pelvic pair, which have bones of connection, called respectively the pectoral and pelvic arches. In the horse, as in many other animals, there is no *articular* connection between the anterior limb and the trunk, hence *the pectoral arch is incomplete*. The actual attachment of this limb is entirely muscular, the body being suspended, as it were, in a muscular swing between the anterior limbs.

There is a certain correspondence between the bones of the front and those of the hinder limb, as reference to the skeleton and the following Table will show :—

PECTORAL LIMB.	PELVIC LIMB.
Humerus. . . . .	Femur.
(Olecranon). . . . .	Patella.
Radius and Ulna. . . . .	Tibia and Fibula.
Carpus (8 bones). . . . .	Tarsus (6 bones).
Metacarpus (3 bones). . . . .	Metatarsus (3 bones).
Phalanges, 3. . . . .	Phalanges, 3.
Sesamoids, 3. . . . .	Sesamoids, 3.

The humerus and femur, when the animal is stationary, slope in opposite directions, and the two pairs of bones beneath them appear to do the same ; it is probable, however, that the axis of the radius itself is as nearly perpendicular as possible.

The carpus and tarsus bend or flex in opposite directions, but below these joints the skeleton of the fore limb differs in no very material point from that of the hinder one.

#### PECTORAL ARCH.

The *pectoral arch* or shoulder-girdle consists, in the horse, of a bone called the scapula, on which we find a prominent object, the *coracoid* apophysis. This process being developed from a distinct ossific centre, is considered the homologue of the coracoid bone, a bone which is greatly developed in some animals, articulating, in some cases, with the sternum below. Another bone that very frequently assists in the formation of the arch, the *clavicle* or collar bone, is altogether absent in the horse, as in the rest of the Ungulata. On the other hand, the pelvic or hinder limb is firmly attached to the sacrum by means of the pelvic arch, which is complete.

#### PECTORAL OR FORE LIMB.

Regarding the anterior extremity as consisting of the limb and its incomplete arch, the bones we have to describe are the scapula, humerus, radius, and ulna; the carpus, consisting of eight bones—viz., the cuneiform, lunar, scaphoid, and trapezium in the upper row, and the unciform, magnum, trapezoid, and pisiform in the lower row; three metacarpal bones, two of which are imperfect; three sesamoid bones, one pair and a single one, the latter called also the navicular bone: and finally, three phalanges or finger bones, called respectively the *os suffraginis*, *os coronæ*, and *os pedis*.

#### SCAPULA.

(Pl. I. J.)

The scapula is a flat bone situated on the antero-lateral surface of the thorax, with its long axis sloping downwards and forwards; it is triangular in shape, the base being turned upwards. In the horse this bone is strong but comparatively small; it is broad and thin superiorly, becoming both narrower and thicker inferiorly; its position, or rather slope, is a point of importance in the conformation of the animal, and varies to some

extent, but its inferior angle is situated about the level of the first rib, the posterior angle being usually at or near the level of the sixth or seventh. It offers for consideration two surfaces, three borders, and three angles.

The *external surface* or *dorsum* of the scapula is divided into two unequal parts by a crest running nearly the whole length of the bone, termed the *spine*, which at its broadest part has a roughened *tubercle* to which the trapezius muscle is attached; the clavicle, in animals which possess one, is attached to the inferior extremity of the spine. The hollow part in front of the spine, the *antea spinatus fossa*, receives the antea spinatus muscle, and the *postea spinatus fossa*, the larger of the two, is occupied by the postea spinatus muscle; the nutrient foramen is in this fossa.

The *internal* or *venter surface* is smooth, though uneven; its fossa, the fossa subscapularis, lodges the subscapularis muscle, and the rough triangular spaces at the upper angles give attachment to the serratus magnus and rhomboidei muscles.

The *superior border* is nearly straight, roughened, and has the broad cartilage of prolongation fixed to it. The *anterior border* is superiorly convex and sharp, and inferiorly concave and blunted, and it terminates in a large, rough, hemispherical, and internally a somewhat bent process, the *coracoid apophysis*, to which the coraco-humeralis and coraco-radialis muscles are attached. This process is formed from a separate point of ossification. The *posterior border* is blunt and rough, and affords attachment to several muscles.

The *anterior* or *cervical angle* is thin, while the *posterior* or *dorsal angle* is thick and tuberos. The *inferior* or *humeral angle* is expanded, and separated from the rest of the bone by a constriction or *neck*; this extremity is the strongest part of the bone, and contains a shallow, oval, articular depression, the *glenoid cavity*, articulating with the humerus, and surmounted by a rim of bone to which the capsular ligament is attached; at its inner side there is a notch for the passage of blood-vessels.

## HUMERUS.

(PL. I. K.)

The humerus is a long bone extending from the scapula to the radius, in an oblique direction, downwards and backwards. Like all long bones it possesses a shaft and two extremities.

The *shaft* or *body* is characterised in most animals by a more or less twisted appearance, most apparent externally and anteriorly. We will describe it as presenting four surfaces. The *anterior surface*, somewhat triangular in shape, with the apex below, is roughened between its middle and inferior third, for the insertion of the coraco-humeralis muscle. The *posterior surface*, round and smooth, and not clearly divided from the internal and external surfaces, terminates inferiorly in two prominent ridges, the epitrochlea and epicondyle. The *external surface* contains the musculo-spiral groove, which winds obliquely downwards and forwards through the entire length of the shaft. This groove, which is occupied by the humeralis obliquus muscle gives the twisted appearance to the bone; it is separated from the anterior surface by the *deltoid ridge*, which extends from the outer part of the proximal end of the shaft to the coronoid fossa, a depression in its antero-distal end. A roughened prominence, the *external tuberosity*, on the upper third of this ridge, bends backwards over the spiral groove, and gives attachment to the teres externus muscle. The *internal surface* has no distinct separation from the anterior and posterior surfaces; a rough prominence about its middle, the *internal tuberosity*, gives insertion to the teres major and latissimus dorsi muscles. The medullary foramen is in its inferior third.

The *proximal extremity* presents the head and the trochanters. The *head* is convex, and considerably larger than the glenoid cavity with which it articulates, allowing extensive and varied motion; it is surrounded by a roughened border for the insertion of the capsular ligament, below which is the constricted *cervix* or neck of the bone. A rough depression in front of the head contains several small foramina for the blood-vessels which supply the cancellated tissue within.

The *external trochanter* has two prominences, the anterior, or summit of the trochanter, which forms the external boundary of the bicipital groove, and gives insertion to the outer tendon of



the antea spinatus muscle, while the posterior, or convexity of the trochanter, the more prominent of the two, is covered with fibro-cartilage, over which glides the tendon of the postea spinatus muscle, which is inserted to a rough surface below the convexity. The deltoid ridge joins this trochanter to the external tuberosity.

The *internal trochanter* is divided into three roughened parts—anterior, posterior, and inferior. The anterior forms the internal boundary of the bicipital groove, and gives insertion to the inner tendon of the antea spinatus, the posterior giving attachment to the subscapularis, and the inferior to the pectoralis magnus muscles. Between the anterior part of the internal and the summit of the external trochanters is the *bicipital groove*, divided by a middle prominence into two channels, the whole being covered with fibro-cartilage; through this groove the tendon of the flexor brachii muscle plays.

The *distal extremity* is smaller than the proximal, and smooth to articulate with the radius and ulna; its surface is convex, and wider in front than behind. A deep groove, which extends from the coronoid fossa in front, terminating in the condyloid or olecranon fossa posteriorly, divides it into an internal condyle, and an external condyle or trochlea, the latter being the smaller, and having a shallow furrow running across it from before backwards. At the side of the external condyle is a deep pit in which the external lateral ligament is attached, and from which a prominent ridge, the epitrochlea, extends upwards and gives origin to the extensor metacarpi magnus, extensor pedis, and flexor metacarpi externus muscles.

Running upwards from the posterior part of the internal condyle is a large eminence, the epicondyle, from which the flexor metacarpi internus, part of the medius, and the flexor pedis perforans and perforatus muscles arise, and on its side is a small eminence for the attachment of the internal lateral ligament. A deep ovoid fossa, the condyloid, which receives the olecranon process of the ulna during the extension of the joint, separates the epicondyle from the epitrochlea posteriorly; and anteriorly, just above the groove in the articular surface, is the shallow coronoid fossa, which receives the coronoid process of the radius during extreme flexion.

## THE FOREARM.

The bones of the forearm are the radius and the ulna, which in the young animal are distinct, but in the adult become firmly united by ossification, and are sometimes described as one bone, the *os antibrachii*. We describe them separately.

## RADIUS.

(Pl. I. L.)

The radius is a long bone, and occupies a vertical position between the humerus and the carpus. The *shaft* is flattened and curved, with gradually expanding extremities; its anterior surface is smooth, and covered in the fresh state by the extensor muscles of the knee and foot; and its posterior surface, concave from above downwards, and covered by the flexor muscles, presents towards its external border a rough triangular surface, which commences in a slender point near the middle of the bone, and terminates two or three inches below the proximal end, corresponding with the anterior surface of the ulna, to which it is attached by interosseous ligaments in the young animal, and by ossification in the adult. The shallow transverse groove above this surface assists in the formation of the radio-ulnar arch, and the nutrient foramen of the bone is close to the groove. On the inferior third of the internal border of the shaft is a ridge to which the *radialis accessorius* muscle is attached; the external and internal lateral surfaces are rounded, and have no distinct separation from the anterior and posterior surfaces.

The *proximal extremity*, larger than the distal, is widest from side to side, and presents an articular surface, divided into two depressions, the *glenoid cavities*, which receive the condyles of the humerus; the inner is the largest, and articulates with the internal condyle, the outer having a slight eminence on its centre which corresponds with the depression in the trochlea. A rough ridge round the articular surface gives attachment to the capsular ligament; the anterior part has a prominent lip, the coronoid process, in its centre, and near its internal border a rough eminence, the *bicipital tuberosity*, for the insertion of the tendon of the flexor brachii, and part of the humeralis externus muscles. On each side of the articular surface is a roughened portion for

the lateral ligament; the external, which is prominent and called the *external tuberosity*, giving origin to the extensor pedis and extensor suffraginis muscles. Posteriorly, two concave facets articulate with the ulna.

The *distal extremity*, like the proximal, is widest from side to side; its articular surface is divided into three facets, the internal of which, the largest, and quadrilateral in shape, articulates with the scaphoid bone; the middle, resembling the internal, but smaller, articulates with the lunar bone; and the external, the smallest, oval in shape and convex, articulates with the cuneiform bone and the trapezium. The whole articular surface is surrounded by a prominent ridge for the capsular ligament. The anterior part of this extremity is irregular, and has two deep vertical grooves for the tendons of the extensor muscles, and a shallow, oblique one, in which the tendon of the extensor metacarpi obliquus muscle plays. Laterally, two prominent processes, the internal being the largest, give attachment to the lateral ligaments; the external of these processes is grooved for the passage of the extensor suffraginis tendon.

## ULNA.

(PL. I. L'.)

The ulna is an irregular bone, in form triangular, with the base uppermost, and is placed on the supero-posterior part of the radius. This bone, which grows but little after birth, is larger in the young animal, proportionately to its ultimate size, than any other bone. It possesses a body and two extremities.

The *body* is triangular, and has three surfaces and three borders. The *anterior surface* is the counterpart of the posterior surface of the radius against which it is applied, having superiorly two convex facets to articulate with the concave ones on the head of the radius; below these is a rough portion for the attachment of the interosseous ligaments, and still lower, a shallow transverse groove which assists in the formation of the radio-ulnar arch, inferior to which is a roughened surface for the attachment of the ligaments, in which ossification takes place in the adult animal. The *external surface* is flattened and covered by the flexor metacarpi externus muscle, and the excavated *internal face* gives attachment to the ulnaris accessorius, and is covered by the flexor pedis muscles. The *lateral* borders are thin, and have

the arciform ligaments attached, and the *posterior border*, concave and round gives attachment to muscles.

The *distal extremity* is pointed, and extends a little below the middle of the radius, though sometimes, in the ass and mule particularly, it reaches the inferior extremity of that bone.

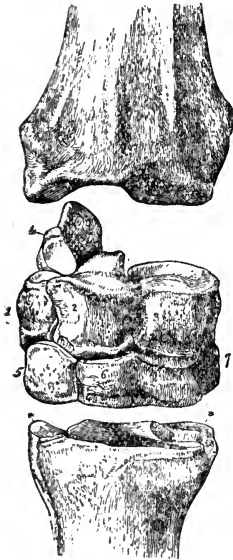


FIG. 16.

Front aspect of the right carpus of a Horse. 1, Cuneiform; 2, Lunar; 3, Scaphoid; 4, Trapezium; 5, Unciform; 6, Magnum; 7, Trapezoid; \*\*, Small metacarpals, the large one lying between and before them. The uppermost bone is the distal end of the radius.

The *proximal extremity* comprises that considerable portion of the bone, corresponding to the elbow of man, which projects upwards and backwards from the articular surface of the radius, and is known as the *olecranon process*. It presents two surfaces, two borders, and a summit. The *external surface* is slightly convex, and roughened for muscular attachment; the *internal surface* is hollowed and smooth; the *posterior border*, concave, thin, and smooth; and the *anterior border*, thin superiorly, is hollowed into a crescent-shaped surface, which articulates with, or rather behind and between, the condyles of the humerus, the prominent portion being known as the *beak* of the olecranon. The summit is the broad roughened protuberance which gives insertion to the tendon of the triceps extensor brachii muscle, the olecranon being the *lever* on which that muscle acts. It is important to note that the development of the ulna is directly proportional to the number of fingers or digits, hence the horse, being a monodactyle, has a very short ulna; compare this bone in the ox and dog.

#### CARPUS.

The carpus, wrist, or *knee*, as it is incorrectly termed in quadrupeds, is composed of seven and often of eight small, irregular bones, arranged in two rows of three each, one above the other, the seventh being at the back of the three in the upper row, and the eighth, when present, in a similar position with respect to the lower row. The joints between them pass completely through from front to back, and are so arranged that

those of one row do not correspond to those of the other. (See Fig. 16.)

It may be noted that, virtually, continuous articular surfaces are formed by the bones, by which the upper row articulates with the radius, the lower with the metacarpus, and the two rows with each other. Each bone also has facets, which are often deep-seated, for articulation with contiguous bones, and roughened depressions between the facets for the attachment of ligaments. The true carpal joint, or principal seat of motion, is between the radius and the upper row; there is less motion between the rows, and still less between the lower one and the metacarpus. The lesion, termed "broken knees," usually occurs where there is the most extensive motion

Naming from within outwards, the bones of the upper row are the scaphoid, lunar, and cuneiform, and the trapezium behind the latter; those of the lower row are the trapezoid, os magnum, and unciform and the pisiform behind the trapezoid.

## SCAPHOID.

(FIG. 16. 3.)

The scaphoid, the innermost and largest of the bones of the upper row, presents six surfaces, the *anterior* and *external* being continuous, convex, and roughened for ligamentous attachment; the *posterior* is rough and irregular; and the *internal*, excavated and roughened, has three projections, bearing facets which articulate with the lunar bone. The *superior surface* is smooth, concavo-convex,

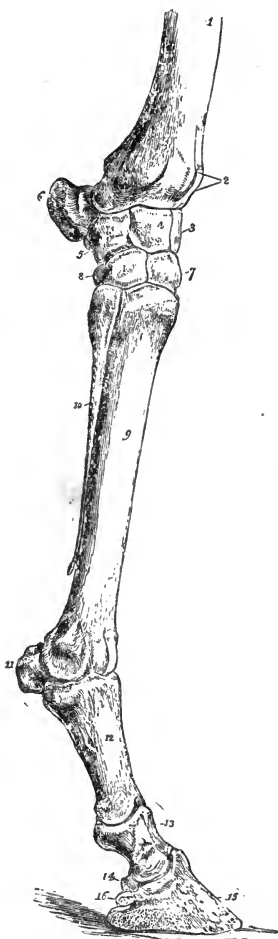


FIG. 17.

External view of bones of right carpus, metacarpus, and digit of a Horse. 1, Distal end of radius; 2, Grooves for extensor tendons; 3, Scaphoid; 4, Lunar; 5, Cuneiform; 6, Trapezium; 7, Magnum; 8, Unciform; 9, Great Metacarpal; 10, External small metacarpal (splint); 11, Sesamoids; 12, Proximal phalanx (os suffraginis); 13, Median phalanx (os coronæ); 14, Third sesamoid (os naviculare); 15, Distal phalanx (os pedis); 16, Basilar process.

smooth, concavo-convex,

and articulates with the internal part of the distal end of the radius; the *inferior surface* is also smooth and articular, consisting of an anterior portion, slightly convex, for the os magnum below, and a posterior concave or cup-shaped one for the trapezoid.

The scaphoid articulates with four bones—viz., the radius above, the lunar internally, and the os magnum and trapezoid below.

#### LUNAR BONE.

(FIG. 16. 2.)

The lunar bone (os lunare), the middle bone of the upper row, both in size and position, is somewhat wedge-shaped, and has four surfaces, a base, and an apex. The *superior surface* is all articular, triangular in shape, with a concavity posteriorly; it articulates with the middle part of the distal end of the radius. The *inferior surface* is articular, and divided by a ridge into an oblong, concavo-convex portion, occupying about five-sixths of the surface, and articulating with the os magnum; and another small, oblong, and flat part, situated at the antero-external border, and articulating with the unciform bone. The *internal surface* is excavated and roughened, and possesses three articular projections, which correspond with those on the scaphoid, the *external surface* having two for the cuneiform bone. The *base* is rough, somewhat trapezium-shaped, and is placed anteriorly, the *apex*, rough and tuberos, being directed backwards.

The lunar articulates with five bones—viz., the radius above, the scaphoid internally, the cuneiform externally, and the os magnum and unciform below.

#### CUNEIFORM BONE.

(FIG. 16. 1.)

This is the smallest and most external of the bones of the upper row, and has five surfaces; the *superior*, which is cup-shaped, articulates with the radius, and the *inferior*, somewhat concave, with the unciform bone. The *external surface* is convex and rough, and gives attachment to ligaments, while the *internal* has two facets which articulate with the lunar; the *posterior*.

*surface*, which slopes downwards and backwards, presents on its inferior half a cup-shaped articular facet for the trapezium.

The cuneiform articulates with four bones—viz., the radius above, the lunar internally, the unciform below, and the trapezium behind.

## TRAPEZIUM.\*

(Fig. 16. 4.)

Placed immediately behind the cuneiform bone, the trapezium is broad and flattened, and presents two surfaces and a circumference. Both its surfaces are rough, the *internal* being concave and the *external* convex, the latter having a deep groove for the passage of one of the tendons of the flexor metacarpi externus muscle. The circumference is roughened, the *superior* part receiving the insertion of the tendon of the flexor metacarpi medius, with the second tendon of the externus muscles, while the remaining portion is rough for ligamentous attachment. Anteriorly there are two small facets, an upper concave one to articulate with the radius, and a lower convex one articulating with the cuneiform bone. As the trapezium is the lever bone of the carpal joint, its development and position are points of very great importance.

## TRAPEZOID

(Fig. 16. 7.)

This, the smallest of all the bones of the carpus, excepting the pisiform, is placed on the lower row on the inside; it presents four surfaces, a base, and an apex. The *superior surface*, smooth and rounded from before backwards, articulates with the scaphoid. The *inferior surface* is smooth, with two united facets, one of which, large, flat, and semicircular, articulates with the inner metacarpal bone, and the other, small, square, and bevelled, with the great metacarpal bone. The *internal surface* is convex and rough, and the *external* rough, with the exception of three projecting facets, which articulate with the os magnum. The *apex* is placed forwards, and the *base* backwards, both being roughened; a very small, cup-shaped articulation for the pisiform bone is often found on the posterior part of the base.

The trapezoid articulates with five bones—viz., the scaphoid

\* See note on page 77.

above, the magnum internally, the large and inner metacarpals below, and the pisiform postero-externally.

#### OS MAGNUM.

(Fig. 16. 6.)

The os magnum, the largest bone in the carpus, and the central one in the lower row, is somewhat triangular in shape, and presents four surfaces, a base, and an apex. The *superior surface* is divided into two portions by a ridge, the concave inner part articulating with the scaphoid, and the external, which is oblong and concavo-convex, with the lunar bone. The *inferior surface*, smooth and flat, rests on, and articulates with the large metacarpal bone, having also a very small bevelled portion near its inner surface, which articulates with the inner metacarpal bone. The *internal surface* is rough and irregular, and has three facets which articulate with the trapezoid; the *external surface* joins the unciform, having two facets. The *base* is placed anteriorly, it and the *apex* both being roughened for ligamentous attachments.

The os magnum articulates with six bones—viz., the scaphoid and lunar above, the large and inner small metacarpals below, the trapezoid internally, and the unciform externally.

#### UNCIFORM BONE.

(Fig. 16. 5.)

This, the external bone of the lower row, is very irregular in form, and somewhat resembles the trapezoid; it has four surfaces, a base, and an apex. The *superior surface*, convex from side to side, and sloping externally, articulates with the lunar and cuneiform bones. The *inferior surface* articulates by two facets with the large, and one with the small metacarpal bone. The *internal surface* presents two facets, which articulate with the os magnum. The *external surface* is narrow; the *base* is situated anteriorly, the *apex* being the prominent unciform process, and all the three parts are roughened for ligamentous attachment.

The unciform articulates with five bones—viz., the lunar and cuneiform above, the magnum internally, and the large and external metacarpals below.



## PISIFORM BONE.\*

The pisiform is a very small, pea-shaped bone, situated, when present, at the postero-internal part of the knee, in some cases articulating with the trapezoid, and in others being imbedded in the internal lateral ligament. It is generally, perhaps always, present in old subjects, but often overlooked owing to its small size.

## METACARPUS.

The metacarpus, that part of the skeleton which lies between the carpus and the finger, consists, in the horse, of three bones. The principal one, the great metacarpal bone, situated between the others, which are called the inner and outer small metacarpals, is the *only perfect one* of the three; the others are not

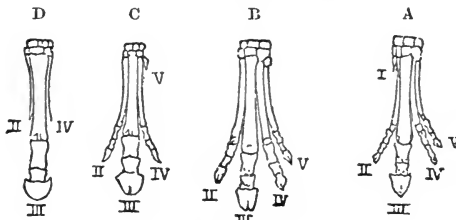


FIG. 18.

Generic development of the Horse's foot. A, Foot of Eohippus; B, That of Orchippus; C, That of Hipparion; D, That of Horse. The digits are numbered, when present, I. to V.

only small, but they have no distal articular surface. Very frequently all three bones become united by ossification.

## OS METACARPI MAGNUM.

(FIG. 17. 9.)

The large metacarpal, or cannon bone, is a long, straight bone, placed in a vertical direction. This bone, one of the most compact in the skeleton, is flattened in its shaft, from before backwards, especially towards its distal end, the anterior surface being convex and smooth, and the posterior broad, flattened, and pierced

\* [Some authorities call this bone the Trapezium, and our Trapezium the Pisiform. Either view may be admissible, as the nomenclature will depend upon whether we compare these bones analogously or homologously with those of the human carpus.—Ed., *Second Edition*.]

at about one-third from the top by the medullary or nutrient foramen. On each side of this surface is a vertical ridge, to which the small metacarpals are attached.

The *proximal extremity* presents a smooth surface, formed by three continuous articular facets. one large and flat, on which the os magnum rests; the second. very small, on the postero-internal border. articulates with a portion of the trapezoid; and the third. which articulates with the unciform, and occupies the whole external border, is bevelled off from within outwards, and divided by a deep furrow into two portions. In front of the large articulation, towards the intero-anterior portion of the head, is a roughened prominence for the insertion of the extensor metacarpi magnus tendon: and at the posterior part of the head a roughened surface, from which the suspensory and check ligaments originate. and on each side two facets, divided by furrows. articulate with the small metacarpal bones.

The *distal extremity*, widest from side to side, and convex from before backwards, presents an articular surface, consisting of two condyles joined by a prominent semicircular ridge, the whole of which articulates with the os suffraginis below, and the two sesamoid bones behind. Each of the condyles, the internal being slightly the larger of the two. presents a depression on its side for the insertion of the lateral ligament. Thus the large metacarpal bone articulates superiorly with the trapezoid. magnum, and unciform, laterally with the small metacarpals, and inferiorly with the os suffraginis and the two sesamoid bones.

#### OSSA METACARPI PARVA.

(Fig. 17. 10.)

The small metacarpal, or splint bones, tuberos in form at the carpus and tapering distally, are attached to the large bone, one on each side of its posterior surface, by ligaments in the young animal, and by ossification in most grown up, and in all old animals. They vary somewhat in length in different animals, but are usually about two-thirds of the length of the cannon, the internal being generally the largest.

The base, or head, of each bone is turned upwards, its superior surface being articulatory, and assisting to form the carpal-joint. The internal one possesses two articular facets, one large and flat, on which the trapezoid rests, and the other small and bevelled

towards its anterior surface, to articulate with a portion of the os magnum, while the external splint has but one carpal facet, which gives support to the unciform bone. Below the articular surface, externally, the heads are roughened for the insertion of the tendon of the flexor metacarpi internus to the inner, and that of the flexor metacarpi externus to the outer. The head of each of these bones presents two articular facets, which correspond to those on the sides of the head of the cannon bone. The middle part or body tapers gradually downwards from the head, and is firmly attached to the large metacarpal bone by its anterior surface. The apex terminates in a small knob, which never, except in disease, becomes attached to the parent bone. These knobs are very prominent in well-bred horses, and are sometimes mistaken for *splints*, which are exostoses between the large and small metacarpal bones.

DIGIT.

The digit or finger is composed of three bones placed one immediately below the other, and having three supplementary or sesamoid bones placed behind. The three principal bones are homologous with the three phalanges of the human finger, the os suffraginis representing the first or proximal, the os coronæ the second or median, and the os pedis the third or distal phalanx.

The joint which the large metacarpal bone forms with the os suffraginis and its two sesamoids is the fetlock-joint, that between the os suffraginis and the os coronæ is the pastern joint, and that between the os corona and the os pedis, with its sesamoid or navicular bone, is the coffin joint.

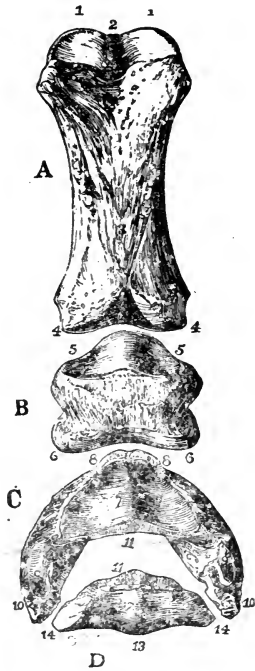


FIG. 19.

Posterior view of phalanges of a Horse disarticulated. A, Os suffraginis; B, Os coronæ; C, Os pedis; D, Os naviculare, or third sesamoid; 1 1, Glenoid cavities, joined by the groove, 2; 3, Rough surface for V-shaped sesamoidean ligament; 4 4, Condyles articulating with cavities, 5 5; 6 6, Condyles of coronæ articulating with glenoid cavities of pedal bone, 7 7; 8 8, Pyramidal process; 9 9, Basilar processes; 10 10, Retrosal processes; 11 11, Articular surfaces between navicular and pedal bones; 12, Surface continuous with glenoid cavities, 7 7; 13, Posterior edge; and 14 14, Extremities for lateralligaments of navicular bone.

## PROXIMAL PHALANX.

(FIG. 19. A.)

The first phalanx, also called the *os suffraginis*, or large pastern bone, passes obliquely downwards and forwards, and articulates with the cannon bone above, and the median phalanx below. It belongs to the class of long bones.

The *shaft*, which is very short and slightly flattened from before backwards, has an anterior surface convex and smooth, and a posterior surface somewhat flattened, the latter presenting two roughened ridges, in the form of a triangle, with its base upwards, to which certain of the sesamoidean ligaments are attached.

The *proximal extremity*, the larger of the two, presents a semilunar-shaped articular surface, convex in front, and consisting of two glenoid cavities for the condyles of the cannon bone, and a deep connecting groove for the eminence between them; behind, on each side, is a roughened tuberosity for the attachment of the crucial sesamoidean ligaments. The *distal extremity*, much smaller than the proximal, presents two condyles connected by a shallow groove, continuous with which, posteriorly, is a pit or depression into which fits a prominent lip on the posterior part of the median phalanx, and in the centre of the front there is a slight eminence, to which a slip of the tendon of the extensor pedis muscle is attached. On each side is a roughened depression for the insertion of the lateral ligaments.

## GREAT SESAMOID BONES.

(FIG. 17. 11.)

These bones, two in number, are placed side by side at the postero-inferior part of the metacarpus and postero-superior part of the *os suffraginis*; they are irregular or polyhedral in shape, having smooth and concave *anterior surfaces*, the internal bevelled edges of which form a groove into which the ridge at the distal extremity of the cannon bone is received, the concave portions articulating with the condyles of that bone. The *posterior surfaces* when *in situ* form a channel, which is covered with fibro-cartilage, for the passage of the flexor tendons of the digit. The *superior extremity* or *apex* of each bone is roughened, as are also their lateral borders, which are grooved for

the reception of the suspensory ligament. The *inferior surface* or *base* is also roughened, to afford attachment to the ligaments by which these bones are attached to the phalanges below.

#### MEDIAN PHALANX.

(FIG. 19. B.)

The second phalanx, os coronæ, or small pastern bone, has no medullary canal, and belongs to the class of irregular bones. It is inclined, like the os suffraginis, obliquely downwards and forwards, and is partly covered by the hoof. The *superior surface* is smooth, and divided by an eminence into two glenoid cavities for the condyles of the os suffraginis, and having in the centre two slight eminences, one in front and one behind, which, by limiting its motion, make the joint more secure; a portion of the tendon of the extensor pedis muscle is attached to the anterior, and a ligament to the posterior of these eminences. The *inferior surface* of the bone is smooth and convex, and divided by a central depression into two condyles, which articulate with the os pedis and os naviculare. The *anterior surface* is convex, very rough, and widest superiorly; it affords attachment to part of the tendon of the extensor pedis muscle. The *posterior surface*, slightly excavated and not very rough, has on its upper part a prominent eminence covered by fibro-cartilage, over which plays the tendon of the flexor perforans, while on either side of this eminence is inserted part of the tendon of the flexor perforatus muscle.

#### DISTAL PHALANX.

(FIG. 19. C.)

The third, or unguis phalanx, os pedis, or coffin bone, is an irregular bone situated within the hoof, and, when in a healthy state, corresponding somewhat to it in shape, being semilunar in form, with the convexity to the front. It is a very hard but porous bone, having many excavations and foramina for the transmission of arteries and veins. In this bone we notice the wall, the sole, the tendinous surface, the articular surface, and the alæ or wings.

The *wall*, or *anterior surface*, is the semicircular part in front

which presents numerous depressions and foramina, the latter being for the passage of blood-vessels and nerves, and the former for the attachment of soft structures. Anteriorly it is surmounted by the *coronal* or *pyramidal process*, which gives insertion to the tendon of the extensor pedis muscle, and prevents the os coronæ from slipping too far forwards; a ligament is inserted in an excavation on each side of this process. The inferior edge of the wall is serrated or notched, the notches opening into various foramina; and its declivity increases in degree, but decreases in extent as it proceeds backwards. At each side is the *preplantar groove*, which terminates posteriorly in the large foramen of the same name, and along which the lateral laminal artery passes.

The *sole*, or *inferior surface*, which lies on the sensitive or vascular sole, is slightly excavated and half-moon shaped, and, excepting the articular surface, is the smoothest part of the bone; it is bounded externally by the inferior edge of the wall, and at its postero-internal part by an uneven semicircular ridge, the *semilunar ridge*, which separates it from the tendinous surface.

The *tendinous surface* is the roughened portion placed immediately behind the sole; it presents a triangular roughened depression on its middle and anterior part, where the tendon of the flexor pedis perforans muscle becomes inserted, and on each side a groove, the *plantar groove*, which terminates in the large *plantar* foramen along which passes the artery and nerve proceeding to the interior of the bone. The posterior part of this surface is roughened for the attachment of the inferior navicular ligament. The *articular surface* presents two glenoid cavities, separated by a slight eminence which terminates in the coronal process; this part of the surface articulates with the inferior extremity of the os coronæ. Behind the cavities, a flattened, narrow triangular surface articulates with the os naviculare.

The *alæ*, or *wings*, are the irregular protuberances on the posterior part of the wall; they are bifid, being divided by a fissure or notch, the *preplantar fissure*, which in old animals is converted into the preplantar foramen, through which the lateral laminal artery passes to gain the groove on the wall. The inferior and posterior portion of the ala, the more bulky of the two, is the *retrossal process*; and the superior portion, thin, and giving attachment to the lateral cartilage, is the *basilar process*

## OS NAVICULARE.

(FIG. 19. D.)

The navicular, third sesamoid, or shuttle bone, is an irregular bone, situated with its long axis transversely, behind and below the os coronæ, and behind the os pedis, with both of which it articulates, the articulation of the three forming the so-called *coffin joint*. The *superior surface* is smooth, with two concavities and a central eminence, which complete the articular surface for the condyles of the os coronæ; the inferior surface is rather rough, and also has two concavities and a central projection, which are covered with fibro-cartilage, and together form a kind of pulley over which plays the tendon of the flexor perforans muscle. The *anterior border* is divided into two portions, a superior, smooth and triangular, which articulates with the os pedis, and an inferior, elongated, rough, and porous, and attached to the same bone by the inferior navicular ligament. The *posterior border* is triangular, rough, and porous, and gives insertion to the superior ligament; the *extremities* are pointed, and attached to the alæ of the os pedis by lateral ligaments.

## PELVIC ARCH.

The posterior extremity is united to the trunk by the direct articulation of the pelvic arch with the femur and sacral vertebræ. The three bones which form the arch become early united by ossification, and the entire arch is called the os innominatum. The two ossa innominata articulate with each other in the inferior median line, and at a later period this union becomes also ossified; the complete structure is called the *pelvis*, and the space which it helps to enclose is the *pelvic cavity*. On examining the pelvis *in situ*, we find that the anterior portion bounds superiorly a space which has no bony floor; this portion has been termed the False Pelvis, the True Pelvis being the posterior part which, by union of its right and left segments, forms the floor of the cavity. Each side of the floor is pierced by a very large opening, the obturator foramen, or foramen ovale.

The *pelvic cavity* therefore is, in the skeleton, included between the sacrum, part of the coccyx, and the two ossa innominata. The pelvis is always much smaller proportionally in the lower

animals than in man. where, especially in the female, it is large and well developed. possessing that peculiar basin-like form identified with an erect posture of body. We have already described the sacrum and coccyx, and have now to describe the ossa innominata. or right and left segments of the *pelvis*.

#### OSSA INNOMINATA.

The ossa innominata are flat, but somewhat irregularly-shaped bones, which form the sides, floor, and part of the roof of the pelvic cavity. Above they are connected with the sacrum, and below united to each other in the adult by ossification. In the young animal, as above stated, and especially in the fœtus, each os innominatum consists of three parts, which retain their names of ilium, ischium, and pubis, even after union by ossification. They all three meet in the acetabulum, or articular cavity for the femur.

#### ILIUM.

(PL. I. U.)

The ilium, the largest and most symmetrical bone of the three, and situated partly upon the sacrum with which it articulates, is flat and irregularly-triangular in shape, its extreme outer angle being one of the most prominent points of the animal, forming the projection commonly called the "point of the hip." It presents for consideration two surfaces, three borders, and three angles or processes.

The *external surface* is concave at its upper part, and marked by elevated lines for the attachment of the gluteus maximus muscle; lower down it becomes convex and narrow, forming the upper part of the shaft of the ilium, which is three-sided. As it approaches the acetabulum the shaft again slightly expands, and becomes roughened for the attachment of the gluteus internus and outer head of the rectus femoris muscles. This surface terminates in an obtuse angle, the outer side of which forms a strong anterior margin for the acetabulum; and the inner side, surmounting this cavity, marks the line of junction between the ilium and the ischium.

The *internal or venter surface* is slightly convex, its upper portion consisting of two parts—an outer smooth one, corresponding to the iliac fossa in man; and an inner, which rests on the



sacrum, and gives attachment to the inferior sacro-iliac ligament. The iliacus muscle is attached to the venter surface. On the lower portion is a line or ridge continuous with the anterior edge or brim of the pubis; together these form the *ilio-pectineal* line, which inferiorly separates the true pelvis from the false. On the inferior border of the shaft is the nutrient foramen, and in front of the acetabulum a second depression for the inner head of the rectus femoris muscle. Below this depression is the ilio-pectineal eminence, which marks the junction of the ilium and the pubis, and gives attachment to the psoas parvus muscle. The inner part is smooth, concave, and grooved backwards and downwards for the obturator vessels

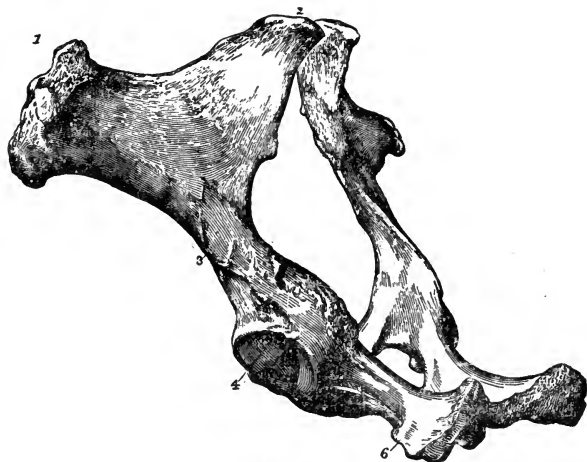


FIG. 20.

Left postero-lateral view of a Horse's pelvis. 1, Anterior iliac spine; 2, Posterior iliac spine. The iliac crest is the border joining 1 and 2; 3, Iliac shaft; 4, The acetabulum, the large rough ridge above is the sciatic spine; 6, Inferior ischiatic spine, posterior to which is the tuberosity.

The *anterior border*, or *crest of the ilium*, lies above the sacral transverse process. It is concave above, convex below, thin in its middle, and roughened for the attachment of the longissimus dorsi and other muscles. Internally it terminates in a rounded eminence, the *posterior iliac spine*, which rises above the last lumbar and first sacral spines, and forms the highest part of the croup. Externally and anteriorly it terminates in the *anterior iliac spine*, which consists of four eminences, two superior and two inferior, supported on a thick, strong, projecting bony plate; these eminences give attachment to the oblique and transverse

abdominal and other muscles; they are more developed in some horses than in others, and occasionally project so far as to form what are termed "ragged hips."

The *superior* or *internal border* extends from the posterior spine to the ischium. It is sharp and thin above, and becomes thicker posteriorly, presenting above the acetabulum a roughened ridge, the *sciatic* or *superior ischiatic spine*, the posterior portion of which is formed by the ischium, and to which a large part of the sacro-sciatic ligament is attached.

#### ISCHIUM.

(Pl. I. 14.)

The ischium, intermediate in size between the ilium and the pubis, is a flat, irregularly quadrilateral bone, which extends from the acetabulum, and forms the posterior part of the pelvis; it presents a body, a shaft, and a ramus.

The *shaft*, which forms part of the sciatic spine, also joins the ilium in the acetabulum; it is rounded, and below the spine has a smooth surface over which the obturator internus and pyramiformis tendons pass. It forms the external boundary of the obturator foramen.

The *body*, which is nearly horizontal, is flat and smooth, and forms the posterior boundary of the obturator foramen. Internally, it is roughened, and joins its fellow of the opposite side, forming the symphysis ischii; posteriorly it is roughened for the attachment of muscles, and possesses on its external part a prominent projection, the *tuberosity of the ischium*, to which several muscles are attached. The ridge or spine below, running forwards from the tuberosity, is the *inferior ischiatic spine*, while the posterior border of the bone is formed by a thick ridge running from the tuberosity to the symphysis, forming with its fellow the *ischial arch*, which, in the male, supports the crura of the penis. The *ramus*, not well developed in the horse, is the small branch which joins the pubis, and forms part of the internal boundary of the obturator foramen, the union between the bones being usually marked by a transverse ridge.

#### PUBIS.

The pubis, which is the smallest division of the os innominatum, is likewise irregular in shape, and forms with its fellow the

antero-inferior part of the pelvis; it consists of a body and a ramus.

The *body* reaches from the acetabulum to the median symphysis; its superior surface is concave to receive the urinary bladder, and its inferior surface is convex, and transversely crossed by a deep groove from the acetabulum, which contains the pubio-femoral ligament. The *crest* is the roughened anterior border, which terminates at the symphysis. The posterior border extends to the ramus, and forms the anterior margin of the obturator foramen; at its junction with the ilium it is crossed by a groove for the obturator vessels. The outer extremity, which joins the ilium and the ischium in the acetabulum, is excavated to form the cotyloid notch. The *ramus* is the flattened portion which projects posteriorly, joins the ramus of the ischium, forming part of the boundary of the obturator foramen, and with its fellow the symphysis pubis internally.

#### ACETABULUM.

(FIG. 20. 4.)

The *cotyloid cavity* or *acetabulum* is situated on the extero-lateral aspect of the pelvis, where the three segments of the os innominatum unite. It receives the head of the thigh-bone, and is one of the deepest articular depressions in the body, though relatively it is much less capacious in the horse and in quadrupeds generally than in man. It is circular in outline, and, except at its inferior median part, is surrounded by a prominent lip of bone, which becomes thin and slightly roughened at its free surface for muscular and ligamentous attachment; its inferior border presents a large notch, the *cotyloid notch*, continued half-way across the articulation as the *fundus acetabuli*, to give attachment to the round ligament (ligamentum teres), which mainly occupies it. Although the cotyloid cavity is formed by the three segments of the os innominatum, the ilium and the ischium are generally the only parts which form its articular surface, the pubis in most cases merely helping to form the roughened notch and fundus.

#### PELVIC APERTURES.

The *obturator* or *thyroid foramen*, or *foramen ovale*, the largest foramen in the body, exists in each os innominatum, and

is oval in outline, its long diameter being directed downwards, backwards, and inwards. It is formed entirely by the pubis and ischium, and possesses smooth margins, and thick, except where they are formed by the pubis.

The *inlet*, or *brim of the pelvis*, is bounded superiorly by the sacral promontory, laterally by the ilio-pectineal line, and inferiorly by the crest and symphysis of the pubis. The aperture thus defined inclines downwards and backwards, being somewhat ovoid in form. The diameters of the inlet vary according to the age and sex of the animal; in the adult male, the verticle or sacro-pubic diameter is a little less than the transverse.

The *outlet*, or *posterior aperture*, is somewhat triangular in form, and is bounded above, at its apex, by the first coccygeal bone, laterally by the sacro-sciatic ligaments, and inferiorly, by the ischia and ischiatic spines. Its vertical diameter, from the last sacral or first coccygeal segment, to the ischiatic symphysis, is less than the transverse, taken between the ischiatic spines. The length, taken from the middle of the lateral part of the inlet to the ischiatic tuberosity, is usually about equal to the transverse diameter of the inlet.

#### FEMALE PELVIS.

The size and proportions of the pelvis differ considerably with the sex of the animal. Bearing in mind that we have referred hitherto to the pelvis of the adult male, the differences in that of the female may be thus summarised:—The whole structure is larger. The transverse diameters above named, in fact, the transverse measurements generally, are very large, the former exceeding the vertical diameters by a much larger difference than is found in the male. The internal border of the ilium is more hollowed out, and smoother. The ischial arch is large, and it presents a concave border, tending but slightly to form an angle at the symphysis. The cotyloid cavities are wider apart than in the male, while the obturator foramina are larger and more circular in form.

#### PELVIC LIMB.

The bones of the pelvic or hind extremity are the femur, patella, tibia, and fibula; the bones of the tarsus—viz., the astragalus, os calcis, cuboid and three cuneiform bones; one large and two small metatarsals; three phalanges and three sesamoids. See p. 65.

## FEMUR.

(FIG. 21.)

The os femoris, femur, or thigh bone, the largest, thickest, and strongest bone in the body, belongs to the class of long or cylindrical bones, and is placed in a direction obliquely downwards and forwards, articulating with the cotyloid cavity of the os innominatum, and also with the tibia and patella.

The *shaft* is irregularly cylindrical, and has two surfaces and two borders. The *anterior surface* is smooth, prominent, and marked by a few muscular imprints. The *posterior surface* is flattened and expanded at its upper part, and presents, towards the external part of its upper third, a circular roughened surface for the insertion of part of the triceps abductor muscle; internal to which a slight ridge runs obliquely upwards and inwards to join the internal trochanter, to this the ischio-femoralis muscle is inserted. About its middle third is a roughened surface, for the attachment of the adductor brevis and part of the adductor longus muscles. The *external border*, which separates the anterior from the posterior surface, presents a prominent ridge, on the upper third of which is a sharp, flat protuberance, the *trochanter minor*, curved forwards, and affording attachment to the gluteus externus and vastus externus muscles. At the lower third of this border is a deep, oval, roughened pit, the *supra-condyloid fossa*, from which the flexor perforatus muscle arises; and about level with this, towards the inner side, is an aggregation of tubercles forming the *supra-condyloid crest*, where arises one portion of the gastrocnemius muscle. The *internal border*, dividing the anterior from the posterior surface internally, presents near its upper third

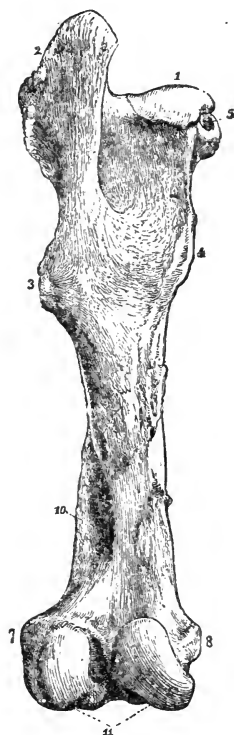


FIG. 21.

Posterior view of left femur of a Horse. 1, Head; 2, Trochanter major; 3, Trochanter minor; 4, Trochanter internus; 5, Notch for the round ligament; 6, Trochanteric fossa; 7, 8, Places of attachment for the lateral ligaments; 11, The condyles, separated by the intercondyloid groove; 10, Supra-condyloid fossa.

a blunt roughened prominence, the *trochanter internus*, from which a ridge extends upwards to the head, and to which the *psoas magnus*, *iliacus*, and *vastus internus* muscles are attached. From this trochanter another ridge, to which the *pectineus* muscle is inserted, runs downwards, the nutrient foramen being in its lower part.

The *proximal extremity* terminates in the *head* and the *trochanter major*. The head is the smooth articular portion directed upwards and inwards, and is received in the cotyloid cavity; it is separated from the body by a constricted portion, the neck, not well marked in solipedes, and between the head and neck there is a ridge for the attachment of the capsular ligament. The deep notch at the inner part of the head is for the attachment of the pubio-femoral and round ligaments. The *trochanter major* is a very large eminence, which projects outwards and upwards, and presents posteriorly a prominent part termed the *summit*, which stands a little higher than the articular head, and gives attachment to one portion of the *gluteus maximus* muscle, and anteriorly the *convexity*, which is rounded and covered externally by cartilage, over which plays another tendon of the *gluteus maximus*, and becomes inserted to the ridge just below. Behind the trochanter, and between it and the head, is the *trochanteric* or *digital fossa*, around and in which several small muscles are inserted; bounding this fossa externally is the trochanteric ridge, continuous with the posterior part of the summit of the trochanter.

The *distal extremity* presents posteriorly two condyles, and anteriorly a trochlea; the condyles, which articulate with the head of the tibia, are placed side by side, being separated by a deep *intercondyloid groove*, from which the interosseous crucial ligaments of the articulation spring, and into which the spine of the tibia projects. The external condyle has two fossæ on the outside, one for the origin of the *popliteus*, and one for the external lateral ligament; the internal condyle has a roughened prominence on its lateral surface, for the attachment of the internal lateral ligament, the *adductor magnus*, and part of the *adductor longus* muscles.

The *trochlea* is the pulley-shaped part to the front of the condyles, which articulates with the patella; it consists of two prominences divided by a groove, and it is in a line with the *intercondyloid fossa*. The internal prominence is the thickest

and most pronounced, and on the side of the bone, between the external prominence and the external condyle, is a depression, in which the tendons of origin of the extensor pedis and flexor metatarsi muscles are attached.

## PATELLA.

(PL. I. X.)

This, the knee-pan or stifle bone, is placed in front of the trochlea of the femur. It is very compact. Its *anterior surface* being irregularly convex and very much roughened, for ligamentous attachment, and its *posterior surface* smooth to articulate with the trochlea of the femur, presenting two concavities divided by a ridge, the innermost being the larger, and in the fresh state enlarged still more by a projecting fibro-cartilaginous lip, or process. The *superior surface* of this bone is broad, uneven, and roughened, giving insertion to the group of muscles called the triceps (or quadriceps) cruralis; the *inferior surface* is rough and pointed, and gives attachment to the middle straight ligament of the patella, while the *lateral borders* and angles have the external and internal straight ligaments attached.

The patella is the lever bone of the stifle joint, or it may be regarded as a sesamoid bone, developed in the tendons of the attached muscles, so as to increase their power, enabling them to act at an advantageous angle. It is liable to fracture by muscular contraction, and to luxation; in the latter case the internal lateral ligament is injured, or may be ruptured.

## TIBIA.

(PL. I. Y.)

The tibia, or leg bone, is a long bone, larger at its proximal than its distal end, situated between the femur and the astragalus, slanting downwards and backwards.

The *shaft* is three-sided, possessing outer, inner, and posterior surfaces, all of which are wider above than below. The *outer surface*, concave superiorly and convex inferiorly, is smooth, and lodges the extensor pedis muscle; the *inner surface*, slightly convex from side to side, is smooth, excepting at its superior part, where it gives attachment to one tendon of the biceps rotator tibialis, the sartorius and gracilis muscles, and is covered chiefly by skin, fascia, and a strong periosteum. The *posterior surface*

the broadest of the three, presents on its superior third a triangular and rather smooth portion, to which the popliteus muscle is attached, the remaining two-thirds being strongly marked by a number of longitudinal ridges, and giving attachment to the deep flexor muscles of the foot; the nutrient foramen is in the upper third of this surface.

The *anterior border* is rounded, and indistinctly marked, except in its upper third, where we find the prominent *tibial ridge*, which is curved outwards, and joins the anterior tuberosity of the proximal extremity. The *external border* is thick and concave above, so that with the fibula it forms the tibial arch. The *internal border* is also thick, and at its upper part has a small tubercle, to which the popliteus muscle is attached.

The *proximal extremity* is much more expanded than the distal, and presents two large, smooth, somewhat undulated, articular surfaces, divided by a roughened conical process, the *tibial spine*, on the outer side of which is an irregular excavation for the insertion of one of the crucial ligaments. The semi-lunar cartilages are interposed between these surfaces and the condyles of the femur. Anteriorly a tuberosity, concave externally and convex internally, joins the tibial ridge, and presents a vertical notch in front for the middle straight ligament of the patella. At the sides are two processes, to which the lateral ligaments are attached, the external being the largest, and presenting also an articular facet for the head of the fibula. Between this process and the anterior tuberosity is a deep groove, for the passage of the tendinous part of the flexor metatarsi muscle.

The *distal extremity*, much smaller than the proximal, and flattened transversely, presents two smooth, deep articular grooves, which run obliquely backwards and inwards, the internal being the deepest, and the external the widest; also three projections, the middle one forming a division between the grooves, being articular and continuous with them, while the others, which form the lateral processes or *malleoli*, are roughened outside for the reception of ligaments. The articular surface corresponds to the trochlea of the astragalus articulating with it. The internal malleolus is the most prominent, and the external the widest, being grooved for the passage of the tendon of the peroneus muscle.



## FIBULA.

(Pl. I. *g*.)

This is a long slender bone, little developed in the horse, and is an appendage to the tibia, being attached to the outer side of that bone, and extending from its head to its lower third, to which it is affixed by a ligement; the space between the two bones is called the tibial arch.

The *head*, or *superior part*, is nodular, somewhat flattened, and roughened externally for the attachment of the external lateral ligament of the joint above; internally it articulates with the external lateral part of the head of the tibia. Distally the bone becomes slender, and tapers to a point, from which a ligament is sometimes continued the whole length of the tibia. The peroneus muscle arises chiefly from the fibula.

## TARSUS.

The tarsus, or hock, corresponding to the ankle-joint of a man, is composed of six irregular, compact bones, placed between the distal end of the tibia and the proximal end of the metatarsus; they are arranged in two series; one, consisting of the cuboid and three cuneiform bones, the magnum, medium, and parvum, corresponds to the lower row of carpal bones; the other, or upper series, consists of the astragalus and calcaneum the first, forming with the bone above the mobile portion of the joint, may be said to correspond to the upper row of carpal bones, while the latter, being the lever bone, corresponds to the trapezium. These bones, like those of the carpus, are thickly covered on their articular surfaces by cartilage, which acts as a protection against concussion.

## ASTRAGALUS.

(Fig. 22. 2.)

This, otherwise termed the os tali or ankle bone, is a pulley-like bone, placed immediately below the tibia, with which it articulates. A very large proportion of the surface of this bone is articular.

The *superior* or *supero-anterior surface* presents an articular

trochlea consisting of two oblique prominences, separated by a deep groove, directed downwards and outwards, which correspond to the articular surface on the distal end of the tibia. The *inferior surface* is concavo-convex, and excepting a small oval external portion, which rests on part of the cuboid bone, and a roughened, excavated posterior portion, in which the great interosseous ligament is attached, the whole of it articulates with the superior surface of the cuneiforme magnum. The *posterior surface* is very irregular, and has four facets, which articulate with the calcaneum, the intervening portion being excavated and roughened. The *lateral surfaces*, the internal of which presents a tubercle inferiorly, are roughened for the insertion of ligaments. The astragalus articulates with the tibia and calcaneum, the cuboid, and great cuneiform bones.

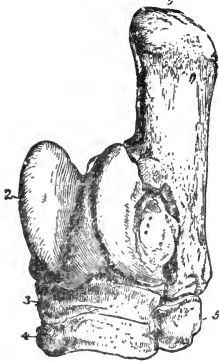


FIG. 22.

Bones of left tarsus of a Horse, seen from the front and outside. 1, Calcaneum; 2, Astragalus; 3, Cuneiforme magnum; 4, Cuneiforme medium; 5, Cuboid.

#### CALCANEUM.

(FIG. 22. 1.)

The os calcis or calcaneum, which forms the prominent part, termed the *point* of the hock, and corresponds to the heel-bone of man, is situated immediately behind the astragalus, and consists of a body and a tuberosity. The *body* is the inferior portion, which is flattened laterally, slightly convex externally, and unevenly concave internally, both surfaces being roughened. Anteriorly it has four articular facets, which correspond to those on the astragalus, the interspaces being rough for ligamentous attachment; posteriorly it is grooved and smooth, for the passage of the deep flexor pedis tendon; inferiorly it has two facets to articulate with the cuboid bone.

The *tuberosity* is oblong, and flattened laterally, its external surface being rough; internally it is smooth, and forms the *tarsal arch*, a groove covered with fibro-cartilage, in which lies the above-named flexor pedis tendon. Both borders are roughened, the posterior one being straight, and giving attachment to the calcaneo-cuboid ligament, while the anterior and shorter one is curved. The superior extremity is expanded and roughened; posteriorly it is covered with fibro-cartilage, over which the

tendon of the flexor perforatus muscle plays ; and anteriorly is a smaller portion, also covered with cartilage, for the gastrocnemius tendon to play over ; and, finally, a roughened depression between the two smooth portions for the insertion of the last named tendon. The calcaneum articulates with the astragalus and cuboid bones.

## OS CUBOIDES.

(FIG. 22. 5.)

The cuboid bone is a small irregularly-shaped bone, which occupies the outer part of the hock between the os calcis and the large and outer small metatarsal bones ; it presents four surfaces.

The *external surface* is convex, very rough and irregular, and gives attachment to ligaments ; the *internal surface* has four articular facets, the two superior of which articulate with the cuneiforme magnum, and the two inferior with the cuneiforme medium ; between the upper and lower facets a large foramen is formed by these three bones, giving passage to the perforating pedal artery. The *superior surface* is smooth, and possesses two continuous articular facets, one large, to articulate with the os calcis, and the other small, to articulate with the astragalus ; the *inferior surface*, also smooth, has two continuous articular facets, separated by a ridge, one flat, to articulate with the large metatarsal, and the other bevelled, to articulate with the outer small metatarsal bone.

The cuboid articulates with six bones—viz., the calcaneum and astragalus above, the cuneiforme magnum and medium internally, and the large and external small metatarsal bones below.

navicular  
OS CUNEIFORME MAGNUM.

(FIG. 22. 3.)

The large cuneiform, called also the scaphoid, and sometimes the navicular bone, is the bone on which the astragalus chiefly rests ; it is somewhat flattened and thin, and presents two surfaces and a circumferent border. The *superior surface* is concave and entirely articular, with the exception of a groove which runs from its outer surface to its middle, and gives attachment to a ligament ; this surface articulates with the astragalus. The

*inferior surface* is slightly convex, and presents three articular facets, two of them, separated by a rough excavation, articulating with the cuneiforme medium, while the third is small, and articulates with the cuneiforme parvum behind. The *anterior* and *internal lateral borders* are rough, for ligamentous attachment; the *external lateral border* has two facets, which articulate with the cuboid, the intervening portion being roughened. The *posterior border*, the smallest, is irregular, and gives attachment to ligaments. The large cuneiform bone articulates with the astragalus, the cuboid, medium and small cuneiform bones.

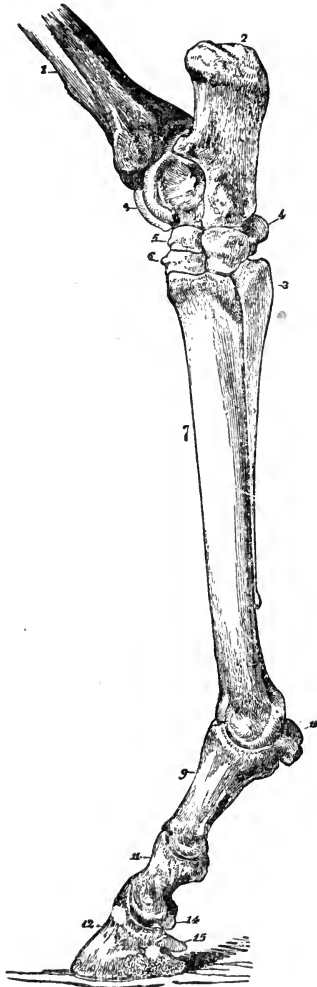


FIG. 23.

External view of bones of left tarsus, metatarsus, and digit of a Horse. 1, Distal end of tibia; 2, Calcaneum; 3, Astragalus; 4, Cuboid; 5, Cuneiforme magnum; 6, Cuneiforme medium; 7, Great metatarsal; 8, External small metatarsal (splint); 9, Proximal phalanx (os suffraginis); 10, Sesamoids; 11, Median phalanx (os coronæ); 12, Distal phalanx (os pedis); 14, Third Sesamoid (os naviculare); 15, Basilar process.

## OS CUNEIFORME MEDIUM.

(FIG. 22. 4.)

The median cuneiform bone is somewhat flattened and triangular in shape, and a little smaller than the magnum, underneath which it is placed.

The *superior surface* is concave, and presents two articular surfaces for the magnum, with a roughened transverse space between. The *inferior surface* is convex, and rests on, and articulates with, the large metatarsal bone. The *anterior border* is rough, for ligaments; the *external lateral border* has two facets for articulation with the cuboid, with a roughened depression between; the *internal lateral border* has one very small

facet, which articulates with the cuneiforme parvum, the remaining portion being excavated and roughened. The middle cuneiform articulates with the large and small cuneiform, the cuboid, and the large metatarsal bones.

## OS CUNEIFORME PARVUM.

The small cuneiform is a very irregular bone, and the smallest in the hock, at the postero-internal part of which it is situated. It is sometimes divided into two parts, and presents four surfaces and two extremities. Its *superior surface* is smooth and concave, to articulate with the magnum; and its inferior surface has usually two small facets, one articulating with the inner small metatarsal, the other with both the inner and large metatarsal bones. The *anterior extremity* presents a very small facet for the cuneiforme medium, the remainder of the bone being very irregular, and roughened for ligaments. The small cuneiform articulates with the large and middle cuneiforms, and the large and inner small metatarsal bones.

## METATARSUS.

## OS METATARSI MAGNUM.

(Fig. 24.)

This bone presents the same general appearance as the large metacarpal bone, from which it differs principally in being about one-sixth longer, flattened laterally, and rounded and more prominent anteriorly. It has three articular facets on its superior surface, a large one in the middle for the middle cuneiform, one on the inner side for the small cuneiform, and one on the outer side for the cuboid bones; this surface also presents a deep, rough fossa of insertion in its centre. The deep groove which passes obliquely backwards and downwards, on the external side of this bone, is for the passage of the great metatarsal artery. The inferior extremity is larger and thicker than the superior.



FIG. 24.

Posterior view of left metatarsus of a Horse. 1, Large metatarsal bone; 2, Internal, and 3, external, small metatarsal bones; 4, Partial origin of suspensory and check-ligaments; 5, Nutrient foramen; 6, Articular ridge joining the condyles.

## OSSA METATARSI PARVA.

(FIG. 24. 2, 3.)

These also present the same general form as the small metacarpal bones; the external is the longest and largest, and has the largest head, with two facets which articulate with the cuboid bone; the internal one has also three articular facets, two for the small, and one for the middle cuneiform bones. The two lateral facets on each head articulate with corresponding ones on the large metatarsal bone.

The remaining bones of the hind extremity—viz., the three phalanges, with their three small accessory bones, so closely resemble the corresponding bones of the fore extremity, that it seems at first sight difficult to distinguish the one from the other; the chief differences being, that the first phalanx of the hind extremity is longer, its proximal end larger, and its distal end smaller, than in the fore extremity. The second phalanx is longer, but not so broad transversely, and the third is more pointed, or semi-elliptical, in front, and more concave on its under surface, all these differences being more or less marked in degree. The three sesamoid bones are almost identical.

---

 COMPARATIVE OSTEOLOGY.

In this section of the subject we shall endeavour to point out where the skeletons of the domesticated animals, other than the horse, differ from the typical skeleton of the latter in any important particular. The following descriptions are therefore in all cases comparisons, where comparison is possible, between the typical skeleton and the skeleton in question.

## RUMINANTIA.

In this class we take the Ox as the animal which represents best, for our purpose, the family Cavicornia or Bovidae.

## AXIAL SKELETON.

## THE SKULL.

In the *cranium* of the ox an important feature is the development of the *frontal bone*, which extends from below the eyes to the back of the skull, forming the entire forehead and crest, in the middle of which is the frontal tuberosity, which is very large in hornless animals. Springing from the sides of the crest are two processes, varying in size and curvature, but corresponding

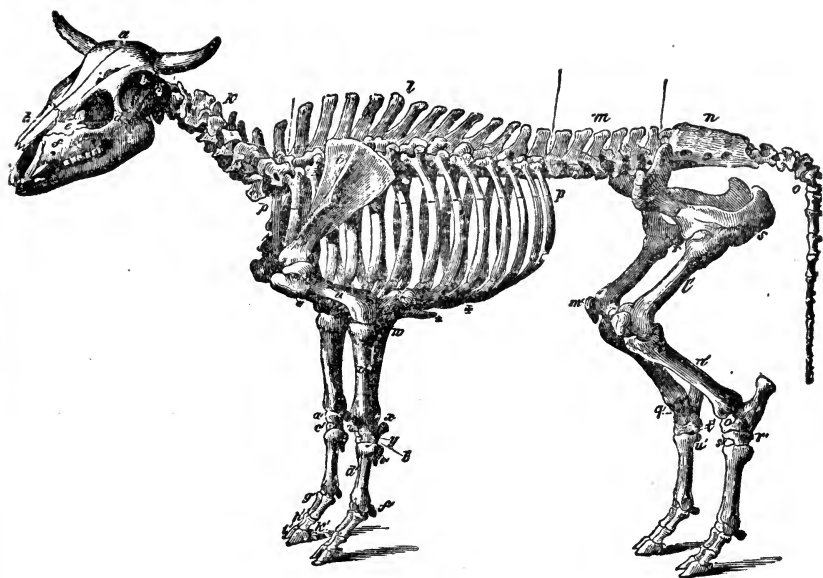


FIG. 25.

## SKELETON OF THE OX (RUMINANTIA).

## AXIAL SKELETON.

## THE SKULL.

*Cranial Bones.*—Occipital, 1; *b*, Parietal, 2; *a*, Frontal, 2; *c*, Temporal, 2; Sphenoid, 1; Ethmoid, 1; Auditory ossicles, 8.

*Facial Bones.*—*h*, Nasal, 2; *e*, Lachrymal, 2; *d*, Malar, 2; *f*, Maxilla, 2; *g*, Premaxilla, 2; *i*, Inferior maxilla, 2; Palatine, 2; Pterygoid, 2; Vomer, 1; Turbinals, 4; Hyoid (segments), 7. Teeth:—Incisors, 6; Canines, 2; Molars, 24.

*The Trunk.*—*k*, Cervical Vertebrae, 7; *l*, Dorsal vertebrae, 13; *m*, Lumbar vertebrae, 6; *n*, Sacrum (five segments), 1; *o*, Coccygeal vertebrae (variable), 20; *p p*, Ribs, 26; \* Sternum (seven sternbrae), 1; † Costal cartilages.

## APPENDICULAR SKELETON.

## PECTORAL LIMB.

*t*, Scapula, 2; *u*, Humerus, 2; *v*, Radius, 2; *w*, Ulna, 2. Carpus:—*x*, Trapezium, 2; *y*, Cuneiform, 2; *z*, Lunar, 2; *a'*, Scaphoid, 2; *b'*, Unciform, 2; *c'*, Magnum, 2. Metacarpus:—*d'*, Large bone, 2; *e'*, Small bone, 4; *f'*, Large sesamoids, 8. Digit:—*g'*, Proximal phalanges, 4; *h'*, Median phalanges, 4; *i'*, Distal phalanges, 4; *k'*, Small sesamoids (naviculars), 4.

## PELVIC LIMB.

*Pelvis.*—Os Innominatum:—*q*, Ilium, 2; *s*, Ischium, 2; *r*, Pubis, 2.

*The Limb.*—*v'*, Femur, 2; *m'*, Patella, 2; *n'*, Tibia, 2. Tarsus:—*o'*, Maleolar, 2; *p'*, Calcaneum, 2; *q'*, Astragalus, 2; *r'*, Cubo-cuneiform, 2; *s'*, Cuneiforme medium, 2; *t'*, Cuneiforme parvum, 2. Metatarsus:—Large bone, 2; *u'*, Small bone, 2. Large sesamoids, 8. Digit:—Proximal phalanges, 4; Median phalanges, 4; Distal phalanges, 4; Small sesamoids, 4.

## VISCERAL SKELETON.

Bones of the heart, 2.

The separate bones of the Ruminant Skeleton, as here considered, are 251.

to the shape of the horns, which they support. These are the flints or *horn cores*, which are porous in their structure, especially at the roots; they are very rough, covered by thick periosteum, and contain sinuses, large canals, and foramina, through which pass arteries and veins, and which are continuous with the largely-developed frontal sinuses; the latter extend from the orbit to the extremities of the cores, and nearly as far backwards and downwards as the foramen magnum. The superior surface of the frontal bone is flat and broad, especially in the male. The supraorbital foramina are double, placed very far backwards, and continued by a groove which extends backwards and forwards. The frontal arch articulates with the malar portion of the zygoma,

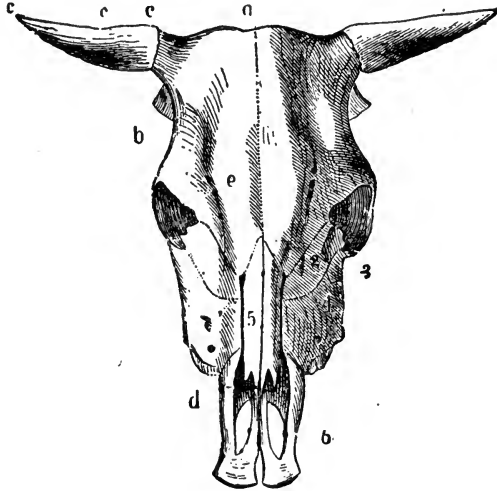


FIG. 26.

## SKULL OF AN OX.—Superior Aspect.

*a*, Frontal crest; *b*, Lateral crest; *c c c*, Horn core.  
*d*, Nasal peak; *e*, Supraorbital foramina. BONES:—  
 1. Frontal; 2. Lachrymal; 3. Malar; 4. Superior maxillary; 5. Nasal; 6. Premaxilla, with incisive-openings.

The *parietal* bone is transversely elongated, and recurved at its extremities. It is placed below the frontal crest, extending under and supporting the cores, and entering the temporal fossa to articulate with the sphenoid and temporal bones. Beneath the crest posteriorly it forms with its fellow the inter-parietal suture.

The *Wormian* bone exists, fused with the occipital and parietals. It is described as “wanting,” by some authorities.

The *occipital* bone is not visible when the skull is viewed superiorly, being concealed by the prominent frontal crest. It is much wider from side to side, but smaller than in the horse. It has neither crest nor tuberosity, the condyles being less prominent, but wider; the styloid processes are shorter, but broader, and curved inwards. The basilar process is short and thick, with a large basilar groove, and two rough prominences for muscular attachment anteriorly. The condyloid foramina are double, sometimes triple.



The *squamosal* and *petrosal* bones are united into a *single temporal-bone*. The temporo-maxillary articulation, zygomatic process, temporal conduit, the auditory bulla, and styloid process, are large. The zygomatic process does not articulate with the frontal bone. The foramen lacerum basis cranii is considerably occluded by the prominence of the auditory bulla. The external auditory meatus is small, and directed slightly downwards. Immediately behind the sella turcica is a slight and rough eminence, very prominent in some classes, the posterior clinoid process.

The *sphenoid* has large and thin pterygoid processes, a deep sella turcica, and a prominent olivary process. The pterygoid foramen is absent; the foramen lacerum basis cranii small, its place being largely occupied by the auditory bulla, but there is a large *foramen ovale*, for the passage of the inferior maxillary nerve and the spheno-spinal artery. The foramen lacerum orbitale, foramen patheticum, and foramen rotundum are represented by an anterior common foramen.

The *ethmoid* and its cells are well developed. It has a large volute, prolonged forwards, forming a kind of third turbinal bone, called the olfactory cave (*antre olfactif*).

The *nasal bones* are shorter, narrower, and not so firmly articulated as those of the horse. The posterior extremity is sunk in a groove in the anterior border of the frontal bone; the anterior extremity presents two points with a notch between them, the central pair joining to form one; therefore the nasal peak is trifid; in the smaller ruminants it is usually double.

The *superior maxilla* is shorter but broader, the maxillary spine being represented by a rough protuberance, not continuous with the zygoma. The infra-orbital foramen is opposite the first molar tooth. The maxillary sinus is large, and is prolonged between the two plates of the palatine bone. There is no alveolus anteriorly for a canine tooth. This bone does not assist in forming the palatine foramen.

The *premaxilla* is broad; its inferior surface is flat and destitute of alveolar cavities. There is no incisive foramen, but very large incisive openings. The premaxillæ are rarely united by suture.

The *lachrymal bone* is large, forming at the bottom of the orbit a large lachrymal protuberance continuous with the maxillary sinus. The wall of this protuberance is thin and fragile. The lachrymal tubercle is absent.

The *molar bone* is well developed. Posteriorly it is bifid; the superior branch meets the orbital process of the frontal bone, and the posterior joins the zygomatic process of the temporal bone, behind the orbital fossa.

The *palatine bones* are large, the part entering into the formation of the bony palate being broad. The palatine *crest* is thin and elevated, being formed by the union of the posterior borders of the palatine, pterygoid, and pterygoid process of the sphenoid bones. The posterior nares are very narrow, and situated behind, not between, the superior maxillæ.

The *pterygoid bones* are large, and usually close an opening which is left between the sphenoid and palatine bones.

The *superior turbinal* is small, while the inferior one is largely developed.

The *vomere* is very large, resting on the anterior half of the maxillary suture.

The *inferior maxilla* is longer but less massive than in the horse; the neck is more constricted, and the symphysis seldom becomes completely ossified.

There are eight small alveoli in front for the incisors and canines, the latter being close up to the former; the condyles are small and convex in their short, but slightly concave in their long diameter, permitting considerable lateral motion to the joint. The coronoid processes are long, and the sigmoid notches very deep.

The *os hyoides* has a cornu and two cornicula on each side—the former (stylchyalæ) are suspended from the temporal bone. The spur process is small and blunt.

#### VERTEBRÆ.

The true vertebral column is made up of 26 segments—7 cervical, 13 dorsal, and 6 lumbar. The bodies of the *cervical* vertebræ are shorter than those of the horse; the transverse processes consist of a superior, small, and an inferior, large portion, pierced by the vertebral foramina; the neural spines are large, and increase from before backwards; the inferior spines unite the anterior and posterior articular ends. The *atlas*, smaller than that of the horse, has its alæ more horizontal and slightly turned up at the external borders. The spinal foramen is large, and the *posterior lateral one absent*. The condyloid articulations are wide, that for the *dentata* being small and flat. The *dentata* is short, the odontoid process being broad, bounded below by a prominent articular ridge, which is not excavated in the inferior median line; the neural spine does not bifurcate nor become continuous with the posterior articular processes. The pedicles on either side are perforated by a circular foramen.

The sixth cervical vertebra has long superior spinous and transverse processes, but no inferior spine. The seventh neural spine is the longest, and points backwards and upwards; the transverse processes are single, and terminate in rough tuberosities; there is no inferior spine, and seldom a vertebral foramen.

The centra of the *dorsal* vertebræ are longer than in the horse, but have the same general form; the pedicles are almost always pierced by foramina in place of the posterior notches. The transverse processes are large, decreasing in size, and assuming an arched form from before backwards; all but the last, or last two, present distinct articular surfaces for the costal tubercles. The neural spines are broad, long, and smooth; the five or six anterior ones incline backwards, then upwards, the remainder simply backwards; the fourth is usually the longest, but the first four or five vary little in length. The rest gradually become shorter backwards to the last. This gives the back when viewed laterally a very different form from that of the horse. The *lumbar* vertebræ are longer and thicker than in the horse, their bodies being more convex on the lateral and inferior surfaces; their transverse processes are long, the fourth being the longest, and they are almost at right angles to the body, concave anteriorly, convex posteriorly, the first four being inclined backwards; they never articulate with each other, nor does the last with the sacrum. The articular processes are small, the posterior being overlapped by the anterior ones.

The *sacrum* is large and more arched, and the superior surface more convex than in the horse; the spinous processes are united by more complete ossification. The superior groove is narrow and uneven, and the superior foramina not so regular; the under surface is more concave, the promontory being

better marked, and the inferior foramina larger. The sacral cornua are large, and expanded for ligamentous attachment; the spinal canal is oval, and the convex articular portion of the body large, the articular processes being widely separated by a triangular opening leading into the canal. The transverse processes are short, thick, and non-articular anteriorly; their external extremities are bounded by a vertical border, the inferior angle of which is directed downwards, giving a deeper surface for articulation with the ilium.

The *coccygeal* bones, from 15 to 20 in number, are strong and tuberosous. Articular processes exist in the anterior ones.

#### THORAX.

Very generally the ruminants have 13 pairs of *ribs*, of which 8 are true and 5 false. They are straight, broad, long, and more uniform than those of the horse; the superior extremity is large and smooth, the necks of the anterior ones short and thick, and the tubercles large; the necks of the posterior ones are long and thin, and smaller than in the horse. The angles are not well marked; the distal extremities are expanded to articulate with their cartilages by means of true joints.

The *sternum* is large and flattened, consisting of seven pieces, which, the anterior one excepted, unite by ossification; and between the first segment or *manubrium* and the second there is, in the larger ruminant, a true joint. The superior surface is concave, forming the floor of the chest, the inferior convex, but slightly concave from side to side. The borders present between each two segments articular depressions for the costal cartilages. The cariniform cartilage is small and conical, the ensiform large and circular.

#### PECTORAL LIMB.

The *scapula* is large and very triangular. The spine does not, as in the horse, terminate gradually in the neck, but by an abrupt angle, prolonged to a point, the *acromion* process. The neck is more distinct, and the coracoid process and glenoid cavity are both small, and placed close together. In the *humerus* (Fig. 25. *u*), the bicipital groove is single; the external trochanter is very large, with its summit curved over the bicipital groove. The head is large, the tuberosities small, and the shaft less twisted, than in the horse. The *radius* is short; the *ulna*, longer and larger than in the horse, extends to the distal end of the *radius*, and articulates with the cuneiform bone. There are two radio-ulnar arches, connected by a deep fissure. It is important to note here the fact that the development of the *ulna*, and to some extent its freedom, are *directly proportional* to the number of digits possessed by the animal.

The *carpus* consists of 6 bones, 4 above and 2 below. The upper are the scaphoid and lunar, which articulate with the *radius*; the cuneiform, articulating with the *radius* and *ulna*; and the trapezium, which is small, tuberosous in shape, and does not articulate with the *radius*. The lower are the *os magnum* and *unciform*, which articulate with the large metacarpal bone, the trapezoid and pisiform bones being wanting; the former, perhaps, is part of the *os magnum*.

The *large metacarpal* bone presents a vertical groove down its anterior middle, which marks the original division of the bone into two. The inferior extremity is divided by a deep fissure into two articulations, each resembling

the single one of the horse, the external one being always the smaller; a rudimentary metacarpal is placed postero-externally. The phalanges and sesamoids in either limb are double, one complete set forming each digit; they are small and narrow, the coffin bone resembling half of that of the horse, mesially divided. Posterior to the fetlock joint are two rudimentary digits, each containing two undeveloped phalanges, the median and the distal.

#### PELVIS.

The *os innominatum* is larger, but presents the same general appearance as in the horse. The *ilium* is thick, and possesses a prominent line running from the anterior spine to the superior ischiatic ridge. The internal surface is very convex, the ridge between the part resting on and that without the sacrum being well marked. The ilio-pectineal eminence is prominent, and the crest and spines very strong. The *ischium* equals the ilium in size; the anterior extremity has a thick projecting external portion, which forms part of the cotyloid cavity, and is surmounted by the large superior ischiatic spine, whence a slight ridge is continued backwards over the thick concave body to the tuberosity. The inferior ischiatic spine is conical, pointing outwards and downwards. The ischial symphysis presents inferiorly a ridge and tubercle, absent in the horse. The *pubis* is large and concave, and the symphysis is never completely ossified. The acetabulum is deep, and the cotyloid notch is narrow and deep, being near the large foramen ovale. The inlet of the pelvic cavity is oval; its sacro-pubic diameter is greater than the transverse one, while the sacro-ischiatic diameter of the outlet is less than the transverse.

#### PELVIC LIMB.

The *femur* (Fig. 25. *l'*) is distinguished from that of the horse by the trochanter minor being wanting. The trochanter internus is a round tubercle near the posterior surface; the head is small, but prominent, the trochanteric fossa deep, but small; the trochanter major has only one eminence, not very prominent, and is united to the internal trochanter by a ridge. The condyles and trochlea are somewhat small, and the supracondyloid fossa is shallow. The *patella* is narrow, and somewhat conical in shape.

The *tibia* (Fig. 25. *n'*) has no vertical fossa on the anterior tuberosity, and no articular facet for the fibula; the distal extremity has its external malleolus detached, forming a small bone called the *malleolar bone*, which articulates with the tibia, calcaneum, and astragalus, and represents the distal end of the fibula, the remainder of which bone, small when present, is usually replaced by a long ligament stretching the whole length of the tibia.

The *tarsus* consists of 5 bones. The astragalus is deep, but narrow, having a pulley-shaped surface inferiorly as well as superiorly. The calcaneum is long and square; the cuneiforme magnum and cuboid are united, forming the *cubo-cuneiform bone*; the cuneiforme medium is like that of the horse, while the parvum is very small.

The *large metatarsal bone* has its inferior extremity divided into two equal parts by a deep fissure, with a groove superiorly. The small metatarsal bones, when present, are rudimentary and single. The digits correspond to those of the pectoral limb.

VISCERAL SKELETON.

In the adult Ruminant, two bones are commonly found in the heart, and may be termed the *cardiac bones* (*ossa cordis*). They are found related with the auriculo-ventricular rings. In shape they present three angles, three borders, and two surfaces. The left bone is considerably smaller than the right.

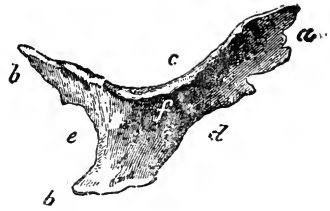


FIG. 27.

Right cardiac bone of an Ox—natural size. *a*, Anterior angle; *b*, Posterior angles; *c*, Superior border; *d*, Anterior border; *e*, Posterior border; *f*, Right surface.

OMNIVORA.

The Omnivora are represented in Veterinary Anatomy only by the Hog.

AXIAL SKELETON.

THE SKULL.

In the skull of this animal the following points are noteworthy. The *supra-occipital* bone forms a very prominent crest; the occipital condyles and the foramen magnum are small; the styloid processes very long, inclining backwards. The *parietal* bones are early ankylosed, the superior surface being contracted in the middle, with a sharp ridge on each side, limiting the temporal fossa. The orbital process of the *frontal* bone is short, the frontal arch being completed by a ligament; in the centre of the bone, about a third from its anterior border, is the supraorbital foramen, and from it a groove passes forwards and outwards. The frontal bone articulates with the superior maxilla. The *temporal* is a single bone on each side; the petrous portion is small, and the zygomatic process large, bearing a prominent spine. A ridge connects the external auditory meatus, placed very high up, with the mastoid protuberance, which is very large, the styloid process being short.

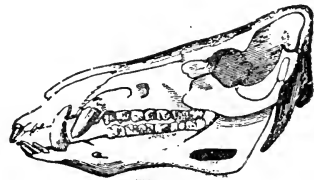

FIG. 28.

Skull of a Boar—lateral aspect.

The maxillary articulation is not supported behind by a well-marked process, and is smallest transversely. The *sphenoid* is short, with large, flat pterygoid processes; the wings do not project, but are nearly perpendicular; the *sella turcica* is deep, and the olivary and clinoid processes large.

The *nasal* bones are long, straight, and strong, firmly connected with the frontal and superior maxillary, but do not articulate with the lachrymal bones; the nasal peak projects nearly to the level of the incisors. The *lachrymals* are small, with lachrymal fossæ on the supero-external part of the bone instead of in the orbit, as in the horse and ox; they are pierced by two conduits, which afterwards form one. The *malar* bone is very strong, and the zygomatic process large, and terminating in two branches, between which rests the zygomatic process of the temporal bone; the anterior branch is short, and not united to the orbital arch of the frontal bone. The *superior maxilla* is proportionally rather short and narrow, and its surface concave, for the reception of large facial muscles; it presents a large lateral protuberance anteriorly, whence

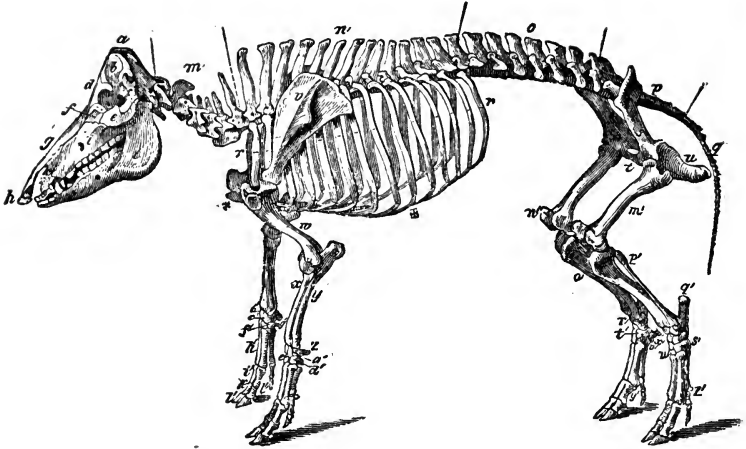


FIG. 29.

## SKELETON OF THE HOG (OMNIVORA).

## AXIAL SKELETON.

## THE SKULL.

*Cranial Bones.*—*a*, Occipital, 1; *b*, Parietal, 2; *d*, Frontal, 2; *c*, Temporal, 2; Sphenoid, 1; Ethmoid, 1; Auditory ossicles, 8.

*Facial Bones.*—*g*, Nasal, 2; *h*, Os rostri, 1; *f*, Lachrymal, 2; *e*, Malar, 2; *i*, Maxilla, 2; *k*, Pre-maxilla, 2; *l*, Inferior maxilla, 1; Palatine, 2; Pterygoid, 2; Vomer, 1; Turbinals, 4; Hyoid series, 5. Teeth:—Incisors, 12; Canines, 4; Molars, 28.

*The Trunk.*—*m*, Cervicle vertebrae, 7; *n*, Dorsal vertebrae, 14; *o*, Lumbar vertebrae, 7; *p*, Sacrum, (four segments), 1; *q*, Coccygeal vertebrae (variable), 18; *r r*, Ribs, 28; \* Sternum (seven sternbrae), 1; † Costal cartilages.

## APPENDICULAR SKELETON.

## PECTORAL LIMB.

*v*, Scapula, 2; *w*, Humerus, 2; *x*, Radius, 2; *y*, Ulna, 2. Carpus:—*z*, Trapezium, 2; *a'*, Cuneiform, 2; *v'*, Lunar, 2; *c'*, Scaphoid, 2; *d'*, Unciform, 2; *e'*, Magnum, 2; *f'*, Trapezoid, 2; *g'*, Plisiform, 2. Metacarpus:—*h'*, Bones, 8; Large sesamoids, 16. Digit:—*i'*, Proximal phalanges, 8; *k'*, Median phalanges, 8; *l'*, Distal phalanges, 8; *l''*, Small sesamoids, 8.

## PELVIC LIMB.

*Pelvis.*—Os Innominatum:—*s*, Ilium, 2; *t*, Pubis, 2; *u*, Ischium, 2.  
*The Limb.*—*m'*, Femur, 2; *n'*, Patella, 2; *o'*, Tibia, 2; *p'*, Fibula, 2. Tarsus:—*q'*, Calcaneum, 3; *r'*, Astragalus, 2; *s'*, Cuboid, 2; *t'*, Cuneiforme magnum, 2; *u'*, Ecto-cuneiforme, 2; *v w*, Meso- and Endo-cuneiformes, 4. Metatarsus:—Large bones, 8; *x'*, Small bones, 2; *y'*, Large Sesamoids, 16. Digit:—Proximal phalanges, 8; Median phalanges, 8; Distal phalanges, 8; Small sesamoids, 8.

## VISCERAL SKELETON.

None.

The separate bones of the Skeleton of the Hog, as here considered, are 324.

springs the tusk; the alveoli for the molar teeth, usually seven in number, gradually increase in size, from the anterior one, which is very small, to the last, largely developed and strong. The maxillary sinus is small, projecting into the malar bone; the palatine foramen opens on the palatine plate of the maxilla, before the palatine bone. The *premaxilla* is large and strong; it is not joined at the symphysis, and consequently forms no foramen incisivum; its external process is very long, and articulates largely with the nasal bone; there are three alveoli on each side for the incisor teeth. Part of the septum of the nose becomes ossified, forming the *prenasal* or snout bone (*os rostri*). The anterior nares are small and round.

The *palatine* bones form a large portion of the bony palate; their orbital portion is very small. The palatine ridge is replaced by a tuberosity, with which the pterygoid process of the sphenoid bone articulates externally, and the pterygoid bone internally, and the union of these three parts results in a large trifold tubercle.

The *turbinals* are longer and less fragile than in the horse.

The *inferior maxilla* is very strong, having no well-defined neck, and small interdental spaces; the coronoid process is short, but strong, and the condyles, somewhat nodular, are compressed laterally. The dental canal terminates anteriorly by numerous small mental foramina; and the alveoli for the molars are seven in number. Posteriorly this bone bears a certain resemblance to the corresponding human bone. The symphysis becomes early ossified in this animal.

The *os hyoides* has a large body, but no appendix. The cornicula are short, while the cornua are thin, twisted somewhat like the letter S, and united to the temporal bones by elastic ligaments.

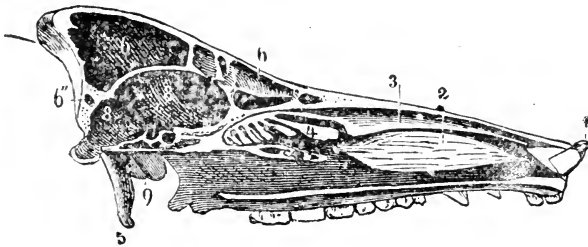


FIG. 30.

Longitudinal Section of a Hog's Skull. 1, Os rostri; 2, Maxillary Turbinal; 3, Frontal Turbinal; 4, Large Ethmoidal volute; 5, Occipital Styloid process; 6 6', Frontal Sinus; 7, Nasal chamber; 8 8', Cranial cavity; 9, Auditory bulla.

#### VERTEBRÆ.

The true vertebral column consists of 28 vertebræ.—7 cervical, 14 dorsal, and 7 lumbar. The *cervical vertebræ* are very short, convex below, and without inferior spines; the transverse processes are bifid, and, excepting the last, the posterior ones are large and overlapping. The articular processes are strong, the anterior being pierced by a foramen entering the spinal canal. The transverse processes are small and generally pierced by vertebral foramina. The *atlas* is strong, rough, and irregular, presenting a large tuberosity on its superior surface; the wings are strong, particularly at their posterior borders;

the posterior foramen is inconstant, usually opening on the posterior edge. The *axis* is broad anteriorly, with a small odontoid process, and extended articular surfaces; small transverse processes are pierced by large vertebral foramina; the neural spine is tall and thin. The five posterior segments have large neural spines, the *prominens* especially so.

There are usually 14 *dorsal* vertebræ, with short centra, increasing in length from before backwards. The neural spines are broad, decreasing gradually from the first backwards; the first is nearly upright, the rest slope backwards, excepting the last two or three, which are slightly inclined forwards. Two foramina enter the neural canal on each side from the base of the transverse process. The *lumbar* vertebræ number 6, sometimes 7; their centra are longer than in any other region, resembling those of the ruminant. The neural spines are strong-pointed, and bifid at the posterior borders, the diverging laminae being continuous with the posterior oblique processes; the transverse processes are long, nearly horizontal, and without articular surfaces; the base of each is pierced by a small foramen leading into the neural canal. The *sacrum* is usually made up of 4 segments; the neural spines are very rudimentary, in fact the laminae scarcely coalesce, leaving the neural canal partly open; the articular processes are large and overlap those of the last lumbar vertebra. The *coccygeal* bones vary in number, being usually from 18 to 23, and the anterior ones have articular processes.

Generally there are 14 pairs of *ribs*—7 true and 7 false. They are thin and flat, the last three having their tubercles and the posterior part of their heads united. The second, third, fourth, and fifth have true articulations distally. The *sternum* is very long, and consists usually of 7 segments, the manubrium remaining separate as in the ox. The cariniform cartilage forms a long eminence terminating in a blunt point.

#### APPENDICULAR SKELETON.

##### PECTORAL LIMB.

The *scapula* is large, without an acromion process; it has a prominent spine, bearing in its centre a large tubercle, which inclines backwards over the *postea-spinatus* fossa. The *humerus* is short, and compressed laterally, the head inclining backwards; the bicipital groove is single, and the external trochanter is very large, with its summit curved over the bicipital groove, as in the ox; the external tuberosity is small, the internal one being replaced by muscular imprints. The *radius* is small, and much curved; while the *ulna* is a true long bone, having a medullary canal, and extending to the carpus, with which it articulates. The radius and ulna are united by ligaments, which rarely become ossified. The ulna is flattened from side to side, and lies on the posterior face of the radius, in close connection, except that there exists a radio-ulnar arch. The *olecranon* is prominent. The *carpus* consists of 8 bones, 4 in the upper and 4 in the lower row. The bones of the upper row are similar to those of the horse, the cuneiform articulating above with the ulna and a small portion of the radius, the lunar and scaphoid bones with the radius, but the trapezium with neither of the bones of the forearm. The bones of the lower row decrease from without inwards, and are the unciform, articulating with the two external, the os magnum with the large internal, and the trapezoid with the small internal metacarpal bones; the pisiform, ter-



minating bluntly, does not articulate with the metacarpus, the pollex or thumb being absent.

The *metacarpal bones* are 4 in number. The middle pair are large, the side pair small; the large ones articulate with each other, and with their relative small ones superiorly. Each terminates distally, as the single one of the horse, but the middle pair are the sole weight-carriers, for the lateral ones do not rest upon the ground. In each of the four digits there are three phalanges, with their accessory sesamoid and ungular bones.

#### PELVIS AND PELVIC LIMB.

The *os innominatum* presents the same general characters as that of the ruminant; it is, however, distinguished by the form of the ilium, which is very convex on its anterior border and crest, and by the absence of the protuberance on the inferior symphysis. The *femur* differs little from that of the ox, except in its more contracted neck, which is about on a level with the trochanter major; the trochanter minor is wanting. The *tibia* resembles that of the ruminant; its anterior tuberosity is notched, and the external malleolus is supplied by the distal end of the fibula. The *fibula* extends the whole length of the tibia, articulating with it at both extremities, and distally with the astragalus and calcaneum. The *tarsus* presents no important deviation from the typical joint, except that the cuneiforme medium is divided, hence there are in the lower row the ecto, meso, and endo-cuneiform bones; the distal articular surface of the astragalus articulates partly with the cuboid bone. The metatarsus and phalanges closely resemble those of the anterior limb. There is a very rudimentary fifth metatarsal bone on the inside, a vestige probably of the hallux or great toe.

### CARNIVORA.

In this order our descriptions allude mostly to the Dog, that animal being an excellent type of the order, and one easily obtained.

#### AXIAL SKELETON.

##### THE SKULL.

The *occipital* bone of the Dog is very strong, and triangular behind, terminating in a sharp pointed crest. The tuberosity is not well marked; the styloid processes are short, and the condyles large. The foramen lacerum basis cranii is divided into two portions by the auditory bulla, which is large and rounded; the basilar process is long and thick. The *Wormian* bone is united to the occipital; the ossific tentorium is large. The *parietal* bones are very convex, in some breeds meeting in a sharp ridge, continuous with the occipital crest. The *frontal* bones are triangular, and present along their middle a hollow, more or less marked. The orbital process is simply a peak, the arch being completed by a ligament; there is no supraorbital foramen; the frontal bone articulates with the superior maxilla. The *temporals* are not divisible into distinct pieces, as in the horse; the zygomatic processes are large, and project very much, forming capacious temporal fossæ, and having glenoid cavities, which are elongated transversely, for the condyles of the inferior maxilla.

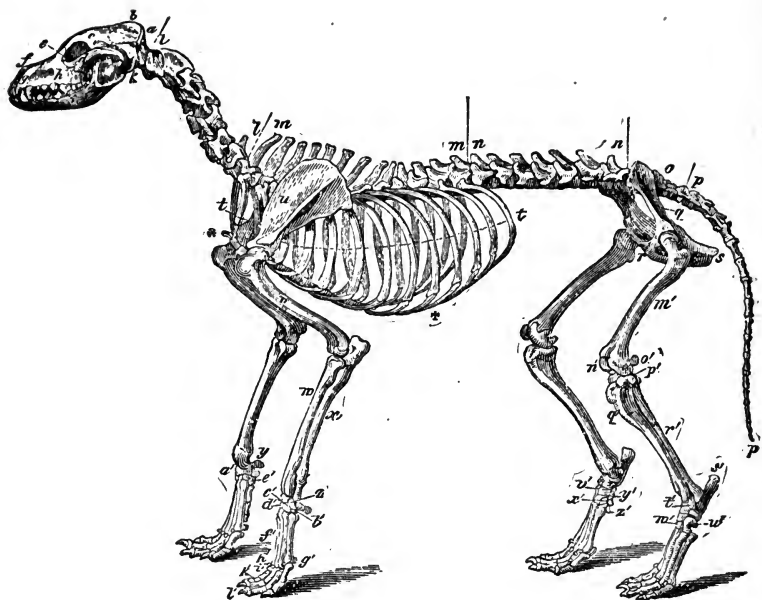


FIG. 31.

## SKELETON OF THE DOG (CARNIVORA).

## AXIAL SKELETON.

## THE SKULL.

*Cranial Bones.*—*a*, Occipital, 1; *b*, Parietal, 2; *c*, Frontal, 2; *k*, Temporal, 2; Sphenoid, 1; Ethmoid, 2; Auditory ossicles, 8.

*Facial Bones.*—*f*, Nasal, 2; *e*, Lachrymal, 2; *d*, Malar, 2; *h*, Maxilla, 2; *g*, Premaxilla, 2; *i*, Inferior Maxilla, 2; Palatine, 2; Pterygoid, 2; Vomer, 1; Turbinals, 4; Hyoid series, 9.

*Teeth.*—Incisors, 12; Canines, 4; Molars, 26.

*The Trunk.*—*l* *l*, Cervical vertebrae, 7; *m m*, Dorsal vertebrae, 13; *n n*, Lumbar vertebrae, 7; *o*, Sacrum (three segments), 1; *p p*, Coccygeal vertebrae (variable), 20; *t t*, Ribs, 26; \* Sternum (eight sternbrae), 1; \* Costal cartilages.

## APPENDICULAR SKELETON.

## PECTORAL LIMB.

*u*, Scapula, 2; *v*, Humerus, 2; *w*, Radius, 2; *x*, Ulna. Carpus:—*y*, Trapezium, 2; *z*, Cuneiform, 2; *a'*, Scaphoid, 2; *b'*, Unciform, 2; *c'*, Magnum, 2; *d'*, Trapezoid, 2; *e'*, Pisiform, 2; Metacarpal bones, 10; *n'*, Anterior sesamoids, 10; *g'*, Posterior sesamoids, 20. Digit:—*h'*, Proximal phalanges, 10; *k'*, Median phalanges, 8; *l'*, Distal phalanges, 10; Small sesamoids wanting.

## PELVIC LIMB.

*Pelvis.*—Os Innominatum:—*q*, Ilium, 2; *r*, Pubis, 2; *s*, Ischium, 2.  
*The Limb.*—*m'* Femur, 2; *o'*, Fabelae, 4; *n'*, Patella, 2; *q'*, Tibia, 2; *p'*, Tibial sesamoid, 2; *r'*, Fibula, 2. Tarsus:—*s'*, Calcaneum, 2; *t'*, Astragalus, 2; *u'*, Cuboid, 2; *v'*, Superior cuneiform, 2; *w'*, Ecto-cuneiforme, 2; *x'*, Meso-cuneiforme, 2; *y'*, Endo-cuneiforme, 2. Metatarsus:—Large bones, 8; *z'*, Small bones, 2; Anterior sesamoid, 8; Posterior sesamoids, 16. Digit:—Proximal phalanges, 8; Median phalanges, 8; Distal phalanges, 8; Small sesamoids wanting.

## VISCERAL SKELETON.

Os Penis, 1; Rudimentary clavicle (inconstant), 2.

The bones of the Carnivora Skeleton, thus considered, are 345.

The external auditory meatus and auditory bulla are large, the sense of hearing in carnivora being very acute; there are only diminutive hyoid, and styloid processes. There are two canals, of which there exists no trace in other domestic animals—viz., the carotid, which traverses the mastoid portion to join the venous canal between the basilar process and temporal; and another which pierces the petrous portion at the upper part of the carotid canal, and gives passage to the fifth pair of nerves. The *sphenoid* bone resembles that of man; its posterior part is short, and presents two large wings, which mount to the temporal fossæ, the anterior part being straight, and prolonged by small wings. The pterygoid processes are very short, the pituitary fossa limited by the clinoid processes. The *ethmoid* bone presents very deep fossæ and well-developed volutes.

The *nasal bones* are small, narrow, but wider in front, presenting a semi-circular concavity, instead of a peak. The *superior maxilla* is short, but strong, differing, as all the facial bones do, with the *breed*; it articulates by a long process with the frontal, forms partly the socket for the canine tooth, and is spineless. The *premaxilla* is short, and presents a small foramen incisivum, which is often wanting in the cat, alveoli for the incisors, and an oval incisive opening. The *lachrymal* is small, and in the cat confined to the orbital cavity. The *malar* bone articulates in the usual manner, while its zygomatic process is large, and curved outwards, and its summit bifid, the arches being formed very similarly to those in the omnivora. The *palatine bones* form about a third of the palate; they do not assist in the formation of the sphenoidal, but furnish a small portion of the maxillary sinuses. The *pterygoids* are strong and quadrilateral. The *turbinals* extend to the anterior nares; they are remarkable for the number of their convolutions, but do not assist in the formation of the frontal and maxillary sinuses.

The *inferior maxilla* is strong, its rami broad and large, presenting a deep depression on the postero-external aspect, in which is inserted the masseter muscle. The condyles are ovoid transversely, and the coronoid processes long and broad, the sigmoid notch very deep, the labial foramen double or triple, and there are no interdental spaces. There is a tubercle at the angle for the insertion of the stylo-maxillaris muscle. The symphysis rarely becomes ossified.

The *hyoid bone* is triple—i.e., its three elements do not unite. It has two cornua and four cornicula, the cornua being united to the temporal bones by elastic ligaments.

#### VERTEBRÆ.

The true vertebral column consists of 27 segments—7 cervical, 13 dorsal, and 7 lumbar. The *cervical vertebrae* in carnivora are proportionally as large as those of the horse. The *atlas* possesses large and expanded alæ; a groove or notch takes the place of the anterior foramen, and the posterior foramen is present; the posterior articulation, instead of being flat, has glenoid cavities, the surface inside the ring, for the odontoid process, being continuous with them. The *axis* is long, its neural spine single and prominent, overlapping and sometimes articulating with the atlas, thereby completely occluding the atlo-axoid space; the odontoid process is long, convex on all its surfaces, pointed anteriorly, and more nearly resembles that of man than does that of any other domestic animal; it serves as a pivot, on which the head and atlas freely

rotate; laterally are the condyles articulating with the glenoid cavities of the atlas. The remaining cervical vertebræ diminish as they proceed backwards, and in most cases have large neural spines, which gradually increase from the third backwards.

The *dorsal vertebræ*, 13 in number, vary with the breed; the pedicles contain large posterior notches in place of foramina. The spinous processes are strong; the four or five anterior ones are equal in height, while the succeeding ones decrease, and incline backwards. There are 7, sometimes 6, strong *lumbar vertebræ*; the bodies are compressed from above downwards, the posterior notches are large, and the neural spines inclined forwards. The transverse processes slope downwards and forwards; the anterior articular processes expand laterally, receiving between them the posterior ones of the contiguous vertebra. These vertebræ possess anapophyses diminishing backwards.

The *sacrum* usually consists of 3 segments, and is frequently as broad behind as in front; the first segment resembles the last lumbar. The sacral spine is thin, and serrated superiorly; the transverse processes are bifid, consisting of upper and lower portions, the upper resembling those of the lumbar region. The *coccygeal* bones vary from 16 to 21, the anterior ones having the characters of true vertebræ.

There are usually 13 pairs of ribs, 9 true and 4 false; their size and curvature vary much, but they are usually somewhat thick and straight. The sternum consists of 8 elongated cylindrical sternibræ, which resemble somewhat in form the terminal coccygeal bones of the horse.

## APPENDICULAR SKELETON.

### PECTORAL LIMB

The *scapula* is very large, the spine being almost central, and terminating inferiorly in an acromion process, which descends close to the glenoid cavity, where it curves backwards. The cartilage of prolongation is wanting. The *humerus* is long, slender, considerably curved, but not much twisted; the external trochanter is well developed, the internal almost wanting; the bicipital groove is single. The condyles are large, and the coronoid and intercondyloid fossæ united, but not always, by a canal which penetrates the bone. In the *Felidæ* there is a supracondyloid foramen, situated above the internal condyle, between the humeral shaft and an outer plate of bone. The *radius* and *ulna* are about equal in volume, the ulna, if anything, being the larger; these bones articulate with each other solely by their extremities, above, by an articular concave facet on the ulna, and a convex one on the radius; below, by a concave facet on the radius and a convex one on the ulna; the two, as it were, cross each other, the upper extremity of the ulna articulating behind and to the inner side, the lower extremity to the outer side.

The bones of the *carpus* are 7. The upper are the scaphoid and lunar united, the cuneiform, and trapezium; the remainder correspond mostly with those of the hog.

There are 5 metacarpal bones, 4 large and 1 small. The digits of the former, homologues of the four fingers of man, have three phalanges each, and two sesamoids, the third sesamoid bone being replaced by a ridge on the third phalanx. The fifth and most internal digit has only two phalanges, the median

phalanx being wanting; it corresponds to the human pollex or thumb. Between each metacarpal bone and its proximal phalanx we have anteriorly a very small sesamoid bone.

#### PELVIS AND PELVIC LIMB.

The pelvic cavity is generally long and narrow, but the ossa innominata are very strong; the iliac spines and crest present a continuous thick rounded ridge. The *ischium* is also thick and strong, the ischiatic spine and tuberosity becoming one tubercle. The cotyloid cavity is surrounded by a prominent border, slightly notched within.

The *femur* is straight and long, presenting a prominent neck, and a muscular line posteriorly, equivalent to the *linea aspera* of man. The supracondyloid fossa is represented by a small tubercle. Above each condyle is a small facet, articulating with a sesamoid bone; these two bones are called the *fabellæ*, or gastrocnemic sesamoids.

The *tibia* and *fibula* are long, and united in the inferior half of their middle by ligaments, at either extremity by articulation; the fibula also articulates with the astragalus, thus supplying the external malleolus to the tibia. There is a small sesamoid bone at the external part of the head of the tibia.

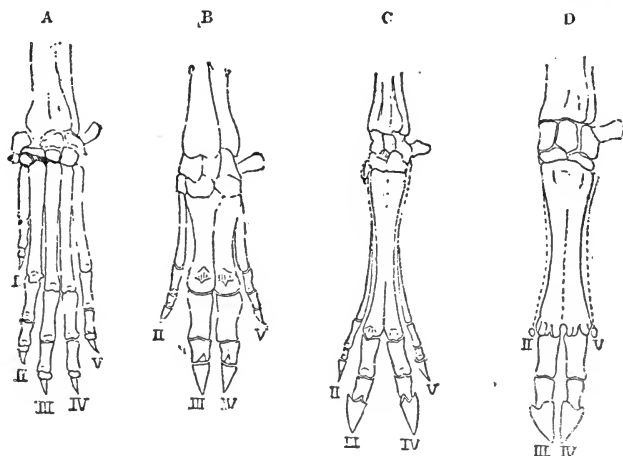


FIG. 32.

A, Hand or Anterior Foot of the Dog; B, That of the Hog; C, That of the Elk; D, That of the Ox. I, Pollex; II, Index; III, Medius; IV, Annulus; V, Minimus.

The *tarsus* consists of 7 bones, as in the hog—viz., the calcaneum, astragalus, cuboid, and four cuneiforms, a superior one corresponding to the magnum of the horse, and three in a row below it, the ecto, meso, and endo-cuneiforms. The astragalus presents distally a distinct head, separated by a neck, which articulates with the cuneiforme magnum.

The *metatarsal* bones are large and 1 rudimentary, the large ones each terminating in three phalanges, with their accessory sesamoids, as in the anterior limb; the fifth, or small rudimentary metatarsal, homologous with the

hallux of man, is very generally only a ligamentous cord, in which is found a short bone, which represents a phalanx.



FIG. 33.

Clavicle of a Dog—enlarged one-half.



FIG. 34.

Clavicle of a Cat—natural size.

#### VISCERAL SKELETON.

In carnivora, generally speaking, there is a *clavicle*, but it is incomplete, and is found embedded in the soft structures between the sternum and shoulder. In the dog it is often represented by a piece of ligamentous tissue, and when it does exist as a bone, it is very small and somewhat triangular in shape.

The Felidæ or cat tribe possess a clavicle which, to a certain extent, resembles in shape that of the human subject, being elongated, rounded, and slightly curved. Occasionally this bone in the cat is continued by ligaments, which unite it both to the sternum and to the acromion process.

#### *Os Penis.*

This is a single bone very generally found in the penis of the carnivora, and always in the dog; in the cat it is said to be less persistent, and when present much smaller. It is a thin piece of bone hollowed to form a longitudinal



FIG. 35.

*Os Penis* of a Dog, half the size of that of a large animal.  
a a, Inferior groove; b, Anterior end; c, Posterior end.

groove, in which the urethra lies; the groove ceases anteriorly, and at this extremity the bone becomes flat and pointed. Both extremities are prolonged by cartilages.

#### RODENTIA.

This large order we have already mentioned as being characterised by its peculiar dentition. One representative of the order is the common Rabbit, which belongs to the family Leporidae.

#### AXIAL SKELETON.

There are 12 dorsal, 7 lumbar, and 4 sacral vertebrae. The wing of the *atlas* presents no foramina externally, but there is a very large notch in its anterior border, inside which is the cerebro-spinal foramen. As in the carnivora, there is no atlo-axoid space. The centra of the *cervical vertebrae* are short, broad, and strong; while those of the dorsal region gradually increase in length backwards. The *lumbar vertebrae* are largely developed,

Their transverse processes, long and slender, being directed downwards and forwards; the articular processes are almost as prominent as the neural spines, the prominent portions being termed the mammillary processes (metapophyses), and they may be traced anteriorly into the dorsal region; they give attachment to portions of the longissimus dorsi muscle. The anterior costal tubercles, prolonged and sharpened, likewise afford attachment to that muscle. The *sternobræ* are five in number, the presternum being very long and cariniform in shape.

In the skull we note the unusual length of the zygomatic process of the malar bone, and absence of a frontal arch, which is represented by a short bifid process. The optic foramina unite to form a single passage leading from one orbital fossa to the other. The *diastema* and incisive openings are both very large, and laterally the *superior maxilla* is incompletely ossified, giving an irregular cribrated appearance to the bone; the bony palate is exceedingly short. The auditory bulla and external meatus are well marked. The long axis of the maxillary condyle is placed longitudinally, and the coronoid process is very small and far below the level of the condyle, while at the angle of the jaw there is a prominent roughened ridge or spine. There are no canine teeth, and two chisel-shaped incisors exist in each jaw; in the upper jaw of the rabbit and hare there are also two very small incisors placed immediately behind the large ones.

#### APPENDICULAR SKELETON.

The *scapula* has a very large acromion process which projects backwards, arching over the postæa-spinatus fossa. There is a small clavicle, but it is incomplete. The coronoid and condyloid fossæ of the *humerus* are connected by a foramen. The *ulna* is complete, reaching to the carpus, but there is no motion between it and the radius, and the extremity is therefore *pronè*. There are five digits, one of which represents the pollex or thumb. The *pelvis* is broad and shallow, the ischial arch deep, and the obturator foramen large. The *femur* has, like that of the horse, a third or minor trochanter; also two well-marked fabellæ. The tibia and fibula are ankylosed, the former bone being very long. The *astragalus* resembles that of the carnivora. There are five digits, including the hallux.

#### AVES.

The scope of the present work will allow only very brief treatment of this part of the subject. We shall, therefore, merely name a few of those features in which the skeleton of the bird differs in a marked manner from the mammalian type.

The vertebræ vary greatly in number, the cervical in some classes numbering over 20, and never less than 8. Small *cervical ribs* exist in the young animal, which in age may become ankylosed to the vertebræ, and in the dorsal region osseous splints unite the successive transverse processes. On the posterior edge of each rib, except the first and last, is a process called the *processus uncinatus*, which overlaps the succeeding rib. The sternum is a single

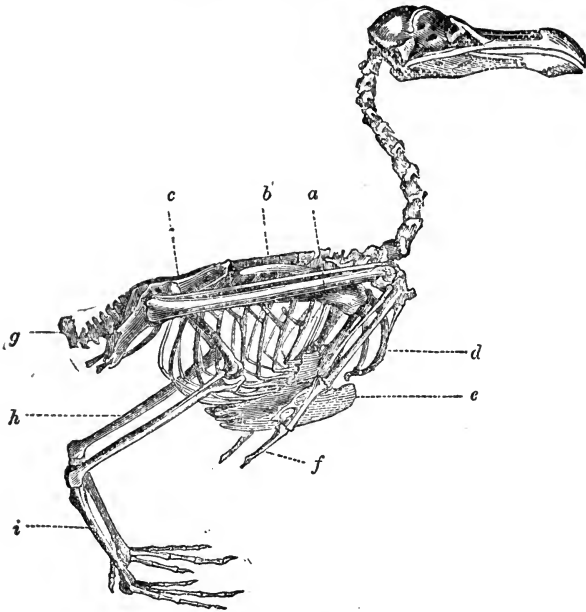


FIG. 36.

Skeleton of a Bird. *a*, Radius and Ulna; *b*, Dorsal vertebræ; *c*, Sacrum and Pelvis; *g*, Ploughshare bone; *h*, Tibia; *i*, Metatarsus; *d*, Furculum; *e*, carina of the Sternum; *f*, Distal phalanx of pectoral limb.

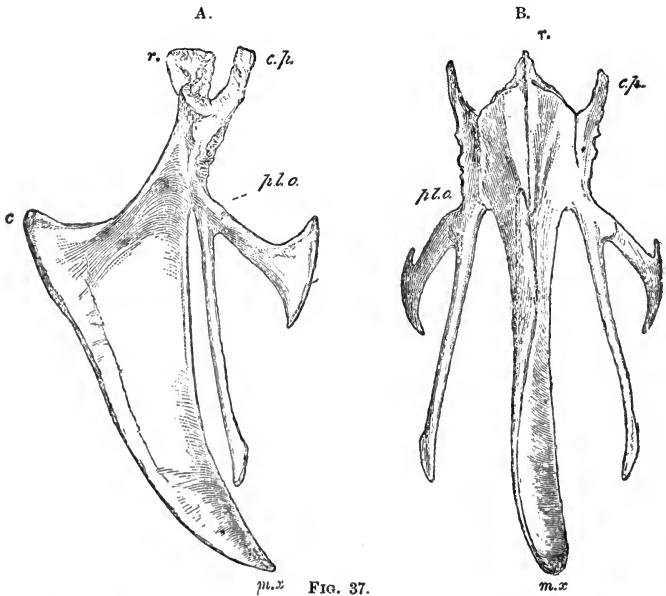


FIG. 37.

Sternum of a Bird. A, Lateral aspect; B, Inferior aspect: *r*, Rostrum; *c.p.*, Costal process; *pl.a.*, Pleurosteon; *c.*, Carina; *m.x.*, Middle Xiphoid process,



bone presenting a very large central process posteriorly, the central xiphoid process (*lophosteon*), outside which is a large bifurcated process (*metosteon*), the two projections of which are called the median and external xiphoid processes, and antero-laterally is the ridge (*pleurosteon*), which gives attachment to the ribs. The inferior edge of the central ridge is called the *carina*; often a small median spine exists anteriorly, the rostrum or presternum.

The following Table shows the number of vertebral segments usually found in domesticated birds:—

	Cervical.	Dorsal.	Lumbo-Sacral.	Coccygeal.
Rasores, . { Pigeon, . . . . . 12 }	7	9	14	7
{ Fowl, . . . . . 14 }				
Natatores, { Duck, . . . . . 15 }	9	9	14	7
{ Goose, . . . . . 18 }				

The costal cartilages are ossified, and thus birds are said to possess *sternal* and *vertebral* ribs. Some of the lumbar and coccygeal vertebræ become ankylosed, and assist in forming the *sacrum*; it is not indeed easy to define the exact points of demarcation between the lumbar, sacral, and coccygeal regions. The coccygeal bones terminate in an expanded segment, termed the

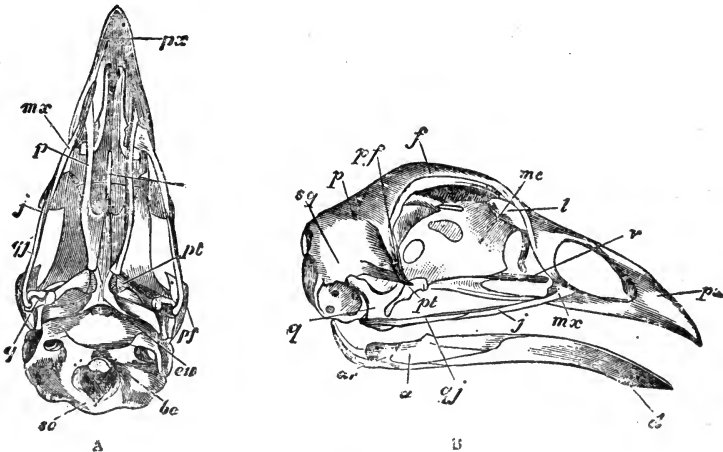


FIG. 38.

Skull of a fowl. A, Inferior aspect, the mandible being removed; B, Lateral aspect; *px*, Premaxilla; *mx*, Superior maxilla; *p*, Palatine bone; *v*, Vomer; *j*, Jugal bone; *qj*, Quadrato-jugal bone; *l*, Lachrymal; *me*, Media ethmoid; *f*, Frontal; *pf*, Post-frontal process; *p*, Parietal; *pt*, Pterygoid; *q*, Os quadratum; *sq*, Squamosal; *eu*, Process before the Eustachian aperture; *bo*, Basi-occipital, and *so*, Supra-occipital bones; *ar*, Articular, *a*, Surangular, and *d*, Dentary portion of the Mandible.

ploughshare bone. In the skull we have to note chiefly the absence of teeth, the existence of *only one* occipital condyle, and the articulation of the mandible or lower jaw, which does not articulate directly with the skull above, but there is interposed the *quadrate bone*, which, when the lower jaw is depressed, acts on a process, the quadrato-jugal bone, connecting it with the maxilla, and so simultaneously raises the upper jaw, there being usually slight vertical motion between the latter and the cranium.

The *pectoral arch* consists of three parts—the scapula, clavicle, and coracoid bone. The scapula is sword-shaped, and placed nearly horizontally; the coracoid bone, the strongest of the three, is almost perpendicular, and firmly attached to the sternum below, affording a strong basis for the bones of the wing to move upon; it helps to form the glenoid cavity for the humerus. The clavicles project downwards and slightly forwards, arching inwards, and generally becoming united below to form a flattened plate, the *hypocleideum*; the united clavicles are termed the *furculum*, familiarly known as the “merry-

thought.” The hypocleideum is usually joined by a ligament to the sternum below; in some classes of birds it is absent; in some the clavicles are not united; in some again they are united by ossification to the sternum. The *ulna* is larger and stronger than the radius; the carpus consists of two bones, the metacarpus of three, one of which is a rudimentary pollex. There are two digits, one of which has one, the other two or three phalanges.

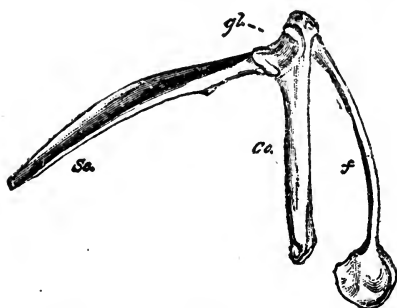


FIG. 39.

Pectoral arch of a Bird. *sc*, Scapula; *co*, coracoid bone; *f*, Clavicles, terminating below in the hypocleideum; *gl*, Glenoid cavity.

The *pelvis* is expanded and shield-like, and consists of the ilium, ischium, and pubis; but there is no inferior symphysis, and, therefore, no *true* pelvic cavity. The pubis is styliform, and directed backwards and inwards; in the ostrich alone it articulates with its fellow. The femur is short, the tibia long, and anchylosed with

The *pelvis* is expanded and shield-like, and consists of the ilium, ischium, and pubis; but there is

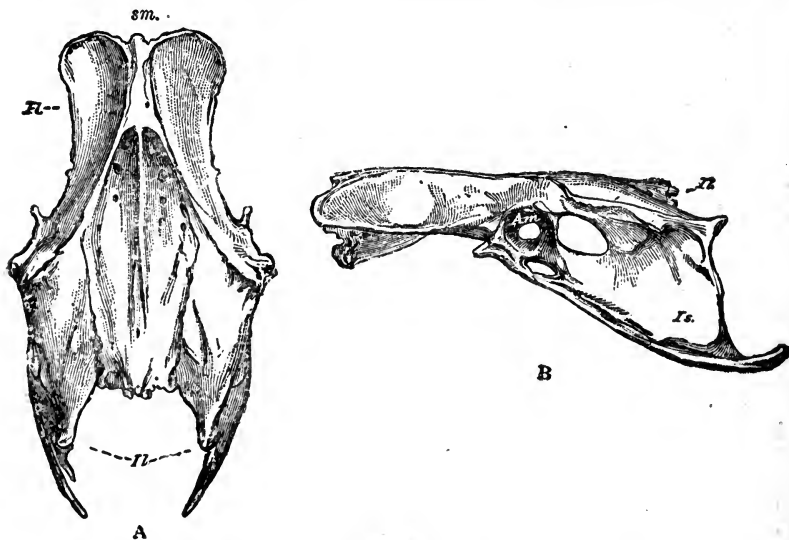


FIG. 40.

Pelvis of a Bird A, Superior; B, Lateral aspect; *sm*, Sacrum; *Il*, Ilium; *Is*, Ischium; *Ac*, Acetabulum.

the fibula, which is small. The tarsus is early fused with the metatarsus, the latter consisting generally of one long bone. The digits vary in number; the domesticated birds usually have three anteriorly and the hallux postero-internally; the outermost has five phalanges, the next four, the next three, while the hallux has only two. The *spur*, a horny projection from the metatarsus, is sometimes counted as a digit.

The bone tissue of birds is exceedingly compact and hard, and white in colour; and some of the bones are *pneumatic*, or contain air instead of marrow; notably these are the bones of the skull, the sternum, and the proximal bones of the limbs. There is great variety in the amount of pneumaticity possessed by the skeleton in different species, but it is not necessarily guided by the *flying* power of the animal.

## CHAPTER II.

### ARTHROLOGY.

THE several bones which form the skeleton are united by means of certain soft structures, forming a series of *articulations* or joints, the study of which is termed Arthrology or Syndesmology.

Before considering the different forms of joints, it will be advisable to describe briefly the various tissues, other than bone, which enter into and contribute towards their formation. These are chiefly cartilage, connective and elastic tissues, and fat.

In health, one bone never comes directly in contact with another, cartilage or fibrous tissue being always interposed; an exception to this exists in the adult skull, most of the bones of which become firmly united by ossification of the interposed soft material.

#### CARTILAGE.

Cartilage, known also by the familiar name of gristle, is a firm, bluish-white, elastic animal substance, somewhat translucent, resilient, and flexible, possessing great cohesive power. That which forms the original basis of the bony framework is termed *temporary*, and that which persists in the adult, *permanent* cartilage; the former disappears as it is replaced by bone, but the latter, of which alone we have to treat here, never under normal circumstances becomes ossified. Cartilage consists of corpuscles or cells, usually imbedded in an intercellular substance or *matrix*. The cells, which are contained in lacunæ in the matrix, are oval, round or fusiform, and nucleated, the *nuclei*, which appear under the microscope as small spots, containing still smaller objects called *nucleoli*. Cartilage when boiled yields chondrine, a substance varying slightly from gelatine.

There are three varieties of the permanent kind—*hyaline*, *fibro*, and *cellular* cartilage. In the first, the matrix is homogeneous, or void of definite structure, appearing slightly granular under

the microscope. Fibro-cartilage is characterised by a matrix of fibrous tissue; while the cellular variety consists of an aggregation of cells without a matrix.

*Hyaline cartilage* is distinguished by the following names, according to the purpose it serves:—*Articular*, when it encrusts the articular surfaces of bones, helping to form joints by supplying a smooth elastic cushion, which diminishes both concussion and friction; *Costal*, when it supplies elastic prolongations (hæmaphyses) to the ribs, connecting them distally with the sternum; *Membraniform*, when it appears as thin plates, forming permanently open tubes,—the trachea or wind-pipe is composed of this kind of cartilage.

In *articular* or encrusting cartilage the matrix is abundant, and the cells vary in form, those near the surface being flatter and more numerous. It is always thickest in the young, becoming thinner as the subjacent ossification proceeds. It is thickest in the centre of convexities, thinnest in the centre of cavities. In the adult it is non-vascular, being nourished by a vascular zone in the synovial membrane, called the *circulus articuli vasculosus*, from which the nutritive material is conveyed. The blood-vessels of the bone underneath the cartilage also assist in supplying nourishment to the latter. All hyaline cartilage, except the articular kind, is covered by a membrane called the *perichondrium*.

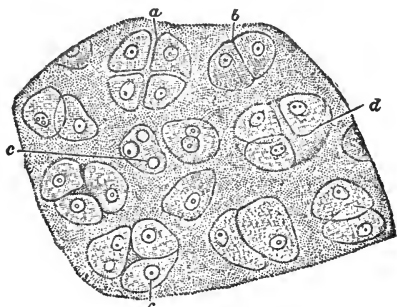


FIG. 41.

Section of hyaline cartilage. *a*, Four separating cells; *b*, Two cells in apposition; *c* *c*, Nuclei; *d*, Cavity in the matrix containing three cells.

*Fibro-cartilage* consists of cartilage cells and fibrous tissue, which may be white or yellow, the former being tough and strong, the latter highly elastic. White fibro-cartilage is much the more plentiful, and presents the following varieties:—It is called *Inter-articular* when it appears as a pad interposed between the two articular cartilages which form a joint; such a pad is termed a *meniscus*, and the temporo-maxillary and femoro-tibial joints are furnished with such. *Circumferential*, where it surrounds and deepens an articular cavity, as the acetabulum. *Connecting*, when it is interposed between bones and firmly connects them, as

between the vertebral centra. *Stratiform* or *Investing*, when it clothes the parts of bones over which the tendons of muscles play, sometimes existing in the tendons themselves.

This tissue is dullish white, opaque, and, for the most part, devoid of perichondrium; it is vascular, but its blood-vessels are few, and confined to the fibrous tissue, which exists as interwoven bundles of fibres, with cartilage cells interspersed amongst them. In the variety connecting vertebræ, it consists of concentric rings of fibrous tissue, enclosing a soft elastic centre, partly made up of cartilage cells, and often regarded as the remnant of the notochord. In fishes this portion is soft and pulpy, filling the opposing concavities of the vertebral centra. Its power of cohesion is very great, surpassing even that of bone.

*Yellow elastic fibro-cartilage* is found in the epiglottis or valve which closes the principal air-tube; it forms part of the framework of the ear, and of the Eustachian tubes which convey air to the tympanum. The fibres forming the matrix are similar to those of yellow elastic tissue.

*Cellular* or *reticular cartilage* is found in the ear of some small rodents, and in the bat. It consists of cells densely packed, and apparently without a matrix: the walls of the cells thus coming into contact, give it a net-like appearance, hence the name *reticular* cartilage.

#### CONNECTIVE TISSUE.

In one form or other this tissue is found in all parts of the body. The chief varieties are the areolar and the fibrous; the former serving as a connecting medium, and support to the various organs, and to the structures of which they are formed. It appears as a loose translucent mesh, its interwoven bundles forming spaces termed the areolæ or cells, hence its name *Cellular* or *Areolar* Tissue. It consists of minute laminæ and filaments mixed with small fibres of elastic tissue, while cells, or their remains, nuclei and walls, are also present, the whole embedded in a perfectly transparent basis. Other slightly varying forms are termed *Retiform*, *Gelatinous*, &c., while the connective tissue of the brain and retina has received the name of *Neuroglia*.

*White fibrous tissue* has a similar structure to the above, but is dense, strong, and practically non-elastic. The filaments which form it are mostly parallel and wavy in their arrangement. It

appears in two forms—the *sheeted* or aponeurotic, which is found in investing ligaments, membranes, periosteum, &c. ; and the cordiform, in which the fibres are collected in strong bundles; this is the chief constituent of the *binding* ligaments, which hold articulating bones together and limit their motion. The tendons of muscles are also made up mostly of this kind of tissue, but both in them and in ligaments yellow elastic fibres are also found.

Connective tissue contains nerves and blood-vessels, for the supply of neighbouring structures as well as for its own nourishment, and also tendon cells, the latter lying in the spaces between the smaller bundles. When healthy this tissue is little sensitive to pain.

#### YELLOW ELASTIC TISSUE.

This differs from the white tissue in being yellow, elastic, and not so tough or strong. Its fibres are sometimes as large in diameter as  $\frac{1}{1000}$  in.; but when mixed with white tissue in tendons the diameter may not be more than one-sixth of this. The fibres branch and join each other, and their ends curl up when cut or broken. Acetic acid has no effect on the yellow tissue, while it causes fibres of the white to swell greatly and become quite transparent; again, when white tissue is boiled gelatine is obtained, which is not the result of boiling the yellow fibres.

Yellow elastic tissue is found nearly pure in the ligamentum nuchæ, the tunica abdominis, the coats of the largest arteries, and elsewhere. The lungs contain a large quantity of this tissue.

#### ADIPOSE TISSUE.

Fat or adipose tissue consists of cells containing an oily material, and arranged in isolated groups, or slightly separated by meshes

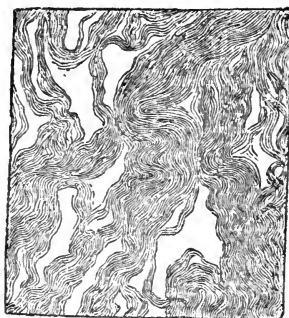

FIG. 42.

White fibrous tissue from a ligament.  
65 diamrs.



FIG. 43.

Yellow elastic tissue, magnified, from the ligamentum nuchæ of a calf. 65 diamrs.

of areolar tissue and capillary blood-vessels. It is found in many parts of the body, and varies greatly in quantity; in joints it occurs between the ligaments, and serves the purpose of a packing material, while in the form of medulla or marrow it occupies the cavities of bones. In fat cells a nucleus is rarely visible, without special preparation.

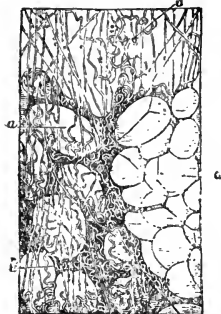


FIG. 44.

Adipose tissue magnified.  
*a a*, Fat cells—those on the right in mass; those on the left spread amongst the connective tissue fibres *b b*.

enclosing true joints. They consist of a dense interlacement of fibres attached to bones, round the edges of the articular cartilages, partially or wholly surrounding the joint; some regard them as a continuation of the periosteum. They are never closely applied, their use being to form cavities round the joints, enclosing and protecting the synovial or lubricating apparatus inside.

*Funicular* or *binding* ligaments consist of rounded or flattened cords, or bands of fibrous tissue, passing from one bone to another, firmly attached to roughened portions of their surfaces. They hold the bones in their places, at the same time allowing the requisite amount of motion in the joints. Ligaments which are situated between bones are often termed *interossecus*. Annular ligaments are those which bind down and protect the tendons of muscles in certain joints, converting grooves in the bones into channels or tubes which are lined with synovial membrane, and through which the tendons play.

Some ligaments are composed almost entirely of *yellow elastic tissue*, such as the ligamentum nuchæ and the ligaments connecting the vertebral arches.

#### SYNOVIAL MEMBRANES.

These are thin membranes lining the capsular or binding ligaments of true joints, or they are interposed elsewhere



between structures which move one upon another, and which would otherwise be injured by the friction. They resemble what are termed *serous* membranes, in lining closed cavities, and in containing a layer of endothelial cells which secrete a lubricating fluid, called *synovia* or joint-oil; the foundation of these membranes is a layer of connective tissue, which varies considerably both in density and thickness.

The synovial membrane terminates at the border of the articular cartilage, which in the adult it never covers; in the fœtus it is said by some authorities that it covers the cartilage also. Near the borders of articular cartilages the membrane is generally found as a projecting fold, the projection being due to a small pad of fat, interposed between the membrane and the capsular ligament. These projections were once erroneously termed synovial glands, but their use is probably to assist in forcing the synovia between the opposing surfaces of cartilage.

Under the cellular layer blood-vessels are found, and near the articular cartilage there is formed a vascular zone, the *circulus articuli vasculosus*, in which the capillaries terminate by dilated loops; articular cartilage derives its nourishment partly from this source (see page 121).

There are three forms of these membranes:—the *capsular*, which line the capsular ligaments of all true joints; *bursal* membranes, found where one structure moves upon another, as when a tendon plays over a bone, and known as *synovial bursæ*; or, when they exist in the subcutaneous tissue, between the skin and certain prominent parts of the skeleton, they are known as *bursæ mucosæ*. The third form, *vaginal membranes* or sheaths, exist where one tendon forms a sheath for another, or in other canals through which tendons glide.

*Synovia*, or joint oil, is a viscid, transparent fluid, colourless, or pale yellow, physically resembling oil, but it contains very little fatty material, consisting chiefly of albumen, salts, and water; it is secreted by the cells on the inner surface of the membrane. When an animal is in active exertion, there is a greater demand for joint oil than when at rest, consequently there is an increased secretion of it.

#### CLASSES OF JOINTS.

Joints may be divided into three classes—*Immovable* or *Synarthrodial*, *Movable* or *Diarthrodial*, and *Mixed* or *Amphiarthrodial*.

## SYNARTHROSIS.

In an immovable joint there is only a thin layer of fibrous or cartilaginous material interposed between the bones, the fibrous layer of the periosteum of both bones uniting to cover and become attached to the connecting material. thus serving as a ligament. If the connection is fibrous, the joint is generally called a suture; if cartilaginous, a synchondrosis. These joints are found chiefly, but by no means solely, in the skull: and they tend to become obliterated, in the adult, by ossification of the connecting material. The varieties of synarthrosis are the *sutura synchondrosis*, *schindylesis*, and *gomphosis*.

Sutures are true or false. In the *sutura vera* or *true* suture, the contiguous margins are united by a series of interlocking processes and indentations, a thin fibrous layer being interposed, connected externally with the periosteum. Variety of shape has led to the following nomenclature:—*sutura dentata*, where the processes are large and tooth-like, as in the interparietal; *sutura serrata*, where they are small and fine, like the teeth of a saw, as in the interfrontal; and *sutura limbosa*, where the contiguous parts are dentated and also bevelled, as in the parieto-occipital—the *sutura lambdoidalis* of the human subject.

In the *false* sutures, or *sutura notha*, the bones are joined by plain rough surfaces, of which there are two forms—*sutura squamosa*, where the adjacent borders are bevelled, the edge of one bone resting on and overlapping the other, as in the parieto-temporal; and *sutura harmonia*, where the articulating surfaces of two bones present no marked irregularity, as the nasal and premaxilla.

*Synchondrosis*, as already stated, resembles a suture, but the connecting medium is cartilage instead of fibrous tissue; examples are found in the joints between the basi-occipital and basi-sphenoid bones, and between the latter and the pre-sphenoid.

*Schindylesis* is that form of immovable articulation, where a ridge or plate of one bone is received into a slit or fissure in another, as the orbito-sphenoid into the incisura sphenoidalis of the frontal bone.

*Gomphosis* is the form where one bone is inserted in a cavity or socket in another, as the teeth in the alveoli.

## DIARTHROSIS.

In movable or *true* joints the articular surface of each bone is covered by cartilage of encrustation; the bones are held together by ligaments, the capsular one closing the cavity of the joint, which is lined by synovial membrane. In some joints there is a pad of fibro-cartilage interposed between the two articular cartilages. Such a pad is called a *meniscus*, and it adds to the elasticity and freedom of the joint. Movable joints form the most numerous class; they are found in the limbs and elsewhere. The chief varieties are the *arthrodia*, *enarthrosis*, and the *ginglymus*.

In *Arthrodia* the motion is slight and gliding, the bony surfaces being flat or slightly undulating, and the motion limited by ligaments or processes of bone, as in the small bones of the carpus and tarsus. *Enarthrosis*, the ball-and-socket joint, is capable of moving in any direction; the extremity of one bone is globular, and fits into a cup-shaped concavity in another bone; the hip and shoulder joints are examples. The *Ginglymus*, or hinge joint, although it may allow extensive motion, limits it to one plane, backwards and forwards, as in the elbow. A *Rotatory* joint (diarthrosis rotatorius), where the motion is limited to rotation, is formed by a pivot on one bone fitting into a ring on another, as the atlo-axoid joint.

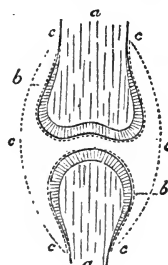


FIG. 45.

Diagram of a diarthrodial joint. *a a*, Articulating bones; *c c c*, Synovial membrane. The shaded portions represent the articular cartilages, which are said by some to be covered in early fetal life by the inflected continuations (*b b*) of the synovial membrane.

## AMPHIARTHROSIS.

There is but one kind of *amphiarthrosis* or mixed joint; the variations are too slight to warrant separation into classes.

The term *mixed* is used with reference, not to the motion in such joints, but to their structure, which partakes of the nature of both the movable and immovable, the bones being firmly *joined together* by a strong interposed pad of fibro-cartilage, which is likewise adherent to the ligaments of the joint. There are no capsular ligaments; the cartilaginous pad or *disc* is softer towards the centre, where occasionally

there may be one, or even two, narrow cavities, and authorities differ as to whether such cavities are lined by synovial membrane or not. Since there are really no frictional surfaces in such a joint, motion depends upon the flexibility of the disc. The joints between the vertebral centra afford the best illustration of the mixed class.

The classification of the joints is here tabulated for reference.

Synarthrosis (Immovable).	{	Sutura.	{	Vera.	{	Dentata. Serrata. Limbosa.
				Notha.	{	Squamosa. Harmonia.
		Synchondrosis. Schindylisis. Gomphosis.				

Diarthrosis (Movable).	{	Arthrodia. Enarthrosis. Ginglymus. Diarthrosis rotatorius.
---------------------------	---	---

Amphiarthrosis  
(Mixed).

#### MOTION IN JOINTS.

The following terms express the various movements allowed by joints:—*extension* tends to bring two bones as nearly into a straight line as the structure of the joint will permit; *flexion* is the reverse of this, and diminishes the angle that extension increases; *abduction* expresses the outward movement of a limb or bone from the central plane of the body; *adduction* is the reverse action; *rotation* signifies the partial revolution of a bone or number of bones, as it were, on their own axis; *circumduction* implies the movement of the distal end of a bone or limb, when it describes a curve, as the arc of a circle, ellipse, &c. The term *gliding* explains itself, and is peculiar to diarthroses, other joints having no frictional surfaces.

## ARTICULATIONS OF THE AXIAL SKELETON.

## COMMON VERTEBRAL ARTICULATIONS.

With the exception of the atlas and dentata, which form *special* joints, the true *Vertebræ* present great uniformity in their mode of union, articulating with each other by an amphiarthrosis, which unites their centra, and by a pair of true joints formed by the oblique processes. These connections are completed or strengthened by ligaments, some of which are *common*, others *special*, the former are continuous, passing over and uniting many *vertebræ*, while the latter exist separately between the contiguous segments.

The bodies are united by *intervertebral discs* of fibro-cartilage, convex in front, and concave behind, firmly fixed to the articular surfaces of the centra. The discs consist of *laminæ* arranged concentrically, with fibres crossing among themselves, and passing from one articular surface to the other. The central portion is yellowish, presenting more the character of true cartilage, and towards the circumference the *laminæ* become denser. The discs do not exist between the first and second cervical joints; they are thick in the neck, and thinner in the dorsal region, where they assist in forming sockets for the heads of the ribs. The lumbo-sacral disc is very thick.

*Common Ligaments.*

These are the Superior and Inferior Common, and the Supraspinous ligaments, the latter in the cervical region being termed the *Ligamentum Nuchæ*.

The *superior common* ligament is ribbon-like in form, extending in the spinal canal from the sacrum to the axis, placed upon the superior part of the bodies of the *vertebræ*, to which, as well as to the *intervertebral substances*, it is attached, becoming broader at each of the latter attachments.

The *inferior common* ligament, situated below the vertebral bodies, stretches from the sacrum only to the sixth dorsal vertebra, anterior to which its place is taken by a muscle called the *longus colli*. It is strongest in the posterior part of the dorsal and in the lumbar regions, and broadest on the *intervertebral substances*.

Posteriorly the *supraspinous ligament* is a white fibrous cord, extending from the spine of the sacrum, along the upper margin of the neural spines to the first dorsal vertebræ, where its character becomes so greatly changed that the cervical portion may be, and often is, described as a separate structure—the *ligamentum nuchæ* or *ligamentum colli* (Pl. I. *f f'*); it is formed of yellow elastic tissue, and remarkable for its strength, elasticity, and insensibility to pain. It consists of a funicular and a lamellar portion; the former, called also the cord of the ligament, is double, and extends from the first, second, and third dorsal spines to the occipital tuberosity, continuous posteriorly with the white supraspinous ligament, in which elastic tissue may be traced to some distance. The right and left ligaments meet in the mesian line, and from the postero-inferior aspect springs the lamellar portion, which is flat and triangular, separating the muscles of the neck into right and left. It consists of two plates, joined by cellular tissue; the lamellæ or bands descending from the cord and spinous processes usually of the first three dorsal vertebræ, run obliquely forwards, to be inserted to the superior spines of the six posterior cervical vertebræ, blending with the interspinous ligaments. The lamellæ although widely separate, are connected by smaller branches, and also by connective tissue. This ligament being highly elastic, is not a binding ligament, but acts as a *passive* support to the head and neck, diminishing the muscular tension in the superior cervical region.

#### *Special Ligaments.*

The special ligaments of a common vertebral articulation are the *interspinous*, the *ligamenta subflava*, the *intertransverse*, and the *capsular*. The *interspinous* ligaments connect the neural spines, and are continuous with the supraspinous ligament above; they are composed of yellow elastic tissue in the cervical region, elsewhere of white fibrous tissue. The *ligamenta subflava*, or *ligaments of the arches*, connect the laminæ of the articulating vertebræ; they may be regarded as bifurcations of the interspinous ligaments, and their regional structure varies like that of the latter. The *intertransverse* ligaments are found between the transverse processes, and are strongest in the lumbar region; these ligaments are well marked only in the solipede (Fig. 60. *a*). The *capsular ligaments* invest the articulations of the oblique processes, forming true synovial joints.

## SPECIAL VERTEBRAL ARTICULATIONS.

*Occipito-atloid Articulation.*—This joint is formed by the occipital condyles and the glenoid cavities of the atlas, and possesses five ligaments—one *capsular*, two *lateral* or *styloid*, *superior suspensory*, *inferior suspensory*. This joint is a true one, having two *synovial membranes*—one for each condyle. The *styloid ligaments* pass from the base of the occipital styloid processes to the sides of the atlas. The *superior suspensory* or *occipito-atloid* is very broad, and consists of fibres, which cross each other, extending from the superior margin of the foramen magnum to the notch on the anterior border of the atlas. The *inferior suspensory* or *occipito-atloid* stretches from a notch on

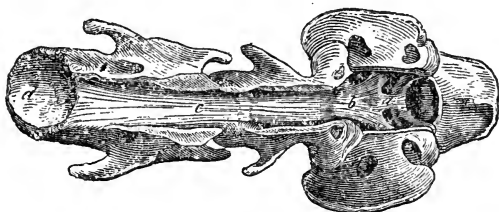


FIG. 46.

Neural canal of first three cervical vertebrae, opened from above to show the internal ligaments. The occiput and foramen magnum are seen to the right. *b*, The odontoid ligament; *a*, The occipito-atloid portion (long odontoid); *c*, Superior common ligament; *d*, Posterior articular cavity of a vertebral centrum.

the antero-inferior part of the atlas to the inferior margin of the foramen magnum; it is thin and membranous. The capsular ligament passing completely round the joint, becomes blended with the other ligaments. The latter are sometimes considered as mere enlargements or strengthenings of the capsular ligament, which, this view being taken, would then become the only ligament of the joint. This joint allows of flexion, extension, circumduction, and lateral motion.

*Atlo-axoid Articulation.*—This joint is formed by the opposing articular surfaces of the atlas and axis, and is also a true joint. The atlo-axoid ligaments are the *capsular*, the *superior*, the *inferior*, and the *odontoid*. The *capsular* is very broad superiorly, where it closes the atlo-axoid space. The *superior ligament* passes from the supero-posterior part of the ring of the atlas to the neural spine of the dentata. The *inferior* joins the inferior spines of the two bones. The *odontoid* springs

from the superior part of the odontoid process, inside the ring of the atlas and may be regarded as a continuation of the superior common ligament; it divides into two strong bands, which become attached on either side to roughened surfaces inside the neural canal of the atlas. This portion is sometimes called the *short* odontoid, while the *long* odontoid consists of smaller bands which pass forwards and are attached inside the foramen magnum of the occipital bone; the latter ligament is also called the occipito-axoid. The motion of this joint is purely rotatory, being in fact the rotatory joint of the head; or, in other words, when the head rotates the atlas moves with it.

*Sacro-lumbar Articulation.*—This is formed by the last lumbar and first sacral vertebræ. There are the usual typical articulations between the centra and zygapophyses, and in addition a pair of diarthroses formed by the facets on the transverse processes, which exist and form joints also between the fifth and sixth lumbar vertebræ (Fig. 60). The usual vertebral ligaments are found, with the addition of a pair of capsular ones for the transverse joints.

*Coccygeal Articulations.*—These are of the typical form, but become more and more rudimentary as the bones lose more and more the true vertebral character, the discs are formed, but the ligaments become gradually blended, finally enveloping the bones in a fibrous sheath.

### THORACIC ARTICULATIONS.

The thoracic skeleton contains the articulations which unite the dorsal vertebræ to one another and to the ribs, those which connect the ribs and costal cartilages, those joining the latter to the sternum, and finally, those which connect the sternal segments. We have already described the vertebral joints.

*Costo-vertebral Articulation.*—A diarthrodial connection is here formed by the head and tubercle of a rib, the juxtaposed facets on the bodies of two dorsal vertebræ, and the transverse process of the posterior one. The ligaments are as follows:—The *stellate* or *radiating* ligament is situated inferiorly, and consists of strong fibres, divided into three fasciculi, uniting the head of the rib, one to the vertebra in front, a second to the intervertebral disc, while the third passes to the posterior vertebra; the *interarticular* or *round* ligament passes from the



ridge on the head of one rib through the articulation, giving a slip to the intervertebral disc, and is attached to the fellow rib on the opposite side; the head of the rib is thus divided into two distinct articulations, with *capsular* ligaments and synovial sacs. Superiorly the *anterior costo-transverse* unites the neck of the rib to the infero-anterior part of the vertebral transverse process, while the *posterior costo-transverse* passes from the supero-posterior part of the tubercle to the lateral part of the transverse process. One *capsular ligament* unites the tubercle and transverse process, enclosing a synovial sac.

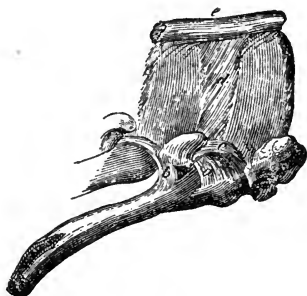


FIG. 47.

Costo-vertebral articulation, right lateral aspect. *a*, Anterior, and *b*, Posterior costo-transverse ligaments; *c*, Ligamentum subflavum; *d*, Interspinal, and *e*, Supra-spinal ligaments.

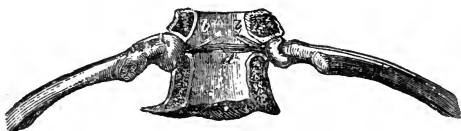

FIG. 48.

Costo-vertebral articulation. Neural canal opened from above, and superior common ligament removed. *a*, Interarticular ligament; *b b*, Branches joining the disc.

*Chondro-costal Articulation.*—This is a fixed joint between the rib and its cartilage; each rib is cupped on its lower extremity, the convexity of the cartilage resting in it, and the joint, a gomphosis, is clothed around with strong fibrous tissue.

*Costo-sternal Articulation.*—This joint is formed by two sternal segments and a true costal cartilage. The first cartilage, however, articulates with the presternum only, and the last only with the last sternal segment. The ligaments are the *capsular* and the *superior* and *inferior costo-sternal*, which stretch from the costal cartilages to the sternum above and below, blending with the capsular ligament.

The asternal or false cartilages are united, each free extremity becoming attached to the cartilage in front by a small elastic ligament. The first asternal cartilage is very firmly attached to the last sternal one; a small ligament, the *chondro-xiphoid*, is also described, which connects the xiphoid and first asternal cartilages.

The first pair of costo-sternal joints which are close together usually have a common capsular ligament.

*Sternal Articulations.*—These bind together the sternal segments. The ligaments in the horse are the *superior sternal*, extending along the upper surface of the bones, and the intervening *fibro-cartilages* which eventually ossify.

The cartilaginous appendages of the sternum are the *cariniform* and *xiphoid* cartilages. In the horse the former appears as a sharp ridge running from above and before the presternum, down the lower mesian line of the anterior sternal segments. Its shape bears a marked resemblance to the keel and cut-water of a boat, hence its name. The xiphoid is a flat ovoid plate of cartilage attached to the posterior segment of the meso-sternum; unlike the cariniform, its sharp edge is placed transversely. It is also called the *ensiform* cartilage.

#### ARTICULATIONS OF THE SKULL.

These are all synarthrodial, excepting the temporo-maxillary joints and those between the hyoid bone and its appendages. Collectively, the remaining joints are called the sutures of the skull, and some of these have received special names.

#### SUTURES.

The straight median suture extending from the occipital crest to the nasal peak is the *longitudinal* one, subdivided into the *nasal* portion, which is open at the apex, the *frontal*, and the *sagittal*, the latter situated between the parietal bones, while joining the nasal and lachrymal bones to the frontal is the *transverse* suture. The *coronal* suture extends obliquely upwards and backwards from the temporal fossa, between the frontal and parietal bones, while the *sutura limbosa* runs upwards between the parietal and occipital bones, reaching from the temporal bone to the sagittal suture. For structure of sutures see page 126.

#### TEMPORO-MAXILLARY JOINT.

This articulation is a diarthrosis, and it is furnished with *capsular*, *external lateral*, and *posterior* ligaments, and also with a *meniscus* or interarticular disc of cartilage. The joint

is formed by the condyle of the inferior maxilla, and the condyle and glenoid cavity of the temporal bone. The *meniscus* is irregular and flattened from above downwards, the superior surface being concavo-convex to correspond with the condyle and glenoid cavity above; its inferior surface being concave for the reception of the maxillary condyle. The *capsular* ligament is attached to the circumference of the meniscus, so forming two synovial cavities. The *posterior* ligament runs from the mastoid process, and the *external lateral* one from the zygomatic arch of the temporal bone, both going to the neck of the maxilla; both are mere thickenings of the capsular ligament. This joint admits of lateral motion, extension, flexion, and in the herbivora elevation and depression.

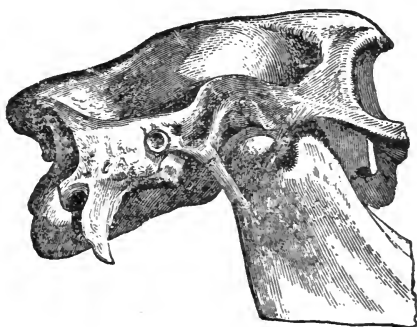


FIG. 49.

Right temporo-maxillary articulation—external view. *a*, The meniscus; *b*, External lateral, and *c*, Posterior ligaments.

## ARTICULATIONS OF THE HYOID SERIES.

The *Hyoid articulations* are as follows. The *temporo-hyoid* articulation is amphiarthrodial, the superior angle of

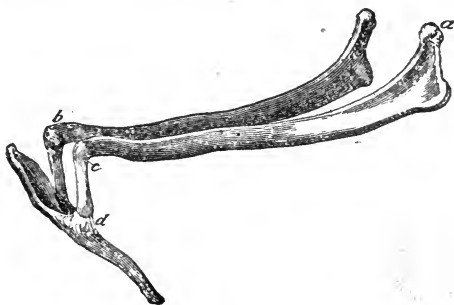


FIG. 50.

Hyoid articulations. *a*, Point going to form the temporo-hyoid articulation; *b*, Rudimentary second corniculum; *c*, Proximal, and *d*, Distal interhyoid articulations.

the cornu articulating with the hyoid process of the petrosal

bone by a piece of fibro-cartilage. The *proximal interhyoid* articulation is also amphiarthrodial, a similar cartilage joining the cornu and corniculum; the latter articulates with the hyoid bone by a true synovial joint, the *distal interhyoid*.

In the proximal interhyoid cartilage a small ossicle may be found, which in ruminants appears as a second corniculum. The motion in the two first-named joints is considerable. We may mention here that the heel processes are attached at their ends to the thyroid cartilage of the larynx by the lateral hyo-thyroid ligaments, between which is found the middle ligament (see "Laryngeal Ligaments").

## ARTICULATIONS OF THE APPENDICULAR SKELETON.

### PECTORAL LIMB.

#### THE SHOULDER JOINT.

The *Scapulo-humeral articulation* is formed by the glenoid cavity of the scapula, and the articular head of the humerus. It is a ball-and-socket joint, with one strong *capsular ligament*. The bones are held in position by the following muscles which pass from the shoulder-blade to the arm, and play the part of active ligaments:—The *antea spinatus*, *postea spinatus*, *postea spinatus minor*, *subscapularis*, and *flexor brachii*. The motion of the joint is angular, lateral, and circumductive.

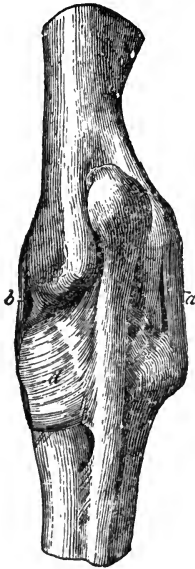


FIG. 51.

Ligaments of the elbow joint — posterior view. *a*, External lateral ligament; *b*, Internal lateral ligament; *c*, External, and *d*, Internal arciform ligaments.

#### THE ELBOW JOINT.

The *Humero-radio-ulnar* is a ginglymus formed by the radius, ulna, and humerus. It has capsular and lateral ligaments. The *capsular* is strongest in front, where it stretches from the distal end of the humerus to the head of the radius; posteriorly it encloses the articulation of the ulna with the humerus, and it also surrounds the double articulation between the head of the ulna and the radius. Anteriorly it is attached to the tendon of the *flexor brachii*, posteriorly to that of the *anconeus*.

muscle. The *internal lateral* ligament is crucial, longer but less strong than the external; it stretches from a small tuberosity on the inner side of the internal condyle of the humerus to the head of the radius. The *external lateral* ligament, crucial, short and thick, passes from a ridge on the epitrochlea, and a cavity on its outside, to a tuberosity outside the head of the radius. The joint possesses flexion and extension only.

#### RADIO-ULNAR JOINT.

This articulation, small and very firm, is formed by the articular surfaces of the radius and ulna, and consists of two true and two mixed joints. The *arciform* or superior radiating ligaments are attached on both sides to the superior part of the ulna and radius. They are curved, and blend with the lateral ligaments of the elbow. Below the radio-ulnar arch are a few fibres, which constitute the *inferior radiating* ligament. The surfaces above and beneath the radio-ulnar arch are joined by the *interosseous* ligaments, which ossify early in life. The motion is practically nil.

#### THE CARPUS.

The ligaments of this, joint or rather group of joints, are special and common. The articulations between the bones of the upper row may be termed the *superior carpal*; those between the bones of the lower row the *inferior carpal*; between the radius and the upper row we have the *radio-carpal*; between the upper and lower rows the *inter-carpal*; and between the lower row and the metacarpus the *carpo-metacarpal*.

#### *Special Ligaments.*

*Superior Carpal Ligaments.*—The four bones of the *upper row* are held together by *three anterior* and *three interosseous* ligaments. The *anterior* are flat bands placed one between each pair of bones; and the two inner ones are covered by and

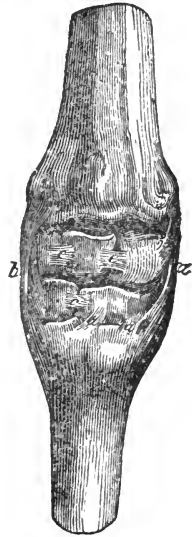

Fig. 52.

Ligaments of the carpus—*anterior aspect*. *a*, Internal lateral ligament; *b*, External lateral ligament; *c c*, Anterior carpal ligaments; *d d*, Anterior carpo-metacarpal ligaments.

attached to the capsular ligament; the third, the median trapezial, is covered by the external lateral ligament. The *interossei* are attached to the roughened grooves between the articular facets on the lateral surfaces of the scaphoid, lunar, and cuneiform bones. The two inner are blended with the anterior, while the external one is covered by the posterior common ligament.

*Inferior Carpal.*—The bones of the *lower row* are held together by *four ligaments*, *two anterior* and *two interosseous*. The *anterior* are covered, the internal one by the internal lateral, the other by the capsular ligament. The *interossei* are two; the one joining the magnum to the trapezoid is blended with the anterior ligament, but the other is separated from the corresponding anterior one by an articular facet.

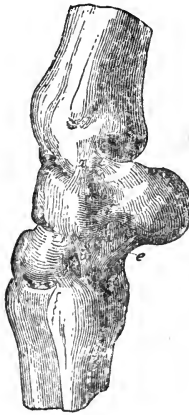

FIG. 53.

Deep ligaments of the carpus -- external view. *a* and *b*, Deep portions of the external lateral ligament; *c*, Superior, *d*, Median and *e*, Inferior trapezial ligaments.

*Radio-carpal.*—The special ligaments joining the radius to the upper row are *three* in number. The *oblique* one stretching obliquely from the lower extremity of the radius, under the posterior common ligament, to the scaphoid bone. A second small one, the *superior trapezial*, stretches from the external side of the inferior extremity of the radius to the superior border of the trapezium, partly covered by the external lateral ligament. A third, the smallest of all, is buried under the former, and stretches from the inferior part of the radius to the os lunare.

*Intercarpal.*—There are *three special ligaments*; two are short, and situated under the posterior common ligaments. The first runs vertically from the scaphoid to the magnum and trapezoid, the second passes obliquely from the cuneiform to the magnum; while the third, the *inferior trapezial*, by far the strongest, stretches from the trapezium to the unciform and head of the external splint bone, blending externally with the lateral, internally with the posterior common ligaments.

*Carpo-metacarpal.*—This joint has the following special ligaments:—*two anterior*, *two posterior*, and *two interosseous*. The *first anterior* consists of two bundles uniting the os magnum to the large metacarpal bone. The *second anterior*

binds the unciform to the external splint bone. The *two posterior* bind the magnum and trapezoid to the large and inner metacarpal bones. The *interossei* unite the heads of the splint bones to the large metacarpal and bones of the lower row.

### Common Ligaments.

The *Common Ligaments* are the *external and internal lateral*, and the *anterior and posterior common*, or *capsular*.

The *internal lateral* ligament, stronger than the external one, is slightly crucial, consisting of two bundles of fibres which cross each other; both spring from the internal side of the inferior extremity of the radius; the superficial bundle goes to the os magnum and large metacarpal, and the deep set to the scaphoid, trapezoid, and inner splint bones. A part of this ligament, deep-seated also, joins the scaphoid and small metacarpal bones.

The *external lateral* ligament also consists of two fasciculi, springing from the external side of the distal end of the radius; the superficial fibres are attached to the external splint, the deep to the same, and also to the cuneiform and unciform bones.

The *anterior common* or *capsular ligament* is membranous, covering the anterior portion of the carpus. This ligament is attached to the radius, the head of the large metacarpal bone, the lateral ligaments, and to the carpal bones and their anterior ligaments. The annular ligaments are thickenings of this structure, which bind down the extensor tendons. The inner surface is smooth, and lined by synovial membrane. The *posterior common* ligament is one of the *strongest in the body*, and covers the posterior surface of the carpus, filling up the depressions. It passes from the distal end of the radius to the head of the large metacarpal bone, adhering to the internal lateral, median,

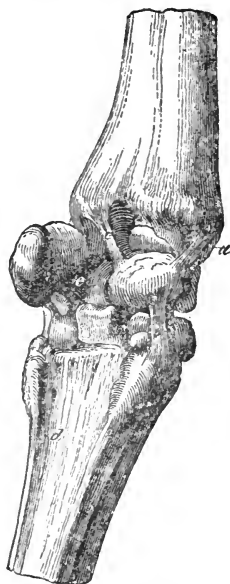

FIG. 54.

Ligaments of the carpus — postero-internal view. *a b*, Deep portions of internal lateral ligament; *c*, Oblique ligament; *d*, Interosseous metacarpal ligament; *e*, External interosseous ligament of the upper row.

and inferior trapezial ligaments. Its anterior surface is attached to the two rows of bones, while its posterior is smooth, for the passage of the great flexor tendons; the inferior carpal or *check* ligament is continuous with it. A ligamentous structure passes obliquely downwards from the posterior border of the trapezium to the large and inner metacarpal bones, completing the carpal groove or sheath for the flexor tendons; this is the posterior or investing *annular* ligament. The *carpal* or *check ligaments*, superior and inferior, will be alluded to in describing the muscles of this region.




FIG. 55.

Superficial ligaments of the carpus—posterior view. *a*, Posterior annular ligament; *b* *b*, Posterior common ligament.

The *synovial capsules* are four, perhaps five—two small and three large. Of the latter, one is for the radius and the upper row, extending between the bones as far as the interossei; another is situated between the upper and lower rows, and a third between the lower row and metacarpus, dipping between its large and small bones. There is usually a separate synovial capsule between the trapezium and cuneiform bone, and perhaps one for the pisiform, when present.

Motion in the carpus takes place chiefly in the radio-carpal portion, to a far less degree in the intercarpal, and very slightly in the carpo-metacarpal; the movements are flexion and extension; very slight lateral and circumductive movements are possible.

#### METACARPAL ARTICULATION.

This consists of diarthrodial and synarthrodial joints. The latter are furnished with interosseous ligaments, which very generally become ossified; the articular surfaces of the former are held together partly by those *carpal* ligaments which surround them, and partly by the interosseous ligaments just named.

#### METACARPO-PHALANGEAL ARTICULATION.

This, which is popularly termed the *fetlock* joint, is formed by the large metacarpal bone, the proximal phalanx, and a pair



of sesamoids. The ligaments may be divided into those *proper* to the joint and the *accessory*. The former consist of a capsular and two lateral ones. The *capsular* ligament passes from the lower end of the large metacarpal bone to the head of the os suffraginis, and is attached to the *lateral* ligaments, which stretch from the infero-lateral aspect of the metacarpus to the supero-lateral surface of the os suffraginis.

The *accessory ligaments* are those immediately connected with the *sesamoid* bones.

The *superior sesamoidean* or *suspensory* ligament is a long, strong band, arising posteriorly from the lower bones of the carpus and the head of the metacarpus, occupying the space between the splints. It bifurcates, and becomes attached to the summits of the sesamoids, whence the parts pass downwards and forwards, reuniting as the *broad ligament*, and joining the extensor pedis tendon at the antero-inferior part of the os suffraginis.

The *inferior sesamoidean* ligaments are named the *external* or long, the *middle* or short, and the *internal* or crucial. The *external* one is Y-shaped, and runs from the base of the sesamoids to the supero-posterior part of the os coronæ. The *middle* one is V-shaped, arising from the base of the sesamoids, and it passes down to a ridge on the back of the os suffraginis. The *internal* one, crucial or X-shaped, likewise passes from the base of the sesamoids to the

supero-posterior part of the os suffraginis, its fibres intercrossing.

The *lateral sesamoidean* ligaments, *external* and *internal*, are two thin layers, passing from the external surfaces of the sesamoids to the tubercles on the head of the os suffraginis. Posteriorly, the sesamoid bones are connected by the *interosseous*

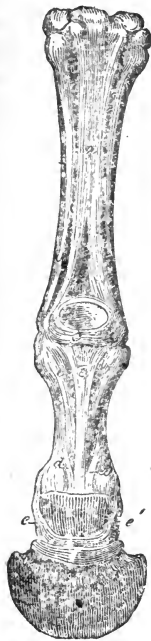

FIG. 56.

Sesamoidean and digital ligaments—posterior aspect. *a*, Suspensory ligament; *b b b*, External and middle inferior sesamoidean ligaments. The central bundle is the Y, the two lateral ones forming the V ligament; *c*, Annular sesamoidean ligament; *d d*, Posterior ligaments of the pastern joint; *e e*, Lateral, and *f*, Inferior, navicular ligaments.

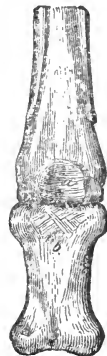

FIG. 57.

Deep sesamoidean ligaments. *a*, Inter-sesamoidean ligament; *b*, Crucial or X ligament.

or *intersesamoidean* ligament, and covered by a pad of fibro-cartilage, which forms a smooth groove for the passage of the flexor tendons, and is converted into a canal by the *annular ligament*, a strong fibrous band which forms an arch posteriorly from one sesamoid bone to the other. The joint is capable of flexion and extension, with very slight lateral motion.

The synovial membrane of this joint is continued upwards posteriorly, in the bifurcation of the suspensory ligament, where it forms a large *cul-de-sac*. "Wind-galls" are projections of this sac when it is abnormally full.

#### PASTERN JOINT.

The *Proximal interphalangeal articulation*, or pastern joint, is formed by the proximal and mesian phalanges, joined by the capsular, lateral, and two posterior ligaments. The *capsular* ligament extends from the articular margin of one bone to that of the other, and is adherent in front to the extensor tendon. The *lateral* ligaments are large and very strong, springing from the distal end of the os suffraginis and passing obliquely downwards to the postero-lateral aspect of the os coronæ. The *two posterior* ligaments run each from three points on the sides of the os suffraginis to a piece of fibro-cartilage, described as the *glenoid* cartilage, and attached to the postero-superior edge of the os coronæ; between them is the insertion of the external inferior sesamoidean or Y-shaped ligament.

The *synovial membrane* of this joint lines the glenoid cartilage and a portion of the extensor tendon, and sends upwards a sac which lies between the postero-inferior part of the first phalanx and the cartilage. The movements are flexion and extension, and, during flexion, some slight lateral motion.

#### COFFIN JOINT.

The *Distal interphalangeal articulation*, or coffin joint, is formed by the mesian and distal phalanges and the navicular bone. Its ligaments are the *capsular*, *antero* and *postero-lateral*, and the *broad*, *lateral*, and *inferior* navicular. The *capsular* ligament includes the articulation formed by the three bones, and is attached to the extensor tendon in front and the flexor behind. The *antero-lateral*, which are strong and thick,

spring from the imprints on the lateral aspect of the os coronæ, and are inserted into two depressions at the superior border of the os pedis, partly covered by the lateral cartilages.

The *postero-lateral* are continuations of the lateral ligaments of the pastern joint, which, after reaching the os coronæ, form an elastic fibrous cord, attached to the upper border of the navicular bone, the two uniting to form the *superior* or *broad ligament*. They give off short *lateral* bundles to the retrossal processes and inner surfaces of the lateral cartilages. The *lateral navicular ligaments* consist of strong white fibres, which join the angles of the navicular bone to the inner aspect of the lateral cartilages, and the wings of the os pedis. The *inferior ligament* is an *interosseous* one, which is attached to a roughened groove on the anterior border of the navicular bone and to the semilunar ridge of the os pedis. The *synovial membrane* lines the cavity of the joint, and sends upwards a very large sac along the posterior surface of the median phalanx. Smaller projections are found between the anterior and posterior lateral ligaments. The motion of the joint is that of flexion and extension.

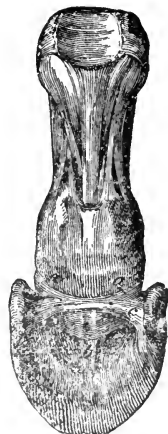

FIG. 58.

Navicular ligaments.  
a a, Superior, or broad;  
b, Inferior; and c c, Lateral ligaments.

## ARTICULATIONS OF THE PELVIC LIMB.

### THE PELVIS.

*Sacro-iliac Articulation.*—This is the articular connection between the axial skeleton and the pelvic limb; it is described both as a diarthrosis and an amphiarthrosis; it is capable of little motion, and the synovia is small in quantity, if present at all; the joint is formed by the venter of the ilium, and the supero-lateral surface of the sacrum, which articular surfaces are clothed with cartilage, and the union completed by the three *sacro-iliac ligaments*, inferior, lateral and superior. The *inferior* consists of strong bundles of fibres, which envelop the articulation like a strong and irregular capsular ligament, and are attached below to the transverse process of the sacrum, and above to the venter ilii. The *superior sacro-iliac*, short and strong, stretches from

the spines of the sacrum to the posterior spine of the ilium. The *lateral sacro-iliac* is triangular, the fibres running obliquely

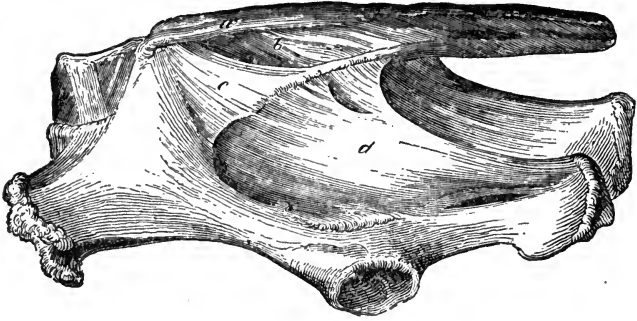


FIG. 59.

Sacral and pelvic ligaments—left lateral aspect. *a*, Superior sacro-iliac ligament; *b*, Sacral ligament; *c*, Lateral sacro-iliac ligament; *d*, Sacro-sciatic ligament.

backwards, and it is attached above to the posterior spine and border of the ilium, below to the lateral border of the sacrum.

*Sacro-sciatic Ligament.*—This is a broad membranous expan-

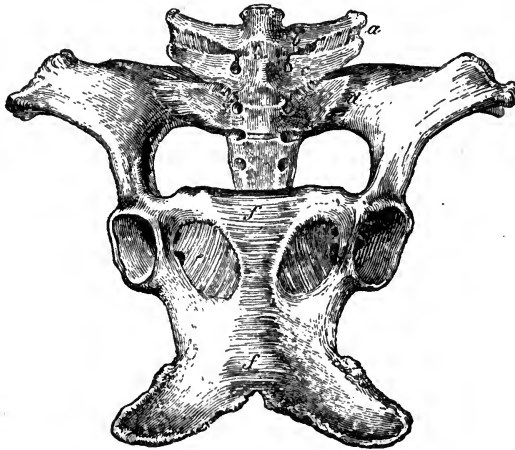


FIG. 60.

Sacral and pelvic ligaments—inferior aspect. *a*, Intertransverse lumbar ligament; *b* and *c*, Capsular ligaments of lumbar and sacro-lumbar transverse articulations; *d*, Inferior sacro-iliac ligament; *e*, Obturator ligament; *f*, Ligament of the ischio-pubic symphysis.

sion situated at the side of the pelvis, helping to form the pelvic cavity. It is attached superiorly to the lateral borders of the transverse processes of the sacrum and first two or three coccygeal

vertebræ ; inferiorly, to the superior ischiatic spine and tuberosity of the ischium. Between this ligament and the iliac shaft is a space, the great sciatic notch ; and a second, the lesser sciatic notch, exists between the ligament and the ischial shaft. The former gives passage to the great sciatic nerve and gluteal blood-vessels, the latter to the tendons of the obturator internus and pyriformis muscles.

Some lateral bands are found joining the sacral spines to the transverse processes ; these are termed the *sacral ligaments*.

*Pelvic or Ischio-pubic Symphysis*.—This articulation is formed by the respective surfaces of the ischium and pubis, and joins the right and left ossa innominata ; in the young it consists of fibro-cartilage and white fibrous tissue, which ossify with age.

The *Obturator ligaments* are thin membranes, almost closing up the obturator foramina, a small passage being left for the transit of blood-vessels.

## HIP JOINT.

The *Femoro-pelvic* is a ball-and-socket or enarthrodial joint, and is formed by the acetabulum of the os innominatum and the articular head of the femur. It has the following ligaments :—

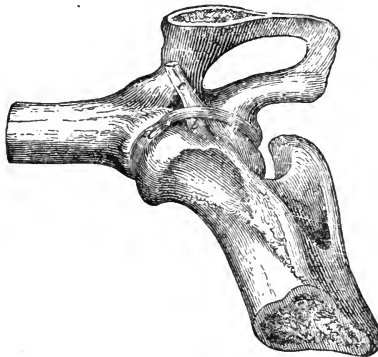

FIG. 61.

Ligaments of the hip joint—infero-internal view.  
a, Cotyloid ligament ; b, Round ligament ; c, Pubio-femoral, crossed by the transverse ligament.

The *capsular*, which grasps the brim of the acetabulum and roughened edge of the head of the femur ; the *cotyloid*, which surrounds and deepens the acetabulum ; and the *transverse*, which stretches over the cotyloid notch, completing the circum-

ference of the cavity, but leaving a space for the passage of the pubio-femoral ligament.

The binding ligaments of the joint are two—the round or *Ligamentum teres*, very short and strong, which arises from the notch in the head of the femur, and is inserted in the fundus acetabuli; the second is the *pubio-femoral* ligament, which arises from the head of the femur, close by the round ligament; bound down by the transverse ligament, it passes through the cotyloid notch and along the groove on the under side of the pubis, meeting and crossing its fellow at the symphysis, and becoming continuous with the abdominal fascia of the *opposite side*; thus the head of the right femur is partially supported in position by the muscles of the left side, and *vice versa*. As it passes over the pubis, a synovial bursa is interposed. This ligament is peculiar to the Equidæ. The motion of the joint is flexion, extension, abduction, adduction, rotation, and circumduction.

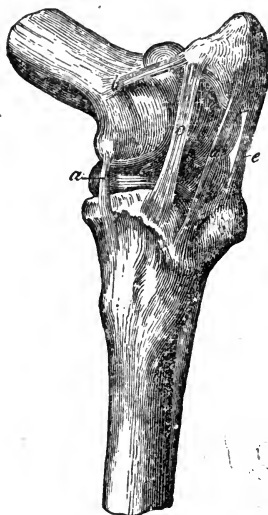


FIG. 62.

Ligaments of the stifle joint—antero-internal aspect. *a*, Internal lateral femoro-tibial ligament; *b*, Internal lateral patellar ligament; *c*, Internal, *d*, Middle, and *e*, External straight patellar ligaments.

#### STIFLE JOINT.

The *Femoro-tibial articulation*, a compound ginglymus, is formed by the trochlea and condyles of the femur, the tibia, and patella. The ligaments consist of two groups, the *femoro-tibial* and the *patellar*.

*Patellar Group*.—The *capsular* ligament, which is attached round the trochlea of the femur, and the articular surface of the patella, is capacious, allowing considerable motion in the joint. The *lateral ligaments*, *internal* and *external*, arise from the lateral aspects of the femur, just above the condyles, and are inserted to the corresponding surfaces of the patella, the *external* being the larger; they may be regarded as thickened portions of the capsular ligament. The *three straight ligaments*, *external*, *middle*, and *internal*, arise from the antero-inferior surface of the patella, and are inserted to the anterior aspect of the tuberosity of the tibia, the middle one occupying the small fossa.

At its patellar attachment, the internal straight ligament becomes enlarged, and fibro-cartilaginous in structure, projecting over the edge of the femoral trochlea, and thus enlarging the articular surface of the patella.

*Femoro-tibial Group.*—There are two crescentic fibro-cartilaginous discs, the *semilunar cartilages* or *menisci*, interposed between the condyles of the femur and the head of the tibia, the internal one being the larger and thinner. Their internal borders are sharp and concave, embracing the tibial spine, while the external are thick and convex. Their superior surfaces are hollowed for the reception of the femoral condyles, while the inferior are smooth and flat, resting on the tibia. Their extremities terminate in the *coronary ligaments*, which attach them to the bones; these are *five* in number, *two* for the *internal* disc, an anterior one attaching it to an excavation in front of, while the posterior one is fixed to a furrow behind, the tibial spine. The external disc has *three*, *one* fixed in front of the tibial spine, and *two* behind it, of which the superior one is longer and stronger, being inserted in the intercondyloid notch of the femur, while the inferior is thin and flat, and fixed to the head of the tibia.

*Crucial or Interosseus Ligaments.*—These, *anterior* and *posterior*, are very strong, and are situated between the condyles of the femur. The *anterior* or external stretches obliquely forwards, and is attached in the intercondyloid notch inside the external condyle of the femur, and to a depression on the summit of the tibial spine. The *posterior* or internal, the longer, arising anteriorly inside the internal condyle, crosses the anterior ligament, and is attached posteriorly to a small eminence behind the inner articular surface of the head of the tibia.

*Lateral Ligaments.*—The *external* one, the shorter and stronger

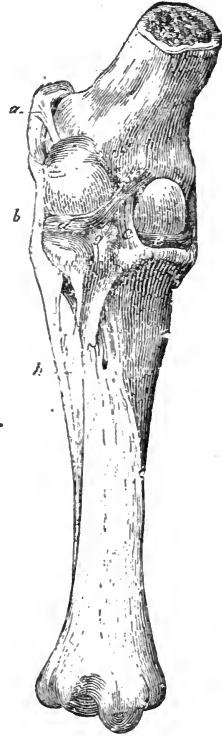


FIG. 63.

Ligaments of the stifle joint —posterior aspect. *a*, External lateral patellar ligament; *b*, External lateral femoro-tibial ligament; *c*, Posterior crucial ligament; *d*, External meniscus; *e*, Internal meniscus; *f*, Femoral coronary ligament; *g*, Posterior external coronary ligament; *h*, Fibulo-tibial ligament.

arises from the external condyle of the femur, and passes over the head of the tibia to the fibula; a synovial bursa lies between it and the tibia. It is separated from the capsular ligament by the tendon of origin of the popliteus. The *internal lateral* arises from the internal condyle of the femur, and is attached to the intero-lateral aspect of the head of the tibia.

*Capsular Ligament.*—This name is usually applied to a membranous ligament enclosing the joint posteriorly, and attached to the femur, tibia, lateral ligaments, and menisci. It is by some called the *posterior* ligament. Anterior to this there is a pair of membranes enclosing the joint antero-laterally. These are generally described as the synovial membranes; but as they are considerably strengthened, and help to play the part of a capsular ligament, it may be convenient to describe them as such. There is therefore a complete capsular ligament investing the joint, thickened posteriorly.

The synovial apparatus is double, each side having its own membrane, and between the two are the crucial ligaments of the joint. Anteriorly, the synovial membranes contact that of the femoro-patellar joint, and it is found that sometimes the synovial cavities are continuous with that of the latter. A large quantity of fat fills up the space between the capsules and the straight ligaments of the patella. The motions of this joint are flexion and extension, and a certain amount of rotation, permitted by the presence of the discs.

#### TIBIO-FIBULAR ARTICULATION.

This small articulation is formed by the facets on the adjacent surfaces of the tibia and fibula, and is a diarthrodial joint. The ligaments are a strong *capsular* one and the *interossei*, which divide into *superior* and *inferior*; the former being a small bundle at the upper third of the fibula; the latter consists of a membranous expansion, extending from the middle to the distal extremity of the fibula. Between the two interosseous parts pass the chief artery and vein of the region, the anterior tibial. A ligamentous cord extends downwards from the fibula to the external malleolus of the tibia, "where this cord bifurcates and unites with the two external lateral ligaments of the tarsal joint" (*Rigot*). Motion in this joint can hardly be said to exist.



## THE TARSUS.

Similar to the carpus, this, the *hock joint*, consists of a true or *tibio-tarsal* portion, together with the *upper and lower tarsal*, the *intertarsal*, and the *tarso-metatarsal* accessory articulations. The ligaments are common and special.

*Common Ligaments.*

These are the *external* and *internal lateral* and the *capsular*.

The *internal lateral* is formed of three fasciculi of fibres, superficial, middle, and deep. The superficial, the longest and strongest, connects the internal malleolus of the tibia with the astragalus, two cuneiform, and the large and inner metatarsal bones. The middle fasciculus, consisting of two cords, likewise arises from the internal malleolus of the tibia, one division being attached to the astragalus, the other to the calcaneum. The deep fasciculus is very small; it passes from the internal malleolus to the astragalus. The *external lateral* ligament consists of two crucial fasciculi, superficial and deep. The superficial is strong and flat, joining the external malleolus of the tibia to the astragalus, calcaneum, cuboid, large and external metatarsal bones. The deep fasciculus is short; it passes obliquely backwards, arising from the external malleolus of the tibia, to the astragalus and calcaneum. The capsular ligament is very strong, and attached superiorly round the distal articular surface of the tibia,

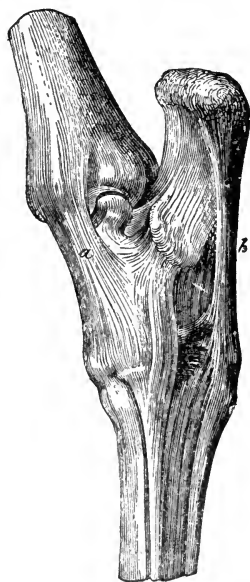

FIG. 64.

Ligaments of the tarsus—postero-internal view. *a*, Internal lateral ligament; *b*, Calcaneo-cuboid ligament.

and calcaneum. The capsular ligament is very strong, and attached superiorly round the distal articular surface of the tibia, to the inferior border of the astragalus, to the cuneiforme magnum and medium, and to the lateral and oblique ligaments; posteriorly it is attached to the calcaneum and astragalus, and there is a fibro-cartilaginous disc in its centre, over which glides the flexor tendon, furnished with a synovial membrane.

The capsular ligament is often described as double, and named the anterior and posterior, the lateral ligaments with which it blends being the lines of division.

*Special Ligaments.*

*Superior Tarsal.*—These ligaments occur between the astragalus and calcaneum, and consist of *one superior, two lateral, and one interosseous*. The *superior* stretches from the upper border of the pulley of the astragalus to the calcaneum; the *lateral* are very thin, and covered by the lateral common ligaments; the *interosseous* one is strong, occupying the greater part of the rough excavation between the articular facets of the bones.

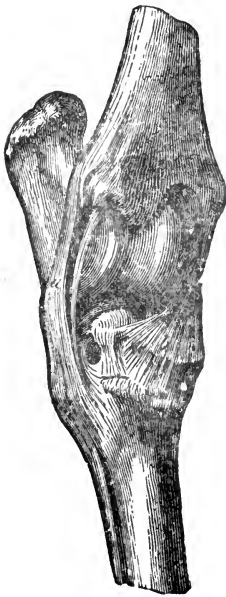

FIG. 65.

Ligaments of the tarsus—  
anterior-external view. *a*,  
External lateral, and *b*,  
Oblique ligament.

*Inferior Tarsal.*—The ligaments of the lower row are *five, two anterior*, which connect the cuboid to the great and middle cuneiform bones, and *three interosseous* ones, two of which correspond to the anterior ligaments; the third *interosseous* ligament unites the three cuneiform bones. Some of these ligaments bound the tarsal foramen, which gives passage to the perforating pedal artery.

*Intertarsal.*—The four ligaments in this group are of greater importance than those of the two last groups. The *calcaneo-cuboid* or *calcaneo-metatarsal* ligament stretches from the posterior border of the calcaneum to the posterior part of the cuboid, terminating on the head of the external metatarsal bone; externally it reaches the lateral, internally the tarso-metatarsal ligament. This ligament becomes implicated in the lesion known as *curb*.

The *Oblique*, or *Astragalo-metatarsal ligament*, arising from the antero-internal side of the astragalus, becomes attached to the cuneiforme magnum and medium, the large metatarsal bone, and the capsular ligament, the fibres radiating from above, and running downwards and outwards. This ligament covers the seat of *bone-spavin*.

The *Tarso-metatarsal* is a single strong ligament, which covers the tarsal groove and unites posteriorly all the bones of the joint to the three metatarsal bones. It is smooth, for the passage of the flexor tendon, and is the analogue of the posterior

carpal ligament. It is pierced by the perforating pedal artery and vein, and inferiorly may be continuous with the check ligament. The *great interosseous ligament* unites the calcaneum and astragalus to the cuboid and cuneiforme magnum, occupying the internal space formed by these bones.

*Annular Ligaments.*—The posterior of these closes in the tarsal groove, completing the sheath for the deep flexor tendon; hence it passes from the tuberosity and posterior border of the calcaneum to the internal ridge of the same bone, and is reflected as far down as the inner metatarsal bone. It is strengthened by a strong band which arises almost with the calcaneo-cuboid ligament. The *anterior* annular ligament presents three well-marked portions; they are strong and more or less flattened bands, an inferior one passing across from the proximal end of the outer to that of the inner metatarsal bone, a middle one attached to the cuboid bone and flexor metatarsi tendon, and a superior crossing the distal end of the tibia obliquely outwards and downwards. The three portions of this ligament bind down the tendons playing over the tarsus anteriorly.

There are at least three *synovial membranes*, one between the astragalus and tibia, another between the rows of bones, and one also between the lower row and the metatarsus, which sends a branch upwards between the calcaneum and astragalus.

The motion in the tarsal joint is in effect limited to flexion and extension, and the joint may therefore be regarded as a ginglymus.

The *tarsal check ligament* will be described with the muscles. The *metatarsal*, *metatarso-phalangeal*, and *interphalangeal* joints are like those of the anterior limb.

## COMPARATIVE ARTHROLOGY.

### RUMINANTIA.

#### AXIAL SKELETON.

In the ox, the dorso-lumbar *supraspinous* ligament is composed of yellow elastic tissue, and anteriorly is expanded, and attached to the sides rather than to the summits of the neural spines. The inferior common ligament is very strong, and the intervertebral discs thicker than those of the horse; the *ligamentum nuchæ* is also stronger, as the weight it has to bear is greater. The sternal ribs articulate with their cartilages by means of true diarthroses, and are supplied with synovial membranes. The sternum is furnished with an inferior common ligament, and the presternum or *manubrium* articulates with the meso-

sternum by a diarthrosis of limited motion. The transverse lumbo-sacral and interlumbar articulations, being peculiar to the horse, are entirely wanting here.

#### PECTORAL LIMB.

In the *elbow joint* the internal lateral ligament is shorter than the external. The carpus, being articulated on the same general plan as that of the horse, calls for no special description. The metacarpo-phalangeal joint is double, each digit articulating in a manner very like the single one of the horse, and each having two lateral ligaments. The *suspensory ligament* divides into several parts inferiorly, four of which go to the sesamoid bones, one to each, either of the two external ones giving off a band which winds round to the front, and joins the tendon of the extensor proprius of the digit, while two other bands pass directly from the ligament through the interarticular notch of the metacarpus, separate and likewise join the above-named extensor tendons from the inside; two slips pass down, unite and become attached to the small rudimentary digits or claws, afterwards separating to become united postero-superiorly to the distal phalanges; finally, two deep branches go to the tendon of the flexor perforatus and form two rings through which passes the divided tendon of the flexor perforans. The *inferior sesamoid* ligaments are small, and consist of two lateral bands, which attach the sesamoid bones to the head of the proximal phalanx, and between them a very small X ligament. The *intersesamoid* ligaments are three in number; there is one between each pair of bones, and one joining the two internal ones. A common annular ligament is found about the region of the fetlocks, and two smaller special annular ligaments lower down. (Fig. 87, *f g g'*.) The *superior interdigital* ligament is crucial, and situated between the two proximal phalanges, in small ruminants it is very rudimentary. There are only two fibrous bands which attach the glenoid cartilage to the first phalanx. The *inferior interdigital* ligament joins the distal phalanges and navicular bones together, and in the ox is connected with the tendon of the flexor perforans. The *superior navicular* ligament, coming from the mesian phalanx, is formed of elastic tissue.

#### PELVIC LIMB.

The *pubio-femoral* ligament is wanting in all the domesticated animals other than the horse; the absence of this ligament enables the larger ruminants to deliver those sweeping circular blows with the foot, which are known by the familiar name of "cow-kicks." There is only one *straight ligament* of the patella in the smaller ruminants. With respect to the *tarsus*, we may remark, that there is more motion in that joint in the ruminant, due to the greater mobility of the astragalus, which possesses gliding motion upon the calcaneum, the cubo-cuneiform bone, the tibia, and the malleolar bone, all of which assist in forming the mobile portion of the joint.

In the elephant there is no round ligament; and the femur instead of being, when at rest, inclined downwards and forwards, maintains an almost perpendicular position; this accounts for the peculiar contour of the haunch in that animal.

## OMNIVORA.

## AXIAL SKELETON.

In the hog the *ligamentum nuchæ* can scarcely be said to exist; a fibrous cord from the dorsal spines to the occiput represents it. There is only one synovial capsule in the occipito-atloid joint, and there is a *transverse odontoid* ligament which passes over the odontoid process, and keeps it down on the floor of the atloid ring. The sternal ribs articulate distally like those of the ox, and the remarks on the sternal articulations of that animal also apply to the hog. The *temporo-maxillary* joint possesses great motion anteriorly and posteriorly, resembling in its structure that of the rabbit, the anterior mastoid process being small, and the temporal articular surface large. The ligaments between the hyoid cornua and cornicula are elastic.

## APPENDICULAR SKELETON.

The synovial membrane of the shoulder joint is continued into the bicipital groove. In the elbow joint the internal lateral ligament is shorter than the external one. The radius and ulna have been described as ankylosed and also as closely connected by fibrous tissue. Whichever be the more common mode of union, there is no motion between these bones. The four bones of the metacarpus are joined by prolongations of the great carpal ligaments above, and below by interarticular ligaments. Each metacarpophalangeal joint is supplied with an intersesamoid, two lateral, a crucial inferior sesamoid, and an anterior capsular ligament, also with a synovial membrane, and lateral ligaments for the joint itself. The *suspensory* ligament is replaced by the *interosseous palmar muscles*, and there are small superior interdigital ligaments between the proximal phalanges. A very small osseous nodule is usually found on each of the anterior capsular ligaments of these joints. The external lateral navicular ligaments resemble those of the horse; the internal ones are wanting. An elastic navicular ligament like that of the ox is found in the large digits.

There is no pubio-femoral and only one *straight patellar* ligament. The tibio-fibular articulation consists of an amphiarthrosis superiorly, a diarthrosis inferiorly, and between these an interosseous ligament, stronger below than above. The tarsal articulation resembles in the main that of the ruminant.

## CARNIVORA.

## AXIAL SKELETON.

The *ligamentum nuchæ* is represented by a fibrous band which is larger in the dog than in the cat; in the cervical vertebræ of the former, and in the vertebræ generally of the latter, there are interspinous muscles instead of ligaments. The occipito-atloid and odontoid ligaments are similar to those of the hog. In the *temporo-maxillary* joint there is merely ginglymoid motion, and the meniscus is very thin.

## APPENDICULAR SKELETON.

In the carnivora the synovial membrane of shoulder joint is similar to that of the hog in its arrangement. The lateral ligaments of the *elbow joint*, together with the annular ligament, form a kind of ring in which the head of the radius slightly revolves, as there is a certain amount of motion between it and the ulna. The *radio-ulnar* articulation consists of a superior and an inferior rotatory diarthrosis, and an interosseous ligament; the rotatory movements between these bones are termed *pronation* and *supination*, the prone being the normal position of the extremity. The metacarpus is formed similarly to that of the hog, but it is more mobile, and the rest of the articulations of the limb resemble those of that animal, with the exception of the distal interphalangeal, where we find anteriorly an elastic ligament which acts as the *retractor* of the claw, and is stronger and much more active in the cat than in the dog, the claw of the former being much more retractile. Posteriorly a piece of fibro-cartilage is the analogue of the navicular bone, which is wanting.

The patella has one *straight ligament*, and the menisci are united. In the tibio-fibular articulation, there is superiorly a diarthrosis, otherwise it is formed on the same plan as that of the hog, as is the tarsal joint, excepting that the astragalus has an inferior *head* instead of a trochlea.

---

## CHAPTER III.

### MYOLOGY.

THE branch of anatomy which treats of the muscular system is called Myology. The muscles are the active organs of motion, or of locomotion, the bones and ligaments being passive organs of the same.

Before studying the muscles individually it is necessary to take a brief view of their anatomical and histological structure. They contain the specific contractile substance termed *muscular tissue*, together with areolar and fibrous tissue, and a certain amount of fatty material; they are also furnished with nerves, blood-vessels, and absorbents.

#### MUSCULAR TISSUE.

*Muscular tissue* is the name applied to contractile fibres, which are either collected into bundles connected at their extremities, and forming distinct organs termed *muscles*, to which the familiar name *flesh* is applied; or they are found helping to form the walls of the hollow viscera, as the bladder, stomach, &c.

In the first variety the fibre presents, when magnified, a striped appearance, the stripes being placed transversely; it is therefore known as striped or *striated fibre*, and as with little exception its contraction and relaxation are controlled by the will of the animal, it is also termed *voluntary fibre* or muscle. The second variety differs from the first in not being striped, and also in its action being beyond the control of the will; hence it is named *non-striated* or *involuntary fibre*. The chief exceptions to this general distinction occur in the heart and in the upper part of the œsophagus, which contain *involuntary striated* tissue. Both varieties are red in colour, but the hue of the striated kind is far deeper. We therefore describe two kinds of muscular tissue, the *striated* and the *non-striated*.

## STRIATED MUSCULAR TISSUE.

*Voluntary* or *striated muscular tissue* forms the mass of the so-called muscles, which terminate at either extremity in fibrous structures termed the *tendons*, by means of which they are attached to the bones; the intermediate fleshy portion is often called the belly of the muscle. A muscle is composed of bundles,

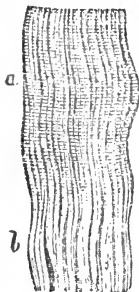

FIG. 66.  
Fasciculus of striated muscular fibres. Transverse striæ seen at a; b, Union of fibres with the tendon.

or fasciculi of fibres, which are the integral parts of the structure. The microscope shows these fibres to consist of fine filaments termed *fibrillæ*, which run parallel to each other, maintaining an undivided course throughout. Each fibre is enclosed in a delicate tubular sheath called the *sarcolemma* or *myolemma*, composed of a transparent and apparently homogeneous membrane, tough and elastic, which isolates each fibre, and frequently remains intact after rupture of its contents. The fibres, about  $\frac{1}{500}$ th of an inch in diameter, are gathered into prismatic or polyhedral fasciculi, and invested with a sheath of connective tissue, which is inflected between the fibres, and called the *perimysium internum*; the entire muscle has likewise an investing sheath of connective tissue, the *perimysium externum*, continuous with the above. This connective




FIG. 67.  
A single striated muscular fibre, showing its component fibrillæ.

tissue is membranous in structure, its use being to connect the bundles and fibres, and to serve as a matrix for the ramification of blood-vessels, nerves, and absorbents.

A muscular fibre, examined under a power of 300 diameters or less, will display the transverse waving *striæ* or lines, from which the name "striated" is derived. Longitudinal markings



or lines are also often apparent, but are less regular than the striæ. The component fibrillæ of a muscular fibre may be demonstrated by macerating the tissue in strong alcohol, and pressing the prepared object, when each fibrilla will be seen to consist of a row of alternately light and dark spots. By other means, such as treatment with hydrochloric acid, or by a smart blow, a muscular fibre may be separated into transverse *discs* corresponding to its striated appearance. These two separations of a fibre have been termed the longitudinal and transverse *cleavages*. Could both these operations be performed on the same fibre, the result would be a crucial cleavage of it into a number of objects which would appear under a high power as dark spots, with light spaces round them, both being rectangular in form; they are known as the *sarcous elements of Bowman*, and in them rests the inherent power of contractility. Thus a transverse row of sarcous elements forms a disc; a longitudinal row a fibrilla. When seen through the medium of the sarcolemma the dark spots appear transversely as a continuous line, hence the striated appearance of the fibre. The fibres cleave more readily into fibrillæ than into discs:

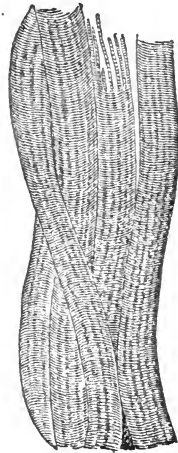


FIG. 68.  
Striated muscular fibres  
from the Horse.

Modern observation modifies the above, the fibre being generally regarded as a series of alternate light and dark discs, the latter having on each transverse surface a number of darker granules, connected by fine longitudinal and transverse lines. The former with their nodular extremities are termed *muscle-rods*.

A number of oval objects, related with the sarcolemma, appear on treating a fibre with acetic acid; these are the *muscle corpuscles*, and they are nucleated. Striated fibres are for the most part isolated, but those of the heart, which, as already stated, are involuntary, divide into branches, and the branches of different fibres frequently join, or, as it is termed, *anastomose*. (Fig. 152.)

#### NON-STRIATED MUSCULAR TISSUE.

*Involuntary* or *non-striated muscular tissue* is pale in colour, and consists of fibres, bound into fasciculi by a fine perimysium of areolar tissue.

The fibres never terminate in tendons, and are not invested in a sarcolemma; they are cylindrical in shape, and composed of

fusiform or elongated cells, which become apparent after maceration of the tissue in dilute hydrochloric acid or other reagents, or it may be without any such preparation. These cells are the *contractile cells* of Kölliker, and in them an elongated nucleus may be visible. The fasciculi vary very greatly in size in different situations, and often crossing each other, they give the tissue in some parts a mesh-like appearance. The non-striated tissue is very abundant, being found in the walls of the alimentary canal and hollow viscera, in gland ducts, in the coats of blood-vessels, in the skin, and elsewhere.

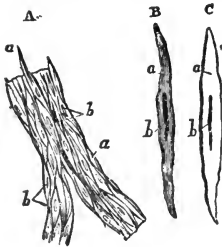


FIG. 69.

A, Non-striated muscular fibres; a a, The component fusiform cells; b, b, The nuclei. B and C, Single cells more highly magnified; C having been treated with acetic acid.

Both varieties of muscular tissue are plentifully supplied with blood, and in striated tissue the capillaries or minute blood-vessels are arranged longitudinally with transverse connecting branches, but they do not penetrate the sarcolemma, they and the larger vessels alike being found in the perimysium or interstitial connective tissue. The striated tissue is supplied with nerves from the cerebro-spinal system, but the non-striated tissue receives its supply from the sympathetic system, and the vital stimulus

conveyed by either of these causes the contraction of the fibres.

The description of the arrangement of involuntary tissue forms no part of the present section of our subject; the tissue is described here chiefly in order that its structure may be compared with that of the voluntary kind.

#### TENDONS.

The tendons in which voluntary muscles terminate at either end are structures resembling ligaments in their composition, being formed of white fibrous tissue mixed with yellow fibres. Like ligaments, they are practically non-elastic, and while they attach the muscles to the bones, they merely transmit the action of the former to the latter, and are therefore passive instruments of motion.

The extremity of a muscle which has the most fixed attachment is called its *origin*; the other extremity attached to the more movable structure, its *insertion*. The tendon of insertion is often longer than that of origin, which is frequently rudimentary. In some cases both extremities are equally movable.

The strongest part of a muscle is its point of union with the tendon, but the manner in which that union is effected is not satisfactorily explained. According to some authorities, the muscular fibres are prolonged into the connective tissue of the tendon; or, "the contractile fibre terminates in a rounded extremity which is buried in a corresponding depression in the tendon" (*Chauveau*). The sarcolemma and the areolar tissue, both of the fibre and tendon, are no doubt instrumental in effecting the union.

Tendons often send processes into the substance of the muscle, which may extend throughout its length; such processes are described as tendinous intersections; they also appear to send small fibres into the substance of the bones to which they are attached. Tendons vary in form, size, and density, but all are either rounded or flattened. The former are *funicular*, the latter *aponeurotic* tendons; in either form their use is the same. They become attached to bones through the medium of the periosteum, sometimes expanding to strengthen its outer layer.

## FASCIA.

Each group of muscles is invested and bound down by a strong membranous expansion of white fibrous tissue, called *fascia*, which is firmly connected with the bone. This term is however applied to other membranous expansions, differing very materially in strength, texture, and relations. For example, below the skin and panniculus there is a membranous expansion, which forms a continuous covering over the whole body, composed of connective tissue more or less condensed. Hence fasciæ have been divided into *superficial*, and *deep* or *aponeurotic*.

*Superficial fascia* consists of cellular and elastic tissue, varying in thickness in different regions of the body. Where the skin is loose it is most distinct; and sometimes it is inseparable from the muscles and skin, as in the eyelids and lips. Its meshes may be filled with adipose cells, or condensed so as to form a fibro-cellular membrane destitute of fat. Its use is to connect and protect the various structures it contacts, and to furnish a matrix for blood-vessels; the fat in the subcutaneous fascia helps to conserve the animal heat, fat being a bad conductor.

*Aponeurotic fascia* not only covers, supports, and binds down the groups of muscles, but affords processes between them, and becomes united to, and blended with, the periosteum. Some of

these fasciæ have distinct muscles for rendering them tense, as the tensor fasciæ latæ. Fasciæ are also found in connection with the walls of cavities, as in the pelvis.

In the limbs, where the muscular bellies form lengthy masses, with long tendons attached at considerable distances, there would be considerable displacement during motion, were it not that in these parts the *fascia is very strong*, enclosing the body of each muscle in a sheath, as also each group of muscles.

#### MUSCULAR NOMENCLATURE.


Muscular nomenclature is unsatisfactory and confused, some muscles being named from their form, as Trapezium, Rhomboideus, Scalenus; others from their use, as Flexor, Extensor, Adductor, Abductor, &c.; some from their direction, as Rectus, Transversus, Obliquus; others from their situation, as Temporalis, Peroneus, Subscapularis; some again from their attachments, as Sternomaxillaris, Coraco-radialis, and Stylo-hyoideus; and some from their homologues in the human subject. A muscle may have a physiological name expressing its use, and an anatomical one alluding to some feature in its morphology; but perhaps the most satisfactory system of nomenclature is that which names muscles from their *attachments*.

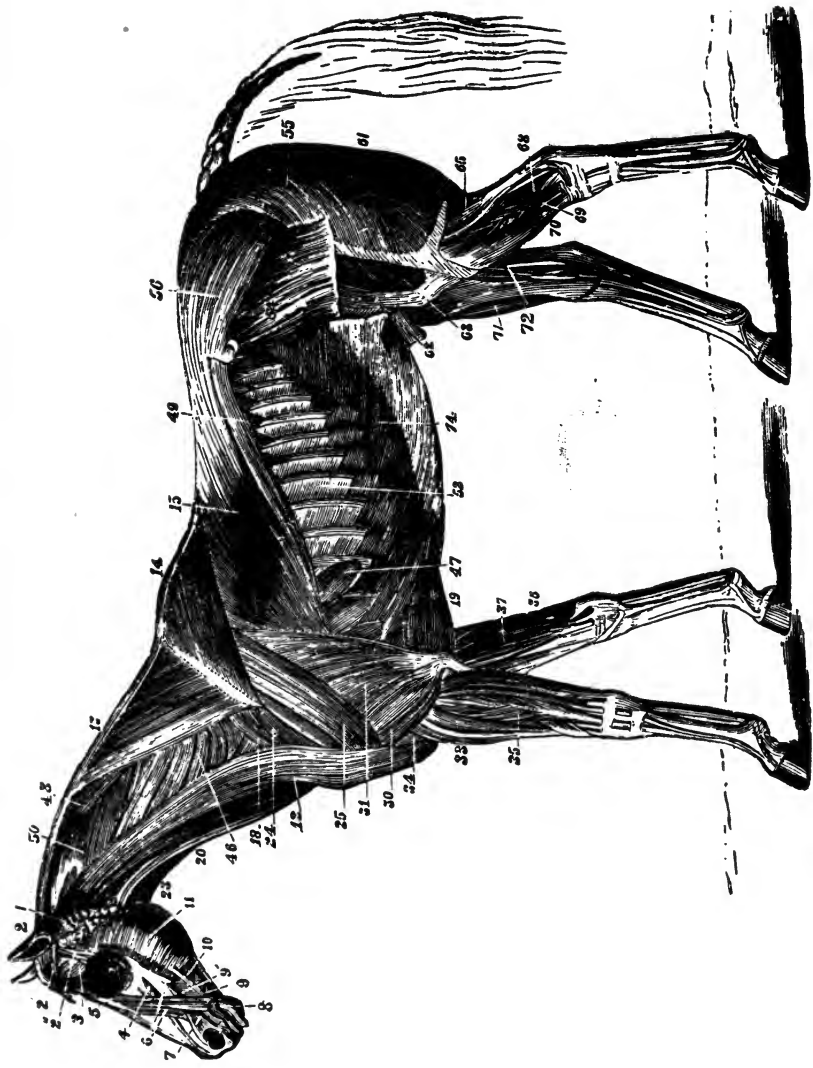
Muscles vary so much in shape that no classification of them can be based on that feature. Some of them, however, present such marked features that certain terms are used to describe their form. Thus, *biceps* and *triceps* express a two or three-headed muscle; a *diagastric* muscle has two bellies, joined by a mesian tendon; a *radiating* muscle consists of bundles diverging from a point of attachment; a *penniform* muscle resembles a feather in shape, and a *semipenniform* one the lateral half of the same, the tendon corresponding to the axis or scapus of the feather.

In the descriptions of muscles which follow, the names printed in small capitals are those most commonly in use in Great Britain, whereas the names below, and in italics, are almost uniformly *anatomical*, expressing in most cases the places of attachment of the muscles,—a nomenclature more valuable though less current than the one in use.

#### CLASSIFICATION OF MUSCLES.

Either an *Anatomical* or *Physiological* mode of classification can be applied to the muscular system, but the former is of course the one adopted here. Again, muscles may be classed





MUSCLES OF THE HORSE—SUPERFICIAL. LAYER—after Magnin.


## EXPLANATION OF PLATE II.

### MUSCLES OF THE HORSE.

#### *Superficial Layer.*

*The panniculus and tunica abdominalis are removed.*

- |   |  |
|---|--|
| 1. Abducens.                                | 33. Extensor metacarpi magnus.               |
| 2. Retrahentes muscles.                     | 34. Humeralis obliquus.                      |
| 2'. Attollens maximus.                      | 35. Extensor pedis.                          |
| 2''. Attollens anticus.                     | 36. Flexor metacarpi externus and<br>medius. |
| 3. Temporalis.                              | 37. Flexor metacarpi internus.               |
| 4. Nasalis longus.                          | 46. Cervical                                 |
| 5. Orbicularis palpebrarum.                 | 47. Dorsal } serratus magnus.                |
| 6. Levator labii superioris alæque<br>nasi. | 48. Rhomboideus longus.                      |
| 7. Dilatator naris lateralis.               | 49. Superficialis costarum.                  |
| 8. Orbicularis oris.                        | 50. Splenius.                                |
| 9. Zygomaticus.                             | 52. Intercostales.                           |
| 9'. Buccinator.                             | 54. Tensor fasciæ latæ.                      |
| 10. Depressor labii inferioris.             | 55. Triceps abductor femoris.                |
| 11. Masseter.                               | 56. Gluteus externus.                        |
| 12. Levator humeri.                         | 61. Biceps rotator tibialis.                 |
| 13. Trapezius cervicalis.                   | 62. Rectus femoris.                          |
| 14. Trapezius dorsalis.                     | 63. Vastus externus.                         |
| 15. Latissimus dorsi.                       | 65. Gastrocnemius                            |
| 18. Pectoralis parvus.                      | 68. Flexor pedis perforans.                  |
| 19. Pectoralis magnus.                      | 69. Peroneus.                                |
| 20. Sterno-maxillaris.                      | 70. Extensor pedis.                          |
| 23. Subscapulo-hyoideus.                    | 71. Flexor metatarsi.                        |
| 24. Antea-spinatus.                         | 72. Flexor pedis accessorius.                |
| 25. Teres externus.                         | 74. Obliquus abdominis externus.             |
| 26. Postea-spinatus.                        |  |
| 30. Caput medium } of the triceps           |  |
| 31. Caput magnum } extensor brachii.        |  |





anatomically either according to their attachments or to the regions their fleshy portions chiefly cover. Although a *nomenclature* based upon the attachments of muscles is most valuable, a descriptive classification so constructed would lead to confusion, hence we group the muscles according to the regions they mainly occupy, and divide them primarily into those covering each of the following regions:—

Subcutaneous region.

Head.

Trunk.

Pectoral limb.

Pelvic limb.

We shall describe them in the above order, subdividing each region as may be necessary.

## MUSCLES.

### SUBCUTANEOUS REGION.

#### PANNICULUS CARNOSUS.

(*Musculus Subcutaneus.*)

After carefully removing the skin and subcutaneous cellular tissue, the first muscle which presents itself is one peculiar to quadrupeds, the *Panniculus carnosus*. This muscle is spread over the greater part of the body, and may be divided into facial, cervical, thoracic, and abdominal portions, but as these are continuous with each other, we can conveniently describe the whole as a single structure. The panniculus, as a whole, is aponeurotic superiorly, becoming more and more fleshy as it descends. It is firmly attached to the skin by connective tissue.

The facial portion consists of an aponeurotic expansion, which becomes muscular over the muscles situated below and before the zygoma. Its fibres are arranged in a divergent manner, radiating from the angle of the maxilla, and a portion is inserted to the orbicular muscle of the mouth, forming the Retractor anguli oris (*Risorius Santorini*). Posteriorly it unites with the cervical portion, which is likewise chiefly aponeurotic, commencing in front of the neck by a thin muscular band, it joins its fellow the median line by a fibrous *raphe*, and covers the muscles of the inferior cervical region. Above it becomes

aponeurotic, and is attached to the ligamentum nuchæ, while infero-laterally it becomes more fleshy, and is inserted to the anterior portion of the cariniform cartilage; some describe this portion as a part of the Levator humeri, the panniculus being firmly blended with that muscle inferiorly. The thoracic portion is continuous with the cervical at the sternum, and passes over the front of the shoulder superiorly, covering its external side; it is attached to the dorsal spines together with the trapezius. The abdominal portion forms a broad oval-shaped fleshy expansion, its fibres running from the flank to the shoulder; it is thick and fleshy behind the arm, where it has a well-marked, flat tendinous attachment to the skin, and below which a tendinous expansion penetrates between the chest and the limb, and is attached to the Pectoralis magnus and internal trochanter of the humerus. Posteriorly, by a strong band, fleshy and aponeurotic, it reaches the stifle joint and fascia of the thigh; above, it reaches the lumbar and dorsal spines, and below it becomes blended with the abdominal fascia.

*Relation.*—It is related externally with the skin; internally with the superficial layer of muscles.

*Action.*—It corrugates the skin, and thus enables the animal to expel insects and irritating bodies, its use being thus protective; to some extent it also supports and binds down the subjacent muscles.

### THE HEAD.

The muscles of this region may be divided into the following groups:—

- Anterior maxillary.
- Posterior maxillary.
- Hyoidean.
- Palpebral.
- Auricular.

In addition to these we have the Glossal, Pharyngeal, and Laryngeal groups also associated with the head; the two first of these will be more appropriately described hereafter when treating of the Tongue and Pharynx, and the last along with the Larynx.

ANTERIOR MAXILLARY GROUP.

In the broad sense this group occupies the anterior half of the skull, certain of the muscles extending further backwards; it consists of the following muscles :—

Zygomaticus.		Dilatator naris transversus.
Buccinator.		Dilatator naris inferioris.
Orbicularis oris.		Dilatator naris superioris.
Levator labii superioris alæque		Depressor labii superioris.
Nasalis longus. [nasi.		Levator labii inferioris.
Dilatator naris lateralis.		Depressor labii inferioris.

ZYGOMATICUS.

(*Zygomatico-labialis.*)

(PL. II. 9.)

A ribbon-shaped muscle, very pale and small, situated on the side of the face, its fibres extending forwards.

*Attachments.*—It arises from the fascia of the masseter, near the anterior aspect of the maxillary spine, being blended with the panniculus, and is inserted near the angle of the mouth, its fibres blending with the buccinator.

*Action.*—It retracts the angle of the mouth.

BUCCINATOR.

(*Alveolo-labialis.*)

(PL. II. 9. FIG. 70. i.)

Situated on the side of the face, covering the diastema and molar teeth, this muscle is flat and thin, and consists of two layers, sometimes described as separate muscles.

*Attachments.*—The internal layer arises, under the masseter, from the alveolar tuberosity, and alveoli of the molar teeth of both jaws, and blends with the orbicularis oris. The external layer exists only anteriorly, and is penniform, its fibres being inserted along the interdental spaces.

*Relations.*—This muscle is related superiorly with the molar glands, postero-externally with the masseter, and internally with the buccal membrane.

*Action.*—It retracts the angle of the mouth, but specially serves to force the food between the molars, and to prevent the buccal membrane from being injured by the latter.

ORBICULARIS ORIS.

(*Labialis.*)

(PL. II. 8.)

This is a *sphincter* or annular constrictor muscle, and as such has virtually neither origin nor insertion; surrounding the mouth and forming the substance of the lips, it is separable into two layers, and is related internally with the mucous membrane of the mouth and the labial glands, and externally with the skin, to which it is firmly adherent. It is the intrinsic muscle of the lips, and receives for the most part the insertions of the extrinsic muscles.

*Action.*—It is the constrictor of the anterior aperture of the mouth, and also assists in mastication, suction, and prehension of food.

LEVATOR LABII SUPERIORIS ALÆQUE NASI.

(*Supernaso-labialis.*)

(PL. II. 6.)

Situated superiorly, on the side of the cheek, running forwards and downwards, this muscle is long, flat, and aponeurotic superiorly, dividing into two unequal bands, between which passes the dilatator naris lateralis.

*Origin.*—It arises from the frontal and nasal bones, the anterior division, the larger and thicker, passing under the dilatator above named.

*Insertion.*—To the nostril and upper lip, the posterior division reaching the angle of the mouth.

*Action.*—It raises the upper lip and angle of the mouth, and dilates the nostril.

NASALIS LONGUS.

(*Supermaxillo-labialis.*)

(PL. II. 4. FIG. 70. g.)

Situated below the preceding muscle, this muscle runs horizontally forwards. In shape it is pyramidal, with a fleshy belly and a long tendon of insertion.

*Origin.*—It arises from the surface of the superior maxilla, at its junction with the malar and lachrymal bones.

*Insertion.*—The tendon passes to the extremity of the nose, where, joining its fellow, it forms a radiating expansion, becoming lost in the upper lip.

*Action.*—It elevates and corrugates the upper lip, if acting with its fellow ; if acting alone, it pulls the lip to one side.

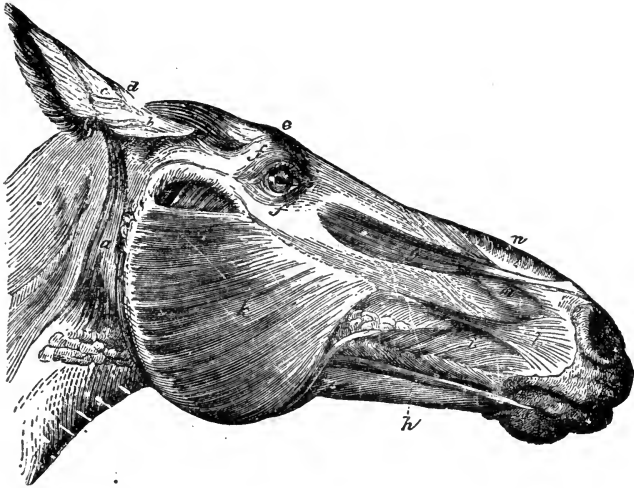


FIG. 70.

Muscles of the head—left lateral view. *a*, Abducens ; *b c d*, Scuto-auricularis externus, inferior, middle, and superior portions ; *e*, Levator palpebræ superioris externus ; *f f*, Orbicularis palpebrarum ; *g*, Nasalis longus ; *h*, Depressor labii inferioris ; *i*, Buccinator ; *k*, Masseter ; *l*, Dilatator naris lateralis ; *m*, Dilatator naris inferioris ; *n*, Dilatator naris superioris.

#### DILATATOR NARIS LATERALIS.

(*Pyramidalis—Supermaxillo-nasalis Magnus.*)

(PL. II. 7. FIG. 70. *l*.)

This muscle is situated on the side of the cheek, between the branches of the levator labii superioris, extending horizontally ; it has a flat belly and tendon of origin.

*Attachments.*—It arises from the anterior extremity of the maxillary spine ; it is inserted to the side of the nostril and the upper lip, blending with the orbicularis oris.

*Action.*—It dilates the nostril, acting on its external wing.

## DILATATOR. NARIS TRANSVERSALIS.

*(Naso transversalis.)*

Situated at the supero-anterior extremity of the nose, in front of the nostrils, it is single, flat, and four-sided, consisting of transverse fibres which cross each other.

*Origin.*—The nasal peak.

*Insertion.*—The superior surface of the cartilaginous alæ of the nostrils.

*Action.*—It dilates the nostrils.

## DILATATOR NARIS INFERIORIS.

*(FIG. 70. m.)**(Nasalis Brevis Labii Superioris—Supermaxillo-nasalis Brevis.)*

Another long and four-sided muscle, situated at the side of, and a little behind the nostrils.

*Origin.*—It arises by an aponeurotic origin from the upper free margin of the superior maxilla and premaxilla.

*Insertion.*—The skin of the false nostril.

*Action.*—It dilates the nostril.

## DILATATOR NARIS SUPERIORIS.

*(FIG. 70. n.)*

Situated just above the preceding, it is broad and thin, with aponeurotic attachments.

*Origin.*—From the lateral surface of the free margin of the nasal bone.

*Insertion.*—The skin of the false nostril.

*Action.*—To assist the preceding muscle.

## DEPRESSOR LABII SUPERIORIS.

Situated on the inner surface of the upper lip, covered by mucous membrane, it is thin and fleshy.

*Origin.*—From the premaxilla at the alveoli, extending from the lateral incisors to the tushes.

*Insertion.*—The diverging fibres pass obliquely forwards to blend with the upper lip and nasal cartilages.

*Action.*—It compresses the upper lip, and perhaps assists in dilating the nostril.

## LEVATOR LABII INFERIORIS.

(*Levator Mentis.*)

Situated on the inner surface of the under lip, below the mucous membrane, it is like the preceding in shape.

*Origin.*—From the alveoli of the inferior maxilla, between the lateral incisors and tushes.

*Insertion.*—The under lip by diverging fibres.

*Action.*—It elevates the under lip and chin, and presses the lip on the teeth.

## DEPRESSOR LABII INFERIORIS.

(*Maxillo-labialis.*)

(PL. II. 10. FIG. 70. h.)

Situated along the surface of the lower jaw, it is in shape long and pyramidal.

*Origin.*—Posteriorly, in common with the buccinator, from the alveolar tuberosity, and the superior border of the inferior maxilla, behind the molar alveoli.

*Insertion.*—The infero-lateral part of the under lip by a flat tendon.

*Action.\**—To depress the under lip.

## POSTERIOR MAXILLARY GROUP.

The muscles constituting this group are chiefly those of mastication, which act upon the temporo-maxillary joint. They are as follows :—

Masseter.		Pterygoideus internus.
Temporalis.		Pterygoideus externus.
Stylo-maxillaris.		Digastricus.

\* [While dissecting at the Edinburgh Veterinary College in December, 1868, I was particularly struck with the action of this muscle ; its tendon subdivides in the areolar and muscular tissue of chin and posterior lip, and its action is not quite to depress the under lip, but to elevate the chin and lower lip, and thus separate the lower lip from the lower incisors. This is the opinion, I find, recorded by the late Professor Goodsir in his posthumous manuscript.—Ed., *First Edition.*]

## MASSETER.

*(Zygomatico-maxillaris.)*

(Pl. II. 11. FIG. 70. k.)

Situated on the posterior part of the cheek, of which it forms the large fleshy portion, it is broad, thick, flat, and irregularly four-sided, consisting of several layers, intersected by tendinous bands, and enclosed in a strong aponeurosis.

*Origin.*—From the zygoma, the spine and external surface of the superior maxilla.

*Insertion.*—The outer surface, posterior border, and angle of the inferior maxilla.

*Relation.*—Externally with the facial panniculus. Over its surface are distributed the facial nerves, and along its anterior border lies the parotid duct, and the facial artery and vein; buried beneath its substance is the alveolar vein or vena varicosa.

*Action.*—To elevate the lower jaw and close the mouth, being an important muscle in mastication.

## TEMPORALIS.

*(Temporo-maxillaris.)*

(Pls. II. 3; III. 1.)

Situated in the temporal fossa, which it fills, this muscle is strong and fleshy, intersected by tendon, and covered by fascia.

*Origin.*—From the parietal ridge, and part of the occipital crest, the zygomatic process of the temporal and the external surface of the parietal bones.

*Insertion.*—The coronoid process of the inferior maxilla.

*Relation.*—Externally with the muscles of the ear, and the scutiform cartilage; inferiorly with the pterygoid muscles. A pad of fat lies between it and the orbital fossa.

*Action.*—With its fellow it assists in closing the mouth; singly it gives slight lateral motion to the lower jaw.

## STYLO-MAXILLARIS.

(Pl. III. 1.)

Situated behind the lower jaw, it is pyramidal and fleshy.

*Origin.*—From the styloid process of the occiput.



*Insertion.*—The posterior angle and inner margin of the lower jaw.

*Relation.*—Externally with the parotid gland; internally with the guttural pouch.

*Action.*—It depresses the lower jaw and draws it backwards.

#### PTERYGOIDEUS INTERNUS.

(*Masseter Internus—Spheno-maxillaris.*)

Situated on the inner surface of the lower jaw, in the maxillary space, corresponding internally to the masseter, it is strong and fleshy, with numerous tendinous intersections.

*Origin.*—From the pterygoid process of the sphenoid bone, and the palatine ridge.

*Insertion.*—The inner posterior border and angle of the inferior maxilla.

*Relation.*—Posteriorly with the pterygoideus externus and temporalis; internally with the guttural pouch, the hyoid bone, and its muscles; externally with the ramus of the maxilla and the inferior maxillary nerve and vessels.

*Action.*—Acting with its fellow, it raises the jaw and closes the mouth; when acting singly, it produces lateral motion.

#### PYTERYGOIDEUS EXTERNUS

(*Part of Spheno-maxillaris.*)

Situated behind the preceding, on the front and inner side of the temporo-maxillary articulation, it is short, thick, and fleshy, with slight tendinous intersections.

*Origin.*—From the ala and pterygoid process of the sphenoid bone.

*Insertion.*—Passing backwards and downwards, it reaches a roughened depression on the inner side of the inferior maxilla, just below its condyle.

*Relation.*—With the temporalis and the pyterygoideus internus, which is below and before it.

*Action.*—It assists the internus, and also draws the lower jaw forwards, antagonising the stylo-maxillaris.

## DIGASTRICUS.

Situated along the inner surface of the lower jaw, in the maxillary space, it contains two fleshy bellies, united by a median tendon.

*Origin.*—From the styloid process of the occipital bone.

*Insertion.*—By a diffused tendon to the inner surface of the lower jaw, towards its symphysis; the mesian tendon plays through a groove formed by the tendon of the hyoideus magnus, at the body of the hyoid bone. The posterior belly gives off also a bundle which is inserted to the posterior border of the ramus, considerably above the angle.

*Action.*—It elevates the hyoid bone, retracts and depresses the inferior maxilla.

## HYOIDEAN GROUP.

The muscles of this group are six in number and they act chiefly upon the hyoid series of bones. Their names are as follows:—

Mylo-hyoideus.		Hyoideus parvus.
Genio-hyoideus.		Hyoideus transversus.
Hyoideus magnus.		Stylo-hyoideus.

## MYLO-HYOIDEUS.

Situated in the maxillary space, along the inner side of the lower jaw, it is broad, flat, and penniform, and attached to a line running along the inferior maxilla, just below the alveolar processes; extending forwards as far as the symphysis, and to the inferior surface of the body and spur process of the hyoid bone, it meets its fellow of the opposite side in the median line.

*Relation.*—Externally with the inferior maxilla, the digastricus and the lymphatic glands; internally with the sublingual gland, Wharton's canal, the genio-hyoideus, hyo-glossus longus, genio-hyo-glossus, and the hypoglossal and lingual nerves; posteriorly with the pterygoidei-muscles.

*Action.*—By drawing the os hyoides upwards and forwards it elevates the tongue, forming a kind of muscular sling in which the latter organ lies.

## GENIO-HYOIDEUS.

(Fig. 71. e.)

Covered by the preceding muscle, this is long, fusiform, and tendinous at its extremities.

*Origin.*—From the lower jaw, near its symphysis.

*Insertion.*—The free extremity of the spur process of the os hyoides.

*Relation.*—Externally with the preceding muscle, superiorly with the genio-hyo-glossus, and internally with its fellow.

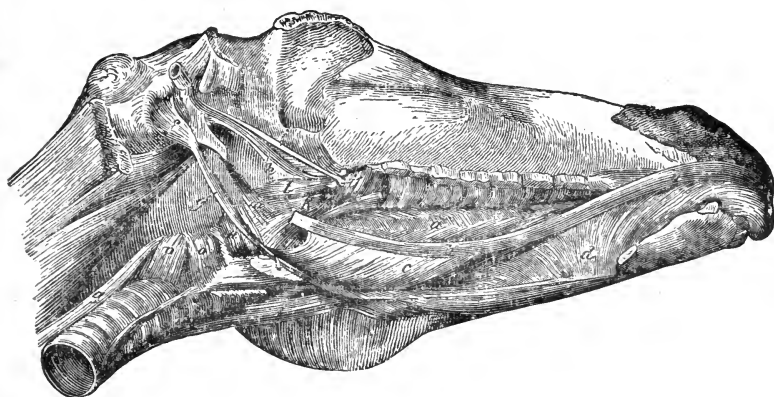


FIG. 71.

*Muscles of the maxillary space—infero-lateral view. Structures removed from the right side. e, Genio-hyoideus; f, Stylo-hyoideus; g, Hyoideus magnus.*

*Action.*—It draws the os hyoides towards the antero-inferior part of the maxillary space.

## HYOIDEUS MAGNUS.

*(Kerato-hyoideus Magnus.)*

(Fig. 71. g.)

Situated on the outer side of the pharynx, larynx, and guttural pouch, behind the cornu of the os hyoides and running in the same direction, it is thin, fusiform, and tendinous at either extremity.

*Origin.*—From the postero-inferior angle of the cornu of the os hyoides.

*Insertion.*—To a small tubercle on the heel process of the os hyoides.

*Relation.*—Externally with the pterygoid muscle; internally with the pharynx, guttural pouch, and hypoglossal nerve; the glosso-facial artery and glosso-pharyngeal nerve pass between it and the cornu. The anterior tendon forms a ring through which plays the middle tendon of digastricus.

*Action.*—It draws the body of the os hyoides backwards and upwards, thus antagonising the preceding muscle; it also assists in dilating the glottis.

#### HYOIDEUS PARVUS.

(*Kerato-hyoideus Parvus.*)

Situated above and before the preceding muscle, it is small, flat, and triangular.

*Origin.*—From the inferior border of the anterior extremity of the cornu, and the posterior border of the corniculum.

*Insertion.*—To the body and heel process of the os hyoides, filling up the space between the three bones.

*Relation.*—Externally with the hyo-glossus and the lingual arteries; internally with the mucous membrane.

*Action.*—It approximates the three bones to which it is attached.

#### HYOIDEUS TRANSVERSUS.

A short, thin muscle, joining the cornicula together by their superior extremities, which on contraction it approximates.

#### STYLO-HYOIDEUS.

(Fig. 71. f.)

Flat and triangular, it fills up the space between the posterior part of the angle of the cornu, and the styloid process of the occipital bone.

*Origin.*—The anterior border of the styloid process.

*Insertion.*—The posterior part of the cornu.

*Relation.*—Externally with the parotid gland, and internally with the guttural pouch. Its posterior fibres blend with those of the origin of the digastricus.

*Action.*—It draws back and depresses the os hyoides.

## PALPEBRAL GROUP.

The palpebral, or muscles of the eyelids are four in number, named as follows :—

- Orbicularis palpebrarum.
- Lachrymalis.
- Levator palpebræ superioris externus.
- Levator palpebræ superioris internus.

## ORBICULARIS PALPEBRARUM.

(*Musculus Ciliaris.*)

(PL. II. 5. FIG. 70. ff.)

A large, thin, oval sphincter, common to the upper and lower eyelids, and situated around them.

*Attachments.*—It is covered by the skin, to which it intimately adheres. The superior portion is the larger, and consists of numerous fleshy fasciculi, with a small flat tendon which is attached to the lachrymal tubercle, near the nasal angle of the eye.

*Action.*—It closes the eyelids.

## LACHRYMALIS.

(*Lachrymo-Labialis.*)

A very thin muscle placed below and before the orbit, continuous with the levator labii superioris in front, the panniculus behind, and the orbicularis palpebrarum above. It becomes blended with the buccinator.

## LEVATOR PALPEBRÆ SUPERIORIS EXTERNUS.

(*Fronto-superciliaris.*)

(FIG. 70. e.)

Situated immediately above the orbit, it is subcutaneous, short, thin, and narrow.

*Attachments.*—It arises from the external surface of the frontal bone, near the supra-orbital foramen. The fibres pass downwards and outwards, blending with the orbicularis at the superior part of the lid, towards the inner angle of the eye.

*Relation.*—Externally with the skin; internally with the bone.

*Action.*—It corrugates the skin of the upper eyelid, but is scarcely a levator.

#### LEVATOR PALPEBRÆ SUPERIORIS INTERNUS.

(*Orbito-palpebralis.*)

Situated within the orbital fossa, in relation with the superior straight muscle of the eyeball, this muscle is narrow, thin, and band-like.

*Origin.*—From the superior border of the optic foramen, on a level with the lachrymal gland, passing under which it becomes aponeurotic, running between the conjunctiva and the fibrous portion of the upper lid.

*Insertion.*—To the inner surface of the lid, and the tarsal cartilage.

*Action.*—It raises the upper eyelid.

#### AURICULAR GROUP.

The external muscles of the ear consist of an extrinsic and an intrinsic group. The extrinsic muscles, eight in number, are as follows :—

Attollens maximus.	Retrahens externus.
Attollens anticus.	Retrahens medius.
Attollens posticus.	Retrahens internus.
Abducens.	
Mastoido-auricularis.	

#### ATTOLLENS MAXIMUS.

(*Temporo-auricularis Externus.*)

(PL. II. 2.)

Situated immediately under the skin, above the temporal muscle, and in front of the inner side of the ear, it is broad, thin, and fleshy.

*Origin.*—From the whole of the parietal crest, joining its fellow in the mesian line posteriorly.

*Insertion.*—To the scutiform cartilage, sending a small band to the internal border of the base of the conchal cartilage.

*Relation.*—Externally with the skin; internally with the temporalis and attollens posticus; posteriorly with the retrahens externus.

*Action.*—It adducts and elevates the ear, and also turns its opening forwards.

ATTOLLENS ANTICUS.

(*Zygomatico-auricularis.*)

(Pl. II. 2'.)

Subcutaneous, and in front of the ear, this muscle is small and thin, consisting generally of two fleshy bundles, joined by condensed cellular tissue.

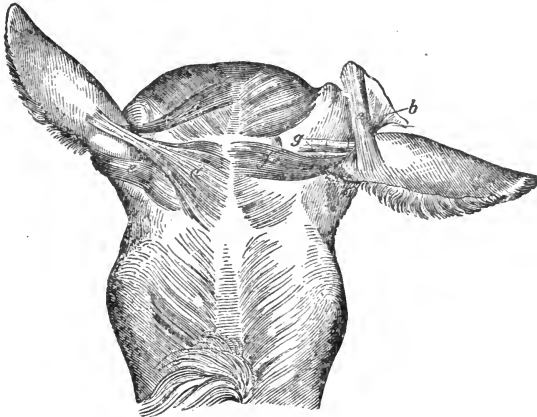


FIG. 72.

Muscles of the external ear—posterior view. *a*, Inferior, and *b*, superior layer of the scuto-auricularis internus; *c*, Attollens posticus; *d*, Retrahens externus; *e*, Retrahens medius; *f*, Retrahens internus; *g*, Mastoido-auricularis.

*Origin.*—From the superior part of the temporal zygomatic process by a flat tendon, which blends in front with the orbicularis palpebrarum.

*Insertion.*—By two sets of fibres—one to the anterior part of the scutiform, the other to base of the conchal cartilage, blending with the scuto-auricularis externus and the abducens.

*Relation.*—Externally with the skin; internally with the temporal muscle; posteriorly with the parotid gland.

*Action.*—It draws the ear forwards.

## ATTOLLENS POSTICUS.

*(Temporo-auricularis Internus.)*

(FIG. 72. c.)

This is a triangular muscle of a bright-red colour, situated under the attollens maximus.

*Origin.*—From the parietal crest, and by cellular tissue from the temporalis.

*Insertion.*—The tendon is directed obliquely round the internal face of the concha, terminating in the conchal cartilage, below the insertion of the retrahens externus.

*Relation.*—Externally with the maximus; internally with the temporalis.

*Action.*—It elevates and adducts the ear.

## RETRAHENS EXTERNUS.

*(Cervico-auricularis Externus.)*

(FIG. 72. d.)

Situated on the poll, at the side of the ear, it is thin and flat, joining the attollens maximus.

*Origin.*—From the cordiform portion of the ligamentum nuchæ.

*Insertion.*—To the middle of the posterior surface of the conchal cartilage.

*Relation.*—Externally with the skin; internally with the retrahens internus and medius.

*Action.*—It draws the ear backwards and downwards.

## RETRAHENS MEDIUS.

*(Cervico-auricularis Medius.)*

(FIG. 72. e.)

Broad and thin; situated below the preceding.

*Origin.*—The same as the externus.

*Insertion.*—To the external part of the base of the concha under the abducens, its tendon passing over the superior portion of the parotid gland.

*Relation.*—Externally with the preceding muscle; internally with the internus and the parotid gland.

*Action.*—It rotates the ear, turning the opening backwards.



## RETRAHENS INTERNUS.

*(Cervico-auricularis Internus.)*

(FIG. 72. f.)

Thin, fleshy, and situated below the preceding muscle.

*Origin.*—The same as the two last named.

*Insertion.*—To the dilated lower part of the conchal cartilage.

*Relation.*—Externally with the medius and the parotid gland.

*Action.*—It assists the medius.

## MASTOIDO-AURICULARIS.

(FIG. 72. g.)

Situated deeply, at the base and inner side of the concha, this muscle is very small, flat, and slender.

*Origin.*—From the external auditory meatus

*Insertion.*—To the base of the concha.

*Action.*—It draws the concha downwards, and thus shortens the external ear.

## ABDUCENS.

*(Deprimens Aures—Parotido-auricularis.)*

(PL. II. 1. FIG. 70. a.)

Situated below the root of the ear, and on the outer side of the parotid gland, it is flat and thin below, narrower and thicker above.

*Origin.*—From the external surface of the parotid gland.

*Insertion.*—To the external part of the base of the concha.

*Relation.*—Externally with a thin aponeurotic portion of the panniculus; internally with the parotid gland.

*Action.*—It draws the ear downwards and outwards.

## INTRINSIC MUSCLES.

The intrinsic muscles of the external ear are the scuto-auricularis, externus and internus.

## SCUTO-AURICULARIS EXTERNUS.

(FIG. 70. *b. c. d.*)

*Origin.*—From the external surface of the scutiform cartilage.

*Insertion.*—To the inner side of the conchal cartilage. It is composed of three bundles, covered by the attollens maximus, and it assists that muscle to turn the opening of the ear forwards.

## SCUTO-AURICULARIS INTERNUS.

(FIG. 72. *a. b.*)

It consists of two pale bundles which cross each other.

*Origin.*—The under surface of the scutiform cartilage, the fibres being directed backwards.

*Insertion.*—The posterior portion of the base of the concha.

*Action.*—It turns the opening of the ear outwards and backwards, thus antagonising the externus.

## MUSCLES OF THE TRUNK.

This large division includes the rest of the muscles, excepting those which more especially belong to the limbs. We shall divide the trunk into the following regions, thus indicating the groups into which the muscles most naturally fall :—

Cervical.	Diaphragmatic.
Pectoral.	Dorso-lumbar.
Costal	Sublumbar.
Abdominal.	Coccygeal.

## CERVICAL REGION.

The muscles of the neck may be said to consist of an *inferior* and two *lateral groups*, the latter lying on each side of the central division formed by the vertebræ and the ligamentum nuchæ, and the former being situated underneath the vertebræ.

## INFERIOR CERVICAL GROUP.

The following muscles, eight in number, may be placed in this group :

Sterno-maxillaris.	Rectus capitis anticus minor.
Sterno-thyro-hyoideus.	Rectus capitis lateralis.
Subscapulo-hyoideus.	Scalenus.
Rectus capitis anticus major.	Longus colli.

STERNO-MAXILLARIS.

(Pl. II. 20.)

Placed along the lower border of the levator humeri, this muscle is long, narrow, and flat, its fibres extending forwards and upwards; it is fleshy, terminating in a flat tendon.

*Origin.*—From the anterior portion of the cariniform cartilage; it is united to its fellow along its inferior third.

*Insertion.*—To the angle of the lower jaw.

*Relation.*—Externally with the panniculus and the parotid gland; internally with the sterno-thyro-hyoideus and subscapulo-hyoideus, the trachea and carotid artery; the jugular vein runs along its superior border.

*Action.*—Acting with its fellow, it flexes the head downwards, or singly, it turns the head to one side.

STERNO-THYRO-HYOIDEUS.

(*Sterno-thyroideus and Sterno-hyoideus.*)

(Pl. III. 3.)

This is a slender muscle situated in front of the trachea; it is narrow, ribbon-shaped, and divided into two parts. Fleshy at its crigin, it divides half way up the neck into two portions, each having a tendon of insertion. About their middle the sterno-thyro-hyodei have tendinous intersections, which render them more or less *digastric*.

*Origin.*—From the superior part of the cariniform cartilage, intimately blended with its fellow.

*Insertion.*—By one tendon, to the postero-inferior part of the thyroid cartilage, and by the other to the spur process of the os hyoides.

*Relation.*—Inferiorly with the sterno-maxillaris; superiorly with the trachea.

*Action.*—It depresses the hyoid bone, and with it the larynx and base of the tongue.

## SUBSCAPULO-HYOIDEUS.

(Pl. II. 23.)

More laterally situated than the last, this muscle is broad, thin, and elongated, its fibres extending forwards and upwards. Aponeurotic at its origin, it is followed by a long, flat, fleshy belly, ending in a flat tendon, which joins that of the sterno-hyoideus.

*Origin.*—From the fascia covering the subscapularis muscle.

*Insertion.*—To the inferior border of the spur process of the os hyoides.

*Relation.*—Externally with the subscapularis, pectoralis parvus, and sterno-maxillaris, blending also with the levator humeri; internally with the muscles on the inner aspect of the shoulder, the scalenus and rectus capitis anticus major, the trachea and the carotid sheath.

*Action.*—It depresses the hyoid apparatus.

## RECTUS CAPITIS ANTICUS MAJOR.

*(Trachelo-suboccipitalis.)*

(Pl. III. 2.)

This is the long flexor of the head, and is situated along the anterior half of the region. It is long, and has a flattened, fleshy belly, converging from two or three slips of origin, and terminating anteriorly in a conical tendon.

*Origin.*—Posteriorly, from the transverse processes of the third, fourth, and fifth cervical vertebræ.

*Insertion.*—To the basilar process of the occipital and body of the sphenoid bone.

*Relation.*—Externally with the levator humeri, and subscapulo-hyoideus; internally with its fellow and the longus colli; anteriorly with the guttural pouch and carotid artery, and superiorly with the occipito-atloid joint, and rectus capitis anticus minor.

*Action.*—With its fellow it flexes the head downwards; when acting singly, it flexes it laterally.

## RECTUS CAPITIS ANTICUS MINOR.

*(Atlido-suboccipitalis.)*

(FIG. 75. c.)

This, the short flexor of the head, is situated on the inner and upper side of the preceding muscle, and is short, slender, and almost entirely fleshy.

*Origin.*—Posteriorly, from the lower part of the body of the atlas.

*Insertion.*—To the basilar process of the occipital, and body of the sphenoid bone, by the preceding muscle.

*Relation.*—Infero-externally with the rectus major; superiorly with the capsular ligament of the occipito-atloid articulation.

*Action.*—It assists in flexing the head.

## RECTUS CAPITIS LATERALIS.

*(Atlido-styloideus.)*

(FIG. 75. b.)

This muscle, still smaller than the last and like it in structure, is placed rather more externally.

*Origin.*—From the inferior part of the ring of the atlas, on the outer side of the rectus minor.

*Insertion.*—To the styloid process of the occipital bone.

*Relation.*—Inferiorly with the rectus major; superiorly with the capsular ligament of the occipito-atloid articulation; externally with the parotid gland.

*Action.*—It assists the preceding muscles.

## SCALENUS.

*(Costo-cervicalis.)*

(PL. III. 6.)

Situated at the postero-inferior part of the region, at the side of the anterior aperture of the thoracic cavity, the scalenus is triangular in shape, and divided into a superior or posterior, and an inferior or anterior portion; the fibres run forwards and upwards, and form several fleshy masses, with strong tendinous

intersections. The anterior portion is the larger, flat from side to side, and thin in front.

*Origin of the Anterior Portion.*—From the transverse processes of the last four cervical vertebræ by short fleshy fasciculi.

*Insertion.*—The anterior and outer border of the first rib.

*Origin of the Posterior Portion.*—From the transverse processes of the last three or four cervical vertebræ.

*Insertion.*—To the superior part of the first rib.

*Relation.*—Superiorly with the intertransversalis colli; inferiorly with the sterno-maxillaris; externally with the levator humeri, pectoralis parvus, and subscapulo-hyoideus; internally with the trachea and carotid artery, and on the left side with the œsophagus. Across its inferior border runs the jugular vein, and between its anterior and posterior portions pass the nerves of the brachial plexus.

*Action.*—When the first rib is fixed, together these muscles extend the neck; acting singly, each turns it to one side. When the neck is fixed, by drawing the first rib forward and supporting it, it acts as an inspiratory muscle.

#### LONGUS COLLI.

(*Subdorso-atloideus.*)

(FIG. 75. a.)

In the horse this is a single muscle, situated under the centra of the cervical and anterior dorsal vertebræ. The dorsal portion is fleshy, the cervical being made up of smaller fasciculi, convoluted and intersected by tendinous fibres. The fasciculi run inwards and forwards.

*Origin.*—From the inferior surface of the centra of the first six dorsal, and the inferior spines and transverse processes of the six posterior cervical vertebræ.

*Insertion.*—By a strong tendon to the inferior spine or tubercle of the atlas; it is also strongly attached to the second cervical segment.

*Relation.*—Externally and anteriorly with the rectus capitis anticus major; externally and posteriorly with the scalenus; inferiorly with the trachea, œsophagus, blood-vessels, and nerves; superiorly with the vertebræ. The dorsal portion is related with the pleura and sympathetic nerves.

*Action.*—It flexes the neck downwards, and moves one vertebra on another.

## LATERAL CERVICAL GROUP.

This is a numerous group, but one difficult of satisfactory subdivision. The following Table enumerates the muscles in the order in which they may be conveniently demonstrated :—

Levator humeri.	Complexus minor.
Trapezius cervicalis.	Rectus capitis posticus major.
Rhomboideus longus.	Rectus capitis posticus minor.
Serratus magnus (a portion).	Obliquus capitis anticus.
Splenius	Obliquus capitis posticus.
Trachelo-mastoideus.	Spinalis colli.
Complexus major.	Intertransversalis colli.

## LEVATOR HUMERI.

(*Mastoido-humeralis.*)

(Pl. II. 12.)

Occupying the infero-lateral part of the neck, this muscle is large, flat, and elongated, extending downwards from the back of the head to the arm. Its fleshy portion is divisible into deep and superficial parts, the first being placed anteriorly.

*Attachments.*—Anteriorly, by one tendon to the crest of the occiput and the mastoid process of the temporal bone; by the other to the wing of the atlas, this tendon being also common to the splenius and trachelo-mastoideus; to the transverse processes of the second, third, and fourth cervical vertebræ, and the fascia of the neck. Covering the shoulder joint, it is attached to a line extending downwards from the deltoid ridge; and to the fascia of the muscles of the shoulder and arm, joining the scapular fascia by an aponeurotic expansion continuous also with the fascia of the cervical trapezius.

*Relation.*—Externally with the panniculus; inferiorly with the carotid artery, jugular vein, and sterno-maxillaris; internally with the splenius, trachelo-mastoideus, rectus capitis anticus major, scalenus, serratus magnus, and other muscles; anteriorly with the parotid gland. It is connected with the ligamentum nuchæ by the aponeurosis of the panniculus, and infero-laterally becomes

blended with that muscle; hence it may be said to have an indirect sternal attachment.

*Action.*—When the head is fixed, it advances the entire limb; if the limbs are fixed, it aids in turning the head and neck to one side, or with its fellow in depressing them.

#### TRAPEZIUS CERVICALIS.

(*Cervico-acromialis.*)

(Pl. II. 13.)

Situated supero-posteriorly, this, the cervical portion of the trapezius muscle, is thin, flat, and triangular, its fibres converging downwards and backwards. It is aponeurotic above, and posteriorly, where it joins the dorsal portion.

*Origin.*—From the funicular portion of the ligamentum nuchæ.

*Insertion.*—With the dorsal trapezius to the spine of the scapula, at its tubercle, and to the scapular fascia.

*Relation.*—Externally with fascia from the levator humeri and panniculus; internally with the splenius, serratus magnus, rhomboideus longus, pectoralis parvus, and antea spinatus.

*Action.*—It elevates, and draws the shoulder forwards.

#### RHOMBOIDEUS LONGUS.

(*Cervico-subscapularis.*)

(Pl. III. 9.)

It is placed on the supero-lateral part of the neck, just below the cordiform portion of the ligamentum nuchæ. It appears as a tapering triangle, widest posteriorly, and very fleshy in its structure.

*Origin.*—From the funicular portion of the ligamentum nuchæ, as high as the second cervical vertebra.

*Insertion.*—To the inner surface of the anterior angle of the scapula, and to its cartilage of prolongation, just above the serratus magnus.

*Relation.*—Externally with the cervical trapezius; inferiorly with the splenius; posteriorly with the rhomboideus brevis, with which it blends; internally with the ligamentum nuchæ.

*Action.*—To elevate and draw the scapula forwards.



## SERRATUS MAGNUS.

(PL. III. 10.)

The cervical portion of the serratus magnus will be described with the costal portion. (See costal region.)

## SPLENIUS.

*(Cervico-mastoideus.)*

(PL. III. 7.)

This is a large muscle included between the funicular part of the ligamentum nuchæ, and the vertebræ below. It is broad,

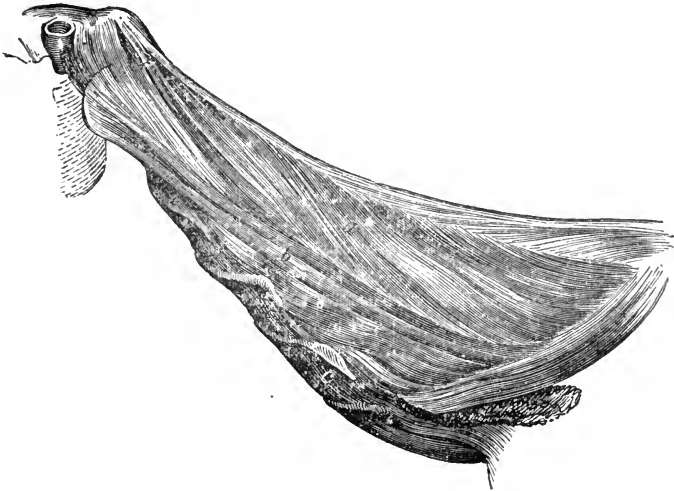


FIG. 73.

Lateral cervical muscles—deep layer. *a*, Complexus major; *b*, Trachelo-mastoideus; *c c c*, Intertransversalis colli.

flat, and triangular; aponeurotic only at its periphery, its belly is made up of large fleshy bundles, which are directed obliquely forwards and upwards to the head and first cervical vertebra.

*Attachments.*—To the funicular portion of the ligamentum nuchæ, the transverse processes of the third, fourth, and fifth cervical, and the spines of the first four or five dorsal vertebræ; to the crest and mastoid ridge, in union with the tendon of the trachelo-mastoideus, and to the wing of the atlas, along with the common tendon of the trachelo-mastoideus and the levator humeri.

*Relation.*—Externally with the levator humeri, cervical trapezius, serratus magnus, and rhomboideus muscles; internally with the complexus major, trachelo-mastoideus, and obliquus capitis muscles.

*Action.*—With its fellow it elevates the head; alone it draws the head to one side.

#### TRACHELO-MASTOIDEUS.\*

(*Dorso-mastoideus.*)

(FIG. 73. b.)

Situated under and along the inferior border of the splenius, it is elongated and fleshy, its fibres passing forwards and upwards; the belly is divided into two portions, which run parallel, each terminating by a tendon anteriorly.

*Origin.*—From the transverse processes of the first two dorsal and the oblique processes of the last five cervical vertebræ.

*Insertion.*—By two tendons; one to the wing of the atlas, common also to the splenius and levator humeri; the other, continuous with that of the splenius, to the mastoid ridge.

*Relation.*—Externally with the splenius; internally with the spinalis colli; posteriorly with the longissimus and spinalis dorsi.

*Action.*—With its fellow to erect the head; acting alone, it draws it to one side.

#### COMPLEXUS MAJOR.

(*Dorso-occipitalis.*)

(FIG. 73. a.)

Situated on the inside of the splenius, this muscle resembles an elongated triangle, with the base backwards; it is fleshy, with tendinous intersections. The posterior part is aponeurotic at its origin, the anterior terminating in a single tendon.

*Origin.*—From the transverse and spinous processes of the first five dorsal, and the oblique processes of all the cervical vertebræ.

*Insertion.*—To the side of the occipital tuberosity.

*Relation.*—Externally with the splenius and trachelo-mastoideus; internally with the complexus minor, ligamentum nuchæ, and oblique muscles; posteriorly with the longissimus

\* This is the complexus minor of M. Chauveau.

and spinalis dorsi. The superior cervical artery passes through its divisions posteriorly.

*Action.*—It extends the head.

#### COMPLEXUS MINOR.

(*Axoido-occipitalis Longus.*)

(FIG. 74. c.)

Situated on the poll, it is fusiform, slender, and fleshy, being tendinous at its insertion.

*Origin.*—From the neural spine of the dentata.

*Insertion.*—With the tendon of the complexus major.

*Relation.*—Externally with the complexus major; inferiorly with the rectus capitis posticus major; internally with the ligamentum nuchæ.

*Action.*—To assist the complexus major.

#### RECTUS CAPITIS POSTICUS MAJOR.

(*Axoido-occipitalis Brevis.*)

(FIG. 74. d.)

Situated below the complexus minor, it is long, slender, and fusiform.

*Origin.*—From the neural spine of the dentata.

*Insertion.*—To a roughened depression on the occiput below its tubercle.

*Relation.*—Externally with the complexus major; inferiorly with the rectus capitis posticus minor.

*Action.*—To extend the head.

#### RECTUS CAPITIS POSTICUS MINOR.

(*Atloido-occipitalis Brevis.*)

(FIG. 74. e.)

Situated below the preceding, this muscle is small, flat, and somewhat triangular.

*Origin.*—From the supero-anterior part of the atlas.

*Insertion.*—Below that of the preceding muscle.

*Relation.*—Superiorly with the major; inferiorly with the capsular ligament; externally with the obliquus capitis anticus; internally with the ligamentum nuchæ.

*Action.*—It assists the preceding muscle.

## OBLIQUUS CAPITIS ANTICUS.

*(Atloido-mastioideus.)*

(FIG. 74. b.)

Situated on the side of the poll, it is flat, nearly square, and fleshy, with tendinous intersections.

*Origin.*—From the supero-anterior portion of the roughened edge of the wing of the atlas.

*Insertion.*—To the mastoid crest and styloid process of the occiput.

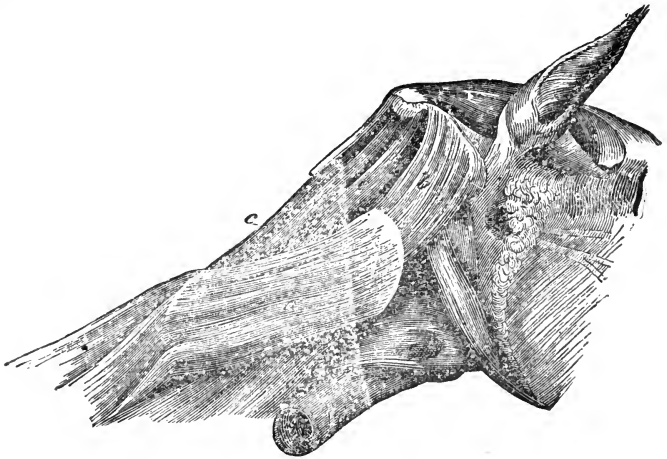


FIG. 74.

Occipito-atlo-axoid muscles—lateral view. *a*, Obliquus capitis posterior; *b*, Obliquus capitis anterior; *c*, Complexus minor; *d*, Rectus capitis posterior major; *e*, Rectus capitis posterior minor.

*Relation.*—Externally with the tendon of the splenius; internally with the capsular ligament and rectus capitis posterior muscles.

*Action.*—Together, to extend the head slightly; singly, to bend it laterally on the atlas.

## OBLIQUUS CAPITIS POSTICUS.

*(Axoideo-atloideus.)*

(FIG. 74. a.)

Situated between and upon the atlas and axis, it is broad, flat, thick, and fleshy.

*Origin.*—From the lateral surface and superior spine of the dentata, and the capsular ligament.

*Insertion.*—To the upper surface of the wing and body of the atlas.

*Relation.*—Externally with the splenius, trachelo-mastoideus, and complexus major; internally with the atlas, axis, and the atlo-axoid capsular ligament; superiorly with the rectus posticus, and inferiorly with the rectus anticus major muscles.

*Action.*—It is the rotator muscle of the head.

#### SPINALIS COLLI.

(*Dorso-spiralis.*)

Deep-seated on the side of the neck, it consists of six short fleshy bundles, intersected by tendons, whose fibres extend obliquely upwards and inwards.

*Origin.*—Posteriorly, from the oblique processes of the first dorsal and the last five cervical vertebræ.

*Insertion.*—To the neural spines of all the cervical vertebræ but the first.

*Relation.*—Externally with the complexus major and trachelo-mastoideus; internally with the ligamentum nuchæ and the vertebræ.

*Action.*—To extend and curve the neck.

#### INTERTRANSVERSALIS COLLI.

(*Intercervicalis.*)

(FIG. 73. c c c c.)

Placed along the lateral part of the cervical vertebræ, it consists of six distinct bundles with strong tendinous intersections, the fibres passing obliquely outwards and upwards.

*Origin.*—The oblique process of one vertebra.

*Insertion.*—The transverse process of the vertebra in front, filling up the interspaces of all, excepting those of the first and second.

*Relation.*—With several deep-seated muscles of the neck, the vertebræ, the vertebral artery, and vein.

*Action.*—To assist in flexing the neck laterally.

## COSTAL REGION.

The muscles of this region are those which cover the lateral aspect of the thoracic cavity; some of them are attached to the anterior limb, three of which we describe the first, as it is necessary in dissection to cut through them, and remove or deflect the limb in order to expose fully the deeper-seated muscles. The following are the muscles of the region:—

Trapezius dorsalis.	Superficialis costarum.
Rhomboideus brevis.	Transversalis costarum.
Latissimus dorsi.	Levatores costarum.
Serratus magnus.	Intercostales.

## TRAPEZIUS DORSALIS.

(*Dorso-acromialis.*)

(Pl. II. 14.)

Situated on the side of the withers, this muscle is flat and triangular, being almost the reversed counterpart of the cervical trapezius. The two form the *trapezius muscle*. It is aponeurotic at its superior border, while its belly is fleshy, terminating in a flat tendon.

*Origin.*—Superiorly, from the supraspinous ligament, and from the third dorsal spine back to the tenth or eleventh. The fibres converge downwards and forwards, over the superior costa of the scapula, and join the cervical portion.

*Insertion.*—The tubercle on the spine of the scapula.

*Relation.*—Externally with the skin and panniculus; internally with the rhomboideus brevis, postea-spinatus, and latissimus dorsi.

*Action.*—To draw upwards and retract the scapula.

## RHOMBOIDEUS BREVIS.

(*Dorso-subscapularis.*)

(Pl. III. 12.)

Deep-seated, on the side of the withers above the scapula, it is flat and square; the fibres extend downwards, and are entirely fleshy.

*Origin.*—From the neural spines of the first four or five dorsal vertebræ, and from their supraspinous ligament.

*Insertion.*—To the inner surface of the superior costa of the scapula, and to its cartilage of prolongation.

*Relation.*—Externally with the cartilage of the scapula, and the dorsal trapezius, and separated from the anterior portion of the superficialis costarum by a thin layer of elastic tissue; anteriorly with the rhomboideus longus; posteriorly with the latissimus dorsi; internally with the splenius.

*Action.*—To draw the scapula upwards.

#### LATISSIMUS DORSI

(*Dorso-humeralis.*)

(Pl. II. 15.)

This muscle is situated on the supero-lateral part of the chest and the loins; it is very large, flat, thick, and triangular, its fibres extending obliquely downwards and forwards; it is aponeurotic above, fleshy below, with a tendinous and aponeurotic insertion.

*Origin.*—By a broad aponeurosis, from the supraspinous ligament and spinous processes of the vertebræ, commencing about the highest point of the withers, and stretching as far as the last lumbar. The fleshy portion becomes thick just behind the scapula, then it contracts, terminating in a flat tendon, which passes under the latter. It fits in a notch at the dorsal scapular angle, formed by the projection of the cartilage of prolongation, which it overlaps.

*Insertion.*—The internal tuberosity of the humerus, along with the teres internus, and between the two insertions of the coraco-humeralis. Before passing under the scapula, it gives off a strong aponeurosis, which passes over the supero-posterior part of the scapula, and becomes continuous with its fascia.

*Relation.*—Externally with the panniculus carnosus, skin, triceps extensor brachii, and dorsal trapezius; superiorly with the rhomboideus brevis and dorsal angle of the scapula; internally with the ribs, serratus magnus, superficialis costarum, and gluteus maximus.

*Action.*—To elevate the humerus, and thus flex the shoulder-joint; it is likewise an expiratory muscle; when the limb is fixed.

## SERRATUS MAGNUS.

*(Costo-subscapularis.)*

(Pl. III. 10. 15.)

Situated between the shoulder and chest, and on the side of the neck, this is a large fan-shaped muscle; it may be divided into a cervical and a costal portion, and consists of several bundles with many tendinous intersections, converging upwards to the common point of insertion.

*Origin.*—Anteriorly, from the transverse processes of the five posterior cervical vertebræ; postero-inferiorly, from the external surfaces of the eight true ribs, from about their middles to their cartilages.

*Insertion.*—Superiorly to the venter surface of the scapula, between the origin of the subscapularis and the insertion of the rhomboidei.

*Relation.*—Anteriorly with the splenius; superiorly with the rhomboidei; supero-posteriorly with the longissimus dorsi; posteriorly with the great oblique muscle of the abdomen, with which it interdigitates; inferiorly with the pectorals; internally with the ribs, longissimus dorsi, splenius, cervical vertebræ, and intercostals; externally with the subscapular and triceps extensor muscles.

*Action.*—It depresses the scapula; when the limbs are fixed, it elevates the neck, and is also a subservient muscle of inspiration; but it chiefly serves with its fellow as a *muscular sling*, in which the body is suspended between the anterior limbs.

## SUPERFICIALIS COSTARUM.

*(Dorso-costalis.)*


(Pl. II. 49.)

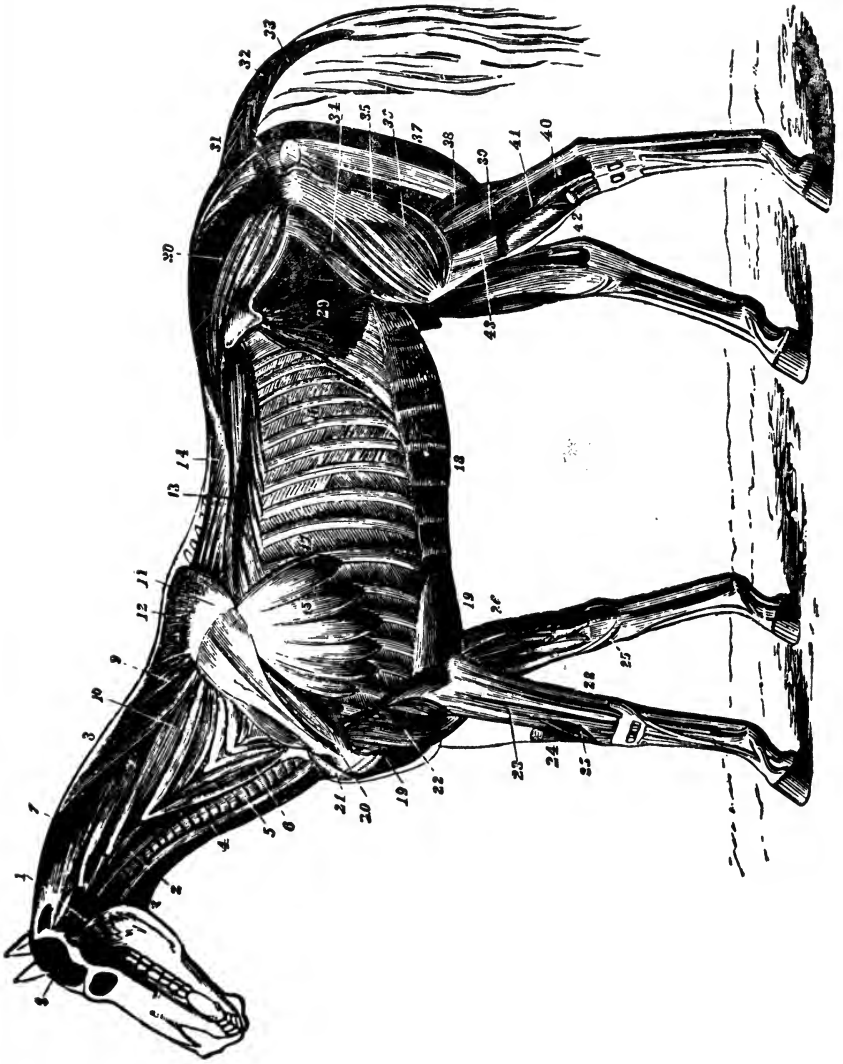
Placed on the supero-lateral part of the back, this muscle is broad, thin, and digitated, and consists of an anterior and a posterior portion.

*Origin.*—Anteriorly, from the supraspinous ligament, and dorsal spines from the second to the thirteenth inclusive; posteriorly from the spines of the last eight dorsal and anterior lumbar vertebræ.

*Insertion.*—The anterior part to the nine ribs behind the fourth, just below their angles, and to their anterior borders; the posterior part to the posterior borders of the last nine ribs.







MUSCLES OF THE HORSE—DEEP LAYER—after Mégnin.

## EXPLANATION OF PLATE III.

### MUSCLES OF THE HORSE.

#### *Deep Layer.*

- |   |   |
|---|---|
| 1. Temporalis.                            | 22. Humeralis obliquus.                             |
| 1. Stylo-maxillaris.                      | 22'. Caput parvum (of triceps extensor<br>brachii). |
| 2. Rectus capitis anticus major.          | 23. Extensor suffraginis.                           |
| 3. Sterno-thyro-hyoideus.                 | 24. Extensor metacarpi magnus divided.              |
| 4. Sterno-maxillaris.                     | 25. Extensor metacarpi obliquus                     |
| 5. The Trachea.                           | 25'. Its tendon.                                    |
| 6. Scalenus.                              | 26, 28. Flexor pedis perforans and per-<br>foratus. |
| 7. Splenius.                              | 29. Obliquus abdominis internus.                    |
| 8. Funicular part of ligamentum<br>nuchæ. | 30. Gluteus maximus.                                |
| 9. Rhomboideus longus.                    | 31. Erector coccygis.                               |
| 10. Cervical } serratus magnus.           | 32. Curvator coccygis.                              |
| 15. Costal }                              | 33. Depressor coccygis.                             |
| 11. Cartilage of prolongation.            | 34. Rectus femoris.                                 |
| 12. Rhomboideus brevis.                   | 35. Vastus externus.                                |
| 13. Transversalis costarum.               | 36. Part covered by triceps abductor.               |
| 14. Longissimus dorsi.                    | 37. Biceps rotator tibialis.                        |
| 15. Serratus Magnus.                      | 38. Gastrocnemius externus.                         |
| 16. External intercostals.                | 39. Plantaris.                                      |
| 17. Internal intercostals.                | 40. Flexor pedis perforans.                         |
| 18. Rectus abdominis.                     | 41. Peroneus.                                       |
| 19 19. Pectoralis magnus.                 | 42. Flexor metatarsi.                               |
| 20. Postea-spinatus minor.                | 43. Extensor pedis (cut across).                    |
| 21. Flexor brachii.                       |   |



*Relation.*—Internally with the ribs, transversalis costarum, and longissimus dorsi; externally with the rhomboideus, serratus magnus, and latissimus dorsi.

*Action.*—Respiratory; the anterior portion drawing the ribs outwards and forwards, acts as an inspiratory, the posterior, by drawing them backwards and upwards, as an expiratory muscle.

#### TRANSVERSALIS COSTARUM.

(*Trachelo-costalis.*)

(Pl. III. 13.)

Situated on the supero-lateral part of the thorax, it is long, thin, and semipenniform, the fibres passing downwards, outwards, and forwards, its numerous muscular bundles each terminating in a flat tendon.

*Origin.*—From the transverse processes of the first lumbar vertebræ, and the ribs near their tubercles.

*Insertion.*—To the external surface of all the ribs, a tendon to each, and one to the last cervical vetebra.

*Relation.*—Externally with the preceding muscle; internally with the ribs; superiorly with the longissimus dorsi.

*Action.*—It compresses the ribs, assisting in expiration.

#### LEVATORES COSTARUM.

(*Transverso-costalis.*)

Situated deeply on the back, these muscles are small, flat, and triangular, extending obliquely downwards and backwards. They are fleshy and tendinous.

*Origin.*—Superiorly, from the transverse processes of the dorsal vertebræ, just above the tubercles of the ribs.

*Insertion.*—Inferiorly to the external faces of the ribs, just above their angles.

*Relation.*—Externally with the longissimus dorsi; internally with the external intercostals, with which posteriorly they are much blended.

*Action.*—To raise and draw the ribs forwards, thus acting as inspiratory muscles.

## INTERCOSTALES.

*(Externi and Interni).*

(PL. III. 16. 17).

These fill up the spaces between the ribs, are external and internal, and usually seventeen in number, consisting of flat bands, included in, and intersected by, many broad aponeurotic slips. The external ones are thickest above, the internal below, the former terminating at the costal cartilages, between which the latter extend.

*Origin.*—From the posterior border of each rib.

*Insertion.*—The anterior border of each succeeding rib, the fibres of the external ones extending downwards and backwards, those of the internal ones downwards and forwards. The external terminate at the costal cartilages, while the internal do not extend above the angles.

*Relation.*—Externally with the serratus magnus, superficialis and transversalis costarum, and latissimus dorsi; internally with the pleura.

*Action.*—They are inspiratory muscles, drawing the ribs forward, the first rib being rendered a fixed point by the contraction of the scalenus. They thus aid the diaphragm in its action.

## PECTORAL REGION.

In this region we describe two groups of muscles, the *pectoral* and the *sternal*, the latter being deep-seated.

## PECTORAL GROUP.

This group consists of four pairs of muscles, which are largely developed in the horse, and all of which arise from the external surface of the sternum and its appendages, and become attached to the pectoral limb, upon which they, as a group, assist in suspending the body, also in moving the limb, and in respiration. They are differently described by different authorities; Percival and Leyh describe three pairs, Chauveau two, but as the latter divides each of them into two parts, his consideration ultimately agrees with the one adopted here. We describe four pairs of pectoral muscles:—

Pectoralis transversus.		Pectoralis anticus.
Pectoralis magnus.		Pectoralis parvus.

## PECTORALIS TRANSVERSUS.

*(Sterno-aponeuroticus.)*(FIG. 75. *d.*)

Situated on the latero-inferior part of the thorax, this muscle is quadrilateral, the fibres extending outwards and downwards.

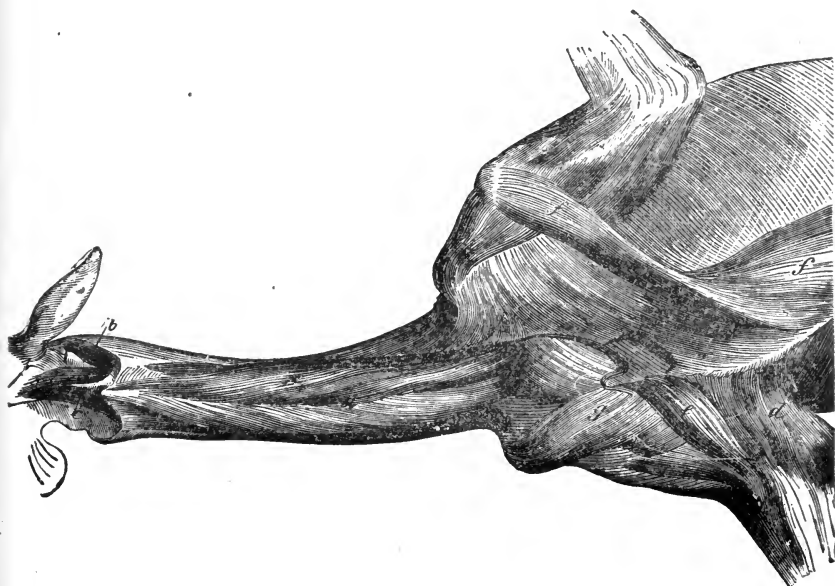


FIG. 75.

Pectoral muscles, and inferior deep muscles of the neck. *a*, Longus colli; *b*, Rectus capitis lateralis; *c*, Rectus capitis anticus minor; *d*, Pectoralis transversus; *e*, Pectoralis anticus; *ff*, Pectoralis magnus; *g*, Pectoralis parvus. On the left side the pectoralis transversus and anticus have been removed.

Near its origin it is fleshy, mixed with tendon, but afterwards becomes aponeurotic.

*Origin.*—By fleshy fibres usually from the first four bones of the sternum, meeting its fellow at a white central line.

*Insertion.*—To the olecranon, by fascia covering the inner side of the arm, and to the anterior part of the humerus.

*Relation.*—Externally with the skin; anteriorly with the pectoralis anticus; superiorly with the pectoralis magnus.

*Action.*—To adduct the arm, and especially to tense the brachial fascia.

## PECTORALIS MAGNUS.

*(Sterno-trochineus.)*

(Pl. III. 19, 19. FIG. 75: ff.)

This muscle is situated on the infero-lateral part of the thorax, and is large, irregularly four-sided, flat, and thick, the fibres extending forwards and outwards. Slightly aponeurotic anteriorly, elsewhere it is fleshy.

*Origin.*—From the inferior border of the last three or four bones of the sternum, the ensiform cartilage, and its fellow of the opposite side; externally from the cartilages of the false ribs, fascia of the external oblique muscle of the abdomen, and the abdominal tunic.

*Insertion.*—To the fascia on the inside of the arm, and to the inner trochanter of the humerus, under the tendon of the coracobrachialis, and by fascia over the bicipital groove, to the external trochanter.

*Relations.*—Externally with the panniculus, skin, and pectoralis transversus; internally with the fascia of the external oblique, and the ribs; anteriorly with the pectoralis parvus.

*Action.*—To draw the shoulder back and adduct the arm; in difficult respiration it acts as an inspiratory muscle.

## PECTORALIS ANTICUS.

*(Sterno-humeralis.)*

(FIG. 75. e.)

Situated on the anterior part of the breast, it forms the fleshy prominence seen in front. Short, thick, and fusiform, its fibres extend outwards; it is tendinous at its attachments, with a fleshy belly.

*Origin.*—From the cariniform cartilage and first bone of the sternum. It is directed somewhat backwards, outwards, and downwards.

*Insertion.*—To a ridge on the anterior part of the shaft of the humerus by fleshy fibres, and an aponeurotic tendon common also to the levator humeri, and pectoralis transversus.

*Relations.*—Externally with the skin; anteriorly with the levator humeri and panniculus; posteriorly with the pectoralis magnus and transversus; internally with the parvus.

*Action.*—Its chief action is to adduct the arm.



## PECTORALIS PARVUS.

*(Sterno-prescapularis.)*

(FIG. 75. g.)

In front of the magnus, on the antero-inferior part of the thorax, elongated and prismatic in form, its fibres extend outwards, forwards, and upwards; it is tendinous at its origin, fleshy elsewhere.

*Origin.*—From the three or four anterior sternal segments, cartilages, ribs, and cariniform cartilage.

*Insertion.*—To the fascia in front of the shoulder-joint, and the anterior costa of the scapula, nearly as high up as the origin of the antea-spinatus.

*Relation.*—Externally with the magnus and transversus; inferiorly with the transversus and anticus; internally with the first costal cartilages, intercostales, and transversalis costarum; anteriorly with the levator humeri.

*Action.*—To draw the shoulder-joint backwards and downwards, assist the magnus, and tense the scapular fascia.

## STERNAL GROUP.

The muscles of this unimportant group are two in number—

Lateralis sterni.

Triangularis sterni.

## LATERALIS STERNI.

*(Costo-sternalis.)*

Placed along the inferior border of the serratus magnus, its fibres extend downwards and backwards. It is flat, thin, and aponeurotic at its extremities.

*Origin.*—From the outer surface of the first rib, passing over the next two or three ribs, and becoming attached to the sternum at about the fourth segment.

*Relation.*—Externally with the pectorals; superiorly with the serratus magnus; posteriorly with the rectus abdominis; internally with the ribs and intercostals.

*Action.*—An auxiliary muscle of expiration.

## TRIANGULARIS STERNI.

*(Sterno-costalis.)*

Situated in the thorax and upon the sternum, it is triangular, tendinous, and dentated on its outer border.

*Origin.*—From the superior sternal ligament and segments.

*Insertion.*—To the cartilages, and inner surfaces of the distal ends of the true ribs, excepting the first.

*Action.*—To assist in expiration.

## DORSO-LUMBAR REGION.

The muscles of this region, a single group, are closely related with the superior aspect of the vertebral column, and we describe them as consisting of four—

Longissimus dorsi.		Semispinalis dorsi et lumborum.
Spinalis dorsi.		Intertransversales lumborum.

## LONGISSIMUS DORSI.

*(Ilio-spinalis.)*

(PL. III. 14.)

Situated on the superior part of the back and loins, this, the longest and most powerful muscle in the body, occupies the space between the costal angles and the dorso-lumbar spines; broad and fleshy at its origin in the loins, it becomes deeper and narrower as it proceeds forwards. Towards the withers it diverges, presenting three distinct portions, two of which proceed in an oblique direction to the neck, and terminate by several tendons (the deeper portion is described as the spinalis dorsi); the third portion is adherent to the sides of the anterior dorsal spines. The belly of this muscle is intersected by several tendons, and is invested posteriorly by a very strong, tendinous aponeurosis.

*Attachments.*—The crest, inner surface, and supero-anterior spine of the ilium; the spinous and transverse processes of the first two bones of the sacrum; the spinous, transverse, and oblique processes of all the lumbar vertebræ; the spinous and transverse processes of all the dorsal vertebræ; the external surface of the last fifteen or sixteen ribs just above the transversalis costarum, and the spinous and transverse processes of the last three or four cervical vertebræ.

*Relation.*—Externally with the superficialis costarum, and gluteus maximus which overlaps it in the lumbar region; inferiorly with the transversalis costarum; internally with the ribs, vertebræ, and semispinalis dorsi et lumborum; anteriorly with the spinalis dorsi.

*Action.*—It is brought powerfully into play in kicking and rearing, by elevating the fore or hind quarters, according to whether the fore or hind limbs are fixed. Acting singly, the result is lateral flexion of the back and loins. It may assist also in expiration.

#### SPINALIS DORSI.\*

Situated deeply on the withers, it is pyramidal in form, aponeurotic at its origin, with a fleshy belly; it is with difficulty separated from the longissimus dorsi.

*Origin.*—By aponeurosis from the supraspinous ligament, as far back as the twelfth, and from the posterior borders of the spinous processes of the six anterior dorsal vertebræ.

*Insertion.*—To the superior spinous processes of the last three or four cervical vertebræ.

*Relation.*—Externally with the trapezius and rhomboideus brevis; anteriorly with the complexus major and splenius; inferiorly with the longissimus dorsi; internally with its fellow, the ligamentum nuchæ, the anterior dorsal vertebræ, and semispinalis dorsi.

*Action.*—To assist in elevating the neck.

#### SEMISPINALIS DORSI ET LUMBORUM.

##### (*Spinalis Transversus.*)

In contact with the dorsal and lumbar spines, this muscle consists of a number of fasciculi, whose fibres are directed upwards and forwards.

*Origin.*—From the sacrum, the oblique processes of all the lumbar, and transverse processes of all the dorsal vertebræ.

*Insertion.*—The spinous processes of the vertebræ, the fasciculi each passing over two or three spines before being inserted; it becomes continuous with the spinalis colli at the seventh cervical.

\* [This muscle may be regarded as part of the longissimus dorsi.—ED.]

*Relation.*—Externally with the longissimus dorsi ; internally with the vertebræ.

*Action.*—To assist in extending the spine.

#### INTERTRANSVERSALES LUMBORUM.

These are small muscular slips, invested by strong tendinous fasciæ, running from the transverse process of one lumbar vertebra to the one adjacent.

*Relation.*—With the longissimus dorsi and intertransverse ligaments.

*Action.*—To assist in flexing the spine laterally, by bringing these processes nearer to each other.

#### ABDOMINAL REGION.

The infero-lateral walls of the abdomen are formed by a large musculo-aponeurotic envelope, consisting of four pairs of muscles, covered externally by the *abdominal tunic*, the muscles on the right being separated from those on the left by the *linea alba*, a white fibrous cord extending from the sternum to the pubis. These muscles, the rectus excepted, consist each of a fleshy and an aponeurotic portion, and the general line of demarcation between the aponeurotic and the fleshy region is known as the *linea semilunaris*. We have to describe the following structures:—

Tunica abdominalis.

Linea alba.

#### *Muscles.*

Obliquus abdominis externus.		Rectus abdominis.
Obliquus abdominis internus.		Transversalis abdominis.

#### TUNICA ABDOMINALIS.

(*Tunica Elastica*).

The *abdominal tunic* is an immense expansion, composed of yellow elastic tissue, which covers the external oblique muscles. It is thickest at the pubis, and on each side of the linea alba, thinning as it approaches the sternum, and disappearing at the posterior attachment of the pectoralis magnus muscle. It blends with the external oblique, anteriorly reaching the digitations of

the serratus magnus; posteriorly it furnishes a few fibres, which, detached from the surface of the common abdominal tendon (prepubian), pass between the thighs, and become lost in the muscles of that region.

*Relation.*—Externally by cellular tissue to the panniculus and skin. It is continuous with the suspensory ligament of the sheath and dartos in the male, and the elastic envelope of the mamma in the female, in whom it is always thickest.

*Use.*—To afford a mechanical support to the abdominal viscera, and conserve muscular action by substituting elasticity for it. On the application of distensile force it yields considerably.

#### LINEA ALBA.

The *linea alba* is a white fibrous cord situated between the inner borders of the two recti-abdominales, to which it gives attachment, as to the other abdominal muscles. Anteriorly it is attached to the inferior surface of the xiphoid cartilage, and posteriorly it becomes confounded with a large tendon, common to the abdominal muscles, the *prepubian tendon*, which is attached to the anterior border of the pubis, and assists in the formation of the internal commissure of the inguinal canals. Between its posterior and middle third the linea alba is enlarged, and forms a lozenge-shaped space, in the centre of which is the remnant of the umbilicus. The fact of this structure joining the sternum to the pubic symphysis, together with certain co-related features, has induced anatomists to regard the linea alba as representing a rudimentary abdominal sternum.

#### OBLIQUUS ABDOMINIS EXTERNUS.

(*Costo-abdominalis.*)

(PL. II. 74.)

The largest and most external muscle of the group, situated on the infero-lateral aspect of the abdomen, and consisting of a fleshy and an aponeurotic portion. It is quadrilateral, its fibres running downwards and backwards. Its aponeurosis commences at a line called the *linea semilunaris*, and is continued to the *linea alba*, where it bends with that of the internal oblique.

*Attachments.*—By fleshy fibres, anteriorly to the outer surface of the last thirteen or fourteen ribs, just below their middle; the

four anterior digitations are received between the corresponding ones of the serratus magnus; to the fascia of the latissimus dorsi, and superiorly to the lumbar fascia: to the anterior iliac spine and crest; to the pubis and prepubian tendon, and inferiorly to the linea alba throughout its whole extent.

*Relation.*—Externally with the abdominal tunic; antero-externally with the pectoralis magnus; internally with the ribs, cartilages, and intercostals, the internal oblique and the rectus; anteriorly with the serratus magnus.

*Action.*—To support and compress the abdominal viscera, and assist in defecation, urination, and parturition. It is also a flexor of the vertebral column. and a muscle of expiration.

#### APONEUROSIS OF THE OBLIQUUS EXTERNUS.

The distribution of this aponeurosis being very singular and important, it merits separate consideration. It stretches from the anterior spine of the ilium to the pubis, answers to the fold of the groin, and marks the division between the trunk and hind extremity. Posteriorly it splits into two layers; one descends internally over the thigh, forming the *crural aponeurosis*; the other is reflected upward, and enters the abdominal cavity, this fold receiving the name of the *crural arch* or *Poupart's ligament*. Near the prepubian tendon, and immediately in front of its division, the aponeurosis is pierced by a large oval aperture, the *external abdominal ring*, which is the external opening of the *inguinal canal*.

#### *Crural Aponeurosis.*

This descends over the fold of the groin to the patella, and internal surface of the thigh, blending outwardly with the fascia lata, and internally becoming less dense in structure: it covers the sartorius, part of the gracilis, vastus internus, and the crural vessels as they leave the abdomen.

#### *Poupart's Ligament.*

The *Crural Arch* or *Poupart's Ligament* is a ribbon-shaped reflected portion of the aponeurosis of the external oblique, and is attached by its extremities to the anterior spine of the ilium, and anterior border of the pubis. Anteriorly it forms the posterior

pillar of the inguinal canal, and externally gives attachment to the posterior fibres of the internal oblique. Posteriorly it contacts the sartorius and pectineus muscles, and the crural vessels, embracing those parts in a sort of arch, hence its name. Its superior border at its external half is attached to the lumbo-iliac aponeurosis; while its middle is confounded with the external surface of the sartorius and iliacus. Inside the attachments of the pectineus and psoas parvus, it forms, with the anterior border of the pubis, the iliacus and sartorius, a triangular opening called the *crural ring*, through which the crural vessels pass out of the abdomen. The inferior border is continuous with the femoral and great oblique aponeuroses.

#### *Inguinal Canal.*

The *Inguinal Canal* is infundibuliform and compressed laterally; through it pass the spermatic cord and external pudic artery of the male, and mammary vessels of the female. It is situated obliquely between the crural arch, which is its posterior, and the internal oblique muscle, which forms its anterior wall. The external orifice is called the *external abdominal ring*, and is larger than the internal, being oval in form and directed backwards and inwards. It presents two *pillars* and two extremities or *commissures*. The pillars, anterior and posterior, are merely the edges or lips of the aperture, and are formed by the arciform fibres of the aponeurosis of the external oblique muscle, the posterior one being assisted by Poupart's ligament. The commissures, external and internal, are formed by the union of the pillars, the latter being limited by the prepubian tendon. The *peritoneal* or *internal abdominal ring*, the internal orifice of the canal, is situated in front of the crural ring. It is a mere dilatable cleft between the crural arch and the internal oblique, and but indifferently marked at its extremities.

#### OBLIQUUS ABDOMINIS INTERNUS.

(*Ilio-abdominalis.*)

(Pl. III. 29.)

Situated under the externus, on the postero-lateral and inferior aspects of the abdomen, its fibres expanding downwards, it is, like the externus, fleshy and aponeurotic; the fleshy portion is

thick, and occupies the flank; the aponeurosis commences at the linea semilunaris, its fibres blending with those of the external oblique.

*Attachments.*—Supero-posteriorly, to the anterior spine of the ilium, whence its fleshy fibres radiate; a portion is attached to the transverse processes of two or three of the first lumbar vertebræ, and passes to the posterior border of the last rib (this portion is described by the German anatomists as a *retractor costæ*); and to the fascia of the latissimus dorsi; to the cartilages of the false ribs; postero-inferiorly to the symphysis pubis, by the prepubian tendon, aiding in the formation of the internal abdominal ring; inferiorly to the linea alba throughout its whole extent.

*Relations.*—Externally with the external oblique; internally with the transversalis and rectus abdominis.

*Action.*—It assists the externus in compressing the abdomen in the act of respiration, and in flexing the spine. It also draws the last rib backwards.

#### RECTUS ABDOMINIS.

(*Sterno-pubialis.*)

(Pl. III. 18.)

Situated along the inferior and middle part of the abdomen, it is long, flat, polygastric, and broadest in the middle. Tendinous at its attachments, its belly consists of numerous flat muscular fasciculi, with transverse tendinous intersections, to which the aponeuroses of the oblique muscles are adherent; these intersections are called the *lineæ transversæ* (*inscriptiones tendinæ*), and may be regarded as the abdominal representatives of the ribs. The posterior part of the muscle assists in the formation of the internal abdominal ring.

*Attachments.*—Anteriorly to the inferior surface of the xiphoid cartilage and sternum; to the cartilages of the last four true and first two false ribs; posteriorly to the crest of the pubis, through the medium of the prepubian tendon, which is directly continuous with it; internally to the linea alba.

*Relations.*—Inferiorly with the aponeurosis of the internal oblique muscle; anteriorly with the pectoralis magnus; superiorly with the transversalis, and the cartilages of nearly all the ribs; internally with its fellow at the linea alba.



*Action.*—To support and compress the abdominal viscera and assist in respiration. It is the chief flexor of the spinal column.

TRANSVERSALIS ABDOMINIS.

(*Lumbo-abdominalis.*)

Placed on the infero-lateral aspect of the abdomen, immediately outside the peritoneum, this muscle is broad, flat, and quadrilateral, its fibres extending downwards. It is fleshy from its origin to the linea semilunaris, where it becomes aponeurotic.

*Attachments.*—To the transverse processes of the lumbar vertebræ, and the inner surface of the cartilages of the false ribs, interdigitating with the attachments of the diaphragm, and by its aponeurosis to the xiphoid cartilage and linea alba, becoming rudimentary posteriorly.

*Relations.*—Anteriorly with the diaphragm; externally with the cartilages of the false ribs, the obliquus internus and rectus; internally with a thin layer of fascia (the *fascia transversalis*) which connects it with the peritoneum.

*Action.*—To assist the oblique muscles, and raise the viscera.

SUBLUMBAR REGION.

The muscles of this region, a single group, connect the lumbar and last dorsal vertebræ with the pelvis or the posterior limb. They are covered by the iliac fascia, and this by the peritoneum, a serous membrane lining the abdominal cavity. In this group we place four muscles:—

Psoas magnus.	Iliacus.
Psoas parvus.	Quadratus lumborum.

PSOAS MAGNUS.

(*Sublumbo-trochantineus.*)

(FIG. 76. c.)

Situated below the transverse processes of the lumbar vertebræ, it is elongated and fusiform, flattened anteriorly, conical posteriorly, its fibres extending downwards and backwards; it is almost entirely fleshy, except at its insertion.

*Origin.*—From the inferior surfaces of the last two ribs, the:

bodies of the last two dorsal, and all the lumbar vertebræ except the last, and to the lumbar transverse processes, passing between the two parts of the iliacus.

*Insertion.*—By a tendon, common to it and the iliacus, to the internal trochanter of the femur.

*Relation.*—Posteriorly with the iliacus; internally with the psoas parvus and the bodies of the vertebræ; above with the

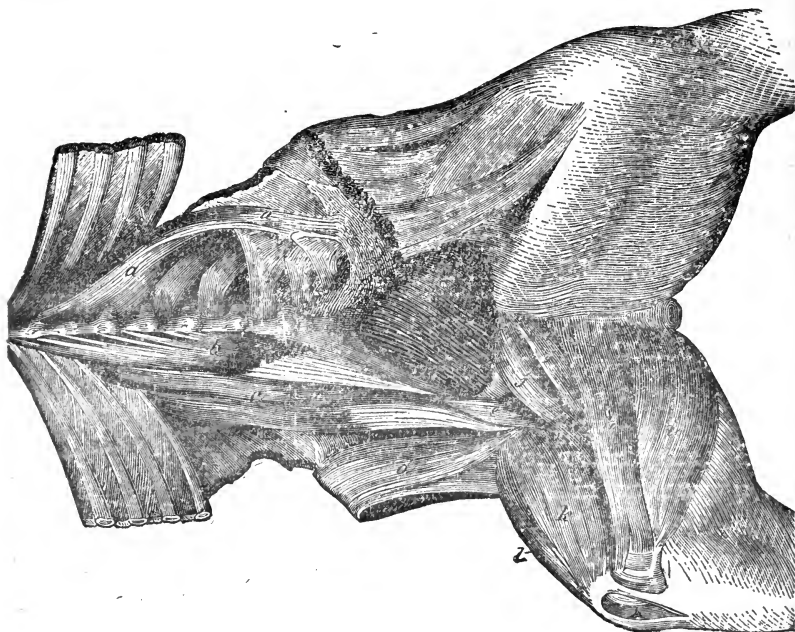


FIG. 76.

Muscles of the sublumbar and internal deep femoral regions—seen from below. *a, a*, Quadratus lumborum; *b*, Psoas parvus; *c*, Psoas magnus; *d, e*, Iliacus; *f*, Pectineus; *g*, Adductor brevis; *h*, Adductor longus; *i*, Adductor magnus; *k*, Vastus internus; *l*, Rectus femoris.

quadratus lumborum, and below with the kidney and iliac fascia, the diaphragm, and, in the thoracic cavity, with the pleura.

*Action.*—To flex and rotate the thigh, or, the latter being fixed, to flex the loins; the latter action tends to “roach” the back.

#### PSOAS PARVUS.

(*Sublumbo-pubialis.*)

(FIG. 76. *b.*)

Situated on the inner side of the psoas magnus, it is long, thin, and semipenniform, the fibres extending backwards and outwards.

Fleshy above, it has posteriorly a strong flat tendon passing along the lower surface to its insertion.

*Origin.*—From the bodies of the last three or four dorsal, and all the lumbar vertebræ.

*Insertion.*—To the ilio-pectineal eminence on the brim of the pubis, midway between the symphysis and the acetabulum, and to the iliac fascia.

*Relation.*—Inferiorly with the diaphragm, pleura, posterior aorta and vena cava; externally with the psoas magnus.

*Action.*—To flex the pelvis on the spine, when the loins are fixed; when the pelvis is fixed, to arch the back. It is also the tensor of the iliac fascia.

#### ILIACUS.

(*Ilio-trochantineus.*)

(FIG. 76. d, e.)

Situated under the false pelvis, this muscle is strong, thick, and pyramidal, the base being forwards, and the fibres extending downwards, backwards, and inwards. The belly is incompletely divided by a fissure into two unequal portions, the external being the larger; through this fissure passes the tendon of the psoas magnus, which its own tendon joins.

*Origin.*—From the ilio-pectineal ridge, nearly all the venter surface of the ilium, and the inferior sacro-iliac ligament.

*Insertion.*—To the internal trochanter of the femur, along with the psoas magnus.

*Relation.*—Superiorly with the ilium; inferiorly with the iliac fascia and sartorius; externally with the tensor fasciæ latæ and rectus femoris, from which it is separated by a layer of fat; internally with the crural vessels. It passes between the vastus internus and the pectineus.

*Action.*—To flex the femur, and rotate it outwards.

#### QUADRATUS LUMBORUM.

(*Sacro-lumbalis.*)

(FIG. 76. a.)

Placed below and between the lumbar transverse processes, this is a flat, thin muscle, consisting of several bundles, with strong tendinous intersections. The principal bundle is situated exter-

nally and longitudinally, the lesser ones diverging from it inwards and forwards.

*Origin.*—The chief bundle arises from the inferior sacro-iliac ligament at the angle of the sacrum, passing directly forwards.

*Insertion.*—To the posterior border of the last rib, becoming attached in its course to the free extremities of the transverse processes of the lumbar vertebræ. The other bundles leave the internal border of the first, and are attached to most of the transverse processes of the lumbar vertebræ, and inner surfaces of the last two or three ribs.

*Relation.*—Superiorly with the vertebræ, and intertransversales lumborum; inferiorly with the psoas magnus.

*Action.*—To assist in lateral flexion of the lumbar vertebræ, and to draw the last ribs backwards.

#### DIAPHRAGMATIC REGION.

This region contains only one muscle, from which it takes its name.

##### DIAPHRAGM.

(*Diaphragma.*)

(FIG. 77. A.)

The diaphragm, or midrif, is the muscular partition which separates the thorax from the abdomen; it slopes obliquely downwards and forwards, and is in form elliptical, or somewhat heart-shaped, being widest superiorly. The thoracic surface is convex and covered with pleura, the abdominal concave and covered with peritoneum. It is divided into a body or septum, and two crura or appendices; the body, or greater muscle, is made up of a fleshy periphery and tendinous *phrenic centre* (*Speculum Helmontii*).

*Attachments.*—The fleshy portion is attached to the inner surface of the distal ends of the last twelve ribs, or to their cartilages, and to the superior surface of the ensiform cartilage, the fibres converging towards the tendinous centre. The *crura* or pillars, two in number, lie below the vertebræ in the sublumbar region. The right is the longer and larger, and arises from the inferior surface of the bodies of all the lumbar vertebræ but the last, by strong tendinous fibres which blend with the inferior common ligament. The left differs from the right in arising from only one or two anterior lumbar vertebræ. The crura pass

down the central line of the tendinous portion, and gradually blend with its fibres. Near the centre of the diaphragm, and a little to the right, is a large opening, the *foramen dextrum*, through which passes the posterior vena cava. Between the pillars superiorly is a second opening, the *hiatus aorticus*, through which pass the posterior aorta, vena azygos, and thoracic duct. Below this, the right crus forms towards the left a third opening, the *foramen sinistrum*, for the passage of the œsophagus and pneumogastric nerves, accompanied by the pleural artery. There

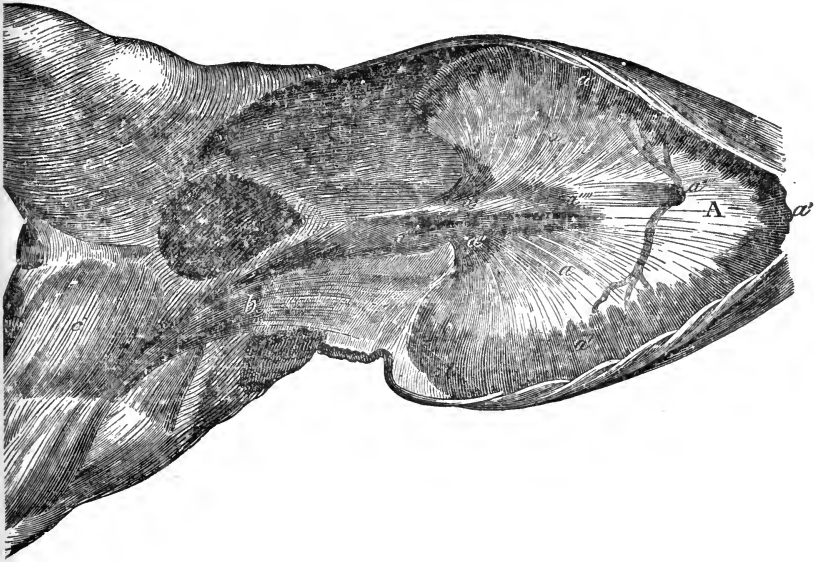


FIG. 77.

The diaphragm, and superficial muscles of the internal femoral region—viewed from below. A, The diaphragm; a a, The tendinous centre; a' a', The fleshy periphery; a'' a'', The crura; a''', The hiatus aorticus; a''''', The foramen sinistrum; a''''', The foramen dextrum; b, The sartorius; c, The gracilis.

are thus three openings—the *hiatus aorticus* above, the *foramen sinistrum* in the middle, and the *foramen dextrum* below. Certain of the sublumbar muscles originate partly in the thorax, and the diaphragm forms arches which allow their passage, and that of the sympathetic and splanchnic nerves; these arches are bounded by ligaments, the *ligamenta arcuata*; outside the arches the diaphragm is attached to the last rib by a broad fold of elastic tissue.

*Relation.*—Anteriorly with the pleura, which covers both it!

and the lungs; posteriorly, covered by peritoneum, it contacts the liver, stomach, spleen, and the large colon.

*Action.*—Essentially a muscle of inspiration. When it contracts it becomes flattened, forces the abdominal viscera backwards, and so enlarges the thoracic cavity. This action is antagonistic to one of the actions of the abdominal muscles. It also assists in the expulsive efforts of defecation and parturition.

#### COCCYGEAL REGION.

The muscles of this region, that of the tail, are enclosed in strong fascia, which may be said to be continuous with the approximate pelvic ligaments. We find one group containing four muscles:—

Erector coccygis.		Curvator coccygis.
Depressor coccygis.		Compressor coccygis.

#### ERECTOR COCCYGIS.

(*Sacro-coccygeus Superior.*)

(Pl. III. 31.)

Situated on the supero-lateral part of the tail, it consists of bundles of fibres, intersected by tendons, which gradually diminish in size from before backwards, each terminating in a short tendon.

*Origin.*—The tuberos summits and lateral aspect of the posterior sacral spines, and superior surface of the coccyx.

*Insertion.*—To the coccygeal bones.

*Relation.*—Internally with its fellow, and the coccygeal vertebræ; externally with the skin and fascia.

*Action.*—When acting together to elevate the tail; singly, to draw it upwards and outwards.

#### DEPRESSOR COCCYGIS.

(*Sacro-coccygeus Inferior.*)

(Pl. III. 33.)

Situated on the infero-lateral aspect of the tail, and similar to the erector, but thicker.

*Origin.*—Within the pelvis, from the inferior surface of the sacrum, the inner surface of the sacro-sciatic ligament, and the coccygeal vertebræ.

*Insertion.*—By tendons to the inferior surface of all the coccygeal vertebræ successively.

*Relation.*—Superiorly with the sacrum, coccyx, and curvator; inferiorly with the rectum; externally with the curvator and sacro-sciatic ligament; internally with its fellow.

*Action.*—To bend the tail downwards; singly, to draw it downwards and to one side.

#### CURVATOR COCCYGIS.

(*Sacro-coccygeus Lateralis.*)

(PL. III. 32.)

Situated on the side of the tail, and similar in structure to the preceding, it is merely a continuation of the semispinalis lumborum.

*Origin.*—From the spines of the last lumbar, and lateral aspect of the sacral and coccygeal vertebræ.

*Insertion.*—The side of the coccyx, between the erector and depressor.

*Relation.*—Superiorly with the erector and sacral ligament; inferiorly with the depressor; externally with the compressor.

*Action.*—To curve the tail, drawing it sideways over the quarter.

#### COMPRESSOR COCCYGIS.

(*Ischio-coccygeus.*)

Situated at the side of the pelvis, it is a large, thin, and triangular muscle.

*Origin.*—By aponeurosis, from the superior ischiatic spine and the inner surface of the sacro-sciatic ligament, running upwards and backwards.

*Insertion.*—By fleshy fibres, to the side of the terminal sacral and first two coccygeal vertebræ.

*Relation.*—Externally with the sacro-sciatic ligament; internally with the curvator and rectum.

*Action.*—To depress the entire tail.

#### MUSCLES OF THE LIMBS.

The muscles of this class are those which are specially related to the limbs, for the most part acting upon them alone; they are intrinsic and extrinsic, according to their origin. These muscles

are either flexors, extensors, abductors, adductors, or rotators, but in the horse the last are comparatively few, limited in their action, and nearly all extrinsic, the joints of the horse's limbs below the shoulder and hip allowing very slight rotatory motion.

### MUSCLES OF THE PECTORAL LIMB.

These may be conveniently divided into the following regions:—

Scapular . . . . .	The shoulder.
Brachial . . . . .	The arm.
Antibrachial . . . . .	The fore-arm.
Metacarpal . . . . .	The foot (hand).

### SCAPULAR REGION.

Externally the region is covered by the strong scapular fascia, and comprises an external group of four and an internal of three muscles.

#### EXTERNAL SCAPULAR GROUP.

Teres externus.		Postea-spinatus.
Antea-spinatus.		Postea-spinatus minor.

#### TERES EXTERNUS.

(*Scapulo-humeralis Magnus.*)

(FIG. 78. c.)

This is the long abductor of the arm, which corresponds to the deltoid of man. Situated on the outer and posterior part of the shoulder, it consists of two portions, anterior and posterior. The posterior or larger portion is triangular in form, and very fleshy, the fibres extending obliquely downwards and forwards; it is lodged in a depression in the caput magnum. The anterior or superior portion is thin, and aponeurotic above, extending over the postea-spinatus muscle, to which it is adherent.

*Attachments.*—The posterior section arises from the dorsal angle and posterior costa of the scapula; the anterior by strong fascia from a tubercle on the spine of the scapula, and the scapular fascia. They unite inferiorly, and by tendinous and fleshy fibres are inserted to the deltoid ridge of the humerus below the insertion of the postea-spinatus minor.



*Relation.*—Anteriorly with the postea-spinatus ; internally with the caput magnum, caput medium, and postea-spinatus ; externally with the scapular fascia.

*Action.*—To abduct the humerus, and rotate it outwards ; when acting with the teres internus to flex the shoulder joint.

#### ANTEA-SPINATUS.

(*Superacromio-trochiterius.*)

(FIG. 78. a.)

Occupying the antea-spinatus fossa of the scapula, this muscle is pyramidal in shape, with the base downwards. Its fleshy fibres extend obliquely forwards ; then becoming tendinous inferiorly, it is bifurcated for the passage of the flexor brachii tendon, the divisions being connected by aponeurosis.

*Origin.*—From the anterior fossa, anterior costa, and cervical angle of the scapula, and the anterior surface of its spine.

*Insertion.*—By two parts, one external, to the summit of the external trochanter, and one internal, to the summit of the internal trochanter, of the humerus.

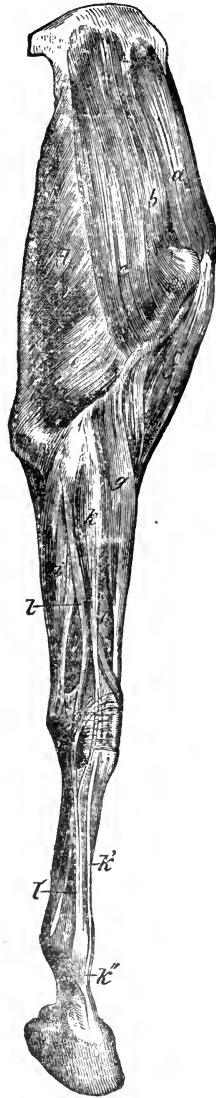


FIG. 78.

Muscles of the anterior limb—external view. *a*, Antea-spinatus ; *b*, Postea-spinatus ; *c*, Teres externus ; *d*, Caput magnum ; *e*, Caput medium ; *f*, Flexor brachii ; *g*, Extensor metacarpi magnus ; *h*, Extensor metacarpi obliquus ; *i*, Flexor metacarpi externus ; *k*, Extensor pedis ; *k'*, Its tendon ; *k''*, Fibrous band from the suspensory ligament ; *l*, Extensor suffraginis ; *l'*, Its tendon.

*Relation.*—Externally with the scapular fascia; anteriorly with the pectoralis parvus; posteriorly with the scapular spine and the anterior border of the postea-spinatus; internally with the bone; antero-inferiorly with the levator humeri and the tendon of the flexor brachii.

*Action.*—To extend the humerus on the scapula, and tense the fascia covering the flexor brachii. It serves, like the other scapular muscles, as an active ligament of the shoulder joint.

#### POSTEA-SPINATUS.

(*Subacromio-trochiterius.*)

(FIG. 78. b.)

Lodged in the postea-spinatus fossa, it is broad, flat, and triangular, with the apex below, to which its fibres converge; it is fleshy, with strong tendinous intersections.

*Origin.*—From the posterior costa and fossa of the scapula, the posterior border of its spine, and the cartilage of prolongation.

*Insertion.*—By two divisions, one of which goes to the inner side of the convexity of the external humeral trochanter; the other, a strong tendon, passes over the trochanter, and is inserted to a roughened ridge below. Between the tendon and convexity is a synovial bursa.

*Relation.*—Externally with the aponeurosis of the teres externus and with the scapular fascia; anteriorly with the antea-spinatus and the scapular spine; posteriorly with the teres externus; internally with the scapula, its cartilage, and the postea-spinatus minor; inferiorly it contacts the capsular ligament of the shoulder joint.

*Action.*—To abduct the humerus, and rotate it outwards.

#### POSTEA-SPINATUS MINOR.

(*Scapulo-humeralis Parvus.*)

(FIG. 80. c a.)

Situated on the inside of the teres externus, below the postea-spinatus, and along the posterior border of the scapula, it is long and prismatic inferiorly, fleshy, and intersected by tendon, and is easily divided into a large and small portion.

*Origin.*—From the posterior border of the scapula, and by

tendinous slips from the posterior fossa, and a small tubercle on the external side of the rim of the glenoid cavity.

*Insertion.*—To the deltoid ridge.

*Relation.*—Externally with the teres externus and postea-spinatus; internally with the caput magnum, caput medium, and capsular ligament.

*Action.*—Like the last, to abduct, and rotate the humerus outwards.

#### INTERNAL SCAPULAR GROUP.

Subscapularis.

Teres internus.

Scapulo-humeralis posticus.

#### SUBSCAPULARIS.

(*Subscapulo-trochineus.*)

(FIG. 79. a.)

Situated on the inner side of the shoulder blade, occupying the subscapular fossa, it is fan-shaped, forming three points superiorly, its fibres converging downwards. It is covered by strong fascia, from which arises the subscapulo-hyoideus.

*Origin.*—From the whole of the subscapular fossa.

*Insertion.*—To the internal humeral trochanter, by a strong tendon passing over its summit, where there is a small synovial bursa.

*Relation.*—Externally with the scapula; internally with the serratus magnus; anteriorly with the antea-spinatus, with which it blends, the two forming a space through which passes the pre-scapular artery; posteriorly with the teres internus.

*Action.*—To adduct the arm, and perhaps to rotate it slightly inwards.

#### TERES INTERNUS.

(*Teres Major—Subscapulo-humeralis.*)

(FIG. 79. b.)

This, an adductor of the arm, is situated just behind the subscapularis, at the posterior border of the scapula; it runs obliquely downwards, corresponding to the teres externus. It is elongated, wide in the middle, tapering at the extremities, its posterior edge being thin.

*Origin.*—From the dorsal angle and posterior costa of the scapula.

*Insertion.*—By a flat tendon, which joins that of the latissimus dorsi, to the internal tuberosity of the humerus, between the tendons of insertion of the coraco-humeralis.

*Relation.*—Postero-externally with the fascia of the latissimus dorsi and scapulo-ulnaris; anteriorly with the subscapularis; internally with the serratus magnus; inferiorly with the coraco-humeralis and humeralis obliquus.

*Action.*—To adduct, and rotate the humerus inwards; acting with the teres externus the result is flexion.

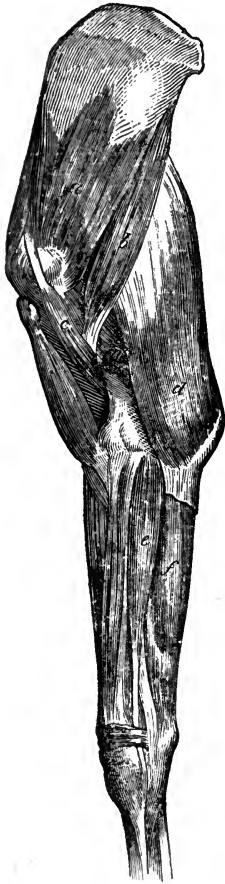

FIG. 79.

Muscles of the anterior limb—internal view. *a*, Subscapularis; *b*, Teres internus; *c*, Coraco-humeralis; *d*, Scapulo-ulnaris; *e*, Flexor metacarpi internus; *f*, Flexor metacarpi medius; *g*, Caput parvum.

#### SCAPULO-HUMERALIS POSTICUS.

(*Scapulo-humeralis Gracilis*—Grêle.)

Situated behind the shoulder joint, between the caput magnum and the capsular ligament, it is very small, slender, and fusiform, with a pale, delicate, fleshy belly, and tendinous extremities.

*Origin.*—From the postero-inferior part of the scapula, just above the glenoid cavity, and the capsular ligament of the shoulder joint.

*Insertion.*—Between the fibres of the humeralis obliquus, to the posterior part of the humerus, just below its head.

*Action.*—To render tense the capsular ligament of the joint, and thus prevent its being crushed during flexion; this action was ascribed to it by Rigot, who was the first to describe it. It is believed to be peculiar to the solidungula.

#### BRACHIAL REGION.

This region clothed by the brachial fascia, includes the muscles which cover the humerus and its vicinity; they consist of an

anterior and a posterior group, the former being mostly anterior or lateral to the bone, the latter situated behind it. In either group we find three muscles.

## ANTERIOR BRACHIAL GROUP.

Flexor brachii.  
Coraco-humeralis.  
Humeralis obliquus.

## FLEXOR BRACHII.

(*Coraco-radialis.*)

(FIG. 78. f.)

The analogue of the biceps in man, this muscle is situated in front of the humerus: it is long and cylindrical, passing downwards and backwards. The tendon of origin contains fibro-cartilage, and the belly is intersected by tendinous fibres.

*Origin.*—From the base of the coracoid process of the scapula, by a strong tendon, which passes over the bicipital groove where there is a synovial bursa.

*Insertion.*—By a short tendon to the bicipital tuberosity on the antero-internal part of the head of the radius, and to the capsular ligament of the elbow joint; a part of it passes under the internal-lateral ligament of the elbow joint. A strong fibrous band is given off inferiorly which joins and expands over the extensor metacarpi magnus, and becomes blended with the anti-brachial fascia.

*Relation.*—Anteriorly with fascia, covered by the levator humeri; internally with the coraco-humeralis; posteriorly with the humerus; superiorly its tendon passes between the two insertions of the antea-spinatus, where a strong fascia envelopes it and is tensed by the last-named muscle.

*Action.*—To flex the radius on the humerus, extend the latter on the scapula, and to tense the anti-brachial fascia. A band of unyielding tendinous material runs through this muscle, enabling it to act as a ligament, and passively support the shoulder joint, when the animal is at rest; the band joining the extensor metacarpi also relieves muscular tension.

## CORACO-HUMERALIS.

*Omo-brachialis.*

(Fig. 79. c.)

Situated on the inner side of the humerus, this muscle is tendinous, long, and fusiform, its fibres passing obliquely downwards.

*Attachments.*—From the beak of the coracoid process of the scapula. Passing between the subscapularis and the antea-spinatus, the tendon is succeeded by two fleshy bellies, a superficial and a deep one. The latter, thin and short, is inserted to the shaft of the humerus just above its internal tuberosity; the former, by far the larger, is inserted to a rough surface on the same bone, lower down, and more anteriorly.

*Relation.*—Anteriorly with the flexor brachii; superiorly with the antea-spinatus and subscapularis; internally with the pectoralis magnus; posteriorly with the latissimus dorsi and teres internus, whose tendons pass between its two bellies.

*Action.*—To extend, adduct, and rotate the arm inwards.

## HUMERALIS OBLIQUUS.

*(Humero-radialis—Brachialis Anticus.)*

(Fig. 80. d.)

Occupying the musculo-spiral groove, it is flat, oblong, wide superiorly, and almost entirely fleshy; it covers successively portions of the posterior, external, and anterior surfaces of the humerus, terminating on the inner aspect of the radius.

*Origin.*—From the postero-superior part of the shaft of the humerus, just below the articular head, winding round the bone under the external tuberosity.

*Insertion.*—To a ridge on the inner part of the head of the radius, after passing through a transverse groove just below, and within the insertion of the flexor brachii; also to the ulna, passing under the internal-lateral ligament of the joint, and blending with the arciform ligament.

*Relation.*—Externally with the caput magnum and caput medium; internally with the humerus; anteriorly with the flexor brachii.

*Action.*—Solely to flex the elbow joint.

## POSTERIOR BRACHIAL GROUP

Scapulo-ulnaris.  
Triceps extensor brachii.  
Anconeus.

## SCAPULO-ULNARIS.

(*Scapulo-olecranius Longus.*)

(FIG. 79. d.)

Situated on the postero-internal aspect of the region, adhering to the caput magnum, this is a broad and flat muscle, aponeurotic at its origin, with a fleshy belly, and divisible into an anterior and posterior portion.

*Origin.*—Aponeurotic, from the dorsal angle and posterior costa of the scapula.

*Insertion.*—To the inner part of the apex of the olecranon, and to the antibrachial fascia.

*Relation.*—Externally with the caput magnum; anteriorly with the caput medium; internally with the pectoralis magnus; superiorly with the latissimus dorsi.

*Action.*—To flex the shoulder joint, extend the elbow joint, and tense the antibrachial fascia.

## TRICEPS EXTENSOR BRACHII.

(*Triceps Brachii.*)

(FIG. 78. d, e.)

A very large and powerful muscle, occupying the space between the posterior border of the scapula, the humerus, and the olecranon. It consists of three parts, which have different origins, but a common insertion to the olecranon process. We describe them as if they were separate muscles, under their respective names :—

Caput magnum.  
Caput medium.  
Caput parvum.

## CAPUT MAGNUM.

*(Scapulo-olecranius Magnus.)*

(FIG. 78. d.)

This, the great extensor of the fore-arm, is situated on the posterior aspect of the shoulder. It is thick and triangular, extending obliquely downwards and backwards, and consists of several bundles, with tendinous intersections.

*Origin.*—From the dorsal angle and posterior costa of the scapula.

*Insertion.*—By a strong tendon to the inner and upper part of the olecranon, a synovial bursa being interposed between it and the apex. It receives many fibres from the caput medium.

*Relation.*—Externally with the fascia, the panniculus carnosus, and the teres externus, which occupies a depression in it; internally with the latissimus dorsi, scapulo-ulnaris, and teres internus; inferiorly with the caput medium and caput parvum.

*Action.*—To flex the shoulder joint, and extend the fore-arm.

## CAPUT MEDIUM.

*(Humero-olecranius Externus.)*

(FIG. 78. e.)

Placed between the preceding muscle and the humerus, it is thick, short, and fleshy, extending obliquely backwards and downwards.

*Origin.*—Aponeurotic, from a ridge on the supero-posterior part of the shaft of the humerus, running from the deltoid ridge to the neck.

*Insertion.*—The supero-posterior part of the olecranon; or it may join the tendon of the caput magnum.

*Relation.*—Superiorly with the caput magnum; externally with the teres externus; inferiorly with the humeralis obliquus and extensor metacarpi magnus; internally with the caput parvum.

*Action.*—To extend the fore-arm.



## CAPUT PARVUM.

*(Humero-olecranius Internus.)*

(FIG. 81. a.)

Placed on the inner and mesian portion of the shaft of the humerus, along the inferior border of the caput magnum, this muscle is slender and triangular, with a fleshy origin. The fibres pass obliquely backwards and downwards, terminating in two flat tendons.

*Origin.*—From the postero-internal part of the middle third of the humerus, extending from the inner tubercle.

*Insertion.*—To the inner part of the apex of the olecranon, one tendon passing over a small groove before its insertion, which is situated below the other one.

*Relation.*—Superiorly with the caput magnum; externally with the humerus, humeralis obliquus, and caput medium; internally with the insertion of the coraco-humeralis, with the teres internus, latissimus dorsi, and scapulo-ulnaris.

*Action.*—To extend the fore-arm.

## ANCONEUS.

*(Humero-olecranius Parvus.)*

(FIG. 80. e.)

Situated at the back of the elbow joint, it is small, thick, and almost entirely fleshy, filling up the space between the condyles of the humerus, or the olecranon fossa.

*Origin.*—From the borders of the fossa, chiefly the epitrochlea, and the capsular ligament of the elbow joint.

*Insertion.*—The antero-external part of the olecranon.

*Relation.*—Posteriorly with the caput medium muscle; anteriorly with the elbow joint and humerus.

*Action.*—To tense the capsular ligament, and prevent it from being crushed during extreme extension.

## ANTIBRACHIAL REGION.

The muscles of this region, the fore-arm, cover the ulna and radius, except on the inner aspect of the latter, where there is little interposed between the skin and the bone; they are divided into

two distinct groups, the anterior and posterior, the first of which are all extensors, the second all flexors. All these muscles are inserted below the radius, and therefore act upon the carpus or on the joints below. The region is enclosed in the antibrachial fascia, an exceedingly strong covering, which is firmly attached to the radius and ulna.

### ANTERIOR ANTIBRACHIAL GROUP.

#### EXTENSORS.

The extensor group includes four muscles :—

Extensor metacarpi magnus.		Extensor pedis.
Extensor metacarpi obliquus.		Extensor suffraginis.

#### EXTENSOR METACARPI MAGNUS.

(*Epicondylo-premetacarpeus.*)

(FIG. 78. g.)

Situated in front of the radius, and in figure pyramidal, extending downwards, it consists of a fleshy belly, and a long flat tendon, which commences at about the lower third of the radius, and passes over the carpus, terminating at the head of the metacarpus.

*Origin.*—From the epitrochlea, or ridge above the external condyle of the humerus, from the capsular ligament of the elbow joint anteriorly, and the surface just above. It receives a strong tendinous band from the flexor brachii. The tendon passes through a groove or theca in the anterior part of the distal end of the radius, where there is a synovial sheath or bursa, then over the knee through a second synovial apparatus. Two synovial sheaths are thus interposed between the bones and the tendon, the latter being bound down by the anterior annular ligaments, and by the tendon of the extensor metacarpi obliquus, which crosses it in an oblique manner just above the carpus.

*Insertion.*—To a tuberosity on the anterior part of the head of the great metacarpal bone, towards its inner side.

*Relation.*—Anteriorly with the fascia; posteriorly with the radius; externally with the extensor pedis; supero-internally with the humeralis obliquus and flexor brachii; inferiorly with the extensor obliquus.

*Action.*—To extend the carpus.

**EXTENSOR METACARPI OBLIQUUS.**

(*Radio-premetacarpeus.*)

(Fig. 78. *h.*)

This muscle is situated on the infero-anterior part of the radius, and is triangular and penniform; aponeurotic above, it terminates in a small tendon, which crosses obliquely the inferior extremity of the anterior surface of the radius, under the extensor pedis, and over the extensor metacarpi magnus tendon.

*Origin.*—From the external border of the radius. Its tendon passes through the oblique groove on the antero-internal part of the distal end of the radius, where there is a synovial sheath.

*Insertion.*—The head of the inner metacarpal bone.

*Relation.*—Anteriorly with the extensor pedis and the fascia; posteriorly with the extensor metacarpi magnus and the bone.

*Action.*—To extend the metacarpus, and rotate it slightly, carrying the inner aspect forwards.

**EXTENSOR PEDIS.**

(*Epitrochleo-prephalangeus.*)

(Fig. 78. *k*; Fig. 80. *f.*)

Placed on the antero-external part of the fore-arm, it is long and pyramidal, extending downwards; fleshy above, its belly is bifid inferiorly, and terminates in a long tendon, which is double, and commences about the inferior third of the radius.

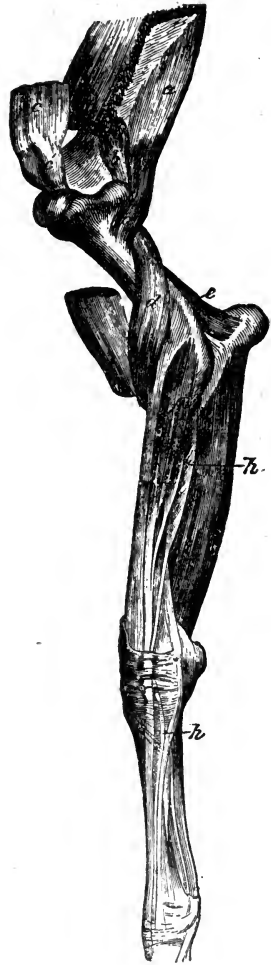

FIG. 80.

External view of the muscles of the anterior limb—showing the deeper ones of the upper region. *a a*, Postea-spinatus minor; *b*, Deep portion of postea-spinatus; *c*, Flexor brachii divided, and the upper part raised; *c'*, Its tendon, which fits the bicipital groove; *d*, Humeralis obliquus; *e*, Anconeus; *f*, Extensor pedis; *g*, Thiernesse's muscle; *h*, Phillips' muscle; *h'*, Its tendon.

*Origin.*—The fleshy part arises from the base of the epitrochlea, and the anterior border of the external lateral ligament of the elbow joint, the front of the distal extremity of the humerus, and the outer part of the head of the radius. The tendon, which is double, passes through a synovial theca in the external groove on the distal end of the radius, under the anterior annular ligament. Below the knee it sends a small tendon to join that of the extensor suffraginis; then expanding, it passes over the front of the fetlock joint, being attached to the capsular ligament, and having a small synovial bursa interposed; below the fetlock it receives on either side a strong slip from the suspensory ligament, and it becomes attached to the anterior part of the first and second phalanges.

*Insertion.*—To the pyramidal process of the os pedis.

*Relation.*—Anteriorly and externally it is covered by the fascia; posteriorly related with the extensor suffraginis, the radius, carpus, metacarpus, and phalanges; internally with the extensor metacarpi magnus.

*Action.*—To extend the phalanges on each other, and assist in extending the carpus.

If the tendon which joins that of the extensor suffraginis be carefully traced upwards, it will be found to be continuous with a long thin muscle separable from the extensor pedis, and placed along its postero-external aspect; it arises from the external lateral ligament of the elbow joint and the corresponding tuberosity of the radius, and has received the name of *Phillips' muscle* (Fig. 80. *h*). Somewhat anteriorly to the above a still smaller muscle may be found arising from the external arciform ligament, and terminating in a small tendon, which joins that of the extensor pedis a short distance above the carpus; this has been called *Thiernes's muscle* (Fig. 80. *g*). These two muscles are not generally described, but are regarded as forming a part of the extensor pedis.

#### EXTENSOR SUFFRAGINIS.

(*Radio-prephalangeus.*)

(Fig. 78. *L*)

Situated on the external part of the fore-arm, between the extensor pedis and the flexor metacarpi externus, this muscle is semipenniform, consisting of a flattened fleshy belly, enveloped in

a strong aponeurotic sheath, and having its edge turned outwards. The belly ends in a round tendon, which passes through a theca in the vertical groove on the external side of the distal end of the radius, and down the external aspect of the carpus, reaching the anterior surface of the large metacarpal bone.

*Origin.*—From the external part of the head of the radius, the external lateral ligament of the elbow joint, the shaft of the radius, and the lateral aspect of the ulna.

*Insertion.*—To the head of the os suffraginis, related also with the capsular ligament of the fetlock joint. Below the knee it is joined by two tendinous slips, one from the tendon of the extensor pedis, the other, a species of *check* ligament, from the trapezium.

*Relation.*—Anteriorly with the extensor pedis; posteriorly with the flexor pedis perforatus, the perforans, and flexor metacarpi externus; externally with the fascia.

*Action.*—To extend the digit, and assist the extensor pedis.

## POSTERIOR ANTIBRACHIAL GROUP.

### FLEXORS.

This, the flexor group, consists of seven muscles, three flexors of the carpus, and four flexors of the digit:—

Flexor metacarpi externus.		Flexor pedis perforatus.
Flexor metacarpi medius.		Flexor pedis perforans
Flexor metacarpi internus.		Ulnaris accessorius.
Radialis accessorius.		

### FLEXOR METACARPI EXTERNUS.

(*Epitrochleo-carpeus.*)

(FIG. 78. i.)

Situated on the postero-external aspect of the fore-arm, this muscle is elongated and flattened, the fleshy belly being intersected by strong tendon.

*Origin.*—By a very short strong tendon from the summit of the epitrochlea of the humerus, terminating in two tendons; the anterior, longer, and more delicate, passes through a synovial theca, in a groove on the external surface of the trapezium.

*Insertion.*—The anterior tendon goes to the head of the outer splint bone; the posterior, short and flat, becomes inserted to the

superior part of the trapezium, blending with the flexor metacarpi medius.

*Relation.*—Externally with the fascia; internally with the flexor pedis muscles and the flexor medius; anteriorly with the extensor suffraginis.

*Action.*—To flex the carpus.

#### FLEXOR METACARPI MEDIUS.

(*Flexor M. Obliquus—Epicondylo-carpeus.*)

(FIG. 79. f.)

Similar in structure to the preceding muscle, it is situated on the postero-internal part of the radius, extending downwards and outwards. It is long, flat, and bifid above; one head is small, the other large and fleshy.

*Origin.*—The large head arises from the epicondyle, the small head from the posterior surface of the olecranon; they unite at a short distance down the radius.

*Insertion.*—By one tendon to the supero-posterior and internal part of the trapezium, blending with the externus.

*Relation.*—Externally with the fascia; internally with the flexors of the foot; anteriorly with the flexor internus; posteriorly with the flexor externus.

*Action.*—To assist the preceding muscle in flexing the carpus.

#### FLEXOR METACARPI INTERNUS.

(*Epicondylo-metacarpeus.*)

(FIG. 79. e.)

Situated on the internal aspect of the fore-arm, it resembles the two preceding muscles in its structure, being long and flattened, with a fleshy belly, but having a long tendon of insertion.

*Origin.*—By tendinous fibres from the base of the epicondyle just by the medius.

*Insertion.*—To the head of the inner splint bone, the long round tendon passing through a synovial theca on the inner side of the carpus.

*Relation.*—Externally with the fascia; internally with the chief radial vessels and nerves, and the flexors of the foot; anteriorly with the radius; posteriorly with the medius.

*Action.*—Like the preceding, to flex the carpus.

## FLEXOR PEDIS PERFORATUS.

*(Flexor Sublimis—Epicondylo-phalangeus.)*

(FIG. 81. b.)

Situated in the posterior region of the fore-arm, under the flexors of the carpus, this muscle is long, thin, and prismatic, its belly being fleshy, with tendinous intersections, and extending almost to the carpus, where it is succeeded by a long tendon, which passes through a synovial sheath behind the joint, closed in by the posterior annular ligament. Above the carpus, the tendon is joined by a broad band of fibrous tissue, called the superior carpal or superior "check" ligament, which springs from the infero-posterior surface of the radius, being also attached to the antibrachial fascia, and usually to the perforans muscle; below the knee, the tendon assists in the formation of a synovial sheath for the tendon of the flexor perforans. At the fetlock it expands and forms a ring or sheath, through which passes the perforans tendon, hence the names perforans and perforatus; below the pastern joint the tendon divides into two.

*Origin.*—From the summit of the epicondyle, by a tendon common to it and the perforans.

*Insertion.*—To the projecting lateral parts of the os coronæ.

*Relation.*—Posteriorly with the flexor metacarpi externus and medius; anteriorly with the perforans. Two important synovial sheaths or canals are related with this and the perforans tendon, the carpal and the metacarpophalangeal. The first, to which is attached the antibrachial fascia, is formed by the posterior

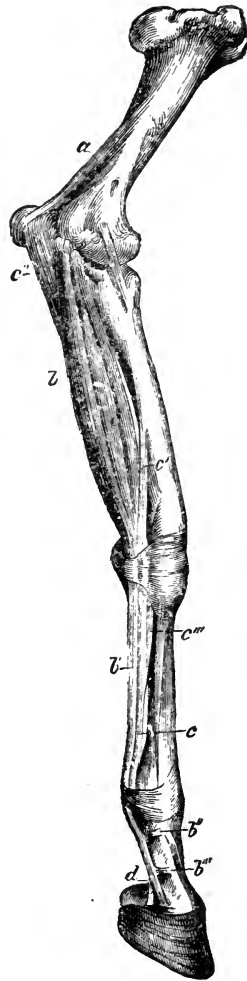


FIG. 81.

Internal view of the deep muscles of the anterior limb. *a*, Caput parvum of triceps extensor brachii; *b*, Flexor pedis perforatus; *b'*, Its tendon; *b'' b'''*, Slips to the phalanges; *c c'*, Flexor pedis perforans; *c'*, Radialis accessorius; *c'''*, Ulnaris accessorius; *c'''*, Inferior check ligament; *d*, Perforans tendon leaving the sheath of perforatus tendon.

carpal and annular ligaments; the second is formed by the cartilaginous pad clothing the great sesamoid bones, the posterior face of their inferior, and their annular ligaments, the latter being very adherent to the perforatus tendon, which it covers, and is continued both upwards and downwards, being attached to the phalanges by three fibrous bands on each side. The synovial membranes lining these sheaths, and reflected on the tendons, are very large, and project considerably above and below, each forming an upper and a lower *cul-de-sac*; the lower one of the sesamoidean sheath reaching that formed by the membrane of the coffin joint, and also the superior one of the navicular sheath.

*Action.*—To flex the pastern and fetlock joints, and assist in flexing the carpus. The superior check ligament enables it to act as an unyielding brace to the joints below during rest.

#### FLEXOR PEDIS PERFORANS.

(*Flexor-Profundus—Epicondylo-phalangeus.*)

(FIG. 81. c c.)

This muscle is situated between the preceding one and the radius; it is long, tendinous at its origin, with a round fleshy belly, much larger than that of the perforatus, and ending, above the carpus, in a funicular tendon. This tendon passes through the posterior carpal sheath, then through a sheath partly formed by the perforatus tendon below; it is joined by the tendons of the accessory flexors, and half-way down the metacarpus by the inferior carpal or *check* ligament, a strong fibrous band which is continuous with the posterior carpal ligament. The tendon then passes through the sesamoidean sheath anteriorly to the perforatus tendon, and then between the terminal slips of the latter, over the supero-posterior part of the os coronæ, when it expands, the expanded part being termed the *plantar aponeurosis*; it passes thence over the navicular bone, and its synovial capsule, to the solar aspect of the pedal bone.

*Origin.*—In common with the perforatus from the epicondyle.

*Insertion.*—To the semilunar ridge on the solar aspect of the os pedis.

*Relation.*—Posteriorly with the perforatus; anteriorly with the radialis accessorius and the radius. Connected with the terminal portion of the tendon, we may remark that the synovial



capsule of the navicular bone, termed the *navicular sheath*, forms two *cul-de-sacs*, one stretching upwards almost to the inferior *cul-de-sac* of the sesamoid sheath, the other being situated under the inferior navicular ligament. A broad *strengthening sheath* of fibrous tissue covers the plantar aponeurosis and blends with it inferiorly, being attached above by two bands to the sides of the first phalanx.

*Action.*—It flexes the joints below the carpus, and assists in flexing the latter.

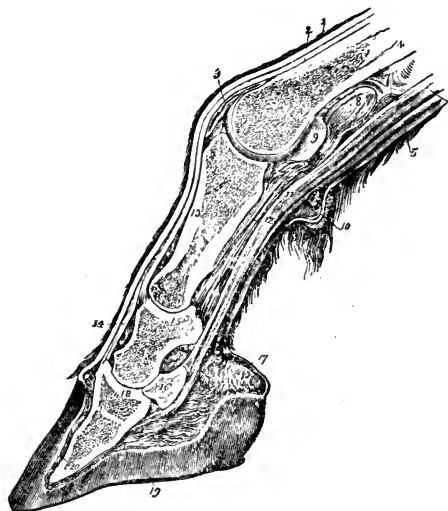


FIG. 82.

Longitudinal section through the digit of a Horse.  
 1, The skin; 2, Extensor pedis tendon; 3, Synovial capsule of pastern joint; 4, Metacarpus; 5, Perforatus tendon; 6 (omitted in cut), Perforans tendon; 7, Synovial sheath; 8, Projecting synovial *cul-de-sac*; 9, Inner aspect of sesamoid bone; 10, The fetlock; 11, The v-ligament; 12, The v-ligament; 13, Proximal phalanx; 14, Terminal portion of extensor tendon; 15, Mesian phalanx; 16, Third sesamoid or navicular bone; 17, The sensitive frog; 18, Distal phalanx; 19, The hoof; 20, Sensitive laminae.

## ULNARIS ACCESSORIUS.

(*Flexor Accessorius Sublimis.*)

(FIG. 81. c'')

Situated on the posterior part of the fore-arm, between the external and middle flexors of the metacarpus, it is triangular,

passing obliquely downwards and inwards; it has a short, thick, fleshy belly, ending in a long, slender, flat tendon.

*Origin.*—From the posterior border and summit of the olecranon.

*Insertion.*—It blends with, and helps to form the tendon of the perforans near the carpus.

*Relation.*—Superiorly with the fascia; internally with the flexor metacarpi internus; externally with the medius.

*Action.*—It assists the flexor perforans.

#### RADIALIS ACCESSORIUS.

(*Flexor Accessorius Profundus.*)

(FIG. 81. c'.)

A small muscle situated on the postero-inferior part of the radius. Somewhat radiating, flat, and elongated, passing downwards and slightly inwards, it ends above the knee in a slender tendon.

*Origin.*—From the posterior part of the shaft of the radius.

*Insertion.*—It joins the tendon of the perforans.

*Relation.*—Anteriorly with the radius; posteriorly with the perforatus and perforans.

*Action.*—To assist the flexor perforans.

#### METACARPAL REGION.

Below the carpus we find only two pairs of exceedingly small muscles:—

Interossei metacarpei.

Lumbricales.

#### INTEROSSEI METACARPEI.

(*Interossei Palmares, Human.*)

Situated on the inside of the small metacarpal bones, these muscles each consist of a thin, fleshy belly, and a long, slender tendon, which sometimes joins the band extending from the suspensory ligament to the extensor tendon, or may join the tendon itself. These muscles belong to the rudimentary small metacarpal bones, and hence are themselves rudimentary; the interosseus of the middle bone is usually considered as being represented by the suspensory ligament.

LUMBRICALES.

(*Lumbrici.*)

These small muscles originate on either side of the perforans, and the sesamoidean ring of the perforatus tendons ; they terminate in their tendons, which become lost in the coverings of the fetlock joint.

MUSCLES OF THE PELVIC LIMB.

The movements caused by these muscles resemble those of the anterior limb. It should, however, be borne in mind that the stifle joint allows more extensive and varied motion than the elbow, while the motion in the tarsus is less free than that in the carpus, the former being in effect purely ginglymoid ; also that the posterior is capable of more extensive abduction at the hip joint than is the anterior limb at the shoulder, although the former is more bound by ligaments. The muscles of the limb in question may be divided into those associated with the following regions :—

Gluteal . . . . .	The hip.
Femoral . . . . .	The thigh.
Tibial . . . . .	The leg.
Metatarsal . . . . .	The foot.

GLUTEAL REGION.

The muscles of this region, called also the hip or the croup, arise externally or internally from the pelvis, the sacrum, and the sacro-sciatic ligament, and are all attached to the femur near its proximal end, being related with the hip joint. Collectively the muscles from which this region is named form in the horse an enormous fleshy mass, apparent in the living animal as a rounded prominence, behind and above the anterior iliac spine, to which, and to the sacral spine, the strong gluteal fascia which invests them is firmly attached ; a thin layer of fat is generally found covering the region superiorly. In this region we have one group containing nine muscles, named as follows :—

Gluteus externus.	Obturator externus.
Gluteus maximus.	Obturator internus.
Gluteus internus.	Pyriformis.
Rectus parvus.	Gemellus anticus.
Gemellus posticus.	

## GLUTEUS EXTERNUS.

*(Ilio-trochanterius Medius.)*

(PL. II. 56; FIG. 84. b.)

This is a V-shaped muscle situated on the external part of the croup, its fibres converging downwards. It consists of a muscular and an aponeurotic portion; the former is double, the parts converging and ending in a flat tendon; the aponeurotic joins the fleshy portion posteriorly, and is hidden under the triceps abductor femoris.

*Origin.*—The anterior portion arises from the anterior spine of the ilium, the posterior from the second and third sacral spines; also from the gluteal fascia.

*Insertion.*—To the trochanter minor; the aponeurotic portion reaches the tuberosity of the ischium and the sacro-sciatic ligament.

*Relation.*—Externally with the gluteal fascia; anteriorly with the fascia lata; posteriorly with the triceps abductor; internally with the maximus.

*Action.*—It abducts the thigh.

## GLUTEUS MAXIMUS.

*(Ilio-trochanterius Magnus.)*

(PL. III. 30; FIG. 84. c.)

This is a very large muscle occupying the iliac dorsum, and stretching forwards over the lumbar region; it is fleshy and thick in its centre, terminating in two tendons.

*Origin.*—From the iliac shaft, crest, dorsum, and spines, anterior and posterior, the side of the sacrum, the sacral and part of the sacro-sciatic ligaments, and the tendinous envelope of the longissimus dorsi as far forward as the last rib.

*Insertion.*—By two tendons, one to the summit of the trochanter major, the other anteriorly to the crest below the con-

vexity, over which it passes, with an interposed synovial bursa ; a small fleshy insertion is often found posteriorly.

*Relation.*—Externally with the externus and the fascia ; internally with the internus, sacro-sciatic ligament, and the ilium ; anteriorly with the fascia lata and the longissimus dorsi ; posteriorly with the triceps abductor femoris. The inner and anterior portion which terminates in the anterior tendon has been rather unnecessarily described as a separate muscle ; this possible separation is shown in Fig. 83. *a*.

*Action.*—To extend the femur on the pelvis, and when the posterior limbs are fixed, to assist in rearing.

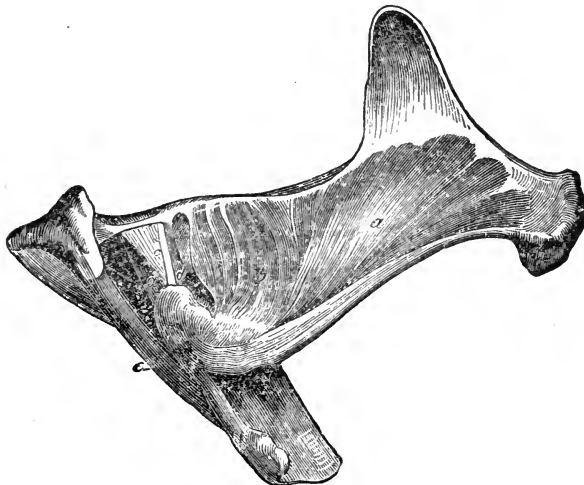


FIG. 83.

Deep-seated muscles of the gluteal region. *a*, Deep anterior portion of gluteus maximus ; *b*, Gluteus internus ; *c*, Common tendon of obturator internus and pyriformis ; *d*, Gemellus anticus and posticus ; *e*, Ischio-femoralis.

#### GLUTEUS INTERNUS.

(*Ilio-trochanterius Parvus.*)

(FIG. 83. *b*.)

Situated underneath the maximus and above the hip joint, this is a short and fan-shaped muscle, the fibres converging outwards.

*Origin.*—From the shaft of the ilium, the ischiatic spine, and the capsular ligament of the hip joint.

*Insertion.*—By a tendon to a roughened space inside the convexity of the trochanter major of the femur.

*Relation.*—Externally with the maximus; internally with the femur and hip joint.

*Action.*—To abduct the thigh, and rotate it inwards.

#### RECTUS PARVUS.

(*Ilio-femoralis Parvus—Grêle.*)

Situated in front of the hip joint, this is a very small, pale, and fusiform muscle, with a fleshy belly, and tendinous extremities.

*Origin.*—From the brim of the acetabulum, towards the outside; or it may be by two origins, an outer one, and one from between the tendons of origin of the rectus femoris, and the capsular ligament of the hip joint.

*Insertion.*—To the anterior and upper part of the femur, just below the hip joint, by aponeurotic slips.

*Relation.*—Externally and internally with the rectus femoris; posteriorly with the capsular ligament.

*Action.*—To tense the capsular ligament of the hip joint during flexion of the femur.

#### OBTURATOR EXTERNUS.

(*Subpubio-trochanterius Externus.*)

Placed on the inferior surface of the os innominatum, below the obturator foramen, which it covers, this muscle is flat, thick, and triangular, its belly consisting of delicate fasciculi, which pass outwards.

*Origin.*—From the surface of the pubis and ischium, attached to the obturator ligament.

*Insertion.*—In the trochanteric fossa.

*Relation.*—Inferiorly with the pectineus and adductors; superiorly with the capsular ligament of the hip joint and obturator ligament; posteriorly with the triceps abductor and ischio-femoralis.

*Action.*—To rotate the femur outwards, and adduct it.

## OBTURATOR INTERNUS.

*(Subpubio-trochanterius Internus.)*

(FIG. 83. c.)

Situated on the floor of the pelvic cavity, covering the obturator foramen, and corresponding to the externus; it is fan-shaped, with a delicate, fleshy belly, terminating in a flat tendon.

*Origin.*—From the border of the obturator foramen and its ligament; it passes through the lesser sciatic notch, behind the acetabulum, where its tendon joins that of the pyriformis.

*Insertion.*—In the trochanteric fossa.

*Relation.*—Superiorly with the pelvic fascia; inferiorly with the obturator ligament, ischium, and pubis; outside the pelvis, with the sciatic nerve above, and the externus below.

*Action.*—To rotate the femur outwards, and perhaps to abduct it slightly.

## PYRIFORMIS.

*(Sacro-trochanterius.)*

(FIG. 83. c.)

Situated laterally in the pelvic cavity, this is a flat, elongated, semipenniform muscle, with a small tendon of insertion.

*Origin.*—From the transverse processes of the sacral vertebræ, and the inner surface of the iliac shaft; lying along the inner side of the sacro-sciatic ligament, it passes through the lesser sciatic notch to join the tendon of the obturator internus.

*Insertion.*—In the trochanteric fossa.

*Relation.*—With the pelvic fascia internally; externally with the os innominatum; outside the pelvis it is crossed by the sciatic nerves; the obturator vessels and nerves pass along its lower border.

*Action.*—To rotate the femur outwards.

## GEMELLUS ANTICUS AND POSTICUS.

*(Gemini—Ischio-trochanterii.)*

(FIG. 83. d d.)

A pair of very delicate muscles, variable in form, and usually situated one above and before, the other below and behind the obturator internus tendon, with fleshy bellies and tendinous insertions.

*Origin.*—From the shaft of the ischium on either side of the conjoined tendon of the pyriformis and obturator internus, their fibres blending with it and passing outwards. There may be another flat and somewhat large muscle situated between the above and the obturator externus, originating also from the ischial ramus.

*Insertion.*—In the trochanteric fossa.

*Relation.*—Posteriorly with the sciatic nerves; anteriorly with the capsular ligament of the hip joint, and the obturator externus.

*Action.*—Like the preceding, to rotate the femur outwards.

### FEMORAL REGION.

The muscles of this region cover more or less the shaft of the femur, some of them reaching as far as, or below the stifle joint; the majority of them have a pelvic origin. These muscles may be conveniently divided into the four following groups:—

Internal.		Anterior.
External.		Posterior.

### INTERNAL FEMORAL GROUP.

#### ADDUCTORS.

These form the large fleshy mass situated between the inferior pelvic surface and the stifle joint; they are six in number:—

Sartorius.	
Gracilis.	
Pectineus.	
Adductor brevis.	}
Adductor longus.	
Adductor magnus.	

#### SARTORIUS.

(*Sublumbo-tibialis.*)

(FIG. 77. *l.*)

Situated in the abdominal cavity at the pelvic inlet, and along the inner aspect of the thigh, it is long, thin, fleshy, and pyramidal, extending obliquely downwards, forwards, and outwards.



*Origin.*—From the brim of the pelvis, and from the iliac fascia, near the tendon of the *psoas parvus*.

*Insertion.*—In common with the *gracilis*, by fascia to the internal straight ligament of the patella.

*Relation.*—Anteriorly with the crural arch and fascia; internally with the *psoas magnus* and *iliacus*; posteriorly with the *gracilis*, *pectineus*, and *vastus internus*. Its posterior border is related with the femoral artery, which, with the vein and internal saphenic nerve, passes through a space included between this muscle, the *iliacus*, and the *pectineus*, termed the *femoral space*.

*Action.*—To adduct and flex the femur.

#### GRACILIS.

(*Subpubio-tibialis.*)

(FIG. 77. c.)

Situated on the internal part of the thigh, this is a broad, thin, quadrilateral muscle, directed downwards and outwards. It has a flat fleshy belly, terminating in a broad aponeurosis.

*Origin.*—From the inferior surface of the ischio-pubic symphysis, where it meets its fellow.

*Insertion.*—With the *sartorius*, to the internal straight ligament of the patella, and also to the supero-internal part of the tibia; posteriorly its fascia blends with that of the *biceps rotator tibialis*, the two forming the fascia of the region.

*Relation.*—Anteriorly with the *sartorius*; internally with the adductor muscles of the thigh; posteriorly with the *biceps rotator tibialis*; externally with the crural aponeurosis and saphenic vein.

*Action.*—To adduct the limb, and tense the fascia of the leg.

#### PECTINEUS.

(*Super-pubio-femoralis.*)

(FIG. 76. f.)

Situated on the inner side of the preceding, this muscle is conical, the fibres extending outwards and backwards. It is tendinous, with a fleshy belly, bifid superiorly for the passage of the pubio-femoral ligament.

*Origin.*—From the brim and inferior surface of the pubis; it is also attached to the pubio-femoral ligament, which passes through its tendons of origin.

*Insertion.*—To a roughened surface on the inner side of the femur, below the internal trochanter, and near the nutrient foramen.

*Relation.*—Anteriorly with the sartorius, part of the psoas magnus, iliacus, and vastus internus; posteriorly with the adductor brevis and gracilis; superiorly with the obturator externus. The femoral vessels cross it.

*Action.*—To adduct and flex the thigh, and to rotate it inwards.

#### TRICEPS ADDUCTOR FEMORIS.

This name has been applied to a group of three muscles, situated on the inner surface of the thigh, and covered by the gracilis, which act the part of adductors. They have also been described as consisting of a biceps and a single muscle; we describe them as three distinct muscles, and name them, from before backwards, the *brevis*, the *longus*, and the *magnus*.

#### ADDUCTOR BREVIS.

(*Subpubio-femoralis*.)

(FIG. 76. g.)

Situated on the inner aspect of the thigh, behind the pectineus, this muscle is pyramidal, with the base upwards, its fibres converging downwards and outwards. Fleishy, with tendinous insertions inferiorly, it is often somewhat blended with the longus.

*Origin.*—Superiorly from the inferior surface of the pubis.

*Insertion.*—To a square, roughened surface on the posterior part of the shaft of the femur, about the middle, together with a portion of the long adductor.

*Relation.*—Anteriorly with the pectineus; posteriorly with the longus; externally with the gracilis; internally with the obturator externus.

*Action.*—To flex, adduct, and rotate the femur outwards.

## ADDUCTOR LONGUS.

*(Subpubio-femoralis Posterior.)*

(FIG. 76. h.)

Situated on the inner aspect of the thigh, covered by the gracilis, this muscle is long, flat, and prismatic, extending outwards and downwards.

*Origin.*—From the inferior surface of the posterior part of the pubis.

*Insertion.*—By two divisions, one attached by the insertion of the brevis, the other, with the magnus, above the internal condyle of the femur at the attachment of the lateral ligament.

*Relation.*—Anteriorly with the brevis and obturator externus; posteriorly with the magnus; externally with the gracilis; internally with the ischio-femoralis and sciatic nerves. The femoral vessels pass between its two divisions.

*Action.*—To adduct the femur, and rotate it outwards.

## ADDUCTOR MAGNUS.

*(Semimembranosus—Ischio-tibialis.)*

(FIG. 76. i.)

Placed behind the preceding, on the postero-internal part of the thigh, this muscle is thin at its extremities and posterior border, thick and fleshy elsewhere, terminating in a short tendon.

*Origin.*—Chiefly from the inferior surface and tuberosity of the ischium by tendinous fibres, and by a slender band from the coccygeal fascia.

*Insertion.*—To a small roughened surface on the inner side of the internal condyle of the femur

*Relation.*—Anteriorly with the longus, to which it is very adherent; externally with the gracilis; posteriorly with the biceps rotator tibialis; internally with the triceps abductor.

*Action.*—To adduct and extend the thigh. If the limb be fixed, it assists in raising the anterior parts of the trunk in "rearing."

## EXTERNAL FEMORAL REGION.

## ABDUCTORS.

This region contains only one muscle, which is situated laterally with respect to the haunch, but more posteriorly with regard to the femur.

## TRICEPS ABDUCTOR FEMORIS.

*(Ischio-tibialis Externus.)*(PL. II. 55; FIG. 84. *d d d*.)

Situated on the external part of the haunch, behind and below the great gluteal muscles, this is a very large and fleshy muscle,

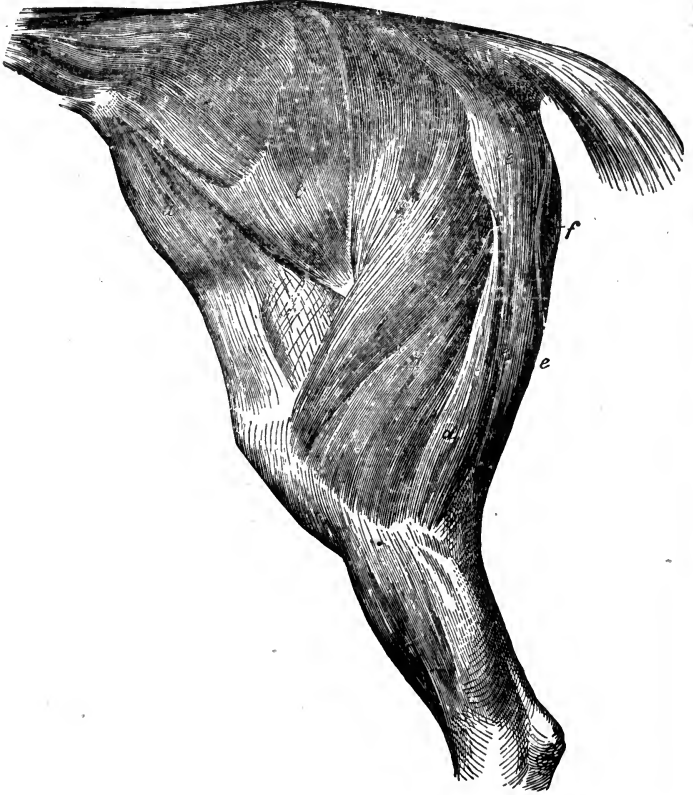


FIG. 84.

Muscles of the thigh and haunch—left side; the external fascia being removed. *a*, Tensor fasciæ latæ; *b*, Gluteus externus; *c*, Gluteus maximus; *d d d*, Triceps abductor femoris; *e e*, Biceps rotator tibialis; *f*, Part of adductor magnus.

made up of two prismatic portions, with two origins and three insertions. The anterior portion is much the longer. The fibres pass downwards in a somewhat curved manner, the larger convexity being to the rear.

*Origin.*—The anterior portion arises from the spine of the sacrum, the coccygeal fascia, and the sacro-sciatic ligament; also from the ischial tuberosity; the posterior portion is attached to the crest of the ischial tuberosity.

*Insertion.*—Anteriorly to the external side of the patella and its external ligament, a synovial bursa lying between it and the bone; posteriorly by a strong aponeurosis to the tibial fascia, which it helps to form, and by it to the tibial crest. It sends a strong slip which is attached near the insertion of the ischio-femoralis.

*Relation.*—Externally and superiorly with the gluteal fascia, to which it adheres above; internally with the fascia of the gluteus externus, which separates it from the maximus and the femoral trochanter; with the sciatic nerves, the adductor muscles, and biceps rotator, excepting at the upper portion, where it is related posteriorly with the latter muscle.

*Action.*—The anterior portion extends the femur and abducts the limb; the posterior portion flexes the stifle joint and tenses the tibial fascia. It assists the abductor magnus when the limb is fixed. (*Vide* Abductor Magnus.)

#### ANTERIOR FEMORAL REGION.

The muscles of this region lie in the space between the iliac spine above, the patella below, and the femur and hip joint posteriorly. They are as follows:—

Tensor fasciæ latæ.	}	Triceps or quadriceps cruralis.
Rectus femoris.		
Vastus externus.		
Vastus internus.		
Crureus.		

#### TENSOR FASCLE LATÆ.

(*Tensor Vaginæ Femoris—Ilio-aponeuroticus.*)

(PL. II. 54; FIG. 84. a.)

Situated in front of the gluteus externus, and on the outside of the vastus externus, this muscle is flat and triangular, radiating downwards and backwards.

*Attachments.*—The fleshy portion arises from the anterior iliac

spine, and from it springs the aponeurotic expansion termed the fascia lata. (See Fasciæ of the Posterior Limb, p. 255.)

*Relation.*—Internally with the iliacus, rectus femoris, and vastus externus; externally with the skin; posteriorly with the gluteus maximus and externus; anteriorly with the precruval lymphatic glands.

*Action.*—It assists in flexing the femur, raising the limb; and it tenses the fascia lata.

#### CRURAL MUSCLES.

The remaining muscles of this region, being all of them inserted to the patella, may be described as a single muscle, the *triceps* or *quadriceps cruralis*; or the rectus may be regarded as a single muscle, and the other three described together as the *triceps cruralis*; or, again, they may be considered as separate muscles. The above names being borne in mind, the last is perhaps the simplest method, and is the one adopted here. These muscles are considerably blended, and cannot well be perfectly separated without cutting muscular fibre.

#### RECTUS FEMORIS.

(*Ilio-rotuleus.*)

(PL. III. 34; FIG. 76. l.)

Situated on the anterior part of the thigh, between the two vasti, it is thick, elongated, and fusiform, consisting of two short, flat tendons of origin, and a fleshy intersected belly, terminating in a conical aponeurotic envelope. It is directed downwards and forwards.

*Origin.*—From two depressions, one on each side of the iliac shaft, just before the acetabulum.

*Insertion.*—To the upper part of the patella.

*Relation.*—It lies between the vasti, and above the crureus, and superiorly between the iliacus and the tensor fasciæ latæ, with which it is related anteriorly. A pad of fat occupies the space between its tendons of origin and the capsular ligament of the hip joint.

*Action.*—To flex the femur, and extend the leg.

## VASTUS EXTERNUS.

*(Femoro-rotuleus Externus.)*

(Pl. III. 35.)

Situated on the outer side of the rectus femoris, this muscle is broad, thick, flattened laterally, and semi-ovoid, extending downwards and forwards; it is fleshy, with strong tendinous intersections.

*Origin.*—From the external and part of the anterior aspects of the shaft of the femur, and from the base of the trochanter major downwards.

*Insertion.*—To the upper and outer part of the patella; or it may join the rectus femoris.

*Relation.*—Externally with the tensor fasciæ latæ, and gluteus externus; internally with the rectus, crureus, and vastus internus, with which inferiorly it is intimately blended; posteriorly with the triceps abductor femoris and the femur.

*Action.*—To extend the leg.

## VASTUS INTERNUS.

*(Femoro-rotuleus Internus.)*

(Fig. 76. k.)

Corresponding to the externus, this muscle is situated on the inner side of the rectus femoris, the two forming a channel in which are lodged the rectus and crureus. It is semi-ovoid, and fleshy, becoming tendinous at its insertion.

*Origin.*—From the neck of the femur, its antero-internal surface, and the trochanter internus.

*Insertion.*—To the upper and inner side of the patella.

*Relation.*—Externally with the rectus; internally with the sartorius, pectineus, psoas magnus, iliacus, adductor magnus, and crural fascia.

*Action.*—To extend the leg.

## CRUREUS.

*(Femoro-rotuleus Medius.)*

Situated below the rectus, and between the two vasti, this muscle is small, cylindrical, fleshy, and tendinous at its extremities; it is separated from the vasti with difficulty.

*Origin.*—From about the lower third of the anterior surface of the femur.

*Insertion.*—To the upper surface of the patella, and the capsular ligament of the joint.

*Relation.*—Anteriorly with the rectus; posteriorly with the femur; laterally with the vasti.

*Action.*—To assist the vasti, and tense the capsular ligament.

#### POSTERIOR FEMORAL REGION.

This region contains two muscles, a large superficial one, and a small one deeply situated; they are as follows:—

Biceps rotator tibialis.

Ischio-femoralis.

#### BICEPS ROTATOR TIBIALIS.

(*Semitendinosus—Ischio-tibialis Posticus.*)

(Pl. II. 61; FIG. 84. e. e.)

Situated behind the triceps abductor, and curved like it, with the convexity behind, this muscle is long, cylindrical, and bifid above, consisting of pale, fleshy fibres, divided by a strong aponeurosis.

*Origin.*—By one head, from the spine of the sacrum, and the sacro-sciatic ligament, in common with the triceps abductor; the other, which is considerably shorter, comes from the ischial tuberosity.

*Insertion.*—To the supero-internal part and anterior crest of the tibia, its aponeurosis blending with the tibial fascia and the periosteum.

*Relation.*—Superiorly and posteriorly it is covered by the gluteal fascia, and its sacral portion partly covers the triceps abductor, being related with it and the sciatic nerves anteriorly; externally with the abductor magnus.

*Action.*—To extend the femur, flex and rotate the leg outwards, and tense the tibial fascia.

#### ISCHIO-FEMORALIS.

(*Quadratus Femoris.*)

(FIG. 83. e.)

Situated behind the femur, between the adductor and abductor muscles. This muscle consists of a flattened band, running downwards and outwards.



*Origin.*—From the inferior surface of the ischium, in front of the tuberosity.

*Insertion.*—To a linear imprint on the posterior surface of the femur, just below the level of the trochanter internus.

*Relation.*—Anteriorly with the femur and obturator externus; posteriorly and externally with the adductor magnus; internally with the gemellus posticus, and the sciatic nerves.

*Action.*—To extend and adduct the femur, but not, in the horse, to rotate it.

TIBIAL REGION.

This region corresponds to the antibrachial region of the anterior limb, and, like the latter, contains chiefly flexor and extensor muscles. The strong tibial fascia invests the region, and is attached to the tibial crest, and to the summit of the calcaneum, being tensed by the gracilis and other muscles. The muscles of this region cover the tibia and fibula, except on the inner side of the former, and they consist of an anterior and a posterior group; but as the flexor side of the tarsal joint is anterior, and, in the joints below, posterior, we find flexor and extensor muscles both before and behind. In the anterior limb it is not so, the carpus and the joints below all flexing in the same direction.

ANTERIOR TIBIAL GROUP.

We subdivide this group into the flexors and extensors; there are two of the latter and only one of the former.

<i>Flexor.</i>		<i>Extensors.</i>
Flexor metatarsi.		Extensor pedis. Peroneus.

FLEXOR METATARSII.

(*Tibio-premetatarsus.*)

(FIG. 85. a.)

This muscle is situated on the antero-external aspect of the leg, and consists of two distinct parts, one fleshy, the other tendinous. The tendinous portion appears as a very strong fibrous cord, situated in front of the fleshy portion, and running the whole length of the muscle. The fleshy portion is coniform, thick above, and thinner below.

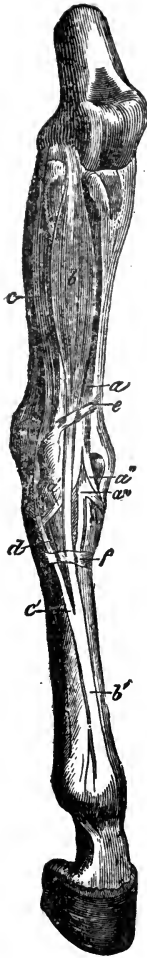


FIG. 85.

Anterior tibial group of muscles of the right limb, seen from before and the outside. *a*, Flexor metatarsi; *a'*, Tendon to the cuboid; and *a''*, Tendon to the metatarsus, from its funicular portion; *a'''*, Tendon of its fleshy portion, sending a straight slip to the metatarsus, and an oblique one to the cuneiform bone; *b*, Extensor pedis; *b'*, Its tendon; *c*, Peroneus; *d*, Point where its tendon joins that of the extensor pedis; *e*, Extensor pedis brevis; *e*, Superior, and *f*, Inferior thick portions of the annular ligament.

*Attachments.*—The tendinous portion arises from the depression between the trochlea and condyle of the femur, and lies in the superior tibial groove, clothed above by a reflection of one of the synovial membranes of the stifle joint; below this point it gives attachment to fibres of the fleshy portion and of the extensor pedis; in front of the astragalus it forms a ring, through which the tendon of the fleshy portion passes; at the tarsus it bifurcates, a very strong slip being attached to the large metatarsal bone, and a small one, which inclines outwards, to the cuboid bone.

The fleshy portion arises from the head of the tibia, and its groove, also from the tendinous part, receiving slips from the latter; its tendon of insertion, after passing through the above-named ring, bifurcates, and is inserted by a broad portion to the front of the great metatarsal bone, and by a smaller slip, which winds inwards, to the small cuneiform bone.

*Relation.*—Anteriorly with the extensor pedis; posteriorly with the external aspect of the tibia, and the anterior tibial artery.

*Action.*—It flexes the tarsal joint. The tendinous portion may be regarded as a strong fibrous communication between the femur and the metatarsus, which, when the stifle joint is flexed, becomes tensed, and *mechanically* repeats the action upon the joint below.

## EXTENSOR PEDIS.

*(Femoro-prephalangeus.)*

(FIG. 85. b.)

Situated on the anterior surface of the tibia and bones below, this is a long fusiform muscle, extending downwards and backwards. A little above the tarsus, the belly terminates in a long, flat tendon, which, bound down by the three bands of the annular ligament, passes down the front of the tarsus and metatarsus, near the middle of which it receives the extensor brevis, and the tendon of the peroneus; the united tendon now passes down, and is arranged *like that of the anterior limb*.

*Origin.*—From the fossa between the trochlea and external condyle of the femur, by the tendon of the flexor metatarsi, common to it.

*Insertion.*—To the capsular ligament of the fetlock joint, the anterior surface of the two first phalanges, and the pyramidal process of the os pedis.

*Relation.*—Anteriorly with the fascia; internally with the flexor metatarsi; posteriorly with the peroneus.

*Action.*—To extend the entire digit, and flex the tarsal joint.

## PERONEUS.

*(Peroneo-prephalangeus.)*

(FIG. 85. c.)

Situated on the external side of the leg, this is a long and somewhat penniform muscle, consisting of a prismatic, fleshy belly, which originates by a short, and terminates by a long tendon; the latter passes through a theca on the external side of the tarsus, joining the tendon of the extensor pedis below the joint.

*Origin.*—From the external lateral ligament of the stifle joint, and the entire length of the fibula.

*Insertion.*—It joins the tendon of the extensor pedis.

*Relation.*—Externally with the fascia; anteriorly with the extensor pedis; posteriorly with the flexor pedis perforans.

*Action.*—It assists the extensor pedis.

## POSTERIOR TIBIAL GROUP.

For convenience of description, we subdivide the muscles of this group, but the subdivision is a somewhat artificial one, as some of the muscles have two actions, flexing one joint and extending another.

*Extensors.*

Gastrocnemius.  
Plantaris.

*Flexors.*

Flexor pedis perforatus.  
Flexor pedis perforans.  
Flexor pedis accessorius.  
Popliteus.

## GASTROCNEMIUS.

(*Bifemero-calcaneus.*)

(PL. III. 33.)

Situated at the back of the leg, this muscle is somewhat heart-shaped, ending in a flattened tendon; the fleshy belly is divisible into two portions, and intersected superiorly by strong tendons.

*Origin.*—By two heads; one from a ridge extending upwards from the external condyle in front of the supracondyloid fossa; the other from the posterior surface of the femur, just above the intercondyloid fossa, and from the internal condyle.

*Insertion.*—To the posterior part of the summit of the calcaneum, a synovial bursa being interposed between it and the anterior part, over which it passes.

*Relation.*—Anteriorly with the flexor perforatus, popliteus, popliteal vessels and nerves, and the vastus externus above; posteriorly with the triceps abductor femoris; internally with biceps rotator tibialis; superficially with the tibial fascia; inferiorly the tendon is covered by that of the flexor perforatus, the two forming the *Tendo-Achillis*.

*Action.*—To extend the tarsal joint.

## PLANTARIS.

*(Soleus—Peroneo-calcaneus.)*

(PL. III. 39.)

Situated on the postero-external part of the leg, to the outside of the gastrocnemius, this muscle is, in the horse, slender and rudimentary, with a small, delicate tendon of insertion.

*Origin.*—From the external part of the head of the fibula.

*Insertion.*—Together with the tendon of the gastrocnemius to the point of the calcaneum.

*Relation.*—Externally with the fascia; internally with the gastrocnemius.

*Action.*—It assists very slightly the gastrocnemius.

## FLEXOR PEDIS PERFORATUS.\*

*(Femoro-phalangeus.)*

(FIG. 86 b.)

Situated immediately underneath the gastrocnemius, this muscle is in shape funicular, consisting of a strong fibrous cord, with a slightly fleshy portion above, and arising from the supracondyloid fossa; the belly is succeeded by a strong tendon, united to fascia, which is fixed to the inner surface and ridge of the tibia and the summit of the calcaneum, being continuous with the tibial fascia, and enclosing the entire tendo-Achillis. The tendon, at first under that of the gastrocnemius, winds round its inner side, and then surmounts it; on reaching the point of the calcaneum it forms a cap, giving slips of insertion to the sides of that bone; a large synovial bursa exists here, which is one of the seats of the lesion termed *capped hock*. It now descends posteriorly, and is disposed as is the corresponding tendon in the anterior extremity, forming a synovial sheath and ring for the perforans tendon, and finally bifurcating to become attached to the sides of the os coronæ.

*Relation.*—Posteriorly with the gastrocnemius; anteriorly with the tibia, the popliteus, perforans, and accessorius muscles.

\* This muscle was formerly described under the name of gastrocnemius internus. The more appropriate one now in use is adopted here.

*Action.*—To flex the fetlock and pastern joints, and assist in extending the tarsus; when the animal is stationary, it serves mechanically, as a fibrous band, to prevent flexion of the tarsal joint.

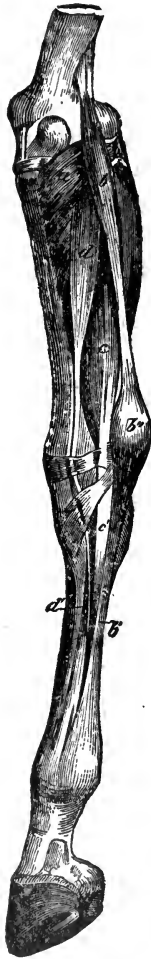

FIG. 86.

Posterior tibial group of muscles of the right limb—postero-internal view. The gastrocnemius is removed. *a*, Popliteus; *b*, Flexor pedis perforatus; *b'*, Its tendon; *b''*, Expansion of its tendon forming the cap of the hock; *c*, Flexor pedis perforans; *c'*, Its tendon; *d*, Flexor accessorius; *d'*, Union of its tendon with that of the perforans.

#### FLEXOR PEDIS PERFORANS.

(*Tibio-phalangeus.*)

(FIG. 86. *c.*)

Situated on the posterior aspect of the leg, extending from the head of the tibia to the distal phalanx, this muscle is thick and prismatic, consisting of a fleshy, intersected belly and long tendon of insertion. The belly is partially bifid, the internal portion being the larger. The tendon commences a little above the hock, passes through the groove on the inner side of the calcaneum, first crossing the posterior capsular ligament of the tarsus, where it is bound down by fibrous tissue, in a synovial sheath, the usual seat of *Thorough-pin*. It then descends behind the metatarsal bone; about half-way down, it is joined by the check ligament, which springs from the lower bones of the tarsus and head of the metatarsal bone, and is similar to, but considerably less than, that of the fore extremity. It is joined above by the tendon of the flexor accessorius, and is otherwise disposed exactly as the perforans tendon of the anterior extremity.

*Origin.*—From the roughened posterior aspect, and head of the tibia, the fibula, and fibulo-tibial ligament.

*Insertion.*—To the semilunar ridge

on the solar surface of the os pedis.

*Relation.*—Posteriorly with the gastrocnemius and flexor perforatus; anteriorly with the tibia; internally with the flexor pedis accessorius; externally with the peroneus.

*Action.*—To flex the phalanges, and assist in extending the tarsal joint.

#### FLEXOR PEDIS ACCESSORIUS.

(*Flexor Obliquus—Peroneo-phalangeus.*)

(FIG. 86. d.)

This muscle is situated on the posterior part of the leg, between the popliteus and flexor pedis perforans. It is fleshy, with numerous fibrous intersections, and inferiorly a terminal tendon.

*Origin.*—From the external tuberosity of the tibia, and sometimes slightly from the fibula; the tendon commences just above the tarsal joint, and passes through a theca on its internal aspect.

*Insertion.*—It joins the tendon of the flexor perforans at about a third from its commencement.

*Relation.*—Posteriorly with the gastrocnemius and flexor perforatus; anteriorly with the perforans, the popliteus, and the posterior tibial artery.

*Action.*—To assist the flexor pedis perforans.

#### POPLITEUS.

(*Femoro-tibialis Obliquus.*)

(FIG. 86. a.)

Situated at the back of the tibia, just below the stifle joint, this muscle is triangular and fleshy, the fibres passing obliquely downwards and inwards.

*Origin.*—By a tendon from a fossa outside the external condyle of the femur; it is attached to the capsular ligament of the stifle joint.

*Insertion.*—The triangular surface on the supero-posterior part of the tibia, and the upper portion of its internal border.

*Relation.*—Posteriorly with the gastrocnemius and flexor perforatus; anteriorly with the tibia, the capsular ligament, and the tibial vessels; externally with the flexor pedis perforans and accessorius; internally with the biceps rotator, and tibial fascia.

*Action.*—It flexes the leg, rotates it inwards, and tenses the capsular ligament of the stifle joint.

## METATARSAL REGION.

In this region we have the lumbricales and interossei as in the anterior extremity, and also the extensor pedis brevis.

## EXTENSOR PEDIS BREVIS.

(*Extensor Pedis Accessorius.*)

(FIG. 85. d.)

Situated in front of, and below the tarsal joint, it is small and triangular in form, filling up the space between the converging tendons of the extensor pedis and peroneus.

*Origin.*—From the infero-anterior part of the astragalus; it is also attached to the cuneiform bones.

*Insertion.*—It joins the tendons of the extensor pedis and peroneus.

*Relation.*—Underneath this muscle passes the anterior tibial artery, giving off the perforating pedal branch.

*Action.*—It assists slightly the extensors of the foot.

## ARRANGEMENT OF THE FASCIAE.

We have already seen that the muscular system is invested by an areolo-fibrous covering, which has been named the superficial fascia. This covering varies very much in density in different regions, and in some becomes blended with the aponeurosis of the panniculus; and generally where the muscles are braced by the fleshy portion of the latter, the investing fascia is more or less rudimentary, as in the head and neck; it is with difficulty demonstrable as a separate structure in the latter. The tunica abdominalis has been considered as an elastic development of the investing abdominal fascia.

## DEEP FASCIAE.

The following may convey a general idea of the arrangement of the deep or aponeurotic fasciæ. Each muscle is more or less completely covered by a fold of fascia, which forms a sheath round it and its tendon; it then passes to and covers another



muscle, and so on until it finally gives off an expansion which covers the entire group or region, becoming firmly attached to the skeleton, and usually at its salient points. Hence we may regard an aponeurotic fascia as a compound sheath, which contains in its compartments muscles and their concomitant structures, and aids the former in their action by passive support; the support thus afforded is not always wholly passive, since, as we have seen, some fasciæ are regulated as to their tension by special muscles, the fasciæ of the limbs affording good examples of this arrangement.

Some of the deep fasciæ merit special attention, and we shall consider them in the order generally observed in dealing with other widely-diffused structures—*i.e.*, as pertaining to the Head, the Trunk, and the Limbs.

#### FASCIÆ OF THE HEAD.

In this region there is little that is noteworthy in the disposition of the fascia. It is, however, much stronger in the posterior than in the anterior portion, the muscles of the former being separated merely by folds which closely resemble ordinary connective tissue. The *temporal fascia* is the name given to a strong fold which covers the temporal fossa, being attached to the parietal ridge and to the zygoma, and corresponding to the temporalis and attollentes muscles.

#### FASCIÆ OF THE TRUNK.

These are the cervical, dorso-lumbar, abdominal, and thoracic fasciæ.

The deep fascia of the *cervical* region is better marked than the superficial, and it invests the muscles in the typical manner above described, becoming attached to the vertebræ. In the *dorso-lumbar* region it is variable, being thin in some situations, but thick and strong in others; that covering the postero-superior part of the longissimus dorsi is actually tendinous in structure, giving origin to part of the gluteus maximus. The dorso-lumbar fascia becomes continuous posteriorly with that of the gluteal region, and anteriorly with that of the external scapular region.

The deep *abdominal fascia* chiefly includes the following

portions:—The *transverse*, the *iliac*, the *pelvic*, the *inguinal*, and the *perineal*. The *transverse* (fascia transversalis) is interposed between the transversalis abdominis and the peritoneum, and is in the horse a very thin structure; in the human subject, and in some other animals, it is thickened posteriorly, and attached to the crural arch. The *iliac fascia* (fascia iliaca) covers the muscles of the sublumbar region, especially the psoas magnus and iliacus, which it enfolds and accompanies to their insertion. It is attached internally along the tendon of the psoas parvus muscle, by which it is tensed, externally to the anterior iliac spine; anteriorly it becomes very rudimentary, although it may sometimes be traced as far as the arcuate ligament of the diaphragm. The sartorius and cremaster muscles arise partly from this fascia.

The *pelvic fascia* (fascia pelvica) is a strong layer lining the pelvic cavity, and covered anteriorly by the peritoneum; inferiorly, it splits into two folds, the external of which lines the sides and floor of the cavity, and is named the *obturator fascia*, since it covers the internal muscles of that name; it also furnishes a sheath for the internal pudic vessels. The other fold, the *rectovesical fascia*, is reflected inwards and posteriorly gives off bands, one of which separates the bladder from the rectum, another investing the latter, while two others serve as ligaments of the bladder. The *inguinal* and *perineal fasciæ* will be more appropriately described in a future section of the work.

The *thoracic fascia* stretches across the anterior opening of the thorax, and is its anterior boundary, surrounding and bracing the various structures which pass through, and helping to keep them in their relative positions.

#### FASCIAE OF THE ANTERIOR LIMB.

These correspond to the various regions of the limb. The *external scapular fascia* is very strong superiorly, and it covers the external scapular muscles, giving off folds which enclose them. It is attached to the cartilage and spine of the scapula, and is continuous with the dorso-lumbar fascia behind, the subscapular fascia round the edge of the antea-spinatus, and below with the brachial fascia. It is tensed by the pectoralis parvus and teres externus muscles. The *brachial fascia* is comparatively thin; it covers and invests the humeral and triceps extensor muscles,

and is continued below by the *antibrachial fascia*, which is exceedingly thick and strong, firmly bracing the muscles of the fore-arm; it is attached to the inner side of the radius, to its distal end both externally and internally, and likewise to the olecranon. On the inner aspect of the limb it is separable into layers, the external of which is tensed by the *pectoralis transversus*, while the internal gives off folds which pass between the muscles and form sheaths for them, and is attached superiorly to the *flexor brachii* and *scapulo-ulnaris* muscles, which are its tensors. Inferiorly, this fascia becomes continuous with the annular ligaments of the carpus, thus helping to form sheaths for the passage of the tendons.

#### FASCIÆ OF THE POSTERIOR LIMB.

The *gluteal fascia* covers the region of the same name, and is thick, strong, and somewhat elastic, usually containing more or less fatty matter. It is continuous anteriorly with the fascia of the dorso-lumbar region, posteriorly and externally with the crural fascia, and is firmly attached to the anterior iliac and the sacral spines. Its internal surface gives attachment to portions of the *gluteus maximus* and *externus*.

The *femoral* or *crural fascia* surrounds the muscles of the thigh. The anterior and external portions are known as the *fascia lata*; the internal portion anteriorly is derived from the aponeurosis of the *obliquus abdominis externus*; passing backwards, it becomes rudimentary, and is replaced posteriorly by connective tissue. The *fascia lata* encloses the *triceps cruralis*, and externally divides into two folds, internal and external; the former passes between the *vastus externus* and *triceps abductor*, and accompanies the tendon of the *gluteus externus* to its insertion at the trochanter minor; the external fold covers the *triceps abductor* muscle, becoming continuous above with the *gluteal fascia*. The *fascia lata* is attached inferiorly to the patella, and below is continuous with the aponeurotic insertion of the *triceps abductor*, and so with the *tibial fascia*; it is tensed by its own muscle, the *tensor fasciæ latæ*.

The *tibial fascia*, like the *antibrachial*, to which it corresponds, is very strong and thick, and covers the tibial group of muscles, sending in folds to form sheaths for them. It gives attachment to the *triceps abductor*, *biceps*, *rotator*, and *gracilis* muscles, which

presumably act as its tensors. It is attached to the crest and inner aspect of the tibia, and also to the calcaneum, and it blends with the annular ligaments of the tarsal joint, assisting in forming sheaths for the tendons. This fascia is continued over the tarsus and metatarsus: becoming somewhat thinner inferiorly; between the tendo-Achillis and the flexor muscles of the foot it is very strong, giving powerful bands to the former, and, near the calcaneum, helping to form a sheath for the gastrocnemius tendon. Below and before the tendo-Achillis it divides into two folds, which assist externally and internally in the formation of the tarsal sheath, for the perforans tendon; between these folds are the posterior vessels and nerves of the region.

#### TABLE OF MUSCULAR ATTACHMENTS.

In the following Table we enumerate the principal bones of the horse, tabulating the names of the most important muscles which are attached to each :-

##### THE HEAD.

<p>CRANIAL BONES.</p> <p>OCCIPITAL.</p> <p>Levator humeri.</p> <p>Splenius.</p> <p>Complexus, major and minor.</p> <p>Rectus capitis anticus, major, minor, and lateralis.</p> <p>Rectus capitis posticus, major and minor.</p> <p>Obliquus capitis anticus.</p> <p>Stylo-hyoideus.</p> <p>Stylo-maxillaris.</p> <p>Digastricus.</p> <p>PARIETAL.</p> <p>Temporalis.</p> <p>FRONTAL.</p> <p>Levator labii superioris aëque nasi.</p> <p>TEMPORAL.</p> <p>Trachelo-mastoideus.</p>	<p>Levator humeri.</p> <p>Temporalis.</p> <p>Mastoido-auricularis.</p> <p>SPHENOID.</p> <p>Rectus capitis anticus, major and minor.</p> <p>Pterygoideus, externus and internus.</p> <p>FACIAL BONES.</p> <p>SUPERIOR MAXILLA</p> <p>Panniculus carnosus.</p> <p>Masseter.</p> <p>Buccinator.</p> <p>Nasalis longus.</p> <p>Dilatator naris lateralis.</p> <p>PREMAXILLA.</p> <p>Dilatator naris inferioris.</p> <p>Depressor labii superioris.</p>
---	--

## NASAL.

Dilatator naris superioris.

## LACHRYMAL.

Orbicularis palpebrarum.  
Lachrymalis.

## MALAR.

Nasalis longus.

## PALATINE.

Pterygoideus internus.

## INFERIOR MAXILLA.

Masseter.  
Temporalis.  
Pterygoideus, externus and internus.  
Sterno-maxillaris.  
Stylo-maxillaris.Buccinator.  
Levator labii inferioris.  
Depressor labii inferioris.  
Mylo-hyoideus.  
Genio-hyoideus.  
Digastricus.

## HYOID SERIES.

Sterno-thyro-hyoideus.  
Subscapulo-hyoideus.  
Myo-hyoideus.  
Genio-hyoideus.  
Hyoideus magnus.  
Hyoideus parvus.  
Hyoideus transversus.  
Stylo-hyoideus.  
Certain muscles of the tongue,  
pharynx, larynx, and soft palate  
are not enumerated here.

## THE TRUNK.

## CERVICAL VERTEBRÆ.

## ATLAS.

Levator humeri.  
Splenius.  
Trachelo-mastoideus.  
Obliquus capitis, anticus and  
posticus.  
Rectus capitis anticus, major,  
minor, and lateralis.  
Longus colli.

## DENTATA.

Longus colli.  
Levator humeri.  
Intertransversalis colli.  
Obliquus capitis posticus.  
Complexus minor.  
Rectus capitis posticus major.  
Spinalis colli.

## SEGMENTS 3 TO 7.

Longus colli.

Rectus capitis anticus major (3rd  
to 5th).  
Intertransversalis colli.  
Transversalis costarum (7th)  
Levator humeri (3rd and 4th).  
Splenius (3rd to 5th).  
Serratus magnus.  
Spinalis colli.  
Trachelo-mastoideus.  
Complexus major.  
Longissimus dorsi (4th to 7th).

## DORSAL VERTEBRÆ.

Splenius } (first 6).  
Complexus major }  
Trachelo-mastoideus (first 2).  
Trapezius dorsalis (3rd to 11th).  
Latissimus dorsi (last 15).  
Superficialis costarum (last 17).  
Rhomboides brevis (2nd to 7th).  
Longissimus dorsi.

Semispinalis dorsi.  
 Levatores costarum.  
 Longus colli.  
 Psoas parvus (last 3).  
 Psoas magnus (last 2).

## LUMBAR VERTEBRÆ.

Latissimus dorsi.  
 Superficialis costarum (first 3).  
 Longissimus dorsi.  
 Semispinalis lumborum.  
 Psoas magnus.  
 Psoas parvus.  
 Quadratus lumborum.  
 Intertransversalis lumborum.  
 Transversalis abdominis.  
 Crura diaphragmatica.

## SACRUM.

Longissimus dorsi.  
 Semispinalis lumborum.  
 Gluteus externus.  
 Gluteus maximus.  
 Triceps abductor femoris.  
 Biceps rotator tibialis.  
 Piriformis.  
 All the coccygeal muscles.

## COCCYX.

All the coccygeal muscles.  
 The Compressor coccygis to the  
 first 2 segments.

## SCAPULA.

Trapezius.  
 Levator humeri.  
 Antea-spinatus.  
 Postea-spinatus.  
 Postea-spinatus minor.  
 Teres externus.  
 Rhomboideus, longus and brevis.  
 Serratus magnus.  
 Subscapularis.

## RIBS AND COSTAL CARTILAGES.

Scalenus (1st).  
 Superficialis costarum (last 14).  
 Longissimus dorsi (last 16).  
 Transversalis costarum.  
 Serratus magnus (first 8).  
 Lateralis sterni (1st).  
 Triangularis sterni (2nd to 8th).  
 Intercostales.  
 Levatores costarum.  
 Obliquus abdominis externus (last  
 14).  
 Transversalis abdominis (last 10).  
 Obliquus abdominis } (cartilages).  
 internus. }  
 Rectus abdominis. }  
 Diaphragm (last 12).  
 Psoas magnus (last 2).  
 Quadratus lumborum (last 3).

## STERNUM.

Panniculus carnosus.  
 Sterno-maxillaris.  
 Sterno-thyro-hyoideus.  
 The four Pectorales.  
 Lateralis sterni.  
 Triangularis sterni.  
 Rectus abdominis.  
 Transversalis abdominis.  
 Diaphragm.

## PECTORAL LIMB.

Pectoralis parvus.  
 Scapulo-ulnaris.  
 Caput magnum.  
 Scapulo-humeralis posticus.  
 Teres internus.  
 Coraco-humeralis.  
 Flexor brachii.

## HUMERUS.

Antea-spinatus.  
 Postea-spinatus.

Postca-spinatus minor.  
 Subscapularis.  
 Scapulo-humeralis posticus.  
 Pectoralis, magnus and anticus.  
 Panniculus carnosus.  
 Teres, externus and internus.  
 Coraco-humeralis.  
 Humeralis obliquus.  
 Caput medium and parvum.  
 Anconeus.  
 Latissimus dorsi.  
 Levator humeri.  
 Extensor metacarpi magnus.  
 Extensor pedis.  
 Three Flexores metacarpi.  
 Flexor, perforans and perforatus.

## RADIUS.

Flexor brachii.  
 Humeralis obliquus.  
 Extensor metacarpi, magnus and obliquus.  
 Extensor pedis.  
 Extensor suffraginis.  
 Radialis accessorius.

## ULNA.

Triceps extensor brachii.  
 Scapulo-ulnaris.  
 Anconeus.  
 Flexor metacarpi medius.  
 Ulnaris accessorius.  
 Humeralis obliquus.  
 Extensor suffraginis.

## TRAPEZIUM.

Flexor metacarpi, externus and medius.

## METACARPUS.

## LARGE BONE.

Extensor metacarpi magnus.

## EXTERNAL BONE.

Flexor metacarpi externus.

## INTERNAL BONE.

Extensor metacarpi obliquus.  
 Flexor metacarpi internus.

## DIGIT.

Extensor pedis (three phalanges).  
 Extensor suffraginis (1st phalanx).  
 Flexor perforatus (2nd phalanx).  
 Flexor perforans (3rd phalanx).

## PELVIC LIMB.

## OS INNOMINATUM.

Longissimus dorsi.  
 Compressor coccygis.  
 Four Abdominales.  
 Three Glutei.  
 Tensor fasciæ latæ.  
 Rectus femoris.  
 Rectus parvus.  
 Obturator, externus and internus.  
 Piriformis.  
 Two Gemelli.  
 Iliacus.  
 Psoas parvus.  
 Quadratus lumborum.  
 Gracilis.

Sartorius.  
 Pectineus.  
 Triceps adductor femoris.  
 Triceps abductor femoris.  
 Biceps rotator tibialis.  
 Ischio-femoralis.

## FEMUR.

Psoas magnus.  
 Iliacus.  
 Three Glutei.  
 Obturator, externus and internus.  
 Piriformis.  
 Two Gemelli.  
 Tensor fasciæ latæ.  
 Vastus, externus and internus.

Rectus parvus.

Crureus.

Pectineus.

Triceps adductor femoris.

Triceps abductor femoris.

Ischio-femoralis.

Gastrocnemius.

Flexor perforatus:

Extensor pedis.

Flexor metatarsi.

Popliteus.

## TIBIA.

Sartorius.

Gracilis.

Triceps abductor femoris.

Biceps rotator tibialis.

Flexor metatarsi.

Plantaris.

Popliteus.

Flexor perforans.

Flexor accessorius.

## FIBULA.

Peroneus.

Flexor perforans.

## PATELLA.

Tensor fasciæ latæ.

Quadriceps cruralis.

Triceps abductor femoris.

## TARSUS.

## CALCANEUM.

Gastrocnemius.

## CUBOID AND SMALL CUNEIFORM.

Flexor metatarsi.

## METATARSUS.

## LARGE BONE.

Flexor metatarsi.

## DIGIT.

Extensor pedis (three phalanges).

Flexor perforatus (2nd phalanx).

Flexor perforans (3rd phalanx).

## COMPARATIVE MYOLOGY.

AN extensive section devoted to this subject would be somewhat out of place in an ordinary class-book; therefore for fuller descriptions and details the student must have recourse to exhaustive works of reference, or, what is still better, to his own dissections and observations, bearing in mind the typical branch of the subject. We shall endeavour to point out where the more important muscles of the domesticated animals present features which, for our purpose, are worthy of comparison with those of the selected type; and in this attempt we observe very generally the same sequence as to regions and groups that we have adopted in describing the muscles of the horse.

## RUMINANTIA.

## SUBCUTANEOUS REGION.

The panniculus carnosus in the cervical region is mostly aponeurotic; a muscle which resembles the sterno-maxillaris of the horse is sometimes regarded as constituting its inferior fleshy portion. In the head it resembles that of the horse, but there is a fleshy expansion in the frontal region—the so-called *frontalis* muscle—which is apparently a part of the panniculus. In the trunk there is no very important deviation from the arrangement already described.



## THE HEAD.

In the ruminant the palatine ridges being closer together, the *pterygoid* muscles originate nearer to the median line of the head, and thus produce more lateral motion in the lower jaw than there is in that of the horse. There is no *digastric* muscle in the domesticated animals other than the horse, the muscle representing it having only one belly; in the ox it is joined to its fellow on the other side by a small, square, transverse muscle. The *masseter* and *temporalis* are both less strong. Passing from the root of the horn core to the upper edge of the orbital fossa is a flat thin muscle, the *frontalis*, which blends with the external levator of the eyelid; it is, perhaps, a portion of the *panniculus*. The *levator labii superioris aequae nasi* is not present in the smaller ruminants, and in the ox it differs in that the anterior, instead of the posterior division, covers the dilatator naris lateralis, and that it covers the *nasalis longus* as well. Two accessory muscles arise in common with the last named, and go to the upper lip. The *dilatators* of the nostril, except the *lateralis*, are wanting. The *zygomaticus* has a long tendon of origin reaching up to the zygoma. The long tendon of insertion of the *depressor labii inferioris* is wanting.

The *hyoides magnus* has a long tendon of origin, and it forms no sheath, there being no median digastric tendon. The *lachrymalis* is closely blended above with the anterior border of the orbicularis palpebrarum, and is more developed and thicker than in the horse.

## THE TRUNK.

The muscle which would appear to correspond to the sterno-maxillaris of the horse, is considered by Chauveau as representing the inferior fleshy band of the *panniculus carnosus*; it is attached superiorly, not to the angle of the maxilla, but to the fascia of the masseter muscle, and sometimes it may be traced to the zygoma. This view being taken, the sterno-maxillaris finds its representative in the *sterno-suboccipitalis*, a muscle which becomes inserted to the basi-occipital bone in company with a tendon of the levator humeri. The *sterno-thyro-hyoides* is larger than in the horse, and not digastric. The *rectus capitis anticus major* is covered by the *trachelo-atloideus*, a flat muscle joining the atlas inferiorly to some of the succeeding vertebrae.

The *levator humeri* is attached anteriorly to the mastoid process, to the posterior surface of the occipital bone and the ligamentum nuchae, to the basi-occipital bone together with the sterno-suboccipitalis, and to the wing of the atlas by a tendon *separate* from that of the splenius and trachelo-mastoideus. In ruminants the *splenius* is very small; in the camel it is stated by Cuvier to be non-existent, or at least so small as to escape observation.

In the costal and dorso-lumbar regions there is little that merits comparison; we may, however, note that the *trapezius* and *serratus magnus* are largely developed; also that the intercostales and levatores costarum of course vary in number with the ribs. The *pectoralis anticus* is small, and blended considerably with the transversus.

The abdominal tunic is large and very thick, its development being always proportional to the magnitude of the abdominal viscera. The *lineae transversae* of the rectus abdominis are very well marked. The *obliquus internus* is large,

and fills up the space between the ilium, the last rib, and the lumbar vertebrae. The fascia transversalis is better marked than in the horse. In the

muscles of the sublumbar region no comparison is necessary.

The *diaphragm* in ruminants is thick and strong, being proportionate to the weight of the abdominal viscera, which it is its function to compress and force backwards. The crura are both long and large, and the periphery is attached more anteriorly than in the horse. In the camel the diaphragm usually contains a small bone.

#### PECTORAL LIMB.

The extensors of the metacarpus are disposed as in the horse, excepting that the tendon of the *obliquus* is inserted to the great metacarpal bone. The *extensor pedis* is divided throughout its length, giving rise to an external muscle, the *extensor communis digitorum*, and an internal one, the *extensor proprius internus*, the former being rather larger than the latter. The tendons of these muscles run down the metacarpus in company, and at the commencement of the digits that of the *extensor communis* bifurcates, a portion being inserted to the pyramidal process of each distal phalanx. The tendon of the *extensor proprius internus* receives slips from the suspensory ligament about the middle of the first phalanx, and is attached to the median, and outer surface of the internal distal phalanges. The *extensor suffraginis* becomes, in the ruminant, the *extensor proprius externus*, differing from the former

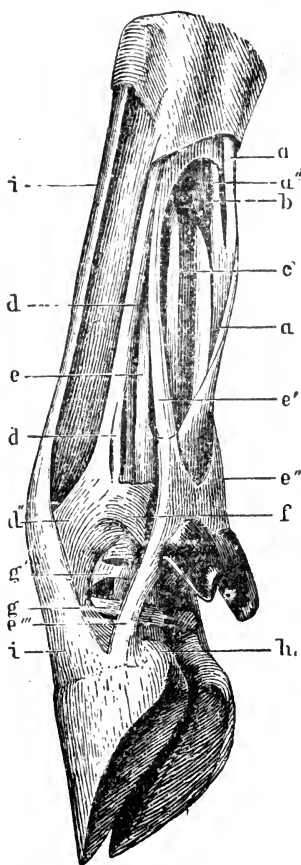


FIG. 87.

Tendons and ligaments of left anterior extremity of Ox, viewed from external side. *a*, Flexor perforatus tendon; *a'*, Its superficial; *a''*, Its deep branch; *b*, Interosseus metacarpeus; *c*, Flexor perforans tendon; *d*, *d'*, *e-e''*, Superior suspensory ligament and attachments; *d*, anterior division; *d'*, Its superficial branch, blending at *d''* with extensor proprius tendon; *e*, Deep branch of posterior division; *e'*, *e''*, Branches forming superior ligaments of small claw; *e'''*, Inferior ligament of small claw; *f*, Common annular ligament; *g*, *g'*, Superior and inferior special annular ligaments; *h*, Interdigital ligament; *i*, *i'*, Tendon of the extensor proprius externus.

muscle of the horse in being thicker and stronger, and in being inserted in the same manner as the internus. These three muscles are all extensors, but the

*communis* is also an *approximator*, while the *proprii* are *divertors* or expanders of the digits. The *flexor perforatus* is a double muscle, but unites to form a single tendon, which divides, and each part behaves as the single portion in the horse, being however assisted in the formation of the sheaths for the perforans tendons by two strong slips from the suspensory ligament, which correspond to the check ligament. In effect the check ligament may be said to be attached in the ruminant to the *perforatus* tendon only. The tendon of the *flexor perforans* also divides, the two parts passing through the sheaths formed as above described, and terminating in a similar manner to that of the horse, becoming however blended with the plantar cushion of the foot, and the inferior interdigital ligament.

#### PELVIC LIMB.

The *gluteus externus* is intimately blended with the triceps abductor. The *maximus* is nearly covered by the above compound muscle and that of the fascia lata, and is smaller than in the horse, while the *internus*, on the other hand, is larger. The *tensor fasciæ latæ* and triceps abductor become firmly united over the region of the trochanter major, the former muscle being largely developed, while the latter has no femoral attachment. The *rectus parvus* is wanting.

The *biceps rotator tibialis* has no sacral origin. There is no pyriformis muscle, but a muscle has been described, pursuing a similar course *outside* the pelvis, and so far corresponding to it. The tendon of the *obturator internus* passes through the obturator foramen.

The fibrous portion of the *flexor metatarsi*, and the extensor pedis of the horse have in the ox a common tendon of origin, giving rise to three large muscles of which the external one is the *extensor communis digitorum*, and the internal the *extensor proprius internus*, the tendons of these two terminating as in the anterior limb. The third muscle, situated before, and somewhat to the inner side of the others, is a flexor of the metatarsus, and represents the fibrous portion of the *flexor metatarsi* in the horse, forming a sheath or ring through which passes the tendon of the *tibialis anticus*, a muscle representing the fleshy portion of the same.

The peroneus becomes the *extensor proprius externus*, and is attached distally as in the fore limb. A muscle which has no representative in the horse is one which has been named the *peroneus longus lateralis*. It arises, deeply seated, from the external part of the head of the tibia, and terminates in a long slender tendon which winds obliquely over that of the *proprius externus* at the tarsal joint, and after pursuing a tortuous course round the outside of the joint, is inserted to the small cuneiform and metatarsal bones.

The *flexor perforatus* of the ruminant is thicker in the fleshy portion than that of the horse, and the *flexor perforans* is more clearly divisible into two parts.

#### OMNIVORA.

##### SUBCUTANEOUS REGION.

In the hog the cervical portion of the *panniculus carnosus* is double, one part arising from the cariniform cartilage of the sternum, and the other from the

external scapular region. Anteriorly the parts unite, and the muscle expands over the face, joining its fellow of the opposite side.

#### THE HEAD.

The *levator labii superioris aequae nasi*, *dilatator naris transversus*, and *lachrymalis* are wanting, but the *nasalis longus* is well developed. The *retrahens externus* has two tendons of insertion, one proceeding to the conchal, the other to the scutiform cartilage.

#### THE TRUNK.

The inferior portion of the *levator humeri* is attached by one tendon to the occipital protuberance, and by a second to the mastoid crest, the superior portion going to the wing of the atlas.

The *sterno-thyroideus* is double, having two attachments to the thyroid cartilage. The *longus colli*, instead of being a single muscle as in the horse, is separable into right and left portions. The *scalenus* extends far backwards, usually reaching the third rib.

In the costal region we have merely to note that the trapezius is largely developed; the *latissimus dorsi* is also large, and presents digitations by which it becomes attached to the ribs it covers.

The pectoral muscles resemble those of the ox. In the dorso-lumbar region we find that the *longissimus dorsi* is divisible into a transverse and a costal portion.

The *abdominal tunic* is a mere fold of cellulo-fibrous membrane, while the *obliquus externus* presents a large fleshy, and a small, or rather narrow, aponeurotic portion. In the sublumbar region the muscles of the omnivora, like those of the ruminants, present no features worthy of comparison with those of the horse; the diaphragm also calls for no special comment.

#### PECTORAL LIMB.

The *flexor brachii* at its insertion gives off a tendon which passes to the ulna, and is attached to the lower part of the olecranon, and close by is attached another slip from the *humeralis obliquus*. The *coraco-humeralis* is short, very tendinous, and consists of only one portion, which is inserted just above the insertion of the *teres internus*. The *scapulo-ulnaris* is continuous with the *latissimus dorsi*. The *extensor metacarpi magnus* is inserted to the inner large, the *obliquus* to the inner small metacarpal bone. The *extensor communis* tendon divides into four parts, one being attached to either distal phalanx; and the *extensor proprius internus* tendon bifurcates, and goes to the distal phalanges of the two inner digits, the *proprius externus* joining the two outer ones in a similar manner. The *flexor pedis perforatus* is double, both as to its fleshy portion and its tendon; a part becomes inserted to the median phalanx of each of the large digits, while the tendon of the *flexor perforans* divides into four parts, one being inserted to each distal phalanx.

In the metacarpal region there are four *interossei* or interosseous palmar muscles, which arise superiorly from the back of the metacarpal bones and ligaments, and terminate each in two small sesamoid tendons, which afterwards

wind round to the front of the bone, and join the chief extensor tendon of their own digit. These muscles are the analogue of the suspensory ligament in the horse and ox, as they perform a similar function. A single large *lumbricalis* joins the flexor perforans tendon of the internal digit to the extensor proprius tendon of the same; and on the outside another muscle runs from the carpo-metacarpal ligament to the extensor proprius tendon of the outer small digit, regarded by M. Chauveau as the representative of the flexor brevis minimi digiti of the dog or the human subject.

#### PELVIC LIMB.

In the gluteal and femoral regions the muscles resemble those of the ruminant; the *adductor magnus* and *biceps rotator* have however a very slight attachment to the coccyx. The tendon of the *extensor communis digitorum* divides into four, a slip going to each digit, those of the *extensores proprii* each into two, attached to their two respective digits. The *peroneus longus* is inserted to the head of the internal metatarsal, and the *tibialis anticus* to the cuneiform bones. The *flexor perforatus* tendon bifurcates, and goes to the two great digits, while that of the perforans divides into four, becoming inserted to all the digits. In the metatarsal region we find the *extensor pedis brevis* attached by a divided tendon to the extensor tendons of the great digits, and sometimes to that of the outer one also. There are four interossei which resemble those of the metacarpus.

#### CARNIVORA.

##### SUBCUTANEOUS REGION.

In the dog the fleshy portion of the *panniculus carnosus* is prolonged over the haunch, and united to its fellow in the median line of the dorso-lumbar region. The cervical portion resembles that of the hog, but is more developed, especially the superior part, which springs from the scapular region; it covers the parotid gland, blends with the abducens muscle, and meets its fellow in the median line of the face. The panniculus is very well developed in the felidæ.

#### THE HEAD.

The *zygomaticus* is continuous posteriorly with the *attollens anticus*. The *levator labii superioris* is single, having no nasal branch. The *nasalis longus* joins the *dilatator naris lateralis*, and together they proceed to the external aspect of the nostril and upper lip; the other dilators of the nostril are absent. The *orbicularis oris* and *buccinator* are very rudimentary.

#### THE TRUNK.

The *levator humeri* is similar to that of the hog, and the clavicle, when present, is found related to the infero-internal aspect of its lower portion. The *sterno-maxillaris* is represented by the sterno-mastoideus; the *subscapulo-hyoideus* is wanting, while the *sterno-thyro-hyoideus* arises from the first costal cartilage, and is not digastric. The *scalenus* passes further back than in the hog, sometimes reaching the eighth rib, and the *longus colli* is separable into a right and left portion.

The remarks made regarding the costal, dorso-lumbar, and abdominal muscles of the hog are, for the most part, applicable here. In the pectoral region also there is little to call for remark, unless it be that the *transversus* and *parvus* are very small and thin. The following features presented by the muscles of the sub-lumbar region should be noted. The *quadratus lumborum* attains its maximum of relative size in the dog, and with it is blended the *psaos parvus*; the *psaos magnus*, smaller and shorter than the *parvus*, becomes so blended posteriorly with the *iliacus* that they may almost be regarded as one muscle. Neither of the *psaos* muscles project into the thoracic cavity.

#### PECTORAL LIMB.

The scapular and brachial muscles are large, corresponding to the development of the bones. Placed before the *teres externus* is a distinct *acromio-humeralis* muscle. The *antea* and *postea spinati* have each only one tendon of insertion, that of the former going to the external humeral trochanter. The *coraco-humeralis* and *flexor brachii* resemble those of the hog, the former being short, and inserted just above the insertion of the *teres internus*.

The antibrachial region includes some muscles, the consideration of which is of importance. The tendon of the *extensor metacarpi magnus* divides, and is attached to the heads of the first and second—*i.e.*, the two inner metacarpal bones—while the *extensor obliquus* is inserted to the metacarpal element of the pollex or thumb. The *extensor communis digitorum* has a tendon divided into four parts, a part going to each distal phalanx, while the *extensor proprius tendon* is trifurcated and attached to the three outer distal phalanges. The *flexor perforatus* tendon divides into four, that of the perforans into five parts, the first being attached to the median phalanges of the four principal digits, the other to the distal phalanges of all the digits. The *ulnaris* and *radialis accessorii* are present. The *extensor pollicis et indicis* arises with the *extensor metacarpi obliquus* on the outer aspect of the radius; its tendon accompanies that of the *extensor communis* through its sheath, bifurcates, and is inserted to the pollex and first digit.

The following muscles occur in the antibrachial region, and are the intrinsic rotators. The *supinator longus*, a very delicate band, arises internally along with the *extensor metacarpi magnus*, and is inserted to the inner distal extremity of the radius; in the dog its action as a supinator is almost *nil*. The *supinator brevis* is a short radiating muscle, covering the elbow joint in front; it arises from the outer distal end of the humerus and lateral ligament, and is inserted to the anterior and inner parts of the head of the radius. It supinates the extremity—*i.e.*, it tends to turn the anterior aspect outwards. The *pronator teres* is a short, thick muscle, arising from a small process on the internal epicondyle, and becoming inserted to the inner border of the radial shaft, at about a third from its head; it rotates the extremity, opposing the supinator. The *pronator quadratus* is deeply seated under the flexor group of muscles; it extends almost from the elbow joint to the carpus, and joins the radius to the ulna, its fibres passing directly from one bone to the other; it acts as a pronator.

There are fifteen muscles in the metacarpal region of the dog, all of which

are situated posteriorly, and for the most part covered by the flexor tendons. All the muscles of the human hand are represented, excepting the *interossei metacarpei*, of which there is in the dog only one set, the *palmares*; they are four in number, and disposed in the same way as in the hog. The *lumbricales* are exceedingly slender, and situated between the branches of the perforans tendon, from which they arise; they are continued by delicate tendons, whose attachment is uncertain; they may be traced sometimes to the extensor tendons of the three outer digits; their use is obscure. Connected with the pollex are three comparatively rudimentary muscles—an abductor, an adductor, and a flexor. The *abductor brevis pollicis* is a very small muscle, directed downwards and outwards; arising from the posterior carpal ligament, it is inserted to the metacarpal element of the pollex, which it abducts and also flexes. The *opponens pollicis*, placed below and beneath the last, is large in the human subject, but very rudimentary in the dog. It has attachments similar to those of the last-named muscle, but is inserted more to the inside; it is an adductor, opposition of the thumb being impossible in the dog. The *flexor brevis pollicis* is rather longer than the preceding muscle, but very slender; it arises also from the posterior carpal ligament, and is inserted to the proximal phalanx of the pollex, of which it is the chief flexor. The *adductor indicis* is a long prismatic muscle, situated in the depression between the two interossei; arising from the posterior carpal ligament, it is inserted to the proximal phalanx of the index or first digit, at its supero-internal part.

Like the pollex, the outer digit has three special muscles, an abductor, an adductor, and a flexor. The *abductor minimi digiti* is situated outside and behind the outer metacarpal bone; it arises from the trapezium, and is inserted by a long tendon to the supero-external part of the proximal phalanx of the outer digit. As its name implies, it is an abductor. The *adductor (opponens) minimi digiti*, long and flat, arises close by the adductor indicis, passes downwards and outwards, and its tendon is inserted as that of the abductor muscle, but to the inside of the bone; it adducts the digit. The *flexor minimi digiti* is placed on the inner side of, and below the abductor of the same digit. Triangular and flat in form, it arises from the inferior unci-form ligament, joining the tendon of the abductor. The *palmaris brevis*, or cutaneous palmar, is a thick and rounded semimuscular mass, situated behind and below the carpus, adhering intimately to the skin, and being deeply attached to the fascia of the subjacent muscles.

In the *felidæ* the claw is retracted by a ligament of yellow elastic tissue. "The apparatus for the retraction of the unguis phalanges is so well developed that the claws are completely retracted within sheaths of the integument, when the animal does not desire to use them. To this end the elastic ligaments are very strong, and the median phalanx is excavated in order to allow of the lodgment of the retracted phalanx on one side of it."—(Huxley.)

#### PELVIC LIMB.

The *gluteus externus* is very large, the *maximus* comparatively small; the latter does not extend before the iliac crest, and it is inserted by a single tendon. The two parts of the *triceps abductor femoris* are closely blended, and

the anterior one has no ischial origin. The *sartorius* has an origin from the venter of the ilium, and its fleshy portion reaches the tibia. The *gracilis* is very small and thin.

In the anterior tibial region we find the following muscles:—The *tibialis anticus*, corresponding to the fleshy portion of the flexor metatarsi, partly covers the extensor communis; it arises from the tibial crest and tuberosity, receives a slip from the peroneus, and is inserted by a tendon to the metatarsal element of the hallux. If the hallux is complete, a tendinous slip passes to the distal phalanx. The tendon of this muscle is bound down by a fibrous band, from which a strong slip passes under the tendon, becoming attached to the tibia, and to the metatarsal bone of the middle digit, to some extent corresponding to the fibrous portion of the flexor metatarsi. The *extensor communis digitorum* arises by a strong tendon from between the femoral condyle and the trochlea; its tendon of insertion passes over the tarsus much in the usual manner, divides into four slips, and is inserted as in the anterior limb. The *peroneus longus* is placed between the preceding muscle and the *peroneus brevis*; it arises from the superior part of the tibia, and its tendon, reaching the tarsus, divides, a slip passing inwards to the first metatarsal bone, the rest winding round the cuboid to gain the back of the joint, and become attached to the metatarsal bone of the hallux. This muscle seems to be an abductor of the extremity. The *peroneus brevis* consists of two parts—a superior, arising from the upper third of the fibula, and having a long thin tendon, which passes underneath the *peroneus longus*, descends and joins the extensor tendon of the external digit. The inferior part is penniform, and arises also from the fibula, ending in a strong tendon which is inserted to the external metatarsal bone. The superior portion is the extensor proprius of the outer digit, the inferior an abductor of the extremity.

In the posterior tibial region we find the *plantaris* wanting. The *flexor perforans* is somewhat blended with the *gastrocnemius*, and its tendon is divided into four parts, and inserted as in the anterior extremity. The *perforans* tendon divides into four, and if the hallux is perfect into five slips, proceeding to the distal phalanges. Between the *perforans* and *flexor accessorius* is a separate muscle, the *tibialis posticus*, very thin and slender, arising from the fibula and tibia above, its tendon accompanying that of the *accessorius* into its sheath, and afterwards becoming blended with the posterior tarsal ligament.

We note the following muscles in the metatarsal region. The *extensor pedis brevis* consists usually of three bundles, and it joins the extensor tendons of the three outer digits. The *perforans* has a small *accessory* muscle, which arises on the outside of the tarsus. The *lumbricales* and *interossei* resemble their analogues of the metacarpus. The muscles proper to the hallux are either absent, or too rudimentary to merit notice. An *abductor minimi digiti* is present, and corresponds to that of the metacarpus.

#### RODENTIA.

The most prominent feature in the myology of the rabbit is the enormous development of the dorso-lumbar, sublumbar, gluteal, and femoral muscles.



The *longissimus dorsi* is attached to the mammillary processes of the lumbar vertebræ. The muscles of mastication are also well developed, especially the *masseter*.

The muscles of the limbs bear a general resemblance to those of the dog. In the fore-arm there is no rotation, hence we find the *supinator longus* and *pronator quadratus* wanting; the other rotators being small, and acting as mere flexors of the elbow joint.

#### AVES.

A remarkable feature in the muscular system of birds is the liability of the tendons to ossification, and this condition is by no means peculiar to old animals.

Comparing, in the wide sense, the muscles of a bird with those of a mammal, we are struck with their wonderful morphological similarity, although the peculiarities of the skeleton, and physiological characteristics of the animal lead to various deviations in their form and development.

The muscles of the pectoral limbs, and notably those of the pectoral group, are the muscles of flight. There are two pectoral muscles, which may be called the *magnus* and *parvus*. The *magnus*, an enormous muscle, is the depressor of the wing (*depressor alæ*); it is placed posteriorly, arising from the whole of the sternum, carina, and last ribs, and being inserted to the humerus near its head. The *pectoralis parvus* (*levator alæ*) is small, and situated in the depression between the clavicle and coracoid bone, its tendon of insertion passing inside and over the neck of the scapula, as over a pulley, and becoming inserted to the humerus; this is the levator of the wing.

A peculiar arrangement of the muscles enables the perching birds to "roost." A kind of ligament passes over the front of the knee joint and joins the flexor tendon, so that when the tibia is flexed on the femur, the digits are also flexed. Hence during sleep, when the weight of the animal flexes the knee-joint, simultaneously it causes the digits to clasp the perch.

The diaphragm in birds is said to assist both in the dilatation of the lungs, and of the air sacs. Some authorities, however, dispute its existence, others again describe it as rudimentary.

---

## CHAPTER IV.

### SPLANCHNOLOGY.

THIS section of the subject treats of the viscera, or organs which occupy chiefly the cavities of the body, and compose respectively the digestive, respiratory, urinary, and genital systems, all of which communicate with the outside world by apertures on the surface of the body. We will describe these systems in the order here given, first noting that in all of them there is a certain similarity in structure, in so far that each consists of a tube or canal, lined by mucous membrane, and provided with various glands and other accessory organs.

Before treating of these systems, it will be advisable to allude briefly to certain tissues and structures which are closely associated with them. These are epithelium, mucous and serous membranes, and glands. Involuntary muscular tissue which occurs extensively in these organs has been alluded to already. (See p. 157.)

#### EPITHELIUM.

This is a tissue consisting chiefly of cells, which, in one form or other, covers all the free surfaces of the body—*i. e.*, the skin and mucous membranes; one variety of it also covers the inner surfaces of closed and air-tight membranous sacs, the serous and synovial membranes, in which case it is distinctively known as *endothelium*. The following varieties of epithelium are described:—squamous, columnar, spheroidal, and ciliated.

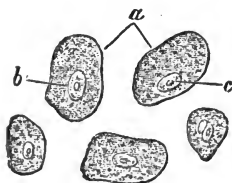


FIG. 88.

Detached epithelium cells from the mucous membrane of the mouth. *a*, Cell wall; *b*, Nucleus; *c*, Nucleolus.

*Squamous*, *tesselated*, *pavemental*, or *scaly* epithelium consists of flattened scaly cells, usually arranged in superimposed layers. In shape irregularly oval, these cells vary somewhat, those on the surface being more

flattened than those of the deeper layers, which are more spherical in form. They contain protoplasm, a nucleus, and a number of granules. The superficial cells are eventually cast off, the deeper ones taking their place, and the latter become more and more flattened as they approach the surface. Consisting thus of layers or strata of cells, the name *stratified* epithelium has been applied to this tissue; it is found in the alimentary mucous membrane, from the mouth to the first half of the stomach, in the bladder, the rectum, the entrances to the nose, the eye, urethra, and vagina, and in a dried and desquamating form it constitutes the epidermis or scarf skin; it is non-vascular, and for the most part non-sensitive.

*Endothelium*.—This resembles epithelium in structure, differing in its situation, as above described, and in the fact that it is arranged as a single layer of flattened cells.

*Columnar* or cylindrical epithelium.—In this variety the cells are cylindrical in form, and arranged side by side, with their long axes perpendicular to the subjacent surface. Their contents resemble those of the squamous kind, but the nucleus is more distinct. This form of epithelium is found on the mucous membrane of the intestines and pyloric half of the stomach, and it is continued into the ducts of the glands which open on the surface of the membrane. The cells covering the villi of the intestine have expanded free extremities, which may appear slightly striped.

*Spheroidal* or *Polyhedral* epithelium is found in the follicles and ducts of glands, hence the name *glandular* epithelium. The cells of this variety are spheroidal, or it may be irregularly polyhedral in shape. A variety known as *transitoria* occurs in the mucous membrane of the urinary bladder, the cells being transitional in form between those of columnar and scaly kinds, and arranged in a small number of layers.

*Ciliated* epithelium consists of columnar cells, provided at their free extremities with delicate hair-like processes or *cilia*, which wave to and fro in a marked manner. The motion is apparently independent of the direct influence of the nervous system, since it is observable for some time after the death of

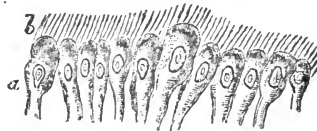


FIG. 89.

Ciliated epithelium, highly magnified.  
a, Nucleated cells; b. Cilia.

the animal. This tissue is found in the mucous membrane of the air-passages, where its cilia tend by their motion to expel particles of foreign matter which are inhaled with the breath; it is found also in the ventricles of the brain, in the canal of the spinal cord, and in the mucous membrane lining the uterus and Fallopian tubes of the female, and part of that lining the vas deferens of the male; and in the convoluted uriniferous tubes.

#### MUCOUS MEMBRANES.

These structures are widely diffused, lining the canals of the four systems now under consideration, and becoming continuous with the skin at each of their orifices. A mucous membrane consists of one or more layers of epithelial cells placed upon a sub-epithelial layer or *corium*, the latter consisting of a modified form of connective tissue, and serving as a matrix in which are situated the nerves and vessels of the membrane, together with numerous glands.

Some authorities have described a membrane separating the cellular from the vascular layer, and it has received the name of the *basement membrane*. By others it is regarded as a mere condensation of the corium. The secretion of the glands proper to the mucous membranes is *mucus*, a viscid fluid which lubricates their free surfaces. The surface of a mucous membrane may be smooth, as in the air-passages, or it may be *papillated*—*i.e.*, furnished with small projections, papillæ, as in the tongue; it may be *rugous*, or thrown into folds or rugæ, as in the œsophagus and stomach; in the small intestine it presents finger-like projections termed villi, and is then said to be *villous*, and in the same situation the membrane presents valve-like folds, and may be termed *valvular*.

The mucous membrane which lines the digestive canal becomes continuous in the pharynx with that lining the respiratory canal, the pharynx being a cavity common to the two systems; hence the entire membrane may be termed the *gastro-pulmonary* mucous membrane, which is also produced so as to line the Eustachian tube and tympanic cavity of the ear, and is, in some animals, continuous by means of the lachrymal duct with the conjunctiva of the eye. At the lips and anus it is directly continuous with the skin. In a similar manner, the mucous membrane of the urinary canal becomes continuous with that of the

genital canal in the vagina in the female, in the urethra in the male; the membrane so formed is termed the *urino-genital* mucous membrane, and it becomes continuous with the skin at the orifices of these organs. Mucous membrane also lines the ducts of the mammary glands; and in fact the ducts of all glands which open on the skin or mucous membranes.

## SEROUS MEMBRANES.

The closed cavities of the body are lined by membranous structures of this class. By a closed cavity we understand a receptacle impervious, under normal circumstances, to the atmospheric air. A serous membrane consists of an endothelial and a subendothelial portion, the cells of the former being arranged in a single layer. Synovial membranes may be regarded as a variety of serous membranes, differing chiefly in the nature of their secretion; they have already been described (see p 125). Since a serous membrane is so arranged as to line a closed cavity, and at the same time to cover its contents, it follows that the entire membrane must form a closed sac, the endothelial layer being on the inside; such a sac is called a *serous sac* or cavity. The fold of the membrane which lines a cavity is called the *parietal*, that which covers its contents the *visceral* portion; the two surfaces contacting, and gliding readily upon each other, are lubricated by a fluid secretion contained in the sac; hence one use of these membranes is to prevent friction between the walls of cavities and the organs contained therein. The following are the serous membranes and their position in the body:—The arachnoid membranes form closed sacs, situated, one between the two coverings of the brain, the other between those of the spinal cord. The peritoneum lines the abdominal cavity and covers its viscera; the pleuræ, right and left, each covers the lung, and lines the half of the thoracic cavity of its own side. The pericardium lines the fibrous sac which contains and supports the heart, and also covers the latter. The cavities of the heart are also lined by a membrane of a serous nature—the endocardium—which is continued through the veins and arteries; as the chief lymphatic vessels communicate with the venous system, the endothelial lining of the former becomes continuous with that of the latter. Lymphatic vessels open into the serous sacs by very small apertures, or *stomata*, so that these sacs are now con-


sidered as being depositories of lymph; and "thus a continuity of surface is established between the serous membranes and the lining membrane of the blood-vascular system through the lymphatics" (*Turner*).

#### GLANDS.

Without attempting an exhaustive definition of the glands, it may suffice to state here that for the most part they are organs in which is carried on the process of *secretion*, or separation from the blood of certain matters, which may be required to assist in the various vital functions, or may be destined to be speedily cast off as effete or poisonous material. Most glands in their typical structure resemble a mucous membrane, consisting of epithelial, subepithelial, vascular, and nervous portions; the first of these portions usually rests upon a condensed layer of the second, which is known as the *membrana propria*, or basement membrane. The vessels supply the gland with blood, from which the secretion peculiar to the gland is separated by the vital power of the cells, which power is stimulated by the nerves, the latter also regulating the blood supply. Lymphatic vessels are present, but their use in these organs is obscure. The subepithelial tissue supports the other component structures of the gland, at the same time determining its anatomical form. The secretions of glands are, as a rule, discharged on the free surfaces of the body—*i.e.*, on the mucous membranes or skin—by means of tubes known as the gland-ducts; hence such glands may be conveniently regarded as depressions in the mucous membrane or in the skin.

When a gland appears as a tube-like depression in the mucous membrane it is termed a *follicle*, *crypt*, or *simple tubular gland*; if the cavity is dilated, it is known as a *sac*, or *saccular follicle*; and if either of these forms be provided with secondary recesses, it is said to be *multilocular*. A tubular gland may be coiled upon itself; or it may branch, in which case it becomes a *compound tubular gland*. A tubular depression ending in a number of vesicular recesses constitutes a *simple racemose gland*; a *compound racemose* or *conglomerate gland* consists of a number of simple ones with a common duct.

The *ductless glands* form a group which differs from any of the above in the absence of a duct, the secretion usually being

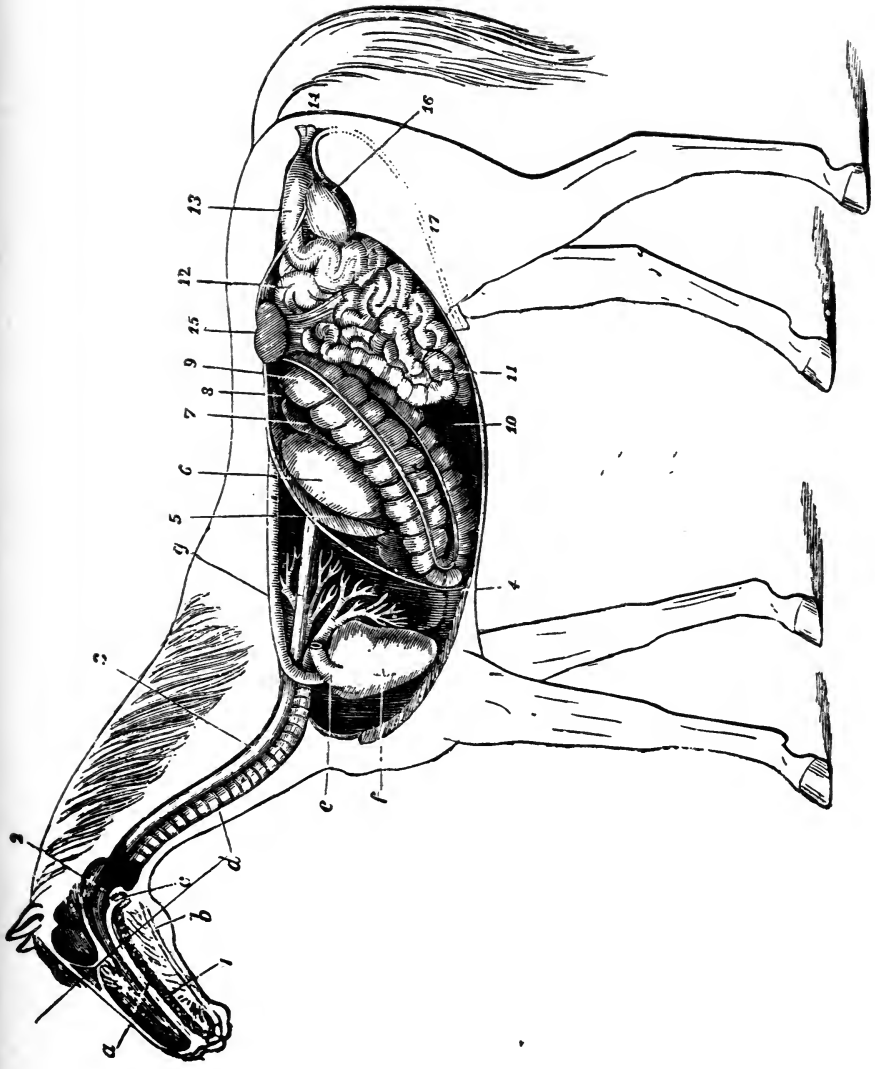


## EXPLANATION OF PLATE IV.

### DIGESTIVE APPARATUS OF THE HORSE.

- |                             |                             |
|-----------------------------|-----------------------------|
| 1. Mouth.                   | 11. Small intestine.        |
| 2. Pharynx.                 | 12. Floating colon.         |
| 3. Œsophagus.               | 13. Rectum.                 |
| 4. Diaphragm.               | 14. Anus.                   |
| 5. Spleen.                  | 15. Left kidney and ureter. |
| 6. Stomach (left sac).      | 16. Bladder.                |
| 7. Duodenum.                | 17. Urethra.                |
| 8. Liver (upper extremity). | A. Hard palate.             |
| 9. Great colon.             | B. Tongue.                  |
| 10. Cæcum.                  | C. Soft palate.             |
- D. Trachea.  
E. Pulmonary artery (divided).  
F. Heart.  
G. Posterior aorta.





DIGESTIVE AND MALE URINARY APPARATUS OF A HORSE—after Mégnin.



carried away by rupture of the glandular sac, or by absorption into the neighbouring lymphatics.

The liver has been termed a *reticular* gland, because its ducts form a network at their origin.

### DIGESTIVE SYSTEM.

The digestive organs comprise the alimentary canal and its accessories, by which the alimentary matter is received and subjected to specific actions, which adapt it for purposes of nutrition. Digestion therefore embraces the collective operations and changes which the food undergoes in the alimentary canal.

The functional processes of digestion are—*Prehension*, the taking up of food, which is performed in the horse by the lips; *Mastication*, chewing, grinding; and, simultaneously with this, *Insalivation*, or mixing the ingesta with the fluid secretion of the salivary glands; *Deglutition*, or swallowing the prepared food by means of the tongue, pharynx, and œsophagus; *Chymification*, or conversion of food in the stomach into a pultaceous chyme, by maceration and the action of the gastric juice; *Chylification*, or conversion of the chyme into chyle, a change which takes place in the duodenum, presumably by the agency of the biliary and pancreatic secretions; *Absorption* of the nutrient material into the circulation; and finally, *Defecation* or excretion, the expulsion of residual inert matter.

### THE ALIMENTARY CANAL.

The alimentary canal is a musculo-membranous tube extending from the lips to the anus; its walls are composed of muscular tissue, for the most part of the non-striated kind, and lined throughout by mucous membrane. It consists of a continuous series of tubes and cavities, the chief of which are the Mouth, Pharynx, Œsophagus, Stomach, and the Intestines. It may be divided into three portions—the preparatory, or ingestive, embracing the mouth, pharynx, and œsophagus, in which the food is prepared; the essential, or digestive, including the stomach and most of the intestines, where the food passes through various changes, and is deprived of its nutritive portions; and the egestive, or expulsive portion, by which the residue is expelled from the system. Each division is provided

with accessories. the preparatory with teeth and salivary glands. and the essential organs with the liver, pancreas. spleen, &c.

We will describe the parts of the alimentary canal in the order above given—the order in which the food traverses them.

#### THE MOUTH.

The mouth is an irregularly oval cavity at the commencement of the alimentary canal, containing the organs of taste and the instruments of mastication ; it is situated between the jaws, its long diameter following that of the head. It is pierced by two openings ; the anterior for the introduction of food, and the posterior, through which the latter passes into the pharynx. It is bounded in front by the lips and their aperture, the *fissura oris*, and laterally by the cheeks ; the roof is formed by the hard palate ; its floor is occupied by the tongue, while the posterior boundary is the *velum pendulum palati*, or soft palate, a membranous partition separating it from the pharynx. The *mucous membrane* is pale, roseate, continuous with the skin at the lips, and covering the whole free surface of the mouth and its contents, excepting the teeth.

#### THE LIPS.

The *labia*, or lips, superior and inferior, are movable fleshy curtains surrounding the anterior opening, and united laterally by a commissure. They consist of skin and mucous membrane, which enclose muscles, vessels, nerves, areolar tissue, fat, and certain *labial glands* situated between the mucous membrane and muscle. The mucous surface of each lip is bridled mesially to the gum by a doubling of the membrane, constituting the *frænum labii superioris* and *inferioris*. The arteries and veins of the lips are the palato-labials and the superior and inferior coronaries. The nerves come from the fifth and seventh cranial pair, the first supplying the *sensory*, or nerves of feeling, which are well developed in the lips of the horse, since these are organs of *touch* as well as of prehension.

#### THE CHEEKS.

The *bucca*, or cheeks, are two musculo-membranous walls, which close the mouth laterally ; they are continuous with the

lips, and consist of an external cuticular, a central muscular, and an internal mucous coat; the latter is termed the *buccal membrane*, and is provided with numerous small *buccal glands*, similar to the labial ones, which open on its surface by straight projecting pointlets; a few larger ones are known as the *molar glands*. On the buccal membrane of each side, near the third upper molar tooth, is a *papilla*, in which is the opening of the duct of the parotid gland. The *gingivæ*, or gums, are reflections of the buccal membrane, and contain dense fibrous tissue, continuous with the periosteum of the alveolar processes, with an epithelial covering; they embrace, without being attached to, the necks of the teeth, and are reflected into the alveoli. The chief arteries and veins of the cheek are the facial and the coronaries. The nerves come from the same source as those of the lips. The cheeks by their muscles serve during mastication to support the food, and press it between the molars.

#### THE HARD PALATE.

The hard palate, or mouth-roof, is bounded anteriorly by the incisor teeth, posteriorly by the soft palate. It is firmly attached to the bony palate, formed by the palatine bones and palatine processes of the superior and premaxillæ. It consists of a dense layer of mucous membrane, with a thick subjacent layer of fibrous tissue. It is equally divided by a longitudinal groove corresponding to the palatine suture, which originates anteriorly at the base of a small tubercle. From this raphe spring transverse ridges, which divide the palate into a number of arches with their concavities backwards; they become smaller posteriorly, and are from seventeen to twenty in number.

The palate is supplied with blood from the palatine arteries, returned in a venous plexus, which forms a kind of erectile tissue in the submucous layer. The sensory nerves come from the superior maxillary division of the fifth pair. The hard palate furnishes a fixed surface, against which the tongue can manipulate the food.

#### THE SOFT PALATE.

The soft palate, or *velum pendulum palati*, is the valvular curtain suspended between the mouth and the pharynx, and it consists of a double fold of mucous membrane, enclosing muscles, glands, vessels, and nerves. It presents two surfaces and four

borders. Its superior border is attached to the palatine arch, and is continuous with the hard palate, whence the velum passes downwards and backwards. The lateral borders are united to the line of demarcation between the cavity of the mouth and that of the pharynx. The inferior border is concave and free, resting upon, and closely embracing the base of the epiglottis. From the extremities of this border, two very thin prolongations run along the lateral walls of the pharynx as far as the beginning of the cesophagus; these are the *posterior pillars* of the fauces. Between the free border of the velum pendulum palati and base of the epiglottis is the posterior opening of the mouth, called the *isthmus faucium*, which in the horse, from the extreme development of the soft palate, is constantly shut, except during the passage of food or water. It is owing to the great size of the velum that a horse is unable to breathe through his mouth. The anterior surface of the velum forms the posterior boundary of the mouth, is marked by longitudinal folds and transverse lines, and studded with the mouthlets of numerous submucous glands. This surface is united laterally to the base of the tongue by large mucous columns, the posterior pillars of the tongue, or *anterior pillars* of the fauces. Behind these are two lateral triangular spaces, the *tonsilar spaces*, which take the place of the tonsils or *amygdalæ*, these being absent in the horse; numerous gland ducts open in these spaces. The posterior surface of the soft palate is convex, and forms the anterior wall of the pharynx; it presents three very small longitudinal ridges.

#### MUSCLES OF THE SOFT PALATE.

A strong layer of aponeurosis or fibrous tissue, the staphyline aponeurosis, forms as it were the foundation of the soft palate, being attached above to the palatine arch. The following muscles control the soft palate :—

Tensor palati.	Pharyngo-staphylinus.
Levator palati.	Palato-staphylinus.
	Palato-glossus.

#### TENSOR PALATI.

(*Peristaphylinus Externus.*)

(FIG. 90. i.)

A long slender muscle with tendinous extremities, running longitudinally between the levator palati and the pterygoidei. It

arises from the petrosal styloid process ; its tendon of insertion, playing over the staphyline groove, expands and becomes lost in the fibrous layer of the velum, of which it is a tensor and depressor.

## LEVATOR PALATI.

(*Peristaphylinus Internus.*)

(FIG. 90. *h.*)

A slender muscle which arises with the last-named one, and lies between it and the Eustachian tube. It passes directly to the soft palate expanding between the Pharyngo-staphylinus and the Palato-staphylinus, and finally joins its fellow of the opposite side. It raises the velum

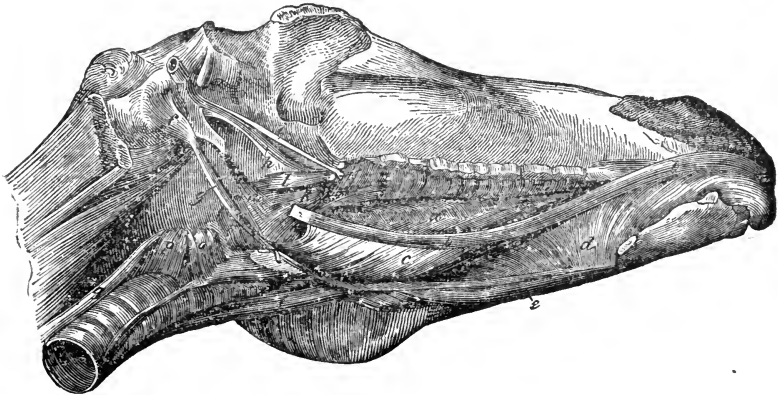


FIG. 90.

Right infero-lateral view of the muscles of the maxillary space ; the ramus and hyoid cornu are cut away. *a*, Lingualis ; *b b'*, Hyo-glossus longus ; *c*, Hyo-glossus brevis ; *d*, Genio-hyo-glossus ; *e*, Genio-hyoideus ; *f*, Stylo-hyoideus ; *g*, Hyoideus magnus ; *h*, Levator palati ; *i*, Tensor palati ; *k*, Pharyngo-staphylinus ; *l*, Pterygo-pharyngeus ; *m*, Kerato-pharyngeus ; *n*, Hyo-pharyngeus ; *o*, Thyro-pharyngeus ; *p*, Crico-pharyngeus ; *q*, Œsophagus.

## PHARYNGO-STAPHYLINUS.

(*Staphylinus Communis.*)

(FIG. 90. *k.*)

This is a broad, thin muscle, occupying the inferior half of the velum, and meeting its fellow in the median line ; they are sometimes described as a single muscle. The fibres run backwards and outwards, and a portion, after following the free border of the velum, is continued under the pharyngeal mucous mem-

brane and attached to the thyroid cartilage; this portion helps to form the posterior pillar of its own side. This muscle is chiefly a tensor of the velum.

#### PALATO-STAPHYLINUS.

(*Azygos Uvulae*—HUMAN.)

This is a small cylindrical muscle contacting its fellow of the opposite side, and arising by a small tendon from the palatine arch and staphyline aponeurosis, to become attached to the free border of the velum at its middle; the pair of muscles thus indicate the right and left halves of the structure. The action of this muscle is to raise and draw forwards the velum, thus helping to dilate the isthmus.

#### PALATO-GLOSSUS.

If this muscle exists in the horse, it will be found under the mucus membrane of the anterior pillar, which it helps to form, thus joining the soft palate and the tongue.

The soft palate is supplied with blood by the staphyline and pharyngeal arteries. Its nerves come from the second division of the fifth pair, and from Meckel's ganglion. It acts as a valve between the mouth and pharynx, opening to allow the passage of alimentary materials during deglutition, but completely preventing the return of such from the pharynx to the mouth; hence in case of vomition in the horse the material is voided through the nasal chambers. Respiration is likewise effected in the solipede only through the nose.

#### THE TONGUE.

The tongue is a movable, musculo-membranous organ, situated on the floor of the mouth, between the rami of the lower jaw; the space it occupies is termed the lingual canal. It is the special organ of taste, and at the same time materially assists in mastication and deglutition. In the ox it is prehensile, and the carnivora lap orprehend water with it. The tongue consists of muscles, glands, vessels, and nerves, having its free surface enveloped by mucous membrane, which varies in thickness,



being smooth and pellucid infero-laterally, where the ranine vein can be traced. Irregularly pyramidal in shape, it has a root or base, a body, and an apex or tip.

The *base*, the widest and thickest part, is muscularly attached to the os hyoides and inferior maxilla; to the epiglottis by a fold of mucous membrane, the *glosso-epiglottic ligament*; and to the velum pendulum palati by the anterior pillars of the fauces. The *apex*, or tip, is free, and broad in the horse, being directed forwards against the inner surfaces of the lower incisors. The under surface of the tongue is attached anteriorly to the lower jaw by the genio-hyo-glossi muscles, and laterally by the reflection of the mucous membrane, over the sublingual glands, to the inner surface of the inferior gums. Antero-mesially, the mucous membrane folds into a *frænum linguae*, or anterior pillar, in front of which is a small papilla, containing the openings of the submaxillary glands; and on either side, between the tongue and maxilla, are the ducts of the sublingual glands.

The *dorsum*, or upper surface, is convex, and marked along its middle by a *raphe*, or groove, which indicates the division of the organ into two lateral halves. The raphe terminates near the base in a cavity known as the *foramen cæcum*, or foramen of Morgagni, in which numerous mucous follicles open.

Posteriorly the tongue is divided by fibrous tissue, which forms a partial longitudinal septem, commencing near the hyoid bone, and losing itself in the muscles. According to Brühl, a piece of fibro-cartilage exists here, peculiar to the solipede, and it has been named the *lingual cartilage*.

## LINGUAL MUSCLES.

The substance of the tongue is composed chiefly of muscular layers running in different directions, between which adipose tissue is interposed. The muscles are divided into extrinsic and intrinsic.

The extrinsic muscles of the tongue are as follows:—

Hyo-glossus longus.  
Hyo-glossus brevis.  
Hyo-glossus parvus.

Genio-hyo-glossus.  
Pharyngo-glossus.  
Palato-glossus.

## HYO-GLOSSUS LONGUS.

*(Stylo-glossus.)*

(FIG. 90, b b.)

Situated along the border of the tongue, this muscle is long and flat.

*Origin.*—From the external surface of the cornu of the os hyoides.

*Insertion.*—To the substance of the tongue expanding towards the tip.

*Relation.*—Externally with the mylo-hyoideus and sublingual gland, sublingual nerve, and canal of Wharton; internally with the genio-hyo-glossus and hyo-glossus brevis.

*Action.*—With its fellow, to retract the tongue within the mouth; singly, to draw it to one side.

## HYO-GLOSSUS BREVIS.

*(Basio-glossus.)*

(FIG. 90. c.)

Situated on the inner surface of the hyo-glossus longus, it is a broad, flat, and somewhat radiating muscle, the fibres passing obliquely forwards and upwards.

*Origin.*—From the side of the body and spur process of the os hyoides and the inferior part of the cornu.

*Insertion.*—The side of the tongue, passing inwards to form the “transverse fibres.”

*Relation.*—Externally with the mylo-hyoideus and hyo-glossus longus, the hypoglossal nerve, Wharton’s canal, and the mucous membrane of the tongue; internally with the hyoideus parvus and the corniculum, genio-hyo-glossus, the lingual artery, and the glosso-pharyngeal nerve.

*Action.*—To draw the base of the tongue downwards and backwards, on one side, or both if acting with its fellow.

## HYO-GLOSSUS PARVUS.

Situated immediately under the mucous membrane, intimately blended with the last named, this is a small radiating muscle.

*Attachments.*—It arises from the inner aspect of the corniculum and hyoid bone, crosses the hyoideus transversus, its fibres then running forwards. It expands over the dorsum and sides of the tongue, its fibres crossing those of the hyo-glossus brevis.

## GENIO-HYO-GLOSSUS

*(Genio-glossus.)*

(FIG. 90. d.)

Situated in the vertical median plane of the tongue, this is a broad, thin, and fan-shaped muscle, its fibres radiating upwards.

*Attachments.*—Its basis may be said to stretch from the hyoid bone to near the maxillary symphysis, the radiating fibres passing upwards and some backwards, some forwards, buried in the substance of the tongue.

*Relation.*—Internally with its fellow; inferiorly with the genio-hyoideus; externally with the hyo-glossus longus and brevis, the sublingual gland, and the lingual artery. The anterior borders of this pair of muscles help to form the frænum linguæ. Posteriorly a certain amount of fat constantly occurs between them.

*Action.*—This varies. It may protrude the tongue by depressing the dorsum, or help to retract it; or it may depress the entire organ, according to the part of the muscle which acts, and to co-operation of the other muscles.

## PHARYNGO-GLOSSUS.

This name has been applied to a few fibres which unite the tongue to the lateral wall of the pharynx, passing between the fibres of the genio-hyo-glossus and hyo-glossus parvus, and blending with them.

## PALATO-GLOSSUS.

(See muscles of the soft palate.)

The intrinsic muscles are collectively described under the name

## LINGUALIS.

(FIG. 90. a.)

This muscle is arranged in two layers of longitudinal, with an intervening set of transverse. fibres. The *lingualis superficialis* lies on the upper surface of the tongue just below the mucous membrane, running longitudinally from the apex nearly to the os hyoides. The *lingualis inferior*, also longitudinal in direc-

tion, is arranged in a rounded band, which extends in the inferior region of the tongue from base to apex, a few fibres reaching the hyoid bone. The *lingualis transversus* lies between the superficial and deep layers, intersecting the extrinsic muscles; its fibres are always intermixed with a quantity of adipose tissue, and form the bulk of the organ. These layers alter the form of the tongue, the superficial tilting the tip upwards; the inferior curves it downwards; while the transverse protracts or elongates it.

The fibres of the intrinsic muscles are regarded by Chauveau and others as prolongations of the extrinsic muscular fibres.

The mucous membrane is plentifully supplied with *glands*, simple and compound. The simple are mere follicles, secreting mucus. The compound glands, and certain closed follicles, are found chiefly at the base of the tongue, about the foramen cæcum, posterior pillars, and papillæ circumvallatæ, into which many of their ducts open.

#### LINGUAL PAPILLÆ.

The mucous membrane covering the under part of the free surface of the tongue is smooth, but as it passes over the borders it assumes a papillary character, and on the dorsum it is covered with papillæ, which roughen and give it a velvety appearance. The papillæ comprise three varieties:—papillæ maximæ, caliciform, or circumvallate; mediæ, or fungiform; and minimæ, or filiform.

The *papillæ circumvallatæ*, three to five in number, are situated at the back part of the dorsum. They are arranged triangularly, the single one being posteriorly and mesially placed, corresponding to the foramen cæcum. These papillæ rest in cup-like depressions of mucous membrane, and are inversely conical, with the apex below; several such papillæ may be enclosed in the same calyx. The *fungiform papillæ* are more numerous, and scattered irregularly over the dorsum, being most numerous on the posterior third; they are attached by a narrow neck, the base being round, free, and often furnished with filiform papillæ. The *filiform papillæ* cover the greater part, but especially the anterior two-thirds of the dorsum, vanishing towards the base. They are simple or compound, the former having one free process, the latter more than one. Papillæ are processes of the corium of the mucous membrane, containing terminal nerve filaments, numerous in the larger, but difficult to trace in the

smaller, papillæ. Like the mucous membrane, they are covered by a thick layer of squamous epithelium, which is sometimes imbricated. It is generally believed that the caliciform papillæ are subservient to the special sense of taste; that the fungiform variety possesses common sensibility; while the filiform papillæ serve a mechanical purpose during the action of the tongue on the food.

The blood-supply of the tongue comes from the lingual and sublingual branches of the glosso-facial artery, and the blood is returned by the lingual or ranine, and sublingual veins.

The principal nerves are—the lingual, or gustatory branch of the fifth; the lingual branch of the glosso-pharyngeal; and the hypoglossal or twelfth pair.

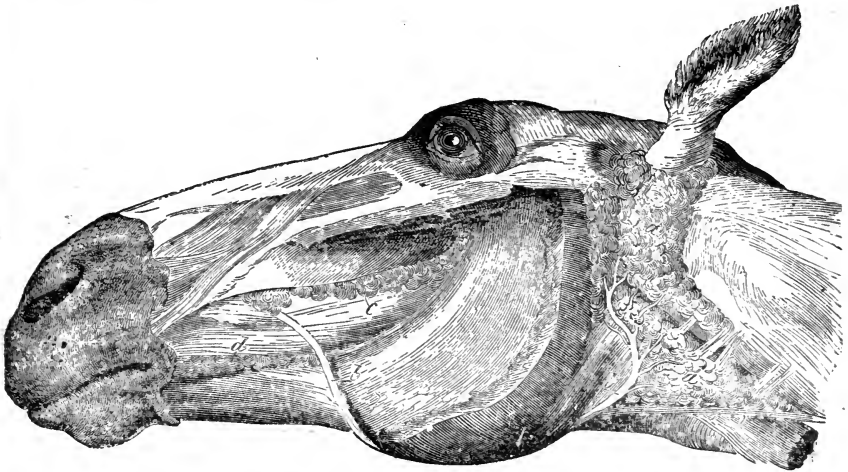


FIG. 91.

Parotid and molar glands of the left side. *a a*, Parotid gland; *b b*, Steno's duct; *c*, Superior, and *d*, Inferior molar glands.

### SALIVARY GLANDS.

The salivary glands are accessories of the mouth. They secrete the saliva, which is discharged into the mouth, and saturates the food, during mastication. There are three primary pairs—viz. the Parotid, the Submaxillary, and the Sublingual.

### PAROTID GLAND.

This, the largest of the salivary glands, is long and flat, and is situated in the space bounded by the posterior border of the

inferior maxilla and the anterior border of the wing of the atlas ; it lies immediately below the ear, which it partly surrounds, and is covered by the *deprimens aurem*. It is related internally with the guttural pouch, and inferiorly it occupies the angular space formed by the jugular and glosso-facial veins. It is greyish, and, like all salivary glands, conglomerate, consisting of a number of lobes held together by dense areolar tissue, these again consisting of lobules, each of which is formed by minute vesicles, originating in the dilatation of the branched origins of the ducts. The latter unite to form larger ones, and terminate in *Steno's duct*, which commences at the antero-inferior surface,

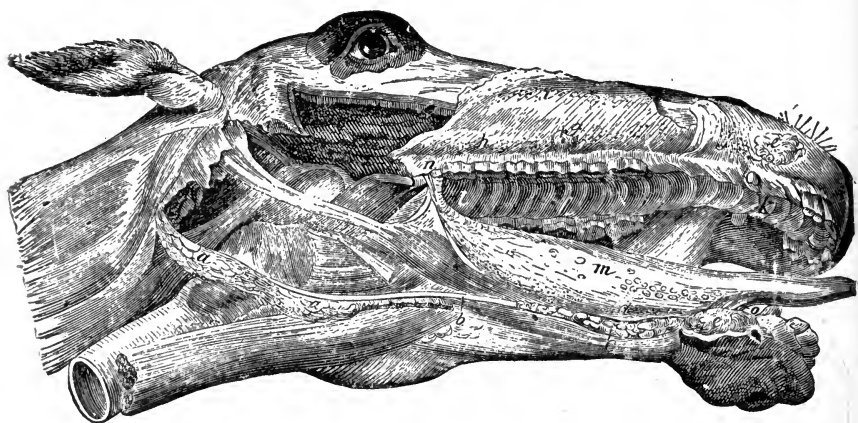


FIG. 92.

Right infero-lateral view of the head ; the maxillary ramus, cheek, parotid gland, and upper lip being removed. *a*, Submaxillary gland ; *b*, Wharton's duct ; *c*, Sublingual gland ; *d*, Its excretory orifices ; *e e*, Labial glands ; *f*, Their excretory orifices ; *g*, Papilla, with orifice of Steno's duct ; *h*, Orifices of the superior, and, *i*, those of the inferior molar glands ; *k*, The hard palate ; *l*, The soft palate ; *m*, The tongue, with its papillæ ; *n*, Pillars of the tongue and soft palate ; *o*, *Frenum-linguæ*.

near the insertion of the sterno-maxillaris, passes along the posterior aspect of the digastricus, round the ramus of the lower jaw, in company with, and posterior to, the glosso-facial artery and vein ; it thus runs along the anterior border of the masseter, and enters the mouth at about the level of the third upper molar tooth, the orifice of the duct being marked by a papilla on the buccal membrane. In some animals there is a small detached gland connected with it, the *glandula socia parotidis*, which opens into the parotid duct as it crosses the masseter. The duct consists of an internal mucous and an external contractile coat.

The parotid gland is supplied with blood by numerous small arteries given off from larger vessels in the immediate neighbourhood. The nerves come from the carotid plexus, also from the fifth and seventh pairs.

#### SUBMAXILLARY GLAND.

This gland, smaller than the parotid, is long, thin, and crescentic, with the concavity directed forwards and upwards. It lies in the maxillary space, below and behind the parotid, and on the outer side of the pharynx, extending from the wing of the atlas to the body of the hyoid bone, where it terminates in *Wharton's duct*, which passes between the mylo-hyoid and hyo-glossus brevis, and is continued along the side of the jaw between the hyo-glossus longus and the sublingual gland, opening into the mouth rather in front of the frænum linguæ, where it is protected by a thick papilla on the mucous membrane, commonly called the *barb*. In structure it is similar to the parotid, but its lobes are larger, its attachments looser, and its duct-coats thinner.

Like the parotid, this gland receives many small arteries; they come mostly from the external carotid and glosso-facial. The nerves are chiefly from the carotid plexus.

#### SUBLINGUAL GLAND.

This gland is smaller than the last-named, long, flat, and delicate. Situated under the tongue, it is placed longitudinally, with its edges vertical, and included between the mylo-hyoideus, hyo-glossus longus, and genio-hyo-glossus muscles; its superior border reaches the mucous membrane of the floor of the mouth; anteriorly it extends to the maxillary symphysis, posteriorly to the hyoidean spur process. In the horse it opens by from fifteen to twenty small ducts, the *ducts of Rivinus*, which are arranged along the floor of the mouth, on what has been termed the sublingual crest, each duct being marked at its opening by a papilla.

Unlike the salivary glands hitherto described, the sublingual gland has a special artery of supply, the sublingual artery; its nerves come from the gustatory nerve and carotid plexus.

#### MINOR SALIVARY GLANDS.

Other presumably salivary glands are the Molar, the Labial, the Lingual, and the Staphyline. The Molar glands, so called

because they are parallel to the rows of molar alveoli, are two in number, superior and inferior; they are situated in the cheek, along the upper and lower borders of the buccinator. They discharge by numerous orifices in the buccal membrane. The Labial glands are placed under the mucous membrane of the lips, especially of the upper one. The Lingual glands are found at the base of the tongue, and partly along its sides. The Staphyline are situated in the soft palate, and between its anterior and posterior pillars, discharging into the mouth or isthmus faucium.

#### SALIVA.

Saliva, the fluid secreted by these glands, is clear, viscid, colourless, and slightly saline in taste, with a specific gravity of 1.005. Alkaline in reaction, it consists of water with about one-half per cent. of solids, including fat, albumen, and a special nitrogenous principle, *ptyalin*, or "animal diastase," which helps to convert starchy material into grape sugar. Saliva also contains alkaline and earthy salts, with a trace of sulphocyanide of potassium. The secretion of the different glands varies; that of the parotid is most watery, while that of the submaxillary and sublingual is viscid. The parotid secretes most abundantly during mastication, and always in direct ratio to the dryness of the food; the others secrete equally, whether the aliment be dry or moist, but appear to be influenced by its *taste*. The sight or thought of food will frequently induce a secretion from the submaxillary and sublingual glands.

The food thus becomes saturated in the mouth with two fluids, mucus and saliva, both assisting in mastication and deglutition, the latter in addition acting upon the starchy constituents of the food.

#### TEETH.

Teeth are objects implanted in and protruding from the maxillary alveoli. They are characterised by the hardness and density of their specific tissues. Like bone, these tissues consist of earthy salts, with a basis of organic animal matter. They are harder than bone, which contains about 67, while teeth contain 76½, per cent. of earthy salts. One material physical difference between a bone and a tooth is that the free portion of the latter bears exposure and friction with impunity, while the former can



endure neither without becoming diseased. Teeth vary with the class of animal in number, size, form, structure, position, and attachment, but in all cases they are in correlation with the food and generic habits of the animal. Thus, in herbivora, where grinding the food is necessary, the contacting surfaces of the molars are rough and flat. In carnivora, where tearing and crushing are requisite, the molars are sharp, pointed, and serrate; in omnivora, where the food is general, the teeth are mixed in their character. The form of the teeth thus depends upon the natural food of the animal, and there is always a certain harmony between their disposition and the conformation of correlated organs. They are not found in all animals. Birds have none, while the typical number of mammalian teeth as viewed by Professor Owen is forty-four.

Three hard structures enter into the formation of the teeth—Dentine, or Ivory; Enamel; and Cementum, or Crusta petrosa.

#### DENTINE.

Dentine constitutes the major part of the tooth, and is a hard, yellowish substance, consisting of very minute tubuli embedded in a dense, granular, intertubular matrix, which contains the bulk of the earthy matter, the latter being about thirty per cent. of the whole. The tubuli commence at the pulp cavity, and radiate to the superficies of the dentine, where they anastomose and their branches terminate in minute cavities, the dentinal cells, which perhaps are analogous to the lacunæ of bone. The tubuli are about  $\frac{1}{4000}$  of an inch in diameter, and, in the fresh state, they contain processes from the pulp.

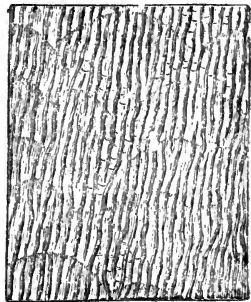


FIG. 93.

Oblique section of dentine, showing the tubuli and coalescence of the calcified nodules.

During the development of a tooth the calcification of the dentine proceeds from centres, around which the calcific material becomes deposited. Thus nodules are formed, which, by expanding, finally coalesce and form the solid matrix.

## ENAMEL.

In appearance enamel is distinguished by its peculiar whiteness. It is the hardest animal texture, containing about 96 per cent. of earthy salts. It consists of hexagonal prisms, which are arranged side by side, with one extremity resting on the surface

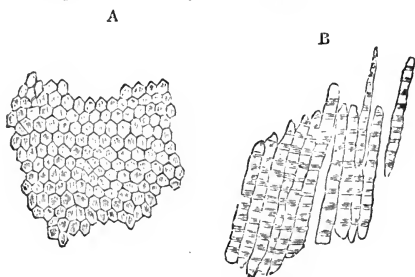


FIG. 94.

A, Transverse section of enamel, showing the cut ends of its hexagonal prisms; B, Prisms separated.

of the dentine, whence they are disposed in gently waving lines towards the surface of the tooth. They vary somewhat in diameter, but average  $\frac{1}{5000}$  of an inch. No nutrient vessels or nerves have been traced into enamel, and when destroyed it is not reproduced.

This tissue is protective, sometimes covering the entire exposed surface of the tooth, as in the human subject and the dog, and it also furnishes the rough projections and cutting edges found in the teeth of some classes of animals, the herbivora affording the best example of this.

## CRUSTA PETROSA.

Crusta Petrosa, or cementum, the third constituent, completely covers the imbedded portion of the tooth, and occupies the cavities on the free portion, where such exist. It is thickest towards the roots, most abundant on the molar teeth, and is distinguished by its brownish-yellow colour. It is the softest dental texture, closely resembling true bone in structure, having tubuli and cells resembling the canaliculi and lacunæ, and where it is thick it may be traversed by vascular tubes analogous to the Haversian canals. The proportion of earthy matter, the same as in bone, is about 67 per cent.

## ARRANGEMENT AND KINDS OF TEETH.

Teeth may be simple or compound. Simple as in the dog, where the entire exposed surface is covered by a solid cap of enamel, which alone is in wear; compound or complex, as in the horse, where various tissues are in wear. A tooth consists of

the following anatomical parts; the body, or *crown*, which is free of the gum, the grinding or cutting surface of which is the *table*; the *cervix*, or neck, the part invested by the gum; and the *fang*, or root, which is inserted into the socket or *alveolus*. The *alveoli* are more porous, spongy, and vascular than other bone; they appear and grow with the teeth, and when these decay, become absorbed. They are lined by periosteum, which, reflected from the gum, at the base of the socket, covers the fang, communicating with the *pulp cavity*, which runs up the fang centre, and contains a highly vascular and nervous organ; the *pulp*, whence the dentine of the tooth grows. This pulp is enclosed in a vascular membrane, the dentine tubuli radiating from it. In the aged tooth this membrane becomes ossified, forming the secondary or *osteo-dentine*. The sensory nerve of the pulp comes from the fifth pair; and it is owing to its extreme sensibility that toothache is so severe when the pulp is exposed.

Teeth are arranged alongside of each other, so as to form the dental arches: these are interrupted at each side, leaving the *interdental spaces*, or *diastemæ*. Teeth are of three kinds; the *Incisors*, or cutting teeth, situated in front of the arches; *Canine* teeth, or tushes, in the interdental spaces; and *Molars*, or grinders, behind. The horse, like many other animals, has two sets; the *temporary* or *milk* teeth, and the *permanent* or *horse* teeth, the former numbering 24, the latter 40. In the mare there are usually 36 permanent teeth, the tushes being wanting or rudimentary.

#### INCISOR TEETH.

The incisor or *front* teeth in the horse are 12 in number, 6 in each jaw; the upper ones are the longer, their surfaces meeting those of the lower ones; in rare cases the former overlap, constituting a "parrot mouth." The *central* pair are the largest, the adjacent ones are called the middle, or *lateral*, while the outer ones, which are the smallest, are termed the *corner* incisors. The row of incisors forms a curve, which is part of the so-called *dental arch*; the younger the tooth the greater the curvature, which gradually decreases with age. The anterior surface of a young incisor tooth presents a triangular shape, with the base at the table. Viewed laterally it is still triangular, but

its apex is at the table. The table is therefore oblong, its long axis following the line of the dental arch. As it wears, it narrows laterally, but its short axis widens, until in old age it is nearly round, what was the fang being in wear.

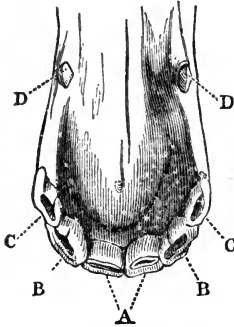


FIG. 95.

Incisor and canine teeth of a Horse. A, Front, B B, Lateral, and C C, Corner incisors; D D, Canine teeth.

The free surface of an incisor tooth, excepting the table, is covered by a layer of enamel; the fang, which is a single process, being covered by crusta petrosa. Towards the centre of the table, in a young tooth, a second ring of enamel is visible, which is the mouth of a funnel-shaped cavity called the *infundibulum*. This cavity in the young animal is ovoid, its long axis following that of the table; it is lined by crusta petrosa, which, becoming stained by the food, constitutes the so-called "mark." The space between the two tubes of enamel is filled up with dentine; hence the table is a compound one—*i.e.*, all three of the dental tissues are in wear on it



FIG. 96.

Incisor tooth of a Horse — posterior view. a, Outer layer of enamel; b, Inner layer of enamel round the infundibulum; c, Dental star; d, The dentine.

The infundibulum, or mark, being conical in shape, wears with the tooth, becomes smaller, and ultimately vanishes. For example, the permanent central incisors are up at three years; in the lower jaw the infundibulum wears away about one-third in each year; the animal will probably, therefore, be six years of age when the mark is gone from the central incisors. Sometimes the cavity is absent, its place being occupied by crusta petrosa; still, in the centre of the tooth there is the inner ring of enamel. Thus, in the transverse section of a young tooth, we notice an outer and an inner ring of enamel, the interspace being filled by a mass of dentine, and the inner ring lined by crusta petrosa (see Fig. 96).

In the centre, the table in front of the infundibulum is broader than that behind it, and as the tooth wears it still broadens. In this space sometimes a spot is apparent which differs from the rest of the dentine; it is the osteo-dentine covering the pulp cavity; this

object has been termed the *dental star*. The corner teeth may have no posterior tables, constituting *shell teeth*; rarely they are absent in every tooth when we have a *shell mouth*. The incisor *milk teeth* are whiter than the permanent ones, and have distinct necks, the necks of the latter being imaginary. They are convex and grooved posteriorly, and have their dentine stained. Almost perpendicular to the axis of the head, in the young animal, the incisors become more and more horizontal as the animal ages. Permanent incisors are convex anteriorly, the lower incisors having one, the superior two grooves down the centre of the body; these are filled with cementum, but are absent in old teeth. The incisor teeth attain their greatest development in the elephant, in which animal they project from the mouth as *tusks*, it may be to an enormous extent.

## CANINE TEETH.

The *tushes*, *tusks*, or canine teeth, well developed in dogs and other carnivora, are simple teeth, four in number, a pair above and below. They rest in the interdental spaces, the lower being nearer the incisors than the upper ones; they are permanent *ab initio*, and appear between the fourth and fifth year, sometimes a year in advance. The crown is somewhat conical, the base being at the gums. The external surface is convex, and marked by several fine longitudinal lines; the internal surface presents on either side a sharp ridge which separates it from the external. The crown terminates in a conical eminence, somewhat hollowed internally during growth, and bounded by a sharp ridge. When a tusk has been long in wear, the ridge disappears, and the internal surface becomes nearly smooth; and as the apex of the tooth becomes worn away, often a small mark appears, but no second ring of enamel. These teeth have no constricted neck, and the fang is single. In the horse tribe, as a rule, canine teeth are developed only in the male; if they exist in the female they are rudimentary.

## MOLAR TEETH.

The *Molars*, or grinders, are 12 in the temporary set, 3 on either side of each jaw; 24 in the permanent set, 6 on each side above and below; they are numbered from before backwards, and, like the incisors, those of the upper jaw are the larger.

A molar tooth is constructed on the same general plan as an

incisor, but the contour of the various parts is much more irregular. There are generally two infundibula containing a large quantity of cementum, a layer of which also covers the greater part of the external enamel.

The crown of the upper molars is somewhat cubic; their external surface presents two grooves running from table to root, the anterior being the deeper. The crown of the lower molars is narrower, but longer than that of the upper ones, and has only one groove. The inner surface of the upper molars is not so deep as the outer, while the inner surface of the lower ones is the deeper; the two lower rows diverge towards the back of the mouth, while the two upper rows are rather convex externally. The molar grinding surface is very irregular, owing to the variable hardness of its components.

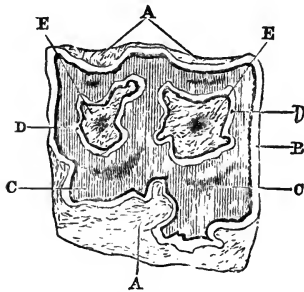


FIG. 97.

Transverse section of a molar tooth. A A, External crista petrosa; B, External enamel; C C, The dentine; D D, Internal enamel surrounding the infundibula; E E, Crusta petrosa occupying the infundibula.

A horse may have supplementary molars, or *wolf* teeth; these are small, and placed one on each side of the jaw, anterior to the first molars; they are usually shed with the milk teeth.

The teeth which replace the deciduous or milk molars are situated anteriorly, and are termed in general zoöotomy *premolars*.

#### DENTAL FORMULÆ.

A dental formula expresses in a concise manner the number and position of the teeth possessed by an animal. The numbers are written somewhat in the form of fractions, and prefixed are the initial letters of the names of the various teeth. Thus, *i.* stands for incisors, *c.* for canines, *p.m.* for premolars, and *m.* for molars. For example, the molar teeth of the dog are thus represented:— $m. \frac{2-2}{3-3}$ ; this means that there are two molars on each side in the upper jaw, and three on each side in the lower jaw. In the ox the incisors are  $i. \frac{0-0}{3-3}$ , or none whatever in the upper, and three on each side in the lower jaw. The full dental formulæ of the horse are as follows:—

*Deciduous or milk teeth.*

$$i. \frac{3-3}{3-3}, c. \frac{0-0}{0-0}, m. \frac{3-3}{3-3} = \frac{12}{12} = 24.$$

*Permanent teeth.*

$$i. \frac{3-3}{3-3}, c. \frac{1-1}{1-1}, p.m. \frac{3-3}{3-3}, m. \frac{3-3}{3-3} = \frac{20}{20} = 40.$$

## DEVELOPMENT OF THE TEETH.

The *development of the teeth*, as demonstrated by the late Professor Goodsir, consists of three distinct stages—papillary, follicular, and saccular. About the sixth week of foetal life a depression is formed in the mucous membrane of the gum, which is the *primitive dental groove*, from the floor of which arise papillæ or processes corresponding numerically to, and constituting the germs of, the milk teeth; this is the *papillary stage*. About the tenth week the groove deepens, the papillæ enlarge, the margins of the grooves thicken and become prominent; prolongations or septa pass from one side of the groove to the other, enclosing each papilla in an open follicle or sac; this constitutes the *follicular stage*; it terminates about the fourteenth week. Somewhat later, the papillæ begin to assume the shape of the crowns of the future teeth. Small membranous processes or opercula are now developed from the sides of the follicle, which correspond in number and shape with the table surfaces of the teeth; thus, for the incisors, there is one on either side, the tushes have three, and the molars four or five, according to their size and situation. The lips of the follicles, as well as the opercula, close and cohere, and the grooves becoming obliterated, what were open follicles are converted into closed sacs, thus completing the *saccular stage*. Shortly before the closing of the follicles of the milk teeth, a lunated depression is noticed behind, and to the inner aspect of each follicle; these become converted into *cavities of reserve*, which ultimately form sacs for the development of the permanent incisors, as well as the three anterior permanent molars. The dental sac, as well as the enclosed papilla, continues to enlarge, the papilla becoming converted into the pulp, and acquiring the semblance of the dental crown. The contents of the sac now consist of the vascular pulp, covered by its membrane—an internal vascular layer, lining the sac, called the *periodontal membrane*; and a fluid lying between the two membranes, the *outer* or

*enamel pulp.* The process of *calcification* now commences. A thin lamina or cap of dentine is first developed on the outer and most prominent part of the pulp, from its covering membrane; this continues to be formed by the substance of the pulp, which gradually decreases as the dentine increases, the enamel being, at the same time, deposited in crystals from its own peculiar or outer pulp. The cementum also forms *pari passu*, from the calcification of the periodontal membrane lining the sac. When calcification of the dental textures is sufficiently advanced, the tooth makes its way through the gum, which is absorbed, as the crowns are forced upwards by the growth of their fangs. The septa or divisions between the dental sacs now ossify, and constitute the alveoli. As growth continues, the base of the pulp contracts and forms the neck. The dental sac now elongates, and gradually becomes less, owing to the formation of dentine on its outer surface, until only a small cavity is left in the centre, in which rests the pulp and its vessels. In the molars, every point on the crown has a separate cap of calcification. These enlarge, and finally meet. In the formation of the molar fangs the pulp divides, ossification in each section proceeding as in a single-fanged tooth.

The permanent teeth are developed like the temporary ones. As the permanent tooth continues to grow, it gradually presses on the milk tooth, and ensures absorption of its roots, until the entire fang becoming removed, the crown of the milk tooth falls out, and the permanent tooth appears above the gum. The remaining permanent teeth, the three posterior molars in each side of either jaw, are developed thus:—Behind the third molars there is a portion of the dental groove unobliterated, which forms a cavity, called the *posterior cavity of reserve*, in which a papilla appears, and undergoes the same change as that of the temporary teeth, forming the rudiment of the fourth molar. From this cavity is developed a second follicle for the fifth, and from this the follicle of the sixth or last molar.

#### PHARYNX.

The pharynx is a musculo-membranous cavity common to the digestive and respiratory canals. Somewhat cylindrical in the horse, it extends obliquely downwards and backwards, and lies behind the velum palati, which separates it from the mouth, and forms its anterior wall. It is attached superiorly to the base of



the cranium by muscles and aponeurosis, infero-laterally to the larynx, and infero-posteriorly it is continuous with the œsophagus. It communicates with other cavities by seven openings—viz., the two *posterior nares* superiorly; posteriorly, on either side, with the slit-like openings of the *Eustachian tubes*, which lead to the guttural pouches, and are guarded by a cartilaginous valve; anteriorly, below the posterior nares, is the *isthmus of the fauces*, leading into the mouth, and, excepting during deglutition, closed by the *velum palati*; inferiorly, behind the root of the tongue, is the *opening of the larynx*, and behind this the *œsophagus*. The walls of the pharynx consist of a muscular layer, with a lining of mucous membrane.

## PHARYNGEAL MUSCLES.

The muscular layer of the pharynx is separable into seven pairs of muscles. These are best seen posteriorly, where they appear as a series of flattened, fleshy bands, the superior of which meet their fellows of the opposite side at a mesian vertical line or raphe. The names of the muscles are as follows, and, excepting the first and last, they are named in order from above downwards :—

Pharyngo-staphylinus.	Hyo-pharyngeus.
Pterygo-pharyngeus.	Thyro-pharyngeus.
Kerato-pharyngeus.	Crico-pharyngeus.
Aryteno-pharyngeus.	

## PHARYNGO-STAPHYLINUS.

(See Muscles of the soft palate.)

## PTERYGO-PHARYNGEUS.

(FIG. 90. L.)

This is a thin, broad band of muscle arising from the pterygoid process. Its fibres are directed backwards and downwards. It terminates by meeting its fellow at the posterior median line of the pharynx, of which cavity it is a constrictor.

## KERATO-PHARYNGEUS.

(FIG. 90. M.)

Arising from the inner aspect of the hyoid cornu, this muscle, a small, narrow band, runs inwards and downwards to the wall of the pharynx, becoming blended with the pterygo-pharyngeus. It is a levator, and by some considered a dilator of the pharynx.

## HYO-PHARYNGEUS.

(FIG. 90. n.)

This is a flat muscle arising from the heel process of the hyoid bone, and slightly from the thyroid cartilage of the larynx. Its fibres passing upwards and backwards, it reaches its fellow of the opposite side at the posterior median line. It is a constrictor.

## THYRO-PHARYNGEUS.

(FIG. 90. o.)

Placed immediately below the muscle last described, this muscle joins its fellow in a similar manner, arising from the thyroid cartilage. It also is a constrictor.

## CRICO-PHARYNGEUS.

(FIG. 90. p.)

Situated below the thyro-pharyngeus, this muscle arises from the lateral aspect of the cricoid cartilage. Its fibres run backwards, converging slightly upwards, and it terminates similarly to the two muscles last described, its action resembling theirs.

## ARYTENO-PHARYNGEUS.

This is a small band stretching from the posterior aspect of the arytenoid cartilage to the muscular wall of the œsophagus, its action being to raise the latter.

The pharynx is supplied with blood by the pharyngeal and thyro-laryngeal arteries. Its nerves are derived from the ninth and tenth pairs, and from the sympathetic. Its respiratory function is purely a passive one, while what may be termed its alimentary function is an active one, to assist in deglutition.

## ŒSOPHAGUS.

The œsophagus, or gullet, is a long musculo-membranous cylindrical canal, passing from the pharynx to the stomach, through which the food reaches the latter. Originating at the lower part of the pharynx, immediately behind the aperture of the larynx, it descends the neck, at first behind the trachea, then inclines to the left of it, the two entering the thorax together; it

then passes to the upper side of the trachea, over the base of the heart, through the posterior mediastinum, and through the diaphragm by the foramen sinistrum; it thus gains the abdominal cavity, and terminates in the cardiac orifice of the stomach. It is narrowest at its origin behind the larynx, then of uniform size until it reaches the diaphragm, where it again constricts.

The œsophagus may be said to consist of a cervical, a thoracic, and an abdominal portion, the latter being very short. It consists of two tunics, an internal mucous and an external muscular, which are very loosely united by areolar tissue. The mucous coat is continuous with that of the pharynx and stomach, but is pale in colour, and clothed with dense stratified epithelium; it presents numerous longitudinal folds, which allow of considerable dilatation, and a number of racemose glands. The muscular coat consists of an external longitudinal, and an internal circular layer of fibres. The cervical and anterior thoracic muscular coat is striated, the remainder non-striated, but both are involuntary. The longitudinal layer commences by three fasciculi, one in front and one on either side, which unite to form a continuous layer. The circular fibres originate at the inferior constrictors of the pharynx. Posteriorly, both sets of fibres pass to the muscular coats of the stomach.

The œsophagus is supplied with blood anteriorly by twigs from the carotid, and the broncho-œsophageal arteries posteriorly; its nerves come from the pneumogastric. The œsophagus has no other use than for the conveyance of aliment from the pharynx to the stomach. Its most noteworthy features in the horse are,—first, the abrupt manner in which it enters the stomach, hardly dilating at all before doing so; secondly, the enormous proportionate size of its mucous membrane posteriorly; this is so large, that near the stomach its folds completely fill the tube when empty, thus acting as a valve, and preventing regurgitation of the food.

The process of deglutition, or swallowing the food, is performed in the following manner:—The masticated food gathers as a bolus at the root of the tongue, which by retracting forces the pellet through the isthmus faucium into the pharynx; the velum pendulum palati recedes backwards and upwards, while the food forces down the epiglottis, effectually closing the larynx; finally, the pharynx, by its constrictor muscles, grasps the bolus, and presses it downwards into the œsophagus. The passage of food

into the pharynx is purely voluntary ; but as soon as it enters the œsophagus, the act of deglutition is entirely involuntary, the food travelling by a vermicular or *peristaltic* motion, caused by the circular muscular fibres of the œsophagus contracting with successive regularity.

#### ABDOMEN.

The ultimate organs of digestion are contained in the abdomen, or belly, which is a large and somewhat ovoid cavity, bounded superiorly by the muscles of the sublumbar region ; inferiorly and laterally by the abdominal muscles ; and anteriorly by the diaphragm ; posteriorly it is continuous with the pelvic cavity. It contains chiefly the *stomach*, *intestines*, and *kidneys*, with their *accessories*. It is lined by the *peritoneum*, a serous membrane, which is reflected over the viscera.

For convenience of description, the abdomen is divided into nine regions, indicated by imaginary lines drawn as follows :— Two transverse lines divide it into three primary regions. The first line is drawn from the cartilage of the last false rib on one side, to that of the other ; the second unites the right and left anterior iliac spines. These divide the cavity into the anterior or epigastric, middle or umbilical, and posterior or hypogastric regions. These regions are each subdivided into three secondary, or right, left, and central regions, by two longitudinal lines, extending from either side of the ensiform cartilage to about the ilio-pectineal eminences, completing the division, which may be tabulated as follows :—

	RIGHT.	CENTRAL.	LEFT.
Anterior.	Right Hypochondriac.	Epigastric.	Left hypochondriac.
Middle.	Right Lumbar.	Umbilical.	Left lumbar.
Posterior.	Right iliac.	Hypogastric.	Left iliac.

The portion of the alimentary canal contained in the abdomen comprises the stomach and intestines.

## STOMACH.

The stomach is a dilatation of the alimentary canal, continuous with the cesophagus and small intestine, where the food is converted into chyme, by maceration and the action of the gastric juice. In the horse it is small in proportion to the size of the animal, and rests in the left hypochondriac region, stretching when full into the epigastric; when distended, it resembles a bent tube with two lateral dilatations, divided by a central constriction into a left, or *cardiac*, and a right, or *pyloric* portion. The former is

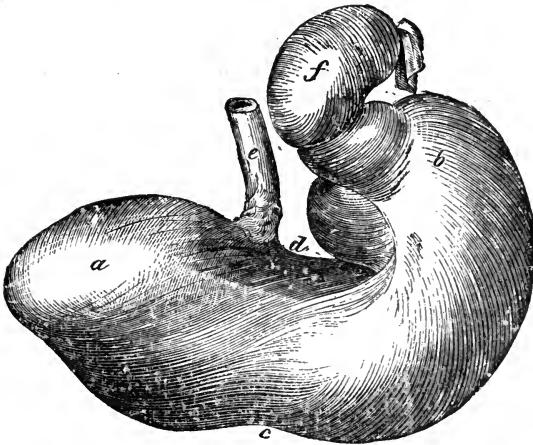


FIG. 98.

Posterior view of the stomach of a Horse. *a*, Left *cul-de-sac*; *b*, Right *cul-de-sac*; *c*, Greater curvature; *d*, Lesser curvature; *e*, *Cesophagus*; *f*, *Duodenum*.

the larger, and called the *greater cul-de-sac*, or *fundus*; the right portion is the *lesser cul-de-sac*, or *antrum pylori*. It has one opening on the left, leading into the cesophagus, through which the food enters; this is the *cardiac orifice*; and another on the right, which communicates with the first portion of the intestine called the duodenum; this is the *pyloric orifice*. At the pyloric orifice there is a constriction called the *pyloric ring*. Between the two openings the upper and lower borders are termed the *curvatures*, the superior or lesser being concave, the inferior or greater convex.

The curvatures indicate the division of the surface of the stomach into two portions, an *anterior* and *posterior*. The

anterior is related with the diaphragm and liver, the posterior with the diaphragmatic flexure of the colon. The spleen lies along the inferior and external part of the greater *cul-de-sac*, its base being directed backwards and somewhat upwards; the pyloric extremity, which is placed lower than the cardiac, is related with the right lobe of the liver and the intestines.

The walls of the stomach are composed of three coats—an external serous, a middle muscular, and an internal mucous coat.

The *serous coat*, a reflection of the peritoneum, is smooth and elastic, adhering intimately to the muscular, except at the lesser curvature, where, strengthened by addition of yellow elastic tissue, it forms a ligament, which appears to support the two extremities of the stomach; forming around the cardiac orifice a circular fold, which surrounds the œsophagus and passes to the diaphragm; this is the *gastro-phrenic*, or *coronary ligament*. The peritoneum also passes in a double fold from the greater curvature to the spleen, as the *gastro-splenic*, to the colon as the *gastro-colic*, or great omentum; and from the lesser curvature to the liver, as the *gastro-hepatic omentum*.

In the *muscular coat* are three sets of fibres—an external longitudinal, a middle circular, and an internal oblique layer. The longitudinal are continuous with those of the œsophagus, and radiate from the cardiac orifice; they are thickest at the curvatures, and are thinly scattered over the surfaces; towards the pyloric end they again converge, and form a uniform layer, which is continuous with that of the duodenum. The middle layer consists of circular fibres, which cover the entire organ; near the pylorus they thicken into a circular ring, which projects into the orifice, and forms with a doubling of the mucous membrane, a sphincter, called the *pyloric valve*, which by contraction prevents crude food from passing into the intestine. The inner layer, is composed of oblique fibres, continuous with the circular œsophageal ones; they are confined to the cardiac portion, descend obliquely over either surface, and disappear towards the central constriction. All these layers are composed of pale or involuntary tissue; the longitudinal layer, by contracting, enables the stomach to dilate; the circular produces vermicular motion, while the oblique layer tends to force the food from the left into the right cavity; thus there is produced a kind of churning motion, which macerates the food and brings each portion of it into contact with the mucous surface.

The internal, or *mucous coat*, is divided into right and left portions. The latter is the *cuticular* portion, continuous with the mucous membrane of the œsophagus, which it resembles in structure and appearance; it is covered by a thick layer of stratified epithelium. The line of demarcation between the two portions is abrupt and dentated. The right portion, the *villous*, or true digestive coat, is reddish in colour, soft, very vascular, and velvety-looking. When examined with a lens, it appears honey-combed, or covered by small shallow polygonal depressions or *alveoli*, separated from each other by projecting intervals.

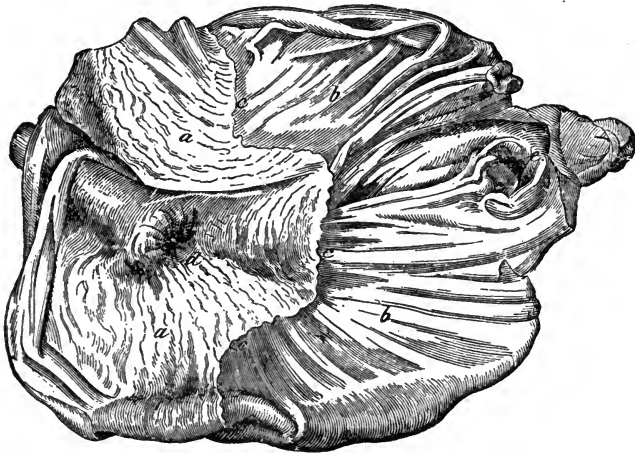


FIG. 99.

Internal aspect of Horse's stomach, opened from below. *a a*, Cuticular mucous membrane; *b b*, Villous mucous membrane; *c c c*, Line of demarcation between the two portions; *d*, Cardiac orifice; *e*, Pyloric orifice and valve.

Into these alveoli the *gastric follicles* open; the latter lie in the subepithelial tissue, perpendicular to the surface of the membrane; at the pyloric end some of these follicles terminate in dilated sacs, or divide into two or more tubes. They consist of a basement membrane, lined by columnar epithelium; some of them secrete gastric juice, others mucus; the latter are lined throughout with epithelium, while the gastric juice follicles have their lower part filled with nucleated cells and granules. The villous coat is also covered with numerous simple or *lenticular follicles*.

The mucous membrane, when the organ is empty, is thrown into folds, or *rugæ*, which are very well seen in the villous por-

tion, where they do not entirely disappear on inflation. The cardiac orifice is closed by the mucous membrane of the cesophagus; its numerous folds completely filling that tube at its termination when empty; the valve thus formed is air-tight.

The arteries of the stomach arise from all the branches of the celiac axis; they are the gastric, the left gastro-epiploic from the splenic, and the right gastro-epiploic from the hepatic; the blood is returned by satellite veins which join the vena porta. The nerves are from the pneumogastric, and solar plexus of the sympathetic.

The use of the stomach is to macerate the food by the action of its muscular walls, and also to saturate it with mucus and gastric juice, the latter containing a principle called *pepsine*, which acts chemically on albuminous matters. The entire operation is called *chymification*, and the food thus prepared the *chyme*.

#### THE INTESTINES.

These are divided into the large and small; the two however form a continuous musculo-membranous tube, the small intestine being likewise continuous with the stomach at its pyloric orifice. These organs are tortuous in their course, and in herbivorous animals are long and capacious.

#### SMALL INTESTINE.

The small intestine commences at the pylorus, and terminates, in the cæcum. It consists of a cylindrical convoluted tube, rather more than an inch in diameter, and about seventy-two feet in length. It presents two curvatures, the greater one, convex and free, the lesser concave and attached to the mesentery, by which it is suspended from the roof of the abdomen, occupying the central region, and partly surrounded by the large intestine. It is arbitrarily divided into the Duodenum, the Jejunum, and the Ileum.

The *duodenum*, continuous with the pylorus, is the only fixed portion of the small intestine. In the horse it is short, presenting a dilatation at its origin resembling a miniature stomach, with its curvatures disposed inversely to those of the stomach itself. On leaving the pylorus it runs forwards, then backwards, forming an abrupt curve. It now crosses from right to left, and



becomes the jejunum at the level of the anterior mesenteric artery. The first portion is more free than the latter. At from four to five inches from the pylorus is the opening by which the ducts of the liver and the pancreas enter the intestine. The *jejunum* succeeds the duodenum, and includes about two-fifths of the remainder of the small intestine, the *ileum* constituting the rest; both are *floating*—*i.e.*, they are attached to the free edge of the mesentery. The ileum terminates, in the right iliac region, in the large intestine.

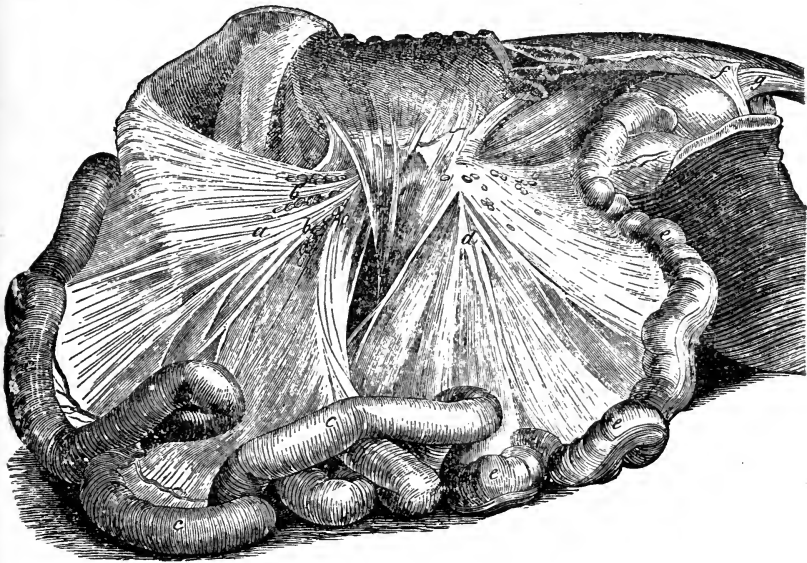


FIG. 100.

The two mesenteries; the great colon being removed. *a*, Anterior mesentery; *b b*, Mesenteric glands; *c c c*, Loops of the small intestine; *d*, Colic mesentery; *e e e*, Loops of the floating colon; *f*, Sphincter ani—internal layer; *g*, Levator ani.

The walls of the small intestine, in common with all hollow viscera of the abdomen, consist of an external serous, a middle muscular, and an internal mucous coat. The two latter are joined by areolar tissue, which is sometimes regarded as a submucous coat. The serous coat envelops the intestine, excepting just at its attached border, where the two folds join and form the mesentery. The muscular coat consists of two layers of fibres, an outer longitudinal, which is very thin, especially at the attached border, and an inner circular one, which is thicker; both are pale, and involuntary.

The mucous coat is soft, spongy, reddish, and vascular, covered

by numerous minute villi and follicular openings, the whole being clothed by columnar epithelium. It is thrown into folds when empty, which usually disappear when it is dilated; these are known as *valvulae conniventes*.

#### INTESTINAL GLANDS.

The mucous membrane of the small intestine is furnished with glands and absorbents. Besides the mucous follicles, we note the following glands:—

Glands of Brunner.		Peyer's patches.
Crypts of Lieberkühn.		Solitary glands.

The glands of *Brunner*, which are small glands, resembling the acini of the salivary glands, are found in the duodenum.

The *crypts*, or *follicles of Lieberkühn*, are very small, and are found throughout the intestines, between the villi and around the larger glands.

The *glands* or *patches of Peyer*, are oval or circular groups of solitary glands, forming *agminated* glands, and are found in the

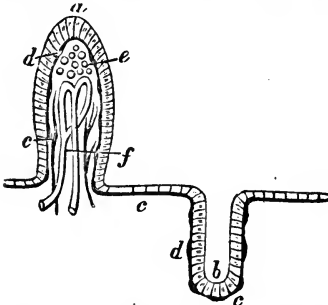


FIG. 101.

Section of mucous membrane of the small intestine. On the left a villus is seen in section. *a*, The epithelial covering; *c*, The blood-vessels; *d*, The basement membrane, or subepithelial layer; *e*, Spaces for reception of the chyle; *f*, Origin of a lacteal vessel. On the right is a follicular depression in the mucous membrane, with *b*, The cells lining it; and *c*, The subepithelial layer.

jejunum and ileum; they are most numerous near the termination of the ileum. Each gland is a simple vesicular ductless sac, containing a lymphoid material. Single sacs, similar to those forming Peyer's patches, called *solitary glands*, are scattered throughout the intestines, and surrounded by Lieberkühn's crypts, which form round each gland a ring known as the *corona tubulorum*.

The absorbents originate in the *villi*, which are small, finger-like, vascular processes, thickly distributed over the mucous surface; they consist of loops of the lacteal or chyle vessels, surrounded by a network of capillaries, fine muscular fibres, and small granular corpuscles, with a mucous layer covered by columnar epithelium. The small intestines are supplied with blood by the anterior mesenteric and duodenal branch of the hepatic arteries, the blood being returned by the satellite veins to

the portal system. The lymphatic vessels of the small intestine are distinctively known as the *lacteal* vessels, and they convey away the chyle absorbed by the medium of the villi. The nerves are from the solar plexus. The vessels and nerves gain or leave the small intestine by passing between the two folds of peritoneum which form the mesentery.

In the duodenum the chyme becomes saturated with the bile and pancreatic juice, the change thus induced being termed *chylification* or conversion of the chyme into *chyle*. In the rest of the intestine we note the absorption of the chyle by the lacteals, the final preparation of the food by the various gland secretions, and the reabsorption of the bile by the blood-vessels. Chyle is a milky-looking fluid, its turbidity being due to the presence of an immense number of minute granules. It contains also the chyle

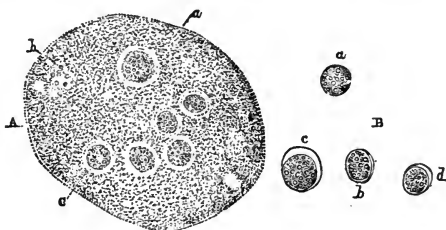


FIG. 102.

A, Microscopic appearance of a drop of chyle from the thoracic duct; c, Granular base; b, Fatty particles; c, Chyle corpuscles; B, Isolated corpuscles showing the cell-membrane in its developing stages, a b c d.

corpuscles, which are nucleated sacs resembling those of the lymph, or the colourless corpuscles of the blood.

#### LARGE INTESTINE.

The large intestine extends from the termination of the ileum to the anus, and may be regarded as consisting of four parts, which will be described in order: the Cæcum, the Great colon, the Floating colon, and the Rectum.

#### CÆCUM.

The cæcum, blind intestine, or *caput cæcum coli*, is a large *cul-de-sac*, commencing in the right iliac region, passing obliquely downwards and forwards, and terminating in the left hypochondriac region by a pointed, blind extremity; thus it crosses

obliquely the middle line of the abdominal floor. It measures about thirty-six inches in length, and its capacity may average six gallons. It is somewhat conical in shape, and curved at its supero-posterior extremity, presenting on its outer surface a number of circular constrictions, and certain longitudinal muscular bands, of which there are four about the middle. The superior extremity is called the base or arch, and presents a convex curvature directed backward, and a concave one forwards. In the concave curvature the ileum terminates, and there also the large colon originates. The middle part of the cæcum is related with the small intestines, the apex being free, and prolonged to the sternum. It is fixed to the abdominal wall posteriorly by cellular tissue, and to the origin of the colon by a double fold of peritoneum, called the meso-cæcum.

The interior of the cæcum presents a number of transverse ridges, corresponding to the external transverse constrictions. Two orifices, placed one above the other, are found in its concave curvature; the inferior one marks the termination of the ileum, and is guarded by the *ileo-cæcal valve*, which is formed by a doubling of the mucous membrane, within which is a band of muscular fibres. The superior opening communicates with the colon. The cæcum has three coats, serous, muscular, and mucous, the latter being thicker than that of the small intestines, and having neither Brunner's glands nor Peyer's patches. The follicles of Lieberkühn, solitary glands, and a few scattered villi are however present.

#### GREAT COLON.

The great or double colon originates from the cæcum, and terminates near its origin in an abrupt contraction, whence arises the floating colon. Taken out of the abdomen, it appears as a voluminous tube, with successive dilated and constricted portions; like the cæcum, it is marked throughout by longitudinal bands and transverse furrows. It measures, on an average, from nine to eleven feet in length, and sometimes has the capacity of eighteen gallons. It is doubled on itself, forming two branches of equal length, placed one on the other, and so disposed that the terminal end is near the origin. When *in situ*, the doubled portion forms a curve whose convexity is directed forwards, and corresponds to the walls of the abdomen, thus forming four divisions, a right and left being above, and a right and left below, with

three *flexures* or bends. In tracing its course, these four divisions present themselves thus. Leaving the arch of the cæcum in the right lumbar region, it passes obliquely forwards to the posterior surface of the diaphragm in the epigastric region, where it turns round to the left, forming the first or *sternal flexure*. Here the second division originates, and in contact with the inferior ab-

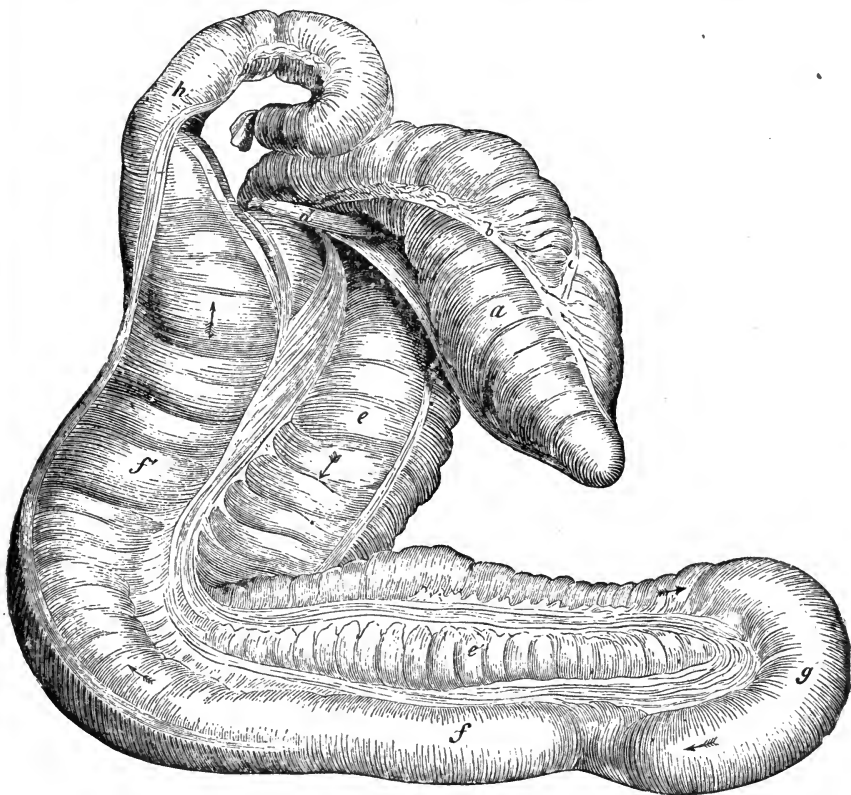


FIG. 103.

Cæcum and Great Colon of a Horse. *a*, Cæcum; *b, c*, Its muscular bands; *d*, Termination of the ileum; *e*, First, *e'*, Second, *f*, Third, and *f'*, Fourth division of colon; *g*, Pelvic flexure; *h*, Origin of Floating Colon. The arrows indicate the course of the food through the colon.

dominal walls, it runs backwards to the hypogastric region, where it is doubled upon itself, forming the second, *sigmoid* or *pelvic flexure*. From this flexure, the third portion passes forwards, above and to the left of the second, to which it is attached by cellular tissue and peritoneum, reaches the diaphragm, and is inflected upwards to the right, forming the third or *diaphragmatic flexure*, which is in relation with and below the liver and

stomach. From this flexure proceeds the fourth and last part of the large colon, which passes backwards, and, at the level of the base of the cæcum, is constricted, and continued as the floating colon.

The attachments of the large colon are, at its origin, to the cæcum by the meso-cæcum, at its terminal portion by cellular tissue to the pancreas and arch of the cæcum, and by the mesocolon, a double fold of peritoneum which unites the two halves for some distance, enveloping the entire organ except at its junction with other viscera, and attaching it to the sublumbar portion of the abdominal wall. The diameter of the canal varies. Very narrow at its origin, it abruptly enlarges, and its size then remains much the same as far as the pelvic flexure, where it contracts; the third division is comparatively small, but at the third flexure it again expands, the fourth division being the largest of all; it is finally constricted, as it forms the origin of the floating colon. Externally, it has numerous transverse furrows and longitudinal muscular bands; the latter vary in number; as far as the pelvic flexure, there are four; along the narrow third portion, only one; at the third flexure, again three, which persist, two being continued along the floating colon. The internal surface resembles that of the cæcum.

#### FLOATING COLON.

The single or floating colon succeeds the great colon, and is convoluted, like the small intestines, but is twice as large, in length averaging about ten feet, and regularly crumpled by transverse folds and longitudinal muscular bands. The latter are two in number, one on the greater or convex, the other on the lesser or concave curvature. It leaves the large colon to the left of the cæcum, in close relation with the termination of the duodenum. It principally occupies the left flank or lumbar region, its convolutions mixing with those of the small intestine, and near the anterior part of the pelvis it terminates in the rectum. Floating like the small intestine, it is suspended by the *colic mesentery*, which is larger than, but resembles in structure that of, the small intestine.

#### RECTUM.

The rectum, or straight intestine, extends in a direct line from the entrance of the pelvic cavity to the anus, and resembles in

structure the floating colon, but its walls are thicker, and more dilatable. It is related superiorly with the sacrum; inferiorly with the bladder, vasa deferentia, vesiculæ seminales, Cowper's glands, and the prostate gland in the horse; in the mare, with the vagina and uterus; laterally it is related with the walls of the pelvic cavity. It is attached to a continuation of the colic mesentery, called the *meso-rectum*; to the pelvis by a reflection of peritoneum; and to the sacrum by the suspensory ligaments of the penis, which, uniting below, at the posterior extremity, surround it; finally, by two triangular fasciculi of pale muscular fibres, which pass up above the anus, and are inserted to the inferior surface of the coccyx, between its depressor muscles. The serous coat is a reflection of the peritoneum; the muscular is very strong, consisting of longitudinal bands, with circular fibres beneath them. The mucous coat is similar to that of the colon; its surface presents a number of transverse ridges, similar to those of the cæcum and large colon. In the spaces between these ridges, the fæces assume their characteristic shape.

## ANUS.

The anus is the posterior opening of the alimentary canal. Lying below the root of the tail, it forms a round projection, which becomes less prominent with age. It consists of thin, hairless skin externally, and of mucous membrane internally, the two being continuous. In the fold between them are the muscles, the terminal muscular fibres of the rectum, and a certain quantity of fat.

The muscles connected with the anus are—

Sphincter Ani.		Levator Ani.
	Retractor Ani.	

## SPHINCTER ANI.

(Fig. 100. f.)

Situated round the termination of the rectum, this muscle is circular, with a central opening, some of the fibres blending with the muscles of the perineal region. It is attached to the fascia covering the perineum, and to the coccygeal vertebræ, and consists of two layers. The inner layer is pale, being part of the muscular coat of the rectum.

*Action.*—To close the anus.

## LEVATOR ANI.

(Fig. 100. g.)

This name has been applied to a kind of small muscular ligament which joins the rectum to the coccyx above.

## RETRACTOR ANI.

Situated on the side of the anus, this is a broad, flat, and powerful muscle, arising from a rough margin just behind the acetabulum, and the inner surface of the sacro-sciatic ligament. It is inserted to the lateral aspect of the anus, its fibres blending with the sphincter.

*Action.*—To retract the anus.

The anterior mesenteric artery supplies the cæcum and great colon, the posterior mesenteric artery supplying the rest of the large intestine, assisted by the internal pudic. The blood is returned by the mesenteric veins to the portal vein. The nerves come from the mesenteric and hypogastric plexuses.

The cæcum seems to be a reservoir for the large quantities of fluid swallowed by the animal. In it and in the great colon absorption of fluid takes place, but the bulk of the ingesta which are passed into the floating colon consists of residual or fæcal matter, having been deprived of its nutritive principles. Hence the floating colon may be regarded as being partly, the rectum entirely, an excretory organ.

## ACCESSORY ORGANS OF DIGESTION.

In the abdominal region these organs are the Liver, the Pancreas, and the Spleen.

## LIVER.

The liver is a solid gland, situated in the abdomen, extending from the right, through the epigastric, to the left hypochondriac region. It is the largest secreting gland in the body, weighing from ten to twelve pounds, and in shape is very irregularly elliptical, thick in the centre, gradually thinning at the borders, and presenting numerous clefts; it has two surfaces and a circumference. The anterior surface is smooth, convex, and cleft by a deep vertical fissure, in which lies the posterior vena cava



the latter before it penetrates the diaphragm, receiving the hepatic veins. The posterior surface is smooth, convex, and marked superiorly with the large transverse fissure by which the vena porta, hepatic artery, and nerves enter, and the hepatic canals leave the liver. Being suspended from the diaphragm in a direction sloping downwards from right to left, the circumference may be divided into a superior right and an inferior left. The superior border presents, from right to left, the attachment of the ligament of the right lobe. The inferior border is cleft by

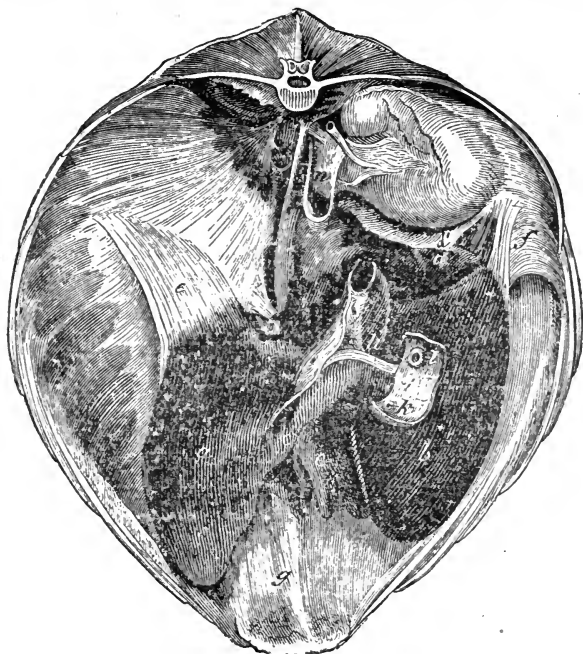

FIG. 104.

Posterior view of the liver and diaphragm *in situ*. *a*, Left lobe; *b*, Right lobe; *c*, Quadrate lobe; *d*, Spigelian lobe; *d'*, Spigelian ligament; just above is the right kidney; *e*, Left lateral ligament; *f*, Right lateral ligament; *g*, Broad ligament; *h*, Hepatic duct; *i*, Piece of the duodenum opened to show, *k*, Opening of the ductus pancreaticus minor, and *l*, Eminence of Vater; *m*, Vena porta; *n*, Posterior vena cava; *o*, Notch for the œsophagus.

two fissures, which divide the organ into three lobes; a right, superior, a middle, and a left inferior. The right lobe, the largest, is flattened, and semi-ovoid, with the point downwards; it has on the upper part of its posterior surface a secondary pyramidal lobe, the *lobulus Spigelii*, to the left of which a slight projection of the right lobe is sometimes called the *lobulus caudatus*. The

middle lobe, the smallest, is placed below the transverse fissure, and consists of several small lobes formed by clefts in its inferior border; sometimes, from its square shape, it is called the *lobulus quadratus*. The middle lobe of the liver is related with the centre and inferior portions of the diaphragm. The left lobe resembles generally the right in form, but is rather smaller, situated lower down, and in the left hypochondriac region.

The ligaments of the liver are six in number, five being partly formed by the peritoneum, while the sixth is the *round ligament*, or fibrous remains of the umbilical vein, a foetal structure, which, ascending from the umbilicus to the anterior fissure, is embedded in the folds of the broad ligament.

The *broad or suspensory ligament* consists of two adherent layers of peritoneum, one border being attached to the anterior surface of the middle lobe, the other to the posterior surface of the diaphragm and abdominal floor; the round ligament is situated between these folds.

The *coronary ligament* consists of fibres covered by peritoneum, and passes from the superior border of the anterior fissure to the pillars of the diaphragm, being attached to the posterior vena cava.

The *right lateral ligament*, in common with the coronary and left lateral, consists of a double layer of peritoneum, strengthened by white fibrous tissue; it stretches from the superior border of the right lobe and lobulus Spigelii to the diaphragm.

The *left lateral ligament* passes from the upper border of the left lobe of the liver to the left side of the foramen sinistrum of the diaphragm, being attached to the fibrous phrenic centre. In addition to the above, there is a small double fold of peritoneum joining the upper border of the lobulus Spigelii to the right kidney; it has been named the *Spigelian ligament*.

#### STRUCTURE OF THE LIVER.

The coverings of the liver are an external serous, and an internal fibrous coat.

The *serous coat* of the liver is a part of the peritoneum, and is reflected from the surface of the gland to assist in forming the ligaments and gastro-hepatic omentum. The inner coat consists of a thin fibrous membrane, adherent to the serous coat and to the glandular substance. It invests the entire organ, and passes

into the several openings in the posterior or transverse fissure; numerous plates from it penetrate the substance of the gland, and separate the ultimate hepatic lobules. This inflected sheath is named *Glisson's capsule*, and processes from it line the portal canals, which pierce the substance of the liver, and envelop the branches of the portal vein, the hepatic artery, and biliary ducts, which run in these canals. It thus forms a web in which these vessels ramify, and surrounds the lobules, binding them together. It is divided into two portions; the *vaginal*, loose and abundant, lining the portal canals; and the *interlobular*, which forms the capsules of the lobules, and supports the ramifications of the smaller vessels.

The *hepatic substance* is variable in colour, depending upon the quantity and quality of the blood and bile in its vessels. Its normal colour is a cool brown; in an animal that has died from hæmorrhage it is a bleached yellowish grey; from general congestion, a purplish-brown or chocolate; from obstruction of the biliary ducts, yellow. It is easily lacerated, the rupture being granulated. It consists of very minute lobules, varying from about  $\frac{1}{17}$  to  $\frac{1}{13}$  of an inch in diameter, separated from each other by the interlobular tissue, continuous with Glisson's capsule. A *lobule* is divided externally into a base, and capsular surface or periphery. The base is polygonal and flat, resting upon a small branch of the hepatic vein—the *sublobular*; joining which, and piercing the centre of the lobule, is the *intra-lobular* vein. The periphery or capsular surface is developed into blunt processes, giving the lobule, which cut longitudinally, a foliated appearance. The surfaces are imperfectly isolated from the surrounding lobules by a thin layer of Glisson's capsule and by the smaller vessels, the intervals being the interlobular spaces. Each lobule consists of numerous cells, biliary ductlets, a plexus of capillary blood-vessels, and probably minute nerves and absorbents. Hepatic cells form the bulk of each lobule, and are irregularly polygonal in shape, averaging about  $\frac{1}{300}$  of an inch in diameter, and containing a nucleus, nucleolus, granular matter, and particles of fat. They are arranged in rows, radiating from the centre of the lobule, and lie in the interspaces of the vascular plexuses.

The liver is supplied with nutritive blood by the hepatic artery, a branch of the celiac axis; with functional blood by the portal vein, both kinds of blood being returned by the hepatic veins.

The *portal vein* enters the liver at the transverse fissure,

accompanied by the hepatic artery and duct, all being invested by Glisson's capsule; it is divided into right and left, and each part subdivides in the portal canals until it reaches the interlobular spaces, where it gives off the *interlobular branches*. These ramify in the interlobular spaces, on the capsules of the lobules, where they give off *lobular branches*, that penetrate the lobules, forming in each an *intralobular plexus*, which terminates in an intralobular branch of the hepatic vein.

The *hepatic artery* enters the liver at the transverse fissure, in company with the portal vein and biliary duct. With them it ramifies in the portal canals, giving off *vaginal branches* to

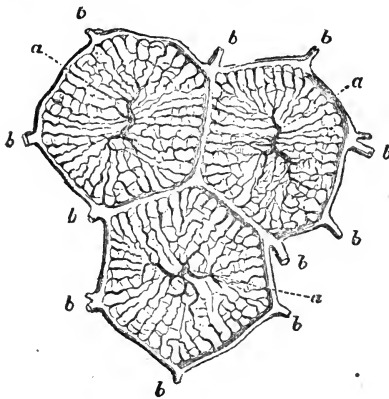


FIG. 105.

Horizontal section of three hepatic lobules. *a a*, Intralobular veins—origins of the hepatic system; *b b*, Interlobular veins—terminations of the portal system. The capillaries joining the two systems are the intralobular plexuses.

Glisson's capsule, and to the coats of the portal vein and biliary duct; *interlobular branches*, which pass to the capsules of the lobules, terminating in the capillary plexus within them; and *capsular branches* which chiefly supply the capsule of the liver. The following names have also been applied to these vessels:—*Rami Vasculares*, supplying the walls of bile ducts and blood vessels, as *Vasa Vasorum*; *Rami Capsulares*, supplying the capsule; and *Rami Lobulares* supplying the substance of the lobule.

The *hepatic vein* commences in the interior of each lobule by twiglets which converge to form the intralobular vein, which leaves the lobule at the middle of its base, and enters the sublobular vein. The sublobular veins unite to form large and still larger veins, the hepatic veins, which finally join the vena cava in the anterior fissure.

The *hepatic or bile duct* is the duct of the gland, conveying away its secretion, the bile.

The *biliary tubes* originate within the lobules in a plexus among the hepatic cells, called the *intralobular biliary plexus*, which on the capsule of the lobule forms the *interlobular branches*, which join each other, gain the portal canals, and ulti-

mately unite to form the hepatic duct, which leaves the liver at the transverse fissure.

It is believed by some of the best authorities that the so-called intralobular *bile tubes* or capillaries are mostly mere spaces between the cells, the tubes being formed only at the periphery of the lobule.

The *hepatic* or *bile duct* (*ductus choledochus*) thus results from the union of the branches of the hepatic tubes in the posterior fissure of the liver. On leaving the liver, it passes between the folds of the gastro-hepatic omentum, and reaches the walls of the duodenum, where it meets with the principal duct from the pancreas; both these ducts, in the horse, enter the duodenum together, some five inches from the pylorus. In some cases the two ducts have been found to unite before reaching the wall of the duodenum, thus forming a short, single canal, termed the *ductus communis*.

The opening is guarded by a prominent circular fold of mucous membrane, the *eminence of Vater*, which serves as a valve, preventing the entrance of food from the duodenum. The *ductus choledochus* and larger bile tubes consist of an external fibrous and slightly muscular coat, and an internal mucous coat, lined with columnar epithelium, and studded with numerous glands.

The nerves come from the solar plexus, with branches from the pneumogastric and diaphragmatic nerves.

The blood of the portal vein, returned chiefly from the abdominal alimentary canal, is charged with bile, which it is the principal function of the liver to remove. This is achieved by the vital power of the hepatic cells, while the blood is passing through the intralobular capillaries. The blood thus deprived of bile, passes into the intralobular veins, and so into the sublobular and hepatic veins, while the bile gains the bile tubes, and ultimately the hepatic duct, to be poured again into the intestine.

Bile is a greenish-yellow, viscid fluid, with an alkaline reaction; it is believed to stimulate peristaltic action, and the secretions of the glands in the mucous membrane.

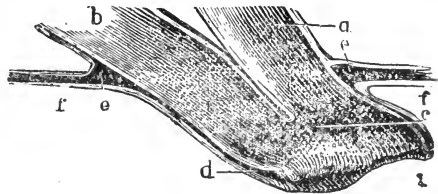


FIG. 106.

Section showing the manner in which the Bile and Pancreatic Ducts enter the Intestine. *a*, Duct of Wirsung; *b*, Bile duct; *c*, Union of the two ducts on the eminence of Vater; *d*, Valve; *e*, Muscular coat of duodenum; *f*, mucous coat of ditto.

In solipedes, also in the elephant and hyrax, the secretion of bile, although more active during digestion, is constant, there being no reservoir for it. Most animals are however provided with a *gall bladder*, lodged in a fissure on the posterior surface of the gland, in which the bile accumulates during the period of abstinence, and from which it passes into the intestinal canal when digestion commences.

#### PANCREAS.

The pancreas is a compound conglomerate gland, and resembles the salivary glands in structure and physical properties, but it is looser and softer, and of a reddish-cream colour. It is situated behind the stomach and liver, and in front of the kidneys, related with the posterior aorta, posterior vena cava, and pillars of the diaphragm, to which it is slightly attached by connective tissue.

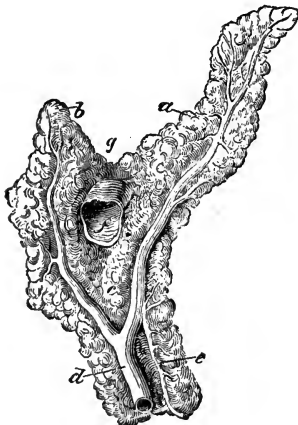


FIG. 107.

Anterior view of the pancreas. *a*, Left branch; *b*, Right branch; *c*, Inferior branch; *d*, Duct of Wirsung; *e*, Ductus pancreaticus minor; *f*, Portal vein cut across; *g*, Notch for the great mesenteric artery.

Its shape in the horse is very irregular and variable, but it is slightly curved upon itself, flattened from above downwards, and presents a right, a left, and an inferior branch. An oblique opening, the ring of the pancreas, passes from the inferior to the superior surface, through which the vena porta runs, in its passage to the liver, and immediately above, on the superior border, is a notch for the great mesenteric artery. The surfaces are flat and lobulated; the superior one is partly covered by peritoneum and attached by cellular tissue to the aorta, celiac axis, posterior cava, and right kidney. The inferior surface is attached to the base of the cæcum and terminal portion of the double colon by cellular tissue. The anterior border contacts the duodenum and left *cul-de-sac* of the stomach. The posterior is convex; about the centre is a groove for the vena porta, before it enters the pancreatic ring.

The duct of this gland, known as the *duct of Wirsung*, lies

near the superior surface of the gland, and is formed by two large radicals, right and left, and in the horse it enters the duodenum with the hepatic duct, in some cases uniting with the latter to form the *ductus communis*. There is sometimes, perhaps always, an accessory canal (*ductus pancreaticus minor*) which enters the intestine separately. The *pancreatic secretion* is clear and colourless; it mixes with the chyme, and assists in chyliification by emulsifying the fatty material, and so rendering the latter fit for absorption. The pancreas is supplied chiefly by the hepatic and anterior mesenteric arteries. Its nerves come from the solar plexus.

## SPLEEN.

The spleen is a soft, reddish-grey organ, situated on the left side of the great curvature of the stomach, in the left hypochon-

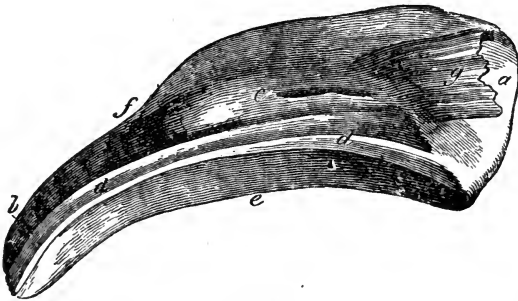


FIG. 108.

Internal aspect of the spleen. *a*, Superior extremity, or base; *b*, Inferior extremity; *c*, Internal surface; *d d*, The hilus; *e*, Anterior border; *f*, Posterior border; *g*, Suspensory ligament.

driac region. It is an exceedingly vascular, ductless gland, having no excretory canal. In the horse it varies in weight,—from about two to four pounds,—and is shaped somewhat like a scythe blade, the apex being directed obliquely downwards and forwards. It has two surfaces, two borders, and two extremities. The superior or external surface is somewhat flat, and is related with the diaphragm; while the inferior or internal is slightly concave, and contacts the large colon. The posterior border is convex, thin, and sharp; the anterior thick, concave, and grooved by the *splenic fissure*, or *hilus*, in which lie nerves and vessels; the gastro-splenic omentum is attached to this border. The base or superior extremity, large, thick, and straight, is related to the

left kidney and left aspect of the pancreas; the *suspensory ligament*, formed of a double fold of peritoneum, with a central layer of yellow elastic tissue, proceeds hence to the anterior border of the left kidney and abdominal wall, becoming blended inferiorly with the great omentum; the apex or inferior extremity is thin, and terminates in a blunt point.

The spleen is soft, elastic, tenacious, distensile, and consists of serous and fibrous coats, and the tissue proper to it, or *parenchyma*. The serous coat envelops all the organ but the hilus, and is a reflection of the peritoneum. Beneath this is the proper capsule,

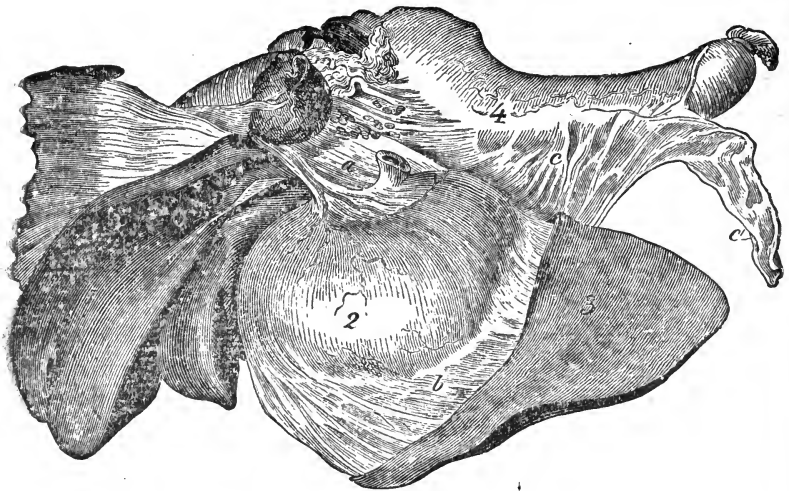


FIG. 109.

Relation of anterior abdominal digestive organs—left antero-lateral view. 1, Liver; 2, Stomach; 3, Spleen; 4, Colon; a, Gastro-hepatic omentum; b, Gastro-splenic omentum; c, Great omentum; c', Its free portion.

a thin, resisting, fibrous coat, formed by connective tissue and elastic fibres. A number of white glistening bands, or *trabeculae*, pass into and traverse the organ, forming a cellular network, in the meshes of which is contained the parenchyma or splenic pulp, a red-looking material, resembling grumous blood, which brightens in colour on exposure to the atmosphere.

The splenic artery, which is a branch of the *cœliac axis*, is very large, and gives off numerous branches, which enter the organ, enclosed in sheaths formed by the fibrous capsule. These ramify and give off branchlets, which run along the *trabeculae*, and terminate in the pulp, in capillary plexuses, supported by minute



trabeculæ of connective tissue. From these spring the capillary veins, which unite and finally form the splenic vein, which is likewise very large, and leaves the organ at the hilus. Some of the small arteries terminate in *lacunæ*, or intercellular spaces of the pulp, whence veins arise. Embedded in the spleen pulp are numerous white bodies, the *splenic vesicles*, or *Malpighian corpuscles*, which are attached to the smaller arteries. They consist of a retiform lymphoid tissue, in the meshes of which are colourless lymph cells and capillary vessels, the tissue itself being continuous with the retiform tissue of the pulp. The nerves come from the solar plexus. The spleen is regarded by some as an internal refuge for blood when cold is applied to the superficies of the body. Its use is very obscure; some maintain that it forms blood-corpuscles; Kölliker, that it is the agent of their destruction. The usual view now taken is that the white blood-corpuscles are formed in it, while the red corpuscles are broken up. It appears not irrational to suppose that, becoming distended with blood during digestion, one of its uses may be to raise the temperature of the food in the stomach to the degree required.

#### THE PERITONEUM.

The abdomen and part of the pelvis are lined by the peritoneum. Like all serous membranes, it is composed of a *parietal* and *visceral* portion, which together form a complete sac, with the organs it covers situated on its outer side. The internal surface is smooth, free, moist, and covered by scaly epithelium; it secretes a serous lubricating fluid. The external or attached surface adheres to the inner parietes of the abdomen and pelvis, excepting the centre of the diaphragm, and also to the outer surfaces of the viscera, the former constituting the parietal, the latter the thinner visceral portion. Besides covering the external surface of the viscera, double folds pass from one organ to another, or from an organ to the parietes of the cavity; these double folds of peritoneum are known either as *ligaments*, *mesenteries*, or *omenta*. In ligaments the two folds are strengthened by an interposed layer of fibro-elastic tissue. A mesentery is a broad, double fold of peritoneum, attached to the abdominal parietes above, and containing a portion of the intestine in its free or remote extremity. Between its folds we find blood-vessels, nerves, and lymphatics or lacteals, hence it permits vascular and nervous communication with the organ attached to it.

The mesenteries are the *mesentery* proper, a huge sheet of

membrane suspending the jejunum and ileum from the abdominal roof, and commencing at the level of the great mesenteric artery; narrow at its origin, it becomes gradually broader posteriorly. The *meso-colon* attaches the great colon to the abdominal parietes, a part uniting the upper and lower portions of it; a portion of this structure, the *meso-cæcum*, covers the cæcum in a like manner, joining part of it to the colon. The *colic mesentery*, similar to the mesentery proper, suspends the floating colon, and a continuation of it which suspends the anterior part of the rectum is termed the *meso-rectum*.

An omentum is a double fold passing from one abdominal organ to another, sometimes establishing vascular and nervous communication between them. There are three omenta, so called, which are continuous with each other. The *great* or *gastro-colic omentum*, stretches from the great curvature of the stomach and duodenum to the colon; the *gastro-hepatic* or small omentum, extends from the lesser curvature of the stomach and œsophagus to the liver; while the *gastro-splenic omentum* passes from the greater curvature of the stomach to the hilus of the spleen. The three omenta together include an anterior sac (*bursa omentalis*), which communicates with the rest of the serous cavity by an aperture called the *hiatus of Winslow*, situated between the anterior end of the right kidney, the pancreas, and the Spigelian lobe of the liver.

In tracing the course of the peritoneum, it may simplify the matter to divide it into two portions, a superior one, leaving the abdominal parietes above, and an inferior one, leaving the parietes below, both passing along the posterior part of the diaphragm, at the centre of which they surround the vena cava, and pass on to the liver, helping to form its ligaments. They then surround that organ, one portion going up, the other down the anterior surface, round to the posterior surface, which they cover, meeting at the posterior fissure to form the gastro-hepatic or lesser omentum, which proceeds from the liver to the lesser curvature of the stomach. The two layers now cover the stomach, form the coronary ligament round the œsophagus, and again meet at the greater curvature, forming on the left the gastro-splenic omentum, and passing to the hilus of the spleen, which is covered by them. On the right the two layers form the gastro-colic or great omentum; these cover the colon and advance upward towards the vertebræ, forming the *meso-colon* and *meso-cæcum*.

The two layers now separate; the superior passes forwards along the roof of the abdomen, and again returns to the posterior part of the diaphragm. The inferior layer descends to and envelops the small intestines, and returns to the abdominal roof, the double layer constituting the mesentery. It now passes backwards to the iliac region, where it again descends to suspend the floating colon and the rectum, forming the colic mesentery and meso-rectum by returning upwards. In the pelvis it forms the recto-vesical ligament, between the bladder and rectum, finally returning along the inferior parietes of the abdomen to the diaphragm. In the female, the peritoneum, after leaving the rectum, passes to the anterior surface of the vagina and uterus, forming the *broad ligaments*.

On the abdominal floor, stretching forwards in the median line from the umbilicus to the quadrate lobe of the liver, is the broad ligament of the latter, and in a similar manner, passing backwards to the fundus of the bladder, we find also a broad ligament. Neither of the latter structures are well marked in the adult, especially the last.

#### RESPIRATORY SYSTEM.

By the action of these organs certain chemical and physical changes take place in the blood, the chief of these consisting in absorption of oxygen from, and giving off carbonic acid to, the atmospheric air, the former change being necessary for the elaboration of the fluid, the latter for the elimination of a substance which, if retained, would prove prejudicial. The organs of respiration are invariably adapted to the wants of the animal and the medium in which it lives. Thus, insects breathe by air-tubes, opening on the surface of the body; in the oyster breathing is performed by fringes; in fishes by gills; in the mammalia by means of elastic air-receptacles, called lungs, which are enclosed in special cavities, and communicate with the atmosphere by means of an air-tube.

In the horse, who breathes only through his nose, the organs of respiration are the Nostrils, Nasal Chambers, Pharynx, Larynx, Trachea, and in the thoracic cavity the Bronchi, Bronchial tubes, and Lungs.

#### THE NOSTRILS.

The nasal openings, or nostrils, are two, right and left, oblong openings, situated in the anterior part of the face at the

extremity of the nasal chambers, and disposed obliquely from above downwards, and without inwards, being slightly curved so as to present their concavities externally. The nostrils consist of an incomplete cartilaginous skeleton covered by muscles, and lined internally by mucous membrane. They are bounded by movable wings, or *alæ*, which are covered within and without by a thin delicate skin, clothed with fine soft hairs. The external wing is concave on its free border, the internal being convex. The commissures of the *alæ* are a superior and an inferior. The finger introduced into the superior commissure does not enter the

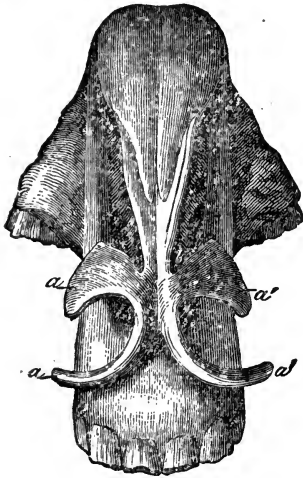


FIG. 110.

Cartilaginous framework of the nostril—seen from above. *a a*, Right alar cartilage; *a' a'*, Left alar cartilage; *b*, Terminal portion of the septum nasi.

nasal cavity, but a conical *cul-de-sac*, the false nostril, a diverticulum of the nose. This cavity is formed by the skin, and lies in the space between the nasal peak and the external process of the premaxillary bone. The false nostrils communicate freely with the nasal chambers; their precise use is unknown, but they probably enlarge the nasal openings during respiratory exertion. The inferior commissure is large and round, presenting, at a short distance within, an opening, sometimes double, which is the inferior orifice of the lachrymal conduit. In the ass and mule this opening is situated on the deep surface of the external *alæ* near to the superior commissure.

Each of the *alar* cartilages resembles an incomplete ring, the incomplete portion being directed outwards. They are loosely attached to the anterior extremity of the septum nasi and to each other, and they serve to keep the nostrils open, permit dilatation, and protect the nasal peak. They are divided into a superior and inferior part. The former is large and flat, and situated within the substance of the internal *alæ*, being covered by the *dilatator naris transversalis*. The inferior part is prolonged by a blunt point to the external *alæ*, to which the *orbicularis oris*, *dilatator naris lateralis*, and *levator labii superioris alæque nasi* are attached. The skin which covers the

nostrils is very thin, containing a quantity of pigment, or colouring material. It is continuous with the mucous membrane of the interior, and adheres to the muscles by dense fibro-cellular tissue.

The blood-vessels are the superior coronary, nasal, and palatolabial arteries and veins. The nerves are derived from the fifth and seventh pairs.

In the horse the power of dilating the nostril attains its maximum. The use of the nostril is to give passage to the air in inspiration and expiration.

#### NASAL CHAMBERS.

These are cavities extending from the cribriform plates of the ethmoid bone to the nostrils, in a direction parallel to the long axis of the face, and are separated from each other by the cartilaginous *septum nasi*, which in age undergoes partial ossification, and is attached postero-inferiorly to the groove of the vomer. Being continuous with the perpendicular plate of the ethmoid, superiorly it rests in a groove formed by the union of the nasal bones, thus preventing any communication between the chambers. Anteriorly, it is expanded and attached to the alar cartilages of the nostrils. The *internal wall* of the chambers is smooth, and formed by the septum nasi; the *external*, which is irregular, is chiefly formed by the superior maxilla. The *roof* is formed by the nasal and part of the frontal bones. The *floor*, broader and shorter than the roof, is completed by the palatine process of the superior maxilla and the palatine bones, and is concave from wall to wall. The *anterior extremity* contains the nasal openings. The *posterior* is occupied above by the cells of the ethmoid; below is the oval opening common to the *posterior nares*, which communicate with the pharynx. Each chamber is divided by the turbinated bones into three passages, or *meati*; the *superior* lies between nasal and frontal bones above, and the superior turbinated bone below; the *middle* between the two turbinated bones, reaching to the cribriform plates of the ethmoid bone; while the *inferior* is between the inferior turbinated bone and the floor of the chamber.

The nasal chambers are lined by a delicate, pale rose-coloured mucous membrane, the *pituitary* or *Schneiderian* membrane, which is continuous with the skin at the nostrils, the mucous

membrane of the pharynx, and with that lining the sinuses of the head, and, in some animals, with the conjunctiva, by the lachrymal duct. It is attached, and sometimes inseparably, to the perichondrium of the septum and the periosteum of the bones. The pituitary membrane is sensitive, varying in vascularity and thickness, being most vascular on the septum and turbinated bones, and thinnest in the sinuses; its free surface is smooth, and covered by epithelium. Near the external opening the epithelium is scaly, the remainder ciliated. It is studded with numerous follicles or crypts, which secrete mucus to keep the surface moist, preserve its sensitiveness, and defend it from noxious vapours. The blood-vessels come from the lateral nasal

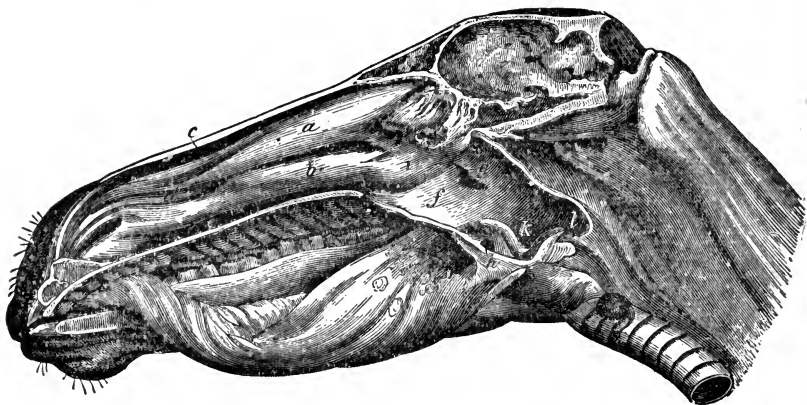


FIG. 111.

Longitudinal section of the head, showing the pharynx and nasal chamber—the septum nasi being removed. *a*, Superior turbinal; *b*, Inferior turbinal; *c*, Superior, *d*, Middle, and *e*, Inferior nasal meatus; *f*, Cavity of the pharynx; *g*, Opening of Eustachian tube; *h*, Isthmus faucium; *i*, Posterior naris; *k*, Opening of the larynx; *l*, Opening of the oesophagus.

and sphenopalatine arteries. The nerves are the first or olfactory pair, or nerves of the special sense of smell, and certain branches of the fifth. The canal of Jacobson in the horse is a blind canal, with its orifice on the floor of the nasal chamber about the incisive opening; it runs backward for about four inches, being related with the septum nasi. Its use is unknown.

Each nasal chamber communicates with four distinct sinuses—Frontal, Maxillary, Ethmoid, and Sphenoid. The maxillary sinus is divided into two; the anterior cavity, often called the inferior maxillary sinus, is generally isolated from the rest. (See p. 44.) The sinuses are lined with mucous membrane, and contain air. The nasal chambers give passage to the respired

air, and are at the same time concerned in the special sense of smell.

The pharynx has been described with the digestive organs. (See p. 296.)

#### LARYNX.

This is a complex musculo-cartilaginous valve, situated at the anterior extremity of the windpipe. It gives passage to air, and at the same time is the organ of voice. The anterior extremity opens into the pharynx; the posterior is continuous with the trachea. It lies at the posterior part of the maxillary space, is directed obliquely from above downwards and backwards, being suspended below the os hyoides, and united by one of its cartilages to the extremity of the heel process on either side. It is attached to the pharynx by muscles, and partly supported by the trachea.

#### LARYNGEAL CARTILAGES.

The cartilages which form the larynx are seven in number, three single ones, and two pairs. The former are the Cricoid, Thyroid, and Epiglottis; the latter, the Arytenoid and Cuneiform cartilages.

The *cricoid*, or ring-like cartilage, is situated at the base of the larynx, surrounding the air passage. It is narrow and convex infero-anteriorly; deep and broad postero-superiorly. It presents two surfaces and two borders. The internal surface is smooth, and covered by mucous membrane; the external one postero-superiorly presents in the median line a longitudinal ridge, to which are attached a few longitudinal fibres of the œsophagus. On either side of the ridge is a broad concavity, in which rests the crico-arytenoideus posticus; while on each side of the concavities is a small protuberance for articulation with the posterior cornu of the thyroid cartilage. The superior border bounding the oval orifice is directed obliquely upwards and backwards, and comprised between the two branches of the thyroid. On either side of this border is a smooth, convex surface for articulating with the arytenoid cartilages. The inferior border is level, and encircles the upper part of the first ring of the trachea, to which it is attached.

The *thyroid*, or shield-like cartilage, is the largest in the

larynx. It consists of two lateral expansions or alæ, which meet and unite antero-superiorly at a rather acute angle, forming a projection called the body of the thyroid, equivalent to the pomum Adami in man. Its inferior surface is smooth, giving attachment to a tendon of the sterno-thyro-hyoideus. On the superior surface is a blunt, irregular protuberance, with which the epiglottis articulates. The alæ are quadrilateral, slightly convex externally, and clothed by the attachments of the hyo-thyroid and thyro-pharyngeal muscles. They are slightly concave internally, and covered postero-superiorly by mucous membrane. From the angle of the wings anteriorly and internally spring the thyro-arytenoideus muscles, the thyro-arytenoidean ligaments or vocal cords, and the thyro-epiglottidean ligament; to the inferior border the crico-thyroid ligament is attached, to the superior the hyo-thyroid ligaments. Posteriorly, each wing terminates in two cornua. The superior inclines upward, and is attached by fibro-cartilage to the extremity of the heel process of the os hyoides; the inferior, the larger and more prominent, articulates with the small protuberance on the posterior surface of the cricoid cartilage.

The *arytenoid*, or ewer-shaped cartilages, a pair, lie upon the cricoid, and bound supero-posteriorly the entrance of the larynx. They are irregularly pyramidal, each presenting two surfaces, four borders, and an apex. The internal surface is smooth, and covered by mucous membrane; the external is divided by a ridge into two portions; a superior which is covered by the arytenoid muscle, and an inferior which receives the attachment of the crico-arytenoideus lateralis and thyro-arytenoideus. The inner border unites with its fellow; the posterior one, forming the base, is turned backwards, and receives the attachment of the crico-arytenoideus posticus the outer angles articulating with convexities on the side of the superior border of the cricoid cartilage. The anterior border is thick, and covered by mucous membrane, while the inferior border receives the insertion of the vocal cords. The apex formed in front by the junction of the two arytenoids is prolonged by two pieces of fibro-cartilage, the *cornicula laryngis*, which pass outwards and backwards, forming a spout or lip, in which rests the epiglottis, when the larynx is closed.

The *epiglottis* is a soft, leaf-like cartilage, flexible, and situated in front of the opening of the larynx, which it completely closes during the passage of food through the pharynx into the œso-



phagus. Its anterior surface, somewhat convex, is attached to the tongue, by the glosso-epiglottidean ligaments, and to the hyoid bone by the hyo-epiglottidean muscle. The posterior surface is rough, and studded with numerous mucous glands. The base articulates with the posterior part of the body of the thyroid. The apex is free, and somewhat curved forwards. From the base of the epiglottis, two lateral processes extend backwards: these are the *cuneiform* cartilages, and they are situated in the folds of mucous membrane which stretch from the epiglottis to the arytenoid cartilages, being attached to the latter by elastic ligaments, together forming the *false vocal cords*.

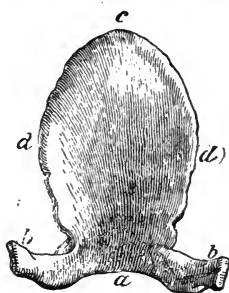


FIG. 112.

Posterior view of the epiglottis.  
 a, Base; b b, Cuneiform cartilages;  
 c, Summit; d d, Lateral borders.

## LARYNGEAL LIGAMENTS.

The ligaments connected with the larynx are *extrinsic* and *intrinsic*. The extrinsic ones are as follows:—

Lateral Hyo-thyroid.		Hyo-epiglottidean.
Middle Hyo-thyroid.		Crico-trachealis.

The *lateral-hyo-thyroid* pass from the superior border of the thyroid cartilage to the heel process of the os hyoides. The *middle hyo-thyroid ligament* is a broad membrane, filling up the space between the anterior border of the thyroid cartilage and the heels and body of the os hyoides. The *hyo-epiglottidean* ligament is a band of yellow elastic tissue, running between the base of the epiglottis and body of the os hyoides, covered by the hyo-epiglottidean muscle. The *crico-trachealis* joins the cricoid cartilage to the trachea.

The intrinsic ligaments are:—

Thyro-epiglottidean.		Crico-arytenoidean.
Arytenoidean.		Crico-thyroidean.
Thyro-arytenoidean.		

The *thyro-epiglottidean* ligament binds the base of the epiglottis to the superior border of the thyroid cartilage. The *arytenoidean* ligament joins the two arytenoid cartilages together.

The crico-arytenoidean ligaments connect the outer angles of the arytenoid with the superior border of the cricoid cartilages. The *crico-thyroidean* ligaments, three in number, connect the cricoid and thyroid cartilages; they consist of an anterior or broad one, and two lateral ones attached to the posterior extremities of the thyroid wings. The *thyro-arytenoidean* ligaments are likewise known as the *true vocal cords*, and they stretch from the inner

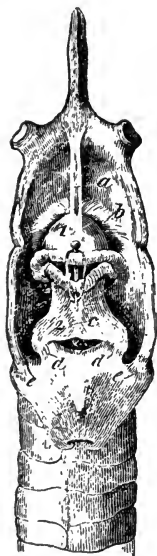

FIG. 113.

Larynx, hyoid bone, and commencement of trachea—posterior view. 1, Epiglottis; 2, Left arytenoid; 3, Posterior ridge of cricoid cartilage. Ligaments—*a*, Hyo-epiglottidean; *b*, Thyro-epiglottidean; *c*, Arytenoidean; *d d*, Crico-arytenoidean; *e e*, Lateral crico-thyroidean—the epiglottis is fastened down.

aspect of the angle of the thyroid cartilage to the base of the arytenoid cartilages. The superior aperture of the larynx, which, when open communicates with the pharynx, is somewhat oval, and bounded anteriorly by the epiglottis, posteriorly by the arytenoids and cornicula laryngis, laterally by the false vocal cords. Inside it becomes constricted, leaving a narrow triangular fissure running antero-posteriorly, and bounded laterally by folds of mucous membrane, in which lie the thyro-arytenoid ligaments or true vocal cords. The narrow opening of the larynx between the right and left vocal cords is called the *rima glottidis*, or *glottis*, and is wider posteriorly from the divergence of the cords.

Between the true and false vocal cords, on either side, is a deep ovoid fossa, the lateral *sinus* or *ventricle* of the larynx; at the base of the epiglottis is a third, small, blind depression, the *middle ventricle*. The inferior opening of the larynx which communicates with the trachea is nearly circular.

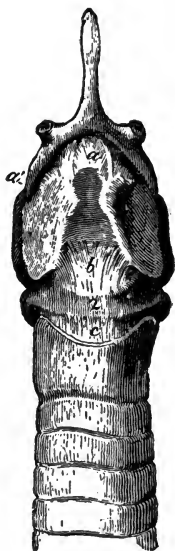


FIG. 114.

Larynx, hyoid bone, and commencement of trachea—anterior view. 1, Thyroid, 2, Cricoid cartilages. Ligaments—*a*, Hyo-thyroid; *a'*, Lateral portion of the same; *b*, Crico-thyroidean; *c*, Crico-trachealis.

## LARYNGEAL MUSCLES.

The muscles of the larynx are *extrinsic*, or those arising from neighbouring parts, and *intrinsic*, or those acting between the different cartilages. The extrinsic muscles are three in number:—

Sterno-thyro-hyoideus.		Hyo-thyroideus.
		Hyo-epiglottideus.

## STERNO-THYRO-HYOIDEUS.

(See page 179.)

## HYO-THYROIDEUS.

(FIG. 115. *b*.)

This is a triangular muscle, its fibres running backwards and downwards.

*Origin.*—The inferior border of the heel process of the os hyoides.

*Insertion.*—To a line on the external side of the wing of the thyroid cartilage.

*Action.*—To depress the os hyoides, or elevate the larynx.

## HYO-EPIGLOTTIDEUS.

(FIG. 115. *a*.)

Single and fusiform, this muscle is usually enveloped in adipose tissue.

*Origin.*—The middle of the body of the os hyoides.

*Insertion.*—The inferior part of the anterior surface of the epiglottis, covered by the mucous membrane.

*Action.*—To draw the epiglottis forward, and thus open the larynx.

The intrinsic muscles consist of four pairs and one single muscle, as follows:—

Crico-thyroideus.		Crico-arytenoideus lateralis
Crico-arytenoideus posticus.		Thyro-arytenoideus.
		Arytenoideus.

## CRICO-THYROIDEUS.

(Fig. 115. c.)

This is a small muscle whose fibres run upwards and backwards.

*Origin.*—The external surface of the cricoid cartilage.

*Insertion.*—To the posterior border of the thyroid cartilage.

*Action.*—To shorten the larynx by drawing the two cartilages together.

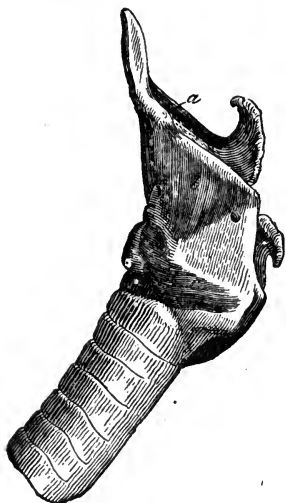

FIG. 115.

Muscles of the larynx—left lateral view. *a*, Hyo-epiglottideus; *b*, Hyo-thyroideus; *c*, Crico-thyroideus.

muscle.

*Action.*—To dilate the entrance of the larynx, and also the glottis by separating the vocal cords.

## CRICO-ARYTENOIDEUS POSTICUS.

(Fig. 116. b.)

The most powerful of the intrinsic muscles, this is situated on the infero-posterior aspect.

*Origin.*—The cavity on the posterior surface of the cricoid cartilage, whence its fibres converge upwards and outwards.

*Insertion.*—To the posterior tubercle of the arytenoid cartilage, covered by the oesophagus and crico-pharyngeus

## CRICO-ARYTENOIDEUS LATERALIS.

(Fig. 116. c.)

This muscle is triangular in shape, and lies between the wing of the thyroid and the arytenoid cartilage.

*Origin.*—The side of the anterior border of the cricoid cartilage, passing upwards.

*Insertion.*—To the outer tubercle at the base of the arytenoid cartilage outside the posticus.

*Action.*—To contract the opening of the larynx, and thus antagonise the posticus.

## THYRO-ARYTENOIDEUS.

(FIG. 116. d.)

Situated on the inner side of the wing of the thyroid cartilage, it consists of two bundles, separated by the ventricle of the glottis.

*Origin.*—From the inner surface of the angle of the thyroid cartilage, outside of the vocal cord.

*Insertion.*—To the middle line at the junction of the arytenoid cartilages.

*Action.*—To constrict the glottis. By its relation with the vocal cord this muscle powerfully influences the tension of the same, and consequently the voice.

## ARYTENOIDEUS.

(FIG. 116. a.)

This muscle, the smallest of the group, is single; and situated upon the arytenoid cartilages, stretching from one cartilage to the other, the fibres intercrossing in the median line.

*Action.*—To approximate the cartilages, and thus constrict the glottis.

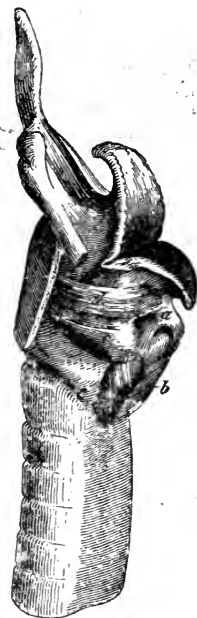


FIG. 116.

Muscles of the larynx—left lateral view—the thyroid wing being removed. *a*, Arytenoideus; *b*, Crico-arytenoideus posticus; *c*, Crico-arytenoideus lateralis; *d*, Thyro-arytenoideus.

The mucous membrane is continuous with that of the tongue and pharynx, forming, from the tongue to the epiglottis, the glosso-epiglottidean folds. It is reflected over the posterior face of the epiglottis to the anterior part of the arytenoids, covering the lateral boundary of the laryngeal opening. In these folds lie the cuneiform cartilages. It thus passes over the false vocal cords, lining the ventricles, and returning over the true vocal cords; it clothes the inner surface of the cricoid cartilage and middle of the crico-thyroid ligament, and so is prolonged into the trachea. It is very thin, and exquisitely sensitive, especially about the glottis; it is covered with ciliated epithelium, and studded with mucous glands, which moisten it and preserve its sensitiveness. The glands are

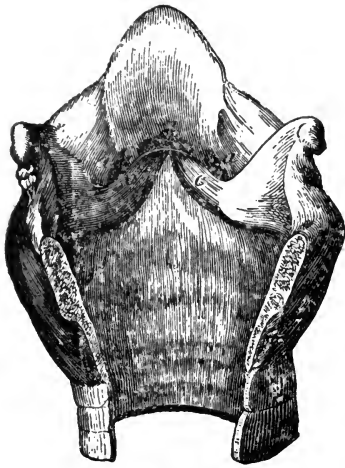


FIG. 117.

Cavity of the larynx—opened posteriorly. *aa*, Lateral ventricles of the larynx; *b*, Middle ventricle; *c c*, True vocal cords.

numerous on the posterior aspect of the epiglottis, in front of the arytenoids, and in the laryngeal ventricles.

The larynx is supplied with blood from the laryngeal arteries. The nerves are from the superior and inferior laryngeal branches of the vagus; twigs also come from the sympathetic.

The larynx gives passage to the air of respiration, prevents the intrusion of food into the air-tubes by closure of its lid, the epiglottis; and it contains the organ of voice, the latter being produced by vibration of the true vocal cords.

#### TRACHEA.

The trachea, or windpipe, is a nearly cylindrical, and flexible tube, consisting of a series of incomplete cartilaginous rings. It succeeds the larynx, runs down the neck, enters the thorax, and terminates at the base of the heart, where it divides into the right and left *bronchi*. Like the neck, it varies in length, and consists of forty or fifty rings, the ends of which overlap posteriorly, forming a perfect expansile tube. It presents a number of transverse furrows, which correspond to the interspaces between the rings. The latter vary in depth, averaging half-an-inch, and they are completed and united by strong elastic ligaments. The first is attached to the cricoid cartilage by a band called the *crico-trachealis ligament*. The ligaments contain involuntary muscular fasciculi, and they are attached by their extremities to the inner and posterior surface of the rings, and to their ends, so completing each ring.

The entire trachea is lined by mucous membrane, which is continuous with, but not so sensitive as that of the larynx; it is clothed with ciliated epithelium, and studded with glands. The trachea is related with the œsophagus and carotid arteries, the latter running along its sides. The arteries supplying the

anterior and middle parts, consist of twigs from the carotid ; posteriorly the supply comes from the broncho-oesophageal ; the nerves are derived from the recurrent and sympathetic.

#### THYROID AND THYMUS GLANDS.

About the two first tracheal rings is the brownish-red, thyroid body, consisting of two lobes, right and left, joined by a narrow band, the isthmus. Each lobe is ovoid, and consists of minute vesicles surrounded by a plexus of capillaries, and connected by areolar tissue. The gland is ductless, but copiously supplied with blood by branches of the carotid, and secretes an albuminous fluid, which is perhaps absorbed by the lymphatics, and conveyed into the blood. It is very large in foetal life, but its use is unknown.

The thymus is another ductless gland, situated on the inferior aspect of the trachea, and above the sternum. It consists of two halves united by areolar tissue, and is composed of lobules disposed round a central canal, having no external opening. Within are vesicles similar to those of the thyroid body ; in the foetus it is attached to the thyroid, and is large at birth, gradually disappearing.

#### BRONCHI—BRONCHIAL TUBES.

The terminal branches of the trachea are the right and left bronchi, which enter the lungs and subdivide dichotomously into branches termed bronchial tubes, the latter becoming gradually smaller, and finally terminating in the air-cells. The entire ramification when isolated has the appearance of a tree, the trachea being the main trunk, the bronchi and bronchial tubes the branches, and the air-cells the leaves. These structures are accompanied throughout by the arteries, veins, and nerves, which have the same arborescent distribution. The right bronchus is the larger, the left the longer, since it passes under the aorta before reaching the lung.

The bronchi and bronchial tubes are made up of cartilaginous rings, differing only from those of the trachea in being made up of several pieces, which overlap and are united by cellular tissue on their inner surface. As the tubes diminish in size, the number of these pieces is diminished, and ultimately they disappear.

The small bronchial tubes, after ramifying in the lungs, terminate in cellular recesses or air-cells, which consist only of the lining membrane of the tubes. The muscular bands of the trachea are continued along the inner face of the rings of the bronchi and larger bronchial tubes, also gradually disappearing. These tubes are lined by mucous membrane, which is continuous with, but more sensitive than that of the trachea. Blood is supplied by the bronchial arteries.

At the root of each lung there are a number of absorbent bronchial glands. The principal ones are closely adherent to the bifurcations of the bronchi

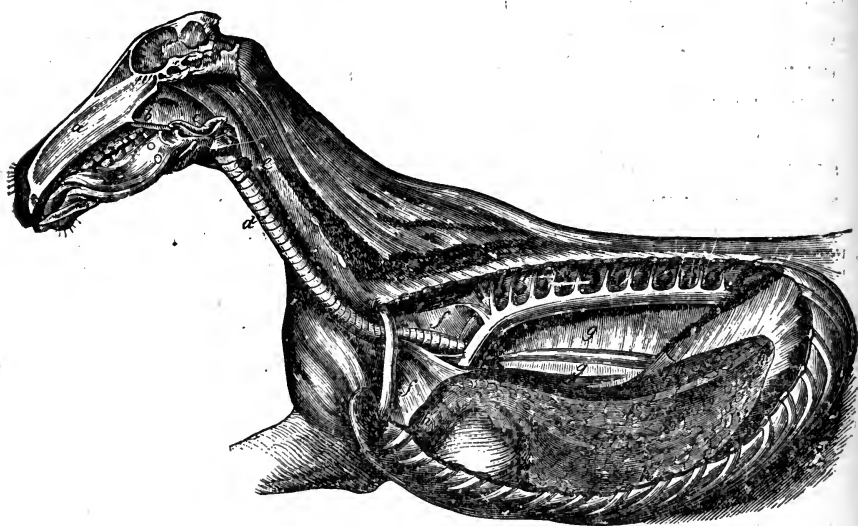


FIG. 118.

General view of the respiratory organs. *a*, Septum nasi; *b*, Posterior naris; *c*, Larynx; *d*, Trachea; *e*, Thyroid gland; *ff*, Anterior mediastinum; *gg*, Posterior mediastinum; *h*, Left lung; *h'*, Its apex; *h''* Its base; *h'''*, Its superior, and *h''''*, Its inferior borders.

#### THORAX.

The thorax, or thoracic cavity, is formed by the ribs, sternum, and bodies of the dorsal vertebræ, the intercostal muscles, thoracic fascia, and diaphragm; it contains the lungs, the heart and its adjuncts, the trachea, œsophagus, and a quantity of nerves; it resembles a hollow horizontal cone, flattened from side to side. Its base, formed by the diaphragm, slopes obliquely downwards and forwards.



## PLEURÆ.

The thorax is lined by two serous membranes, the right and left pleuræ, which consist of parietal and visceral portions, and form distinct sacs. Each pleura lines one side of the thorax and half of the diaphragm; the *pleura costalis* is the portion lining the ribs and intercostal spaces, the *pleura diaphragmatica* is that covering the diaphragm; in the median longitudinal plane it forms with the opposite pleura the *mediastinum*, whence each is reflected over one of the lungs, forming the *pleura pulmonalis*. The mediastinum is therefore a longitudinal passage through the thorax, bounded on each side by a pleural fold; it is divided into three portions—the *anterior* mediastinum lies in front of the heart, the *middle* contains it, while the *posterior* lies behind it. The mediastina are occupied by the trachea, œsophagus, heart, vessels, and nerves, and the anterior one in the fœtus by the thymus gland.

In tracing the course of a pleura. if we commence on the lateral aspect of the bodies of the dorsal vertebræ, we find that it extends downwards over the inner surfaces of all the ribs and intercostal spaces, forming the *pleura costalis*; posteriorly it passes to the anterior convex surface of the diaphragm, constituting the *pleura diaphragmatica*. At the centre of the sternum it is reflected upwards between the lungs, enclosing the pericardial sac. Gaining the root of the lung, the parietal portion passes on to it, forming the visceral portion or *pleura pulmonalis*, clothes the free surface of the lung, and again on the lung root it is reflected up to the vertebra, returning to its place of origin. The pleura is thick and loosely attached over the ribs, attenuated over the diaphragm and pericardium, and extremely so on the lungs; its surface is smooth and glistening, emitting a vapoury fluid, which lubricates the contacting surfaces and facilitates motion. The posterior mediastinum is cribrated inferiorly, several openings leading from one pleural sac to the other. This arrangement is *peculiar to solipedes*, and explains the fact that in these animals there cannot be pleural effusion confined to one side of the chest.

## LUNGS.

The lungs, the essential organs of respiration, are spongy organs of a conical shape, situated in the thoracic cavity, right

and left, the former being a little the larger; they are separated by the mediastinum, heart, pericardium, and large blood-vessels. During life, they occupy the major part of the cavity, resting on the inner surface of the walls, and adapting themselves to its varying capacity. They are light, porous, and highly elastic, possessing considerable strength. Healthy lungs float in water, their buoyancy being due to the air they always contain; when air is admitted into the thorax, they collapse considerably. In the adult, they are of a rosy flesh colour, marked by an irregular marbling or mottling.

The lung is attached midway by the *root*, which consists of the bronchus, vessels, and nerves, enveloped by the pleura. Each lung presents two surfaces, external and internal, a base, an apex, and three borders. The external costal surface is convex, corresponding to the thoracic wall. The internal, or mediastinal surface, forms a vertical plane in contact with the mediastinum, and presents an anterior division, which rests against the anterior mediastinum, in front of an excavation in which the heart is lodged; above and behind this is the root of the lung. Two *fissures* present themselves on the superior aspect, an anterior and posterior. The former crosses towards the superior border, and receives the posterior aorta; the latter, lower down, shallower, and more distinct in the left lung, is destined for the passage of the oesophagus. On the inner aspect of the right lung there is a small lobule, wanting on the left lung, formed by a deep fissure, through which the posterior vena cava passes; it is lined by a fold of pleura. The concave base is sloped downwards and forwards, fitting the convex surface of the diaphragm, where the fissure above noted originates. The summit or apex lies behind the first rib, and presents a partially detached appendage, the anterior lobe. The superior border is round, thick, and convex, and is lodged in the channel between the ribs and bodies of the vertebræ. The inferior border is thinner and shorter, deeply cleft near the heart, and more so on the left than on the right side. The posterior border is elliptical, surrounding the base, which it separates from the costal and mediastinal surfaces.

Structurally, the lungs consist of an external serous coat, a subserous layer, and the lung tissue proper, or *parenchyma*. The serous coat is the pleura pulmonalis. The subserous layer is composed of cellular tissue, intermixed with yellow elastic fibres; it clothes the entire lung surface, and is continuous with the inter-

lobular cellular tissue. The parenchyma is divided into many polyhedral lobules of various sizes, united by connective tissue; these are again made up of smaller ones, which are composed of a small bronchial tube and its terminal air-cells, in the walls of which lie the capillary vessels uniting the pulmonary arteries with the pulmonary veins. The air-cells are vesicular cavities, arranged as it were in bunches at the end of the tube; they consist of a thin membrane of connective and elastic tissue, with a layer of pavement epithelium. Each lobule is provided with its own bronchial tube and air-cells, functional and nutritive vessels, lymphatics, nerves, and interstitial cellular tissue, and is enveloped by the interlobular tissue. The interlobular cellular tissue is very fine, and continuous with the subserous layer. The lobular division is constant in all mammiferous animals; in the horse it is less distinct than in ruminants, where there is a much larger amount of interlobular cellular tissue.

The pneumatic functional vessels are the pulmonary artery and veins. The artery conveys venous blood from the heart to the lungs. At the lung-root it divides into right and left branches, which are distributed to their respective lungs, in company with the ramifying bronchial tubes, terminating in a capillary network around the terminal air-cells, whence arise the radicles of the pulmonary veins, which return the purified blood from the lungs to the heart.

The nutrient vessels are the bronchial arteries and veins. These arteries proceed from the posterior aorta; their branches are smaller than the pulmonary, and also accompany the air-tubes. The pulmonary lymphatics are numerous, and divided into superficial and deep. The former are situated in the subserous layer, forming a network, the latter in the interlobular tissue. Both communicate at the lung-roots, and pass through the bronchial glands. The nerves are from the pulmonary plexus, formed by the vagus and sympathetic.

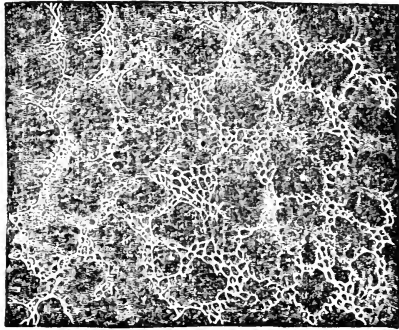


FIG. 119.

Arrangement of capillaries round the air-cells of the lung.

## URINARY SYSTEM.

The organs of this system secrete the urine from the blood; and excrete or expel it from the body. These organs are chiefly the Kidneys, Ureters, Bladder, and Urethra. The urine, which is a watery fluid, is secreted by the kidneys, and carried off by their ducts, the ureters, to a special reservoir, the bladder, where it accumulates, and from which it is finally expelled at intervals through the urethra.

## KIDNEYS.

The kidneys are two compound tubular glands, situated on the right and left of the vertebral column, in the sublumbar

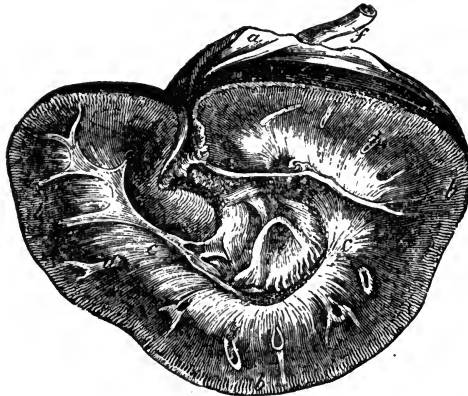


FIG. 120.

Horizontal section of the right kidney. *a*, Fibrous capsule detached; *b b b*, Cortical layer; *c c*, Medullary layer; *d d d*, Cut ends of large blood-vessels; *e*, Pelvis of the kidney; *f*, Ureter.

region of the abdomen, in contact with the crura of the diaphragm and psoe muscles. They are supported by peritoneum and cellular tissue, in which is deposited a quantity of fat; less perhaps in the horse than in other herbivorous animals. The kidneys are also supported by their vessels as well as by the pressure of the digestive organs; the right one is in advance of the left, lying just behind and beneath the last pair of ribs, whereas the left one lies about two inches farther back. They somewhat resemble in shape the heart on playing cards. the left

one being longer and narrower than the right. From perverted development, the kidney of the horse is sometimes lobulated.

The kidney presents two surfaces and a circumference. The surfaces are smooth, the superior one being flattened, and attached to the muscles by cellular tissue; the inferior one is convex, covered by and attached to the peritoneum. The circumference is divided into three borders; anterior, posterior, and internal. The two former are convex; to the first is attached the suprarenal capsule. The *internal border* is slightly concave, being deeply notched in the centre, forming the *hilus*, which leads to a cavity called the *sinus*. The vessels, nerves, and duct of the kidney join it in or about the hilus.

The kidney is made up chiefly of the tubes of the gland, termed the *uriniferous tubes*, with blood-vessels and nerves, and connective tissue; it is invested by a fibrous capsule, and contains a cavity known as the *pelvis* of the kidney. The capsule invests the entire organ, entering the hilus and covering the sinus, vessels, and duct. It consists of thin, smooth, fibro-areolar tissue, intimately connected with the surface of the gland by minute fibrous processes and blood-vessels. On making a horizontal section of a kidney, it is found to consist of an external or *cortical*, and an internal or *medullary* substance. The *cortical* layer is situated beneath the capsule, sending prolongations inwards into the medullary portion. It is dark reddish-brown and friable, consisting of minute blood-vessels, convolutions of the uriniferous tubes, lymphatics, and nerves, united by areolar tissue. On examining the section with or without a lens, numerous minute red points are seen in the cortical portion, the *Malpighian bodies*. Each consists of

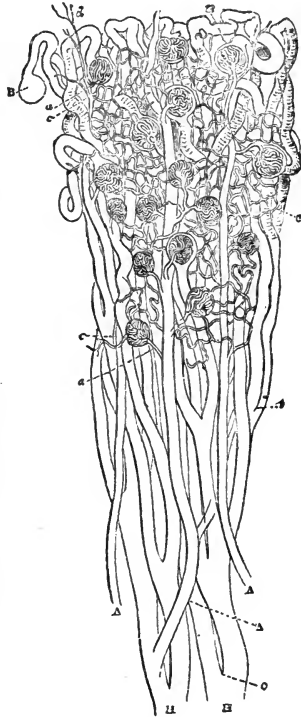


FIG. 121.

Structure of the kidney. A A A, Large branches of renal artery; a a, Afferent vessels; B B, Malpighian bodies; c c c, Capillary plexuses formed by efferent vessels; d, Twigs from renal artery; H H, Larger tubcs of Bellini; t, Smaller branch of the same.

capillary blood-vessels, arranged in a tuft or *glomurulus*, surrounded by epithelium, and enclosed in a membranous capsule, the capsule of Bowman, which is the dilated origin of a uriniferous tube. The small branch of the renal artery, entering the capsule, is the *afferent vessel* (*vas afferens*), whence proceed the capillaries which form the tuft. The *efferent vessel* (*vas efferens*), which leaves the tuft near the afferent one, forms a capillary plexus round the adjacent tubes, terminating in the veins. A dark line separates the cortical from the medullary layer, and has been termed the *limiting layer*, or periphery of the medulla. In or near this layer the larger blood-vessels ramify.

The medullary substance is denser in structure, fibrous in appearance, and consists of pale, conical masses—the *pyramids of Malpighi*; these have their bases directed outwards, their apices converging to the pelvis, and are composed of minute diverging uriniferous tubes, separated from each other by capillary vessels and intermediate tissue, similar to that of the cortical substance. The termination of the pyramids in the pelvis varies in different animals. In the horse they terminate in a continuous ridge, which projects into the pelvis; and on the surface of this ridge are numerous minute orifices, the *outlets*. In the centre of the kidney, and nearly surrounded by the medullary substance, is an irregular cavity formed by the dilatation of the ureter, the *infundibulum*, having lateral prolongations called the *arms*, the whole constituting the *pelvis*.

The urine secreted by the tubuli uriniferi and Malpighian bodies is thus poured into the pelvis. The tubes pass up the pyramids in straight but slightly diverging lines, subdividing at very acute angles until they reach the cortical substance, where they dilate and become 'tortuous'; this part has been termed an *intermediary tube*, and from it a constricted tube passes inwards, dipping more or less into the medullary layer, and then returning to the cortex, so forming a loop. To the *looped tube* succeeds a second dilated portion, greatly convoluted, and known as a *convoluted tube*, which finds its origin in a dilatation—one of the

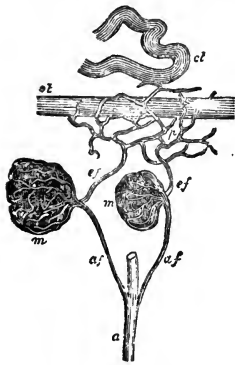


FIG. 122.

Distribution of the renal vessels. *a*, Branch of renal artery; *af*, Afferent vessels; *m*, Malpighian tuft; *ef*, Efferent vessels; *p*, Capillary plexus around the uriniferous tubes; *st*, Straight tube; *ct*, Convoluted tube.

capsules of Bowman. The straight tubes in the medullary substance are the *tubes of Bellini*; the convoluted ones in the cortical substance, the *tubes of Ferrein*; while the looped ones are the *tubes of Henle*. At the base of the pyramids the straight tubes form small bundles or fasciculi, which are prolonged into the cortical substance as the *pyramids of Ferrein*. The tubuli uriniferi consist of a membranous wall of varying thickness, lined by epithelium, which in the straight tubes is columnar in form.

Blood is supplied by the renal artery, nerves by the solar plexus; the latter ramify round the arteries. The superficial lymphatics are situated on the external surface, and pass into the lumbar glands; the deep-seated ones accompany the blood-vessels.

The function of the kidneys is to secrete the urine, a fluid consisting of water, holding in solution a varying quantity of earthy salts, and a peculiar nitrogenous substance, Urea, which if not eliminated, acts as a blood-poison. Strange to say, this effete material is secreted from arterial, or comparatively pure blood.

#### SUPRARENAL CAPSULES.

These are two small, flat, reddish-brown glandular bodies, about two inches long, attached to the anterior borders of the kidneys. They are ductless, larger in the foetus than in the adult, and consist of a fibrous membrane covering a parenchyma, which consists of an external cortical and an internal medullary substance. The external substance is brown in colour; the medullary is yellowish, soft, pulpy, nucleated and granular. The function of these glands is unknown. They are larger in the foetus than in the adult, and are said to be replaced if removed.

#### URETERS.

The ureters, the excretory ducts of the kidneys, are two membranous canals, which convey the urine from the pelvis of the kidney to the bladder. They consist of three coats; an external fibro-cellular, a middle muscular, and an internal mucous, lined with epithelium similar to that of the bladder. On leaving the hilus, they are directed towards the pelvic cavity, alongside the aorta on one, and the posterior vena cava on the other side, and between the peritoneum and the abdominal roof. On arriving at the termination of the aorta they cross the iliac arteries, covered

by peritoneum, which holds them against the lateral walls of the abdomen and pelvis, terminating at the postero-superior part of the bladder, which they enter on either side by piercing its coats in a very oblique manner, and so leading to the formation of a valve which prevents regurgitation of the urine.

The ureters are supplied with blood by twigs from the renal, spermatic, and vesical arteries. The nerves come from the spermatic and hypogastric plexuses.

#### BLADDER.

The bladder, a musculo-membranous organ, serves as the reservoir for the urine, and is situated within the pelvic cavity, and when full projecting into the abdomen. It consists of a fundus, or body, and a neck. The *fundus* when full is ovoid, and turned forwards, having a cicatrix, which marks the site of the *urachus*. The *neck* is turned backwards, and is continuous with the urethra. The bladder is related above with the vesiculæ seminales and rectum in the male, in the female with the vagina and uterus, which are interposed between it and the rectum; below with the floor, and laterally with the walls of the pelvis.

The bladder consists of three coats; mucous, muscular, and serous; The latter is only a partial covering, being a continuation of the peritoneum, clothing the anterior part of the organ; it becomes reflected from it in several places, constituting the *false ligaments* of the bladder. The muscular coat consists of two layers of smooth muscular fibres; an external longitudinal one, the *detrusor urinæ*, and an inner circular layer, thinly scattered over the body, but denser at the neck, forming the *sphincter vesicæ*. The sphincter vesicæ is less developed in quadrupeds than in man. There are also two bands of oblique fibres passing from the posterior aspect of the ureters to the back of the prostate gland.

The internal mucous coat is pale, smooth, roseate, and loosely attached to the muscular layer by cellular tissue, which some consider a fourth coat. It is thrown into *rugæ* when the bladder is empty, and provided with mucous follicles, most abundant at the neck; it is covered by stratified epithelium. Upon the internal surface, between the openings of the ureters and commencement of the urethra, is a smooth triangular space, the *trigonus vesicæ*, which is pale, sensitive, intimately attached to



the adjacent tissue, and never thrown into rugæ. Projecting from the posterior end of the trigonus into the opening of the urethra, is a slight elevation of the mucous coat, the *uvula vesicæ*.

The bladder is maintained in position by false and true ligaments. The false ligaments are folds of peritoneum, of which the anterior or *broad* one passes from the fundus along the abdominal floor to the umbilicus; two *lateral* folds extend from the sides of the bladder to the pelvic walls, enclosing in their folds the remains of the obliterated umbilical arteries; finally a *superior* fold connects it with the rectum. The remains of a foetal organ, the urachus, appearing as a fibrous cord, are generally described as lying between the folds of the broad ligament.

The true ligaments are formed by processes of the pelvic fascia. These are the *inferior true ligaments*, attached to the inferior aspect of the bladder and prostate gland; the *lateral true ligaments* which are attached to the sides of the organ, while the *recto-vesical* ligament joins the bladder and rectum posteriorly.

In the female, the uterus lying between the rectum and the bladder, we have *recto-uterine* and *vesico-uterine* ligaments.

The principal artery is the vesico-prostatic branch of the internal iliac. Lymphatics are numerous in the walls of the trigonus. The nerves are from the hypogastric and sacral plexuses.

The use of the bladder is to store the urine and at intervals, by contraction of its walls force it into the urethra or excretory tube.

The Urethra is a tube common, in the male, to the urinary and genital systems, and will be described with the latter.

#### GENERATIVE SYSTEM.

Animals possess the faculty of reproducing or propagating their species, and this function may be non-sexual or sexual, the former being confined to certain lowly-organised classes of animals.

In all the higher animals the generation of a new being is dependent upon two individuals, a male and a female, the female furnishing a germ or *ovum*, the male a fecundating fluid or *sperm*, which animates the germ and renders it fit for development.

Both the ovum of the female and the sperm of the male are the secretions of glands, which are termed the *genital glands*, male and female; and in either sex the generative system may be said to consist of these glands, with certain accessory organs. The act of coition brings the two secretions into contact.

We have thus two systems of Genital organs to consider—the male and the female.

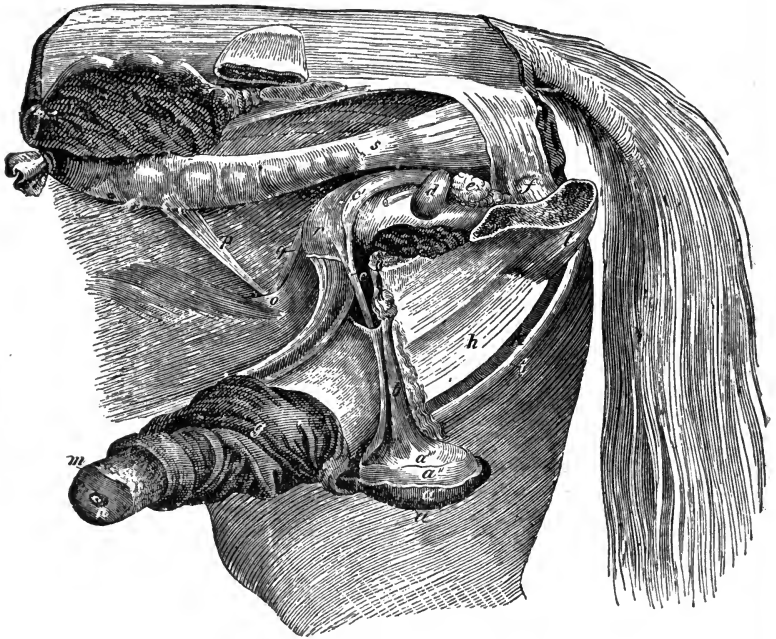


FIG. 123.

General view of male generative organs—the abdomen and pelvis being opened from the left side, *a*, Scrotum; *a'*, Skin; *a''*, Dartos; *a'''*, Tunica vaginalis; *b*, Cremaster; *c*, Left vas deferens; *c'*, Its bulbous portion; *d*, Left vesicula seminalis; *e*, Prostate gland; *f*, Cowper's gland; *g*, Sheath; *h*, Corpus cavernosum; *i*, Retractor muscle of the penis; *k*, Urethra surrounded by accelerator muscle; *l*, Erector penis muscle; *m*, Glans penis; *n*, Mentus urinarius; *o*, Internal abdominal ring; *p*, Peritoneal fold, enclosing spermatic vessels and nerves; *q*, Right vas deferens; *r*, Bladder; *s*, Rectum.

#### MALE GENITAL ORGANS.

The spermatic or *seminal* fluid of the male is elaborated in two glands, situated in the scrotum, called the *testicles*, each being furnished with an excretory duct, the *vas deferens*, which transmits the sperm to reservoirs situated on the bladder, the *vesiculæ seminales*. Here the sperm accumulates, and is expelled by the contractile walls of the vesiculæ during the act of copulation,

through the ejaculatory ducts into the urethra, which is common to the urinary and generative organs. The urethra is provided with accessories, the *prostatic* and *Cowper's* glands, and is supported by an erectile tissue which forms an elongated organ, the *penis*.

## INGUINAL CANALS.

These canals afford communication between the abdominal and scrotal cavities. They have been described (see p. 203).

## SCROTUM—INGUINAL FASCIA.

This is a sac or bag which contains the testicles, situated between the thighs, and made up externally of a layer of the common integument, continuous with that of the abdomen, flanks, and sheath. The skin covering it is soft and thin, generally black, and clothed with fine downy hairs; it is marked mesially by a longitudinal raphe, indicating its division into right and left cavities. Below the skin is a thin layer of muscular and elastic tissue forming the proper scrotal tunic, the *dartos*, which sends in a fold between the testes, constituting the *septum scroti*, and corresponding to the external raphe. The *dartos* is continuous with the superficial abdominal fascia or elastic tunic. Under the *dartos* we find the *spermatic*, or *inter-columnar fascia*, from the external oblique muscle, attached to the margin of the external abdominal ring, and passing down over the cord. Inside this is the *cremasteric fascia*, an expansion of the cremaster muscle, arising from the iliac fascia, and passing through the inguinal canal, down the cord to surround the testicle; this fascia forms only an incomplete covering. Still deeper seated we have the *infundibuliform fascia*, which is an extension of the fascia transversalis, and is funnel-shaped, commencing at the internal abdominal ring; it is prolonged as a sheath over the cord and testicle, and is connected with their serous tunic.

## SPERMATIC CORD.

The testicle is suspended in the scrotum by the spermatic cord, a structure made up of the *vas deferens*, or duct of the testis, which runs along its posterior edge, with various blood-vessels, nerves, serous membrane, muscular tissue, and fascia;

its anterior edge contains the spermatic artery and veins; it extends from the inguinal canal to the testicle, certain coverings being common to it and the latter.

The serous covering of both structures is continuous with the peritoneum, and consists of two folds, the parietal layer being attached to the infundibuliform fascia, the visceral layer to the duct, vessels, and other structures which help to form the cord. The artery of the cord supplies the spermatic cord with blood.

#### TESTICLE.

The male genital glands, or testicles, are two oval, compound tubular glands, situated in the scrotum, and attached superiorly to the spermatic cord; their long axes are placed almost horizontally from before backwards. In foetal life they are at first situated in the abdominal cavity, behind the kidneys, and above the peritoneum. At a certain period, they descend through the inguinal canals into the *scrotum*. In their descent each is guided by a soft cord, the *gubernaculum testis* or pilot, which at first joins them to the abdominal floor, in their descent through which they, and the spermatic cord, carry with them coverings derived from the tissues forming the abdominal parietes.

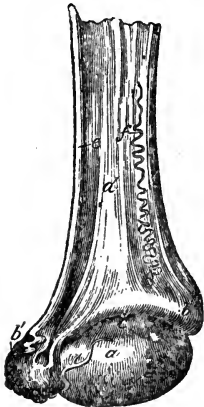

FIG. 124.

External view of right testicle and cord. *a*, Testicle; *b*, Globus major of epididymis; *b'*, Globus minor, *c*, Fold of tunica propria reflected from testicle to epididymis; *d*, Spermatic cord; *e*, Vas deferens; *f*, Spermatic artery.

Thus from without inwards, the scrotum is derived from the skin; the dartos from the abdominal tunic; next the spermatic fascia, very rudimentary in the horse, and especially about the testicle, is derived from the external oblique; then the cremasteric fascia, perhaps from the internal oblique; then the infundibuliform fascia from the fascia transversalis; and finally, two serous folds from the peritoneum, forming a shut sac, continuous in the domesticated mammals with that of the abdomen. The remaining coverings of the testicle are peculiar to itself.

The outer serous covering of the testicle is called the *tunica vaginalis reflexa*, which is united by cellular tissue to the infundibuliform fascia; the inner, the *tunica vaginalis propria*, is

attached to the outer surface of the subjacent tunic—the *tunica albuginea*, dura mater testis, or proper tunic, which is a dense fibrous membrane of a bluish-white colour. The tunica albuginea, after surrounding the testicle, is reflected into its substance, forming a septum called the *mediastinum testis*, or *corpus Highmorianum*, from which originate numerous fibrous cords, the *trabeculæ septulæ*, which terminate on the inner surface of the tunic, dividing the organ into lobules. Finally, we have the most internal covering, the *tunica vasculosa*, or *pia mater testis*, which is the vascular coat; it lies beneath the preceding one, enclosing the testicle, and supporting the vessels, whose branches ramify on the mediastinum testis and trabeculæ septulæ.

The testicle consists of a soft glandular substance of a reddish-yellow colour, and is divided into small distinct *lobules*, varying in number from 200 to 300; they are conical in shape, having their base towards the surface, and consist of several minute convoluted tubes, the *tubuli seminiferi*, which originate as loops or free cæcal ends, and are most convoluted at the base of the lobule, gradually straightening as they approach the apex at the mediastinum, where they unite to form larger tubes, the *vasa recta*, which enter the mediastinum and terminate in a close network of tubules, the *rete testis*. These pass upwards to the superior extremity of the mediastinum, where they terminate in the *vasa efferentia*, a number of small ducts which perforate the tunica albuginea; straight at first, they shortly become convoluted, and form a series of conical masses, the *coni vasculosi*, from whose bases larger tubes issue, the whole forming the origin of the *epididymis*.

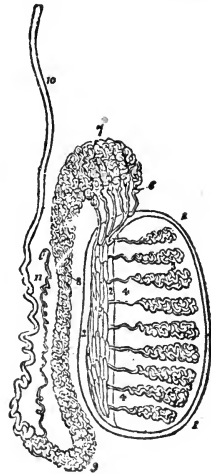


FIG. 125.\*

Diagrammatic view of the structure of the testis. 1 1, Tunica albuginea; 2 2, Mediastinum testis; 3 3, Convoluted origins of seminiferous tubes; 4 4, Vasa recta; 5, Rete testis; 6, Vasa efferentia; 7, Coni vasculosi forming the globus major; 8, Body of epididymis; 9, Globus minor; 10, Vas deferens; 11, Vasculum aberrans.

\* [Fig. 125 represents the structure of the human organ. The chief difference to bear in mind is that of position, the long axis being nearly horizontal in the horse, and the superior extremity in the cut is placed anteriorly in that animal.—ED.]

## EPIDIDYMIS.

The epididymis is an elongated body extending along the upper border of the testis, and covered by a continuation of the tunica vaginalis propria. It consists of a body, a *head* or *globus major*, and a *tail* or *globus minor*. The head, situated anteriorly, is closely adherent to the testicle through the vasa efferentia. The body is free, and curved to the shape of the testicle, to which the head is attached. The globus minor, posteriorly placed, is more free than the rest. The vasa efferentia, forming the coni vasculosi, enter the globus major, and successively join at irregular distances to form the *canal of the epididymis*, the convolutions of the latter forming the body and globus minor. The tubes join and become larger, until they form a single canal, the *vas deferens*, of which the epididymis may be regarded as the origin.

## VAS DEFERENS.

This is a tube with firm solid walls, which, after leaving the globus minor, ascends the back of the spermatic cord to the inguinal canal. On passing through the internal abdominal ring, the vas deferens leaves the cord and enters the pelvis, passing to the antero-lateral aspect of the bladder, where the obliterated umbilical artery winds round it; it then becomes dilated, forming the *bulbous portion*; it is directed backwards and inwards towards the neck of the bladder; here it is joined by the duct of the *vesicula seminalis*, the two forming the *ejaculatory duct*. The vas deferens thus terminates about the base of the prostate gland. A long narrow tube, the *vasculum aberrans*, is sometimes found leaving the lower part of the canal of the epididymis, extending a short way up the back of the testis, between it and the body of the epididymis, and terminating in a cæcal extremity. The vas deferens consists of three coats—an external one of connective tissue, a middle muscular and elastic, and an internal mucous coat, lined chiefly with columnar epithelium.

## VESICULÆ SEMINALES.

The vesiculæ seminales are two lobulated, pear-shaped, glandular pouches, situated on each side of the postero-superior aspect of the bladder, and between it and the rectum. Their larger

ends, directed forward and outward, are widely separated, their narrow ones almost meet, thus forming a triangular space which corresponds to the *trigonus vesicæ* on the inside. They consist of a single tube which terminates in a blind end, and gives off several branches or diverticula, which also end in closed extremities. The narrow end terminates in a duct, which at the base of the prostate is joined at an acute angle by the *vas deferens*; these constitute the ejaculatory duct. The *vesicula seminalis* is made up of three coats—an external fibro-cellular, a central dense, fibrous, and elastic, said to contain muscular fibres, and an inner pale mucous lining, which contains tubular glands, secreting the fluid peculiar to the cavity. The anterior half only is covered by peritoneum, a fold of which is reflected from one vesicula to the other.

Blood is supplied by the vesico-prostatic arteries; the nerves come from the pelvic plexus. They are seminal receptacles, secreting also a special fluid which mixes with the semen.

#### EJACULATORY DUCTS.

These ducts, right and left, are formed by the junction of the narrowed extremities of the *vesiculæ seminales* and the *vasa deferentia* just at the base of the prostate; they pass between its middle and lateral lobes, terminating in the urethra by two orifices, one on each side of an opening on the *verumontanum*, which leads to a sac called the prostate vesicle.

The *prostate vesicle*, sometimes called the *uterus masculinus*, or *sinus pocularis*, represents in the male the uterus and vagina of the female. It is a canal about four inches in length, which ascends in the folds of the peritoneum between the *vasa deferentia*; its lower end is situated between the ejaculatory ducts. It opens into the urethra, on the *verumontanum* between the openings of the ejaculatory ducts, sometimes ending in one of them. It is lined by mucous membrane containing tubular glands, and its walls are of a fibro-muscular nature.

#### PROSTATE GLAND.

Situated upon and partly around the neck of the bladder and commencement of the urethra, this organ, a compound racemose gland, is connected with the pelvis and the rectum by the pelvic

fascia. It varies in size, and consists of three lobes; a middle and two lateral ones; the middle one lies on the posterior part of the neck of the bladder and the superior surface of the urethra; in old animals this lobe may become enlarged, and pressing on the urethra cause retention of urine. It is enclosed in a dense fibrous capsule, which is continuous with the pelvic fascia. It is pale, reddish-grey, and very friable, consisting of glandular and muscular tissue, containing numerous small follicular pouches, which end in elongated canals; these again unite to form a number of excretory ducts, which open in a depression called the prostatic sinus, situated at either side of the verumontanum. The follicles are united together by areolar tissue, supported by prolongations of the capsule. The canals and the follicles are lined with columnar epithelium.

The prostate gland is supplied with blood by the vesicoprostatic artery, its veins forming the prostatic plexus.

#### COWPER'S GLANDS.

Cowper's glands, called also in veterinary anatomy the *lesser prostates*, are a pair of small bodies, situated on either side of the membranous portion of the urethra, above the ischial arch, covered by Wilson's muscle. They are of a reddish-yellow colour, and dense in their structure, consisting of several minute lobules held together by investing cellular tissue. They resemble the prostate gland in their ultimate structure, being compound racemose or aggregated glands, and terminate in the urethra by a row of minute openings on either side.

#### URETHRA.

The urethra is a tube which extends from the neck of the bladder to the glans penis in the male, and from the bladder to the vulva in the female. In the latter it is simply an excretory passage for the urine, but in the male it transmits also the seminal fluid. It consists of two layers; an internal mucous one, continuous with that of the bladder internally, and the covering of the glans penis externally; and an external layer consisting of fibrous tissue, with muscular fibres.

It is divided into prostatic, membranous, and spongy portions. The *prostatic*, very short, is the most dilatable part of the canal, commencing at the neck of the bladder. It passes through the



prostate gland below its middle lobe. The *membranous* division extends from the prostatic portion to the ischial arch, and is the narrowest part of the canal, being surrounded by fibres from the retractor ani and Wilson's muscles; it is sometimes called the muscular division. The *spongy* portion extends from before the ischial arch to the external opening, or *meatus urinarius*; it is narrow in the middle, but dilated at either end. The posterior dilatation is known as the *bulbous portion*. Near the external orifice the canal is contracted, but on reaching the glans it dilates and forms the *fossa navicularis*.

As the urethra leaves the neck of the bladder there is an elevation of its mucous membrane, called the *uvula vesicæ*. On *laying open* the urethra from the neck of the bladder, the first object that attracts attention is an elongated ridge on the roof of the prostatic portion, the *caput gallinaginis, verumontanum*, or

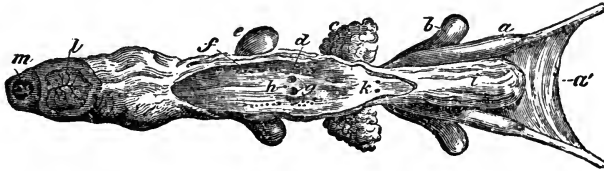


FIG. 126.

Bladder and pelvic portion of urethra, seen from below—the latter being laid open. *a*, Bulbous portion of vas deferens; *a'*, Fold of peritoneum joining vasa deferentia; *b*, Vesicula seminalis; *c*, Right lobe of prostate gland; *d*, Excretory canals of prostate; *e*, Cowper's gland of right side; *f*, Its excretory orifices; *g*, Verumontanum with openings of ejaculatory ducts; *h*, Opening of uterus masculinus; *i*, Bladder; *k*, Orifices of ureters; *l*, Transverse section of corpus cavernosum; *m*, Transverse section of urethra.

crest of the urethra, which contains the orifices of the ejaculatory ducts and prostate vesicle; and on each side of the crest is a slight groove, the *prostatic sinus*, into which the prostatic secretion is poured by numerous orifices. About the commencement of the bulbous portion, just behind the membranous division, are the openings of Cowper's glands. The urethral mucous membrane is furnished with numerous depressions or lacunæ, which are receptacles of mucus. They are most plentiful at the lower part of the spongy portion, and in the fossa navicularis is a very large one, the *lacuna magna*.

#### PENIS.

The penis is the male organ of copulation; it supports, or rather contains, the greater part of the urethra. It may be said

to consist of an attached and a free portion; the first originating at the ischial arch, in the pillars, or *crura penis*, and terminating before the brim of the pubis, where the free portion commences.

The substance of the penis is formed of what is called *erectile tissue*, a tissue which, under certain circumstances, becomes enormously distended with blood. The erectile structures are two in number, the *corpus cavernosum* and the *corpus spongiosum*.

The *corpus cavernosum*, much the larger of these structures, forms the superior and lateral portions of the penis; it is divided by an imperfect fibrous partition, the *septum pectiniforme*, into two lateral halves, which may be regarded as separate *corpora cavernosa*. This septum is thick and complete behind, gradually thinning as it approaches the free extremity of the penis, where it only imperfectly separates the halves. It consists of simple vertical bands, similar to the teeth of a comb, extending from above downwards. The *corpora cavernosa* are invested by a strong elastic fibrous tunic, whence spring *trabeculæ*, which divide it into numerous compartments, giving it a cavernous appearance; in these caverns are cells, which receive the blood during erection of the organ. The upper surface between the cavernous bodies is grooved for the dorsal vessels; the inferior aspect is also grooved, and lodges the *corpus spongiosum*. The *corpora cavernosa* recede from each other posteriorly, forming the pillars, or *crura penis*, which are attached to the ischial arch, and are crossed by the *erectores* muscles, which blend with them; anteriorly they terminate in blunt points behind the *glans penis*. The penis is attached to the symphysis pubis by two suspensory ligaments, which spring from the *corpora cavernosa*.

The *corpus spongiosum* encloses the urethra, is situated in the inferior groove of the *corpora cavernosa*, and surrounded by the accelerator muscle. It commences between the *crura* by an enlarged portion, the bulb of the penis, and passes down the groove until it reaches the anterior extremity, where it expands to form the *glans*. The *spongiosum* is enclosed in a fibrous tunic, similar to, but more delicate than, that of the *cavernosa*.

The *glans* forms the terminal extremity of the penis, and is an enlargement of the *corpus spongiosum*. At its apex is a deep fossa, in the centre of which lies the *meatus urinarius*, bounded by two prominent lips. It terminates posteriorly by a con-

stricted part, the *cervix*, in front of which is the projecting *corona glanulis*.

## SHEATH.

The sheath is a loose process of integument, which invests the free portion of the penis; it forms a corrugated sac extending from the scrotum, with which it is continuous, to a varying distance forwards. Anteriorly a loose double fold of the sheath projects, covering the anterior extremity of the penis completely when quiescent; this is the *prepuce*, or foreskin, and from it the skin is continued in a modified form over the glans, which it covers, and becomes continuous with the urethral mucous membrane; the skin around the prepuce is so corrugated as to admit of the erection and projection of the penis, during which the corrugations become effaced.

The inflected fold of the prepuce is void of hair, and resembles that of the glans in structure, being intermediate between that of skin and mucous membrane; opening on its inner surface are the *glandulæ odoriferæ*, which secrete a peculiar odorous matter, and are most numerous about the cervix. The sheath is suspended from the abdominal walls by the *suspensory ligaments*, which are two layers of yellow elastic tissue, passing from the abdominal fascia to the sides of the sheath.

## MUSCLES OF THE MALE GENITAL ORGANS.

These are as follows:—

Cremaster.	Erector penis.
Accelerator Urinæ.	Retractor penis.
Wilson's muscle.	

*Cremaster*.—A ribbon-shaped muscle arising from the fascia covering the psoe muscles; it is attached by cellular tissue to the psoas magnus and iliacus, passes through the inguinal canal, and is distributed over the infundibuliform fascia; it consists of pale delicate fibres, terminating in slender tendinous slips. It raises and assists in suspending the testicle.

*Accelerator urinæ*.—This may be regarded as single or a pair, consisting of transverse fibres, which arise from the ischial arch, pass along the under surface of the penis, completely investing the urethra, and extend as far forwards as the glans, the fibres mutually blending. This muscle comprises the urethra, and assists in the discharge of urine and semen.

*Erector penis.*—This is a somewhat conical muscle, arising from the inferior portion of the tuberosity of the ischium. It is inserted to the penis, and is a retractor and levator of that organ.

*Retractor penis.*—This is a long, flat muscle, arising from the inferior surface of the sacrum; it descends in front of the sphincter ani, between the retractor ani and the walls of the rectum, where it gives off numerous short bundles, which unite below and form a suspensory ring for the rectum. It now passes along the inferior surface of the penis, is attached to the accelerator urinæ by cellular tissue, reaching the glands, on which it is lost. It retracts the penis within the sheath.

*Wilson's muscle.*—A muscle, consisting of transverse fibres, which arise from the lateral walls of the pelvis, and are attached to the membranous urethra, embracing Cowper's glands. It compresses and aids in the discharge of the glands, and contracts the membranous portions of the urethra.

*Perineal fascia.*—This is situated in the perineal region, and it consists of two layers, a superficial and a deep. The former, which is fibro-elastic in its structure, lies immediately under the skin, and is connected inferiorly with the dartos; it extends upwards, gradually disappearing as it nears the anus. Internally this layer is attached to the deep portion, which is more of a white fibrous nature, and extends from the rectum downwards between the thighs, becoming gradually lost in either direction. It is related with the erector, and accelerator muscle, and also passes between the former and the adductor magnus, to become attached to the ischial tuberosity.

The arteries of the penis are the external and internal pudic, and twigs from the obturator. The nerves come from the internal pudic and sympathetic.

#### SEMINAL FLUID.

The secretion of the male genital glands is a viscid, whitish, albuminous fluid—the sperm, or seminal fluid, which contains the *spermatozoa*, microscopic objects consisting each of an ovoid head, and a long wavy filamentous tail. They possess a certain vibratory motion, and have the power of penetrating and fertilising the female ovum.

## FEMALE GENITAL ORGANS.

Adopting a similar sequence of description to that observed in treating of the male organs, we note that the female genital glands are the *ovaries*, which furnish the *ovum* or germ of the future animal; the ovum is conveyed along the *Fallopian tube* to the *uterus*, a cavity in which it becomes impregnated and developed. The *vagina* is a tube or cavity analogous to the urethra in the male, in that it is common to the Urinary and Genital systems, the uterus opening into it anteriorly, and the meatus urinarius being situated at its posterior boundary. As

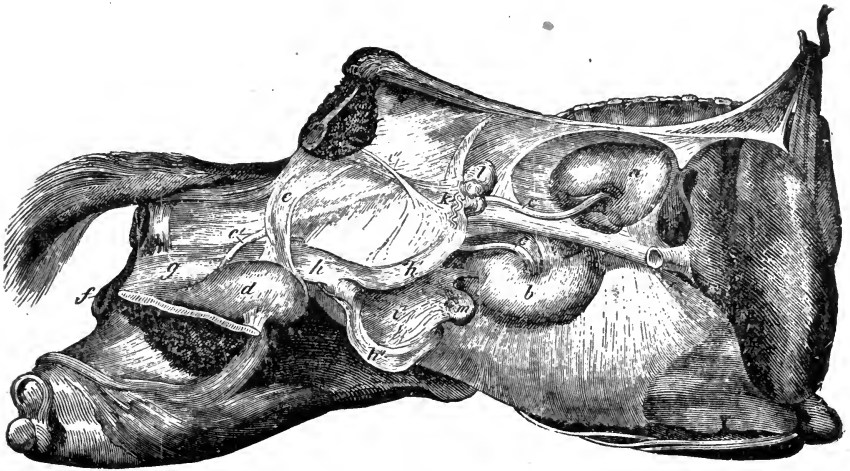


FIG. 127.

Female urino-genital organs *in situ*—the abdomen and pelvis being opened on the right side; *a*, Right kidney; *b*, Left kidney; *c c*, Ureters; *c'*, Right ureter entering bladder; *d*, Bladder; *e*, Right lateral ligament of the bladder; *f*, lips of the vulva; *g*, Vagina; *h*, body of uterus; *h'*, Its right cornu; *h''*, Its left cornu; *i*, Broad ligament of right, and *i'*, Of left side; *k*, Fallopian tube; *l*, Right ovary; *m*, Left ovary.

the neck of the bladder lies immediately under the vagina, the urethra in the female is exceedingly short. The *vulva* is the external orifice of the vagina, the name being usually held to include a small portion of the cavity within.

To these organs may be added structures which are of importance, since they form the most prominent characteristic of the mammalian female—the *mammary glands*.

## OVARY.

The ovaries, being the analogues of the testes, are the ultimate organs of generation in the female. They are ovoid, similar in

shape to, but smaller than the testicles, and are situated in the sublumbar region of the abdomen, being suspended from its roof, a little behind the kidneys; they are attached anteriorly to the broad ligament of the uterus, behind and below the Fallopian tubes. In addition to this connection, they are attached at their inner end to the uterus by a muscular cord, the *ligament of the ovary*, and by their rounded outer end to the fimbriated extremity of the Fallopian tube; they are also supported by their blood-vessels, which enter anteriorly at a depression called the hilus. An ovary possesses an external serous investment from the peritoneum; and beneath is the dense fibrous *tunica albuginea*, resembling that of the testicle, which encloses the *stroma*, a firm reddish-white vascular substance, consisting for the most part of connective tissue, and apparently continuous with the external coat. Within are numerous small, round ovisacs or *Graafian vesicles*, which consist of two coats, an external vascular and an inner one, the ovi-capsule, lined by a granular and so-called *epithelial* layer, the *membrana granulosa*. The granular cells of which this is composed accumulate at one part of the vesicle forming the layer (*cumulus proligerus*), in which is embedded a small, round vesicular body, the true *ovum*. The Graafian vesicle contains a fluid secreted by the cells, and this fluid increases in quantity as the vesicle develops, and at the same time the latter gradually approaches the surface of the ovary, the intervening stroma becoming absorbed. Ultimately the wall of the ovary and the Graafian vesicle give way, the ovum escapes into the Fallopian tube, and is by it conveyed into the womb, the remains of the vesicle being converted into a yellow mass, the *corpus luteum*, which shortly becomes a small puckered cicatrix.

The ovum or egg is in the higher animals microscopic, being about  $\frac{1}{150}$  of an inch in diameter. It is a cell, possessing all the characteristics of such; the cell-wall is called the *zona pellucida*, vitelline or yolk membrane, which contains a protoplasm called the *vitellus* or yolk; the nucleus of the cell is known as the *germinal vesicle*, the nucleolus as the *germinal spot*. The arteries are derived from the utero-ovarian.

#### FALLOPIAN TUBES.

The Fallopian tubes, oviducts, or uterine trumpets, are two canals which convey the ova from the ovaries to the uterus. They

are enclosed in the free borders of the broad ligament, and run in a serpentine course from the *cul-de-sac* of each uterine horn to the ovary. The canal commences at the horn of the uterus by a very minute opening, the *ostium uterinum*, gradually enlarging into a trumpet-shaped tube, which is contracted at its termination, forming a small round orifice, the *ostium abdominale*, which communicates with the abdomen, thus forming a direct communication between the mucous membrane of the uterus and the serous membrane of the abdomen. The free extremity of the tube terminates in a series of irregular *fimbriæ* or fringes, which are arranged in a circle around the ostium abdominale. One of these is adherent to the ovary, and along it is a fissure continuous with the external opening of the tube; the fimbriæ embrace the ovary during sexual excitement, receiving the ovum on rupture of the ovisac, and conveying it into the Fallopian tube. The walls of these tubes consist of three coats—an external or serous one, derived from the peritoneum; a middle muscular, continuous with the uterine muscular wall, and consisting of an external longitudinal, and an internal circular layer of smooth fibres; and an internal mucous coat thrown into longitudinal folds, and continuous with that of the uterus. Ciliated epithelium lines both the tubes and the inner surface of the fimbriæ, changing to endothelium as the mucous and serous membranes unite.

Between the ovary and Fallopian tube, in the folds of the broad ligament, may be found an isolated bunch of small radiating tubes termed the *Par-ovarium*.

#### UTERUS.

The uterus, or womb, is a musculo-membranous sac situated in the sublumbar region and pelvic cavity; it consists of a *body* and *two cornua*.

The body is cylindrical and somewhat flattened; its superior surface contacts the rectum, which passes between the horns, while the suspensory or broad ligaments are attached laterally; the inferior surface and borders are related with the bladder and intestinal convolutions; the anterior extremity, or *fundus*, is continuous with the cornua; the posterior is continuous with the vagina, constituting the *cervix*, or *neck*, which is thick, round, and projecting in the virgin animal. In the centre is a transverse aperture or fissure, opening into the vagina, and closed

during utero-gestation. The cylindrical cornua spring from the anterior extremity of the body, diverge upwards and forwards, together presenting an inferior free convex curvature and a superior concave one, to which are attached the suspensory ligaments. Their posterior extremity is continuous with the body; while the anterior, or summit, forms a cavity turned upwards, into which the Fallopian tube enters.

The uterus consists of three coats; an external serous, central muscular, and internal mucous. The serous coat, a reflection of

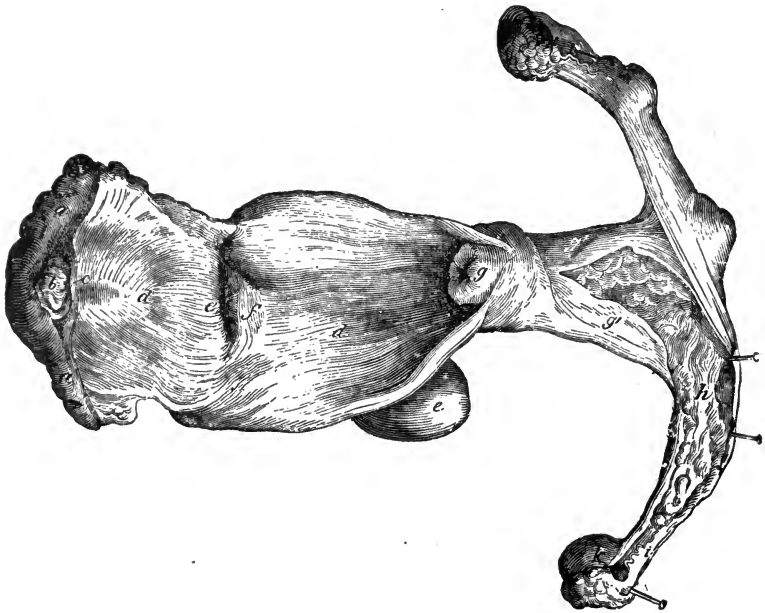


FIG. 128.

Female generative organs partly laid open—seen from above. *a a*, Lips of vulva divided at the superior commissure; *b*, Clitoris; *c*, Prepuce; *d d*, Vagina laid open; *e*, Bladder; *e'*, Meatus urinarius; *f*, Its valve, of mucous membrane; *g*, Neck of the uterus; *g' g'*, Body of uterus opened; *h*, Right cornu opened; *i*, Fallopian tube; *k*, Ovary.

the peritoneum, covers the body and horns, forms the *broad*, or *suspensory ligaments*, and is reflected on to the bladder, rectum, vagina, and walls of the pelvic cavity, forming the ligaments. The *broad ligaments* pass from either side of the uterus to the pelvic walls, forming a septum across, and dividing the pelvis into two portions, the *inferior* containing the bladder, vagina, and urethra; the *superior* the rectum. Two peritoneal folds, the *superior*, or *recto-uterine ligament*, unite the uterus to the



rectum; and two pass from the uterus to the bladder, the *inferior*, or *vesico-uterine* ligament. Two fibrous cords, the *round* ligaments, arise from the upper angle of the uterus, proceed to the internal abdominal rings through the inguinal canals, and are lost in front of the symphysis pubis. The arteries are the uterine and utero-ovarian, with corresponding veins. After once bearing young these vessels are very large. The nerves are from the mesenteric and pelvic plexus.

The muscular coat consists of two layers analogous to those of the intestine, longitudinal and transverse. The external layer is thin, and encircles the anterior part of the body, cornua, and Fallopian tubes, sending fasciculi between the folds of the broad ligament. The muscular coat is better developed in the gravid uterus. The mucous coat is thin, smooth, and closely adherent to the muscular one, more especially in the body; it is pale reddish-white, clothed with ciliated epithelium, and furnished with numerous mucous follicles and glands peculiar to the organ—the *utricular glands*. A network of rugæ exists, termed the *arbor vitæ uterinus*. The uterus has three openings, one, the *ostium uterinum*, at the end of each horn, for the Fallopian tube, and one, the *ostium internum*, leading through the cervix, about which the mucous glands are vesicular and prominent, and known as the *Nabothian Glands* (*Ovuli Nabothi*).

## VAGINA.

The vagina is the cylindroid membranous canal leading from the vulva to the uterus, and also situated between the rectum and the bladder. It consists of two membranes; an inner mucous and an outer muscular, invested by a reflection of the pelvic fascia. Constricted at its origin, the vagina widens at its inner portion, and surrounds the neck of the uterus. The mucous coat, clothed with numerous papillæ, and studded with follicles, presents a number of longitudinal rugæ, which abound at the constricted opening, and which facilitate dilatation during parturition. Blood is supplied by the internal pudic artery; nerves by the pelvic plexus.

The vagina is the chief female organ of coition.

## VULVA.

This, the external orifice of the urino-genital system, is situated in the perineal region, immediately below the anus;

the opening appears as a long verticle ovoid slit, the *fissura magna*, presenting two lips and two commissures. The *labia*, or lips, are formed by an external soft unctuous layer of skin, destitute of hair, but rich in pigment, and an inner one of mucous membrane; between these is a quantity of fat and areolar tissue, most abundant in the young animal, and the erectile *vaginal bulb*, divided into two branches, which leave the clitoris, and pass along the sides of the vulva, terminating in round lobes; this structure is filled with blood during copulation, rendering co-aptation very complete. The *superior commissure* is very acute, and reaches almost to the anus; the space between the two is the *perineum*. The *inferior commissure* is obtuse and rounded.

In the interior of the vulva, and in a depression on its floor called the *fossa navicularis*, lies the *clitoris*, which originates by two crura from the ischial arch, and is attached to the symphysis by a suspensory ligament. The clitoris passes backwards, jutting towards the inferior commissure, its free extremity being lodged in the fossa navicularis, and enveloped by a mucous covering, the *prepuce of the clitoris*. The structure of the clitoris resembles that of the corpora cavernosa of the male; and, having a fibrous capsule, erectile tissue, and cavernous vessels, it becomes erect during copulation.

The external orifice of the urethra, the meatus urinarius, opens on the inferior surface of the vulva, about four inches from its external opening; it is larger than the male opening, and surmounted by a fold of mucous membrane, which acts as a valve. The *hymen* is a thin semilunar fold of mucous membrane, which separates, usually imperfectly, the vulva from the vagina, lying immediately before the meatus; it is ruptured during the first act of copulation, which gives rise to a number of small round elevations surrounding the entrance of the vagina, called the *carunculæ myrtiformes*.

The mucous membrane lining the vulva is pale rose-coloured, and covered with mucous follicles, which are more numerous near the opening of the urethra, and sebaceous glands, the *glandula odorifera*, which secrete an odorous unctuous substance, and are found for the most part under the prepuce of the clitoris and on the labia.

## MUSCLES OF THE FEMALE GENITAL SYSTEM.

*Erectores clitoridis.*—A pair of very small muscles analogous to the *erectores penis* of the male. They arise from the ischial arch, and are attached to and closely associated with the crura of the clitoris.

*Constrictor vulvæ anterior.*—This is considered the homologue of Wilson's muscle; its fibres are arciform, and embrace the posterior part of the vagina, below and at the sides, its aponeurosis being reflected on the sides of the rectum.

*Constrictor vulvæ posterior.*—Included in the labia of the vulva, and disposed as a sphincter, this muscle is attached to the skin by cellular tissue. It is attached to the sphincter ani above, and also to the sacrum by the suspensory ligaments. It is the analogue of the sphincter vaginæ in the human subject.

*Suspensory ligaments.*—Attached to the sacrum above, and uniting under the rectum, these structures resemble the retractor penis of the male. They again separate and become lost laterally in the posterior constrictor muscle.

From the above descriptions it will be apparent that in the male animal the female generative organs are indicated, as are the male organs in the female. Thus in the male the sinus pocularis represents an undeveloped uterus; and in the female the clitoris a rudimentary penis. This points to the fact that in early foetal life there is no distinction of sex, each animal having rudimentary male and female generative organs; only one of these becomes developed, thus determining the sex of the animal. Should both systems of organs in the same animal become more or less developed, but neither of them perfectly so, the animal is said to be *hermaphrodite*.

## MAMMARY GLANDS.

The *mammæ*, or mammary glands, are characteristic of the highest class of the animal kingdom—the *mammalia*. They are compound racemose glands, which secrete milk for the nourishment of the recently-born animal. In the young female, as in the male, they are rudimentary, becoming developed in the former at puberty, or when the female is fit for reproduction. During utero-gestation they gradually enlarge, and at parturi-

tion reach their greatest activity. When the period of suckling terminates, they shrink, returning almost to their original state.

In the mare, these glands are two in number, and placed, side by side, in the inguinal region, between the thighs and under the pubis, having the same relative position in the female as the scrotum has in the male. In full activity, they present two hemispherical masses, separated by a shallow fissure, each half presenting in its centre a nipple, *teat*, or mammary process, pierced at its free extremity by numerous orifices for the passage of the milk. The mammæ are supported by an outer covering, a continuation of the common integument, and by numerous short elastic plates, similar to the suspensory ligament of the male sheath, derived from the elastic abdominal fascia. The outer tunic of integument is soft, black, and covered with fine downy hair, which disappears towards the teat. Below this is a thin elastic covering which blends with the elastic plates descending from the abdominal fascia. Besides supporting the gland, it sends into its substance several prolongations, which form partitions between the principal lobes.

The interior of a mamma is made up of yellow glandular tissue, consisting of numerous lobes, united by cellular tissue. Each of these is again made up of small lobules, composed of minute ducts and numerous small cells, or *acini*, in which the milk is secreted and conveyed to the ducts, which unite to form a common excretory duct for each lobe—the *ductus lactiferus*, or *galactophorus*. These increase in size, and by repeated union converge to the centre of the gland, where they terminate in dilated cavities—the *lactiferous sinuses*, which vary in number, and freely communicate with each other. From these proceed a number of distinct canals, which run in a straight course to the free extremity of the teat, where they terminate in a cribriform manner, and by contracted orifices. The internal surface of this excretory apparatus is lined by a fine mucous membrane, clothed with columnar epithelium.

The mucous membrane of the ducts is surrounded by a layer of muscular fibre, which acts involuntarily as a sphincter, and retains the milk, being assisted by a thin layer surrounding the free end of the teat. The teat is covered with skin, devoid of hair, and at its base is encircled by certain glands, secreting a sebaceous lubricating matter which protects the teat during the suckling of the young, and prevents plugging of the orifices by

coagulation of the milk. The mammæ are supplied with blood by the mammary arteries, vessels corresponding to the external pudics of the male.

---

## COMPARATIVE SPLANCHNOLOGY.

ALTHOUGH the viscera of the domestic animals are constructed on the same general plan, still there are many important deviations in form and arrangement from those of the typical animal. The more important of these features we now proceed briefly to consider.

### RUMINANTIA.

#### DIGESTIVE SYSTEM.

The *lips* of the ox are thick and rigid, and having very little mobility, are only indirectly prehensile. A large part of the outer centre of the upper lip is devoid of hair, prolonged between the nasal openings, and constitutes the muzzle. It varies in colour with the animal, but in health is always moist. It is covered with papillæ and the orifices of the ducts of subcutaneous glands, which moisten the part with their secretion. The lips of the smaller ruminants are thin, and, being very mobile, are agents of prehension; the superior one is divided in front by a median fissure.

The *cheeks* of ruminants present on their inner surface, between the commissure of the lip and the first molar tooth, numerous large, long, conical papillæ which point backwards. Posteriorly a row of the same runs along the level of the upper molars. Small round papillæ are also present.

The *hard palate* is large, its posterior third being smooth; the anterior two-thirds are covered with transverse bars, which do not form arches, but are denticulated, the ridges projecting backwards. Behind the pad of cartilage which replaces the upper incisors there is a mark resembling a letter T in the middle line, with the normal directed backwards, and at each extremity of the transverse line is the buccal opening of Jacobson's canal.

The *soft palate* is not so complete and pendulous as in the horse. The isthmus faucium is always open, thus permitting the animal to breathe through the mouth, and allowing the upward passage of food. Some authorities hold that the tonsils are present in ruminants.

The *tongue* of the ox being prehensile, its muscles are well developed, and it possesses great mobility. It is much rougher, shorter, and thicker than in the horse, and pointed at the tip. The papillæ are better developed, the filiform being very large and numerous near the apex. The circumvallatæ are arranged in two rows, one on each side of the base, and number about ten on either side. Between the lower border of the tongue and sides of the lower dental arch is a row of conical papillæ, similar to those on the cheek. The tongue of the smaller ruminants is very delicate.

The *parotid gland* is small and red; the duct follows a similar course to that of the horse, but enters the mouth much more posteriorly; in small ruminants it crosses the masseter externally. The *submaxillary gland* is very large and yellow in colour. The canal of Wharton opens close to the incisors, the papillæ being lodged in an elliptical fossa. The *sublingual gland* is divided into two portions, the posterior opening by a single duct (the duct of *Bartholini*) close behind Wharton's, the anterior by a row of ducts as in the horse.

The *dentition* of the ruminant is characteristic. With the exception of the camel and llama, which are not usually domesticated in Europe, the ruminant has neither incisor nor canine teeth in the upper jaw, the former being replaced by a thick cartilaginous pad, covered by the mucous membrane of the hard palate, forming a *point d'appui* for the lower incisors to press against in cropping grass, &c. In the lower jaw there are six incisor teeth, and two canines; the latter closely resembling the former in shape, and being situated immediately behind them, indeed it is customary to describe the incisors as eight in number; it signifies little which view is taken. These teeth are chisel-shaped, rather like the human incisors, but with a curved contour, convex anteriorly, and concave behind, the whole of the crown being covered with enamel; the neck is small and constricted, and the teeth are arranged in the jaw in an almost horizontal position, forming a radiating, or fan-like series. They are not firmly fixed in the alveoli, but have a certain degree of mobility, thus preventing injury to the cartilaginous pad above. The *molars* have compound tables like those of the horse, but the teeth are much smaller and more cuboid in shape.

The dental formula of the domesticated ruminant is as follows :

$$i. \frac{0-0}{3-3}, c. \frac{0-0}{1-1}, p.m. \frac{3-3}{3-3}, m. \frac{3-3}{3-3} = 32$$

That of the camel is :—

$$i. \frac{1-1}{3-3}, c. \frac{1-1}{1-1}, p.m. \frac{3-3}{2-2}, m. \frac{3-3}{3-3} = 34.$$

(THOMES.)

The *pharynx* is large, but the muscles composing it are less distinctly separable. The *œsophagus* is well developed, and its muscular walls are red throughout. It joins the stomach by expanding, so that its termination is funnel-shaped. The muscular fibres induce both a downward or peristaltic, and an upward or anti-peristaltic motion.

#### STOMACH.

The stomach of the ruminant is a very complex organ, consisting of four compartments, which vary in size, form, and in the disposition of their mucous coats. The first compartment is the *rumen*, or paunch; the second the *reticulum*, or honeycomb; the third the *omasum*, *psalterium*, or manyplies; the fourth the *abomasum*, or true digestive cavity. The first three have little to do with the essential process of digestion, being principally concerned in macerating and preparing the food, and are analogous to the cardiac portion of the stomach of the horse. The *rumen* in the adult is very large, occupying about three-fourths of the abdomen. It is situated

on the left side, inclining obliquely downwards from left to right, and elongated from before backwards. The surface is smooth, and divided into two lateral regions or hemispheres by slight grooves, which deepen towards the extremities. The sides are smooth, thick, and rounded; the extremities are divided by a deep fissure into two lobes, the anterior being concealed. These two fissures, continued by the grooves, divide the rumen into a right and

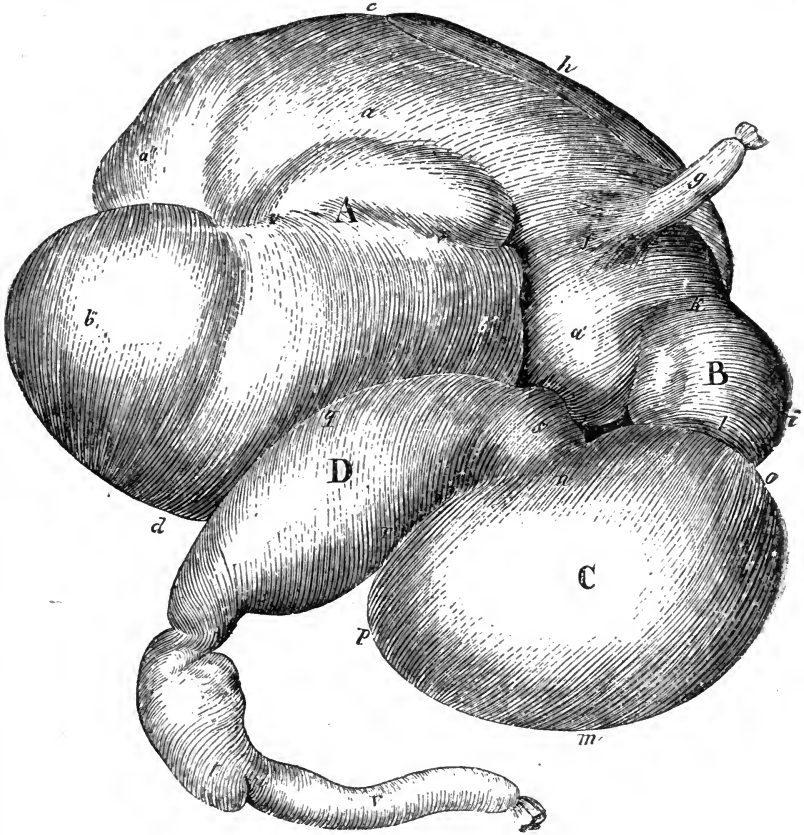


FIG. 129.

Stomach of an Ox inflated—viewed from the right side. A, Rumen; *a*, Left sac; *a'*, Its anterior extremity; *a''*, Left conical sac; *b*, Right sac; *b'*, Its anterior extremity; *b''*, Right conical sac; *c*, Superior border of rumen; *d*, Its inferior border; *e e*, Longitudinal groove; *g*, Œsophagus; *j*, Its dilated extremity entering rumen; *h*, Spleen; B, Reticulum; *i*, Its greater curvature; *k*, Its left extremity; *l*, Its right extremity; C, Psalterium; *m*, Its greater curvature; *n*, Its lesser curvature; *o*, Its anterior extremity; *p*, Its posterior extremity; D, Abomasum; *q*, Its greater curvature; *r*, Its lesser curvature; *s*, Its anterior extremity; *t*, Its posterior extremity; *u*, Pylorus; *r*, Duodenum.

left sac, which is most manifest in the anterior. The right sac is the shortest, being covered in the major part by the peritoneal omentum; the left is prolonged beyond, and at either extremity curved on the right, receiving superiorly the insertion of the œsophagus, and is also continuous anteriorly with

the second compartment. The anterior extremity is bounded by the second and third compartments, and lies near the diaphragm; the posterior occupies the entrance of the pelvic cavity, where it contacts the urino-genital organs. In the female, the uterus is prolonged over this surface.

The superior surface is related with the intestines; the inferior rests upon the abdominal floor; the left side, to which the spleen is united, is in contact with, and attached by cellular tissue to the abdominal wall in the lumbar region. The right side is related with the fourth compartment in the right hypochondriac and lumbar regions, and is surrounded by convolutions of the intestines.

The interior of the rumen is incompletely divided into four sacs by fleshy pillars. The principal ones are the anterior and posterior, which correspond to the anterior and posterior fissures; processes from these run transversely, corresponding to constrictions on the outer surface; thus anteriorly there are formed the right and left sacs; posteriorly the right and left conical sacs.

The *rumen*, like the other compartments, consists of three coats; an external

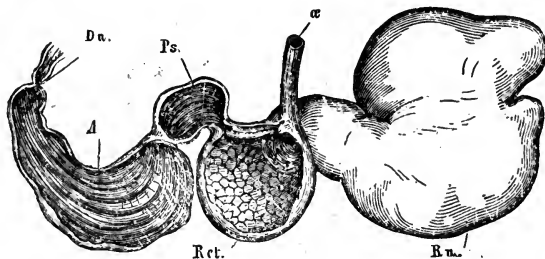


FIG. 130.

Stomach of a Sheep, seen from the left side—the last three compartments are laid open and reflected forwards. *œ*, Oesophagus; *Ru.*, Rumen; *Ret.*, Reticulum; *Ps.*, Psalterium; *A.*, Abomasum; *Du.*, Duodenum. The oesophageal canal is seen traversing the lesser curvature of the reticulum.

serous, a continuation of the peritoneum, which envelops the entire organ, excepting where it contacts the lumbar region; the thick muscular middle coat is an extension from the oesophageal fibres; the internal mucous coat is cuticular, papillated and covered by thick epithelium. The papillæ are foliate or leaf-like, conical, and fungiform, the first variety being by far the most numerous. The rumen has two openings, both of which enter the anterior extremity of the left sac: the superior, or oesophageal, which opening is prolonged over the small curvature of the second compartment by the oesophageal canal, shortly to be described; the inferior, large and communicating with the reticulum, is circumscribed laterally and below by the free border of a kind of valve, formed by the walls of the rumen, along with the cells of the second compartment.

The second compartment, or *reticulum*, the smallest of the four, is slightly bent upon itself, and placed transversely between the posterior surface of the diaphragm and the anterior extremity of the left sac of the rumen. The anterior surface adheres to the centre of the diaphragm by cellular tissue; the posterior



is united to the anterior extremity of the rumen. The inferior convex curvature occupies the epigastric region; the superior concave one is partially related with the small curvature of the third compartment. The left extremity is separated from the rumen by a fissure, in which runs the inferior artery of the reticulum. The right forms a round *cul-de-sac*, and is related with the base of the fourth compartment. The internal surface of the reticulum is divided into polyhedral alveoli or cells, by folds of the mucous membrane. These folds are studded with papillæ, and serrated at their edges; in the alveoli are secondary ones, where mucous follicles open. The reticulum communicates with the left sac of the rumen, the œsophagus, and third compartment. The communication with the two latter is by the œsophageal canal, a continuation of the œsophagus, which commences at the cardiac orifice, passes along the roof of the reticulum, and enters the third compartment by a circular opening. Its sides consist of two movable lips, the *œsophageal pillars*, which are continuous with the muscular wall of the œsophagus, and are attached by one border to the superior wall of the reticulum, the other being free. The latter get gradually thicker and more projecting as they reach the opening of the third compartment. At the entrance into the rumen is a sort of valve, formed by the attachment of the pillars to its walls. The mucous membrane of this

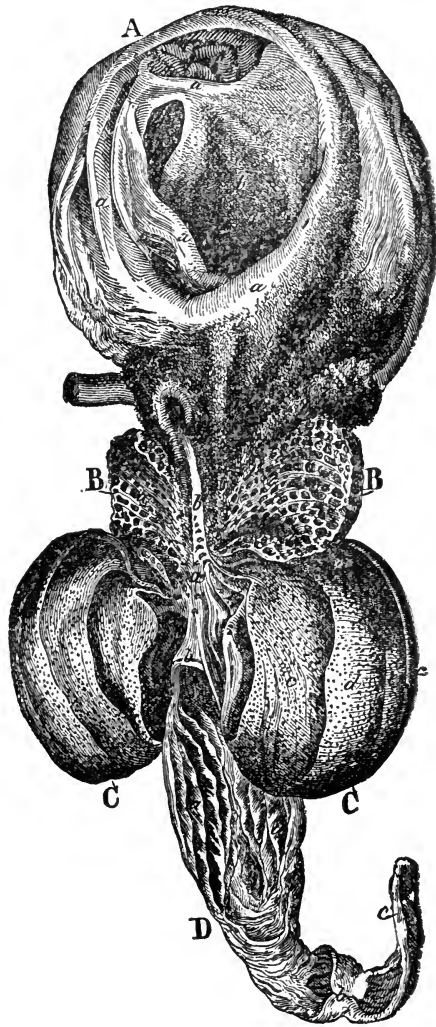


FIG. 131.

Compartments of a Ruminant Stomach, laid open. *A*, Rumen—*a, a, a*, Pillars; *b, b*, Papillæ; *c*, Œsophageal orifice. *B*, Reticulum—*a, a*, Alveoli; *b*, Œsophageal canal. *C*, Psalterium—*a*, Hooked papillæ; *b*, Valve at orifice leading to abomasum; *c, d, e, f*, Leaves graduated from large to small. *D*, Abomasum—*a, a*, Folds of mucous membrane; *b*, Pyloric orifice; *c*, Duodenum.

canal is wrinkled on its free surface, but on the interior resembles that of the œsophagus, being white, and longitudinally folded. At its opening into the third compartment are a number of conical papillæ. Transverse and longitudinal muscular fibres control the canal; the longitudinal fibres, by drawing the lips of the pillars together, form a channel leading from the œsophagus into the third compartment, thus effectually closing the openings into the rumen and reticulum.

The third compartment, *psalterium* or *omasum*, is situated at the anterior extremity of the right sac of the rumen. When full, it is ovoid, slightly curved, and depressed from above downwards. The anterior surface is in relation with and attached to the diaphragm by cellular tissue, while the posterior is related with the rumen. The greater or convex curvature is turned upwards, and fixed to the posterior fissure of the liver by a fold of peritoneum, which is continued on to the lesser curvature of the fourth compartment, and thence to the duodenum. The lesser curvature looks downwards, and is related with the reticulum. The left extremity is constricted, forming the neck, by which it communicates with the reticulum. The right extremity is continuous with the base of the fourth compartment, from which it is separated by a constriction similar to, but less marked than, the neck.

The interior presents two openings, one of which communicates with the second, the other with the fourth compartment. It is filled with leaves or folds of mucous membrane, which follow the long axis of the organ. They are unequally developed, and attached by one border to the great curvature of the cavity; while the other, free and concave, is turned towards the lesser curvature. The cavity being ovoid, the central leaves are the largest; and between each pair of large we have intermediate and small leaves, which extend a limited distance only. They consist of an inner framework of muscular fibres, clothed with mucous membrane, and studded with papillæ, some of which are small, others large and bent, the latter retaining crude portions of food, for further trituration and maceration, while fluid and finer pabulum pass directly through into the fourth compartment. The papillæ at the entrance of the œsophageal canal are large and hooked; perhaps their use is to retain the alimentary material in the cavity, to which end the latter is also furnished with a small valve at the orifice leading into the abomasum.

The fourth, the true digestive compartment, or *abomasum*, is curved upon itself, elongated from before backwards, and continuous with the psalterium about the right sac of the rumen. The right side is in the epigastric region, and related with the diaphragm, while the left contacts the rumen. The greater curvature is turned backwards, receiving the insertion of the great omentum; the lesser is directed upwards, and is attached by serous membrane to the greater curvature of the psalterium. The base is in contact with the *cul-de-sac* of the second, and separated from the third compartment by a constriction. The point, directed upwards and backwards, is continuous with the duodenum, forming the pylorus, which is constricted by a muscular ring. The interior resembles the villous portion of the stomach of the horse, and the mucous membrane is thrown into oblique folds, crossing from end to end in a spiral direction. The serous coat is a continuation of the great omentum, the

muscular resembles that of the horse, while the mucous is covered by a thin layer of epithelium, and studded with glands and follicles, which secrete gastric juice.

The stomach thus described may be termed the *typical* ruminant stomach, as it exists in the cavicornia, and in most deer (constituting the group *Cetylaphora* of Professor Huxley). In the camel there are certain compartments or diverticula in the rumen, which serve to store up a quantity of water. The psalterium is devoid of leaves, and is not well developed. In one group of deer, *Tragulius*, the psalterium may be said to be absent, being represented only by a short tube joining the reticulum and abomasum; in this group the cesophagus marks the line of separation between the rumen and the reticulum.

By most of the best authorities the process of rumination is believed to be effected somewhat as follows:—The food having been masticated and swallowed, falls into the first compartment, where it is tossed about by

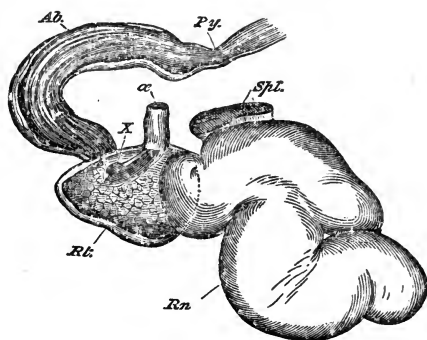


FIG. 132.

Stomach of a Musk Deer, left aspect—the last three compartments opened and reflected forwards. *Rn*, Rumen; *Rt*, Reticulum; *Ab*, Abomasum; *Py*, Pylorus;  $\alpha$ , Cesophagus; *X*, Opening of the tube which represents the psalterium; *Spl*, Spleen.

muscular action and saturated with fluid; a portion is thrown up through the valvular opening into the reticulum, and gains a further supply of mucous fluid, and the finer are separated from the coarser particles; the former proceed to the psalterium; the latter, by the muscular contraction of the reticulum, the relaxation of the cesophageal pillars, and anti-peristaltic action of the cesophageal walls, is returned to the mouth to be remasticated, and once more swallowed; a portion now passes into the rumen, the remainder down the cesophageal canal to the psalterium, whence liquids flow onwards to the abomasum, while solids are drawn between the leaves of the psalterium to be further prepared.

#### THE INTESTINES.

The *small intestine* of the ox differs little from that of the horse, except that it is smaller in calibre, but on an average double the length. Peyer's patches are larger, but not so numerous.




FIG. 133.

Mesentery and intestines of an Ox.—1 1, Duodenum. 2 2 2, Small intestines. 3, Cæcum.  
4 4, Colon. 5, Rectum. 6 6, Great mesentery.

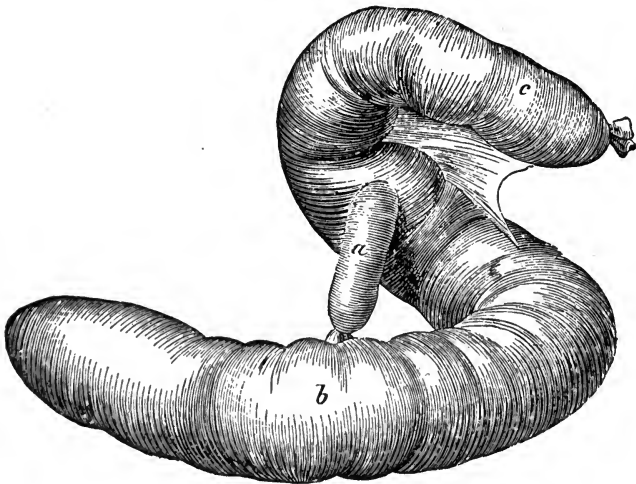


FIG. 134.

Cæcum and origin of colon of an Ox—inflated. a, Terminal portion of the ileum.  
b, Cæcum; c, Origin of colon.

The *cæcum* is devoid of longitudinal bands, and terminally of transverse furrows. Its blind extremity is blunt, rounded, and directed backwards, and it floats free in the abdomen. The other extremity, having received the insertion of the ileum, is continuous with the *colon*, which likewise wants bands and furrows. The colon soon becomes greatly constricted; then, preserving about the same diameter throughout, it is arranged in an irregularly elliptical coil between the folds of the mesentery.

Thus there is no distinct separation between the great and floating colon as in the horse. The total length of the large intestine in the ox, from the *cæcum* to the rectum, is about 36 feet, but its capacity is much less than it is in the horse. Apart from the question of measurement, these remarks will apply to ruminants generally.

#### ACCESSORY ORGANS OF DIGESTION.

The *liver* of the ox, situated in the right hypochondriac region is very thick,

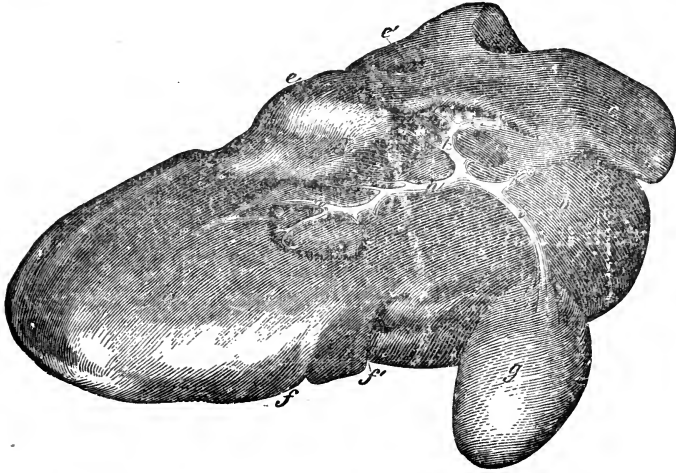


FIG. 135.

Posterior view of the liver of an Ox. *a*, Left lobe; *b*, Right lobe; *c*, Spigelian lobe; *d*, Quadrate lobe; *e*, Superior border; *e'*, Anterior fissure; *f*, Inferior border; *f'*, Notch for the umbilical vein; *g*, Gall bladder; *h h h*, Biliary tubes; *i*, Cystic duct; *k*, Ductus choledochus.

and has two large lobes, right and left, with a Spigelian lobe, and a small quadrate lobe situated supero-posteriorly. It is provided with a pear-shaped gall bladder attached above, and lying upon its posterior surface. The gall bladder is furnished with three coats, serous, muscular, and mucous, and it is continuous with the biliary ducts. The cystic duct extends from the gall bladder almost to the transverse fissure, where it joins the ductus choledochus; in the ox the latter enters the duodenum singly, in advance of the pancreatic duct, being guarded at its orifice by a valve-like doubling of the mucous membrane.

In the smaller ruminants there is formed a ductus communis. The camel has no gall bladder.

The *pancreas* presents no comparative feature of interest, excepting that its duct forms in the ox no ductus communis, but enters the duodenum separately. The *spleen* is of one thickness throughout, with two rounded extremities; it adheres to the left side of the rumen and the diaphragm, but is not supported by the great omentum.

#### RESPIRATORY SYSTEM.

The *nostrils* are narrow, and are capable of little dilatation compared with those of the horse. The nasal fossæ differ chiefly in there being an additional third turbinal, the olfactory fossa, and in the arrangement of the *frontal sinuses*, which extend over the cranium, and are continuous with the cavities in the horn cores (see p. 100). The nasal chambers communicate at the posterior nares below the inferior border of the vomer, and each of them contains a structure called the *canal of Jacobson*, communicating with the mouth. It commences in the floor of the nasal chamber, at the base of the septum, on each side of the vomer, proceeds forwards, and terminates behind the pad in front of the palate. It contains a number of mucous follicles; its use is unknown. The *larynx* is simpler in structure, the lateral ventricles and true vocal cords being only slightly developed. The *trachea* presents no important variation. We may note the presence of a third bronchus, which passes to the right lung to supply a lobe which is wanting in the horse.

The thoracic cavity is relatively smaller in the ruminant, and the pleuræ present a very important deviation from the arrangement found in the solipede—viz., the posterior mediastinum is *imperforate* and strong, completely separating one pleural sac from the other. This arrangement exists in all the domesticated mammals but the solipede.

The left *lung* is divided into two lobes, the right into four, the anterior one recurring over and almost covering the front of the heart. The interlobular cellular tissue is exceedingly thick, the separation between the lobules being distinctly visible. This arrangement explains perfectly the special nature of pneumonic lesions in the larger ruminants.

#### URINARY SYSTEM.

In the comparative anatomy of the kidney, the chief variation from the simple type consists in the gland being more or less divided or lobulated. In some animals the kidney is so lobulated as almost to resemble a bunch of grapes, each lobule having its own blood-vessels and excretory duct. This subdivision is constant in all animals in early foetal life; but in the majority, the parietes of the lobules coalesce, and the organ becomes a single mass. The kidney of the ox is intermediate in form, the medullary or inner substance of the organ being united, while the cortical or outer substance is divided into lobes. The pelvis consists of a principal cavity, with a diverticulum or calyx for each lobule, the uriniferous tubes of each calyx opening on a papilla. The general form of the gland is ovoid and elongated; in the smaller rumi-

nants the kidney is simple in form, resembling in a general sense that of the horse.

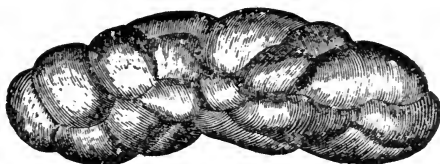


FIG. 136.  
Lobulated Kidney of an Ox.

The *bladder* calls for little remark ; it is larger, and its peritoneal covering extends further backwards than in the horse.

### GENITAL SYSTEM.

#### MALE ORGANS.

The *testicle* is ovoid and well developed, its long axis being nearly vertical ; the mediastinum is very strong. The *epididymis* presents a well-marked globus major ; the globus minor gives off inferiorly a free projection, which doubles upon itself and leads to the vas deferens ; the bulbous portion of the latter joins its fellow at the neck of the bladder, forming the *common deferent canal*, which opens by two orifices into the urethra. The *vesiculæ seminales* are large, lobulated, yellow in colour, and essentially glandular in structure ; they have been termed the lateral prostates, and they discharge into the common deferent canal. The *urethra* gradually diminishes in calibre from its origin ; its most prominent feature is that just before the pubis it describes a double curve on itself, something like a letter S. The *prostate gland* is small, but it extends posteriorly under Wilson's muscle ; Cowper's glands are wanting, according to some authorities, while others, Leyh among the number, describe them as being present, though small.

The penis of the ruminant is long and thin, and projects far under the abdomen. Like the urethra, it is bent upon itself, in the form of the letter S, a little anterior to the bulb, the inferior curvature being forwards, the superior backwards. About the level of these, the suspensory ligaments join the penis, and extend to its extremity. The glans is small and attenuated, the canal of the urethra ending in front in a narrow whip-like process of the corpus spongiosum, which is covered by a rosy, papillated, and sensitive integument. The sheath extends much farther forwards than in the horse, and presents at its opening a number of long stiff hairs, the prepuce being prolonged as an elastic sheath. It is furnished with four thin muscles—two anterior and two posterior. The *anterior* are *protractors*, restoring the prepuce to its normal position ; the *posterior*, or *retractors*, draw the sheath backwards during the erection of the penis. During the erection, the curves in the penis are effaced, but when quiescent, and drawn into the sheath by the retractor muscles, the curvatures are re-formed.

The urethra is completely enveloped by the fibrous sheath of the corpus cavernosum ; the latter is little developed.

## FEMALE ORGANS.

In the female ruminant the *ovaries* are comparatively small. The *uterus* presents generally the typical arrangement; its cornua are slightly twisted, and the ligaments are large; the fundus is short and narrow.

The mucous membrane of the uterus presents a number of rounded vascular processes, which exhibit eminences and depressions; these are termed the *maternal cotyledons*, and their function is a foetal one. During gestation the lateral walls of the *vagina* are transversed by a mucous canal, which opens into the vulva on either side of the meatus urinarius; these are the *canals of Gärtner*, but their use is unknown; they are not found in the smaller ruminants.

The labia of the *vulva* are thick; its inferior commissure is narrow and furnished with a few hairs. Inside the vulval cavity we have to note the

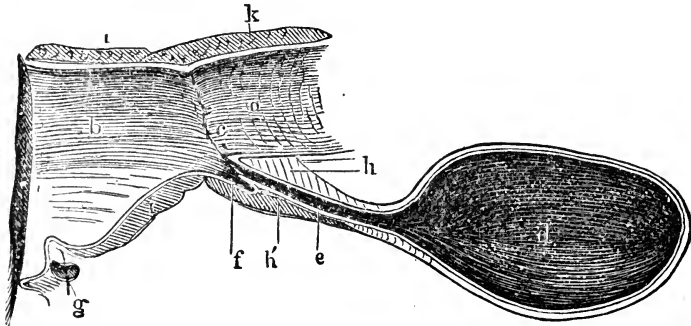


FIG. 137.

Longitudinal vertical section through the vagina and bladder of a cow. *a*, Vagina; *b*, Vulva; *c*, Openings of Gärtner's canals; *d*, Bladder; *e*, Urethra; *f*, Urethral diverticulum; *g*, Clitoris and fossa navicularis; *h* *h'* *k*, Constrictors; *i* *i*, Constrictor vaginae.

peculiar *vulvo-vaginal* glands; also a small blind cavity or diverticulum in the wall of the urethra, covered by a fold of mucous membrane.

The mammary glands constitute an organ termed the *udder*, which is composed of two symmetrical halves, placed one against the other. Each half is again divided into two distinct glands, each with its own teat, so that the udder consists of four mammæ and four teats; behind this there may be two small rudimentary teats. In the centre of each quarter, just at the base of the teat, is a large galactopherous *sinus*, the general receptacle of all the lactiferous conduits. From this sinus, which is sometimes large enough to contain a quart, proceeds down the centre of the teat one definite excretory canal.

In the small ruminants there are two mammæ and two teats, constructed like those of the cow.



OMNIVORA.

DIGESTIVE SYSTEM.

In the hog the *mouth* is large, the labial fissures extending far backwards; the upper lip is confounded with the snout, while the under one is short and pointed. The canal of Jacobson opens towards the front of the hard palate by a small orifice. The tongue and velum palati are like those of the smaller ruminants, but the filiform papillæ of the former are more developed.

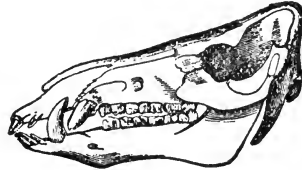


FIG. 138.

Skull of a Hog—showing the teeth.

The *parotid* and *submaxillary* glands have relative proportions similar to those of the ruminant. There are two *sublingual glands* on either side; one long and straight, situated near the angle of the jaw, and terminating in a single duct, which opens near that of the submaxillary; the other, flat and four-sided, is the true sublingual, and lies in front of the former, opening along the lower dental arch by eight or ten ducts.

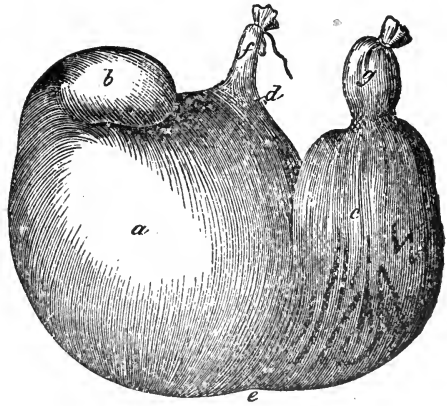


FIG. 139.

Stomach of a Hog—inflated. *a*, Cardiac portion; *b*, Its accessory *cul-de-sac*; *c*, Pyloric portion; *d*, Lesser curvature; *e*, Greater curvature; *f*, Œsophagus; *g*, Pyloric orifice.

The hog is one of the few existing animals which possesses what Professor Owen

regards as the typical mammalian number of *teeth*; its permanent dental formula is this :—

$$i. \frac{3-3}{3-3}, \quad c. \frac{1-1}{1-1}, \quad p.m. \frac{3-3}{3-3}, \quad m. \frac{4-4}{4-4} = 44.$$

The *incisors* differ from each other in a remarkable degree; the central and lateral ones in the upper jaw resemble the corresponding ones in the horse, having cavities in their tables, while the upper corner incisors are isolated, and small in proportion to the other four. The central and lateral incisors of the lower jaw are long, nearly straight, projecting forwards, and somewhat resembling the incisors of the rodent; the lower corner incisors are also isolated, but smaller than those of the upper jaw. The *canine* teeth are well developed,

especially in the male, having the character of tusks; the lower ones are the largest, and curve outwards and upwards; the upper pass outwards and downwards. The tusks continue to grow during the life of the animal.

The *molars* also vary in shape, gradually increasing from the first to the last, which is large and strong; they are intermediate between herbivorous and carnivorous, and somewhat resemble the human teeth. The first, which is small, and corresponds to the wolf-tooth of the horse, is a permanent or true molar, the next three are the premolars, and the remaining three, true molars.

The *stomach* is simple and somewhat capacious; it consists, as in the horse, of two divisions, cardiac and pyloric, the latter being the smaller, but the division externally is marked by a much more distinct constriction. At the upper and left portion of the cardiac half is a small diverticulum or *cul-de-sac*. The *oesophagus* is infundibuliform at its termination. The mucous membrane, for

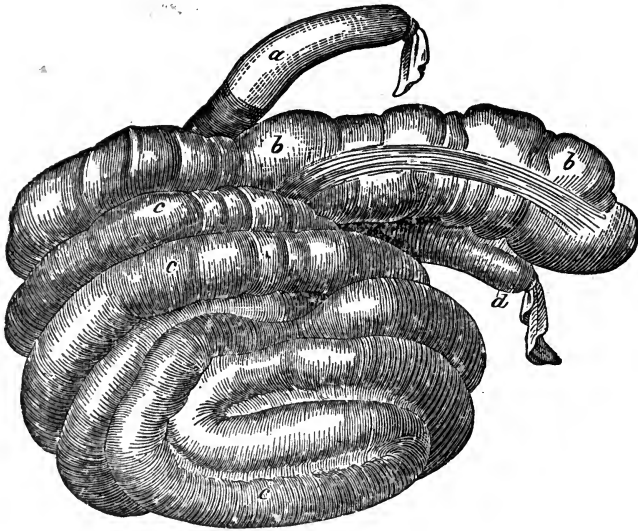


FIG. 140.

Cæcum and colon of a Hog—inflated. *a*, Ileum; *b b*, Cæcum; *c c c*, Colon; *d*, Rectum.

the most part villous in its structure, forms two folds which extend from the cardiac towards the pyloric orifice, representing undeveloped *oesophageal* pillars and canal.

In the general sense the *intestines* resemble those of the ruminant, but only the posterior part of the colon lies between the folds of the mesentery. A Peyer's patch of enormous size occurs at the terminal portion of the small intestine. The *cæcum* resembles that of the horse in having longitudinal muscular bands, three in number, and transverse constrictions, and that of the ruminant in its shape, and the direct continuity of its canal with that of the colon; the latter is coiled in a similar manner to that of the ruminant.

The *liver* of the hog consists of four chief lobes ; a right and left external, and a right and left internal ; a small quadrate and a Spigelian lobe exist, the

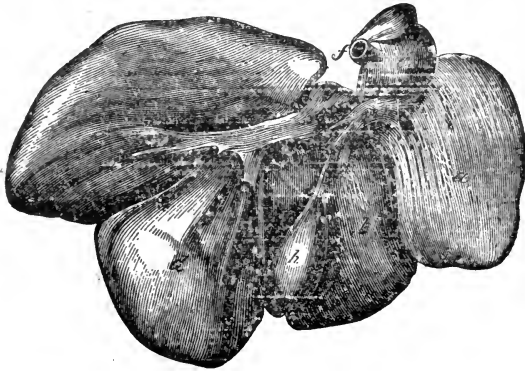

FIG. 141.

Liver of a Hog—posterior view. *a*, Right external lobe ; *b*, Right internal lobe ; *c*, Left external lobe ; *d*, Left internal lobe ; *e*, Spigelian lobe ; *f*, Posterior cava ; *g*, Quadrate lobe ; *h*, Gall bladder ; *i*, Cystic duct ; *k*, Ductus Choledocus.

latter being cleft by a fissure for the posterior vena cava. There is a gall bladder, and the biliary and pancreatic ducts enter the intestine singly.

#### RESPIRATORY SYSTEM.

The anterior extremity of the nose is the *snout*, which is flat anteriorly, and presents on either side the small, round nasal opening. Like the muzzle of the ruminant, it is always damp in health. At the anterior extremity of the septum nasi is the small snout bone, *os rostri*, covered by cartilage which extends round the nasal openings.

The nasal fossæ are long and narrow. The frontal sinuses extend backwards to the parietal bone. The *larynx* is loose and mobile, being attached to the hyoid heel processes by the epiglottis rather than by the thyroid cartilage. The *epiglottis* is very large ; the lateral ventricles are large but shallow. The *trachea* and lungs resemble those of the ruminant, and, as in that animal, there is a third bronchus ; the pleural sacs are separated completely.

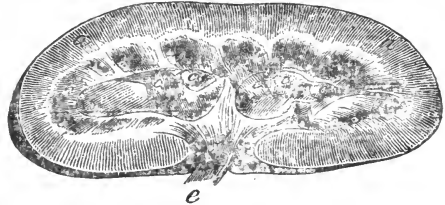


FIG. 142.

Horizontal section of the kidney of a Hog. *a*, Cortical substance ; *b*, Medullary substance ; *c*, Renal papillæ ; *d*, Infundibulum ; *e*, Ureter cut across.

#### URINO-GENITAL SYSTEM.

The *kidney* is large, simple in form, and like that of the horse externally. The uriferous tubes discharge by papillæ and calices. The *ureters* enter the bladder very near together ; the bladder itself is large, projecting considerably into the abdomen.

The *testicle* is large and spherical, being situated in the perineal region, and closely covered by the scrotum. The bulbous portion of the *vas deferens* is less marked, but the *vesiculæ seminales* are large and very glandular in structure, like those of the ruminant, and diverticular internally. There are two *prostate glands*, an anterior and posterior. The latter may be alluded to by Leyh, when he describes Cowper's glands as being very large in this animal.

The *penis* also resembles that of the ruminant; it is long, thin, and provided with a preputial sac, which secretes a peculiar fluid. The sheath has no muscles.

In the *female* the ovary is irregularly lobulated, owing to the Graafian vesicles being prominent. The body of the uterus is short, but the cornua are extremely long, depending among the intestinal convolutions. In the vulva we find the canals of Gärtner as in the ruminant, which apparently originate in the parovarium.

The *mammæ* usually number five or six on each side, arranged in a longitudinal row; each gland has its own teat, which is pierced by several lactiferous canals, but there are no sinuses.

## CARNIVORA.

### DIGESTIVE SYSTEM.

The *lips* of carnivora are thin and mobile, but are not organs of prehension; the upper one is mesially fissured, and projects more or less over the lower; the latter is dentated posteriorly. The upper lip of the felidæ is provided with long, straight, stiff hairs. The *hard palate* is like that of the small ruminant; the *soft palate* is very short; the tonsils are well marked. The buccal membrane often contains much pigmentary matter, giving rise to large patches of a black colour. The *tongue* is thin and very mobile. In cats, the papillæ on the anterior part are numerous and horny, their points being directed backwards, giving the organ a rough surface; in dogs the papillæ are neither prominent nor hard. The *parotid gland* is small, its duct crossing the masseter externally. The *submaxillary gland* is larger than the parotid, and has a small accessory gland anteriorly. The *sublingual gland* is very small in the cat, and wanting in the dog; in the latter is the *orbital gland*, which is placed under the zygoma, and in the inferior part of the orbit; its canals unite to form the *duct of Nuckius*, which opens into the mouth about the last molar tooth.

The dog has forty-two *teeth*, formulated thus:—

$$i. \frac{3-3}{3-3}, c. \frac{1-1}{1-1}, p.m. \frac{4-4}{4-4}, m. \frac{2-2}{3-3} = 42.$$

In the carnivora the crowns of all the teeth are completely covered with enamel. The upper incisors are the strongest; the corner ones are the largest, the central the smallest. They, in common with the other teeth, are remarkable for their brilliant whiteness, and present, when not worn on their tables, three tubercles, a large central and two small lateral ones, the tooth somewhat resembling a trefoil or *fleur-de-lis*. As the animal ages, these projections wear

away. The canines, temporary and permanent, are very large, strong, conical, and curved outwards and backwards; the upper ones are the largest, and have a space between them and the incisors, which lodges the lower canines when the mouth is shut. The molars, twelve in the upper, and fourteen in the lower jaw, terminate in sharp projections; the last upper premolar and the first lower true molar are the largest, and being furnished with cutting edges, they have been termed the sectorial teeth, *dens sectorius* ("dent carnassière" of Cuvier). The other molars are slightly sectorial, and also tuberculate—*i.e.*, provided with processes for crushing the food.

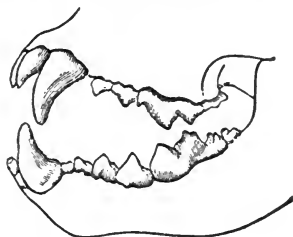


FIG. 143.  
Teeth of a Lion (Carnivora).

The cat has only fourteen molars, eight above and six below; the other teeth are like those of the dog, making up a total of thirty. The formula probably is:—

$$i. \frac{3-3}{3-3}, c. \frac{1-1}{1-1}, p.m. \frac{3-3}{2-2}, m. \frac{1-1}{1-1} = 30.$$

The last upper premolar, and all the lower molar and premolar teeth may be said to be sectorial in this animal.

The œsophagus is very dilatible, and presents a well-marked infundibuliform union with the stomach.

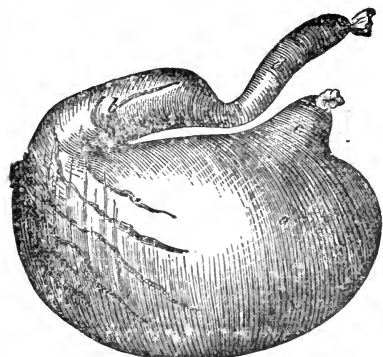


FIG. 144.

Stomach of a Dog—inflated. *a*, Cardiac portion; *b*, Pyloric portion; *c*, Œsophageal orifice; *d*, Duodenum.

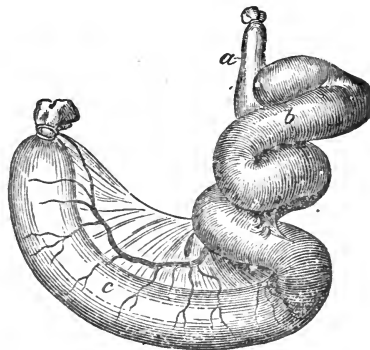


FIG. 145.

Cæcum and colon of a Dog—inflated. *a*, Ileum; *b*, Cæcum; *c*, Colon.

The *stomach* is simple and only slightly curved; it is commonly described as pear-shaped, resembling that of the horse, but with a very small and narrow pyloric portion, terminating in a constricted valve. The mucous membrane is all villous, the natural food of these animals requiring but little preparation.

The *intestines* are short and small. The small intestine is suspended by a mesentery; its walls are thick. The colon is somewhat larger than the small intestines, and divided, as in man, into ascending, transverse, and descending portions; the cæcum is only a small, spiral appendix; there is no floating

colon. Near the anus, the rectum presents on either side the openings of two glandular pouches, where is secreted a strong fœtid matter.

#### ACCESSORY ORGANS OF DIGESTION.

The *liver* is large, and deeply cleft into five lobes, a gall bladder being lodged in the middle lobe. The biliary duct unites with a small duct from the pancreas before entering the duodenum.

The *pancreas* is elongated, running along the concave curvature of the duodenum; its anterior end reaches the lesser curvature of the stomach. There are two ducts, a large one entering the duodenum alone, and a smaller, which joins the bile duct.

The *spleen* is long and irregularly club-shaped. It is suspended in the great omentum, near the left sac of the stomach. Its thick, blunt extremity is placed anteriorly.

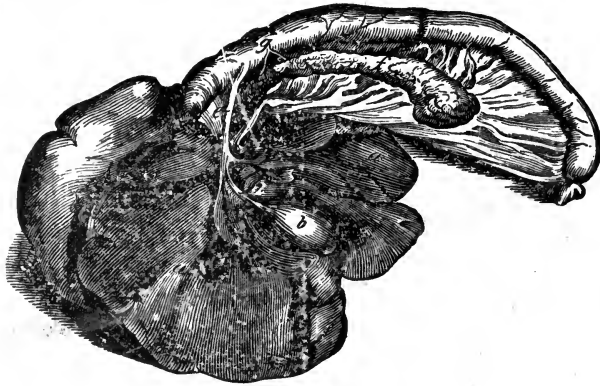


FIG. 146.

Stomach, Liver, Pancreas, and Duodenum of a Dog. *a a*, Liver; *b*, Gall-bladder; *c c*, Biliary Canals; *d*, Cystic Duct; *e*, Ductus Choledocus; *f*, Pancreas; *g*, Pancreatic Ducts.

#### RESPIRATORY SYSTEM.

The *septum nasi* is prolonged on either side, thus taking the place of the alar cartilages, and being continuous with the cartilaginous prolongations of the inferior turbinals. There is only one maxillary sinus on each side. The *thoracic cavity* is usually very large in carnivora. The *lungs* are divided, the left into three, the right into four lobes, by clefts which reach almost to the root of the organ. The heart is completely surrounded by the lungs, not embedded in depressions in them. The pulmonary tissue is very compact, the lobules being small, while the air-cells are well developed.

#### URINARY AND GENITAL SYSTEMS.

The *kidney* is ovoid, but shorter than in the hog; in the cat it is still shorter, being almost round. The pelvis is simple, presenting a single large elongated papilla. The *bladder* is furnished with a very strong muscular coat.

The *testicles* are situated in the perineal region, below the anus. The *vesiculae seminales* are wanting, but the prostate is large, forming a conspicuous bulb around the origin of the urethra. Cowper's glands are wanting in the dog, and are small in the cat. The penis of the dog is long, and terminates in a point. In common with the carnivora generally, a bone is found in the penis; its anterior extremity is fixed in the glans, while the posterior is attached to the corpus cavernosum, occupying all that portion of the organ which is lodged in the sheath. The os penis is long and curved, presenting an inferior gutter, in which the urethra is placed, continuous with the groove of the corpus cavernosum; it favours the introduction of the penis into the vulva. In the dog, the corpus spongiosum forming the glans undergoes a very remarkable degree of tumefaction, which retains the two sexes *in coitu* for a considerable time. The differences in the *female* organs are unimportant. In the cat, the penal bone is not so well developed, and the penis, when relaxed, is turned backwards; when erect, it assumes the same position as in other carnivora. In the female, a small bone exists in the clitoris. The *mammæ* are arranged as in the sow.

## RODENTIA.

The front teeth form one of the leading characteristics of the rabbit. The dental formula is—

$$i. \frac{2-2}{1-1}, c. \frac{0-0}{0-0}, p.m. \frac{3-3}{2-2}, m. \frac{3-3}{3-3} = 28.$$

The upper incisors consist of a large, curved, chisel-shaped pair, which grow from permanent pulps; they are covered with enamel only on their anterior surface, which, wearing more slowly than the rest, gives rise to the chisel-like edge. The second pair of upper incisors are situated immediately behind the first, and are remarkably small. The lower incisors resemble in most respects the large upper ones.

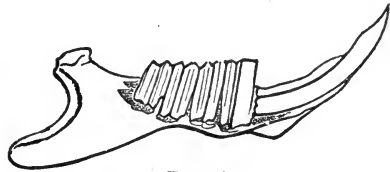


FIG. 147.  
Lateral half of Mandible of a Rabbit, opened to show the arrangement of Rodent Teeth.

There is an enormous *diastema*.

The *molar* and premolar teeth have compound transversely ridged tables, and grow from permanent pulps.

The large papillæ of the tongue appear as two well-marked oval spaces, the *papillæ foliata*, one on each side posteriorly, not upon the dorsum. These contain the minute organs of taste, which occur in the larger papillæ of the horse's tongue.

The *stomach* is simple in structure. The *cæcum* is long, being slender and glandular at its termination. The *liver* and *pancreas* are both large, and the pancreatic duct enters the intestine far behind the biliary duct.

The *testicle* is large, ovoid, sometimes scrotal, sometimes abdominal in situation; in the latter case it is fixed by the gubernaculum testis. The *vas deferens* is so separated from the blood-vessels that the spermatic cord is really double. The vasa discharge into the urethra on each side of the duct of a large uterus masculinus, described by some authorities as a single median vesicula seminalis.

is the possession of two uteri, each uterus opening into the vagina by a distinct orifice; the two are near together posteriorly, and anteriorly they diverge. The vulva has both major and minor labia, and the *clitoris* is large and very prominent.

"The following principal forms of uterus are found in the mammalia :— The *simple uterus* (uterus simplex), in woman and the monkey; the *two-horned uterus* (uterus bicornis), in the mare and ruminant; the *bifurcated uterus* (uterus divisus), in the sow and carnivora; and the *double uterus* (uterus duplex), in the rodent."—FRANCE.

## AVES.

For many reasons, this part of the subject is interesting, but very little space can be given here to its discussion.

Birds have no teeth, the maxillæ being covered anteriorly, on the outside, by a horny modification of the integument, the whole constituting the *rostrum* or beak. The *tongue* is horny in structure, and apparently an organ of prehension, not of taste. The *oesophagus* is very long, and its longitudinal muscular coat, is internal, the circular external. In seed-eating birds, the oesophagus expands in the cervical region into the *ingluvies*, or crop,—a large sac which rests upon the fascia connecting the clavicles, and in which maceration of the food is carried on. The oesophagus is then continued and expanded into the first cavity of the stomach, the *proventriculus*, a very vascular and glandular cavity, where a fluid analogous to the gastric juice is secreted. To this portion succeeds the second or muscular cavity, the *gizzard*, which is oval and flattened in shape, but with a structure varying according to the nature of the animal's food. In *granivorous* or seed-eating birds, the muscular coat possesses extraordinary thickness and strength, while the lining membrane exhibits a dense, horny, epithelial structure. In the upper portion are two orifices, a large one opening into the proventriculus, and just to the right of this a smaller pyloric orifice opening into the duodenum. All the domesticated birds possess a gizzard similar to this, but in those birds which feed naturally on flesh, the walls of the gizzard are membranous in their thinness, the development of the organ being usually correlated with the size of the ingluvies.

Granivorous birds always swallow a quantity of stones or sand, which is deposited in the gizzard, and with the action of the muscular wall and horny lining, assists in grinding the ingesta to a pulp. Thus the gizzard may be viewed as an organ of mastication.

The *intestines* are very much shorter than in the mammalia, the layers of muscular fibre being inversely arranged, as in the oesophagus. There are two separate *cæca*, long and narrow, with their blind ends directed forwards. The duodenum forms a loop or bend near its origin, embracing the pancreas; the rest of the small intestine is suspended by a mesentery. The *large intestine* is very short, running straight from the cæca to the termination of the canal; it is commonly termed the rectum, and it opens into a cavity called the *cloaca*, an excretory recess, *common to the alimentary, urinary, and genital organs*.

The *pancreas* usually consists of two distinct pieces, and its ducts are two in number, opening separately into the duodenal loop. The *liver* is very large, and as the diaphragm is rudimentary, it can hardly be regarded as a pure



abdominal organ. It consists of two lobes, between which, anteriorly is the apex of the heart, and posteriorly a double fold of peritoneum, analogous to the broad ligament of the mammal. There are two hepatic ducts, one proceeding direct to the duodenum, the other passing from the right lobe to the gall bladder, a *cystic duct* proceeding from the latter to the intestine. The Columbidae or pigeon class, as also some classes of the order Scansores, have no gall bladder. The vena porta, in addition to its fundamental radicals, is joined by branches from the femoral and sacral veins.

The organs of respiration in birds are interesting. The nasal openings are very small, and placed on each side of the beak, or at its base, surrounded by naked skin, a few feathers, or even scales, which form alæ or wings; the nasal cavities open into the pharynx by two distinct apertures, which lie close together. The air-passages consist of a superior larynx, trachea, inferior larynx, bronchi, bronchial tubes, and air-sacs. The *superior larynx* is situated just behind the root of the tongue, opening by a longitudinal slit. It consists of several bony or cartilaginous pieces, varying in number, joined by membranes and moved by muscles. There is no *epiglottis*, the sides of the rima closing the orifice during the passage of food. The *trachea* winds down the neck as a single tube, composed of complete bony or cartilaginous rings, not overlapping, as in mammalia. They are round or compressed, varying in diameter. The *syrix*, or *inferior larynx*, is the organ of sound, and is best developed in song-birds, varying in form and structure in different species. At its origin is a membranous tongue, composed of a doubling of lining membrane; the free portion is directed upwards, and its vibration produces sound.

Below, the tube divides into a pair of *bronchi*, which lead to the lungs. They consist of incomplete segments of bone or cartilage, completed by membrane. The *lungs* are spongy, bright red, long, flat, oval, and applied against the sides of the vertebræ and ribs, to which they are attached by cellular

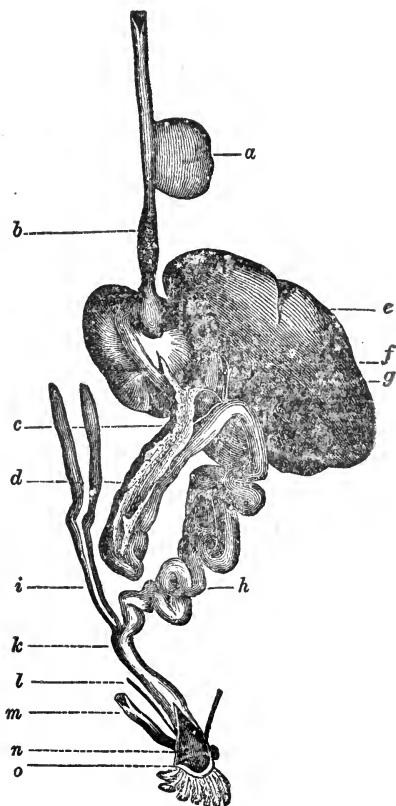


FIG. 148.

Alimentary canal of a Bird. *a*, Inguivies; *b*, Proventriculus; *c*, Pancreas; *d*, Duodenum; *e*, Liver; *f*, Biliary cyst and duct; *g*, Pancreatic duct; *h*, Intestine; *i*, The two caeca; *k*, Rectum; *l*, Right ureter; *m*, Oviduct; *n*, Its aperture in cloaca; *o*, Opening of cloaca.

tissue. They present several openings on their surfaces, which communicate with *air-sacs* hollowed out in the cellular tissue of the body. These sacs are continuous with the interior of certain bones, which thus receive a constant supply of air (see p. 119). There are usually nine sacs—viz., one interclavicular, and the cervical, anterior and lateral thoracic, and abdominal, which are pairs. By means of these, air penetrates nearly every region of the body.

The *kidney* is very irregular in shape, consisting of several portions which occupy the osseous irregularities in the sublumbar and anterior pelvic regions. The *ureters* open into the cloaca, a diverticulum of which is regarded as the analogue of the urinary bladder; the latter organ is distinctly possessed by only one member of the class, the ostrich.

The *testicle* is abdominal, occupying almost the position of the mammalian kidney, which it resembles somewhat in shape, being ovoid. There is scarcely any epididymis; the *vas deferens* is tortuous, and it terminates in the cloaca at the side of a papilla, which is the organ of copulation. In the natatores this papilla is very large, spirally elongated, and retractile.

In the bird there is only one *ovary*, the right one being undeveloped. It resembles a bunch of grapes in form, consisting of ova in various stages of development; the more advanced ones are large, and yellow in colour. The representative of the Fallopian tube is called the *oviduct*, which is large, flexuous, and very dilatable, leading to the cloaca. It is not merely the duct of the ovary, since it also assists in forming the ovum; while the latter is passing through it, the outer casing of calcareous material known as the shell, and the inner layer of albumen or "white of the egg" become developed. The coats of the duct are serous, muscular, and mucous, arranged in the typical manner.

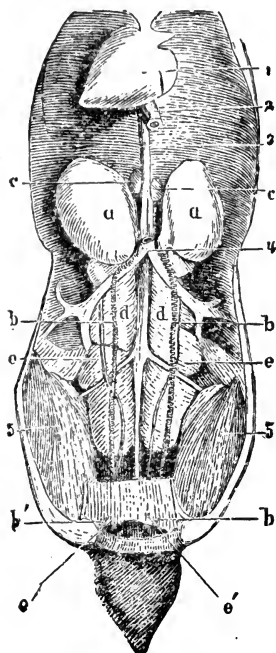


FIG. 149.

Urino-genital organs, &c., of a male bird (fowl). 1, Heart; 2, Esophagus cut across; 3, Aorta; 4, Posterior cava; 5 5, Psoe muscles; a a, Testicles; b b, Vasa deferentia; b' b', their orifices; c c, Suprarenal capsules; d d, Kidneys; e e, Ureters; e' e', Their openings into the cloaca.

## CHAPTER V.

### ANGIOLOGY.

UNDER this heading we describe the organs of circulation, by the action of which certain fluids are propelled through the body. It is customary to divide this branch of the subject into two sections, considering respectively the Blood-Vascular and Lymphatic Systems.

#### BLOOD-VASCULAR SYSTEM.

This involves the consideration of the Blood, a fluid which supplies nutriment to the tissues, and receives effete material from them; the Heart, a muscular organ which, by its contraction, initiates the motion of the blood; the Arteries, a series of tubes which convey the blood from the heart to all parts of the body; the Veins, tubes which return that fluid to the heart; and the Capillaries, minute tubes joining the smaller arteries and veins.

#### BLOOD.

Blood is a fluid tissue, which nourishes all living structures, being the medium by which nutritive material is conveyed to, and effete or waste material conveyed away from, the solid tissues. It is an opaque, thickish, clammy fluid, with a peculiar odour, sickly saline taste, and alkaline reaction. Its colour varies in different parts of the same animal, that in the arteries being bright red or scarlet, while the blood in the veins is of a dark purplish hue.

When examined microscopically, the blood is found to consist of minute corpuscles, and a clear, transparent, yellow fluid, the *liquor sanguinis*, or *plasma*, in which the corpuscles float. The corpuscles are of two kinds, the red, and the white or colourless; the former, by far the more numerous, exist in vary-

ing proportions. *Red corpuscles* vary in shape, but in all mammals are more or less discoid, the camelidæ excepted, where they are oval; in birds, reptiles, and fishes, they are oval, and also nucleated. Their average diameter in the horse, ox, or sheep is about  $\frac{1}{4000}$ th part of an inch, their average thickness being about one-fourth of this. Each surface is depressed towards its centre, hence the corpuscle is appropriately described as a *bi-concave disc*.

The *white corpuscles* are larger than the red, round in shape, and nucleated. Occurring also in lymph they are sometimes termed *lymph-corpuscles*.

The *liquor sanguinis* is pale and clear, and consists of water, fibrin, albumen, fatty compounds, extracts, odoriferous and saline matters. The *serum* is a thin, transparent liquid, of a pale-straw or yellow colour, consisting of the liquor sanguinis deprived of fibrin. It contains nearly 90 per cent. of water, is always slightly alkaline, and coagulates when heated, owing to the large quantity of albumen it contains. *Fibrin* is a white, stringy, elastic substance, which, when the blood is in circulation, is in solution, and cannot be distinguished from the other constituents of the plasma.

#### HEART.

The heart is a hollow, involuntary muscular organ, situated between the layers of the middle mediastinum, and in the pericardial sac, to a reflection of which it owes its external smooth, glistening aspect. Its form is that of a blunt cone, slightly flattened from side to side, and it presents a base and an apex. The former is turned upwards, and towards the dorsal vertebræ, from which the heart is suspended by the blood-vessels that spring from it; the apex points downwards, backwards, and to the left side, lying at about the level of the last bone of the sternum; the organ extends from about the third to the sixth rib inclusive. The average weight of the horse's heart is about six pounds and a-half, its length from base to apex about eight inches, its antero-posterior diameter rather less, and its lateral diameter less still.

The heart is divided by a longitudinal septum into a right and left, or anterior and posterior side. Each of these is again subdivided by a transverse septum into two compartments, which communicate. Thus there are four cardiac cavities, the superior ones, whose free extremities somewhat resemble the ears of a

dog, being called the *auricles*, the inferior the *ventricles*. These divisions are marked externally by deep grooves, in which the cardiac blood-vessels run, and which are generally filled with fat. Two of these grooves extend from the base of the ventricles to the apex of the heart, and correspond to the internal septum; they are called the *anterior* and *posterior longitudinal furrows*. Around the base of the ventricles is a deep transverse *auriculo-ventricular furrow*, which marks the division of the heart into an upper or auricular, and a lower or ventricular portion.

The right side of the heart is sometimes called the *venous*, the left the *arterial* side, named from the kind of blood which passes through them. We will describe first the cavities of the right side, and then those of the left.

## RIGHT AURICLE.

The right auricle is the larger, and forms the right and anterior portion of the base. It consists of two portions; the *sinus venosus*, or principal cavity, is somewhat quadrangular; its walls are thin, and connected inferiorly with the right ventricle; internally, with the left auricle; anteriorly, they are prolonged to form the appendix. The *appendix auriculæ*, or proper auricle, is a small conical pouch, which projects forwards from the sinus; its walls are thick, and its edges, more particularly the outer one, serrated. On laying open the interior of the auricle (which is best done by an incision from the appendix to the mouth of the posterior vena cava, then opening the anterior cava, and connecting the incisions), the smooth transparent Endocardium or lining membrane, anterior and posterior Venæ cavæ, Coronary sinus, Foramina Thebesii, and right Auriculo-ventricular opening are displayed.

The *anterior vena cava* returns the blood from the anterior part of the body, and opens into the supero-posterior part of the sinus venosus. The *posterior cava*, which returns the blood from the posterior region of the body, opens into the infero-posterior part of the external wall of the sinus, near the inter-auricular, or superior part of the longitudinal septum. The *coronary sinus*, the dilated termination of the larger coronary or cardiac veins, is situated below the opening of the posterior cava, between it and auriculo-ventricular opening; and through it the blood is returned from the substance of the heart. The *coronary*

*valve* or *valve of Thebesius*, is a fold of the endocardium which covers the coronary sinus, preventing regurgitation of blood during the contraction of the auricle. The *foramina Thebesii* are minute openings on the inner surface of the auricle; some of them are mere depressions, whilst others are the openings of minute veins, *venæ cordis minimæ*, which return blood directly from the substance of the walls. The *right auriculo-ventricular opening* is a large oval aperture, occupying the floor of the auricle; it communicates with the right ventricle. The *tuberculum Lowerii* is a slight projection situated between the openings of the cavæ, and is supposed to direct the blood from

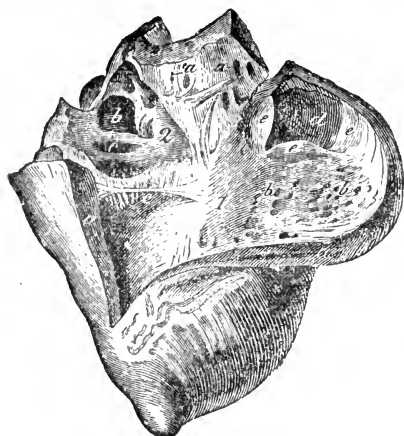


FIG. 150.

Right side of the heart—laid open. 1, Right ventricle; *a a*, Its external wall; *b b*, Carnea columnæ; *c*, Great moderator band; *d*, Origin of pulmonary artery; *e e e*, Sigmoid valves; 2, Right auricle; *a a*, Foramina Thebesii and muscoli pectinati; *b*, Opening of anterior, and *c*, of posterior vena cava.

the anterior cava into the auriculo-ventricular opening.

In man the remains of a foetal structure, called the *Eustachian valve* are situated at the anterior margin of the posterior cava, stretching from it to the left side of the *annulus ovalis*. It is a doubling of the lining membrane, largest in the foetus, and serves to direct the blood from the vein to the foramen ovale; in quadrupeds, this structure, if present at all, is extremely rudimentary.

The *fossa ovalis* is an oval depression in the interauricular septum, being an obliterated foramen, which in the foetus joins the right and left auricles. At birth this opening is closed. Its lower border is indistinct; its upper thick and projecting, forming the *annulus ovalis* or *isthmus Vieusseni*. The *muscoli pectinati* are columns of muscular fibres situated chiefly in the appendix; they are called pectinati, from their resemblance in arrangement to the teeth of a comb. Smaller bundles cross the large ones, giving the whole a reticulated appearance, between which are depressions, some of which are the foramina Thebesii.

## RIGHT VENTRICLE.

The blood leaves the right auricle through the auriculo-ventricular opening, and enters the right ventricle, which occupies the antero-inferior part of the right side of the heart. It is somewhat conical in shape, with its base uppermost, and extends from the auriculo-ventricular septum to near the apex. Its outer walls, although thicker than those of the auricle, are much thinner than those of the left ventricle. The inner wall is convex, and formed by the interventricular septum; on laying the cavity open (by an incision along the side of the anterior longitudinal furrow, and a second one below and parallel to the transverse septum, joining the first), two openings present themselves.

The *auriculo-ventricular* is the large oval opening, situated at the base of the ventricle, surrounded by the fibrous auriculo-ventricular ring; it communicates with the auricle, and is guarded by the *tricuspid valve*, which is formed by a redoublicature of the endocardium, strengthened by an intermediate layer of fibrous tissue. It consists of three triangular cusps or segments, which, connected at their bases, surround the auricular opening. The cusps are attached to each other above for a short distance, but their apices freely project into the cavity of the ventricle; the largest is placed between the auriculo-ventricular opening and the opening of the pulmonary artery; a second rests against the septum of the ventricles, the third between the other two. The free edges of the cusps are thickened, and to their ventricular surfaces and free margins are attached a number of delicate tendinous cords, or *chordæ tendineæ*, which spring from the inner surface of the ventricle. The majority of these arise from the free blunt extremities of the *musculi papillares*, which are a variety of *carneæ columnæ*, the remainder from the walls of the ventricle, diverging towards the valve; some terminate in the free margins and apices of the cusps, others in the central thick portion; while a few reach the attached borders, and become continuous with the auriculo-ventricular ring. This valve prevents the regurgitation of blood into the auricle when the ventricle contracts.

The second opening in the right ventricle is the origin of the *pulmonary artery*. It is situated above and to the left of the auriculo-ventricular opening, is circular, and arises from the summit of a conical prolongation called the *conus arteriosus*, or

*infundibulum*, whose smooth inner surface is destitute of carneæ columnæ. The entrance of the pulmonary artery is guarded by three *semilunar* or *sigmoid valves*, which consist of semicircular folds of the lining membrane; they are almost transparent, and attached by their convex margins to the tendinous ring which surrounds the origin of the artery. Their free edges are almost straight, and thinner than the attached ones, each presenting a mesian fibro-cartilaginous nodule, the *corpus Arantii*.

When blood passes from the ventricle to the pulmonary artery, the valves are laid against the sides of the vessel; when the current is checked, a portion of it falls back towards the ventricle, and the valves are now thrown inwards; they become distended, overlap, and completely close the tube. When the valves are shut, the surfaces next the vessel are concave, the ventricular ones convex.

The *corpora Arantii* are said to fill up the small space that would otherwise be left in the axis of the canal by the meeting of the circular valves; but these bodies are frequently indistinct in the pulmonary artery, and rarely project beyond the free margins of the valves. Behind the valves, at the commencement of the artery, are three dilations or pouches, bounded below by the valves themselves, and called the *sinuses of Valsalva*.

From the inner surface of the ventricular walls project the fleshy columns, or *carneæ columnæ*. They are of three kinds, attached by their external surface and extremities, their internal surfaces being free, forming prominent ridges, sometimes dividing and subdividing. One variety, three or four in number, terminate in short blunt processes, and constitute the *musculi papillares*, whence the chordæ tendineæ spring. These carneæ columnæ form an intricate network on the inner surface of the ventricle, occasionally crossing the cavity, and forming what are called the *moderator bands*. A very well developed one crosses the middle of the cavity from the interventricular septum to the outer wall; this is termed the *great moderator band*, and is said to be especially well marked in "running" animals.

#### LEFT AURICLE.

The blood, after being purified in the lungs, re-enters the heart at the left auricle, which is smaller than the right, but its walls are thicker. It is situated at the left postero-superior part



of the heart, and consists of two parts, a *sinus* and *auricular appendix*. The sinus is separated from the right one by the interauricular septum. The *appendix* is longer, narrower, more serrated than the right one, and constricted at its junction with the sinus. It runs along the left side of the origin of the pulmonary artery, which helps to separate it from the right auricle.

On laying open the cavity, we find the openings of the *pulmonary veins*, usually two pairs, one pair on the right, the other on the left of the sinus; they are not guarded by valves. The remaining opening in the left auricle is the *auriculo-ventricular*, which occupies the floor, and communicates with the left ventricle, its upper margin being surrounded by a white tendinous ring. The obliterated *foramen ovale* on the septum is indistinct. The inner surface of this auricle is smoother than that of the other, the *musculi pectinati* fewer, and confined to the appendix. The *appendix* communicates with the sinus through a round constricted opening.

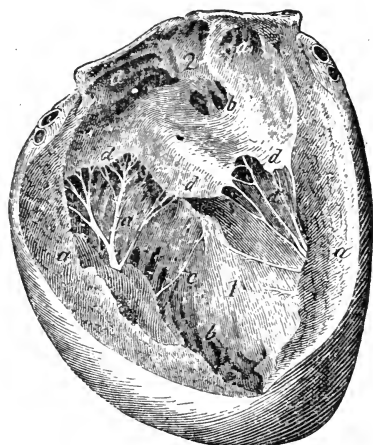

FIG. 151.

Left side of the heart—laid open. 1, Left ventricle; *a a*, External wall; *b*, *Carneæ columnæ*; *c*, *Moderator band*; *d d d*, *Mitral valve*; *d' d'*, *Chordæ tendineæ*; 2, *Left auricle*; *a a*, *Musculi pectinati*; *b*, *Openings of pulmonary veins*.

## LEFT VENTRICLE.

The blood leaving the left auricle enters the left ventricle, which is conical, and occupies the posterior left region of the heart. It is larger, rounder, and more prominent than the right, extending from the auricle to the apex, which it occupies, projecting lower than the right ventricle. The external wall is much thicker than that of the right side, being thickest in the centre. After death the walls of this cavity remain apart, those of the right collapsing; on laying open the cavity (by an incision close upon the anterior furrow, from the apex to near the origin of the aorta, and another upon the posterior furrow, the two meeting at the apex), two openings present themselves, the left *auriculo-ventricular* and the *aortic*. The *left auriculo-ventricular* open-

ing resembles the right in structure, and is guarded by a valve with two cusps, the *bicuspid* or *mitral* valve. The cusps consist of doublings of the lining membrane, strengthened with fibrous tissue, and, it has been said, by muscular fibre. One cusp rests between the auriculo-ventricular and aortic openings; the other, larger and freer, is opposite. They surround the opening, their sides being attached for a short distance, their apices separate. The *musculi papillares* of the left side are two, corresponding to the valve segments; they are large and prominent, one anterior, the other posterior. The *chordæ tendineæ* are few, longer, and more powerful than those of the right side; they are attached to the flaps in a similar manner, and spring from the *musculi papillares*.

The *aortic opening* is deeply situated in the supero-anterior part of the ventricle, a little to the right of the auriculo-ventricular opening, from which it is separated by one of the segments of the mitral valve. It is guarded by three semilunar valves, which are similar in shape and appearance to, but thicker and stronger than, those of the right side; the *corpora Arantii* are larger and better developed, the sinuses of Valsalva deeper. From two of the latter spring the coronary arteries, which supply the substance of the heart with blood.

The *septum of the ventricles* is triangular in shape, and extends to the apex of the heart. It is thick at the base, thinner at the apex; convex in the right ventricle, concave in the left.

#### STRUCTURE OF THE HEART.

The heart consists of a fibrous framework, muscular and connective tissue, vessels, and nerves, the whole being covered by one, and the cavities lined by another, serous membrane. The *fibrous framework* consists of fibro-cartilaginous rings placed around the auriculo-ventricular and arterial openings, extending within the doubling of lining membrane which forms the valves and *chordæ tendineæ*; they are strongly developed on the left side. The *auriculo-ventricular rings* divide the heart into two distinct parts, an auricular and ventricular; they are thicker on their lower edge, whence spring the muscular fibres of the ventricles, the mitral and tricuspid valves, while from the upper edge arise the muscular fibres of the auricles. The right margin of the left auriculo-ventricular ring is connected with the ring surrounding

the aortic opening. Between the aortic ring and auriculo-ventricular opening is a fibro-cartilaginous mass, connected with the several rings, to which muscular fibres are attached, and which in the Ruminant is replaced by a triangular bone or *os cordis*. A second bone is sometimes found between the pulmonic and auriculo-ventricular rings. The *arterial rings* gird the arterial openings, and serve for the attachment of the vessels, semilunar valves, and some of the ventricular muscular fibres. They seem to consist of three semilunar portions united, which gives them a festooned border, to which is attached the middle coat of the artery. The other edge is straight, affording attachment to the muscular fasciculi of the ventricles.

The mass of the heart is composed of *muscular fibres*, connected by filamentous areolar tissue. These fibres are involuntary, and of a deep-red colour, differing from other involuntary muscles, the œsophagus excepted, in being transversely and longitudinally striated. They are smaller than voluntary fibres, and are anastomatic.

The *muscular fibres of the auricles* are separable into superficial and deep; the former common to both auricles, the latter proper to each. The superficial, common, or transverse fibres surround the base of the auricles, and are most abundant on their anterior part. They cross from one auricle to the other, diverging to enclose the appendices and the openings of the large veins. They are also prolonged into the inter-auricular septum, to assist in forming the circular band which surrounds the fossa ovalis. The deep fibres proper to each auricle consist of two sets, looped and annular, which are superficial where the external circular fibres are deficient. The looped fibres are attached by their extremities to the auriculo-ventricular tendinous rings; passing over, they embrace each auricle, forming right and left loops. The annular fibres are arranged in rings, forming a continuous layer. They abound most in the appendices, and around the coronary sinus and pulmonary veins, extending some distance along the course of the latter, and of the cavæ.

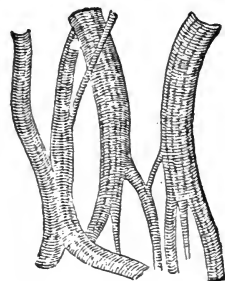


FIG. 152.  
Muscular fibres from the heart  
of the Horse. Magnified 310  
diamrs.

Like the muscular fibres of the auricles, those of the ventricles

are arranged in two sets, one common to both, and another proper to each ventricle, thus forming as it were two muscular sacs enclosed in a third. The fibres, whether common or proper, are attached directly or indirectly by both extremities to the tendinous-rings. The common fibres are arranged in successive layers, arising from the auriculo-ventricular ring. They extend spirally from above downwards, on the anterior surface from right to left, on the posterior from left to right. They are thin and broad at the upper part of the ventricles, becoming thick and narrow as they reach the apex, where they encoil, forming a whorl, then penetrate beneath the layers, and pass up internally, forming the walls and septum, terminating on the auriculo-ventricular ring. The common fibres thus form a superficial layer, passing downwards, and a deep layer reflected upwards, between which are enclosed the layers special to each ventricle. The special fibres form circular or curved bands, inserted by both extremities to the tendinous rings.

The heart is supplied with blood by the coronary arteries, which arise from the sinuses of Valsalva. The blood is returned by the coronary veins which pass to the coronary sinus, and the venæ cordis minimæ, which terminate in the foramina Thebesii. The nerves of the heart come chiefly from the cardiac plexus, formed by the sympathetic and the vagus. The lymphatics follow the course of the blood-vessels, and terminate in glands at the base of the heart.

#### ENDOCARDIUM.

The cavities of the heart are all lined by the serous endocardium, which is continuous with the lining membrane of the blood-vessels. It is thin, smooth, and glistening, giving a polished appearance to the inside of the heart, to which it adheres by cellular tissue. It enters into the formation of the valves, being strengthened by fibrous and muscular tissue between its folds. It is rather red in colour on the right side.

So far as the heart itself is concerned, since, in the adult, the right side is separate from the left, there are two Endocardia, but as the lining membrane of the arteries is continuous through the capillaries with that of the veins, the two membranes *ultimately* form a continuous structure.

## PERICARDIUM.

The pericardium is a fibro-serous sac, which encloses and is reflected over the heart, and origins of the large blood-vessels. It consists of a parietal and visceral portion, and is composed of two membranous layers; one external, dense, and fibrous, the other internal and serous. The outer fibrous layer enters into the formation of the sac, or free portion only of the pericardium, having no direct attachment to the heart itself. It is made up of fibres, which interlace with each other and form a sac, whose apex embraces the origins of the larger blood-vessels, as tubular prolongations. The basal fibres of the membrane sometimes blend with the diaphragm, and are also attached to the last bones of the sternum and ensiform cartilage. The parietal layer is covered by the pleural folds which form the middle mediastinum. The serous layer is much larger than the fibrous, which it lines, and is reflected over the origin of the blood-vessels, and external surface of the heart, thus forming a closed sac. The reflected portion is often called the *epicardium*. Between the parietal and visceral layers is secreted a pale, lubricating serous fluid, the *liquor pericardii*. The pericardium supports the heart, and isolates it from the other thoracic viscera.

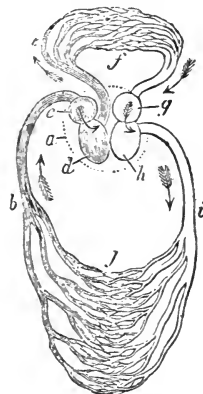


FIG. 153.

Diagram of the circulation in Mammalia and Aves. *a*, Boundary of the heart, containing four cavities; *b*, Vena cava (represented as single here); *c*, Right auricle; *d*, Right ventricle; *e*, Pulmonary artery; *f*, Capillaries of the lungs; *g*, Left auricle, receiving the purified blood from the pulmonary vein (only one shown here); *h*, Left ventricle; *i*, Aorta; *j*, Somatic capillaries conveying the blood again to the veins.

## COURSE OF THE CIRCULATION.

We have seen that the heart is divided into a right or venous, and a left or arterial portion. In tracing the circulation it matters little where we commence, since wherever it be we come back to the same point. Briefly, the following is the course of the blood:—The venous blood is carried into the right auricle by the anterior and posterior venæ cavæ. It then passes through the right auriculo-ventricular opening into the right ventricle; thence through the pulmonary artery to the lungs. It returns by the pulmonary veins to the left auricle; thence to the left ventricle, which propels it through the aorta and its branches

into the system generally ; the veins returning it again to the heart. The circulation is, therefore, double—the Pulmonary or lesser being performed by the right, and the Somatic or greater circulation by the left side. Some writers speak of the portal and chylo-poietic or visceral circulation as forming a third system, but with respect to the heart it is not so, since they are merely a branch of the somatic circulation.

#### ARTERIES.

These are tubes conveying the blood from the heart, a series belonging to each circulation. The somatic and pulmonary arteries leave the heart each by a single trunk, which subdivides and terminates in capillaries, whence the venous radicles originate. The volume of the secondary arteries exceeds that of the primitive trunk, and similar relations exist, as far as the ultimate divisions of the artery, their inclusive capacity increasing towards their termination. Arterial branches arise at variable angles, and the originating angle exerts a decided influence on the velocity of the blood current. Blood passing from a primary into a secondary vessel which arises from it at a right angle, as in some branches from the aorta, must have its speed slackened ; on the contrary, the velocity is little modified in vessels which leave the parent trunk at a very acute angle, as do many of the arteries of the limbs.

The large arteries are usually deep-seated, occupying the cavities of the trunk and the inner surfaces of the limbs, where they are less exposed to injury. When they pass over an articulation, they are generally found on the flexor side. In general, the direction of the larger arteries is straight, but in some parts they are tortuous, as in the stomach, intestines, bladder; tongue, and lips; in fact, wherever the circulation might be impeded, by sudden functional change in the form or volume of the organ. Sometimes this tortuosity is apparently for the purpose of moderating the energy with which the fluid is propelled into delicate structures, such as the brain and testicle; small arteries which run amongst loose structures generally become tortuous during the contraction of the left ventricle.

Arteries freely communicate with each other, forming what are termed *anastomoses*; by *convergence*, where two branches join at an angle to constitute a single trunk, as the cerebro-spinal

branches to form the basilar; by *inosculation*, where two vessels of nearly equal size become continuous and form an arch, from which may spring smaller vessels, as in the arteries of the intestines; by *transverse branches*, where two collateral arteries are joined by a small communicating branch, as between the umbilicals as they approach the placenta. In the smaller arteries anastomoses are frequent, forming a network which pervades almost every tissue of the body. This is a point of great importance, since the circulation can be thus carried on after the main artery of the region has been obliterated, blood being conveyed from neighbouring sources by the anastomosing arteries, and it is proved that under such circumstances the smaller arteries of the part increase in size.

## STRUCTURE OF ARTERIES.

Arteries are dense and elastic, possessing great power of resistance. When empty, they are of a pale buff colour, and preserve their cylindrical form. Their walls consist of three tunics—an internal, middle, and external. The internal, serous, or *tunica intima*, is the thinnest, and continuous with the lining membrane of the heart. It is made up of two layers; an inner, consisting of a layer of epithelial scales; and an outer, transparent, whitish, highly elastic, and perforated, being known as the *fenestrated membrane of Henle*. When the artery is empty, it is thrown into folds, longitudinal in the large, transverse in the small arteries; and when distended, it is smooth and glistening. The *tunica media*, or *contractile middle coat*, is elastic, dense, and of a yellow colour, consisting of non-striated muscular, and elastic fibres; thickest in the larger arteries, it becomes thinner in the smaller. In the largest arteries this coat is composed chiefly of elastic tissue; in the smallest vessels it is almost entirely muscular. The *tunica externa*, or external coat, is made up of areolar tissue and elastic fibres, very thin in the large, as thick as the middle coat; in the smaller, while in the smallest arteries it is rudimentary or wanting. The external surface is loose, and connected by laminæ with the sheath.

The *arterial sheaths* consist of cellular tissue, intimately connected with the surrounding textures. The artery has only a loose attachment to the sheath, so as to allow of free gliding on its inner surface. An artery is usually accompanied by a vein,

sometimes by two veins, and generally by a nerve, all of which may lie in the same sheath, the veins being usually more superficial. The coats of arteries are supplied with nutrient blood-vessels, the *vasa vasorum*, which come from neighbouring vessels, and ramify in the external tunic; they can occasionally be traced into the middle tunic. Arteries are also provided with absorbents, which are only visible on the larger trunks; and plentifully supplied with nerves, chiefly by the sympathetic, which form plexuses on the larger vessels. The external coat is very tough, while the middle and internal are elastic and brittle. On ligaturing an artery, the internal and middle coats give way, while the external one is left unbroken. From the power of resistance possessed by the external coat, we are enabled to stop hæmorrhage by torsion; the middle and internal coats giving way, the external, which remains unbroken, forms a spiral ligature round the others, so tight that it cannot be unravelled by twisting in an opposite direction.

#### CAPILLARIES.

The smaller arteries terminate in a system of minute vessels—the *capillaries*—which are interposed between the termination of the arteries and the commencement of the veins, forming plexuses which vary much in arrangement. Their average diameter is about  $\frac{1}{3000}$ th of an inch, varying in different textures, smallest in the brain and mucous membrane of the intestines, largest in the skin, in glands, and the interior of bones. All arteries do not terminate in capillaries, an exception being in erectile tissue, where the arteries end in cells or cavities placed at the origin of the veins.

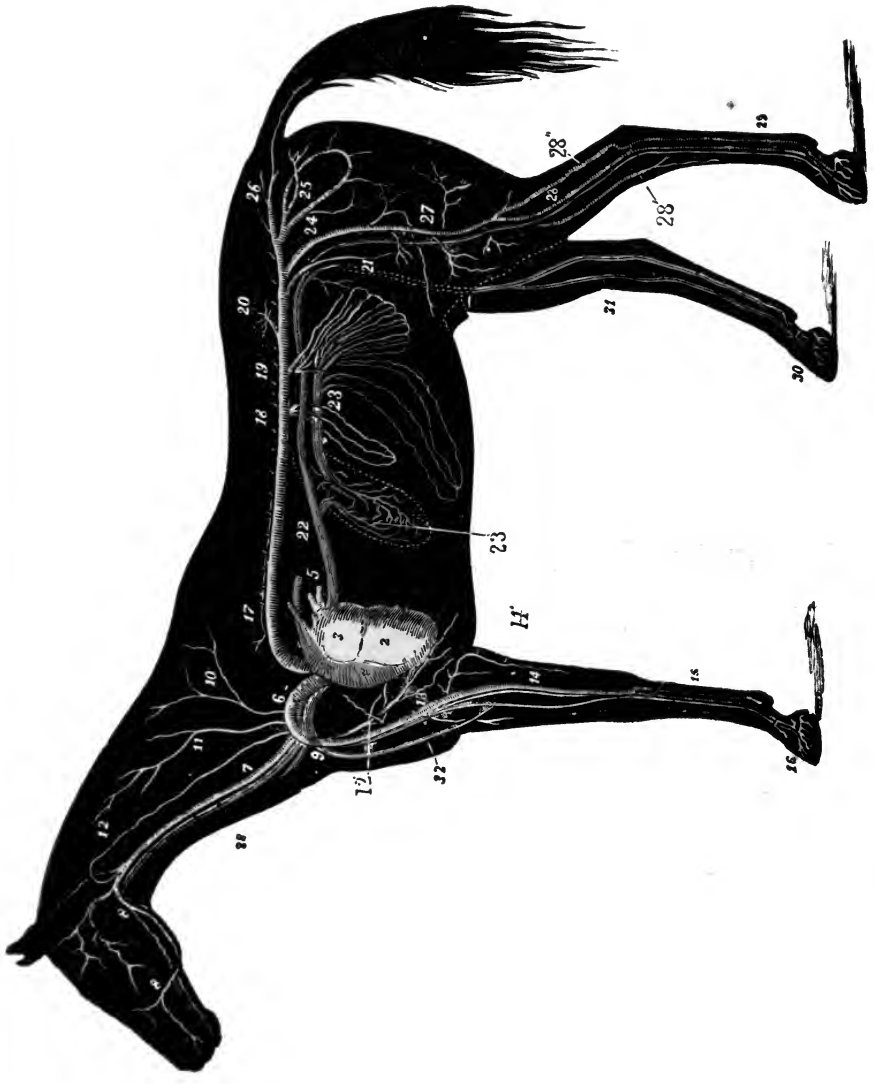
#### PULMONARY ARTERY.

(FIG. 154. f.)

The pulmonary artery springs from the conus arteriosus of the right ventricle, its origin being guarded by the sigmoid valves; it curves upwards and backwards until it reaches the upper part of the left auricle, where it divides into right and left branches, which penetrate the substance of their respective lungs, along with the bronchi, ramifying in the substance along with the bronchial tubes, and terminating by capillary branches, which form a dense network on the walls of the air-cells; the branches,







THE HEART AND CHIEF BLOOD VESSELS OF THE HORSE-- after Meunier

## EXPLANATION OF PLATE V.

### BLOOD-VASCULAR SYSTEM OF THE HORSE.

- |                                |                                |
|--------------------------------|--------------------------------|
| 1. Heart, right ventricle      | 18. Cœliac axis.               |
| 2. Heart, left ventricle.      | 19. Mesenteric arteries.       |
| 3. Heart, left auricle.        | 20. Renal artery (left).       |
| 4. Pulmonary artery.           | 21. Small testicular artery.   |
| 5. Pulmonary veins.            | 22. Posterior vena cava.       |
| 6. Anterior aorta.             | 23. Portal vein.               |
| 7. Carotid artery.             | 23'. Hepatic circulation.      |
| 8 8. Glosso-facial artery.     | 24. External iliac artery.     |
| 9. Left brachial artery.       | 25. Internal iliac artery.     |
| 10. Dorsal artery.             | 26. Lateral sacral artery.     |
| 11. Superior cervical artery.  | 27. Femoral artery.            |
| 12. Vertebral artery.          | 28. Posterior tibial artery.   |
| 12'. Internal thoracic artery. | 28'. Anterior tibial artery.   |
| 13. Humeral artery.            | 28''. Femoro-popliteal artery. |
| 14. Radial artery.             | 29. Metatarsal vessels.        |
| 14'. Cubital artery.           | 30. Venous plexus of the foot. |
| 15. Great metacarpal artery.   | 31. Internal saphenic vein.    |
| 16. Ungual branches.           | 32. Cephalic vein.             |
| 17. Posterior aorta.           | 33. Jugular vein.              |



belonging to different lobules do not anastomose; from these capillaries spring the radicles of the pulmonary veins. The pulmonary artery at its origin is joined by its right side to the aorta, round which it winds, both vessels being enclosed in a serous tube, formed by a continuation of the visceral layer of the pericardium; above this is attached the fibrous layer of the same membrane, which is carried onwards for a short distance as a tubular sheath. About its centre, this artery is united to the posterior aorta by a short, dense, fibrous cord, the remains of the foetal *ductus arteriosus*; its walls are thinner than those of the aorta. The pulmonary is the only artery in the adult that conveys venous blood.

## COMMON AORTA.

(Fig. 154. c.)

The common or primitive aorta is the main trunk of the arterial system. It arises from the antero-superior part of the left ventricle, being attached to the aortic fibrous ring, and guarded by the sigmoid valves; it passes upwards and forwards for nearly two inches, then divides into two, the *anterior and posterior aorta*, the former supplying the fore extremity, neck, and head, the latter the rest of the body, and limbs. The aorta has on its right side the right auricle, and on its left the pulmonary artery, to which it is joined by cellular tissue, the two lying in one sheath. The trunk is traversed by the cardiac nerves.

## CORONARY ARTERIES.

(Fig. 154. d.)

In addition to its terminal divisions, the aorta gives off the right and left coronary, or *cardiac* arteries, each of which arises from one of the sinuses of Valsalva; thence the right one passes to the right of the pulmonary artery, under the right auricle, and along the auriculo-ventricular furrow; on reaching the right longitudinal furrow, it divides into vertical and transverse branches. The vertical descends the right longitudinal furrow, yielding branches to the ventricular walls, rounds the apex, and anastomoses by convergence with the corresponding left branch; the small transverse branch passes along the transverse furrow, anastomosing with its fellow. The left coronary artery arises as the

right, passing out behind and between the pulmonary artery, and the apex of the left auricular appendix, and immediately divides into vertical and transverse branches, with a distribution similar to that of the right one.

We will first consider the Posterior, afterwards the Anterior Aorta.

#### POSTERIOR AORTA.

(PLATE V. 17.)

The posterior aorta is larger and longer than the anterior. It

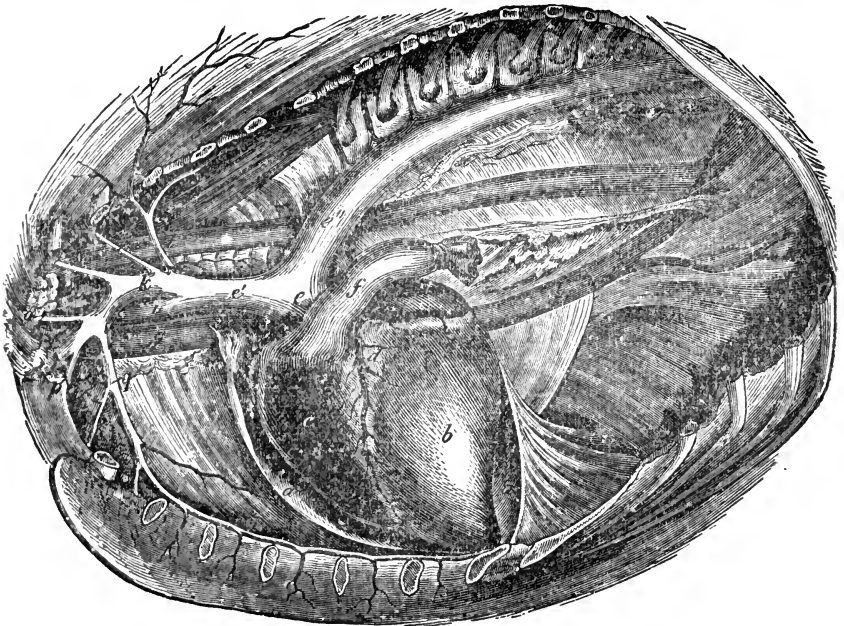


FIG. 154.

Thorax opened on the left side—showing the heart and large vessels *in situ*. *a a*, Pericardial sac; *b*, Left ventricle; *c*, Right ventricle; *d*, Left coronary artery; *e*, Primitive or common aorta; *e'*, Anterior aorta; *e''*, Posterior aorta; *f*, Pulmonary artery, divided and ligatured; *g*, Anterior vena cava; *h*, Posterior vena cava; *i*, Right bracial, or brachio-cephalic artery; *k*, Left brachial artery; *l*, Left dorsal artery, giving off the subcostal posteriorly; *m*, Left superior cervical artery; *n*, Left vertebral artery; *o*, Left inferior cervical artery; *p*, Left external; and *q*, Internal thoracic arteries.

commences at about the level of the fourth dorsal vertebra, passes upwards and backwards, forming the aortic arch, and reaching the left side of the spine at the sixth or seventh dorsal vertebra. It passes straight backwards to the hiatus aorticus, entering the abdomen between the pillars of the diaphragm, and terminat-

ing in the posterior part of the sublumbar region by breaking up into the external and internal iliacs. It is divided into thoracic and abdominal portions. The arch of the *thoracic* portion is crossed on the right by the trachea and œsophagus, having the pulmonary artery on the left; along the spine it lies in the posterior mediastinum, related on the right with the vena azygos and the thoracic duct. The *abdominal* portion is embraced by twigs of the sympathetic nerve, and related with the reservoir of Pecquet above, and the posterior vena cava on its right. The posterior aorta furnishes parietal and visceral branches, which we tabulate as follows :—

PARIETAL BRANCHES.

Aortic intercostal.	Phrenic.
Lumbar.	Middle sacral.

The INTERCOSTAL arteries are doublets, seventeen in number, the last thirteen of which, the *aortic intercostals*, arise directly from the posterior aorta; while the first arises from the superior cervical, the next three from the dorsal artery. The aortic intercostals leave the superior part of the trunk at right angles, skirt the dorsal vertebræ, and at the upper margin of the intercostal spaces divide into inferior or intercostal, and superior or dorso-spinal. The *intercostal* branch is the larger, and travels along the grooved posterior border of the rib down the side of the thorax, associated with the vein and nerve. These arteries anastomose with the asternal, and anterior abdominal branches of the internal thoracic; while the last four traverse the abdominal muscles, and anastomose with the abdominal and circumflex ilii. The intercostal branch supplies the pleura, intercostal, and thoracic muscles. The *dorso-spinal* branch is distributed to the dorsal muscles and integument, supplying the spinal cord and its coverings through the intervertebral foramen.

The LUMBAR arteries, five or six pairs, originate like the intercostals, dividing in the intertransverse spaces into *superior* or *lumbo-spinal*, the larger, which are distributed to the muscles and integument of the loins, furnishing spinal branches to the cord and its membranes; and *inferior*, which pass to the *psœ*, *transversalis abdominis*, and internal oblique muscles, and there anastomose with the circumflex ilii. The last lumbar may arise from the internal iliac artery (Fig. 158. 1, 1).

The PHRENIC or DIAPHRAGMATIC arteries are usually two or

three small vessels which arise at the hiatus aorticus; one goes to the left, the other to the right diaphragmatic crus, terminating on the phrenic centre. The right gives twigs to the pleura and right lung.

The MIDDLE SACRAL artery is a single mesian continuation of the posterior aorta. Large in some animals, when present in the horse it is extremely rudimentary, and it is often absent.

#### VISCERAL BRANCHES.

Broncho-oesophageal.—Thoracic	}	Abdominal.
Cœliac axis.		
Great mesenteric.		
Small mesenteric.		
Renal.		
Spermatic.		
Small testicular.		

The BRONCHO-ŒSOPHAGEAL arises close to and sometimes with the first pair of aortic intercostals, breaking up into bronchial and œsophageal branches. The *bronchial* arteries pass between the aortic arch and the œsophagus, to the bifurcation of the trachea, dividing into right and left, which enter the lungs with the bronchi, ramifying with the air-tubes, and terminating in the pulmonary capillaries. The *œsophageal* artery proceeds backwards to the posterior mediastinum; reaching the œsophagus, it divides into two. The large superior one is distributed to the upper, the inferior to the under surface, anastomosing with the *pleural branch* of the gastric, and supplying the posterior mediastinum.

#### CŒLIAC AXIS.

(FIG. 155. 1.)

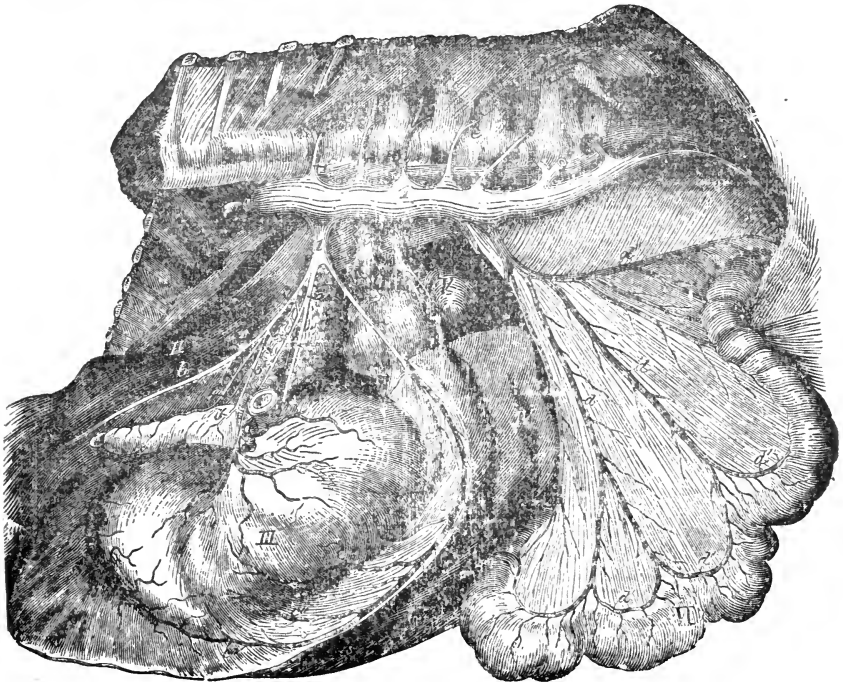
This is a short trunk arising from the lower surface of the aorta as it enters the abdomen. About an inch in length, it divides into the gastric, splenic, and hepatic arteries.

The GASTRIC, the central and smallest division, passes the cardiac orifice of the stomach, and divides into *right* or *anterior*, *left* or *posterior*, and *pleural*; the latter enters the thorax by the foramen sinistrum, bifurcates and anastomoses with the œsophageal and superior branches of the thoracic artery. The *right gastric* passes to the œsophagus over the lesser curvature of the stomach,



and is distributed to the anterior aspect of the greater *cul-de-sac*; the *left gastric* gains the posterior aspect, and ramifies over the right *cul-de-sac*; both are tortuous, and anastomose with each other and with the splenic artery.

The **SPLenic** artery, the largest cœliac division, passes to the left, over the fundus of the stomach, and enters the hilus of the



1. a. 155.

Abdominal branches of the posterior aorta. The left abdominal wall and diaphragm, small intestine and great colon being removed. I, Aorta; II, Liver; III, Stomach; IV, Spleen; V, Left kidney; VI, Floating colon; 1, Cœliac axis; a, Gastric artery; a', Its anterior, and a'', Its posterior branch; a''', Pleural artery; b b, Hepatic artery; b' b', Pyloric artery; b'', Duodenal artery; b''', Right gastro-epiploic artery; c, Splenic artery; c', Pancreatic branch; c'' c'', Small branches to the stomach; c''', Left gastro-epiploic artery; 2, Anterior mesenteric artery divided; 3, Left renal artery; 4, Left spermatic artery divided; 5, Posterior mesenteric artery; d d, Its radiating branches; d' d', Their inosculatory arches; d'', Hæmorrhoidal branch; 6 6, Lumbar arteries; e e, Their spinal branches.

spleen, enveloped in the gastro-splenic omentum; at the splenic apex it becomes the *left gastro-epiploic*, which passes along the greater curvature of the stomach as far as the lesser *cul-de-sac*, finally anastomosing with the right gastro-epiploic branch of the hepatic artery; it supplies the spleen and stomach, and gives a small twig to the pancreas.

The **HEPATIC** artery passes to the right, partly embedded in

the pancreas, crosses obliquely under the posterior vena cava,

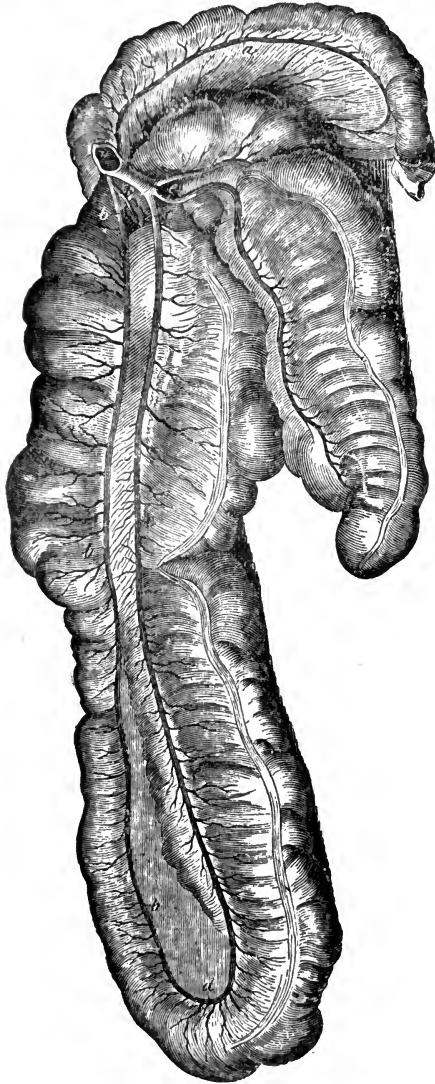

FIG. 156.

Arteries of the cæcum, colon, and part of the floating colon. I, Trunk of the great mesenteric artery; a, Anastomotic artery of the floating colon; b b b, Left colic artery; b', Pancreatic branch; c c c, Right colic artery; d, Inosculation of the two colic arteries; e, Ileo-cæcal artery.

and entering the transverse fissure of the liver, is distributed to that organ, along with the vena porta; it supplies the substance of the liver, in which organ its ultimate branches form three communicating series, to which the following terms have been applied: the *rami vasculares*, which supply the walls of the bile ducts and blood vessels, as *vasa vasorum*; the *rami capsulares*, which supply the capsule; and the *rami lobulares*, supplying the substance of the lobules. The hepatic artery gives off *pancreatic* twigs to the pancreas, and the *pyloric*, which passes over the duodenum to the pylorus and lesser curvature of the stomach, anastomosing with the left gastric. The hepatic artery also gives off the *right gastro-epiploic* and *duodenal*. The former crosses the duodenum, gains the greater curvature of the stomach, and inosculates with the left gastro-epiploic; the latter proceeds along the curvature of the duodenum, and

anastomoses with a branch of the great mesenteric artery.

## GREAT MESENTERIC ARTERY.

(Fig. 155. 2.)

The anterior or great mesenteric artery arises a little behind the cœliac axis, and splits into left, right, and anterior divisions. The *left* consists of a score or so of branchlets, which pass to the mesentery, being arranged in a radiating manner between its folds, and inosculating with each other near the lesser curvature of the small intestine, so forming arches, from which twigs proceed to the intestine. The first of these branches anastomoses with the duodenal branch of the hepatic.

The *right* division divides into ileo-cæcal, superior and inferior cæcal, and right colic arteries. The *ileo-cæcal* passes in the mesentery along the ileum, and inosculates with the last branch of the left division. The *superior* or *internal cæcal* goes to the upper, the *inferior* or *external cæcal* to the lower fissure of the cæcum; as it crosses the junction of the colon and cæcum, it supplies the *artery of the arch* which winds partly round the origin of the colon. The *right colic* supplies the first and second portions of the large colon, inosculating with the left colic at the pelvic flexure.

The *anterior* division consists of the left colic or retrograde, and a branch to the floating or single *colon*; near its origin it gives off a branch to the pancreas. The *retrograde* runs parallel with the right colic, inosculating with it, and supplying the third and fourth portions of the great colon. The *artery of the floating colon* anastomoses with the posterior mesenteric artery.

## LESSER MESENTERIC ARTERY.

(Fig. 155. 5.)

The posterior or lesser mesenteric artery originates at from three to four inches behind the great mesenteric; longer but less capacious than the latter, it divides into thirteen or fourteen branches, which supply the floating colon and rectum, one branch anastomosing with the artery of the floating colon from the anterior mesenteric. They lie in the folds of the colic mesentery, and the first eight form arches as in the anterior mesentery, but the rest, which chiefly supply the rectum, break up singly without forming arches; these are known as the *hæmorrhoidal* arteries.

The RENAL arteries, right and left, leave the aorta at right angles, almost corresponding with the anterior mesenteric artery; the right, having to cross the vena cava, is the longer. They pass straight to the hilus of the kidney. Reaching the limiting layer, they break up and form the capillary network, and Malpighian

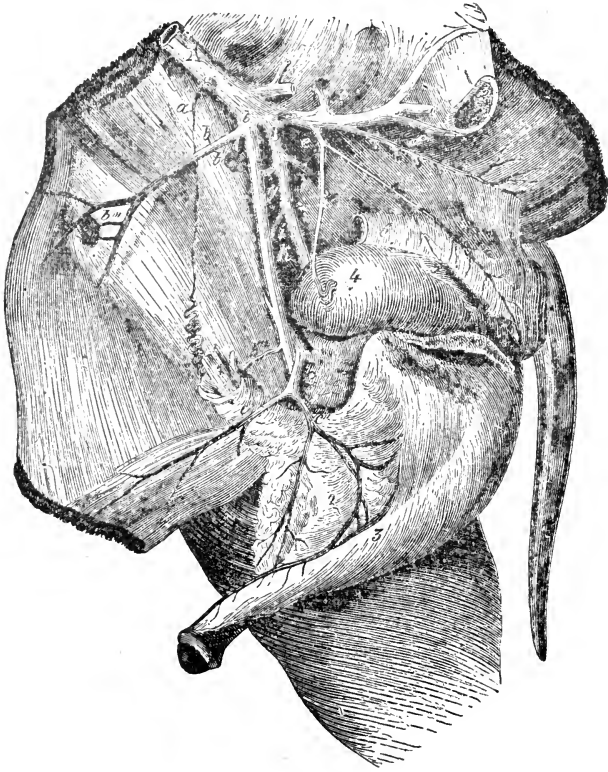


FIG. 157.

Breaking up of the posterior aorta—the pelvis being opened on the left side. 1, Spermatic cord divided; 2, Septum scroti; 3, Penis; 4, Bladder; 5, Left vesicula seminalis; C, Rectum. ARTERIES—A, Posterior aorta; a, Spermatic; b, External iliac; c, Circumflex ilii; b' b'' b''' b''', Branches to iliac glands; b''''', Small testicular; c, Prepubian; c', Epigastric; c'', External pudic; B B, Internal iliacs; d, Left ilio-lumbar; e, Common Origin of umbilical and internal pudic; e', Umbilical; e'', Internal pudic; f, Lateral sacral; g, Right ilio-lumbar; h, Gluteal; i, Iliaco-femoral; k, Obturator.

tufts (see Kidney). An anterior branch supplies the suprarenal capsule.

The SPERMATIC arteries, right and left, become, in the female, the utero-ovarian. They spring from the under surface of the posterior aorta, near the posterior mesenteric, it may be behind,

on a level with, or before it, and they may both arise in common. The spermatic, their diameter considered, are the *longest arteries in the body*; they pursue a diverging course through the inguinal canal, and become a constituent of the spermatic cord, lying on its anterior border; as they near the testicle they become extremely tortuous, and are finally distributed to the tunica vasculosa.

The UTERO-OVARIAN artery passes to the broad ligament of the uterus, dividing into *ovarian* and *uterine* branches. The former is tortuous, supplying the ovary; the latter passes to the cornu of the uterus, anastomosing with the uterine artery.

The SMALL TESTICULAR, or ARTERY OF THE CORD, is small, and sometimes arises from the aorta, between the internal and external iliac arteries, or it may arise from the latter, far down. It passes through the inguinal canal, and supplies the tissues of the cord, first giving twigs to the ureter, vas deferens, and peritoneum. In the female, this artery becomes the UTERINE, which is much larger, and is distributed to the body and cornu of the uterus, anastomosing with the utero-ovarian and vaginal arteries.

The posterior aorta at the level of the last lumbar vertebra gives off the External Iliac arteries, and a little posterior to this the rest of its trunk bifurcates, forming the Internal Iliac arteries. These four vessels are all large, and their origins are so near together that the breaking up of the aorta has been termed the *iliac quadrifurcation*.

## INTERNAL ILIAC ARTERY.

(FIG. 157. B B. ; FIG. 158. C C.)

The internal iliac arteries are short, thick trunks, extending from the last lumbar vertebra to near the insertion of the psoas parvus. They supply the pelvic viscera, and partially the muscles of the hind quarter. Each of these trunks gives off the following arteries:—

Umbilical.		Iliaco-femoral.
Internal pudic.		Obturator.
Ilio-lumbar.		Gluteal.
	Lateral sacral.	

The UMBILICAL artery, large in the foetus, is a mere fibrous

cord in the adult ; it extends from the aorta to the fundus of the bladder, inside the free border of the lateral false ligament, winding partly round the vas deferens.

The INTERNAL PUDIC, or ARTERY OF THE BULB, passes backwards and downwards, related with the supero-lateral aspect of the bladder ; it winds over the ischial arch, supplying the bulb and crura of the penis. It gives off posteriorly several twigs to

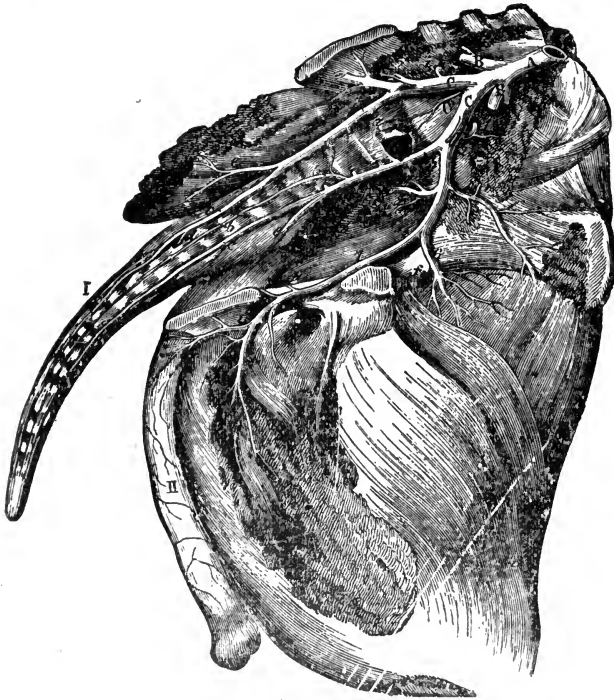


FIG. 153.

Distribution of the internal iliac arteries—the pelvis opened from the right side and the viscera removed. I, The tail ; II, The penis ; A, Posterior aorta ; B B, External iliacs ; C C, Internal iliacs ; C' Middle sacral ; 1 1, Last lumbar ; 2 2, Internal pudic cut ; 3 3, Lateral sacralis ; a a, Sacro-spinalis ; b b, Middle coccygeal ; c c, Lateral coccygeal ; d, Superior branch of same, e e, Ischiatics ; 4, Ilio-lumbar ; 5, Gluteal ; 6, Ilio-femoral ; f, Nutrient artery of ilium ; 7, Obturator ; g, Nutrient artery of ischium ; h, Inferior branch ; i, Cavernous and crural portion.

Cowper's gland, and anteriorly the *vesico-prostatic* artery, which gives a posterior branch to the prostate gland, an anterior one to the vas deferens, and also twigs to the bulb of the latter, to the vesicula seminalis, and walls of the bladder ; one branch is the perineal artery which passes the ischial arch, and supplies the anus and urethral muscle superiorly. In the female the internal

pubic artery furnishes branches to the rectum, vulva, and vaginal bulb, together with the analogue of the vesico-prostatic in the male—the *vaginal* artery, which anastomoses with the uterine, supplying also the bladder. The perineal artery in the female supplies the vulva.

The ILIO-LUMBAR artery is given off at a right angle, passing between the iliacus muscle and the venter surface of the ilium. It supplies the sacro-iliac articulation, the sublumbar muscles, and surmounting the iliac crest, becomes buried in the gluteus maximus.

The ILIACO-FEMORAL artery, large in the horse, passes downwards and outwards, crossing the iliacus, to supply the crural triceps and tensor fasciæ latæ from the outside.

The OBTURATOR artery is sometimes regarded as having a common origin with the iliaco-femoral, sometimes, and more correctly as being given off by the latter. It is a long vessel passing backwards and downwards, along the lower edge of the pyriformis muscle, and through the obturator foramen, when it divides into *cavernous* and *crural* branches, the first going to the dorsum, the other to the bulb and crus of the penis. It gives *en route* an inferior branch to the ischio-tibial muscles.

The GLUTEAL artery is the largest branch of the group, and passes along the pelvic roof downwards, and through the great sciatic notch, along with the great sciatic nerve. It supplies the gluteal muscles, anastomosing with the ilio-lumbar.

The LATERAL SACRAL artery runs straight backwards along the side of the sacrum near its inferior foramina, through which it sends in the *sacro-spinal* branches to supply the spinal cord. It finally divides into *ischiatric* and *lateral coccygeal*; the former winds outwards behind the sacro-sciatic ligament, and breaks up in the ischio-tibial muscles, anastomosing with ascending twigs of the femoro-popliteal, deep femoral, and obturator arteries. The lateral coccygeal branch is continued backwards, supplying the tail; a *middle coccygeal* branch is given off usually from the right or left lateral sacral artery, perhaps oftener from the left.

## EXTERNAL ILIAC ARTERIES.

(FIG. 157. b.)

These, the anterior or external branches of the aortic quadrifurcation, are essentially the arteries of the pelvic limb. Each of them arises below the last lumbar vertebra, curving obliquely

outwards and downwards. At the level of the ilio-pectineal line it becomes the femoral. The external iliac artery gives off the circumflex ilii, and sometimes, as we have seen, the small testicular artery.

The CIRCUMFLEX ILII springs from the outer side of the iliac near its origin, or occasionally from the aorta, crosses the psoas magnus and iliacus towards the anterior iliac spine, where it divides into two branches, an anterior, which ramifies in the transversalis and internal oblique, anastomosing with the abdominal branches of the intercostal and lumbar arteries; and a posterior, which crosses the abdomen just below the external iliac spine, between the iliacus and internal oblique, descending in the tensor fasciæ latæ anteriorly, and terminating in subcutaneous twigs.

#### FEMORAL ARTERY.

(FIG. 159. 1.)

This is the artery of the thigh, a continuation of the external iliac, extending from the level of the pelvic brim to the heads of the gastrocnemius muscle; it lies in the femoral space between the iliacus, pectineus, and sartorius muscles, and is related with the internal saphenic nerve and satellite vein, along the pectineus and vastus internus, and the posterior border of the sartorius; it then enters a ring formed by the two parts of the adductor longus and the femur, and passing between the bifid origin of the gastrocnemius muscle becomes the popliteal. Two important arteries are given off at the point where the iliac becomes the femoral, but are best regarded as branches of the later, they are the prepubian and arteria profunda femoris; they generally have a common origin. The branches of the femoral artery are:—

Prepubian.		Superficialis femoris.
Profunda femoris.		Small muscular.
Saphenic.		

The PREPUBIAN artery, a short vessel, arises in common with the arteria profunda femoris at the level of the pelvic brim. Crossing the crural ring it gains the posterior aspect of the internal abdominal ring, and divides into the epigastric and external pudic. The *epigastric* or *posterior abdominal* artery, runs forwards between the small oblique and transverse muscles, and along the border of the rectis abdominis and inner side of the



internal abdominal ring, thus crossing the spermatic cord on the inside. It supplies the rectus muscle and other portions of the abdominal parietes, anastomosing with the circumflex ilii and anterior abdominal arteries. The *external pudic* artery descends to the dorsum penis, through the inguinal canal, where it becomes the *dorsal* artery of the penis, and divides into anterior and posterior. The anterior is long and flexuous, so as to allow protrusion of the penis; it runs along to the anterior extremity, supplying the erectile tissue. The posterior also passes to the dorsum, and anastomoses with the internal pudic and obturator, supplying the scrotum.

The external pudic gives off the *subcutaneous abdominal* artery which passes forwards through the inguinal canal, and over the abdominal fascia, reaching the anterior extremity of the suspensory ligament of the sheath, where it terminates by numerous subcu-

taneous twigs supplying the skin, sheath, and superficial inguinal glands, one twig circling round the umbilicus to inosculate with its fellow from the opposite side. In the female, the *mammary* replaces the dorsal artery of the penis; it is much larger

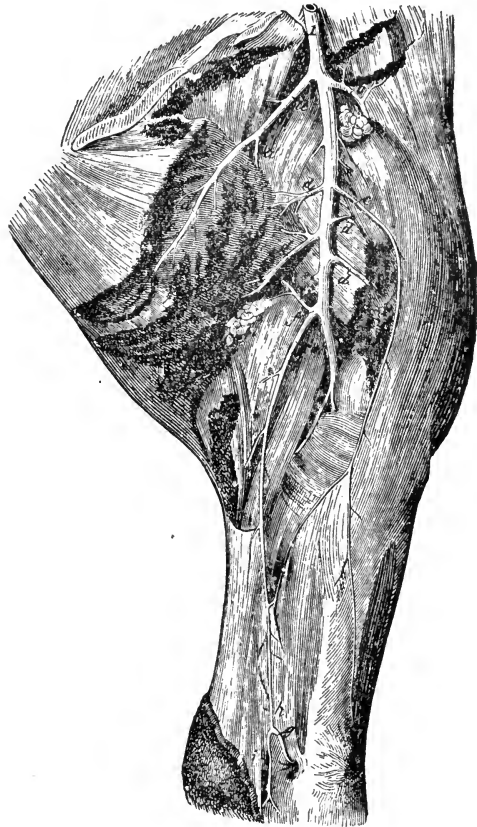


FIG. 159.

Internal view of left thigh—showing the arteries. 1, Femoral; a a a, Profunda femoris; b, Superficialis femoris; c, Saphenic; d d d d, Muscular branches; e, Femoral nutrient vessels cut; (the femoral becomes the popliteal at about this point); f, Femoro-popliteal; f', Its muscular branches; f'', Its descending branch; g, Recurrent tibial; h, United trunk of saphenic and femoro-popliteal; i, Internal plantar.

than the subcutaneous abdominal branch, and ramifies in the substance of the gland; and as it dips between the thighs it sends a twig along the perineum to the inferior commissure of the vulva.

The *ARTERIA PROFUNDA FEMORIS* arises with the prepubian at the origin of the femoral. Some regard it as a bifurcation of the iliac. It passes directly backwards between the iliacus and pectineus, and over the obturator externus, gains the deep face of the adductors, winds round the femur, supplying the hip joint and adjacent muscles, and is lost in the biceps rotator tibialis and triceps adductor femoris, anastomosing with branches of the ischiatic and obturator arteries.

The *ARTERIA SUPERFICIALIS FEMORIS* arises nearly opposite to the profunda, but runs outwards and forwards between the long adductor and the common convergence of the psoas magnus and iliacus towards their insertion; giving twigs to them, it passes between the vastus internus and rectus femoris, supplying the crural triceps from the inside (compare the iliaco-femoral artery).

The *SMALL MUSCULAR* arteries include a series of small in-nominate branches supplying the neighbouring muscles, and given off at intervals from the femoral; one of them sends a long branch to the stifle joint, and one becomes the nutrient artery of the femur.

The *SAPHENIC* artery, a small vessel in the horse, arises from about the middle of the femoral, and gains the subcutaneous region inside the thigh, generally passing between the adductors brevis and longus. Associated with the saphenic vein and its radicals it divides into an anterior and posterior branch, the latter descending and forming just above the tarsus a peculiar anastomotic arch with the posterior tibial, and femoro-popliteal arteries

#### POPLITEAL ARTERY.

(FIG. 159. at e.)

The popliteal artery is a continuation of the femoral, commencing between the heads of the gastrocnemius muscle; it passes under the popliteus muscle, and at the upper part of the tibia bifurcates into anterior and posterior tibial arteries. Its branches are femoro-popliteal, articular and muscular.

The *FEMORO-POPLITEAL* artery, given off just at the origin of the popliteal, springs from its posterior aspect, and passes back-

wards, between the biceps rotator and adductor magnus, supplying them, and gaining the subcutaneous or posterior aspect of the haunch; it terminates in ascending and descending branches, which inosculate with the profunda, ischiatic, and posterior tibial, supplying also the skin at the back of the haunch. The *articular* branches assist in supplying the stifle joint; the *muscular* go to the gastrocnemius; one slender twig descends in front of the flexor perforatus, along with the popliteal nerve, and anastomoses with a recurrent branch of the posterior tibial artery near the tendo-Achillis.

The POSTERIOR TIBIAL artery lies beneath the popliteus, flexor perforans, and accessorius muscles, becoming more superficial, and covered by the tibial fascia, as it travels down the side of the leg to the crest of the os calcis, where it terminates in the tarsal arch, whence spring usually two *recurrent* branches, which inosculate with small branches of the popliteal and the saphenic arteries. Small branches are given off by it to supply the muscles, the tarsal joint, and the nutrient artery of the tibia.

From the S shaped arch formed at the hock by the above anastomoses, two small branches arise, the *internal* and *external plantar* arteries. Each clings to its relative side of the deep flexor tendon, and at the level of the upper end of the suspensory ligament, both anastomose with the perforating pedal artery, forming a second or inferior anastomotic arch. From this arch are given off two small vessels which ramify over the flexor tendons, and an external and internal *interosseous plantar* artery; the latter is the larger, and appears to be the continua-

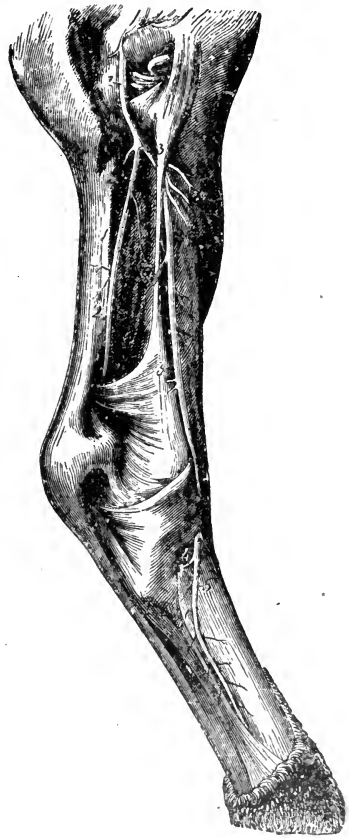

FIG. 160.

Arteries of the right posterior limb—external view. 1, Popliteal; 2 2, Posterior tibial; 3 3, Anterior tibial; a, Peroneal; b, Muscular branches; 4, Perforating pedal; 5, Great metatarsal.

tion of the perforating artery, running down the inner border of the suspensory ligament; the external one, very small, passes down the outer border. At the fetlock joint these vessels unite with the great metatarsal artery to form the sesamoidean arch.

#### ANTERIOR TIBIAL ARTERY.

(FIG. 160. 3, 3.)

This is part of the main trunk, being really the continuation of the popliteal; it winds forwards between the tibia and fibula to the fore part of the leg, gaining it midway between the stifle and hock. It lies between the deep face of the flexor metatarsi muscle and the tibia. At the hock it passes obliquely outwards, crossing the joint, and becomes the *great metatarsal* artery at the proximal end of the metatarsus. It gives off twigs to the adjacent muscles, which anastomose with the popliteal, and the *peroneal* branch, which supplies and runs under the peroneus, and it finally divides about the tarsus into the *great metatarsal* and *perforating pedal* arteries.

The ARTERIA PEDIS PERFORANS, or PERFORATING PEDAL artery passes through the tarsal joint, in a canal between the cuboid and cuneiformes magnum and medium, down the back of the metatarsus, to the arterial arch formed by the plantar branches of the posterior tibial artery.

#### GREAT METATARSAL ARTERY.

(FIG. 160. 5.)

The great metatarsal artery originates at the proximal and external aspect of the large metatarsal bone; lying in the groove between it and the small metatarsal bone, it insinuates itself between them, passing under the osseous nodule of the latter; it gains the back of the large bone, passing through the bifurcation of the suspensory ligament, and finally anastomoses with the internal and sometimes the external interosseous plantar branches of the posterior tibial; thus forming the *sesamoidean arch*, whence spring the external and internal digital arteries, which gain the sides of the fetlock.

## DIGITAL ARTERIES.

The digital arteries, which are alike in the fore and hind limbs, originate at an acute angle below the bifurcation of the suspensory ligament, in front of the flexor tendons, passing over the inner and outer sides of the fetlock joint, accompanied by satellite veins and nerves; the artery being central, and the nerve posterior. Each runs down the side of the digit, inside the lateral cartilage, to the superior border of the ala of the os pedis, thence they reach the tendinous surface of the bone, terminating at the plantar foramina on either side of the insertion of the flexor pedis perforans. They supply numerous twigs to the flexor and extensor tendons, fetlock pad and joint, and give off the following branches, which are usually regarded as the arteries of the foot—

Perpendicular.		Artery of the Frog.
Transverse.		Preplantar unguial.
Plantar unguial.		

The PERPENDICULAR artery, which arises at right angles, below the middle of the os suffraginis, descends on the side of the digit, inclining forwards, and terminates above the coronary ligament by anastomosing with its fellow, their union forming the *superficial coronary arch*, whence spring about twenty branchlets, which descend to the coronary substance.

The TRANSVERSE artery, given off under the lateral cartilage, passes forward between the front of the bone and the extensor tendon, and inosculates with its fellow, forming a second arch—the *deep coronary arch* (superior coronary circle), from which spring several branches to the neighbouring parts, some passing on to the superficial coronary arch; a second branch inosculates with its fellow posteriorly just above the navicular bone.

The ARTERY OF THE FROG arises behind the pastern joint at the superior part of the lateral cartilage, entering the sensitive frog. It divides into anterior and posterior; the latter also assists in supplying the lateral cartilage.

The PREPLANTAR UNGUAL, or LATERAL LAMINAL, given off at the posterior aspect of the ala of the distal phalanx, passes through the notch and foramen between the retrorsal and basilar processes, and along the preplantar groove in the wall of the bone, at the anterior extremity of which it terminates by several branches, which enter the pedal bone, and anastomose with the

circulus arteriosus. At its origin, a *retrograde branch* passes to the bulb of the frog; and after traversing the preplanter groove, it gives off a *second retrograde*, which supplies the external part of the lateral cartilage, one twig inosculating below with the circumflex artery. It supplies numerous ascending and descending branches which ramify in the sensitive laminæ, anastomosing with those of the coronary arch and circumflex artery.

The PLANTAR UNGUAL is the terminal branch of the digital; it passes through the plantar foramen on the tendinous surface of the os pedis, and enters the bone, within which it inosculates with its fellow, forming the *circulus arteriosus*, or *plantar circle*, from which spring ascending and descending branches. The former are the *anterior laminals*, which leave the bone through numerous apertures on its wall, and ramify among the sensitive laminæ; the latter are the *inferior communicating arteries*, which average fourteen in number; they pass through the foramina situated just above the edge of the os pedis, and unite outside to form the *circumflex artery*, which runs round the toe, giving off *ascending branches* to the sensitive laminæ, and about fourteen descending ones, the *solar arteries*, which supply the sensitive sole, uniting posteriorly to constitute the *inferior circumflex artery*.

#### ANTERIOR AORTA.

(FIG. 154. e.)

The anterior aorta is rather more than one inch in length, and passes obliquely upwards and forwards, between the layers of the anterior mediastinum, over the right auricle, under the trachea, and to the left of the anterior vena cava; after furnishing a few insignificant twigs to the pericardium and mediastinum, it divides into the right and left arteria innominata, or brachial arteries.

#### BRACHIAL ARTERIES.

(FIG. 154. i, k.)

The brachial arteries separate at an acute angle, the left being uppermost, and pursue a diverging course towards the anterior aperture of the thorax, whence they proceed to the pectoral limbs, winding round the first ribs, and below the scalenus muscles; the right one gives off the *common carotid trunk*; hence it is distinctively known as the brachio-cephalic artery, and is larger

than the left. Both pass forward between the layers of the anterior mediastinum, the right below, the left to the side of the trachea, and partly under the œsophagus.

The following are the arteries given off alike by both brachials. The first four arise within the thorax, the next two at its entrance, while the last two arise externally.

Dorsal.	External thoracic.
Superior cervical.	Inferior cervical.
Vertebral.	Prescapular.
Internal thoracic.	Subscapular.

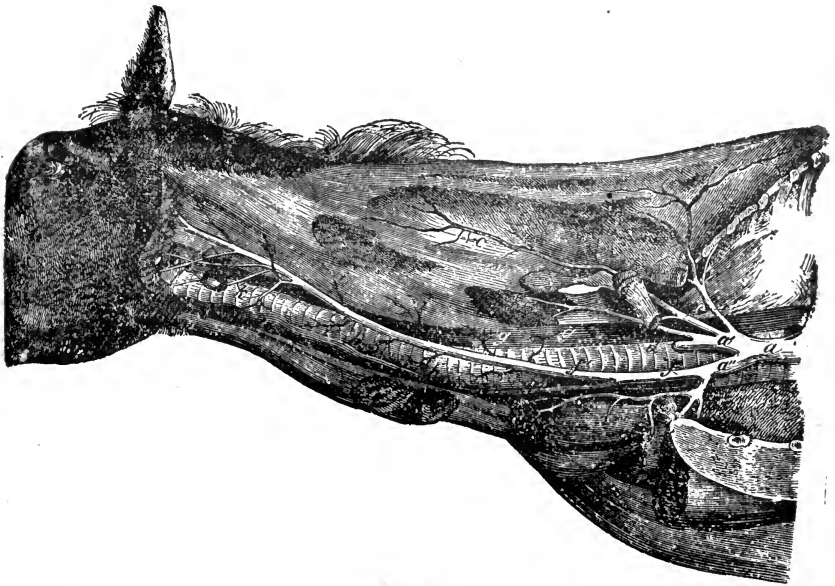


FIG. 161.

Arteries of the neck exposed on the left side. *a*, Anterior aorta; *a'*, Left brachial; *a''*, Right brachial, or brachio-cephalic; *b*, Left dorsal; *c, c'*, Superior cervical; *d*, Vertebral; *e*, Inferior cervical; *f*, Cephalic or common carotid; *f'*, Left, and *f''*, Right carotid; *g, g'*, Œsophageal twigs; *h, h'*, Tracheal twigs; *i, i'*, Muscular twigs; *k*, Thyroid; *l*, Thyro-laryngeal; *m*, Branch to Parotid gland.

The DORSAL artery runs on the outer side of the trachea, œsophagus, sympathetic nerve, and longus colli muscle, through the second intercostal space, reaching the withers; it supplies the muscles of that region. The anterior branch goes to the splenius and complexus major, anastomosing with the terminal twigs of the cervical. Within the thorax, the dorsal gives off a few twigs to the mediastinum, and a large *subcostal* branch

which furnishes usually from the second to the fourth anterior *intercostal* arteries.

The SUPERIOR CERVICAL artery arises anterior to the dorsal, sometimes along with it, having the same relations until it passes through the first intercostal space. It then runs upwards along the ligamentum nuchæ, covered by the complexus major, as far as the vertebra dentata, distributing branches to the muscles of the neck, and anastomosing with the dorsal and vertebral arteries. Within the thorax, it gives off the first *intercostal* artery, and a twig to the mediastinum.

The VERTEBRAL artery arises opposite the first rib, gains the outer side of the trachea and œsophagus, and leaves the thorax, passing under the transverse process of the seventh, and through the foramina in the transverse processes of the sixth to the second cervical vertebræ, covered by the intertransversalis colli. On reaching the atlas it anastomoses with the retrograde branch of the occipital artery, or *ramus anastomoticus*, which comes through the posterior foramen on the wing of the atlas. Here it is covered by the obliquus capitis posticus muscle. It supplies branches to the muscles of the neck, also to the spinal cord and its membranes, through the intervertebral foramina.

The INTERNAL THORACIC, PECTORAL, or MAMMARY artery, originates at the first rib, opposite the vertebral. It descends to the second bone of the sternum, passing over the costal cartilages to the ensiform, where it splits into anterior abdominal, and asternal branches, after giving twigs to the pericardium and mediastinum; and intercostal branches, which are distributed to the pectoral muscles, anastomosing with the external thoracic and first seven intercostal arteries. In the young it supplies the thymus gland. The *anterior abdominal* leaves the thorax at the ensiform cartilage, penetrates the rectus abdominis, and anastomoses with the epigastric artery. The *asternal* artery winds round the cartilages of the false ribs, crossing the digitations of the transversalis abdominis, and terminating in the thirteenth intercostal space, by anastomosing with the intercostal artery; it supplies the diaphragm and transversalis muscles.

The INFERIOR CERVICAL artery is given off as the brachial leaves the thorax, passing between the jugular confluent and the pectoralis parvus, and dividing into ascending and descending branches. The former runs between the levator humeri and subscapulo-hyoideus, supplying the lymphatic glands and adjacent



muscles; the latter lies between the pectoralis anticus and levator humeri, terminating in the pectoral muscles.

The EXTERNAL THORACIC or MAMMARY artery arises close to the inferior cervical, turns round the anterior border of the first rib, and passes along the internal aspect of the pectoralis magnus and parvus, a small branch accompanying the spur vein, and ramifying in the panniculus.

The PRESAPULAR artery arises from the brachial, in front of the tendon of the subscapularis, passing between it and the antea-spinatus; it is accompanied by a vein and nerve to the dorsum scapulæ, supplying the shoulder joint, pectoralis parvus, scapular muscles, and flexor brachii tendon.

The SUBSCAPULAR artery arises at right angles from the brachial, just before it becomes the humeral, near the interstice separating the subscapularis and teres internus muscles. It passes up the inner side of the caput magnum, and terminates at the dorsal angle of the scapula, supplying branches to the latissimus dorsi, scapular, and lateral thoracic muscles; also the *nutrient scapular*, and the *scapulo-humeral*, or *posterior circumflex* artery, which passes outwards behind the shoulder joint, under the caput magnum and postea-spinatus, terminating in the external muscles of the region.

When the brachial artery reaches the humerus it assumes the name of the humeral artery, just as the external iliac becomes the femoral as it passes the pelvic brim.

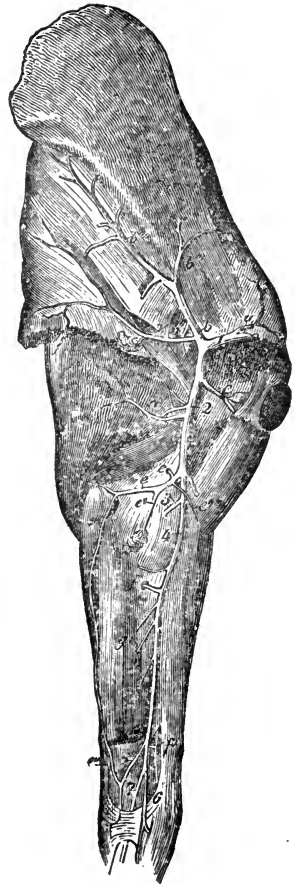


FIG. 162.

Arteries of the anterior limb—viewed from inside. 1, Brachial; 2, Humeral; 3, Anterior radial; 4, Posterior radial; 5, Recurrent radial; 6, Radio-palmar; 7, Large metacarpal; a, Prescapular; b, Subscapular; b', Branch to latissimus dorsi; b'', Posterior circumflex; b''', Scapular nutrient and muscular branch; b''', Main branch supplying the muscles; c, Anterior circumflex; d, Humeralis profunda; e, Cubital; e', Nutrient artery of humerus; e'', Branch to inferior brachial glands; e''', Descending branch forming superior carpal arch; e''', Anterior subcutaneous; f, Interosseous; f', Branch to the carpus; g, Muscular branches.

## HUMERAL ARTERY.

(FIG. 162. 2.)

The humeral artery, the continuation of the brachial, descends obliquely backwards, along the inner side of the humerus; just above the elbow joint it divides into anterior and posterior radial arteries, or more correctly speaking it gives off the former, and is continued by the latter. Its principal branches are as follows:—

Anterior circumflex.		Cubital.
Humeralis profunda.		Coraco-radial.
Anterior radial.		

The PREHUMERAL or ANTERIOR CIRCUMFLEX artery passes between the two heads of the coraco-humeralis, reaches the front of the humerus, and terminates in the levator humeri, giving twigs to the flexor brachii, coraco-humeralis, and the shoulder joint, anastomosing with the posterior circumflex.

The ARTERIA HUMERALIS PROFUNDA arises near the conjoined tendon of the latissimus dorsi and teres internus, is divided into two chief branches, which are distributed to the caput magnum and medium, the anconeus, humeralis obliquus, and extensor metacarpi magnus, anastomosing by one branch with the anterior radial artery.

The CUBITAL or ULNAR artery passes backwards beneath the scapulo-ulnaris, along the lower border of the middle head of the triceps extensor, down the forearm, between the external and middle flexors of the metacarpus, with the cubital nerve and vein, inosculating at the knee with the recurrent branch of the posterior radial artery, so forming the *superior carpal arch*. It gives off branches, to the caput medium, scapulo-ulnaris, pectoralis transversus, brachial fascia, and flexors of the leg; also a *nutrient* artery to the humerus, and twigs to the elbow joint, with a small anterior *subcutaneous* branch.

The CORACO-RADIAL artery, given off nearly opposite to the last, passes forwards to the flexor brachii muscle, dividing into ascending and descending branches.

The SPIRAL or ANTERIOR RADIAL artery is given off at an acute angle, just above the condyle of the humerus. It descends over the anterior surface of the elbow joint, and beneath the flexor muscles of the fore-arm and origin of the extensor metacarpi, where it meets the radial nerve. They travel together in

front of the radius, and approach the knee below the extensor p $\acute{e}$ dis. It divides into numerous branches, which are distributed to the capsular ligament of the carpus and extensor muscles, anastomosing with the interosseous branch of the posterior radial artery.

## POSTERIOR RADIAL ARTERY.

(Fig. 162. 4.)

The posterior radial is the continuation of the humeral artery. It passes down the inner side of the fore-arm, with a vein and nerve, inclining backwards beneath the flexor metacarpi internus, and is sometimes described as dividing at the distal end of the radius into large and small metacarpals; it can be felt just behind the insertion of the flexor brachii. It supplies twigs to the elbow joint, which anastomose with those of the ulnar, and muscular branches to the posterior region of the arm, with the following named branches:—

Interosseous.		Radio-palmar.
		Recurrent radial.

The INTEROSSEUS artery of the fore-arm comes off near the radio-ulnar arch, through which it passes outwards, crossing the posterior surface of the radius below the perforans. It then descends in the radio-ulnar groove, covered by the extensor suffraginis, and inosculates with the anterior radial, forming a plexus above the carpus; it yields branches to the elbow joint and flexor muscles, also the *nutrient radial*, to supply the radius.

The RECURRENT RADIAL artery is a small branch given off just above the carpus; passing outwards and downwards, under the flexor metacarpi medius, it inosculates with the cubital and forms the *superior carpal arch*, from which a branch descends in the thickness of the annular ligament, to inosculate with the radio-palmar, below the carpus, and form the *inferior carpal arch*.

The RADIO-PALMAR or SMALL METACARPAL artery is given off at an acute angle. It passes the inner and posterior aspect of the carpus, external to the posterior annular ligament, which separates it from the large artery. About the head of the metacarpus it crosses from the inner to the outer side at the back of the leg, inosculating with a descending branch from the superior carpal arch, and so forming the *inferior carpal arch*; whence

originate two anterior and two posterior interosseous palmars. The *anterior* ones pass round the heads of the small metacarpal bones, and along the grooves between them and the large bone, anastomosing with the spiral above, and a branch of the large metacarpal artery below. The *posterior interossei* descend on either side of the suspensory ligament, inosculating near the distal end of the metacarpus with branches from the large metacarpal artery. One of them gives off the nutrient artery of the great metacarpal bone.

#### LARGE METACARPAL ARTERY.

(FIG. 162. 7.)

This is the continuation of the posterior radial artery. It runs beneath the posterior annular ligament in company with the flexor tendons, afterwards descending to their inner side, along with the internal metacarpal nerve and vein. Above the fetlock it passes between the tendons and suspensory ligament, dividing into the *external* and *internal digital* arteries. At its bifurcation it gives off a *recurrent* branch, which divides and ascends, one branch on the *inner*, another on the *outer lateral* aspect of the suspensory ligament, anastomosing with the posterior interosseï. From the sesamoidean arch, thus formed by union of all the posterior arteries of the region, the digital arteries may be said to arise, and likewise small transverse branches, which encircle the fetlock joint. The metacarpal artery gives off branchlets to the tendons and ligaments during its course.

The circulation of the digit is the same as in the pelvic limb.

#### CEPHALIC AND CAROTID ARTERIES.

(FIG. 161. *ff' f''*.)

The right brachial artery, besides supplying branches corresponding to those of the left, gives off the *common carotid* or *cephalic* artery, which is detached at an acute angle, and directed forwards under the trachea and above the anterior vena cava. On reaching the anterior opening of the thorax, it bifurcates, forming the Left and Right carotids, which pass up the side of the neck, diverging as they ascend, at first below, afterwards on the sides of the trachea, to which they are attached by areolar tissue. At the middle of the neck, they reach the posterior

tracheal aspect, and are continued to the level of the larynx, where they break up. Throughout their course, they are accompanied by the par vagum, cervical portion of the sympathetic, and inferiorly by the recurrent nerves, all being enclosed in the same sheath. The arteries are covered at the lower part of the neck by the scalenus and levator humeri; in the middle by the subscapulo-hyoideus, which separates them from the jugular vein; and they are related with the rectus capitis anticus major, and longus colli superiorly. The carotid and jugular are usually separated by slips of the subscapulo-hyoideus, but at the entrance of the thorax they contact, the artery lying superiorly. The carotids give off several small branches to the muscles of the neck, twigs to the trachea and œsophagus, and near their termination, the thyroid and thyro-laryngeal arteries. The *thyroid* artery enters the inferior part of the thyroid gland, to which it is distributed. The *thyro-laryngeal* arises just above the latter, opposite the upper tracheal ring, winds round the trachea, and divides into branches, supplying the thyroid body, pharynx, and larynx.

The carotid artery terminates by a trifurcation, forming the following important arteries:—

Occipital.		Internal carotid.
		External carotid.

## OCCIPITAL ARTERY.

(Fig. 163. 1.)

The occipital artery comes off at the carotid trifurcation. At first it accompanies the internal carotid, then crosses it, and reaches the under surface of the wing of the atlas, at the back of the guttural pouch, passing between the submaxillary gland and anterior straight muscles of the head, through the external anterior foramen of the atlas, and at the upper surface of the latter it divides into the *cerebro-spinal* and *musculo-occipital*. It is crossed by the par vagum and spinal accessory nerves and the cervical portion of the sympathetic chain, and accompanied by divisions of the inferior branch of the spinal nerves. Its branches are these:—

Prevertebral.		Ramus anastomoticus.
Mastoid.		Musculo-occipital.
		Cerebro-spinal.

The PREVERTEBRAL artery comes off as it crosses the internal carotid, and divides into muscular and meningeal branches, the *muscular* going to the anterior straight muscles of the head and occipito-atloidean articulation. The *meningeal* are small *superior* and *inferior* branches, which are distributed to the dura mater through the foramen lacerum basis cranii, and the condyloid foramen.

The MASTOID artery leaves the trunk opposite the pre-vertebral, is directed to the mastoid foramen of the temporal bone, passing over the styloid process of the occipital, under the obliquus capitis anticus. It gains the parieto-temporal conduit, and inosculates with the meningeal branch of the internal maxillary artery. It supplies the temporal muscle, and the dura mater.

The RAMUS ANASTOMOTICUS\* is detached at the under surface of the wing of the atlas; it passes backwards through the posterior foramen under the obliquus capitis posticus, and inosculates with the vertebral artery. It supplies numerous muscular twigs, and furnishes a direct communication between the carotid and vertebral arteries.

The MUSCULO-OCCIPITAL artery arises from the occipital, in the alar gutter; covered by the obliquus capitis posticus, it passes transversely outwards to the posterior straight muscles, and divides into *ascending* muscular and cuticular branches for the occipital region, and *descending*, which anastomose with the superior cervical artery.

The CEREBRO-SPINAL artery springs from the occipital in the alar gutter, and enters the neural canal through the internal atloid foramen, traverses the spinal dura mater, dividing on the inferior surface of the cord into an *anterior branch*, which passes forwards, anastomosing by convergence with its fellow from the opposite side, to form the *basilar trunk*; and a *posterior branch*, which, after a short backward course, likewise anastomoses with its fellow from the opposite side, constituting the *middle spinal artery*.

#### INTERNAL CAROTID ARTERY.

(FIG. 163. 2.)

This, the second terminal of the common carotid, is directed upwards towards the base of the skull, to the outer side of the

\* [This artery is described as inconstant and variable; doubtless it is the latter, but hitherto I do not recollect ever to have sought for it in vain.—ED.]

anterior straight muscles, accompanied in the first part of its course by the occipital artery, the carotid being more posterior. At the origin of the prevertebral and mastoid branches, it is inflected forwards, crossing the occipital behind the cornu of the os hyoides; it passes to the foramen lacerum basis cranii, at first lying in a fold of the guttural pouch, along with the superior cervical ganglion and a branch of the sympathetic which enters the cranium; it is crossed by the nerves which form the guttural plexus. Passing through the foramen lacerum, it enters the cranial cavity to assist in supplying the brain. For description of the cranial portion of this artery, see the description of the brain itself.

## EXTERNAL CAROTID ARTERY.

(FIG. 163. 3.)

The external carotid artery is the continuation of the carotid itself, being deeply buried between the guttural pouch and parotid gland. It passes forwards and upwards, until it reaches the cornu of the os hyoides, passing between it and the hyoideus magnus, and curves upwards towards the neck of the condyle of the lower jaw, where it divides into *superficial temporal* and *internal maxillary* arteries, the latter being its continuation. In the first part of its course it has the guttural pouch, glossopharyngeal, and superior laryngeal nerves on its inner, and the superior belly of the digastricus and the hypo-glossal nerve on its outer aspect. From it spring the four following branches:—

Glosso-facial.		Posterior auricular.
Maxillo-muscular.		Superficial temporal.

The GLOSSO-FACIAL or SUBMAXILLARY artery arises before the carotid passes between the hyoid cornu and the hyoideus magnus. It passes the anterior extremity of the submaxillary gland, runs along the upper border of the digastricus, crosses the outside of Wharton's canal, reaches the ramus of the lower jaw within the maxillary space, and winds round it subcutaneously, reaching the cheek, where it ascends in front of the masseter muscle, and at the maxillary spine terminates in ascending and descending branches; the latter, or *lateral nasal*, passes forwards; the former divides into *dorsal nasal*, which goes inwards, and *angular artery* of the eye, which passes backwards to supply the orbicularis palpebrarum, inosculating with branches from the superior dental artery. In

addition to twigs supplied to the submaxillary gland and facial muscles, five branches are given off, the pharyngeal, lingual, sublingual, and inferior and superior labial or coronary arteries.

The *pharyngeal*, or *ascending pharyngeal*, is given off near the origin of the glosso-facial, passing obliquely upwards between the cornu of the os hyoides and the hyo-pharyngeal muscle. It takes a flexuous course towards the pterygoid process, terminating in the velum palati, and giving off *ascending* and *descending* branches to the walls of the pharynx.

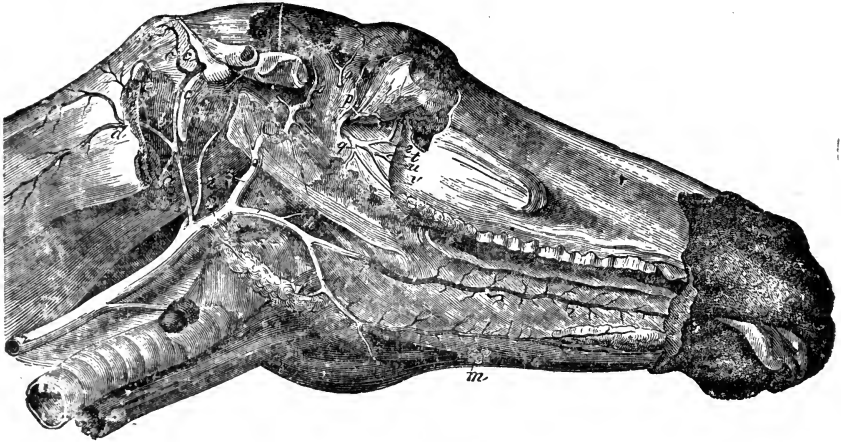


FIG. 163.

Arteries of the head—the left maxillary ramus being removed. 1, Occipital; 2, Internal carotid; 3, External carotid; a, Branch to submaxillary gland; b, Prevertebral; c, Mastoid; c c, Muscular twigs; d, Ramus anastomoticus; e, Occipital gaining alar gutter; f, Branch to submaxillary gland; g g, Laryngeal branches; A, Glosso-facial; h, Pharyngeal; i t, Lingual; k, Branch to submaxillary gland; l l, Sublingual; m, Branch to lymphatic gland; B, Continuation of external carotid—it becomes the internal maxillary at the bend; n, Spheno-spinal; o o, Deep temporals; p, Ophthalmic; q, Buccal; r, Orbital branch of dental; s, Dental; t, Spheno-palatine; u, Palatine; v, Staphyline.

The *lingual*, almost as large as the parent artery, originates near the cornu of the hyoid bone, passes under the hyo-glossus brevis in company with the glosso-pharyngeal nerve, crosses the corniculum, and is thence prolonged almost to the free extremity of the tongue in a very tortuous manner. This artery, sometimes called the *ranine*, is buried in the interstices between the hyo-glossal and genio-hyo-glossal muscles in company with branches of the lingual and hypo-glossal nerves.

The *sublingual* artery is given off at the anterior extremity of the submaxillary gland, passing to the external surface of the mylo-hyoideus, on which it runs forwards, and along the inferior surface of the sublingual gland, supplying it as well as the genio-



hyo-glossus and genio-hyoideus muscles; it is then continued along the side of the frænum, where it breaks up, its branches being chiefly distributed to the mucous membrane. The sub-lingual gland may be supplied by the *submental* branch of the lingual.

The *inferior labial* or *coronary* artery is the first branch given off after the glosso-facial rounds the jaw; arising near and passing under the depressor labii inferioris, it goes to the under

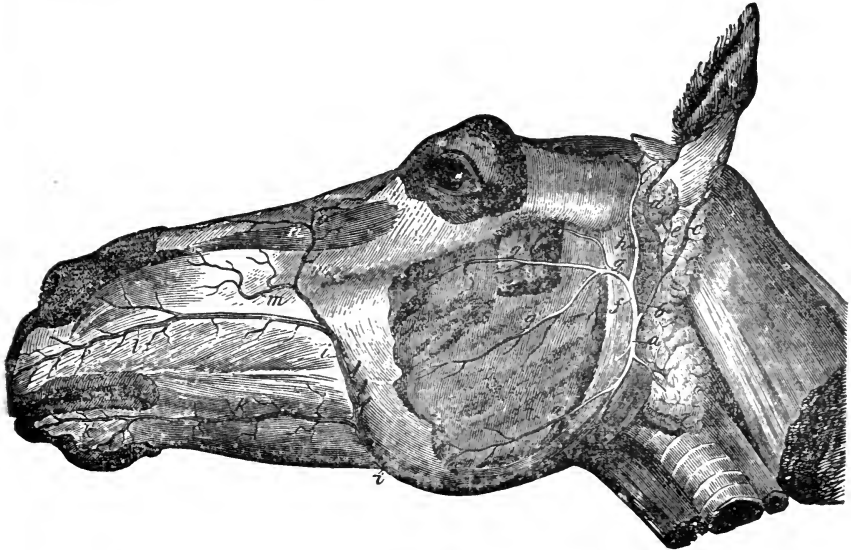


FIG. 164.

Facial arteries of the left side. *a*, Maxillo-muscular; *a'*, Posterior masseter; *b, c*, Posterior auricular; *d*, Anterior branch of it; *e*, Inferior auricular branch; *f*, Superficial temporal; *g*, Subzygomatic; *g'*, Transverse facial; *g''*, Masseter; *h*, Anterior auricular; *i i*, Facial portion of glosso-facial; *k k*, Inferior coronary; *l*, Superior coronary; *m*, Lateral nasal; *n*, Dorsal nasal; *o*, Angular artery of the eye.

lip, supplying the buccinator, depressor labii inferioris, the glands, the cuticle, and buccal membrane, anastomosing with its fellow of the opposite side.

The *superior labial* or *coronary* artery is larger than the inferior. It springs from the trunk, near the infraorbital branch of the superior maxillary nerve, passes under the dilatator naris lateralis and levator labii superioris, anastomosing with the palato-labial branch of the internal maxillary, and supplying twigs to the nasal tissues, upper lip, and buccinator muscle.

The MAXILLO-MUSCULAR artery arises just above where the main trunk passes between the hyoideus magnus and the cornu

of the hyoid bone, passes down behind the posterior border of the jaw, covered by the parotid gland, and divides into superficial and deep branches; the latter is the *pterygoidean* artery, which passes into the pterygoid muscles, after furnishing branches to the neighbouring organs; the former is the *posterior masseter*, which winds round the posterior border of the lower jaw, about the insertion of the sterno-maxillaris. It passes into the masseter muscle, anastomosing with the masseter branch of the subzygomatic artery.

The POSTERIOR AURICULAR artery springs from the posterior aspect of the carotid, behind the maxillo-muscular, ascends under the parotid, to the back of the base of the ear, giving off numerous ascending branches; it passes up the posterior aspect of the concha between the cartilage and the skin, the terminal twigs anastomosing with each other. Besides supplying the parotid and retrahentes muscles, this artery gives off a large branch, which divides into deep and superficial. The *deep* one, after giving a small twig to the middle ear, which enters by the stylo-mastoid foramen, passes between the external auditory meatus and the mastoid process of the temporal bone, dips into the adipose tissue below the ear, and supplies the deep conchal muscles. The *superficial* branch passes to the external side of the concha, gaining the interior of the conchal cartilage, with the middle auricular nerve.

The SUPERFICIAL TEMPORAL artery ascends between the parotid gland, guttural pouch, and the neck of the inferior maxilla, dividing after a short course into anterior auricular and subzygomatic branches. The *anterior auricular* passes upwards to the anterior aspect of the root of the ear, between the temporo-maxillary articulation, and the upper part of the parotid gland. After giving off twigs to the temporalis muscle, and to the interior of the concha and its cuticle, it is lost in the attolentes muscles. The *subzygomatic* artery is much larger than the anterior auricular. Passing under the parotid, it rounds the posterior border of the inferior maxilla just below its condyle, and then terminates by two branches of nearly equal volume, the one being superior and superficial, the other inferior and deep. The former is the *transverse facial*, which runs under the zygomatic ridge of the anterior border of the masseter, where it is lost, anastomosing with the maxillo-muscular and glosso-facial arteries. The latter is the *masseter artery*, which plunges into the substance of the masseter muscle, anastomosing with the maxillo-muscular artery.

## INTERNAL MAXILLARY ARTERY.

(FIG. 163. B.)

The continuation of the external carotid is the internal maxillary artery, which commences at the inner side of the temporo-maxillary articulation, just below the condyle, passes between the neck of the lower jaw and the cornu of the os hyoides, where it describes two successive curves, the first convex backwards, the second convex forwards. It passes through the pterygoid foramen in the sphenoid bone, and gains the orbital hiatus; crossing the floor of the orbit, it enters the maxillary hiatus, and palatine conduit, where it takes the name of the *palatine artery*. The internal maxillary gives off the following branches before entering the pterygoid foramen:—

Inferior dental.	Tympanic.
Pterygoid fasciculus.	Spheno-spinal.
Posterior-deep temporal.	

The first two of these pass downwards, the rest upwards.

The **INFERIOR DENTAL** artery, given off from the middle of the first curve of the internal maxillary, passes downwards and forwards between the internal and external pterygoids, enters the dental foramen on the inner surface of the ramus of the lower jaw, accompanied by the dental branch of the inferior maxillary division of the fifth nerve, passes forward in the bone, supplying the molars, and dividing at the neck of the jaw into two branches, one supplying the tush and incisors, the other making its exit through the mental foramen, to anastomose with the inferior coronary artery, and terminate in the gums and lower lip.

The **PTERYGOIDEAN FASCICULUS** is a bundle of small arteries which arises from the second curve, and is distributed chiefly to pterygoid, the tensor and levator palati muscles.

The **TYMPANIC** artery is a very small branch which passes into the petrosal bone at the base of the Eustachian tube, and gains the walls of the tympanum.

The **SPHENO-SPINAL** or **GREAT MENINGEAL** artery enters the cranial cavity by the foramen lacerum basis cranii, passing under the dura mater, to which it supplies numerous branches; it gains the parieto-temporal conduit, inosculating with the mastoid branch of the occipital artery.

The **POSTERIOR DEEP TEMPORAL** artery arises just as the main

artery enters the pterygoid foramen ; it passes directly upwards, ramifying in the substance of the temporalis muscle, and anastomosing with the masseter by a small branch which passes through the sigmoid notch.

In the pterygoid foramen the internal maxillary artery gives off two branches :—

Anterior deep temporal.     |     Ophthalmic.

The ANTERIOR DEEP TEMPORAL artery, given off in the pterygoid foramen, passes upwards along the anterior border of the temporalis muscle, in which it becomes buried, supplying, in addition, the attolentes and the neighbouring tissues.

The OPHTHALMIC artery is a large branch, which leaves the internal maxillary in the pterygoid foramen, near to and sometimes with the last. By the orbital hiatus it gains the lower part of the orbital fossa, forms a circular loop upon itself, and then enters the cranial cavity through the internal orbital foramen, and terminates in *meningeal* and *internal lateral nasal* branches. The former, after distributing branches to the dura mater and *falx cerebri*, anastomoses at the base of the crista galli, with its fellow and the anterior cerebral artery. The *internal lateral nasal* artery passes through the cribriform plate of the ethmoid bone, enters the nasal chamber, and is distributed over the ethmoidal volutes and septum nasi. The ophthalmic gives off *muscular branches* to the muscles of the eye; the *ciliary arteries*, which go to the eyeball, and are chiefly distributed to the choroid coat, ciliary processes and iris; the *arteria centralis retinae*, which passes through the axis of the optic nerve; the *supraorbital* artery, which passes up the internal wall of the orbital fossa in company with the vein and nerve, and through the supraorbital foramen, to be distributed to the skin of the forehead and muscles of the frontal region; the *lachrymal* artery, which runs between the muscles and upper wall of the fossa, and terminates in the lachrymal gland and upper eyelid; finally, *cranial* branchlets, which are distributed over the anterior lobe of the cerebrum, anastomosing with the anterior cerebral artery.

The branches given off by the internal maxillary artery, after leaving the pterygoid foramen, are :—

Buccal.		Superior dental.
Staphyline.		Spheno-palatine.

The **BUCCAL** artery arises just before the orbital hiatus; it passes between the inferior maxilla and the pterygoid muscles, supplying the molar glands, various muscular branches, and a twig to the fatty cushion of the orbital fossa.

The **STAPHYLINE** artery, very small, accompanies the nerve of the same name through the staphyline groove to the soft palate.

The **SUPERIOR DENTAL** artery, a large branch, leaving the orbit through the maxillary hiatus, enters the maxilla, passing through the dental canal, along the tops of the molar fangs; at the infra-orbital foramen, it divides into two branches, one passing through the foramen to be distributed over the cheeks, anastomosing with the superior labial, the other terminating in the tush and incisors of the upper jaw. The dental gives off an *orbital* branch to supply the lachrymal sac, and other ocular structures.

The **SPHENO-PALATINE** artery is a short, thick trunk, which passes through the spheno-palatine foramen, and divides into branches which are distributed over the walls of the nasal chamber.

#### PALATINE ARTERY.

(FIG. 163. u.)

The continuation of the internal maxillary is the palatine artery, which gains the posterior part of the hard palate through the palatine foramen; it then runs in a furrow along the side of the palate, and inosculates with its fellow, forming an arch, from which is given off the *palato-labial* artery, which passes through the foramen incisivum to assist in supplying the gum and lips. The arterial arch passes under the free extremities of two small cartilaginous processes, one on each side, which are attached posteriorly to the bony palate.

#### VEINS.

Veins are vessels which return blood to the cardiac auricles, and consist of two sets—the *pulmonary*, which transmit arterial blood from the lungs to the left auricle, and the *systemic*, which convey venous blood from the somatic capillaries to the right auricle. They are larger and more numerous than the arteries. The smallest veins commence at the capillaries, and converge to form larger ones, terminating in trunks which enter the heart.

Veins are superficial and deep. The former lie immediately below the skin, and are mostly unaccompanied by arteries; the latter are situated deeply, and usually related with arteries, and hence they are called *satellite veins*. Two veins sometimes accompany one central artery. Veins anastomose more freely than arteries; and in the head they form dilated pouches or sinuses, and plexuses in the palate and foot; their coats are thinner, but stronger than those of arteries, and collapse when cut across or emptied. After death, they are usually distended with blood, their walls being thin, semi-transparent, and elastic, generally consisting of three tunics, arranged for the most part like those of an artery.

The majority of veins are provided with valves, somewhat similar to the semilunar ones at the origins of the great arteries. These are folds of the lining membrane, strengthened by fibrous tissue, and present an adherent and a free semilunar border when the valves are shut. When distended they have a concave surface towards the heart, and a convex one towards the origin of the vein; they may consist of from one to five, but generally of two flaps, opposed to each other. The walls of the veins immediately above the valves are pouched into sinuses, which produces a knot or swelling. Their use is to favour the course of the blood and oppose its reflux from the heart. During its normal flow, they are placed against the walls, offering no obstacle to the current. When the current is intercepted, the valves are pressed back, the reflux column of blood gets between the concave surfaces of the flaps and the dilated pouches, pressing the former inwards until their edges, meeting in the centre, arrest the retrograde current. Valves are irregularly distributed, and are most numerous near the convergent points; they are absent in the pulmonary, cranial, spinal, pedal, and osseous veins, in the foetal umbilical vessels, and *venæ cavæ*. They are only rudimentary in the portal, rare in the azygos, spermatic, uterine, and ovarian veins; but numerous, large, and complete in those of the extremities. Their coats, like the arterial, are supplied with capillary *vasa vasorum*. Their nerves, few and only traceable on the larger vessels, come from the sympathetic system. Veins may originate from arteries without the intervention of capillaries, as in the erectile tissue of the penis.

## PULMONARY VEINS.

The pulmonary veins originate from the capillaries of the corresponding arteries, in the walls of the air-cells and lesser air-tubes. By repeated union they become larger, ultimately converging to form from four to eight trunks, but usually four, at the root of the lung, which enter the left auricle at various points. They are destitute of valves, which permits easy reflux of blood. These veins differ from others in the kind of blood which they convey, the latter being arterial instead of venous.

## SYSTEMIC VEINS.

The systemic veins commence in the capillaries, which, by repeated union, form, in entering the right auricle, the cardiac or coronary sinus, which opens directly into the cavity of the auricle; and two large trunks, the anterior and posterior venæ cavæ, which terminate by two openings. There is a set of systemic veins which neither go *directly* to the heart nor to the larger trunks; *i.e.*, the veins of the chylo-poietic viscera, which unite to form the vena porta, terminating in the hepatic substance.

## CORONARY VEINS.

The cardiac or coronary veins consist of one vena cordis magna and numerous small venæ cordis minimæ. The *great coronary* is formed by two branches: one is lodged in the right ventricular furrow, being a satellite of the descending branch of the right coronary artery; the other, a satellite of the left coronary artery, passes up the left ventricular furrow to the origin of the pulmonary artery, then backwards, turning round the base of the left ventricle, finally uniting with the right branch near the termination of the posterior cava; the common trunk, or coronary sinus, enters the right auricle, receiving various branchlets from the ventricles and auricles; these have valves at their termination. The *lesser cardiac veins* are numerous, coming chiefly from the walls of the right side, penetrating it by the foramina Thebesii in the right auricle.

The *bronchial* veins, which return the venous blood from the substance of the lungs, are satellites of, and disport themselves as do the bronchial arteries. At the root of the lungs they form one vein, which enters the great coronary just as it terminates in the sinus, or rarely enters the auricle separately.

## POSTERIOR VENA CAVA.

(FIG. 165. 1.)

The posterior vena cava returns the blood from the posterior extremities, abdominal, and pelvic viscera. It corresponds to the posterior aorta, and commences at the entrance of the pelvic cavity by the pair of common iliac veins, runs forwards under the bodies of the lumbar vertebræ, in contact with the psoas parvus, having the posterior aorta on its left. On reaching the superior border

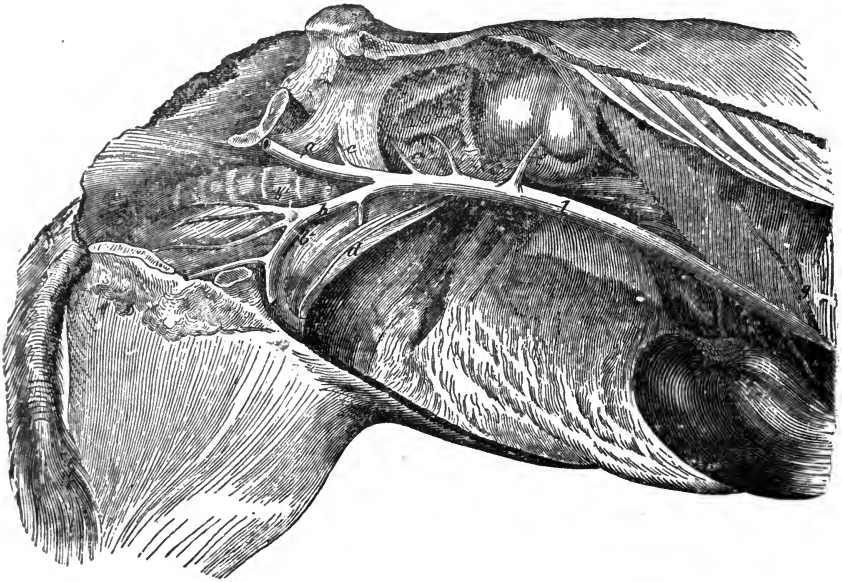


FIG. 165.

Abdominal portion of the posterior cava—the cavity opened on the right side, and most of the viscera removed. 1, Posterior cava; a, Right, b, Left common iliac vein; b, Left external iliac; b', Left internal iliac; c, Right circumflex ilii; c c', Lumbar; d, Left spermatic; e, Right renal; f, Hepatic veins; g, Diaphragmatic vein.

of the liver, it is inclined downwards; and thus leaving the sub-lumbar region, it occupies the anterior fissure of the liver, passes through the foramen dextrum of the diaphragm, into the thoracic cavity, then through the notch in the right lung, covered by a reflection of pleura, and finally enters the right auricle of the heart at its postero-external part. In the abdomen, it is related with the right kidney and pancreas. It receives the satellite veins of the various arteries of the region; but those of the chylo-poietic



viscera form the portal vein, whose blood is conveyed by the medium of the hepatic veins.

The PHRENIC or DIAPHRAGMATIC veins commence in the fleshy portion of the diaphragm, forming two or three large branches, which enter the cava as it passes through the foramen dextrum.

The HEPATIC veins are numerous, and commence by intralobular branchlets in the capillary terminations of the hepatic artery and vena porta. These discharge into sublobular veins, which unite, passing upwards and forwards, unaccompanied by arteries. Leaving the gland in the anterior fissure, they enter the cava by a number of minute oblique openings, and usually one or two larger ones.

## PORTAL VEIN.

(Fig. 166.)

The portal vein commences in the sublumbar region, near the anterior mesenteric artery, concealed by the pancreas, and is formed by the union of three large branches, which return the blood from the visceral organs of digestion. It is directed forwards with an inclination to the right, passes through the pancreatic ring below the vena cava, reaches the posterior fissure of the liver, and, entering the gland, it is distributed like an artery, finally terminating in the hepatic veins. The branches which form the portal vein are the anterior and posterior mesenteric, and gastro-splenic veins.

The *anterior mesenteric* vein is large; its divisions exactly correspond to the branches of the anterior mesenteric artery, while the *posterior mesenteric* vein is made up of branches corresponding to those of the posterior mesenteric artery. The *gastro-splenic* vein is large, formed by the union of the *left gastro-epiploic*, *splenic*, and *gastric satellites* of the splenic artery, and the *posterior gastric* vein. The portal thus formed receives the right *gastro-epiploic* vein, the latter receiving the *pyloric*, *duodenal*, and *pancreatic* veins, all satellites of the corresponding arteries. The *anterior gastric* vein enters separately.

The RENAL veins have very thin walls, and are formed by the union of the veinlets which leave the hilus of the kidney, and a branch from the suprarenal capsule. The left renal having to cross the posterior aorta, is the longer.

The SPERMATIC veins leave the testicles and enter the sper-

matic cord. On reaching the abdomen they communicate freely, forming the *spermatic plexus*, finally terminating in the cava near the renal, by one or two trunks. In the female these veins become the *utero-ovarian*, which follow the exact course of the utero-ovarian arteries.

The LUMBAR veins correspond to their satellite arteries, and result from muscular, spinal, and abdominal parietal branches.

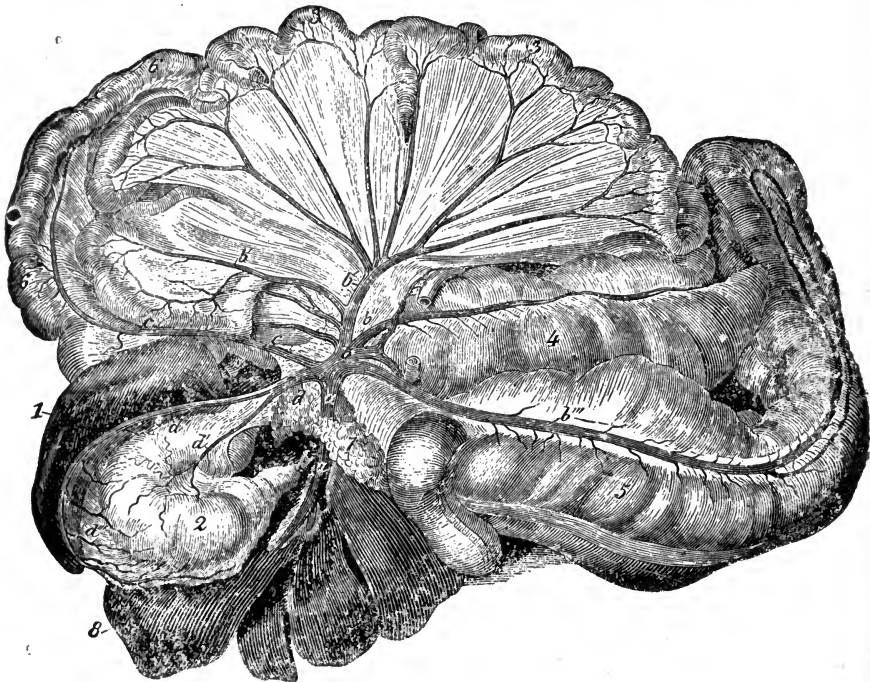


FIG. 166.

Viscera and veins of the portal system. 1, Spleen; 2, Stomach; 3 3, Convolution of small intestine; 4, Cæcum; 5, Great colon; 6 6, Floating colon and rectum; 7, Pancreas; 8, Liver; *a a*, Portal vein; *b*, Anterior mesenteric vein; *b' b'*, Veins of small intestine; *b'*, Ileo-caecal; *b''*, Colic vein; *c c*, Posterior mesenteric vein; *d*, Gastro-splenic; *d'*, Posterior gastric vein; *d''*, Splenic vein; *d'''*, Its gastric branches.

They join the upper surface of the vena cava. The anterior ones often terminate in the vena azygos.

#### COMMON ILIAC VEINS.

(FIG. 165. *a, b*.)

These are two large, short vessels, formed by the union of the *external* and *internal iliacs*, the former collecting the blood from

the posterior extremity, the latter from the hinder part of the trunk. They are lodged in the angles of separation comprised between the external and internal iliac arteries, the right one, the shorter, passing above the external iliac artery to meet the left at the origin of the posterior vena cava. The left one before it joins its fellow passes between the body of the last lumbar vertebra and terminal extremity of the posterior aorta.

## EXTERNAL ILIAC VEIN.

(FIG. 165. B.)

In studying the branches of the *external iliac* vein, it is advisable to commence at the foot. The venous plexuses of the foot unite to form two *digital* veins, and these are succeeded by *three metatarsals*, the common origin of the four veins of the thigh, which are distinguished as subcutaneous and deep. The deep are continued as the *popliteal* and *femoral*, the latter being continued by the external iliac vein.

## VEINS OF THE FOOT.

The veins of the foot are very numerous, and arranged in a superficial and interosseous network. They are valveless, allowing the blood to flow in either direction during sudden emergency. The *external* or *superficial plexuses* are the *solar*, *laminal*, and *coronary*.

The **SOLAR PLEXUS** is remarkable for the equality of the diameter of its veins throughout the extent of the plantar surface of the foot, as well as for the paucity of anastomoses of them with the deep-seated veins. They chiefly terminate in the *large circumflex* vein which accompanies the artery of the same name, and receives also descending twigs from the laminal plexus, as it passes back to the wing of the bone, and thence into the *coronary plexus*. The remaining branches of the solar plexus reach the small central vein, situated around the semilunar ridge, on the solar surface, and terminate also in the coronary plexus.

The **LAMINAL PLEXUS** rests on the sensitive wall of the foot. The branches, uniform in the sensitive laminæ, gradually increase in size as they approach the coronet, where the majority terminate in the *coronary plexus*; the remainder pass down to the circumflex vein.

The CORONARY PLEXUS surrounds the os coronæ and upper part of the os pedis. Extending backwards below the lateral cartilages, the plexus consists of an anterior or middle, and two lateral portions. The *middle coronary* lies in front of the foot, and receives the anterior ascending branches of the laminal plexus. The *lateral coronary* plexus consists of a superficial and a deep portion, the former situated upon, the latter under, the lateral cartilage, and formed by the posterior branches of the laminal, the deep one being joined by veins from the coronet, and from the ligaments and tendons of the region. The *veins of the frog* extend over the external surface of the sensitive frog, ascend the sides of the lateral cartilages, and unite to form a large vein, which, with branches from the superficial and deep coronary plexuses, runs up the lateral aspect of the os coronæ, all uniting near its head to form the digital vein.

The *internal or interosseous veins* of the foot form a system of satellites to the circulus arteriosus and its branches. They pass out of the bone through the plantar foramina, at each side of the tendinous surface; thence up the inner side of the lateral cartilages, finally uniting with the branches of the deep coronary plexus.

#### DIGITAL VEINS.

The digital veins, formed by the union of the deep and superficial coronaries, and veins from the frog, ascend the digit in company with the arteries and nerves, and terminate a little above the fetlock, by uniting to form an arch between the flexor tendons and suspensory ligament. From this arch, the *sesamoidean*, spring the three metatarsal veins. The digitals receive branches corresponding to the perpendicular and transverse divisions of the arteries, as well as twigs from surrounding structures.

#### METATARSAL VEINS.

The metatarsal veins are three in number, internal, external, and deep, originating in the sesamoidean arch. The *internal* is the largest, and appears to be a continuation of the internal digital. It passes up the cannon bone, internal to, and a little in front of, the flexor tendons, accompanied by the internal metatarsal nerve. Nearing the hock, it crosses obliquely to the anterior surface of the joint, where it communicates by a large

transverse branch with the origin of the anterior tibial vein, and then passes along the inner surface of the leg, forming the *anterior root of the internal saphenic vein*. The *external metatarsal* vein occupies a position on the outer side of the flexor tendons, analogous to that of the internal. Towards the superior extremity of the cannon, it anastomoses with the deep vein, then continues its course upwards, accompanied by the plantar arteries, gains the hollow above the tarsus, passing along the femoro-popliteal nerve, and forms the *posterior root of the internal sphenic vein*. The *deep metatarsal* vein originates below the flexor tendons, and passes up underneath the suspensory ligament, to the inner side of the chief interosseous plantar artery. Below the hock, it receives the large anastomotic branch from the external vein, passes through the canal formed between the cuboid and cuneiform bones, finally forming the principal branch of the *anterior tibial vein*.

Above the hock there are four large veins—a deep-seated pair, the anterior and posterior tibial, and a superficial pair, the internal and external saphenic veins.

#### DEEP VEINS.

The ANTERIOR TIBIAL vein is a satellite of the corresponding artery. It is frequently double, arising on the anterior surface of the hock by several branches, the chief one being the deep metatarsal vein. Accompanying the artery, between the tibia and fibula, it joins the posterior tibial to form the popliteal vein.

The POSTERIOR TIBIAL vein commences in the hollow in front of and inside the calcaneum, by branches furnished principally by the two saphenic veins. It passes up the leg, with the posterior tibial artery, and under the popliteus muscle unites with the anterior tibial vein.

#### SUPERFICIAL VEINS.

The superficial or subcutaneous veins are the internal and external saphenics.

The INTERNAL or VENA SAPHENA MAJOR originates by two large roots at the inner part of the hock. The *anterior* root is a continuation of the internal, the *posterior* of the external metatarsal veins; these converge, and form one large vessel on

the internal surface of the leg. It ascends, and terminating near the groin, may either pass through the interstice between the gracilis and sartorius muscles, entering the femoral vein; or it may end, near the origin of the gracilis, by joining the external pudic veins.

The **EXTERNAL SAPHENA** or **VENA SAPHENA MINOR**, originates at the front of the os calcis, anastomosing with the posterior root of the internal saphenic, with which, above the hock and in front of the calcaneum, it forms a large plexus of veins. It also anastomoses with the posterior tibial vein, by a large branch which passes between the tibia and flexor pedis perforans; and it runs along the tendon of the gastrocnemius, in company with a nerve, terminating near the stifle joint in the popliteal vein.

The **POPLITEAL** vein, formed by the union of the anterior and posterior tibials, is a satellite of the popliteal artery, and receives branches corresponding to those given off from the latter. The principal one is the *femoro-popliteal*, which enters with the external saphenic vein.

The **FEMORAL** vein, a satellite of the artery, is the continuation of the popliteal. Its branches are similar to those of the femoral artery, with the addition of the *internal saphena*, which joins about its middle third. The femoral terminates in the external iliac vein.

The **EXTERNAL ILIAC** is thus the continuation of the femoral vein; and is the larger of the two branches which form the common iliac. In its course, this vein, which commences at the pubis, receives no important collateral branches, excepting the *circumflex* vein of the ilium, a satellite of the corresponding artery.

#### INTERNAL ILIAC VEIN.

(Fig. 165. b'.)

The internal iliac vein, which, with the external, forms the common iliac trunk, is very short, and formed by the union of satellites, corresponding to the branches given off from the internal iliac artery.

#### ANTERIOR VENA CAVA.

(Fig. 167. 1, 1.)

The anterior vena cava is the venous trunk, which returns the blood chiefly from the head, neck, fore extremities, and part of

the thorax. This large but short vessel is situated at the anterior part of the thorax, between the layers of the anterior mediastinum, below the trachea, and to the right of the anterior aorta, to which it corresponds. It is formed between the first pair of ribs, by the union of the two jugular and two brachial veins, receiving the internal thoracic, vertebral, superior cervical, dorsal, and the great vena azygos.

The INTERNAL THORACIC, VERTEBRAL, and SUPERIOR CERVICAL veins, are satellites of, and counterparts in distribution to, their corresponding arteries.

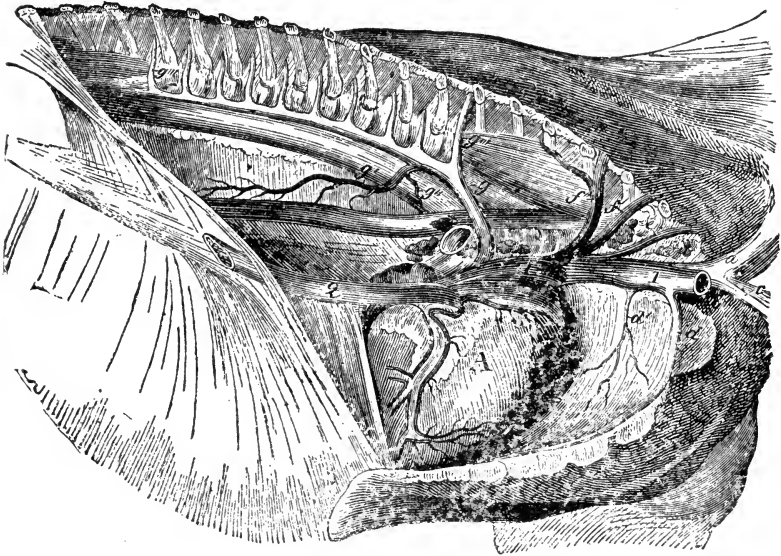


FIG. 267.

Thorax opened on the right side to show the heart and veins. A, Heart, with left coronary vein; 1 1, Anterior cava; 2, Posterior cava; a, Left brachial; b, Right brachial cut; c, Left jugular; d, Internal thoracic; d', A mediastinal vein; e, Right vertebral; f, Dorsal and superior cervical veins discharging together; f', Right superior cervical; f'', Right dorsal; g, Vena azygos; g', Esophageal; g'', Bronchial; g''', Intercostals.

The DORSAL vein follows the same course as the dorsal artery, receiving also several intercostal branches, the right one returning the blood from the second to the fifth intercostal spaces; the left, sometimes called the *lesser vena azygos*, is prolonged as far back as the eleventh or twelfth intercostal space, receiving blood from the intercostal veins of all the spaces it crosses.

On the right side the vertebral, superior cervical, and dorsal veins may reach the vena cava separately, whereas those on the left enter by a common trunk.

The *VENA AZYGOS* is a long single branch, whose radicles originate near the first lumbar vertebra. It passes forwards on the right side of the posterior aorta, below the bodies of the dorsal vertebræ, reaching the sixth, where it becomes inclined downwards, and terminates in the anterior vena cava. It receives branches from the spinal and psoe muscles, the posterior thirteen right, and usually the posterior five or six left intercostal, and also the œsophageal veins.

#### BRACHIAL VEIN.

(FIG. 167. a, b.)

The brachial vein, the largest trunk which enters into the formation of the anterior vena cava, receives the greater part of the blood from the anterior extremity, as well as extrinsic branches corresponding to those of the artery, and the subcutaneous thoracic or spur vein.

The *PEDAL PLEXUSES* and digital veins are identical with those of the posterior limb.

The *METACARPAL* veins are the external, internal, and interosseous. The *internal* vein, by far the largest, passes up the limb to the side of the flexor tendons, in company with the artery and nerve, the vein being in front, the artery in the centre; passing the knee in company with the radio-palmar artery it is continued as the *internal subcutaneous* vein. It forms a free anastomosis with other metacarpal veins, receiving also branches from the joint. The *external metacarpal* is situated on the external side of the flexor tendons, accompanied by the corresponding nerve, and it also receives branches from the skin and adjacent structures. On reaching the upper part of the trapezium, it divides into numerous branches, which either anastomose with those of the internal, or go to form the posterior radial and cubital veins. The *deep* or *interosseous* vein is very irregular and flexuous, and may be double; it passes up the limb between the posterior surface of the cannon bone and the suspensory ligament. At the head of the metacarpus, it splits up to unite with branches of the external and internal veins, and sends one or two small branches, through the carpal sheath, which help to form the posterior radial vein.

The *POSTERIOR RADIAL* vein is a continuation of the metacarpals, terminating at the lower end of the humerus in the



humeral. The artery is always accompanied, and in a great measure enveloped, by three or four venous branches, that freely anastomose, and result from the terminals of the metacarpals.

The ANTERIOR RADIAL follows a course similar to the anterior radial artery, receiving satellite branches equivalent to those of the latter.

The ULNAR or cubital accompanies the ulnar artery, receiving muscular and cutaneous branches, terminating at the inferior extremity of the humeral. It is sometimes double in the latter part of its course.

#### SUPERFICIAL VEINS.

The *superficial* veins of the arm and chest are the *external* and *internal subcutaneous*, which are slightly separated from the skin and fascia of the arm; and the *subcutaneous thoracic*.

The INTERNAL SUBCUTANEOUS vein ascends the limb on the inner side of the fore-arm, at the superior extremity of which it passes obliquely forwards, and terminates by two large branches—the basilic and the cephalic. The *basilic* vein crosses the pectoralis transversus, and terminates in the humeral. The *cephalic* vein passes over the flexor brachii to the interstice between the pectoralis anticus and levator humeri, emptying itself into the jugular vein.

The EXTERNAL SUBCUTANEOUS vein is much smaller than the internal, and ascends the leg on the anterior surface of the fore-arm, terminating at the superior extremity by uniting either with the internal, or more commonly, the cephalic vein.

The SUBCUTANEOUS THORACIC or SPUR vein commences by numerous branches in the flank, which unite in one common trunk. Posteriorly it lies near the external surface of the panniculus, being directed along the superior border of the pectoralis magnus; it then dips into the caput muscles, terminating in the humeral, sometimes in the brachial vein.

#### DEEP VEINS.

The HUMERAL vein is a satellite of the corresponding artery, and lies behind it, commencing above the elbow by the union of the radial and articular branches. It terminates in the brachial vein.

The BRACHIAL vein commences at the scapulo-humeral articula-

tion, being the continuation of the humeral; in company with the artery, it winds round the first rib, below the lower insertion of the scalenus muscle, enters the thorax, uniting with its fellow and the jugular confluent to form the anterior vena cava.

#### JUGULAR VEIN.

(FIG. 168. 2, 4.)

The jugular vein, the great vein of the head, and satellite of the carotid, commences by two branches, the superficial temporal and internal maxillary, just behind and below the temporo-maxillary articulation, its origin thus corresponding to the breaking up of the external carotid artery. Lodged at first in the posterior part of the parotid gland, in the neck it is superficially placed, occupying the *jugular gutter*, a canal formed by the levator humeri and sterno-maxillaris muscles; it enters the thorax, joining its fellow, between the first ribs, and under the trachea, to form the *jugular confluent*, into which the brachial veins discharge, the whole forming the anterior cava. The veins joining the jugular correspond for the most part to their respective arteries.

#### SUPERFICIAL TEMPORAL VEIN.

(FIG. 168. i.)

The superficial temporal, one of the radicals of the jugular vein, and a satellite of the corresponding artery, is situated behind the posterior border of the jaw, near the temporo-maxillary articulation, and buried in and under the parotid gland. It results from the union of the anterior auricular and subzygomatic veins. The large *anterior auricular* receives the superior cerebral vein, which leaves the cranium by the parieto-temporal conduit, just behind the articulation of the lower jaw. The superficial temporal vein passes through the temporalis muscle, receiving branches from it and from the external part of the ear.

The *subzygomatic* vein is divided into two branches, the transverse, a satellite of the equivalent artery, and the masseter, which anastomoses with the maxillo-muscular inferiorly, and with a large vein from the temporalis which comes through the sigmoid notch, and receives the deep temporal branches of the internal maxillary vein superiorly.

## INTERNAL MAXILLARY VEIN.

This, the other radical of the jugular, is a large vessel situated between the pterygoid muscles and the maxillary bone; it runs obliquely upwards and backwards, to the inner aspect of the maxillary articulation, just below the condyle of the lower jaw, where, after turning slightly downwards, it joins the superficial temporal; it originates in the *buccal* vein, near the superior extremity of the buccinator. Its branches are the lingual, the inferior dental, deep temporals, pterygoids, and other satellites of the branches of the internal maxillary artery.

The arrangement of the buccal vein is worthy of note. It proceeds from the facial vein at the anterior edge of the masseter muscle, and passes upwards and backwards under that muscle, presenting an enormous dilatation or pouch. Towards the superior end of the buccinator it becomes the internal maxillary vein.

## BRANCHES OF THE JUGULAR VEIN.

(FIG. 168.)

The chief branches entering the jugular are the maxillo-muscular, posterior auricular, occipital, glosso-facial, thyroid, and cephalic. The *maxillo-muscular* veins are two in number, and correspond to the branches of the artery. The *posterior auricular*, which commences under the ear, descends over the parotid gland, where it receives numerous branches, and enters the jugular just below, and on the opposite side of the preceding. The *occipital* vein, the satellite of the artery, receives blood from the brain, spinal cord, and muscles about the poll.

The *glosso-facial*, external or submaxillary vein, also a satellite, commences by two branches: the posterior or *angular* comes from the angle of the eye; the anterior or *dorsalis nasi*, from the upper part of the nose. It descends along the anterior border of masseter, and winds round the lower jaw, between the artery and Steno's duct. Below the pterygoideus, at the antero-inferior border of the submaxillary gland, it leaves the artery, and enters the jugular at an acute angle. The chief branches of the glosso-facial, in addition to a small *lateral nasal* vein near its origin, are the alveolar, superior and inferior coronary, buccal, and sublingual veins.

The *alveolar* vein, or *vena varicosa*, is peculiar in form and disposition, being buried under the masseter, between the zygoma.

and the alveoli of the upper molars ; its anterior extremity opens into the facial vein ; posteriorly it crosses the alveolar tuberosity, and passes through the optic fossa, receiving the superior dental, spheno-palatine palatine, and staphyline veins ; in the ocular sheath, it receives the veins from the eye. By the side of the ophthalmic nerve, it enters the cranium by the foramen lacerum orbitale, and communicates with the cavernous sinus at the base of the brain. Before this vein winds round the alveolar tuber-

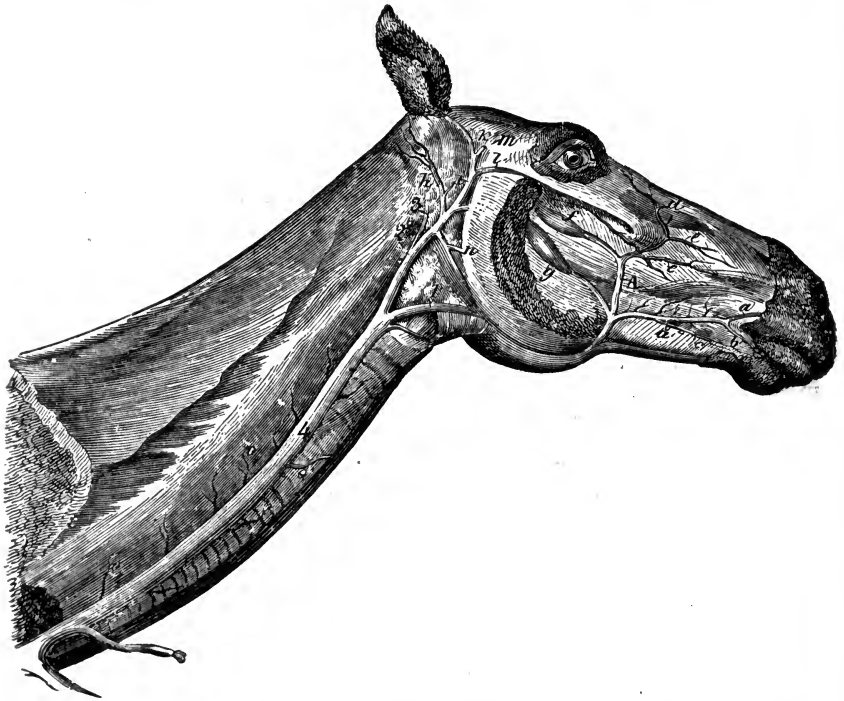


FIG. 168.

Veins of the face and neck. 1, Glosso-facial ; A, Its facial portion ; 2, Jugular ; 3, Occipital ; 4, Cervical portion of jugular ; a, Superior coronary ; b, Small labial branch ; c, Inferior coronary ; a', Common coronary trunk ; d, Angular vein of the eye ; e, Dorsal nasal ; e', Lateral nasal ; f, Alveolar ; g, Buccal ; h, Posterior auricular ; i, Superficial temporal ; k, Anterior auricular ; l, Subzygomatic ; m, Superior cerebral—cut ; n, Maxillo muscular ; o o o, Muscular, œsophageal and tracheal twigs.

osity, it forms a large venous reservoir, which diminishes before entering the ocular sheath. The use of this reservoir is apparently to prevent congestion in the cavernous sinuses.

The *superior* and *inferior coronary* veins are the next branches, and sometimes they unite to form a common trunk. The superior gives off a small labial branch.

The *buccal* or *inferior communicating* vein resembles the vena varicosa, and is a satellite of the buccal artery; being the radical of the internal maxillary vein, we have described it with that vessel.

The *sublingual* vein is large, consisting of two branches, which unite and pierce the mylo-hyoideus muscle.

The *thyroid* vein, a large vessel formed by the laryngeal and thyroid veins, gains the jugular near the termination of the glosso-facial.

The *cephalic* vein enters at the inferior extremity of the jugular, coming from the internal superficial vein of the arm; it is a satellite of the pectoral branch of the inferior cervical artery, and is found in the interstice between the levator humeri and pectoralis anticus muscles.

The minor branches of the jugular are several nameless ones, which return blood from the parotid gland and cervical muscles.

#### LYMPHATIC SYSTEM.

The lymphatic or absorbent system is connected with the blood-vascular system, and consists of a series of tubes, which absorb and convey to the blood certain fluids; a number of glandular bodies through which the tubes frequently pass; and the fluids themselves, which are lymph and chyle.

#### LYMPHATIC VESSELS.

These are called lymphatic vessels, because they convey a clear limpid fluid; or absorbent vessels, because they absorb alimentary matter. The absorbents of the chyle are called *lacteal*, or chyliferous vessels, but do not differ from the rest in character or anatomical structure. The lymphatics unite to form two large trunks, the thoracic duct, and the right lymphatic vein, both of which enter the venous system near the heart. Delicate in structure, and transparent, they are present in nearly every tissue; and although more numerous than the blood-vessels, their collective capacity is probably not greater. They are placed superficially and deeply with respect to the more solid organs. The walls of the larger vessels consist of three coats; the external is composed of a network of interlacing areolar tissue, mixed with fibres of elastic and smooth muscular tissue, this coat connects the vessel with its surroundings. The middle coat is

thin and highly elastic, consisting of smooth muscular fibres interlaced with areolar and elastic tissue. The internal coat is merely a basement membrane of elastic tissue, covered by a simple layer of endothelium. The coat of the small vessels, lymph capillaries, consists of membranous and cellular layers.

The lymphatic vessels are beaded in appearance, due to the presence of *valves* in their interior, which aid the onward flow of their contents. These generally consist of two semilunar flaps, with an attached convex and a free concave border; they are most numerous in the proximity of the glands, and are always found where the lymphatic trunks enter the blood-vessels.

Lymphatic vessels may pass through two or more glands, or they may enter a central trunk without approaching any gland.

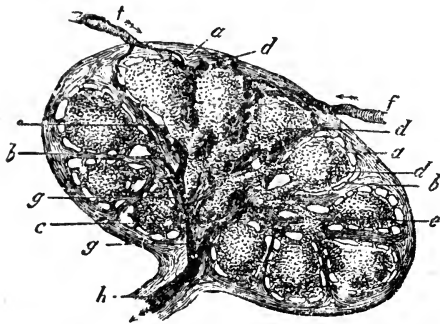


FIG. 162.

Section of a Lymphatic Gland. *a a*, Capsule; *b b*, Trabeculae of cortical portion; *c*, Trabeculae of medullary portion; *d e*, Lymphoid contents of loculi; *f f*, Afferent vessels; *g g*, Their confluence, leading to *h*, the efferent vessel.

#### LYMPHATIC GLANDS.

The lymphatic glands are small, round, or oval in shape, varying in size from a hemp seed to a kidney bean; in colour they vary much, but are generally some modification of pale red, reddish brown, or grey. They consist of a cortical sub-

stance covered externally by a fibrous capsule which sends trabeculae within the gland, dividing it into numerous polygonal cavities, called *loculi* or *alveoli*, which are filled with a whitish pulp containing cells and nuclei, identical in character with lymph corpuscles; the deeper part of the gland is called the *medullary substance*; it also contains loculi and lymphoid tissue. The loculi are lined by very delicate processes given off from the trabeculae, which divide them into very minute cavities communicating with each other, forming a spongy texture enclosing the lymphoid tissue. The vessels, just before reaching the glands, divide into the afferent vessels, or *vasa afferentia*, which enter the gland; these subdivide into intricate plexuses, which open into the spongy cavities, whence originate vessels which lead to those

emanating from and leaving the gland, the *vasa efferentia*, or efferent vessels. The efferent, fewer but larger than the afferent, after a short course unite to form larger vessels. Sometimes a depression on the surface of a gland, the *hilus*, marks the spot where the efferent vessels leave it.

The closed glands of the stomach, intestines, tongue, &c., consist of a material resembling that of the lymphatic glands, and which has been termed *lymphoid* or *adenoid tissue*; it consists mainly of retiform connective tissue and colourless corpuscles.

#### LYMPH AND CHYLE.

Lymph is a colourless fluid, containing a number of objects which resemble almost perfectly the white corpuscles of the blood; these are the *lymph corpuscles*, and they are believed to be formed in lymphoid tissue, but notably in the lymphatic glands, and conveyed thence by the efferent vessels.

Chyle is a milky fluid found in the lacteals or lymphatic vessels of the intestines during digestion; it contains corpuscles similar to those of the lymph. Since both the lacteal and posterior lymphatic vessels lead to the great lymphatic trunk, or thoracic duct, it follows that the lymph and the chyle become mixed.

#### THORACIC DUCT.

(Fig. 170.)

This, the largest and longest lymphatic vessel, receives all the others, except those of the right anterior extremity, and right side of the head, neck, and thorax; it originates in the lumbar region between the posterior aorta and vena cava, by a very irregular dilatation called the *receptaculum chyli*, or reservoir of Pecquet, into which flow the contents of the neighbouring vessels. From the anterior aspect of this reservoir, the duct proceeds forwards on the right side of the vertebral column, enters the thoracic cavity through the aortic hiatus of the diaphragm, passing along the vertebræ until it reaches about the sixth dorsal, where it curves downwards to the left side, over the base of the heart, and towards the beginning of the anterior vena cava, in most cases terminating in the jugular confluent about the anterior border of the first rib. Its orifice is dilated and guarded by a valve, which prevents the influx of blood; it may be double, when we

have a right and left, or double at its origin only; or it may be single at its origin, then bifid for a short distance, again forming a single trunk; it contains a few valves.

The lymphatics, which form the affluents of the thoracic duct, may be divided into five groups, comprised within the following divisions of the body:—

Posterior region.  
Digestive viscera.

Anterior region.

Thoracic viscera.  
Thoracic walls.

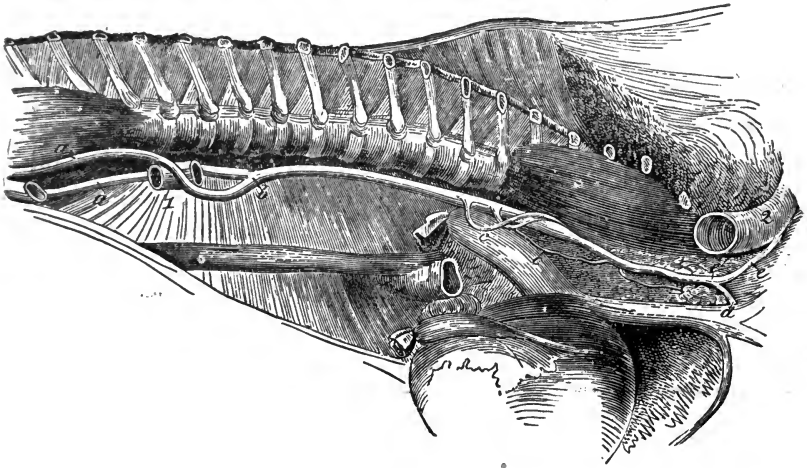


FIG. 170.

Thorax laid open on the right side—the lungs being removed. 1, Part of posterior aorta; 2, Trachea divided; *a a*, Right and left branches of origin of thoracic duct (double posteriorly in this instance); *b*, Point of union of the branches; *c c*, Loops leaving and rejoining the duct; *d*, Point of discharge of the duct; *e*, Cervical lymphatic vessel; *e'*, Its termination in the duct.

#### POSTERIOR REGION.

This embraces the lymphatics of the posterior extremity, pelvis, abdominal walls, and organs of the pelvic region. They all converge to a large group of glands, the sublumbar, presenting, however, at different parts of their passage, other groups. We note the following:—

Sublumbar.

Deep inguinal.

Superficial inguinal.

Popliteal.

Iliac.

Precurral.

The *sublumbar* glands occupy the sublumbar region, resting in the angles formed by the bifurcation of the posterior aorta,



extending as far forward as the posterior mesenteric and spermatic arteries. This group receives the lymphatics of the pelvis, the efferent branches from the deep inguinal, and iliac glands, branches from the rectum, double colon, and spermatic cord. The numerous different branches of the sublumbar glands, after forming one or more trunks, terminate in the receptaculum chyli.

The *deep inguinal* glands are formed by a considerable number of lobes lodged under the crural aponeurosis and arch, in the interstices between the adductor muscles of the thigh, along with, and to the inner aspect of, the crural vessels. The group is elongated, and superficial exteriorly, reaching almost to the anterior pubic border. The colour of the lobes varies from grey to brown, or almost black. The afferent vessels are formed by the superficial lymphatics, which accompany the internal saphenic vein, and by satellites of the deep blood-vessels. The efferent branches of this group pass into the sublumbar glands, entering the abdomen in company with the external iliac vessels.

The *superficial inguinal* glands are placed in front of the inguinal ring, at the side of the sheath. They are oblong, and consist of ten or twelve lobes. The afferent vessels are numerous, and receive the lymph from the internal part of the thigh, the sheath, scrotum, and inferior abdominal walls. The efferents, larger, but less numerous, pass up the inguinal canal in company with the external pudic artery, and terminate in the deep inguinal glands.

The small *popliteal* glands consist of from three to five lobes, situated just behind the great sciatic nerve and gastrocnemius muscle, and between the adductor magnus and biceps rotator tibialis, near the femoro-popliteal artery. They receive the lymphatics from the posterior part of the haunch and from the neighbourhood of the hock. The efferents join the deep inguinal glands, passing through the muscular interstices of the thigh.

The *iliac* glands consist of five or six lobes, which form a soft yellow group, situated in the triangular space between the two branches of the circumflex ilii artery. They receive the efferents from the precrural glands, and numerous deep lymphatics from the abdominal walls. The five or six efferent vessels follow the circumflex artery, and terminate in the sublumbar glands.

The *precrural* glands rest on the inner side of the anterior border of the tensor fascia lata, upon the circumflex artery, and constitute a small elongated mass, composed of about twelve lobes. It receives the lymphatics from the anterior and internal

part of the thigh. Its three or four efferents are very large; passing up the internal face of the fascia lata muscle, they enter the abdominal cavity towards the angle of the haunch, and join the iliac glands.

#### ABDOMINAL VISCERA.

The *lymphatics of the rectum and floating colon*. There are two or three lobes at the base of the tail on each side of the sphincter, a series of glands along the small curve of the viscera, and the mesenteric glands, comprised between the layers of the mesentery, receiving the radical vessels which arise in the mucous and fleshy coats of the intestine generally. Their efferent vessels frequently traverse the glands placed on the passage of the blood-vessels, and reassemble towards the origin of the posterior mesenteric artery by numerous large branches, which join the divisions of the sublumbar lymphatics, or those of the double colon.

The *lymphatics of the large colon*.—Upon this viscus a double chain of glands accompanies the colic arteries. Numerous small lobes, at short distances from the principal glands, are disseminated over the lateral branches of the blood-vessels. The lymphatics emanating from the coat of this intestine pass for the most part into these small lobes, afterwards joining the principal glands, whence they emerge as numerous large satellites of the colic blood-vessels. These, and the lymphatics of the small intestine, unite to form the two great mesenteric trunks, which, with the efferent branches of the sublumbar glands, form the reservoir of Pecquet.

The *lymphatics of the cæcum*.—The glands of this organ are found along the passage of the cæcal arteries, constituting a series not so close as those of the great colon, into which are received the lymphatic vessels of the membranes of the cæcum. These, on leaving the glands, form larger branches, which are satellites of the blood-vessels, and enter the same trunk as those of the small intestine.

The *lymphatics of the small intestine*.—The lymphatic glands, which receive the lacteals of this intestine, are about thirty in number, of a grey colour, large, fusiform, very compact, and often bifurcated at their superior extremity. They are lodged in the mesentery, near the origin of the anterior mesenteric artery.

Besides these larger glands, there are about fifteen smaller lobes dispersed along the course of the ilio-cæcal artery.

The lymphatic vessels form a large network, converging from the visceral walls to the mesenteric glands, which they enter at the superior extremity of the mesentery. The efferent branches, usually two or three from each gland, unite to form larger ones, which finally join the intestinal branch of the receptaculum chyli.

The *lymphatics of the stomach*.—The glands of the stomach are divided into two classes; a large series, situated in the lesser, and a chain of smaller ones, distributed along the greater curvature, and attached to the gastro-colic omentum. The deep and superficial lymphatics of the stomach enter these glands, and collecting on the blood-vessels, pass up towards the greater *cul-de-sac* near the celiac axis, where they anastomose with branches from the spleen and liver, forming large flexuous trunks, some of which enter the thoracic duct, while others pass backwards to the trunks of the intestinal lymphatics.

The *lymphatics of the spleen*.—Those of the spleen are deep and superficial; the former occurring in the parenchyma, the latter on the surface. They all pass to the branches of the vessels in the hilus, enter numerous groups of glands, and are dispersed along the blood-vessels, anastomosing with the lymphatics of the stomach and liver.

The *lymphatics of the liver* consist of a deep series in the parenchyma of the gland, and a network of superficial ones on the capsule. They assemble towards the posterior fissure, and, entering a group of small glands, pass into a much larger group situated between the trunk of the vena porta and the pancreas. Their efferents anastomose with those of the stomach and spleen.

#### THORACIC VISCERA.

In the thorax there are three groups of lymphatic glands; a series of small ones in the posterior mediastinum, which receive the lymphatic vessels of the posterior part of the œsophagus; the *bronchial glands*, which are situated at the angle of bifurcation of the trachea, stretching a short distance into the parenchyma of the lungs, and receiving their lymphatic vessels; two series of glands, extending along the infero-lateral face of the trachea from the base of the heart to the first rib, receiving the lymphatics from the pericardium and heart, and portions of the trachea and

œsophagus. The efferent vessels unite to form two or three trunks which enter the thoracic duct in different places.

#### THORACIC WALLS.

In this group there are also three sets ; a double chain of small round glands, situated on each side of the dorsal vertebræ above the intercostal spaces, and under the costal pleura ; a large glandular mass, resting on the xiphoid cartilage, just behind the heart and in front of the inferior part of the diaphragm ; and a group of rudimentary glands, which accompany the internal thoracic arteries.

The *lymphatics of the diaphragm*, after receiving, it is said, those from the convex face of the liver, enter the glands at the base of the diaphragm, leaving them by numerous branches which accompany the internal thoracic arteries, and either join the anterior extremity of the thoracic duct or the great lymphatic vein, usually after passing through the prepectoral glands. They receive the lymphatics from the inferior part of the intercostal spaces. The other lymphatic vessels of the thoracic walls run upwards in the intercostal spaces, and enter the chain of glands along the sides of the dorsal vertebræ, forming two canals, which pass forwards to enter the anterior portion of the thoracic duct.

#### ANTERIOR REGION.

The lymphatics of the head, neck, and anterior extremity are directed to the entrance of the thorax, where there is a group of glands termed the *prepectoral*, which may be regarded as the lymphatic centre of the whole anterior, as the *sublumbar* is of the posterior part of the body. Before the vessels reach this point of convergence, they are intercepted by one or more of four other glandular groups. We have in this region the following groups of glands :—

Prepectoral.		Subaxillary.
Guttural.		Prescapular.
	Brachial.	

The *prepectoral* glands are found on each side of the terminal extremity of the jugular veins, inside the inferior border of the scalenus ; they are massive, passing into the chest under the brachial vessels, and along the internal aspect of the first pair of

ribs. Entering these glands are the emerging lymphatic branches of the prescapular and brachial glands, those from the guttural glands, which descend the trachea with the carotid artery, as well as most of those which accompany the internal thoracic vessels. They afford numerous short and voluminous branches, those of the right side forming the lymphatic vein; those of the left joining the thoracic duct, at times reaching the anterior cava by a separate trunk.

The *guttural* glands are numerous, and attached slightly to each other. They are disposed in an elongated mass which occupies the lateral wall of the pharynx, below the guttural pouch, reaching almost to the thyroid gland. They receive all the lymphatics of the head, some directly from the base of the tongue, soft palate, walls of the larynx and pharynx; others are efferents from the submaxillary glands, and from a lobe lodged in the substance of the parotid gland. The efferents form four or five large branches, which descend the trachea singly, or united into a bundle which follows the carotid; numerous elongated glands receive the radical lymphatics from the cervical portion of the trachea and œsophagus. On arriving at the entrance of the thorax, the efferents enter the prepectoral glands; branches sometimes pass directly to the thoracic duct on the left, or the lymphatic vein on the right side.

The *submaxillary* glands are a fusiform mass situated at the base of the tongue, between the digastric and mylo-hyoid muscles, and a little above the glosso-fascial artery; they receive the lymphatic vessels from the tongue, cheeks, lips, nose, and nasal cavities, the efferent vessels going to the guttural glands.

The *prescapular* glands form by their union a chain running in the course of the ascending branch of the inferior cervical artery, under the internal face of the levator humeri, and descending almost to the attachment of the sterno-maxillaris. The *cervical lymphatics*, superficial and deep, mostly enter this glandular chain, as well as those from the breast, and a part of those from the shoulder; their efferents, short and voluminous, pass to the prepectoral glands.

The *brachial* glands, situated under the shoulder, consist of two groups; one is situated near the elbow to the inside of the inferior extremity of the humerus, receiving the lymphatic vessels of the foot and fore-arm, which accompany the superficial veins, or pass up the interstices of the muscles with the deep vessels;

the other is disposed in a mass behind the brachial vessels, near the common insertion of the latissimus dorsi and teres internus; it receives nine or ten lymphatic branches from the shoulder and arm. The efferents accompany the brachial vessels, and enter the pectoral glands.

#### LYMPHATIC VEIN.

The second principal trunk is the *lymphatic vein*, or *ductus lymphaticus dexter*, a vessel measuring in length from three-quarters to one inch, situated near the junction of the jugular veins, and terminating in their confluent; it is also guarded by a valve, and receives the lymphatic vessels from the right anterior extremity, and the right side of the head, neck, and thorax.

---

### COMPARATIVE ANGIOLOGY.

#### RUMINANTIA.

IN the heart of the ruminant, the most prominent feature is the presence of the *cardiac bones* (see p. 105), which appear in adult life. They are two in number, and lie between the auriculo-ventricular rings and the common aorta on the left, the pulmonary artery on the right side. There is a third longitudinal furrow running down the wall of the left ventricle posteriorly. The furrows contain more fat as a rule than those of the horse's heart. There are usually nine aortic intercostals, and three anterior ones, or twelve in all. The *coeliac axis* reaches the rumen just behind the oesophagus. On the left is given off the *artery of the reticulum*, which passes to the left of the oesophagus, and divides into a superior and an inferior branch. Just posterior to this the *splenic* artery arises, and still farther back the *hepatic*, which supplies the liver and gall-bladder, giving off the *duodenal* branch, which anastomoses with the superior artery of the abomasum, and the anterior mesenteric. The terminal branch of the coeliac axis divides and forms a superior and an inferior *artery of the psalterium and abomasum*, which pass along the surfaces of these cavities, the former anastomosing with the duodenal. The superior and inferior *arteries of the rumen* are placed in the longitudinal groove, the former usually arises from the splenic, running backwards; the latter is generally given off by the artery of the reticulum, and runs forwards and between the anterior sacs, to gain the inferior surface, where it passes backwards and reaches the groove between the conical sacs, anastomosing with the superior vessel.

The *anterior mesenteric* artery divides into two branches, an anterior for the small, and a posterior for the large intestine. The former resembles that of the horse in its distribution; the latter instead of following the flexures of the colon gives off branches which cross them. The *posterior mesenteric* artery is small. The *middle sacral* artery is very large, giving off the arteries of the tail; it may be regarded as the continuation of the posterior aorta, the *lateral sacrals* being somewhat rudimentary, and their terminal branches

wanting. In the smaller ruminants, branches from the deep femoral take the place of the *obturator* and *iliaco-femoral* arteries which are wanting; in the ox they are rudimentary. The *uterine* artery is very large, arising from a trunk common also to the *umbilical*.

The arteries of the pelvic limb offer no deviation from those in the typical animal, of sufficient importance to merit description in an elementary work, until we descend to the tarsal joint, below which the arteries, like the other appendicular structures, present certain comparative features worthy of notice. The *great metatarsal* artery, with two veins, occupies the median groove on the front of the metatarsus, passes through the notch between the distal articular surfaces, and gains the back of the digit as the *common digital* artery. Above the distal ends of the *ossa suffraginias* it divides into external and internal unguis arteries, each of which gains the inner aspect of its respective digit, and enters the distal phalanx, where it behaves similarly to the plantar unguis of the horse. The *lateral digital* arteries pass down the outer sides of the digits, that of the external digit being formed by the interosseous plantar and a transverse communicating branch, while that of the internal digit is given off by the great metatarsal artery.

The *anterior aorta*, it has been stated, is wanting; if it is present it is remarkably short. If it be absent, we must describe the brachials as arising from the common aorta. The *dorsal* and *vertebral* arteries arise by a common trunk, the former furnishing a branch which takes the place of the *superior cervical* artery, which is wanting. The vertebral artery is large, and does not inosculate with the occipital, but terminates in muscular branches. The *humeral* artery is small, as are most of its branches; the chief artery supplying the muscles of the posterior brachial region is the *scapulo-humeral* branch of the subscapular artery. The *radio-palmar* artery forms an inferior arch, as in the horse, from which are given off three interosseous *palmaris* and one *dorsal*; of the former the internal is the largest and most constant; the dorsal or anterior interosseous artery gains the front of the limb, anastomosing superiorly with the anterior radial artery, while inferiorly it occupies the vertical groove in the metacarpus, and inosculates with a recurrent branch of the great metacarpal artery, which passes between the articulations at the distal end of the bone. The arteries of the digit resemble in the main those in the pelvic limb.

The *carotid* arteries arise, as in the horse, by a primitive trunk from the brachio-cephalic artery; they break up at the head, forming the external carotid, and a small occipital artery; the internal carotid is wanting, its function being performed by the *encephalic* artery. The *occipital* artery enters the cranium by the condyloid foramen, passes backwards and inosculates with the lateral artery of the spinal cord, at about the level of the internal foramen of the atlas; a branch given off from this union passes out through the foramen to supply the muscles of the poll. The *lingual* artery is given off by the external carotid, and the former gives off the sublingual branch. The *mastoid* artery of the horse is represented by a branch of the posterior auricular. In the smaller ruminants the *coronary* arteries of the lips are formed by the bifurcation of the *transverse facial*, a branch of the superficial temporal artery.

The *internal maxillary* artery has no pterygoid foramen to pass through in

any of the domesticated ruminants ; some of its branches, however, lead to the formation of structures interesting to the anatomist ; these are the arterial plexuses, or *retia mirabilia*, the largest of which is formed inside the cranium by branches from the internal maxillary artery. One of these branches, the *spheno-spinal*, enters the cranium by the foramen ovale, and, as a rule, two *arteries of the rete* enter by the anterior common foramen ; the first of these inclines forwards, the two latter backwards. The three arteries anastomose by forming a small and intricate plexus known as the cranial *rete mirabile* ; it is situated at the side of the sella turcica of the sphenoid bone, communicating with its fellow posteriorly, and giving off superiorly the *encephalic* artery, a branch considered by Chauveau to be "completely analogous to the intracranial portion of the internal carotid in the solipede." From this artery are given off the cerebral branches, anterior, middle, and posterior ; the last passing backwards, forms a convergent anastomosis with its fellow, thus constituting the *basilar* trunk leading to the middle spinal artery. Another arterial plexus is found on the *ophthalmic* artery just where the arteries of the eye are given off. The *glosso-facial* artery is found only in the larger ruminants.

#### VEINS.

The *subcutaneous abdominal* vein is very large in the ox, the *subcutaneous thoracic* being proportionally small. The *saphenic* veins differ from those of the horse, the external one being larger than the internal. The *jugular* vein is large, and there is a small accessory jugular which varies much in size, originating in the occipital vein, and joining the great jugular near its termination. The *angular vein* of the eye is very prominent in small ruminants.

The digital veins of the posterior limb are three in number, an anterior or common one between the digits, formed by twigs from the solar plexuses of both, and two lateral ones placed on the outer sides of the digits. There are usually five metatarsal veins ; two *anterior deep* ones which accompany the great metatarsal artery ; an *anterior superficial* one, which forms one root of the external saphenic ; an internal and external *posterior* vein, which pass upwards over the tarsus, and assist in forming the saphenic veins. In the anterior limb there is a fourth or *posterior digital* vein, which accompanies the common digital and internal metacarpal arteries.

#### THE LYMPHATICS.

In the large ruminants the thoracic duct not only exhibits great complexity of form, but it is also extremely variable, being sometimes double throughout its extent. Some complexity generally exists near its anterior termination. It is more deeply seated than that of the horse, lying between the right upper part of the aorta and the vertebral column, buried in a quantity of fat. It does not pass through the aortic hiatus, but has an opening in the diaphragm for itself.

#### OMNIVORA.

In the hog the branches of the posterior aorta call for no remark, since they resemble those of the horse, excepting the mesenteric arteries, which are distributed somewhat like those of the ruminant. After giving off the *gluteal* and



*umbilical* branches, the *internal iliac* artery is apparently continued by the *internal pudic*, which gives off the hæmorrhoidal artery to supply the urinary and genital organs of the region, and the rectum posteriorly, and finally the *cavernous* arteries.

The *external iliac* artery resembles in its distribution that of the ruminant.

The *anterior aorta* is wanting, the brachial trunks arising from the common aorta. The *vertebral*, *dorsal*, and *subcostal* arteries of the right side are given off by a branch which itself appears to represent the superior cervical artery. A branch from the *subscapular* artery is the analogue of the deep humeral in the horse; the rest of the circulation of the anterior limb is mostly like that of the ruminant.

The *carotid arteries* arise singly from the brachio-cephalic trunk; they break up like those of the horse. There is no *cerebro-spinal* branch of the occipital artery. The *internal carotid* enters the cranium by the foramen lacerum posticum, and forms a *rete mirabile*, assisted by the ophthalmic. The *basilar* artery is formed as in the ruminant. The *external carotid* extends to the maxillary hiatus, where it breaks up—*i.e.*, the internal maxillary artery is in this animal considered as part of the carotid. The *lingual* artery is separate from the facial.

The veins call for little remark. What we have said of the jugular and saphenic veins of the ruminant is also applicable here. The superficial veins in the hog are for the most part buried in an exceedingly thick layer of fat.

The thoracic duct usually opens into the left jugular vein, near its termination. It sometimes divides anteriorly and reunites, forming a cavity which receives the terminal lymph vessels.

### CARNIVORA.

The heart in carnivora is extensively related with the sternum, the apex being directed backwards. In shape the organ is very bluntly ovoid. There are no well-defined *bronchial* arteries, but several œsophageals proceeding direct from the aorta, in the posterior mediastinum; some of these give off bronchial branches.

The *coeliac axis* divides into the three typical branches, but there is no distinct right and left division of the gastric artery. There is given off a *pancreatico-duodenal* branch from the hepatic which anastomoses with the great mesenteric artery. Near the latter a vessel arises which divides, supplying the diaphragm anteriorly and the sublumbar region posteriorly.

The *internal iliac* arteries are somewhat separated from the external ones, the umbilicals being given off from their common trunk. They divide into two chief branches, which may be considered representatives of the internal pudic and gluteal arteries of the horse; the first of these calls for no special comment, the second passes through the great sciatic notch with the great sciatic nerve, and becomes lost in the gluteal and femoral muscles, first giving off spinal branches; the coccyx is supplied by branches of the *middle sacral* artery.

The branches of the *external iliac* artery present few deviations of importance. The *circumflex ilii* comes direct from the aorta. The *posterior tibial* artery is rudimentary, while the anterior one gives off a large *tarsal* branch, and descends in the third intermetatarsal space, inclining backwards, and forming a plantar arch underneath the flexor tendons; from this arch are given off three *digital*

or plantar arteries, which are distributed like those of the superficial palmar arch in the anterior limb.

The *brachial* arteries in the main resemble those of the hog. The *vertebral* inosculates with the *ramus anastomoticus*; it supplies many cervical branches, the superior cervical artery being both small and short. The *humeral* artery gives off branches resembling those described in the typical animal, but it terminates by dividing into radial and cubital arteries, the presence of the anterior radial being merely indicated. The *cubital* artery gives off the *interosseous*, which divides under the pronator quadratus, into anterior and posterior branches; the former passes between the radius and the ulna, forms a carpal plexus, and supplies the digits anteriorly; the latter is the larger, and in the region of the carpus divides into a superficial and a deep branch; the first assists with the cubital in forming the *superficial palmar arch*, which is chiefly formed by the inosculation of the cubital and radio-palmar arteries; the deep branch helps with the radial to form the *deep palmar arch*, underneath the flexor tendons. From the latter arch are given off eight interosseous branches, four *palmares* and four *dorsales*, the latter passing through the intermetacarpal spaces and anastomosing with branches of the anterior interosseous artery. All these vessels pass down the digits, and join ultimately the *collateral palmars*, which emanate from the superficial palmar arch. Thus there are three sets of digital vessels, an anterior, and a superficial and deep posterior.

The *carotid* arteries arise singly from the brachio-cephalic trunk, but otherwise resemble those of the horse; in their breaking up and in the disposition of the *occipital* artery and *ramus anastomoticus* there is no important deviation. The *internal carotid* enters the carotid canal, passes forwards, and sends a projecting loop out through the carotid foramen, receiving a small branch of the external carotid; it joins the sphenospinal and recurrent ophthalmic branches, forming a kind of rudimentary *rete mirabile*.

The *glosso-facial* artery is represented by separate facial and lingual branches.

The *internal maxillary* artery resembles that of the horse; the superior dental is usually regarded as its continuation. It gives off an *alveolar* artery which chiefly supplies the orbital gland.

The *receptaculum chyli* in carnivora is very large, extending forwards as far as the thorax. The thoracic duct usually bears a marked resemblance to that of the hog.

#### RODENTIA.

Even were the subject of importance, there is little space for its consideration here. It is, however, interesting to note that the heart presents external indications of *division*, the apex being in some cases slightly cleft. The external jugular vein is very much larger than the internal, and there are two separate anterior venæ cavæ.

#### AVES.

The heart in birds is divided into four cavities as in mammals; its apex is situated between the lobes of the liver, as there is no absolute separation between the thoracic and abdominal cavities.

The right auricle is much larger than the left, and a single triangular valve takes the place of the tricuspid.

The *common aorta* divides into three branches, a single descending or posterior aorta, and a right and left trunk, termed by Chauveau the *brachio-cephalic* arteries, the first supplying chiefly the viscera; the latter the wing, head, neck, and anterior parietes of the body; these lateral trunks are regarded by some authorities as representing the mammalian thoracic arteries, giving off the carotid and subclavian branches.

A large number of *retia mirabilia* are found among the arteries of the head and viscera.

There is only one terminal *pulmonary* vein and two *superior cavæ*. The *jugular* veins have a large transverse anastomotic branch just below the cranium. The *portal* vein receives branches from the veins of the posterior extremities, notably the coccygeo-mesenteric vein, which is connected with the femoral by the renal-portal vein. Thus is constituted the *renal-portal system*, whose existence in the bird is a disputed point, even amongst high authorities.

The *blood* of birds is higher in temperature than that of any other vertebrate class. The corpuscles are large, elliptical in shape, and nucleated.

The *lymphatics* consist of glands and vessels. There are two thoracic ducts, each discharging into the cava of its own side. They originate in a kind of receptaculum chyli, near the celiac axis. The glands are said to be *confined to the cervical region*.

#### CIRCULATION IN LOWER ANIMALS.

It may be not out of place here to explain very briefly how the circulatory apparatus, in animals placed lower than the class *Aves*, differs in the general plan from the type we have hitherto considered. It will be seen that in none of the mammals or birds we have attempted to describe, is there any important difference in the general plan of the heart, course of the blood, or function of the vessels.

In that class placed next below the *Aves*, the *Reptilia*, or reptiles, we find the following interesting features (see Fig. 171). The heart is less complex, having only three cavities, two auricles, and *one common ventricle*. As the general disposition of the vessels is the same as in the heart of four cavities, it follows that both the purified blood from the lungs, and the venous blood from the *cavæ*, are passed through their respective auricles to the ventricle, where they become mixed. This mixed blood is driven into the aorta and pulmonary artery, both of which arise from the common ventricle. Hence, though the circulation in these animals is double, the blood supplied to the tissues is impure or mixed.

In a still lower class of animals, that of the *Pisces*, or fishes, we find that the

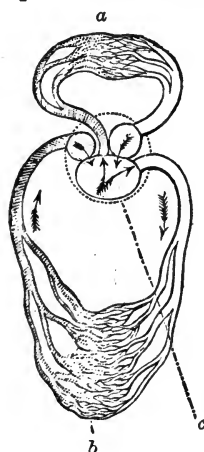


FIG. 171.

Diagram of the Circulation in a Reptile. *a*, Pulmonic, and *b*, Somatic circulation; *c*, Heart, showing the three cavities. The arrows indicate the course of the blood current.

heart is still more rudimentary, consisting of but two cavities, an auricle and a ventricle, but still the tissues are supplied with pure arterial blood; the course of the blood being as follows:—The venous blood is conveyed by the cava to the auricle, thence into the ventricle, and then by the *branchial artery* to the *Branchiæ* or gills, structures which are analogous to the lungs of higher animals, and in which, consequently, the blood becomes arterialised. The blood thus purified, is sent from the gills throughout the body to supply the various tissues, and is finally returned by the cava to the heart. Hence the circulation in these animals is *single*, the purified blood *not being returned to the heart*, but driven all through the body. The impulse of the heart is therefore *branchial*.

In the higher orders of the *Crustacea*, a still lower class of animals (Inverte-

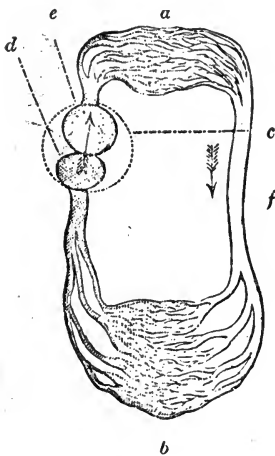


FIG. 172.

Diagram of the Circulation in a Fish. *a*, Branchial circulation; *b*, Somatic circulation; *c*, Heart; *d*, Auricle; *e*, Ventricle; *f*, Arterial trunk.

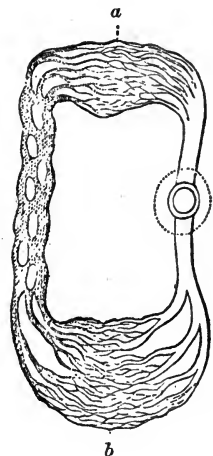


FIG. 173.

Diagram of the Circulation in a Crustacean. *a*, Branchial; *b*, Somatic circulation. On the right is the heart with its single cavity, and on the left the venous lacunæ.

brate), we find that the cavities of the heart are reduced to one, which is however contained in a kind of sac, very incorrectly called the pericardium. Although these animals are supplied with gills, the impulse of the heart is *systemic*, not branchial; and, as in the fishes, the circulation is single. The blood is driven by the heart through the body, and then collected into certain venous dilatations or lacunæ, whence it is conveyed to the branchiæ for purification. The branchial vessels then pour it into the so-called pericardium, and it finally re-enters the heart by a number of valvular orifices.

The blood thus supplied to the tissues is, however, not pure; for it is ascertained that certain veins, instead of leading to the lacunæ, or branchiæ, pass to the pericardium, in which cavity the blood thus becomes mixed.

## CHAPTER VI.

### NEUROLOGY.

THE subject of this chapter, the nervous system, includes those organs which may be regarded as receiving and interpreting impressions; stimulating and regulating the vital functions. The nervous system in the broad sense consists of three sets of organs, peripheral, central, and communicating, the function of the latter being to establish a communication between the other two; that of the first to receive and deliver impressions; and that of the second to generate the nervous force. In other words, the system comprises *peripheral end-organs, nerves, and nerve centres*; it is with the two latter that we have more immediately to deal. The nervous system is divided into two minor systems—the Cerebro-Spinal, which is to a considerable extent influenced by the *will* of the animal; and the Sympathetic, or ganglionic system, which comprises the nerves of organic life, which are not directly influenced by the will. Each of these has its own central and peripheral organs.

In the first, the centre is made up of two portions—one large and expanded, the brain or encephalon, which occupies the cranial cavity; the other, the spinal cord, is elongated and continuous with the brain, being lodged in the canal of the vertebral column. The communicating portion of this system consists of the cerebro-spinal nerves, which leave the axis in symmetrical pairs, and are distributed to the voluntary muscles, and the organs of common sensation, and special sense.

In the second, the central organ consists of a chain of ganglia connected by a nerve cord, which extends from the head to the coccyx, on each side of the spine. The nerves of this system are distributed to the involuntary muscles, mucous membranes, viscera, and blood-vessels. The two systems have free intercommunication, ganglia being placed at the junctions.

## NERVOUS TISSUE.

Two substances, distinguishable by their colour, enter into the formation of nervous tissue—viz., the *white* and the *grey* matter. Both are soft, fragile, and easily injured, in consequence of which the principal nervous centres are always well protected by the skeleton. When examined under the microscope, two distinct structures, fibres and cells, are found; the fibres being of two kinds, the white or medullated, and grey or non-medullated, the former being more abundant.

The *white fibres*, which form the white matter of the brain, spinal cord, and the nerves, and are also sparingly met with in the ganglia and nerves of the sympathetic system, have three distinct components—1st, An external envelope, the *neurilemma*, which is fine, transparent, and nearly homogeneous; 2nd, A layer of white, fatty matter, the *medullary sheath*, or *white substance of Schwann*; and 3rd, the *cylinder axis*, or *primitive band of Remak*, in the centre of all. The diameter of these fibres varies between  $\frac{1}{10000}$ th and  $\frac{3}{10000}$ th of an inch, though some are very much less.

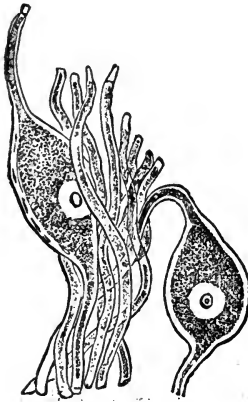


FIG. 174.

Nerve tissue—bi-polar cells and fibres.

The *grey* or *non-medullated fibres* constitute the chief nerves of the ganglionic system, and are also present in the cerebro-spinal nerves. They are smaller than the white fibres, resembling their cylinder axis, measuring from  $\frac{1}{10000}$ th to  $\frac{3}{10000}$ th of an inch in diameter, and are apparently almost homogeneous in their structure.

The *nerve cells*, or *ganglionic corpuscles*, are found in the nerve centres, and in the peripheral end organs of some of the nerves. In shape they are spheroidal, caudate, or stellate. Each cell is composed of a transparent membrane, filled with a homogeneous, colourless matrix, in which is a number of diffused minute granular bodies, and an internal vesicular nucleus, presenting one or more minute, but distinct nucleoli. The processes of the cells become continuous with the cylinder axes of nerve fibres, while the medullary sheath appears to be prolonged over the cell; hence these cells have been described

as "*nucleated* enlargements of the axial cylinders." The cells are termed unipolar, bipolar, and multipolar, according to the number of processes they possess.

The *ganglia* are composed of nerve cells and gelatinous fibres, invested by a thin envelope, continuous with the neurilemma of the nerves, which sends minute processes inwards.

## NERVES.

A nerve consists of a bundle of tubular fibres, held together by areolar tissue, enclosed in a membranous sheath, and divided into a number of fasciculi, each being invested by an inflection of the sheath; they have also an external covering of cellular tissue, known as the *vagina cellulosa* or cellular sheath.

During their course, the nerves have frequent intercommunication, either by connecting branches or in a more intimate and complex manner in what is termed a *plexus*. When the nerves divide into branches, there is never any splitting of the ultimate fibres, nor yet is there ever any coalescing of them—they retain their individuality from their source to their termination.

Nerves may be traced from the surface of the brain and spinal cord into the substance of these organs, the place where they leave the surface being termed the *apparent*, and the ultimate origin the *deep origin* or *root* of the nerve. In some cases the root is single, but in others the fibres spring from different parts of the nerve centre; such nerves are said to have two or more roots. These roots may have different functions, as in the spinal nerves, where the superior root is sensory and the inferior motor. Whenever this admixture of functionally distinct fibres is found, a ganglion is placed at or near the apparent root of the nerve.

Nerves terminate in a variety of ways—by loops, as in the voluntary muscles, and in some of the soft structures, as the dental pulp; by terminal plexuses, and bulbs in mucous membranes. In many of the sensory nerves, there are small, oval masses, the *Pacinian bodies*, at or near their peripheral terminations; these

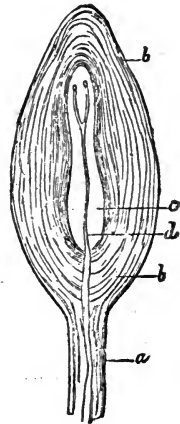


FIG. 175.

Pacinian body from the mesentery of a cat. a, Stem of the body; b, Layer of connective tissue; c, Cavity of the body; d, Nerve fibre.

are plentiful in the spinal nerves. Some nerve fibres have no termination, but form a loop by joining with others in the same bundle, and so return to the axis; while others, as the auditory and optic nerves, have end organs of great complexity.

Nerves which convey impressions to the centres are termed *centripetal* or *afferent*; those which transmit stimuli from the centres to the various organs, *centrifugal* or *efferent*; while those which pass from one centre to another are called *inter-central*.

Centrifugal nerves are called *motor* when they stimulate muscular contraction, and if this contraction be in the coats of vessels, the nerves are then *vaso-motor*; when they stimulate the secretion of glands, they are called *secretory*, and when they have the power of diminishing function, *inhibitory*; some nerves are believed to control the process of nutrition in the parts they supply, and have been named *trophic*.

Centripetal nerves which convey ordinary feeling are termed *sensory*; when they convey impressions peculiar to an organ, as the nerves of sight and hearing, they are known as nerves of *special sense*. Nerves conveying impressions which lead to the stimulation of motor nerves are termed *excito-motor*; if to that of secretory nerves, *excito-secretory*; and if to that of inhibitory nerves *excito-inhibitory*. This reflection of nervous impulse from one nerve to another is known as *reflex action*.

#### CEREBRO-SPINAL SYSTEM.

The centre of this system is the *cerebro-spinal axis*, consisting of the brain and spinal cord, which like their coverings or *meninges*, are continuous with each other.

The cerebro-spinal axis is invested by three distinct membranes—viz., the *dura mater* externally, the *arachnoid* in the middle, and the *pia mater* internally.

#### MENINGES OF THE SPINAL CORD.

The *dura mater of the cord* is a strong, inelastic membrane, composed of intersecting bands and laminae of white fibrous tissue. It extends from the foramen magnum, to which it is attached, and where it is continuous with the *dura mater* of the brain, to the posterior extremity of the neural canal, where, as a slender cord,



it blends with the periosteum in the first bones of the coccyx. Excepting near the posterior part, where they are attached by fibrous slips, the dura mater is separated from the periosteum of the canal by areolar tissue and a plexus of veins, so that it forms a loose sheath round the cord. Its inner surface is smooth, and lined by the arachnoid membrane; opposite each intervertebral foramen it is pierced for the passage of the spinal nerves, which it accompanies, as a tubular sheath, through the foramen.

The *arachnoid* (so called from its extreme tenuity, resembling somewhat a spider's web) is a delicate serous membrane, and, like other serous membranes, is a shut sac. Its visceral layer loosely envelops the pia mater of the cord, leaving between them an interval, the *sub-arachnoidean space*, continuous with an opening at the posterior border of the brain, which contains the limp cerebro-spinal fluid. The parietal layer is a continuation of the visceral, the latter surrounding the nerves as they leave the cord until they pierce the dura mater, when it is reflected on to the inner surface of that membrane.

The *pia mater*, the inner envelope of the cord, is a thin vascular membrane, composed of areolar tissue, containing blood-vessels. It is less vascular, but thicker, denser, and more fibrous than the corresponding membrane of the brain, of which it is a continuation. It closely invests the whole surface of the cord, sends processes into its longitudinal fissures, and forms a sheath for the spinal nerves. When the cord terminates, the pia mater is prolonged as a slender filament (*filum terminale*) through the centre of the mass of nerves forming the *cauda equina*, and blends with the terminal cord of the dura mater.

The *ligamentum denticulatum* is a narrow fibrous band, which runs between the superior and inferior roots of the spinal nerves, from the foramen magnum backwards, so as to form a support for the cord. Its inner border is continuous with the pia mater; the denticulations of its outer edge being attached to the dura mater in the intervals between the roots of the nerves.

#### MENINGES OF THE BRAIN.

The DURA MATER is the thick, white, fibrous membrane which lines the cavity of the cranium, acting as the internal periosteum of the bones. It is continuous with the spinal dura mater at the foramen magnum, and is also prolonged as a sheath for the nerves.

In some places its layers separate to form irregular channels, *the sinuses of the dura mater*, which are lined by a continuation of the inner coat of the veins, for the reception of the venous blood. On its external surface, the branches of the meningeal arteries can be traced; and from the inner surface, which is smooth and lined by the arachnoid membrane, processes are directed inwards for the support and protection of the different parts of the brain. These membranous processes, regarded as duplicatures of the inner layer of the *dura mater*, are three in number—viz., the *falx cerebri*, *tentorium cerebelli*, and *falx cerebelli*.

The *falx cerebri*, so named in the human subject from its being sickle-shaped, is an arched process, which descends in the longitudinal fissure between the hemispheres of the cerebrum. Anteriorly it is attached to the crista galli process, and posteriorly to the upper part of the ossific tentorium. Its convex upper border, along which runs the superior longitudinal sinus, is attached along the longitudinal suture joining the pairs of parietal and frontal bones; its under border is free.

The *tentorium cerebelli* is a transverse partition, formed by lateral inflections of the *dura mater*, between the cerebellum and the hemispheres of the cerebrum. Each lamina presents an outer convex adherent border, attached to the lateral ridges of the ossific tentorium, and enclosing a lateral sinus; an inferior concave, free border, turned outwards and a little forward; a superior extremity attached to the ossific tentorium; and an inferior extremity, which reaches the upper part of the Gasserian ganglion, and contains the petrosal sinus.

The *falx cerebelli* is a short double process, proceeding from the ossific tentorium towards the foramen magnum, between the lobes of the cerebellum. The occipital sinus is found within its folds.

The ARACHNOID MEMBRANE, like that of the cord, is a closed sac, the parietal layer of which is firmly adherent to the *dura mater*, and is reflected over the several processes. The visceral layer is thin and transparent on the upper surface of the brain, to which it is loosely attached by the subarachnoidean cellular tissue; at the base, where the subarachnoidean spaces are found, it is thicker and more opaque. These spaces, three in number (anterior, middle, and posterior), contain the cerebro-spinal fluid; they communicate freely with each other, and with the spinal

subarachnoidean space. The anterior space is situated between the lobes of the cerebrum, immediately in front of the optic commissure; the middle, between the pituitary body and the pons Varolii; and the posterior, between the medulla oblongata and the posterior part of the cerebellum.

Yellow and white fibres, intimately blended, enter into the composition of the arachnoid, the free surface being lined with scaly epithelium. It surrounds the nerves at their apparent origin, and accompanies them to their exit from the cranial cavity, when the layers become continuous.

The PIA MATER (tunica vasculosa) is closely adherent to the entire surface of the brain, dipping into every fissure or depression, into the sulci between the convolutions, and passing into the interior in several places. It is thinner, but much more vascular, than the pia mater of the cord, its vascularity being greatest on the surface of the hemispheres, where it is little more than a ramification of minute vessels, part of which can be traced some distance into the brain substance.

#### SPINAL CORD.

The spinal cord, *medulla spinalis*, or *myelon*, is a large, white, irregularly cylindrical cord, flattened from above downwards, which extends from the foramen magnum to the sacral portion of the neural canal, where it terminates in a slender filament. In order to allow considerable motion of the vertebral column without risk of injury to the cord, it is loosely suspended in the canal, the other contents being the meninges and subarachnoidean fluid, with numerous arterial and venous plexuses. In its course, the cord varies in size, being dilated at its origin, where it joins the medulla oblongata, and having a considerable enlargement between the fifth cervical and second dorsal vertebræ, where the large nerves which form the brachial plexus are given off; and again at and posterior to the third lumbar vertebra, where the lumbar and sacral nerves which constitute the lumbo-sacral plexus arise. Towards its termination the cord gradually tapers to a point, to which portion the name *conus medullaris* has been applied; and here is given off an indefinite number of filaments to supply the coccyx and neighbouring structures, forming a bundle of nerves termed the *cauda equina*. The roots of the spinal nerves have their origin opposite to the intervertebral foramina.

The terminal filament of the cord, which is constructed of white fibrous tissue externally, and nervous matter internally, passes through the centre of the cauda equina backwards to the second coccygeal bone.

When denuded of its coverings, the spinal cord is found to be divided into two lateral symmetrical *columns* by longitudinal fissures, one on the upper surface, narrower but deeper, the *superior median fissure*; the other, on the under surface, broader, but shallower, the *inferior median fissure*. A layer of white matter at the bottom of the latter fissure unites the lateral columns, constituting the *inferior white commissure*, above which a band of grey matter, the *grey commissure*, extends the whole length of the cord.

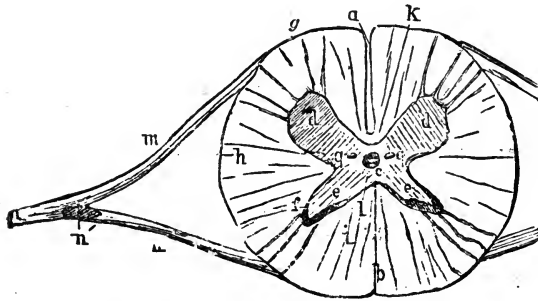


FIG. 176.

Transverse Section through Spinal Cord, showing roots of nerve. *a*, Inferior median fissure; *b*, Superior median fissure; *c*, Central canal; *d*, Inferior, and *e*, Superior cornu of grey matter; *g*, Inferior lateral fissure; *h*, middle, *i*, superior columns (?); *k*, White commissure; *l*, Grey commissure; *m*, Motor root, and *n*, Sensory root of spinal nerve; *n'*, Ganglion on sensory root. (This cut is lettered upside-down.)

Each lateral column is again divided conventionally into three parts by lateral fissures, a superior (best marked), corresponding with the sensory, and an inferior, corresponding with the motor roots of the spinal nerves.

A transverse section of the cord shows the white matter externally, in the form of two *semi-cylinders*, and the grey matter in the centre of each. The grey substance varies in size in different parts of the cord, but always presents the same general appearance of two *crescentic-shaped* masses united in the middle by the grey commissure. Each crescent presents two *cornua* or horns; the superior, long and thin, traversing the whole thickness of the cord, and prolonged outwards and upwards to the superior lateral fissure; the inferior, thicker and more irregular, is directed towards

the inferior roots of the nerves. The connective tissue of the cord is a reticular variety, very delicate and gelatinous in its structure; it is termed the *neuroglia*. In the middle of the grey commissure the central spinal canal runs the whole length of the cord, being continuous anteriorly with the fourth ventricle of the brain.

The fibres of the cord are not all continuous with those of the encephalon, some being proper to the cord itself; while of those which proceed to the brain, some decussate with each other before doing so.

The proportionate size of the brain and spinal cord varies in different animals, according to the position which they occupy in the scale of intelligence; the higher that position the larger and heavier proportionately is the brain, and the smaller and lighter the cord relatively. Thus in man, the most intelligent of the animal creation, the brain averages 50 oz.; and the spinal cord about 1½ oz.—a proportionate weight of 1 to 33. In the horse the brain averages about 23 oz., and the spinal cord 10½ oz., or a proportionate weight of 1 to 2·19.

#### THE ENCEPHALON.

The encephalon or brain is that portion of the cerebro-spinal axis situated within the cranium. In form it is a slightly flattened and elongated ovoid body, which may be considered as consisting of four parts—the *medulla oblongata*, the *pons Varolii*, the *cerebellum*, and the *cerebrum*.

#### MEDULLA OBLONGATA.

This is the prolongation of the spinal cord, extending to the pons Varolii, from which it is separated by a shallow fissure. This portion of the brain is very large in the domesticated animals, and wherever the spinal cord is largely developed. It is pyramidal in shape, the narrowest part being continuous with the cord. The inferior surface is convex, and rests upon the basilar process, and the superior surface is received between the hemispheres of the cerebellum, where it forms the floor of the fourth ventricle. Two median fissures, continuous with the superior and inferior longitudinal fissures of the cord, divide the medulla into symmetrical halves. The superior, deep and narrow, expands

into the posterior part of the fourth ventricle, while the inferior terminates in a small depression, the *foramen cæcum*, at the posterior part of the pons Varolii. On each half of the medulla the following objects can be distinguished—viz., the *inferior pyramids*, the *olivary bodies*, the *restiform bodies*, the *intermediate fasciculi*, and the *superior pyramids*.

The *inferior pyramids* are bundles of white fibres, placed on each side of the inferior median fissure, and continuous with portions of both the inferior and lateral columns of the cord. They are constructed of three sets of fibres, the innermost of which

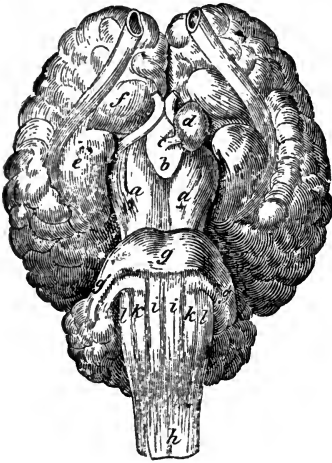


FIG. 177.

Base of the brain. *a a*, Crura cerebri; *b*, Corpus albicans; *c*, Infundibulum; *d*, Pituitary body; *e*, Mammillary eminence; *f*, Tuber cinereum; *g*, Pons Varolii; *g' g'*, Middle peduncles of the cerebellum; *h*, Medulla oblongata; *i i*, Inferior pyramids; *k k*, Olivary bodies; *l l*, Restiform bodies.

decussate with those of the opposite pyramid; the second pass in a direct manner from the cord; and the third, the arciform fibres, form a series of curves which wind round the olivary body, to join the restiform body.

The *corpora olivaria*, very rudimentary, are two elongated, oval-shaped bodies, on the outside of the inferior pyramids. They are separated from the pons Varolii by a slight depression, and are partly covered by the arciform fibres. A section shows the corpus olivarium to be a mass of white matter, in which is a hollow indented capsule of grey matter (*corpus dentatum*). This capsule has an anterior opening, and contains a nucleus of white

matter, from which a bundle of fibres springs. These fibres pass through the opening, and, joining the fibres from the inferior pyramids, constitute the *olivary columns*, which become continuous with the thalami optici and corpora quadrigemina.

The *restiform bodies* constitute the lateral, and greater part of the superior portion of the medulla, and form the connecting link between the cord and cerebellum. They are composed chiefly of white longitudinal fibres, derived from the superior and lateral columns of the cord, and the arciform fibres, and they increase in thickness as they pass forwards and upwards to form

the posterior peduncles of the cerebellum. The lateral walls of the fourth ventricle are formed by the divergence of the restiform bodies.

The *superior pyramids* are small bands of fibrous matter between the superior mesian fissure and restiform bodies on each side. They are a continuation of the superior columns of the cord, passing to the crura of the cerebrum.

The *intermediate fasciculi* are bundles of fibres, which pass from the lateral columns to the crura cerebri, between the restiform bodies and olivary fasciculi.

#### PONS VAROLII.

The pons Varolii is the transverse projection on the base of the brain, between the medulla oblongata and the crura of the cerebrum; it is lodged in the anterior depression on the basilar process of the occipital bone, and has a groove for the basilar artery along its middle line. It consists of a semicircular band of white fibres, which stretch as a bridge from one side of the cerebellum to the other, each extremity being curved upwards, to form the thick processes, which constitute the *middle peduncles* of the cerebellum.

#### CEREBELLUM.

The cerebellum, or lesser brain, is lodged in the posterior part of the cranial cavity, immediately above the medulla oblongata, and, in the domestic animals, behind the cerebrum, from which it is separated by the tentorium cerebelli. It is globular or elliptical in shape, the transverse diameter being the greater, and it consists of a body and three pairs of peduncles, the anterior of which connect it with the corpora quadrigemina, the middle with the pons Varolii, and the posterior with the restiform bodies of the medulla oblongata.

The body of the cerebellum is composed of grey matter externally, and white in the centre. Its surface presents numerous fissures, the two deepest of which run in a longitudinal manner, so as to divide it into a middle and two lateral lobes. The middle lobe projects beyond the lateral ones, and winds forwards, being known as the vermiform process; to its anterior extremity a thin plate of white fibre, the *valve of Vieussens*, is attached, and passes forwards to unite the anterior peduncles of the cerebellum.

This valve covers the aqueduct of Sylvius, and, with the vermiform process, forms the roof of the fourth ventricle. The posterior vermiform process is not so well marked. The smaller fissures, or sulci, divide the cerebellum into numerous lobules, which, when separated, are found to be indented with numerous secondary fissures. Each lobule consists of a periphery of grey matter, and a ramification of white fibres from the centre, so that the whole organ presents an arborescent appearance when cut across, an appearance which has gained the name of the *arbor vitæ*. The centre of the cerebellum contains a mass of white matter, within which is a denticulated capsule of grey matter (*corpus dentatum*), similar to that of the olivary bodies, from which white fibres proceed to the peduncles and to the valve of Vieussens, the centre white mass consisting of three bundles of fibres, each of which proceeds to a separate peduncle.

#### FOURTH VENTRICLE.

The fourth ventricle is the lozenge-shaped space between the cerebellum and the medulla, its roof being formed by the vermiform process and valve of Vieussens, its lateral walls by the superior pyramids, restiform bodies, and anterior peduncles of the cerebellum, and its floor by the medulla and pons Varolii; the testes being its boundary anteriorly, and the restiform bodies posteriorly. A fissure, continuous with the superior median fissure of the cord, passes along the floor of the ventricle into the aqueduct of Sylvius, which is a canal leading into the third ventricle; and on either side of this fissure a few fibres, which join the auditory nerve, unite at an angle somewhat resembling the barb of a pen, and constitute what is known as the *calamus scriptorius*. The lining membrane of this ventricle is continuous with that of the others, through the aqueduct of Sylvius, and with the subarachnoidean space; it forms a small fringe known as the choroid plexus of the fourth ventricle.

#### CEREBRUM.

The cerebrum, or great brain, occupies the anterior portion of the cranial cavity. It is ovoid in shape, with an irregularly flattened base, and consists of lateral halves or hemispheres, separated by the longitudinal fissure, in which the *falx cerebri* is



lodged. Anteriorly to the optic commissures, this fissure reaches quite to the base, but on the superior surface it is interrupted by a broad lamina of white fibres, the *corpus callosum*, or great commissure of the hemispheres; and, at the upper part of its posterior extremity, it is crossed by a species of bridge, under which the venæ Galeni pass to the interior. Deep, irregular *sulci* map out the surface of the hemispheres into numerous convolutions, the number of which, and the depth of the sulci, indicate the range of intelligence possessed by the animal, as the grey matter, which is believed to be the seat of the intellectual faculties, is found on the surface of the convolutions and on the sides and bottom of the sulci, so that the deeper and more numerous these are, the greater is the amount of grey matter in the brain.

In the domesticated animals, each hemisphere is divided into an anterior and a greater lobe, the posterior lobe which is found in man being wanting. The *anterior lobe*, which forms the bulk of the organ, is separated from the greater lobe by the *fissure of Sylvius*, not very distinct in the lower animals. This fissure, which is on a level with the optic tracts, and contains the middle cerebral artery, divides into two branches, one going upwards and forwards, the other downwards and inwards.

Between the bifurcations, a cluster of convolutions, forming the *island of Reil* or *central lobe*, converge towards the median line. These convolutions, from their being concealed in the fissure, are also called the *covered convolutions*.

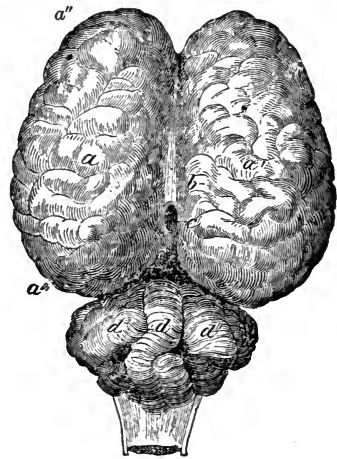


FIG. 173.

Superior aspect of the brain. *a*, Left, and *a'*, Right cerebral hemisphere; *a''*, Anterior lobe; *a'''*, Greater lobe; *b*, Corpus callosum; *c*, Opening of venæ Galeni; *d*, Vermiform process; *d' d''*, Lateral lobes of cerebellum.

## BASE OF THE BRAIN.

At the base of the brain are the *crura*, or *peduncles of the cerebrum*, two large bundles which, commencing in front of the pons Varolii, proceed forward in a divergent manner, entering

the under part of each hemisphere, and terminating in the optic thalami and corpora striata. These crura consist of two layers of white matter, with a mass of grey matter, the *locus niger*, interposed. Both layers are longitudinal, the superficial being continuous with the inferior pyramids, and the deep with the lateral and superior columns of the medulla and olivary fasciculi. They are covered by the corpora quadrigemina and optic thalami, and are crossed in front by the *optic tracts* and first portion of the optic nerves. These nerves proceed forwards and inwards, and decussate in the median line, the junction being termed the *optic commissure*. The lozenge-shaped space between the crura and the optic tracts is the *interpeduncular space*, in which we find the pituitary body or gland (*hypophysis cerebri*), the infundibulum, the corpus albicans, the locus perforatus posticus, and the pons Tarini.

The *pituitary* body or gland, is a small, round, reddish-grey, vascular body, lodged in the sella turcica, where it is held by a fold of dura mater; it is similar in structure to the ductless glands, and in the foetus it contains a central cavity, which communicates, through the infundibulum, with the third ventricle.

The *corpus albicans* is a round object, white externally and grey internally, situated behind the optic commissure. It is connected with the crura or bulb of the fornix. From its under surface is prolonged the *infundibulum*, a conical process of reddish colour, to the summit of which the pituitary body is attached. The funnel-shaped cavity in this process communicates superiorly with the third ventricle of the brain.

The remaining space between the corpus albicans and the crura of the cerebrum, forming part of the floor of the third ventricle, is the *locus perforatus posticus*, the numerous minute openings in which are for the passage of blood-vessels to the optic thalami. The white fibres which cross this space from one crus to the other form the *pons Tarini*.

On each side, rather to the front of the optic tracts, and near the commencement of the Sylvian fissure, is a triangular space of grey matter, the *locus perforatus anticus*. This space, like the posterior perforated space, is pierced for the passage of blood-vessels to the corpora striata, which lie immediately above.

The *tuber cinereum*, a spherical mass, connected with the corpus striatum, is situated immediately before the optic tract, and behind it is the *mammillary eminence*.

The *olfactory bulbs*, the apparent origin of the first pair of cranial nerves, arise from the anterior perforated spaces. They consist of a layer of white, surrounding an inner tube of grey matter, the interior being hollow, and communicating with the lateral ventricles.

## CORPUS CALLOSUM.

On removing the upper part of the hemispheres, by a section midway between the corpus callosum and the superior surface of the brain, a central mass of white matter, surrounded by a convoluted border of grey, is exposed. The white portion, known as the *centrum ovale minus*, is studded with numerous red spots, *puncta vasculosa*; caused by the escape of blood from the vessels which have been divided. A second section, made immediately above the corpus callosum, exposes the greatest amount of white matter, *centrum ovale majus*, above which, on the inner surface of the hemisphere, is the *gyrus fornicatus*, a convolution which follows the curve of the corpus callosum. The space between this convolution and the corpus is known as the *ventricle of the corpus callosum*.

The *corpus callosum*, or *great commissure (trabs cerebri)*, is the white, quadrilateral, and arched body which unites the hemispheres. Its lateral borders are hidden by the gyri fornicati and substance of the hemispheres, in which they become lost; while the middle of its superior surface, seen at the bottom of the longitudinal fissure, is free, and covered with pia mater. Along its middle line, between two delicate cords of white matter (*striae longitudinales*) runs a line or seam, the *raphe*, on either side of which may be seen the transverse markings, which indicate the direction of the fibres of which the corpus callosum is composed. Its inferior surface is connected posteriorly with the fornix, the remainder being divided by the septum lucidum into two parts, which form the roofs of the lateral ventricles. Its anterior extremity is reflected downwards, the bend being the knee or *genu*, and the tapering reflection the rostrum or beak. From the sides of the *rostrum* a delicate grey membrane, the *lamina cinerea*, extends to the tuber cinereum, and from the point divergent white bands, the *crura of the corpus*, extend to the anterior perforated spaces. The posterior extremity of the corpus callosum is thick, and forms a free rounded border, which is in connection with the fornix.

## LATERAL VENTRICLES.

When the corpus callosum is cut through, two large cavities in the substance of the hemispheres, the *lateral ventricles*, are exposed. These cavities are lined with a delicate membrane, covered with ciliated epithelium, which secretes a serous liquid similar to the spinal fluid. They are each possessed of a roof and two small recesses or cornua. The *roof* of the body of the ventricle is formed by the corpus callosum, and the *floor* by the corpus striatum in front, and the internal part of the hippocampus behind; while the *septum lucidum* stretches as a partition between the two ventricles. Running obliquely from behind forwards, and from without inwards, between the corpus striatum and the hippocampus, is a furrow in which a red vascular fringe, the *choroid plexus*, is lodged; and between the corpus striatum and the thalamus opticus is a narrow band of white matter, the *tænia semicircularis*.

The *anterior cornu* stretches from the body of the ventricle into the anterior lobe of the cerebrum, and is continued as a straight canal to the cavity of the olfactory lobe. The *descending cornu* passes backwards, outwards, and downwards, and then forwards and inwards, thus winding round the optic thalamus and crus cerebri, to terminate in a *cul-de-sac* in the great lobe, near the fissure of Sylvius. As there are no posterior lobes to the cerebrum of quadrupeds, so the posterior cornu of the lateral ventricle, which is found in man, is also wanting.

The *septum lucidum* is the thin, semi-transparent substance which stretches between the corpus callosum above and the fornix below, and forms the partition between the lateral ventricles. It is triangular in shape, and in man is said to be composed of two laminae, between which a perfectly isolated cavity, lined with epithelium and containing a serous fluid, is found. This cavity is the *fifth ventricle*, or ventricle of the septum lucidum; it appears to be wanting in the domesticated animals.

The *fornix* is the longitudinal band which extends as an arch along the lower border of the septum lucidum, and is attached to the posterior extremity of the corpus callosum. It is made up chiefly of white matter, and consists of a body and four pillars. The body is triangular in form, broad and flat behind, and narrow in front, where it dips down to leave the corpus callosum; its edges reach the choroid plexuses, and its inferior

surface rests on the velum interpositum. The anterior pillars descend in front of the anterior commissure of the brain, and, becoming inflected downwards and backwards by the sides of the third ventricle, pass to the corpus albicans, of which they form the external fibres.

Behind the anterior pillars of the fornix on each side, small openings pass downwards and backwards, and, uniting in the middle line, lead into the third ventricle. This is the *anterior common opening* or *foramen of Monro*, which forms a communication between the two lateral and the third ventricles.

The posterior pillars of the fornix pass downwards and outwards to the descending cornua of the lateral ventricles, and then become continuous with the hippocampi. The thin prolongation behind the choroid plexus is the *corpus fimbriatum* (*tænia hippocampi*), and the transverse white fibres which pass, like the strings of a harp, between the pillars, form the *lyra*.

The *hippocampus* (*cornu Ammonis*) is the large eminence, constructed of white matter externally and grey internally, which occupies the posterior part of the floor of the lateral ventricle. The hippocampi are continuous with the posterior pillars of the fornix, and are separated from the optic thalami by the choroid plexuses. Posteriorly they diverge and enter the descending cornua of the ventricles, occupying the *cul-de-sacs*. Towards their terminations they become enlarged, and each presents a number of rounded elevations, with indented edges somewhat resembling the foot of an animal, and called the *pes hippocampi*. The external white matter of the hippocampi is continuous, through the corpora fimbriata, with the fornix and corpus callosum.

The *corpus striatum* is the pear-shaped prominence which

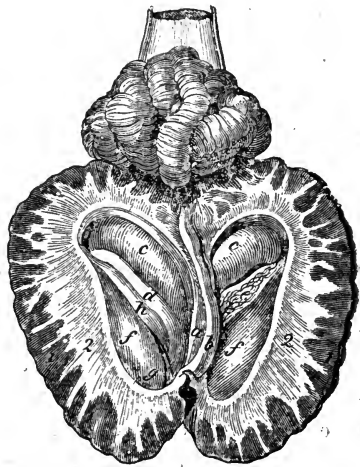


FIG. 179.

Lateral ventricles opened from above. 1, Grey matter; 2, White matter; a, Septum lucidum; b, Part of corpus callosum; c c, Hippocampus; d, Tænia semicircularis; e, Choroid plexus; f f, Corpus striatum; g, Anterior cornu of the ventricle; h, Furrow leading backwards to descending cornu.

occupies the anterior region of the floor of the lateral ventricle. Its broad anterior extremity stretches into the anterior cornu, while its narrow posterior extremity passes into the descending cornu, and is embedded in the substance of the hemisphere. The furrow along its oblique inner side, which separates it from the hippocampus and the optic thalamus, contains the choroid plexus and the *tænia semicircularis*. The corpora striata are grey externally, and are composed of grey matter, with numerous white fibres traversing it, which give it a striated appearance when cut across. They are the anterior ganglia of the cerebrum.

The *tænia semicircularis* is a narrow, white, semi-transparent band, which separates the corpus striatum from the optic thalamus. In front it is continuous with the fornix, becoming lost near the foramen of Monro; and posteriorly it disappears in the descending cornu. A vein beneath this band (*vena corporis striati*) receives the blood from the corpus striatum, and empties itself into the vena Galeni.

The *velum interpositum* is a double fold of pia mater, which passes into the anterior of the brain by the transverse fissure, passing between the corpora quadrigemina and the posterior part of the corpus callosum; it supports the fornix, being interposed between that body and the third ventricle. It is triangular in shape, its apex corresponding to the anterior common opening; it consists of a layer derived from the posterior surface of the cerebrum, and another from the anterior surface of the cerebellum. A process from it embraces the pineal gland; and its sides, projecting into the lateral ventricles, form the free borders of the choroid plexuses.

The *choroid plexus* is the vascular fringe in the lateral ventricle, which stretches from the foramen of Monro to the descending cornu, in the furrow between the hippocampus and the corpus striatum. It is a highly vascular membrane, containing looped plexuses of blood-vessels, and often calcareous matter. The two plexuses are united by a cord which passes through the foramen of Monro.

The *optic thalami* (beds of the optic nerves) are the two large oval bodies, seen when the fornix and hippocampi are removed, embracing the anterior portion of the crura cerebri, and placed in front of the corpora quadrigemina. They form the inferior ganglia of the brain, and, like the corpora striata, consist of grey matter, with intersecting white fibres, derived from the crura

cerebri and hemispheres. The anterior portions of the optic thalami approximate most closely. Their upper surfaces are convex and free, and their posterior surfaces project into the descending cornua of the lateral ventricles. Between the thalami and the crura cerebri are rounded grey prominences, the *corpora geniculata*, two on each side, the innermost of which connect the thalami with the nates, and the outermost, which are the larger, with the testes.

## THIRD VENTRICLE.

The third ventricle is the space between the optic thalami, which form its lateral walls, seen on removing the fornix and velum interpositum, which form its roof; its floor being formed by the tuber cinereum, corpus albicans, locus perforatus posticus, and lamina cinerea; its anterior boundary is known as the lamina terminalis. Three *commissures*, anterior, middle, and posterior, cross this ventricle. The *anterior* is a bundle of white fibres, which forms the anterior boundary of the ventricle, and unites the *corpora striata* behind the pillars of the fornix; the *middle*, consisting of grey matter, is the *grey or soft commissure*, which stretches between the thalami; and the *posterior*, which is white, and also unites the thalami, crosses the posterior part of the ventricle in front of the pineal gland. There are three openings into this ventricle—1st, Between the anterior and middle commissure, in the centre of the floor, a deep pit or cavity, the *iter ad infundibulum*, leads to the infundibulum; 2nd, Between the grey commissure and summit of the fornix, the foramen of Monro leads into the lateral ventricles; and 3rd, The *aqueduct of Sylvius*, or *iter e tertio ad quartum ventriculum*, which leads into the fourth ventricle. Through these

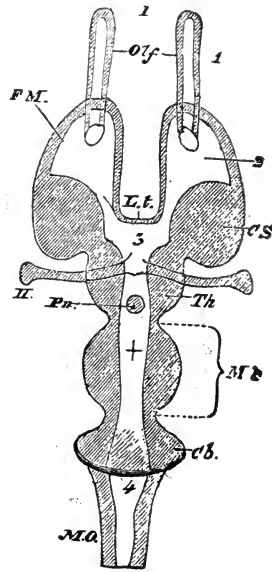


FIG. 180.

Horizontal and diagrammatic section, showing the cavities of the brain. 1, Olfactory ventricle; 2, Lateral ventricle; 3, Third ventricle; 4, Fourth ventricle; +, Aqueduct of Sylvius; Olf., Olfactory lobes; F.M., Foramen of Monro; L.t., Lamina terminalis; C.S., Corpus striatum; Th., Optic thalamus; Pn., Pineal gland; M.b., Middle brain; Cb., Cerebellum; M.O., Medulla oblongata, Origins of nerves:—I., Olfactory; II., Optic.

openings, the lining membrane of the third ventricle is continuous with that of the others.

The *pineal gland* is a small reddish-brown tubercle, placed behind and above the third ventricle, in a groove between the corpora quadrigemina, where it is kept in its place by a layer of the velum interpositum, to which it is attached. In shape it is somewhat conical, having a broad base and a free apex. The base, which is turned forwards, has bands of white matter, its

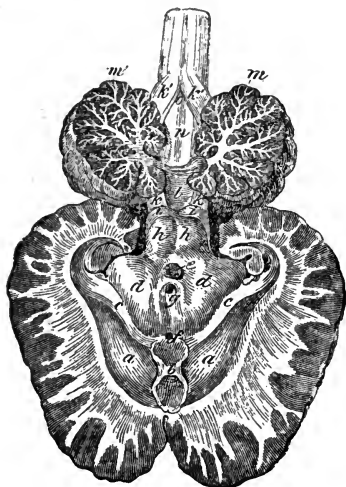


FIG. 181.

Entire brain opened from above—the fornix and hippocampi being partly removed. *ca*, Corpus striatum; *b*, Body of fornix; *cc*, Tæniae semicirculares; *dd*, Optic thalami; *e*, Pineal gland; *f*, Iter ad infundibulum; *g*, Opening of aqueduct of Sylvius; *hh*, Nates; *ii*, Testes; *kk*, Anterior peduncles of the cerebellum; *kk*, Posterior peduncles of the cerebellum; *l*, Valve of Vieussens; *m m'*, Cerebellum; *n*, Fourth ventricle; *o*, Calamus scriptorius.

*crura* or peduncles, passing from it to the optic thalami, which they join. The pineal gland is very vascular, and is constructed of arcolar tissue and cells, which contain, besides a viscid fluid, a quantity of sand-like matter (*acervulus cerebri*), which gives a gritty feel to the body. Though these grains often accumulate largely in old animals, they are not regarded as the products of disease. The use of this gland is not known; the ancients regarded it as the seat of the soul, and the chief source of nervous power.

The *corpora quadrigemina* or *optic lobes* are the four rounded eminences situated immediately behind the optic thalami, surmounting the posterior part of the *crura cerebri*, and forming part of the roof of the aqueduct of Sylvius. They are separated by a crucial depression, and are placed one before the other in the median line. In the horse the anterior pair, the *nates*, which are grey in colour, are larger than the posterior pair, the *testes*, which are rounded and farther apart. These bodies have connection with the olivary fasciculus, and, by the *crura cerebelli ad corpora quadrigemina*, or anterior peduncles, are joined to the cerebellum. The white processes (*brachia*), given off from each side, pass to the optic thalami and to the commencement of the optic tracts. The corpora quadrigemina are ganglionic in structure, with inter-



acing white fibres, the testes, in addition, having an external white tunic.

The brain is developed from three *cerebral vesicles*, the cavities in which relatively represent the third and fourth ventricles and the aqueduct of Sylvius; hence these three spaces and their surroundings may be said to constitute the primary division of the brain, and the parts have been named respectively the fore, the middle, and the hind brain. The lateral ventricles and hemispheres are regarded as offshoots or expansions of the fore-brain.

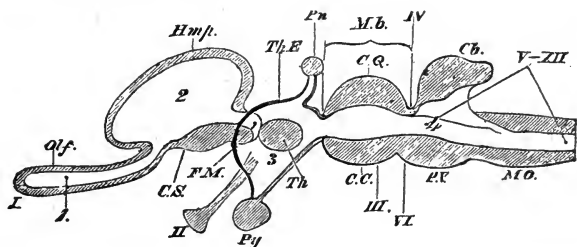


FIG. 122.

Longitudinal, vertical, and diagrammatic section of a brain. *Hmpt.*, Cerebral hemispheres; *Py.*, Pituitary body; *Th.E.*, Thalamencephalon, or fore-brain (the dark line joining *Pn.* and *Py.* represents the lamina terminalis); *C.Q.*, Corpora quadrigemina; *C.C.*, Crura cerebri; *P.V.*, Pons Varolii. The origins of the twelve cranial nerves are marked in order, in roman figures. For other descriptions, see explanation of Fig. 180.

#### ENCEPHALIC CIRCULATION.

The circulation of the blood in the brain differs in a remarkable degree from that of any other region, one great peculiarity being that the general arrangement of the vessels in the substance of the organ is almost entirely capillary. The larger arteries all ramify in the dura mater, and in the sulci between the convolutions, and the smaller branches, from which the extremely fine penetrating twigs are given off, in the pia mater. The veins also are extremely small, and as a rule do not unite to form trunks until they emerge from the nervous substance, while their superficial branches, dispersed over the surface of the brain, enter large sinuses or canals within the dura mater. These sinuses are remarkable for their rigidity, which enables them to preserve an almost uniform diameter. Another remarkable feature is the great freedom of anastomosis which exists among the arteries, in the larger trunks, as well as in the smaller branches.

## ARTERIAL CIRCULATION.

Four large arteries, two internal carotids, and two cerebro-spinal branches of the occipital arteries, convey the blood to the encephalon. An examination of the tortuous course of these arteries shows how beautifully Nature has provided against injury to the delicate brain-structure, by the blood impinging with too great a force against its base.

The CEREBRO-SPINAL ARTERIES enter the neural canal through the internal foramina in the wings of the atlas, and wind round the cord to its inferior surface, where they each divide into two branches, one of which, the *anterior* or *cerebral branch*, passes forwards and joins its fellow near the middle of the medulla

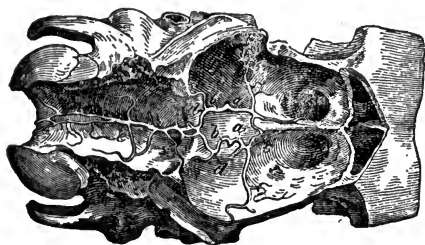


FIG. 183.

The encephalic arteries. *a*, Anterior branch of the right, and *a'*, of the left carotid arteries; *b* *b'*, Posterior communicating branches; *c*, Inosculation of the anterior branches; *d* *d'*, Inosculation of posterior communicating, and posterior cerebral branches of basilar artery; *e*, Basilar trunk.

oblongata, to form the *basilar artery*. The *posterior branches* pass backwards, and also coalesce to form the *middle spinal artery*, which runs along the longitudinal fissure of the cord.

The **BASILAR ARTERY** is continued forwards in the longitudinal furrow on the inferior surface of the pons Varolii, near the anterior border of which it divides into two branches, the *pos-*

terior cerebrals. In its course the basilar artery gives off—*1st*, Several small branches, which penetrate the surface of the medulla oblongata and pons Varolii; *2nd*, The *posterior cerebellars*, right and left, which, like the terminal branches, are given off at right angles behind the posterior border of the pons. They are carried outwards, ascending over the pons, and then, inflected backwards, are distributed over the lateral and posterior parts of the cerebellum. *3rd*, The *anterior cerebellar arteries*, two or three on each side, the principal being given off just in front of the pons, on the outer side of which it ascends in an outward and slightly backward direction, to be distributed to the anterior surface of the cerebellum.

The terminal branches, the **POSTERIOR CEREBRAL** arteries, are the largest, and form the posterior border of that peculiar arterial

circle at the base of the brain, known as the **CIRCLE OF WILLIS**. They are joined by the posterior communicating branches of the internal carotid, and pass outwards round the *crura cerebri* towards the transverse fissure, anastomosing with the middle cerebrals, and are finally distributed over the posterior part of the cerebrum. In their course, these arteries give off branches which penetrate the interpeduncular space, and a branch distributed over the *velum interpositum*.

The **INTERNAL CAROTID ARTERY** is one of the three terminal branches of the common carotid. It enters the cranial cavity through the *foramen lacerum basis cranii*, and through the cavernous sinus, where it forms a double curve. The first of these curves, which occupies the carotid fossa in the sphenoid bone, has its convexity looking forwards, and the second has its convexity looking backwards, so that the two curves resemble the letter **S**. After the second curve, a transverse branch joins the right and left trunks, and then the internal carotid pierces the *dura mater*, and, at the fissure of Sylvius, divides into posterior communicating and a branch which furnishes the anterior and middle cerebral arteries.

The **POSTERIOR COMMUNICATING ARTERY**, which forms the lateral boundary of the circle of Willis, passes backwards by the side of the interpeduncular space, and inosculates with the posterior cerebral branch of the basilar artery.

The **ANTERIOR CEREBRAL BRANCHES** are carried forwards to the longitudinal fissure, where they converge and unite; and, passing through the fissure, after a short course, the vessel divides into two branches, which subdivide to supply the *corpus callosum*, the

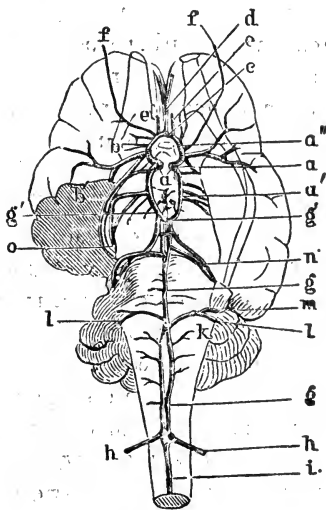


FIG. 134.

Arteries at the base of the brain. *a*, Internal carotid; *a'*, Its superior; *a''*, Its inferior branch; *b*, Middle cerebral; *b'*, Artery of the choroid plexus; *c*, Transverse communicating; *d*, Anterior cerebral; *e e*, Anterior meningeal; *f*, Branch anastomosing with meningeal branch of ophthalmic; *g g*, Basilar; *g' g'*, Posterior cerebrals; *h h*, Cerebro-spinals; *i*, Middle spinal; *k*, Arteries of the medulla; *l l*, Posterior cerebellar; *m*, Artery of internal ear; *n*, Anterior cerebellar; *o*, Artery supplying optic thalamus, corpora quadrigemina and choroid plexus.

third ventricle, and the under surface of the cerebrum. Sometimes, instead of forming a single trunk, the anterior cerebral arteries are joined by a transverse branch, termed the *anterior communicating artery*. These vessels, or they and their communicating branch, form the antero-lateral and anterior boundaries of the circle of Willis.

The MIDDLE CEREBRAL ARTERY passes directly outwards to the fissure of Sylvius, where it divides into numerous branches, which ramify over the lateral and inferior surfaces of the cerebrum, and anastomose with branches of the anterior and posterior cerebrals. Just before this artery divides, it gives off a small branch, the *anterior choroid*, which enters the descending cornu of the lateral ventricle, and supplies the choroid plexus.

#### VENOUS CIRCULATION.

The encephalic venous circulation consists of veins and vascular triangular channels of various sizes, found within the dura mater. These are the *venous sinuses*, which are lined by a continuation of the inner tunic of the veins, and which, like the other veins of the brain, are destitute of valves, but present numerous bands or cords stretched across their anterior so as to prevent distention. The veins are divided into superficial and deep.

The SUPERFICIAL VEINS are distributed over the whole surface, mostly in the sulci, between the convolutions; they receive small capillary branches from the substance, and terminate, those from the superior surface in the longitudinal sinus, and those on the inferior and lateral surfaces in the lateral and other sinuses.

The cerebellar veins are, like the cerebral, scattered over the whole surface of the cerebellum, and mostly terminate in the petrosal sinus.

The DEEP or VENTRICULAR VEINS arise by very minute branches, which form intimate plexuses in the ventricles, the chief being the veins of the corpora striata, and those of the choroid plexuses, uniting to form the venæ Galeni, which leave the interior through foramina at the posterior part of the longitudinal fissure, and terminate in the longitudinal sinus.

#### SINUSES.

The principal sinuses of the dura mater are the superior and inferior longitudinal, two lateral, two petrosal, two cavernous, the occipital, and the transverse.

The SUPERIOR LONGITUDINAL SINUS, situated in the attached border of the falx cerebri, commences at the crista galli process, and terminates at the ossific tentorium, in a reservoir termed the torcular *Herophili*, or confluent of the sinuses, which bifurcates and joins the lateral sinuses.

The INFERIOR LONGITUDINAL SINUS is small, and not always present. It is situated in the lower part of the falx, below the superior one, pursuing a similar course, and discharging into the torcular *Herophili*.

The LATERAL SINUSES, situated within the folds of the tentorium cerebelli, receive the blood from the longitudinal sinus, and terminate in veins, which empty themselves into the temporal veins, through the parieto-temporal conduits.

The PETROSAL SINUSES, situated at the sides of the petrosal bone, form a communication between the parieto-temporal confluent and the cavernous sinuses.

The CAVERNOUS SINUSES are situated under the dura mater at the sides of the sella turcica, and are united by an arched branch, sometimes termed the *transverse sinus*, which winds round the back of the pituitary gland; posteriorly they open through the foramen lacerum basis cranii into the subsphenoidal confluent. Anteriorly these sinuses lead to the alveolar veins.

The OCCIPITAL SINUSES, which are very irregular, are situated in the falx cerebelli, and terminate, through the condyloid foramina, in the subsphenoidal confluent.

#### EMERGENT VEINS.

The venous blood from the encephalic sinuses leaves the cranium in various ways by the emergent vessels. These are the Parieto-temporal and Subsphenoidal confluent, the Spinal and Alveolar veins.

The PARIETO-TEMPORAL CONFLUENT occupies the conduit of the same name, receiving the blood of the longitudinal and transverse sinuses, and discharging into the temporal veins, which arise chiefly in this confluent.

The SUBSPHENOIDAL CONFLUENT lies along the side of the basi-occipital and basi-sphenoid bones, terminating anteriorly in a blind end. The cavernous sinus opens into it through the foramen lacerum basis cranii, the internal carotid artery passing through the orifice. Posteriorly it terminates as the anterior

branch of the occipital vein. and furnishes branches leading to the pterygoid veins.

The SPINAL veins are simple in their arrangement, being satellites of the several arteries.

The ALVEOLAR vein has already been described as a branch of the glosso-facial (see p. 447).

#### CRANIAL NERVES.

The nerves which are transmitted through the foramina at the base of the cranium are denominated cranial nerves. They leave in pairs, regularly-disposed, one on the right side and the other on the left, and are named numerically, according to the order in which they leave the cavity, and by names derived from the parts to which they are distributed, or the functions they perform.

The cranial nerves are differently enumerated by different authorities, some dividing them into nine, and others into twelve pairs. The first classification is that of Willis, who makes the number correspond with the number of foramina through which they find their exit; and the last that of Scemmering, who counts the number of the apparent roots of the nerves. They are also arranged in three divisions, according to their functions, as Nerves of special sensation; Nerves of motion; and Mixed or compound nerves—that is, nerves which contain both motor and sensory fibres. Scemmering's classification is the one adopted in this work.

#### DESIGNATION OF THE CRANIAL NERVES.

According to Willis's Classification.	According to Scemmering's Classification.	According to their Distribution or Function.
1	1	Olfactory.
2	2	Optic.
3	3	Motores oculorum.
4	4	Pathetici (trochleares).
5	5	Trifacial (trigemini).
6	6	Abducentes.
7	{ 7	Facial (portio dura).
	{ 8	Auditory (portio mollis).
	{ 9	Glosso-pharyngeal.
8	{ 10	Pneumogastric (vagus, par vagum).
	{ 11	Spinal accessory.
9	12	Hypo-glossal (sublingual).

## FIRST PAIR—OLFACTORY NERVES.

The olfactory, or nerve of the special sense of smell, arises by three roots—an *inner, short* root of white fibres, derived from the inner and posterior part of the anterior lobe; an *outer, long* root, also white, which crosses the Sylvian fissure into the greater lobe, where it is continuous with fibres of the optic thalamus; and a *middle* or *grey* root, which also contains white fibres from the corpus striatum, and arises from a papilla of grey matter (caruncula) in the mammillary eminence. The union of these roots forms the olfactory lobe, which, as it passes forward, swells into an oblong mass, the olfactory bulb, which rests on the cribriform plate of the ethmoid bone. From the under part of the bulb spring the olfactory nerve filaments, which pass through the foramina in the cribriform plate, and are distributed in the mucous membrane of the posterior part of the nasal fossa. These filaments are divisible into three groups, an *outer*, sent to the turbinated bones and surface of the ethmoid; a *middle*, which supplies the mucous membrane of the roof of the fossa; and an *inner*, spread over the septum nasi.

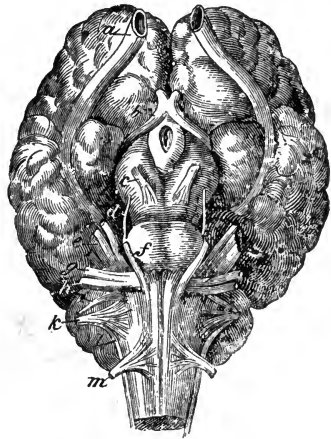


FIG. 135.

Base of the brain—showing the apparent origins of the cranial nerves. *a*, Olfactory; *b*, Optic; *c*, Motor oculi; *d*, Pathetic; *e*, Trifacial; *f*, Abducens; *g*, Portio-dura; *h*, Portio-mollis; *i*, Glosso-pharyngeal; *k*, Pneumogastric; *l*, Spinal accessory; *m*, Hypo-glossal.

## SECOND PAIR—OPTIC NERVES.

The optic, or nerve of the special sense of sight, is a large nerve, which has its deep origin in the corpora geniculata, optic thalamus, and corpora quadrigemina; the fibres from these three different sources uniting to form the optic tract, which winds round the crus cerebri to join its fellow, and form the optic commissure. After leaving the commissure, the nerves become rounded, and diverge to pass through the optic foramina, where they receive a covering of dura mater, which immediately splits

into two portions, one of which forms the periosteum of the orbit, and the other a sheath for the nerve. After piercing the sclerotic and choroid coats of the eyeball, the nerve expands into the nervous retina. A little behind the eyeball, the nerve is pierced to its centre for the passage of a small artery, the *arteria centralis retinae*, which supplies the retina.

In the optic commissure a peculiar decussation of nerve fibres takes place; while the outer fibres of the optic tract continue their course direct to the eye of the same side, the innermost pass to that of the opposite side; at the same time, some of the fibres cross from one tract to the other, and have no connection with the eyes; while others, it is said, proceed from eye to eye, without having communication with the brain.

#### THIRD PAIR—MOTORES OCULORUM.

This, the common motor nerve of the eye, has its apparent origin on the inner side of the *crus cerebri*, close to the *pons Varolii*, its course lying between the posterior cerebral and anterior cerebellar arteries; its deep origin may be traced to the *locus niger*, *pons Varolii*, and *corpora quadrigemina*. It makes its exit from the cranial cavity through the *foramen lacerum orbitale*, into the orbital fessa, where it divides into several branches, supplying the superior, internal, and inferior recti, inferior oblique, and *levator palpebrae* muscles, and also branches to the lenticular ganglion.

#### FOURTH PAIR—PATHETIC NERVES.

This is a motor nerve, and the smallest of the cranial nerves; it has its superficial origin by the side of the *pons Varolii*, but its deep fibres may be traced to the valve of Vieussens and the *corpora quadrigemina*. Winding round the *crus cerebri*, this nerve passes through the outer wall of the cavernous sinus, leaves the cranium through the *foramen patheticum*, and is distributed to the superior oblique muscle of the eye. It communicates with the sympathetic, near the cavernous sinus.

#### FIFTH PAIR—TRIFACIAL NERVES.

Called also the trigeminal, this is the largest of the cranial nerves, and, being a nerve of common sensation, of motion, and indirectly, perhaps, of special sense, belongs to the class of mixed nerves.



It resembles a spinal nerve in having its origin by two roots, sensory and motor, and in having a ganglion on the sensory root. It arises on the side of the pons Varolii; and the sensory root, which is the larger, may be traced to the restiform bodies and lateral columns of the cord, the motor root having its deep origin near the floor of the fourth ventricle. The nerve passes through an opening in the dura mater, at the apex of the petrous temporal bone, where the posterior root spreads out into a large ganglion, the *Gasserian*, the anterior root passing beneath without any connection. The Gasserian ganglion gives off the ophthalmic, superior maxillary, and inferior maxillary branches.

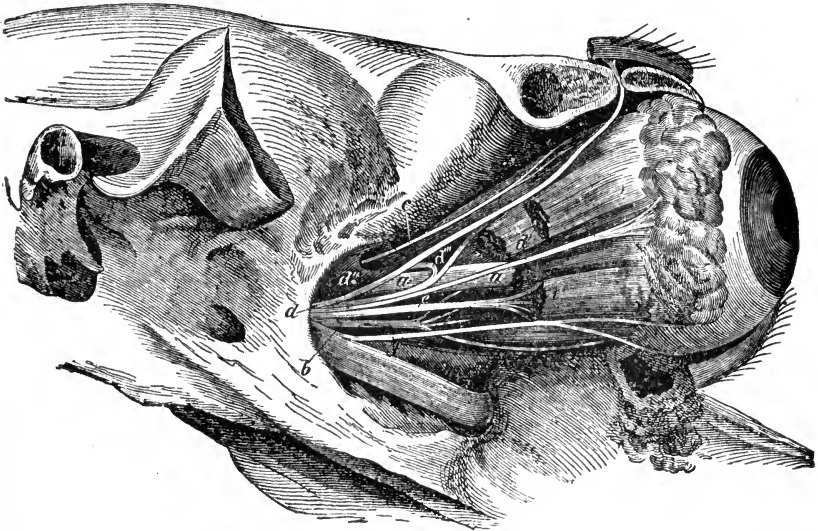


FIG. 186.

Right orbit opened to show the nerves of the eye. *a a*, Optic; *b*, Motor oculi; *c*, Patheti; *d*, Ophthalmic division of fifth pair; *d'*, Lachrymal; *d''*, Supraorbital; *d'''*, Nasal; *e*, Abducens; *e'*, Rectus externus muscle; *f*, Orbital branch of superior maxillary nerve.

The **OPHTHALMIC NERVE**, the smallest of the three divisions of the trifacial nerve, passes forwards by the outer wall of the cavernous sinus, in company with the third and sixth nerves, enters the orbital fossa through the foramen lacerum orbitale, and divides into three branches, the frontal, lachrymal, and nasal.

The *frontal* or *supraorbital nerve* is a large, flat branch, placed on the internal wall of the optic fossa; it ascends parallel to the superior oblique muscle, passes through the supraorbital foramen, and, after giving a branch to the upper eyelid, divides

into several branches, some distributed to the skin of the forehead, others to the muscles above the eye. This nerve communicates, and forms a plexus with the anterior auricular nerve.

The *lacrimal nerve*, the smallest of the three, passes straight up to the lacrimal gland, which it supplies, together with branches to the muscles and tegument of the anterior part of the ear, anastomosing with the anterior auricular nerve.

The *nasal or palpebro-nasal nerve*, the largest branch of the ophthalmic, curves inwards between the retractor and levator oculi, and re-enters the cranial cavity through the internal orbital foramen, with the ophthalmic artery; it then passes through the cribriform plate of the ethmoid, and divides into two branches, which ramify in the pituitary membrane on the walls of the nasal fossa. Before entering the internal orbital foramen, it gives off a long branch to the membrana nictitans and lower eyelid, another to the lacrimal sac, and sensory roots to the ophthalmic ganglion.

The SUPERIOR MAXILLARY NERVE leaves the cranium through the foramen rotundum, and gains the orbit in company with the internal maxillary artery, crosses the lower part of the orbit, enters the maxillary hiatus, passes through the infraorbital or dental canal, and emerges on the face, at the infraorbital foramen, where it divides into numerous facial branches. The lateral branches of the superior maxillary nerve are—

1. The *orbital branch*, which leaves the trunk in the orbit, and is distributed to the eyelids and integument.

2. The *anterior palatine or palato-maxillary*, which enters the palatine foramen, and accompanies the palatine artery, giving branches to the palate and gums.

3. The *posterior palatine, or staphyline*, which accompanies the staphyline artery, and is distributed to the soft palate.

4. The *spheno-palatine, or nasal*, which passes through the spheno-palatine foramen, is distributed to the mucous membrane of the nasal chamber, and sends a branch to the spheno-palatine or *Meckel's* ganglion.

5. The *dental branches*, which are given off behind and in the infraorbital canal, consist of posterior and anterior; the former supplying the molar teeth, and sending a branch to the maxillary sinus, and the latter furnishing nerves to the incisor and canine teeth.

The terminal branches of the superior maxillary nerve, supe-

rior, middle, and inferior, are distributed to the nose, false nostril, upper lip, and muscles and integument of the face, and form intimate plexuses with branches of the seventh pair or facial motor nerves.

The INFERIOR MAXILLARY NERVE, the largest of the three divisions of the fifth, unites with the anterior root of the nerve immediately after it passes through the oval opening in the dura mater, so that it is both sensory and motor. The course of this nerve is through the foramen lacerum basis cranii, and between

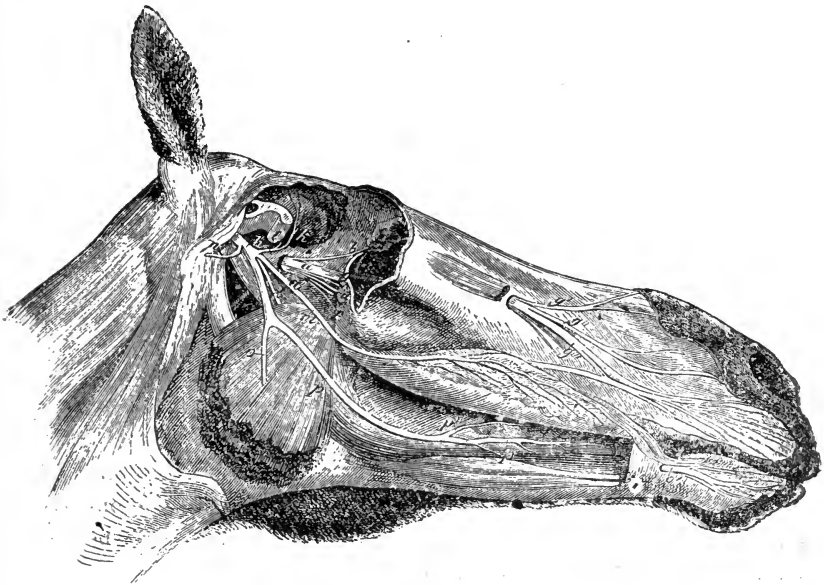


FIG. 187.

Nerves of the right side of the head—the maxillary ramus and cheek being removed. *a*, Superior maxillary branch of fifth; *a'*, Spheno-palatine; *b*, Orbital; *c*, Branch of spheno-palatine; *d*, Palatine; *e*, Superior dental; *f*, Staphyline; *g*, Superior maxillary trunk entering infraorbital foramen; *g'*, Superior; *g''*, Middle; *g'''*, Inferior nasal nerves; *h*, Inferior maxillary branch of fifth; *i*, Masseter; *k*, Anterior deep temporal; *l*, Pterygoid; *m*, Buccal; *n*, Subzygomatic; *o*, Inferior dental; *o'*, Mental; *p*, Lingual; *p'*, Its superficial; *p''*, Its deep branch.

the pterygoid muscles, to the inferior dental foramen, which it enters, and, passing through the lower jaw, makes its exit at the anterior maxillary or mental foramen, and terminates in the mental nerves. In its course it gives off masseter, buccal, internal pterygoidean, subzygomatic, lingual, mylo-hyoidean, and dental branches.

The *masseter branch* is detached from the trunk at the base of the cranium, passing through the sigmoid notch in front of the

temporo-maxillary articulation, and is distributed to the masseter muscle. It gives off branches to the temporal muscle.

The *buccal* nerve is directed forwards, traverses the external pterygoid muscle, and is distributed to the buccinator muscle and to the mucous membrane of the cheek, descending to the commissures of the lips and the labial glands. In its course it gives small branches to the external pterygoid muscle, a branch (the anterior deep temporal nerve) to the temporal muscle, and branches to the molar glands. The branches to the pterygoid and temporal muscles are for the most part motor, the others sensory.

The *pterygoid* nerve supplies the pterygoid muscles.

The *subzygomatic* or *superficial temporal* nerve winds round the ramus of the lower jaw, and, passing between the parotid gland and the posterior border of the jaw, joins the nerves of the seventh pair. In its course it gives off twigs to the guttural pouch, parotid gland, and teguments of the temporal region.

The *lingual*, considered by some authorities as the *gustatory* or nerve of the *special sense of taste*, is the principal branch of the inferior maxillary; its course lies between the ramus of the jaw and the pterygoid muscles, round which it winds anteriorly, to reach the base of the tongue, along the side of which, under the mucous membrane, it runs to the tip, giving off in its course numerous branches to the lingual papillæ, the mucous membrane of the mouth and gums, and the sublingual gland. The lingual receives the *chorda tympani* branch of the facial, and anastomoses with terminal branches of the twelfth nerve; it also sends a branch to the submaxillary ganglion.

The *mylo-hyoidean* nerve distributes branches to the mylo-hyoideus and digastricus muscles, and twigs to the submaxillary glands.

The *dental* branches are given off in the dental canal, to supply the teeth of the lower jaw; one series supplying the molars, the other the front teeth.

The *mental* or terminal branches of the nerve, issuing from the mental foramen, are distributed to the lower lip, and communicate with the facial nerve.

The sympathetic ganglia, communicating with the fifth pair, are the ophthalmic or lenticular, the spheno-palatine or Meckel's, and the otic. (See Sympathetic System.)

SEVENTH PAIR—PORTIO DURA, OR FACIAL.

SIXTH PAIR—ABDUCENS.

This is a nerve of motion, has its apparent origin close behind the pons Varolii, at its junction with the inferior pyramids, and its fibres can be traced to the inferior pyramids and lateral bundles of the medulla. From its origin it passes forwards through the foramen lacerum orbitale, in company with the third and the ophthalmic branch of the fifth nerves, and is distributed to the abductor oculi, or external rectus, and the external portion of the retractor oculi muscles.

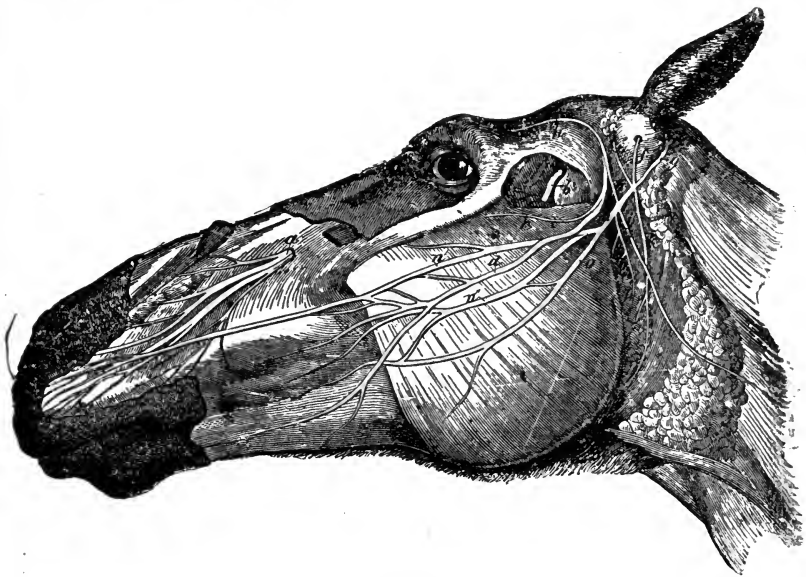


FIG. 188.

Left side of the face—showing the distribution of the facial portions of the fifth and the seventh nerves. *a*, Infraorbital; *b*, Masseter; *c*, Superior; *d*, Inferior branch of subzygomatic; *e*, Anterior; *f*, Middle; *g*, Posterior auricular; *h h*, Posterior temporal; *i*, Cervical branch; *k*, Styloid; *lll*, Parotid branches; *m*, Facial; *n n' n''*, Its superior portion; *o*, Its inferior portion.

SEVENTH PAIR—PORTIO DURA, OR FACIAL.

This nerve has its apparent origin in a depression in the medulla oblongata between the olivary and restiform bodies: its deep origin can be traced to the floor of the fourth ventricle and olivary fasciculus. From its origin it passes outwards, in company with the eighth nerve, along with which it enters the meatus auditorius internus, and thence into the aqueduct of Fallopius.

where it bends upon itself and forms a slight enlargement, the *genicular ganglion*, making its exit through the stylo-mastoid foramen, where it lies deeply buried beneath the parotid gland. Afterwards, inflected forwards, it passes between the gland and the guttural pouch to gain the posterior border of the maxilla, round the cervix of which it turns, and, reaching the external surface of the masseter muscle, terminates in two or three branches, which anastomose with the subzygomatic branch of the fifth, forming the subzygomatic plexus. At the genicular ganglion the seventh nerve is joined by a slender cord, the *nerve of Wrisberg*, which is regarded by some authorities as the sensory root of the seventh, by others as a connecting medium between the seventh and eighth nerves.

In its course the facial nerve gives off numerous branches; some before leaving the bone, the intraosseous, and some after leaving it, extraosseous.

The intraosseous branches are the *superficial petrosal*, which, leaving the genicular ganglion, re-enters the cranial cavity by the Fallopian hiatus, and passing through the cavernous sinus, it receives a branch from the cavernous plexus of the sympathetic. The nerve thus formed—the *Vidian nerve*—traverses the fissure and conduit of the same name and gains the orbital hiatus, where it joins Meckel's ganglion, to which it thus supplies motor and sympathetic roots. A little to the outside of the above, the *lesser superficial petrosal* furnishes motor fibres to the otic ganglion, and a small filament supplies the stapedius muscle. The *chorda tympani* branch is given off in the aqueduct of Fallopius. It enters the cavity of the tympanum, passes through the middle of the chain of small bones, or auditory ossicles, and, leaving the cavity through the Glaserian fissure, after a short course under the pterygoid muscle, joins the lingual branch of the fifth. The last intraosseous branch is one which anastomoses with the pneumogastric.

After emerging from the stylo-mastoid foramen, the facial nerve gives off *styloid* branches to the stylo-hyoid and digastricus muscles; a *cervical branch*, which passes downwards below the *deprimens aurem* muscle to the panniculus and skin of the neck; twigs to the guttural pouch and parotid gland; and lastly, the anterior, posterior, and middle auricular nerves.

The *anterior auricular* nerve ascends over the front of the ear, supplying the muscles and uniting with branches of the fifth,

to form the auricular plexus. It gives twigs to the anterior auricular muscles; to the orbicularis palpebrarum, and levator palpebræ superioris externus. The *posterior auricular* nerve passes upwards with the posterior auricular artery, and supplies the posterior muscles of the ear and the skin. The *middle auricular* nerve enters the concha, to the inner surface and cartilage of which it is distributed.

The *terminal* or *temporo-facial* branches of the facial nerve are in two sets; an inferior, which passes downwards to the lower lip and muscles of the side of the cheek and lower jaw; and a superior, which supplies the muscles of the nose and tissues of the upper lip. They anastomose with the terminal branches of the superior and inferior maxillary divisions of the fifth nerve, and, from the peculiar looped and radiate manner of their terminations, have obtained the name of *pes anserinus*.

#### EIGHTH PAIR—PORTIO MOLLIS, OR AUDITORY.

The nerve of the special sense of hearing has its origin on the medulla oblongata, close to the facial nerve. Its deep roots are anterior and posterior, the one springing from the central grey matter of the medulla, and the other from the floor of the fourth ventricle. The auditory nerve enters the meatus auditorius internus in company with the seventh, and at the bottom of the passage divides into two branches; an *anterior* or *cochlear*, distributed to the cochlea, and a *posterior* or *vestibular*, which supplies the vestibule and the remaining portions of the internal ear.

#### NINTH PAIR—GLOSSO-PHARYNGEAL.

This is a mixed nerve, principally distributed to the tongue and pharynx, and it arises from the medulla, the fibres composing it being traceable to the restiform bodies and the olivary fasciculi. It pierces the dura mater through a distinct opening, and leaves the cranium through the foramen lacerum basis cranii; previously however presenting a gangliform swelling, the *petrosal* or *Andersch's ganglion*, which rests on the petrosal bone. Leaving the cranium, it passes downwards and forwards, between the guttural pouch and pterygoid muscles, and along the posterior border of the cornu of the os hyoides, to gain the base of the tongue, being distributed to the mucous membrane and substance, principally of the base and sides of that organ.

Its branches are the *nerve of Jacobson*, given off from the petrosal ganglion, and distributed to the tympanum and its membrane; filaments to the superior cervical ganglion; a branch to the carotid plexus; branches to the muscles of the pharynx; and a communicating branch to the pneumogastric nerve.

#### TENTH PAIR—PAR VAGUM, OR PNEUMOGASTRIC.

This is a mixed nerve, which originates by motor and sensory roots. Its apparent origin is from a groove in the medulla oblongata, immediately behind the ninth nerve; its deep roots can be traced to the restiform bodies, olivary fasciculi, and the grey matter near the floor of the fourth ventricle. This nerve is remarkable for its extent; for the numerous dissimilar organs to which it is distributed; and for its free and extensive anastomoses with other cerebro-spinal, and with the sympathetic nerves. It pierces the dura mater in company with the eleventh nerve, and passes through the foramen lacerum basis cranii, previously presenting an oblong grey mass, the *jugal ganglion*.

After leaving the cranium, the par vagum descends behind the guttural pouch, close to the superior cervical ganglion, crosses to the inner side of the occipital artery, and joining the common carotid, proceeds down the neck in the same sheath with that artery. After entering the thorax, the course of the nerve on either side varies. The *right nerve*, turning obliquely round the brachial artery, proceeds backwards by the side of the trachea to the origin of the bronchi, where it gains the under and right side of the œsophagus; while the *left nerve* passes along the anterior aorta, crosses the origin of the posterior aorta, and gains the upper and left side of the œsophagus, the two being continued to the stomach and the solar plexus.

The branches of the par vagum are—

1. An anastomotic branch to the facial near its origin.
2. Numerous branches to the superior cervical ganglion.
3. A sensory-motor branch to the pharynx, which anastomoses with the pharyngeal branch of the ninth.
4. The *superior laryngeal*, which passes to the sides of the larynx, which it enters through a hole in the thyroid cartilage, being distributed to the mucous membrane, and giving motor fibres to some of the muscles of that organ.
5. Filaments to the inferior cervical ganglion, two or three



large ones being given off by the *right nerve*, and one long small branch, by the *left nerve*.

6. The *inferior*, or *recurrent laryngeal nerve*.—On the right side, this nerve leaves the par vagum as it passes the first rib, and winds round the origin of the dorsal artery, to gain the side of the trachea. The left one is given off near the root of the lungs, and is inflected round the posterior aorta to reach the trachea. Passing up the trachea below the carotids, the nerves reach the larynx, and are distributed to all its intrinsic muscles excepting the crico-thyroideus, and giving off in their course the tracheal and the recurrent œsophageal nerves.

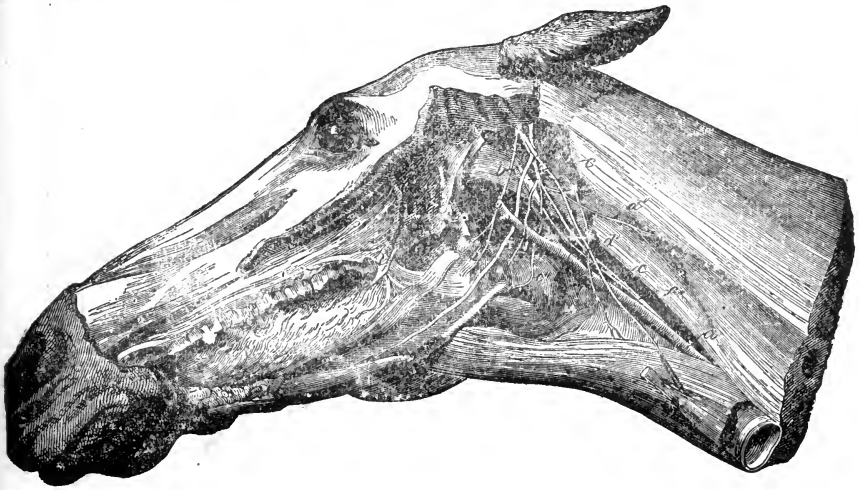


FIG. 189.

Ninth, tenth, eleventh, and twelfth cranial, first cervical, and part of the sympathetic nerves—the left maxillary ramus and parotid gland being removed. *a*, Carotid artery; *b*, Glosso-pharyngeal; *b'*, Its pharyngeal; *b''*, Its lingual branch; *c c*, Pneumogastric; *c'*, Pharyngeal; *c''*, Superior laryngeal; *d d' d''*, Spinal accessory; *e e*, Hypo-glossal; *f*, Great sympathetic; *f'*, Superior cervical ganglion; *f''*, Anastomosis of sympathetic and pneumogastric; *g*, First cervical nerve.

7. Cardiac branches which help to form the cardiac plexus.

8. Numerous branches at the root of the lungs, which form the *bronchial plexus*, from which branches are distributed to the divisions of the bronchi, and to the lungs.

After this plexus is formed, each par vagum is continued along the œsophagus by a superior and an inferior branch. After a short course, the superior branches unite, and the inferior branches doing the same, they accompany the œsophagus, one above and the other below, supplying it with numerous twigs, till they enter the abdomen through the œsophageal opening of the

diaphragm, when the inferior branch terminates at the lesser curvature of the stomach, in a plexus which sends numerous branches to the right sac of that organ; and the superior branch, passing to the left of the cardiac orifice, becomes lost in the *solar plexus*. In passing it gives numerous twigs to the left sac of the stomach, mingles its branches with those of the sympathetic from the hepatic plexus, and anastomoses with the terminal twigs of the right nerve.

#### ELEVENTH PAIR—SPINAL ACCESSORY.

The eleventh is a nerve of motion, arising from the whole extent of the cervical portion of the spinal cord, running along between the roots of the spinal nerves, and after entering the cranium by the foramen magnum, it receives additional filaments from the medulla oblongata. It passes through the dura mater, in company with the tenth pair, and leaves the cranium through the foramen lacerum basis cranii. In the cranial cavity, it receives twigs from the par vagum, and after emerging therefrom, is directed backwards under the superior extremity of the submaxillary gland, and passing down the neck, gains the border of the levator humeri muscle near the shoulder; then mounting slightly upwards, it crosses under the cervical trapezius, and is lost in the dorsal trapezius and rhomboideus brevis muscles.


In its course it gives off numerous twigs to the superior cervical ganglion, to the maxillary gland, and a large branch to the sterno-maxillaris, levator humeri, and trapezius muscles, and receives branches from the first, second, third, fourth, fifth, and sometimes sixth cervical nerves.

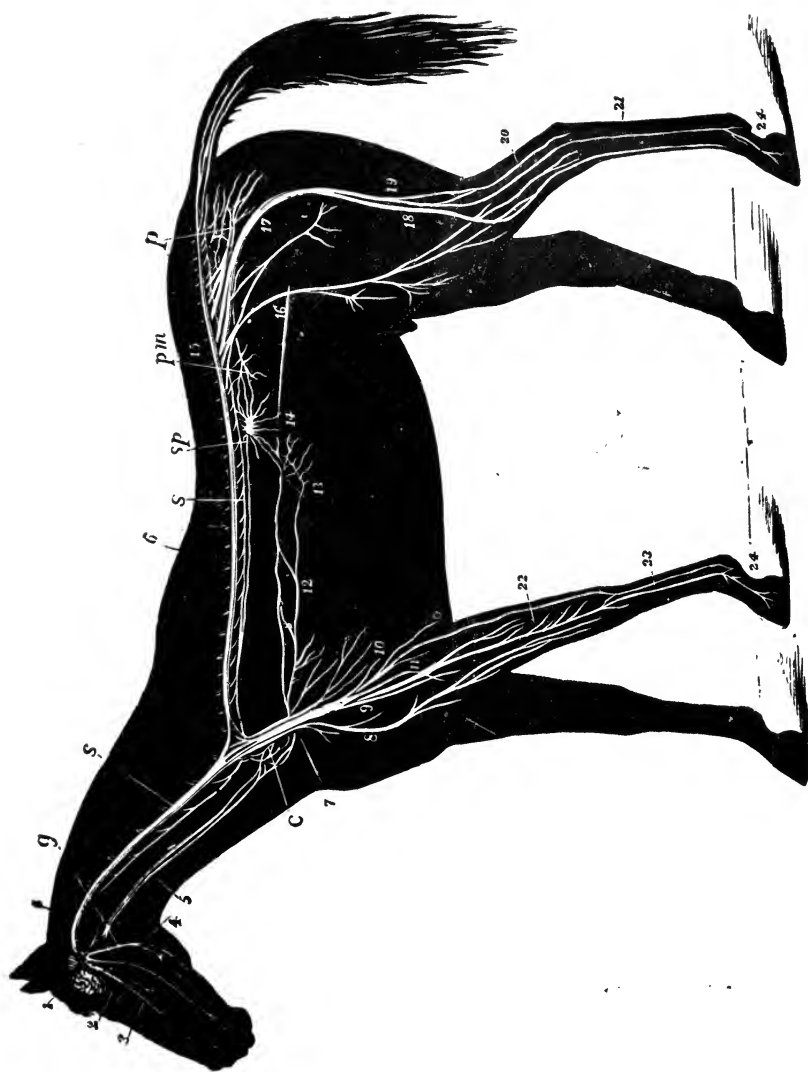
#### TWELFTH PAIR—HYPO-GLOSSAL.

This, a motor nerve, has its origin in numerous filaments derived from the medulla oblongata. It makes its exit from the cranium by the condyloid foramen of the occipital bone, descends by the external face of the guttural pouch, and is distributed to all the muscles of the tongue, after communicating with the first cervical nerve and superior cervical ganglion of the sympathetic.

#### SPINAL NERVES.

The nerves which emanate from the spinal cord, and make their exit through the intervertebral foramina are collectively





NERVOUS SYSTEM OF A HORSE—after Magnin.

## EXPLANATION OF PLATE VI.

### NERVOUS SYSTEM OF THE HORSE.

- |                                    |                                     |
|------------------------------------|-------------------------------------|
| 1. Brain.                          | 13. Solar plexus.                   |
| 2. Optic nerve.                    | 14. Semilunar ganglion.             |
| 3. Superior maxillary nerve (5th). | 15. Lumbo-sacral plexus.            |
| 4. Inferior maxillary nerve (5th). | 16. Anterior crural nerve.          |
| 5. Pneumo-gastric nerve.           | 17. Great sciatic nerve.            |
| 6. Medulla oblongata.              | 18. External popliteal nerve.       |
| 7. Right brachial plexus.          | 19. External saphenic nerve.        |
| 8. Musculo-cutaneous nerve.        | 20. Tibial nerve.                   |
| 9. Median nerve.                   | 21. Metatarsal nerve.               |
| 10. Radial nerve.                  | 22. Radial portion of median nerve. |
| 11. Cubital nerve.                 | 23. Metacarpal nerves.              |
| 12. Pneumogastric nerve.           | 24. Digital branches.               |

*s.s.* Sympathetic chain.

*c.* Inferior cervical plexus.

*g.* Gutteral ganglion.

*Sp.* Great splanchnic nerve.

*p.m.* Posterior mesenteric plexus.

*p.* Pelvic plexus.



known as the spinal nerves. They consist of forty-two or forty-three pairs, and are divided, according to the regions, into eight cervical, seventeen dorsal, six lumbar, five sacral, and six or seven coccygeal pairs. The whole of the spinal nerves originate by two orders of roots, *superior* or *sensory*, and *inferior* or *motor*; the former, which are larger and more numerous, arising from the superior lateral fissure, and the latter from the inferior lateral fissure of the cord. In the intervertebral foramina there is a *ganglion on each of the superior roots*, underneath which the inferior root passes. The union of the two roots constitutes the spinal nerve, which, almost immediately after it passes through the foramen, divides into two branches; a *superior*, distributed to the spinal muscles and the integument which covers them; and an *inferior*, longer and larger, distributed to the inferior and lateral parts of the trunk, and in some cases the extremities. The spinal nerve sends varicous communicating branches to the sympathetic system.

#### CERVICAL NERVES (8 pairs).

The first cervical nerve, the suboccipital of Willis, leaves the spinal canal through the internal foramen of the atlas; the second through a foramen in the anterior part of the axis, the succeeding five through the corresponding intervertebral foramina, and the eighth between the last cervical and first dorsal vertebræ.

**SUPERIOR BRANCHES.** — The superior division of the *first* nerve, after reaching the interstice between the anterior oblique and the posterior straight muscles of the head, divides into numerous branches, which are distributed to the muscles at the back of the poll and to the retrahentes muscles of the ear; one long branch, which anastomoses with the posterior auricular branch of the seventh cranial nerve, to form the *auricular plexus*, is sent to the concha, and the skin covering it.

The superior division of the *second* nerve, situated under the obliquus capitis posticus muscle, to which and the anterior oblique it gives branches, is distributed in a similar manner to the superior branches of the remaining cervical nerves. These, gradually diminishing in size as they proceed backward, pierce the intertransversalis muscle, and divide into *superficial branches*, distributed to the superficial muscles and skin, and the *deep branches*, larger than the others, which cross the transverse pro-

cesses, and form the *deep cervical plexus*, from which the deep muscles are supplied.

**INFERIOR BRANCHES.**—The inferior divisions of the cervical nerves gradually increase in size from the first to the last. They separate into two distinct groups, composed of the anterior six, which furnish branches to the muscles and skin of the breast, and of the lateral and anterior part of the neck, transmitting intercommunicating branches, which form a vast network known as the *superficial cervical plexus*, and which is traversed by the cervical branch of the facial and an important branch from the spinal accessory nerves. The last two, together with a branch from the sixth, join the two first dorsal nerves to form the *brachial plexus*.

The inferior branches of the *first cervical nerve* pass through the foramen in front of the atlas in company with the occipital artery and vein, cross the rectus capitis anticus major muscle, and the spinal accessory nerve, and, describing a curve towards the top of the trachea, enter the subscapulo-hyoideus muscle, where they terminate in numerous branches. In their course they furnish filaments to the three recti muscles, to the thyrohyoid, sterno-thyro-hyoideus, sterno-maxillaris, and the muscles connecting the hyoid bone to the larynx, and communicate with the superior cervical ganglion, the spinal accessory, and hypoglossal nerves.

The inferior branch of the *second cervical nerve* descends under the posterior oblique, and is distributed by numerous branches to the rectus capitis anticus major and minor, levator humeri, deprimens aurem, retrahentes aurem, and subscapulo-hyoideus muscles; to the outer side of the concha, and to the panniculus and skin, communicating with a branch of the spinal accessory and cervical branch of the facial nerves, and with the inferior cervical ganglion of the sympathetic.

The inferior branches of the *third, fourth, fifth, and sixth cervical nerves* pass through the intertransverse muscle, and divide into deep and superficial branches, the one being distributed to the deep muscles of the neck and anterior part of the shoulder, and the other to the skin of the neck and the panniculus. The deep branches of the sixth and seventh, and a filament from the fifth help to form the *phrenic* or *diaphragmatic nerve*.

The *seventh cervical nerve*, a very large nerve, passes between the two portions of the scalenus muscle, and helps to form the



brachial plexus. It receives an anastomosing branch furnished by the sixth nerve.

The *eighth cervical nerve*, larger than the preceding, also passes to the brachial plexus. It sends a branch to the inferior cervical ganglion.

#### DORSAL NERVES (17 pairs).

The dorsal nerves, with the exception of the first, are all distributed in a similar and very simple manner, as compared with the cervical nerves. The *superior branches*, passing up between the transverse processes, bifurcate, one branch being sent to the spinal muscles and the skin of the dorsal region, the other being distributed to the longissimus dorsi muscle. The *inferior branches* descend to the intercostal spaces, and pass along between the pleura and internal intercostal muscles. Each of these *intercostal nerves*, at its origin, gives one or two branches to the sympathetic, and, towards its middle, a perforating branch directed obliquely outwards to the skin, where it ramifies, and, in its course, gives off muscular filaments.

The *inferior branch of the FIRST DORSAL NERVE* goes almost entirely to the brachial plexus. It has no cutaneous division, and its intercostal branch is very slender.

The **SECOND DORSAL NERVE** sends a large branch to the brachial plexus. Its intercostal branch, more considerable than that of the first, extends down to the sternum, and gives off cutaneous twigs.

The **THIRD, FOURTH, FIFTH, SIXTH, SEVENTH, and EIGHTH DORSAL NERVES** pass to the extremity of the intercostal spaces, and are prolonged into the pectoralis magnus and rectus muscles; *the last nine*, after reaching the cartilages of the false ribs, are continued into the walls of the abdomen, and under the internal oblique, to the rectus, where they divide, one division going to the substance of the muscles, the other furnishing twigs to the skin of the abdomen. The **SEVENTEENTH DORSAL NERVE** furnishes a large branch to the fleshy portion of the internal oblique, and another which anastomoses with the first lumbar nerve.

#### LUMBAR NERVES (6 pairs).

The **SUPERIOR BRANCHES** of the lumbar nerves are distributed to the muscles of the loins, and to the integument of the loins and croup.

The INFERIOR BRANCHES send twigs to the sympathetic, and branches which anastomose with one another.

That of the *first lumbar nerve* receives a branch from the last dorsal, and turning backwards under the transverse process of the second lumbar vertebra, passes between the transversalis abdominis and internal oblique, to which it sends filaments, and terminates in the rectus muscle. Near its origin, it gives off a perforating branch which, passing through the abdominal muscles, terminates in numerous cutaneous filaments.

The inferior branch of the *second lumbar nerve* has similar anastomosing branches to the first, and two perforating nerves which, receiving a small branch from the third, descend under the skin of the internal and anterior face of the thigh, and are distributed to the skin of the flank and the crural region.

The inferior branch of the *third nerve*, besides its anastomosing branches, sends usually three branches downwards and outwards to the inguinal canal, where they ramify in the cremaster muscle; it also furnishes numerous twigs to the psoas magnus. One of the inguinal nerves generally unites with a large branch of the fourth nerve.

The inferior branch of the *fourth lumbar nerve*, besides the branches common to all, gives a large branch to the lumbo-sacral plexus, and a long branch which unites with an inguinal branch from the third. It is then directed downwards to the thigh, where it terminates in numerous cutaneous and aponeurotic branches.

The *fifth lumbar* gives a large branch to the lumbo-sacral plexus, and branches to the psoas parvus.

The *sixth lumbar* is the principal branch of the lumbo-sacral plexus.

#### SACRAL NERVES (5 pairs).

The sacral nerves, which diminish in size from the first to the last, have their origin close to each other, their roots surrounding the conus medullaris, in which the spinal cord terminates, and by which it extends into the canal of the sacrum. With the coccygeals they form the nerve tuft known as the *cauda equina*.

The *superior branches* of the sacral nerves leave the spinal canal through the superior sacral foramina, and are distributed to the muscles of the superior region of the sacrum, and terminate in the skin of the croup.

The *inferior branches*, the *first three* of which assist in the formation of the lumbo-sacral plexus, converge at the side of the pelvic cavity. The *fourth* constitutes the *internal pudic nerve*, which, at its origin, sends an anastomosing branch to the origin of the fifth. It is distributed to the penis, where it terminates, by numerous branches, in the glans. Before leaving the pelvic cavity, it sends filaments to the muscles and skin of the perineo-anal region. In the female, this nerve is distributed to the parts analogous to those of the male.

The *fifth* forms the anal or *hæmorrhoidal nerve*, distributed to the sphincter ani, and the skin covering it.

Small filaments which form the *pelvic* or *hypogastric* plexus are given off from near the origins of all the sacral nerves.

#### COCYGEAL NERVES (6 or 7 pairs).

The coccygeal nerves differ from the other spinal nerves in having no immediate communication with the sympathetic. They diminish in size from the first to the last. The *superior* branches unite to form one large nerve, which passes under the *curvator coccygis* muscle, and extends to the tip of the tail, giving off muscular and cutaneous filaments in its course; the *inferior* branches likewise coalesce and extend in a similar manner under the *depressor* muscle.

The inferior branch of the first coccygeal receives a branch from the last sacral, and sends a filament down towards the anus and perinæum.

#### NERVES FORMED BY THE INFERIOR BRANCHES OF THE SPINAL NERVES.

These nerves form three groups, as follows:—The Phrenic nerve, the Brachial plexus, the Lumbo-sacral plexus.

#### PHRENIC NERVE.

(FIG. 195. *g g g.*)

The phrenic or diaphragmatic, the motor nerve of the diaphragm, is formed by three principal branches; one from the brachial plexus, one from each of the sixth and seventh cervical nerves, with a filament, not constant, from the fifth. It enters

the thoracic cavity, and passing to the inner side of the brachial artery, receives a filament from the sympathetic; thence it travels between the two layers of the mediastinum, and reaching the aponeurotic centre of the diaphragm, divides into numerous branches, which are carried towards the periphery of the muscle.

#### BRACHIAL PLEXUS.

(FIG. 190.)

The brachial plexus comprehends that large bundle of nerves formed of the inferior branches of the seventh and eighth cervical, the first and part of the second dorsal nerves, all of which converge to the interstice between the two divisions of the scalenus muscle, where they unite, and pass outwards round the first rib. At and below the arm, the plexus divides into numerous branches, distributed to the muscles and teguments of the anterior extremity; the chief branches we describe as follows:—

The ANTERIOR SCAPULAR NERVE is a large branch which supplies the muscles on the dorsum of the scapula; it turns round the anterior border of the bone, a little above its neck, passing under the antea-spinatus, to which and to the postea-spinatus it gives twigs, terminating in the latter.

The THORACIC NERVE consists of six or seven branches of unequal size and length, usually distributed to the muscles between the shoulder and the trunk; three anterior ones are directed obliquely downwards, losing themselves in the muscles attached to the sternum; while of the three posterior branches, one, winding round the posterior border of the caput muscles, becomes superficial, and is distributed to the panniculus and skin; while the remainder are distributed to the latissimus dorsi and serratus magnus.

The SUBSCAPULAR NERVE includes two principal cords, the smaller of which goes to the subscapularis, and the larger, the *axillary* or *circumflex nerve*, turning round the scapulo-humeral articulation, terminates in a subcutaneous branch which descends the arm. It supplies the subscapularis, teres externus, and levator humeri, and furnishes articular and cutaneous filaments.

The RADIAL NERVE, a large branch of the brachial plexus, is principally furnished by the first dorsal. It arises behind the humeral artery, and is directed backwards and downwards under the subscapularis and teres major muscles, being accompanied for

a short distance by the artery. Near the deep humeral artery, it turns round the back of the humerus, between the *caput magnum* and *humeralis obliquus*, and passing down the outer surface of the bone, gains the anterior face of the elbow joint and radius, where it meets the anterior radial artery, and accompanies it almost as far as the carpus, supplying the extensor muscles of the forearm. In its course it gives off branches to the *caput*

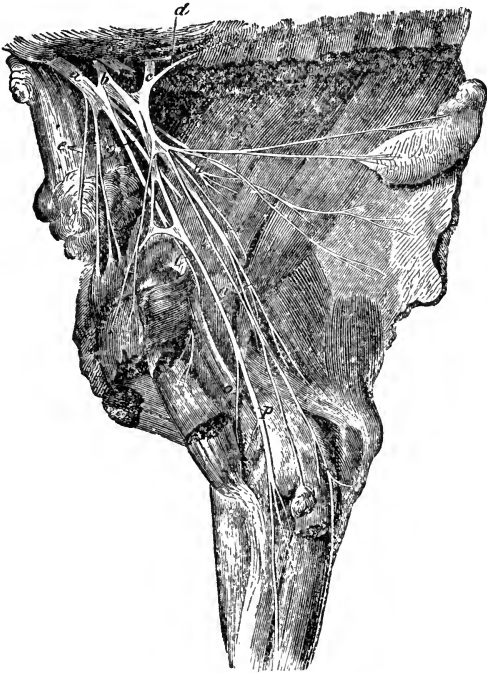


FIG. 190.

Internal aspect of right anterior extremity—showing the brachial plexus. *a*, Seventh cervical nerve; *b*, Eighth cervical nerve; *c*, First dorsal nerve; *d*, Branch from second dorsal nerve; *e*, Anterior thoracic; *f*, Posterior thoracic; *g*, Anterior scapular; *h*, Subscapular; *i*, Axillary; *k*, Cubital; *l*, Small musculo-cutaneous branch; *m*, Radial; *n*, *p*, Median; *o*, Musculo-cutaneous.

muscles and *scapulo-ulnaris*, to the elbow joint, and to the skin covering the arm.

The **ULNAR** or **CUBITAL NERVE** is formed of fibres from the dorsal nerves; it is less than the radial, and originates on the outer side of the humeral artery, which it accompanies beyond the origin of the deep humeral artery; crossing the latter, and

passing between the scapulo-ulnaris and caput parvum muscles, it gains the inner side of the elbow. Afterwards, descending to the bend of the carpus, it passes under the annular ligament and divides into two branches, one of which unites with a branch from the median, to constitute the external metacarpal nerve, and the other, traversing the space between the tendons of the flexor metacarpi externus and medius, is distributed by numerous branches to the skin covering the radius, carpus, and the outer side of the metacarpus. This nerve accompanies the artery and vein of the same name.

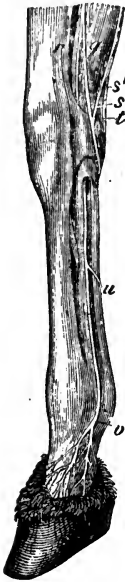

FIG. 191.

Carpal and metacarpal nerves—internal aspect. *q*, External branch of median; *r*, Internal branch of median, or internal metacarpal; *s*, Internal branch of cubital; *s'*, External branch of cubital; *t*, External branch of median, and internal branch of cubital uniting to form external metacarpal; *u*, Anastomotic branch uniting metacarpal nerves; *v*, Internal digital.

In its course, the ulna nerve gives off, a branch which proceeds downwards between the scapulo-ulnaris and pectoralis transversus, furnishing many filaments to the latter; becoming cutaneous, it is distributed to the skin below the elbow. It also furnishes a branch to the flexor metacarpi muscles.

The MEDIAN NERVE, composed of fibres from the two dorsal and the eighth cervical nerves, descends the humerus in company with the humeral artery to the inner side of the elbow, runs down the side of the radius till it reaches the carpus, and then, passing under the posterior annular ligament, divides into the *internal metacarpal*, and a branch to the external metacarpal nerve. In its course it gives off, under the brachial artery, a branch to the pectoral muscles; and near the middle of the humerus, a long branch, the *musculo-cutaneous* or *antibrachial nerve*, which passes obliquely under the coraco-humeralis and coraco-radialis muscles; here it divides, one branch going to the humeralis externus, while the other, passing between this muscle and the coraco-humeralis, gains the inner aspect of

the arm, where it becomes subcutaneous, and ramifies on the antibrachial fascia, sending its branches down to the carpus. The median nerve also supplies numerous filaments to the elbow joint, to the flexor muscles of the phalanges, and the internal flexor of the metacarpus.

The METACARPAL NERVES, external and internal, are formed, the first by the union of a branch from the median and one from the cubital; the second may be regarded as the continuation of the median. They run down the metacarpus by the sides of the flexor tendons, to which they give filaments, and terminate at the fetlock; the internal nerve lies posterior to the great metacarpal artery. Midway down the metacarpus, they anastomose by means of an oblique branch which crosses the flexor tendons posteriorly. At the fetlock, near the insertion of the suspensory ligament to the sesamoids, each metacarpal nerve divides into three digital branches; anterior, middle, and posterior.

The *anterior branch* descends in front of the digital vein, and distributes its branches on the anterior surface of the foot. The *middle branch* frequently anastomoses with the others, and always with the anterior branch. It supplies the fetlock pad and sensitive sole. The *posterior branch*, by far the largest, and the true continuation of the metacarpal nerve, is continued behind the digital artery to the basilar process of the os pedis, entering the lateral fissure, and being distributed to the substance of the bone and the laminæ. It gives off branches to the flexor tendons, and a *filament* which is carried forwards and distributed to the sensitive frog; minute filaments accompany the plantar unguis artery into the pedal bone.

## LUMBO-SACRAL PLEXUS.

(Fig. 192.)

This plexus, which supplies the posterior extremity, is formed by the inferior branches of the last two lumbar and the first three sacral nerves; it is divided into two portions, an anterior or lumbar, and a posterior sacral, each of which has a large trunk for its centre. The anterior division is constituted by the above-mentioned lumbar nerves, receiving, after a short course, a branch from the fourth one; the posterior division is formed by the first three sacral nerves, which unite to form a single bundle. These trunks are united by communicating branches.

The *anterior division* is buried under the psoas parvus, and is separated from the posterior division by the internal iliac artery. The *posterior division* is placed within and on the side of the pelvic cavity. The anterior division furnishes the *iliaco-muscular, crural, and obturator nerves*. The posterior division gives

off *ilio-muscular* and *ischio-muscular* or *lesser sciatic* branches, and terminates as the *great sciatic* nerve.

The ILIACO-MUSCULAR are numerous small branches, the chief of which accompany the ilio-muscular artery across the iliacus muscle.

The CRURAL or ANTERIOR FEMORAL NERVE is the largest branch of the anterior division. It descends between the psoas magnus and psoas parvus, and passing under the sartorius, enters between the rectus femoris and vastus internus, distributing branches to these muscles. Near the groin, it gives off the *internal saphenic nerve*, which accompanies the femoral artery for some little distance, then passes between the sartorius and gracilis, becoming subcutaneous, and passing down the limb, in company with the internal saphena vein, and, on the inner face of the leg, it is continued to the hock, and by delicate branches as far as the fetlock and pastern. Another long subcutaneous branch is given off, which breaks up and surrounds the saphenic artery and vein. These branches furnish filaments to the stifle, to the adductor and pectineus muscles, and to the skin of the anterior and inner part of the leg.

The OBTURATOR NERVE, situated at first under the peritoneum, accompanies the obturator artery through the obturator foramen, and gaining the muscles on the internal face of the thigh, terminates in the obturator externus, adductors, pectineus, and gracilis, also giving twigs to the obturator internus.

The ILIO-MUSCULAR or ANTERIOR GLUTEAL NERVES, four or five in number, leave the pelvis through the great sciatic notch. The principal branch loses itself in the gluteus maximus, another crossing the neck of the ilium, above the gluteus internus, is directed outwards, and distributed to the tensor fasciæ latæ. Another passes to the gluteus internus, in the substance of which it terminates.

The ISCHIO-MUSCULAR or POSTERIOR GLUTEAL NERVES are the superior and inferior. The first, the course of which lies through the sciatic notch, and between the sacro-sciatic ligament and the gluteus maximus muscle, to the posterior portion of which it gives a small branch in passing, and sends another to the gluteus externus, terminating by numerous branches in the triceps abductor muscle. The second is situated below the preceding, and supplies the biceps rotator tibialis muscle and skin of the posterior part of the haunch.



The GREAT SCIATIC NERVE, the largest nerve in the body, leaves the pelvis in company with the gluteal nerves, through the great sciatic notch, and is directed downwards along the posterior face of the femur. Near the stifle, it passes between the two portions of the gastrocnemius muscle, where it forms two branches; a short one, which enters the muscles attached to the posterior part of the tibia, and is distributed to the flexor pedis, popliteus, and flexor pedis accessorius muscles; and a principal

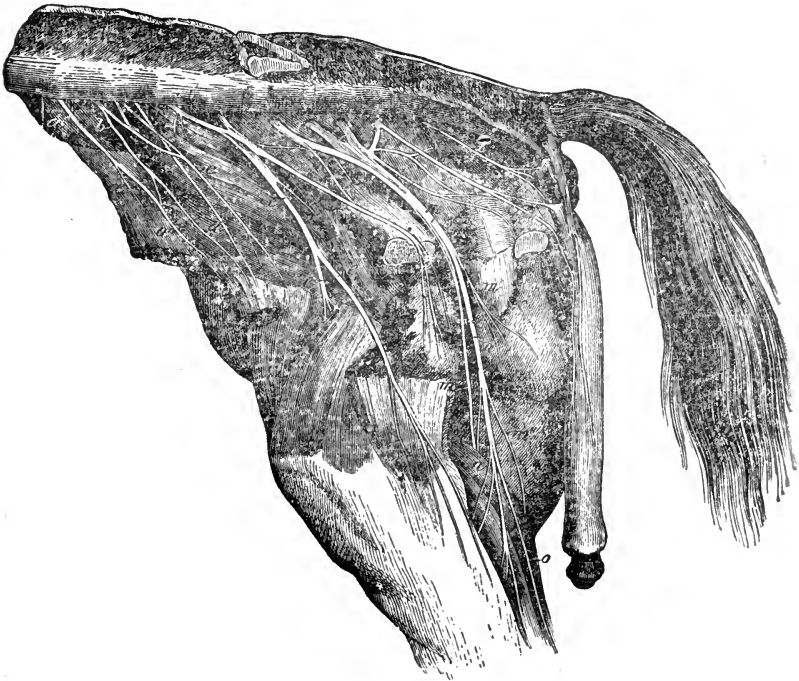


FIG. 192.

Lumbo-sacral plexus of the right side—the pelvis opened and viscera removed. *a*, First lumbar nerve: *a'*, Its branches; *b*, Second lumbar nerve: *c*, Inguinal branch: *d*, Femoral cutaneous: *e*, Crural: *e'*, Internal saphenic; *f*, Obturator: *g*, Anterior; and *h*, Posterior gluteal; *i*, Posterior cutaneous branch; *k*, Internal pudic; *k'*, Its perineal branch: *k''*, Dorsal branch to the penis; *l*, Hæmorrhoidal; *m*, Great sciatic: *m'*, Posterior crural: *m''*, External popliteal: *m'''*, External saphenic: *n*, Muscular branch; *o*, Tibial.

branch, the *tibial* or *popliteal* nerve, which descends at the posterior part of the tibia, below the flexor perforatus, and divides at the hock into *external* and *internal metatarsal* branches. In its course, the sciatic nerve furnishes filaments to all the muscles situated at the posterior part of the thigh, with

two important branches, the external popliteal and external saphenic nerves.

The **EXTERNAL POPLITEAL NERVE** leaves the great sciatic about the level of the gemelli muscles. It passes between the adductor magnus and gastrocnemius, and arrives at the superior extremity of the leg, behind the lateral ligament of the femoro-tibial articulation, when it terminates in two branches; one, the *anterior tibial nerve*, is short, and enters the muscles attached to the superior extremity of the anterior face of the tibia, in which it ramifies; the other the *musculo-cutaneous*

nerve turns downwards by the outer side of the anterior surface of the leg, and, passing the hock, metatarsal bone, and fetlock, terminates at the pastern. It gives off numerous muscular and cutaneous filaments.

The **EXTERNAL SAPHENIC NERVE** is given off shortly before the great sciatic enters the gastrocnemius muscle, descending under the fascia which covers the latter, and accompanying the external saphenic vein. It passes the tarsal joint, and ramifies on the external aspect of the metatarsus, some of its filaments reaching the digital region.

In addition to the above, a small nerve is given off from the great sciatic to supply the ischio-femoralis, gemelli, and obturator internus; also a large branch, the *posterior crural*, arises as the sciatic nerve bends downwards over the femur, and supplies the muscles of the lateral and posterior femoral regions. A fasciculus of nerves, given off as the sciatic enters the gastrocnemii, assists in supplying the posterior tibial group of muscles.

The **EXTERNAL and INTERNAL METATARSAL NERVES**, formed by the bifurcation of the great sciatic, pass down the side of the flexor tendons, and terminate as the digital nerves. Towards the superior extremity of the cannon bone, the external metatarsal nerve is carried outwards between the splint bone and the tendon, while the internal one is placed on the inner side of the tendon, and follows the posterior border of the inner splint. The *digital nerves* are distributed in a similar manner to those of the fore foot.

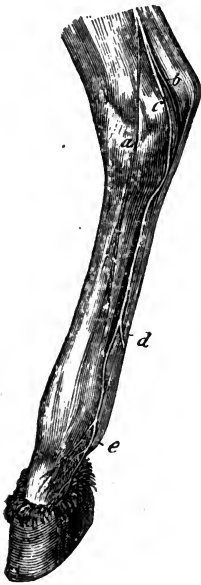


FIG. 193.  
Tarsal and metatarsal nerves  
—internal aspect. a, Internal  
cutaneous branch; b, External  
metatarsal; c, Internal meta-  
tarsal; d, Their connecting  
branch; e, Internal digital.

SYMPATHETIC SYSTEM.

The *sympathetic* or ganglionic system of nerves, the nerves of organic life, consists of two large cords or chains of nerves, which extend from the head to the posterior extremity of the sacrum, under the lateral parts of the bodies of the vertebræ, on each side of the column. These nerve cords are furnished with a number of ganglia, which both give and receive numerous communicating filaments from the cerebro-spinal nerves.

A sympathetic ganglion is a nerve centre, to which converge various so-called *afferent* branches, motor, sensory, and sympathetic, while the filaments which leave the ganglion to supply the various organs, are known as the *emergent* branches, which thus exercise a mixed and varied function.

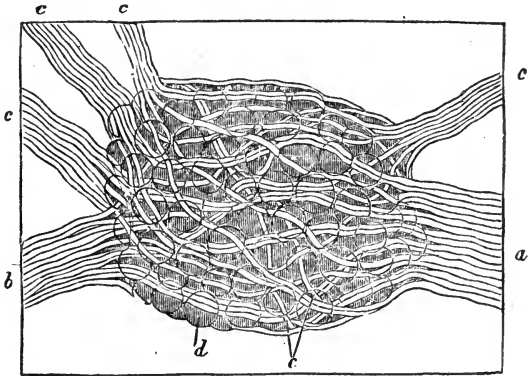


FIG. 194.

Dorsal ganglion of sympathetic nerve from a Mouse. *a, b*, Connecting cords to adjacent ganglia; *c c c*, Efferent and spinal nerve branches; *d*, Ganglionic cells; *e*, Nerve fibres crossing the ganglion.

The sympathetic nerves chiefly supply the blood-vessels (round which they twine in a complex manner), the glands, and the viscera.

For the convenience of description, the sympathetic system may be divided into five regions—viz., the cephalic, cervical, dorsal or thoracic, lumbar or abdominal, and sacral or pelvic.

CEPHALIC PORTION OF THE SYMPATHETIC SYSTEM

The cephalic portion consists chiefly of the *ophthalmic* or *lenticular*, *spheno-palatine* or *Meckel's*, and the *otic ganglia*.

The **LENTICULAR GANGLION** is situated between the optic

nerve and the inferior oblique muscle of the eye, in close contact with the motor oculi nerve and the ophthalmic artery. Its motor root is furnished by the third pair, and its sensory is derived from the palpebro-nasal. It also communicates with the superior cervical ganglion. Its emergent branches are the ciliary nerves, which accompany the ciliary arteries, and supply the tunics of the eyeball.

MECKEL'S GANGLION, much larger than the ophthalmic, is situated between the orbital and maxillary hiatuses, in close contact with the superior maxillary division of the fifth pair. Its motor root is formed by the Vidian nerve, by which it is also connected with the superior cervical ganglion, and its sensory roots are derived from the sphenopalatine nerve. Its emergent branches are numerous, and are sent to the muscles and vessels of the orbit, to the soft and hard palate, to the nose, and to the superior cervical and ophthalmic ganglia.

The OTIC GANGLION (Arnold's) is inconstant; it is connected with the inferior maxillary division of the fifth pair, under the guttural pouch and close to the Eustachian tube; its sensory root is derived from the buccal nerve, and its motor from the small superficial petrosal. It also communicates with the superior cervical ganglion. Its emergent branches are to the muscles of the middle ear, to the Eustachian tube, and to the pterygoid and tensor palati muscles.

#### CERVICAL PORTION OF THE SYMPATHETIC SYSTEM.

The cervical portion of the sympathetic chain is formed of two large ganglia, connected by an intermediate cord, and placed one at the superior, and the other at the inferior extremity of the neck.

The SUPERIOR CERVICAL or GUTTURAL GANGLION is a long, fusiform body in close connection with the internal carotid artery, and included with it in a fold of the membrane of the guttural pouch; it is situated in front of the wing of the atlas, and in close proximity to the ninth, tenth, eleventh, and twelfth cranial, and first cervical nerves, from all of which it receives branches. These filaments form a plexus round the ganglion, known as the *guttural plexus*. The emergent branches of the superior cervical ganglion are divided into three orders—viz., 1st, Those accompanying the internal carotid into the cranium; 2nd, A large

bundle, which gains the origin of the three terminal divisions of the primitive carotid; and 3rd, Small filaments supplying the guttural pouch and pharynx.

1. The branches which accompany the carotid, generally two in number, the anterior being largest, wind round the artery, and anastomose one with the other. Extending to the cavernous sinus, they form the *cavernous plexus*, by which they communicate with many of the cranial nerves, and send filaments to join analogous filaments from the opposite side. A branch from this plexus joins the superficial petrosal nerve, and contributes to the formation of the Vidian nerve, which joins the spheno-palatine ganglion.

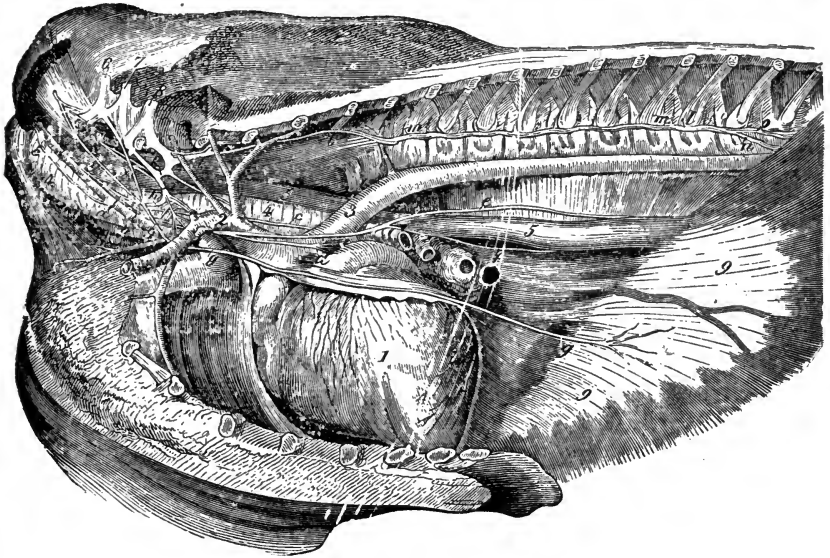


FIG. 195.

Thorax opened from the left side to show the nerves. 1, Heart; 2, Anterior aorta; 3, Posterior aorta; 4 4, Trachæa; 5 5, Œsophagus; 6, Seventh, 7, Eighth cervical nerves; 8, First dorsal nerve; 9 9, Diaphragm; *a*, Point of separation of sympathetic and pneumogastric; *b*, Pneumogastric; *c c*, Recurrent; *d*, Cardiac; *e*, Superior, *f*, Inferior branch of the pneumogastric; *g g g*, Phrenic; *g' g'*, Its roots, from the sixth and seventh cervicals; *h*, End of cervical portion of sympathetic cord; *i*, Inferior cervical ganglion; *k*, First dorsal ganglion; *l l l*, Thoracic part of sympathetic cord; *m m*, Union of sympathetic and dorsal nerves; *n*, Continuation of sympathetic; *o*, Splanchnic.

In company with fibres from the ophthalmic branch of the fifth, it communicates with the ophthalmic ganglion, and also sends a filament to the Gasserian ganglion, and mingles its fibres with those of the third, fourth, and sixth cranial nerves, or motor nerves of the eye.

2. The fasciculi joining the primitive carotid leave the inferior part of the ganglion in numerous branches, united by communicating filaments; at the division of the artery, they anastomose with branches from the glosso-pharyngeal and pneumogastric, forming the *carotid plexus*, the ramifications of which are almost exclusively distributed to the external carotid artery and salivary glands, one twig being sent to the otic ganglion.

3. The guttural or pharyngeal are very delicate branches, which leave the anterior border of the ganglion, and, gaining the superior walls of the pharynx, communicate with filaments from the glosso-pharyngeal and pneumogastric nerves to form the *pharyngeal plexus*.

The *intermediate cord of the cervical ganglia* leaves the inferior part of the ganglion, and passes down the neck in company with the par vagum to the entrance of the thorax, where it joins the inferior ganglion.

The INFERIOR CERVICAL GANGLION, larger than the superior, is placed on the inner side of the costal insertion of the scalenus muscle, and against the trachea, the right ganglion being always a little in advance of the left, which is separated from the trachea by the œsophagus. The form of this ganglion is variable and irregular, sometimes being lenticular and sometimes elongated, but always more or less radiated. Occasionally it is double; in this case, which occurs more generally in the right than in the left ganglion, the two portions are distinguished as anterior and posterior; the former, which is the smaller, being the *middle cervical ganglion* of the human anatomist, the two being joined by a short band of grey matter.

This ganglion receives two branches from the cervical nerves, one being formed by filaments which emanate from the second to the seventh pairs, inclusive, the other being a single branch from the eighth. In addition to these, several filaments are transmitted to it from the pneumogastric.

The emergent branches, detached from the inferior and posterior parts of the ganglion, chiefly supply the heart, some filaments being sent to the anterior mediastinum and the arteries of the brachial trunk.

The CARDIAC NERVES are five in number, three coming from the left and two from the right cervical ganglion; these, assisted by branches from the vagus, form the cardiac plexus, some branches from which accompany the aorta, and are distributed

to the tissue of the ventricles and auricles; some follow the divisions of the pulmonary artery, and assist in the formation of the bronchial plexus; and others, following the brachial arteries and trachea, form, on the inferior face of the latter, a very large fasciculus known as the *tracheal plexus*. This plexus is traversed by the two recurrent nerves, which give and receive numerous filaments as they pass.

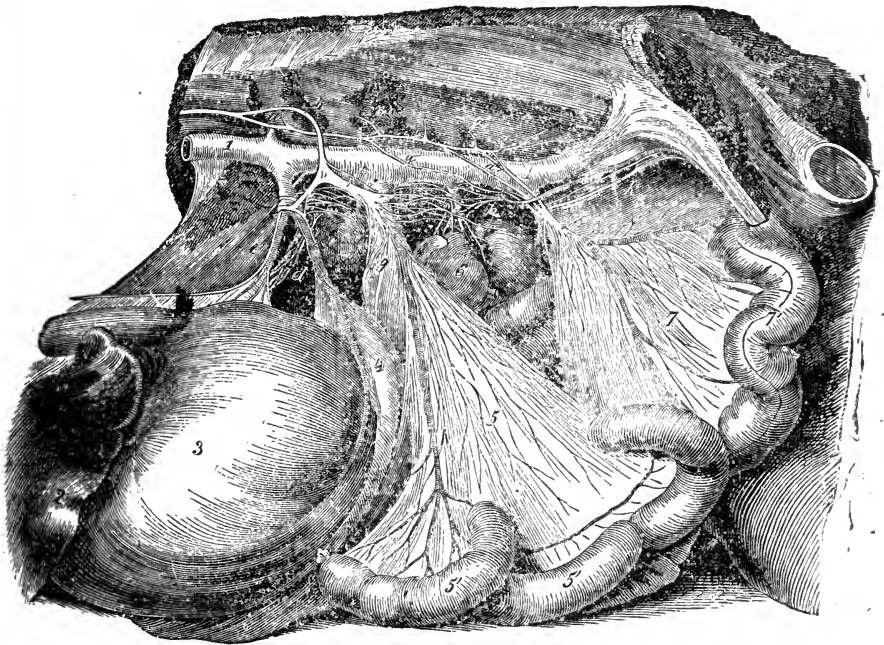


FIG. 196.

Abdominal portion of sympathetic nerves—viewed from the left side. 1 1, Posterior aorta; 2, Liver; 3, Stomach; 4, Spleen; 5, Anterior mesenteric nerves; 5' 5', Small intestine; 6, Left kidney; 7, Small mesenteric nerves; 7', Floating colon; a a, Sympathetic cord; a' a', Union of sympathetic and lumbar nerves; a'' a'', Branches joining sympathetic and posterior mesenteric plexus; b, Great splanchnic; c, Semilunar ganglion; d, Hepatic plexus; e, Gastric plexus; f, Splenic plexus; g, Anterior mesenteric plexus; h, Left renal plexus; i, Posterior mesenteric plexus; k, Left spermatic plexus.

THORACIC PORTION OF THE SYMPATHETIC SYSTEM.

The cord which represents the dorsal portion of the sympathetic chain extends from the inferior cervical ganglion to the diaphragm, crossing the intercostal arteries, and passing under the vertebro-costal articulations, against which it is fixed by the pleura. Passing through the arch at the superior border of the diaphragm,

by the side of the *psoas parvus* muscle, it is continued in the abdominal cavity by the lumbar portion. During its passage through the thorax, seventeen small fusiform ganglia, one at each intercostal space, present themselves. The afferent branches, from one to three generally, are furnished by the inferior branches of the dorsal nerves, which pass through the intervertebral foramina to each ganglion. The emergent branches are some small fibres which supply the pleura, and the large and small splanchnic nerves.

The GREAT SPLANCHNIC NERVE is detached from the sixth or seventh ganglion, and receives, in its backward course, additional fibres from all the other ganglia except the last two or three. It enters the abdominal cavity in company with the *psoe* muscles, when it presents a small ganglionic mass, and is then bent inwards, and terminates in a large ganglion, the semilunar or solar ganglion, between the cœliac axis and the anterior mesenteric trunk.

The SEMILUNAR GANGLIA, the largest of all the sympathetic ganglia, are elongated from before backwards, and flattened from above downwards. They communicate by means of a large and strong grey cord, which passes behind the mesenteric trunk, and by a number of filaments which proceed from side to side in front of this artery. On the inferior face of the aorta these filaments form the *solar plexus*, which receives branches from the superior cord of the *par vagum*, and is divided at its periphery into numerous secondary plexuses, from which many ramifications interlace and anastomose in a very complex manner round the divisions of the arteries, which they accompany into the neighbouring organs.

Of these secondary plexuses, the *gastric* distributes its branches to the stomach, on the walls of which they anastomose with the pneumogastric nerve; the *hepatic* supplies the liver, duodenum, pylorus, and pancreas; the *splenic*, the spleen and part of the stomach; the anterior *mesenteric*, the largest of all, the viscera supplied by the anterior mesenteric artery; and the *renal* and *suprarenal*, double and less distinct than the others, supply the kidneys and suprarenal capsules.

The numerous strong branches which leave the solar plexus, behind the anterior mesenteric artery, and run along the inferior face of the aorta, frequently anastomosing with each other, form the *lumbo-aortic* plexus, which unites with the posterior mesenteric plexus.



The LESSER SPLANCHNIC NERVE is formed by filaments from the last two or three dorsal ganglia, which instead of uniting with the great splanchnic, are sent direct to the solar plexus, and are confounded with the nerves of the kidneys and suprarenal plexus.

#### LUMBAR PORTION OF THE SYMPATHETIC SYSTEM.

The lumbar or abdominal portion of the sympathetic chain is a continuation of the dorsal, and like it, has fusiform ganglia at each lumbar nerve. It rests against the psoas parvus muscle, near the inferior common vertebral ligament, and is covered, on the left, by the aorta, and on the right, by the posterior vena cava. It is directly continuous with the sacral portion at the sacro-lumbar articulation.

The afferent branches to the lumbar ganglia are furnished by the inferior branches of the lumbar nerves; the emergent branches, analogous to those which form the splanchnic nerves, are not constant in number, but are generally fewer than the ganglia. Two or three of them unite with the lumbo-aortic plexus, and the others, gaining the origin of the posterior mesenteric artery, and anastomosing with the posterior branches of the lumbo-aortic form the *posterior mesenteric plexus*, which contains a ganglion more or less voluminous, in its centre. The ramifications of this plexus accompany the different branches of the posterior mesenteric artery, to be distributed to the floating colon and rectum; and two or three large branches join the anterior mesenteric plexus, after sending a few small divisions to the colic mesentery. Branches from it also surround and accompany the spermatic arteries, constituting the *spermatic plexus*; and lastly, two other long divisions enter the pelvis on each side, and being distributed over the external surface of the peritoneum, gain the side of the rectum, where they meet filaments which emanate directly from the sacral nerves. The anastomosis of these divisions results in a rich nervous network, the *pelvic* or *hypo-gastric plexus*, which supplies the organs contained within the pelvis.

#### SACRAL PORTION OF THE SYMPATHETIC SYSTEM.

The sacral or pelvic portion of the sympathetic is the continuation of the lumbar, and is situated under the sacrum, and to the inner side of the sacral nerves. It presents four ganglia, which

communicate with these nerves by numerous filaments, and give off several small twigs, which are lost in the cellular tissue on the inferior face of the sacrum.

The termination of the sympathetic nerve is not always the same, and while it often ends in a delicate filament, which is carried under the middle coccygeal artery, and unites with that of the opposite side, it sometimes terminates in a filament which communicates with the last pair of sacral nerves.

---

## COMPARATIVE NEUROLOGY.

### RUMINANTIA.

NOTWITHSTANDING the greater development of the coccyx in the ox, the *spinal cord* is not prolonged further backwards than in the horse; nor is it so in any of the animals which engage our attention, with the exception of the rabbit and bird.

The *optic nerves* and *pituitary gland* are larger, and the *testes* more separated from the nates than in the horse. The *cerebral convolutions* are fewer in number but larger, while the hemispheres themselves are larger posteriorly. With respect to the cranial nerves the differences are not, as a rule, of sufficient importance to claim notice here. We may, however, note that the *jugular ganglion* and *pharyngeal* branch of the tenth nerve both are very large. The *recurrent nerves* are separated from the pneumogastric trunk and carotid artery by the breadth of the oesophagus; the latter organ is more amply supplied with nerves than that of the horse. The superior oesophageal branch chiefly supplies the rumen, the inferior the other compartments. The *spinal accessory* divides into two branches, superior and inferior, the latter supplying the muscles of the infero-lateral cervical region.

The *radial nerve* sends two cutaneous branches downwards, one of which becomes lost at the carpus, while the other, becoming more anterior, descends the metacarpus, and supplies the dorsal nerves of the digits. The *median* and *cubital nerves* are not connected at the carpus, but continued downwards, the former as the internal, the latter as the external *metacarpal nerve*, each supplying its respective digit; about the distal end of the metacarpus, a branch from the internal passes across to join the external nerve, while lower down a second branch from the internal nerve forms the external collateral nerve of the inner digit, and still lower a third branch from the same source forms the internal collateral nerve common to both the digits.

In the nerves of the lumbo-sacral plexus there is little to note of importance. The *dorsal nerves of the digits* are given off by the musculo-cutaneous nerve. The *anterior tibial nerve* sends a branch down the anterior groove in the metatarsus; it divides in the distal notch to form the posterior deep digital nerves. There is no connecting branch between the external and internal metatarsal nerves.

## OMNIVORA.

In the hog the cerebral convolutions are still fewer than in the ruminant, but beyond this fact, the brain presents no important comparative features. The *superior maxillary* division of the fifth nerve pursues a remarkably short course in the orbital fossa. The *pneumogastric* nerve unites in the cervical region with the sympathetic; its oesophageal portions differ chiefly in the superior branch being very much larger than the inferior.

The nerves of the brachial plexus present few deviations from the type, with the exception of the *median* and *cubital* nerves. The former of these, below the carpus, supplies the interosseous palmar muscles, and afterwards divides into four branches, one for each of the four digits; those supplying the large digits reach the central interdigital space. The cubital nerve bifurcates near the trapezium, one branch running down the flexor tendons externally, to supply the outer digit, the other gains the anterior aspect of the metacarpus, and furnishes the dorsal nerves of the external digits.

In the lumbo-sacral plexus we note that the *musculo-cutaneous* nerve on reaching the metatarsus trifurcates, thus forming the dorsal nerves of the digits. The *anterior tibial* nerve passes down between the large metatarsal bones, and communicates with the *plantar* nerves, the external of which supplies the outer and partly the inner digits, the internal nerve being small.

## CARNIVORA.

In the brain of carnivora the *nates* are smaller than the *testes*, and the olivary bodies well marked. The *olfactory* lobes are exceedingly well developed, the sense of smell attaining, perhaps, its maximum of acuteness in these animals. The fourth ventricle is large and deep.

A branch of the seventh nerve accompanies the duct of Steno to the facial region. The pneumogastric and sympathetic trunks are inseparably united in the cervical region. The recurrent nerves arise by two branches which supply sparingly the trachea and oesophagus, these organs being also supplied by the *tracheo-oesophageal* branch of the superior laryngeal nerve. The oesophageal plexus of the pneumogastric is better marked than in the horse. The *bronchial* nerves are numerous and large.

In the dog, the nerves of the *brachial* plexus as far as the carpal region resemble in the main those of the horse. The *dorsal* nerves of the digits are supplied by a cutaneous branch of the radial nerve. The *median* nerve is attached superiorly to the cubital. Inferiorly it inclines to the inner aspect of the limb, and below the carpus it divides into six branches, one of which crosses over to unite with a branch of the cubital, and form the superficial palmar arch. The remaining palmar branches supply all the digits excepting the fourth and part of the third. The *cubital* nerve divides into a dorsal and a palmar branch; the first running down the forearm and carpus externally to supply the fourth digit; the latter divides into eight branches, which, deep-seated, supply all the digits excepting part of the index or first, a branch passing across to the pollex, and forming what may be regarded as a deep palmar arch.

In the posterior limb the *dorsal nerves* of the digits are formed by the three terminal branches of the musculo-cutaneous nerve. The external and internal plantar nerves supply digital branches, the former to all the digits except the internal branch of the fourth.

#### RODENTIA.

The brain of the rabbit is more lowly organised than that of any other domesticated mammal. The convolutions cannot be said really to exist; and the Sylvian fissure is merely indicated. No portion of the cerebellum is covered by the cerebrum when *in situ*. The olfactory lobes are very large, and the testes are smaller than the nates.

Although in this animal the tail is very short, the *spinal cord* extends beyond the sacrum. A singular nerve is formed by a branch from the superior laryngeal, and usually one from the pneumogastric, and proceeds down the neck with the sympathetic trunk, entering the thorax to reach the substance of the heart; it receives twigs from the first thoracic ganglion. The name "depressor nerve of the circulation" has been given to this nerve by its discoverers, MM. Cyon.

#### AVES.

In the nervous system of birds the chief point of interest is the brain, which is less highly organised than that of the mammalia. The *cerebrum* is pointed anteriorly, the hemispheres being separated by a shallow longitudinal fissure. There is a very slight indication of the fissure of Sylvius, but the convolutions, corpus callosum, and septum lucidum are absent. Two rounded bodies, the *optic lobes*, occupy the position of the mammalian greater lobes. The lateral lobes of the *cerebellum* are very rudimentary, and the *pons Varolii* is wanting.

The cranial nerves are, in number, twelve pairs, and they resemble those of the mammal in their origins, and, in a general sense, in their distribution also.

In birds the *spinal cord* extends into the coccygeal region. The nerves of the brachial plexus are divisible in the wing into two groups; a posterior which represents the *brachial*, *internal cutaneous*, and *radial*; and an anterior representing the *cubital*, *median*, and *musculo-cutaneous*.

The lumbo-sacral plexus likewise consists of two portions, the anterior supplying the *fascia lata*, *crural*, *internal saphenic*, and *obturator* nerves; while the posterior gives off the *gluteal*, *great sciatic*, and *popliteal* nerves.

---

## CHAPTER VII

### ÆSTHESIOLOGY.

THIS section of the subject deals with the organs of sensation. When sensation is peculiar to a certain organ, and received therein by the medium of a complex anatomical mechanism, it is known as sensation of the higher order, or *special sense*; the special senses are hearing, sight, smell, and taste, localised respectively in the ear, the eye, the nose, and the tongue.

On the other hand, when the organs of sensation merely transmit the impressions of pleasure and pain, such impressions are termed common sensation; and sensitiveness to such is shared by nearly all parts of the body, though in a much greater degree in some than in others.

Portions of the surface of the body which are more sensitive than the rest, and prominent, are known as the *organs of touch*, such as the end of the finger in man, the nose in the horse, &c. The skin being a very sensitive structure, we place it and its appendages under the heading of organs of common sensation.

We describe first the organs of special sense, then those of common sensation.

#### THE EAR.

The apparatus of hearing is composed of three parts—the external, middle, and internal ear; the two first being accessory, for the collection and transmission of sounds, and the latter the essential organ which receives the impressions thus conveyed.

#### EXTERNAL EAR.

The external ear consists of the *concha*, or projecting shell-like orifice, and the *meatus auditorius externus*, or passage which

extends from the base of the concha to the tympanic membrane bounding the cavity. It is partly osseous and partly cartilaginous, and is narrower in the middle than at either extremity. Its lining is a continuation of the skin of the concha, and it gradually becomes thinner as it descends; it is perforated by numerous small openings from the *ceruminous glands*, which secrete the wax of the ear. The cartilages of the external ear are the *conchal*, the *annular*, and the *scutiform*.

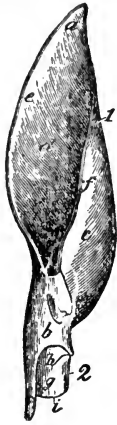

FIG. 197.

Right conchal and annular cartilages. 1, Conchal cartilage; *a*, Superior extremity; *b*, Inferior extremity; *c*, Outer surface; *d*, Inner surface; 2, Annular cartilage; *g*, Anterior surface; *h*, Superior; and *i*, Inferior border.

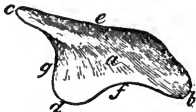

FIG. 198.

Scutiform cartilage. *a*, External surface; *b*, Inferior angle; *c*, Supero-anterior angle; *d*, Supero-posterior angle; *e*, Anterior border; *f*, Posterior border; *g*, Superior border.

The conchal cartilage has some characteristic feature, in shape or size, in most classes of animals; in the horse it is a conical tube, with the narrow end downwards, and having a perpendicular aperture directed forwards when the ear is "set;" it terminates superiorly in a point on the posterior border. Inferiorly it is attached to the annular or ring-shaped cartilage, which surrounds and is attached to the bony meatus. The scutiform cartilage is an irregularly triangular plate, partly covering the temporalis muscle, and attached by muscles

to the conchal cartilage and to the bones of the skull; it appears to act as a kind of lever in moving the concha, the mobility of which structure is so great in the solipede, that it is regarded, not inappropriately, as the chief *organ of expression* in that animal.

#### MIDDLE EAR.

The middle ear or *tympanum* is an irregular bony cavity within the petrosal bone. It is bounded externally by the membrane tympani or *drum* of the ear; internally by the bony walls of the internal ear; anteriorly by the Eustachian tube; and posteriorly by the mastoid cells.

The MEMBRANA TYMPANI is a semi-transparent, nearly circular membrane, with its middle drawn inwards. It is inserted to a

groove round the inner end of the external meatus, and is composed of *three layers*; an *external*, or epidermic, a prolongation of the skin lining the meatus; a *middle*, or fibrous, the fibres being in two sets, one radiating from the centre to the circumference, the other scattered and indistinct, except near the periphery, where they form a dense ring; and an *internal*, or mucous, derived from the mucous lining of the middle ear.

A chain of small bones, the auditory ossicles (ossicula auditūs) stretch across the tympanum. They are the malleus, incus, stapes, and lenticular bone, or os orbiculare.

The **MALLEUS**, or **HAMMER**, presents a rounded head (*capitulum*), a neck, a handle (*manubrium*), a long and a short process (*processus gracilis* and *brevis*). The head articulates with the incus; the handle is received between the inner and middle coats of the *membrana tympani*; the long process, in man, extends to the Glaserian fissure; and the short process, very obtuse, lies in contact with the drum.

The **INCUS**, or **ANVIL**, which in shape somewhat resembles the bicuspid tooth of man, has a body and two crura or processes. The body is concave on its surface, and articulates with the head of the malleus; the short crus is connected with the posterior wall of the *tympanum*; and the long crus bears the *os orbiculare*, a round bone, about the size of a grain of sand, at its extreme point.

The **STAPES**, or **STIRRUP**, possesses a base, two crura, and a head. The base is oval, and placed upon the *fenestra ovalis*; the crura converge from each extremity of the base to a constricted portion termed the neck, on which is placed the head, which articulates with the *os orbiculare*.

The inner wall of the *tympanum* is very uneven, and presents several eminences and openings. The oval opening, near its upper part, is the *fenestra ovalis*, which leads into the cavity of the vestibule. Above this fenestra, between it and the roof, is a ridge formed by the aqueduct of Fallopius, and beneath is the round opening of the *fenestra rotunda*. The

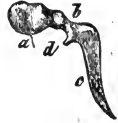

FIG. 199.

The malleus. a, Head; b, Neck; c, Handle; d, Processus gracilis.



FIG. 200.

Incus. a, Body; b, Articular surface for malleus; c, Short crus; d, Long crus; e, Os orbiculare.



FIG. 201.

Stapes. a, Head; b b, Crura; c, Base.

latter opening leads into the cochlea, and in the recent subject is closed by the lining membrane of the cavity; between the two fenestræ is the projection termed the *promontory*. At the posterior part of the tympanum, numerous openings lead into the *mastoid cells*, which are small, irregular, freely-communicating cavities in the auditory bulb of the temporal bone. Behind the fenestra ovalis is a conical eminence, the *pyramid*, in the apex of which is a groove for the tendon of the stapedius muscle. The anterior part of the tympanum narrows towards the opening of two canals, separated from each other by a lamina of bone, the *processus cochleariformis*; the upper and smaller of these canals contains the tensor tympani muscle,

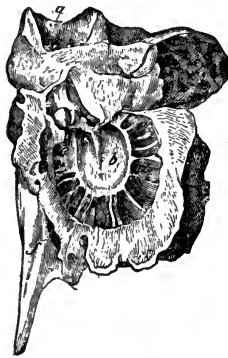


FIG. 202.

External wall of the tympanum—viewed from within. *a*, Meatus auditorius externus; *b*, Tympanic membrane; *c*, Malleus; *d d*, Mastoid cells; *e e*, Outer boundary, or ring of tympanum; *f*, Orifice for Eustachian tube.

and the other leads into and forms the bony portion of the *Eustachian tube*; a tube partly osseous and partly cartilaginous, which extends from the tympanum to the guttural pouch, and is the passage through which air is supplied to the middle ear. The Glaserian fissure is immediately in front of the ring to which the membrana tympani is inserted.

The bones of the middle ear are united and kept in their positions by muscles and ligaments. The muscles are the *stapedius*, which has its origin in the interior of the pyramid, and is inserted into the neck of the stapes; the *tensor tympani*, which arises from the cartilaginous portion of the Eustachian tube, and surface of the sphenoid, and passing through a small canal, becomes inserted into the handle of the malleus; the *laxator tympani*, which arises from the sphenoid, and passing through an opening in the Glaserian fissure, is inserted into the neck of the malleus. The ligaments are the *suspensory*, which attaches the head of the malleus to the upper wall of the tympanum; the *posterior*, which attaches the short crus of the incus to the margin of the mastoid cells; and the *annular*, which attaches the foot of the stapes to the membrane closing the fenestra ovalis.

The tympanum is lined by a vascular mucous membrane,



which is continuous, through the Eustachian tube, with that of the guttural pouch and pharynx, and is reflected into the mastoid cells. The whole of this membrane is lined with epithelium, that in the tube being ciliated.

## INTERNAL EAR.

The internal ear, from its complexity termed the *labyrinth*, is the ultimate part of the organ of hearing. It consists of a cavity whose boundaries include an osseous outer, and a membranous inner portion, respectively termed the *bony* and the *membranous labyrinths*. The bony labyrinth is an irregular cavity, divided into three separate parts; the vestibule, semicircular canals, and cochlea.

The VESTIBULE is an irregular, oval-shaped cavity, situated between the cochlea and the semicircular canals, having the fenestra ovalis penetrating its outer wall, and the five round openings of the semicircular canals at its back. At the upper part of its inner wall are two depressions, the *fovea elliptica* and *fovea hemispherica*, separated by a ridge, the *eminentia pyramidalis*, all of which are pierced by numerous small openings, *macula cribrosa*, for the passage of nerve filaments. Behind the fovea hemispherica is the opening of the *aqueduct of the*

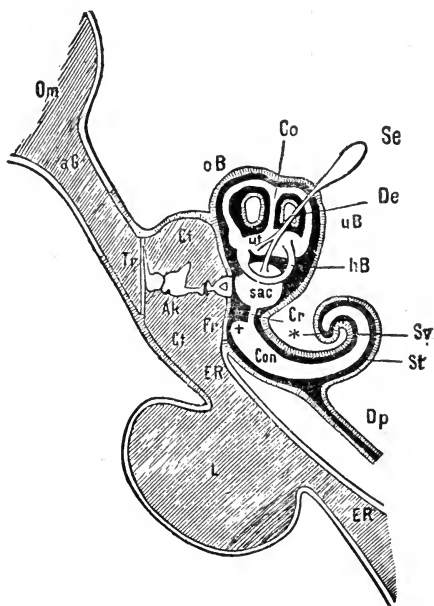


FIG. 203.

Diagram of the ear. In the internal portion, the black part shows the cavities of the bony, and the white part those of the membranous labyrinth. *Om*, Cavity of the concha: *aG*, External auditory meatus; *Tr*, Tympanic membrane; *T*, Tympanum; *Ak*, Auditory ossicles; *Fr*, Fenestra rotunda; *ER*, Eustachian tube; *L*, Guttural pouch; *Sac*, Sacculus; *ut*, Utricle; *oB*, *uB*, Bony; *Co*, *hB*, Membranous semicircular canals; *De*, Aquæductus vestibuli; *Se*, Saccus endolymphaticus; *St*, Scala tympani; *Sv*, Scala vestibuli; *Con*, Scala intermedia; +, Its vestibular creal sac; *Cr*, Ductus reuniens; \*, Its apex; *Dp*, Aquæductus cochleæ, vel Cotunnii.

*vestibule*, which extends to the posterior surface of the petrosal bone, and gives passage to a diverticulum of the membranous labyrinth. At the lower and anterior part of the vestibule is the large opening, *apertura scalcæ vestibuli*, or vestibular canal of the cochlea.

The SEMICIRCULAR CANALS are three half-circular passages communicating with the vestibule, into which they open by both extremities, and having, near one extremity of each, a dilatation termed the *ampulla*. These canals are distinguished as *superior* or *perpendicular*, *posterior* or *oblique*, and *inferior* or *horizontal*. The anterior or dilated end of the superior canal enters the vestibule by a distinct orifice, while its posterior or non-dilated end joins the anterior non-dilated end of the oblique; thus the two enter the vestibule by one common opening, the posterior end of the oblique canal being dilated, and entering by a distinct opening. The inferior canal has two openings, of which the anterior is dilated.

The COCHLEA, or SNAIL SHELL, is the anterior division of the labyrinth, and the most complex of the three. It consists of a gradually tapering spiral canal, which takes two and a-half turns round a central axis. This axis, termed the *modiolus*, is widest at its base, where it is pierced by numerous small openings, through which pass the filaments of the cochlear branch of the auditory nerve. The spiral canal is divided into two compartments (*scalcæ*) by a partition, partly bony and partly membranous, the *lamina spiralis*, which is wound spirally around the modiolus in the direction of the canal, and terminates, at the apex of the cochlea, by a hook-shaped process, the *hamulus*. The two compartments are thus completely separated, except at the apex, where they communicate by means of an opening, the *helicotrema*, under the hamulus; inferiorly, one scala terminates in the vestibule, it is hence called the *scala vestibuli*; the other leads to the tympanum at the fenestra rotunda, and is called the *scala tympani*.

The whole of the bony labyrinth is lined by a thin fibrous membrane, which closes the openings of both the fenestra rotunda and fenestra ovalis, and, adhering to the bone, acts the part of a periosteum. The inner surface of this membrane is smooth, and secretes a thin limpid fluid, the *perilymph* or *liquor Cotunnii*, which entirely fills the cochlea, and in the canals and vestibule, separates the bony from the membranous labyrinth.

The **MEMBRANOUS LABYRINTH**, though smaller in size, is nearly the counterpart in form of the vestibule and semicircular canals, and consists of two sacks within the vestibule, the larger of which, the *utricle* or *sacculus communis*, is elongated and lodged in the fovea elliptica; the smaller, the *sacculus* or *sacculus proprius*, is round, and lodged in the fovea hemispherica. The semicircular canals, which are about one-third the size of the bony canals, open by five orifices into the sacculus communis. The sacculus and utricle are united by an angular duct, which also leads to the aqueduct of the vestibule, a canal terminating in a blind dilatation, the *sacculus endolymphaticus*. The bony lamina spiralis being incomplete, the division is completed by two membranes, the membrane of Reissner and the basilar membrane, between which is the *scala intermedia*

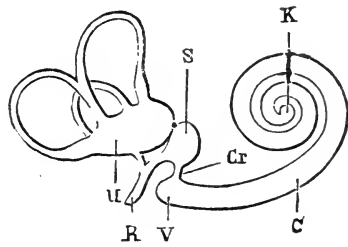


FIG. 204.

Membranous labyrinth. C, Ductus cochlearis; K, Its cochlear blind end, and V, Its vestibular blind end; Cr, Ductus reuniens; S, Sacculus; U, Utricle; R, Aquæductus vestibuli.

or *ductus cochlearis*, a tube which thus follows the turns of the cochlea, originating at its apex in a blind extremity, and terminating in a tube, the *ductus reuniens*, which unites it to the sacculus. This labyrinth is filled by a limpid fluid, termed the *endolymph* or *liquor Scarpæ*, and is constructed of four coats; an external serous, a vascular, a nervous, and an inner serous, from which the *endolymph* is secreted.

Within the sacculi are small, rounded, calcareous bodies, the *oto-coniæ*, which consists of particles of carbonate and phosphate of lime, held together by animal matter; these *oto-coniæ* are suspended from the membrane, and float freely in the endolymph.

The **MEATUS AUDITORIUS INTERNUS** is a bony canal, which leads from the cranial cavity to the vestibule, and terminates in the cribriform plate of the fovea hemispherica and eminentia pyramidalis.

The **GUTTURAL POUCHES**.—The mucous membrane, projecting through a slit in the inferior extremity of the Eustachian tube, becomes dilated into a large sac, the guttural pouch, which is peculiar to the *solipedæ* and the *Hyrax*. These pouches, which meet in the middle line, are irregular in form, are related above

with the base of the sphenoid and occipital bones, descending to the sides of the pharynx and larynx, where they terminate in a *cul-de-sac*; they likewise extend from the inferior extremity of the parotid gland to the anterior face of the atlas. For the auricular muscles, see p. 174.

### THE EYE.

The apparatus of vision comprises the essential organ, the globe of the eye or eyeball, and its accessory parts or appendages.

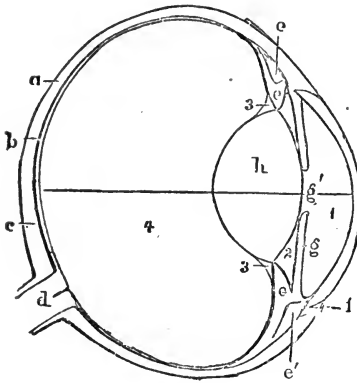


FIG. 205.

Diagrammatic horizontal section of horse's eye. 1, Anterior chamber containing aqueous humour; 2, Posterior chamber; 3 3, Canal of Petit; 4, Vitreous humour; a, Sclerotic coat; b, Choroid coat; c, Retina; d, Optic nerve; e e, Ciliary zone; e' e', Ciliary muscle; f, Junction of cornea with sclerotic; g, Iris; g', Pupil; h, Crystalline lens.

The GLOBE OF THE EYE is spherical in form, having the segment of a smaller sphere engrafted upon its anterior surface, and increasing its antero-posterior diameter. It consists of a membranous sac, containing certain transparent *humours*, of different densities, which serve as refracting media; it is attached to the orbit by the muscles which move it, and reposes on a cushion of fat, which not only maintains it in its proper position, but also assists in steadying its movements.

### TUNICS OF THE EYEBALL.

These are three in number—1. The *sclerotic* and *cornea*; 2. The *choroid* and *iris*; 3. The *retina*.

The sclerotic coat and cornea form the external tunic, and it is to them that the eyeball owes its peculiar shape. About four-fifths of the globe are invested by the sclerotic, the remaining fifth by the cornea.

The **SCLEROTIC COAT** is a dense white fibrous membrane, which extends from the insertion of the optic nerve, with the sheath of which it is continuous, to the cornea. Its external surface is in

connection with the cellular and adipose tissue, and with the muscles of the eyeball, the tendons of the four recti expanding over it and forming a thin tendinous layer, the *tunica albuginea*, which is partly covered by the conjunctiva, and forms the "white of the eye." Its internal surface is in contact with the choroid coat, from which it receives a stain, and to which it is united by very delicate cellular tissue, and by minute nerve filaments and vascular ramifications. Its anterior opening is elliptical, and presents a bevelled edge, which receives the cornea in a manner similar to that in which a watch-glass is received by the groove in its case. Posteriorly it is pierced for the passage of the optic and ciliary nerves, and ciliary arteries, the optic nerve filaments passing through numerous minute openings in the portion called the *lamina cribrosa*, the larger opening in the centre, the *porus opticus*, being for the passage of the *arteria centralis retinae*.

The CORNEA is transparent, elliptical in shape, and fitted into the bevelled edge of the sclerotic, to which it is firmly adherent. Its anterior surface is convex, and covered by a continuation of the conjunctiva, while its inner surface is concave, and covered by the lining membrane of the anterior chamber of the eyeball.

The cornea is composed of two layers; the *cornea propria* and the *cornea elastica*. The former consists of several thin lamellæ, held together by extremely fine areolar tissue; the latter is a fine, elastic, and exquisitely transparent membrane, closely applied to the inner surface of the propria. It retains its transparency long after the

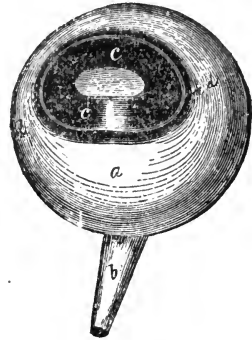


FIG. 206.

Globe of the eye—Antero-lateral view. *a*, Sclerotic; *b*, Optic nerve; *c*, *c*, Cornea; *d*, *d*, Elliptic opening in the cornea.

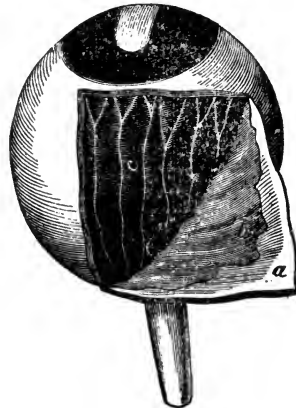


FIG. 207.

Globe of the eye—part of the sclerotic reflected away. *a*, Sclerotic; *b*, Membrana fusca; *c*, Choroid, with ciliary nerves.

other has become opaque, and from its great elasticity, its use is supposed to be that of preserving the correct curvature of the flaccid cornea propria.

The proper cornea is continuous with the sclerotic coat, and the elastic one with the ciliary muscle.

The SECOND TUNIC of the eyeball is formed by the choroid coat and iris.

The CHOROID COAT is a thin vascular membrane, of a brownish or black colour. Externally it is connected to the sclerotic by means of a fine areolar tissue, the *membrana fusca*, minute blood-vessels, and nerves; internally it is in simple contact with the retina; posteriorly it is pierced for the passage of the optic nerve; and anteriorly, at the junction of the sclerotic and cornea, it is connected with a white circular ring, the *ciliary muscle*, which is continuous with the circumference of the iris.

The choroid membrane is composed of three layers; external, middle, and internal. The *external layer* consists principally of veins, *venæ vorticosæ*, arranged in peculiar curves, all of which converge to four or five trunks, which pierce the middle of the sclerotic; the larger branches of the short ciliary arteries mingle with the veins, and the numerous pigment cells, to which the outer colour of the choroid is due, are interspersed among the vessels. This layer is connected with the ciliary muscle. The *middle layer* is formed by the ciliary arteries, which ramify into a fine capillary plexus, formerly known as the *tunica Ruyschiana*, which is reflected inwards, and is continuous with the ciliary processes. The *internal* or *pigmentary layer* is composed of laminae of hexagonal cells, containing black pigment granules, and arranged in a tessellated form. On




FIG. 208.

Pigment cells. *a*, The pigment granules concealing the nucleus. *b*, The nucleus visible.

the posterior wall the black pigment is absent, causing a peculiar bluish lustre, which, owing to its brilliancy, has received the name of the *tapetum lucidum*.

The *ciliary muscle* is a white ring of fibres, which forms the bond of union between the external and middle tunics of the eye, and serves to connect the cornea and sclerotic with the external layer of the choroid and with the iris. A minute vascular canal, the *ciliary canal*, exists between this ligament and the sclerotic coat.

The CILIARY PROCESSES, from sixty to eighty in number, and arranged in a circle, are formed by the plating or folding inwards of the middle and inner layers of the choroid; their circumference is attached to the ciliary muscle, and their central border is received between corresponding foldings of the suspensory ligament of the crystalline lens, or zonula of Zinn. The anterior face of these processes is turned towards the back of the iris, and the posterior face closely connected with the zonula of Zinn, through which connection a communication is established between the inner and choroid tunics of the eyeball. Externally, they are covered with a thick layer of pigmentary cells.

The IRIS is a thin diaphragm or curtain, suspended immediately in front of the crystalline lens, its periphery being connected with the choroid coat and ciliary muscle, and its centre pierced by an elliptical opening, the *pupil*. It is variously coloured, but in the horse is brown, with more or less of a yellow tinge; sometimes, however, it is almost white or grey, when the animal is said to be "wall-eyed." Its anterior surface is slightly convex, and its posterior surface covered with a deep purple pigment, called the *uvea*, from its resemblance in colour to a ripe grape.

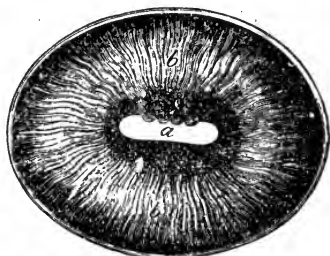


FIG. 209.

Iris and anterior part of choroid coat—  
internal view. *a*, Pupil; *b*, Ciliary pro-  
cesses.

Two sets of fibres enter into the formation of the iris, one of which, converging from the circumference towards the centre, has the power of dilating the pupil; the other, surrounding the margin of the pupil on its posterior surface, and blending with the radiating fibres, has the power of contracting it.

In the fœtus, the pupil is closed by a delicate transparent vascular membrane, the *membrana pupillaris*, which begins to be absorbed a short time before birth, the absorption commencing at the circumference. At the period of birth it is almost entirely removed.

The small bodies situated on the upper pupillary margin of the iris, three or four in number, are the *corpora nigra*, their use appearing to be that of concentrating the rays of light, and preventing their too direct passage through the pupil.

THIRD TUNIC.—The last tunic of the eye is the RETINA, which

is prolonged forwards to the ciliary processes. The retina is the terminal expansion of the optic nerve, over the internal face of the choroid coat, from which it is easily separated. It is commonly described as consisting of nine layers, arranged as follows from within outwards:—1. Internal limiting layer; 2. Optic nerve fibres; 3. Ganglionic cells; 4. Internal molecular layer; 5. Internal granular layer; 6. External molecular layer; 7. External granular layer; 8. External limiting membrane; 9. Basillary layer, or rods and cones. The *vascular* portion consists of the ramifications of the arteria centralis retinae and its satellite vein, their branches being continued into the zonula of Zinn.

The **CILIARY ZONE**, or *Zonula of Zinn*, is a thin vascular layer, which connects the anterior margin of the retina with the anterior surface of the lens, and presents a number of folds which are received between the corresponding folds of the ciliary processes. The under surface of this zone is in contact with the hyaloid membrane, and is separated from the circumference of the lens by the small circular canal termed the *canal of Petit*.



FIG. 210.

Globe of the eye seen from before—the cornea and aqueous humour removed. 1, Sclerotic; 2, Anterior part of choroid; a a, Ciliary muscle; b b, Iris; c, Pupil; d d, Corpora nigra.

#### HUMOURS OF THE EYE.

These, the refracting media, are three in number; the aqueous and vitreous humours, and the crystalline lens.

The *aqueous humour* consists chiefly of water, possessing an alkaline reaction, and completely fills the anterior and posterior chambers of the eye. The *anterior chamber* is the space intervening between the internal face of the cornea and the iris, pupil, and ciliary muscle. The *posterior chamber*, ignored by some authorities, is the very narrow space bounded in front by the iris, and behind by the capsule of the lens and zonula ciliaris. Both chambers are lined by a thin membrane, which secretes the aqueous humour.

The *vitreous humour* occupies about four-fifths of the whole interior of the globe. It is a highly albuminous and perfectly



transparent substance, of the consistence of jelly, enclosed in a delicate membrane, the *hyaloid*, from the inner surface of which numerous lamellæ are sent inwards, to form the compartments in which the fluid portion is contained.

The *crystalline humour*, or *lens*, is situated immediately behind the pupil, in front of the vitreous humour, and is surrounded by the ciliary processes, which slightly overlap its margin. It is biconvex, the convexity of the posterior face being the greater, and is enveloped by a transparent elastic membrane, the *capsule of the lens*, which is connected with its surface by a layer of transparent cells. After death, these cells absorb fluid from the eye, and break down into the *liquor Morgagni*. The lens is constructed of concentric layers or laminæ, of which the external are soft, and the internal firmer. It is supported in its place by the ciliary zone.

## MUSCLES OF THE EYE.

The intrinsic or motor muscles of the globe of the eye are seven, five of which are *straight* muscles—viz., the posterior or retractor, the superior or levator, the inferior or depressor, the external or abductor, and the internal or adductor; the remaining two are the *oblique* muscles, distinguished as superior, and inferior.\*

The RECTUS OCULI POSTERIOR, or RETRACTOR OCULI, completely envelopes and forms a sheath round the extra-cranial portion of the optic nerve. It originates from the edge of the optic foramen, and is inserted to the posterior part of the external face of the sclerotic, its action being to retract the eye within the orbit.

The remaining four RECTI muscles have their origin round the margin of the optic foramen, within the orbit, and become inserted by a broad expansion, which forms the tunica albuginea, on the anterior portion of the sclerotic coat. These four muscles form a fleshy sheath round the eyeball, similar to that which the retractor forms round the optic nerve. They are all flat and ovoid in form, the narrowest part being at their origin. Acting together, they retract the eyeball; singly, the superior rectus turns the eye upwards; the inferior turns it downwards; the internal turns it inwards; and the external turns it outwards.

\* We may here call attention to the very small muscle, described by Strangeways as a supernumerary oblique muscle—*vide* Appendix II.

The SUPERIOR OBLIQUE muscle is situated at the side of the internal and superior recti. It arises from near the optic foramen, and is directed forwards against the internal wall of the cavity, passing through a cartilaginous loop at the base of the orbital process of the frontal bone, near the inner canthus, whence it is directed backwards, and under the terminal extremity of the superior rectus, to become inserted to the sclerotic, between the superior and external recti. The action of this muscle is to elevate and rotate the eyeball.

The INFERIOR or LESSER OBLIQUE arises from the lachrymal fossa, is carried obliquely outwards, and is inserted to the sclerotic between the external and inferior recti muscles. Its action being to depress and turn the eye inwards, is antagonistic to that of the superior oblique muscle.

Professor Turner has described a non-striated mass of muscular fibres connected with the periosteum of the orbit. (See APPENDIX III.)

#### APPENDAGES OF THE EYE.

The accessory parts or appendages of the eye, are the *eyebrows*, *eyelids*, *membrana nictitans*, *conjunctiva*, *caruncula lachrymalis*, *lachrymal apparatus*, and *ocular sheath*.

The EYEBROWS, very rudimentary in the horse, are the eminences formed by the orbital processes of the frontal bone. They are furnished with a few long hairs, and serve to interrupt the too vivid rays of light, and prevent foreign bodies from descending into the eyes.

The EYELIDS are the two moveable curtains, superior and inferior, which protect the eye. Both are capable of expansion and contraction, though the superior is the larger and more movable of the two. When drawn apart, they form an elliptical opening, the angles of which are termed the *canthi*. The outer canthus, or temporal angle, is acute; the inner canthus, or nasal angle, is more obtuse or rounded, and it contains the *caruncula lachrymalis*. The external surface of the eyelids is covered with fine short hairs; the internal surface is smooth, lined by the *conjunctiva*, a continuation of the skin modified, and is in contact with the globe of the eye. Their free borders are thick, and on their margins are rows of long hairs, the *eyelashes*, or *cilia*, which serve to prevent the intrusion of foreign bodies. The ciliary borders of the lids also present a series of minute openings, which are the *ducts of the Meibomian glands*.

Entering into the structure of the eyelids, there are, therefore, skin, muscles, fibrous tissue, tarsal cartilage, Meibomian glands, and conjunctiva. The skin covering the eyelids is very fine, and adheres intimately to the levator palpebræ and orbicularis palpebrarum muscles. The fibrous tissue, thickest in the inferior eyelid, is firmly attached by its adherent border to the periosteum of the orbit, and the bone under the eyebrow, and by its free border to the tarsal cartilage, hence it is sometimes termed the tarsal ligament. The *tarsal cartilages* are the two cartilaginous plates which form the solid framework of the free border of the eyelids. They are elongated, narrowest at their extremities, and thin on their attached borders, which are continuous with the fibrous membrane. These cartilages afford a firm and very pliant support to the eyelids, and present on the side next the globe of the eye a series of vertical furrows, which lodge the ciliary follicles. The tarsal cartilage of the superior lid is longer and thicker than that of the inferior.

The CILIARY FOLLICLES, or MEIBOMIAN GLANDS, are situated between the tarsal cartilages and the conjunctiva. Each gland consists of a single tube, into which a cluster of follicles opens, and the whole row of glands along the edge of the cartilage bears a strong resemblance to a string of beads. These glands secrete a sebaceous fluid, which prevents the eyelids adhering together during sleep.

The CONJUNCTIVA, the mucous membrane of the eye, is very thin and very vascular, its vascularity being greatest on the inner surface of the lids, and least on the cornea, where in health no vessels are traceable. It lines the entire inner surface of the eyelids, being continuous with the skin on their edges, covers the anterior part of the membrana nictitans, and passes down the nasal duct. It is reflected over the whole of the anterior portion of the globe; adhering very loosely to the sclerotic and aponeurotic expansion of the recti muscles, and very firmly to the cornea, where it is extremely delicate and transparent.

The MEMBRANA NICTITANS, or accessory eyelid, vulgarly the "haw of the eye," is situated near the nasal angle, between the globe and the side of the orbit. It is composed of elastic fibrocartilage, and is irregular in form, being thick and somewhat prismatic at its base, and thin anteriorly, where it is covered by a fold of conjunctiva. Posteriorly, it is continuous with the pad of fat which is insinuated between all the muscles of the eye.

Its external surface is convex, and its internal concave. When the eye is in its natural position, only the margin of the *membrana nictitans*, covered by conjunctiva, is perceptible, the rest being buried in the ocular sheath; but when, by the contraction of the straight muscles, the globe presses upon the pad of fat, the membrane is forced out, and covers more or less of the transparent cornea. This movement, which is instantaneous, is for the purpose of removing any offending agent from the surface of the eye. In some diseases, as tetanus, this membrane is forced outwards, and remains so.

A very small reddish-yellow gland, the *gland of Harder*, is found near the middle of the outer surface of the *membrana*; it is covered by fat and fibrous tissue, and it secretes an unctuous, lubricating fluid, which is poured on the internal surface of the cartilage, by several small openings. All authorities do not describe this gland.

The *CARUNCULA LACHRYMALIS* is the small round body, of a reddish colour, seen in the inner canthus. It consists of a number of follicles, and the bulbs of soft, fine hairs. Its use is to direct the tears towards the *puncta lachrymalia*.

#### LACHRYMAL APPARATUS.

The lachrymal apparatus consists of the lachrymal gland, lachrymal canals, lachrymal sac, and nasal duct.

The *LACHRYMAL GLAND*, situated between the orbital process and the superior straight muscle, is convex superiorly, concave inferiorly, thickest and broadest anteriorly, and thinnest and narrowest posteriorly. It belongs to the class of conglomerate glands, is of a pale yellow colour, and consists of numerous lobules, composed of sacculi and tubes held together by cellular tissue. The secretion, which constitutes the tears, destined to lubricate the anterior surface of the eye, escapes through numerous straight ducts, *hygrophthalmic canals*, which open on the surface of the conjunctiva underneath the upper lid, and towards the outer canthus; it is carried between the lids and the globe towards the inner canthus, and enters two small openings, the *puncta lachrymalia*, one on each side of the *caruncula lachrymalis*. These *puncta lachrymalia* are the openings of the minute *lachrymal canals*, which are formed in the substance of the eyelids, and are lined by a continuation of the conjunctiva; they

enter the lachrymal sac, the superior, being the longer, a little behind the inferior.

The LACHRYMAL SAC is a small reservoir lodged in a fossa in the lachrymal bone, and is the origin of the lachrymal duct.

The LACHRYMAL or NASAL DUCT (ductus ad nasum) is a long membranous canal, which begins at the sac, passes through a conduit in the bone, and terminates on the internal face of the nasal opening, on the skin, near to and a little above the inferior commissure of the ala; it sometimes terminates in two openings. It is lined by a continuation of the conjunctiva, which also lines the lachrymal canals and sac. In some animals it is partly lined by an inflexion of the mucous membrane of the nostril.

The OCULAR SHEATH is a dense fibrous membrane lining the orbit and enclosing its contents. It is strongest supero-externally, where the cavity is deficient in osseous boundary. It has been said that this membrane is continuous with the dura mater, to which it bears resemblance in structure.

The senses of Taste and Smell rest respectively in the tongue and nasal chambers, which have previously been considered.

#### SKIN AND ITS APPENDAGES.

The skin and its appendages constitute the exoskeleton or external casing of the body. The skin itself consists of two parts, the *dermis*, cutis vera, or corium, which forms the deep layer, and the *epidermis* or cuticle, superficially placed. Its chief appendages are glands, and the epithelial modifications, hair, horn, and hoof.

The EPIDERMIS, cuticle, or scarf skin, is an epithelial structure, forming a protective covering to the corium. It varies in thickness; is quite insensitive and non-vascular, and consists of agglutinated cells which are formed on the surface of the true skin; they contain nuclei, vary in form, the deep layers being columnar, those above rounded, those on the surface flat, being finally cast off as dry, desquamating scales. They also change in physical and chemical constitution, the deep ones being soft and opaque, the superficial dry, horny, and soluble in acetic acid. Their fluid portion when pressed out serves to cement them together. The epidermis is divided into a firm and transparent superficial and a deep soft layer. The latter is the *rete mucosum*, in whose cells

the pigment exists which gives colour to the skin. The deep surface of the epidermis is accurately moulded on the papillary layer of the true skin, and, when removed by maceration, presents depressions, which correspond to the elevations on the dermis; from the cuticle, tubular prolongations pass into the sebaceous and sudoriferous glands. The outer surface is marked by a network of furrows, the deep ones forming lozenge-shaped spaces.

The DERMIS, or true skin, is vascular and highly sensitive, being the seat of touch. It is attached to the underlying parts by a layer of areolar tissue, which usually contains fat, hence called the *panniculus adiposus*. The dermis consists of fibro-areolar tissue and vessels of supply; it is divided into two layers, the *deep* or *true corium*, and the *upper* or *papillary*. The deep corium consists of strong interlacing fibrous bands, chiefly white; its meshes are larger, and more open towards the attached surface, giving lodgment to the sweat-glands and fat. The papillary or superficial layer is formed of a series of small conical eminences or papillæ, which are highly sensitive, and consist of a homogeneous transparent tissue. The blood-vessels form dense capillary plexuses in the corium, terminating by loops in the papillæ. The papillary nerves run in an undulating manner, usually terminating in loops.

#### GLANDS OF THE SKIN.

These are the *sebaceous* and *sudoriferous*.

The SEBACEOUS GLANDS, lodged in the corium, are most abundant in parts exposed to friction. They generally open into the hair follicles, and occasionally on the surface of the skin. Each gland consists of a small duct, which terminates in a lobulated recess. These lobules vary, and are, as is the duct, lined with epithelium. They are filled with sebaceous matter, which, as it is secreted, is discharged into the hair sacs.

The SUDORIFEROUS or sweat glands are situated in the subcutaneous areolar tissue, surrounded by a quantity of fat. They are small, round reddish bodies, each of which consists of one or more fine tubes coiled into a ball, the free end of the tube being continued up through the true skin and cuticle, and opening on the surface by a funnel-shaped orifice. Sometimes there are two apparent ducts, which unite at a short distance from the gland.

The ducts are slightly curved as they pass through the corium. Where the scarf skin is thick, they assume a spiral appearance; where it is thin, they open directly out. They consist of two coats; an outer, continuous with the corium, and an inner epithelial one, which is continued to the surface. Each sweat-gland is supplied with a cluster of capillary blood-vessels. Their size varies, being very large where perspiration is excessive. The contents of the smaller glands are quite fluid, those of the larger contain fine granules.

The skin of the horse is characterised by its great sensitiveness, which is still further promoted by the operation of grooming, and artificial protection; and also by the development and activity of the sudoriferous apparatus; few animals, if any, perspire so freely as the horse. The large quantity of pigment found in the skin is believed to serve as a protection against the heat of the sun. An epithelial excrescence appears on the distal part of the forearm internally, and on the proximal portion of the metatarsus also internally; these objects, *ergots* or *cheshnuts*, the "châtaignes" of French authors, according to Chauveau, "represent the vestige of the thumb."

#### HAIR.

Hair is an appendage of the skin, and in most mammals forms its external covering. It is a special modification of epidermis, having in its bulk the same essential structure. A hair consists of a root, a shaft, and a point. The root has a bulbous enlargement at its extremity, is lighter and softer than the shaft, and is lodged in a recess or *hair follicle*, which may either be in the corium or subcutaneous areolar tissue.

The follicle is dilated at the bottom, to correspond to the root bulb, and the ducts of one or more sebaceous glands open into it. It consists of two coats; an *outer* or *dermic*, an *inner* or *cuticular*. The outer composed of areolar tissue, is highly vascular, continuous with the corium, and possesses numerous minute nerve fibrils; the inner, continuous with the cuticle, is attached at the base of the follicle to the root of the hair. The lining adheres to a hair when plucked out, forming the root sheath. At the bottom of each follicle is a conical vascular papilla, similar in every respect to those on the surface of the skin. This papilla fits into a corresponding depression in the root of the hair.

The hair shaft consists of a centre or medulla, a surrounding portion, and an external coating or *cortex*. The medulla consists of cells containing pigmentary matter, is opaque, and usually deeply coloured. All hair has not this medulla. The surrounding portion occupies the bulk of the shaft, and is composed of elongated cells, which form horny fusiform fibres. The cortex is merely a single layer of thin, flat, imbricated scales, which assume a different appearance in the hair of animals of different species.

About the muzzle of the horse are a number of largely-developed and strong hairs, commonly known as the *cat-hairs*, from their resemblance to the whiskers of a cat. These are media of touch, their bulbs receiving filaments of sensory nerves.

### FOOT.

In equine anatomy the word "foot" implies the hoof, together with the bones and soft structures contained therein. Many of these objects have already been described, so that our description here will be confined almost entirely to the hoof and the internal structures with which it comes into immediate contact.

In the broad sense we may regard the foot as consisting of three well-marked portions,—the basis or skeleton; the highly-sensitive secreting portion; and the non-sensitive protective portion. The two latter may be regarded as modifications of the skin; the sensitive part corresponding to the dermis or true skin, while its covering, the hoof, corresponds to the epidermis, both the latter structures being composed of a modified form of epithelium, and each being secreted by the sensitive structures within.

The study of the foot of the horse is of the greatest practical importance, owing to the many diseases and injuries to which it is liable. It resolves itself here into the consideration of the hoof or horny case, and the parts contained within it.

### HOOF.

The hoof of the horse corresponds to the finger-nail of man, but it is developed over the sides, and plantar aspect of the distal phalanx, thus forming a protective horny case, enveloping the inferior extremity of the digit. It is applied in an exact manner to, and united most intimately with, the sensitive struc-



tures which lie within, this union being effected by reciprocal depressions and elevations of the two surfaces, which fit into or receive each other. The general form of the hoof somewhat resembles that of the section of a cylinder which has been cut obliquely across.

By maceration, the hoof is divisible into three distinct parts; the *wall*, the *sole*, and the *frog*, which we will endeavour to describe separately.

## WALL.

The wall is that part which is visible when the hoof rests on the ground, and is generally divided into the toe, quarters, heels, bars, internal and external surfaces, and superior and inferior borders. The *toe* forms the front of the hoof, and is the deepest as well as the thickest part of the wall, which gradually declines in height as it passes backwards to form the *quarters*; these occupy the space between the toe and heels. The wall decreases in thickness from before backwards, more markedly so at the inner portion. It also apparently decreases in obliquity; but on careful examination, it is found that the fibres of the quarters have the same degree of obliquity as those of the toe. At the posterior part of the foot, the wall takes on each side a sudden bend, forming an acute angle, and is continued inwards to the centre of the foot, where the two parts unite with the sole. The angles of inflection are called the *heels*, the inflections themselves the *bars*; these latter forming stays to the quarters. The *external surface* of the wall is convex, smooth, and covered by a thin layer, the *periople*, which is continuous above with the coronary frog band. The *internal surface* of the wall presents throughout its whole extent white, parallel, perpendicular plates or processes of horn, the so-called *keratophyllous tissue*, which extend from the coronary border to the sole, and are continued over the inner surface of the bars. These insensitive or horny laminæ vary from 500 to 600 in number, and are separated from each other by deep fissures, in which are inserted the sensitive laminæ. In the fresh subject the horny laminæ are soft, elastic, and consist of two layers of fibres; one running parallel with themselves, and others obliquely projecting from them. The *superior* or *coronary border* of the wall presents an excavation or groove, which slopes somewhat obliquely downwards and inwards, forming a circular gutter, the *cutigeral*

groove, in which is lodged the *coronary substance* or *band*. In this groove are numerous minute orifices, in which are inserted the secretory villi of the coronary band. The *inferior border* is that part in contact with the ground, and to which the shoe is fitted. In an unshod animal it is always in wear, and protrudes beyond the rest, more especially round the outer quarter, and is known as the *spread*. The inner surface of the inferior border is united in a very intimate manner with the periphery of the sole. The external layer of horn in the wall is distinctively known as the *crust*, and is secreted by the coronary band; the rest being secreted by the sensitive laminae.

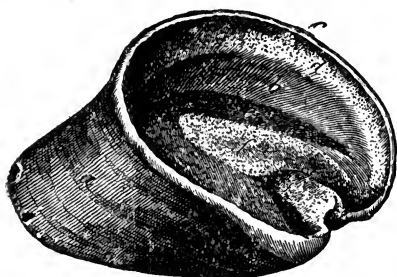


FIG. 211.

Detached hoof—supero-lateral view. *a*, Crust, or outer layer of the wall; *b*, Horny laminae; *c*, Superior border; *d*, Cutigeral groove; *e*, Inner surface of sole; *f*, Inner surface of frog; *f'*, Frog-stay.

such as the breed and age of the animal, the condition of the foot, &c., which may influence the angle.

Supposing the hoof to rest on a perfectly level plane, the line joining the toe to the middle of the coronary border should make with the ground an angle of about 50 degrees in the fore, and perhaps a little more in the hind feet. An angle exceeding or falling short to any extent of this, would indicate defective conformation. In this particular, however, it is necessary to make allowances for many circumstances,

#### SOLE.

The sole is a thick plate of horn, which helps to form the inferior portion of the hoof. It is comprised between the inner border of the inferior part of the wall and the inflections or bars, and presents two surfaces and two borders. The *inferior* or *external surface* forms a vault, which is more or less concave in different animals. The *superior* or *internal surface* is unevenly convex, and is studded with a number of small orifices, which run obliquely forwards; into these are inserted the vascular papillae of the sensitive sole. The *external border* or circumference of the sole is convex, abuts upon, and is united throughout its whole extent to the internal part of the inferior border of

the wall, the union between the two being very intimate, through the intervention of horny matter. The inner border represents a deep cut or notch, in the form of the letter V, and is related with the bars, excepting at the narrow part, where it is bounded by the frog. The two angles uniting the outer and inner circumferences correspond to the heels, and are received between the wall and the bars; this part of the sole covers the region which is most liable to injuries, especially to bruises or *corns*.

## FROG.

The frog is the prominent, somewhat pyramidal mass of spongy horn lodged between the bars, and filling up the triangular space. It has four surfaces, a base, and an apex. The *inferior* or *external surface* is very irregular, and presents a longitudinal triangular cavity, which varies in breadth and depth, being broadest and deepest in well-formed feet. This cavity is the *cleft* of the frog, bounding which are two sloping projections or branches, which unite at the apex of the frog anteriorly, and diverge posteriorly where they join the heels. The *superior* or *internal surface* is also very irregular, but exactly the reverse of the inferior; where the one is hollow the other has a projection, and *vice versa*. It presents over its whole surface numerous small foramina, into which are inserted the vascular or secreting papillæ of the sensitive frog, likewise a triangular excavation, which is divided posteriorly into two lateral gutters by a long projection or elevation, corresponding to the cleft on the outer surface. This somewhat conical eminence is called the *frog-stay*, and it assists in establishing a firm union between the horny and sensitive frogs. The *lateral surfaces* incline obliquely from above downwards, and from without inwards. In their upper third they are firmly united to the external surface of the bars, and anteriorly, to the notch in the sole. Between the inferior




FIG. 212.

Solar aspect of the hoof. *a a*, Bars; *b b*, Solar border of wall; *c c*, Line of union between wall and sole; *d*, Inferior aspect of sole; *d' d'*, Posterior branches of sole; *e*, Cleft of the frog; *e' e'*, Lateral segments of frog; *f f*, Bulbs of the frog; *g*, Point of the frog.

part of the lateral surfaces of the bars and the frog are deep triangular hollows, called the *commissures* of the frog. The base or posterior extremities constitute the *heels* or *bulbs* of the frog; these are two round flexible and elastic eminences, formed by the two extremities, and separated by the cleft. They cover the two angles of inflection of the walls, and are continued round the external part of the superior surface of the wall in the form of a band, which is the *coronary frog band*; it is from the inferior border of this that the thin covering of the hoof is continued.

The *summit* or *toe of the frog* is the anterior pointed portion, which is inserted into the narrow part of the notch in the sole.

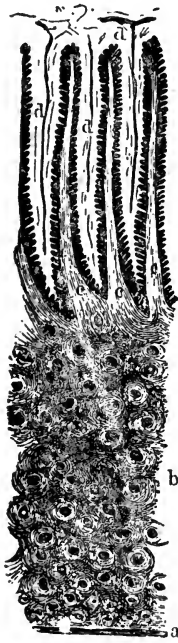


FIG. 213.

Transverse section of the horn of the wall magnified. *a*, Periople; *b*, Horn tissue; *c c*, Horny laminae; *d d*, Sensitive laminae.

#### HORN TISSUE.

The horn of the hoof presents a fibrous appearance, very distinct in the wall, less so in the deep-seated parts of the sole and frog, and scarcely traceable in the superficies of the sole, where there is a continual disintegration or separation of the horn in layers more or less extensive. It consists of minute cylindrical *tubes* or *fibres*, which have a direction obliquely downwards and forwards, and are arranged in parallel rows, forming layers, placed one over the other, and internally lamellæ or plates, the whole united together by an amorphous or intertubular substance. Besides the fibres, plates, and intertubular substance, there is always more or less *pigmentary matter*, which consists of colour-cells distributed amongst the concentric plates or layers forming the walls. The horny fibres of the sole have the same obliquity as those

of the walls, are secreted from the villi on the sensitive sole, and finally united to the wall round the outer circumference; they receive a few villi from the inferior extremity of each sensitive lamina.

The horn of the frog differs considerably from that of both wall and sole. The tubes are much finer and softer, and have a flexuous arrangement. They are united to those of the walls at

the base, and are secreted from the papillæ on the surface of the sensitive frog. The fibres of the coronary frog-band are very fine, and are continued by a delicate layer of fibres, which covers the external surface of the wall. Horn is tough, elastic, flexible, and admirably adapted for protecting delicate parts; it is secreted in the form of cells, which become elongated. The colour of the hoof varies, but it generally corresponds in depth with that of the neighbouring skin. It is an acknowledged fact, that white hoofs, like white skin, are more delicate, porous, and prone to disease than dark ones.

## SOFT STRUCTURES OF THE FOOT

The parts contained *within the hoof* are the os pedis, os naviculare, the distal extremity of the os coronæ, the ligaments by which these are connected together, the insertion of the extensor pedis and flexor perforans tendons, and the vessels and nerves. These have been described in their respective sections; but there are also certain structures proper to the foot which it is necessary to describe here—viz., the lateral cartilages, sensitive frog, coronary band, sensitive laminae, and sensitive sole.

The LATERAL CARTILAGES are two thin plates composed of hyaline cartilage in the middle, partaking more of the nature of fibro-cartilage towards the borders. They are of an irregularly quadrangular form, and surmount the wings of the coffin bone; each presents two surfaces and four borders. The external surface is convex, the internal one concave, presenting numerous vascular grooves, and is continuous postero-interiorly with the sensitive frog. The superior border is thin, generally convex, and pierced by several foramina for vessels to pass to the frog; the inferior border is attached to the wing of the os pedis posteriorly, it is inflected inwards, and is continuous with the inferior surface of the sensitive frog; the posterior border is slightly convex, and has a direction obliquely downwards and backwards, joining the superior and inferior borders, being separated from the former by an obtuse angle; the anterior border, also directed obliquely downwards and backwards, becomes intimately blended with the anterior lateral ligament of the coffin joint. The anterior borders of the two lateral cartilages are united by fibrous expansions from the extensor tendon and the above-mentioned lateral ligament

## SENSITIVE STRUCTURES.

Attached to the inner surface of the hoof is the sensitive portion of the foot, which may, like the hoof itself, be divided into the regions of the wall, the sole, the frog, and the coronary band. The extremity of the digit has been regarded not inaptly, as being enveloped in a sensitive sheath, which extends upwards beyond the level of the coffin joint, and becomes continuous with the skin. This sheath has been called the *keratogenous membrane*, since on its outer surface it is endowed with the function of secreting horn tissue, for the renewal of various parts of the hoof. The part of this membrane which forms the coronary band is villous or papillated; that forming the sensitive wall is laminated, constituting what has been termed the *podophyllous tissue*; finally, that forming the sensitive sole and frog is finely villous, and may be called the *velvety tissue*.

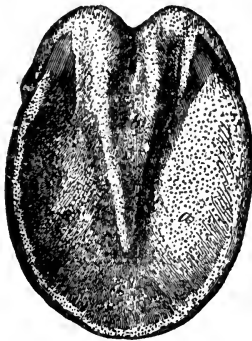


FIG. 214.

Sensitive foot—solar aspect.  
a, Velvety tissue of the sole; b,  
That of frog.

The SENSITIVE FROG occupies the posterior and central parts of the foot, filling up the irregular space between the lateral cartilages, flexor tendon, and os pedis. Bounded laterally by the cartilages, superiorly by the perforans tendon and common integument, infero-externally by the horny frog, it is continuous with the sensitive bars and sole, and the coronary ligament. Like the horny frog, it presents two surfaces, two lateral borders, a base, and an apex. The supero-anterior surface is related with the strengthening sheath of the flexor tendon, the ligament of the navicular joint, and the *alæ* of the os pedis; the infero-posterior surface is covered by villi, from which the horny frog is secreted, and in its centre is a deep cavity for the insertion of the frog-stay. The base looks backwards, and is divided into two bulbous enlargements, which are united to the lateral cartilages. The summit looks forwards, and is attached to the plantar surface of the os pedis in front of the semilunar ridge. The lateral surfaces correspond to the commissures of the frog, and are continuous with the inner surface of the lateral cartilages. The sensitive frog is made up of an external layer of cuticular structure, the

villi of which secrete the horny frog; below this is a layer of capillary blood-vessels; its substance is made up of connective tissue, intermixed with yellow-fibro-cellular tissue of a peculiar elastic nature, which used to be described as fat.

The CORONARY SUBSTANCE, or coronary band, formerly called the coronary ligament, is that vascular structure which occupies the cutigeral groove on the superior border of the wall. It consists of a dense fibrous mesh or band, which is connected with the coffin bone and extensor tendon by the medium of dense cellular tissue. Reposing on this is a plexus of blood-vessels, which is covered by a modification of the true skin, containing numerous papillæ, which enter the funnel-shaped openings in the crust, the horn of which is thus secreted.

The coronary band presents along its upper border a narrow lip or process—the *perioplic ring*—which secretes the horn of the periople.

The SENSITIVE LAMINÆ (podophyllous tissue) are the continuation of the coronary substance, and are attached to the coffin bone by a dense fibrous membrane, in which ramifies the vascular plexus emanating from the bone. These highly-organised plates are interposed between, and firmly attached to, the horny laminæ on the wall, and are covered by minute papillæ, which secrete the horny laminæ; on their inferior extremity are a few papillæ, which help to secrete the horny sole.

The SENSITIVE SOLE, continuous with the sensitive laminæ and frog, is firmly attached to the coffin bone; like the sensitive laminæ, it is made up of a fibro-vascular membrane, clothed by a continuation of the corium, which is covered by the villi which secrete the horny sole.

For the circulation of the foot, see pp. 417, 439; for its nerves, pp. 511, 514.

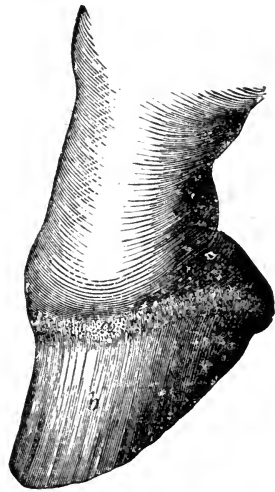


FIG. 215.

Sensitive foot—lateral view. a, Coronary band; b, Podophyllous tissue.

## COMPARATIVE ÆSTHESIOLOGY.

## RUMINANTIA.

THE concha of the ear is widely opened, projects outwards, and is less mobile than that of the horse; the internal and middle ears present no feature worthy of note, except that the handle of the malleus is more curved. The tapetum lucidum of the eye is of a golden green colour, inclining to blue at the circumference. In all the domesticated animals the *gland of Harder* occurs; and in other respects generally the eye of the ruminant resembles that of the solipede.

The *hair* on the tail of the ox, like that of the ass, is long only at the extremity, where it forms a tuft. About the frontlet—*i.e.*, between the horns—the hair is thick and curly, but in a degree varying in different breeds. The wool found on some of the smaller ruminants may be regarded as a modification of hair.

The *horns*, or weapons of offence, consist of a layer of horn tissue, developed from the secretion of a vascular and nervous membrane which covers the horn-core, and forms at its base a circular pad, becoming continuous with the dermis. Both the membrane and the pad contain keratogenous tissue, hence the tissue of horns, like the wall of the horse's hoof, is derived from two sources. The portion of the horn surrounding the pad is known as the *root*, that covering the core the *body*, while the part projecting beyond the core is the *point*. A number of rings appear, surrounding the horn just above its root, which are rather unreliable indications of the age of the animal. In shape horns vary much; in the bovidæ, the typical form is crescentic, with the convexity turned more or less downwards and outwards; in the ovidæ, where developed horns are less general, they are usually curved spirally, sometimes assuming a very graceful curve, the first bend being with the convexity outwards and forwards; in the goat they are closer together, and more perpendicular, being slightly curved, with the convexity inwards; all these forms are subject to great variation, some species of ruminants, as the camelidæ, being altogether without horns, while in others their development is enormous.

Animals possessing horns of the above type are classed as *cavicornia*, or hollow-horned. The horns of deer (antlers) differ from these, in being formed of solid bone, in having branches, and being deciduous, falling off every year to be replaced by new ones.

The hoof is, of course, divided into two parts, one for each digit, each part resembling in shape the distal phalanx. Their general structure resembles that of the horse's hoof, but the frog is little developed. A small horny projection appears on each side of the posterior aspect of the fetlock; these are rudimentary hoofs, each containing a small bone disconnected with the skeleton.

## OMNIVORA.

In the hog the concha is large, but variable in its arrangement, being sometimes erect sometimes flaccid. In connection with the eye the gland of Harder exists. The skin is thick, often destitute of pigment, and has a very



thick subjacent layer of fat. The amount of hair on the skin varies greatly, but appears to decrease in proportion to the domesticity of the animal, the wild boar being provided with a comparatively thick coat. The hairs are thick and strong, being commonly known as *bristles*. In a general sense the hoofs resemble in form those of the ruminant, but they consist of four pieces on each extremity. See Fig. 32.

## CARNIVORA.

The *conchal cartilage* in the dog is extremely variable, both in shape and size, according to the breed, but in most breeds it folds downwards, forming the *drop*, or flap, which serves to protect the cavity of the external ear from the intrusion of foreign matters. In the cat, and in fact in the *felidæ* generally, the concha is broad, short, and erect, with the opening turned forwards.

The *globe* of the eye is much more spherical, while the iris is of various modified shades of yellow. The pupil is circular, and the tapetum lucidum of a bluish white. In some features the eye of the cat differs, the pupil being circular only when fully dilated; when contracted it appears as a narrow vertical slit; the iris has a greenish lustre, while the tapetum lucidum is golden yellow.

The sudoriferous glands are extremely minute and difficult to find, excepting about the region of the nose and digital pads. The latter are callous thickenings of the epidermis, upon which the animal walks. The distal phalanges are covered by horn, which projects, curving outwards and downwards to form the *claws*. As we have already seen, the claws are retractile in the cat, where they are also sharp, and serve chiefly as weapons of offence. In the dog the claws are virtually fixed and blunt, becoming worn by constant locomotion and scratching.

No rule can be given as to the nature of the hair in dogs, as it differs greatly in length, texture, and colour. In the cat it is short, sleek, and furry, and in colour equally variable. The *touch-hairs*, or whiskers, situated at the sides of the nose, are well marked in the cat, and are usually white in hue; the tail is generally covered by hair nearly as short as that on the rest of the body.

## RODENTIA.

The *concha* of the ear is large and very long in the rabbit, and may be either erect or pendent, but most usually it is the former. There are no *puncta lachrymalia*; the lachrymal gland and membrana nictitans are both large. The rabbit tribe is remarkable for including a large number of *albinos* or individuals devoid of pigmentary tissue; the result of this is perfect whiteness of hair and skin, and *redness of the iris*, the latter being due to the thick plexus of blood-vessels contained therein, which is displayed by the absence of pigment.

The claws somewhat resemble those of the dog, but they are better adapted for scraping the soil, the animal being naturally a *burrower*.

## AVES.

Birds have no *concha*, the external ear comprising only the auditory meatus. This deficiency in the apparatus for collecting sound is compensated for in the large size of the labyrinth. The cochlea is not shell-shaped, but merely a bent tube; the semicircular canals are proportionally very large. The auditory ossicles are represented by a single bone, called the *columella*, which perhaps represents the stapes, attached by processes of cartilage to the tympanic membrane. Owen considers these cartilages the representatives of the mammalian *malleus*, Huxley that they represent the *incus*, while the latter authority holds that the malleus is represented by the *os quadratum*. The Eustachian tube is large and osseous in structure.

The eye in birds is very large, and only slightly movable. The sclerotic coat contains anteriorly a ring of imbricated osseous scales varying in number from twelve to twenty. Not unfrequently it becomes ossified posteriorly forming an osseous sheath round the optic nerve. The *pecten* is a vascular membrane stretching from the *porus opticus* into the substance of the vitreous humour. The *choroid* coat is always black, and the pupil round; the iris is said to contain *striated* muscular fibre. The *membrana nictitans* is well developed, and moved by two muscles. The lachrymal and Harderian glands are present, but the Meibomian glands are wanting.

The exoskeleton consists of the skin, modified in places into horn or scales, and elsewhere covered by structures peculiar to the class—the *feathers* or plumage; these are chiefly of two kinds, the quill-feathers and the clothing feathers, the most rudimentary of the latter being known as “down.” A quill-feather consists of two principal portions—the quill (*calamus*) and the vane (*veillum*); the quill is continuous with the central shaft called the *rachis*, the two forming the stem or *scapus* of the feather. Projecting outwards from the stem on each side are a large number of pointed and very flexible *barbs*, these again bearing still smaller processes or *barbules*. At either end of the quill is a small opening or *umbilicus*, and inside the barrel is contained a pulp, which in young feathers is very vascular, the vessels entering by the proximal umbilicus, which, along with part of the quill, is buried in a papillated follicle of the skin; at the base of the shaft a second rudimentary shaft is usually formed, which, however, may be represented by a mere tuft of down. The smaller feathers are constructed on the same general principles; they cover the body, the upper part of the legs, and the head, while the larger feathers and quills are confined to the wings and tail.

The longest quill-feathers are those arising from the hand, called the *primaries*; those arising from the distal part of the fore-arm are the *secondaries*; while the *tertiaries* are those which spring from the proximal part of the same. The rudimentary pollex carries some feathers which form the *alula* or bastard wing. The *scapularies* are feathers covering the scapula and humerus. The *wing coverts* are rows of small feathers covering the bases of the larger ones; they are described as three, the greater, the lesser, and the inferior. The quill-feathers of the tail are called the *rectrices*; they have considerable mobility, and their bases are covered by a row of *tail-coverts*.

The skin becomes horny where it covers the *rostrum* or beak, and in some birds at the base of the same, it forms scales round the nostril; or this part may have a naked or waxy appearance, which is known as the *cere*. Below the tarsal joint the extremity is usually covered with horny scales or plates, but some breeds of domesticated birds are "feathered to the ground." The pedal digits of the natatores in each limb are joined by a membrane, which is covered with scaly skin, forming the *web-foot*. In the domestic fowl the claws are blunt and very strong, that bird being a good example of the order *Rasores*, or *scratchers*. The glands of the skin are few, but in many birds, and notably in aquatic species, there is a large gland in the skin of the *uropygium*, or basis of the tail; this gland secretes an oily sebaceous fluid, which is employed by the animal in dressing or *preening* its feathers. The *combs* or *wattles*, which are the red or sometimes blue processes formed about the heads of certain birds, are very vascular and often erectile structures, appendages of the integument.

## CHAPTER VIII.

### EMBRYOLOGY.

As this branch of the subject is better studied from a physiological point of view, we must refer the student to some able work on physiology for a description of the changes in, and development of, the fecundated germ of the future animal. Our few remarks, for the most part, apply to the fully, or nearly fully, developed foetal animal.

As we have previously seen, the *ovum* is the germ of the future animal, while the fecundating principle is the spermatozoön. From the period of fecundation to that of parturition, or birth of the young, the interval is said to be that of *utero-gestation*. This interval differs in different classes of animals, but in the same class it persists with singular uniformity, the variations being small. The period of utero-gestation in the mare is 48 weeks; in the cow, 40; in the sheep, 21, or 22; in the sow, 16, or 17; in the bitch, 9; and in the rabbit, about 4 weeks.

In its early stages of development the fecundated ovum is known as the *embryo*; in the later stages it is called the *fœtus*; but the exact condition at which this change of name occurs is indeterminate. The fœtus occupies the cavity of the uterus, the neck of that organ being closed during gestation by the Nabothian glands.

#### OVUM AFTER FECUNDATION.

The primary changes undergone by the fecundated ovum, interesting as they are, can be merely alluded to here. By repeated fusion of the vitelline substance there arises a cellular material called the *embryogenic tissue*, or *blastoderm*, out of which the body of the embryo is formed. This tissue divides into three layers, an outer, a middle, and an internal, called

respectively the epiblast, mesoblast, and hypoblast. From the epiblast become developed the epidermis and its appendages, and the cerebro-spinal axis, from the hypoblast the mucous membrane of the alimentary canal, while the mesoblast gives rise to the intervening organs and tissues.

A linear indentation, the *primitive groove*, appears on the epiblast, and below and coincident with this the *notochord*, which indicates the position of the vertebral column, becomes formed.

The chief appendages and coverings associated with foetal life are the umbilical sac, the amnion, chorion, and allantois, the placenta, and the umbilical cord.

The outer covering of the foetus is the chorion, a membrane derived from the blastoderm and reflected over the foetus; the placenta is formed by the connection of this covering with the mucous membrane of the uterus. The inner covering is the amnion, which contains a fluid, the *liquor amnii*. The allantois or urinary vesicle is regarded as taking its origin from the primitive intestine. Becoming vesicular in form to it proceed the ducts of the *Wolfian bodies*, or primordial kidneys.

The umbilical sac proceeds from the blastoderm; it covers the yolk, and like the allantois is not included in the amnion.

#### PLACENTA.

The blood of the foetus becomes purified, and charged with the materials of nutrition, by being brought into close connection with the blood of the mother, and this process is achieved in a structure called the *placenta*, an organ which contains capillary plexuses derived from the umbilical arteries of the foetus, and others from the uterine arteries of the mother; it is situated between the mucous membrane of the uterus and the external membranous sac, the *chorion*, which completely envelops the foetus, to both of which structures it is attached.

The placenta assumes a variety of forms in the various classes of animals. In the mare and sow it is *diffused*—i.e., it consists of villi scattered over nearly the whole outer surface of the chorion, and received into crypts or corresponding recesses in the uterine mucous membrane. In the ruminant the placental villi are collected into groups, forming a number of rounded or ovoid objects termed *cotyledons*, hence this placenta is said to be *polycotyledonary*. However in the *Camelidæ*—"The foetal villi are

scattered evenly over the chorion, so that the placenta is *diffuse*." (Huxley). In carnivora the villi are collected in a mass which assumes the form of a belt, surrounding the chorion, and hence called a *zonary* placenta. In rodentia the placenta is *discoid*, the villi being assembled in a more or less circular mass.

The placenta is found in most orders of mammals, and in them alone; its presence or absence has led to the separation of the class mammalia into a placental and an implantal division.

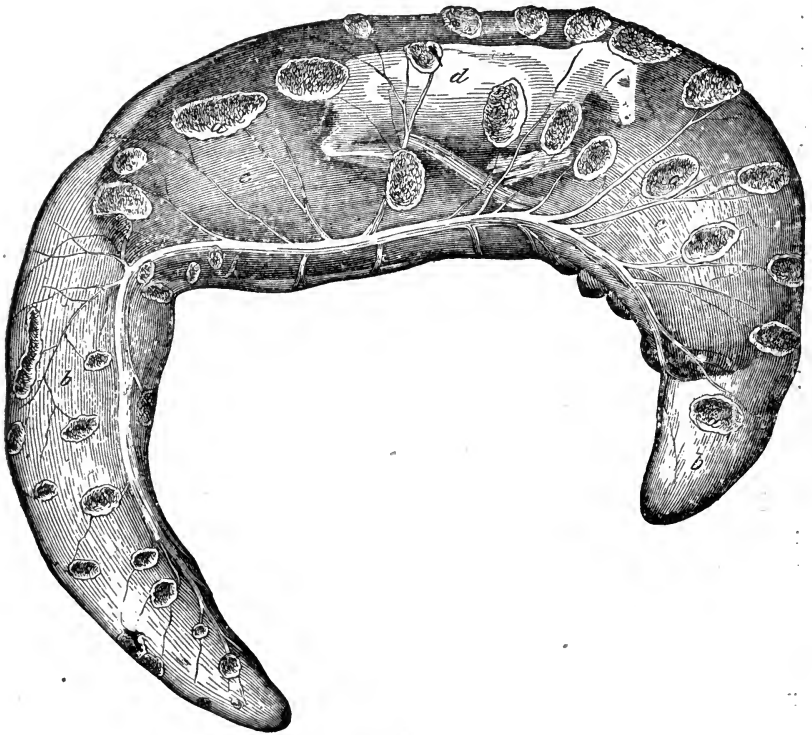


FIG. 216.

Fœtus of the Cow, with its membranes. *a a*, Placenta; *b b*, Chorion with the Allantois adherent to its inner surface; *c c*, Amnion seen through outer covering; *d d*, Fœtus seen through its coverings.

#### UMBILICAL CORD.

This structure is the medium of connection between the fœtus and the placenta, reaching from the latter to the umbilical opening in the linea alba. It consists mainly of the umbilical vessels, one vein, and two arteries, and superiorly contains the urachus, a fœtal tube continuous with the bladder.

## CIRCULATION OF THE FŒTUS.

In the fœtus there is a direct communication between the right and left auricles, by the *foramen ovale* in the interauricular septum; and in man the large Eustachian valve, situated at the anterior border of the posterior vena cava, at its entrance into the auricle, directs the blood from the posterior vena cava through the foramen ovale into the left auricle; as we have before remarked, the presence of this valve in quadrupeds is very doubtful. Another difference between the fœtus and adult is the presence of a communicating branch between the pulmonary artery and posterior aorta, called the *ductus arteriosus*. There

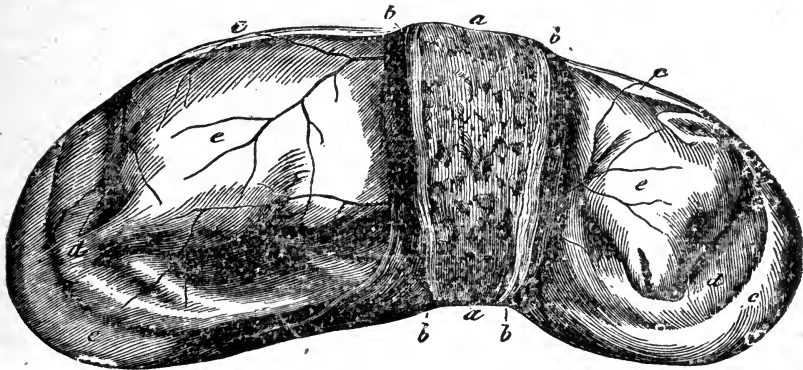


FIG. 217.

Fœtus of the Bitch, with its membranes. *a a*, Uterine placenta; *b b*, Fœtal placenta; *c c*, Chorion; *d d*, Amnion seen through former; *e e*, Fœtus visible through its coverings.

are two large arteries, the *umbilical* or *hypogastric*, which arise from the internal iliacs, pass along the sides of the bladder to its fundus, and out of the umbilical opening, being continued along the umbilical cord to the placenta; in their course down the cord they wind spirally round the umbilical vein. Finally, the *umbilical vein* leaves the placenta, passes up the cord, and enters the umbilicus, running along the floor of the abdomen, to reach the liver, where it joins the vena porta. We may now proceed to trace the course of the fœtal circulation.

The purified blood leaves the placenta by the umbilical vein, which is formed by the junction of numerous radical branches, and passes along the umbilical cord, accompanied by the two arteries,

on entering the abdomen, it passes forward along the floor of the abdominal cavity, covered by peritoneum, and thus arrives at the liver; it joins the portal vein, its blood thus gaining the hepatic veins, and afterwards the posterior vena cava, where it mingles with the venous blood from the posterior region. The mixed blood is conveyed by the posterior cava into the right auricle, and passes directly through the foramen ovale into the left auricle; from the left auricle it enters the left ventricle, and by it is forced into the aorta; the major part passing into the anterior aorta, is distributed to the head and fore extremities; the remainder passes into the posterior aorta.

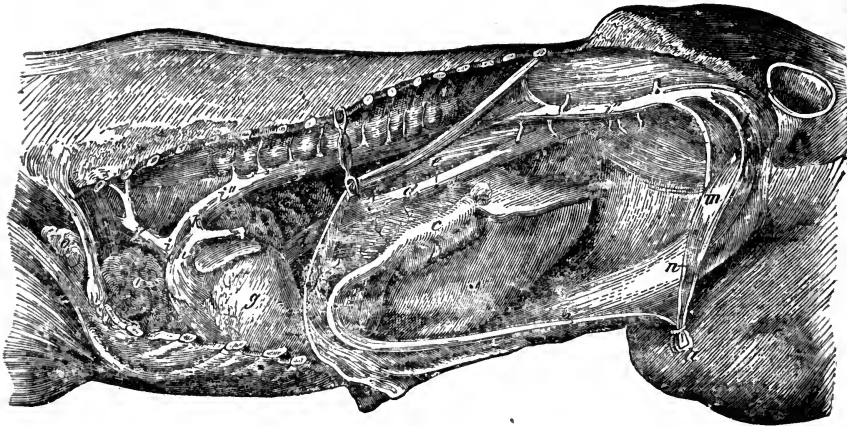


FIG. 218.

Trunk of a fully-developed fœtus—opened from the left side to show the circulation. *a*, Umbilical cord, cut and ligatured; *b b*, Umbilical vein; *c*, Portal vein ligatured; *d d*, Posterior vena cava; *e e*, Openings of hepatic veins; *f*, Diaphragm cut and reflected; *g*, Heart; *h*, Pulmonary artery; *i*, Common aorta; *i'*, Anterior aorta; *i'' i''*, Posterior aorta; *k*, Ductus arteriosus; *l*, Left, *l'*, Right umbilical arteries; *m*, Bladder; *n*, Urachus; *o o*, Thymus gland.

Venous blood is returned from the anterior region to the right auricle by the anterior vena cava, and passes directly into the right ventricle along with a small portion of the blood from the posterior vena cava; the right ventricle propels it through the pulmonary artery, from which only a small portion passes into the *impervious lungs*, to be returned to the left auricle by the pulmonary veins, the greater part going through the ductus arteriosus into the posterior aorta, where it becomes mixed with a portion of the blood from the left ventricle. In the posterior aorta, it flows backwards to supply the posterior extremities and abdominal viscera; the chief portion, however, on arriving at the termination of the posterior aorta, enters the umbilical arteries, and by



them is returned to the placenta to be purified. *At birth*, when respiration has been established, the placental circulation is cut off, the foramen ovale rapidly closes up, leaving the fossa ovalis; the ductus arteriosus contracts, and together with the umbilical arteries and vein, becomes obliterated.

The consideration of these facts will show that the fœtus is nourished by blood less perfectly arterialised than that of the adult, the blood becoming mixed in the liver, in the heart, and in the posterior aorta by means of the ductus arteriosus. It should be borne in mind that the blood which supplies the posterior region is less pure than that supplying the head and anterior region; this accounts for the fact that at birth the posterior parts of the frame are less developed than the anterior.

#### DEVELOPMENT OF THE FŒTUS.

The following facts and measurements derived from the observations of Gurlt, Leyh, Franck, and others, may be useful in determining the age of the fœtus or embryo.

To facilitate the study of the development of the fœtus, the time which elapses between conception and birth has been divided into seven periods as follows:—

I. *Period*.—Includes, in all the domesticated mammals, the first and second weeks after conception. The ovum lies free in the uterus. In the dog it measures about one line in length. The chorion and amnion can be made out.

II. *Period*.—Includes, in the horse and ruminant, the 3rd and 4th weeks; in the pig, the 3rd and half of the 4th week; in carnivora, the 3rd week.

(a) *Horse*.—At 28 days the embryo is a little over  $\frac{1}{2}$  inch long. The division into head, trunk, and limbs is indicated.

(b) *Ox*.—At 28 days, the embryo has a length of  $\frac{2}{5}$  inch, and corresponds in its development to the sheep's embryo of 25 days.

(c) *Sheep*.—The embryo of the sheep, at 18 days, has a length of  $\frac{1}{3}$  inch. At 23 days, indications of the feet appear. At 25 days, it has a length of  $\frac{2}{5}$  inch; indications of the eyes, ears, and tail are present; the intestine exists as a tube connected with the umbilical vesicle; the Wolffian body is well developed.

(d) *Pig*.—The pig's embryo, at 21 days, has a length of about  $\frac{1}{3}$  inch; at 24 days,  $\frac{1}{2}$  to  $\frac{2}{5}$  inch. The umbilical vesicle has reached its maximum size.

(e.) *Carnivora*.—The villi appear on the chorion, and become attached to the mucous membrane of the uterus. At 18 days, the embryo of the dog has a length of about  $\frac{1}{5}$  inch; the primitive groove and chorda dorsalis are present. At 19 or 20 days, the heart is present as an S-shaped tube; the intestine begins to form. At 21 days, indication of the eyes, ears, and Wolffian body are present; the limbs are present as small blunt processes.

III. *Period*.—Includes, in the horse and ox, the 5th to the 8th week; in the sheep and goat, the 5th, 6th, and first half of the 7th week; in the pig, the last half of the 4th, the 5th, and first half of the 6th week; in carnivora, the 4th week.

(a.) *Horse*.—The horse's embryo, at 6 weeks, has a length of  $1\frac{3}{8}$  inch. At 7 weeks, 2 inches; and at 8 weeks,  $2\frac{3}{8}$  inches; the thoracic and abdominal cavities are closed.

(b.) *Ox*.—At 6 weeks, the embryo is  $\frac{4}{5}$  inch in length, and corresponds to the 22-23 days-old dog's embryo. At 7 weeks, it is about  $1\frac{1}{5}$  inch in length; the udder begins to form; the kidneys and ureters are present. At 8 weeks, the embryo is from 2 inches to  $2\frac{3}{8}$  in length.

(c.) *Sheep*.—At the 5th week, the embryo has a length of 1 inch, and, in development, corresponds to the 25 days-old dog's embryo.

(d.) *Pig*.—At 28 days, the embryo has a length of 1 inch. At 37 days,  $2\frac{1}{8}$  inches.

(e.) *Carnivora*.—At 22-23 days, the embryo has a length of about  $\frac{3}{8}$  inch; mouth-groove, nostrils, lungs, trachea, and larynx are present; the anus is still closed; Wolffian body well formed; limbs about one line in length. At 25 days, the thorax is closed, and the abdominal cavity almost closed. At 26-28 days, the embryo is about  $1\frac{3}{8}$  inch in length; all organs are more or less distinctly marked.

IV. *Period*.—Includes, in the horse, the 9th to the 13th week; in cattle, the 9th to the 12th week; in the sheep and goat, the last half of the 7th, the 8th, and the 9th weeks; in pigs, the last half of the 6th, the 7th, and first half of the 8th week; in carnivora, the 5th week.

(a.) *Horse*.—At the 9th week, the embryo measures  $3\frac{1}{2}$  inches; the external ears are very small; the Wolffian body, genital

glands, kidneys, and suprarenal capsules are present. At 10 weeks, the embryo measures  $3\frac{2}{5}$  inches; the internal and external genital organs are formed. At 11 weeks, the embryo measures  $4\frac{1}{5}$  inches. At 12 weeks,  $4\frac{3}{5}$  inches; and at 13 weeks  $5\frac{3}{5}$  inches.

(b.) *Ox*.—At 9 weeks, the embryo measures almost  $3\frac{1}{5}$  inches. At 10 weeks,  $3\frac{3}{5}$  inches. At 11 weeks,  $4\frac{2}{5}$  inches, and its development corresponds to that of the horse's embryo of the same age; mouth-groove and nostrils are closed by a thin membrane; the divisions of the stomach are present. At 12 weeks, the embryo measures  $5\frac{3}{5}$  inches.

(c.) *Sheep and Goat*.—At 8 weeks, the length of the embryo is about 2 inches. At 9 weeks,  $3\frac{3}{5}$  inches; the nostrils are still closed.

(d.) *Pig*.—Length of embryo in the 8th week is  $3\frac{1}{5}$  inches.

(e.) *Carnivora*.—Length of embryo in the 5th week is  $2\frac{3}{5}$  inches.

V. *Period*.—Includes, in the horse, the 14th to the 22nd week; in the ox, the 13th to the 20th; in the sheep and goat, the 10th to the 13th; in the pig, the last half of the 8th, the 9th, and the 10th week; in carnivora, the 6th week.

(a.) *Horse*.—During this period the embryo increases from  $5\frac{3}{5}$  inches to  $14\frac{3}{5}$  inches. At 17 weeks, the first hair appears on the lips. At 22 weeks, the lips, eyelids, and point of tail are provided with hair.

(b.) *Ox*.—The embryo increases from  $5\frac{3}{5}$  inches to  $12\frac{2}{5}$ . At 18 weeks, the hair appears, and the testicles descend into the scrotum.

(c.) *Sheep and Goat*.—At the end of this period the embryo measured  $6\frac{2}{5}$  inches; hair is still wanting.

(d.) *Pig*.—The embryo measures  $5\frac{1}{5}$  inches.

(e.) *Carnivora*.—The embryo has a length of  $3\frac{1}{5}$  inches.

VI. *Period*.—Includes, in the horse, the 23rd to the 34th week; in cattle, the 21st to the 32nd week; in the sheep and goat, from the last half of the 13th to the 18th week; in the pig, from the 11th to the first half of the 15th; in the dog, the 7th and 8th weeks; in the cat, to the end of the 7th week.

(a.) *Horse*.—The embryo grows about one inch weekly, and at the end of the period has a length of about 27 inches. The

hair appears on the crest and back. The testicles lie near the abdominal ring.

(b.) *Ox.*—The embryo at the end of 32 weeks measures about 25 inches.

(c.) *Sheep and Goat.*—The embryo has a length of from 10 to 13 inches.

(d.) *Pig.*—The embryo measures about 7 inches in length.

(e.) *Carnivora.*—The dog's embryo measures about 5 inches; the cat's embryo, 4 inches. The body is covered with hair, and the claws are present. The eyelids are closed, and the testicles are still in the abdomen.

VII. *Period.*—Includes, in the horse, the 35th to the 48th week; in cattle, the 33rd to the 40th week; in the sheep and goat, the 19th to the 21st or 22nd week; in the pig, the last half of the 15th to the 16th or 17th week; in dogs, the 9th week; and in cats, the 8th week. In all animals it reaches up to the time of birth.

(a.) *Horse.*—The fœtus attains at the end of this period a length of over a metre (3 feet); it is completely covered with hair, and the testicles pass into the scrotum. The inguinal ring is very wide, and slight hernia is generally present.

(b.) *Ox.*—The fœtus measures about 32 inches.

(c.) *Sheep.*—The fœtus has a length of about 18 inches. *Goat.*—The fœtus measures about 13 inches; if only one fœtus is present, 18 inches.

(d.) *Pig.*—The fœtus has a length of 10 inches.

(e.) *Carnivora.*—The fœtus measures about 7 inches. The cat's fœtus, about 5 inches.

---

# APPENDIX.

No. I.

## GENERAL DIRECTIONS FOR DISSECTION.

*Compiled chiefly from Chauveau's "Traité d'Anatomie Comparée des Animaux Domestiques."*

### THE ARTICULATIONS AND LIGAMENTS.

IN order to prepare the articulations, the student should select young, in preference to subjects advanced in age, because in the former the density of the cellular tissue is less than in the latter. As the ligaments are prepared with difficulty when their external surface is dried up, care should be taken to keep them protected from the air until the time to dissect them, by covering them with wet linen rags, or with the hide of the animal.

It is convenient to separate the articulation which one wishes to study, by cutting the bones at a short distance from the articular surfaces. The handling of the piece is thus more easy, and the dissection is made under more favourable conditions.

It is important to take as much care as possible of the muscles which surround the articulations, so as to be able to study their connections with the ligaments. If it is absolutely necessary to take away the muscles, their attachments should be preserved.

Study first the capsular ligaments, and then remove them so as to display the funicular bands. The latter, in their turn, are to be sacrificed so as to expose, by means of different sections, the interosseous ligaments, if any exist. Separate at last, in a complete manner, the two articular surfaces, laying them bare, and then examine their conformation.

The synovial membranes, with their different *cul-de-sacs*, being a very important subject of study with reference to the diagnosis and treatment of certain articular diseases, the student is recommended to preserve a

special piece or preparation for the study of those serous membranes. He may also very easily inject their interior with plaster of Paris, or with tallow, coloured black, so as to distend their *cul-de-sacs*, and favour the study of their connections with the ligaments, tendons, or muscles.

## THE MUSCLES.

*Choice of a Subject.*—If a number of subjects are at the disposal of the student, so that he has it in his power to make a choice, he should give the preference to those in which the muscular system is well developed, avoiding however very fat animals. Subjects of small or middle size are always more convenient than those having great masses of muscle and fat. Asses and mules, when they are very lean, show the muscular system very distinctly.

*Position of the Subject.*—It is important to place the subject, immediately after death, in a convenient position, as cadaveric rigidity preserves it. Without this precaution, the different parts of the body of the animal may take an inconvenient attitude, and all attempts to rectify the position will be for some time futile, especially in animals of great size.

The subject may be placed in three different positions:—

1. The animal is placed in the *first position* when it is laid upon its back, and the four extremities are raised in the air, and supported by means of cords or ropes fixed to the pasterns and passed through movable rings, which are fixed to the extremity of four upright bars or posts at the corners of the table upon which the animal is laid. The head passes over the end of the table, and rests upon a stool, on a lower level, so that the neck may not be twisted.

2. To place the animal in the *second position*, it is turned upon its belly, the extremities extended upon the table, and the head supported between two upright bars, by means of a rope passed under the jaw.

3. The subject is said to be in the *third position* when it reposes on its side.

As far as possible the skin should not be removed, except from those regions which are to be dissected at the time. If it can be done, the student should take the precaution of wrapping up the parts with cloths wet with some preservative fluid, to prevent the drying up of the aponeuroses and the superficial muscles.

To dissect a muscle, raise the aponeurosis, or the other muscles which cover it, and dissect off the cellular tissue which enwraps it, the fat, and after ascertaining their names, the glands, vessels, and nerves lodged in the interstices. Dissect the aponeurosis in strips, making the scalpel glide

between the fibrous layers, holding the blade always parallel to the surfaces. Any muscles covering it ought to be entirely cut away, by being divided near the middle, across their fibres, the two ends reflected to the side, and the study of their attachments is thus more easily made. Remove the cellular tissue by lifting it with a pair of forceps, and inserting the edge of the scalpel in the angle formed by the cellular tissue and the surface of the muscle. For removing fat, glands, &c., scissors may be used with great advantage.

#### DISSECTION OF ALL THE MUSCLES UPON THE SAME SUBJECT.

Place the subject in the first position, and commence the study of the muscles of the inferior abdominal region. Then cut off these muscles, the one extremity from the sternal attachments, the other from the prepubial tendon and crural arch. The cavity of the abdomen and viscera will thus be displayed; and the latter being removed, the student should proceed to study the diaphragm, internal crural region, the sublumbar region, the anterior and posterior femoral regions, as also the superficial muscles of the inferior cervical and pectoral regions.

Turn the animal over, and place it in the second position. Dissect the muscles of the ears, those of the superior cervical region, the withers, the costal region, the spinal region of the back and the loins, and the region of the croup. The fore limbs may be partly prepared at the same time, one being removed for the study of the fore-arm and foot.

Afterwards, separate one hind limb by sawing the femur through the middle, and then proceed to the dissection of the muscles of the leg and hind foot. Then by means of another cut of the saw carried through the middle of the loins, isolate completely the pelvis, to make a dissection of the coccygeal muscles and the deep muscles of the internal femoral region.

The animal having been turned upon its side in the third position, open the cavity of the chest and saw through the ribs near their extremities, thus forming two sections, the one containing the triangularis sterni, the other the inferior and lateral muscles of the head and neck. The subject may afterwards serve for the study of nearly all the joints.

#### REMOVAL OF THE HOOF.

As the terminal insertions of some of the muscles of the limbs are situated in the interior of the hoof, it is absolutely necessary, in order to see them, to break open this horny case, and we will describe a simple method of performing this operation. The instruments necessary for breaking open the hoof are a scalpel, a chisel, a hammer, and a pair of strong forceps. The limb is fixed by one or two

assistants holding it in a vertical position, the foot resting upon a table, stool, or solid block of wood. Push in, as deeply as possible, the blade of the scalpel between the sensitive and the horny wall; move it about from right to left, and make it follow the contour of the latter. By means of the chisel and the hammer, split the wall into four or five fragments by a convenient number of vertical incisions. When the wall has been thus divided into several segments, detach each of these, by inserting the point of the chisel into one of the incisions, and, using this instrument as a lever, throw back the portion of horny substance to the right or left. The flap of the opposite side is then raised and separated from the subjacent tissues. Their complete detachment will be effected by means of the strong forceps, and by twisting them with considerable force, the portion of the wall will be torn from the sole. In order to uncover the latter, pass the blade of the scalpel between the upper face of the horny arch and the sensitive sole; push the point of the chisel into the space thus opened, raising lightly the external edge of the sole. Then seize the latter with the forceps, and detach it, as well as the frog, by a wrench, giving the instrument a vigorous movement backwards and forwards, the assistants holding the limb tightly and with a force opposed to that of the operator.

### THE ORGANS OF DIGESTION.

**THE MOUTH.**—The whole of the mouth ought to be examined by an antero-posterior and vertical section of the head.

**THE PALATE.**—Separate the head from the trunk; then saw through the ramus of the inferior maxillary bone above the angle of the jaw and the crown of the last molar tooth, in such a manner as to pass between the velum palati on the one side, the base of the tongue on the other, and leave this latter organ adherent to the lower jaw. Separate the lower jaw from the upper, cutting the masseter and alveolo-labial muscles, and in this way expose the palate and the velum palati, upon which it will then be possible to execute easily the special dissection necessary for their study. For the palate, these dissections consist in raising the mucous membrane which conceals the deep venous plexus, and in the partial removal of the latter so as to see the artery and the palatine nerves.

**THE TONGUE.**—1. Make, by means of a strong saw without a back, an antero-posterior and vertical section of the head, to study the general disposition of the tongue. 2. Remove from another head the lower jaw, leaving the tongue in the maxillary space, so as to examine the external conformation of the organ. 3. Upon another head intended for the



study of the muscles, lay bare these structures in the following manner:—Remove entirely the masseter; detach the cheek from the lower jaw and reflect the flap upon the upper; saw through the ramus of the jaw transversely, immediately behind, and then before the line of the molar teeth; remove and dislocate from the temporo-maxillary articulation the upper fragment of the bone, destroying the capsular ligament and the insertions of the pterygoid muscles; reverse the lower fragment so as to place the line of the molar teeth below, and the inferior border of the bone above, in the bottom of the intermaxillary space; it is sufficient, in performing this last operation, to separate the buccal mucous membrane from the mylo-hyoid muscle, proceeding from above downwards. The dissection thus made is convenient not only for the study of the muscles of the tongue, but also for the study of the deep salivary glands, the pharynx, the larynx, the guttural pouches, the nerves and arteries of the head, &c. It is always well, to facilitate this dissection, to keep the jaws open by inserting a piece of wood between the incisor teeth, immediately after the death of the animal.

**THE VELUM PALATI.**—Study the velum palati: 1. By an antero-posterior and vertical section of the head. 2. Make the dissection described under “The Palate,” and dissect off the mucous and glandular layer, so as to lay bare the fibrous membrane, and the two intrinsic muscles; the extrinsic muscles ought to be studied with those of the pharynx.

**THE STOMACH.**—In order to study the organ in its connections, it is sufficient to open the abdomen, and raise the intestinal mass, proceeding in the following manner:—The animal is placed in the first position, and slightly inclined to the left side; make a crucial incision upon the inferior abdominal wall, or surround all this wall by a circular incision, taking care not to wound any part of the intestine; the whole mass of the viscera is then drawn out of the abdominal cavity and brought upon the table which supports the subject; do not allow any part of this mass to slip down upon the ground, and so avoid tearing either the intestine or the parts which the student desires to preserve intact in the abdominal cavity; afterwards cut the floating colon, at the point of its union with the rectum, and the duodenum, where it passes behind the great mesenteric artery; detach the base of the cæcum from the sublumber wall by the rupture of the cellular tissue which connects this organ with the right kidney and the pancreas; destroy the same cellular union which exists between the pancreas and the terminal extremity of the fourth part of the colon; separate the mesentery along with the vessels contained between its folds; the intestinal mass is thus at last expelled from the abdominal cavity, and a convenient preparation is made, not

only of the stomach, but also of the spleen, liver, pancreas, kidneys, ureters, &c. The following is the method of turning the stomach inside out, so as to study its internal surface, and to dissect its muscular coats :—Cut out the stomach, with about three inches of the œsophagus, and six inches of the duodenum, and then proceed to wash out the interior of the organ in the following manner,—introduce a quantity of water into the stomach by fixing the duodenum to the stop-cock of a cistern ; then with the right hand relax the stomach, holding firmly the duodenum with the left hand to prevent the escape of the liquid. The alimentary substances contained in the viscus are thus mixed with the water, and may be expelled by a little pressure made upon the stomach ; repeat this four or five times, thus completely washing the inner surface of the organ. To invert the stomach, making the external surface the internal, introduce through the duodenum a loop of iron-wire, passing out through the œsophagus ; pass through the loop a very strong waxed ligature, and then tie it securely round the œsophagus ; by pulling the iron-wire passed through the pylorus, the latter will be sufficiently dilated to permit the passage of the cardiac end, and the stomach will be completely inverted. By inflating it, the stomach may be easily restored to its normal form and disposition, with this difference, that the mucous surface is external, and the serous internal.

**THE INTESTINE.**—The study of the intestine must be made on a special preparation ; open the inferior wall of the abdomen to show the organs. But as the mass which constitutes it is heavy and difficult to move, proceed to expel the contents by a proceeding analogous to that described under “The Stomach.” A puncture is made in the cæcum, sufficient to permit the escape of the substances accumulated in this reservoir. Those accumulated in the colon are got rid of by an incision in the pelvic flexure, those in the rectum, through an opening made in the floating colon ; the small intestine is cut into three or four nearly equal parts. This operation having been completed, inflate the intestines so as to show their normal size ; and thus the general disposition of the intestinal mass may be studied with the greatest ease in the interior of the abdomen. It will also be well to take the whole intestine out of the body of the animal, and, placing it upon the table, isolate the different parts, study their succession, and gain a complete idea of their form.

### THE ORGANS OF CIRCULATION.

**STRUCTURE OF THE HEART.**—Before proceeding to the dissection of the muscular fibres of the heart, it is indispensable to boil this viscus in water for half or three-quarters of an hour.

**THE HEART.**—Place the animal in the second position; remove the sternal ribs, separating them from their cartilages; then dislocate the costo-vertebral articulations. This dissection permits the study of the situation and general disposition of the heart and of the pericardium. To examine with ease the reciprocal arrangement of these two organs, remove them from the thoracic cavity by detaching the sternal insertion of the pericardium.

**PREPARATION OF ARTERIES.**—The preparation of arteries consists of two successive operations—1. Injection; 2. Dissection.

**INJECTION OF ARTERIES.**—Injection is an operation consisting of the introduction into the interior of the vessels of a solidifiable substance, intended to give to their canals the volume and conformation which they present during life, when they are filled with blood. Lard mixed with lamp-black is the material usually employed. Another injection sometimes used consists of gelatine, mixed with a certain quantity of plaster of Paris; but this is little used in the French school. A copper or brass syringe and a nozzle, fitted with a stop-cock upon the extremity of the syringe, is necessary for pouring the injection into the arterial vessels.

The method of making a general injection is as follows:—The animal having been laid upon a table, the carotid artery is laid bare by means of an incision made in the jugular gutter. The vessel is opened longitudinally. A ligature is applied above the opening, and the nozzle is securely fixed in the artery, upon the cardiac side, by aid of a second ligature. The injection, prepared beforehand, is drawn into the syringe. The syringe is then carefully screwed upon the nozzle, and the piston is pushed steadily onwards, so as to make the injection pass into the arterial canals.

The following form useful injections:—

Lard, or Tallow,	.	.	.	9 parts.
Oil of Turpentine,	.	.	.	1 „
Colouring Matter,	.	.	.	2 „
Bees'-wax,	.	.	.	1 part.
Tallow,	.	.	.	8 „
Colouring Matter,	.	.	.	<i>ad. lib.</i>

Lamp-black, Indigo, and Prussian blue may be used for the veins; for the arteries, as vermilion is expensive, venetian red mixed with red lead is a good substitute.

To succeed well in this operation, attend carefully to the following precautions:—

Inject an animal which has been killed by bleeding, and before it is cold, and wash out the vessels with warm water.

2. Heat the injection to a degree of temperature which the finger can bear without pain. If it is colder, the lard solidifies too soon; if it is warmer, it may shrivel up the sigmoid valves, pass into the left ventricle, thence into the auricle and pulmonary veins, an accident which is also sometimes caused by pushing the piston of the syringe with too much force.

3. Avoid applying too much force to the piston.

4. Stop the injection when the arteries react, by their elasticity, upon the piston, so as to drive it backwards.

Instead of making the injection into the carotid, we may fix a long curved nozzle into the aortic trunk itself, after having made an opening into the left side of the chest, at the level of the heart, by cutting away two segments of the ribs, and by making an incision into the pericardium over the left ventricle, so as to introduce the nozzle directly into the aorta. This proceeding allows the injection to be as hot as possible, and gives sufficiently good results, because the injection then penetrates, if it be injected under favourable conditions, almost into the capillary vessels; and in some organs, forces the injection even into the veins.

But whichever method is followed, there are certain parts which cannot be reached by a general injection; thus a special operation must be performed to force the injection into the vessels of the extremities. After having separated them from the trunk, by sawing them through above the knee or the hock, they are allowed to remain for two hours in a bath of water, kept constantly at a temperature of from 60 to 70 degrees, or more, and then they are very easily injected through the posterior radial artery or the anterior tibial, or through any of the other arteries which present their open mouths upon the section of the limb. If we wish to make partial injections of other parts of the body, it may be found easier not to separate them completely from the trunk; but then the student should take the precaution of cutting off or tying the vessels which establish anastomotic communications between the arteries injected and those which he does not wish to inject. For example, if he wishes to inject the arteries of the head, it is sufficient to inject one of the two common carotids, having tied the other in the middle of the neck, and the two vertebral arteries in the interstice between the two portions of the scalenus muscle.

To inject the capillary system, recourse is had to other substances, and to a different method. The following may be used: varnish, alcohol, essence of turpentine, holding in suspension very fine colouring materials, gum arabic, dissolved and coloured by any soluble colouring matter, and colours ground in oil, or suspended in essence of turpentine.

It is evident that the pulmonary artery will not be reached by the general injection already described. Inject it directly by passing the injection into the right side of the heart, through the anterior vena cava, after having tied the posterior vena cava.

**DISSECTION OF ARTERIES.**—There are no general rules to be given for the dissection of arteries.

**INJECTION OF VEINS.**—It will make the study and dissection of the veins easier, to fill them with injection; but to do this, a different proceeding is followed from that described for arteries. In place of making the injection flow from the trunks towards the branches, as in arteries, *it must flow from the branches to the trunks* in the case of the veins, owing to the presence of the valves. Four injections are in general sufficient to fill the whole venous system in a satisfactory manner: the first is poured through the alveolar vein under the masseter muscle; the second into a digital vein of one or two fore-limbs, on the side of the foot, after having destroyed with a stylette the several valves which are sometimes found near the point of union of the roots of this vein, from the cardiac side; the third into a posterior digital vein; the fourth into an intestinal vein. If any important veins require to be studied after these four operations, they are separately injected.

### THE LYMPHATIC SYSTEM.

The lymphatic plexuses are studied after having being injected with mercury, a proceeding which may be very briefly described, as it is seldom done by those for whom this work is intended. The apparatus commonly used consists of a tube of glass, continued by a flexible tube, which carries at its lower end an iron stopcock and a fine cannula made of iron or glass. To use this apparatus, fill the tube with mercury and suspend it; grasp the cannula with the right hand, holding it parallel to the membrane which is to be injected, and push it into the superficial layer of this membrane. The extremity of the cannula is thus introduced into the middle of the meshes of the plexus, and of course wounds one of the small vessels which compose it; then turning the stopcock, permit the mercury to flow into the vessels through the puncture. In this way they may be perfectly filled. The lymphatic plexuses being always placed above sanguineous ones, always take the precaution of puncturing the membrane as superficially as possible, because if the point of the cannula penetrate too deeply, the mercury passes into the veins, and the operation is a failure.

The study of the branches and trunks of the lymphatics may also be facilitated by inflating them from their origin to their termination. If

well done, this proceeding, which was almost exclusively followed by the ancient anatomists, gives very satisfactory results. It is sufficient to demonstrate the texture of the glands.

**THE THORACIC DUCT.**—Ligature the jugular and brachial veins near their termination, as also the anterior vena cava about its middle; lay bare the thoracic duct by cutting the right ribs; open it near the pillars of the diaphragm, and pour into it two injections of lard, the one before and the other behind the incision. The first injection will fill the duct along with the venous reservoir, which is intercepted by the ligatures applied to the vessels, as already described; the second, since it is directed in the opposite direction to the valves, overcomes the resistance offered by them, and expands the canal of Pecquet and the chief branches which end in it. Another method is as follows:—One of the branches in the abdominal cavity may be selected, as, for example, one of those united to the colic arteries, near their origin, and the thoracic duct completely injected from its origin to its termination. But this operation requires more practical dexterity than the first, in order to reach the vessel into which the nozzle is to be inserted; and it is not at all easy to perform it upon fat animals.

## THE NERVOUS SYSTEM.

**THE BRAIN.**—To study the brain, it is first removed from the cranial cavity. This is done by two operations. The first consists of opening the cranium by removing its vault, using a saw, a chisel, and a hammer, after having first removed all the parts covering it. Then open the dura mater with the scissors, and expose the brain, which is to be removed by raising its posterior extremity, and cutting from behind forwards all the nerves issuing from its base, with the pituitary gland, as far forwards as the end of the olfactory lobes. This operation is quickly performed, but it does not permit of the preservation of the pituitary gland, which is strongly fixed in the sella turcica, an inconvenience avoided by employing the following method of opening the cranium at the base. After having separated the head from the trunk, remove the inferior maxilla, the tongue, the hyoid bone, and lay bare the osseous surface, cutting away all the soft parts. The head thus prepared is held by an assistant, the cranial vault being laid upon the table or a block of wood. The operator divides the zygomatic arches and the styloid processes of the occipital; then divides in succession the condyles of the same bone, the basilar process, the sphenoid, the palatines, the ethmoid; and returns to the lateral parts, which he cuts through successively from the occipital to the ethmoid. The brain having been thus sufficiently exposed, the dura

mater is set free as in the first operation, and raising it with the left hand, the adhesions by which it is yet fixed to the vault of the cranium, adhesions chiefly composed of the veins of the brain, which disgorge themselves into the sinuses of the dura mater, are divided by the scissors held in the right hand. Break down the adhesion in the ethmoidal fossa with the point of the scalpel, detach the olfactory lobes, and the mass of the brain is then set quite free. This proceeding is an operation more difficult than the first, but it has many advantages, preserving intact not only the pituitary gland, but also the ethmoidal lobes; and the ganglia of the cranial nerves are exposed as distinctly as the nerves themselves. Having thus described the means of removing the brain from its osseous cavity, it is enough to state here that in order to study its structure with advantage, it will be well to have two brains, hardened by soaking for a week or more in alcohol, or in water having a little nitric acid added to it (1 to 20), so as to contract the nervous substance, and make more apparent the outline of the cavities of the brain.

---

## No. II.

### ON A SUPERNUMERARY OBLIQUE MUSCLE OF THE EYEBALL.

BY THOMAS STRANGEWAYS, PROFESSOR OF VETERINARY  
ANATOMY, EDINBURGH.

*(Journal of Anatomy and Physiology, second series, No. II., May, 1868.)*

A FEW days ago, when dissecting the muscles of the eyeball of an ass, in the dissecting room of the Veterinary College, I was somewhat astonished at finding a small but well-defined muscle, situated between the superior and inferior oblique muscles. It originated by a delicate tendon from a minute depression, in the superior part of the orbital plate of the frontal bone, about midway between the origin of the inferior oblique and the loop or pulley through which the belly of the superior oblique passes. The tendon of origin was succeeded by a fusiform fleshy belly of about three lines in diameter, and about an inch in length, which passed obliquely upwards and outwards on the outer side of the external rectus. The belly, embedded in a quantity of adipose tissue, terminated in a thin, flat tendon, which, after running nearly parallel for a short distance with, and loosely attached by cellular

tissue to, the upper part of the belly of the superior oblique, became blended with the tendon of insertion of that muscle just as it passed under the tendon of insertion of the superior rectus.

As there are some slight differences between the arrangements of the oblique muscles of the eyeball of the Equidæ and those of Man, it may be necessary to point these out, so as to prevent any misunderstanding as to the position of this small oblique muscle.

The superior oblique muscle in the horse and ass is—*1st*, Relatively longer and larger than in man, and is fleshy for some distance after it has passed through the loop, which loop is situated at the base of the orbital process of the frontal bone; *2nd*, The muscle, after passing through the loop, extends almost directly outwards under the tendon of the superior rectus, to gain its insertion between the tendons of insertion of the superior and external recti. The point of insertion is thus not so near to the back of the eyeball as in man.

The inferior oblique, arising from the lachrymal fossa, is directed forwards and upwards, its belly running in the same direction as the reflected portion of the superior oblique, and becomes finally inserted between the tendons of insertion of the external and inferior recti, much lower down and also farther forwards than in man.

So far as my researches have gone, this small muscle has not hitherto been described, either in consequence of being an exceptional occurrence in this animal, or of having been overlooked. There can be no doubt, I think, of its being an accessory or check muscle of the superior oblique, placed there for the purpose of preventing the belly of that muscle becoming fixed in the loop through which it has to pass at such an acute angle, in the lower animals more especially.

Unfortunately, the other eyeball had been removed by one of the students, to whom the subject belonged, before I had commenced my dissections; but still, on searching within the orbit, I was enabled to find part of the belly and the tendon of origin of a similar muscle, which had precisely the same point of origin, and in all probability, a similar insertion.\*

---

\* (Since the above was published, Dr. Johnston has dissected the muscle in both eyes of two subjects.—1st Edition.)



## No. III.

ON A NON-STRIPED MUSCLE CONNECTED WITH THE  
ORBITAL PERIOSTEUM OF MAN AND MAMMALS.

BY WM. TURNER, M.B. (LOND.), F.R.S.E., PROFESSOR OF ANATOMY,  
UNIVERSITY OF EDINBURGH.

(*Natural History Review*, January, 1862.)

WHILST engaged in making a dissection, in the human subject, during the winter session of last year, of the superior maxillary, or second division of the fifth cranial nerve, my attention was attracted to a pale-reddish, soft mass, filling up the narrow chink of the sphenomaxillary fissure, and extending, from the sphenoidal fissure in the sphenoid bone to the infra-orbital canal in the superior maxillary bone. It was evidently connected to the superior (ocular) aspect of the periosteum of the orbit, and it was pierced by the orbital branch of the superior maxillary nerve, from which, as well as from the ascending branches of the sphenopalatine ganglion, it appeared to receive its supply of nerves. It completely shut off the superior maxillary nerve, with its infra-orbital continuation, from the cavity of the orbit.

Since the period of making the above observation, I have availed myself of several opportunities of examining the same region in other subjects, and have constantly observed appearances of a nature similar to those just described. The amount of the reddish mass, and the depth of its tint, varied slightly in different instances. Frequently, it was so pale as scarcely to attract attention, which may perhaps be the reason why it has so long been neglected by anatomists. When carefully examined with the naked eye, or, still better, with a single lens, it was seen to exhibit a fibrous appearance. A small portion snipped off with scissors, teased out with needles, and placed on the stage of the microscope, under a quarter-inch objective, was observed to be composed of pale, flattened, band-like fibres, having a faintly granular aspect, and presenting indications of elongated nuclei at intervals. From these characters I had little doubt that the structure in question consisted of the non-striped form of muscular fibre.

As considerable difficulty is always experienced in obtaining for examination the contents of the human orbit, in a perfectly fresh condition, I, in the next instance, proceeded to dissect the orbits of some of the more readily obtained mammals, with a view of ascertaining if a

similar structure existed in them. In the orbit of the sheep I have most satisfactorily observed appearances which have fully confirmed the opinion of the structure already expressed. The orbit of this animal differs from that of man in possessing much less perfect walls. As a consequence of this, the orbital membrane, or periosteum, is a structure of much importance, for it stretches across the floor of the orbit from its outer to its inner wall, extends backwards to the optic foramen, and completes the boundary of the cavity at the spot where the bony wall is wanting.

If the contents of the orbit be carefully removed, and the orbital membrane examined from above, it will be seen to be a well-defined structure distinctly fibrous, and in many places having an almost tendinous-like aspect. Intimately connected with, and forming an essential part of it, is a thin layer of a pale reddish substance, which extends across the greater part of the floor of the orbit, passing backwards to the optic foramen and sphenoidal fissure. In close contact with this structure, especially at the posterior part of the orbit, is a well-marked vascular network, sufficiently injected with blood to be distinctly visible. This vascular plexus constitutes a small rete mirabile, connected with the ophthalmic artery. By removing a small portion of the reddish mass, teasing it out with needles under water, and examining it with a quarter-inch objective, it may be seen to be composed for the most part of flat, pale, non-stripped fibres, collected together in bundles, having a faintly granular aspect, and exhibiting decided indications of nuclei in their interior. These bundles of flat fibres are mingled with ordinary fibrous tissue, both white and yellow, the latter becoming more distinct after the addition of acetic acid. The pale, non-stripped fibres have all the characters of the involuntary muscular fibre. Being desirous, however, of ascertaining if these fibres could be resolved into their constituent fibre-cells, I adopted the plan which has been recommended by *Reichert*, and macerated a portion of the orbital membrane for forty-eight hours in dilute hydro-chloric acid. I then found that, by the aid of a very slight dissection, the fibres readily resolve themselves into the elongated fusiform cells of which they were composed. In no tissue which I ever examined, consisting of the non-stripped muscle, have I succeeded in obtaining more beautiful and more perfect specimens of the contractile fibre-cell than in this muscle of the orbital membrane. The fusiform shape of the cells, their size, and the elongated rod-like nucleus in the centre of each cell, gave to the texture a most characteristic appearance. I may also mention, that when the orbital muscle in the sheep was examined without the addition of any re-agent, besides distilled water, a number of elongated rod-like nuclei were always met

with, lying free in the water surrounding the preparation, which had evidently been loosened and detached during the dissection with the needles. These nuclei corresponded in their characters to those met with in the interior of the fibro-cells. The characters which I have now enumerated render the muscular nature of the reddish texture connected with the orbital membrane sufficiently clear.

On referring to the authorities who have written on the structure of the orbital membrane, I find that the following opinions have been expressed concerning it:—

*Bendz*, in a paper "On the Orbital Membrane in the Domestic Mammals," describes it as distinctly fibrous, but possessing a considerable quantity of a yellowish tissue, which he considers to be elastic, interpolated with it. He regards the opinion, which had been previously advanced by *Gurli*, that the tissue was muscular, to be erroneous. *Siannius* states that in those animals, in which the bony wall of the orbit is incomplete, the separation between the orbital cavity and the temporal fossa is mostly effected by a fibrous membrane, containing also abundant elastic tissue. He states that *Rudolphi* regarded these elastic fibres to be muscular in bears, and that *Meckel* described a muscle in the orbital membrane of *Ornithorynchus*. *Chauveau* speaks of the fibrous membrane which completes the cavity of the orbit as entirely composed of white inextensible fibres. *Gurli* considers it to be a strong fibrous membrane, with yellow elastic fibres interpolated. *H. Müller*, in a very brief communication, states that he has found flat muscular fibres in the inferior orbital fissure in man, and corresponding structures connected to the *membrana orbitalis* of mammalia.

It was supposed by those who held that the *membrana orbitalis* was a highly elastic and not a muscular structure, that it was through its elastic recoil that the eyeball was reprotuded in those animals which retracted the ball through the contraction of a retractor muscle. *H. Müller*, again, who speaks more positively than any who have preceded him, not only of the existence of a muscle, but also of the kind of fibre of which it is composed, considers that it antagonises those muscles which retract the eyeball into the socket, and that thus, the reprotusion of the globe is produced, not by a mere elastic recoil but by a muscular contraction.

If this hypothesis be correct, an arrangement exists in this locality, which is certainly to be regarded as an unusual one—viz., an involuntary muscle acting as a direct antagonist to a voluntary muscle. Whether the hypothesis be correct or not, I am disposed to consider that the muscle has some especial relation to the vascular arrangements in the orbit. Its extension backwards to the foramina through which the

orbital vessels proceed, and with which it is in immediate relation, and the very abundant vascular network found in connection with it, point, I think, to some special relation between the muscle and the vessels, a relation which is not at all inconsistent with what is known of the function of non-stripped muscle in other localities.

\*            \*            \*            \*            \*            \*

*Note.*—Since the above paper was in type, my attention has been directed, by Professor Huxley, to a communication by H. Müller, dated 15th Dec. 1860, entitled “On the Influence of the Sympathetic upon some Muscles, and on the extensive occurrence of Unstripped Muscles in the Skin in the Mammalia.”

As this paper throws some additional light upon the probable action of the orbital muscle, I append a short abstract of it:—

H. Müller, after referring to the many puzzling questions which have arisen respecting the function of the sympathetic nerve, and its relations to the muscles supplied by it, proceeds to ask two questions—

1st, Whether, and which, unstripped muscles are supplied by other nerves than the sympathetic?

2nd, Whether, and which, transversely-stripped muscles are under the influence of the sympathetic?

In answer to the first, the action of the oculo-motor nerve upon the unstripped fibres of the iris cannot be doubted: the vagus also acts upon unstripped muscles, and the experiments of Schiff have shown that the greater part of the vascular nerves are not connected with the sympathetic.

The second question may be most effectively answered by considering the effect produced upon the eyeball by division or irritation of the cervical sympathetic. Müller, for this purpose, refers to the experiments of Bernard, R. Wagner, and Brown-Sequard; the general tendency of which is to show, that division of the cervical sympathetic produces narrowing of the palpebral fissure, retraction of the bulb, projection of the nictitating membrane and narrowing of the anterior nares and the mouth. Irritation of the nerve by galvanisation, on the other hand, produces increase of the opening of the lids, projection of the bulb retraction of the nictitating membrane, relaxation of several facial muscles. Respecting the causes which produced these changes there was some difference of opinion. R. Wagner could scarcely conceive that any force, save the contraction of the two obliqui, could produce projection of the eyeball, and yet he asks, “How could these transversely-stripped muscles receive excito-motory fibres from the sympathetic?” Brown-Sequard, again, considered that retraction of the bulb, after section of the nerve, was produced by the active contraction of the retractor and recti, and

that its projection by subsequent irritation was a reposition. Schiff regarded the projection of the bulb as due to the action of the obliqui: the movements of the lids he considered to be passive, and due to those of the bulb.

Remak, on the other hand, believed that the narrowing of the palpebral fissure was due to a relaxation of the levator palpebræ superioris, accompanied by a spasmodic contraction of the orbicularis. Moreover, he conceived that the sympathetic acted upon the voluntary muscles of the lids about the eye.

Müller considers that it is now no longer necessary to discuss the various probabilities respecting the influence of the sympathetic upon the voluntary muscles of the eye, as a complete series of unstriped muscles have now been observed, which will serve as a foundation for explaining the movements in question.

These muscles consist of three divisions—

*1st*, In the orbital cavity of mammals, a membrane (*membrana orbitalis*), consisting of unstriped muscles with elastic tendons, exists, which, by irritation of the cervical sympathetic, projects the contents of the orbit, especially the bulb, forwards. Retraction is produced by the transversely-striped retractor. In man, the orbital muscle is much reduced in size, and the retractor is wanting, so that a distinct projection of the bulb does not follow irritation of the sympathetic, as Wagner and H. Müller himself have observed.

*2nd*, The projection of the nictitating membrane in mammals is mostly due to the retractor bulbi under the influence of the N. abducens. Its withdrawal depends on some unstriped muscles which are under the influence of the sympathetic. In hares, however, the withdrawal is due to a transversely-striped muscle, which is not supplied by the sympathetic but by the oculo-motorius. In man, the lid and its muscles are rudimentary.

*3rd*, The upper and lower lid possess in man, and in very many mammals, unstriped muscles, which have the power of drawing them back. They are more feeble in the upper than the lower lid, so that by irritation of the sympathetic the latter is drawn back in a more marked manner than the former. Narrowing of the palpebral fissure, after section of the cervical sympathetic, depends upon relaxation of these muscles. Yet recession of the eyeball may depend upon relaxation of the orbital muscle. Müller, then, concludes that the movements occasioned by experimenting on the cervical sympathetic are not such as to entitle us to infer an influence of that nerve upon voluntary striped muscle. He also considers that the movements about the nose and mouth, said by Bernard to be produced by section of the sympathetic,

if they do take place, are owing to the presence of unstriped cutaneous muscles.

Müller next inquires into the existence of unstriped muscles in the skin of the ear. He has occasionally found, on galvanising the cervical sympathetic in cats, that a movement of the hairs growing upon the skin at the entrance of the concha has taken place. This experiment has, however, frequently failed both in cats and other animals. A careful examination of the skin of the part did not give any indications of unstriped muscles, but very distinct muscles were seen connected to the hair follicles. He considers these experiments of interest, as they appear to indicate whence the muscles of the hair follicles receive their nerves. Owing to the movement of the hairs being limited to a very small locality, during the irritation of the sympathetic, one must suppose that only a very small part of the unstriped muscular apparatus of the skin of the cat can be regulated by the cervical sympathetic.

---

# INDEX.

- ABDOMEN**, 300.  
     regions of, 300.  
**Abdominal rings**, 203.  
     tunic, 200.  
**Abducens nerve**, 497.  
**Accessory organs of digestion**, 312.  
     in Carnivora, 382.  
     in Ruminants, 373.
- Acervulus cerebri**, 484.  
**Acetabulum**, 87.  
**Adipose tissue**, 123.  
**Æsthesiology**, 525.  
     comparative, 552.
- Air cells**, 339.  
**Albinos in Rodentia**, 553.  
**Alimentary canal**, 275.  
**Allantois**, 557.  
**Alula**, 554.  
**Alveoli canine**, 58, 63.  
     incisor, 58, 63.  
     molar, 57, 63.
- Amnion**, 557.  
**Amphiarthrosis**, 127.  
**Amphioxus**, 4.  
**Ampullæ**, 530.  
**Analogy**, 6.  
**Anapophysis**, 112.  
**Anatomy**, animal, 1.  
     comparative, 1.  
     descriptive, 6.  
     distinguished from physiology, 2.  
     divisions of, 6.  
     minute, 2.  
     morbid, 2.  
     practical, 2.  
     special, 1.  
     surgical, 2.  
     transcendental, 1.  
     veterinary, 2.
- Andersch's ganglion**, 499.  
**Angiology**, 387.  
     comparative, 458.
- Annular cartilage**, 526.  
     ligaments, 124.
- Anterior aorta**, 418.  
     in Omnivora, 461.  
     in Ruminants, 459.  
     nares, 42.  
     vena cava, 442.
- Anus**, 311.  
**Aorta anterior**, 418.  
     common, 401.  
     in aves, 463.  
     posterior, 402.
- Aponeurotic tendons and fascia**, 159.  
**Apophysis**, 16.  
**Appendages of the eye**, 538.  
**Appendicular joints**, 136.  
     in Carnivora, 153.  
     in Omnivora, 153.  
     in Ruminantia, 152.
- Appendicular skeleton**, 65.  
     of Dog, 112.  
     of Hog, 108.  
     of Rodent, 115.  
     of Ruminant, 103.
- Appendix I.**, 565.  
     II., 575.  
     III., 577.
- Aqueduct**, 14.  
     of Sylvius, 483.  
     of Fallopius, 51.  
     of vestibule, 51, 531.
- Aqueous humour**, 536.  
**Arachnoid membrane**, 469.
- Arbor vitæ**, 476.  
     uterinus, 361.
- Arch**, crural, 202.  
     hæmal, 23.  
     neural, 21.  
     palatine, 38, 60.  
     pectoral, 66.  
     pelvic, 83.  
     radio-ulnar, 70.  
     tibial, 93.  
     zygomatic, 40.
- Arcuate ligaments**, 209.  
**Arnold's ganglion**, 516.
- Arrangement of fasciæ**, 252.
- Arteries**, 398.  
     structure of, 299.  
     angular of eye, 427.  
     anterior abdominal, 420.  
     anterior aorta, 418.  
     anterior auricular, 430.  
     anterior cerebellar, 486.  
     anterior cerebral, 487.  
     anterior choroid, 488.  
     anterior communicating, 488.  
     anterior deep temporal, 432.  
     anterior radial, 422.  
     anterior tibial, 416.  
     arteria centralis retinae, 432, 536.  
     arteria humeralis profunda, 422.  
     arteria pedis perforans, 416.  
     arteria profunda femoris, 414.  
     arteria superficialis femoris, 414.  
     asternal, 420.  
     basilar, 486.  
     brachial, 418.  
     brachio-cephalic, 418, 463.  
     broncho-oesophageal, 404.  
     buccal, 433.  
     cardiac, 401.  
     carotid, 424.  
     carpal arch, inferior, 423.  
     carpal arch, superior, 422.  
     centralis retinae, 432.  
     cephalic, 424.  
     cerebral, 486.  
     cerebro-spinal, 426, 486.  
     ciliary, 432.

- Arteries, circle of Willis, 487.  
 circulus arteriosus, 418.  
 circumflex, 418.  
 circumflex, illi, 412.  
 coecygeal, 411.  
 coeliac axis, 404.  
 colic, 407.  
 common aorta, 401.  
 common carotid, 418, 424.  
 coraco-radial, 422.  
 coronary, 401.  
 cubital, or ulnar, 422.  
 digital, 417, 424.  
 dorsal, 419.  
 dorsal nasal, 427.  
 dorsal of penis, 413.  
 duodenal, 406.  
 epigastric, 412.  
 ext-renal carotid, 427.  
 external iliac, 411.  
 external thoracic, 421.  
 external plantar, 415.  
 external pudic, 413.  
 femoral, 412.  
 femoro-popliteal, 414.  
 gastric, 404.  
 gastro-epiploic, 405, 406.  
 glosso-facial, 427.  
 gluteal, 411.  
 great meningeal, 431.  
 great mesenteric, 407.  
 great matatarsal, 416.  
 hæmorrhoidal, 407.  
 hepatic, 405.  
 humeral, 422.  
 humeralis profunda, 422.  
 hypogastric, 559.  
 iliaco-femoral, 411.  
 ilio-lumbar, 411.  
 ilio-cæcal, 411.  
 inferior cervical, 420.  
 inferior circumflex, 418.  
 inferior dental, 431.  
 inferior labial or coronary, 429.  
 intercostal, 403.  
 internal carotid, 426, 427.  
 internal iliac, 409.  
 internal maxillary, 431.  
 internal plantar, 415.  
 internal pudic, 410.  
 internal thoracic, 420.  
 interosseous of fore-arm, 423.  
 interosseous palmars, 424.  
 interosseous plantars, 415.  
 ischiatic, 411.  
 lachrymal, 432.  
 lateral laminal, 417.  
 large metacarpal, 424.  
 lateral nasal, 427, 432.  
 lateral sacral, 411.  
 lesser mesenteric, 407.  
 lingual, 428.  
 lumbar, 403.  
 mammary, 413.  
 masseter, 430.  
 mastoid, 426.  
 maxillo-muscular, 429.  
 meningeal, 432.  
 middle cerebral, 488.  
 middle sacral, 404.  
 middle spinal, 426, 486.  
 musculo-occipital, 426.  
 nutrient humeral, 422.  
 nutrient radial, 423.  
 nutrient scapular, 421.  
 obturator, 411.  
 occipital, 425.  
 of the bulb, 410.  
 of the cord, 409.  
 of fore-limb Carnivora, 462.  
 of the Frog, 417.  
 ophthalmic, 432.
- Arteries, orbital, 433.  
 palatine, 433.  
 palato-labial, 433.  
 perforating pedal, 416.  
 peroneal, 416.  
 perpendicular, 417.  
 pharyngeal or ascending pharyngeal, 428.  
 phrenic, 403.  
 plantar, 415.  
 plantar unguinal, 418.  
 popliteal, 414.  
 posterior abdominal, 412.  
 posterior aorta, 402.  
 posterior auricular, 430.  
 posterior cerebellar, 486.  
 posterior cerebral, 486.  
 posterior circumflex, 421.  
 posterior communicating, 487.  
 posterior deep temporal, 431.  
 posterior masseter, 430.  
 posterior radial, 423.  
 posterior tibial, 415.  
 prehumeral, 422.  
 prescapular, 421.  
 preplantar unguinal, 417.  
 prepubian, 412.  
 prevertebral, 426.  
 profunda femoris, 414.  
 pterygoid-fascicular, 431.  
 pterygoidean, 430.  
 pulmonary, 400.  
 pyloric, 406.  
 radio-palmar, 423.  
 ramus anastomoticus, 426.  
 ranine, 428.  
 recurrent radial, 423.  
 renal, 408.  
 saphenic, 414.  
 scapulo-humeral, 421.  
 sesamoidæan arch, 416.  
 small metacarpal, 423.  
 small muscular, 414.  
 small testicular, 409.  
 solar, 418.  
 spermatic, 408.  
 spheno-spinal, 431.  
 spheno-palatine, 433.  
 spiral, 422.  
 splenic, 405.  
 staphyline, 433.  
 subcutaneous abdominal, 413.  
 subcostal, 419.  
 sublingual, 428.  
 submaxillary, 427.  
 subscapular, 421.  
 subzygomatic, 430.  
 superficial temporal, 430.  
 superficialis femoris, 414.  
 superior cervical, 420.  
 superior dental, 433.  
 superior labial or coronary, 429.  
 supraorbital, 432.  
 thyroid, 425.  
 thyro-laryngeal, 425.  
 transverse, 417.  
 transverse facial, 430.  
 tympanic, 431.  
 ulnar, 422.  
 umbilical, 409, 559.  
 uterine, 409.  
 utero-ovarian, 409.  
 vaginal, 411.  
 vertebral, 420.  
 vesico-prostatic, 410.
- Arthrology, 120.  
 comparative, 151.
- Articular cartilage, 121.  
 depressions, 15.  
 eminences, 14.  
 facet, 15.  
 head, 14.



- Articulations, atlo-axoid, 131.**  
 chondro-costal, 133.  
 coccygeal 132.  
 commor vertebral, 129.  
 costo-s'ternal 133.  
 costo-vertebral 132.  
 distal inter-phalangeal, 142.  
 femoro-pe'vic 145.  
 femoro-tibial, 146.  
 humero-radial 136.  
 ischio-pubic (symphysis), 145.  
 n.etacarpal 140.  
 metacarpo-phalangeal, 140.  
 occipito-atloid 131.  
 of appendicular skeleton, 136.  
 of axial skeleton, 129.  
 of axial skeleton in Rumi-  
 nantia, 151.  
 of carpus, 137.  
 of hyoid series, 135.  
 of pectoral limb, 136.  
 of pelvic limb, 143.  
 of skull, 134.  
 pectoral limb in Ruminantia,  
 152.  
 pelvic limb in Ruminantia,  
 152.  
 proximal interphalangeal, 142.  
 radio-ulnar, 137.  
 sacro-iliac, 143.  
 sacro-lumbar, 132.  
 scapulo-humeral, 136.  
 special vertebral, 131.  
 sternal, 134.  
 tarsal, 149.  
 temporo-maxillary, 134.  
 tibio-fibular, 148.  
 thoracic, 132.
- Astragalus, 93.**  
**Atlas, 26.**  
**Atlo-axoid articulation, 131.**  
 space, 28.
- Auditory bulla, 51.**  
 ossicles, 527.  
 ossicles in Aves, 554.
- Aves, 5.**  
 skeleton of, 115.
- Axial joints in Carnivora, 153.**  
 Omnivora, 153.  
 Ruminantia, 151.
- Axial Skeleton, 21.**  
 articulations of, 129.  
 Carnivora, 109.  
 Omnivora, 105.  
 Rodentia, 114.  
 Ruminantia, 98.
- Axis, 27.**
- BARBS, 554.**  
 Bars of the hoof, 545.  
 of the mouth, 63.
- Base of the brain, 477.
- Basement membrane, 272.
- Bastard wing, 554.
- Bellini, tubes of, 343.
- Bicipital groove, 69.
- Bilateral symmetry, 19.
- Bile, 317.
- Biology, 1.
- Birds, characteristics of, 5.  
 eye in, 554.  
 muscles, 269.  
 pectoral arch, 117.  
 sketeton in, 115.
- Bladder, 344.
- Blastoderm, 556.
- Blood, 387.  
 in Aves, 461.
- Blood-Vascular System, 387.
- Bones, canaliculi of, 10.  
 cannon, 77.  
 cardiac, 105.
- Bones, classes of, 12.  
 coffin, 81.  
 contents of, 12.  
 covering of, 11.  
 cranial, 45.  
 cubo-cuceiform, 104.  
 cuneiform of tarsus, 95, 96, 97.  
 density of, 8.  
 development of, 15.  
 diploë of, 11.  
 ethmoid, 54.  
 facial, 54.  
 flat, 13.  
 frontal, 48.  
 hyoid, 64.  
 inferior maxillary, 62.  
 innominate, 84.  
 irregular, 13.  
 lachrymal, 59.  
 lacunæ of, 9.  
 large metacarpal, 77.  
 large pastern, 80.  
 large sesamoid, 80.  
 long, 12.  
 lymphatics in, 12.  
 malar, 58.  
 malleolar, 104.  
 metacarpal, 77.  
 metatarsal, 97.  
 minute structure of, 9.  
 nasal, 54.  
 navicular, 83.  
 neck of, 15.  
 nutrient foramina of, 12.  
 occipital, 45.  
 of carpus, 72.  
 of digit, 79.  
 of hind limb, 88.  
 of penis in Carnivora, 114.  
 of Ruminant skull, 98.  
 of tarsus, 93.  
 palatine, 59.  
 parietal, 47.  
 petrosal, 50.  
 pisiform, 77.  
 pneumatic, 119.  
 premaxillary, 57.  
 pterygoid, 60.  
 quadrate, 117.  
 quadrato-jugal, 117.  
 small pastern, 81.  
 small sesamoid, 83.  
 sphenoid, 52.  
 splint, 78.  
 squamosal, 49.  
 stifle, 91.  
 structure of, 7.  
 superior maxillary, 56.  
 surfaces of, 14.  
 temporal, 49.  
 turbinated, 61.  
 unciform, 76.  
 vessels of, 12.  
 Vomer, 61.  
 Wormian, 48.
- Bowman, capsules of, 342.
- Brachial arteries, branches of, 419.
- Brain, 473.**  
 arterial circulation of, 486.  
 in Aves, 524.  
 in Carnivora, 523.  
 in Omnivora, 523.  
 in Rodentia, 524.  
 in Ruminants, 522.  
 meninges of, 469.  
 removal of, 574.  
 sand, 484.  
 venous circulation of, 488.
- Branches of jugular vein, 447.
- Broad ligaments of uterus, 323.  
 ligament of bladder, 345.  
 of coffin-joint, 143.

- Broad ligament of digit, 141.  
of liver, 314.
- Bronchial tubes, 335.
- Bronchi, 335.
- Bursæ mucosæ, 125.  
synovial, 125.
- CÆCUM, 307.
- Calamus, 554.  
scriptorius, 476.
- Calcaneo-cuboid ligament, 150.
- Calcaneum, 94.
- Calvarium, 37.
- Canal, 14.  
alimentary, 275.  
Haversian, 9.  
inguinal, 203.  
lachrymal, 56, 59.  
neural, 3, 21.  
of Gärtner, 376.  
of Petit, 536.
- Canaliculi of bone, 10.
- Cancellated tissue, 10.
- Cannon bone, 77.
- Canthi, 538.
- Capillaries, 400.
- Capsular ligaments, 124.
- Capsule of the lens, 537.
- Cardiac bones, 105, 458.
- Cariniform cartilage, 36.
- Carnivora, bone of penis, 114.  
characteristics of, 5.  
clavicle in, 113.  
joints in, 153.  
skeleton in, 109.  
tapetum lucidum in, 553.
- Carotid artery, 424.  
in Carnivora, 462.  
in Omnivora, 461.
- Carpal cuneiform bone, 74.  
joint, 137  
bones, 72.
- Cartilage, 120.  
articular, 121.  
cariniform, 36.  
cellular, 122.  
ensiform, 86.  
fibro-, 121.  
glenoid, 142.  
hyaline, 121.  
lateral, 549.  
of ear, 526.  
semilunar, 147.  
tarsal, 539.  
temporary, 15.  
xiphoid, 36.
- Carunculæ myrtiformes, 362.  
lachrymales, 540.
- "Cat hairs," 544.
- Cauda equina, 471.
- Cavernous sinuses, 489.
- Cavicornia, 4.
- Cavities, cotyloid, 15.  
glenoid, 15.  
in the skull, 42.
- Cells, air, 339.  
giant, 12.  
osteoblastic, 17.
- Cellular cartilage, 122.
- Centrum ovale majus and minus, 479.
- Cere, 555.
- Cerebellum, 475.
- Cerebral commissures, 483.  
convolutions, 477.  
lobes, 477.  
sulci, 477.
- Cerebro-spinal system, 468.
- Cerebrum, 476.
- Cereminous glands, 526.
- Cervical fascia, 253.  
nerves, 503.  
vertebræ, general features, 23.
- Cervical vertebræ, special, 26.  
the two last, 28.
- Chambers of the eye, 536.
- Characteristics of Aves, 5.  
of Carnivora, 5.  
of Equidæ, 4.  
of Omnivora, 5.  
of Rodentia, 5.  
of Ruminantia, 5.  
of vertebrata, 3.
- "Châtaignes," 543.
- Check ligament, 227, 228.
- Cheeks, 276.
- Chondro-costal articulation, 133.
- Chorion, 557.
- Choroid coat, 534.  
plexus, 482.
- Chyle, 451.
- Ciliary muscle, 534.  
processes, 535.  
zone, 536.
- Ciliated epithelium, 271.
- Circle of Willis, 487.
- Circulation, 397.  
in foetus, 559.  
in lower animals, 463.
- Classes of bones, 12.  
of joints, 126.
- Classification of muscles, 161.
- Clavicle, 66.  
in Carnivora, 113.  
in Aves, 117.
- Cleft of Frog, 547.
- Clitoris, 362.
- Cloaca, 384.
- Coccygeal articulations, 132.  
nerves, 485.  
vertebræ, 32.
- Coccyx, 32.
- Cochlea, 530.
- Cœliac axis in Carnivora, 461.  
in Ruminants, 458.
- Coffin bone, 81.  
joint, 142.
- Colon, floating, 310.  
great, 308.
- Column vertebral, 21.
- Columnar epithelium, 271.
- Commissures of the cord, 472.  
of Frog, 548.  
optic, 478, 492.
- Common aorta, 401.  
carpal ligaments, 139.  
tarsal ligaments, 149.  
vertebral articulations, 129.  
vertebral ligaments, 129.
- Compact tissue, 9.
- Comparative Anatomy, 1.  
Æsthesiology—Aves, 554.  
Carnivora, 553.  
Omnivora, 552.  
Rodentia, 553.  
Ruminantia, 552.
- Angiology—Aves, 462.  
Carnivora, 461.  
lower animals, 463.  
Omnivora, 460.  
Rodentia, 462.  
Ruminantia, 458.
- Anthrology—Carnivora, 153.  
Omnivora, 153.  
Ruminantia, 151.
- Myology—Aves, 269.  
Carnivora, 265.  
Omnivora, 263.  
Rodentia, 268.  
Ruminantia, 260.
- Neurology—Aves, 524.  
Carnivora, 523.  
Omnivora, 523.  
Rodentia, 524.  
Ruminantia, 522.

- Comparative Osteology—Aves, 115.  
 Carnivora, 109.  
 Omnivora, 105.  
 Rodentia, 114.  
 Ruminantia, 98.  
 Splanchnology—Aves, 384.  
 Carnivora, 380.  
 Omnivora, 377.  
 Rodentia, 383.  
 Ruminantia, 365.
- Concha, 525.  
 Conchal cartilage, 526.  
 Conduit, lachrymal, 56.  
 parieto-temporal, 42, 50.  
 Vidian, 52, 60.  
 Condyles, 14.  
 Cofluent, parieto-temporal, 489.  
 subphenoidal, 489.  
 Conjunctiva, 539.  
 Connective tissue, 122.  
 Contents of bone, 12.  
 Conus medullaris, 471.  
 Coracoid apophysis, 66.  
 Corium, 542.  
 Cornea, 533.  
 Corona glandis, 355.  
 tubulorum, 306.  
 Coronary arteries, 401.  
 band, 551.  
 Coronoid process, 63.  
 Corpora, geniculata, 483.  
 nigra, 535.  
 quadrigemina, 484.  
 Corpus albicans, 478.  
 callosum, 479.  
 fimbriatum, 481.  
 Highmorianum, 349.  
 luteum, 358.  
 striatum, 481.  
 Costo-sternal articulation, 133.  
 Costo-vertebral articulation, 132.  
 Cotyloid cavity, 15.  
 notch, 87.  
 Covering of Bone, 11.  
 "Cow-kicks," 152.  
 Cowper's glands, 352.  
 Cranial bones, 45.  
 nerves, 490.  
 Cranium, 37, 42.  
 Crest, 14.  
 Cribriform plates, 54.  
 Crista galli process, 54.  
 Crura cerebri, 477.  
 of diaphragm, 208.  
 penis, 354.  
 Crural aponeurosis, 202.  
 arch, 202.  
 Crust, 546.  
 Crusta petrosa, 290.  
 Crystalline lens, 537.  
 Cubo-cuneiform bone, 104.  
 Cuboid bone, 95.  
 Cuneiform bones, 95, 96, 97.  
 bone of carpus, 74.  
 bones of hog, 109.  
 Cuticle, 541.  
 Cutigeral groove, 545.
- DEEP FASCIAE, 252.  
 veins of arm, 445.  
 Deltoid ridge, 68.  
 Density of bone, 8.  
 Dental formulæ, 294.  
 Dentata, 27.  
 Dentine, 289.  
 Dentition, 288.  
 in Carnivora, 380.  
 in Hog, 377.  
 in Rodentia, 383.  
 in Ruminant, 366.  
 Depressions, articular, 15.  
 non-articular, 14.
- Dermis, 542.  
 Descriptive anatomy, 6.  
 Development of bone, 15.  
 of fœtus, 561.  
 of teeth, 295.  
 of ulna, 72, 104.
- Diaphragm, 208.  
 Diaphysis, 16.  
 Diarthrosis, 127.  
 Diastema, 38, 57, 63.  
 Digit, bones of, 79.  
 Digestive system, 275.  
 in Aves, 384.  
 in Carnivora, 380.  
 in Omnivora, 377.  
 in Rodentia, 383.  
 in Ruminant, 365.
- Diploë of bone, 11.  
 Dissection, general directions for, 565.  
 of articulations and ligaments, 565.  
 of lymphatic system, 573.  
 of muscles, 566.  
 of nervous system, 574.  
 of organs of digestion, 568.  
 of organs of circulation, 570.
- Distal, 20.  
 phalanx, 81.  
 Division of skeleton, 20.  
 of skull, 37.  
 of sphenoid bone, 52.  
 of anatomy, 1.  
 Domesticated Aves, 5.  
 Mammals, 4.
- Dorsal nerves, 505.  
 vertebræ, 28.  
 Dorso-lumbar fascia, 253.  
 Duct, hepatic, 317.  
 of Bartholini, 366.  
 of Nuckias, 380.  
 of Rivinus, 287.  
 of Steno, 286.  
 of Warton, 287.  
 of Wirsung, 318.  
 thoracic, 451.  
 Ductus ad nasum, 541.  
 arteriosus, 401, 559.  
 choledochus, 317.  
 cochlearis, 531.  
 communis, 317.  
 lactiferus, 364.  
 lymphaticus dexter, 458.  
 pancreaticus minor, 319.  
 reuniens, 531.
- Duodenum, 304.
- EAR, 525.  
 Ejaculatory ducts, 351.  
 Elbow joint, 136.  
 Embryo, 556.  
 Embryogenic tissue, 556.  
 Embryology, 2, 556.  
 Eminence of Vater, 317.  
 Eminences, articular, 14.  
 ilio-pectineal, 85.  
 non-articular, 14.
- Enamel, 290.  
 Encephalic circulation, 485.  
 Ecephalon, 473.  
 Endocardium, 396.  
 Endolymph, 531.  
 Endoskeleton, 17.  
 Endosteum, 11.  
 Endothelium, 271.  
 Ensiform cartilage, 36.  
 Epidermis, 541.  
 Epididymis, 350.  
 Epiphysis, 16.  
 Epithelium, 270.  
 Equidæ, characteristics of the, 4.  
 Erectile tissue, 354.  
 Ethmoid bone, 54.

- Ethmoidal sinus, 45.  
Eustachian tubes, 528.  
    openings for, 51.
- Exoskeleton, 17.
- External ear, 525.  
    jugular vein, Rodents, 462.
- Eye, 532.  
    appendages of, 538.  
    in Aves, 554.
- FABELLÆ in Carnivora, 113.  
    Rodentia, 115.
- Facet, articular, 15.
- Facial bones, 54.
- Fallopian tubes, 358.
- False vertebrae, 23.
- Falx cerebelli, 470.  
    cerebri, 470.
- Fascia, 159.  
    arrangement of, 252.  
    crural, 202.  
    deep, 252.  
    deep abdominal, 253.  
    inguinal, 347.  
    of the anterior limb, 254.  
    of external oblique, 202.  
    of the head, 253.  
    of the posterior limb, 255.  
    of the trunk, 253.  
    perineal, 356.  
    plantar, 228.
- Fat, 123.
- Feathers, anatomy of, 554.  
    classification of, 554.
- Felidæ, retractor ligament of claw, 267.
- Female genital organs, 357.  
    in Ruminants, 376.
- Female pelvis, 88.
- Femur, 89.
- Ferrein, tubes of, 343.
- Fetlock joint, 140.
- Fibro-cartilage, yellow, 122.  
    varieties of, 121.
- Fibula, 93.
- Fifth ventricle, 481.
- Fissures, 15.  
    of Sylvius, 477.  
    of the cord, 472.
- Flat bones, 13.
- Fœtus, 556.  
    circulation in, 559.
- Foot, 544.  
    circulation of, 417, 439.  
    soft structures of, 549.
- Foramen, 14.  
    aortic (hiatus), 209.  
    cæcum, 474.  
    condyloid, 46.  
    dental, 57.  
    dextrum, 209.  
    Eustachian, 51.  
    external auditory (meatus), 51.  
    incisivum, 58.  
    inferior dental, 63.  
    infra-orbital, 56.  
    internal auditory (meatus), 50.  
    internal orbital, 52.  
    lacerum basis cranii, 40.  
    lacerum orbitale, 53.  
    lachrymal (conduit), 56.  
    magnum, 45.  
    mental, 63.  
    obturator, 87.  
    of Fallopius (aqueduct), 51.  
    of Monro, 481.  
    of the vestibule (aqueduct), 51.  
    optic, 52.  
    palatine, 56, 60.  
    parieto-temporal (conduit), 42,  
    50.  
    patheticum, 53.  
    plantar, 82.
- Foramen, preplantar, 82.  
    pterygoid, 30, 52.  
    rotundum, 53.  
    sinistrum, 209.  
    spheno-palatine, 57, 60.  
    stylo-mastoid, 51.  
    styloid, 51.  
    subspheonoidal, 39, 52.  
    supra-orbital, 48.  
    Vidian (canal), 52, 60.
- Fore-arm, bones of, 70.
- Fore-limb, bones of, 66.
- Forms of uterus in mammalia, 384.
- Fornix, 480.
- Fossa, 14.  
    cavernous, 53.  
    lachrymal, 59.  
    nasal, 44.  
    navicularis, 353, 362.  
    orbital, 41.  
    sphenoidal, 45.  
    supracondyloid, 89.  
    temporal, 41.
- Fourth ventricle, 476.
- Frog, 547.  
    band, 548.  
    sensitive, 550.
- Frontal bone, 48.  
    sinus, 44.
- Fundus acetabuli, 87.
- Funicular ligaments, 124.  
    tendons, 159.
- GANGLIA, Andersch's, 499.  
    Gasserian, 493.  
    genicular, 498.  
    guttural, 516.  
    inferior cervical, 518.  
    jugular, 500.  
    lenticular, 515.  
    Meckel's, 516.  
    of spinal nerves, 503.  
    otic, 516.  
    petrosal, 499.  
    semilunar, 520.  
    superior cervical, 516.  
    sympathetic, 515.
- Gärtner, canals of, 376.
- General view of the skull, 37.
- Generative system, 345.
- Genicular ganglion, 498.
- Genital system in early foetal life, 363.  
    in Ruminant, 375.
- Genito-urinary organs in Aves, 386.  
    Rodents, 383.
- Giant's Cells, 12.
- Gizzard, 384.
- Glands, 274.  
    Brunner's, 306.  
    buccal, 277.  
    ceruminous, 526.  
    Cowper's, 352.  
    ductless, 274.  
    gastric, 303.  
    lachrymal, 540.  
    liver, 312.  
    lymphatic, 450.  
    mammary, 363.  
    minor salivary, 287.  
    molar, 277.  
    mucous, 272.  
    Nabothian, 361.  
    of Harder, 540.  
    of intestines, 306.  
    of pancreas, 318.  
    of skin, 542.  
    parotid, 285.  
    prostate, 351.  
    salivary, 285.  
    solitary, 306.  
    spleen, 319.  
    submaxillary, 287.

- Glands, sublingual, 287.  
thyroid and thymus, 335.  
urophygeal, 553.
- Glans penis, 354.
- Glandular epithelium, 271.
- Glaserian fissure, 51.
- Glenoid cartilage, 142.  
cavity, 15.
- Globe of the eye, 582.
- Glossio-facial artery in Carnivora, 462.
- Graafian vesicle, 358.
- Great cerebral commissure, 479.
- Grey matter of the cord, 472.
- Groove, bicipital, 69.  
palatine, 56.  
staphyline, 69.
- Gums, 277.
- Guttural ganglion, 516.  
pouches, 531.
- Gyrus fornicatus, 479.
- HÆMAL SYSTEM, 3.**
- Hair, 423.
- Harderian glands, 540.
- Haversian canals, 9.
- Haw, 539.
- Head, articular, 14.
- Heart, 388.  
in Aves, 462.  
in Carnivora, 461.  
in lower animals, 463.  
in Rodents, 462.  
in Ruminants, 458.  
muscular fibres of, 395.  
structure of, 394.
- Heels, 545.
- Helicotrema, 530.
- Henle, tubes of, 343.
- Hermaphrodite, 363.
- Hiatus, 14.  
aortic, 209.  
maxillary, 57.  
of Winslow, 322.  
optic, 43, 53.  
orbital, 52.
- Hind limb, bones of, 88.
- Hip joint, 145.
- Hippocampus, 481.
- Hippotomy, 3.
- Histology, 2.
- Hock joint, 149.
- Homology and Analogy, 6.
- Hoof, 544.  
in Ruminantia, 552.
- Horn tissue, 548.
- Horns in Ruminantia, 552.
- Horny laminae, 545.
- Humerus, 68.
- Humours of the eye, 536.
- Hyaline cartilage, varieties of, 121.
- Hyaloid membrane, 537.
- Hymen, 362.
- Hyoid series of bones, 64.  
articulations of, 135.
- ILEUM, 305.**
- Iliac arteries in Carnivora, 461.
- Ilium, 84.
- Incisura sphenoidalis, 48.
- Incus, 527.
- Inferior cervical ganglion, 518.  
maxilla, 62.  
pyramids, 474.
- Infundibulum, 473.
- Ingluvies, 384.
- Inguinal canal, 203.
- Injection of arteries, 571.  
of lymphatics, 573.  
of veins, 573.
- Interdental space, 38, 57, 63.
- Intermediate fasciculi, 475.
- Internal ear, 529.
- Internal iliac artery of Omnivora, 461.  
maxillary artery in Carnivora, 462.
- Interpeduncular space, 478.
- Intervertebral discs, 129.
- Intestines, 304.  
glands of, 306,  
in Aves, 384.  
in Carnivora, 381.  
in Omnivora, 378.  
in Ruminants, 371.  
large, 307.  
small, 304.
- Introduction, 1.
- Invertebrata and vertebrata compared, 3.
- Iris, 535.
- Irrregular bones, 13.
- Ischium, 86.
- Island of Reil, 477.
- Isthmus faucium, 278.
- Iter ad infundibulum, 483.  
e tertio ad quartum ventriculum, 483.
- JEJUNUM, 305.**
- Joint oil, 125.
- Jugular confluent, 446.  
ganglion, 500.  
gutter, 446.  
vein, 446.
- KERATOGENOUS MEMBRANE, 550.**
- Keratophyllous tissue, 545.
- Kidneys, 340.
- LABYRINTH, 529.**  
membranous, 531.
- Lachrymal apparatus, 540.  
bone, 59.  
conduit, 56.  
duct, 541.  
fossa, 59.  
gland, 540.
- Lactiferous duct, 364.  
sinuses, 364.
- Lacunæ of bone, 9.
- Lamina spiralis, 530.
- Lamprey, 4.
- Lancelet, 4.
- Larynx, 327.  
cartilages of, 327.  
intrinsic muscles of, 331.  
ligaments of, 329.  
extrinsic muscles of, 331.  
ventricles of, 330.
- Lateral cartilages, 549.  
sinuses, 489.  
ventricles, 480.  
cornua of, 480.
- Lamina cinerea, 479.  
cribrosa, 533.
- Left auricle, 392.  
ventricle, 393.
- Lenticular ganglion, 515.
- Levator palati muscle, 279.
- Ligaments, 124.  
arcuate, 209.  
broad, 141.  
calcaneo-cuboid, 150.  
capsular, 124.  
cervical, (*Ligamentum nuchæ*), 130.  
check, 227, 228.  
common of carpus, 139.  
common of tarsus, 149.  
common vertebral, 129.  
crico-trachealis, 329.  
funicular, 124.  
inferior sesamoidean, 141.  
laryngeal, 329.  
obturator, 145.  
of bladder, 345.  
of liver, 314.

- Ligaments of uterus**, 360  
 of tympanum, 528.  
 of vulva, 363.  
 Poupart's, 202.  
 pubio-femoral, 146.  
 retractor of claw in cats, 267.  
 round, 146.  
 sacro-sciatic, 144.  
 special carpal, 137.  
 special tarsal, 150.  
 special vertebral, 130.  
 superior sesamoidean, 141.  
 suspensory, 141.  
 transverse odontoid, 153.  
 V. X. and Y, 141.
- Limb, bones of pectoral**, 66,  
 of pelvic, 88.
- Linea alba**, 201.  
 semilunaris, 200.
- Lips**, 276.
- Liquor amnii**, 557.  
 Contunnii, 530.  
 Morgagni, 537.  
 Scarpa, 531.
- Liver**, 312.  
 in Omnivora, 379.  
 ligaments of, 314.  
 structure of, 314.
- Locomotion, organs of**, 6.
- Locus niger**, 478.  
 perforans, anticus and posticus,  
 478.
- Long bones**, 12.
- Longitudinal sinuses**, 489.
- Low forms of vertebrata**, 4.
- Lumbar nerves**, 505.  
 vertebræ, 30.
- Lunar bone**, 74.
- Lungs**, 337.
- Lymph**, 451.  
 corpuscles, 451.
- Lymphatic system**, 449.  
 vessels, 449.
- Lymphatics, brachial**, 457.  
 deep inguinal, 453.  
 bronchial glands, 456.  
 glands, 450.  
 guttural, 457.  
 iliac, 453.  
 in bone tissue, 12.  
 in ruminants, 460.  
 of abdominal viscera, 454.  
 of anterior region, 456.  
 of cæcum, 454.  
 of diaphragm, 456.  
 of large colon, 454.  
 of liver, 455.  
 of posterior region, 452.  
 of rectum and floating colon,  
 454.  
 of spleen, 455.  
 of stomach, 455.  
 of thoracic viscera, 455.  
 of thoracic walls, 456.  
 popliteal, 453.  
 precural, 453.  
 prepectoral, 456.  
 prescapular, 457.  
 sublumbar, 452.  
 submaxillary, 457.  
 superficial inguinal, 453.  
 valves of, 450.  
 vein, 458.
- Lyra**, 481.
- MALAR BONE**, 58.
- Male genital organs**, 346.  
 in Ruminant, 375.
- Malleolar bone**, 104.
- Malleus**, 527.
- Malpighian bodies**, 341.  
 corpuscles, 321.
- Mammalia**, 4.
- Mammals, domesticated**, 4.
- Mammary glands**, 263.
- Mammillary eminence**, 478.  
 processes, 115.
- Mandible**, 62.
- Manubrium**, 103.
- Marrow**, 12.
- Mastoid ridge**, 46.
- Maxillary hiatus**, 57.
- Maxilla inferior**, 62.  
 pre, 57.  
 superior, 56.
- Maxillary nerve, inferior**, 495.  
 superior, 494.  
 rami, 38.  
 sinus, 44.  
 space, 38. 62.
- Meatus**, 14.  
 external auditory, 51.  
 internal auditory, 50.  
 nasal, 62.  
 urinarius, 354.
- Meckel's ganglion**, 516.
- Median phalanx**, 81.
- Mediastinum**, 337.  
 testis, 349.
- Medulla oblongata**, 473.
- Medullary cone**, 471.
- Meibomian glands**, 539.
- Membranes, basement**, 272.  
 basilar, 531.  
 fascia, 534.  
 mucous, 272.  
 nictitans, 539.  
 of Reissner, 531.  
 osteogenic, 17.  
 pupillaris, 535.  
 serous, 273.  
 synovial, 124.  
 tympanic, 526.
- Meninges of the brain**, 469.  
 cord, 468.
- Meniscus**, 134, 147.
- Mesenteries**, 321.
- Metacarpal articulation**, 140.  
 bone, large, 77.  
 bones, small, 78.
- Metacarpus**, 77.
- Metapophyses**, 115.
- Metatarsal bones**, 97.
- Metatarsus**, 97.
- Middle ear**, 526.
- Minute anatomy**, 2.  
 structure of bone, 9.
- Monro, foramen of**, 481.
- Morbid anatomy**, 2.
- Morphology**, 2.
- Motion in joints**, 128.
- Motores oculorum**, 492.
- Mouth**, 276.  
 bars of, 63.
- Mucous membranes**, 272.
- Muscles, abdominal region**, 200.  
 abducens, 177.  
 abductor brevis pollicis, 267.  
 abductor minimi digiti, 267.  
 accelerator urinae, 355.  
 acromio-humeralis, 266.  
 adductor brevis, 268.  
 adductor indicis, 267.  
 adductor longus, 239.  
 adductor magnus, 239.  
 adductor minimi digiti, 267.  
 anconæus, 221.  
 antea-spinatus, 213.  
 anterior femoral region, 241.  
 anterior maxillary group, 163.  
 anterior tibial group, 245.  
 antibrachial extensor group, 222.  
 antibrachial flexor group, 225.  
 aryteno-pharyngeus, 298.

**Muscles, arytenoideus, 333.**  
 attollens auticus, 175.  
 attollens maximus, 174.  
 attolleus posticus, 176.  
 auricular group (extrinsic), 174.  
 auricular group (intrinsic), 177.  
 biceps rotator tibialis, 244.  
 brachial group (anterior), 217.  
 brachial group (posterior), 219.  
 buccinator, 163.  
 caput magnum, 220.  
 caput medium, 220.  
 caput parvum, 221.  
 cervical region, 178.  
 coccygeal region, 210.  
 complexus major, 186.  
 complexus minor, 187.  
 compressor coccygis, 211.  
 constrictores vulvae, 363.  
 coraco-humeralis, 218.  
 costal region, 190.  
 cremaster, 355.  
 crico-arytenoideus lateralis, 332.  
 crico-arytenoideus posticus, 332.  
 crico-pharyngeus, 298.  
 crico-thyroideus, 332.  
 crural group, 242.  
 cururus, 243.  
 curvator coccygis, 211.  
 depressor alae, 269.  
 depressor coccygis, 210.  
 depressor labii inferioris, 167.  
 depressor labii superioris, 166.  
 diaphragm, 208.  
 digastricus, 170.  
 dilatator naris inferioris, 166.  
 dilatator naris lateralis, 165.  
 dilatator naris superioris, 166.  
 dilatator naris transversalis, 166.  
 dorso-lumbar region, 198.  
 erector clitoridis, 363.  
 erector coccygis, 210.  
 erector penis, 356.  
 extensor communis digitorum, 262.  
 extensor metacarpi magnus, 222.  
 extensor metacarpi obliquus, 223.  
 extensor pedis, 223, 247.  
 extensor pedis brevis, 252.  
 extensor pollicis et indicis, 266.  
 extensor proprius externus, 262.  
 extensor proprius internus, 262.  
 extensor suffraginis, 224.  
 femoral abductor group, 239.  
 femoral adductor group, 236.  
 flexor brachii, 217.  
 flexor brevis pollicis, 267.  
 flexor metacarpi externus, 225.  
 flexor metacarpi internus, 226.  
 flexor metacarpi medius, 226.  
 flexor metatarsi, 245.  
 flexor minimi digiti, 267.  
 flexor pedis accessorius, 251.  
 flexor pedis perforans, 228, 250.  
 flexor pedis perforatus, 227, 249.  
 frontalis, 261.  
 gastrocnemius, 248.  
 gemelli (gemini), 235.  
 genio-hyo-glossus, 283.  
 genio-hyoideus, 171.  
 gluteal region, 231.  
 gluteus externus, 232.  
 gluteus internus, 233.  
 gluteus maximus, 232.  
 gracilis, 237.  
 humeralis obliquus, 218.  
 hyo-epiglottideus, 331.  
 hyo-glossus brevis, 282.  
 hyo-glossus longus, 282.  
 hyo-glossus parvus, 282.  
 hyo-pharyngeus, 298.  
 hyo-thyroideus, 331.

**Muscles, hyoidean group, 170.**  
 hyoideus magnus, 171.  
 hyoideus parvus, 172.  
 hyoideus transversus, 172.  
 iliacus, 207.  
 in birds, 269.  
 inferior cervical group, 178.  
 inferior oblique of eye, 538.  
 intercostales, 194.  
 interossei (hog), 261.  
 interossei metacarpi, 230.  
 intertransversales lumborum, 200.  
 intertransversalis colli, 189.  
 ischio-femorals, 244.  
 kerato-pharyngeus, 297.  
 lachrymalis, 173.  
 laryngeal, 331.  
 lateral cervical group, 183.  
 lateralis sterni, 197.  
 latissimus dorsi, 191.  
 levator alae, 269.  
 levator ani, 312.  
 levator humeri, 183.  
 levator labii inferioris, 167.  
 levator labii superioris alaeque nasi, 164.  
 levator palati, 279.  
 levator palpebrae superioris externus, 173.  
 levator palpebrae superioris internus, 174.  
 levatores costarum, 193.  
 lingual, 281.  
 lingualis, 283.  
 longissimus dorsi, 198.  
 longus colli, 182.  
 lumbricales, 231.  
 masseter, 168.  
 mastoideo-auricularis, 177.  
 metacarpal region, 230.  
 metatarsal region, 252.  
 mylo-hyoideus, 170.  
 nasalis longus, 164.  
 obliquus abdominis externus, 201.  
 obliquus abdominis internus, 203.  
 obliquus capitis anticus, 188.  
 obliquus capitis posticus, 188.  
 obturator externus, 234.  
 obturator internus, 235.  
 of dog's paw, 266.  
 of eye, 537.  
 of female genital system, 363.  
 of head, 162.  
 of larynx, 331.  
 of limbs, 211.  
 of male genital organs, 355.  
 of pectoral limb, 212.  
 of pelvic limb, 231.  
 of pharynx, 297.  
 of Phillips, 224.  
 of soft palate, 278.  
 of Thiernesse, 224.  
 of tongue, 281.  
 of trunk, 178.  
 of tympanum, 528.  
 opponens, 267.  
 orbicularis oris, 164.  
 orbicularis palpebrarum, 173.  
 palato-glossus, 280, 283.  
 palato-staphylinus, 280.  
 palmares, 267.  
 palmaris brevis, 267.  
 palpebral group, 173.  
 panniculus carnosus, 161.  
 pectineus, 237.  
 pectoral region and group, 194.  
 pectoralis anticus, 196.  
 pectoralis magnus, 196.  
 pectoralis parvus, 197.  
 pectoralis transversus, 195.

**Muscles, peroneus, 247.**  
 peroneus longus lateralis, 263.  
 pharyngeal, 297.  
 pharyngo-glossus, 283.  
 pharyngo-staphylinus, 279, 297.  
 plantaris, 249.  
 popliteus, 251.  
 postea-spinatus, 214.  
 postea-spinatus minor, 214.  
 posterior femoral region, 244.  
 posterior maxillary group, 167.  
 posterior tibial group, 248.  
 pronator quadratus, 266.  
 pronator teres, 266.  
 psoas magnus, 205.  
 psoas parvus, 206.  
 pterygo pharyngeus, 297.  
 pterygoideus externus, 169.  
 pterygoideus internus, 169.  
 pyriformis, 235.  
 quadratus lumborum, 207.  
 quadriceps cruralis, 242.  
 radialis accessorius, 230.  
 recti oculi, 537.  
 rectus abdominis, 204.  
 rectus capitis anticus major, 180.  
 rectus capitis anticus minor, 181.  
 rectus capitis lateralis, 181.  
 rectus capitis posticus major, 187.  
 rectus capitis posticus minor, 187.  
 rectus femoris, 242.  
 rectus parvus, 234.  
 retractor ani, 312.  
 retractor oculi, 537.  
 retractor penis, 356.  
 retrahens externus, 176.  
 retrahens internus, 177.  
 retrahens medius, 176.  
 rhomboideus brevis, 190.  
 rhomboideus longus, 184.  
 sartorius, 236.  
 scalenus, 181.  
 scapular group (external), 212.  
 scapular group (internal), 215.  
 scapulo-humeralis posticus (grêle), 216.  
 scapulo-ularis, 219.  
 scuto-auricularis externus, 178.  
 scuto-auricularis internus, 178.  
 semispinalis dorsi et lumborum, 199.  
 serratus magnus, 185, 192.  
 sphincter ani, 311.  
 spinalis colli, 189.  
 spinalis dorsi, 199.  
 splenius, 185.  
 sternal group, 197.  
 sterno-maxillaris, 179.  
 sterno-suboccipitalis, 261.  
 sterno-thyro-hyoideus, 179.  
 stylo-hyoideus, 172.  
 stylo-maxillaris, 168.  
 subcutaneous region, 161.  
 subscapularis, 215.  
 subscapulo-hyoideus, 180.  
 sublumbar region, 205.  
 superficialis costarum, 192.  
 superior oblique of eye, 538.  
 supinator brevis, 266.  
 supinator longus, 266.  
 temporalis, 168.  
 tensor fasciæ latæ, 241.  
 tensor palati, 278.  
 teres externus, 212.  
 teres internus (major), 215.  
 thyro-arytenoideus, 333.  
 thyro-pharyngeus, 298.  
 tibial region, 245.  
 tibialis anticus, 263.  
 tibialis posticus, 268.  
 trachelo-altoideus, 261.  
 trachelo-mastoideus, 186.

**Muscles, transversalis abdominis, 205.**  
 transversalis costarum, 193.  
 trapezius cervicalis, 184.  
 trapezius dorsalis, 190.  
 triangularis sterni, 198.  
 triceps abductor femoris, 240.  
 triceps abductor femoris, 238.  
 triceps cruralis, 242.  
 triceps extensor brachii, 219.  
 ulnaris accessorius, 229.  
 vastus externus, 243.  
 vastus internus, 243.  
 Wilson's, 356.  
 zygomaticus, 163.

**Muscular attachments, table of, 256.**  
 classification, 160.  
 nomenclature, 160.  
 tissue, 155.

**Myelon, 471.**  
**Myology, 155.**  
 comparative, 260.

**NARES, ANTERIOR, 42.**  
 posterior, 39.

**Nasal bone, 54.**  
 chambers, 335.  
 duct, 541.  
 fossæ, 44.  
 meati, 62.

**Natatores, 6.**  
 Nates, 484.  
 Navicular bone, 83.  
 Neck of a bone, 14.  
 Nerve cells, 466.  
 Nerves, 467.  
 abducens, 497.  
 anterior auricular, 498.  
 anterior palatine, 494.  
 anterior scapular, 508.  
 anterior tibial, 514.  
 auditory, 499.  
 auricular plexus, 503.  
 axillary, 508.  
 brachial plexus, 508.  
 bronchial plexus, 501.  
 buccal, 496.  
 cardiac, 518.  
 carotid plexus, 518.  
 cauda equina, 506.  
 cavernous plexus, 517.  
 cephalic portion of sympathetic, 515.  
 cervical, 503.  
 cervical portion of sympathetic, 516.  
 chorda tympani, 498.  
 circulatory depressor, in Rabbit, 524.  
 classification of, 468, 490.  
 cochlear, 499.  
 coccygeal, 507.  
 cranial, 490.  
 crural, 512.  
 cubital, 509.  
 deep cervical plexus, 504.  
 dental, 494, 496.  
 digital, 511, 514.  
 dorsal, 505.  
 external popliteal, 514.  
 external saphenic, 514.  
 facial, 497.  
 facial branches of fifth, 494.  
 gastric plexus, 520.  
 glosso-pharyngeal, 499.  
 gluteal anterior, 512.  
 gluteal posterior, 512.  
 great sciatic, 513.  
 great splanchnic, 520.  
 gustatory, 496.  
 guttural plexus, 516.  
 hæmorrhoidal, 507.  
 hepatic plexus, 520.



- Nerves, hypogastric plexus,** 507, 521.  
 hypoglossal, 502.  
 iliaco-muscular, 512.  
 ilio-muscular, 512.  
 in Aves, 524.  
 in Carnivora, 523.  
 in the Hog, 523.  
 in Ruminants, 522.  
 inferior dental, 496.  
 inferior maxillary, 495.  
 inguinal, 506.  
 intercostal, 505.  
 intermediate cord of cervical ganglia, 518.  
 internal metacarpal, 510.  
 internal pudic, 507.  
 internal saphenic, 512.  
 ischio-muscular, 512.  
 Jacobson's, 500.  
 lachrymal, 494.  
 lesser splanchnic, 521.  
 lingual, 496.  
 lumbar, 505.  
 lumbar portion of sympathetic, 521.  
 lumbo-aortic plexus, 520.  
 lumbo-sacral plexus, 511.  
 masseter, 495.  
 median, 509.  
 mental, 496.  
 mesenteric plexus, 520.  
 metacarpal, 511.  
 metatarsal, 514.  
 middle auricular, 499.  
 motores oculorum, 492.  
 musculo-cutaneous (fore-limb), 510.  
 musculo-cutaneous (hind-limb), 514.  
 mylo-hyoidean, 496.  
 nasal, 494.  
 obturator, 512.  
 olfactory, 491.  
 ophthalmic, 493.  
 optic, 491.  
 orbital, 494.  
 origin and termination of, 467.  
 par vagum, 500.  
 pathetic, 492.  
 pharyngeal plexus, 518.  
 phrenic, 507.  
 pneumogastric, 500.  
 portio dura, 497.  
 portio mollis, 499.  
 posterior auricular, 499.  
 posterior crural, 514.  
 posterior mesenteric plexus, 521.  
 pterygoid, 496.  
 radial, 508.  
 recurrent laryngeal, 501.  
 renal plexus, 520.  
 sacral, 506.  
 sacral portion of sympathetic, 521.  
 solar plexus, 520.  
 spermatic plexus, 521.  
 sphenopalatine, 494.  
 spinal, 502.  
 spinal accessory, 502.  
 splenic plexus, 520.  
 staphyline, 494.  
 subscapular, 508.  
 subzygomatic, 496.  
 superficial cervical plexus, 504.  
 superficial petrosal, 498.  
 superior dental, 494.  
 superior laryngeal, 500.  
 superior maxillary, 494.  
 supraorbital, 493.  
 suprarenal plexus, 520.  
 sympathetic system, 515.  
 temporo-facial, 499.
- Nerves, thoracic,** 508.  
 thoracic portion of sympathetic, 519.  
 tibial, 513.  
 tracheal plexus, 519.  
 trifacial, 492.  
 ulnar, 509.  
 vestibular, 499.  
 Vidian, 498.  
 Wrisberg's, 498.
- Nervous tissue,** 466.  
 Neural canal, 3.  
 Neuroglia, 473.  
 Neurology, 465.  
 comparative, 522.
- Nomenclature, muscular,** 160.
- Non-articular depressions,** 14.  
 eminences, 14.
- Non-striated muscular tissue,** 157.
- Nostrils,** 323.
- Notch,** 14.  
 carotid, 53.  
 cotyloid, 87.  
 inferior maxillary, 53.
- Notochord,** 4, 557.
- OBTURATOR FORAMEN,** 87.  
 ligaments, 145.
- Occipital bone,** 45.  
 bone, segments of, 46.  
 sinuses, 489.
- Ocular sheath,** 541.
- Odontoid ligament, transverse,** 153.  
 process, 27.
- (Oesophagus,** 298.
- Olecranon process,** 72.
- Olfactory bulbs,** 479.
- Olfactory lobes in carnivora,** 523.  
 nerves, 491.
- Olivary bodies,** 474.
- Omenta,** 322.
- Omnivora, characteristics of,** 5.  
 skin in, 552.
- Ophthalmic nerve,** 493.
- Optic hiatus,** 43, 53.  
 lobes, 484.  
 nerves, 491.  
 thalami, 482.  
 tracts, 478.
- Orbital fossa,** 41.  
 hiatus, 52.
- Organs of locomotion,** 6.
- Os calcis,** 94.  
 coronæ, 81.  
 hyoides, 64.  
 innominatum, 84.  
 magnum, 76.  
 orbicular, 527.  
 pedis, 81.  
 suffraginus, 80.  
 triquetrum, 48.  
 uteri, 361.
- Osseous tissue,** 9.
- Ossific centres,** 15.  
 tentorium, 42, 47.
- Ossification,** 15.
- Osteoblasts,** 11.
- Osteology,** 7.  
 comparative, 98.
- Osteogenic membrane,** 17.
- Ostium internum,** 361.  
 uterinum, 361.
- Otic ganglion,** 516.
- Oto-coniæ,** 531.
- Ovary,** 357.
- Oviduct,** 358, 386.
- Ovum,** 358.  
 after fecundation, 356.
- PACINIAN BODIES,** 467.
- Palate, hard,** 277.  
 soft, 277.

- Palate, blood supply of, 280.  
     muscles of, 278.  
 Palatine arch, 38, 60.  
     bone, 59.  
     groove, 56.  
 Pancreas, 318.  
 Pancreas and liver in Aves, 384.  
 Panniculus adiposus, 542.  
 Papillæ of the tongue, 284.  
 Parietal bone, 47.  
     branches of posterior aorta, 403.  
 Parotid gland, 285.  
 Par-ovarium, 359.  
 Pastera bone, large, 80.  
     bone, small, 81.  
     joint, 142.  
 Patella, 91.  
 Pathetic nerves, 492.  
 Pecten, 554.  
 Pectoral arch, 65.  
     arch in birds, 117.  
     limb, 66.  
         articulations of, 136.  
         fascia of, 254.  
 Peduncles of the cerebellum, 475.  
     cerebrum, 477.  
 Pelvic apertures 87.  
     arch, 83.  
     cavity, 83.  
     limb, 85.  
         articulations of, 143.  
         fasciæ of, 255.  
     symplysis, 145.  
 Pelvis, 83.  
 Penis, 353.  
     arteries and nerves of, 356.  
 Pericardium, 397.  
 Perichondrium, 121.  
 Pericranium, 12.  
 Perilymph, 530.  
 Perineal fascia, 356.  
 Perineum, 356, 362.  
 Periople, 545.  
 Periopic ring, 551.  
 Periosteum, 11.  
 Perissodactyla, 4.  
 Peritoneum, 321.  
 Petrosal bone, 50.  
     ganglion, 499.  
     sinuses, 489.  
 Phalanx, distal, 81.  
     median, 81.  
     proximal, 80.  
 Pharyngeal muscles, 297.  
 Pharynx, 596.  
 Phrenic centre, 208.  
 Physiology distinguished from Anatomy,  
     2.  
 Pia mater, 469, 471.  
 Pineal gland, 484.  
 Pisiform bone, 77.  
 Pituitary gland, 478.  
 Placenta, 557.  
 Plantar aponeurosis, 228.  
     strengthening sheath, 229.  
 Pleuræ, 337.  
 Plexuses. *See* NERVES.  
 Pneumatic bones, 119.  
 Pneumogastric nerve, 500.  
 Podophyllous tissue, 550.  
 Pons Tarlini, 478.  
     Varolii, 475.  
 Portio dura, 497.  
 Portio mollis, 499.  
 Porus opticus, 533.  
 Posterior aorta, 402.  
     bifurcation of, 409.  
     parietal branches of, 403.  
     visceral branches of, 404.  
         nares, 39.  
         vena cava, 436.  
 Poupart's ligament, 202.  
 Practical anatomy, 2.  
 Preening in birds, 555.  
 Premaxilla, 57.  
 Premaxillary symphysis, 58.  
 Prepubian tendon, 201.  
 Prepuce, 355.  
 Process, 14.  
     basilar, 46.  
     crista galli, 54.  
     olecranon, 72.  
     olivary, 53.  
     pyramidal, 82.  
 Pronation, 154.  
 Prostate gland, 351.  
     vesicle, 351.  
 Proventriculus, 384.  
 Proximal, 20.  
     phalanx, 80.  
 Pterygoid bone, 60.  
 Pterygoidean fasciculus, 431.  
 Pubio-femoral ligament, 146.  
 Pubis, 86.  
 Pulmonary artery, 400.  
 Puncta lachrymalia, 540.  
     vasculosa, 479.  
 Pupil, 535.  
 Pyramidal process, 82.  
 QUADRATO-JUGAL BONE, 117.  
 Quadrate bone, 117.  
 Quarters, 545.  
 RACHIS, 554.  
 Rachitis, 8.  
 Radio-ulnar arch, 70.  
     radius, 70.  
 Rami of the Jaw, 33.  
 Rasores, 6.  
 Receptaculum chyli, 451.  
     in Carnivora, 462.  
 Rectum, 310.  
 Removal of the hoof, 567.  
 Renal-portal system, 463.  
 Respiratory organs, 323.  
     in Aves, 385.  
     in Carnivora, 382.  
     in Omnivora, 379.  
     in Ruminants, 374.  
 Respiratory system, 323.  
 Restiform bodies, 474.  
 Rete mirabile, 460.  
     mucosum, 541.  
 Reticular cartilage, 122.  
 Retina, 535.  
 Ribs, 33.  
     special, 35.  
 Ridge, 14.  
     mastoid, 46.  
     semilunar, 82.  
 Right auricle, 389.  
     ventricle, 391.  
 Rings, abdominal, 203.  
 Rodentia, albinos in, 553.  
     appendicular skeleton, 115.  
     characteristics of, 5.  
     axial skeleton, 114  
 "Roosting," mechanism of, 269.  
 Ruminantia, appendicular skeleton of, 103.  
     bones of skull, 98.  
     characteristics of, 4.  
     horns in, 552.  
     vertebræ of, 102.  
     visceral skeleton of, 105.  
 SACCULUS COMMUNIS, 531.  
     proprius, 531.  
 Saccus endolymphticus, 531.  
 Sacral nerves, 506.  
     vertebræ, 31.  
 Sacro-iliac joint, 143.  
 Sacro-lumbar articulation, 132.  
 Sacro-sciatic ligament, 144.

- Sacrum, 31.  
 Saliva, 288.  
 Salivary glands, 285.  
 Scala intermedia, 531.  
   tympani, 530.  
   vestibuli, 530.  
 Sphenoid, 73.  
 Scapula, 66.  
 Scapus, 554.  
 Schneiderian membrane, 525.  
 Sclerotic coat, 532.  
 Scrotum, 347.  
 Scutiform cartilage, 526.  
 Sebaceous glands, 542.  
 Sella turcica, 53.  
 Semi-circular canals, 530.  
 Semilunar cartilages, 147.  
   ganglion, 520.  
   ridge, 82.  
 Seminal fluid, 356.  
 Sensation, organs of, 525.  
 Sensitive frog, 550.  
   laminae, 551.  
   sole, 551.  
 Separate bones of the skull, 45.  
 Septum lucidum, 480.  
   pectiniforme, 354.  
 Serous membranes, 273.  
 Sesamoid bones, large, 80.  
   small, 83.  
 Sesamoid ligaments, 141.  
 Sharpey, fibres of, 10.  
 Sheath, 353.  
 Shoulder joint, 136.  
 Sinus procaricaris, 351.  
 Sinuses, cavernous, 489.  
   ethmoidal, 45.  
   frontal, 44.  
   lactiferous, 364.  
   lateral, 489.  
   longitudinal, 489.  
   maxillary, 44.  
   occipital, 489.  
   of the dura mater, 488.  
   of the skull, 44.  
   petrosal, 489.  
   sphenoidal, 45.  
   transverse, 489.  
 Skeleton, 17.  
   appendicular, 65.  
   axial, 21.  
   division of, 20.  
   in Birds, 115.  
   in Carnivora, 109.  
   in Hog, 105.  
   in Rodentia, 114.  
   in Ruminants, 98.  
 Skin, 541.  
   in Carnivora, 553.  
   in Omnivora, 552.  
 Skull, articulations of, 134.  
   cavities in, 42.  
   division of, 37.  
   general view, 37.  
   of Dog, 109.  
   of Hog, 105.  
   of Ruminant, 98.  
   separate bones of, 45.  
   sinuses of, 44.  
   sutures of, 134.  
 Snout, 379.  
 Sole, 546.  
 Solidungula, 4.  
 Space, atlo-axoid, 28.  
   interdental, 38, 57, 63.  
   maxillary, 62.  
 Special anatomy, 1.  
   ligaments of carpus, 137.  
   ligaments of tarsus, 150.  
   ribs, 35.  
   vertebral articulations, 131.  
   vertebral ligaments, 130.  
 Speculum Helmontii, 208.  
 Spermatic cord, 347.  
 Spermatozoa, 356.  
 Sphenoid bone, 52.  
 Sphenoidal sinus, 45.  
 Spheroidal epithelium, 271.  
 Spinal accessory nerve, 502.  
 Spinal cord, 471.  
   meninges of, 468.  
 Spine, 14.  
 Spirochology, 270.  
   comparative, 365.  
 Spleen, 319.  
 Splint bone, 78.  
 Squamosal bone, 49.  
 Squamous epithelium, 270.  
 Stapes, 527.  
 Sternal articulations, 134.  
 Sternebrae, 35.  
 Sternum, 35.  
 Stifle bone, 91.  
   joint, 146.  
 Stomach, 301.  
   in Carnivora, 381.  
   in Omnivora, 378.  
   in Rodents, 383.  
   in Ruminants, 366.  
 Strangeways on a supernumerary oblique  
   muscle of the eyeball, 575.  
 Strengthening plantar sheath, 229.  
 Striated muscular tissue, 156.  
 Structure of bone, 7.  
   minute, 9.  
 Sudoriferous glands, 542.  
 Superficial fascia, 159.  
 Superior maxilla, 56.  
   pyramids, 475.  
 Supination, 154.  
 Supracondyloid fossa, 89.  
 Suprarenal capsules, 343.  
 Surfaces of bones, 14.  
 Surgical anatomy, 2.  
 Suspensory ligament, 141.  
 Sutures, 126.  
   of the skull, 134.  
 Symmetry, bilateral, 19.  
 Sympathetic system of nerves, 515.  
 Symphysis, pelvic, 145.  
   premaxillary, 58.  
   inferior maxillary, 63.  
 Synarthrosis, 126.  
 Syndesmology, 120.  
 Synovia, 125.  
 Synovial bursae, 125.  
   membranes, 124.  
 Syrinx, 285.  
 System, hæmal, 3.  
 TABLE of muscular attachments, 256.  
 Tania semicircularis, 482.  
 Tapetum lucidum, 534.  
   in carnivora, 553.  
 Tarsal cartilages, 539.  
 Tarsus, 93.  
 Teeth, 288.  
   arrangement, and kinds of, 290.  
   canine, 293.  
   in Carnivora, 380.  
   in Rodents, 383.  
   incisor, 291.  
   molar, 293.  
 Temporal bone, 49.  
   fossa, 41.  
 Temporary cartilage, 15.  
 Temporo-maxillary joint, 134.  
 Tendons, 153.  
 Tendo-Achillis, 248.  
 Tendon, prepubian, 201.  
 Tentorium cerebelli, 470.  
   ossific, 42, 47.  
 Testes, 484.  
 Testicle, 348.

- Testicle in Carnivora, 383.  
 Tensor palati muscle, 278.  
 Third ventricle, 483.  
 Thorax, 33, 336.  
 Thoracic articulations, 132.  
     duct, 451.  
 Thoracic duct in Omnivora, 461.  
 Thyroid and Thymus glands, 335.  
 Tibia, 91.  
 Tibial arch, 93.  
 Tibio-fibular articulation, 148.  
 Tissue, adipose, 123.  
     cancellated, 10.  
     compact, 9.  
     connective, 122.  
     horn, 548.  
     muscular, 155.  
     osseous, 9.  
     white fibrous, 122.  
     yellow elastic, 123.  
 Tongue, 280.  
     muscles of, 281.  
     papillæ of, 284.  
 Torcular Herophilii, 489.  
 Touch-hairs, 553.  
 Trachea, 334.  
 Transcendental anatomy, 1.  
 Transverse sinus, 489.  
 Trapezium, 75.  
 Trapezoid, 75.  
 Trifacial nerves, 492.  
 Trochanter, 14.  
 Trochlea, 15.  
 True vertebrae—general view, 21.  
 Tuber cinereum, 478.  
 Tubercle, 14.  
 Tuberosity, 14.  
 Tubuli uriniferi, 341.  
     seminiferi, 349.  
 Tunica abdominalis, 200.  
     albuginea, 349, 358, 553.  
     Ruyschiana, 534.  
     vaginalis, 348.  
     vasculosa, 349.  
 Tunics of the eyeball, 532.  
 Turbinals, 61.  
 Turner, Professor, on a muscle connected  
     with orbital periosteum, 577.  
 Tusks, 5.  
 Tympanic membrane, 526.  
 Tympanum, 526.  
 Types in anatomy, 1.  
 ULNA, 71.  
     development of, 72, 103.  
 Umbilical cord, 558.  
 Umbilicus, 201.  
 Unciform bone, 76.  
 Ungulata, 4.  
 Urachus, 558.  
 Ureters, 343.  
 Urethra, 352.  
 Urinary system, 340.  
 Urino-genital system in Aves, 386.  
     in Carnivora, 382.  
     in Omnivora, 379.  
     in Rodentia, 383.  
     in Ruminants, 374.  
 Uropygeal gland, 555.  
 Utero-gestation, 556.  
 Uterus, 359.  
     forms of, 384.  
 Uvea, 535.  
 VAGINA, 361.  
 Valve of Vieussens, 475.  
 Vas deferens, 350.  
 Vater, eminence of, 317.  
 Veins, structure of, 433.  
     alveolar, 447.  
     angular, 447.  
     anterior auricular, 446.  
     anterior cava, 442.  
     anterior mesenteric, 437.  
     anterior radial, 445.  
     anterior tibial, 441.  
     azygos, 444.  
     basilic, 445.  
     brachial, 444, 445.  
     bronchial, 435.  
     buccal, 449.  
     cardiac, 435.  
     cephalic, 445, 449.  
     common iliac, 438.  
     coronary, 435, 448.  
     coronary plexus, 440.  
     cubital, 445.  
     deep, of arm, 445.  
     deep, of brain, 488.  
     deep, of posterior limb, 441.  
     deep, or interosseous, of anterior  
         extremity, 444.  
     diaphragmatic, 437.  
     digital, 440, 444.  
     dorsal, 443.  
     dorsalis nasi, 447.  
     duodenum, 437.  
     emergent veins of the cranium, 489.  
     encephalic sinuses, 488.  
     external iliac, 439, 442.  
     external saphenic, 442.  
     external subcutaneous of arm, 445.  
     femoral, 442.  
     gastric, 437.  
     gastro-epiploic, 437.  
     gastro-splenic, 437.  
     glosso-facial, 447.  
     hepatic, 437.  
     humeral, 445.  
     in Aves, 463.  
     in Omnivora, 461.  
     in Ruminants, 460.  
     inferior communicating, 449.  
     internal iliac, 442.  
     internal-maxillary, 447.  
     internal saphenic, 441.  
     internal subcutaneous of arm, 445.  
     internal thoracic, 443.  
     interosseous of foot, 440.  
     jugular, 446.  
     jugular, branches of, 447.  
     jugular confluent, 446.  
     laminal plexus, 439.  
     lateral coronary plexus, 440.  
     lateral nasal, 447.  
     lesser azygos, 443.  
     lingual, 447.  
     lumbar, 438.  
     maxillo-muscular, 447.  
     metacarpal, 444.  
     metatarsal, 440.  
     middle coronary, 440.  
     occipital, 447.  
     of the brain, 488.  
     of the foot, 439.  
     of the Frog, 440.  
     pancreatic, 437.  
     parietal-temporal (confluent), 489.  
     pedal plexuses of anterior limb,  
         444.  
     phrenic, 437.  
     popliteal, 442.  
     portal, 437.  
     posterior auricular, 447.  
     posterior mesenteric, 437.  
     posterior radial, 444.  
     posterior tibial, 441.  
     posterior vena cava, 436.  
     pulmonary, 435.  
     pyloric, 437.  
     renal, 437.  
     saphena major, 441.  
     saphena minor, 442.  
     satellite, 434.

- Veins, sesamoidean arch, 440.  
   solar plexus, 439.  
   spermatic, 437.  
   spermatic plexus, 438.  
   spinal, 490.  
   spur, 445.  
   subcutaneous thoracic, 445.  
   sublingual, 449.  
   subphenoidal (confluent), 489.  
   subzygomatic, 446.  
   superior cerebral, 446.  
   superior cervical, 443.  
   superior and inferior coronary, 448.  
   superficial of arm, 445.  
   superficial of brain, 488.  
   superficial of posterior limb, 441.  
   superficial temporal, 446.  
   systemic, 435.  
   thyroid, 449.  
   ulnar, 445.  
   umbilical, 559.  
   utero-ovarian, 438.  
   valves of, 431.  
   vena varicosa, 447.  
   vertebral, 443.  
   venæ vorticossæ 534.
- Velum interpositum, 482.
- Ventricles of brain, 476.  
   of heart, 389.  
   of larynx, 390.
- Vermiform process, 475.
- Vertebrae, cervical, general features, 23.  
   cervical, special, 26.  
   cervical, the two last, 28  
   coccygeal, 32.  
   dorsal, 28.  
   false, general view, 23.  
   in the Dog, 111.  
   in the Hog 107.
- Vertebrae, in Ruminants, 102.  
   lumbar, 30.  
   sacral, 31.  
   true, general view, 21.
- Vertebral column, 21.
- Vertebrata, 3.  
   low forms of, 4.
- Verumontanum, 353.
- Vesiculæ seminales, 350.
- Vessels of bone tissue, 12.
- Vestibule, 529.
- Veterinary anatomy, 2.
- Vexillum, 554.
- Visceral branches of posterior aorta, 404.  
   skeleton in Carnivora, 113.  
   in Ruminantia, 105.
- Vidian fissure, 52.
- Vitreous humour, 533.
- Vomer, 61.
- Vulva, 361.
- WALL OF THE HOOF, 545.
- Wattles, 555.
- Web-foot, 555.
- White fibrous tissue, 122.
- Wind galls, 142.
- Withers, 30.
- Wolffian bodies, 557.
- Wormian bone, 48.
- XIPHOID CARTILAGE, 35.
- YELLOW ELASTIC TISSUE, 123.
- ZONULA OF ZINN, 536.
- Zoölogy, 1.
- Zoöotomy, 1.
- Zygomatic arch, 40, 49.  
   process, 58.



WILLIAM R. JENKINS'

CATALOGUE OF VETERINARY BOOKS

1904

(\*) *Single asterisk designates New Books.*

(\*\*) *Double asterisk designates Recent Publications.*

**ANDERSON.** "Vice in the Horse" and other papers on Horses and Riding. By E. L. Anderson. Demy, 8vo, cloth.....2 00

— "How to Ride and School a Horse." With a System of Horse Gymnastics. By Edward L. Anderson. Cr. 8vo.....1 00

**ARMSTEAD.** "The Artistic Anatomy of the Horse." A brief description of the various Anatomical Structures which may be distinguished during Life through the Skin. By Hugh W. Armstead, M.D., F.R.C.S. With illustrations from drawings by the author. Cloth oblong, 12½ x 10.....3 75

**BACH.** "How to Judge a Horse." A concise treatise as to its Qualities and Soundness; Including Bits and Bitting, Saddles and Saddling, Stable Drainage, Driving One Horse, a Pair, Four-in-hand, or Tandem, etc. By Captain F.W. Bach. 12mo, cloth, fully illustrated.....1 00

(\*\*) **BANHAM.** "Anatomical and Physiological Model of the Horse." Half life size. Composed of superposed plates, colored to nature, showing internal organs, muscles, skeleton, etc., mounted on strong boards, with explanatory text. By George A. Banham, F.R.C.V.S. Size of Model 38x41 in.... 7 50

(\*\*)- "Tables of Veterinary Posology and Therapeutics," with weights, measures, etc. By Geo. A. Banham, F.R.C.V.S. New edition. 12mo, cloth..... 1 00

**BAUCHER.** "Method of Horsemanship." Including the Breaking and Training of Horses..... 1 00

(\*) **BELL.** "The Veterinarian's Call Book (Perpetual)," By Roscoe R. Bell, D.V.S., editor of the *American Veterinary Review*. Revised for 1903.

A visiting list, that can be commenced at any time and used until full, containing much useful information for the student and the busy practitioner. Among contents are items concerning: Veterinary Drugs; Poisons; Solubility of Drugs; Composition of Milk, Bile, Blood, Gastric Juice, Urine, Saliva; Respiration; Dentition; Temperature, etc., etc. Bound in flexible leather, with flap and pocket ..... 1 25

**BRADLEY.** "Outlines of Veterinary Anatomy." By O. Charnock Bradley, Member of the Royal College of Veterinary Surgeons; Professor of Anatomy in the New Veterinary College, Edinburgh.

The author presents the most important facts of veterinary anatomy in as condensed a form as possible, consistent with lucidity. 12mo.

Complete in three parts.

PART I.: *The Limbs* (cloth)..... 1 25  
 PART II.: *The Trunk* (paper) ..... 1 25  
 PART III.: *The Head and Neck* (paper)..... 1 25  
 THE SET COMPLETE ..... 3 50



**CADIOT.** "Roaring in Horses." Its Pathology and Treatment. This work represents the latest development in operative methods for the alleviation of roaring. Each step is most clearly defined by excellent full-page illustrations. By P. J. Cadiot, Professor at the Veterinary School, Alfort. Trans. Thos J. Watt Dollar, M.R.C.V.S., etc. Cloth.....75

— "Exercises in Equine Surgery." By P. J. Cadiot. Translated by Prof. A. W. Blitting, M.D., V.S.; edited by Prof. A. Liautard, M.D.V.S. 8vo, cloth, illustrated ..... 2 50

(\*)—"A Treatise on Surgical Therapeutics of the Domestic Animals." By P.J. Cadiot and J. Almy. Translated by Prof. A. Liautard, M.D., V.S. 2 Parts ready.

Part I, Vol. I, 8vo, 93 pages, 45 illustrations.....1 00

Part II, Vol., I, 8vo, 96 pages.....1 00

Part III, Vol., I, 8vo, 134 pages, 33 illustrations..1 00

Part IV, in preparation, to be ready in 1903.

(\*)—"Clinical Veterinary Medicine and Surgery." By P. J. Cadiot. Translated, edited, and supplemented with 49 new articles and 34 illustrations by Jno. A. W. Dollar, M.R.C.V.S. Royal 8vo, 619 pages, 94 black and white illustrations.....5 25

*See also "Dollar."*

(\*\*) **CHAPMAN.** "Manual of the Pathological Treatment of Lameness in the Horse," treated solely by mechanical means. By George T. Chapman. 8vo, cloth, 124 pages..... 2 00

**CHAUVEAU.** "The Comparative Anatomy of the Domesticated Animals." By A. Chauveau. New edition, translated, enlarged and entirely revised by Geo. Fleming, F.R.C.V.S. 8vo, cloth, 585 illus...6 25

**CLARKE.** "Chart of the Feet and Teeth of Fossil Horses." By W. H. Clarke.....25

**CLEAVELAND.** "Pronouncing Medical Lexicon." Pocket edition. Cloth.....75

**CLEMENT.** "Veterinary Post Mortem Examinations." By A. W. Clement, V.S. Records of autopsies, to be of any value, should accurately represent the appearances of the tissues and organs so that a diagnosis might be made by the reader were not the examiners' conclusions stated. To make the pathological conditions clear to the reader, some definite system of dissection is necessary. The absence in the English language, of any guide in making autopsies upon the lower animals, induced Dr. Clement to write this book, trusting that it would prove of practical value to the profession. 12mo, cloth, illustrated.....75

(\*) **COURTENAY.** "Manual of the Practice of Veterinary Medicine." By Edward Courtenay, V.S. Revised by Frederick T. G. Hobday, F.R.C.V.S. Second edition. Crown, 8vo, cloth.....2 75

**COX.** "Horses : In Accident and Disease." The sketches introduced embrace various attitudes which have been observed, such as in choking ; the disorders and accidents occurring to the stomach and intestines ; affection of the brain ; and some special forms of lameness, etc. By J. Roalfe Cox, F.R.C.V.S. 8vo, cloth, fully illustrated .....1 50

**CURTIS.** "Horses, Cattle, Sheep and Swine." The origin, history, improvement, description, characteristics, merits, objections, etc. By Geo. W. Curtis, M.S.A. Superbly illustrated. Cloth, \$2 00; half sheep, \$2.75; half morocco.....3 50

(\*\*) **DALRYMPLE.** "Veterinary Obstetrics." A compendium for the use of advanced students and Practitioners. By W. H. Dalrymple, M. R. C. V. S., principal of the Department of Veterinary Science in the Louisiana State University and A. & M. College; Veterinarian to the Louisiana State Bureau of Agriculture, and Agricultural Experiment Stations; Member of the United States Veterinary Medical Associations, etc. 8vo, cloth, illus.....2 50

**DALZIEL.** "The Fox Terrier." Illustrated. (Monographs on British Dogs). By Hugh Dalziel.....1 00

— "The St. Bernard." Illustrated.....1 00

— "The Diseases of Dogs." Their Pathology, Diagnosis and Treatment, with a dictionary of Canine Materia Medica. By Hugh Dalziel. 12mo, cloth.....80

— "Diseases of Horses." 12mo, cloth.....1 00

— "Breaking and Training Dogs." Being concise directions for the proper education of dogs, both for the field and for companions. Second edition, revised and enlarged. Part I, by Pathfinder; Part II, by Hugh Dalziel. 12mo, cloth, illus....2 60

— "The Collie." Its History, Points, and Breeding. By Hugh Dalziel. Illustrated, 8vo, cloth.....1 00

— "The Greyhound." 8vo, cloth, illus.....1 00

**DANA.** "Tables in Comparative Physiology." By Prof. C. L. Dana, M.D.....25

**DANCE.** "Veterinary Tablet." Folded in cloth case. The tablet of A. A. Dance is a synopsis of the diseases of horses, cattle and dogs, showing *at a glance* the causes, symptoms and cures .....75

- (\*) **DE BRUIN.** "Bovine Obstetrics." By M. G. De Bruin, Instructor of Obstetrics at the State Veterinary School in Utrecht. Translated by W. E. A. Wyman, formerly Professor of Veterinary Science at Clemson A. & M. College, and Veterinarian to the South Carolina Experiment Station.  
8vo, cloth, 382 pages, 77 illustrations..... 5 00

**Synopsis of the Essential Features of the Work**

1. Authorized translation.
2. The only obstetrical work which is up to date.
3. Written by Europe's leading authority on the subject.
4. Written by a man who has practiced the art a lifetime.
5. Written by a man who, on account of his eminence as bovine practitioner and teacher of obstetrics, was selected by Prof. Dr. Fröhner and Prof. Dr. Bayer (Berlin and Vienna), to discuss bovine obstetrics, both practically and scientifically.
6. The only work containing a thorough differential diagnosis of ante and post partum diseases.
7. The only work doing justice to modern obstetrical surgery and therapeutics.
8. Written by a man whose practical suggestions revolutionized the teaching of veterinary obstetrics even in the great schools of Europe.
9. The only work dealing fully with the now no longer obscure contagious and infectious diseases of calves.
10. Absolutely original and no compilation.
11. The only work dealing fully with the difficult problem of teaching obstetrics in the colleges.
12. The only work where the practical part is not overshadowed by theory.

. . . A veterinarian, particularly if his location brings him in contact with obstetrical practice, who makes any pretence toward being scientific and in possession of modern knowledge upon this subject, will not be without this excellent work, as it is really a very valuable treatise. It contains nearly 400 pages, numerous illustrations, and is put together in Jenkins' best style.—*Prof. Roscoe R. Bell, in the American Veterinary Review.*

In translating into English Professor De Bruin's excellent textbook on Bovine Obstetrics, Dr. Wyman has laid British and American veterinary surgeons and students under a debt of gratitude. The work represents the happy medium between the booklets which are adapted for cramming purposes by the student, and the ponderous tomes which, although useful to the teacher, are not exactly suited to the requirements of the everyday practitioner . . . It contains seventy-seven excellent illustrations . . . Both translator and publisher have done their work in a way that deserves praise, and we can strongly recommend the work to veterinary students and practitioners.—*The Journal of Comparative Pathology and Therapeutics.*

This grand volume, written by Europe's leading authority on the subject, who has practiced the art for a lifetime, is the most recent and up-to-date obstetrical work. It discusses bovine obstetrics, both practically and scientifically, and contains thorough differential diagnoses of ante and post mortem diseases. It deals fully with the now no longer obscure contagious and infectious diseases of calves, and is the only work of the kind in which the practical part is not overshadowed by theory.—*American Agriculturist, Aug., 1902.*

See also "Wyman."

(\*) **DOLLAR.** "Clinical Veterinary Medicine and Surgery." By P. J. Cadiot. Translated, edited, and supplemented with 49 new articles and 34 illustrations by Jno. A. W. Dollar, M.R.C.V.S. Royal 8vo, 619 pages, 94 black and white illustrations. . . . . 5 25

. . . This work, containing as it does the ripe experience of the author, who may be considered one of the foremost surgeons and clinicians of the day, contains a vast amount of exact scientific information of the utmost value to the busy workaday practitioner, while for the student of either human or comparative medicine, no better book could be placed in their hands, that will give them a clear insight into the many intricate problems with which they are daily confronted. . . .—*American Veterinary Review.*

*See also "Cadiot."*

(\*)— "Operative Technique." For veterinary surgeons. Being the first volume of a new work on the practice of veterinary surgery. By Jno. A. W. Dollar, M.R.C.V.S. 8vo, cloth . . . . . 3.75

(\*\*)— "A Hand-book of Horse-Shoeing," with introductory chapters on the anatomy and physiology of the horse's foot. By Jno. A. W. Dollar, M.R.C.V.S., translator and editor of Möller's "Veterinary Surgery," "An Atlas of Veterinary Surgical Operations," etc.; with the collaboration of Albert Wheatley, F.R.C.V.S. 8vo, cloth, 433 pp., 406 illustrations. . . 4.75

— "Roaring in Horses." By Prof. P. J. Cadiot. Translated by Dr. Dollar. Cloth, illustrated. . . . . 75  
*See also "Cadiot."*

— "Operative Veterinary Surgery." By Prof. Dr. H. Möller. Translated by Dr. Dollar. 8vo, cloth, illustrated. . . . . 5 25  
*See also "Moller."*

**DUN.** "Veterinary Medicines, their Actions and Uses." By Finlay Dun, V.S., late lecturer on *Materia Medica* and *Dietetics* at the Edinburgh Veterinary College, and Examiner in Chemistry to the Royal College of Veterinary Surgeons. New (tenth) revised and enlarged English edition. 8vo, cloth.....3 75

The new volume has been carefully revised, adapted to the official British Pharmacopœia, 1898, and brought up to date by Prof. James Macqueen, F.R.C.V.S., Royal Veterinary College, London. Clinical experiments and therapeutic observations—which form the basis of the rational treatment of disease—directions for using mallein, tuberculin, and Black-quarter vaccine, and all the more important recently introduced medicines have been added. An index of diseases and remedies, supplemented by a copious index of medicines, will enhance the usefulness of the book to students and practitioners.

**DWYER.** "Seats and Saddles." Bits and Biting, Draught and Harness and the Prevention and Cure of Restiveness in Horses. By Francis Dwyer. Illustrated. 1 vol., 12mo, cloth, gilt.....1 50

**FLEMING.** "Veterinary Obstetrics." Including the Accidents and Diseases incident to Pregnancy, Parturition, and the Early Age in Domesticated Animals. By Geo. Fleming, F.R.C.V.S. Illustrated .....6 25

— "Operative Veterinary Surgery." Part I, by Dr. Geo. Fleming, M.R.C.V.S. This valuable work, one of the most practical treatises yet issued on the subject in the English language, is devoted to the common operations of Veterinary Surgery; and the concise descriptions and directions of the text are illustrated with numerous wood engravings. 8vo, cloth.....2 75

(\*) Part II, containing nearly 500 pages and 400 illustrations, edited and passed through the press by Principal W. Owen Williams, F.R.C.V.S. 8vo, cloth.....3 25

**FLEMING.** "Tuberculosis." From a Sanitary and Pathological Point of View. By Geo. Fleming, F.R.C.V.S. ....25

— "The Contagious Diseases of Animals." Their influence on the wealth and health of nations. 12mo, paper... 25

— "The Comparative Anatomy of the Domesticated Animals." By A. Chaveau. Translated by Dr. Fleming. 8vo, cloth, illustrated .....6 25  
*See also "Chaveau."*

— "Human and Animal Variolæ." A Study in Comparative Pathology. Paper .....25

— "Animal Plagues." Their History, Nature, and Prevention. By George Fleming, F. R. C. V. S., etc. First Series. 8vo, cloth .....6 00  
Second Series. 8vo, cloth .....3 00

— "Roaring in Horses." By Dr. George Fleming, F.R.C.V.S. A treatise on this peculiar disorder of the Horse, indicating its method of treatment and curability. 8vo, cloth, with col. plates .....1 50

**FLEMING-NEUMANN.** "Parasites and Parasitic Diseases of the Domesticated Animals." A work to which the students of human or veterinary medicine, the sanitarian, agriculturist or breeder or rearer of animals, may refer for full information regarding the external and internal Parasites—vegetable and animal—which attack various species of Domestic Animals. A Treatise by L. G. Neumann, Professor at the National Veterinary School of Toulouse. Translated and edited by George Fleming, C. B., L.L.D., F.R.C.V.S. 873 pages, 365 illustrations, cloth, 7 50

- GRESSWELL.** "Diseases and Disorders of the Horse."  
By Albert, James B. and George Gresswell.  
Crown, 8vo, illustrated, cloth.....1 75
- Manual of "The Theory and Practice of Equine Medicine."  
By James B. Gresswell, F.R.C.V.S., and Albert  
Gresswell, M.R.C.V.S., second edition, enlarged,  
8vo, cloth.....2 75
- "Veterinary Pharmacology and Therapeutics." By  
James B. Gresswell, F.R.C.V.S. 16mo, cloth ...1 50
- "The Bovine Prescriber." For the use of Veterina-  
rians and Veterinary Students. By James B. and  
Albert Gresswell, M.R.C.V.S. Cloth.....75
- "The Equine Hospital Prescriber." For the use of Veter-  
inary Practitioners and Students. By Drs. James  
B. and Albert Gresswell, M.R.C.V.S. Cloth.....75
- "Veterinary Pharmacopœia, Materia Medica and  
Therapeutics." By George and Charles Gresswell,  
with descriptions and physiological actions of medi-  
cines. By Albert Gresswell.  
Crown, 8vo, cloth.....2 75
- GOTTHEIL.** "A Manual of General Histology."  
By Wm. S. Gottheil, M.D., Professor of Pathology in  
the American Veterinary College, New York; etc., etc.  
Histology is the basis of the physician's art, as  
Anatomy is the foundation of the surgeon's science.  
Only by knowing the processes of life can we under-  
stand the changes of disease and the action of  
remedies; as the architect must know his building  
materials, so must the practitioner of medicine know  
the intimate structure of the body. To present this  
knowledge in an accessible and simple form has  
been the author's task.  
8vo., cloth, 148 pages, fully illustrated .....1 00



**HASSLOCH.** "A Compend of Veterinary Materia Medica and Therapeutics." By Dr. A. C. Hassloch, V.S., Lecturer on Materia Medica and Therapeutics, and Professor of Veterinary Dentistry at the New York College of Veterinary Surgeons and School of Comparative Medicine, N. Y. 12mo, cloth, 225 pages . . . 1 50

**HEATLEY.** "The Stock Owner's Guide." A handy Medical Treatise for every man who owns an ox or cow. By George S. Heatley, M.R.C.V. 12mo, cloth. . . 1 25

— "The Horse Owner's Safeguard." A handy Medical Guide for every Horse Owner. 12mo, cloth. . . . . 1 50

— "Practical Veterinary Remedies." 12mo, cloth. . . . . 1 00

**HILL.** "The Management and Diseases of the Dog." Containing full instructions for Breeding, Rearing and Kenneling Dogs. Their Different Diseases. How to detect and how to cure them. Their Medicines, and the doses in which they can be safely administered. By J. Woodroffe Hill, F.R.C.V.S. 12mo, cloth, extra fully illustrated. . . . . 2 00

(\*)**HILL.** "The Diseases of the Cat." By J. Woodroffe Hill, F.R.C.V.S. 12mo, cloth, illustrated. . . . . 1 25

Written from the experience of many years' practice and close pathological research into the maladies to which our domesticated feline friends are liable—a subject which it must be admitted has not found not prominence in veterinary literature to which it is undoubtedly entitled.

**HINEBAUCH.** "Veterinary Dental Surgery." For the use of Students, Practitioners and Stockmen. 12mo, cloth, illustrated. . . . . 2 00  
Sheep. . . . . 2 75

**HOARE.** "A Manual of Veterinary Therapeutics and Pharmacology." By E. Wallis Hoare, F.R.C.V.S. 12mo, cloth, 560 pages.....2 75

"Deserves a good place in the libraries of all veterinarians. \* \* \* Cannot help but be of the greatest assistance to the young veterinarian and the every day busy practitioner."—*American Veterinary Review*.

(\*)**HOBDAY.** "Canine and Feline Surgery." By Frederick T. G. Hobday, F.R.C.V.S., Professor in Charge of the Free Out-Patients' Clinique at the Royal Veterinary College, London. The work contains 76 illustrations in the text. Demy 8vo, 152 pp., full-bound cloth.2 00

(\*\*) **HUNTING.** *The Art of Horse-shoeing.* A manual for Farriers. By William Hunting, F.R.C.V.S., ex-president of the Royal College of Veterinary Surgeons. One of the most up-to-date, concise books of its kind in the English language. 8vo, cloth, with nearly 100 illustrations.....1 00

(\*\*) **JENKINS.** "Model of the Horse.".....7 50  
*See also "Banham."*

(\*\*) **KOBERT.** "Practical Toxicology for Physicians and Students." By Professor Dr. Rudolph Kobert, Medical Director of Dr. Brehmer's Sanitarium for Pulmonary Diseases at Goerbersdorf in Silesia (Prussia), late Director of the Pharmacological Institute, Dorpat, Russia. Translated and edited by L. H. Friedburg, Ph.D. Authorized Edition. 8vo, cloth.2 50

**KOCH.** "Etiology of Tuberculosis." By Dr. R. Koch. Translated by T. Saure. 8vo, cloth.....1 00

**KEATING.** "A New Unabridged Pronouncing Dictionary of Medicine." By John M. Keating, M.D., LL.D., Henry Hamilton and others. A voluminous and exhaustive hand-book of Medical and scientific terminology with Phonetic Pronunciation, Accentuation, Etymology, etc. With an appendix containing important tables of Bacilli, Microcci Leucomaines, Ptomaines; Drugs and Materials used in Antiseptic Surgery; Poisons and their antidotes; Weights and Measures; Themometer Scales; New Official and Unofficial Drugs, etc., etc. 8vo, 818 pages . . . . 5 00

**LAMBERT.** "The Germ Theory of Disease." Bearing upon the health and welfare of man and the domesticated animals. By James Lambert, F.R.C.V.S. 8vo. paper . . . . . 25

**LAW.** "Farmers' Veterinary Adviser." A Guide to the Prevention and Treatment of Disease in Domestic Animals. By Prof. James Law. Illus., 8vo, cloth. 3 00

(\*\*)**LEGGE.** "Cattle Tuberculosis." A Practical Guide to the Farmer, Butcher and Meat Inspector. By T.M. Legge, M.A., M.D., D.P.H., Secretary of the Royal Commission on Tuberculosis, 1896-98; author of "Public Health in European Capitals," and "Harold Sessions, F.R.C.V.S." Cloth . . . . . 1 00

(\*)**LIAUTARD.** "A Treatise on Surgical Therapeutics of the Domestic Animals." By Prof. Dr. P.J. Cadiot and J. Almy. Translated by Prof. Liautard.

Part I, Volume I. . . . . 1 00  
 Part II, " . . . . . 1 00  
 Part III, " . . . . . 1 00

(Part IV in preparation.)  
 See also "Cadiot."

**LIAUTARD. "Median Neurotomy in the Treatment of Chronic Tendinitis and Periostosis of the Fetlock."**

By C. Pellerin, late Repetitor of Clinic and Surgery to the Alfort Veterinary School. Translated with additional facts relating to it, by Prof. A. Liautard, M.D., V.M.

Having rendered good results when performed by himself, the author believes the operation, which consists in dividing the cubito-plantar nerve and in excising a portion of the peripheral end, the means of improving the conditions, and consequently the values of many apparently doomed animals. Agriculture in particular will be benefited.

The work is divided into two parts. The first covers the study of Median Neurotomy itself; the second, the exact relations of the facts as observed by the author. 8vo., boards.....1 00

- **"Manual of Operative Veterinary Surgery."** By A. Liautard, M.D., V.M., Principal and Professor of Anatomy, Surgery, Sanitary Medicine and Jurisprudence in the American Veterinary College; Chevalier du Merite Agricole de France, Honorary Fellow of the Royal College of Veterinary Surgeons (London), etc., etc. 8vo, cloth, 786 pages and nearly 600 illustrations.....6 00

- (\*)— **"Animal Castration."** A concise and practical Treatise on the Castration of the Domestic Animals. The only work on the subject in the English language. Illustrated with 52 cuts, having a fine portrait of the author. A new revised and enlarged edition, 1902. 12mo, cloth. ....2 00

. . . . . The most complete and comprehensive work on the subject in English veterinary literature.—*American Agriculturist*, July 19th, 1902.

- **"Exercises in Equine Surgery."** By Prof. Dr. P. J. Cadiot. Translated by Prof. Bitting and edited by Dr. Liautard. 8vo, cloth, illustrated .....2 50

*See also "Cadiot."*

- LIAUTARD.** "On the Lameness of Horses." By A. Liautard, M.D., V.S. .... 2 50
- "How to Tell the Age of the Domestic Animal." By Dr. A. Liautard, M.D., V.S. Profusely illustrated. 12mo, cloth ..... 50
- "Vade Mecum of Equine Anatomy." By A. Liautard, M.D.V.S. Dean of the American Veterinary College. 12mo, cloth. New edition, with illustrations ... 2 00
- "Translation of Zundel on the Horse's Foot." Cloth.. 2 00
- LONG.** "Book of the Pig." Its selection, Breeding, Feeding and Management. 8vo, cloth ..... 4 25
- (\*\*) **LOWE.** "Breeding Racehorses by the Figure System." Compiled by the late C. Bruce Lowe. Edited by William Allison, "The Special Commissioner," *London Sportsman*, Hon. Secretary Sporting League, and Manager of the International Horse Agency and Exchange. With numerous fine illustrations of celebrated horses. Quarto, cloth ..... 7 50
- (\*) **LUDLOW.** "Science in the Stable"; or How a Horse can be Kept in Perfect Health and be Used Without Shoes, in Harness or under the Saddle. With the Reason Why. Second American Edition. Enlarged and Exemplified. By Jacob R. Ludlow, M.D. Late Staff Surgeon, U. S. Army. Paper, 166 pages..... 50
- LUPTON.** "Horses: Sound and Unsound," with Law relating to Sales and Warranty. By J. Irvine Lupton, F.R.C.V.S. 8vo, cloth, illustrated..... 1 25
- "The Horse." As he Was, as he Is, and as he Ought to Be. By J. I. Lupton, F.R.C.V.S. Illus., Crown, 8vo.. 1 40

**MAGNER.** "Facts for Horse Owners." By D. Magner.  
Upwards of 1,000 pages, illustrated with 900 engravings. 8vo, leather binding. ....7 50

**MAYHEW.** "The Illustrated Horse Doctor." An accurate and detailed account of the Various Diseases to which the Equine Race is subject; together with the latest mode of Treatment, and all the Requisite Prescriptions written in plain English. By E. Edward Mayhew, M.R.C.V.S. Illustrated.  
8vo, cloth.....2 75

**McBRIDE.** "Anatomical Outlines of the Horse."  
12mo, cloth. Reduced to.....1 50

**McCOMBIE.** "Cattle and Cattle Breeders." Cloth.....1 00

(\*)**MPFADYEAN.** "Anatomy of the Horse." Second edition completely revised. A Dissection Guide. By John M'Fadyean, M.B., B.Sc., F.R.S.E., Principal of the Royal Veterinary College, London.  
8vo, cloth .....5 50

This book is intended for Veterinary students, and offers to them in its 48 full-page colored plates 54 illustrations and excellent text, the most valuable and practical aid in the study of Veterinary Anatomy, especially in the dissecting room.

— "Comparative Anatomy of the Domesticated Animals."

By J. M'Fadyean. Profusely illustrated, and to be issued in two parts.

Part I—Osteology, ready. Paper, 2.50; cloth....2.75

(Part II in preparation.)

**MILLS.** "How to Keep a Dog in the City." By Wesley Mills, M.D., V.S. It tells how to choose, manage, house, feed, educate the pup, how to keep him clean and teach him cleanliness. Paper.....25

**MOLLER.** "Operative Veterinary Surgery." By Professor Dr. H. Moller, Berlin. Translated and edited from the 2nd edition, enlarged and improved, by John A. W. Dollar. M.R.C.S.

Prof. Moller's work presents the most recent and complete exposition of the Principles and Practice of Veterinary Surgery, and is *the standard text-book on the subject throughout Germany.*

Many subjects ignored in previous treatises on Veterinary Surgery here receive full consideration, while the better known are presented under new and suggestive aspects.

As Prof. Moller's work represents not only his own opinions and practice, but those of the best Veterinary Surgeons of various countries, the translation cannot fail to be of signal service to American and British Veterinarians and to Students of Veterinary and Comparative Surgery.

1 vol., 8vo. 722 pages, 142 illustrations . . . . .5 25

**MORETON.** "On Horse-breaking." 12mo, cloth..... 50

**MOSELMAN-LIENAU.** "Veterinary Microbiology." By Professors Mosselman and Liénaux, Nat. Veterinary College, Cureghem, Belgium. Translated and edited by R. R. Dinwiddie, Professor of Veterinary Science, College of Agriculture, Arkansas State University. 12mo, cloth, 342 pages..... 2 00

**NOCARD.** "The Animal Tubercloses, and their Relation to Human Tuberculosis." By Ed. Nocard, Prof. of the Alfort Veterinary College. Translated by H. Scurfield, M.D. Ed., Ph. Camb. 12mo, cloth, 143 pages....1 00

Perhaps the chief interest to doctors of human medicine in Professor Nocard's book lies in the demonstration of the small part played by heredity, and the great part played by contagion in the propagation of bovine tuberculosis. It seems not unreasonable to suppose that the same is the case for human tuberculosis, and that, if the children of tuberculosis parents were protected from infection by cohabitation or ingestion, the importance of heredity as a cause of the disease, or even of the predisposition to it, would dwindle away into insignificance.

**PEGLER.** "The Book of the Goat." 12mo, cloth.....1 75

**PELLERIN.** "Median Neurotomy in the Treatment of Chronic Tendinitis and Periostosis of the Fetlock." By C. Pellerin, late repetitor of Clinic and Surgery to the Alfort Veterinary School. Translated, with Additional Facts Relating to It, by Prof. A. Liautard, M.D., V.M. 8vo, boards, illustrated..... 1 00

*See also "Liautard."*

**PETERS.** "A Tuberculous Herd—Test with Tuberculin." By Austin Peters, M. R. C. V. S., Chief Inspector of Cattle for the New York State Board of Health during the winter of 1892-93. Pamphlet.... 25

**REYNOLD.** "Breeding and Management of Draught Horses." 8vo, cloth..... 1 40



**ROBERGE.** "The Foot of the Horse," or Lameness and all Diseases of the Feet traced to an Unbalanced Foot Bone, prevented or cured by balancing the foot. By David Roberge. 8vo, cloth..... 5 00

**SEWELL.** "The Examination of Horses as to Soundness and Selection as to Purchase." By Edward Sewell, M.R.C.V.S. 8vo, paper..... 1 50

.... It is a great advantage to the business man to know something of the elements of law, and nobody ought either to buy or own a horse who does not know something about the animal. That something this book gives, and gives in a thoroughly excellent way....

—*Our Animal Friends.*

**SMITH.** "A Manual of Veterinary Physiology." By Veterinary Captain F. Smith, M.R.C.V.S. Author of "A Manual of Veterinary Hygiene."

Throughout this manual the object has been to condense the information as much as possible. The broad facts of the sciences are stated so as to render them of use to the student and practitioner. In this second edition—rewritten—the whole of the Nervous System has been revised, a new chapter dealing with the Development of the Ovum has been added together with many additional facts and illustrations. About one hundred additional pages are given. *Second edition*, revised and enlarged, with additional illustrations ..... 3 75

— "Manual of Veterinary Hygiene." 2nd edition, revised. Crown, 8vo, cloth ..... 3 25

(\*\*)**STRANGEWAY.** "Veterinary Anatomy." Edited by I. Vaughan, F.L.S., M.R.C.V.S. New edition revised, with several hundred illustrations. 8vo, cloth.... 5 00

**SUSSDORF.** "Large Colored Wall Diagrams." By Prof. Sussdorf, M.D. (of Göttingen). Text translated by Prof. W. Owen Williams, of the New Veterinary College, Edinburgh. Size, 44 inches by 30 inches.

- |           |                   |
|-----------|-------------------|
| 1.—Horse. | 4.—Ox.            |
| 2.—Mare.  | 5.—Boar and Sow.  |
| 3.—Cow.   | 6.—Dog and Bitch. |

Showing the position of the viscera in the large cavities of the body.

Price, unmounted..... 1 75 each  
 " mounted on linen; with roller... 3 50 "

(\*)**THOMPSON.** "Elementary Lectures on Veterinary Science." For agricultural students, farmers and stock keepers. By Henry Thompson, M.R.C.V.S., lecturer on Veterinary Science at the Aspatria Agricultural College, England.

8vo, cloth, 397 pages, 51 illustrations ..... 3 75

It is complete yet concise and just the up-to-date book for a beginner.

**VAN MATER.** "A Text Book of Veterinary Ophthalmology." By George G. Van Mater, M.D., D.V.S., Professor of Ophthalmology in the American Veterinary College; Oculist and Aurist to St. Martha's Sanitarium and Dispensary; Consulting Eye and Ear Surgeon to the Twenty-sixth Ward Dispensary; Eye and Ear Surgeon, Brooklyn Eastern District Dispensary, etc. Illustrated by one chromo lithograph plate and seventy-one engravings.

8vo cloth..... 3 00

. . . We intend to adopt this valuable work as a text book.—*E. J. Creely, D.V.S.*, Dean of the San Francisco Veterinary College. May 16th, 1902.

**VETERINARY DIAGRAMS** in Tabular Form.

Size, 28½ in. x 22 inches. Price per set of five.... 4 75

**No. 1. "The External Form and Elementary Anatomy of the Horse."** Eight colored illustrations—  
1. External regions; 2. Skeleton; 3. Muscles (Superior Layer); 4. Muscles (Deep Layer); 5. Respiratory Apparatus; 6. Digestive Apparatus; 7. Circulatory Apparatus; 8. Nerve Apparatus; with letter-press description ..... 1 25

**No. 2. "The Age of Domestic Animals."** Forty-two figures illustrating the structure of the teeth, indicating the Age of the Horse, Ox, Sheep, and Dog, with full description ..... 75

**No. 3. "The Unsoundness and Defects of the Horse."** Fifty figures illustrating—1. The Defects of Conformation; 2. Defects of Position; 3. Infirmities or Signs of Disease; 4. Unsoundnesses; 5. Defects of the Foot; with full description..... 75

**No. 4. "The Shoeing of the Horse, Mule and Ox."** Fifty figures descriptive of the Anatomy and Physiology of the Foot and of Horse-shoeing..... 75

**No. 5. "The Elementary Anatomy, Points, and Butcher's Joints of the Ox."** Ten colored illustrations—1. Skeleton; 2. Nervous System; 3. Digestive System (Right Side); 4. Respiratory System; 5. Points of a Fat Ox; 6. Muscular System; 7. Vascular System; 8. Digestive System (Left Side); 9. Butcher's Sections of a Calf; 10. Butcher's Sections of an Ox; with full description ..... 1 25

**WALLEY. "Four Bovine Scourges."** (Pleuro-Pneumonia, Foot and Mouth Disease, Cattle Plague and Tubercle.) With an Appendix on the Inspection of Live Animals and Meat.

Illustrated, 4to, cloth..... 6 40

- (\*) **WALLEY.** "A Practical Guide to Meat Inspection." By Thomas Walley, M.R.C.V.S., formerly principal of the Edinburgh Royal (Dick) Veterinary College; Professor of Veterinary Medicine and Surgery, etc. Fourth Edition, thoroughly revised and enlarged by Stewart Stockman, M.R.C.V.S., Professor of Pathology, Lecturer on Hygiene and Meat Inspection at Dick Veterinary College, Edinburgh.  
12mo, cloth, with 45 colored illus., 295 pages. . . . 3 00

An experience of over 30 years in his profession and a long official connection (some sixteen years) with Edinburgh Abattoirs have enabled the author to gather a large store of information on the subject, which he has embodied in his book. Dr. Walley's opinions are regarded as the highest authority on Meat Inspection.

This fourth is an entirely re-written and enlarged edition, and while Dr. Stockman is indeed indebted to the old for much useful information, this up-to-date work will hardly be recognized as the old "Walley's Meat Inspection." It will be found the most valuable work on the subject in the English language, has many illustrations, many of which are colored, and a complete index.

- WILLIAMS.** "Principles and Practice of Veterinary Medicine." Author's edition, entirely revised and illustrated with numerous plain and colored plates. By W. Williams, M.R.C.V.S.  
8vo., cloth. . . . . 6 00

- "Principles and Practice of Veterinary Surgery." Author's edition, entirely revised and illustrated with numerous plain and colored plates. By W. Williams, M.R.C.V.S.  
8vo., cloth. . . . . 6 00

THE MOST COMPLETE, PROGRESSIVE AND  
SCIENTIFIC BOOK ON THE SUBJECT IN  
THE ENGLISH LANGUAGE

(\*) **WINSLOW.** "Veterinary Materia Medica and Therapeutics." By Kenelm Winslow, B.A.S., M.D.V., M.D., (Harv.); formerly Assistant Professor of Therapeutics in the Veterinary School of Harvard University; Fellow of the Massachusetts Medical Society; Surgeon to the Newton Hospital, etc.

*Second Edition Revised.*

8vo, cloth, 750 pages.....6 00

Your letter received and I am pleased to know that we are to have an American Materia Medica.—*J. H. Wattles, Sr., M.D., D.V.S.,* The Western Veterinary College, Kansas City, Mo.

. . . Am delighted with it. It is remarkably correct, complete and up to date and is bound to supersede any other work on the same subject heretofore before the profession.

No practitioner's library is complete without it and it will be indispensable for students, as it does away with the necessity of their having a number of collateral books on the subject.

It will be adopted as the text book in the Chicago Veterinary College.—*Dr. E. L. Quitman,* Chicago Veterinary College.

. . . The book is of admirable merit and full of valuable information from beginning to end, very explicit, rich and interesting, and should be in the hands of every student as well as practitioner of the art of Veterinary Medicine.—*Thurston Müller, M.D.,* Professor of Materia Medica, Therapeutics and Chemistry, San Francisco Veterinary College.

. . . I have found the book very satisfactory as a reference book to be used in connection with lectures. . .—*Dr. W. A. Landacre,* College of Pharmacy, Ohio State University.

I consider it the only work on materia medica and therapeutics suitable to the American veterinary practitioner. It deserves a wide distribution among veterinarians. I have recommended it to my students.—*John J. Repp, V.M.D.,* Iowa State College, Ames, Iowa.

- (\*\*) **WYMAN.** "The Clinical Diagnosis of Lameness in the Horse." By W. E. A. Wyman, V.S., formerly Professor of Veterinary Science, Clemson A. & M. College, and Veterinarian to the South Carolina Experiment Station. 8vo, cloth, illustrated.....2 50
- (\*)— "Bovine Obstetrics." By M. G. De Bruin, Instructor of Obstetrics at the State Veterinary School in Utrecht. Translated by W. E. A. Wyman, M.D.V., V.S., formerly Professor of Veterinary Science, Clemson A. & M. College, and Veterinarian to the South Carolina Experiment Station.  
8vo, cloth, 382 pages, 77 illustrations.....5 00  
*See also "De Bruin."*
- (\*)— "Tibio-peroneal Neurectomy for the Relief of Spavin Lameness." By W. E. A. Wyman, M.D.V., V.S.  
8vo, boards, 30 pages. .... 50  
Anyone wanting to perform this operation should procure this little treatise; he will find it of considerable help.—*The Veterinary Journal*, Sept., 1902.
- ZUNDEL.** "The Horse's Foot and Its Diseases." By A. Zundel, Principal Veterinarian of Alsace Lorraine. Translated by Dr. A. Liautard, V.S. 12mo, cloth illustrated.....2 00
- ZUILL.** "Typhoid Fever; or Contagious Influenza in the Horse." By Prof. W. L. Zuill, M.D., D.V.S. Pamphlet.....25


*Our Books are for sale by all booksellers,  
or will be sent prepaid for the prices here quoted.*




**WILLIAM R. JENKINS,**

851 and 853 Sixth Avenue,

NEW YORK











Wm

~~Notes to Smith~~

- 921

