



FOR THE PEOPLE  
FOR EDUCATION  
FOR SCIENCE

LIBRARY  
OF  
THE AMERICAN MUSEUM  
OF  
NATURAL HISTORY







# The Edinburgh Veterinary Series.

*General Editor—*

**O. Charnock Bradley, M.D., D.Sc., M.R.C.V.S.,**  
Principal, Royal (Dick) Veterinary College, Edinburgh.

**A Guide to the Dissection of the Dog.** By **O. Charnock Bradley, M.D., D.Sc., M.R.C.V.S.** Demy 8vo, 15s. 1919.

**The Topographical Anatomy of the Limbs of the Horse.** By **O. Charnock Bradley, M.D., D.Sc., M.R.C.V.S.** With 115 illustrations, mostly coloured. Royal 8vo, 21s. 1920.

**Essentials of Veterinary Physiology.** By **D. Noël Paton, M.D., B.Sc., LL.D., F.R.S.,** Professor of Physiology, University, Glasgow; late Lecturer in Physiology, Royal (Dick) Veterinary College, Edinburgh; and **John Boyd Orr, D.S.O., M.C., M.A., M.D., D.Sc.,** Director, Rowett Institute for Research in Animal Nutrition, Aberdeen; Research Lecturer on Physiology of Nutrition, University, Aberdeen. Third Edition. Revised and enlarged. Royal 8vo, 25s. 1920.

**Veterinary Hygiene.** By **R. G. Linton, M.R.C.V.S.,** Professor of Hygiene, Royal (Dick) Veterinary College, Edinburgh. Royal 8vo, 26s. 1921.

**Topographical Anatomy of the Thorax and Abdomen of the Horse.** By **O. Charnock Bradley, M.D., D.Sc., M.R.C.V.S.** With 85 illustrations. Royal 8vo, 21s. 1922.

## *In Preparation.*

**Topographical Anatomy of the Head and Neck of the Horse.** By **O. Charnock Bradley, M.D., D.Sc., M.R.C.V.S.**

**A Handbook of the Law for Veterinary Surgeons.** By **James R. Gibb, Advocate.** Lecturer in Veterinary Jurisprudence, Royal (Dick) Veterinary College, Edinburgh.

**Veterinary Dietetics.** By **R. G. Linton, M.R.C.V.S.,** Professor of Hygiene, Royal (Dick) Veterinary College, Edinburgh.

The Edinburgh Veterinary Series

General Editor—

O. CHARNOCK BRADLEY, M.D., D.Sc., M.R.C.V.S.

THE THORAX AND ABDOMEN  
OF THE HORSE



PRINTED BY  
LORIMER & CHALMERS  
EDINBURGH

1922



THE  
Topographical Anatomy  
OF THE  
Thorax and Abdomen  
of the Horse

BY

O. CHARNOCK BRADLEY

M.D., D.Sc., M.R.C.V.S.

Principal, Royal (Dick) Veterinary College, Edinburgh ;  
Lecturer on Comparative Anatomy, University of Edinburgh.

EDINBURGH

W. GREEN & SON, LIMITED

1922



## P R E F A C E

THE plan of the present book is the same as that of its predecessor on *The Topographical Anatomy of the Limbs of the Horse*. Its aim is also the same, namely, to serve as a sufficiently full dissection-guide for the student, and, possibly, to help the practitioner when in doubt respecting the topography of a region.

My thanks are gratefully tendered to Mr. James T. Murray for again expending great care and patience on the preparation of drawings of dissections; to my colleague, Mr. T. Grahame, M.R.C.V.S., for help when reading the proof-sheets, and at other times; and to the publishers for their generosity in allowing a goodly number of illustrations, and for meeting my wishes in so far as the existing difficult circumstances have permitted.

O. C. B.

*April, 1922.*



## CONTENTS.

	PAGE
THE THORAX . . . . .	1
ARTERIES OF THE THORAX . . . . .	67
THE ABDOMEN . . . . .	68
THE PELVIC CAVITY . . . . .	156
THE FEMALE PELVIS . . . . .	180
ARTERIES OF THE ABDOMEN . . . . .	188
NERVE AND BLOOD SUPPLY OF THE MUSCLES OF THE THORAX AND ABDOMEN . . . . .	189
LYMPH GLANDS OF THE THORAX AND ABDOMEN . . . . .	190
THE FETAL CIRCULATION . . . . .	192
INDEX . . . . .	196



## LIST OF ILLUSTRATIONS.

FIG.	PAGE
1. Superficial dissection of the thorax and abdomen before removal of the limb . . . . .	2
2. Dissection of the chest wall, seen from the right . . . . .	4
3. Deep dissection of the back in the thoracic region . . . . .	6
4. Diagram of a typical thoracic nerve . . . . .	9
5. Diagrams to illustrate the arrangement of the pleurae in transverse sections of the thorax . . . . .	13
6. Dissection to show the relation of the lung to the chest wall . . . . .	17
7. Medial aspect of the left lung . . . . .	19
8. Medial aspect of the right lung . . . . .	20
9. The heart and great blood-vessels as seen from the left . . . . .	25
10. The heart and great blood-vessels as seen from the right . . . . .	26
11. The base of the heart with the great blood-vessels . . . . .	27
12. The base of the ventricles of the heart . . . . .	28
13. The heart and great blood-vessels viewed from the right, with the interior of the right atrium and right ventricle exposed . . . . .	30
14. The heart viewed obliquely from the left and behind, with the interior of the left atrium and left ventricle exposed . . . . .	33
15. Key outline of the heart to show the position of the sections illustrated in Figs. 16 and 17 . . . . .	34
16. Transverse section of the heart at the level indicated by the line A in Fig. 15 . . . . .	35
17. Transverse section of the heart at the level indicated by the line B in Fig. 15 . . . . .	36
18. Diagram of the arteries arising from the aortic arch . . . . .	37
19. Dissection of the thoracic contents from the left side, after removal of the lung . . . . .	39
20. Dissection of the vessels and nerves in the region of the entrance to the thorax, seen from the left . . . . .	40
21. Dissection of the thoracic contents from the right side, after removal of the lung . . . . .	43
22. Dissection of the blood-vessels, &c., of the thorax, as seen from the right side . . . . .	44
23. The blood-vessels and nerves within the first three ribs of the left side . . . . .	56
24. The blood-vessels and nerves within the first three ribs of the right side . . . . .	57
25. Scheme of the sympathetic cord and its connections with the spinal nerves . . . . .	60
26. The costo-vertebral articulations. Cranial aspect . . . . .	63
27. Costo-vertebral articulations, with associated structures . . . . .	64
28. The structures in an intercostal space, viewed from within . . . . .	65
29. The male external genital organs . . . . .	70
30. Lateral aspect of the right testis and epididymis . . . . .	72
31. Medial aspect of the right testis and epididymis . . . . .	73
32. Vertical section through the penis, scrotum and testis. Diagrammatic . . . . .	74
33. Horizontal sections through the scrotum (semi-diagrammatic) . . . . .	75
34. Diagram to illustrate the descent of the testis . . . . .	76
35. Transverse section of the penis . . . . .	78
36. Extremity of the penis . . . . .	79
37. Superficial dissection of the wall of the thorax and abdomen . . . . .	81
38. Dissection of the right flank after removal of part of the external oblique abdominal muscle . . . . .	83
39. Diagram illustrating the topography of the thoracic and abdominal viscera as seen from the right . . . . .	90

FIG.	PAGE
40. Diagram illustrating the topography of the thoracic and abdominal viscera as seen from the right . . . . .	91
41. Diagram illustrating the topography of the thoracic and abdominal viscera as seen from the left . . . . .	92
42. Diagram illustrating the topography of the thoracic and abdominal viscera as seen from the left . . . . .	93
43. Intestines as exposed by removal of the ventral wall of the abdomen . . . . .	95
44. The colon and cæcum of the horse . . . . .	97
45. The cæcum and its connections . . . . .	99
46. Diagram to illustrate the arrangement of the peritoneum in median longitudinal section . . . . .	102
47. Diagram to illustrate the arrangement of the peritoneum in horizontal section . . . . .	104
48. Scheme of the alimentary tract, &c., of an 8-mm. sheep embryo . . . . .	106
49. Diagram of the branches of the cranial mesenteric artery . . . . .	108
50. To show the manner of distribution of the intestinal arteries . . . . .	109
51. View of the interior of the cæcum showing the position of its openings . . . . .	111
52. Caudal surface of the stomach . . . . .	113
53. Cranial surface of the stomach . . . . .	114
54. The viscera of the female abdomen after removal of the intestines . . . . .	116
55. Medial aspect of the spleen . . . . .	119
56. The visceral surface of the liver . . . . .	121
57. Diagram of the branches of the coeliac artery . . . . .	124
58. Dissection of the female abdomen after removal of the intestines . . . . .	126
59. Diagram of the portal vein and its tributaries . . . . .	127
60. Longitudinal section of the stomach . . . . .	133
61. The abdominal urinary and reproductive organs of the female . . . . .	135
62. The right ovary, uterine tube, &c. . . . .	137
63. Diagrams to illustrate the development of the ovulation fossa . . . . .	138
64. Outline of the dorsal surface of the kidneys, to show the relative position, shape and relations of the two organs . . . . .	140
65. Outline of the ventral surface of the kidneys, to show the relative position, shape and relations of the two organs . . . . .	141
66. Dissection of the sublumbar region and entrance to the pelvis . . . . .	148
67. Dissection of the dorsal wall of the abdomen . . . . .	154
68. Cranial aspect of the hip-bone and sacrum, with areas of muscular attachment . . . . .	157
69. Diagram to illustrate the arrangement of the peritoneum in the male pelvis . . . . .	158
70. Dissection of the structures about the entrance to the male pelvis . . . . .	160
71. Lateral aspect of the male pelvis after removal of the sacro-spinous and sacro-tuberous ligaments . . . . .	162
72. Lateral aspect of the urinary bladder and pelvic part of the urethra of the male . . . . .	163
73. Dorsal view of the urinary bladder and intrapelvic urethra of the male, with their associated structures . . . . .	165
74. Dissection of the vessels and nerves of the male pelvis . . . . .	168
75. Transverse section of the tail on a level with the sixth coccygeal vertebra . . . . .	172
76. Lateral aspect of the pelvic vessels, nerves and organs of the male, after removal of the hip-bone . . . . .	173
77. Diagram of the arteries of the male pelvis . . . . .	174
78. Diagram of the plexus formed by the lumbar and sacral nerves . . . . .	177
79. Diagram to illustrate the arrangement of the peritoneum in the female pelvis . . . . .	181
80. Dissection of the female reproductive organs . . . . .	183
81. Dissection of female pelvis . . . . .	184
82. Viscera of the female pelvis, with reproductive and urinary organs in longitudinal section . . . . .	186
83. Fœtal circulation in the foal . . . . .	192
84. Diagram of the fetal circulation . . . . .	193
85. The fetal heart viewed from the left . . . . .	194



## THE THORAX.

THE dissection of the thorax cannot be begun until the thoracic limbs have been removed. Along with the thorax it is convenient to combine the examination of the muscles, &c., of the back and loins.

*Dissection.*—The dissector's first duty is the removal of the remains of muscles left behind on the separation of the thoracic limbs from the trunk. In doing this care should be taken not to destroy the various branches of the intercostal and lumbar nerves and vessels.

The dissection of the aponeurotic tendon of origin of the latissimus dorsi muscle demands special care if the lumbo-dorsal fascia (and origin of the dorsal serratus muscle) is not to be injured.

THE LUMBO-DORSAL FASCIA (*Fascia lumbodorsalis*).—This extensive sheet of deep fascia invests the muscles of the back and loins, but may be easily raised from the underlying longissimus dorsi. Medially it is connected with the supra-spinous ligament and the extremities of the spinous processes of the vertebræ. Caudally it is continuous with the gluteal fascia. In the region of the scapula it develops into a strong sheet, firmly attached to the spinous processes of the third, fourth and fifth thoracic vertebræ, affording origin to the rhomboid and splenius muscles and connected with the scapular attachment of the ventral serratus muscle. Later in the dissection it will be found that the lumbo-dorsal fascia sends a strong septum from its deep face between the longissimus dorsi and ilio-costalis muscles, and a weaker septum between the longissimus dorsi and spinalis muscles.

Laterally the lumbo-dorsal fascia splits into two layers, the more superficial of which constitutes the aponeurotic origin of the latissimus dorsi muscle. The deeper layer affords origin to the dorsal serratus and ilio-costalis and muscles of the abdominal wall.

MM. SERRATI DORSALES.—The two dorsal serratus<sup>1</sup> muscles form together a thin sheet extending along the greater part of the dorsal wall of the thorax. Their origin is from the lumbo-dorsal fascia, and the muscular bundles succeeding this extensive aponeurotic origin run in different directions in the two muscles.

<sup>1</sup> *Serratus* (from *serra*, a saw) [L.], toothed or notched like the edge of a saw.

*M. serratus dorsalis caudalis*.—The fibres of the caudal portion of the dorsal serratus are arranged in an oblique cranial and ventral direction. They terminate in very definite slips or digitations that are inserted into the caudal border of the last eight or nine ribs.

*M. serratus dorsalis cranialis*.—The fibres of the cranial muscle run obliquely in a ventral and caudal direction, and end in digitations that are attached to the cranial border of the ribs, from the fifth or

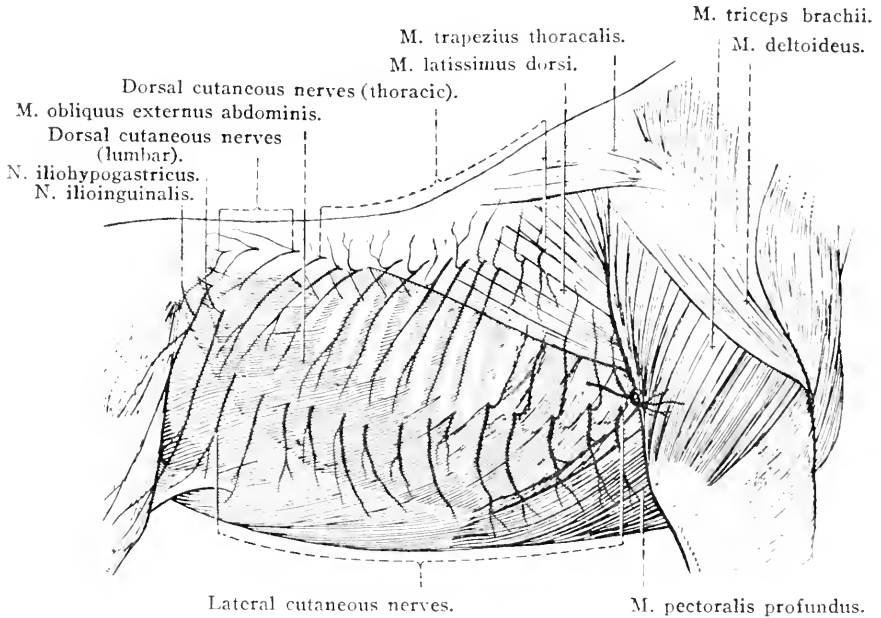


FIG. 1.—Superficial dissection of the Thorax and Abdomen before removal of the Limb.

sixth to the eleventh or twelfth. Two or three of these digitations are covered by the caudal muscle.

*Dissection*.—Reflect both serratus muscles by making a longitudinal incision through their aponeurotic tendon of origin. In reflecting these muscles it will be found that the lumbo-dorsal fascia detaches a partition that passes inwards between the adjacent borders of the longissimus dorsi and ilio-costalis muscles. This will require to be cut through before the ilio-costalis can be thoroughly exposed.

The reflection of the dorsal serratus reveals three deeper muscles. The largest and longest of these is the longissimus dorsi. It is the chief occupant of the groove formed by the ribs and the spinous processes of the vertebrae. The narrow lateral muscle, *m. ilio-costalis*, is readily distinguished by its numerous tendinous attachments to the ribs. The third muscle is the shortest and lies medial to the longissimus, with which it is continuous, where the thoracic spinous processes are longest.

The dissector will observe a series of cutaneous nerves piercing the

longissimus dorsi muscle close to its lateral border or emerging from the interval between this muscle and the ilio-costalis. These are derived from the dorsal branches of the thoracic nerves. That part of the longissimus dorsi which lies over the lumbar vertebræ is pierced by cutaneous branches of the lumbar spinal nerves. Small blood vessels, branches of the intercostal and lumbar vessels, accompany these nerves.

M. ILIOCOSTALIS.<sup>1</sup>—The composite ilio-costalis muscle has origin from the lumbo-dorsal fascia, the first two or three (or more) lumbar transverse processes, and the cranial border and lateral surface of the last fifteen ribs. The oblique bundles of fibres of which the muscle is composed, more or less blended with each other, terminate in long, narrow, flattened tendons. The tendons of the more superficial and lateral bundles cross three or four ribs, with a slight lateral inclination, to end on the caudal border of the first fourteen or fifteen ribs, close to their angles, and the transverse process of the seventh (possibly also of the sixth) cervical vertebra. The slenderer tendons of the deeper and medial bundles are directed in a caudal direction. They cross one or two ribs and end on the cranial border of the ribs from the fourth to the last. Small synovial bursæ may intervene between some of the tendons and the ribs over which they pass.

M. LONGISSIMUS DORSI.—This very long and powerful muscle is of great complexity, and extends from the sacrum to the last cervical vertebra. Close to the ilium it forms a shoaling depression into which the middle gluteal muscle extends, and from which a considerable number of the fibres of the muscle take origin. In the loins the longissimus is at its thickest, and entirely fills the space between the spinous and transverse processes of the vertebræ. Indeed, it overhangs the tips of the lumbar transverse processes. In the thoracic region the muscle gradually becomes narrower and of less thickness, until it terminates at the last cervical vertebra as a single flattened tendon. A strong, glistening tendinous sheet, particularly noticeable in the lumbar region, covers the surface of the muscle, blends with the supraspinous and sacro-iliac ligaments, and is firmly attached to the crest and sacral tuber of the ilium and the spinous processes of the first two segments of the sacrum.

The longissimus dorsi has, naturally, extensive attachments. It arises from the crest and the coxal and sacral tubers of the ilium, the transverse and spinous processes of the first and second sacral vertebræ, and the inner surface of the ilium between these points. It is attached to the spinous, transverse, articular and mammillary processes of the lumbar vertebræ, the transverse processes of the thoracic vertebræ, the

<sup>1</sup> It has been suggested that this muscle should be called *longissimus costarum*.

lateral surface of the ribs as far as their angles, and, finally, to the transverse process of the last cervical vertebra.

**M. LONGISSIMUS CERVICIS.**—If the dissection of the neck has been

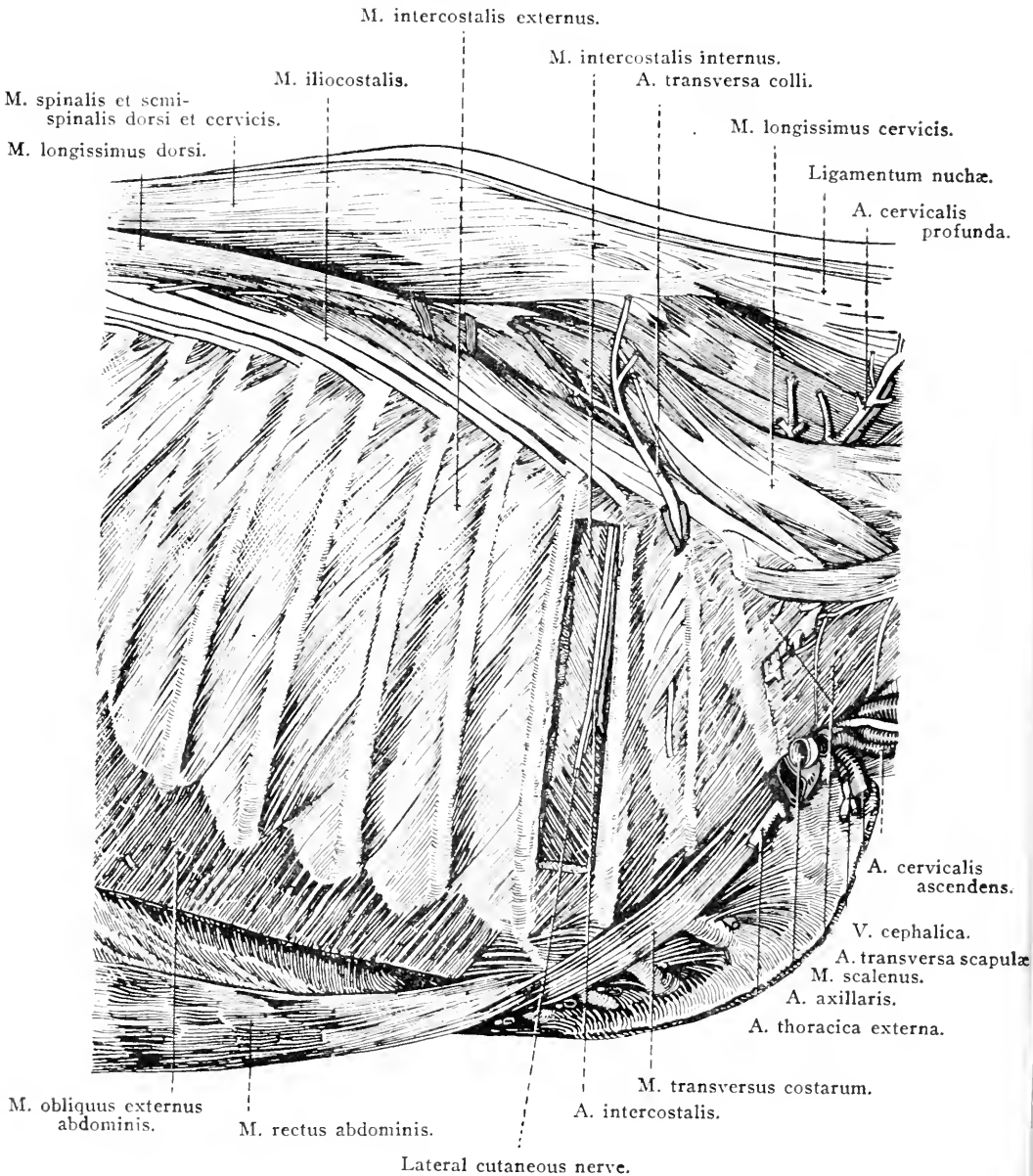


FIG. 2.—Dissection of the Chest Wall, seen from the right.

carried far enough, the dissector of the muscles of the back should examine the longissimus cervicis. This muscle appears to be a continuation of the longissimus dorsi, from which it is only separated with

difficulty. Its fibres take origin from the transverse processes of the first six thoracic vertebræ; and its insertion is to the transverse processes of the last four cervical vertebræ.

M. SPINALIS (ET SEMISPINALIS) DORSI ET CERVICIS.—The spinal muscle of the back and neck appears to be an off-shoot from the longissimus dorsi with which its caudal portion is connected in the most intimate fashion. Careful dissection shows that the muscle has tendinous connections with the spinous processes of the lumbar and the last five or six thoracic vertebræ; but it is here that the identity of the muscle is confused with that of its much larger neighbour. About the eleventh or twelfth thoracic vertebra the spinal muscle begins to become more independent. Its more cranial attachments are to the caudal border of the first five or six thoracic spinous processes and the rudimentary spinous processes of the last four or five cervical vertebræ.

*Dissection.*—Remove the longissimus dorsi and spinalis muscles. In doing so, observe the muscular branches of the dorsal rami of the intercostal and lumbar arteries.

M. MULTIFIDUS<sup>1</sup> DORSI.—A series of small muscles lie close against the vertebral column. They arise from the sacrum, the articular and mammillary processes of the lumbar and the last two or three thoracic vertebræ, and from the transverse processes of the other thoracic vertebræ. Each muscular bundle crosses from two to four spinous processes in an oblique cranial and dorsal direction to its insertion into the spinous process of a lumbar or thoracic vertebra. In the lumbar region the insertion is close to the free end of the spinous process, and this is also the case from the last to about the tenth thoracic vertebra. Thereafter, however, the insertion is further and further removed from the extremity of the process.

MM. LEVATORES COSTARUM.—The levators of the ribs form a series of small muscles arising from the transverse processes of the thoracic vertebræ. The fibres of each muscle run in a caudal, ventral and lateral direction to be inserted into the cranial border of the rib succeeding the vertebra from which they have taken origin. The first rib is not provided with a levator muscle.

MM. INTERTRANSVERSALES LUMBORUM.—Thin and weak inter-transverse muscles, containing a considerable proportion of tendinous tissue, occupy the intervals between the transverse processes of the lumbar vertebræ. Generally there is no muscle between the processes of the fifth and sixth vertebræ.

<sup>1</sup> *Multifidus* (from *multus*, many + *findere*, to cleave or split) [L.], cleft or divided into many parts.

*Dissection.*—Clean the surface of the muscles that lie between the ribs, and of the transverse costal muscle that runs obliquely over the sternal end of the first three ribs.

**M. TRANSVERSUS COSTARUM.**—The transverse costal muscle is flat and thin, and arises from the first rib ventral to the scalene tubercle. It passes obliquely in a caudal and ventral direction and ends on the

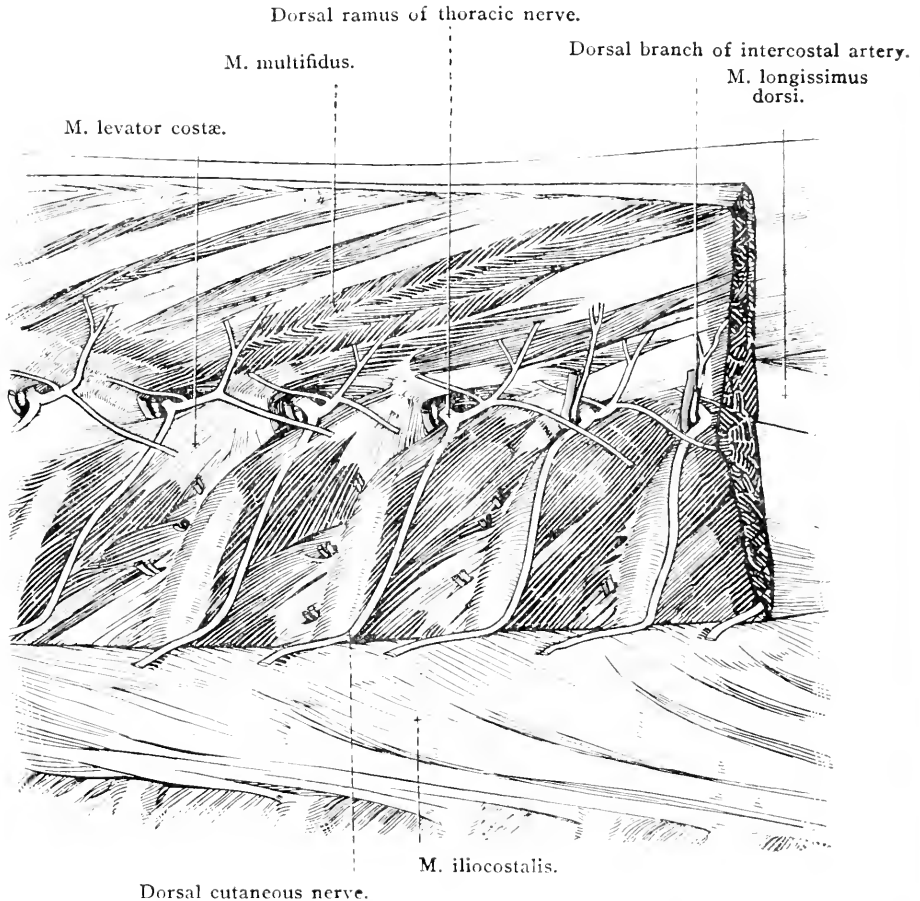


FIG. 3.—Deep dissection of the Back in the Thoracic Region.

extremities of the second, third and fourth costal cartilages and the adjacent part of the sternum.

**MM. INTERCOSTALES EXTERNI.**—On each side of the chest there are seventeen external intercostal muscles. Each passes from the caudal border of one rib to the cranial border of the next, its fibres sloping in a caudal and ventral direction. Ventrally the muscles end at the junction of the bony segment of the rib and the costal cartilage. Dorsally each muscle comes into contact with a levator of the rib, from

which it is distinguished with difficulty; indeed, the levator may be regarded as a strong and specialised part of the intercostal.

It should be noted that the degree of development of the external intercostal muscle varies greatly in different parts of the chest as well as in different individuals. In some intercostal spaces the muscular fibres may fail to reach from one rib to the next, a thin aponeurosis taking their place. In the ventral part of the last few intercostal spaces also the muscle may be very defective.

*Dissection.*—Remove the external intercostal muscles from several interspaces in order to show the underlying internal muscles. Take care not to injure the intercostal vessels and nerves that, near the vertebral column, will be found lying between the two muscles and about midway between two ribs.

MM. INTERCOSTALES INTERNI.—The seventeen internal intercostal muscles differ from the external intercostals in that their fibres run with a ventro-cranial slope, and each muscle is continued between the costal cartilages. In the neighbourhood of the sternum and costal arch, therefore, the internal muscles can be seen before the external intercostals have been removed.

Near the vertebral column the internal intercostal muscles become thin and may disappear.

AA. INTERCOSTALES.—The origin of the seventeen intercostal arteries cannot be determined at the present time. When the interior of the thorax is being examined at a later stage of the dissection, it will be found that the first intercostal arises from the deep cervical artery; the second, third and fourth (possibly also the fifth) from the supreme intercostal artery; while all the rest spring from the thoracic portion of the aorta.

Each intercostal artery divides into a small dorsal and a larger ventral branch. The *dorsal branch* (ramus dorsalis) divides into (1) a ramus spinalis that enters the vertebral canal by an intervertebral foramen, supplies small twigs to the membranes enclosing the spinal cord, and ends by joining the ventral spinal artery; and (2) a ramus muscularis that pierces the dorsal end of an intercostal space to supply the muscles and skin dorsal to the plane on a level with the bodies of the thoracic vertebræ.

The *ventral branch* (ramus ventralis) is now under examination. At first it lies between the external and internal intercostal muscles about midway between two ribs. Later it runs between the internal intercostal muscle and the pleura in a groove on the caudal border of a rib.

Each intercostal artery ends at the ventral extremity of an inter-

space by anastomosing with the intercostal branches of the internal thoracic and musculo-phrenic arteries.

In its course, an intercostal artery furnishes branches to the pleura, ribs, muscles and overlying skin.

VV. INTERCOSTALES.—Intercostal veins accompany the intercostal arteries and are to be sought between the artery and the rib. Their termination will be revealed when the interior of the thorax is being examined.

NN. INTERCOSTALES.—Intercostal nerves follow the caudal border of the arteries of the same name, and are derived from the thoracic spinal nerves. Eighteen pairs of *thoracic nerves* (nn. thoracales) leave the vertebral canal by the intervertebral foramina, each nerve receiving a numerical designation in accordance with the thoracic vertebra behind which it leaves the canal. That is, the first thoracic nerve passes between the first and second thoracic vertebræ: the eighteenth thoracic nerve leaves the vertebral canal between the eighteenth thoracic and the first lumbar vertebra.

Within the intervertebral foramen, or immediately on its exit therefrom, each thoracic nerve divides into a dorsal and a ventral branch. The smaller *dorsal branch* (ramus dorsalis) crosses the medial border of the levator muscle of the rib, and thereupon divides into a medial and a lateral ramus. The medial ramus runs upwards on the surface of the multifidus and supplies the deep muscles of the back. The lateral ramus passes in a lateral direction under the longissimus dorsi, and has already been noted as piercing the edge of this muscle or emerging between it and the ilio-costalis. It furnishes twigs to these muscles, and ends, as a *dorsal cutaneous nerve*, in the skin of the back. In the scapular region it supplies the dorsal serratus and rhomboid muscles and ends in a cutaneous nerve in the skin over the scapular cartilage and the ligamentum nuchæ.

The larger *ventral branches* (rami ventrales) of the thoracic nerves form the intercostal nerves at present under examination.

The first thoracic nerve contributes to the brachial plexus nearly all the fibres composing its ventral branch. Consequently, the first intercostal nerve is very small. The second intercostal is also relatively small, because many of the fibres of the ventral branch of the second thoracic nerve go to the brachial plexus.

The other intercostal nerves are about equal in size but of varying length in accordance with the intercostal space in which they are placed. They accompany the intercostal vessels, lying at first between the external and internal intercostal muscles, and later between the internal muscle and the pleura. The second to the sixth nerves end in



the pectoral muscles. The second to the eighth furnish branches to the transverse thoracic muscle. The seventh to the seventeenth pass beyond the costal arch and are found during the dissection of the wall of the abdomen between the transverse and internal oblique muscles. They end in the rectus abdominis muscle. Small branches are supplied to the diaphragm by the intercostal nerves from the eighth to the last.

At a distance from the vertebral column that becomes greater with

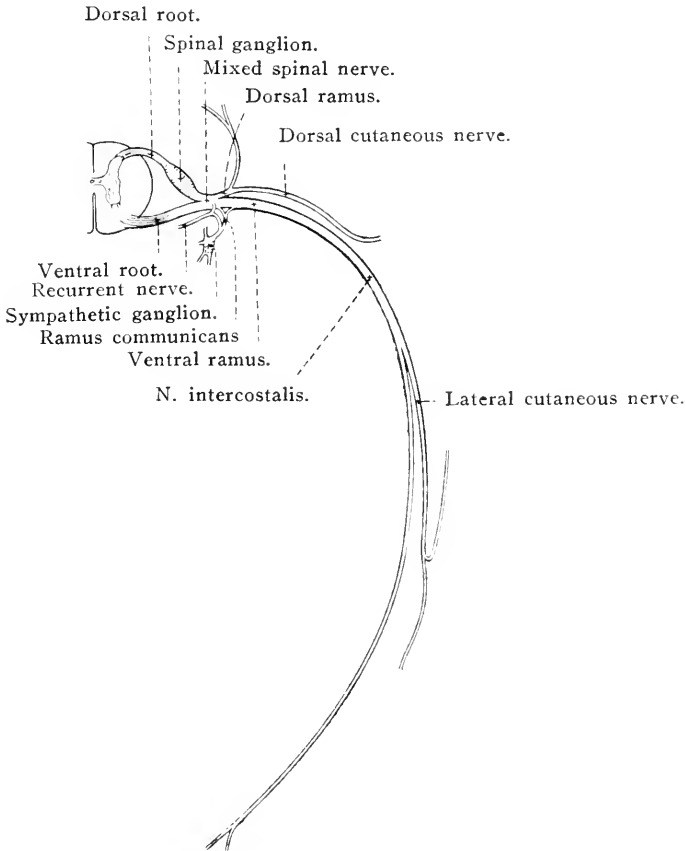


FIG. 4.—Diagram of a typical Thoracic Nerve.

each succeeding nerve, the intercostal nerves (with the exception of the first) give off a large *lateral cutaneous branch* (*ramus cutaneus lateralis*), which passes down the intercostal space between the external and internal intercostal muscles. The earlier lateral cutaneous rami pierce the external intercostal and end in the ventral serratus and latissimus dorsi muscles and the skin, and one or two of them are connected with the caudal pectoral nerves. The middle members of the series of cutaneous branches pierce the external intercostal muscles close to the attachment of the digitations of the external oblique ab-

dominal muscle, and each divides into a small dorsal and a larger ventral branch. The latter supply filaments to the skin and the external oblique muscle. The lateral cutaneous branches of some of the last intercostal nerves are distributed in the wall of the abdomen.

AA. LUMBALES.—Lumbar arteries behave, in the main, in the same manner as do the intercostal arteries. In the present dissection it is only necessary to note that their dorsal branches supply the muscles and skin of the back in the lumbar region.

NX. LUMBALES.—Like the thoracic nerves, these divide into dorsal and ventral branches. They are examined in detail during the dissection of the abdomen. It has already been noted that the dorsal branches furnish cutaneous nerves that pierce the lumbar portion of the longissimus dorsi muscle.

*Dissection.*—The intercostal muscles should be carefully removed from one or two interspaces. This will reveal that part of the endothoracic fascia that lines the lateral wall of the chest.

THE ENDOTHORACIC FASCIA (Fascia endothoracica).—The endothoracic<sup>1</sup> fascia forms a thin elastic lining to the wall of the chest. Its inner face is covered by and gives support to the parietal part of the pleura. In the mid-dorsal line the fascia is connected with the aorta and the other large blood vessels in this neighbourhood, while in the sternal region it is continuous with the fibrous layer of the pericardium.

At the present moment, only those portions of the endothoracic fascia that bridge the intervals between the ribs are exposed. An examination here will show that the fascial fibres run, for the most part, from the border of one rib to the adjacent margin of the next; and later, when portions of the ribs are removed, it will be possible to determine that the fascia is stronger where it crosses the intercostal spaces than it is where it is applied to the inner surface of the ribs themselves. And at a still later stage of the dissection, it will be found that the fascia is very thin where it covers the cranial surface of the diaphragm.

THE THORACIC CAVITY (Cavum thoracis).—It is necessary that the dissector should have some general idea of the thoracic cavity and the organs contained therein before he proceeds to their examination. The thorax is a cavity with a bony wall formed by the thoracic vertebræ, the ribs and the sternum. In form it resembles a laterally flattened cone, with a sloping base bounded by the diaphragm, which forms a thin muscular and tendinous partition between the cavity of the thorax and that of the abdomen. It is important to remember that, the diaphragm being markedly concave when viewed from the abdominal aspect, the

<sup>1</sup> ἔνδον (endon) [Gr.], within. Θώραξ (thorax) [Gr.], a breastplate, cuirass, corslet, the part covered by the breastplate, the chest.

cavity of the thorax is not so spacious as an examination of the skeleton would lead one to imagine. This may be realised by reference to Figs. 39-42, in which it is indicated that, at the end of expiration, the curve of the diaphragm, about the median plane of the body reaches the level of the sixth rib.

The undissected wall of the thorax may be described as containing the following six layers:—(1) The skin. (2) The cutaneous muscle and fascia. (3) Several strata of muscles applied to the outer surface of the ribs, vertebræ and sternum. (4) A bony skeleton consisting of the thoracic vertebræ, the ribs (including bony and cartilaginous segments), and the sternum. Between the ribs are the *intercostal spaces* (*spatia intercostales*) occupied by the intercostal muscles. (5) The endothoracic fascia, with which are associated the longus colli and transverse thoracic muscles. (6) The pleura.

The entrance to the thorax (*apertura thoracis cranialis*), ovoid in outline and flattened laterally, is bounded by the first thoracic vertebra, the first pair of ribs and the cranial end of the sternum. It is occupied by the longus colli muscle, trachea, œsophagus, nerves, large blood vessels proceeding to and from the neck and the thoracic limbs, lymphatic vessels and lymph glands, and (in the young) the thymus.

The opposite extremity of the thoracic cavity (*apertura thoracis caudalis*) is bounded by the last thoracic vertebra and the costal arch, and is closed by the diaphragm.

It is convenient to consider that the thorax possesses a dorsal, a ventral and right and left lateral walls, though the demarcation of these is largely arbitrary. The dorsal wall may be held to correspond to the thoracic vertebræ and the ribs as far as their angles, with the ligaments and muscles connected with these bones. The ventral wall is formed by the sternum and the cartilaginous segments of the sternal ribs, with their associated muscles and ligaments. The lateral walls consist of the bony segments of the sternal ribs from their angles onwards, the corresponding part of the asternal ribs and their cartilaginous segments and the intercostal muscles. The limits of the lateral wall of the thorax, as distinct from the wall of the abdomen, are marked by the border of the last rib and the gently curved line, the *costal arch* (*arcus costalis*), with a concavity looking in a dorsal and cranial direction, formed by the overlapping cartilages of the asternal ribs.

Although the cavity of the thorax has been described above as having the form of a flattened cone with a sloping base, this description requires amplification, as can best be done by a consideration of the various diameters of the cavity. Because the distance between the sternum and the vertebral column increases from the level of the first

rib to that of the sixth, and because of the cranial and ventral slope of the diaphragm, the greatest dorso-ventral (vertical) diameter of the cavity occurs on a level with the diaphragmatic attachment to the sternum. The slope of the diaphragm is also responsible for the fact that the dorsal wall is almost twice as long as the ventral wall (sternum). The degree of curvature of the ribs causes the transverse diameter to increase from the first rib to the last; though, in some animals, this diameter remains fairly constant from the eleventh rib to the last.

The chief organs contained within the thorax are the heart and the two lungs. The heart lies between the lungs and is enclosed in a fibrous sac, the *pericardium*. The lungs fill the greater part of the thoracic cavity, and, except where it is connected with the heart by large vessels, and where it is joined to the trachea by a bronchus, each lung lies free in its own side of the thorax. A serous membrane, the *pleura*, covers each lung and lines the corresponding part of the thoracic wall. Where the two pleuræ come into contact with or approach each other in or near the median plane, they form the *mediastinal septum*, a partition in which all the thoracic contents, with the exception of the lungs, the caudal vena cava and the right phrenic nerve, are contained. Part of the septum and some of the features of the pleural cavity must now be displayed. That part of the pleura that covers the lung is known as visceral; the rest of the membrane is the parietal pleura.

*Dissection.*—On both sides of the body the ribs from the second to the fourteenth inclusive must be cut through with bone forceps about their angles. The same ribs are, in like manner, to be separated from their cartilages. Then, with a knife, remove *en masse* the portion of the chest wall thus indicated. The greatest care is necessary in conducting this dissection, otherwise the lung, which, in a properly hardened subject, is closely applied to the inner surface of the chest wall, will be injured.

THE PLEURA.—Before any further dissection is undertaken, the disposition of the pleura<sup>1</sup> must be ascertained. That part of the membrane which is applied to the ribs, and in which a large window has just been made, is known as the *costal pleura* (pleura costalis). If this be traced in a ventral direction it will be found to approach or reach the middle line of the sternum, where it meets its fellow membrane of the opposite side of the thorax. From the sternum each membrane is reflected dorsalwards as the *mediastinal pleura* (pleura mediastinalis). In some regions the mediastinal pleuræ are intimately related to each other, and a thin double membrane, the *mediastinal septum* (septum mediastinale), is produced. In other regions, however,

<sup>1</sup> πλευρά (pleura) [Gr.], the side, rib, the membrane that lines the chest.

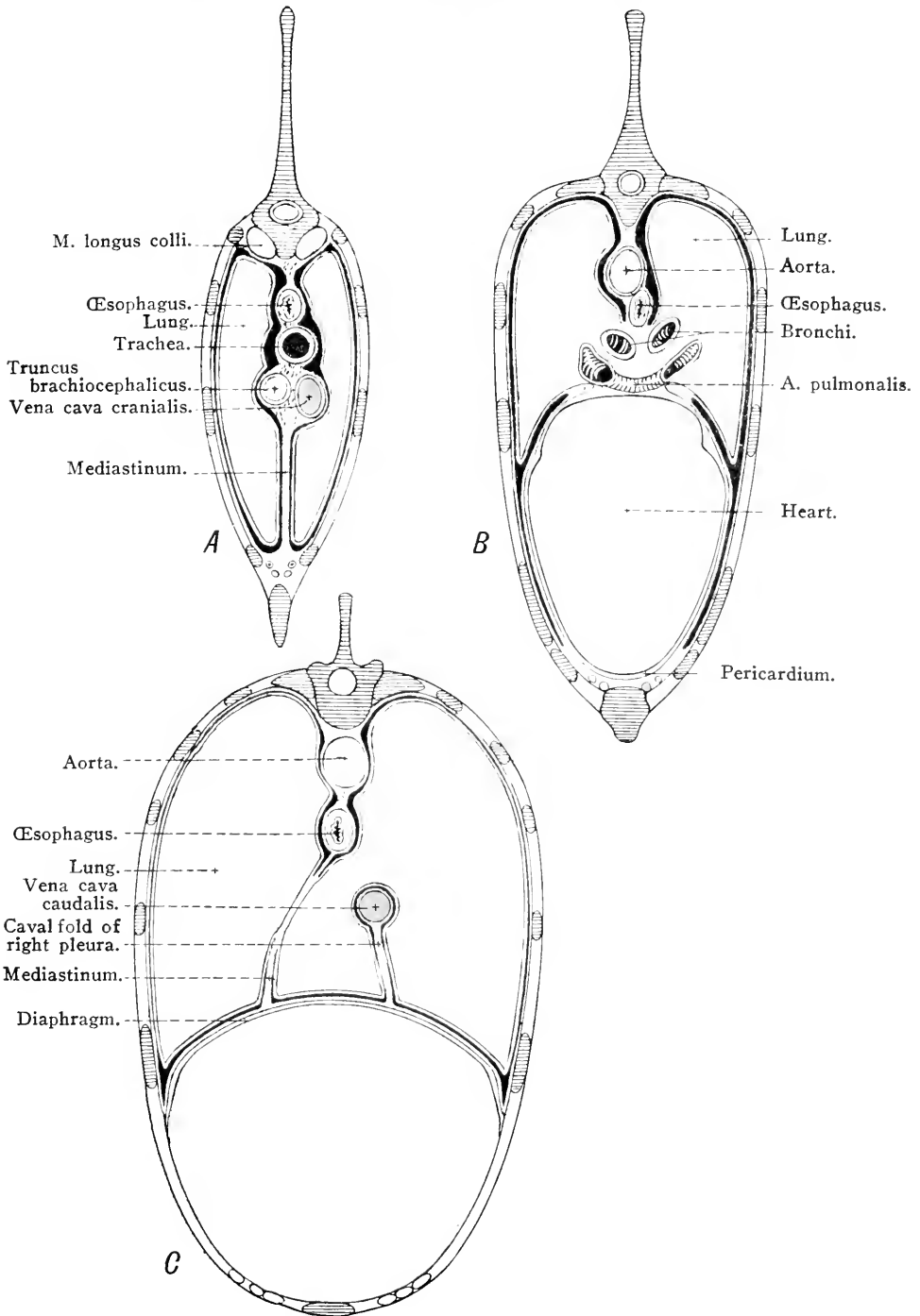


FIG. 5.—Diagrams to illustrate the arrangement of the Pleuræ in transverse sections of the Thorax.

*A* = Cranial to the Heart. *B* = On a level with the Heart. *C* = Caudal to the Heart. The Pleuræ are represented by the red lines.

structures of considerable size intervene between the two mediastinal pleuræ, with the result that a more or less extensive mediastinal space is formed. The heart is the largest of these structures, and it is customary to designate that part of the mediastinal pleura that is applied to the membranous sac surrounding this organ by the specific name of *pericardiac pleura* (pleura pericardiaca).

On following the pleura over the heart—or, more correctly, over the pericardium—it will be discovered that it is reflected over the root of the lung on to the lung itself; that is, the parietal pleura here becomes continuous with the visceral or *pulmonary pleura* (pleura pulmonalis). It should be further noticed that caudal to the root of the lung the reflection of the mediastinal pleura is carried backwards as far as the diaphragm in the form of the *pulmonary ligament* (ligamentum pulmonale).

During the foregoing examination it will have been observed that the mediastinal and costal pleuræ meet at the sternum at a very acute angle. Thus the most ventral part of the pleural cavity is very narrow, and is distinguished as the *costo-mediastinal sinus* (sinus costo-mediastinalis).

Now trace the costal pleura in a dorsal direction. On reaching the vertebral column the membrane is reflected ventralwards as the mediastinal septum, in which the œsophagus and aorta are conspicuous objects. Again the mediastinal pleura is continuous with the pulmonary pleura by way of the root of the lung and the pulmonary ligament.

Next investigate the disposition of the pleura at the apex of the chest. Here each sac ends blindly in the *cupula*<sup>1</sup> *pleuræ*, which, on the left side, generally lies within the first rib, but on the right side may extend beyond the rib and come into contact with the scalenus muscle.

Finally, the costal pleura should be followed to the diaphragm—where it forms the *diaphragmatic pleura* (pleura diaphragmatica)—and thence again to the mediastinal septum.

Owing to the bulging of the diaphragm towards the cavity of the chest, the part of the muscle close to its costal attachment is applied to the inner surface of the ribs. Consequently, in this region—the *phrenico-costal sinus* (sinus phrenicocostalis)—there is a certain amount of the pleural cavity into which the thin edge of the lung does not extend even during inspiration. Naturally, during expiration and when the hollow abdominal organs are distended, the area of contact of diaphragmatic and costal pleuræ is greater.

The diaphragmatic line of pleural reflection, that is, the line along

<sup>1</sup> *Cupula* [L.], a cup, dim. of *cupa*, a tub.

which the pleura passes from the ribs on to the diaphragm, should be examined with care, since it is of clinical importance. The line runs over the union of the seventh and eighth ribs and their cartilages, crosses the sternal end of the ninth rib close to the costochondral articulation, and then sweeps over the ribs, with a gentle curve, the convexity of which looks downwards, in such a manner as to recede gradually from the sternal end of the successive ribs until the second last of these is crossed scarcely ventral to the middle of its length. About the middle of the cranial border of the last rib the line turns towards the middle line, and, with a slight forward inclination, ends opposite the middle of the width of the last intercostal space.

On the right side of the thorax the arrangement of the pleura is complicated by the presence of a fold, the *fold of the vena cava* (plica venæ cavæ), that leaves the diaphragm and passes dorsalwards to surround the caudal vena cava as this travels from its point of perforation of the diaphragm to the heart. The right phrenic nerve is enclosed in a secondary fold that springs from the right face of the main fold. The plica venæ cavæ is delicate and lace-like in the adult horse, and occupies a deep fissure between the intermediate lobe and the main mass of the right lung.

*The mediastinal septum* (septum mediastinale). The septum between the two pleural cavities is formed, as has been seen, by the apposition of the two pleural membranes at or about the median plane. The space between the two membranes is known as the *mediastinum*<sup>1</sup> or mediastinal cavity, and is bounded laterally by the mediastinal pleuræ, ventrally by the sternum, dorsally by the vertebral column, and caudally by the diaphragm. Since the unpaired, more or less median structures of the chest occupy a position therein, the greater part of the dissection of the thorax takes place within the mediastinal cavity.

For convenience in description, the cavity is divided conventionally into three parts: (1) A *precardial mediastinum*, cranial to the heart; (2) a *cardial mediastinum*, containing the heart and other structures occupying the same transverse zone of the thoracic cavity; and (3) a *postcardial mediastinum*, of triangular outline and circumscribed by the heart, the diaphragm and the vertebral column. The precardial and cardiac mediastina occupy approximately the median plane; but the postcardial mediastinum is pushed over to the left by the intermediate lobe of the right lung. The right pleural sac, consequently, is more extensive than the left.

It should be noted that, ventral to the œsophagus, the postcardial

<sup>1</sup> *Mediastinum* [L.], a common servant, a median partition or septum (*mediastinus* [L.], being in the middle).

mediastinum presents a cribriform or lace-like appearance in the adult horse. The numerous small openings place the right and left pleural cavities in communication with each other; and this is not without clinical significance, for it means that a pleural effusion into one pleural cavity will find its way into the other.

The precardial mediastinum contains the large blood vessels connecting the heart with the head, neck and thoracic limbs, the terminal part of the thoracic duct, the vagus, recurrent, phrenic, sympathetic and cardiac nerves, the œsophagus and trachea, and the thymus and lymph glands.

The cardial mediastinum contains the heart and its enveloping pericardium, the commencement of the arterial and the end of the venous systems, the œsophagus, the termination of the trachea, the vagi, left recurrent, phrenic, cardiac and pulmonary nerves, and the thoracic duct.

The postcardial mediastinum contains the aorta, the azygous vein, the vagi, left phrenic and sympathetic nerves, the thoracic duct, and the œsophagus.

THE THYMUS.—If the horse is more than two or two and a half years old, there is little chance of seeing more than a trace of the thymus.<sup>1</sup> When present and of good size, the organ is a greyish lobulated body lying in the precardial mediastinum ventral to the trachea and the large vessels, and flattened laterally in conformity with its place of location. It is often possible to show that the organ consists of two thin, flattened lobes (right and left) pressed close to each other at the median plane.

At its maximum development the thymus extends for some distance beyond the first rib into the neck. The opposite end of the organ slightly overlaps the pericardium.

THE LUNGS (Pulmones).<sup>2</sup>—Each lung is a soft, crepitant, spongy organ occupying a considerable part of one side of the thoracic cavity, and, as has been seen, in intimate association with the pleura of that side. It is also very precisely moulded upon all the other thoracic contents, even such a small object as the phrenic nerve being accommodated in its own impression on the surface of the organ. It must be remembered, however, that the fresh lung, or one that has not been absolutely successfully hardened *in situ*, loses most or many of its surface markings, as well as its

<sup>1</sup> Θύμος (thymos) [Gr.], a warty excrescence (from its likeness to a bunch of thyme-flower), the sweet-bread.

<sup>2</sup> Pulmo [L.], (apparently borrowed from the Gr. πλεύμων (pleumon), for πνεύμων (pneumon)), the organs of respiration, the lung.



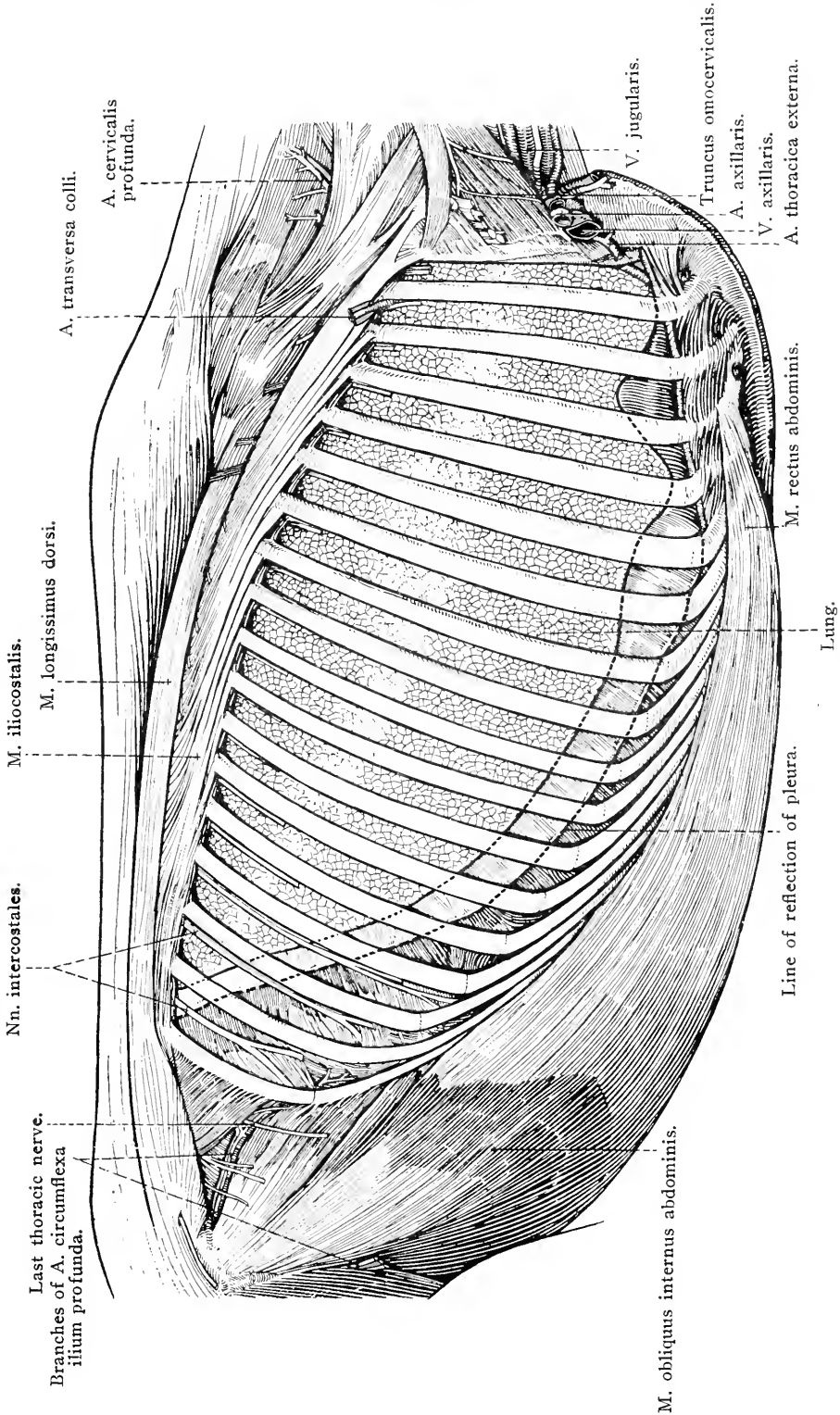


FIG. 6.—Dissection to show the relation of the lung to the chest wall. The intercostal muscles have been removed.

true form when exposed for examination. The unhardened organ collapses immediately the cavity of the chest is opened, and assumes a size not much more than one-third of that it possessed during life.

With the exception of attachments at its *root* (*radix pulmonis*) and the pulmonary ligament, each lung lies free in its own side of the chest. The colour of the lungs depends largely upon whether they contain much blood or not. In the healthy living animal they are pale red or pink; after death one is generally darker than the other owing to hypostasis of blood.

From a clinical point of view it is noteworthy that the thickest part—that is, the greatest transverse diameter—of the lungs is about the middle of the length and the middle of the external dorso-ventral diameter of the chest.

In all domestic animals, except those belonging to the Equidæ, each lung is divided into lobes (*lobi pulmonis*). These, from their position, are known as apical, cardiac and diaphragmatic. The right lung, in addition, possesses an intermediate lobe. In the horse there are occasionally indications of a division into lobes, but generally no real fissures are present. Consequently, the lungs of the horse present one continuous mass, except that an intermediate lobe is always present in association with the right organ.

The *intermediate lobe* (*lobus intermedius*) has the form of an irregular three-sided pyramid, and lies between the two lungs caudal to the heart and medial to the double fold of pleura (*plica venæ cavæ*) that encloses the caudal vena cava. Though the lobe is structurally connected with and forms a part of the right lung, it has also a connection with the left lung by connective tissue and pleura.

The lateral or *costal surface* (*facies costalis*) of each lung is smooth and glistening from the presence upon it of visceral pleura. Being applied closely to the wall of the chest, the surface follows the curve of the ribs, and is, therefore, convex in its dorso-ventral diameter. When the lungs have been satisfactorily hardened with preservative before the thorax is opened, the surface is often lightly marked by grooves which indicate the position of the ribs.

The medial or *mediastinal surface* (*facies mediastinalis*) is of much smaller extent owing to the fact that the diaphragm encroaches more upon the thoracic cavity medially than laterally. The presence of the heart produces a deep depression (*impressio cardiaca*) on this surface. Immediately dorsal to the cardiac impression is the *hilus*<sup>1</sup> *pulmonis*,

<sup>1</sup> *Hilum* [L.], (whence *nihilum* and *nihil*, nothing), a small part, a trifle. The hilus of an organ is small relative to the total area of its exterior.

that is, the point of attachment of the root. Behind the hilus there is a triangular area uncovered by pleura; or, in other words, the two layers (dorsal and ventral) of pleura that form the pulmonary ligament gradually separate more and more as the hilus is approached. The right and left lungs are closely adherent to each other over this uncovered area. Dorsal to the hilus and the attachment of the pulmonary ligament there is a longitudinal groove produced by the œsophagus; and still more dorsal another groove, curved for the accommodation of the aorta, may be noticed, especially on the left lung. On the right lung the most cranial (curved) part of the aortic groove is replaced by one, also curved, for the vena azygos.

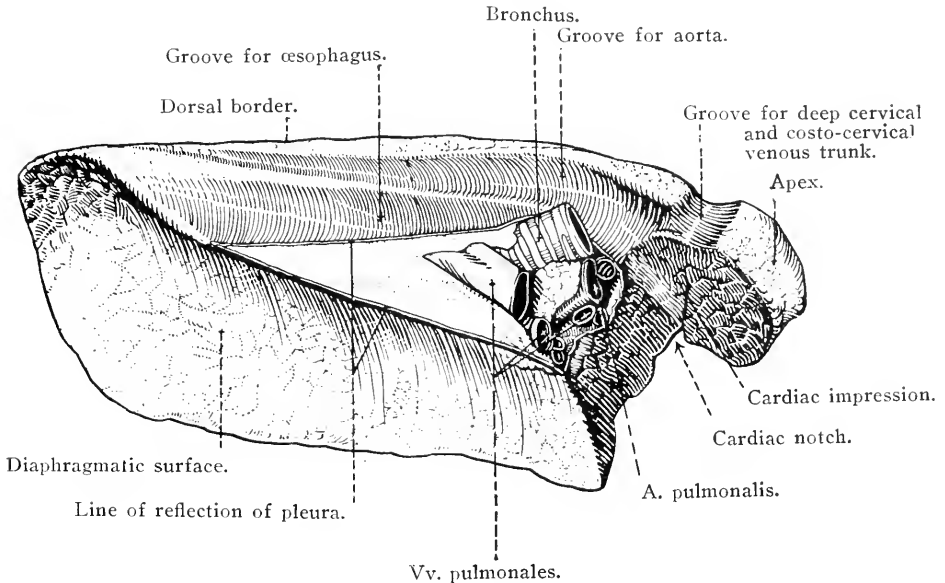


FIG. 7.—Medial aspect of the left lung.

Cranial to the hilus are grooves for the reception of the trachea, and the common brachio-cephalic trunk and cranial vena cava, and their branches.

The intermediate lobe forms a prominent projection on the mediastinal surface of the right lung.

The *dorsal border* (margo dorsalis) of the lung is adapted to the channel formed by the ribs and the bodies of the thoracic vertebræ, and consequently is comparatively thin at the apex, but becomes thick and rounded towards the base of the organ.

The *ventral border* (margo ventralis) is much shorter and thin throughout. It occupies the narrow space (sinus costomediastinalis) between the ribs and the mediastinal septum, and is notched for the

accommodation of the heart. The cardiac notch (*incisura cardiaca*) is deeper in the left lung than it is in the right; consequently more of the heart is uncovered by lung on the left side of the chest than on the right.

The *apex* of the lung (*apex pulmonis*) is free, blunt, and laterally flattened.

The *base* (*basis pulmonis*), being applied to the diaphragm, possesses a concave surface (*facies diaphragmatica*) which slopes in a caudal and lateral direction. Except medially, the border circumscribing the base is sharp and fits into the narrow space (*sinus phrenicocostalis*) between the diaphragm and the ribs.

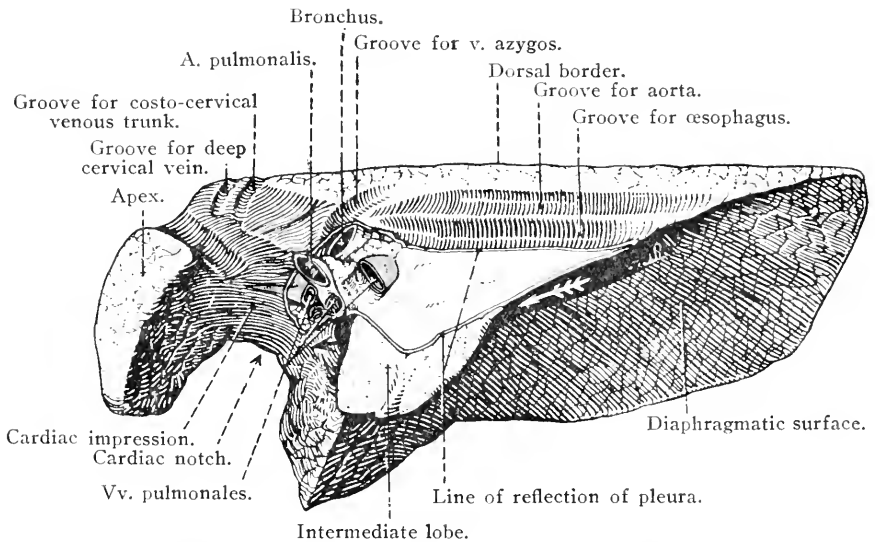


FIG. 8.—Medial aspect of the right lung. The arrow indicates the position of the caudal vena cava.

*Dissection.*—The constituents of the roots of the lungs should now be isolated. In removing the pleura and the fatty connective tissue, great care should be exercised not to injure the pulmonary plexus of nerves.

The various structures forming the root should be followed into the interior of the lung in order that their manner of branching may be observed.

**THE ROOT OF THE LUNG (*Radix pulmonis*).**—The roots of the lungs are placed about the junction of the dorsal and middle thirds of the dorso-ventral diameter of the thoracic cavity, and opposite the fifth rib and the fifth intercostal space.

Each root contains the following structures:—(1) Several pulmonary veins conveying the aerated blood from the lungs to the heart. (2) Pulmonary artery distinguished from the veins by the greater

thickness of its wall and by its position cranial and somewhat dorsal to the veins. (3) Bronchus, a large air-tube produced by the division of the trachea. In position it is the most dorsal of the larger constituents of the root. (4) Bronchial artery, of small size, running along the dorsal surface of the bronchus. (5) Nerves in the form of the pulmonary plexus, produced by the intercommunication of branches from the vagus and sympathetic. (6) Lymphatic vessels and lymph glands.

Each root has certain structures closely related to it. The vena azygos curves over the root of the right lung; and the aorta is similarly disposed on the left side. The œsophagus crosses the dorsal aspect of the left root. Both roots are crossed by a vagus nerve; and a phrenic nerve, though not in actual contact with each root, is ventral thereto.

If the bronchus be followed from the hilus into the interior it will be found to pass backwards parallel to the dorsal border of the lung, its size being gradually reduced by the production of branches. A branch of notable size, and larger in the right lung than in the left, arises as the bronchus is entering the lung and passes to the equivalent of the apical lobe. Another large branch leaves the ventral border of the bronchus and ramifies in that part of the lung that is the homologue of the cardiac lobe. The right bronchus furnishes a special branch to the intermediate lobe. All bronchial branches divide repeatedly until small tubes, the lobular bronchioles, enter the lobules of the lung and are there connected with the ultimate microscopic air-vesicles of the respiratory tract. In the lung of the adult horse the lobules are not very distinct because the amount of connective tissue between them is scanty. They may, however, be recognised, both on the surface of the lung and in sections, as polygonal areas varying considerably in size.

Naked-eye examination suffices to show that the bronchus and its branches are provided with a skeleton in the form of curved plates of cartilage, and that they are lined by a longitudinally folded mucous membrane. As the branches become smaller their walls are reduced in thickness, and it may be determined that the cartilaginous skeleton has disappeared by the time the diameter of the tubes has been reduced to about 1 mm. Finer details of structure can only be determined by the aid of the microscope.

Branches of the pulmonary artery follow the bronchial tubes, subdivide with them, and finally end in the lobules where they form rich capillary plexuses in the walls of the air-vesicles. Branches of the very much smaller bronchial artery also accompany the bronchial tubes to the lobules, but do not extend as far as the air-vesicles. The blood they

carry is for the nutrition of the lung, while that borne by the pulmonary artery is concerned with the respiratory function.

It should be added that, in the horse, the œsophageal branches of the broncho-œsophageal and left gastric arteries contribute small twigs that ramify in the subpleural lung tissue in the neighbourhood of the pulmonary ligament.

Bronchial lymph glands (lymphglandulæ bronchiales), into which the lymphatic vessels of the lungs drain, are grouped about both the dorsal and ventral aspects of the bifurcation of the trachea and the initial part of the bronchi. The dorsal group is frequently continued for a short distance along the ventral border of the œsophagus, while a prolongation of the ventral group may be insinuated between the aorta and the pulmonary artery. A few small glands are contained within the substance of the lung, where they are related to the main bronchus.

N. PHRENICUS.—The origin of each phrenic<sup>1</sup> nerve by roots from the fifth, sixth and seventh cervical nerves is noted during the dissection of the neck. The root from the fifth cervical nerve is very frequently absent, and, when present, is smaller than the other two.

Both right and left nerves enter the thorax ventral to a subclavian artery, and pass through the precardial mediastinum. They then cross the pericardium ventral to the roots of the lungs. The left nerve continues through the postcardial mediastinum to the diaphragm; but the right nerve gains that muscle by running along the lateral aspect of the caudal vena cava, and is therefore not contained in the mediastinal septum, but in the special caval fold of pleura. There are also further differences between the relations of the two nerves. The left follows a course along the left aspect of the brachio-cephalic artery and the common brachio-cephalic trunk and then crosses the commencement of the aortic arch and the pulmonary artery, the pericardium intervening: the right nerve lies along the right face of the cranial vena cava.

THE PERICARDIUM (Pericardium).—The pericardium<sup>2</sup> is a fibrous sac somewhat loosely enclosing the heart, and, in agreement with the organ it surrounds, is conical in form with the base of the cone directed towards the vertebral column. The apex points towards the sternum and the sternal attachment of the diaphragm. Strong and slightly elastic fibrous tissue, *sterno-pericardiac ligaments* (ligamenta sterno-pericardiacæ), fixes the pericardium to the sternum from the level of the fifth rib to near where the diaphragm takes origin from the xiphoid process. The area of attachment is triangular with the apex looking towards the thoracic entrance. The outer face of the pericardium is

<sup>1</sup> φρήν (phrēn) [Gr.], the diaphragm, heart, seat of the emotions.

<sup>2</sup> περί (peri) [Gr.], around: καρδία (cardia) [Gr.], the heart.

covered by pleura (pleura pericardiaca), and, as has just been noticed, is crossed by the phrenic nerves.

The outer layer of the pericardium is composed of strong fibrous tissue that is continued, as tubular investments, on to the caval veins, vena azygos, pulmonary vessels, brachio-cephalic trunk, and aorta. The adhesion of the membrane to these vessels begins about 6 cm. from the point at which they enter or leave the heart.

*Dissection.*—Make a crucial incision through the pericardium on both sides of the chest. The two horizontal incisions should *not* be made to meet.

Within the fibrous pericardium is a serous membrane disposed after the customary manner of its kind; that is to say, the parietal part of the membrane lines the fibrous pericardium, and is reflected from the great vessels on to the heart itself as the visceral pericardium or *epicardium*. It will be observed that the aorta and pulmonary artery are enclosed within a common tubular sheath of serous pericardium, and that caudal to these vessels there is a passage, the *transverse sinus of the pericardium* (sinus transversus pericardii). The serous membrane endows the interior of the fibrous pericardium and the surface of the heart with a smooth, glistening appearance, and, like all other serous membranes, is always moist.

A considerable amount of fat generally underlies the epicardium in the grooves on the surface of the heart and around the roots of the great blood vessels.

*Dissection.*—The large veins that return the blood to the heart from all parts of the body except the lungs are to be approached from the right side of the thorax. The pleura must be stripped from their surface and the fat that covers them must be removed. Every care must be taken not to injure nerves that are related to the veins.

V. CAVA CRANIALIS.—The cranial vena cava<sup>1</sup> is the large unpaired vessel that drains the head and neck, both thoracic limbs, and a considerable part of the wall of the thorax. It is formed at the entrance to the chest by the union of the two jugular and the two subclavian veins. Very commonly the jugular veins join together and enter the vena cava as a common vessel. At its commencement the caval vein is fixed by connective tissue to the medial surface of the first rib.

The cranial caval vein traverses the precordial mediastinum slightly to the right of the median plane, ventral to the trachea, and to the right of the brachio-cephalic artery and trunk. Piercing the pericardium to the right of the aortic arch, it terminates in the right atrium of the heart. The exact point at which the vein ends and the atrium begins

<sup>1</sup> *Cavus* [L.], hollowed; deep-channelled (as applied to a river).

is obscured by the prolongation of atrial muscular fibres on to the terminal part of the vein.

The collateral tributaries of the cranial vena cava are the internal thoracic, vertebral, deep cervical and costo-cervical veins from both sides of the body. It frequently happens that the left vertebral, left deep cervical, and left costo-cervical veins join together before reaching the vena cava. The vena azygos may or may not be a tributary of the vena cava.

V. AZYGOS.—The azygos<sup>1</sup> vein begins in the abdomen and drains a considerable proportion of the wall of the chest. At the present moment no attempt need be made to do more than examine its terminal part. The vein either joins the cranial vena cava just as this is entering the heart, or it opens into the right atrium itself.

V. CAVA CAUDALIS.—The caudal vena cava begins within the abdomen on a level with the fifth lumbar vertebra, and enters the thorax by the foramen venæ cavæ of the diaphragm, where it receives two or three large *phrenic veins* (vv. phrenicæ) that drain the greater part of the diaphragm. The thoracic part of the caval vein, which is all that can be examined at present, lies in the cleft between the main mass of the right lung and its intermediate lobe, in the edge of the caval fold of the right pleura. The vein pierces the pericardium and opens into the right atrium of the heart.

The right phrenic nerve, as has been already noted, lies lateral and ventral to the vena cava.

*Dissection.*—In order to give more room for the dissection of the heart, &c., the lungs may now be removed.

THE HEART (Cor).—The heart is a hollow muscular organ of conical shape, with a base that is dorsal in position and an apex that is ventral. The long axis of the organ is mainly vertical, but has a degree of inclination that brings its ventral end towards the diaphragm and the left side of the body. This obliquity causes about three-fifths of the total bulk of the heart to be on the left side of the median plane of the body.

The heart of the horse lies under cover of the third, fourth, fifth and sixth ribs; the cranial border generally lying opposite the second intercostal space, while the caudal border extends more or less beyond the sixth rib. The position of the base of the heart may be indicated as coinciding with a horizontal plane taken on a level with the junction

<sup>1</sup> a priv. + ζυγός (zygos) [Gr.], a yoke; unpaired.



of the sixteenth bony rib and its cartilaginous segment.<sup>1</sup> The apex is opposite the space between the fifth and sixth costal cartilages (or under cover of the sixth cartilage) from 1 to 1.5 cm. from the sternum.<sup>2</sup>

The heart of the horse is slightly flattened laterally, and thus may be described as possessing right and left surfaces (facies dextra, facies sinistra) and cranial and caudal borders (margo cranialis, margo caudalis).

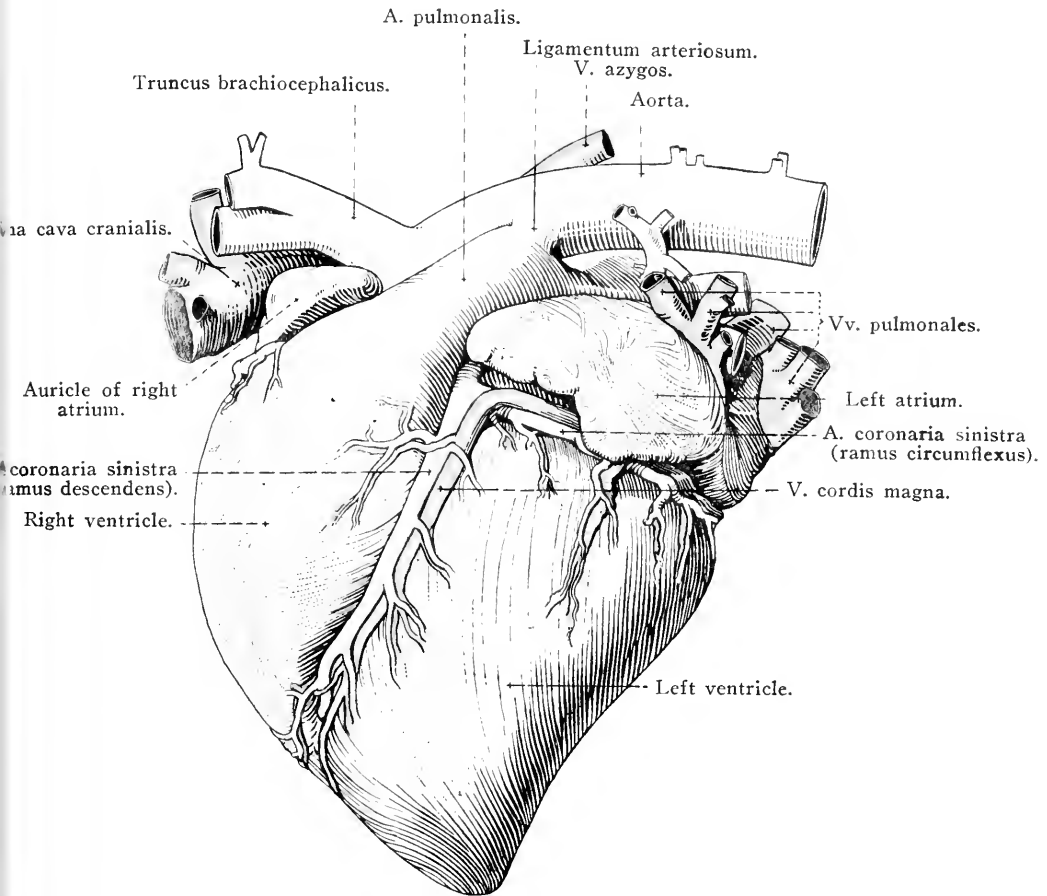


FIG. 9.—The heart and great blood-vessels as seen from the left.

The exterior of the heart is divided into areas corresponding to the four cavities in the interior. Forming the base are the two atria,

<sup>1</sup> In terms of the cavity of the chest, the base of the heart is approximately on a level with the junction of the middle and dorsal thirds of the vertical diameter of the cavity. Though less precise, it may also be said that the base lies about the middle of the vertical diameter of the exterior of the chest taken from the highest part of the withers.

<sup>2</sup> When the horse is standing firmly on all four limbs, the apex of the heart is slightly behind the free end of the olecranon.

separated from the much larger ventricles by the *coronary groove* (sulcus coronarius), which is continuous round the heart except where interrupted by the pulmonary artery. The groove is generally largely occupied by fat; consequently its depth cannot be properly estimated in the undissected organ. Externally the distinction between the right and left atria is indifferently marked except on the left side. The common atrial mass is crescentic in form, the horns of the crescent

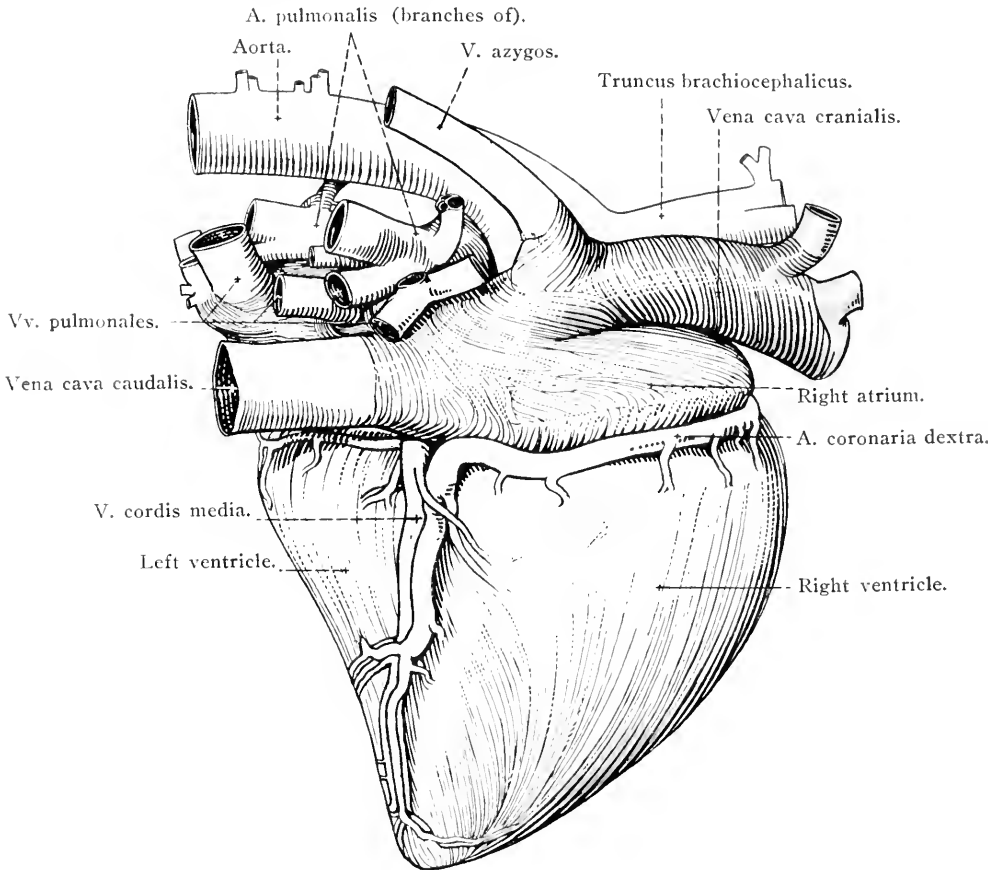


FIG. 10.—The heart and great blood-vessels as seen from the right.

being two free projections, the *auriculæ*<sup>1</sup> *cordis*, separated from each other by the pulmonary artery and aorta.

The ventricular part of the heart is responsible for the conical shape of the organ as a whole. Its base is connected with the atria, while its apex forms the apex of the entire organ. The common mass of the ventricles presents two surfaces and two borders. The right surface is

<sup>1</sup> *Auricula* (dim. of *auris*) [L.], the external ear, the lobe of the ear. The term is applied to part of the atrium because of its ear-like shape.

convex and crossed obliquely by a furrow, the *right longitudinal groove* (*sulcus longitudinalis dextra*), that begins at the coronary groove and ends on the caudal border of the heart close to the apex. The groove divides the surface into two areas, of which the more cranial, formed by the right ventricle, is about twice as extensive as the caudal area, formed by the left ventricle.

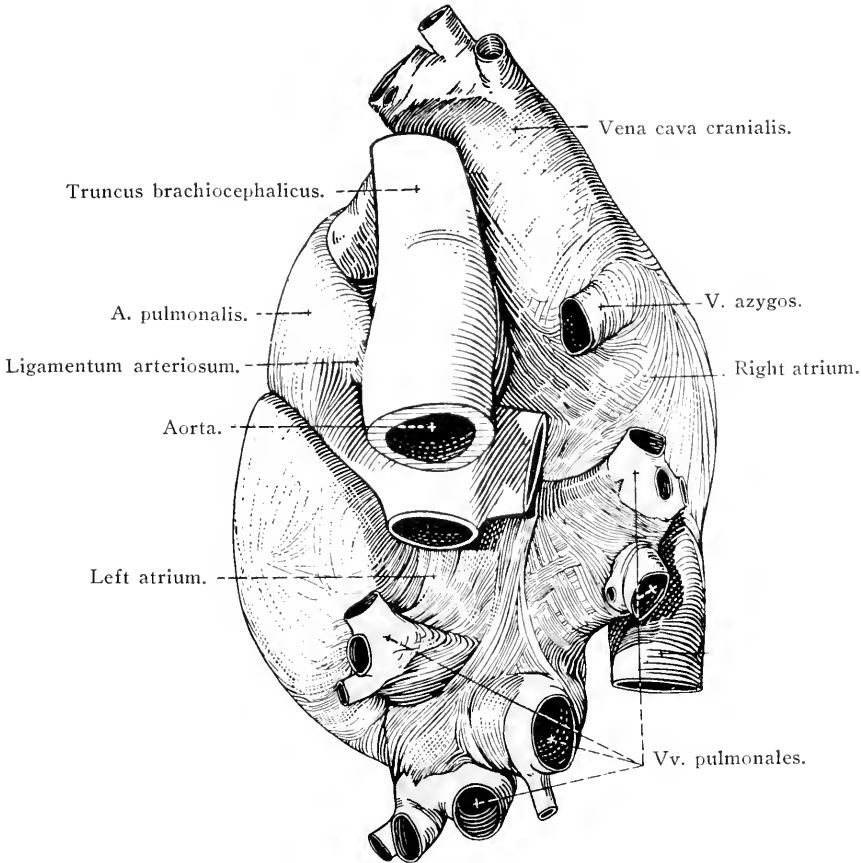


FIG. 11.—The base of the heart with the great blood-vessels.

Like the right, the left surface of the ventricles is convex and crossed by a groove, the *left longitudinal groove* (*sulcus longitudinalis sinistra*). But the left groove is nearer the cranial border of the heart, so that the caudal two-thirds of the surface is formed by the left ventricle, while the cranial third is occupied by the right ventricle. The left longitudinal groove begins at the coronary sulcus immediately caudal to the origin of the pulmonary artery, and ends on the cranial border of the heart a short distance from the apex.

From the circumstance that the longitudinal grooves mark the position of the interventricular septum, and that neither reaches the

apex, it is clear, even on an external examination, that the apex of the heart is formed by one ventricle only, namely, the left.

The cranial border (*margo cranialis*) of the heart is gently convex and mainly formed by the right ventricle. The caudal border (*margo caudalis*), formed entirely by the left ventricle, is convex in its dorsal half and slightly concave towards the apex of the heart.

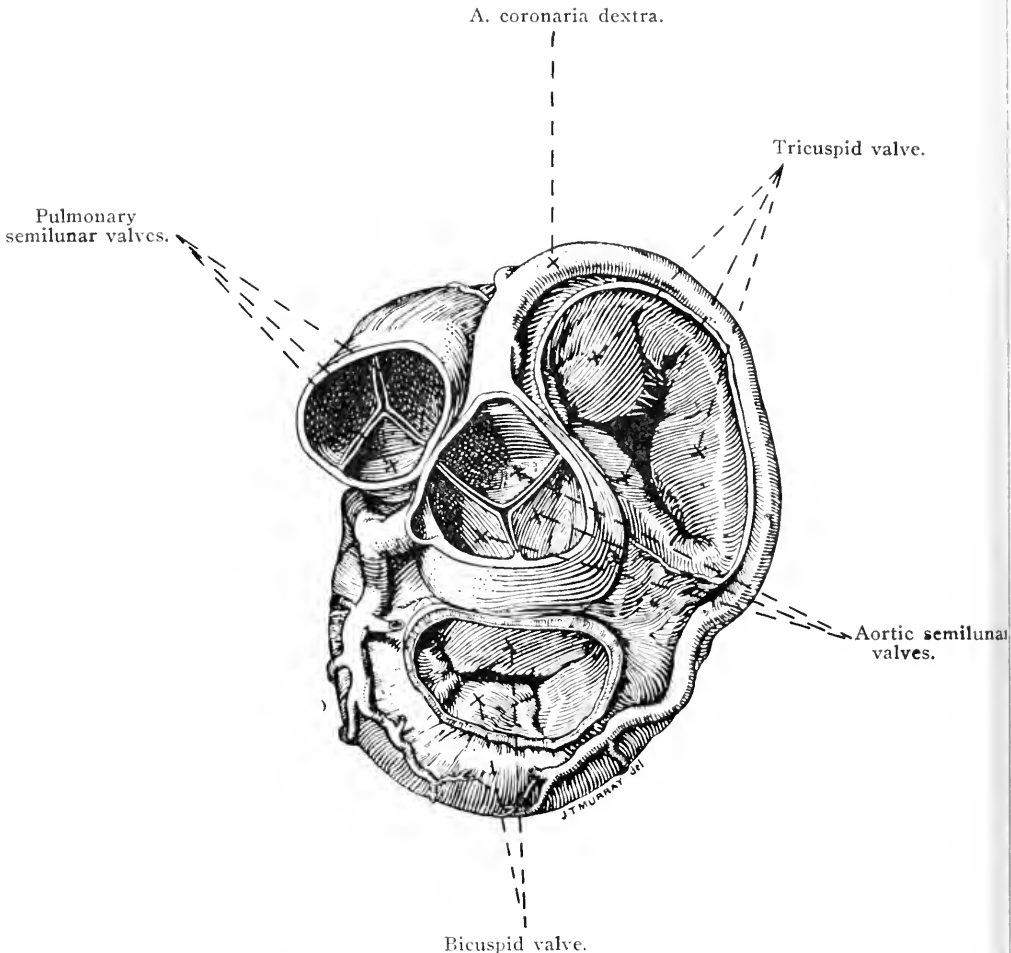


FIG. 12.—The base of the ventricles of the heart. The atria have been removed to show the arrangement of the valves.

*Dissection.*—The vessels and nerves that supply the tissues of the wall of the heart should now be dissected. In order to do this, it is necessary to remove the epicardium and the subjacent fat from the grooves. The remains of the pericardium should also be cleared away.

The wall of the heart is supplied with blood by the two coronary arteries, right and left, and is drained by the great cardiac, the middle cardiac, and a number of small cardiac veins.

A. CORONARIA DEXTRA.—As will be seen later, the right coronary<sup>1</sup> artery leaves the aorta behind the cranial semilunar valve at the origin of this vessel from the left ventricle. The first part of its course is cranial in direction, but it soon bends towards the right, and then sweeps in a caudal direction along the right part of the coronary groove. A descending branch (*ramus descendens*) follows the right longitudinal groove of the heart to within a measurable distance of the apex.

A. CORONARIA SINISTRA.—The left coronary artery leaves the aorta behind the left caudal semilunar valve and passes backwards to the right of the pulmonary artery. Its circumflex branch (*ramus circumflexa*) follows the coronary groove to near the caudal border of the heart, and ends close to the termination of the right coronary artery. Numerous branches ramify over the surface of the left ventricle, but the largest (*ramus descendens*) leaves the parent vessel close to the pulmonary artery and runs down the left longitudinal groove.

V. CORDIS MAGNA.—The great cardiac vein begins near the apex of the heart as a companion of the descending branch of the left coronary artery. It accompanies the artery as far as the coronary groove, then turns at a right angle to follow the groove along the left side and round the caudal border of the heart, and ends by opening into the *coronary sinus*<sup>2</sup> (*sinus coronarius*), a short but wide vessel that will be found ventral to the termination of the caudal vena cava.

V. CORDIS MEDIA.—The middle cardiac vein lies in the right longitudinal groove in company with the descending branch of the right coronary artery. Its mode of termination is variable. In the majority of subjects it pours its blood into the coronary sinus; but not infrequently it opens independently into the right atrium.

VV. CORDIS MINORES.—Four or five small veins drain the surface of the right atrium and ventricle, and enter the right half of the coronary groove to end finally in the depressions between the pectinate muscles on the inner surface of the wall of the right atrium.

*Dissection.*—Now proceed to examine the interior of the cavities of the heart, beginning with the right atrium. To open this cavity most advantageously two incisions are necessary: (1) Enter the knife at the termination of the caudal vena cava and carry it in a straight line to the point at which the cranial vena cava joins the heart. (2) From the middle of the first incision carry a second to the tip of the auricle of the atrium.

It is well not to depart from the instructions laid down for opening the various cavities of the heart, as the incisions have been planned to give the maximum of exposure of the interior with the minimum of damage.

<sup>1</sup> *Corona* [L.], a crown, something crown-like or encircling.

<sup>2</sup> *Sinus* [L.], a curved surface, a curve; in a borrowed sense, the bosom, a cavity.

## THE CAVITIES OF THE HEART.

*Atrium*<sup>1</sup> *dextrum*.—As an examination of the exterior of the heart has already shown, each atrium is divisible into a main part intimately connected with the other atrium and the ventricle of its own side, and a freer part or auricle (*auricula cordis*).

Like all the cavities of the heart, the right atrium has a smooth glistening lining, the *endocardium*; but the wall of the auricle is

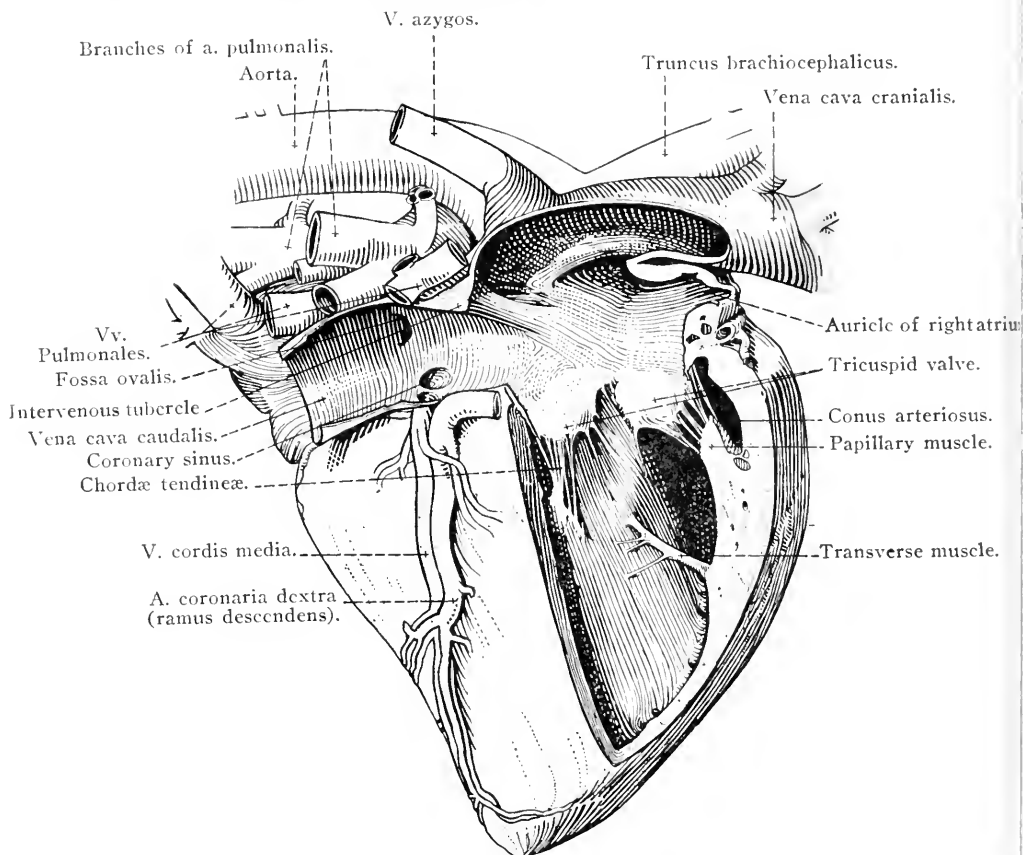


FIG. 13.—The heart and great blood-vessels viewed from the right, with the interior of the right atrium and right ventricle exposed. In taking away the wall of the ventricle, one of the cusps of the tricuspid valve was also removed.

rendered uneven by the presence of reticulated muscular ridges of varying height, the *musculi pectinati*.<sup>2</sup> The ridges end at a semilunar crest (*crista terminalis*), which corresponds in position to a shallow and often very imperfectly defined groove, the *suleus terminalis*, on the exterior of the atrium.

<sup>1</sup> *Atrium* [L.], antechamber, the hall or principal room in a Roman house.

<sup>2</sup> *Pecten* [L.], a comb. From the comb-like arrangement of the muscular ridges.

The constant openings by which blood enters the right atrium are:—(1) The opening of the caudal vena cava; (2) the opening of the cranial vena cava; (3) the opening of the coronary sinus; and (4) the openings of the small veins of the heart. In addition to these there may be two other venous openings, namely, those of the vena azygos and the middle cardiac vein.

The caval openings occupy the caudal and cranial ends of the atrium. Between them is a semilunar ridge projecting from the roof of the cavity and known from its position as the *intervenous tubercle* (tuberculum intervenosum). It will be observed that the term "tubercle" is not very appropriate as descriptive of the object in the heart of the horse. It is obvious that the ridge will serve the mechanical purpose of directing the two caval streams towards the exit from the atrium. The coronary sinus debouches immediately ventral to the termination of the caudal vena cava, and between this and the opening that leads from the atrium into the ventricle. The opening is provided with a small valve (valvula sinus coronarii). If the middle cardiac vein does not terminate in the coronary sinus, its mouth will be found close to that of the sinus. Four or five openings of the small cardiac veins are hidden in the depressions between the pectinate muscles.

Occasionally in young animals a variable fold of endocardium and subendocardial tissue, the *valve of the vena cava* (valvula venæ cavæ), is present between the caval opening and the mouth of the coronary sinus.

The blood passes from the atrium into the right ventricle by a rounded *atrio-ventricular orifice*, about 5 cm. in diameter, which occupies the entire floor of the main part of the atrium.

The septum between the right and left atria (septum atriarum) is not equally thick throughout. The thinnest part is at the bottom of a well-defined *fossa*<sup>1</sup> *ovalis* that marks the position of an embryonic connection between the two cavities. The mouth of the fossa looks towards the caudal caval opening and is partly surrounded by a prominent margin, the *limbus*<sup>2</sup> *fossæ ovalis*. The interatrial communication (foramen ovale) of the embryo may be regarded as a means by which most of the blood brought to the heart by the caudal vena cava may be quickly restored to the systemic circulation instead of being compelled to follow a route impeded by the as yet undistended lungs. Another provision of a like nature exists in the ductus arteriosus that connects the pulmonary artery with the aorta of the embryo.<sup>3</sup>

<sup>1</sup> *Fossa* [L.], a ditch, trench, fosse.

<sup>2</sup> *Limbus* [L.], a border.

<sup>3</sup> See the appendix on the fetal circulation, p. 192.

*Dissection.*—The right ventricle must now be opened. Make an incision through the wall of the ventricle parallel to, and a short distance from, the coronary groove. Care must be taken not to insert the knife too deeply, or the tricuspid valve will be injured. The incision should be carried well towards the commencement of the pulmonary artery. A second incision must begin where the first finished, *i.e.*, near the pulmonary artery, and should be made parallel to, and a short distance from, the left longitudinal groove and carried as far as possible towards the apex of the ventricle.

*Ventriculus dexter.*—The cavity of the right ventricle<sup>1</sup> has a triangular outline, with the base of the triangle in the vicinity of the right longitudinal groove, while the apex is formed by that part of the ventricle which is known as the *conus arteriosus* from its conical shape and its communication with the pulmonary artery. During the examination of the exterior of the heart it was noted that the right ventricle does not extend to the apex. This may now be verified. It will be observed that the septum between the two ventricles (*septum ventriculorum*) is convex towards the right. Thus the cavity of the ventricle would present a crescentic outline were a transverse section to be made.

The internal surface of the wall of the ventricle, especially where it joins the ventricular septum, is irregular from the presence of fleshy ridges (*trabeculæ*<sup>2</sup> *carneæ*) of variable size and form. These are small or absent in the *conus arteriosus*. Most of the *trabeculæ* are ridges simply; but one or possibly more (*musculi transversi cordis*) are cords stretching from the lateral wall of the ventricle to the septum. Three conical muscular processes, the *musculi papillares*,<sup>3</sup> spring from the wall of the ventricle by broad bases, and have fine *tendinous cords* (*chordæ tendineæ*) attached to their apices.

The opening (*ostium atrioventriculare dextrum*) from the atrium into the ventricle is guarded by the *tricuspid valve* (*valvula tricuspidalis*) composed of three triangular membranous cusps that hang down into the ventricle. The bases of the cusps are attached to the margin of the atrio-ventricular orifice, and each cusp has *chordæ tendineæ* affixed to its ventricular surface and free edge; the tendinous cords from one papillary muscle being distributed to the adjacent halves of two cusps. It is generally possible to demonstrate smaller cusps between the major cusps. The major cusps have a constant disposition. One lies between the atrio-ventricular opening and the *conus arteriosus*; another lies against the interventricular septum; while the third is related to the lateral wall of the ventricle.

<sup>1</sup> *Ventriculus* [L.], dim. of *venter*, the belly; a small cavity.

<sup>2</sup> *Trabecula* [L.], dim. of *trabs*, a beam. *Carnæus* [L.], fleshy.

<sup>3</sup> *Papilla* [L.], a nipple.



The exit from the ventricle, that is, the opening (ostium pulmonale) from the conus arteriosus into the pulmonary artery, is furnished with three pocket-shaped *semilunar valves* so arranged as to prevent the backward flow of blood from the artery into the ventricle, but offering no obstacle to the passage of blood from the ventricle into the artery. These valves will be more conveniently examined when, at a later stage of the dissection, it is possible to remove the heart from the thorax.

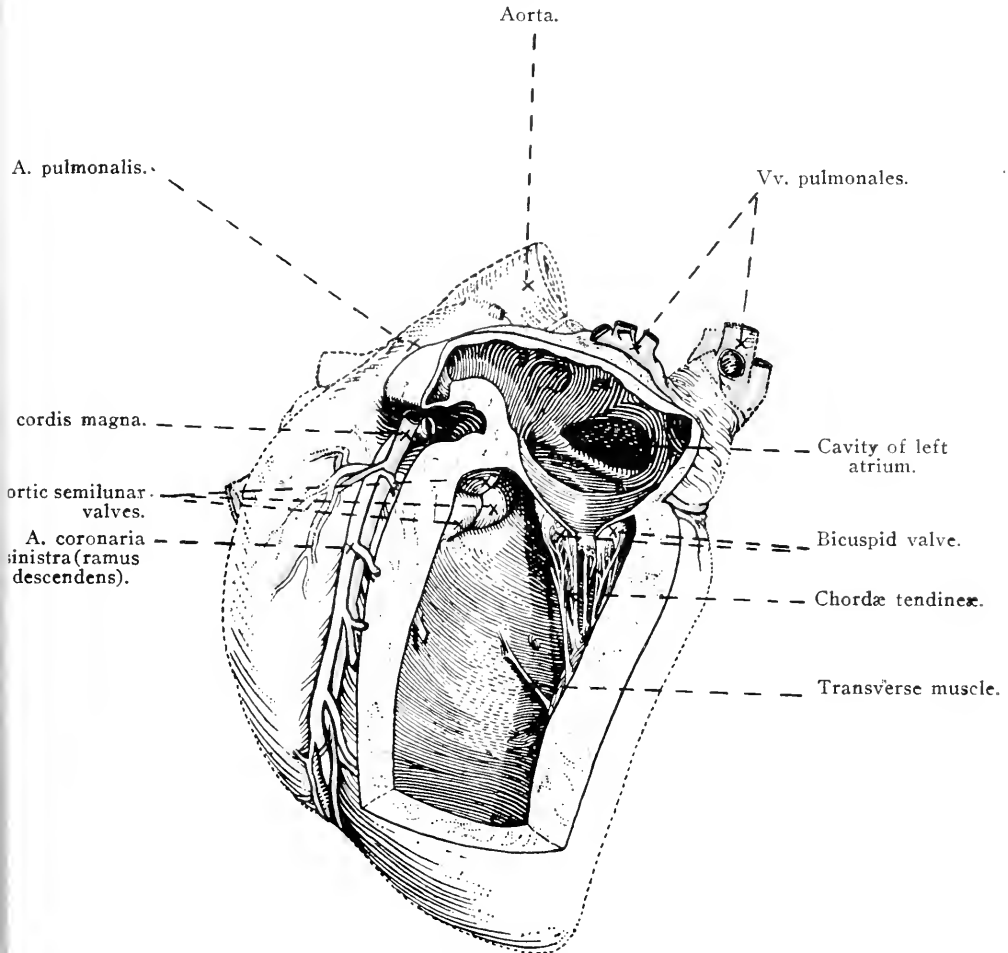


FIG. 14.—The heart viewed obliquely from the left and behind, with the interior of the left atrium and left ventricle exposed.

*Dissection.*—Now proceed to examine the left side of the heart, beginning with the left atrium. To open this cavity it is necessary to make one incision only, entering the knife far back and cutting forwards to the extremity of the auricular appendage. The incision should be made near the coronary groove, so as to avoid injury to the terminations of the pulmonary veins.

*Atrium sinistrum.*—In its external characters the left atrium

differs somewhat from the corresponding cavity on the right side of the heart. The auricle, the tip of which is slightly blunter than that of the right auricle, is more or less dentated along its border, points in a cranial direction, and fits into an angle formed by the pulmonary artery and the base of the left ventricle. In the interior of the cavity the wall is smooth, except in the auricle, in which part alone there are *musculi pectinati*. The number of openings from the pulmonary veins into the atrium is variable (from four or five to eight or nine). The atrio-ventricular orifice (*ostium*<sup>1</sup> *atrioventriculare sinistrum*) is oval in outline and somewhat smaller than the corresponding opening in the right atrium, though the size of the opening depends largely on the

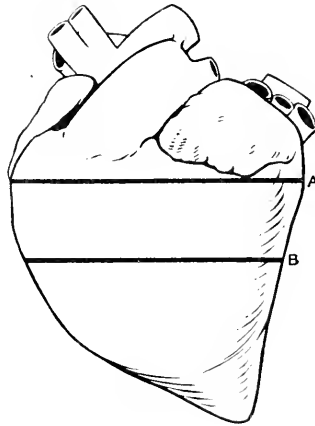


FIG. 15.—Key outline of the heart to show the position of the sections illustrated in Figs. 16 and 17.

condition of contraction or relaxation of the muscular wall of the ventricle.

*Dissection.*—To open the left ventricle an incision should begin near the coronary groove and be carried parallel to one longitudinal groove round the apex and up the other side parallel to the other longitudinal groove.

*Ventriculus sinister.*—The left ventricle differs from the right in its general shape. It is conical in conformity with the form of the ventricular mass of the heart, and its apex forms the apex of the heart as a whole. Owing to the thickness of its wall, combined with the fact that the interventricular septum is concave towards the left, a transverse section of the left ventricle would present an oval or rounded outline. At the same time it must be noted that the wall of the cavity is not of uniform thickness. It is thin at the apex, and the septum is divisible into a lower thick muscular part (*septum musculare*) and a thinner upper part (*septum membranaceum*).

<sup>1</sup> *Ostium* [L.], (*os*, a mouth; in a borrowed sense, an entrance), a door or entrance.

The papillary muscles are two in number and large in size. Trabeculæ carneæ are less conspicuous than in the right ventricle. The valve (valvula bicuspidalis) guarding the atrio-ventricular orifice has two cusps, larger and stronger than the segments of the tricuspid valve, and cranial and caudal in position. The caudal cusp lies between the atrio-ventricular orifice and the opening into the aorta.

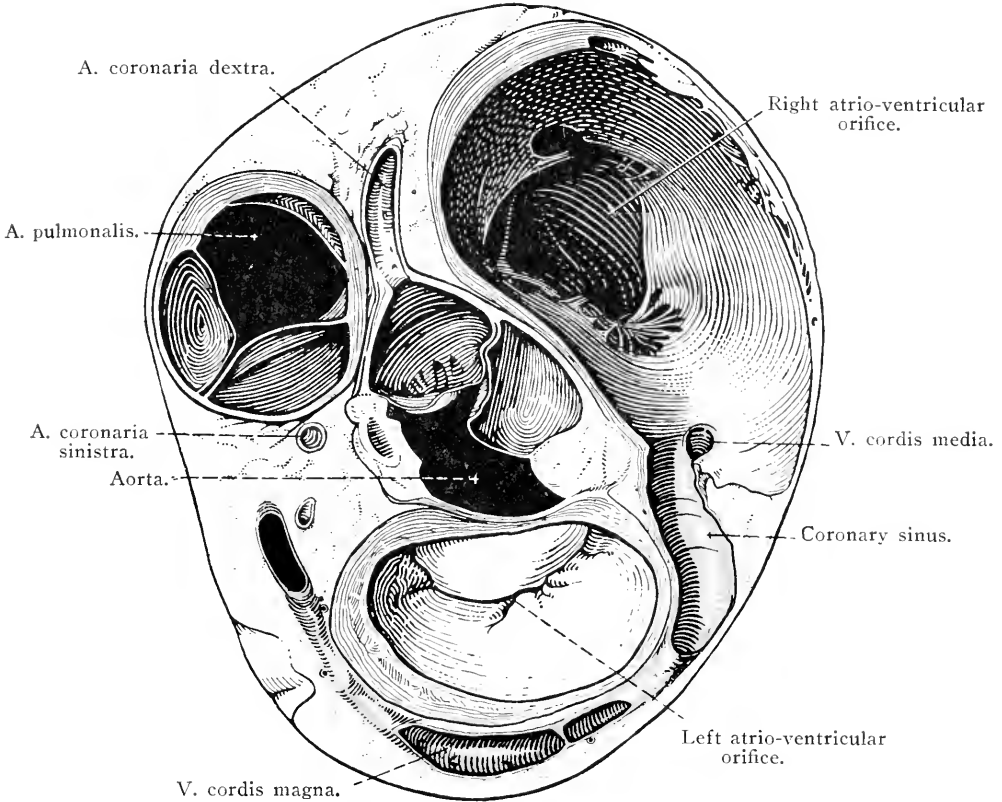


FIG. 16.—Transverse section of the heart at the level indicated by the line A in Fig. 15.

Blood leaves the left ventricle by an opening (ostium aorticum) leading into the aorta, round which there are three semilunar valves similar to those guarding the entrance into the pulmonary artery, but stronger in order to support a greater pressure of blood. These will be examined later.

**A. PULMONALIS.**—The pulmonary artery is the large vessel that leaves the conus arteriosus of the right ventricle. The first part of the artery lies between the apices of the auricles of the right and

left atria of the heart. After a short, oblique course in a dorsal and caudal direction, the artery terminates by dividing into right and left branches (one for each lung) that have already been examined in connection with the roots of the lungs (page 20).

**AORTA.**—The main systemic arterial trunk, the aorta,<sup>1</sup> springs from the left ventricle, its origin lying to the right of that of the pulmonary artery and slightly caudal thereto. It is customary to

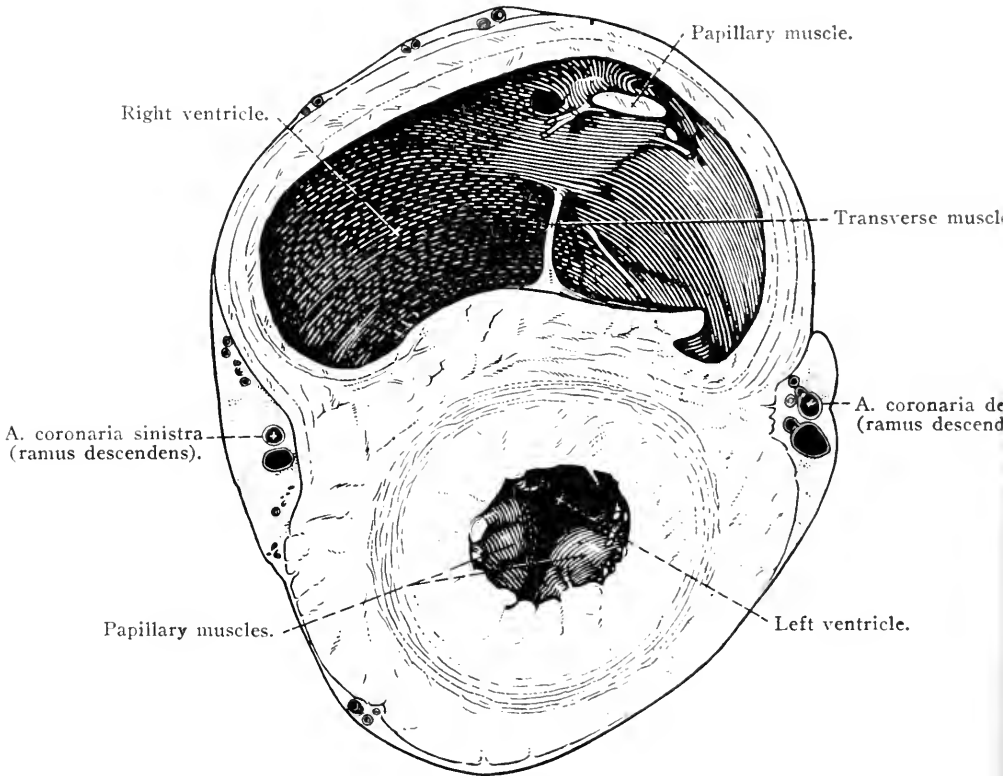


FIG. 17.—Transverse section of the heart at the level indicated by the line B in Fig. 15.

consider the first part of the aorta as divisible into two portions: (1) the ascending aorta (*aorta ascendens*), and (2) the aortic arch (*arcus aortæ*). In the horse, however, such a strict division is impracticable, and it is sufficient to say that the ascending aorta is that part of a continuous curved vessel from which the coronary arteries arise.

Where it leaves the left ventricle the aorta is at its widest (*bulbus aortæ*), and here it is dilated into three pouch-like *aortic sinuses*

<sup>1</sup> *ἀορτή* (*aorte*) [Gr.], from *ἀείρω* (*æiro*), I lift up. The term was first applied to the bronchus, but later (Aristotle) it was used as in modern anatomy.

(sinus aortæ), which correspond in position to the three cusps of the aortic valve.

The aortic arch has its convexity looking in a dorso-cranial direction and slightly to the left of the median plane. The curve of the vessel brings the aorta into contact with the vertebral column about the sixth or seventh thoracic vertebra, at which point the descending aorta<sup>1</sup>

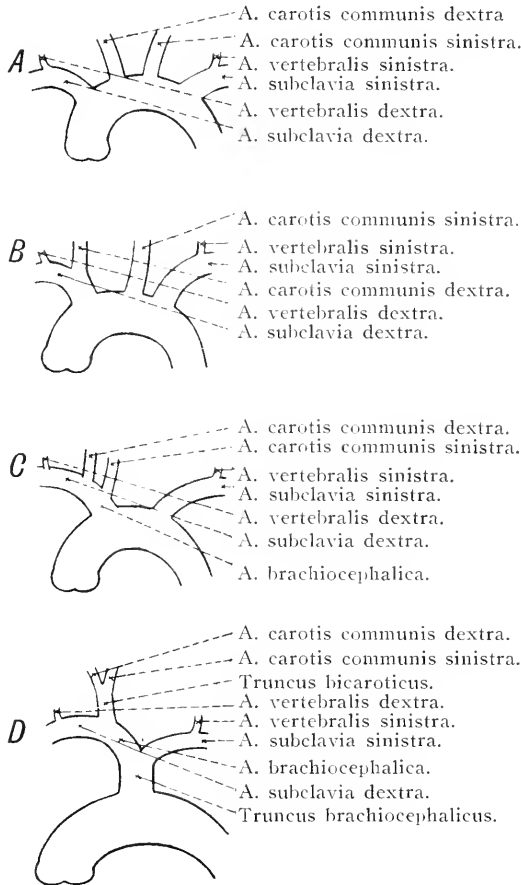


FIG. 18.—Diagram of the arteries arising from the aortic arch.

A=primitive arrangement ; B=man ; C=dog ; D=horse and ruminants.

(aorta descendens) may be assumed to begin. From the convexity of the arch springs a large vessel—the *common brachio-cephalic trunk*—from which arise the arteries that supply the head and neck, both thoracic limbs, and a considerable amount of the wall of the chest. The concavity of the arch is crossed very obliquely by the pulmonary artery, with which it is connected by a fibrous cord, the *ligamentum*

<sup>1</sup> The term “descending aorta” is borrowed from human anatomy and is not appropriate in the domestic mammals.

*arteriosum*. The ligament of the adult represents the *ductus arteriosus* of the embryo, by which most of the blood of the pulmonary artery, not required by the non-functioning lungs, was transferred to the aorta.

The aortic arch is enclosed within the pericardium to about the point of attachment of the ligamentum arteriosum and is crossed on the right by the trachea, the œsophagus and the left recurrent nerve. The left surface of the arch is related to the left vagus nerve, from which the left recurrent turns round the concavity of the arch to reach its right face.

*Dissection.*—The common brachio-cephalic trunk and its branches must be followed to the entrance to the thorax. This will be made easier if the cranial vena cava is cut across just before it enters the pericardium. In cleaning the blood vessels great care must be taken to preserve intact the numerous nerves—some of them of small size—to which they are related.

Consideration of the arteries arising from the aortic arch in different mammals leads to the conclusion that the most primitive arrangement is one in which four vessels have independent origin from the arch. In the order of their origin these are the right subclavian, the right common carotid, the left common carotid and the left subclavian. The right and left subclavian arteries supply blood to the right and left thoracic limbs and the right and left sides of the wall of the chest respectively; while the right and left common carotid arteries furnish branches to the two sides of the head and neck.

The simple arrangement of four independent arteries, however, is not common. In most mammals a greater or less amount of fusion occurs whereby two or more arteries arise together from the aortic arch. In man, for example, the right subclavian and the right common carotid arteries spring from a common trunk, with the result that the vessels leaving the aortic arch are reduced to three in number. In the dog a further reduction is produced by the fusion of the left common carotid with the common trunk; so that, in this animal, the aortic arch has only two arteries springing from it, namely, a brachio-cephalic and a left subclavian: the brachio-cephalic giving off the left common carotid and ending in the right common carotid and right subclavian arteries.

In the horse and the domestic ruminants the maximum of fusion takes place, for in these animals the left subclavian has also joined the common trunk. The single vessel leaving the aortic arch of these animals is the common brachio-cephalic trunk, which divides into the brachio-cephalic and left subclavian arteries.

In the horse and ruminants, moreover, the right and left common

carotid arteries have blended at their origin to form a *bicarotid trunk*.

**TRUNCUS BRACHIOCEPHALICUS COMMUNIS.**—If, as has been stated above, the common brachio-cephalic<sup>1</sup> trunk is the result of fusion of four vessels, all of which, in the primitive arrangement, have independent

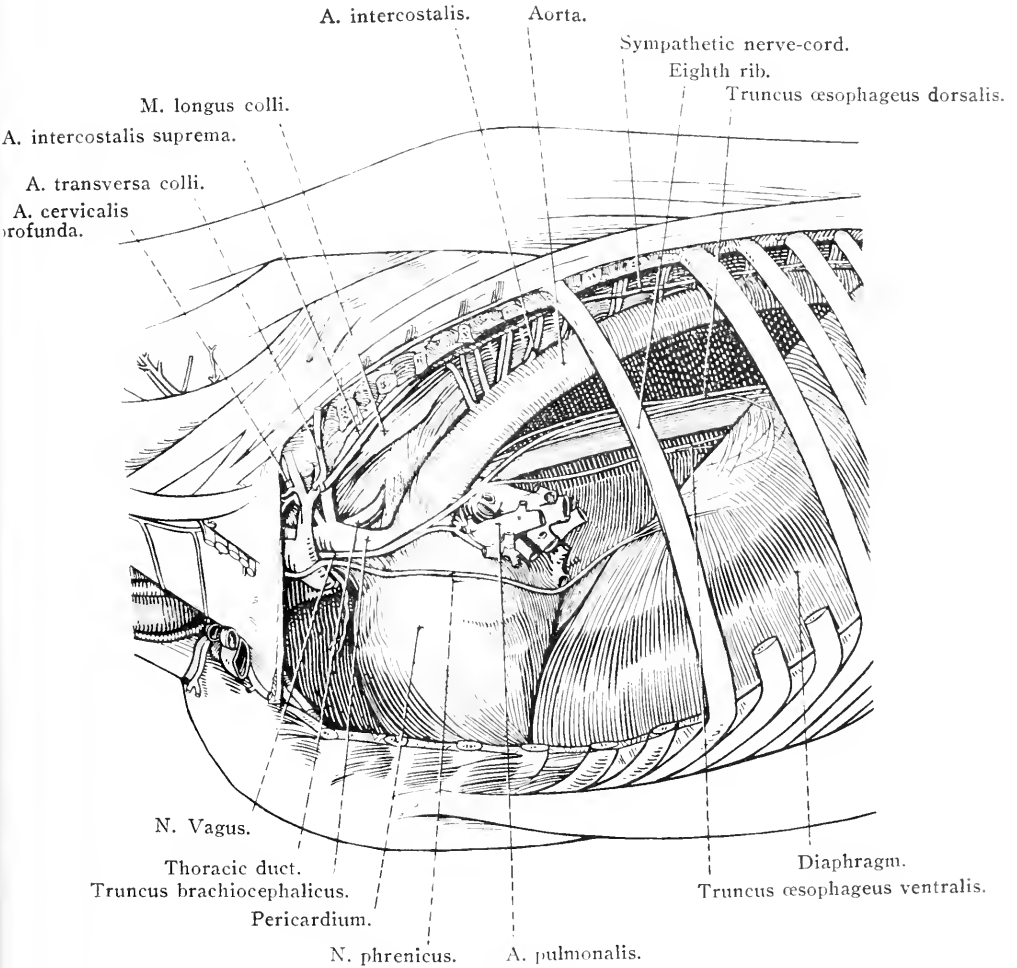


FIG. 19.—Dissection of the thoracic contents from the left side, after removal of the lung.

origin from the aortic arch, it will not be unreasonable to expect considerable individual variation in the length of the common trunk so formed. Sometimes, indeed, the trunk as such does not exist, the left subclavian and brachio-cephalic arteries arising from a common point on the convex side of the aortic arch.

<sup>1</sup> *Brachium* [L.], *βραχίων* (brachiōn) [Gr.], the arm (above the elbow). *Cephalicus* [L.], *κεφαλικός* (cephalicos) [Gr.], pertaining to the head (*κεφαλή*).

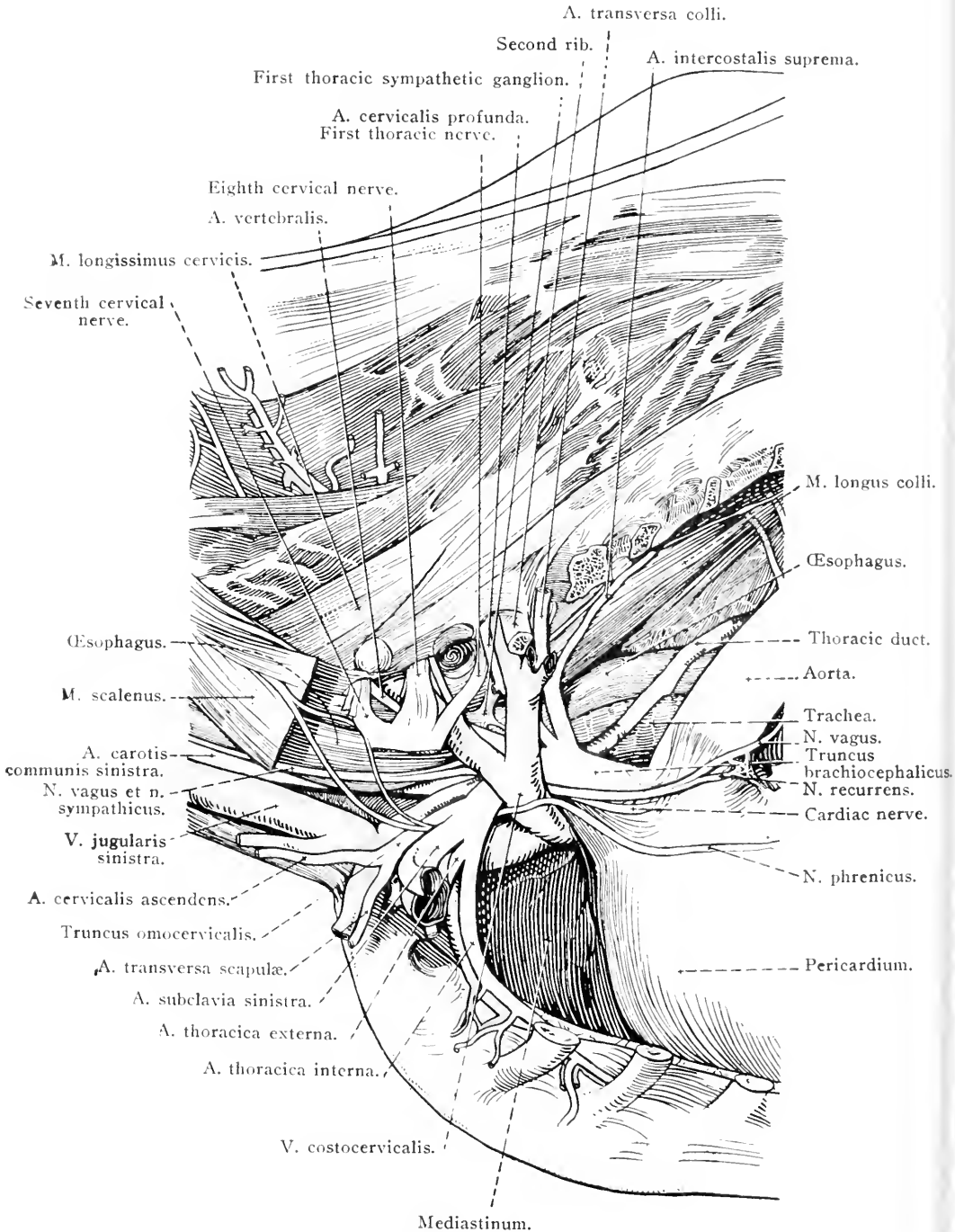


FIG. 20.—Dissection of the vessels and nerves in the region of the entrance to the thorax, seen from the left.



When well developed, the common brachio-cephalic trunk may be as much as 6-7 cm. in length. Leaving the aortic arch within the pericardium, it runs in an oblique cranio-dorsal direction, slightly to the left of the median plane of the body, ventral to the trachea and dorsal to the cranial vena cava. Opposite the second intercostal space or the third rib the trunk ends by dividing into two vessels of unequal size, the left subclavian and brachio-cephalic arteries.

A. SUBCLAVIA SINISTRA.—The left subclavian<sup>1</sup> artery is the smaller of the two terminal branches of the common brachio-cephalic trunk. It passes to the thoracic inlet in a curved course the convexity of which is dorsal, and, at the border of the first rib, becomes the axillary artery. To the right of the subclavian artery lie the trachea, the œsophagus and the thoracic duct; while its left face is crossed by the common venous trunk formed by the union of the vertebral, deep cervical and costo-cervical veins. The concavity of the arch formed by the subclavian artery is related to the left phrenic, cardiac and vagus nerves.

The branches of the left subclavian are: (1) The costo-cervical artery; (2) the deep cervical artery; (3) the vertebral artery; (4) the internal thoracic artery; (5) the omo-cervical trunk; and (6) the external thoracic artery.

(1) *A. costocervicalis*.—The costo-cervical<sup>2</sup> artery is a short vessel that crosses the left face of the trachea, œsophagus and longus colli muscle, with a slight degree of obliquity, to reach the vertebral end of the second intercostal space. Here it divides into the transverse artery of the neck and the supreme intercostal artery.

(a) The *transverse artery of the neck* (*A. transversa colli*) at once leaves the chest by passing between the second and third ribs, and traverses the surface of the ilio-costalis and longissimus dorsi muscles. Its branches supply the ventral serratus, longissimus cervicis, spinalis dorsi et cervicis, multifidus, rhomboid and trapezius muscles. One branch runs in a dorsal and cranial direction underneath the splenius muscle and anastomoses with branches of the deep cervical artery.

(b) The *supreme intercostal artery* (*A. intercostalis suprema*) travels in a caudal direction in the groove between the bodies of the thoracic vertebræ and the longus colli muscle in company with the sympathetic trunk. It furnishes the second, third and fourth (sometimes also the fifth) intercostal arteries.

(2) *A. cervicalis profunda*.—The deep cervical artery leaves the convex side of the curve of the left subclavian close to the origin of the

<sup>1</sup> *Sub* [L.], under, near. *Clavicula* [L.], dim. of *clavus*, a nail, or *clavis*, a key.

<sup>2</sup> *Costa* [L.], a rib. *Cervicalis* [L.], pertaining to the neck (*cervix*).

costo-cervical artery (possibly in common with it), runs obliquely across the œsophagus and the longus colli muscle, and leaves the chest between the first and second ribs. Before leaving the thorax, it supplies a small *cranial mediastinal artery* (a. mediastinalis cranialis) to the precardial mediastinum, and the *first intercostal artery* (a. intercostalis prima).

After leaving the thorax, the deep cervical artery divides into transverse and ascending branches. The *ramus transversus* furnishes vessels to the muscles in the neighbourhood of the junction of the neck and thorax. The *ramus ascendens* passes up the neck in relation to the ligamentum nuchæ, and is examined during the dissection of the neck.

(3) *A. vertebralis*.—The vertebral artery passes in a cranial and dorsal direction across the œsophagus to the thoracic entrance, where it disappears between the longus colli and scalenus muscles. Its further course belongs to the neck.

(4) *A. thoracica interna*.—The internal thoracic artery leaves the concave side of the left subclavian about the caudal border of the first rib. Following the inner surface of the rib, it reaches the sternum about the extremity of the second costal cartilage and there disappears under the transverse thoracic muscle. Its subsequent course will be followed later.

(5) *Truncus omocervicalis*.—The omo-cervical<sup>1</sup> trunk arises about the same level as the internal thoracic, but from the convex side of the subclavian artery. Leaving the thorax at once, under the scalenus muscle, it divides into ascending cervical and transverse scapular arteries.

(6) *A. thoracica externa*.—The external thoracic is the smallest branch of the subclavian, and leaves the thorax by curving round the sternal end of the first rib to pass backwards on the deep face of the pectoral muscles.

A. BRACHIOCEPHALICA. —The brachio-cephalic artery is a short vessel, of larger size than the left subclavian, placed between the trachea and the cranial vena cava. It ends by dividing into the right subclavian artery and the much smaller bicarotid trunk. As a rule there is only one collateral branch, namely, a common vessel (costo-cervical trunk) from which the right costo-cervical and deep cervical arteries take origin. It will be noted that these vessels on the right side of the body differ from those on the left in not having independent origins. The common stem from which they spring crosses the right face of the trachea and may extend so far as to come into contact with the longus

<sup>1</sup> ὠμος (ōmos) [Gr.], shoulder. *Cervicalis* [L.], pertaining to the neck (*cervix*).

colli muscle. It is not, as a rule, related to the œsophagus, because this tube is here placed to the left of the median plane of the body.

The right costo-cervical and deep cervical arteries behave in the same manner as do those on the left side of the thorax.

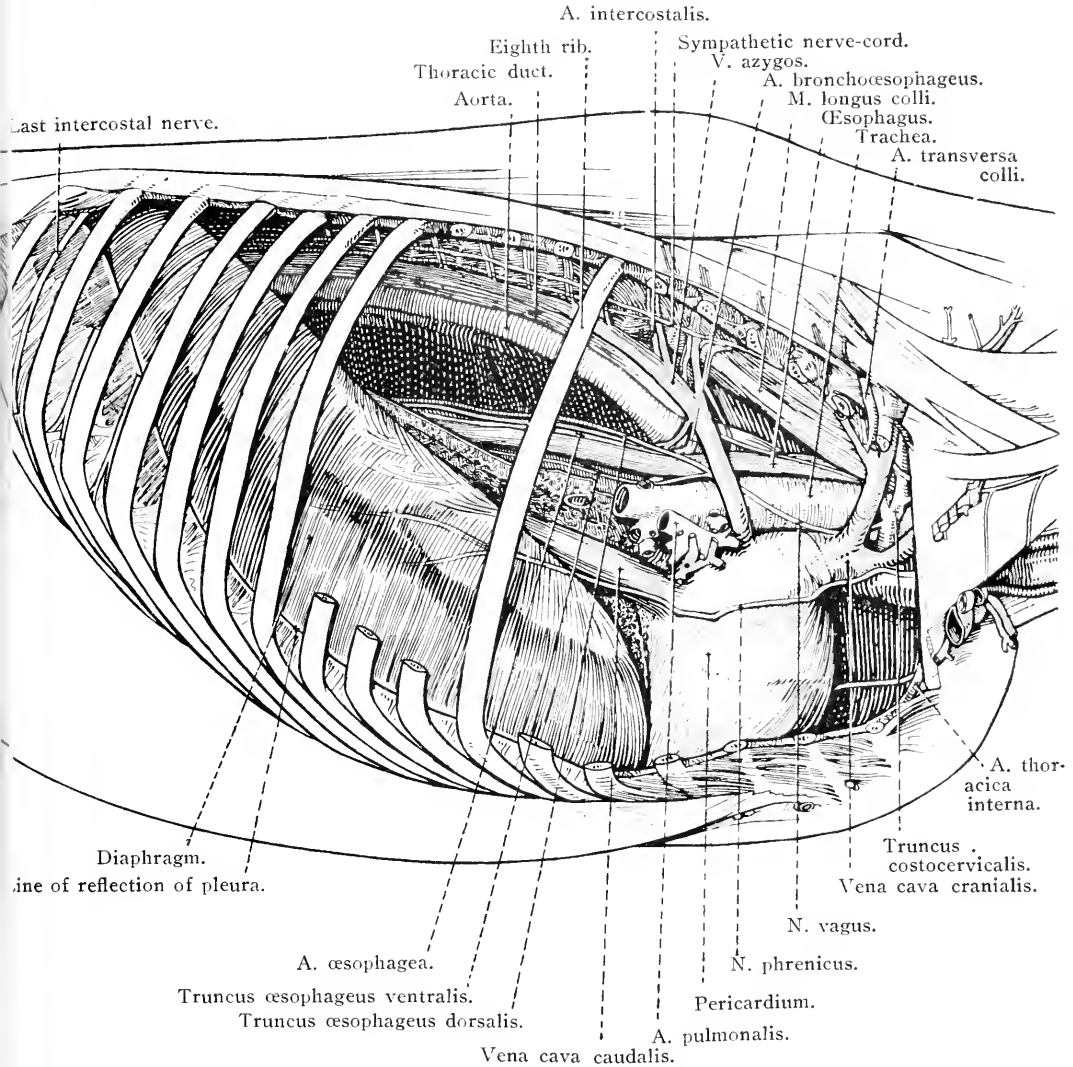


FIG. 21.—Dissection of the thoracic contents from the right side, after removal of the lung.

**TRUNCUS BICAROTICUS.**—The bicarotid trunk, presumably because of its production by the fusion of two vessels, is very variable in length. It passes to the entrance to the chest ventral to the trachea, and divides into the right and left common carotid<sup>1</sup> arteries. Ventral to the trunk

<sup>1</sup> *καρωτις* (*carōtis*) [Gr.], from *κάρος* (*caros*), deep sleep. It is stated that the ancients believed that sleep was induced by increased flow of blood through the arteries passing to the head.

are the termination of the jugular veins and the commencement of the

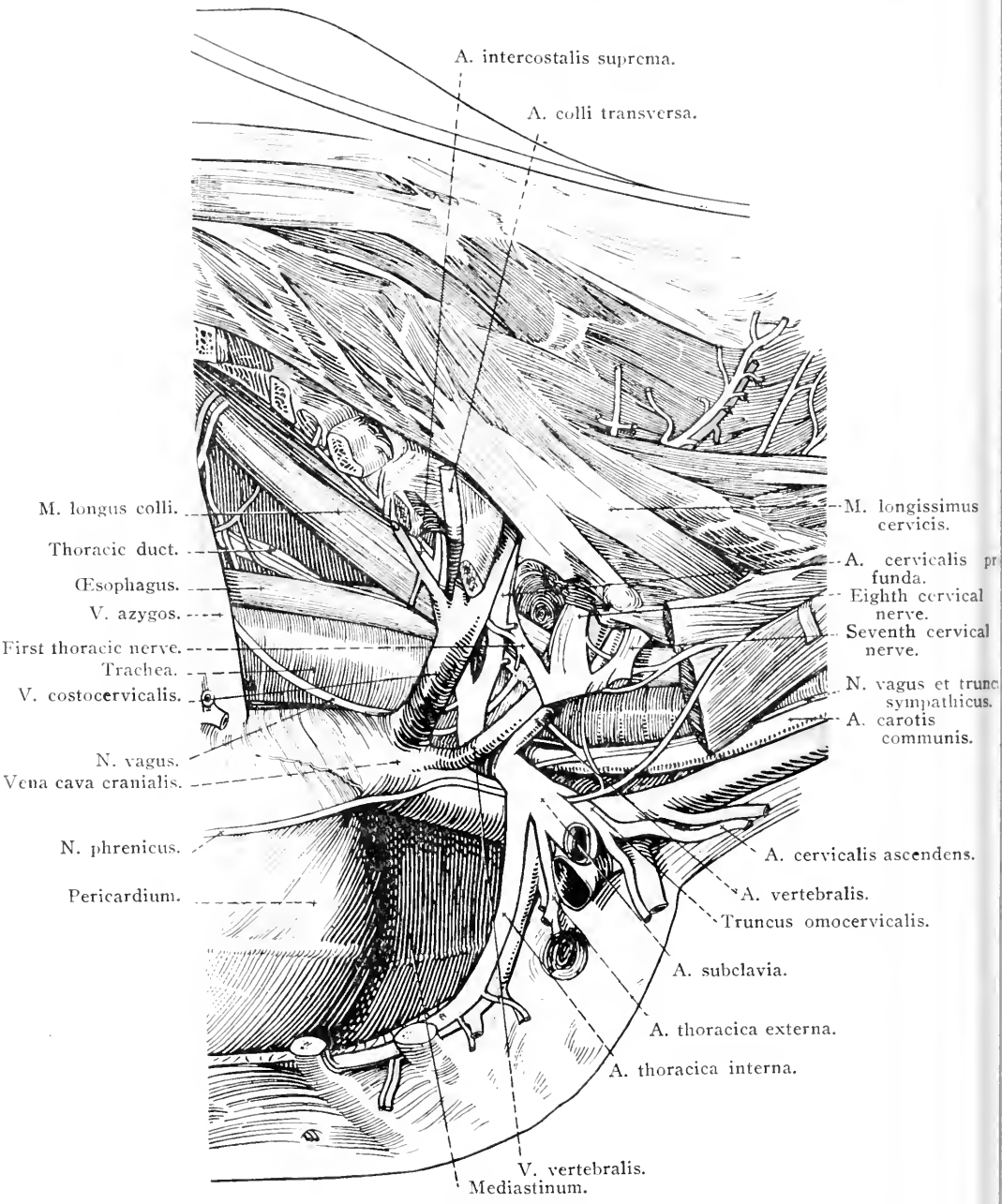


FIG. 22.—Dissection of the blood-vessels, &c., of the thorax, as seen from the right side.

cranial vena cava. Lateral to the trunk are the vagus and recurrent nerves.

A. SUBCLAVIA DEXTRA.—The right subclavian artery continues the curve that has been begun by the brachio-cephalic, and, like the left artery of the same name, terminates at the border of the first rib, where it becomes the axillary artery. The right subclavian is at a slightly more ventral level than the left artery.

From the right subclavian arise the vertebral artery, internal thoracic artery, omo-cervical trunk and external thoracic artery of the right side of the body. Each of these pursues a course similar to that of its counterpart on the other side of the thorax.

*Lymph glands.*—A considerable number of lymph glands have been encountered during the dissection of the large vessels in the pre-cardial mediastinum. Numerous glands (lymphoglandulæ mediastinales craniales), variable in size but generally small, lie along the course of the common brachio-cephalic trunk and its branches. On the right side of the body they are in contact with the trachea; on the left side, with the œsophagus also. Some of them will be found between the trachea on the one hand, and the cranial vena cava and the right atrium on the other, and these are generally continuous with the bronchial lymph glands that have already been examined in connection with the roots of the lungs. It is possible also that a few small glands may be found on the dorsal surface of the trachea.

The caudal cervical lymph glands (lymphoglandulæ cervicales caudales) form a large group continuous with the foregoing, ventral to the trachea at the entrance to the chest. They fill the various chinks between the large vessels and muscles in this region, and extend for some distance into the neck.

*Dissection.*—Cut through the costo-cervical, deep cervical and vertebral arteries close to their origins on both sides of the body. In doing this, every care must be taken not to injure neighbouring structures. The thoracic duct is most liable to injury, and should be secured before the arteries are severed. If a careful search be made on the left side of the chest in the angle formed by the divergence of the aorta and the common brachio-cephalic trunk, the duct will be found as a very thin-walled vessel crossing the left face of the trachea and the œsophagus.

THE TRACHEA AND BRONCHI.—The trachea<sup>1</sup> or tube by which air passes to and from the lungs begins in the neck, traverses the thoracic inlet and the pre-cardial mediastinum, comes into contact with the base of the heart, and terminates in the two bronchi on a level with the fifth rib or the fifth intercostal space, some 10 or 12 cm. from the vertebral column. The thoracic portion of the trachea is not precisely in the median plane except at its termination. The presence of the œsophagus causes it to incline a little to the right.

<sup>1</sup> τραχεΐα (tracheia) [Gr.], rough (artery).

The main ventral relations of the trachea in the thorax are the bicarotid trunk, the brachio-cephalic artery, the common brachio-cephalic trunk and the cranial vena cava. Along the ventral border of each lateral surface runs a recurrent nerve. To the left the trachea is related to the left subclavian and costo-cervical arteries, the thoracic duct and the aorta. Close to the thoracic inlet the œsophagus also lies to the left of the trachea, but later it becomes dorsal in position.

The right vagus nerve runs along the right face of the trachea, and this surface is crossed by the costo-cervical trunk and vertebral artery and the corresponding veins, and the vena azygos, as well as by sympathetic nerves.

Dorsally the trachea is at first in contact with the longus colli muscle, and later with the œsophagus.

Of the bronchi,<sup>1</sup> the right is the wider and shorter, and is in contact with the vena azygos; the left bronchus is related to the aorta, and is crossed dorsally by the œsophagus.

A group of lymph glands (lymphoglandulæ bronchiales), previously noted, generally more or less pigmented, will be found about the bifurcation of the trachea.

THE OESOPHAGUS.—The œsophagus<sup>2</sup> enters the chest along with and to the left of the trachea. This relationship is maintained for a little distance, but later the œsophagus, inclining to the right, becomes dorsal to the trachea and crosses its bifurcation in the median plane of the body. Having traversed the postcardial mediastinum, the tube leaves the thorax by the hiatus œsophageus of the diaphragm on a level with the thirteenth thoracic vertebra. Its relations on the left are the first rib, the roots of the left brachial plexus, sympathetic ganglia, the vertebral, deep cervical and costo-cervical arteries, the thoracic duct and the aortic arch. On the right it is crossed by the vena azygos.

The gullet and the vagus nerves are intimately related to each other.

It should be noted that the wall of the œsophagus is red in colour until the neighbourhood of the tracheal bifurcation is reached, after which it is pale.

Pale muscular fibres are often described as connecting the œsophagus to the trachea and left bronchus (m. bronchoœsophageus) on the one hand, and the vertebral column (m. pleuroœsophageus) on the other.

A chain of small lymph glands (lymphoglandulæ mediastinales caudales) lies along the œsophagus in the postcardial mediastinum.

N. VAGUS.—The right and left vagus<sup>3</sup> nerves descend the neck in

<sup>1</sup> βρόγχος (bronchos) [Gr.], windpipe.

<sup>2</sup> ὀσείν (oîsein) [Gr.], to carry. φάγῳνα (phagma) [Gr.], food.

<sup>3</sup> Vagus [L.], wandering, rambling. The nerve "wanders" from the head, down the neck and through the thorax into the abdomen.

intimate contact with the right and left sympathetic cords, and enter the thorax between the subclavian artery and vein of their own side. In the precardial and cardial mediastina the two nerves have different relations.

The right nerve passes underneath the arch formed by the subclavian artery, and then traverses obliquely the right face of the brachio-cephalic artery and the trachea. This brings it into contact with the œsophagus where a division into dorsal and ventral branches (*ramus dorsalis et ramus ventralis*) takes place. Close to the point of division the nerve is crossed to the right by the *vena azygos*.

The left nerve enters the thorax related to the œsophagus, passes underneath the arch of the left subclavian artery, crosses the left face of the common brachio-cephalic trunk and the aortic arch and the dorsal face of the left bronchus, and divides into two branches—dorsal and ventral.

The dorsal branches of the two vagus nerves run along the dorsal border of the œsophagus to the level of the twelfth or thirteenth thoracic vertebra, where they unite to form the *dorsal œsophageal trunk* (*truncus œsophageus dorsalis*), which accompanies the œsophagus through the diaphragm into the abdomen. The termination of the trunk in association with the stomach, &c., is examined during the dissection of the abdomen. It should be noted that the right vagus contributes more fibres to the dorsal œsophageal trunk than does the left nerve.

A *ventral œsophageal trunk* (*truncus œsophageus ventralis*) is in like manner formed by the union of the ventral branches of the two vagus nerves, but this is effected earlier, namely, close to the bifurcation of the trachea.

Both dorsal and ventral branches of the vagus send filaments (*rami bronchiales*) to the *pulmonary plexus* (*plexus pulmonalis*), a network of small nerves, dorsal and ventral to the tracheal bifurcation, formed by twigs from the caudal cervical sympathetic ganglia and some of the thoracic ganglia.

The branches derived from the thoracic part of each vagus are a recurrent nerve, and cardiac, tracheal and œsophageal rami.

The tracheal and œsophageal branches (*rami tracheales*, *rami œsophagei*) concur in the formation of the tracheal and œsophageal plexuses, to which the recurrent nerves and sympathetic ganglia contribute branches.

The cardiac rami (*rami cardiaci*) of the vagus, generally two or three from each nerve, pass to the *cardiac plexus* (*plexus cardiacus*), to which the sympathetic and recurrent nerves contribute. From the plexus

nerves pass to each side of the heart. The right nerves, two or three in number, gain the heart by penetrating between the trachea and the cranial vena cava. They are distributed to the termination of the cranial vena cava, both atria, and the right part of both ventricles. From one to three left cardiac nerves pierce the pericardium close to its connection with the aortic arch, and supply the left part of both ventricles, as well as a portion of the right atrium. They are connected with branches of the right nerves.

**N. RECURRENS.**—The right recurrent nerve<sup>1</sup> leaves the vagus about the level of the second rib, turns round the costo-cervical arterial trunk, and thus gains the right ventral border of the trachea which it follows into the neck. In the neighbourhood of the thoracic inlet the recurrent nerve is related to the bicarotid arterial trunk.

The left recurrent nerve does not leave the vagus until this has reached the aorta. It bends round the aortic arch, between this and the left bronchus and beneath the bronchial lymph glands, and then follows the left ventral border of the trachea through the precordial mediastinum into the neck.

The recurrent nerves furnish filaments to the cardiac (rami cardiaci), tracheal (rami tracheales), and œsophageal (rami œsophagei) plexuses. At the entrance to the thorax each nerve is connected with the caudal cervical ganglion of the sympathetic, as will be seen later.

*Dissection.*—The heart may now be removed from the chest. Cut across the brachio-cephalic trunk, the aortic arch, the vena azygos and the caudal vena cava close to the point at which each pierces the pericardium.

The aortic semilunar valves should be displayed by slitting open the commencement of the aorta. The cut should be made between two cusps so as to avoid unnecessary injury.

**THE SEMILUNAR VALVES (Valvulæ semilunares).**—At the entrance to the aorta and pulmonary artery there are three semilunar valves, all constructed on the same principle and arranged in such a manner as to prevent the regurgitation of blood from the artery into the ventricle, but offering no obstacle to the flow of blood in the normal direction. Each valve, as its name indicates, is crescentic, with a fixed convex border and a free concave edge. The convex border is attached to one of three crescentic projections of a fibrous ring that surrounds the exit from the ventricle. The free margin projects into the lumen of the artery and, though concave, is not markedly so. In the middle of this border a small nodular thickening (nodulus valvulæ semilunaris) can be detected in the aortic semilunar valves, but is either very inconspicuous

<sup>1</sup> *Recurrens* [L.], running back. Fibres composing the nerve, having passed down the neck in the vagus, run back to the larynx.



or entirely absent in the pulmonary valves. Behind each semilunar valve the wall of the artery is slightly dilated to form a sinus.

The *aortic semilunar valves* (valvulæ semilunares aortæ) are stronger than those at the entrance to the pulmonary artery in accordance with the greater pressure of blood that they have to withstand. The three valves are arranged so that one of them is cranial in position; the others being right caudal and left caudal. From two of the sinuses behind the valves, namely, cranial and left caudal, openings into the coronary arteries will be readily discovered.

The *pulmonary semilunar valves* (valvulæ semilunares arteriæ pulmonalis) are caudal, right cranial, and left cranial in disposition. The sinuses behind them have no openings leading into arteries.

THE STRUCTURE OF THE HEART.—The greater part of the bulk of the heart is formed by muscular tissue constituting the *myocardium*. This is much more abundant in the walls of the ventricles than in the atria, and particularly abundant in the wall of the left ventricle.

The muscular bundles of the atria may be described as disposed in two strata. The bundles of the more superficial stratum are not confined to one atrium but pass from the wall of one cavity to the wall of the other, and are mostly arranged so that they begin and end in connection with the fibrous rings surrounding the atrio-ventricular orifices. Some of them enter into the formation of the septum between the two atria. The bundles of the deep stratum are confined to one or other of the atria. Many of them begin at an atrio-ventricular fibrous ring, pursue a looped course over the atrium, and end at the ring from which they sprang. Other bundles surround the orifices of the various veins that enter the atria, and are disposed in a circular or spiral fashion. There is no difficulty in determining that these bundles are continued for some distance on to the terminations of the venæ cavæ, and also, for a shorter distance, on to the pulmonary veins where these join the left atrium. Circular fibres also surround the fossa ovalis.

The arrangement of the muscle of the ventricles is more complicated. The surface bundles may be readily traced in a spiral sweep from the base of the ventricles to the apex of the heart. At the apex they converge to a *vortex cordis* in curves that, when the heart is viewed from the apex, run clock-wise. From the vortex the bundles run upwards, deep in the wall of the heart, and end in a papillary muscle in the ventricle opposite to that from which they originally started. Underneath the superficial bundles are others that become less and less spiral the deeper they lie in the wall of the ventricle, until their course is at right angles to the long axis of the cavity. Casual

examination of these circular bundles might lead to the supposition that they are limited to one ventricle. It is stated, however, that they circle round one ventricle, traverse the interventricular septum, and then circle round the other ventricle. The wall of the left ventricle contains also deep bundles in the neighbourhood of the left atrio-ventricular fibrous ring, to which they are attached.

Until comparatively recent years it was generally believed that there was no connection between the musculature of the atria and that of the ventricles. It has been shown, however, that a fasciculus of somewhat modified cardiac muscle, known as the *atrio-ventricular bundle*, begins in a plexiform mass (the *node of Tawara*) on the right face of the interatrial septum. The bundle gains the upper margin of the septum between the ventricles and there bifurcates, one branch passing to the left of the septum, and the other, the larger and more definite, to the right. The right branch crosses the ventricle in the transverse muscle (moderator band) and thus reaches the lateral papillary muscle of this cavity. Another plexiform mass (the *node of Keith and Flack*) with which the atrio-ventricular bundle is also connected, is described as occurring close to the entrance of the cranial vena cava into the atrium.

At the junction of the atria and the ventricles, and round the origins of the aorta and pulmonary artery, are rings of fibrous tissue in association with which one or possibly two irregular masses of cartilage may be found. The larger and more constant of these, lying cranial to the termination of the caudal vena cava, is connected with the fibrous ring that surrounds the origin of the aorta, and to it is attached the right caudal aortic semilunar valve. In old animals this cartilage may be partially or completely ossified. A second, but smaller, cartilage may be present at the origin of the aorta, and to it, when present, the left caudal semilunar valve is attached.

As has been previously remarked, the fibrous rings about the origin of the aorta and the pulmonary artery present crescentic notches into which the convex edges of the semilunar valves are received.

The visceral portion of the serous pericardium, the *epicardium*, covers the heart externally. Between it and the myocardium, especially in the region of the grooves of the heart, is an accumulation of fat in greater or less abundance.

The interior of the heart is lined by a smooth, shining membrane, the *endocardium*, continuous with the lining of the blood vessels. The cardiac valves may be regarded as strengthened duplicatures of the endocardium.

*Arrangement of the cardiac orifices.*—Removal of the atria

permits an examination of the relative position of the various openings associated with the ventricles. Cranial and to the left is that leading into the pulmonary artery, and immediately caudal and to the right of this is the aortic opening. The right atrio-ventricular opening is to the right of the pulmonary orifice, while the left atrio-ventricular opening is immediately caudal to the entrance into the aorta.

Referred to the wall of the thorax, it may be said in general terms that the pulmonary orifice is opposite the third rib and the third interspace, the aortic orifice is opposite the fourth rib and the fourth interspace, the right atrio-ventricular orifice is opposite the fourth and fifth ribs, and the left atrio-ventricular orifice is opposite the fifth rib and the fifth interspace.

*Dissection.*—The sternum should now be removed in the following manner. Cut through the first rib on each side about the middle of its length. Cut across the internal thoracic artery (and vein) close to its origin. Cut through the fifteenth, sixteenth and seventeenth ribs at the same level as that at which the other ribs have been previously severed. Run the knife through the intercostal muscles between the seventeenth and eighteenth ribs and their cartilages.

If now the diaphragm be incised about an inch from its sternal and costal attachments, the sternum, &c., will be free.

(In this operation it is assumed that the dissection of the abdomen has been proceeding at the normal rate.)

M. TRANSVERSUS THORACIS.—The transverse thoracic is a thin sheet of muscle, triangular in outline, lying on the inner (dorsal) surface of the sternum and costal cartilages and covered to a great extent by pleura. Its origin is from the internal proper sternal ligament; and its insertion, by serrations, is to the costal cartilages from the second to the eighth and the sternal ends of the corresponding rib bones.

*Dissection.*—Follow the internal thoracic vessels by incising the transverse thoracic muscle along the line of their course. Occasionally a few small lymph glands may be found along the vessels.

A. THORACICA INTERNA.—The origin of the internal thoracic artery from the subclavian about the caudal border of the first rib has already been noted. After following the inner surface of the rib, the artery disappears by passing under the edge of the transverse thoracic muscle. It now runs towards the diaphragm beneath the muscle and along the line of articulations of the costal cartilages and the sternum, and at the seventh or eighth cartilage it divides into the musculo-phrenic and cranial epigastric arteries. Its branches are as follows:—

(1) *Rami intercostales.*—Intercostal branches are distributed to the sternal ends of the first seven intercostal spaces, where they anastomose with the terminations of the corresponding intercostal arteries.

(2) *Rami perforantes.*—Perforating branches supply the transverse

thoracic and pectoral muscles, as well as the skin in the neighbourhood of the sternum, and anastomose with branches of the external thoracic artery.

(3) *Aa. thymicæ*.—Thymic arteries are, naturally, only possible of demonstration in young animals before the disappearance of the thymus.

(4) *A. pericardiophrenica*.—A very small pericardiaco-phrenic artery may sometimes be found arising on a level with the fourth rib and ending in the pericardium, mediastinum and (possibly) the sternal part of the diaphragm.

(5) *A. musculophrenica*.—The musculo-phrenic artery follows the sternal attachment of the diaphragm—at first on its thoracic side, and afterwards on its abdominal aspect—as far as the cartilage of the last rib. It furnishes branches that supply part of the diaphragm, the intercostal muscles, and the transverse muscle of the abdomen. Branches (*rami intercostales*) also anastomose with the intercostal arteries.

(6) *A. epigastrica cranialis*.—The cranial epigastric artery, from its size and the direction of its course, may be regarded as the direct continuation of the internal thoracic. It quickly leaves the thorax by passing between the ninth costal cartilage and the xiphoid process of the sternum. The rest of its course belongs to the abdomen, where it is found on the dorsal face of the *rectus abdominis* muscle.

V. THORACICA INTERNA.—The internal thoracic vein lies medial to the artery, and is a close satellite of this vessel. It ends by joining the cranial vena cava at the first rib.

*Dissection*.—The joints connected with the costal cartilages and sternum should now be exposed by clearing away all the remains of muscles, &c.

COSTO-CHONDRAL<sup>1</sup> ARTICULATIONS (*Articulationes costochondrales*).—The vertebral end of each costal cartilage is received into a shallow pit at the extremity of a rib-bone, the periosteum of the rib being continuous with the perichondrium of the cartilage.

STERNO-COSTAL ARTICULATIONS (*Articulationes sternocostales*).—The cartilages of the sternal ribs are received into fovea ranged along the border of the sternum. Since movement is necessary in these joints, each is provided with a strong joint-capsule (*capsula articularis*) enclosing a joint-cavity and furnished with a synovial lining. It will be noticed that the cartilaginous extremities of the first pair of ribs are received into a common fovea, and enclosed in a common joint-capsule.

<sup>1</sup> *Costa* [L.], a rib. *Χόνδρος* (*chondros*) [Gr.], cartilage.

The union of each costal cartilage with the sternum is reinforced by a *radiate sterno-costal ligament* (ligamentum sternocostale radiatum), of considerable strength and triangular outline, placed on the inner side of the joint.

**INTERCHONDRAL LIGAMENTS.**—In general, the cartilages of the asternal ribs are attached to each other by elastic tissue; but the eighth and ninth are more firmly united by strong fibrous tissue. A band, the *chondro-xiphoid ligament* (ligamentum chondroxiphoidea), passes from the ninth cartilage to the xiphoid cartilage.

**INTERSTERNAL SYNCHONDROSES**<sup>1</sup> (Synchondroses intersternales).—In the animal at birth the individual bony segments of the sternum are united by cartilage, which, with advancing age, becomes more and more invaded by ossification, until in old animals the various segments may be fused into one bony mass. The coalescence of the sternebrae begins with the last two, and gradually extends in a cranial direction.

An *internal proper sternal ligament* (ligamentum sterni proprium internum) runs along the inner surface of the sternum. It begins as a narrow single band, just behind the joint between the first rib and the sternum, where it is connected with strong fibrous tissue binding the first pair of ribs together, but soon divides into three limbs. The two lateral limbs disappear on the seventh or eighth costal cartilages; while the medial limb can be followed along the sternum to the xiphoid process.

*Dissection.*—Clean the thoracic part of the aorta and the vena azygos, and do so with care, otherwise the thin-walled thoracic duct, which lies between the aorta and the vein, will be destroyed.

**AORTA THORACICA.**—The thoracic part of the aorta continues the aortic arch. At first to the left of the median plane, it gradually inclines towards the right and gains the middle line before the diaphragm is reached. Leaving the thorax by the hiatus aorticus, it enters the abdomen and is thereafter distinguished as the abdominal aorta.

Close to its commencement, the aorta crosses the left face of the œsophagus. To the right it is also related to the vena azygos and the thoracic duct. Ventral to the aorta is the root of the left lung.

The branches of this part of the aorta are as follows:—

(1) *Truncus bronchoœsophageus.*—The broncho-œsophageal trunk is a short single stem that leaves the aorta about the sixth thoracic vertebra, descends over the right face of the parent vessel, and soon divides into the bronchial and œsophageal arteries. Occasionally the trunk leaves the aorta in common with the first pair of aortic inter-

<sup>1</sup> σύν (syn) [Gr.], together. Χόνδρος (chondros) [Gr.], cartilage.

costal arteries; or the trunk may be absent, in which case the bronchial and œsophageal arteries rise separately from the aorta or from the intercostal artery.

The *bronchial artery* (a. bronchialis) runs in a vertical direction between the aorta and the œsophagus to the bifurcation of the trachea, where it divides into right and left branches for the nutritive supply of the right and left lungs respectively. Some twigs are furnished to the trachea, œsophagus, pleura and the bronchial lymph glands.

The *œsophageal artery* (a. œsophagea) is the smaller of the two branches of the broncho-œsophageal trunk. It runs along the dorsal border of the œsophagus to the diaphragm and anastomoses with the œsophageal ramus of the left gastric artery. Small branches are distributed to the œsophagus, caudal mediastinal lymph glands and the pleura; and two or three branches pass between the two layers of the pulmonary ligament to the lungs, where they ramify underneath the pleura.

(2) *Arteriæ intercostales*.—The first four (possibly five) intercostal arteries have been described in connection with the deep cervical and supreme intercostal arteries, from which they arise. The remaining thirteen (or twelve), which may be conveniently distinguished as the aortic intercostals, spring from the dorsal surface of the aorta in pairs; but the fifth and sixth not uncommonly leave the aorta as a common stem.

Each intercostal artery crosses the body of a thoracic vertebra to reach the vertebral end of an intercostal space where it divides into dorsal and ventral rami. A description of these has already been given (page 7).

About the origins of the intercostal arteries small lymph glands (*lymphoglandulæ intercostales*) should be sought.

(3) *Arteriæ phrenicæ craniales*.—Two small cranial phrenic arteries leave the ventral face of the aorta as it is passing through the hiatus aorticus of the diaphragm, or arise from the aorta in common with an intercostal artery. They are distributed to the crura of the diaphragm.

V. *Azygos*.—The vena azygos begins by the union of the first pair of lumbar veins. Entering the thorax to the right of the aorta, it passes along the vertebral bodies to the right of the median plane as far as the sixth thoracic vertebra. Then the vein curves towards the heart, and finally opens into the cranial vena cava just as this is entering the right atrium, or it may possibly enter the atrium directly. To the left the vein is in contact with the thoracic duct and the aorta. Towards its termination it crosses the right face of the œsophagus and trachea.

The vena azygos receives the last twelve or thirteen intercostal veins from the right side of the thorax, and the last five or six (possibly more) from the left side. Sometimes the left intercostal veins join a small vessel (v. hemiazygos) that follows the left dorsal border of the aorta for a distance, then crosses the dorsal face of this artery, and finally unites with the vena azygos.

Small œsophageal and bronchial veins empty their blood into the vena azygos as this vessel is crossing the œsophagus and trachea.

DUCTUS THORACICUS.—By means of the thoracic duct the lymph from the whole body, with the exception of that from the right side of the thorax, the right thoracic limb, and the right side of the head and neck, gains the venous system. Consequently, the duct is the largest lymphatic vessel in the body.

The thoracic duct begins in the abdomen, on a level with the first and second lumbar vertebræ and between the aorta and the right crus of the diaphragm, as an irregular, elongated dilatation known as the *cisterna chyli*.<sup>1</sup> It enters the thorax to the right of the aorta, between this vessel and the vena azygos.

The thoracic part of the duct is subject to a considerable amount of variation. For a longer or shorter distance there may be two ducts, right and left. The right duct—often the only one—runs between the aorta and the vena azygos to about the sixth thoracic vertebra. Here it inclines to the left, and, sloping in a ventral direction, crosses the left face of the œsophagus and trachea. Then, running to the right of the left subclavian artery, it terminates, somewhat dilated, on a level with the cranial border of the first rib by joining either the commencement of the cranial vena cava or the short common vein produced by the union of the two jugulars. The opening of the duct into the vein is provided with a valvular arrangement for the purpose of preventing entrance of blood into the duct. It commonly happens, however, that a small amount of blood eludes the valve and stains the contents of the duct for some little distance.

The left duct is very frequently absent, either wholly or in part. At its greatest development it runs along the vertebral bodies to the left of the aorta as far as the sixth thoracic vertebra, where it joins the right duct. If the two ducts are both present, frequent communications are established between them.

DUCTUS LYMPHATICUS DEXTER.—The lymph from those parts of the body not drained by the thoracic duct finds its way to the venous system by way of the right lymphatic duct. This is a short vessel (4 or 5 cm. in length), not wider than a goose-quill, which terminates in a

<sup>1</sup> χυλός (chylos) [Gr.], juice.

manner similar to the ending of the thoracic duct. The duct varies within very wide limits in different individuals. It may even happen that it is replaced by two or three vessels that enter the venous system at a common point, or the duct may join the thoracic duct.

*Dissection.*—The thoracic part of the sympathetic nervous system must now be examined. This is facilitated by the disarticulation of those parts of the first pair of ribs that are still connected with the vertebral column.

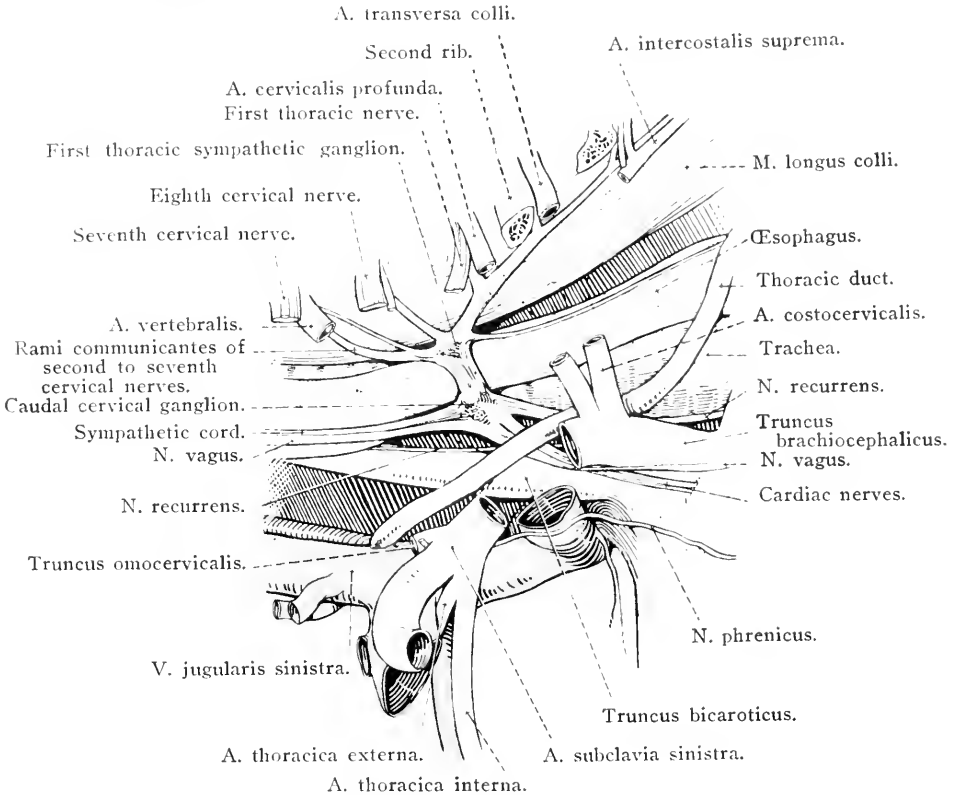


FIG. 23.—The blood-vessels and nerves within the first three ribs of the left side.

**PARS THORACALIS SYSTEMÆ SYMPATHICI.**—Because of its close juxtaposition to, and even confluence with, the first thoracic ganglion, the caudal cervical ganglion should be examined by the dissector of the thorax.

In the neck the cord of the sympathetic and the vagus nerve are contained in the same sheath. At the entrance to the thorax the irregular *caudal cervical ganglion*<sup>1</sup> (ganglion cervicale caudale) is developed on the sympathetic, and thereafter the two nerves separate. On the right side of the body the ganglion usually lies along the

<sup>1</sup> γάγγλιον (ganglion) [Gr.], a knot.



ventral border of the trachea and medial to the scalenus muscle, and on this side it is joined to the first thoracic ganglion by a short cord. On the left, however, it is common to find the two ganglia so blended as to make it impossible to distinguish them. The common ganglion so formed lies within the first rib, lateral to the œsophagus and the longus colli muscle.

The irregularly quadrilateral *first thoracic ganglion* (ganglion thoracale primum) lies within the first rib upon the longus colli muscle

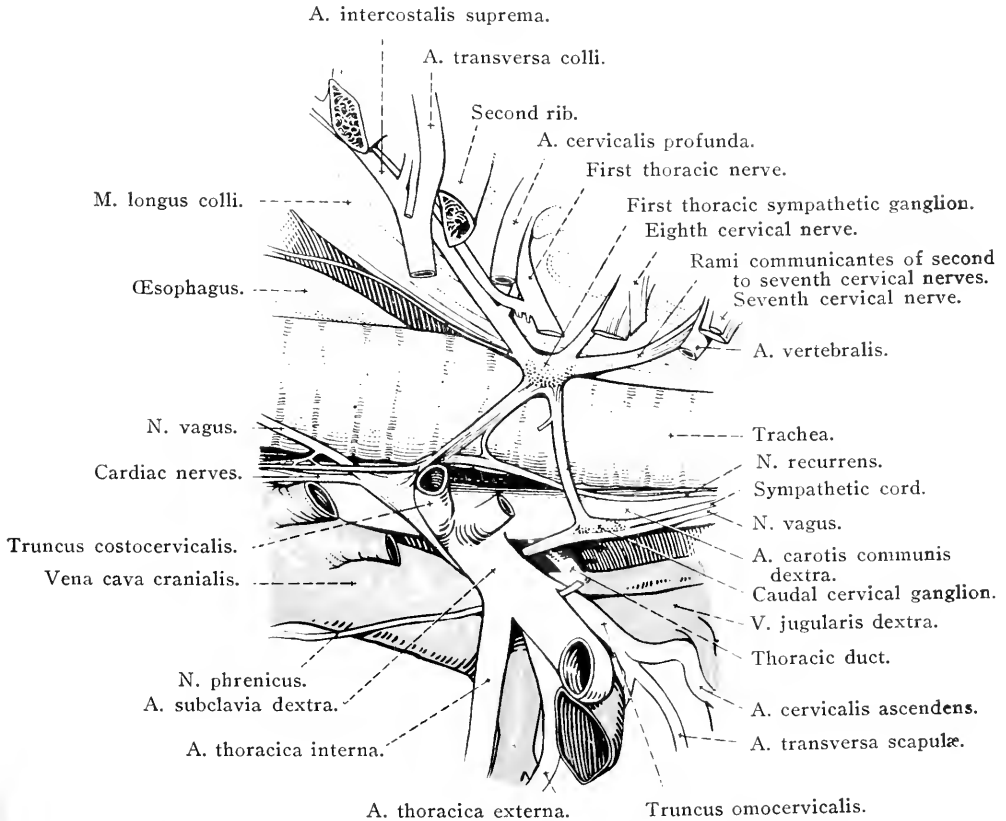


FIG. 24.—The blood-vessels and nerves within the first three ribs of the right side.

and trachea (right), or œsophagus (left), and between the vertebral and deep cervical arteries. Joining the ganglion is a large nerve formed by branches (*rami communicantes*) from the second to the seventh cervical nerves inclusive. This accompanies the vertebral vessels, and therefore traverses the various transverse foramina of the cervical vertebra. Communicating branches also connect the ganglion with the eighth cervical and the first and second thoracic nerves. Cardiac nerves leave the ganglion to join the cardiac plexus on the ventral surface of the trachea.

From the first thoracic ganglion also arises a nerve cord that can be followed along the dorsal wall of the thorax, over the edge of the diaphragm (between one of its crura and the psoas minor muscle), and into the abdomen. At first the cord occupies a groove at the border of the longus colli muscle, but later it runs across the heads of the ribs and the intercostal vessels immediately underneath the pleura.

Ganglia on the cord, at first small and inconstant but afterwards larger, begin about the third or fourth intercostal space and occur, one at each space, throughout the rest of the thorax. Each ganglion is connected with the ventral primary branch of the corresponding spinal nerve by means of a communicating branch, the *ramus communicans*.

Numerous delicate filaments leave the ganglia to join the fine plexuses associated with the aorta and œsophagus. Two nerves of greater size are known as the splanchnic<sup>1</sup> nerves.

The *greater splanchnic nerve* (n. splanchnicus major) begins as a filament detached from the sixth or seventh<sup>2</sup> thoracic ganglion. Accompanying the sympathetic cord (to which it is generally medial) along the vertebral column, the nerve receives contributions from the succeeding ganglia up to and including the fifteenth or sixteenth. It enters the abdomen by passing between the psoas minor muscle and a crus of the diaphragm, and therein joins the combined cœliac and cranial mesenteric ganglia.

The *lesser splanchnic nerve* (n. splanchnicus minor) is composed of filaments derived from the last two or possibly three thoracic ganglia. This nerve also enters the abdomen and joins the cœliac or the renal plexus.

**M. LONGUS COLLI.**—Only a part (pars thoracalis) of the longus colli muscle can be dissected at the present time. It forms a rounded mass of muscular fibres springing from the bodies of the first five or six thoracic vertebrae, and it is inserted by a strong tendon into the bodies and transverse processes of the last two cervical vertebrae. A synovial bursa lies between the tendon and the vertebral column about the junction of the last cervical and the first thoracic vertebrae.

*Dissection.*—The remains of the muscles should be cleared away from the vertebrae and ribs in order that the joints and ligaments may be examined. Before the articulations can be studied in a thorough manner, it is necessary to open the vertebral canal and remove the spinal cord. Though the cord and its covering membranes (which must be left intact) should be laid aside for examination at a future time, the origins of the spinal nerves—so far as they can be seen without opening the stout,

<sup>1</sup> *σπλαγχνικός* (splanchnicos) [Gr.], pertaining to viscera (*σπλαγχνον* (splanchnon) a viscus).

<sup>2</sup> Throughout the above enumeration, a thoracic ganglion is named in agreement with the thoracic spinal nerve with which it is connected.

tubular dura mater—must now be noted, as must also certain blood vessels associated with the vertebral canal.

The interior of the canal must be exposed by sawing through the vertebral arches on each side as close as possible to the transverse processes. In this way the greater part of the arches, with the spinous processes and ligaments, may be removed from the thoracic and lumbar regions of the vertebral column in one continuous length.

**NERVI SPINALES.**—In the thoracic and lumbar regions the spinal nerves agree in number with the vertebræ. There are, therefore, eighteen thoracic and six lumbar nerves on each side of the body. Each spinal nerve is connected with the spinal cord by two roots—dorsal and ventral—and each root is composed of a number of converging bundles of nerve fibres that pierce the dura mater of the spinal cord. A *spinal ganglion* is developed on the dorsal root as it occupies an intervertebral foramen. Immediately lateral to the ganglion the dorsal and ventral roots unite: thus a mixed spinal nerve is formed. From the mixed nerve a delicate *recurrent nerve* passes to the vertebræ, vertebral ligaments, blood vessels within the vertebral canal and the dura mater of the spinal cord.

It will be noted that most of the spinal nerves gain immediate exit from the vertebral canal by an intervertebral foramen. Towards the end of the spinal cord, however, it is necessary for the nerves to travel for some distance before they reach their foramina of exit; and this distance is greatest in the case of those nerves that arise from the extreme end of the cord. This circumstance is further commented upon and explained in connection with the dissection of the spinal cord itself.

Each spinal nerve divides into two branches: (1) A *dorsal branch* (*ramus dorsalis*) supplying the muscles and skin dorsal to the bodies of the vertebræ; and (2) a much larger *ventral branch* (*ramus ventralis*). From the ventral branch arises a small *communicating branch* (*ramus communicans*) that is connected with a ganglion of the sympathetic cord. *Rami communicantes* consist of white fibres (*white ramus communicans*) passing from the spinal cord to the ganglia, and grey fibres (*grey ramus communicans*) running in the opposite direction. Sometimes the grey and white rami are merged into one: sometimes they are independent. It is largely by way of the *rami communicantes* that nerve impulses are conveyed from the central nervous system to the abdominal and thoracic viscera, and *vice versa*. Typically a slender filament from the *ramus communicans* joins the recurrent nerve mentioned above as leaving the mixed spinal nerve.

In the thoracic region the ventral branches of spinal nerves constitute the intercostal nerves; while in the lumbar region they form the roots of the ilio-hypogastric, ilio-inguinal, genito-femoral, lateral

cutaneous nerve of the thigh and obturator nerves, and contribute fibres to the cranial gluteal and sciatic nerves.

The size of the ventral branches of the thoracic and lumbar nerves

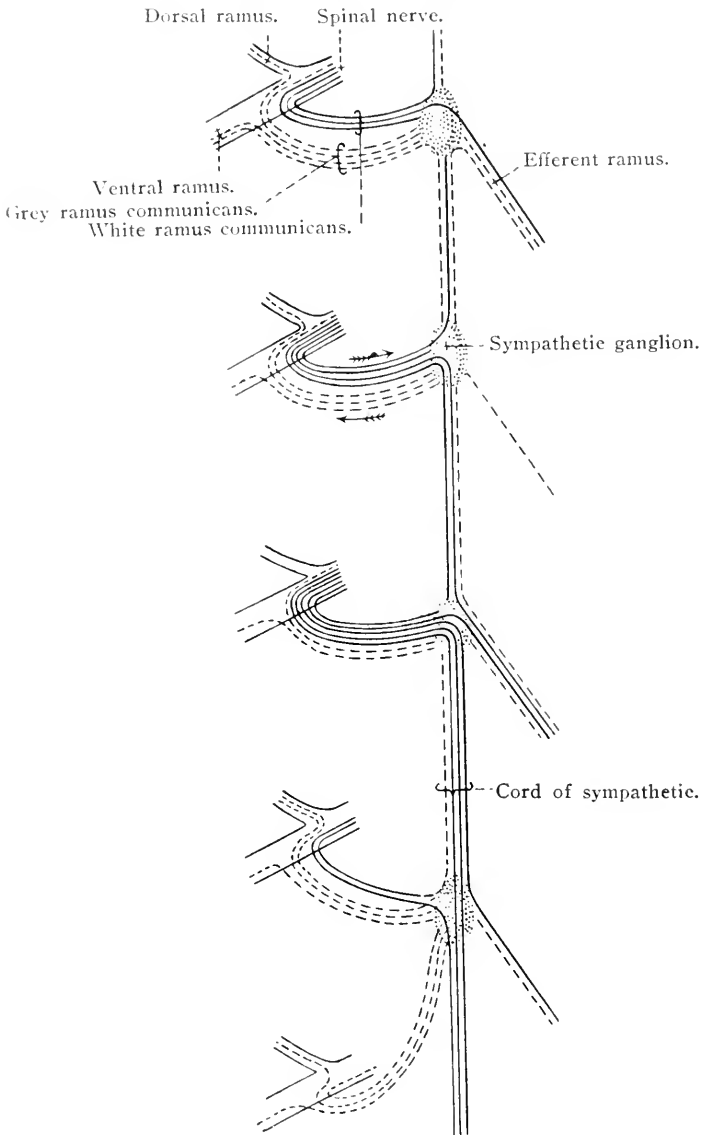


FIG. 25.—Scheme of the sympathetic cord and its connections with the spinal nerves (after Thane).

varies greatly. That of the first thoracic is large: that of the second is smaller. The rest of the thoracic rami are fairly uniform in size; but from the first to the last lumbar there is a gradual increase in size. If any general statement were permissible it would be, that those ventral

branches that are concerned in the formation of limb-plexuses are larger than those not so concerned.

**VEINS OF THE VERTEBRAL CANAL.**—If the floor of the vertebral canal be examined, a large venous trunk—really a sinus (*sinus vertebralis longitudinalis*)—will be found running along each border of the dorsal longitudinal ligament. Transverse communications between the two sinuses pass underneath the ligament, and into them open veins from the interior of the bodies of the vertebræ. Veins from the spinal cord (*venæ spinales*) and its membranous coverings also open into the sinuses.

The sinuses are drained by effluents that pass out of the vertebral canal by the intervertebral foramina and, in the thoracic, lumbar and sacral regions, open into the intercostal and the lumbar and sacral spinal veins.

**THE ARTICULATIONS OF THE VERTEBRAL COLUMN** (*articulationes columnæ vertebralis*).—When two macerated neighbouring vertebræ are placed in their proper position relative to each other, they come into contact at three points—the bodies and the articular processes. In the recent state, however, the bodies do not actually touch each other because, interposed between them, there is a disc-shaped *intervertebral fibro-cartilage* (*fibrocartilago intervertebralis*), thickest in the cervical and coccygeal regions, and thinnest between the thoracic vertebræ. The peripheral part of each fibro-cartilage contains dense fibres arranged in a ring-like manner (*annulus fibrosus*), while the centre of each cartilage, the remains of the embryonic notochord, is softer and yellower (*nucleus pulposus*).

Forming a further connective medium between the vertebral bodies are two longitudinal ligaments.

The *ventral longitudinal ligament* (*ligamentum longitudinale ventrale*) is attached along the ventral surface of the vertebral bodies from the eighth or ninth thoracic to the last lumbar. It ends by expanding and merging into the periosteum of the sacrum. The ligament widens slightly opposite each intervertebral fibro-cartilage, with which it is intimately connected.

The *dorsal longitudinal ligament* (*ligamentum longitudinale dorsale*) extends along the floor of the vertebral canal from the dens of the epistropheus to the sacrum. It is attached firmly to the dorsal aspect of the vertebral bodies and the intervening fibro-cartilages. The width of the ligament is not uniform. Opposite the intervertebral fibro-cartilages it is broad; but opposite the middle of each vertebral body, where the transverse communications between the two longitudinal venous sinuses run beneath it, it is much narrower.

The *supra-spinal ligament* (ligamentum supraspinale), like the foregoing, is common to a number of intervertebral joints. About the fourth thoracic vertebra it is directly continuous with the occipital part of the ligamentum nuchæ. Caudal to this point it forms a strong band firmly attached to the extremities of the vertebral spinous processes, varying in its breadth with the variation in expansion of the ends of the processes.

Though the yellow and elastic *ligamentum nuchæ*,<sup>1</sup> a modification of the supraspinal ligament, belongs to the neck, the dissector of the thorax should examine that part of it which is attached to the thoracic vertebrae. The ligament is readily divisible into two portions: (1) A cord-like or funicular *occipital part* (pars occipitalis), and (2) a lamellar *cervical part* (pars cervicalis). The occipital part merges gradually into the ordinary supraspinal ligament about the fourth thoracic spinous process, and here forms a flattened cord that, on section, is apparently composed of right and left bands blended in the median plane of the body. In this region (the withers) also the right and left borders of the ligament are continued into lateral expansions, about 12-15 cm. wide, that thin out over the surface of the trapezius and rhomboid muscles. A synovial bursa, of variable extent and size, is placed between the ligament and the summits of the thoracic spinous processes over which it passes.

Only a limited extent of the cervical part of the ligament is associated with the thorax. It is attached by digitations to the spinous processes of the second and third thoracic vertebrae, and can readily be separated into right and left halves.

*Interspinal ligaments* (ligamenta interspinalia) fill the intervals between adjacent spinous processes, and consequently vary in dimensions with the length of these processes. It will be noted that the fibres of these ligaments do not take the shortest possible course between two processes, but are disposed obliquely with a slope in a ventral and caudal direction. Further, careful dissection will reveal the fact that each ligament is composed of two layers of fibres—right and left.

*Ligamenta flava*<sup>2</sup> consist of short elastic fibres passing between the opposed borders of adjacent vertebral arches.

*Joint capsules* (capsulae articulares), each possessed of a synovial lining, enclose the joints between opposed articular processes. In those parts of the vertebral column where movement is most free, the capsules are loosest. In the thoracic region, where movement is hampered, the capsules are short.

<sup>1</sup> *Nucha* [L.], the nape of the neck.

<sup>2</sup> *Flavus* [L.], yellow.

*Inter-transverse ligaments* (ligamenta intertransversaria) are developed in the lumbar region, where the transverse processes are best developed. In the Equidae, between the fourth and fifth, fifth and sixth, and sixth lumbar and first sacral vertebræ, joint capsules, strengthened ventrally, surround intertransverse diarthroses.

The movements that are possible between any two adjoining vertebræ are obviously not very extensive; but the sum of the movements in all the joints of a region of the vertebral column may result in a very appreciable bending in a dorsal, ventral, or lateral direction. In addition, it must be remembered that a small amount of rotation of each vertebra about the longitudinal axis of the body is possible.

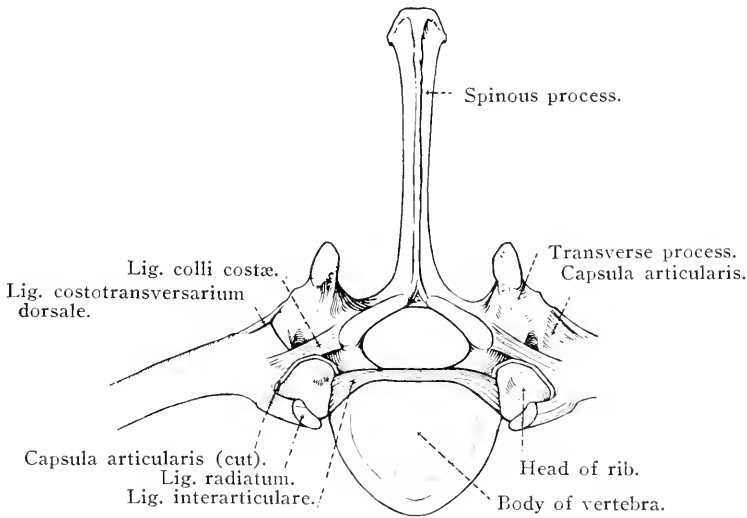


Fig. 26.—The costo-vertebral articulations. Cranial aspect.

During any movement between a vertebra and its neighbour, their articular surfaces glide over each other in an excursion of limited extent.

Naturally, in the thoracic region the range of movement is restricted by the character of the articular surfaces and the presence of ribs.

**THE COSTO-VERTEBRAL ARTICULATIONS** (articulationes costo-vertebrales).—The head of a rib being in contact with the costal foveæ of the bodies of two adjoining vertebræ, and the tubercle of the rib articulating with the transverse process of the more caudal of the two vertebræ, it follows that there are two joints between a typical rib and the vertebral column.

(1) The *capitular articulation* (articulatio capituli costæ) is

provided with a joint capsule which encloses two joint-cavities corresponding to the two vertebral bodies with which the head of the rib articulates, and separated from each other by an interarticular ligament to which the joint capsule is attached. The *interarticular ligament* (ligamentum capituli costae interarticulare) springs from the rough depression on the head of the rib, and passes between the bodies of the vertebrae to the median plane, where it is continuous with the corresponding ligament of the opposite side. The union of the ligaments from opposite sides of the body occurs under cover of the dorsal longitudinal ligament of the vertebral column. Here, also, some fibres of the interarticular ligament are attached to the vertebral bodies and

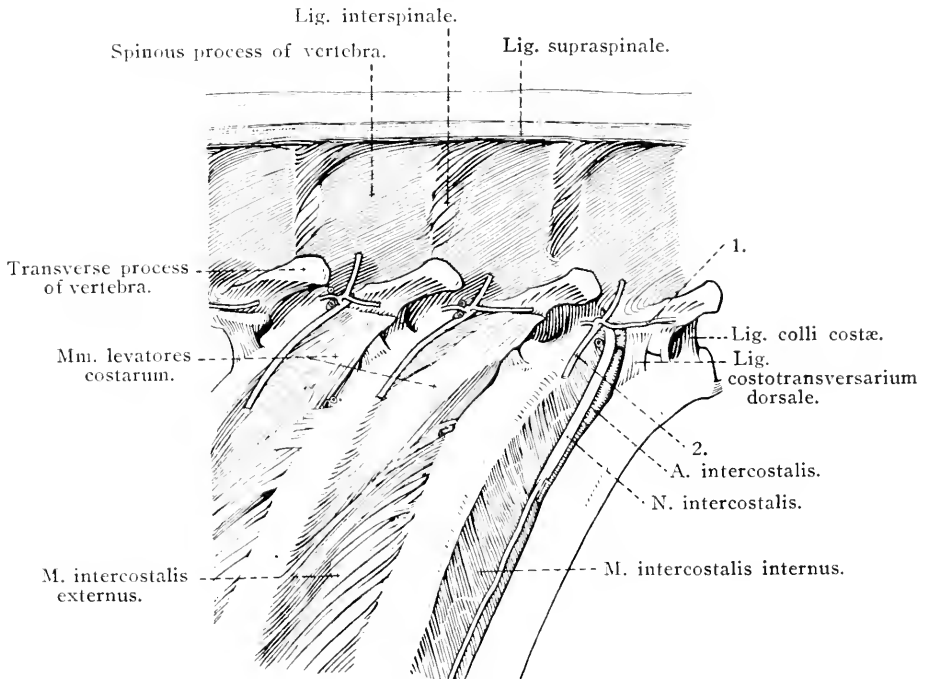


FIG. 27.—Costo-vertebral articulations, with associated structures.

1 = a muscular branch of the dorsal ramus of a thoracic nerve.  
2 = dorsal cutaneous nerve.

the intervertebral fibro-cartilage. The first rib is not provided with an interarticular ligament. A *radiate ligament* (ligamentum capituli costae radiatum) is present on the ventral aspect of the joint. Its fibres pass from the neck of the rib, in a slightly divergent manner, to the bodies of the vertebrae and the interposed fibro-cartilage.

(2) The *costo-transverse articulation* (articulatio costotransversaria), between the tubercle of the rib and the transverse process of the vertebra, has a joint capsule enclosing its joint-cavity. A *dorsal*



*ligament* (ligamentum costotransversarium dorsale) passes from the dorsal surface of the vertebral transverse process to a roughened area on the tubercle of the rib, and is closely applied to the capsule of the joint. The *ligament of the neck of the rib* (ligamentum colli costæ) begins close to the cranial costal fovea of the vertebra and ends on the roughened area on the dorsal aspect of the neck of the rib.

Not infrequently, in the horse, the capitular and costo-transverse

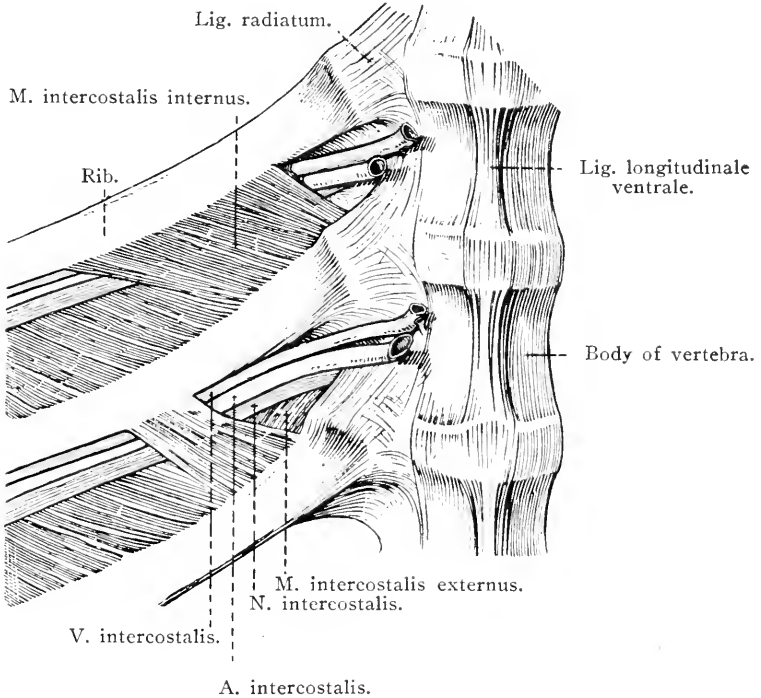


FIG. 28.—The structures in an intercostal space, viewed from within.

articulations are confluent in connection with the last, and sometimes also the second last rib.

Movements of the ribs have for their object an alteration in the transverse diameter of the thorax. During the act of inspiration the rib rotates about an axis that passes through the capitular articulation and the joint between the rib-cartilage and the sternum, or an equivalent point in the case of the asternal ribs. Seeing that, when the thorax is in the condition of expiration, the rib is so placed that its convexity inclines markedly backwards, it follows that if the rib be acted upon by muscles in such a manner as to draw it forwards (that is towards the head), rotation about the axis above-mentioned will cause

the convexity of the rib to move in a lateral direction. This occurring simultaneously on both sides of the body, the transverse diameter of the chest is materially increased.

During movement of the rib as a whole, its tubercle glides on the vertebral transverse process in the arc of a circle, the centre of which is at the capitular attachment of the interarticular ligament.

From the differences in the curve of the various ribs, as well as from certain differences in the form of their articular surfaces, it is evident that the possible range of movement increases from the first backwards. It is also evident that extensive movement of those sternal ribs to which the thoracic limbs are applied is undesirable.

---

ARTERIES OF THE THORAX.

A. coronaria dextra . . . . .	Ramus descendens.		
A. coronaria sinistra . . . . .	{ Ramus circumflexa. Ramus descendens.	A. costocervicalis . . . . .	{ A. intercostalis suprema. A. transversa colli.
Truncus brachiocephalicus communis . . . . .	{ A. subclavia sinistra	A. cervicalis profunda . . . . .	{ A. mediastini cranialis. A. intercostalis prima. Ramus transversus. Ramus ascendens.
		A. vertebralis . . . . .	{ Rami spinuales. Rami musculares.
		Truncus omocervicalis . . . . .	{ A. cervicalis ascendens. A. transversa scapulae.
		A. thoracica interna . . . . .	{ Rami perforantes. Rami intercostales. A. pericardiacophrenica. A. musculophrenica. A. epigastrica cranialis.
		A. thoracica externa . . . . .	
		Truncus costocervicalis . . . . .	{ A. intercostalis suprema. A. transversa colli. A. cervicalis profunda.
		Truncus bicaroticus . . . . .	{ A. carotis communis dextra. A. carotis communis sinistra.
Truncus bronchoesophageus . . . . .	{ A. oesophageus. A. bronchialis.	A. subclavia dextra . . . . .	{ A. vertebralis. Truncus omocervicalis. A. thoracica interna. A. thoracica externa.
Aa. intercostales . . . . .	{ Ramus dorsalis. Ramus ventralis.		
Aa. phrenicae craneales . . . . .			

## THE ABDOMEN.

THE dissection of the abdomen proper should be preceded by an examination of the mammary glands of the female or the external genital organs of the male, according to the sex of the subject being dissected.

THE MAMMARY GLANDS (*Mammæ*).<sup>1</sup>—The mammary glands of the mare are two in number, attached to the abdominal wall immediately in front of the pubes. Each gland forms a rounded eminence, of greater or less prominence dependent upon the activity or quiescence of the organ, with an antero-posterior diameter somewhat in excess of the transverse measurement. In the middle line, a shallow, longitudinal *inter-mammary groove* (*suleus intermammaricus*) marks the extent of each gland. The skin covering the *mammæ* is thin, soft and generally deeply pigmented, with hairs that are few in number and downy in texture, and numerous large sebaceous and sweat glands.

From the most prominent part of each gland a laterally flattened, conical *teat* (*papilla mammæ*) projects. At the summit of the teat there are two—rarely three—orifices that lead into *milk canals* (*ductus lactiferi*).<sup>2</sup> If one of these be slit open it will be found to traverse the length of the teat and end in a dilated *milk sinus* (*sinus lactiferus*) at the base thereof. An examination of the wall of the sinus reveals the openings of ducts from the glandular substance of the organ.

It should be noted that hairs are very few on the teat generally and entirely absent over its apex.

*Dissection.*—The skin must be carefully incised along the inter-mammary groove and raised from the surface of the gland. On reaching the base of the nipple, make a circular incision through the skin, so as to leave the teat intact and in position.

Over the whole of the mammary gland, except the teat, no very great difficulty is experienced in demonstrating the presence of superficial and deep fascia. The superficial fascia is loose and continuous with the like investment of the abdominal wall in general. A greater

<sup>1</sup> *Mamma* [L.], breast.

<sup>2</sup> *Lac* [L.], milk; *ferre* [L.], to carry.

or less amount of fat is contained in it, but it should be noted that no fat occurs beneath the skin of the teat.

The deep fascia is more definite. It forms a yellow elastic envelope for each gland, and serves to connect it with the elastic tunic of the abdominal wall by a *suspensory ligament* (ligamentum suspensorium). Where the two glands meet, the deep fascia forms a septum between them. Further, it is continuous with the septa between the lobes of glandular tissue of which the organ is composed.

An incision into the substance of the mamma reveals a yellowish pink granular tissue of lobulated character; and, if the gland is active, milk exudes freely from the cut surface.

Associated with the mammary glands are numerous veins of considerable size with frequent anastomoses. These communicate with two main veins—cranial and caudal—on each side of the body. The cranial vessel should be sought between the mammary gland and the wall of the abdomen; the caudal vein lies between the gland and the ventral wall of the pelvis. They both join the external pudendal vein which enters the abdomen by the inguinal canal.

Blood is brought to the mammary gland by the external pudendal artery, the main stem of which leaves the inguinal canal by the subcutaneous ring and almost immediately divides into cranial and caudal branches.

Numerous nerves supply the mamma, and are derived from the ilio-hypogastric, ilio-inguinal and genito-femoral (external spermatic) nerves and from the caudal (posterior) mesenteric plexus of the sympathetic.

A small group of lymph glands—the superficial inguinal (lymphoglandulæ inguinales superficiales)—are associated with the external pudendal artery and its cranial branch.

*Dissection.*—Remove the mammary glands and clean away the surrounding fat. Then proceed with the dissection as in the male.

If the subject is a male, the external genital organs must be dissected before the wall of the abdomen itself is examined.

EXTERNAL GENITAL PARTS (Partes genitales externæ).—The male external genital parts consist of the scrotum, the penis and the prepuce.

The *scrotum*<sup>1</sup> is a membranous bag with a double cavity in which the testes are lodged. It lies in the pubic region between the thighs, and presents a slightly constricted neck where it is joined to the body wall. A shallow groove runs in a cranio-caudal direction (seldom exactly in the middle line), and in it there is an indistinct *raphe*<sup>2</sup> *scroti*.

<sup>1</sup> *Scrotum* [L.], a bag.

<sup>2</sup> *ράφή* (*raphe*) [Gr.], a seam.

The skin of the scrotum is thin, soft to the touch, generally darkly pigmented, and shiny from the secretion of its numerous sweat and sebaceous glands. Hairs are fine and soft and comparatively few in number.

*Dissection.*—Make an incision through the skin along the raphe, and expose the underlying dartos tunic. When making the incision, remember that the skin is thin.

The wall of the scrotum can be resolved into three or four layers, of which the most superficial is formed by the skin. The second layer,

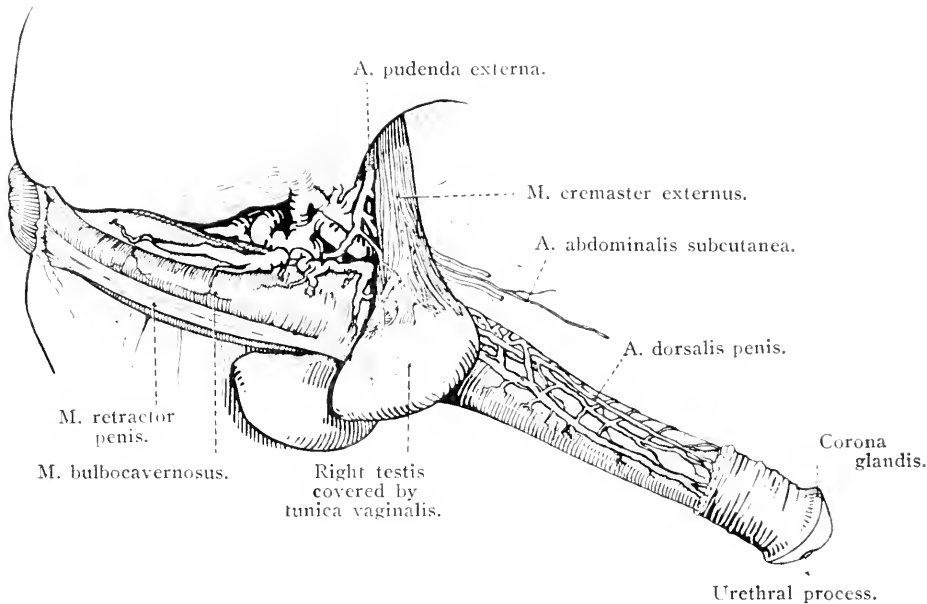


FIG. 29.—The male external genital organs.

known as the *tunica dartos*,<sup>1</sup> is pinkish-yellow in colour and contains a considerable quantity of elastic and muscular tissue. Unlike the skin, which forms a single investment for both testes, the dartos tunic is double, that is, each testis is surrounded by its own dartos. The two tunics, meeting in the middle line of the body, form a median septum between the two scrotal cavities—the *septum scroti*—that splits close to the abdominal wall in order to accommodate the penis.

Removal of the dartos tunic exposes an ill-defined *scrotal fascia*, within which is the fourth scrotal layer, the *tunica vaginalis*, consisting of a fibrous lamina lined with a serous membrane. The fibrous layer of the vaginal tunic is continuous with the fascia covering the deep face of the transverse muscle of the abdominal wall, and is in the form of a blunt-pointed, pear-shaped sac, the narrow end of which is con-

<sup>1</sup> δαρτός (dartos) [Gr.], flayed, skippy.

nected with the superficial opening of the inguinal canal. Along the lateral wall of the sac there is a flattened band of red muscular tissue, the *external cremaster*<sup>1</sup> muscle (m. cremaster externus), which a later dissection will show to be associated with the internal oblique muscle of the abdominal wall. Where the cremaster appears at the subcutaneous ring of the inguinal canal, it is narrow. From this point its fibres diverge somewhat and end in an aponeurosis blended with the fibrous sac upon which it lies.

The innermost and thinnest stratum of the scrotal wall is formed by the serous layer of the vaginal tunic, which is continuous through the inguinal canal with the peritoneal lining of the abdomen, and, like other serous membranes, is divisible into a parietal and a visceral part. The potential space between the two parts is known as the *vaginal cavity* (cavum vaginale), and has a comparatively narrow connection with the peritoneal cavity through the *vaginal ring* (annulus vaginalis). The parietal part of the serous layer of the tunica vaginalis lines and is closely adherent to the fibrous layer, and forms a smooth and glistening lining to the scrotal sac. The visceral portion, which will be examined shortly, forms a smooth, moist and shining covering to the testis and certain associated structures.

*Dissection.*—Cut through the parietal tunica vaginalis with a pair of scissors and examine the contents of the scrotum.

TESTIS AND EPIDIDYMIS.—Each testis, weighing from 230 to 300 grammes, is an ovoid organ, slightly flattened medially, lodged within its own compartment of the scrotum. The long axis of the gonad is approximately horizontal; consequently its extremities are cranial and caudal. The two surfaces, medial and lateral, are smooth and convex, as is also the ventral or free border (margo liber). The dorsal border (margo epididymidis), comparatively straight, is associated with the epididymis, and affords attachment to the spermatic cord.

The epididymis<sup>2</sup> consists of an elongated mass formed by the tortuous windings of a long tube—the *duct of the epididymis* (ductus epididymidis)—held together by dense connective tissue, and covered by visceral tunica vaginalis. The connective tissue covering of the surface is intruded into the interior of the epididymis in the form of strong septa that divide the organ into lobules (lobuli epididymidis).

The central part or *body* of the epididymis (corpus epididymidis) lies along the dorsal border of the testis to which it is attached by the vaginal tunic. The cranial and caudal extremities, known respectively as the *head* (caput epididymidis) and *tail* (cauda epididymidis), overlap

<sup>1</sup> *Cremaster* [L.]; *κρεμαστήρ* (cremaster) [Gr.], a suspender.

<sup>2</sup> *ἐπί* (epi) [Gr.], upon; *δίδυμος* (didymos) [Gr.], double, twain, testis.

the ends of the testis. It should be noted that both the head and the tail are much thicker than the body, and that the head is closely applied, and adherent to, the testis. From the tail the *ductus deferens* takes origin, to pass upwards into the inguinal canal as one of the constituents of the spermatic cord. The cauda epididymidis is not adherent to the testis, but is joined to the wall of the scrotum by a short, stout ligament (ligamentum epididymidis), covered by a reflection of the vaginal tunic.

THE SPERMATIC<sup>1</sup> CORD (Funiculus spermaticus).—The term spermatic “cord” is somewhat misleading. It is applied to a triangular reflection of the vaginal tunic and certain structures (ductus deferens, bundles of

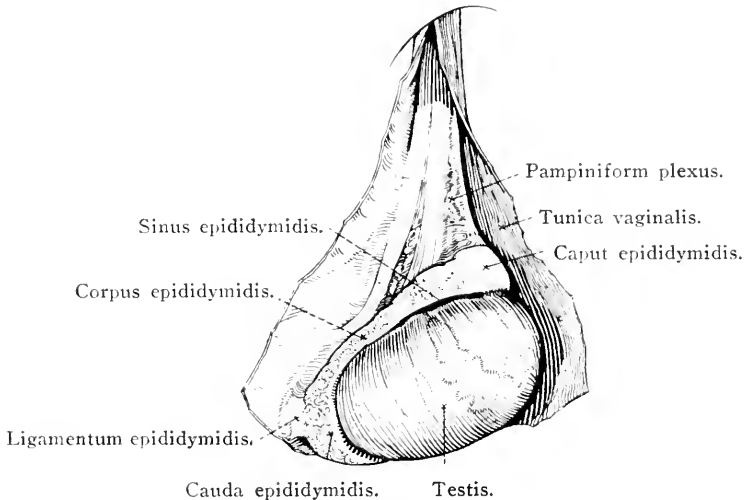


FIG. 30.—Lateral aspect of the right testis and epididymis.

unstripped muscular fibres—*m. cremaster internus*—blood-vessels, nerves and lymphatics) contained therein. The apex of the triangle disappears into the inguinal canal: the base is connected with the testis and the epididymis.

The cranial free edge of the cord is formed by a prominent mass composed of a richly coiled vein (pampiniform<sup>2</sup> plexus), and, buried within the venous mass, the internal spermatic artery by which the testis is supplied with blood.

The deferent<sup>3</sup> duct is enclosed in a special fold (*plica ductus deferentis*), springing from the medial face of that part of the serous vaginal tunic which encloses the other constituents of the spermatic cord.

<sup>1</sup> *Spermaticus* [L.]; *σπερματικός* (*spermaticos*) [Gr.], pertaining to the semen.

<sup>2</sup> *Pampinus* [L.], a tendrill or young shoot of the vine; *forma* [L.], form.

<sup>3</sup> *Deferens* [L.], carrying away.



The disposition of the visceral portion of the tunica vaginalis should now receive attention. Applied to the surface of the testis and epididymis, it gives these organs their smooth appearance and lines a cavity, the *sinus epididymidis*, between them. Note that the entrance to this cavity is lateral in position. Leaving the dorsal border of the epididymis, the vaginal tunic forms an investment for the spermatic cord.

The continuity of the visceral and parietal parts of the tunica vaginalis is along the caudal border of the scrotum and over the ligament of the epididymis.

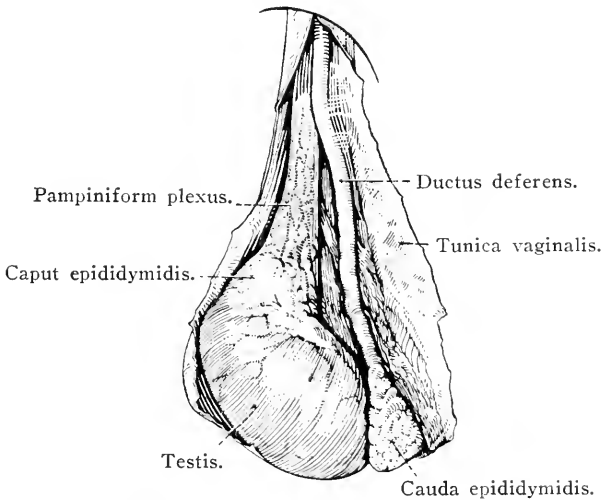


FIG. 31.—Medial aspect of the right testis and epididymis.

**DESCENT OF THE TESTIS (Descensus testis).**—The characteristic disposition of the spermatic cord, and the fact that the blood-supply of the testis is derived from a considerable distance, will be understood if it is remembered that the testis does not develop in the scrotum, nor does it arrive in that sac until the end of intra-uterine life. The testis develops in the sublumbar region ventral to the position assumed by the permanent kidney. Here, in the embryo, it is held in position by a short mesenterial fold of peritoneum, the *mesorchium*,<sup>1</sup> containing blood vessels and nerves.

The scrotum is formed by a diverticulum of the abdominal wall, into which, about the middle of intra-uterine life, a blind pouch of peritoneum—the *processus vaginalis*—is protruded. Into this diverticulum the testis with its mesorchium descends. How far the descent of the testis is governed by a muscular and fibrous cord, the *gubernaculum*<sup>2</sup>

<sup>1</sup> μέσος (mesos) [Gr.], middle; ὄρχις (orchis) [Gr.], the testis.

<sup>2</sup> *Gubernaculum* [L.], a governor or guide; *gubernare* [L.], to govern, steer, or pilot.

*testis*, is a matter of controversy. Seeing, however, that the gubernaculum is attached by one end to the caudal extremity of the testis, and is fixed in the inguinal region by the other, it is reasonable to suppose that in some measure, at least, the testis is guided in its descent by the gubernaculum.

The tail of the epididymis is the first object to enter the processus vaginalis. Thereafter follow the testis and its mesorchium.

The descent of the testis is frequently complete at the time of birth; but the inguinal ring (the neck of the processus vaginalis) being

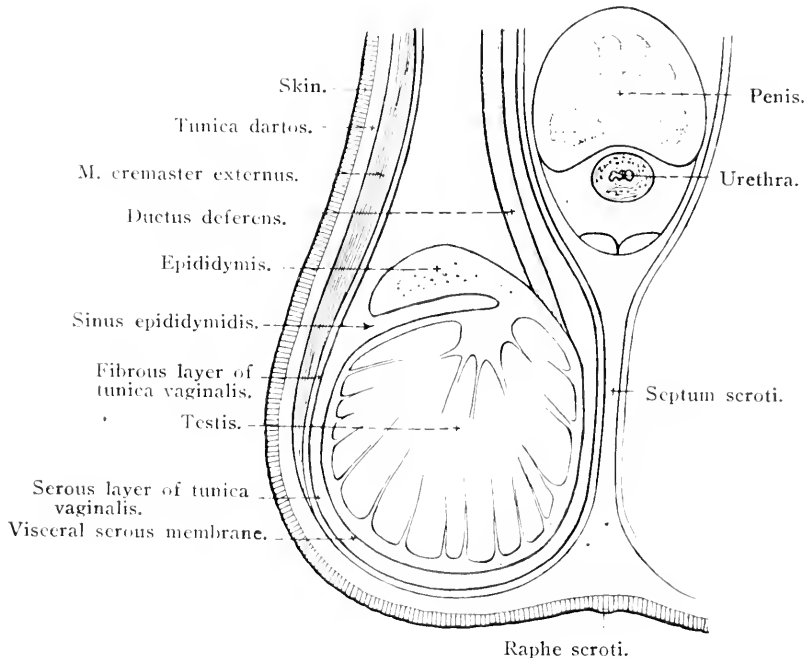


FIG. 32.—Vertical section through the penis, scrotum and testis. Diagrammatic.

wide at this time, the testis may be withdrawn into the inguinal canal or into the abdomen, and not find a permanent residence in the scrotum until several months after birth. In some instances the testis is permanently retained in the abdomen or (more rarely) in the inguinal canal. This condition of malposition is known as *cryptorchism*.

*Dissection.*—A longitudinal incision should be made through one of the testis, entering the knife at the free ventral border, and carrying the incision through the organ to the dorsal border. The other testis may be sectioned transversely.

Immediately underneath the serous covering of the testis there is a whitish, resisting *tunica albuginea*,<sup>1</sup> about 2 mm. in thickness. In

<sup>1</sup> *Albus* [L.], white.

some mammals septules of fibrous tissue run into the testis from this tunic and converge towards the *mediastinum*<sup>1</sup> *testis*, an elongated mass of fibrous tissue placed near the dorsal border. The presence of septules causes the division of the testicular parenchyma into lobules, each lobule presenting a granular appearance on section due to the circumstance that it is composed of richly convoluted seminiferous tubules. A relatively thin but loose and highly vascular tissue, sometimes called the *tunica vasculosa testis*, lies within the tunica albuginea and extends over the septules, and serves to distribute blood vessels to the lobules.

In the horse, neither septules nor mediastinum are very distinct.

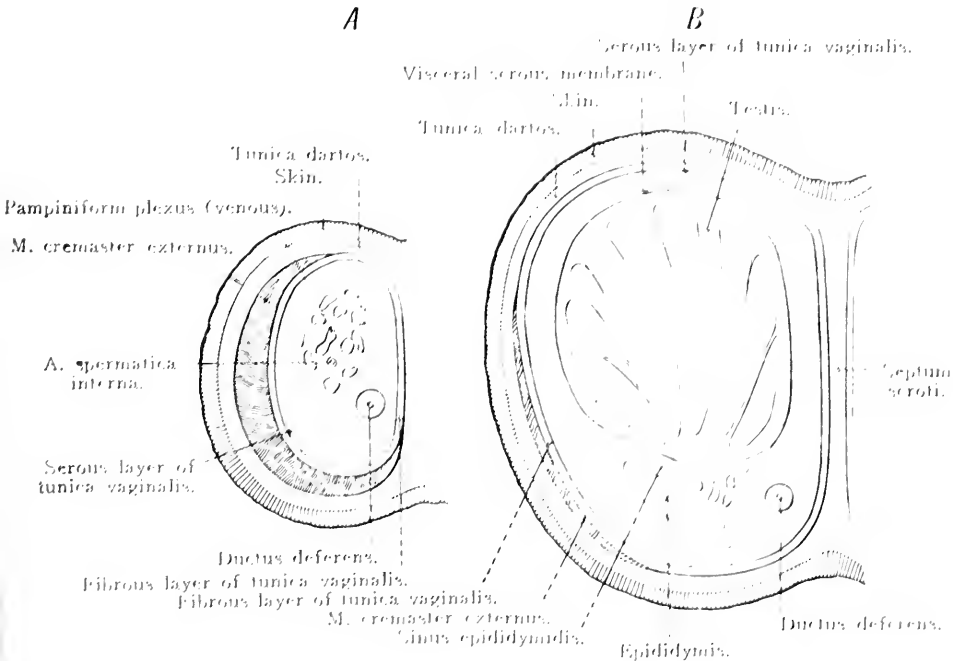


FIG. 33. Horizontal sections through the scrotum (semi diagrammatic).  
*A* above the testis. *B* on a level with the testis.

**THE PREPUCE (Prepuceum).** The prepuce<sup>2</sup> is a tubular sheath of integument enclosing the free portion of the penis, and in the retracted state of this organ, circumscribing a cavity that communicates with the exterior by a large *preputial orifice* (*ostium preputiale*), situated close behind the umbilicus.

The prepuce consists of two layers: a parietal and a visceral. The parietal layer presents a superficial sheet composed of skin continuous

<sup>1</sup> *Mediastinum* [L.], a median partition or septum; *mediastinus* [L.], being in the middle, a common servant.

<sup>2</sup> *Preputium* [L.], the foreskin; the root is *pu*, to generate, to produce.

with and similar to that over the scrotum. The deep sheet of the parietal layer is thinner and devoid of hairs. The visceral layer of the prepuce is closely adherent to the surface of the penis in the region of the glans, and becomes continuous with the mucous lining of the urethra at the external urethral orifice. Behind the glans the visceral layer is looser and generally folded in such a way as to form an inner sheath for the penis ending at a thickened *preputial ring* (annulus preputialis). The degree of development of the inner sheath varies considerably in different individuals.

To obtain a satisfactory view of the visceral layer of the prepuce, no attempt should be made to withdraw the penis; but a longitudinal incision should be made through the parietal layer, beginning at the preputial orifice and carrying the cut towards the scrotum.

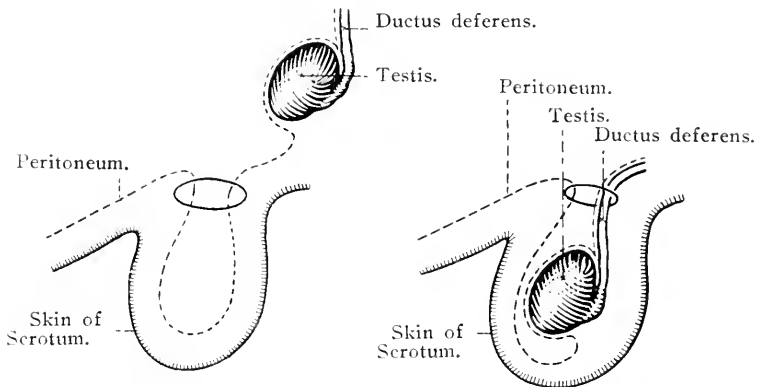


FIG. 34.—Diagram to illustrate the descent of the testis.

*Dissection.*—Before any further examination of the genital organs is attempted, the external pudendal vessels must be followed from the subcutaneous ring of the inguinal canal. Associated with them is a scattered group of *superficial lymph glands* (lymphoglandulæ inguinales superficiales). The dissection is generally rendered tedious by the presence of an accumulation of fat in the inguinal region.

A. PUDENDA EXTERNA.—The external pudendal<sup>1</sup> artery descends the inguinal canal and appears in the present dissection at the medial angle of the subcutaneous ring thereof, in company with the external cremaster muscle. After a short course in a ventral and lateral direction, the artery divides into cranial and caudal branches. The cranial branch, sometimes called the *subcutaneous abdominal artery* (a. abdominalis subcutanea), runs forwards along the abdominal wall for a considerable distance, its terminal twigs being traceable as far as the umbilicus. Many branches are distributed to the prepuce and the superficial inguinal lymph glands, and one vessel follows the dorsum of

<sup>1</sup> *Pudere* [L.], to be ashamed; *pulendus* [L.], of which one ought to be ashamed.

the penis towards the glans as the *dorsal artery of the penis* (a. dorsalis penis), deep rami (rami profundi penis) of which pierce the albugineous tunic of the penis. The caudal branch of the external pudental artery supplies the scrotum and penis and very often anastomoses with a branch of the obturator artery.

V. PUDENDA EXTERNA.—The region of the prepuce and penis contains a large number of veins between which are frequent anastomoses. These, by their union, produce the cranial and caudal radicles of the external pudental vein, which is a companion of the artery of the same name. Not infrequently the saphenous vein of the thigh joins the external pudental.

The nerves of the prepuce are derived from the ilio-hypogastric, ilio-inguinal and genito-femoral (external spermatic).

*Dissection.*—Remove the prepuce entirely and clean the surface of the penis, being careful, however, to leave the dorsal vessels and nerves in position. To obtain a complete view of the penis, it is necessary to dissect its connection with the sciatic arch. Here care must be exercised not to injure the termination of the internal pudental vessels.

THE PENIS.—The penis consists of a middle part or *body* (corpus penis), a *root* (radix penis), attached to the sciatic arch, and a free extremity or *glans*<sup>1</sup> (glans penis) that lies in the region of the umbilicus enclosed within the prepuce. Close to the root, two pale, strong bands, the *suspensory ligaments* (ligamenta suspensoria), connect the outer coat of the penis to the symphysis of the two ischial bones and the origin of the gracilis muscles.

Except near its extremities, the penis is compressed laterally and therefore possesses right and left surfaces and two rounded borders. The term *dorsum penis* is applied to that border of the organ that is in contact with the abdominal wall and the corresponding part of the pelvis; whereas the opposite border is called the *urethral surface* (facies urethralis) from the circumstance that the urethra here occupies a groove formed by the cavernous body of the penis.

The body of the penis lies in the middle line, dorsal to the testes, and is crossed laterally by the deferent ducts and the other components of the spermatic cord. It is composed of three erectile cavernous bodies running parallel to each other.

The *corpus cavernosum penis* is generally described as consisting of two rods of erectile tissue bound together by a dense, thick, fibrous envelope, the *tunica albuginea* [*corporum cavernosum*], and separated from each other by a fibrous septum (septum penis). In the ischial

<sup>1</sup> *Glans* [L.], an acorn. In a borrowed sense, an acorn-shaped ball of lead or clay that was slung at an enemy, a bullet.

region the recognition of two bodies is not difficult, for here they diverge to form the two *crura penis*<sup>1</sup> that are attached to the sciatic arch. Elsewhere, however, they are so closely blended, and the septum penis is so imperfect, that a common cavernous body is produced. It is along the urethral surface of this body that a groove is provided for the reception of the urethra and its envelope of erectile tissue. At the base of the glans the corpus cavernosum penis terminates in three processes, of which the two lateral are short and blunt, while the third, nearer the dorsum of the penis, is longer and more pointed.

The third erectile body is the *corpus cavernosum urethræ*, associated, as its name indicates, with the urethra for which it forms a complete investment. This, it will be observed later, is not

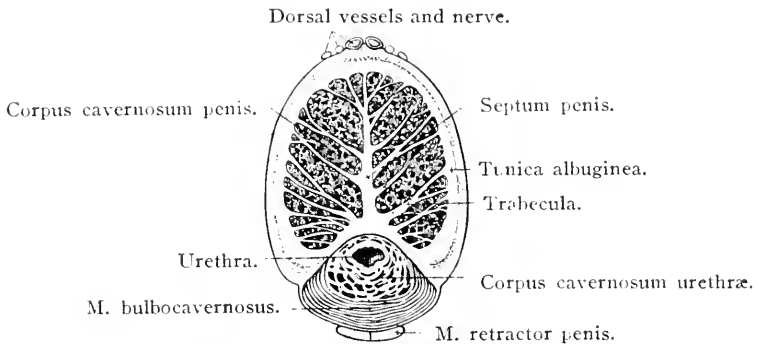


FIG. 35.—Transverse section of the penis.

limited to that part of the urethra that is situated in the penis, but also surrounds the pelvic part of this tube. In the middle line, between the two crura of the penis, the corpus cavernosum urethræ forms a slight swelling that is to be regarded as the representative of a *urethral bulb* (*bulbus urethræ*) such as is present in the dog.

The glans penis of the horse forms a characteristic rounded expansion at the free end of the organ, most prominent in that part which is in line with the dorsum penis. The projecting free edge of the glans (*corona glandis*) is succeeded by a *collum glandis*, by which the glans is superficially marked off from the rest of the penis. Dissection, however, shows that a process of the glans tissue (*processus dorsalis glandis*) is continued along the dorsum of the penis for some eight to ten centimetres behind the collum glandis. The dorsal veins of the penis take their origin in this process. The glans contains a fossa (*fossa glandis*) of some depth, into which the free terminal part of the urethra projects as a tubular *urethral process* (*processus urethralis*) that brings the *external urethral orifice* (*orificium urethræ externum*)

<sup>1</sup> *Crura* [L.], pl. of *crus*, a leg or limb.

flush with, or even slightly beyond, the surface of the glans. The fossa is deepest above the urethral process.

The surface of the glans, the interior of the fossa glandis, and the outer surface of the urethral process are covered by thin, hairless skin, continuous with the innermost layer of the prepuce and merging into the urethral mucous membrane at the external urethral orifice.

A short, rounded and well-developed *ischio-cavernous muscle* (m. ischiocavernosus) covers each crus of the penis, taking origin from the most lateral part of the sciatic arch and the adjacent portion of the sacro-tuberous ligament, and ending on the tunica albuginea of the corpus cavernosum penis. Each ischio-cavernous muscle and the crus penis that it covers are accommodated in a deep depression in the origin of the semimembranosus muscle.

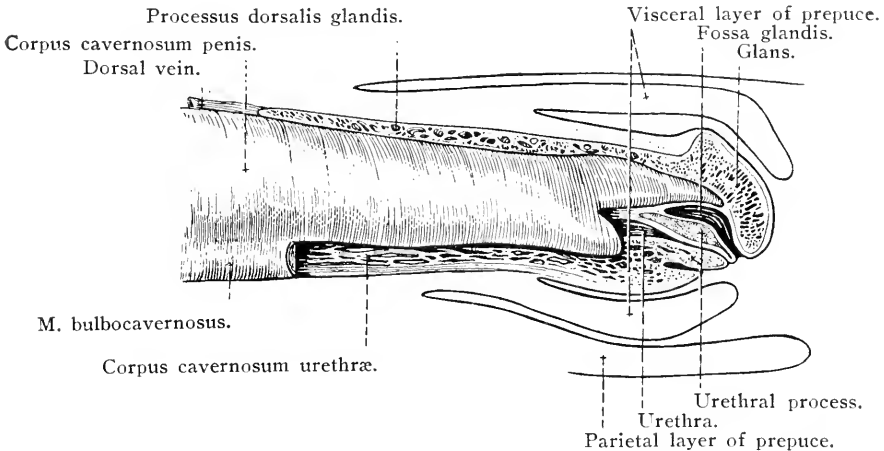


FIG. 36.—Extremity of the penis. A sagittal section of the glans has been made, and the terminal portion of the corpus cavernosum penis exposed.

The penile portion of the urethra is covered by the *bulbo-cavernous muscle* (m. bulbocavernosus), a continuation of the urethral muscle of the pelvis. It may be considered that this muscle begins at the bulbo-urethral glands (to be examined with the pelvic contents) and extends all along the penis to the glans. For the most part, the muscle consists of transverse fibres connected with the tunica albuginea along the margins of the groove in which the urethra is lodged, and consequently covers three surfaces of the corpus cavernosum urethrae; but in the region of the root of the penis, where the muscle is thicker than elsewhere, it forms a complete investment of circular fibres surrounding the urethral corpus cavernosum.

Two parallel pale muscular bands appear to begin in the region of the anus, though their fibres may be traced to the first and second

coccygeal vertebrae. These soon become so closely applied to each other as to form apparently a single muscle, *m. retractor penis*, that can be traced along the urethral border of the penis to within a short distance of the glans, where it disappears under the bulbo-cavernous muscle.

A. OBTURATORIA.—Blood is supplied to the penis by three arteries on each side of the body. (1) The external pudendal artery has already been examined (page 76). (2) The internal pudendal artery will be examined along with the contents of the pelvis. (3) The obturator artery appears in the present dissection between the gracilis and semi-membranosus muscles and furnishes numerous branches to the penis in the neighbourhood of the root. One of these anastomoses with the internal pudendal artery, and not infrequently a similar union is effected with the caudal branch of the external pudendal artery.

The obturator vein (v. obturatoria) accompanies the artery.

NX. DORSALES PENIS.—The dorsal nerves of the penis are derived from the right and left pudendal nerves, and reach the penis by bending round the sciatic arch. Each dorsal nerve will be found following the margin of the dorsum of the penis in company with and lateral to a dorsal artery.

*Dissection.*—In order that the internal structure of the penis may be studied, sections should be made across the organ at different levels. Thus an adequate understanding of the arrangement of the cavernous bodies and the urethra may be arrived at.

The thick albugineous coat of the corpus cavernosum penis is very obvious, and there will be no difficulty in recognising branching and anastomosing fibrous trabeculae, connected with the tunica albuginea and supporting the erectile tissue of which the body is composed. The erectile tissue itself consists of thin strands between which are cavernous spaces (cavernae) that must be regarded as taking the place of capillary vessels between the arteries and the veins.

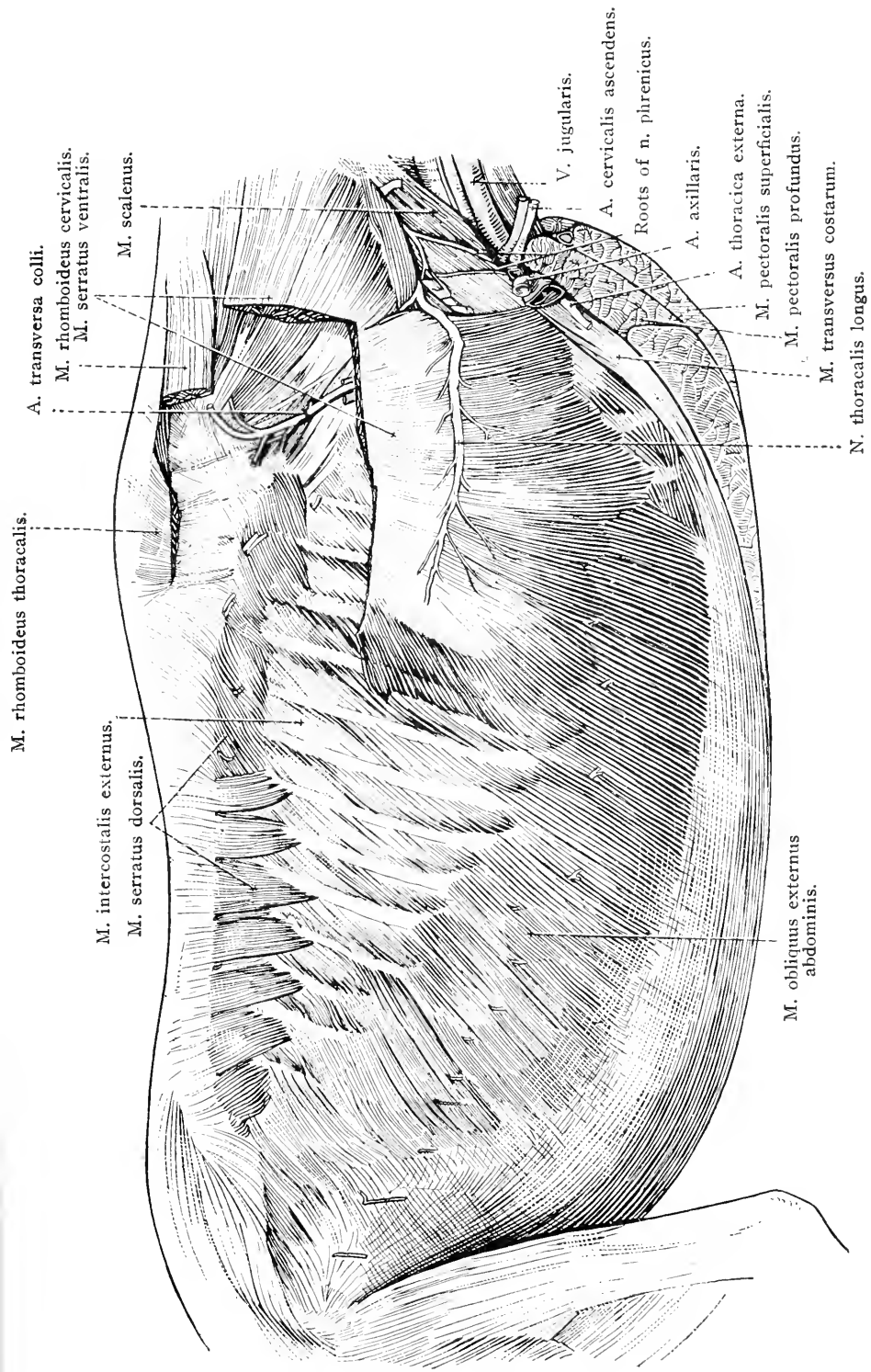
The corpus cavernosum urethrae has a similar structure, but its trabeculae are much finer and the cavernae are greatly more spacious. In the glans penis the cavernae are still larger, and, because of the high elasticity of the trabeculae, are very distensible.

The dissector will now turn his attention to the wall of the abdomen.

M. CUTANEUS.—The cutaneous muscle covers a considerable extent of the abdominal wall. Thickest over the lateral aspect of the thorax and abdomen, it gradually thins towards the mid-ventral line and merges into the superficial fascia of the ventral wall of the abdomen. It will be noted that some fibres of the muscle are continued into the conspicuous and sharp fold of skin that connects the distal part of the thigh with the abdominal wall.

V. THORACICA EXTERNA.—The external thoracic vein drains the surface of the lateral and ventral parts of the abdominal wall, some of





A. transversa colli.  
 M. rhomboideus cervicalis.  
 M. serratus ventralis.  
 M. scalenus.

V. jugularis.  
 A. cervicalis ascendens.  
 Roots of n. phrenicus.  
 A. axillaris.

A. thoracica externa.  
 M. pectoralis superficialis.  
 M. pectoralis profundus.  
 M. transversus costarum.  
 N. thoracalis longus.

M. rhomboideus thoracalis.  
 M. intercostalis externus.  
 M. serratus dorsalis.

M. obliquus externus abdominis.

FIG. 37.—Superficial dissection of the wall of the thorax and abdomen.

its radicles beginning in the prepuce or mammary gland, according to the sex of the subject under dissection. At first the vein is superficial to the cutaneous muscle; but, on the side of the chest, it pierces the muscle and enters the axilla by following the dorsal border of the deep pectoral muscle. It ends by joining the axillary vein.

*Dissection.*—Reflect as much of the cutaneous muscle as is necessary to expose the underlying components of the abdominal wall. In performing this operation, a series of small nerves, cutaneous in distribution, will be observed to pierce the muscle. These should be preserved in order that their connection with deeper nerves may be demonstrated as the dissection proceeds. Small vessels are associated with the perforating nerves.

The *fascia of the abdomen* is continuous with that of the trunk in general, and is like that of the rest of the body in being divisible into superficial and deep layers. The superficial fascia is not notably different from the like fascia of other regions of the trunk with which it is continuous; but the deep fascia is remarkable in that it forms a yellow tunic—*tunica flava abdominis*—of considerable thickness over the abdominal muscles.

The elastic fibres of the tunic run in a longitudinal direction, and are most numerous near the pelvis in the neighbourhood of the linea alba. Over the fleshy part of the external abdominal muscle, with which the tunic is nearly coextensive, the fibres gradually become fewer as they are followed over the ribs and underneath the deep pectoral muscle. The dissector has already noted the presence of prolongations of the tunic in association with the prepuce and the mammary glands.

The important mechanical function of a stout elastic membrane incorporated in the abdominal wall will be obvious.

*Dissection.*—In order that the external oblique abdominal muscle may be examined, it is necessary to remove the yellow abdominal tunic completely. This is a tedious operation, and must be conducted with considerable care. The close adhesion of the tunic to the aponeurotic tendon of the external oblique muscle renders the dissection difficult; but the dissector will run little risk of damaging the underlying aponeurosis if he note that the fibres of the tunic are yellow and run in a longitudinal direction, while those of the tendon of the external oblique muscle are white and glistening and arranged obliquely.

M. OBLIQUUS EXTERNUS ABDOMINIS.—The external oblique abdominal muscle is extensive, and covers the whole of the lateral and ventral part of the abdomen as well as a certain amount of the lateral wall of the thorax. A fleshy origin is connected with the outer surface of the last thirteen or fourteen ribs and the intercostal muscles between them. Some fibres of origin are attached to the lumbo-dorsal fascia. The muscular bundles slope obliquely in a caudal and ventral direction and

end in a relatively thin, but extensive, aponeurotic tendon. The line of separation between the muscular and tendinous portions runs obliquely

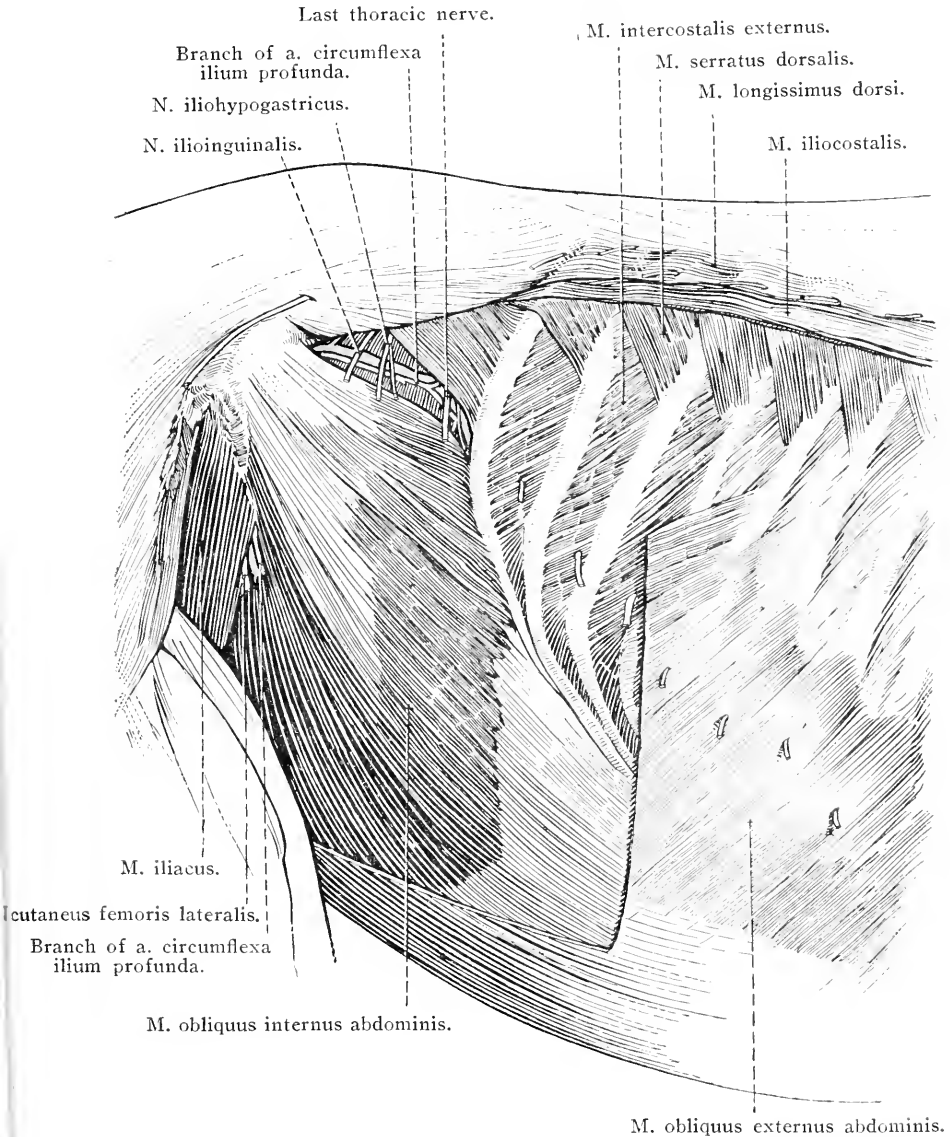


FIG. 38.—Dissection of the right flank after removal of part of the external oblique abdominal muscle.

from the tuber coxæ to the cartilage of the twelfth or thirteenth rib. The line is not straight, but has a flat caudo-ventral convexity.

A comparatively small part of the muscle, namely, that associated with the last rib, has a fleshy insertion to the tuber coxæ. The remaining insertion is tendinous, and of some degree of complexity. The

greater part of the tendon is aponeurotic, and blends with the corresponding tendinous aponeurosis of the internal oblique muscle, thus gaining the linea alba. The fused aponeuroses form the ventral part of the sheath of the straight abdominal muscle.

A considerable band of tendinous fibres stretches from the tuber coxæ to the pecten of the pubis lateral to the symphysis. This band is generally designated the *inguinal ligament of Poupart*,<sup>1</sup> or the lateral crus of the aponeurosis—that part connected with the linea alba being the medial crus. The ligament curves in a dorsal and cranial direction, gradually becoming thinner and finally blending with the iliac fascia. It will also be observed that fibres from the ligament are continued into the fascia on the medial aspect of the thigh.

Laterally the medial and lateral crura of the aponeurosis become indistinguishably blended; but in the vicinity of the pubis they are separated by a slit-like opening, the *subcutaneous inguinal ring* (annulus inguinalis subcutaneus), which is the ventral or outer end of the inguinal canal.

*Dissection.*—Until such time as it is possible to make a complete examination of the inguinal canal, *the dissection of the abdominal wall should be limited to one side of the body.*

Make an incision through the fleshy part of the external oblique muscle close to the line along which it joins the aponeurosis. A transverse incision about midway between the tuber coxæ and the last rib will permit the turning aside of the fleshy part of the muscle, so that the examination of the internal oblique muscle may be proceeded with.

M. OBLIQUUS INTERNUS ABDOMINIS.—The internal oblique abdominal muscle is entirely covered by the preceding, and consists of fleshy fibres arranged in a fan-like manner radiating from the region of the tuber coxæ. Its origin is fleshy, and form the coxal tuber and the adjacent part of the inguinal ligament of Poupart. The most dorsal fibres pursue a slightly oblique course to end, by flattened tendons, on the inner surface of the cartilages of the last four or five ribs. The fibres of the rest of the muscle follow a course of varying obliquity and about the lateral margin of the straight abdominal muscle, become continuous with a broad aponeurotic tendon by which insertion to the linea alba is gained.

The aponeuroses of the two oblique muscles are blended to form the ventral part of the sheath of the straight muscle; but, it will be noticed, the blending is least extensive near the pubis and gradually increases as the xiphoid region is approached.

What doubtless ought to be regarded as a partially or completely isolated part of the internal oblique is frequently described as an

<sup>1</sup> François Poupart, a French anatomist, 1661-1709.

independent muscle under the name of *m. retractor costæ*. It consists of a thin triangular sheet of fibres, arising by aponeurosis from the transverse processes of the first three or four lumbar vertebræ, and inserted to the caudal border of the last rib.

*Dissection.*—Make a longitudinal incision through the internal oblique just lateral to the margin of the straight muscle. A second incision, transverse in direction, should next be made through the fleshy part of the muscle about midway between the coxal tuber and the last rib. In making the second incision the dissector must avoid cutting certain blood vessels and nerves that are to be examined in association with the transverse abdominal muscle. The structures to be preserved are branches of the deep circumflex iliac, lumbar and intercostal arteries and veins, and branches of the ilio-hypogastric, ilio-inguinal, lateral cutaneous and intercostal nerves.

Now reflect the combined aponeurotic tendons of the two oblique muscles where they form an investment for the straight abdominal muscle, turning the combined sheet towards the middle line until the linea alba is reached. This reflection will be facilitated by a transverse incision about midway between the pubis and the xiphoid process of the sternum.

In raising the aponeurotic sheet from the surface of the straight muscle it will be found that some resistance is offered along transverse lines (tendinous inscriptions) that cross the straight muscle. The sheath and the tendinous inscriptions are closely adherent to each other.

**M. RECTUS ABDOMINIS.**—The straight abdominal muscle forms a broad band running along the ventral aspect of the abdominal wall, and separated from its fellow muscle by the linea alba. The muscle is broadest as it lies over the cartilages of the ribs from the ninth to the thirteenth. From this level it gradually narrows towards the pubic region.

The origin of the muscle is from the cartilages of the ribs from the fourth to the ninth, and from the outer surface of the sternum. Its insertion is by a dense and very stout tendon to the pubic tubercle and the immediately adjoining part of the pecten of the pubis. The dissector should notice that the so-called accessory ligament of the hip-joint is continued from the tendon of insertion.

Crossing the straight muscle transversely are some ten or a dozen irregular *tendinous inscriptions* (inscriptiones tendineæ) that doubtless contribute to its strength.

*Dissection.*—Cut across the straight abdominal muscle about the middle of its length and raise the two portions from the dorsal layer of the sheath that contains them. The vessels and nerves of the abdominal wall are then exposed to examination.

**A. EPIGASTRICA CAUDALIS.**—The caudal epigastric artery is a branch of the pudendo-epigastric trunk, and crosses the medial aspect of the inguinal canal in order to reach the deep face of the rectus abdominis

muscle. Most commonly the artery buries itself in the substance of the muscle, about the middle of the length of which it anastomoses with the cranial epigastric artery. It is accompanied by the *caudal epigastric vein* (v. epigastrica caudalis).

A. ET V. EPIGASTRICA CRANIALIS.—The cranial epigastric vessels appear between the xiphoid process of the sternum and the ninth costal cartilage. They follow the deep face of the rectus abdominis muscle and anastomose with the caudal epigastric vessels.

NERVES OF THE ABDOMINAL WALL.—Within the substance of the wall of abdomen are branches of the last ten intercostal, and the last thoracic, ilio-hypogastric, ilio-inguinal and lateral cutaneous femoral nerves.

The last ten *intercostal nerves* are derived from the ventral divisions of the ninth to seventeenth thoracic nerves. They appear from beneath the costal arch, cross the surface of the transverse muscle, and disappear under the edge of the rectus muscle, in which they terminate. Lateral cutaneous branches pierce the two oblique muscles to end in the cutaneous muscle and the skin.

The *last thoracic nerve* is represented in the abdominal wall by two branches. The superficial branch (equivalent to the lateral cutaneous ramus of an intercostal nerve) runs over the surface of the transverse abdominal muscle, pierces the external oblique muscle and ends in the skin of the flank. The deep branch traverses the deep face of the transverse muscle and terminates in the rectus abdominis.

The *ilio-hypogastric* and *ilio-inguinal nerves* arise from the first and second lumbar nerves respectively, of which they constitute the ventral branches. Each divides into a superficial and a deep branch. The ramus superficialis (in series with the lateral cutaneous branches of the intercostal nerves) in each case pierces the oblique muscles to reach the cutaneous muscle and skin of the flank and the lateral anterior part of the thigh. The ramus profundus lies between the transverse abdominal muscle and the peritoneum, and consequently cannot be examined until later.

The *lateral cutaneous nerve of the thigh* arises by roots derived from the third and fourth (often also from the fifth) lumbar nerves. In the present dissection it pierces the abdominal muscles close to the coxal tuber (in company with the caudal branch of the deep circumflex iliac artery) to be distributed in the skin of the lateral aspect of the thigh and the region of the femoro-tibial articulation.

A. CIRCUMFLEXA ILIUM PROFUNDA.—The deep circumflex iliac arises either from the aorta or the external iliac artery. After a course

as yet hidden from view, the artery divides into two branches—cranial and caudal. The cranial branch lies between the transverse and internal oblique muscles and divides into two rami. One of these pursues a horizontal course towards the last rib; the other slopes obliquely in a cranial and ventral direction. The caudal branch pierces the abdominal wall close to the tuber coxæ, follows the medial surface of the tensor muscle of the fascia lata towards the fold of skin that connects the wall of the abdomen to the distal part of the thigh. A group of lymph glands (lymphoglandulæ subiliacæ) is associated with this branch.

M. TRANSVERSUS ABDOMINIS.—The transverse is the weakest member of the group of muscles entering into the formation of the abdominal wall. Part of its muscular fibres (pars costalis) arise from the cartilages of the last twelve or thirteen ribs, where they form serrations interdigitating with similar serrations of the diaphragm. The rest of the origin (pars lumbalis) is from the ends of the transverse processes of the lumbar vertebræ. The fibres of the muscle follow a course at right angles to the long axis of the body, and soon give place to a relatively thin aponeurosis. This passes underneath the straight muscle, of which it forms the dorsal sheath, and blends with the *linea alba*.

The deep surface of the transversus abdominis muscle is covered by a thin layer of fascia—*fascia transversalis*—in which, in well-nourished subjects, there may be considerable deposit of fat. The fascia transversalis is continuous with the iliac fascia, and is prolonged down the inguinal canal to form the fascial tunic lined by serous membrane that constitutes the innermost layer of the scrotum.

THE SHEATH OF THE RECTUS ABDOMINIS MUSCLE (Vagina m. recti abdominis).—The sheath in which the straight muscle is enclosed has now been completely revealed. Its superficial or ventral layer is the stronger, and is formed by the interlacing fibres of the aponeurotic tendons of the two oblique muscles. The deep or dorsal layer of the sheath, formed by the transverse muscle aponeurosis, is thinner, and particularly so close to the pubis. Where the straight muscle lies over the costal cartilages no sheath is interposed.

Where the sheaths of the two straight muscles meet in the middle line a strong cord is formed. This is the *linea alba*, which stretches from the xiphoid process of the sternum to the symphysis pubis, where it blends with the strong conjoined tendons of the two recti muscles. Composed mainly of the interlacing fibres of the oblique and transverse tendons, but also containing a few longitudinal fibres, it is strongest

close to the pubis. Just cranial to the prepuce of the male, or the mammary glands of the female, there is an inconspicuous scar, the *umbilicus*, marking the point of attachment of the umbilical cord of embryonic life.

*Dissection.*—If the dissection has been performed in accordance with the instructions given on the preceding pages, the whole thickness of the abdominal wall will still be undisturbed on one side of the body; while, on the other side, the lining membrane (the peritoneum) and its supporting fascia will alone need incision in order that the abdominal cavity may be opened.

Now open the abdomen in the following manner:—Make an incision along the *linea alba* from end to end. Then make a transverse incision through the peritoneum on the one side, and through the intact wall on the other, about midway between the level of the last rib and the pecten of the pubis.

On that side of the body on which the abdominal wall has not been dissected, the form, course and general anatomy of the inguinal canal should be studied. Begin by making a thorough examination of the intact canal, afterwards performing such dissection as is necessary to display its various boundaries, relations and contents.

**THE INGUINAL CANAL** (*Canalis inguinalis*).—The inguinal<sup>1</sup> canal, some 10-12 cm. in length, is a curved, oblique passage, or flattened tube, lined by peritoneum, that traverses the abdominal wall and contains the spermatic cord, with the external cremaster muscle, in the male. In the mare it is rarely the case that a tubular diverticulum of the peritoneum enters the canal.

The course of the canal is ventral, medial and slightly cranial, with a flat curve the concavity of which looks in a cranial direction. Its caudo-lateral wall is formed by the inguinal ligament of Poupart; while the opposite (cranio-medial) wall mainly consists of the fleshy part of the internal oblique abdominal muscle. The external opening of the canal (*annulus inguinalis subcutaneus*) is essentially a slit, 10-13 cm. long, in the aponeurosis of the external oblique muscle, running obliquely in a lateral and cranial direction in conformity with the course of the aponeurotic fibres. The medial end of the slit is sharply defined by the strong pubic attachment of the tendons of the two recti muscles. The lateral extremity is less definite. For surgical reasons it should be remembered that, though the lips of the opening are at no great distance apart when the limb occupies the position of rest, it is possible to widen the opening to some extent by drawing the limb into a position of extension of the hip joint.

The inner or deep opening of the canal (*annulus inguinalis abdominalis*) is an oval space in the transverse fascia of the abdominal wall

<sup>1</sup> *Inguinalis* [L.], pertaining to the groin; *inguen* [L.], the groin, the organs of generation.



at the caudal border of the internal oblique muscle and between this and the inguinal ligament. The transverse fascia and the peritoneum enter the canal by its inner opening, traverse the canal, and become the vaginal tunic of the scrotum.

In addition to the spermatic cord and the external cremaster muscle in the male, the canal also contains the external spermatic and ilio-inguinal (*ramus profundus*) nerves and the external spermatic artery. In intimate relation to its medial aspect are the external pudendal and caudal epigastric vessels.

THE CAVITY OF THE ABDOMEN (*Cavum abdominis*).—The cavity of the abdomen is separated from that of the thorax by a relatively thin muscular and tendinous partition formed by the diaphragm; and in order that the topography of the abdominal organs may be properly appreciated, it is necessary to remember that the partition is convex in every direction when viewed from the thoracic side, and that the most cranial part of the convexity occurs about the median plane of the body on a level with the sixth rib and about a horizontal plane slightly below the level of the shoulder joint. From this, the vertex of the convexity, the diaphragm curves laterally towards the costal arch and dorsally towards the sixteenth thoracic vertebra. It therefore follows that a considerable proportion of the abdominal viscera lies under cover of the ribs from the seventh to the last.

The greatest vertical (dorso-ventral) diameter of the abdominal cavity occurs on a level with the first lumbar vertebra. Opposite the first lumbar vertebra, also, the transverse diameter of the cavity is greatest.

The bony boundaries of the abdominal cavity are incomplete. Its dorsal wall is formed by the lumbar and sacral vertebræ, with their transverse processes, covered by a thick layer of muscles. Ribs and their cartilages form a girdle round the cranial part of the cavity, while the hip bones fulfil the same purpose at the caudal end. Otherwise the lateral and ventral walls are formed by soft structures only. The ventral wall, much longer than the dorsal, presents a marked downward slope from the pubes to the xiphoid process of the sternum, between which points it is formed by the two straight muscles, the aponeuroses of the external and internal oblique and the transverse muscles, and that yellow elastic tunic which constitutes a specialisation of the deep fascia of the abdominal wall. The oblique and transverse muscles, covered by the rapidly thinning extension of the elastic tunic, compose that part of the lateral wall unprovided with a bony skeleton.

The muscles of the abdominal wall are lined by fascia that varies in thickness and strength in different regions, and is named in accord-

ance with its position—diaphragmatic, iliac, transversalis, &c. Between the fascia and the peritoneum is a *subserous tela* (tela subserosa)

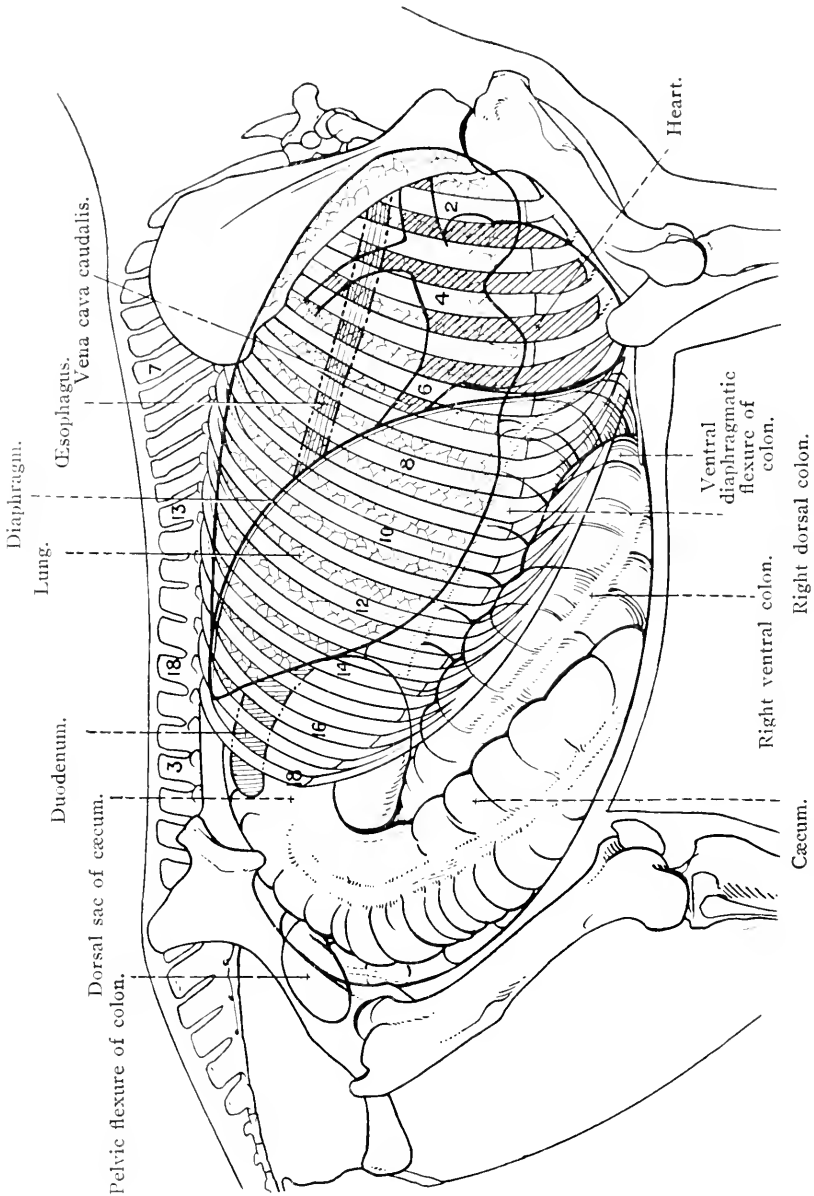


FIG. 39.—Diagram illustrating the topography of the thoracic and abdominal viscera as seen from the right.

containing a variable amount of fat. Fat is absent from most of that part of the diaphragm covered with peritoneum, but there may be a certain amount over the extreme periphery of the muscle.

Though the abdominal cavity is one and continuous, for descriptive purposes it is necessary to divide it into the cavity of the *abdomen proper*

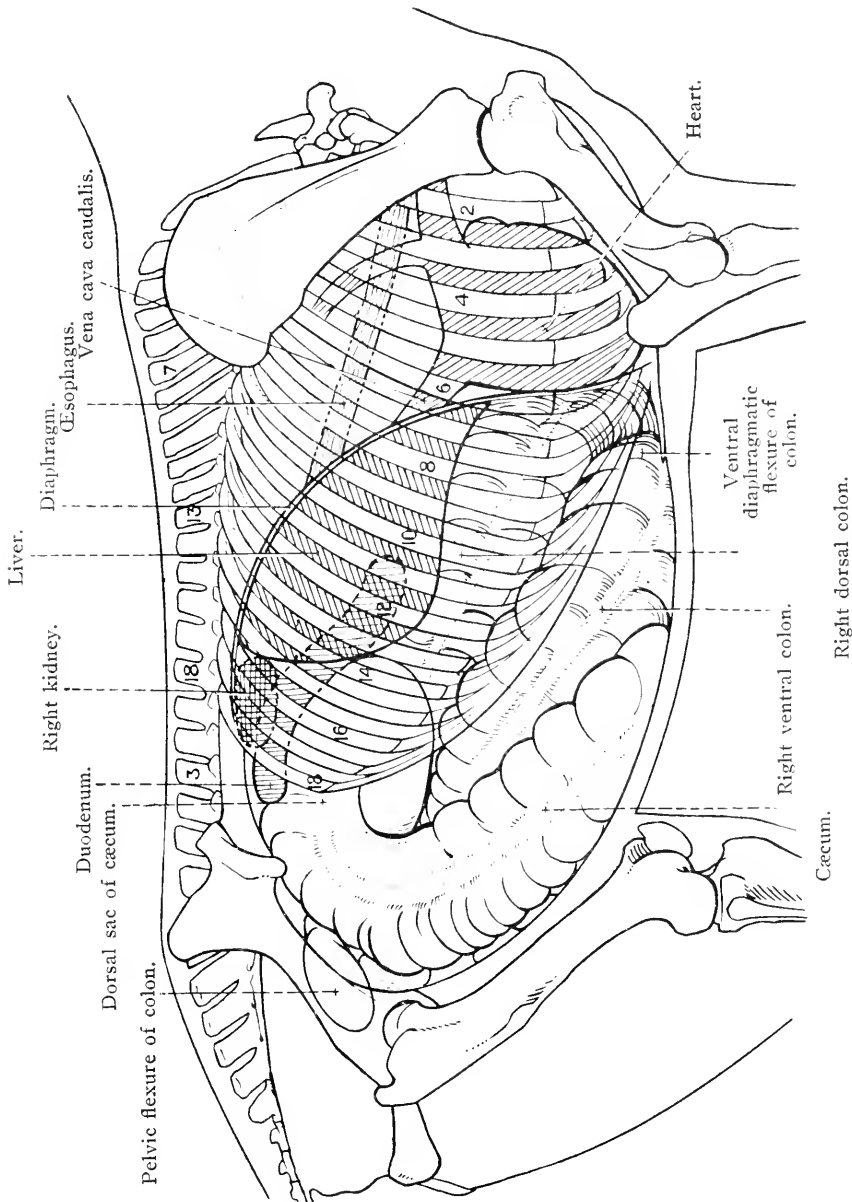


FIG. 40.—Diagram illustrating the topography of the thoracic and abdominal viscera as seen from the right.

and the cavity of the *pelvis*. The distinction between these is that the latter is contained within the hip-bones, and, therefore, is possessed of a complete bony ventral wall. The plane of separation between the

abdomen proper and the pelvic cavity is on a level with the promontory of the sacrum, the ilio-pectineal lines, and the cranial border of the

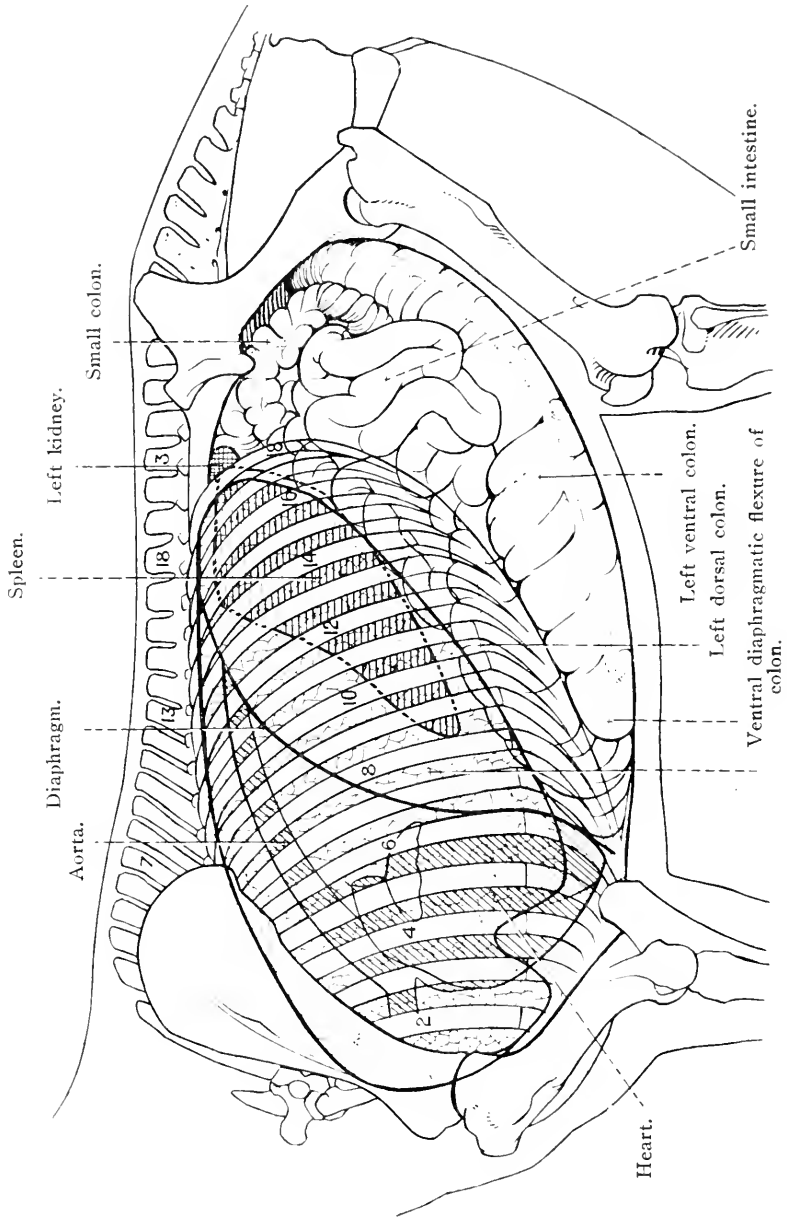


FIG. 41.—Diagram illustrating the topography of the thoracic and abdominal viscera as seen from the left.

pubes. The plane, therefore, lies obliquely to the long axis of the abdomen proper, inasmuch as it slopes in a caudal and ventral direction. The boundaries of the plane circumscribe the brim or inlet of the

pelvis, and constitute the *terminal line* (linea terminalis), which is divisible into pars sacralis, pars iliaca and pars pubica, from the bones with which the line is associated.

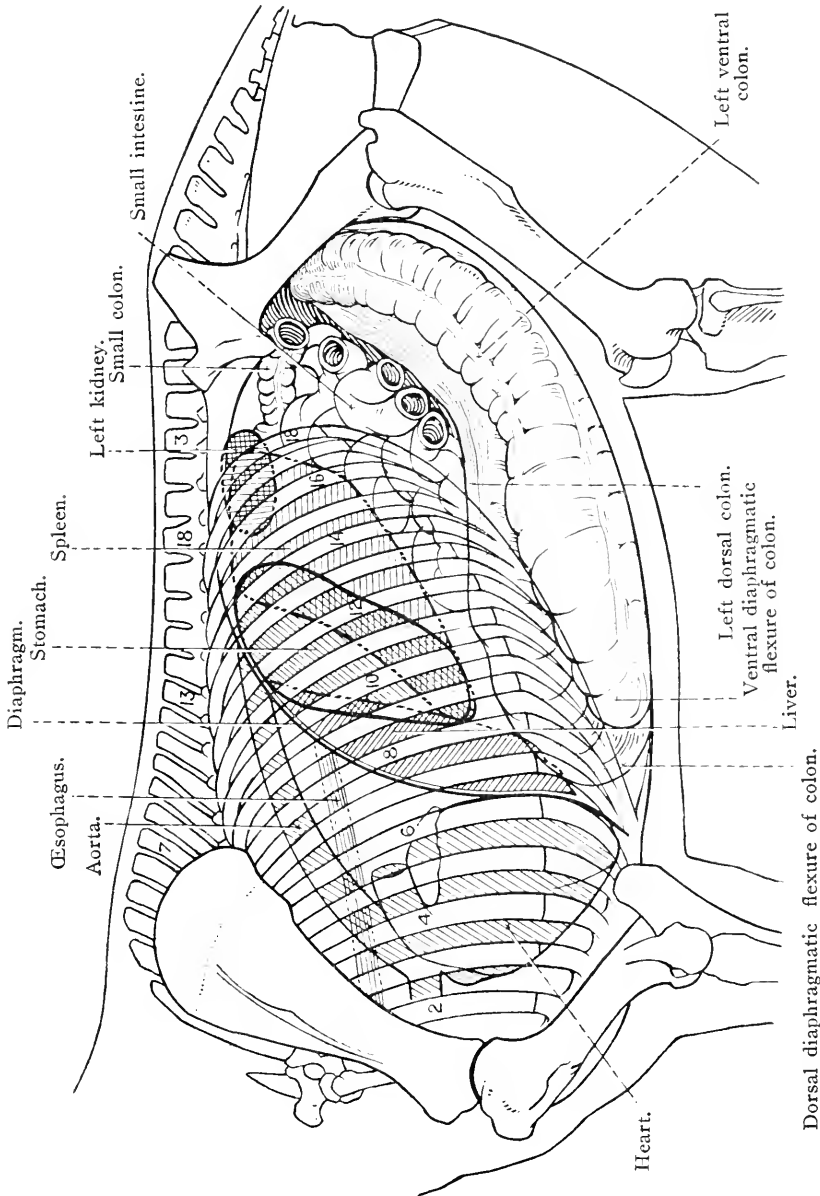


Fig. 42.—Diagram illustrating the topography of the thoracic and abdominal viscera as seen from the left.

*Contents of the abdomen proper.*—As will be appreciated from the following list, the organs and structures within the abdomen are numerous and of widely different physiological function.

Alimentary organs.	{ Stomach. Small intestine. Large intestine. Liver. Pancreas.
Urinary organs.	{ Kidneys. Ureters (greater part). Bladder (when distended).
Reproductive organs.	{ Deferent ducts (part of) in the male. Ovaries, uterine tubes of Fallopius, and uterus (greater part) in the female.
Spleen.	
Adrenal glands.	
Arteries.	The abdominal aorta and its various branches.
Veins.	The caudal vena cava and its tributaries, the portal vein and its tributaries, and the commencement of the vena azygos.
Lymph glands and lymphatic vessels,	including the cisterna chyli and the commencement of the thoracic duct.
The abdominal part of the sympathetic nervous system	and the termination of the two vagus nerves.
The peritoneum,	which forms a lining for the cavity and an investment for the organs contained therein.

Since the knowledge is of the first importance to the clinician, the topography of the abdominal organs, and their relation to the surface of the body, should be studied with care; but it must be borne in mind that the exact relations of the organs are very variable, not only in different animals, but also in the same animal at different times. The posture of the body, the amount of distension of the hollow viscera, and the movements of inspiration and expiration, have all their influence. In the female there must also be added the effect of pregnancy.

Unlike other domestic animals, the horse possesses an inextensive *omentum* (*omentum majus*) which does not overlie the intestinal mass. Consequently, when the abdomen is first opened in the manner above described, certain parts of the intestines are at once revealed. Placed in and about the middle line is the *cæcum*. In shape this is a long cone, with a base at the pelvic inlet to the right of the middle line of the body. The long axis of the cone is slightly oblique; consequently the blind apex, directed towards the diaphragm, may be a little to the left of the middle line.

Other very obvious parts of the intestines are the right and left segments of the *great colon*. If the dissector examine the large gut in the right flank, he will observe that the broad base of the *cæcum* is connected with the *right ventral colon*. From this point the colon runs in a cranial direction towards the diaphragm, and then bends upon itself—at the *ventral diaphragmatic flexure*—to become the *left ventral colon*. If this be followed to the pelvic entrance, a short dorsal bend (the *pelvic flexure*), to the right of the middle line, will be detected. Thereon follow the *left dorsal colon*, the *dorsal dia-*

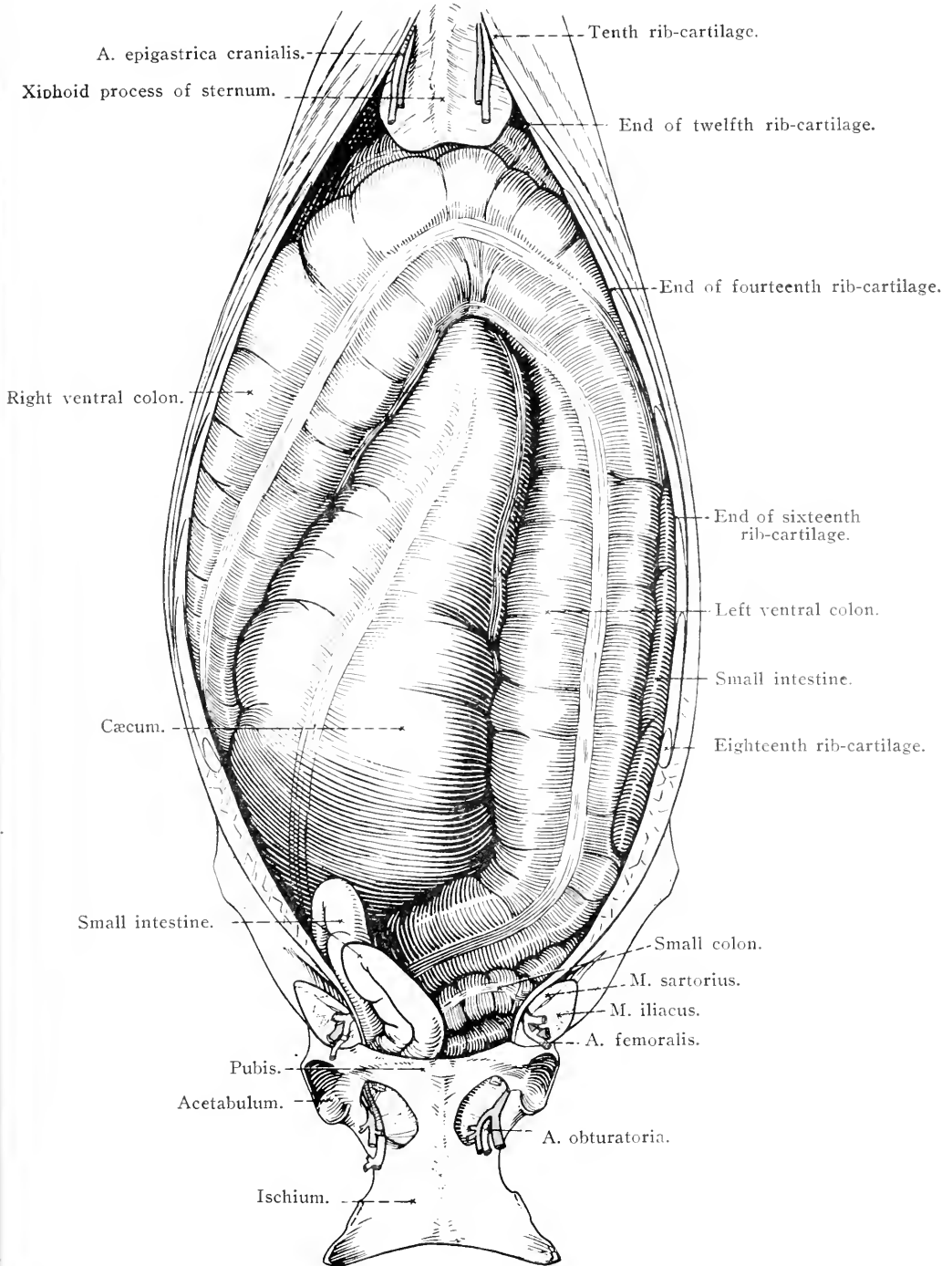


FIG. 43.—Intestines as exposed by removal of the ventral wall of the abdomen.

*phragmatic flexure*, and the *right dorsal colon*, which bring the tube back again to the neighbourhood of the pelvic inlet.

If now the left portion of the great colon be raised, some coils of the *small colon* and the *small intestine* will be disclosed. Not infrequently short lengths of these parts of the intestinal tube are visible without disturbance of the great colon. The small intestine is readily distinguished from the small colon by the absence of those sacculations that produce the characteristic appearance of the large intestine of the horse.

It is worthy of note that, in the horse, neither the stomach nor the liver are visible before disturbance of the intestinal mass. That is, neither of these organs is in contact with the ventral wall of the abdomen.

*Dissection.*—After a general survey of the intestines has been made as above, the dissector should lift the left ventral and left dorsal colon out of the abdomen and straighten out the ventral and dorsal diaphragmatic flexures. This will permit him to examine the whole intestinal tube with the exception of the first and last portions.

THE SMALL INTESTINE (*Intestinum tenue*).—The small intestine is a fairly uniform tube about 6-8 em. in average width and some 20 metres in length. It extends from the pylorus, where it is continuous with the stomach, to the lesser curvature of the cæcum. The greater part of the tube, in company with the small colon, occupies the dorsal and left part of the abdomen, but, owing to its mobility, portions of it may be found in other regions.

The small intestine is divided into — (1) The *duodenum*; <sup>1</sup> (2) the *jejunum* <sup>2</sup> (*intestinum jejunum*); and (3) the *ileum* <sup>3</sup> (*intestinum ileum*). The coils of the jejunum and ileum are freely movable, since they are suspended from the dorsal wall of the abdomen by a long fan-shaped sheet of peritoneum, the *mesentery* <sup>4</sup> (*mesenterium*); but the duodenum, being provided with a very short fold of peritoneum (*mesoduodenum*), is incapable of much displacement.

A definite line of demarcation between the jejunum and ileum cannot be determined. Generally, in the dissection subject, the ileum is the more contracted part of the tube, though when in the flaccid condition it is the wider. The last part of the ileum, however, is not

<sup>1</sup> *Duodeni* [L.], twelve each, by twelves, twelve. This part of the small intestine is so called because in man its length is about twelve finger-breadths.

<sup>2</sup> *Jejunus* [L.], empty.

<sup>3</sup> *Ileum* [L.], *εἰλεῖν* (*eilein*) [Gr.], to roll up, to twist. This part of the intestine is so named from its numerous coils in man. Horace uses *ilia* (the flank) to indicate the entrails of animals.

<sup>4</sup> *μέσος* (*mesos*) [Gr.], middle; *έντερον* (*enteron*) [Gr.], bowel.



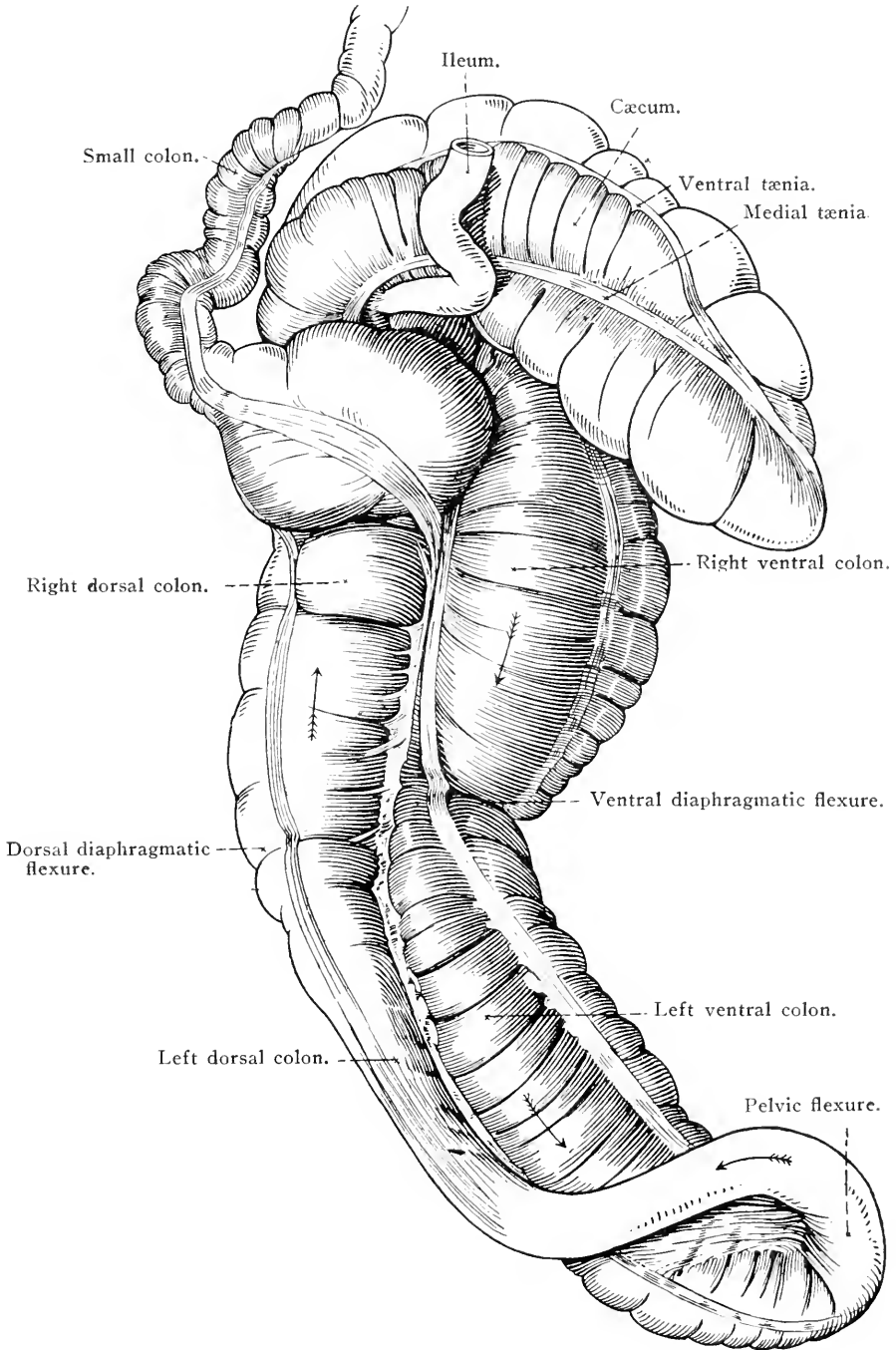


FIG. 44.—The colon and cæcum. The great colon has been straightened as much as possible.

difficult to recognise, because, for a metre or more before the cæcum is reached, the wall of this part of the small intestine is definitely thicker. A considerable part of the ileum lies to the right of the median plane.

The duodenum, being much less mobile than the rest of the small intestine, has a definite position in relation to the liver and the right kidney. The examination of this portion of the intestine is best deferred until later.

THE LARGE INTESTINE (*Intestinum crassum*).—There can be little question that the large intestine of the horse merits its name, for the greater part of the tube is of a calibre many times that of the small intestine. Another striking feature of this part of the alimentary tube is the presence of numerous sacculations (*haustra*)<sup>1</sup> produced by longitudinal bands or flattened bundles (*tæniæ*)<sup>2</sup> of muscular fibres. The bands being shorter than the gut of which they form part, it follows that the surface of the tube cannot be smooth, as it is in the small intestine where muscular bands are absent.

The large intestine is divided into three clearly differentiated portions—the cæcum, the colon and the rectum.

The *cæcum*<sup>3</sup> (*intestinum cæcum*).—The greater part of the large conical cæcum occupies the right dorsal region of the abdomen, the basal extremity of the tube being close to the inlet to the pelvis. The narrower part of the cæcum extends along the floor of the abdomen with some small degree of obliquity, so that the blind, pointed cranial end is ventral in position and generally at, or possibly slightly to the left of, the median plane, a short distance behind the xiphoid process of the sternum.

It is convenient to consider the cæcum as composed of a body, a dorsal sac and an apex. The *body* (*corpus cæci*) is the middle part of the tube and gradually tapers to the blind, pointed *apex* (*apex cæci*). It will be observed that the apex is freely movable.

The *dorsal sac* (*saccus dorsalis cæci*) is the most capacious, as well as the most caudal and dorsal, part of the cæcum. Its form is such as to permit of the ready recognition of two curvatures. The greater curvature (*curvatura major*) is convex, and is in contact with and adherent to the right kidney and the pancreas. The concave lesser curvature (*curvatura minor*) has a ventral and medial aspect. The cranial end of the dorsal sac is blind; while the caudal or pelvic end is continuous with the body of the cæcum. To the right the sac is in contact with the duodenum: its left face being related to the jejunum,

<sup>1</sup> *Haustrum* [L.], a machine for drawing up water from a well, a drawer.

<sup>2</sup> *Tænia* [L.], *ταινία* (*tainia*) [Gr.], a flat band, a tape, a ribbon.

<sup>3</sup> *Cæcus* [L.], blind.

small colon, the right dorsal colon, and, frequently, the pelvic flexure of the great colon.

The lesser curvature of the dorsal sac is connected with the ileum and the colon. The termination of the ileum is surrounded by a strong ring of muscular fibres (sphincter ilei) that gives sharp definition to the emergence of the small intestine into the cæcum. The connection of the cæcum and colon, while sufficiently definite, is not so narrow as the ileo-cæcal junction. The cæco-colic union, moreover, is lateral to (that is, to the right of) and somewhat nearer the pelvic brim than is the entrance of the ileum into the cæcum. It also is provided with a ring of muscular fibres (sphincter cæci).

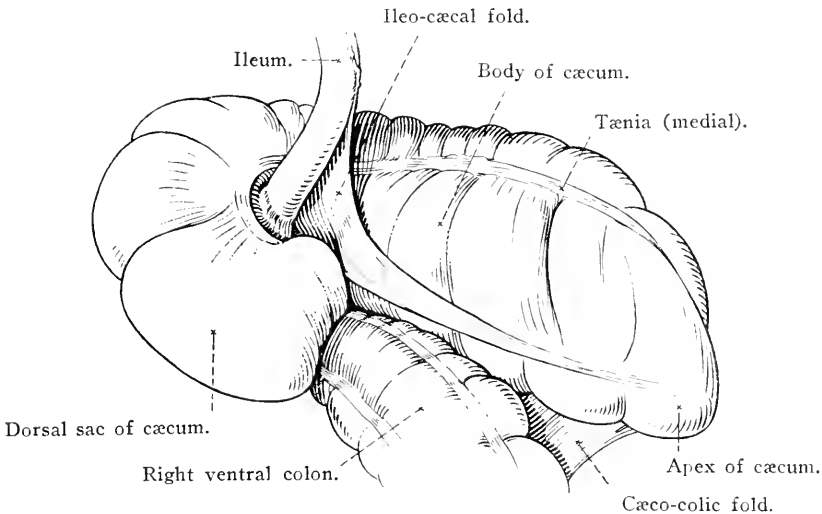


FIG. 45.—The cæcum and its connections.

The ileo-cæcal and cæco-colic openings will be examined later with the rest of the interior of the cæcum.

Four longitudinal muscular bands (tæniæ cæci), ventral, dorsal medial and lateral in position, produce four rows of sacculations (haustra cæci) on the exterior corresponding to four rows of saccular cells (cellulæ cæci) in the interior of the tube. Three of the longitudinal bands are associated with peritoneal folds: only one of them, the ventral, being entirely free.

The *colon*.<sup>1</sup>—This part of the large intestine of the horse is characterised by being readily divisible into two parts, namely—(1) an enormous and capacious *great colon* that leads from the cæcum and resembles this in its calibre, and (2) a very much narrower *small*

<sup>1</sup> κóλον (kolon) [Gr.], food, meat, fodder. The term was used by Aristotle in the sense in which it is applied in anatomy to-day.

*colon*, not very greatly wider than the small intestine with which its coils are mixed, and possessed, like the small intestine, of a mesentery that permits of a considerable degree of mobility.

*Great colon*.—The disposition of the great colon is most easily understood if it is regarded as having been twice doubled upon itself, so that four lengths of intestine, united by three bends, have been produced. This will also account for the circumstance that the beginning and the end of the tube are at no great distance from each other.

Beginning at the lesser curvature of the cæcum, the great colon passes down the slope of the abdominal wall, on the right side of the body, as the *right ventral colon* (*colon ventrale dextrum*), which ends in the xiphoid region (on a level with the seventh or eighth rib) at the *ventral diaphragmatic flexure* (*flexura diaphragmatica ventralis*) that carries the intestine over to the left side of the abdomen. From this flexure the gut proceeds along the left side of the ventral part of the abdomen—as the *left ventral colon* (*colon ventrale sinistrum*)—to the entrance to the pelvis. At the pelvic inlet, and to the right of the median plane, is the *pelvic flexure* (*flexura pelvina*), a bend in a dorsal and forward direction, from which the tube again runs towards the thorax. This part of the gut, the *left dorsal colon* (*colon dorsale sinistrum*), lies dorsal and medial to the left ventral colon. A bend to the right, the *dorsal diaphragmatic flexure* (*flexura diaphragmatica dorsalis*), on a level with the sixth or seventh rib, leads to the *right dorsal colon* (*colon dorsale dextrum*) that passes towards the pelvis, gradually increasing in diameter to assume finally the form of a bent, blind, saccular tube. The termination of the great colon is marked by a sudden narrowing of the gut, ventral and slightly to the right of the left kidney.

The peritoneal relations of the cæcum and great colon are conveniently observed at the present time.

A triangular *cæco-colic fold* (*plica cæcocolica*) connects the lesser curvature of the dorsal sac and body of the cæcum with the right ventral colon. A similar but smaller *ileo-cæcal fold* (*plica ileocæcalis*), produced by the ileum forsaking the border of the mesentery, passes from the cæcum to the terminal part of the ileum.

The right ventral and right dorsal parts of the colon are closely applied to each other and intimately united by peritoneum which forms a common investment. The union of the left ventral and left dorsal parts is also effected by peritoneum, but the association is much less close; for between the two tubes is a double layer of peritoneum that gradually increases in breadth from the diaphragmatic to the pelvic flexure.

The last point to notice is the fixation of the dorsal sac of the cæcum and the terminal part of the right dorsal colon to organs on the dorsal wall of the abdomen (right kidney and pancreas) and to a small area of the wall itself. Fixation is effected by fibrous tissue (in which are blood vessels and nerves), surrounded by a reflection of peritoneum, and an offshoot from the right triangular ligament of the liver.

The right and left portions of the ventral colon carry four tæniæ and four rows of sacculations. These two parts of the intestine, it will be noted, are approximately equal in width. The pelvic flexure and the greater part of the left dorsal colon are much narrower than the rest and carry only one longitudinal band. The rest of the colon, gradually dilating until it ends as the widest part of the tube, has three tæniæ.

The *small colon* consists of coils mixed with those of the small intestine in the left dorsal fourth of the abdominal cavity. Because of the presence of a definite and broad mesentery, this part of the large intestine is capable of a considerable degree of mobility. Like the great colon, the small colon is characterised by sacculations and tæniæ. The bands are two in number: one following that border of the intestine to which the mesentery is attached, the other running along the convex border of the gut.

The examination of the terminal part of the large intestine, the rectum, must be postponed until the contents of the pelvis are dissected.

**PERITONEUM** (Peritonæum).—The peritoneum<sup>1</sup> is an elastic, smooth, moist and glistening serous membrane that covers, more or less completely, the surface of the organs contained in the abdomen, and also lines the inner surface of the abdominal walls. It is continued beyond the limits of the abdomen proper, clothes part of the pelvic organs, and lines part of the pelvic wall. The part within the pelvis will be examined later. A layer of areolar tissue, containing a variable amount of fat, connects the peritoneum to the walls and viscera. In some places the tissue is abundant, while in others, especially over the viscera, it is scanty in amount. The presence of subserous tissue gives a flocculent appearance to the detached membrane.

Like other serous membranes, the peritoneum is described as consisting of two layers: a parietal layer (*lamina parietalis*) adherent to the abdominal wall, and a visceral layer (*lamina visceralis*) applied to the abdominal organs. Between the two is a potential space, the peritoneal cavity, which is opened into when the wall of the abdomen is

<sup>1</sup> *περιτόναιον* (*peritonaion*) [Gr.] = *περί* (*peri*), around + *τείνειν* (*teinein*), to stretch.

incised. It should be carefully noted that the peritoneal cavity does not exist as an actual space so long as the wall of the abdomen is intact; the parietal and visceral layers of the peritoneum being separated only by a very thin film of serous fluid, secreted by the membrane itself. Macroscopically, the peritoneal cavity is completely closed in the male; in the female two small openings, the abdominal ostia of the uterine tubes, place it in indirect communication with the exterior by way of the tubes, uterus, and vagina. In all animals the peritoneal cavity communicates by microscopic stomata with lymph vessels.

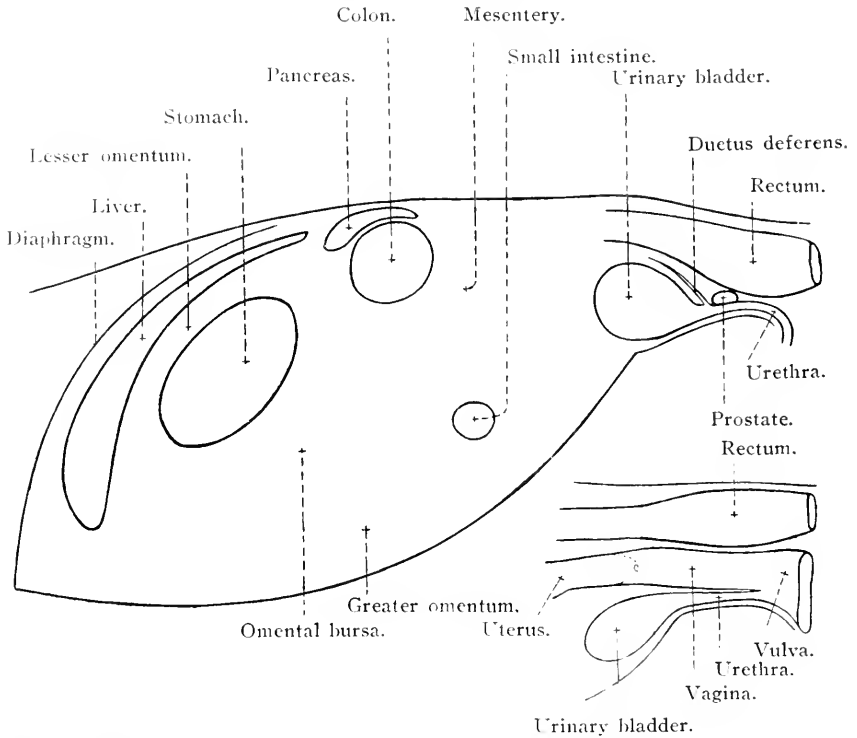


FIG. 46.—Diagram to illustrate the arrangement of the peritoneum in median longitudinal section. The peritoneum is represented by the red lines. The larger figure indicates the arrangement in the male pelvis; the smaller figure represents the female pelvis.

As will be seen as the examination of the peritoneum proceeds, there are numerous special folds and dependencies associated with certain of the abdominal organs. Mesenteries, or broad folds, suspend the small intestine and the small colon from the dorsal wall of the abdomen. Ligaments, so-called, are numerous, and are either long or short. Some of them are truly binding structures, as those in connection with the liver; others are only binding in a limited sense, as, for example, the gastro-splenic ligament, which loosely connects the

stomach and spleen with each other. A ligament, further, may have a very close morphological resemblance to a mesentery, as is the case with the broad ligament of the uterus. Some ligaments, the falciform of the liver and one on each side of the urinary bladder, are peritoneal folds with a free margin containing the remains of an embryonic blood vessel. All peritoneal folds contain a varying amount of connective tissue and fat, and many of them supply a means whereby vessels and nerves reach the viscera. In some folds, notably in the mesentery of the small intestine, lymph glands are readily discernible, and in some also—in the broad ligament of the uterus, for example—there is an appreciable amount of unstripped muscular tissue.

In connection with the peritoneum there are two omenta, a greater and a lesser. The *lesser omentum* (omentum minus) may be demonstrated by turning the intestinal mass aside and then separating the liver and stomach as far as possible. When this has been done, a loose membranous sheet of peritoneum will be found stretching from the liver to the lesser curvature of the stomach and the first part of the duodenum. It is customary, for convenience of description, to divide the lesser omentum into the hepato-duodenal and hepato-gastric ligaments—names which sufficiently clearly indicate their connections.

The *greater omentum*<sup>1</sup> (omentum majus) has a more complicated series of connections. In the horse it is small and not disposed, as in the dog, over the whole of the intestinal mass, but is generally invisible when the abdomen is first opened. It has to be sought dorsal to the larger intestine, immediately caudal to the stomach, where it is readily recognised by its lace-like appearance. A variable amount of fat, commensurate with the deposit of fat in the body in general, is contained within the omentum. When the membrane is straightened out it will be noticed that it apparently consists of two layers enclosing a cavity. In reality, however, it is composed of four layers of peritoneum, as will be demonstrated presently. In order to study the connections of the omentum it is well to make an opening into the cavity (bursa omentalis) enclosed within it. In general terms it may be stated that the greater omentum is a loose double membrane with a ventral attachment to the greater curvature of the stomach and a dorsal attachment to the termination of the large colon and the commencement of the small colon. It simplifies matters to regard the spleen as insinuated between the layers of the ventral sheet of the omentum.

The attachments of the greater omentum should be followed, beginning at the greater curvature of the stomach. An examination of the gastric line of attachment at once convinces the dissector that what

<sup>1</sup> *Omentum* [L.], the fat-containing membrane that covers the intestines.

appears at first sight to be a single membrane is really composed of two thin membranes closely adherent to each other; for at the greater curvature of the stomach the omentum very obviously splits into two sheets, each continued over one of the two surfaces of the stomach.

Following the gastric line of attachment towards the right, it will be found to be continued along the ventral surface of the pylorus and obliquely across the left face of the beginning of the duodenum. Thence it proceeds along the cranial surface of the great colon from right to left, and for some 25 or 30 cm. along the small colon. A sharp

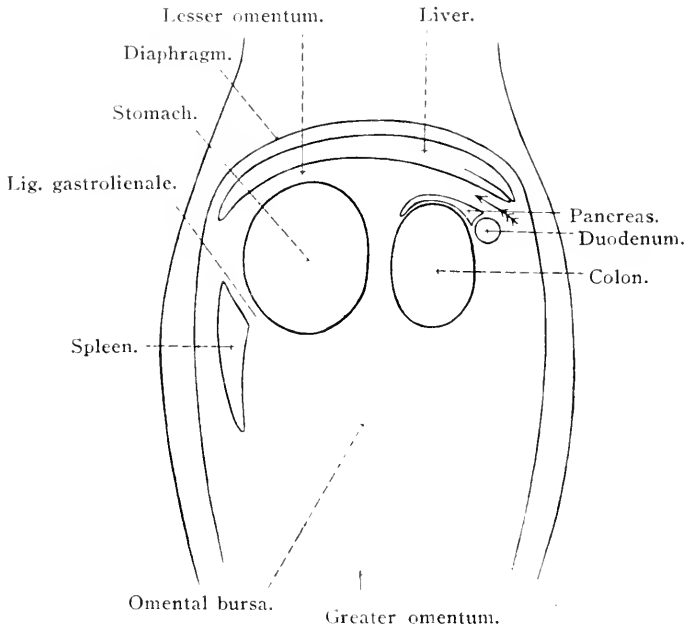


FIG. 47.—Diagram to illustrate the arrangement of the peritoneum in horizontal section. The peritoneum is represented by the red lines. The position of the epiploic foramen is indicated by an arrow.

bend in a cranial direction brings the line of attachment to the base of the spleen, where the omentum is continuous with the suspensory ligament of that organ. From this point the attachment follows the hilus of the spleen, from which the omentum proceeds to the greater curvature of the stomach as the loose gastro-splenic ligament. This brings the dissector back to the point from which he started, and serves to show the continuity of the omentum.

The *omental bursa*<sup>1</sup> (*bursa omentalis*) is the cavity contained within the greater omentum, and was opened when the omentum was incised. Exploration of the bursa will show that it communicates by a large

<sup>1</sup> *Bursa* [L.]; *βυρσα* (*byrsa*) [Gr.], the skin, a hide, a purse.



*aditus*<sup>1</sup> (*aditus ad bursam omentalem*), over the lesser curvature of the stomach, with the *vestibule of the bursa* (*vestibulum bursae omentalis*), a smaller cavity included, roughly speaking, between the stomach and the liver. The vestibule is bounded ventrally by the stomach and the lesser omentum, and dorsally by the gastro-pancreatic fold of peritoneum and the tail of the pancreas. The gastro-pancreatic fold passes from the saccus cæcus of the stomach to the pancreas and duodenum, and is attached in addition to the dorsal border of the liver and the caudal vena cava. To the left the vestibule is bounded by the gastro-phrenic ligament, a double fold of peritoneum passing from the stomach to the diaphragm.

It must not be supposed that the cavity of the omental bursa and its vestibule is not part of the peritoneal cavity in general. If the finger of one hand be passed towards the left along the surface of the caudate process of the liver, and the other hand be introduced into the vestibule of the bursa, the fingers of the two hands may be made to meet at an opening, the *epiploic foramen* (of Winslow). The foramen is small, being in the form of a slit not more than from 6 to 10 cm. long. It lies a little to the right of the median plane, immediately medial to the right kidney and dorsal to the porta of the liver. The foramen is bounded dorsally by the caudate process of the liver and the caudal vena cava; and ventrally by the portal vein, the pancreas and the gastro-pancreatic fold.

*Development of the peritoneum.*—The peculiarities of the omenta and the omental bursa will perhaps be better understood if the development of the peritoneum in this region is very briefly described.

In its early embryonic condition the alimentary canal is suspended from the dorsal wall of the abdomen by a simple and continuous dorsal mesentery, such as is a permanent feature in many reptiles. When the cavities of the thorax and abdomen have been separated from each other by the development of the diaphragm, a ventral mesentery (*ventral mesogastrium*) can also be recognised. This forms a connection between the stomach and duodenum and the liver, and between the liver and the ventral wall of the abdomen. The liver, indeed, by its development has caused the production of the ventral mesogastrium. The lesser omentum of the adult represents that part of the ventral mesogastrium that lay between the stomach and the liver; while the falciform ligament is the remains of the ventral mesogastrium between the liver and the ventral wall of the abdomen.

The term *dorsal mesogastrium* is applied to that part of the dorsal mesentery that is connected with the stomach. So long as the

<sup>1</sup> *Aditus* [L.], a way or entrance, access.

stomach is merely a fusiform dilatation of the alimentary tube, the dorsal mesogastrium is short; but with the disproportionate growth of the dorsal surface of the stomach, whereby the greater curvature is produced, and the rotation of the sac so that its left surface becomes ventral, the mesogastrium gradually assumes a pouch-like form. The greater omentum of the adult develops from part of the wall of the pouch. At first the pouch has a wide mouth directed towards the right; but with the growth of the liver the mouth of the pouch becomes narrower and is finally reduced to the epiploic foramen.

As stated above, the dorsal mesentery is at first simple and continuous; but the elongation and rotation of the intestinal tube renders permanence of this simple condition impossible. Hence the complexity met with in the adult.

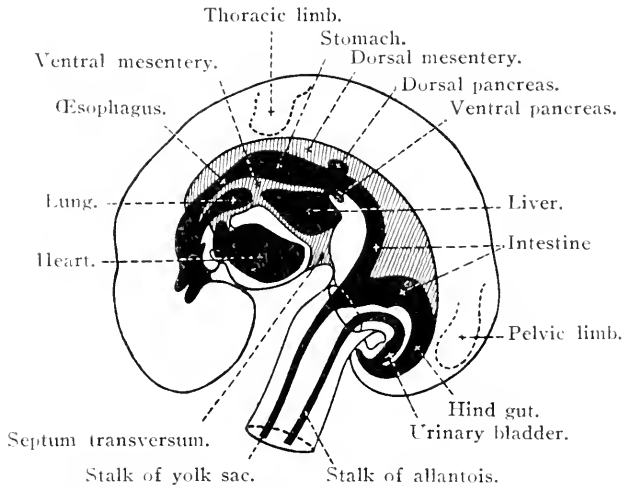


FIG. 48.—Scheme of the alimentary tract, &c., of an 8-mm. sheep embryo.  
(After Martin.)

Owing to the large and unwieldy intestines, a detailed examination of the rest of the peritoneum is not easy in the adult. If opportunity offers, the dissector should examine its disposition in a foal—the smaller the better.

If the peritoneum that lines the ventral wall of the abdomen be followed forwards in the region of the median plane of the body, it will be found to be continued on to the surface of the diaphragm, and thence, by way of the various hepatic ligaments, to the surface of the liver. From the diaphragm and the liver, the gastro-phrenic ligament and the lesser omentum continue the peritoneum to the lesser curvature of the stomach and the duodenum. After clothing both surfaces of the stomach and duodenum, the peritoneum reaches the greater curvature of the

stomach, where it is continuous with the ventral sheet of the greater omentum, as has already been discovered.

On the left side of the abdomen, the peritoneum leaves the surface of the diaphragm and the left kidney as the suspensory ligament of the spleen, whence it can be traced into the greater omentum. On the right side the line of reflection is somewhat more complicated. From the diaphragm and the liver the peritoneum passes to the duodenum and the dorsal surface of the pancreas. From the edge of the pancreas and the right kidney the reflection is to the base of the cæcum and the terminal part of the large colon, from which point two lines diverge. To the right the peritoneum passes to the terminal part of the duodenum; to the left it is applied for a time to the left kidney, from which it is continued as the ventral layer of the suspensory ligament of the spleen.

Behind the termination of the large colon is the root of the *mesentery*, that fan-like sheet of peritoneum connected with the small intestine, and by way of which vessels and nerves gain access to the gut. Behind the root of the mesentery is a transverse fold stretching from the commencement of the small colon to the duodenum.

The *colic mesentery*, associated with the small colon, is reflected from the dorsal wall of the abdomen along a line that extends from the ventral surface of the left kidney backwards into the cavity of the pelvis.

A detailed examination of the arrangement of the peritoneum in association with the liver had better be postponed until that organ is considered. And the disposition of the peritoneum in the pelvis should be examined along with the viscera with which it is connected.

*Dissection.*—Owing to the large size of the intestinal mass in the horse, it is very difficult to dissect the blood vessels in the orthodox fashion. Unless the dissection subject is quite small, it is permissible to remove most of the intestines and examine the vessels after they have been severed.

The removal of the intestines should be performed with care, or other organs, notably the pancreas, will suffer injury. Proceed as follows. Pull the cæcum and great colon as far towards the left as possible. Then liberate the terminal part of the colon and the dorsal sac of the cæcum from their attachment to the dorsal wall of the abdomen. This should be done as far as possible with the fingers, the knife, however, being needed to sever the cranial mesenteric vessels. Next cut along the mesenteries of the small intestine and the small colon, keeping within a few centimetres of the border of the intestine.

Apply two ligatures, a short distance apart, round the small colon about the point where it enters the pelvis, and sever the gut between them. Do the same close to the junction of the duodenum and jejunum.

Now proceed to examine the branches of the cranial and caudal mesenteric arteries and veins. The proper cleaning of the arteries is rendered difficult by the presence of a network of sympathetic nerves around them. These nerves should be preserved.

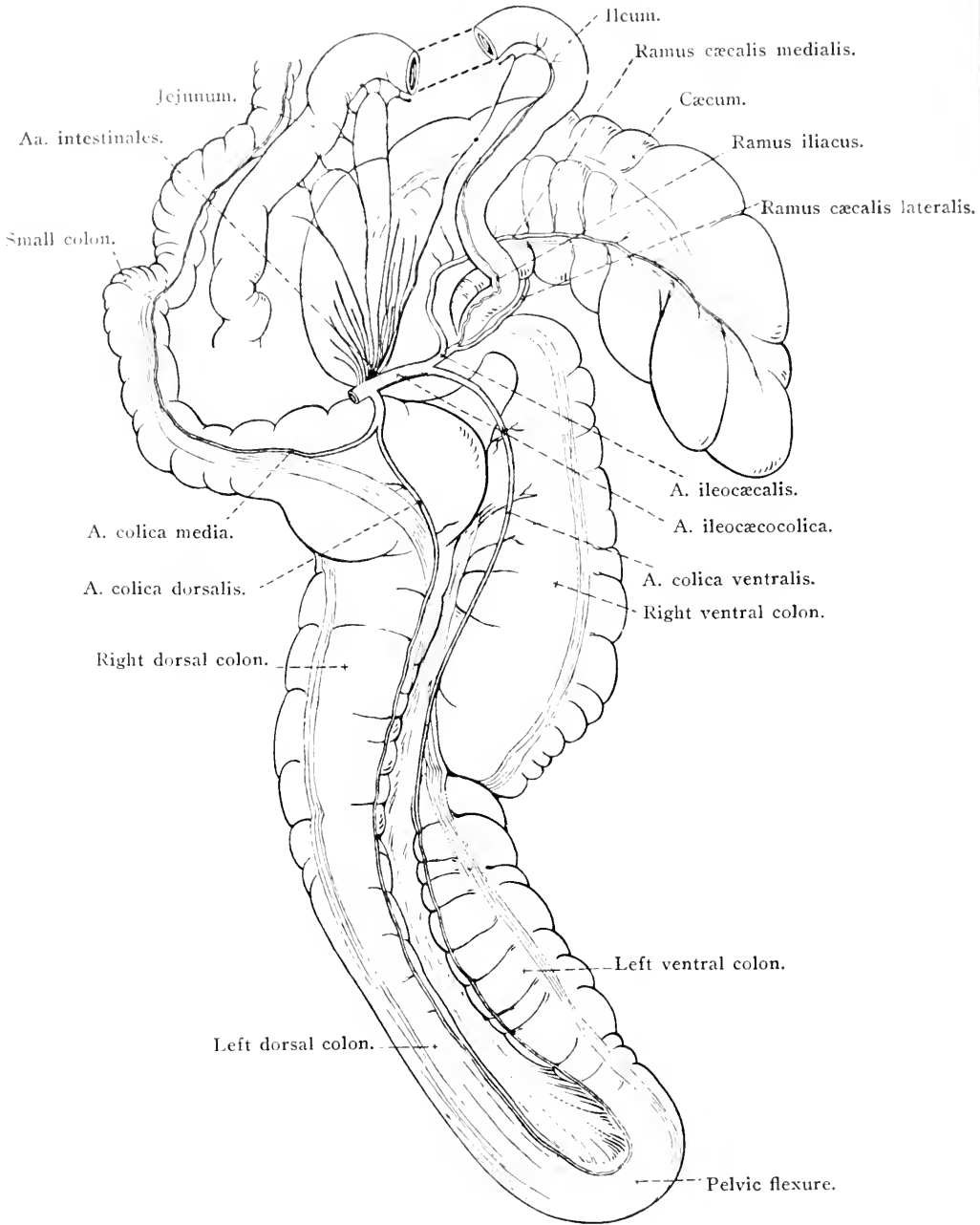


FIG. 49.—Diagram of the branches of the cranial mesenteric artery.

A. MESENTERICA CRANIALIS.—The cranial mesenteric artery is the largest branch of the abdominal aorta, from the ventral border of which it arises opposite the first lumbar vertebra. The artery is very short, and, immediately after leaving the aorta, breaks up into branches for distribution to all the intestinal tube except the commencement of the duodenum, the rectum and part of the small colon. Its branches are the intestinal, middle colic, dorsal colic and ileo-cæco-colic arteries.

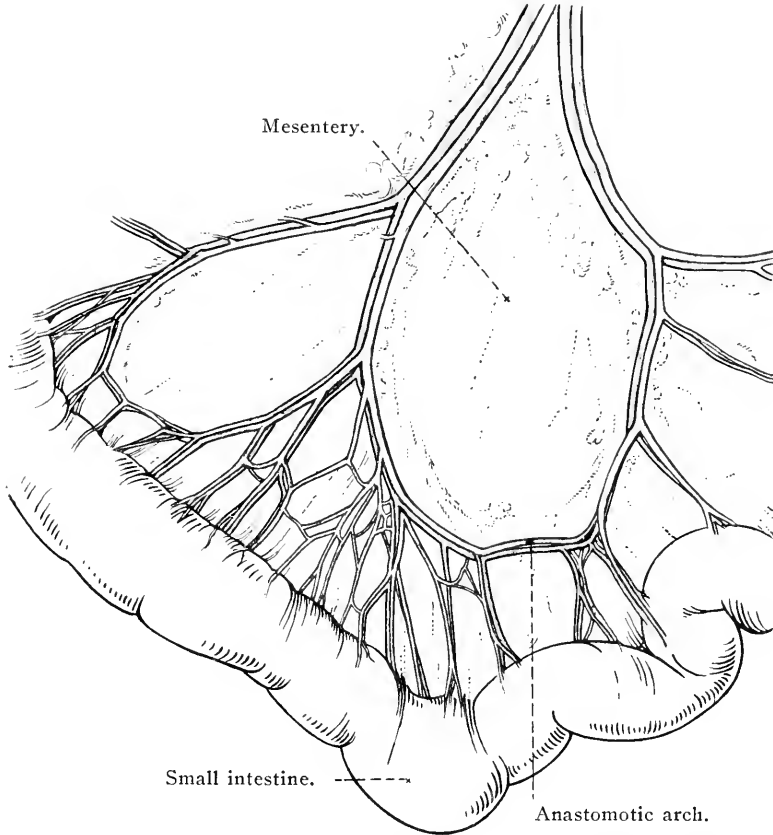


FIG. 50.—To show the manner of distribution of the intestinal arteries.

(1) *Aa. intestinales*.—From eighteen to twenty intestinal arteries leave the cranial mesenteric close together, and run, in a radiating manner, towards the small intestine between the two peritoneal layers of the mesentery. Before reaching the intestine, each vessel divides into two branches, and the branches of adjacent arteries anastomose. Thus a series of arterial arches is formed. From the convexity of the arches branches proceed to the wall of the intestine. The first intestinal artery supplies a part of the duodenum and anastomoses with the duodenal branch of the pancreatico-duodenal artery. The last intestinal artery anastomoses with the iliac branch of the ileo-cæcal artery.

(2) *A. colica media*.—The middle colic artery is scarcely, if at all, larger than one of the intestinal arteries, and consequently might be mistaken for a branch of the dorsal colic artery since both vessels arise from a short common stem. The middle colic artery is distributed to the terminal part of the great colon and a short length of the small colon—the mesentery of which it anastomoses with the left colic artery.

(3) *A. colica dorsalis*.—There can be little question that this vessel should be regarded as the equivalent of the right colic artery of the dog. It is of large size and is conveniently called “dorsal” because of its distribution to the dorsal colon (right and left parts).

(4) *A. ileo-cæco-colica*.—The ileo-cæco-colic artery is the largest branch of the cranial mesenteric, and, as its name implies, is the vessel that supplies blood to the cæcum and ventral colon as well as part of the ileum. It divides into two vessels—the ventral colic and ileo-cæcal arteries.

(a) The *ventral colic artery* (*a. colica ventralis*) supplies the ventral colon (right and left parts) and anastomoses with the dorsal colic at the pelvic flexure.

(b) The *ileo-cæcal artery* (*a. ileo-cæcalis*) furnishes an *iliac branch* (*ramus iliacus*) which carries blood to the terminal part of the ileum and anastomoses with the last intestinal artery. Lateral and medial *cæcal branches* (*rami cæcales*) proceed along the corresponding surfaces of the cæcum to its apex, and frequent anastomoses occur between them. The lateral cæcal branch furnishes twigs to the commencement of the ventral colon.

**A. MESENTERICA CAUDALIS.**—Very much smaller than the cranial mesenteric, the caudal mesenteric artery leaves the ventral border of the abdominal aorta opposite the fourth lumbar vertebra. Running for a short distance between the two peritoneal layers of the mesentery of the small colon, it soon divides into the left colic and cranial hæmorrhoidal arteries.

(1) *A. colica sinistra*.—The left colic artery divides into three or four branches that behave like the intestinal arteries in that they form arterial arches just before reaching the intestine. The first branch anastomoses with the middle colic artery.

(2) *A. hæmorrhoidalis cranialis*.—The cranial hæmorrhoidal artery supplies branches to the terminal part of the small colon and the rectum, ending close to the anus where it anastomoses with the internal pudendal artery. The first four or five branches continue the series of arches begun by the left colic artery.

**VV. MESENTERICA CRANIALIS ET CAUDALIS.**—The tributaries of

the mesenteric veins correspond in general to the branches of the arteries of the same name. The cranial mesenteric vein is of large size but of little length, and lies to the right of the homonymous artery. The caudal mesenteric vein is of much smaller volume. The two vessels are concerned—along with the splenic vein—in the formation of the vena portæ, of which the cranial vein forms the largest radicle.

Numerous, flattened groups of lymph glands (lymphoglandulæ mesentericæ) occur in the mesentery of the small intestine in the neighbourhood of the cranial mesenteric artery. A few glands, small in size, are to be found in association with the iliac ramus of the ileo-cæcal artery. The lymph glands of the cæcum and colon (lymphoglandulæ cæcalis, lymphoglandulæ colica) are disposed in scattered linear

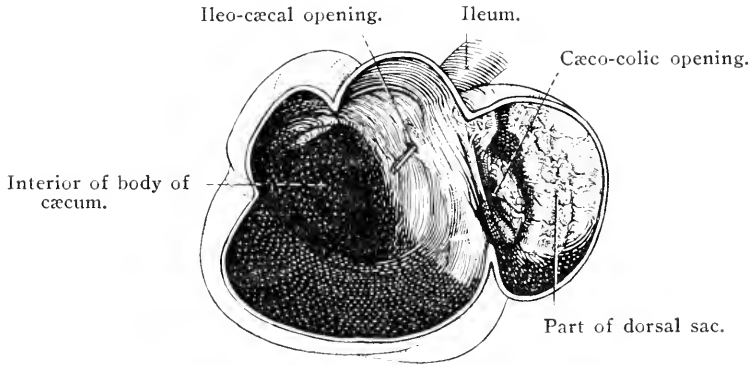


FIG. 51.—View of the interior of the cæcum showing the position of its openings.

groups following the course of the vessels of these parts of the large intestine. The glands of the small colon are to be looked for near the root of the mesentery of this intestine, and also near the attachment of the mesentery to the gut.

**INTERIOR OF THE INTESTINES.**—The intestines should be slit open and their interior examined. The internal lining is a soft, slimy mucous membrane, more or less folded. In the small intestine the folds are longitudinal, and may be obliterated by distension. In the large intestine the folds or ridges are permanent, transverse to the long axis of the tube, and correspond to the constrictions between the sacculations observable on the exterior. Between them are saccular pouches, or *cellulæ*.

The mucous membrane around the ileo-cæcal opening is slightly raised into a circular fold, and at the cæco-colic opening there is a crescentic fold of mucous membrane.

In the small intestine, and more particularly in the ileum, it is

often possible to distinguish oval patches of mucous membrane characterised by the presence of numerous punctiform depressions. These are the *aggregated lymph nodules* of Peyer<sup>1</sup> (*noduli lymphatici aggregati*), and should be looked for along the border of the intestine opposite the mesenteric attachment. Their length may range from 2 to 6 centimetres, and their breadth from 5 to 15 millimetres; but they vary considerably in size in different parts of the intestine, becoming larger as the termination of the ileum is approached. They also vary greatly in different individuals, being generally more conspicuous in young animals.

STRUCTURE OF THE INTESTINES.—A certain amount of the structure of the intestines can be determined by the naked eye, and there will be no difficulty in detecting three tunics: (1) A serous tunic (*tunica serosa*), consisting of visceral peritonemum on the exterior; (2) a muscular tunic (*tunica muscularis*); and (3) a mucous membrane (*tunica mucosa*) lining the interior.

To facilitate the examination of the wall of the gut, a piece should be pinned on a sheet of cork or paraffin with the mucous membrane downwards, and the thin serous investment then carefully removed. The dissector will notice that the serous covering of the intestine is thinner than the membrane forming the mesentery with which it is continuous.

Now turn the piece of intestine over and examine the mucous lining. If the piece of gut belongs to the small intestine, and if it be sunk in water and its surface thoroughly cleared of mucin, a velvety character, due to the presence of delicate projections (*villi*), will be noticeable.

Next remove the mucous tunic and note that the connective tissue under it and between it and the muscular tunic—the submucous tissue or *tela mucosa*—is loose in texture.

An examination of the muscular tunic shows that the fibres composing it are arranged in two strata. The more superficial fibres are longitudinal, and, in the large intestine, gathered together to form bands (*tæniæ*); the deeper stratum consists of circular fibres, particularly obvious at the end of the ileum, where they form what may be regarded as a sphincter muscle, and at the commencement of the colon.

THE STOMACH (*Ventriculus*).—The stomach is the most dilated part of the alimentary canal, intervening between the œsophagus and the small intestine. In view of the herbivorous habit of its possessor, the stomach of the horse is remarkably small, its capacity being scarcely ever greater than 15 litres. In form it is an elongated sac very sharply

<sup>1</sup> Johann Conrad Peyer, a Swiss anatomist, 1653-1712.



bent upon itself so that the entrance and the exit are within a short distance of each other.

The stomach is placed in the dorsal part of the abdomen caudal to the diaphragm and liver, all except a small part of the right extremity being to the left of the median plane of the body. The most dorsal part of the organ, the saccus cæcus, lies under cover of the fifteenth to seventeenth ribs on the left side of the body, and in contact with the left dorsal part of the diaphragm. During expiration the stomach, when moderately distended, occupies a position opposite the thoracic vertebrae

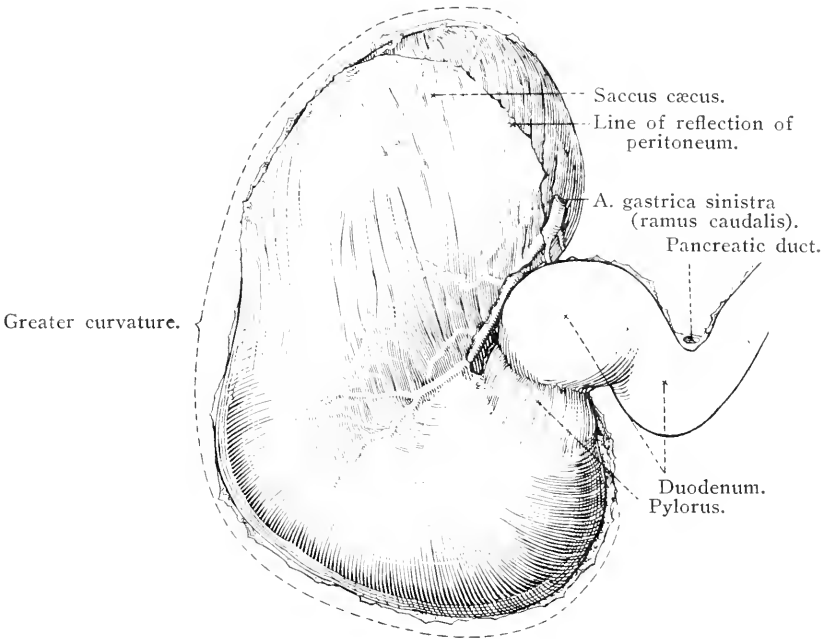


FIG. 52.—Caudal surface of the stomach.

from the thirteenth to the seventeenth. Inspiration pushes it backwards (towards the pelvis), a distance about equal to the length of one vertebra.

Not infrequently a shallow constriction divides the exterior of the organ into an *œsophageal part* (*pars œsophagea*), to the left and dorsal in position, and a larger ventral *intestinal part* (*pars intestinalis*). This external distinction is of some moment, inasmuch as it corresponds to a difference in the structure and function of the mucous lining of the interior.

That part of the stomach which is connected with the œsophagus is known as the *cardia*,<sup>1</sup> dorsal to and to the left of which is the blind sac

<sup>1</sup> καρδία (*cardia*) [Gr.], the heart. The œsophageal opening into the stomach is close to the heart in the human subject.

or *saccus cæcus*. It is remarkable that, in the comparatively empty stomach, the muscular tissue of the blind sac is strongly contracted, and that the sac itself appears to contain little or nothing but gas. It is important to note that the œsophagus joins the stomach abruptly and very obliquely, and that the cardia is situated at a considerable distance (20-25 cm.) from the left extremity of the organ. The deeply hollowed *lesser curvature* (*curvatura minor*) extends from the cardia to the pyloric region or right extremity of the stomach. Roughly midway between the cardia and the pylorus, there is a sharp fold of the wall intruded into the interior. This, it will be seen later, coincides in

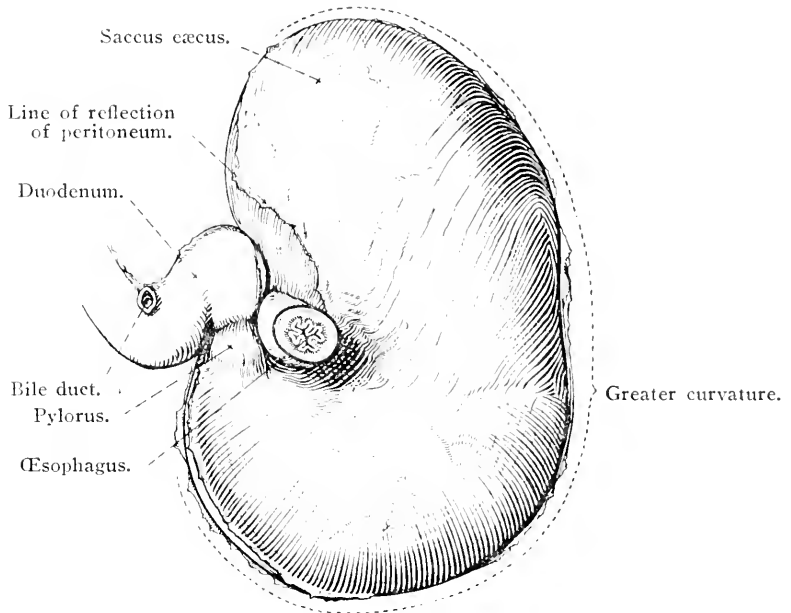


FIG. 53.—Cranial surface of the stomach.

position with a sharp line of division between the two regions of the mucous lining of the organ.

The much more extensive *greater curvature* (*curvatura major*) is convex. Followed from the cardia, it first passes in a dorsal direction, then curves to the left over the *saccus cæcus*, proceeds in a ventral direction, bends to the right across the median plane, and finally ascends to the pylorus. As already stated, not infrequently the even line of the curvature is interrupted by a shallow constriction. That portion of the stomach which is immediately to the right of and ventral to the constriction corresponds to the *fundus* (*fundus ventriculi*) of the stomach of man and the dog. For clinical reasons it is important to note that the greater curvature is usually in contact with the dorsal diaphragmatic

flexure of the larger colon, and is only slightly ventral to the mid-point of the dorso-ventral diameter of the abdominal cavity. Thus the stomach, when moderately distended, is at some distance from the ventral wall of the abdomen. Distension, moreover, does not cause the stomach to approach the abdominal wall to any great extent, but rather causes the organ to bulge towards the pelvis.

The left extremity (*extremitas sinistra*) of the stomach is formed by the *saccus cæcus*. The right extremity (*extremitas dextra*) is more ventral in position and is formed by the *pylorus*<sup>1</sup> and the *antrum pylori*. The antrum is the small part of the stomach preceding the pylorus, and is marked off by two constrictions which correspond to thickenings of the circular stratum of the muscular tunic. The thickening to the right, that is the one encircling the pylorus, is the true *pyloric sphincter* (*sphincter pylori*). The pylorus, leading into the duodenum, is about 5 or 6 centimetres ventral to the cardia, immediately to the right of the median plane, and in contact with the liver close to the porta.

The two surfaces of the stomach are smooth and convex and covered by peritoneum. The cranial or parietal surface (*faciēs parietalis*) is in contact with the diaphragm and liver, and is so inclined as to look in a cranial and dorsal direction and towards the left. The caudal or visceral surface (*faciēs visceralis*) has a correspondingly oblique aspect, and is related to the small intestine, the small colon, the terminal part of the large colon, the pancreas and the greater omentum.

Apart from the fixation afforded by the œsophagus, the stomach depends upon the peritoneum for its connection with surrounding structures. The *gastro-phrenic*<sup>2</sup> *ligament* (*ligamentum gastro-phrenicum*) passes from the region of the cardia and the immediately adjacent part of the greater curvature to the neighbouring part of the diaphragm. A narrow triangular area of the stomach is here left uncovered by peritoneum, with the result that loose connective tissue alone intervenes between the stomach and the diaphragm. The *gastro-splenic ligament* (*ligamentum gastrosplenicum*), which may be regarded as part of the greater omentum, passes from the greater curvature to the hilus of the spleen. Dorsally it is continuous with the phrenico-splenic ligament, and thus the *saccus cæcus* of the stomach is suspended from the left lumbar part of the diaphragm. The *gastro-hepatic ligament* (*ligamentum gastrohepaticum*) leaves the lesser curvature of the stomach and is attached to the central lobe of the liver. To the right it is continuous with the hepato-duodenal ligament: the two together forming the lesser omentum. The *gastro-pancreatic fold*

<sup>1</sup> πυλωρός (*pyloros*) [Gr.], a gatekeeper.

<sup>2</sup> φρήν (*phrēn*) [Gr.], the diaphragm, heart, seat of the emotions.

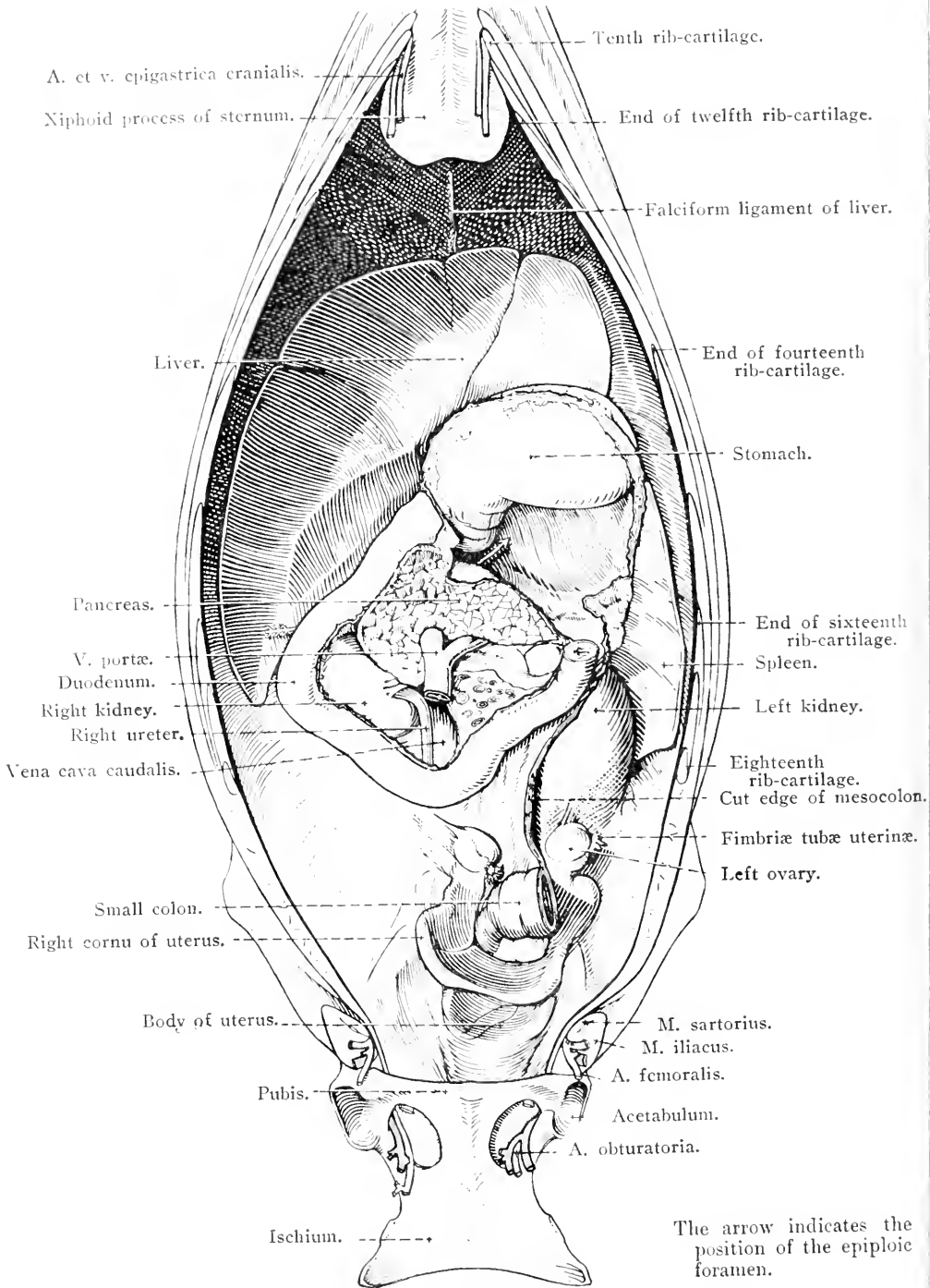


FIG. 54.—The viscera of the female abdomen after removal of the intestines.

(*plica gastropancreatica*) connects the *saccus cæcus* to the pancreas and the duodenum.

The dissector should leave the examination of the interior of the stomach until later.

**THE DUODENUM (Duodenum).**—The duodenum, about one metre in length, is the most distinctive part of the small intestine, inasmuch as its position is definitely fixed. Beginning at the pylorus, the *first part* of the tube is sigmoid and lies on the right lateral lobe of the liver, ending, after a short course to the right, at the *first flexure* (*flexura prima*) which turns towards the pelvis. The *second part* (*pars descendens*) runs ventral to the liver and the right kidney, and ends at the *second flexure* (*flexura secunda*), which, turning to the left, carries the duodenum across the median plane, behind the root of the mesentery and opposite the third or fourth lumbar vertebra, to end in the jejunum.

The calibre of the duodenum is not uniform, for, as it leaves the pylorus, there is a reniform dilatation, with a convexity looking in a dorsal direction.

The first part of the duodenum is connected with the liver by a narrow *hepato-duodenal ligament* (*ligamentum hepatoduodenale*), and the second part is attached to the right kidney by the *reno-duodenal ligament* (*ligamentum renoduodenale*). The peritoneum also forms a short mesentery that passes to the *saccus dorsalis* of the *cæcum* and the right dorsal colon.

**THE PANCREAS.**—The pancreas<sup>1</sup> is a lobulated gland of pinkish-yellow or grey colour when fresh, but after death it quickly assumes a dark grey or even greenish tint. In shape it is irregularly triangular, with its base directed towards the right; its weight is about 350 grammes in a horse of average size. In general appearance the pancreas resembles the salivary glands, but its lobules are more readily separated because of the looseness of the interlobular connective tissue. The gland lies near the vertebral column (opposite the sixteenth, seventeenth and eighteenth thoracic vertebræ), ventral to the aorta and caudal vena cava. Its cranial border touches the *cœliac artery*, while its caudal border is in contact with the cranial mesenteric artery, and is notched by the root of the mesentery.

The greater bulk of the gland lies to the right of the median plane, where it forms a *head* (*caput pancreatis*) related to the duodenum and the right lateral lobe of the liver. The much smaller *cauda pancreatis* is to the left, and in contact with the *saccus cæcus* of the stomach, the

<sup>1</sup> *πᾶς* (*pas* (*pan*)) [Gr.], all; *κρέας* (*creas*) [Gr.], flesh.

basal part of the spleen, the left kidney and the terminal part of the great colon. In general terms, the pancreas is placed between the liver and stomach on the one hand, and the dorsal sac of the cæcum and right dorsal colon on the other.

The dorsal surface is largely covered by peritoneum, and is in contact with a considerable area of the right kidney, the caudal vena cava, the portal vein, the saccus cæcus of the stomach, the gastro-phrenic ligament and the right lateral lobe and caudate process of the liver. The ventral surface has only a limited peritoneal covering, which is absent over the area that is adherent to the cæcum and colon.

Piercing the pancreas from its ventral to its dorsal surface is a short passage, the *portal ring* (*annulus portarum*), for the portal vein.

The pancreas has two ducts, the larger of which, the *pancreatic duct* (*ductus pancreaticus*), leaves the head of the gland, and immediately pierces the wall of the duodenum. When the time arrives to examine the interior of the duodenum, it will be found that the pancreatic and bile ducts open into a common diverticulum. The *accessory pancreatic duct* (*ductus pancreaticus accessorius*) also leaves the head of the gland to pierce the wall of the duodenum immediately. At a later stage in the dissection its opening will be found opposite to that of the main duct. Both ducts are of considerable size and thin-walled, and they intercommunicate within the substance of the gland.

The presence of two pancreatic ducts, and the termination of one of them in common with the bile duct, can be accounted for by the mode of development of the gland. The pancreas develops from dorsal and ventral rudiments. The dorsal pancreas springs from the duodenum opposite the bile duct; while the ventral pancreas begins as two lateral diverticula from the duodenal end of the bile duct. Some authorities are of opinion that both ventral diverticula give origin to pancreatic gland tissue, but others hold that only the right persists. In the horse, the dorsal and ventral pancreas both retain their connection with the gut; and, consequently, in the adult there are two ducts opening into the duodenum opposite each other, the ventral duct maintaining its association with the bile duct.<sup>1</sup>

The double origin of the pancreas can also be adduced in explanation of the occurrence of a portal ring, which is formed by the originally

<sup>1</sup> The various domestic mammals afford interesting illustrations of the possible persistence or disappearance of the dorsal and ventral pancreatic ducts. In the horse (as stated above) and in the dog both ducts persist; in the ox and pig the dorsal duct (opening into the duodenum independently) persists and the ventral duct disappears; and in the sheep the dorsal duct disappears and the ventral duct (opening into the duodenum along with the bile duct) persists.

independent dorsal and ventral glands approaching each other, and finally fusing round the portal vein.

**THE SPLEEN (Lien).**—The spleen is a bluish-red or purple organ of triangular outline, weighing about 1 kilogramme, and placed to the left of the stomach, with the greater curvature of which it is closely related. The *base* of the organ is truncated and dorsal (*extremitas dorsalis*), and almost reaches the vertebral column, being insinuated between the diaphragm and the left kidney. On it the kidney causes a slight concavity (*facies renalis*) with a medial and dorsal aspect. In terms of the

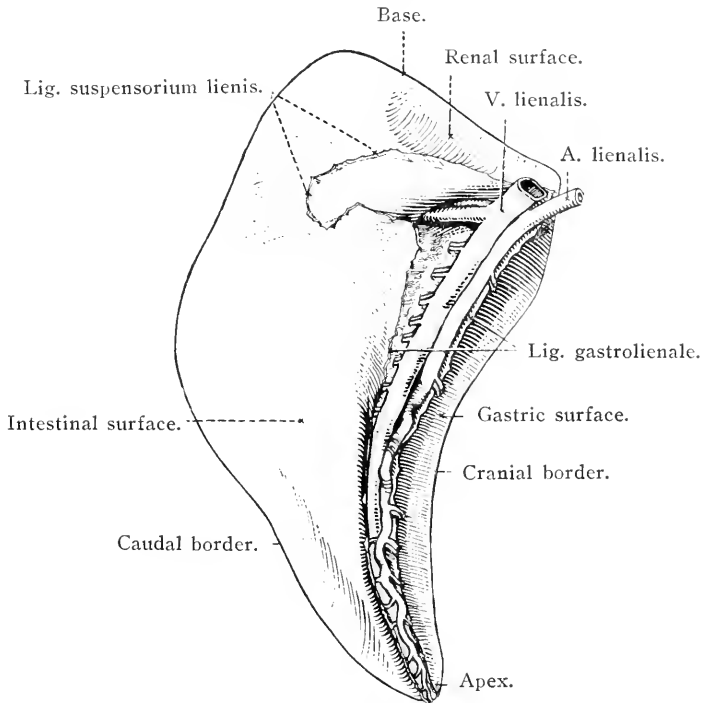


FIG. 55.—Medial aspect of the spleen.

skeleton, the base of the spleen lies under the last three or four ribs. The *apex* (*extremitas ventralis*) is bluntly pointed and directed in a ventral and cranial manner; but, being the mobile part of the organ, varies somewhat in position with the movements of respiration and the amount of distension of the stomach. During expiration it reaches the ninth or tenth intercostal space, but during inspiration it may be pushed backwards as far as the twelfth interspace.

Three definite surfaces of the spleen can be distinguished. The lateral or *parietal surface* (*facies parietalis*) is smooth and convex, and applied to the diaphragm and the dorsal part of the last two ribs. The *visceral surface* (*facies visceralis*) is concave, and related to the small

intestine, the small colon, the omentum and (commonly, but not always) the left dorsal colon. The *gastric surface* (facies gastrica) is elongated, narrow and concave, and lies cranial to the visceral surface. It is chiefly related to the stomach, but may also be in contact with the tail of the pancreas. Between the visceral and gastric surfaces is the *hilus* (hilus lienis), by which blood vessels, nerves and lymphatics enter and leave the organ, and to which the gastro-splenic ligament is attached.

The *cranial border* (margo cranialis), separating the gastric and parietal surfaces, is thin and concave, in conformity with the curvature of the organ as a whole. The *caudal border* (margo caudalis), between the parietal and visceral surfaces, is not quite so thin, and is convex. Its relative position is not constant, but in the majority of horses it begins slightly caudal to the border of the last rib, and follows a line 2 or 3 centimetres dorsal to the union of the ribs with their cartilages.

The spleen is connected with the stomach by the gastro-splenic ligament, as was seen during the examination of the latter viscus. From the medial face of the spleen, close to its base, springs the *suspensory ligament* (ligamentum suspensorium lienis), divisible into a very elastic *reno-splenic ligament* (ligamentum renolienale), attached to the kidney, and a *phrenico-splenic ligament* (ligamentum phrenicolienale), connected with the left lumbar part of the diaphragm and continuous with the gastro-phrenic and gastro-splenic ligaments.

THE LIVER (Hepar).—The liver is the largest gland in the body, weighing about 5 kilogrammes, and is placed in contact with the diaphragm, the curves of which it follows closely. The direction of the longest diameter of the organ is oblique; the right extremity being dorsal and in contact with the right kidney, while the left extremity lies opposite the junction of the seventh or eighth rib and its cartilage. The greater bulk of the organ is to the right of the median plane of the body.

The *diaphragmatic surface* (facies diaphragmatica) is convex, with a dorsal and cranial aspect, and smooth except for a deep groove, running in a ventral direction with a slight degree of obliquity towards the left, and beginning at the dorsal border of the gland. The groove lodges the caudal vena cava, and is known as the *fossa venæ cavae*. Numerous hepatic veins open into the vena cava during its course through the fossa, as may be seen if the vein be slit open.

The *visceral surface* (facies visceralis), speaking generally, is concave; but ridges and projections are readily noted if the organ has been well hardened before the abdomen was opened. An unhardened liver, on the other hand, loses many of its characteristic features



immediately the support of the surrounding organs is removed. On the visceral surface, dorsal to the middle of the organ and immediately to the right of the median plane of the body, there is an elongated oblique depression, the *porta* (*porta hepatis*), by which the portal vein the hepatic artery and nerves enter the liver, and the hepatic ducts and lymphatic vessels leave it.

The *dorsal border* (*margo dorsalis*) is of varying thickness, and

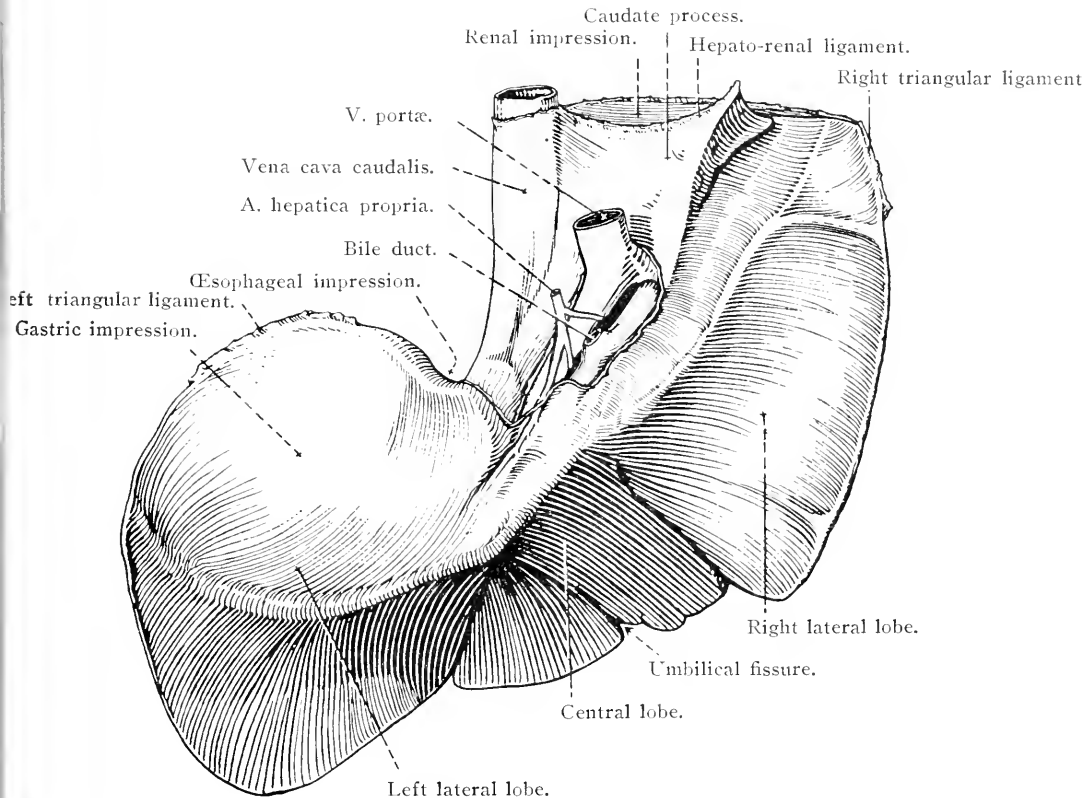


FIG. 56.—The visceral surface of the liver.

presents a number of features to which attention must be directed. On the extreme right there is a depression caused by the right kidney (*impressio renalis*). Immediately to the left of this is a notch produced by the caudal vena cava as it crosses the edge of the liver to gain the fossa on the diaphragmatic surface. Further to the left is a much more definite notch (*impressio œsophagea*) with rounded edges that accommodates the œsophagus as it approaches the cardia of the stomach.

The *right* and *left borders* (*margo dexter*, *margo sinister*) are thin and present no features of moment.

The *ventral border* (*margo ventralis*) is cut by two deep *interlobar*

*incisions* (*incisurae interlobares*) that divide the organ into three lobes. Between these incisions is a much shallower cleft, the *umbilical fissure*, in which the remains of the umbilical vein may be found.

*Lobes of the liver* (*lobi hepatis*).—The three lobes into which the liver is divided are known as *central*, *right lateral* and *left lateral*. The central lobe is the smallest. The left lateral lobe is next in point of size and is simple in form. The right lateral lobe, while possessed of the greatest bulk, is also distinguished by the presence of a *caudate process* (*processus caudatus*) on its visceral surface. The process is three-sided and tapering. Its base springs from the main mass of the right lateral lobe dorsal to and immediately to the right of the porta. The pointed apex of the process is directed horizontally towards the right, and generally reaches the border of the liver as a whole.

In a typical mammalian liver, such as that of the dog, a second or *omental process* projects towards the left from that part of the right lateral lobe that is dorsal to the porta. The horse differs from the rest of the domestic mammals in that the omental process is absent.

Having recognised the subdivisions of the liver, the dissector should endeavour to distinguish certain special impressions on the visceral surface. This will be easy if the organ has been properly hardened *in situ*.

The best marked concavity has already been mentioned in connection with the dorsal border of the gland. It is caused by the right kidney (*impressio renalis*), and is bounded by the caudate process and the most dorsal part of the right lateral lobe. The dorsal part of the left lateral and central lobes carries a depression (*impressio gastrica*) produced by the stomach. The exact extent of the concavity naturally varies in accordance with the amount of gastric distension. A well-marked curved groove crosses the right lateral lobe from the region of the porta to the margin of the liver. This lodges the duodenum, and hence is known as the duodenal impression (*impressio duodenalis*). Ventral to the gastric and duodenal impressions is a transversely elongated depression (*impressio colica*) produced by the dorsal diaphragmatic flexure and right dorsal part of the colon. Immediately ventral to the termination of the groove for the duodenum is an ill-marked cæcal impression (*impressio cæcalis*) associated with the dorsal sac of the cæcum.

*Ligaments of the liver*.—Inasmuch as the ligaments that hold the liver in position are parts of the peritoneum, it follows that they are all continuous with each other and not independent structures. To appreciate this it is only necessary to follow the various peritoneal lines of attachment. This is perhaps best done by beginning with the

*falciform*<sup>1</sup> *ligament* (ligamentum falciforme hepatis), a narrow, sickle-shaped band, with a free dorsal edge, that begins on the ventral wall of the abdomen near the umbilicus. From this point it may be followed forwards from the abdominal wall on to the diaphragm, gradually increasing in width, until it reaches the liver where its free border disappears into the umbilical fissure. The free edge of the ligament contains a feeble fibrous cord, the shrivelled remains of the umbilical vein, generally known as the *round ligament* (ligamentum teres hepatis). If the falciform ligament be traced up the diaphragmatic surface of the liver, it will be found that the two layers of peritoneum that compose it separate when the caudal vena cava is reached. The layers diverge to right and left to become the right and left laminae of the *coronary*<sup>2</sup> *ligament* (ligamentum coronarium hepatis), which forms a connection between the liver, in the neighbourhood of the vena cava, and the immediately adjoining part of the diaphragm. An offshoot from the coronary ligament crosses the edge of the liver at the œsophageal notch and becomes continuous with the lesser omentum.

Laterally the coronary ligament is continuous with the right and left triangular ligaments. The *right triangular ligament* (ligamentum triangulare dextrum) is a strong and very definite fold of peritoneum connecting the edge of the right lateral lobe to the dorsal costal part of the right half of the diaphragm. The *left triangular ligament* (ligamentum triangulare sinistrum) in like manner attaches the left lateral lobe to the tendinous part of the left half of the diaphragm. An offshoot from the right triangular ligament connects the caudal dorsal border of the caudate process to the right kidney and the cæcum, and is distinguished as the *hepato-renal ligament* (ligamentum hepato-renale).

The peritoneal connections of the liver with the stomach and the duodenum have already been studied (pages 115 and 117).

*Bile duct* (Ductus choledochus<sup>3</sup>).—The absence of a gall-bladder in the horse makes for greater simplicity in the arrangement of the ducts whereby bile is conveyed from the liver to the intestine. The bile duct is formed in the region of the porta by the union of two hepatic ducts—one, the larger, from the left lateral and central lobes; the other from the right lateral lobe. The single vessel so formed is about 5 cm. in length, and passes towards the right, between the two layers of the hepato-duodenal ligament, to open into the duodenum, in common with the pancreatic duct, about 13 to 15 cm. from the pylorus. The

<sup>1</sup> *Falx* [L.], a sickle; *forma* [L.], form.

<sup>2</sup> *Corona* [L.], a crown; *coronarius* [L.], encircling after the manner of a crown.

<sup>3</sup> *χολή* (cholē) [Gr.], bile; *δέχεσθαι* (dechesthai) [Gr.], to receive.

termination of the duct will be examined along with the interior of the duodenum.

What is here described as ductus choledochus is strictly speaking equivalent to the ductus hepaticus and ductus choledochus of those animals in which a gall-bladder is present. The ductus choledochus in such animals is formed by the union of the hepatic duct and the cystic duct (from the gall-bladder).

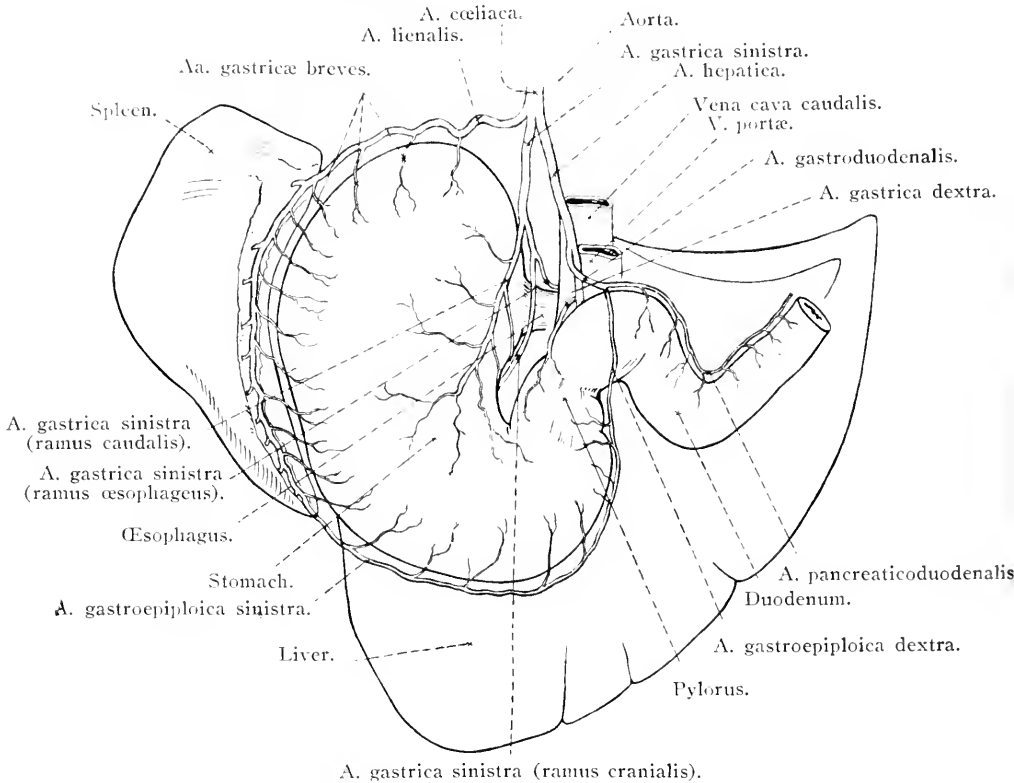


FIG. 57.—Diagram of the branches of the celiac artery.

*Dissection.*—There should be little difficulty in finding the celiac artery dorsal to the pancreas, but the process is made simpler by following one of its branches, the splenic artery (running along the hilus of the spleen), towards the aorta. In cleaning the branches of the celiac artery it will be found that they are surrounded by a network of nerves. These should be preserved and their ganglionic connections determined. The two oesophageal nerve trunks, ventral and dorsal, should be secured as they pass through the diaphragm in company with the oesophagus. Various groups of lymph glands must also be preserved.

**A. CEILICA.**—The liver, spleen, pancreas, stomach and part of the duodenum are supplied with blood by the celiac<sup>1</sup> artery, which leaves

<sup>1</sup> κοιλία (coilia) [Gr.], belly.

the ventral border of the aorta immediately this vessel has passed through the diaphragm. The cœliac artery is scarcely more than 1 cm. in length, and divides into three branches—the left gastric, splenic and hepatic.

(1) *A. gastrica sinistra*.—The left gastric artery is the middle one of the three vessels. It passes towards the cardia of the stomach, where it ends by dividing into cranial and caudal branches. In addition, it contributes an œsophageal branch and several twigs to the pancreas. (a) *Pancreatic branches* (rami pancreatici) supply the middle part of the gland. (b) The *œsophageal branch* (ramus œsophageus) is somewhat variable in its origin. Instead of arising from the main stem of the gastric, it may leave the caudal branch of this artery. In other cases it leaves the splenic artery. Whatever its origin, it follows the dorsal border of the œsophagus through the diaphragm into the thorax, where it anastomoses with the œsophageal artery. (c) The *cranial branch* (ramus cranialis) of the left gastric artery crosses the lesser curvature of the stomach to the right of the cardia, and is distributed over the cranial surface of the organ. (d) The *caudal branch* (ramus caudalis) passes to the right along the lesser curvature and ramifies on the caudal surface of the stomach. Twigs from both the cranial and the caudal branches establish numerous anastomoses with the right gastric and short gastric arteries.

(2) *A. lienalis*.—The splenic artery passes towards the left, across the saccus cæcus of the stomach, and so gains the base of the spleen. Running down the hilus to the apex of this organ, it becomes the left gastro-epiploic artery. Its branches are:—(a) *Pancreatic branches* (rami pancreatici) to the left extremity of the gland. (b) Numerous *splenic branches* (rami lienales) leave the splenic artery as it traverses the hilus, and immediately sink into the substance of the spleen. (c) From the opposite (concave) border of the splenic numerous *short gastric arteries* (aa. gastricae breves) arise and pass between the two layers of the gastro-splenic ligament to reach the greater curvature of the stomach. They anastomose with branches of the left gastric artery. (d) On passing beyond the apex of the spleen the splenic becomes the *left gastro-epiploic*<sup>1</sup> *artery* (a. gastrœpiploica sinistra). This runs from left to right between the two layers of the great omentum, supplies numerous omental branches and several short gastric arteries, and ends by anastomosing with the right gastro-epiploic artery.

(3) *A. hepatica*.—The hepatic artery pursues an oblique course to the right and ventralwards to reach the visceral surface of the liver, where it divides into proper hepatic and gastro-duodenal arteries. The

<sup>1</sup> ἐπιπλοῖον (epiploon) [Gr.], the caul of the entrails = omentum [L.].

following are its branches:—(a) Numerous *pancreatic arteries* (aa. pancreaticæ), (b) The *right gastric artery* (a. gastrica dextra) passes

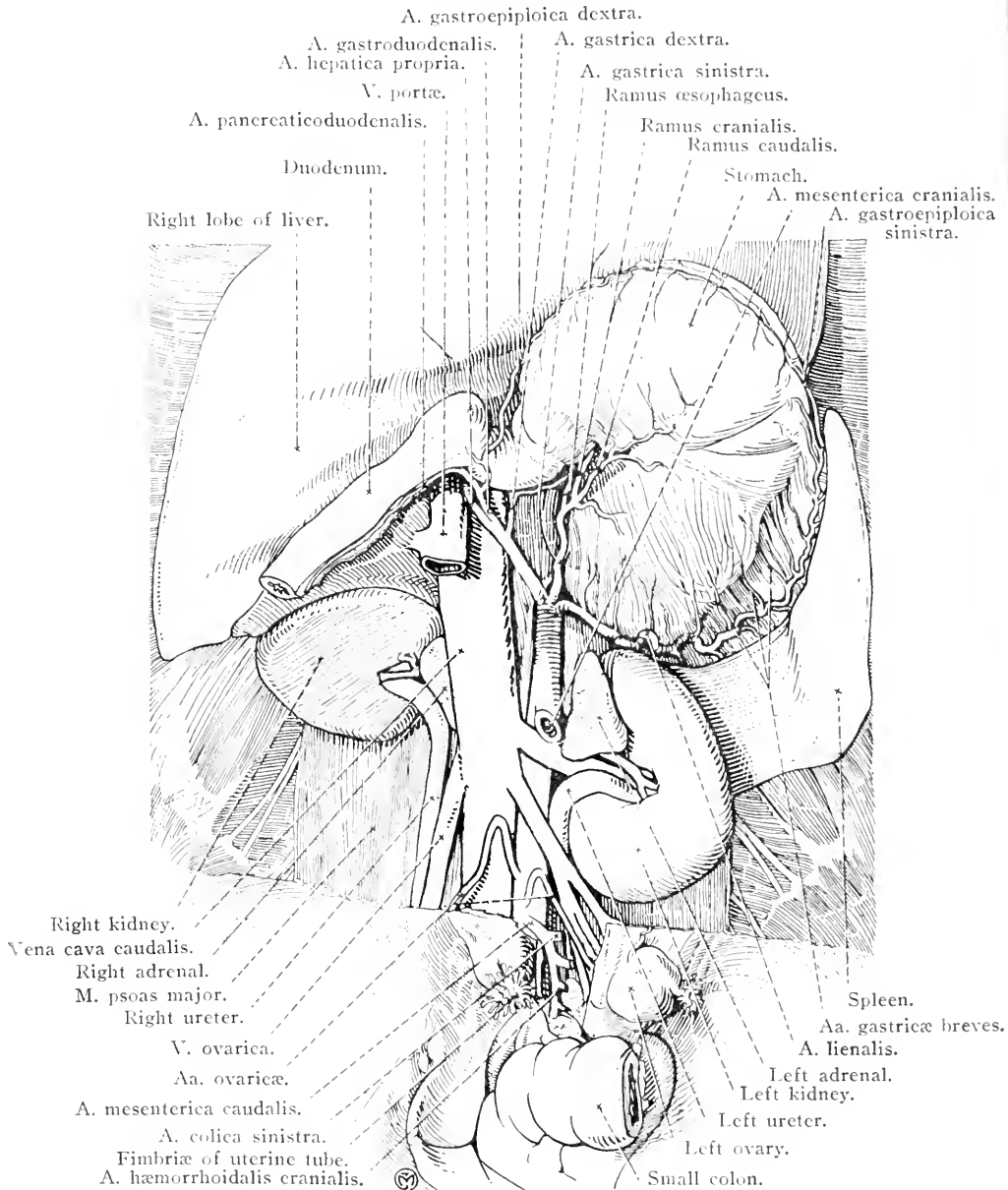


FIG. 58.—Dissection of female abdomen after removal of the intestines. In the lower part of the figure the peritoneum has not been removed.

under the pancreas in order to reach the pylorus. It divides into numerous branches, some of which follow the lesser curvature of the

stomach and anastomose with the left gastric artery. Others carry blood to the pylorus and the beginning of the duodenum, as well as to

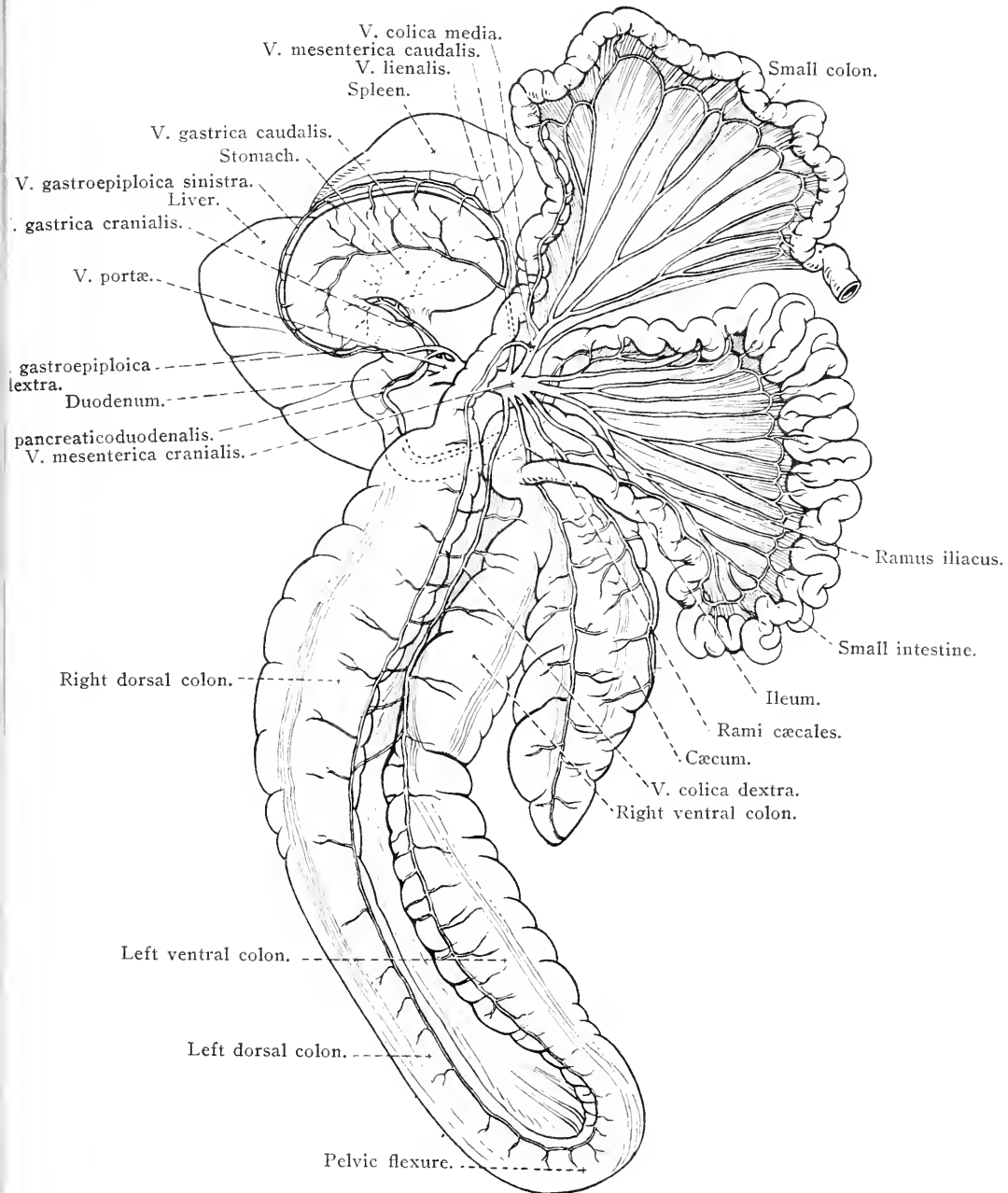


FIG. 59.—Diagram of the portal vein and its tributaries.

the right extremity of the stomach. (c) The *proper hepatic artery* (a. hepatica propria) gains the porta of the liver and there divides into

three main branches for the central and right and left lateral lobes. (d) The *gastro-duodenal artery* (a. gastroduodenalis) runs to the beginning of the duodenum, where it divides into the *right gastro-epiploic* and *pancreatico-duodenal arteries*. The first named (a. gastro-piploica dextra) gains the greater curvature of the stomach by passing between the pancreas and the stomach, and ends by anastomosing with the left gastro-epiploic artery derived from the splenic. The pancreatico-duodenal artery (a. pancreaticoduodenalis) soon divides into pancreatic and duodenal branches. The former (ramus pancreaticus) supplies the adjacent part of the pancreas. The duodenal branch (ramus duodenalis) follows the border of the mesoduodenum and ends by anastomosing with the first intestinal artery.

V. PORTÆ.—It is by way of the short but wide portal vein that the blood is removed from the intestines (except the rectum), the stomach, the pancreas and the spleen. Or, in other words, the drainage area of the portal vein is the same as the distribution area of the cœliac, cranial mesenteric and caudal mesenteric arteries, except that, instead of draining the liver, the portal vein carries blood to this gland.

The portal vein is formed close to the stem of the cranial mesenteric artery by the union of the cranial mesenteric, caudal mesenteric and splenic veins. The two last named vessels frequently unite into a short trunk before the cranial mesenteric joins them. Thus constituted, the portal vein pursues a short course immediately ventral to the caudal vena cava before it penetrates the portal ring of the pancreas. Once clear of the pancreas, the vein passes to the porta of the liver between the two layers of the gastro-hepatic ligament, and so, dividing into three main branches, enters the liver in company with the hepatic artery and the bile duct.

(1) *V. mesenterica cranialis*.—The cranial mesenteric vein is a fairly close companion of the artery of the same name. Its tributaries are:—Eighteen to twenty *intestinal veins*; the *ileo-cæcal vein*, corresponding to the ileo-cæco-colic artery, except that there is no tributary equivalent to the ventral colic artery; the *right colic vein*, beginning in branches in the wall of the left ventral and left dorsal colon and draining also the right ventral and right dorsal parts of this tube. The right colic vein is, therefore, mainly at any rate, equivalent to the dorsal and ventral colic arteries.

A small vessel assists in the drainage of the right dorsal colon, and is connected with the right colic vein on the one hand, and with either the caudal mesenteric or the middle colic vein on the other.

(2) *V. mesenterica caudalis*.—The caudal mesenteric vein is formed



by the union of the *left colic* and *cranial hæmorrhoidal* vessels, and receives the *middle colic vein* and possibly also the small vein that assists in draining the right dorsal colon.

(3) *V. lienalis*.—This should rather be called the gastro-splenic vein, since it helps materially to drain the wall of the stomach. Beginning as the *left gastro-epiploic vein*, it receives *short gastric* and *pancreatic* tributaries corresponding to branches of the splenic artery. Into it also flows the *caudal gastric vein*.

Into the stem of the portal vein formed as indicated above the following tributaries open:—(a) *Pancreatic branches*. (b) The *gastro-duodenal vein*, which begins as the *right gastro-epiploic* and receives the *pancreatico-duodenal*. (c) The *cranial gastric vein*, which drains the cranial surface of the stomach, opens into the portal vein (or possibly one of its three main divisions) at the porta of the liver.

Within the substance of the liver the portal vein behaves after the manner of an artery, inasmuch as it divides and re-divides until its smallest branches open into the sinusoids of the liver lobules.

The blood brought to the liver by the portal vein, as well as that brought by the hepatic artery, flows away by the *hepatic veins* (vv. hepaticæ), the openings of which into the caudal vena have already been noted in the examination of this large vessel as it lies in the fossa venæ cavæ on the diaphragmatic surface of the liver.

Lymph glands are associated with each of the three branches of the celiac artery. Gastric lymph glands (lymphoglandulæ gastricæ) are diffused and generally small. A group lies in the lesser curvature of the stomach; a small group is associated with the caudal gastric artery; a few lie on the saccus cæcus; two or three small glands are related to the ventral aspect of the pylorus; and a scattered chain of small glands follows the gastro-epiploic arteries. Hepatic lymph glands (lymphoglandulæ hepaticæ) are associated with the portal vein and hepatic artery in the neighbourhood of the porta of the liver. Splenic lymph glands (lymphoglandulæ lienales) lie along the hilus of the spleen in association with the splenic vessels.

TRUNCUS ŒSOPHAGEUS VENTRALIS.—Within the thorax each vagus nerve divides into a dorsal and a ventral branch. The two dorsal branches unite to form the dorsal œsophageal trunk; the two ventral branches in like manner form the ventral œsophageal trunk.

The ventral œsophageal trunk, the smaller of the two, follows the œsophagus through the diaphragm and divides into many small nerves that form a plexus (plexus gastricus) over the cranial surface of the stomach. The larger filaments of the plexus follow the lesser curvature

to the pylorus and the commencement of the duodenum and the pancreas. Some few filaments follow the bile duct to the liver and unite with the hepatic plexus.

TRUNCUS ŒSOPHAGEUS DORSALIS.—The dorsal œsophageal trunk receives the majority of its fibres from the right vagus nerve, and is distributed over the caudal surface and saccus cæcus of the stomach. Its filaments unite with those of the ventral trunk in the formation of the gastric plexus. A strong nerve joins the cœliaco-mesenteric ganglia and the cœliac plexus.

GANGLIA CŒLIACOMESENTERICA.—In the horse a large ganglion, on each side of the ventral border of the aorta between the origins of the cœliac and cranial mesenteric arteries, represents the combined cœliac and cranial mesenteric ganglia. The right ganglion is entirely covered on its ventral aspect by the vena cava; while the left ganglion is partly covered by the left adrenal. The right and left ganglia are connected with each other by a plexus of filaments that embraces the cranial mesenteric artery.

As has just been stated, the dorsal œsophageal trunk is connected with the ganglia, as are also the greater splanchnic nerves that, formed in the thorax, gain the abdomen by crossing the edge of the diaphragm ventral to the psoas minor muscle.

Radiating from the ganglia are the cœliac and cranial mesenteric plexuses, with which hepatic, gastric, splenic, aortic and renal plexuses are connected. The cœliac plexus forms an intricate feltwork of fibres with the cœliaco-mesenteric ganglia as a centre. Connected with it are filaments from the vagus and splanchnic nerves, and from some of the lumbar sympathetic ganglia. The hepatic, gastric, splenic, aortic and renal plexuses are associated with the like-named arteries. A spermatic plexus (or utero-ovarian plexus in the female), on each side of the body, is formed by fibres derived from the aortic plexus and the caudal mesenteric ganglion, and accompanies the spermatic (or utero-ovarian) artery to the testis (or ovary and uterine cornu).

GANGLION MESENTERICUM CAUDALE.—A relatively small unpaired caudal mesenteric ganglion will be found close to the origin of the caudal mesenteric artery. Two stout nerve cords connect this ganglion with the cœliaco-mesenteric ganglia. The caudal mesenteric plexus radiates from the like-named ganglion, and is connected with the left colic and cranial hæmorrhoidal plexuses which accompany the vessels of the same name. An *internal spermatic nerve* (n. spermaticus internus) leaves the caudal mesenteric ganglion and follows the internal spermatic

artery to the spermatic cord and testis of the male, or the ovary, uterine tube, and part of the uterus of the female.

*Dissection.*—The stomach, duodenum, spleen and liver must now be removed from the abdomen, and their structure studied as far as is possible with the naked eye.

STRUCTURE OF THE STOMACH.—In common with the other parts of the alimentary canal contained within the abdomen, the wall of the stomach is composed of four layers—(1) an external serous tunic derived from the peritoneum; (2) a muscular tunic; (3) submucous tissue; and (4) a mucous lining.

The serous tunic is closely applied to the muscular tunic over the greater part of the stomach. There is a very narrow strip uncovered by it along the greater curvature where the greater omentum and the gastro-splenic ligament are attached; and a wider area along the lesser curvature and in association with the attachment of the gastro-phrenic ligament. In the region of the lesser curvature the peritoneum is notably strengthened by elastic tissue.

The muscular tissue is disposed in three strata. When the serous investment of the stomach has been removed, longitudinal fibres, most numerous along the curvatures but very sparse elsewhere except at the antrum pylori, are exposed. There should be little difficulty in determining that these fibres are continuous with the longitudinal fibres of the œsophagus and duodenum. A stratum of circular fibres is not readily defined over the left half of the stomach, where it is replaced by oblique fibres, but can be distinguished easily over the right half of the organ, where its thickness increases as the pylorus is approached. At the pylorus itself the circular fibres are numerous and produce a double sphincter (*sphincter pylori*). The circular fibres of the stomach are to be looked upon as a continuation of the circular fibres of the œsophagus, and are clearly continuous with those of the duodenum.

The deepest fibres, oblique in direction, are best examined from within after the mucous membrane has been studied and removed. If possible the stomach should be turned outside in; but, if the preservative has rendered this impossible otherwise, it may be affected through a small opening made along the greater curvature.

The mucous membrane of the stomach of the horse is remarkable, in that it is divided into two parts, very different in character, which meet at an abrupt uneven line, the *margo plicatus*. This line corresponds to a shallow constriction that has already been noticed on the exterior. The membrane to the left of the line is pale, dense and skin-like in appearance. Indeed, it closely resembles the mucous lining of the

œsophagus, of which it may be regarded as an extension. Microscopically also it is like the œsophageal membrane, being without glands and covered with stratified and squamous epithelium. At the cardia the mucous membrane forms numerous folds that, with the abrupt and oblique manner in which the œsophagus enters the stomach, must render the return of food from the stomach to the œsophagus a matter of some difficulty. The lining to the right of the margo plicatus is soft and generally much folded. It can be divided into a darker portion to the left, the fundus region, and a somewhat paler pyloric part. These two regions differ in the structure of the glands contained within them. It is generally possible also to distinguish a narrow yellowish or greyish zone immediately adjoining the margo plicatus. This is the cardiac gland zone.

The mucous membrane should now be removed, the highly vascular submucous tela noted, and the deepest layer of muscle exposed. The deep muscular fibres are oblique in direction, and most plentiful about the cardiac orifice, where they form an elongated loop, sometimes called the *sphincter cardiacus*. The oblique fibres, like the circular, are continuous with the circular fibres of the œsophagus.

INTERIOR OF THE DUODENUM.—The wall of the duodenum has the same structure as that of the rest of the small intestine. The tube should be slit open by an incision made along a line midway between the two curvatures.

At a distance of from 13 to 15 cm. from the pylorus, the mucous membrane is considerably raised in the form of a tubular or saccular *diverticulum duodeni*, opening into the duodenum by a conspicuous orifice. If a probe be passed along the pancreatic and bile ducts towards the duodenum, it can be demonstrated that these end in the diverticulum, and that, consequently, the secretion they carry finds its way into the duodenum by a common exit from the diverticulum.

On the mucous membrane of the duodenal wall, opposite the diverticulum, is a much smaller papillary projection. On its summit is the opening of the accessory pancreatic duct.

STRUCTURE OF THE LIVER.—Some features of the structure of the liver may be determined without microscopic examination. If the surface of a slice of the gland be examined, the presence of polyhedral areas of various size will be recognised. These are sections of the hepatic lobules. In some animals, the pig for example, the lobules are clearly defined by a considerable quantity of interlobular connective tissue. The healthy liver of the horse, however, contains only a small

amount of interlobular tissue, with the result that the lobules are not very sharply bounded, and the liver tissue is comparatively friable. In certain pathological conditions, not uncommonly met with in old dissection-subjects, the interlobular septa are exaggerated.

Under the serous investment provided by the peritoneum, there is a thin fibrous capsule that may be traced into the interior of the organ at the porta. The various structures that enter or leave by the porta (portal vein, hepatic artery, bile-duct, &c.) are thus provided with a fibrous sheath that divides with the ramification of the vessels, &c. The sheath, as well as the capsule on the exterior, is continuous with the interlobular septa.

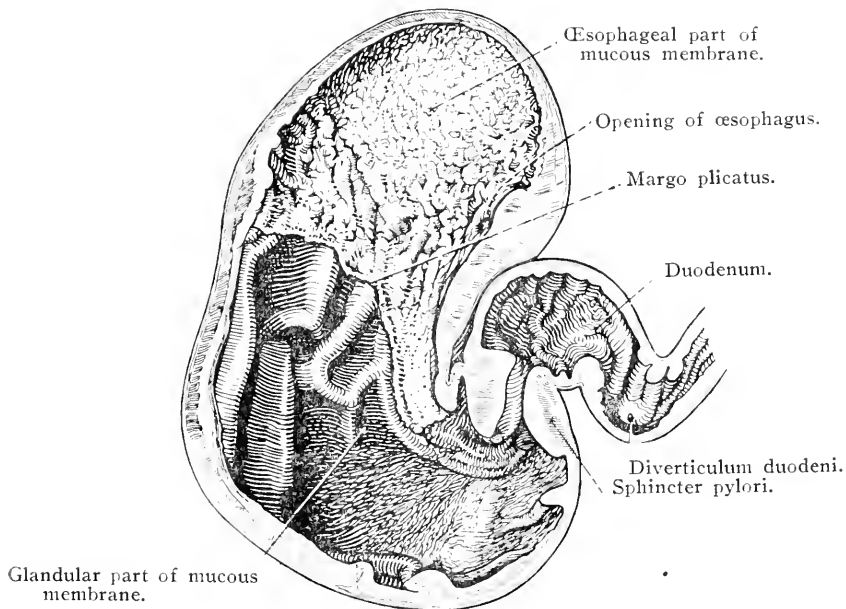


FIG. 60.—Longitudinal section of the stomach.

**STRUCTURE OF THE SPLEEN.**—Under the peritoneal covering of the spleen there is a fibrous tunic, from which irregular branching *trabeculae*<sup>1</sup> proceed into the interior, where, by the union of their branches, they produce the sponge-like framework of the organ. In the meshes of the sponge is the *splenic pulp*, composed very largely of blood, and therefore resembling a blood-clot. Certain small, pale, rounded areas in the pulp are the *splenic corpuscles* of Malpighi,<sup>2</sup> consisting of rounded masses of lymphoid tissue intimately associated with the wall of the smaller branches of the splenic artery.

*Dissection.*—If the subject is a female, those reproductive organs that are contained within the abdomen must now be examined.

<sup>1</sup> *Trabecula*, dim. of *trabs* [L.], a beam.

<sup>2</sup> Marcello Malpighi, an Italian anatomist, 1628-1694.

The female reproductive organs consist of two ovaries, each with a uterine tube, the uterus, the vagina, the uro-genital sinus or vestibule, and the vulva and external genitalia. Of these, the vagina, vestibule and vulva will be considered with the other contents of the pelvis.

THE UTERUS.—Part of the uterus is contained within the pelvis but by far the greater part of it is abdominal in position. The organ consists of a single portion, the *body* (corpus uteri), in the form of a short tube (18-20 cm. in length), approximately in the middle line of the cavity containing it, and two divergent *cornua*<sup>1</sup> (cornua uteri). The body of the uterus lies at the pelvic entrance, partly abdominal and partly pelvic in situation, to the left of the pelvic flexure of the colon, generally placed slightly oblique to the long axis of the abdomen so that its cranial end, or *fundus* (fundus uteri), inclines towards the left. The body is flattened dorso-ventrally, and consequently presents two surfaces and two borders. To the latter the broad ligaments are attached. The dorsal surface (facies dorsalis s. rectalis) is in contact with the rectum, and possibly also with coils of the small colon; while the ventral face (facies ventralis s. vesicalis) is related to the urinary bladder, and, when the bladder is empty, to parts of the intestines. The caudal end of the body is connected with the vagina, is known as the *neck* (cervix uteri), and is readily distinguishable from the rest of the body on palpation by its greater solidity. When the interior of the vagina is examined later, it will be observed that the neck of the uterus intrudes for a distance into the vaginal cavity as the *vaginal portion* of the uterus (portio vaginalis uteri).

The cornua of the uterus are divergent tubes from 20 to 25 cm. long, entirely abdominal in position, and mainly related to the convolutions of the small intestine and the small colon, but also in contact with the cæcum and the left colon. The left cornu generally lies to the left of the commencement of the left dorsal colon. Each cornu presents a convex ventral free border (margo liber), and a concave dorsal margin (margo mesometricus), to which the broad ligament is attached.

It will be noted that the uterine cornua are not closely fixed to the abdominal wall, but are permitted a considerable amount of freedom as a result of the width of the broad ligament.

Suspending the uterus are two broad duplicatures of peritoneum, the *broad ligaments* (ligamenta lata uteri), reflected from the dorsal wall of the abdomen and pelvis caudal to the level of the third or fourth lumbar vertebra. The line of attachment of the broad ligaments to the body wall is from 5 to 8 cm. from the median plane in the lumbar region,

<sup>1</sup> *Cornu* [L.], a horn.

but gradually approaches this plane as the pelvis is reached. The ligaments are broadest about the junction of the uterine cornua and body, narrowing from this point in both directions, but most markedly towards the caudal end. They contain a considerable amount of non-

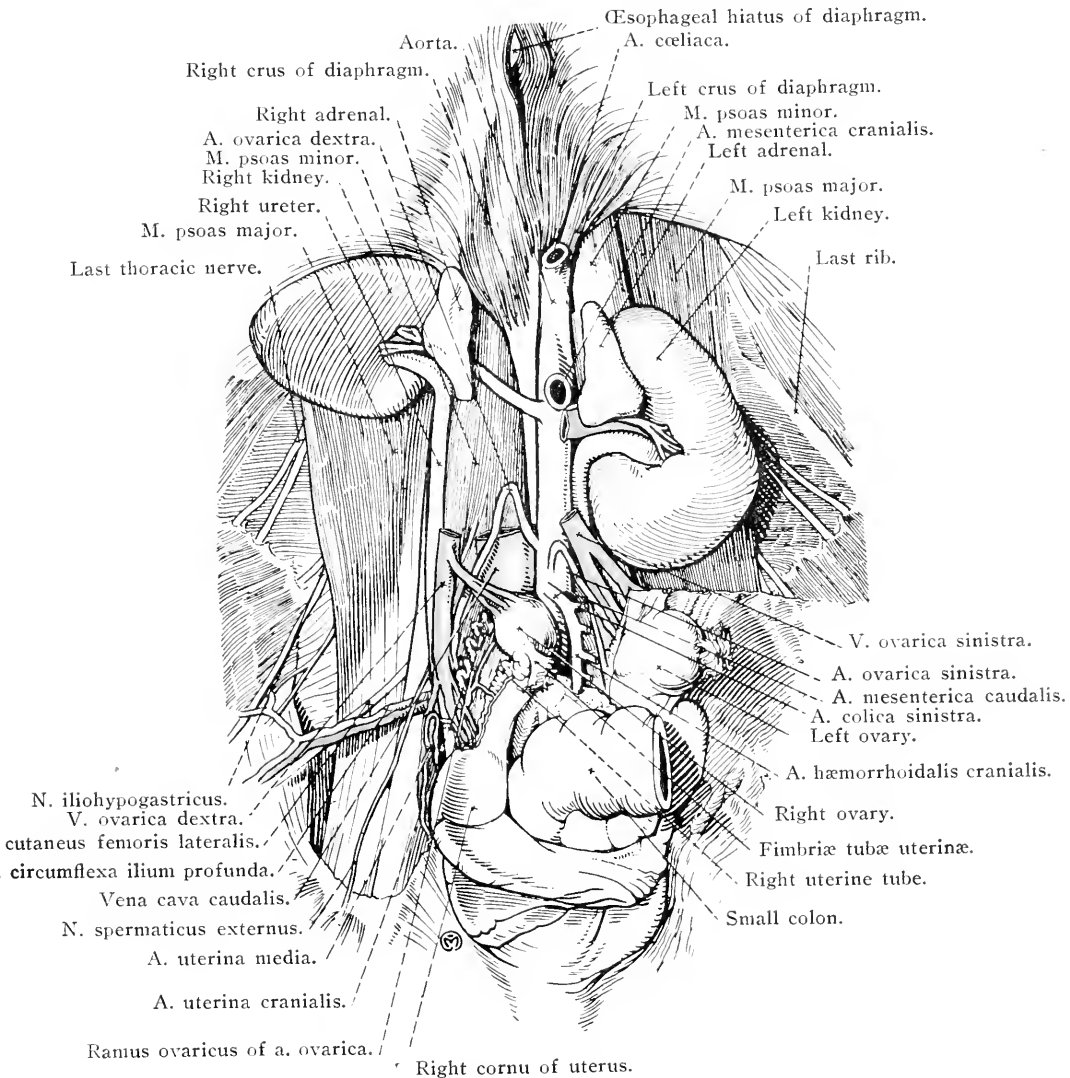


FIG. 61.—The abdominal urinary and reproductive organs of the female.

striated muscular tissue, continuous with the musculature of the uterus, and form a means whereby vessels and nerves reach the uterus, uterine tubes and ovaries.

The broad ligaments assist in bounding a peritoneal pouch, the *recto-uterine excavation* (*excavatio rectouterina*), containing the termination of the small colon and the commencement of the rectum.

On the lateral surface of each ligament is a long irregular fold known as the *round ligament of the uterus* (ligamentum teres uteri), which extends from near the level of the cranial end of the uterine cornu to the vicinity of the abdominal ring of the inguinal canal. The round ligament contains muscular tissue, and is the homologue of the gubernaculum testis of the male.

It is important to note that in its association the broad ligament is not confined to the uterus, but is also connected with the uterine tube and ovary. The terms *mesometrium*,<sup>1</sup> *mesosalpinx*,<sup>2</sup> and *mesovarium* are applied to the parts of the ligament connected with the uterus, uterine tube and ovary respectively.

The examination of the structure and interior of the uterus should be postponed until the interior of the vagina can be exposed at the same time. This will be done in connection with the examination of the pelvic viscera.

**THE OVARIES (Ovaria).**—Seeing that the ovaries are somewhat loosely suspended from the lumbar region of the abdominal cavity, their position is liable to some amount of variation, dependent upon the movement and degree of distension of the intestinal mass. Expressed in general terms, however, it may be said that they lie midway between the last rib and the coxal tuber of the ilium, at a distance of some 6 to 8 cm. from the median plane of the body. The size and weight of each organ is variable, but the average weight may be stated as about 75 grammes. They are largest in the young animal.

Each ovary is bean-shaped with a convex border (margo mesovarius), looking in a dorsal and cranial direction,<sup>3</sup> to which the mesovarium or *suspensory ligament* (ligamentum suspensorium ovarii) is attached. Nerves and blood vessels enter the ovary at the hilus, a narrow area on the dorsal border between the two layers of the suspensory ligament. A fold of peritoneum that can be traced to the last rib passes from the suspensory ligament in a lateral and slightly cranial direction. The opposite border, ventral and caudal in aspect is free (margo liber) and is characterised in the mare by the presence of a narrow depression, the *ovulation fossa*. It is worthy of remark that an ovulation fossa is peculiar to the mare among domestic animals in its

<sup>1</sup> μέσος (mesos) [Gr., middle; μέτρα (metra) [Gr., the uterus.

<sup>2</sup> μέσος (mesos) [Gr., middle; σάλπιγξ (salpinx) [Gr., tube.

<sup>3</sup> This applies to the organ when it hangs freely in an abdomen from which the other viscera have been removed. In the living animal the pressure of the intestinal mass deflects the ovary so that its borders may be medial and lateral in aspect, and its surfaces dorsal and ventral.



occurrence ; its production is post-natal in time. It is known that the ovary of the new-born agrees in confirmation with the usual mammalian type, and is ovoid in shape with both its borders convex. During the first year of extra-uterine life the extremities of the ovary bend towards each other, and thus the ovulation fossa is produced.

The two ends of the ovary are rounded and free. The cranial end (*extremitas tubaria*) is related to the fimbriated extremity of the uterine tube of Fallopius, while the ligament of the ovary connects the caudal

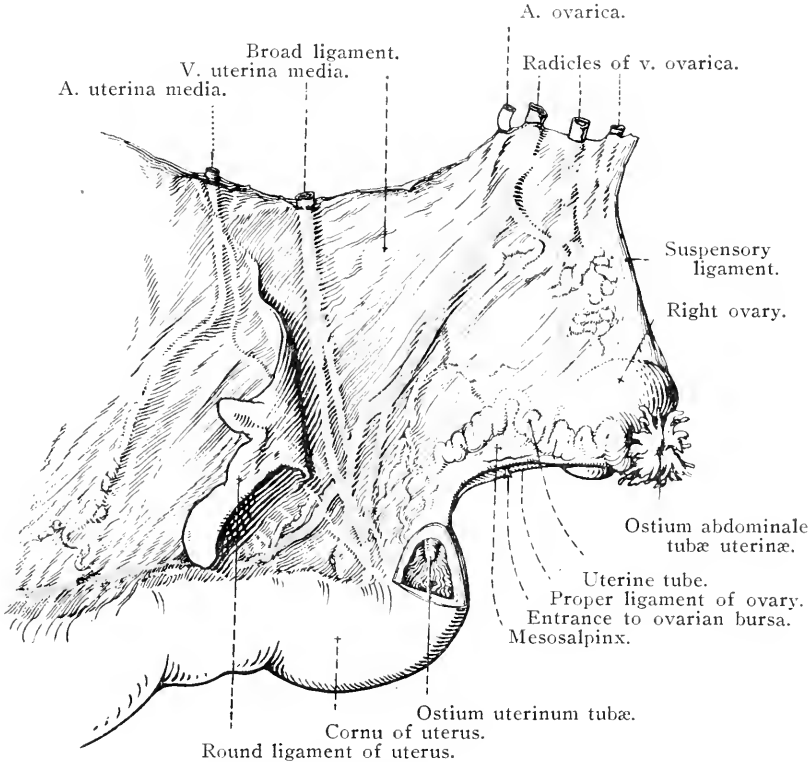


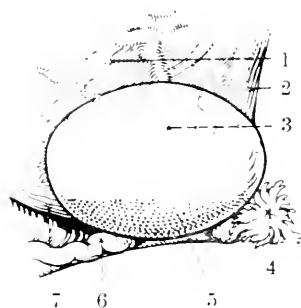
FIG. 62.—The right ovary, uterine tube, &c.

end (*extremitas uterina*) with the cornu of the uterus. The medial and lateral surfaces are convex, smooth and free.

The *suspensory ligament* or mesovarium is a double fold of peritoneum, about 10 cm. broad, with a free cranial border. In a caudal direction it is continuous with the mesometrium. Its dorsal edge splits to become continuous with the peritoneum covering the lumbar muscles.

The *proper ligament of the ovary* (*ligamentum ovarii proprium*) is a strong peritoneal band containing muscle and connecting the ovary, caudal to the ovulation fossa, with the extremity of the uterine cornu.

If a section be made through the ovary of a young animal numerous vesicular cavities, the *Graafian*<sup>1</sup> follicles (folliculi oophori vesiculosi), varying in size and containing fluid (liquor folliculi), will be found scattered throughout the stroma of the organ. The largest, and most mature,



1 = Mesovarium.

2 = Suspensory ligament.

3 = Area of ovary covered by peritoneum.

4 = Ostium abdominale tubæ.

5 = Area of ovary covered by germinal epithelium.

6 = Uterine tube.

7 = Ligamentum ovarii proprium.

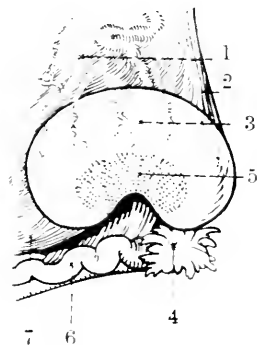
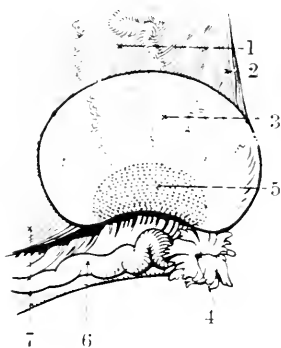


FIG. 63.—Diagrams to illustrate the development of the ovulation fossa.

follicles are close to the surface from which they not infrequently project slightly. Pathological cysts, commonly present in the ovaries of old mares, must not be mistaken for Graafian follicles. When a follicle ruptures to permit the escape of the contained ovum, its cavity becomes

<sup>1</sup> Reinhart de Graaf, a Dutch physician and anatomist, 1641-1673.

obliterated by the formation of a yellow body, the *corpus luteum*. The superficial part of the ovary of the mare is more vascular than the rest: in this respect there is a departure from the usual mammalian arrangement in which the most vascular part of the organ (*zona vasculosa*) is most deep seated, while the superficial stratum (*zona parenchymatosa*) contains the ovarian follicles.

THE UTERINE TUBE.—The uterine tube (of Fallopius) affords a means by which the ova pass from the ovary to the uterus, though there is no anatomical continuity between the tube and the gonad. Each tube is from 25 to 30 cm. long and pursues a very wavy course, especially in that part of it that is in the neighbourhood of the ovary. The first part of the tube, the *ampulla*,<sup>1</sup> is relatively wide, but the diameter diminishes in that portion, the *isthmus*, which approaches the uterus. Here, too, the tube becomes straighter. The cranial or ovarian end possesses an *ostium*<sup>2</sup> *abdominale tubæ* that is in direct communication with the peritoneal cavity. The peritoneal cavity of the female, therefore, differs from serous cavities in general, inasmuch as it communicates (indirectly) with the exterior. The margin of the abdominal ostium is fringed with irregular processes, the *fimbriæ*<sup>3</sup> *tubæ*, a few of which, the *ovarian fimbriæ* (*fimbriæ ovaricæ*), are attached to the cranial lip of the ovulation fossa of the ovary. That portion of the tube formed by the fimbriæ is generally designated the *infundibulum*,<sup>4</sup> from its shape.

The uterine end of the tube (*pars uterina tubæ*) projects into the cavity of the cornu as a small, firm papilla, on the summit of which is the small *uterine ostium* (*ostium uterinum tubæ*).

The uterine tube is included within a double peritoneal fold, the *mesosalpinx*, connected with the lateral face of the broad ligament. The mesosalpinx and the proper ligament of the ovary bound a long slit-like opening, ventral in aspect, which leads into the *ovarian bursa* (*bursa ovarii*), into which the lateral surface of the ovary projects.

In young animals a blind, coiled tube, the *paroophoron*,<sup>5</sup> may generally be found in the mesosalpinx between the free border of the ovary and the uterine tube. This is the remains of the embryonic mesonephros.

If the dissection-subject is a male, the distribution of the con-

<sup>1</sup> *Ampulla* [L.], a globular vessel, a flask.

<sup>2</sup> *Ostium*, dim. of *os* [L.], a mouth or orifice, any kind of entrance or exit.

<sup>3</sup> *Fimbriæ* (pl. only) [L.], a border, edge, or fringe.

<sup>4</sup> *Infundibulum* [L.], a funnel.

<sup>5</sup> *πάρα* (*para*) [Gr.], near, about: *ωοφόρος* (*oophoros*) [Gr. *ὠόν* (*oon*), egg + *φέρειν* (*pherein*), to bear], the ovary.

stituents of the spermatic cord from the abdominal ring of the inguinal canal should be noted. The ductus deferens, enclosed in a fold of peritoneum of increasing width, at once turns into the pelvis, where it will be found crossing the dorsal surface of the urinary bladder obliquely as it approaches the median plane of the body. The internal spermatic vessels, enclosed in a small and variable peritoneal fold, proceed towards the vertebral column.

**THE KIDNEYS (Renes).—**The kidneys are placed against the dorsal wall of the abdomen and are embedded in loose areolar tissue generally containing a considerable quantity of fat. In cleaning away the fat, care must be taken not to injure the ureters and the adrenal glands.

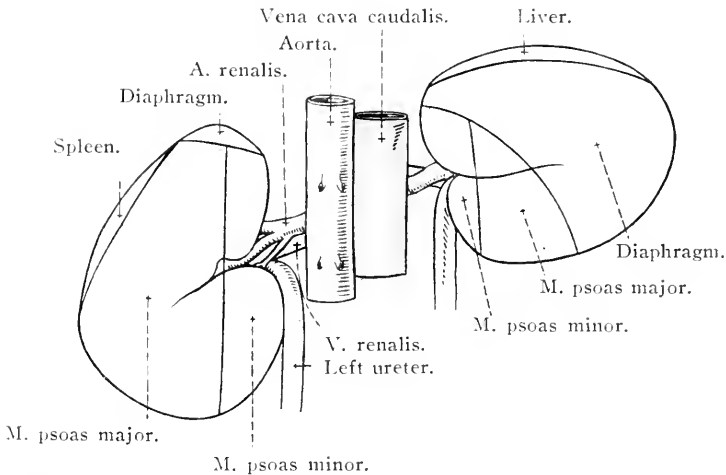


FIG. 64.—Outline of the dorsal surface of the kidneys, to show the relative position, shape and relations of the two organs.

The two kidneys differ in position, size, form and relations. The right kidney is more cranial than the left, and, in terms of the skeleton, extends from the level of the transverse process of the first lumbar vertebra to the interspace between the sixteenth and fifteenth ribs. The cranial end of the left kidney lies under the eighteenth rib (or sometimes the seventeenth interspace), while its caudal end reaches the level of the transverse process of the third lumbar vertebra.

The right kidney (about 700 grammes in weight) is generally larger than the left (about 680 grammes).

The difference in the shape of the two organs is sometimes very striking. The right kidney is broader than it is long, and has an outline that may be likened to that of the heart on a playing-card. The left kidney, on the other hand, is shaped like an elongated bean, and is longer than it is broad. Though this may be regarded as the

typical shape of the kidneys, there are often deviations from the type. With no great infrequency the right gland may be nearly or quite as elongated as the left, and the left may sometimes have a form simulating that of the right.

The dorsal surface (*facies dorsalis*) of the right kidney is convex and in contact with the diaphragm and the psoas muscles in about equal proportion. The corresponding surface of the left kidney has only a small area of contact with the diaphragm, most of it being related to the psoas muscles. Consequently, the surface is crossed longitudinally by a low ridge, produced by the shallow groove between the major and minor psoas muscles, separating two gentle slopes caused by contact with these muscles.

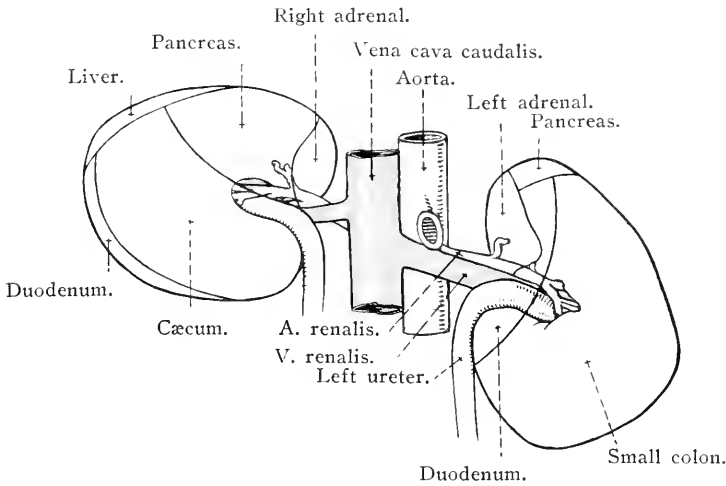


FIG. 65.—Outline of the ventral surface of the kidneys, to show the relative position, shape and relations of the two organs.

The ventral surface (*facies ventralis*) may be convex in both organs, but most frequently that of the right kidney is flattened or even slightly hollowed. The relations of the surface are naturally different in the two organs. The right kidney is in contact with the liver, pancreas, dorsal sac of the cæcum, and possibly also the duodenum; and is covered by peritoneum along a narrow lateral area only. Nearly the whole of the ventral surface of the left kidney has a peritoneal covering, and it is related to some of the coils of the small intestine and small colon, and (possibly) the left end of the pancreas.

The rounded cranial end (*extremitas cranialis*) of the right kidney is received into the *impressio renalis* of the liver; while the corresponding end of the left gland is generally in contact with the tail of the pancreas, but may touch the stomach if this organ is distended.

The flattened caudal end (*extremitas caudalis*) of the right kidney

is in contact with the second flexure of the duodenum and the dorsal sac of the cæcum. The caudal end of the left kidney—broader and blunter than the cranial extremity—is related to various coils of the intestinal mass.

The medial border (*margo medialis*) of both glands is indented by the hilus. This border of the right kidney is related to the caudal vena cava, the right adrenal gland and the right ureter. The left kidney is medially related to the abdominal aorta, the left adrenal and the left ureter.

The lateral border (*margo lateralis*) of both kidneys is divisible into two parts, meeting at an angle that, because of the triangular conformation of the organ as a whole, is much more distinct and acute in the right gland. The lateral border of the right kidney is followed by the duodenum; while the corresponding border of the left gland is in contact with the spleen and the small colon.

The *renal hilus*<sup>1</sup> (*hilus renalis*) is a sharp indentation on the medial border of the kidney and affords entrance and exit for blood vessels, nerves, lymphatics and the ureter. Of the three main structures connected therewith the renal artery is the most ventral, the renal vein most dorsal, and the ureter intermediate in position. It should be noted that, though branches of the renal artery enter at the hilus, others pierce the capsule of the gland at various points on the ventral surface.

If the lips bounding the hilus be separated, a cavity of some extent and depth, the *renal sinus*<sup>2</sup> (*sinus renalis*), will be disclosed. The most important object contained within the sinus is the funnel-like commencement of the ureter.

*Interior of the kidney.*—The surface of the kidney is covered by a strong fibrous capsule that can readily be stripped off except where it is continuous with the sheaths of the various structures entering the organ at or in the neighbourhood of the hilus.

A horizontal section of the kidney should be made by entering the knife at the lateral border and carrying it to the hilus. When this has been done, the cut surface will reveal the presence of two distinct portions of kidney tissue. The cortical substance, which is towards the exterior, is reddish-brown in colour and granular in texture; whereas the medullary substance is pale and striated. In the dark boundary zone between the two substances the cut ends of numerous large vessels should be noted. These indicate the former limits of the primitive lobes, readily recognisable in the fetal organ, of which the kidney is composed.

<sup>1</sup> *Hilum* (whence *nihilum* and *nihil*, nothing) [L.], a small part, a trifle.

<sup>2</sup> *Sinus* [L.], a bay, hollow, cavity.

The innermost zone of the medullary substance is often the palest part of the section, and forms a curved ridge, the *common renal papilla*<sup>1</sup> (*papilla renalis communis*), running longitudinally to the long axis of the kidney and projecting into a cavity known as the *renal pelvis* (*pelvis renalis*). In conformity with the shape of the kidney as a whole, the pelvis is elongated and crescentic, each horn of the crescent being abruptly curved to form a terminal recess (*recessus terminalis*). In the concavity of the crescent is the funnel-shaped portion of the pelvis (*recessus medius*), from which the ureter arises.

The *ureter*,<sup>2</sup> a tube about 7 or 8 mm. wide and some 65 to 70 cm. long, leaves the central part (middle recess) of the renal pelvis, passes through the renal sinus, and appears at the renal hilus. From the hilus the duct runs backwards between the *psoas minor* muscle and the peritoneum (in the subperitoneal tissue) and enters the pelvis to end by obliquely piercing the dorsal wall of the urinary bladder. It may, therefore, be divided into an abdominal part (*pars abdominalis*) and a pelvic part (*pars pelvina*). Before the pelvis is reached, the ureter crosses the ventral border of the deep circumflex iliac and external iliac arteries: the internal spermatic artery crosses the ventral border of the ureter. At the entrance to the pelvis, the ureter of the male crosses the dorsal surface of the ductus deferens, and from this point is associated with the *urogenital fold* (*plica urogenitalis*) of the peritoneum. In the female the greater part of the tube is enclosed in the dorsal edge of the broad ligament of the uterus.

The right and left ureters have the caudal vena cava and the aorta respectively on their medial aspect, though they do not as a rule touch these vessels.

The terminal part of the ureter runs for 3 or 4 cm. between the muscular tunic and the mucous lining of the bladder before opening into this sac. As will be determined when the interior of the urinary bladder is examined in a later dissection, the peculiar mode of termination of the ureter results in a valve-like closure of the tube against the backward passage of urine into it from the bladder, but normally no obstacle is offered to the flow of urine from the ureter into the bladder.

**ADRENAL GLANDS** (*Glandulæ suprarenales*).—The adrenals or suprarenal glands are two elongated, irregularly triangular bodies placed on

<sup>1</sup> In a typical mammalian kidney the organ is divisible into renal pyramids with bases directed towards the surface. The apices of the pyramids form papillæ that project into the renal pelvis. In the horse the pyramids are indistinct and their papillæ are fused together into a ridge or crest, the common renal papillæ.

<sup>2</sup> *Ureter* [L.], *ούρητήρ* (*oureter*) [Gr.], urinary canal.

the medial border of the kidneys, generally cranial to the hilus. The right gland lies along the lateral border of the caudal vena cava, the left having a similar relation to the aorta. The right gland is usually more prismatic in form than the left.

Section of the adrenals reveals a thin fibrous capsule on the exterior enclosing a parenchyma, in which two parts can be readily distinguished. A paler, reddish-brown cortical substance lies immediately underneath the capsule, and a darker, more vascular, and somewhat softer medullary substance occupies a considerable area in the centre of the gland. In the medullary substance it is not difficult to recognise venous spaces with the naked eye.

The adrenals belong to the group of structures known as the ductless glands, or, according to more modern nomenclature, endocrine organs; and their secretion is poured into the blood stream. A material known as adrenalin is elaborated by the cells composing the medullary substance.

The developmental history of the adrenals is of interest. The cortical substance is derived from the same cells as is the endothelium of the peritoneum. The medullary substance, on the other hand, is apparently developed from the neural crest of the embryonic spinal cord, which also gives origin to the ganglia on the dorsal roots of spinal nerves and the ganglia of the sympathetic nervous system.

*Renal lymph glands* (Lymphoglandulæ renales).—A small group of lymph glands can generally be demonstrated about the hilus of the kidney.

*Dissection.*—With great care remove the fat that lies dorsal to the kidneys and about the aorta as it passes through the diaphragm. The greater and lesser splanchnic nerves are to be sought as they bend round the dorsal border of the diaphragm lateral to the so-called crura of this muscle.

**N. SPLANCHNICUS MAJOR.**—The greater splanchnic<sup>1</sup> nerve arises from the sympathetic ganglia within the thorax from the sixth or seventh to the fourteenth or fifteenth inclusive, and enters the abdomen by curving round the dorsal border of the diaphragm (lumbo-costal arch) in relation to the lateral border of the psoas minor muscle. It ends by joining the cœliaco-mesenteric ganglion. Close to its termination a small *splanchnic ganglion* is occasionally developed on the nerve. From both the nerve and the ganglion small filaments pass to the œsophagus, aorta and vertebræ.

**N. SPLANCHNICUS MINOR.**—The lesser splanchnic nerve is formed

<sup>1</sup> σπλαγχνικός (splanchnicos) [Gr.], pertaining to the viscera.



by rootlets from the last two or three thoracic sympathetic ganglia. It enters the abdomen by crossing the lumbo-costal arch in company with the greater nerve, and ends by joining the nerve plexus about the hilus of the kidney.

**THE DIAPHRAGM** (*Diaphragmā*).—The diaphragm<sup>1</sup> forms a dome-shaped, muscular and tendinous partition between the cavities of the thorax and abdomen. Viewed from the abdominal side, it is concave in all directions, and largely covered by peritoneum. The thoracic surface is correspondingly convex, and is invested by the pleuræ. The partition, as a whole, has a marked slope in a ventral and cranial direction from the sixteenth or seventeenth thoracic vertebra to the base of the xiphoid process of the sternum. The vertex of the dome of the diaphragm occurs (during expiration) on a level with the seventh rib about the junction of the dorsal and middle thirds of the vertical diameter of the thoracic cavity.

The diaphragm may be described as consisting of a tendinous centre around which are grouped lumbar, costal and sternal muscular portions.

*Centrum tendineum*.—The tendinous centre is scarcely more than 2 mm. in thickness, and consequently the abdominal and thoracic viscera in contact with its two surfaces are very close to each other. In outline the tendinous centre resembles the conventional heart of playing-cards, with the truncated and indented base dorsal in position. The tendinous fibres forming the centre are chiefly radiate in disposition; but there are also interlacing fibres, especially noticeable about the opening for the caudal vena cava.

*Pars lumbalis*.—The lumbar part of the diaphragm consists of two strong muscular *crura* (*crura diaphragmatis*), of which the right is by far the larger and stronger. The right crus arises by a flattened tendon from the ventral longitudinal ligament on the bodies of the first four (possibly five) lumbar and the last thoracic vertebræ. The muscular fibres succeeding the tendon run in a ventral and cranial direction, in the middle line of the body, to end diverging in the tendinous centre. A slit-like opening, through which the œsophagus passes, separates the fibres into two unequal bundles.

The slenderer left crus is separated from the right by an opening occupied by the aorta. Its fleshy fibres continue a tendon that is attached to the ventral longitudinal ligament on the bodies of the first two lumbar vertebræ. They terminate in the tendinous centre after a course to the left of the median plane. Some of the fibres of the two *crura* intermingle ventral to the opening for the aorta.

<sup>1</sup> δία (*dia*) [Gr.], across; φράγμα (*phragma*) [Gr.], a wall. A partition wall.

*Pars costalis.*—The converging fibres that compose the costal part of the diaphragm arise by digitations from the last eleven ribs, the digitations being closely related to the costal attachment of the transverse abdominal muscle. The origin of the diaphragm from the eighth, ninth and tenth ribs is at the junction of the bone and the cartilage, and from the cartilage itself. The origin from the succeeding ribs is from the rib-bone at a gradually increasing distance from the cartilage, so that on the last rib the attachment is 10 cm. or more from the ventral end. From this it is evident that the diaphragm is not attached to the actual margin of the costal arch, but to a line within it. The costal fibres are lost at the edge of the tendinous centre.

Between the crura and the attachment of the *pars costalis* to the last rib there is an unattached border that crosses the ventral surface of the *psoas* muscles, and is known as the *lumbo-costal arch* (*arcus lumbo-costalis*). The thoracic and abdominal cavities are here separated only by the pleura and the peritoneum and a certain amount of loose connective tissue.

*Pars sternalis.*—The sternal part, directly continuous with the *pars costalis*, is small and consists of muscular fibres taking origin from the dorsal surface of the xiphoid process of the sternum.

*Openings in the diaphragm.*—There are numerous openings in the diaphragm, but most of them are of small size and of not more than minor importance. Three openings, however, are of moment—(1) the *aortic hiatus*<sup>1</sup> (*hiatus aorticus*) occurs between the two crura immediately ventral to the vertebral column. Through it pass the aorta, the vena azygos and the commencement of the thoracic duct. (2) The *œsophageal hiatus* (*hiatus œsophageus*) is a slit-like opening in the right crus close to its meroence into the tendinous centre. It transmits the œsophagus, the œsophageal nerve-trunks of the vagus and the œsophageal branch of the left gastric artery. (3) The *caval foramen*<sup>2</sup> (*foramen venæ cavae*) is a large opening in the tendinous centre a short distance to the right of the median plane, and about the junction of the dorsal and middle thirds of the vertical diameter of the thoracic cavity, that is, near the vertex of the diaphragmatic dome. Through it passes the caudal vena cava on its way from the abdomen to the heart. It will be observed that the large diaphragmatic veins open into the vena cava as it is passing through the foramen.

**AORTA ABDOMINALIS.**—The abdominal part of the aorta extends from the aortic hiatus of the diaphragm to the fifth lumbar vertebra,

<sup>1</sup> *Hiatus* [L.], a gap, opening, cleft.

<sup>2</sup> *Foramen* [L.], an opening, hole.

where it ends by dividing into four large vessels, the right and left hypogastric and the right and left external iliac arteries.

The aorta is not in the median plane, but inclines to the left except at its termination. Lying to the right of the vessel is at first the right crus of the diaphragm and then the caudal vena cava; and, on a level with the first lumbar vertebra, between the aorta and the right crus of the diaphragm, there is the thin-walled cisterna chyli, in which the thoracic duct has its origin, as well as the beginning of the vena azygos. The cisterna must be carefully preserved during the removal of the fibrous tissue and fat from around the aorta where it enters the abdomen. A number of lymph glands (lymphoglandulæ lumbales) will be observed arranged in an irregular chain along both sides of the aorta.

To the left of the aorta are the left adrenal gland, the left kidney and the left ureter; but the ureter is not usually in actual contact with the artery.

Dorsally the aorta is related to the bodies of the lumbar vertebra (ventral longitudinal ligament) and the left psoas minor muscle. Ventrally it is covered by a plexus of sympathetic nerves.

The branches of the abdominal aorta may be divided into two groups, according as they are paired or single, as follows:—

Paired.	Single.
Renal arteries.	Cœliac artery.
Internal spermatic arteries.	Cranial mesenteric artery.
Lumbar arteries.	Caudal mesenteric artery.
External iliac arteries.	Middle sacral artery.
Hypogastric arteries.	

The cœliac, cranial mesenteric and caudal mesenteric arteries have already been examined (pages 109 and 124).

AA. RENALES.—The renal arteries are short but large relative to the size of the organs to which they carry blood. They leave the aorta at a right angle about the level of the origin of the cranial mesenteric artery; but the origin of the right artery is nearly always slightly cranial to that of the left. The right artery, further, is longer than the left, and crosses somewhat obliquely the dorsal surface of the caudal vena cava. In the region of the hilus of the kidney each artery divides into a variable number of branches (six to eight), some of which enter the hilus, while the rest disappear into the ventral surface of the kidney.

Small branches are distributed to the adrenals, ureters, renal lymph glands and the adipose tissue about the kidney.

AA. SPERMATICÆ INTERNÆ.—Speaking generally, the internal spermatic arteries leave the aorta about the origin of the caudal mesenteric

artery, but variations are so frequent as to make impossible the enunciation of a strict rule. Within a fold of peritoneum which also contains

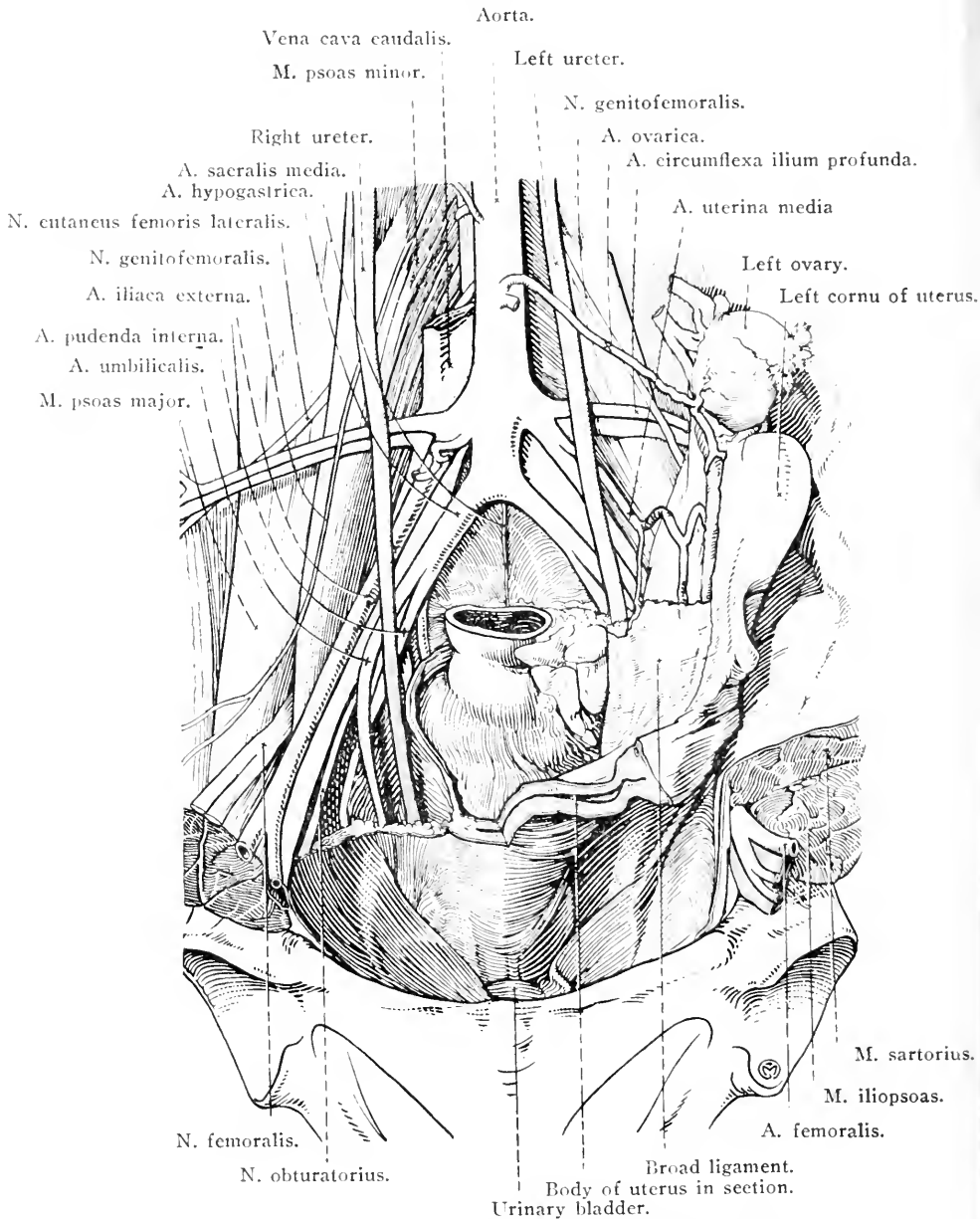


FIG. 66.—Dissection of the sublumbar region and entrance to the pelvis (female).

the corresponding vein, each small vessel follows an oblique course to the abdominal ring of the inguinal canal, which it enters to form one of the constituents of the spermatic cord.

The corresponding arteries of the female (aa. ovaricæ) are shorter and much larger, run between the two layers of the broad ligament, and divide into two branches. The tortuous *ramus ovaricus* terminates in the ovary. The *ramus uterinus* becomes the cranial uterine artery, inasmuch as it ramifies along the concave border of the uterine cornu.

AA. LUMBALES.—The lumbar arteries arise in pairs from the dorsal side of the aorta. In all there are six pairs, but the last arises from either the hypogastric or the lateral sacral artery and not directly from the aorta. Each artery disappears almost at once under the psoas muscles and therefore cannot be followed at present. Later it will be seen that the first lumbar artery passes between the transverse processes of the first and second lumbar vertebræ: the sixth passes between the sixth lumbar and the first sacral vertebræ.

A. ILIACA EXTERNA.—The external iliac artery leaves the abdominal aorta at the fifth lumbar vertebra. From its origin it pursues a curved course, close to the brim of the pelvis, under peritoneum and fascia, to the pecten of the pubis, where it enters the thigh as the femoral artery. Lateral and somewhat cranial to the artery are the psoas minor and ilio-psoas muscles; while lateral and caudal to it are the common iliac and external iliac veins.

The following are the branches of the external iliac artery:—

(1) *A. circumflexa ilium profunda*.—It is well to remember that, on one or both sides of the body, the deep circumflex iliac artery may arise directly from the aorta. Generally, however, it leaves the external iliac close to the origin of this vessel from the aorta. Whatever its source, the deep circumflex artery runs in a lateral direction at right angles to the long axis of the body between the peritoneum and the psoas minor and major muscles, accompanied by a vein on each side. At the lateral border of the psoas major it divides into two branches. The cranial branch has already been encountered between the internal oblique and transverse muscles of the abdominal wall. The caudal branch pierces the oblique abdominal muscles to appear underneath the *m. tensor fasciæ latæ* close to the coxal tuber of the ilium. Its subsequent course beneath this muscle is examined during the dissection of the pelvic limb.

(2) *A. spermatica externa*.—The external spermatic artery is a small vessel with a very variable origin. It may arise from the deep circumflex iliac artery or even from the hypogastric, instead of from the external iliac. In the male it follows the caudal border of the cremaster muscle down the inguinal canal, and terminates in the spermatic cord and vaginal tunic. In the female the vessel is larger and may be called

the *middle uterine artery* (a. uterina media), which gains the cornu and part of the body of the uterus by passing, in a tortuous fashion, between the two layers of the broad ligament. The middle uterine artery anastomoses with the uterine branch (cranial uterine artery) of the ovarian artery.

(3) *Truncus pudendae-epigastricus*.—The pudendo-epigastric trunk is generally described as arising just as the external iliac is about to become the femoral artery, but not infrequently its point of origin is distal to the pecten of the pubis, that is, distal to the level at which the external iliac artery is arbitrarily considered to end. The most common arrangement is for the trunk to leave the parent vessel along with the deep femoral; that is to say, a short, thick vessel forms a common artery of origin and divides into the deep femoral and pudendo-epigastric trunk. The trunk follows a very short course round the caudal border of the inguinal ligament (of Poupart) and ends under the peritoneum by dividing into the external pudendal and caudal epigastric arteries, both of which have already been dissected (pages 76 and 85).

Two groups of lymph glands should be recognised at the present stage of the dissection. The *medial iliac glands* (lymphoglandulae iliacae mediales) form a considerable group about the origin of the external iliac artery. The *lateral iliac glands* (lymphoglandulae iliacae laterales) are few and small, and occupy the angle of divergence of the two chief branches of the deep circumflex iliac artery.

VENA CAVA CAUDALIS.—This large vein begins, to the right of the median plane, at the fifth lumbar vertebra, where it is formed by the union of the right and left common iliac veins, which drain the limbs and the pelvis. The vessel runs forwards on the ventral surface of the psoas minor muscle and along the right side of the aorta for some distance, but ultimately the right crus of the diaphragm separates the vein from the artery. The last part of the abdominal course of the vena cava is between the liver and the diaphragm, where it occupies the fossa venae cavae of the former organ. Not infrequently liver-tissue completely encircles the vein as it lies in the fossa. Finally, the vein reaches the foramen venae cavae of the diaphragm by which it enters the thorax on its way to the right atrium of the heart.

The tributaries of the caudal vena cava are as follows:—(1) *Common iliac veins* (vv. iliacae communes); (2) *lumbar veins* (vv. lumbales), five in number; (3) *deep circumflex iliac veins* (vv. circumflexae ilium profundae); (4) *internal spermatic veins* (vv. spermaticae internae); (5) *renal veins* (vv. renales); (6) *hepatic veins* (vv. hepaticae); and (7) *phrenic veins* (vv. phrenicae).

With the exception of the two last named, all these veins are satellites of the corresponding arteries. The hepatic veins are numerous and of various sizes. They join the vena cava as it lies in the fossa provided for it by the liver. The phrenic veins are of great size, generally two but possibly three in number, and enter the vena cava as it is passing through the diaphragm.

V. ILIACA EXTERNA.—The external iliac vein differs from the homonymous artery in that it does not, as a rule, receive the deep circumflex iliac vein; and it does receive blood from the obturator vein.

V. ILIACA COMMUNIS.—This short, wide vein lies between the external iliac and hypogastric arteries, and is formed by the union of the external iliac and hypogastric veins. The sixth lumbar and the ilio-lumbar veins join it, as does also the deep circumflex iliac vein in those cases where it is not connected with the caudal vena cava itself.

CISTERNA CHYLI.<sup>1</sup>—This elongated, thin-walled cistern lies to the right of and slightly dorsal to the aorta, and between this vessel and the right crus of the diaphragm, at the level of the first and second lumbar vertebræ. Into the cistern open four or five large lymphatic trunks, along which flows the lymph collected from the pelvic limb, the pelvis, the abdominal wall and the abdominal viscera. Two *lumbar trunks* (trunci lumbales) carry lymph from the lumbar lymph glands, and two or three *intestinal trunks* (trunci intestinales) are formed by the efferents from the gastric, hepatic, splenic and mesenteric glands.

The thoracic duct (ductus thoracicus) leaves the cranial end of the cistern and enters the thorax by following the right border of the aorta.

V. AZYGOS.—The commencement of the vena azygos<sup>2</sup> must also be sought to the right of the aorta, not far from the hiatus aorticus of the diaphragm. The vein is formed by the union of the first lumbar vein of the right side and vessels bringing blood from the psoas and transverse abdominal muscles and the crura of the diaphragm. The azygos vein accompanies the thoracic duct into the thorax.

THE ILIAC FASCIA (fascia iliaca).—Preparatory to the dissection of the lumbar musculature, an examination must be made of the iliac fascia. This is a stout sheet interposed between the peritoneum and

<sup>1</sup> χυλός (chylos) [Gr.], juice.

<sup>2</sup> α (priv.) + ζυγός (zygos) [Gr.], a yoke. Unpaired.

the psoas major and iliacus muscles. Thickest and densest in the neighbourhood of the pelvic inlet, where it is continuous with the pelvic fascia, it becomes thinner towards the diaphragm. Medially it is attached to the lateral border of the psoas minor muscle. Other connections and attachments are to the inguinal ligament and the coxal tuber of the ilium. The iliac fascia affords origin to the sartorius and cremaster muscles and the transverse muscle of the abdominal wall.

*Dissection.*—The iliac fascia must be removed. In doing this, preserve the nerves and blood vessels related to it. The psoas minor and ilio-psoas muscles are now to be examined.

**M. PSOAS MINOR.**—The lesser psoas<sup>1</sup> muscle is elongated and flattened, and lies alongside the median plane. Its origin is from the bodies of the last three thoracic and the first four or five lumbar vertebrae, and from the vertebral end of the last two or three ribs. Some of its fibres arise from the tendinous origin of the diaphragmatic crura. It is inserted by a flattened tendon to the psoas tubercle of the ilium.

**M. ILIO-PSOAS.**—The powerful and fleshy ilio-psoas muscle lies lateral to, and partly covered by, the preceding. It is divisible into two parts—m. psoas major and m. iliacus—which quickly merge into a single structure inserted into the lesser trochanter of the femur.

*M. psoas major.*—The greater psoas begins as a broad, flat muscle that gradually becomes more compact and rounded. Its origin is from the internal surface of the last two ribs near their vertebral end, and from the transverse processes and bodies of the lumbar vertebrae. The terminal part of the muscle is received into a deep groove on the surface of the m. iliacus.

*M. iliacus.*—The iliac muscle is of triangular outline and of considerable extent. It covers the whole of the ventral surface of the ilium and projects for some distance beyond the lateral border of this bone. The origin of the iliacus is from the entire ventral surface of the ilium, the ventral sacro-iliac ligament, and the adjacent part of the sacrum.

*Dissection.*—Some of the lumbar spinal nerves should be examined at this stage of the dissection. Certain derivatives of these are visible without further dissection. From the lateral margin of the greater psoas muscle the ilio-hypogastric and ilio-inguinal nerves emerge; and between the psoas minor and psoas major the lateral cutaneous nerve of the thigh appears. A small nerve, the genito-femoral (external spermatic), pierces the psoas minor; and along the medial border of the same muscle the lumbar part of the gangliated cord of the sympathetic should be found.

<sup>1</sup> ψόα (psoa) [Gr.], the loins.



After the foregoing nerves have been recognised, they must be followed to their several origins. This can only be done by removing the psoas minor and major muscles piecemeal. This dissection reveals the quadratus lumborum muscle, and the lumbar arteries will also be open to examination.

M. QUADRATUS LUMBORUM.—The quadrate<sup>1</sup> muscle of the loins lies between the ventral surface of the lumbar transverse processes and the psoas major muscle. In the horse the muscle is much less developed than it is in the other domestic animals, and is further characterised by a large admixture of tendinous fibres.

Partly fleshy partly tendinous bundles arise from the internal surface of the vertebral extremities of the last two or three ribs and from the transverse processes of the lumbar vertebræ. After a short oblique (caudal and lateral) course, these bundles are attached to the transverse processes of the lumbar vertebræ succeeding those from which they arise, and to the ventral sacro-iliac ligament and the adjacent part of the sacrum.

NN. LUMBALIS.—The lumbar nerves, six in number, emerge from the vertebral canal by traversing intervertebral foramina. The first nerve emerges by the foramen between the first and second lumbar vertebræ; the sixth nerve leaves the vertebral canal between the sixth lumbar and the first sacral vertebra. The first two or three nerves are about equal in size and not larger than the last thoracic; but each of the last three lumbar nerves is larger than its predecessor.

Each lumbar nerve behaves as a typical spinal nerve in dividing into two rami—dorsal and ventral. The *dorsal ramus* (ramus dorsalis) is much the smaller of the two, and, passing between adjacent transverse processes, is distributed to the muscles and skin of the loins and gluteal region. The *ventral ramus* (ramus ventralis) sends a small white ramus communicans to a ganglion on the sympathetic nerve cord and receives a grey ramus communicans therefrom. The ventral ramus then passes in a lateral direction (generally oblique to the long axis of the body) on a plane ventral to the transverse processes of the vertebræ.

It is to the ventral rami of the lumbar nerves that attention is now to be directed.

N. ILIOHYPOGASTRICUS.—The ilio-hypogastric nerve, the ventral ramus of the first lumbar nerve, runs in a lateral direction between the psoas major and quadratus lumborum muscles. After its emergence

<sup>1</sup> *Quadratus* [L.], squared.

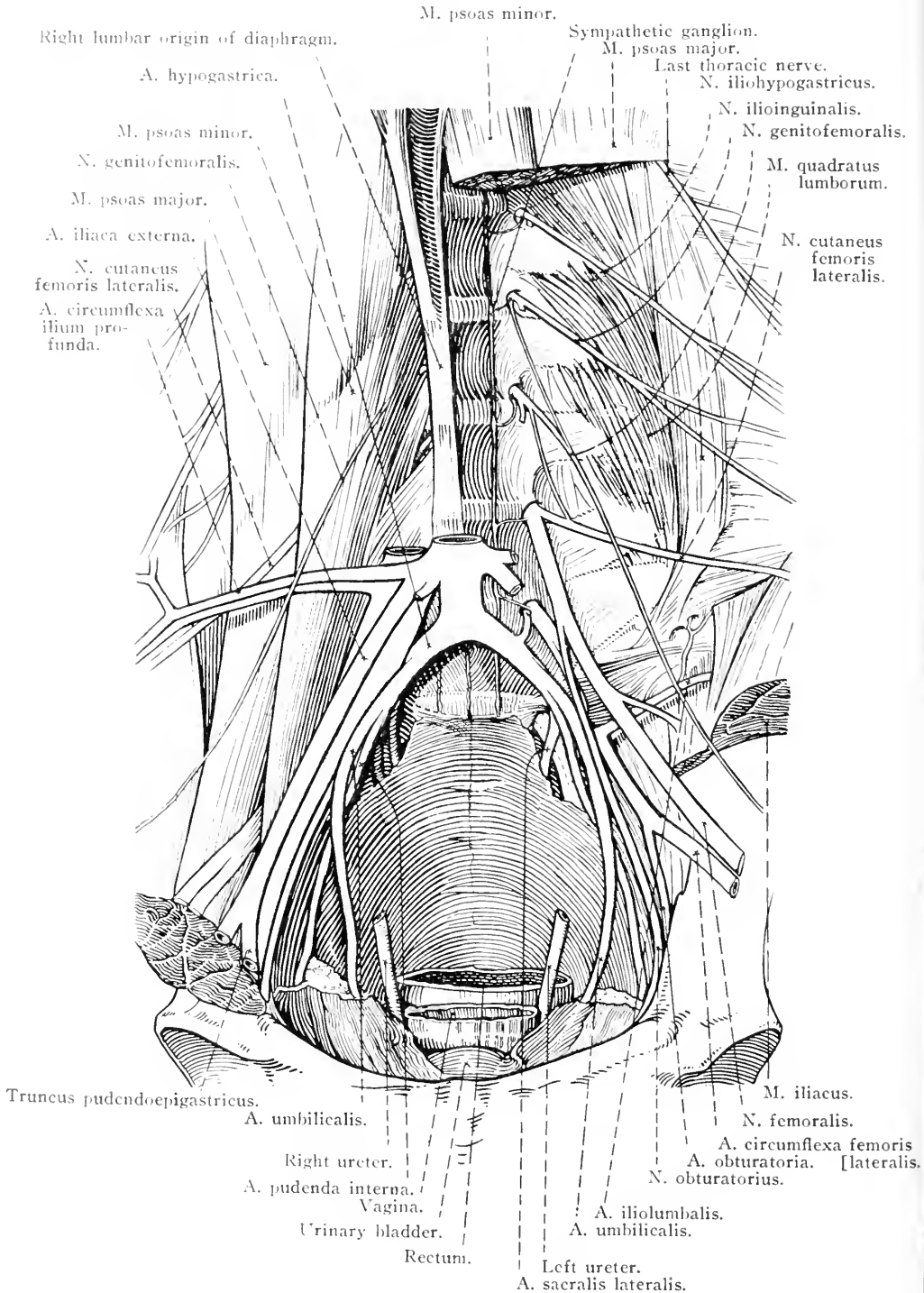


FIG. 67.—Dissection of the dorsal wall of the abdomen (female).

from beneath the lateral border of the former muscle, and as it lies on the transverse muscle of the abdomen, the nerve divides into two branches. The superficial branch (*ramus superficialis*) pierces the transverse muscle almost at once, and has already been found in the abdominal wall. The deep branch (*ramus profundus*) runs ventralwards and towards the pelvis between the peritoneum and the transverse muscle, giving branches to the internal oblique and straight muscles of the abdomen.

**N. ILIOINGUINALIS.**—The ilio-inguinal nerve is derived from the second lumbar nerve. Like the preceding, it lies at first between the *psaos major* and *quadratus lumborum*, and also like the ilio-hypogastric, divides into superficial and deep branches. The superficial branch pierces the abdominal wall a short distance in front of the coxal tuber, and is distributed over the front of the thigh and the lateral aspect of the patellar region. The deep branch has a course and distribution similar to the corresponding branch of the ilio-hypogastric nerve.

The possibility that the ilio-inguinal nerve may end in branches distributed in the *psaos major* muscle must be kept in mind.

**N. GENITOFEMORALIS.**—Though mainly formed by the ventral branch of the third lumbar, the genito-femoral nerve generally receives small contributions from the second and fourth nerves. After piercing the *psaos minor*, the nerve runs towards the pelvis between this muscle and the peritoneum, crosses the deep circumflex iliac vessels obliquely (caudal, lateral and ventral), and divides into two branches. One of these ends in the internal oblique and cremaster muscles. The other (*n. spermaticus externus*) descends the inguinal canal, medial to the constituents of the spermatic cord and in relation to the internal pudendal artery, and ends in the external genitalia and the skin of the inguinal region. This branch is not infrequently joined by one from the ilio-inguinal nerve.

**N. CUTANEUS FEMORIS LATERALIS.**—The lateral cutaneous nerve of the thigh arises by two roots from the third and fourth (often also the fifth) lumbar nerves. The first part of its course is between the *psaos minor* and *major* muscles. Appearing at the lateral margin of the former, it crosses the surface of the latter muscle, where it comes into relation with the deep circumflex iliac vessels, the caudal branch of which it follows. Thus the terminal part of the nerve pierces the abdominal wall close to the coxal tuber of the ilium to be distributed over the patellar region.

N. FEMORALIS.—The femoral nerve is much larger than any of the foregoing, and is formed by roots from the fourth and fifth (possibly also the sixth) lumbar nerves. The third nerve also commonly contributes a small root. The femoral nerve lies at first between the greater and lesser psoas muscles, and afterwards on the lateral surface of the tendon of the psoas minor. It enters the thigh under cover of the sartorius in company with the ilio-psoas muscle, and just before doing so, gives origin to the *saphenous nerve* (n. saphenus). A collateral branch is furnished to the ilio-psoas muscle. The distribution of the nerve to the quadriceps femoris muscle is examined during the dissection of the thigh.

N. SYMPATHICUS.—The gangliated cord of the sympathetic in the abdomen is a continuation of a similar cord in the thorax. Passing from the thoracic cavity between a crus (right or left) of the diaphragm and the psoas minor muscle, the cord ranges itself along the medial border of the latter, runs through the entire lumbar region, and is continued into the pelvis. Irregular spindle-shaped ganglia, six in number, occur at intervals along the cord, and are connected by rami communicantes with the lumbar nerves.

Filaments from the ganglia pass to the lumbar blood vessels, and larger nerves proceed to the coeliaco-mesenteric and caudal mesenteric ganglia and the plexuses that lie about the aorta (plexus aorticus abdominalis) and within the pelvis.

#### THE PELVIC CAVITY.

The pelvic cavity (cavum pelvis) is bounded by the sacrum, the first two coccygeal vertebrae<sup>1</sup> and the two hip bones. Cranially it communicates freely with the cavity of the abdomen proper by the *cranial pelvic aperture* or *pelvic inlet*, bounded by the terminal line or pelvic brim. The dorsal wall of the cavity is formed by the sacrum and two coccygeal vertebrae. The lateral walls are only partly bony, those parts of the ilia caudal to the ilio-pectineal lines alone being concerned in their formation. The rest of the wall on each side is formed by the extensive sheet consisting of the fused sacro-spinous and sacro-tuberous ligaments. Between the ilium and the sacro-spinous ligament there is a defect in the wall, the *greater sciatic*<sup>2</sup> *foramen*, containing loose connective tissue surrounding nerves and blood vessels; and another

<sup>1</sup> The definition of the caudal limit of the pelvic cavity is not very precise. Some writers include only one coccygeal vertebra in the boundary of the cavity; others consider that three should be included.

<sup>2</sup> *Sciaticus* [L.], *ἰσχιαδικός* (ischiadikos) [Gr.], pertaining to the ischium.

defect, the *lesser sciatic foramen*, occurs between the ischium and the sacro-tuberous ligament. The ventral wall is formed by the ilia and the ischia, and is entirely bony except at the obturator foramina. The *outlet* or *caudal pelvic aperture* may be described as triangular in form, with a blunt apex at the second coccygeal vertebra and a base formed by the sciatic arch of the ischia. The outlet of the pelvic

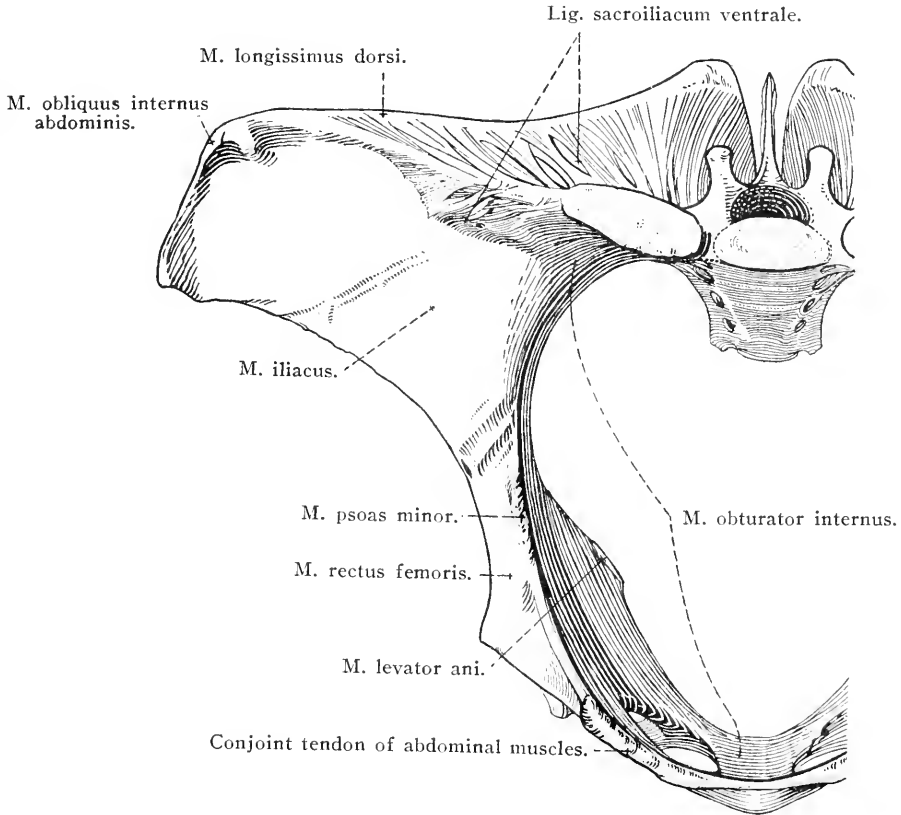


FIG. 68.—Cranial aspect of the hip-bone and sacrum, with areas of muscular attachment.

cavity, being smaller than the inlet, is of importance in obstetrics in that its lateral boundaries are ligamentous and not bony. The thin and not very definite caudal border of the sacro-tuberous ligament, to which is attached the semimembranous muscle, stretches from the second coccygeal vertebra to the sciatic tuber of the ischium.

The contents of the pelvic cavity differ with the sex, but it is convenient to suppose that the subject being dissected is a male. The contents of the female pelvis will be considered later.

The contents of the male pelvis may be tabulated as follows:—

Viscera.	{	Rectum.
		Urinary bladder.
		Prostate.
		Part of the urethra.
		Deferent ducts (terminal part).
{	Seminal vesicles.	
	Prostatic utricle.	
Blood vessels.	{	Hypogastric vessels and their branches.
		Middle sacral vessels.
Lymph glands and lymphatic vessels.		
Nerves.	{	Pudendal nerve.
		Obturator nerve.
		Sacral plexus and its branches.
		Pelvic part of the sympathetic nervous system.

Before any dissection is effected, it is well to examine, as far as

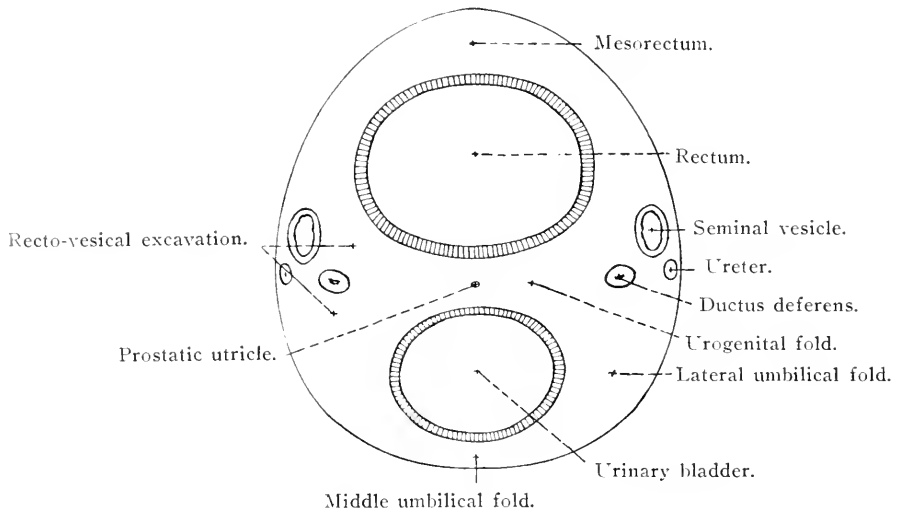


FIG. 69.—Diagram to illustrate the arrangement of the peritoneum in the male pelvis. Transverse section. The red line represents the peritoneum.

possible, the general disposition of the viscera and the arrangement of the peritoneum in the pelvis.

At the inlet to the cavity the urinary bladder and the termination of the small colon at its merrgence into the rectum will be encountered. The urinary bladder is pear-shaped with its narrow end directed towards the tail. When entirely empty it is small in size, firm to the touch, and so retracted into the pelvis that scarcely anything but the broad vertex is determinable until actual dissection is performed. When distended with urine it projects for a variable distance into the abdomen.

The arrangement of the peritoneum of the pelvis, as at present

determinable, should receive consideration. Beginning at the dorsal wall of the pelvis, little difficulty will be experienced in demonstrating a mesentery belonging to the first part of the rectum and continuous with the mesocolon. The two layers of the mesorectum separate on reaching the sacrum, and each layer sweeps down the lateral wall of the pelvis. Between the rectum and the urinary bladder the *urogenital fold* (plica urogenitalis) is produced by a horizontal duplicature of the peritoneum in which are contained the deferent ducts, the seminal vesicles and the unpaired prostatic utricle. The peritoneal pouch (excavatio rectovesicalis), between the rectum and the bladder, is thus incompletely subdivided by the fold. The seminal vesicles are partially covered by the dorsal layer of the urogenital fold.

The peritoneal covering of the urinary bladder is reflected from this organ in the form of three sheets. One of these, the *middle umbilical fold* (plica umbilicalis media) is ventral in position and triangular in outline, with a free cranial edge. The other two folds are lateral in position (*lateral umbilical folds*: plicæ umbilicales laterales) and also triangular in form, with an apex directed towards the neck of the bladder. The base of each is free and contains the rounded cord (ligamentum teres vesicæ) which is the remains of the umbilical<sup>1</sup> artery.

It will be noted that the peritoneal covering of the bladder is carried closer to the neck on the dorsal than on the ventral surface.

*Dissection.*—Clear the remains of muscles from one hip-bone. Liberate the root of the penis from the ischium of the same side. Make a saw-cut through the pubis and ischium on a level with the most medial part of the obturator foramen. Saw through the ilium on a level with the greater sciatic foramen. In making these sections, every care must be taken that the saw does not go deeper than is absolutely necessary. Now cut through the sacro-spinous and sacro-tuberous ligament close to its attachment to the hip-bone. This will isolate a piece of bone consisting of most of the pubis and ischium and part of the ilium. Remove this carefully, keeping the knife as close to the bone as possible. To do this it will be necessary to sever the origins of the levator ani and ischio-urethral muscles; but this is of little consequence, as these muscles will be intact on the opposite side of the pelvis.

Turn the sacro-spinous and sacro-tuberous ligament as far as possible towards the sacrum.

The next step in the dissection is to clean the lateral surface of the pelvic organs, preserving the vessels and nerves and observing the arrangement of the pelvic fascia and peritoneum.

M. COCCYGEUS.—The coccygeus<sup>2</sup> muscle consists of a broad

<sup>1</sup> *Umbilicus* [L.], the navel, a round pebble, the projecting end of the cylinders on which the books of the ancients were rolled.

<sup>2</sup> κόκκυξ (coccyx) [Gr.], cuckoo. The bony mass attached to the human sacrum, representing the tail or coccygeal vertebrae of mammals in general, is supposed to resemble the beak of the cuckoo.

flattened band of fibres arising from the medial surface of the sacro-spinous ligament close to the sciatic spine. Passing in a

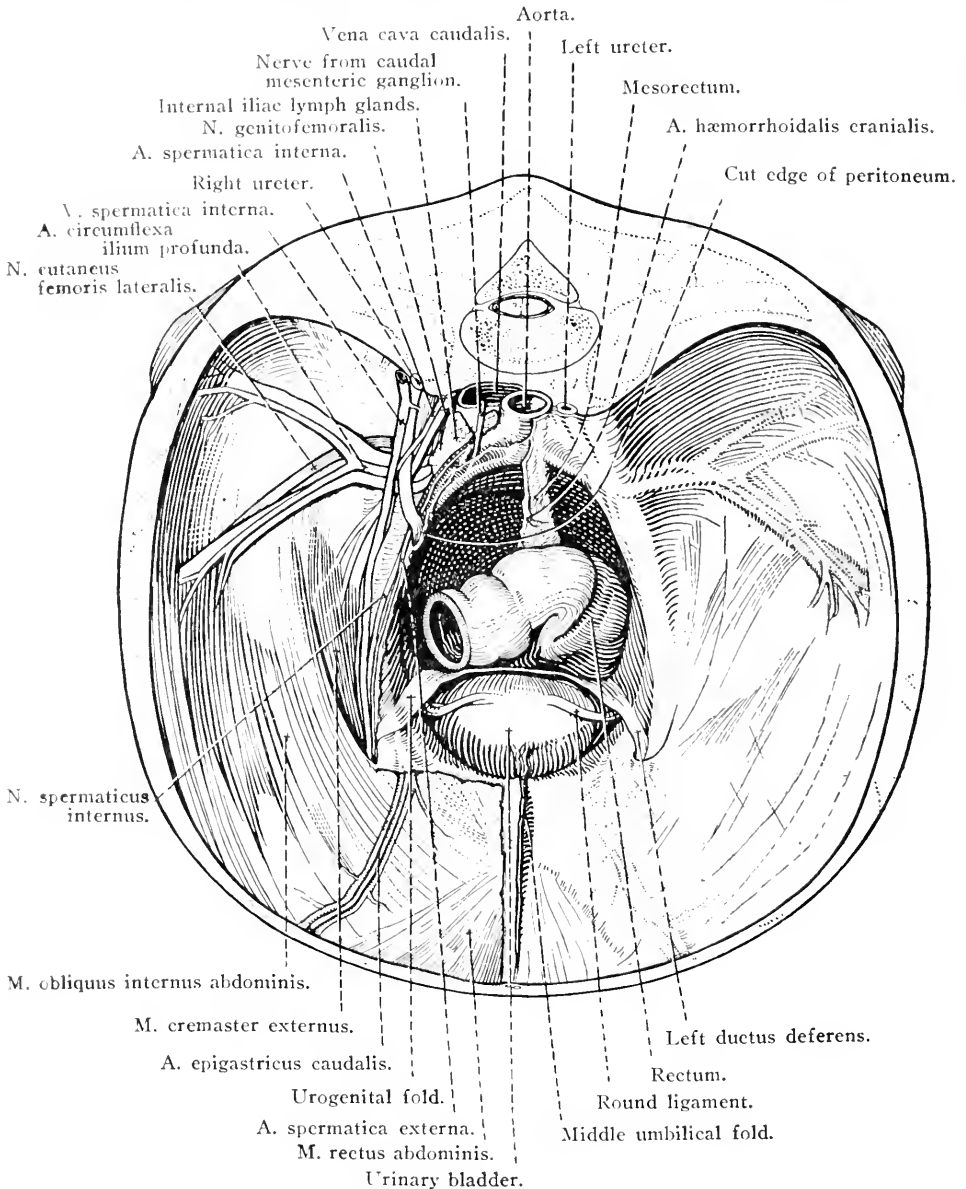


FIG. 70.—Dissection of the structures about the entrance to the male pelvis.

dorsal direction it reaches the root of the tail where it splits into two layers, one passing on each side of the lateral ventral sacro-coccygeal muscle. The insertion of the coccygeus is to the transverse processes of the first three or four coccygeal vertebrae and the fascia of the tail.



THE PELVIC FASCIA (*Fascia pelvis*).—The wall of the pelvis is lined by a layer of fascia (*parietal pelvic fascia*), which is connected with all the muscles and blood vessels applied to the wall, and from which sheets pass into the several peritoneal folds. Wherever there is a free bony surface, as, for example, on the ventral surface of the ilium, the fascia fuses with the periosteum. At the outlet of the pelvis it is continued on to the surface of the pelvic viscera (*visceral pelvic fascia*), and in this way assists in the closure of the outlet.

The fascia of the pelvis is continuous with that clothing the internal surface of the transverse abdominal muscles (*fascia transversalis*) and with the iliac and coccygeal fasciæ.

THE RECTUM (*Intestinum rectum*).—In the male, the greater part of the cavity of the pelvis is occupied by the flask-shaped rectum,<sup>1</sup> the terminal and widest part of which is known as the *ampulla*. In length the rectum is from 20 to 30 cm. In position it occupies the median plane, except at the pelvic inlet where the pelvic flexure of the great colon generally pushes it towards the left.

The first part of the rectum is provided with a mesentery (*mesorectum*), but this gradually narrows, and the terminal part of the tube is connected with the sacrum and the coccygeal musculature by loose connective tissue.

The ventral relations of the rectum of the male are the urinary bladder, the terminal parts of the ureters, the seminal vesicles, the prostatic utricle, the terminal part of the ductus deferentes, the prostate, the bulbo-urethral glands and the pelvic part of the urethra.

It will be observed that the wall of the rectum is smooth and reveals the presence and course of longitudinal muscular fibres.

The last part of the rectum which surrounds its external orifice, the *anus*, forms a projection covered with soft, thin, hairless and pigmented skin, in which sebaceous and sweat glands are numerous. Surrounding the anus, and lying immediately under the skin, is the well-developed *external sphincter*<sup>2</sup> of the *anus* (*m. sphincter ani externus*). Two portions of this muscle may be distinguished. The deeper and more extensive fibres form a complete ring-like investment to the terminal part of the rectum. Lying superficial to these is a narrow band on each side with a dorsal attachment to the fascia of the tail and the coccygeus muscle. Ventrally some of these fibres blend with the retractor muscle of the penis, while others mix with the circular fibres of the rectum. The *anal canal*, about 5 cm. in

<sup>1</sup> *Rectus* [L.], straight. The rectum is that part of the intestine in which convolutions are absent.

<sup>2</sup> *σφιγκτήρ* (*sphincter*) [Gr.], a band, a binder.

length, is closed by the contraction of the sphincter muscle and the presence of mucous folds, except during the passage of fæces.

**M. LEVATOR ANI.**—The flattened levator muscle of the anus arises from the medial surface of the sciatic spine and the sacro-spinous ligament. An oblique course in a dorsal and caudal direction carries the muscle to the edge of the external sphincter of the anus under which it disappears.

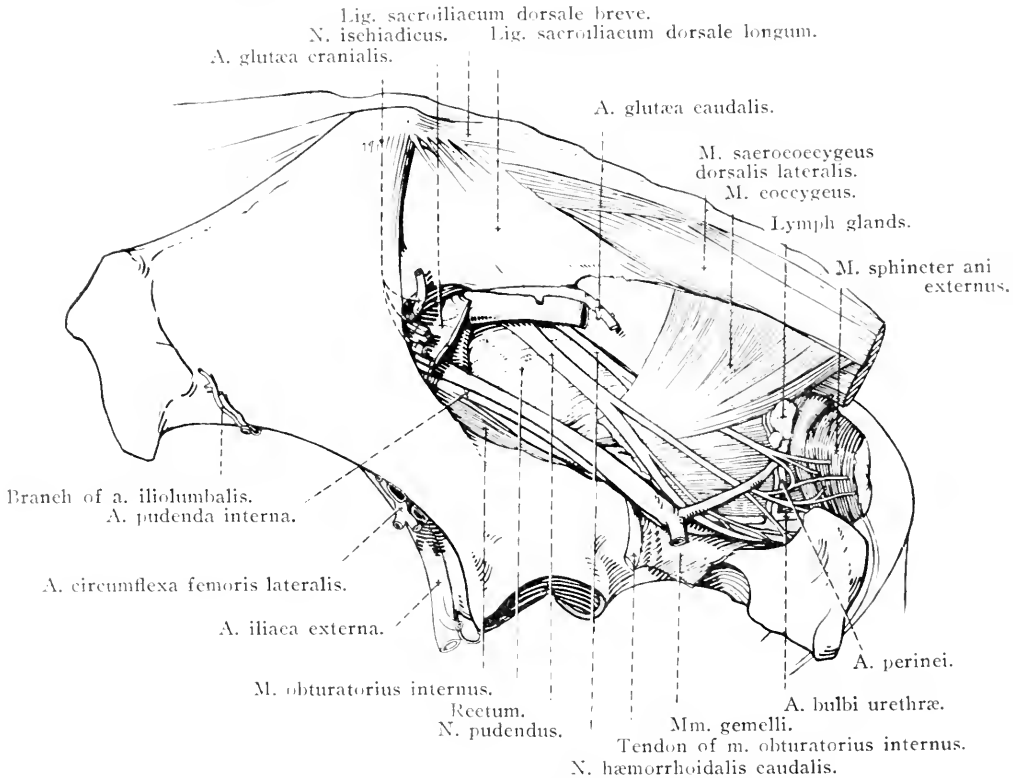


FIG. 71.—Lateral aspect of the male pelvis after removal of the sacro-spinous and sacro-tuberous ligaments.

**M. SPHINCTER ANI INTERNUS.**—If the levator muscle of the anus be reflected and the bundles of longitudinal fibres of the rectum separated, a partial view of the internal sphincter muscle may be obtained. This consists of pale, circular fibres in no way separable from the circular muscular stratum of the wall of the rectum, of which the sphincter must be regarded as a specialised part.

**M. RECTOCOCYGEUS.**—A bundle of the longitudinal fibres of the rectum becomes isolated and, proceeding in a dorsal direction, ends on the ventral aspect of the root of the tail.

**M. RETRACTOR PENIS.**—If the terminal part of the m. levator ani

be raised, a flat bundle of pale fibres will be disclosed. They originate from the first two coccygeal vertebræ, cross the lateral face of the rectum close to the border of the external sphincter, and blend with the corresponding fibres from the opposite side ventral to the anus. From this point the fibres are continued on to the penis, where they have already been traced to the neighbourhood of the glans.

THE URINARY BLADDER (*Vesica urinaria*).—An ovoid sac, with a strong muscular wall, the urinary bladder rests on the ventral wall of the pelvis, and possibly also on the ventral wall of the abdomen. For descriptive purposes, it is divided into a main portion or *body* (*corpus*

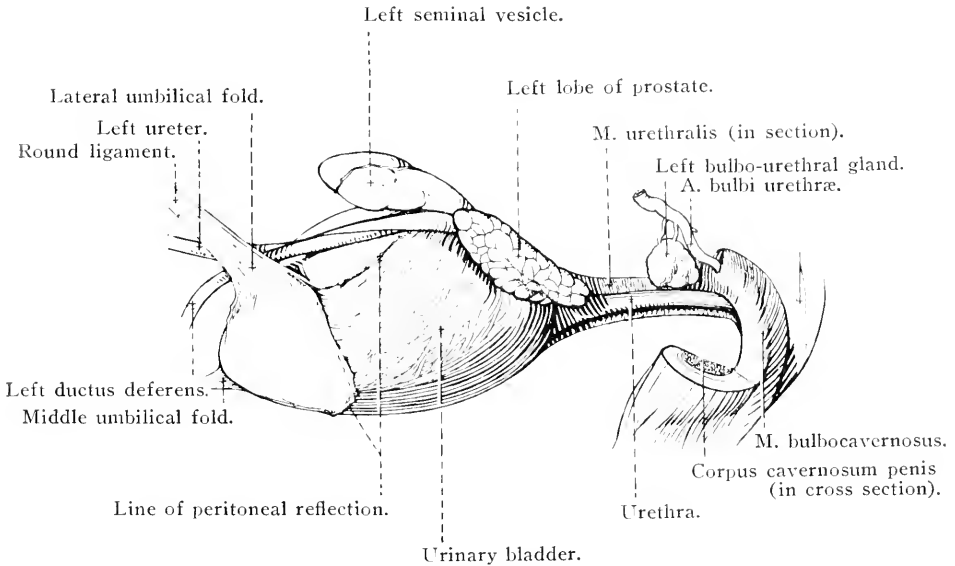


FIG. 72.—Lateral aspect of the urinary bladder and pelvic part of the urethra of the male.

vesicæ); a blunt cranial end, the *vertex* (*vertex vesicæ*); and a narrow *neck* (*collum vesicæ*) continuous with the urethra.

The neck lies on the internal obturator muscle medial to the obturator foramen. The dorsal relations of the bladder are the prostate, the urogenital fold and its contents (the terminations of the deferent ducts and ureters, the seminal vesicles and the prostatic utricle) and the rectum. On either side the bladder is related to the wall of the pelvis.

Naturally the relations of the vertex depend in some measure upon the amount of distension of the organ. It is not commonly the case that the distension is so great as to carry the vertex to any considerable distance beyond the margin of the pubis, and, consequently, this part of the bladder is generally in contact with the pelvic flexure of the great colon and the end of the left ventral colon. Coils of small intestine or

small colon may lie in relation to the vertex and part of the lateral surface.

The middle part of the vertex is marked by a puckered scar, the *centrum verticis*, which indicates the remains of the connection in the embryo between the bladder and the fetal envelope known as the allantois. On each side of the centrum is the termination of a ligamentum teres.

The neck of the urinary bladder is definitely fixed in position by its connection with the urethra. The rest of the organ is necessarily capable of some amount of displacement, dependent upon the quantity of urine contained in the sac. As has already been noted, the peritoneum furnishes an unstable anchorage by its reflection from the wall of the pelvis and by the formation of the middle and lateral folds or ligaments. Behind the peritoneum the bladder is moored by loose connective tissue, in which there is generally a considerable amount of fat.

**THE PROSTATE (Prostata).**—The prostate<sup>1</sup> of the horse is a relatively large body, yellowish in colour and lobulated, lying upon the neck of the bladder and the commencement of the urethra. It covers the termination of the deferent ducts and the narrow caudal extremity of the seminal vesicles. The rectum is in contact with its dorsal surface, while laterally it is separated from the wall of the pelvis by a greater or lesser accumulation of fat.

The gland is divisible into two lateral *lobes* (*lobus dexter*, *lobus sinister*) connected by a comparatively narrow *isthmus* (*isthmus prostatae*), over which lies a thin stratum of transverse muscular fibres (*m. prostaticus*). The gland pours its secretion into the first part of the urethra by 15 to 20 ducts (*ductus prostatici*).

**THE DEFERENT DUCTS (ductus deferentes).**—The deferent ducts have already been observed where they leave the other constituents of the spermatic cord at the abdominal ring of the inguinal canal and turn caudalwards into the pelvis. They are enclosed in the urogenital fold of peritoneum, and, as they pass obliquely along the dorsal face of the urinary bladder, they generally converge until they meet on the dorsal surface of the neck of this sac. The last part of each duct insinuates itself beneath the prostate, and finally opens, as will be seen later, into the prostatic part of the urethra.

The greater part of each duct is about 5-6 mm. in diameter; but where it is enclosed in the urogenital fold, its diameter increases to

<sup>1</sup> *προστάτης* (*prostatēs*) [Gr.], one standing before (*πρό*, before + *ιστάναι*, to stand). So named because in the human subject the gland stands before the neck of the bladder.

about 2 cm. This portion of the duct is known as the *ampulla*, but it is to be noted that the increase in diameter is caused by a thickening of the wall by glandular tissue, and not by any increase in the lumen of the tube. Beyond the ampulla the duct narrows abruptly.

**THE SEMINAL VESICLES** (*Vesiculæ seminales*).—These are pear-shaped, hollow bodies partly enclosed in the urogenital fold lateral to the ampullæ of the deferent ducts and dorsal to the last part of the ureters. Their dorsal surface is in contact with the rectum. The main part, or *body* (*corpus*), of each vesicle expands towards a rounded cranial

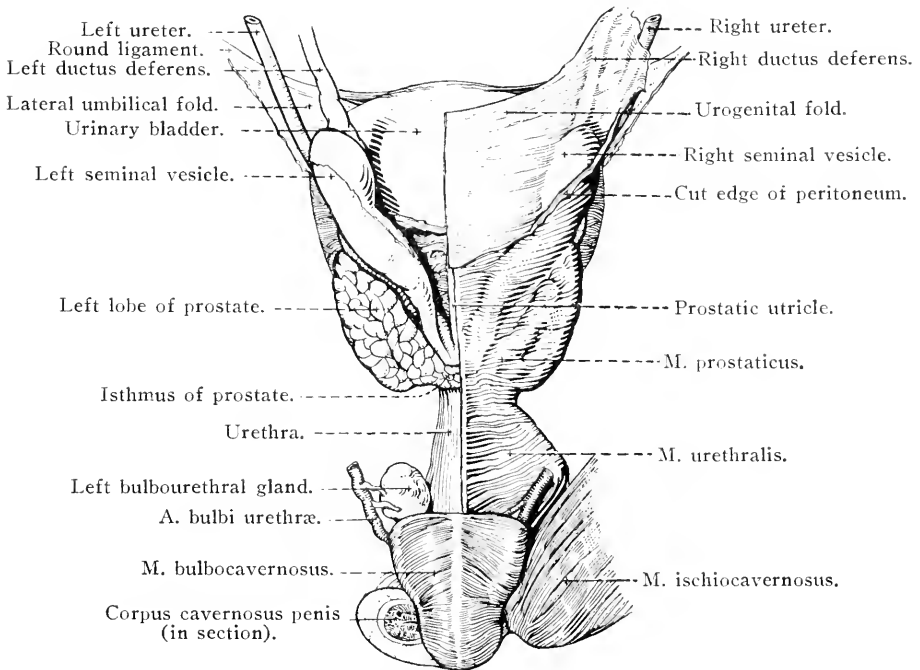


FIG. 73.—Dorsal view of the urinary bladder and intrapelvic urethra of the male, with their associated structures.

extremity, the *fundus*, while its caudal end, approaching the middle line, narrows to an *excretory duct* (*ductus excretorius*) that opens into the urethra underneath the prostate.

It is often stated that the excretory duct of the seminal vesicle joins the termination of the deferent duct of its own side in a common *ejaculatory duct* (*ductus ejaculatorius*); but in most horses the two ducts open into the urethra by a common orifice (*orificium ejaculatorium*) or diverticulum.

**THE PROSTATIC UTRICLE** (*Utriculus prostaticus*).—When the dorsal layer of the urogenital fold is removed, it is generally possible to find

an elongated, pyriform, blind tube occupying the middle line between the two deferent ducts. This is the homologue of the uterus and vagina of the female, and is consequently sometimes known as the uterus masculinus. The tube varies greatly in its degree of development, and is sometimes impossible of demonstration. In other animals, on the contrary, it is some 10 cm. in length, and may terminate cranially in two very slender cornua. The utricle may open into the urethra, or its caudal end may be blind.

**THE URETHRA (Urethra).**—The male urethra<sup>1</sup> (*urethra masculina*) is a tube concerned in the transmission of both urine and semen; consequently it is sometimes designated the male urogenital canal. It extends from the neck of the urinary bladder to the free end of the penis, and is therefore divisible into pelvic and penile or extra-pelvic portions. The pelvic part (*pars pelvina*), from 10 to 15 cm. in length, runs along the ventral wall of the pelvis beneath the rectum. A portion of it, the *pars prostatica*, is associated with the prostate and is not so wide as that part which extends from the prostate to near the sciatic arch. The thin *urethral muscle* (*m. urethralis*) covers the pelvic part of urethra. The term *isthmus urethrae* is applied to the somewhat constricted part of the tube that is related to the bulbo-urethral glands.

The penile portion (*pars cavernosa*) of the urethra has already been examined in connection with the penis (page 78). An examination of the interior of the tube should be postponed.

**THE BULBO-URETHRAL GLANDS (glandulae bulbourethrales).**—A short distance from the sciatic arch an elongated or ovoid bulbo-urethral gland lies on each side of the urethra covered by the urethral muscle. The size of the glands varies in different animals; but in the uncastrated male their long diameter is approximately 4 cm., while the transverse diameter is rather more than half the length. In the castrated animal they are much smaller than this. On section each gland consists of ill-defined lobules separated by trabeculae, into the larger of which fibres are projected from the urethral muscle. It will be observed later that each gland pours its secretion into the urethra by several (5 to 8) small excretory ducts (*ductus excretoria*).

**M. URETHRALIS.**—The urethral muscle consists of dorsal and ventral strata of transverse (and longitudinal) fibres, investing the dorsal and ventral surfaces of the pelvic portion of the urethra. Some of the fibres cover the surface of the prostate (*m. prostaticus*), while others, in like manner, are associated with the bulbo-urethral glands.

<sup>1</sup> *οὐρήθρα* (*ourethra*) [Gr.], urinary canal (*οὐρέω* (*oureo*) to make water).

The urethral muscle is continued from the bulbo-urethral glands to the glans of the penis as the *bulbo-cavernous muscle* (m. bulbocavernosus).

M. ISCHIOURETHRALIS.—The ischio-urethral muscle consists of a pale band of fibres arising from the sciatic arch and one of the crura of the penis, and blending with the ventral stratum of the urethral muscle.

A. PUDENDA INTERNA.—The internal pudendal is a branch of the hypogastric artery. On entering the pelvis the vessel runs obliquely across the lateral wall of the cavity along the dorsal border of the iliac head of the internal obturator muscle. Part of its course is related to the inner surface of the sacro-spinous ligament close to the sciatic spine. Sometimes the artery is embedded in the ligament; at other times it may even pierce the ligament and run for a short distance on its outer surface before again perforating it to re-enter the pelvic cavity. Finally, having crossed the lateral face of the levator ani muscle, the artery reaches the sciatic arch, where it ends by dividing into the perineal artery and the artery of the urethral bulb. The following are its principal branches:—

(1) *A. umbilicalis*.—This is the shrivelled remains of a vessel that, in the embryo, carries blood from the hypogastric artery through the umbilicus to the placenta. In the adult it occupies the free edge of the lateral umbilical fold of the urinary bladder, and constitutes the so-called round ligament of the bladder. Only the first part of the vessel possesses any lumen, and from this spring small arteries for the bladder and prostate (aa. vesicales craniales) and the ductus deferens (a. deferentialis).

(2) *A. hæmorrhoidalis media*.—The middle hæmorrhoidal<sup>1</sup> artery arises medial to the sciatic spine and passes to the rectum. It gives branches to the bladder, urethra, seminal vesicle, prostate and bulbo-urethral gland.

(3) *A. perinei*.—In the male the perineal artery is small, and supplies the skin of the perineum and the projecting anal part of the rectum.

(4) *A. bulbi urethrae*.—As its name indicates, this vessel supplies the bulb of the urethra. A small branch bends round the sciatic arch and anastomoses with a branch of the obturator artery.

V. PUDENDA INTERNA.—The internal pudendal vein, in the main,

<sup>1</sup> *αἰμορροΐς* (haimorhois) [Gr.], a pile, or vascular tumour of the rectal mucous membrane (Hippocrates). The hæmorrhoidal vessels are involved in piles.

corresponds to the artery of that name, and ends by joining the hypogastric vein. A large anastomotic branch connects it with the obturator vein at the lesser sciatic foramen.

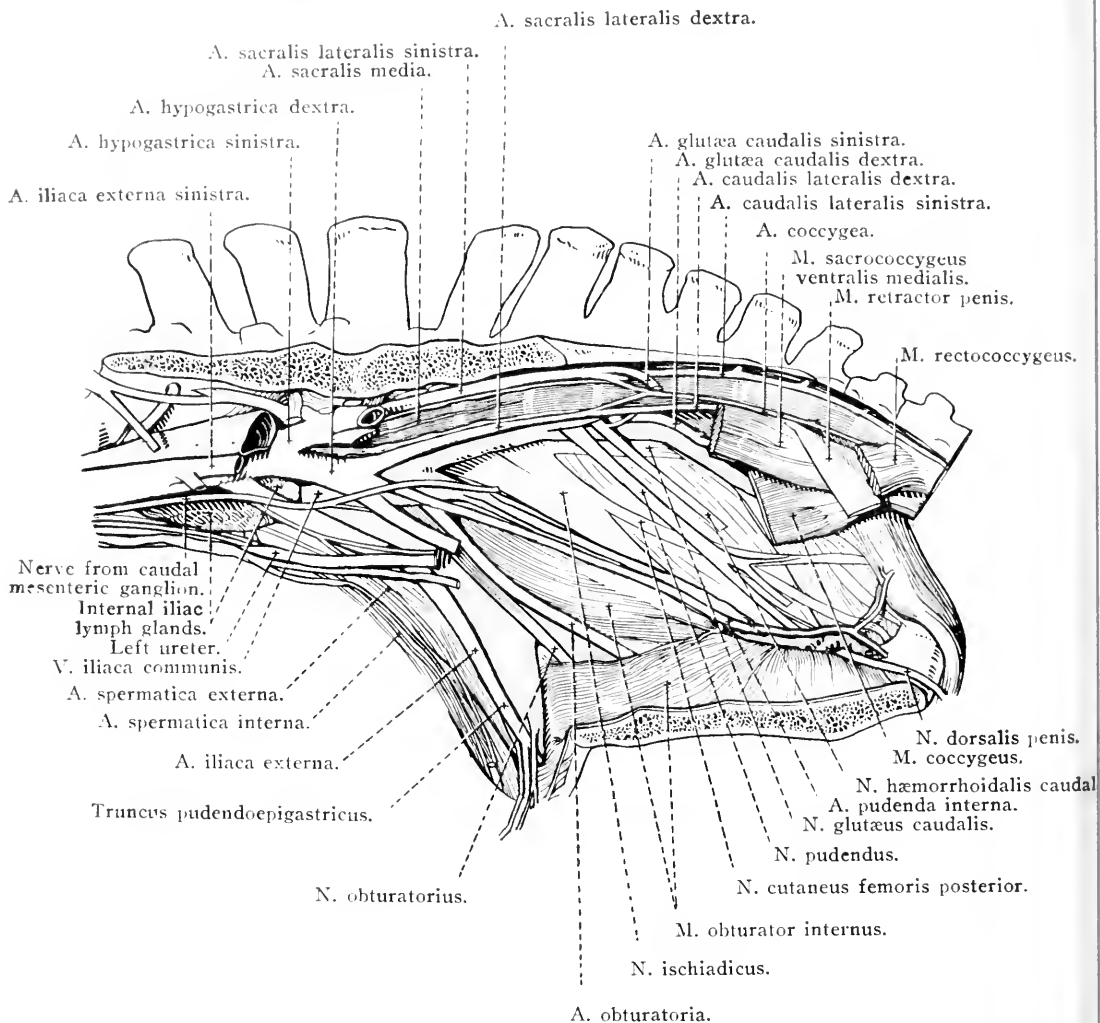


FIG. 74.—Dissection of the vessels and nerves of the male pelvis.

**A. HÆMORRHOIDALIS CRANIALIS.**—It will be remembered that the cranial hæmorrhoidal artery is one of the two vessels into which the caudal mesenteric divides (page 110). The terminal part of the artery must now be sought between the two layers of the mesorectum, where it anastomoses with the middle hæmorrhoidal artery. It is accompanied by a vein bearing the same name.

**N. PUDENDUS.**—The pudendal nerve is formed by roots from the ventral branches of the third and fourth sacral nerves. It accompanies



the internal pudendal artery to the sciatic arch, where it becomes the dorsal nerve of the penis. From it the following branches take origin :—

(1) To the coccygeus and levator ani muscles; (2) the *middle hæmorrhoidal nerve* (n. hæmorrhoidalis medius) which furnishes twigs to the levator ani muscle and the rectum; (3) the *perineal nerve* to the skin of the perineum and about the anus. The last-named nerve receives fibres from the posterior cutaneous nerve of the thigh.

The *dorsal nerve of the penis* (n. dorsalis penis) turns round the sciatic arch, and has already been traced along the dorsum of the penis in company with the dorsal artery and vein. The nerve is the most lateral of the three structures.

**N. HÆMORRHOIDALIS CAUDALIS.**—The caudal hæmorrhoidal nerve is mainly formed by roots from the third and fourth sacral, but a slender root from the fifth nerve also is not uncommon. Passing in a caudo-ventral direction medial to the sacro-tuberous ligament and the coccygeus muscle, the nerve ends in filaments distributed to the terminal part of the rectum and the skin surrounding the anus.

**PLEXUS HYPOGASTRICI.**—Accompanying all the vessels of the pelvis are filaments of sympathetic nerve plexuses. These are continuous with the aortic and caudal mesenteric plexuses, and connected with them are two, or possibly more, small nerves that leave the caudal mesenteric ganglion and enter the pelvis ventral to the large blood vessels. They are also joined by filaments from the third and fourth sacral nerves.

The hypogastric<sup>1</sup> plexuses are associated with the pelvic organs, as well as with the penis in the male.

*Dissection.*—Remove the pelvic organs. Open the rectum longitudinally and observe the character of its lining. Open the urinary bladder by making an incision along the mid-ventral line from the vertex to the neck. Continue this incision along the ventral border of the urethra.

**THE INTERIOR OF THE URINARY BLADDER** is lined by a pale mucous membrane of distinctly rugose character; but towards the neck the rugæ are generally less pronounced than elsewhere. In the dorsal part of the neck the opening of the ureter (orificium ureteris) will be found, and if a probe be passed along the tube, its very oblique course through the wall of the bladder can be determined. An indistinct fold of mucous membrane (plica ureterica) stretches from the ureteral opening into the urethra, where the folds of the two sides of the bladder meet and fuse into the *urethral crest* (crista urethralis). The term *trigone of the bladder* (trigonum vesicæ) is applied to the area bounded

<sup>1</sup> ὑπό (hypo) [Gr.], under + γαστήρ (gaster) [Gr.], the stomach. In the erect posture assumed by man, the hypogastrium is below the stomach.

by the two ureteral folds and a transverse line joining the two ureteral orifices. The trigone is not quite an equilateral triangle, for its base (between the openings of the ureters) is about 3 cm., and its sides about 4 cm. in length. The apex of the triangle is at the *internal urethral orifice* (orificium urethræ internum).

STRUCTURE OF THE BLADDER.—From a naked-eye examination, it is evident that the wall of the bladder is composed of the four layers customarily found in connection with hollow viscera of a like nature. The peritoneum provides a serous tunic that does not cover the whole of the organ. The greater part of the dorsal surface is covered, but a smaller amount of the ventral surface has a serous investment. As already noted, reflections of peritoneum from mid-ventral and lateral lines produce the three ligaments by which the bladder is kept in position.

The fibres composing the muscular tunic are easily demonstrated in the distended fresh organ, in which they will be observed to run in different directions, with an ill-defined arrangement in strata. The superficial stratum contains fibres mainly longitudinally disposed, and most clearly defined on the dorsal and ventral surfaces. For the most part, circular fibres form a middle stratum, while the deepest fibres are oblique and longitudinal in direction. Around the neck of the bladder the circular and oblique fibres form a sphincter muscle (sphincter vesicæ). Muscular fibres pass from the wall of the bladder for a short distance into the middle and lateral peritoneal folds.

A vascular submucous tela unites the muscular tunic and the mucous lining in which lymph nodules occur.

THE MALE URETHRA (*Urethra virilis*).—The male urethra, extending from the neck of the urinary bladder to the glans penis, may be divided into pelvic and extra-pelvic parts. The extra-pelvic part is contained in the penis. The pelvic part (*pars pelvina*), now under consideration, is about 10-12 cm. in length, and runs along the floor of the pelvis to the sciatic arch. The initial portion of it, associated with the prostate, is not sharply marked off from the neck of the bladder.

The prostatic portion of the urethra, which communicates with the bladder by the *internal urethral orifice* (orificium urethræ internum) is narrow; but beyond the prostate the lumen of the tube is greater. After the bulbo-urethral glands have been passed, the lumen again diminishes as the root of the penis is approached. This part of the urethra is known as the *isthmus* (isthmus urethræ).

Along the dorsal wall of the prostatic portion of the urethra runs a fold of mucous membrane, the *urethral crest* (crista urethralis), con-

tinuous with the ureteral folds of the bladder. In association with the crest is a rounded eminence (colliculus seminalis), of some size in the stallion but inconspicuous in the castrated animal, on the sides of which are the openings of the ejaculatory ducts, or, if these do not exist, the common openings of the deferent ducts and the excretory ducts of the seminal vesicles. On each side of the urethral crest is an irregular row of openings (12 to 15 in number) of the prostatic ducts.

It is sometimes possible to detect a small, unpaired opening in the middle line between the ejaculatory duct orifices. This, when present, leads into the prostatic utricle or uterus masculinus.

The openings of the ducts of the bulbo-urethral glands, on the dorsal wall of the tube, should be sought, as should also the openings, on papillæ, of the small urethral glands which occur at the same level but on the lateral wall.

The mucous membrane of the urethra is surrounded by a layer of erectile tissue except in the immediate neighbourhood of the neck of the bladder. At the sciatic arch this becomes slightly thicker and forms the *bulb of the urethra* (bulbus urethræ), which, however, is very indifferently developed in the horse.

*Dissection.*—The fat and loose connective tissue must be removed from that wall of the pelvis that is still intact, and its blood vessels and nerves defined.

As a matter of convenience, the dissection of the tail should be included in the examination now being conducted.

M. OBTURATOR INTERNUS.—The internal obturator muscle consists of two parts. The more extensive portion is fan-shaped and covers the greater part of the ventral wall of the pelvis. Its fibres arise from the cranial and medial borders of the obturator<sup>1</sup> foramen, the body of the ischium, and the symphysis between the two hip-bones; and converge towards the lesser sciatic foramen.

The other part of the muscle is narrow and semipenniform and arises from the medial surface of the body of the ilium and the transverse process of the first sacral vertebra.

The two portions join a narrow, flattened tendon that leaves the pelvis by the lesser sciatic foramen and is inserted into the trochanteric fossa of the femur. A synovial bursa intervenes between the tendon and the ischium at the lesser sciatic notch.

The small nerve to the internal obturator muscle, derived from the sciatic, must be sought as it enters the pelvis by the lesser sciatic foramen.

M. SACROCOCCYGEUS DORSALIS MEDIALIS.—This is a strong rounded

<sup>1</sup> *Obturo* [L.], to stop up, to close. The obturator foramen is closed by tissues.

muscle abutting upon the median plane and arising from the spinous processes of the last two or three sacral vertebræ. It also receives fibres from the multifidus, and terminates in a tendon which blends with that of the following muscle.

**M. SACROCOCYGEUS DORSALIS LATERALIS.**—The lateral dorsal sacro-coccygeus muscle follows the lateral border of the foregoing, and appears to be a continuation of the multifidus muscle. Fibres join it from the transverse processes of the sacrum and the first few coccygeal vertebræ, and it terminates in a tendon (with which the medial muscle is blended) that is inserted into the rudiments of the transverse processes of the coccygeal vertebræ with the exception of the first three or four.

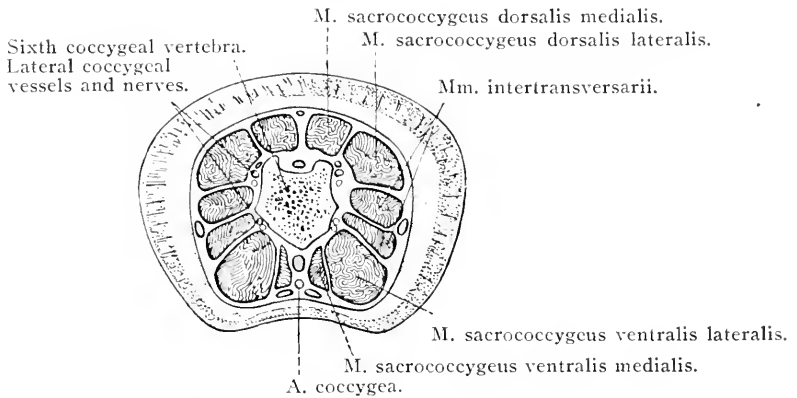


FIG. 75.—Transverse section of the tail on a level with the sixth coccygeal vertebra.

**M. SACROCOCYGEUS VENTRALIS MEDIALIS.**—This muscle lies ventral to the coccygeal vertebræ and lateral to the recto-coccygeal muscle. Its origin is from the pelvic surface of the sacrum and the ventral aspect of the bodies of the first seven or eight coccygeal vertebræ. Its insertion—in common with part of the lateral muscle of the same name—is to the ventral surface of the bodies of the coccygeal vertebræ.

**M. SACROCOCYGEUS VENTRALIS LATERALIS.**—A stronger muscle than the preceding, the lateral ventral sacro-coccygeal arises from the pelvic surface of the sacral vertebræ from the second or third to the last and from the transverse process of the first coccygeal vertebra. Bundles of muscular fibres are succeeded by a double series of tendons. Some of these join the tendons of the preceding muscle. Others are attached to the transverse processes of the coccygeal vertebræ.

**MM. INTERTRANSVERSARII.**—Lying between the lateral dorsal and

lateral ventral sacro-coccygeal muscles are bundles of fibres which fill the intervals between the transverse processes of the last sacral and first coccygeal and succeeding vertebræ.

A. HYPOGASTRICA.—The hypogastric arteries, right and left, form two of the four terminal branches of the abdominal aorta. Leaving the aorta on a level with the joint between the bodies of the fifth and sixth lumbar vertebræ, each hypogastric artery pursues an oblique

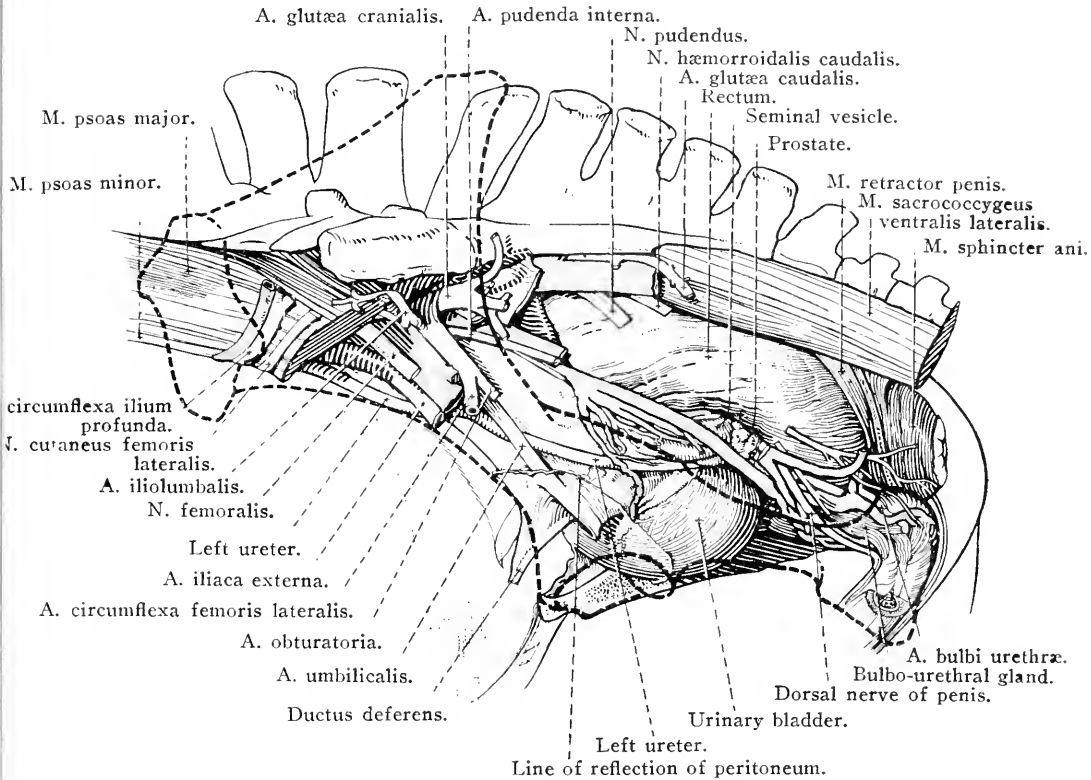


FIG. 76.—Lateral aspect of the pelvic vessels, nerves and organs of the male, after removal of the hip-bone. The position of the bone is indicated by the strong dotted line.

lateral and caudal course ventral to the transverse process of the first sacral vertebra and the articulation between this and the ilium. At the sacro-iliac joint, or slightly beyond it, the vessel divides into three arteries—ilio-lumbar, cranial gluteal and obturator.

The following are the branches of the hypogastric artery :—

(1) Close to its origin from the aorta the hypogastric furnishes the sixth lumbar artery, which conducts itself after the manner of the other members of the series.

(2) *A. pudenda interna.*—The internal pudendal artery is also

an early branch of the hypogastric. Its course and distribution have already been examined (page 167).

(3) *A. sacralis lateralis*.—The lateral sacral artery is generally the largest branch of the hypogastric. Beginning on a level with the joint between the last lumbar vertebra and the sacrum, the artery follows the line of the ventral sacral foramina to about the

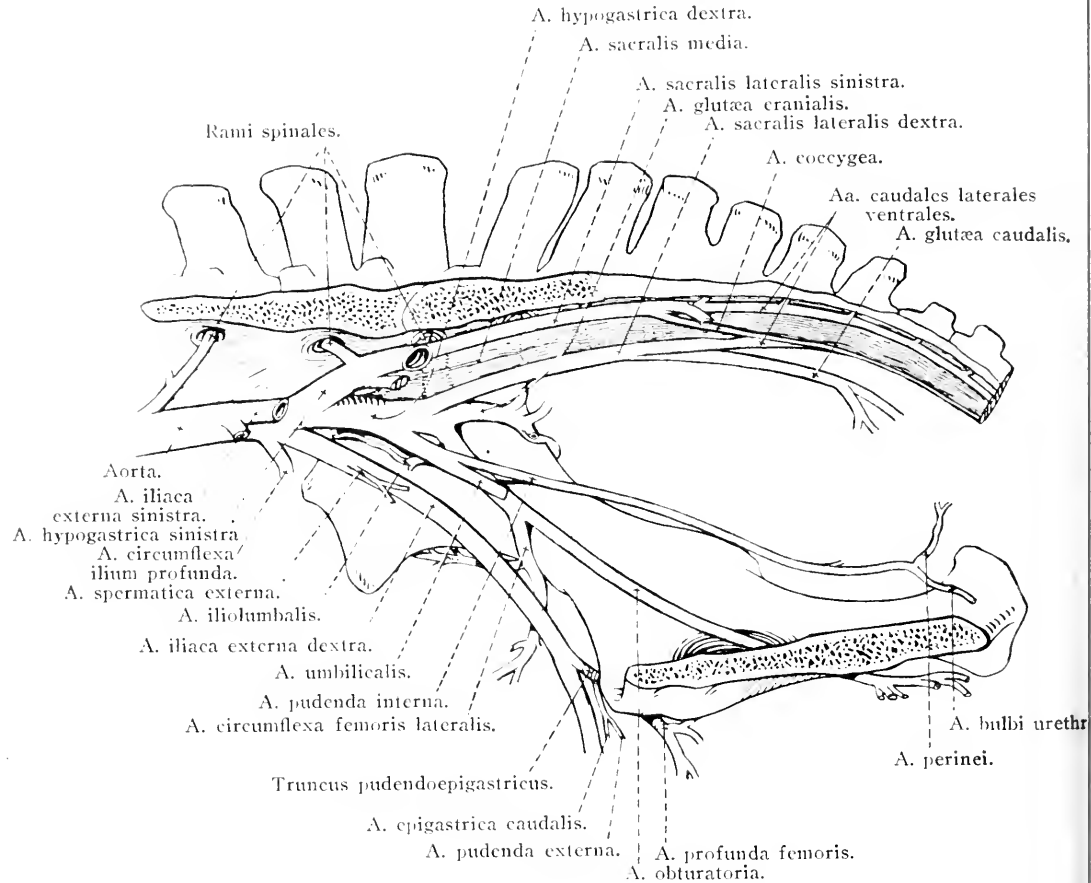


FIG. 77.—Diagram of the arteries of the male pelvis.

third sacral vertebra, where it divides unequally into the caudal gluteal and ventral lateral caudal arteries.

(a) *Spinal branches* (rami spinales)—generally two in number—leave the lateral sacral artery and immediately enter the vertebral canal by the ventral sacral foramina. They end partly by ramification in the dura mater, and partly by union with the ventral artery of the spinal cord. (b) The *caudal gluteal artery* (a. glutea caudalis) pierces the dorsal border of the combined sacro-spinous and sacrotuberous ligament, and thus gains the gluteal region where it is

examined during the dissection of the pelvic limb. (c) The *lateral ventral artery of the tail* (a. caudalis lateralis ventralis) continues the original direction of the lateral sacral and thus reaches the tail, where it runs between the inter-transverse and lateral ventral sacro-coccygeal muscles. Between the second and third (or third and fourth) coccygeal vertebræ it gives off the *lateral dorsal artery of the tail* (a. caudalis lateralis dorsalis) which runs in the cleft between the inter-transverse and the lateral dorsal sacro-coccygeal muscles. (d) From either the right or left lateral sacral or a lateral caudal artery a single (unpaired) *coccygeal artery* (a. coccygea) takes origin. This follows the middle line of the tail between the recto-coccygeal muscles, and afterwards between the two medial ventral sacro-coccygeal muscles. Not infrequently the coccygeal artery is formed by the union of branches of both lateral sacral arteries.

(4) *A. iliolumbalis*.—The ilio-lumbar artery leaves the common point of origin of the cranial gluteal and obturator vessels and runs in a lateral direction, between the transverse process of the first sacral vertebra and the ala of the ilium on the one hand and the ilio-psoas muscle on the other. It supplies branches to this muscle, and, close to the coxal tuber, ends in the middle gluteal and tensor fasciæ latæ muscles.

(5) *A. glutæa cranialis*.—The large cranial gluteal artery at once passes through the greater sciatic foramen and is found during the dissection of the gluteal region of the pelvic limb.

(6) *A. obturatoria*.—The obturator artery continues the direction of the parent vessel, sweeping along the iliac portion of the internal obturator muscle to the obturator foramen. It passes through the foramen by insinuating itself underneath the pubic portion of the internal obturator muscle, and thus gains the deeper part of the medial aspect of the thigh, where it is encountered during the dissection of the pelvic limb.

Just before the obturator artery reaches the psoas tubercle it gives off a large branch, the *lateral circumflex artery of the thigh* (a. circumflexa femoris lateralis), which passes between the ilium and the ilio-psoas muscle to ramify in the superficial and middle gluteal, tensor fasciæ latæ, lateral vastus and rectus femoris muscles. The circumflex also furnishes the *nutrient artery of the ilium* (a. nutritia ossis ilium).

V. HYPOGASTRICA.—The hypogastric vein is formed by the union of tributaries corresponding to the branches of the artery, except that, most commonly, the ilio-lumbar and last lumbar veins join the common

iliac, which is produced by the junction of the external iliac and hypogastric veins. The obturator vein may be a tributary of the hypogastric, but it more usually joins the external iliac vein.

A. SACRA MEDIA.—The middle sacral artery arises from the end of the aorta in the angle of divergence of the two hypogastric arteries, and runs for a variable distance along the mid-ventral line of the sacrum. It frequently happens that this artery is entirely absent; and, at its best, the size of the vessel is inconsiderable.

PELVIC LYMPH GLANDS.—A number of scattered lymph glands (lymphoglandulæ sacrales) should be found on the pelvic surface and about the borders of the sacrum. A chain of glands (lymphoglandulæ rectales) follows the dorsal surface of the rectum; and three or four glands of small size (lymphoglandulæ anales) are related to the sphincter muscle of the anus.

NN. LUMBALES: NN. SACRALES.—The time has arrived when it is possible to make a general survey of the lumbar and sacral nerves. These agree in number with the vertebræ of the lumbar and sacral regions respectively, and leave the vertebral canal by the intervertebral foramina caudal to the vertebræ with which they are in numerical correspondence. Each nerve divides into dorsal and ventral branches. Owing to coalescence of the transverse processes of the sacral vertebræ, the dorsal and ventral branches of the sacral nerves (except the last) escape by the dorsal and ventral sacral foramina respectively. The dorsal branches are distributed to the muscles and skin of the sacral region and the root of the tail. The ventral branches of five lumbar and five sacral nerves form a plexus that is simple at the beginning of the lumbar region, but becomes increasingly complicated as the sacrum is approached. The first lumbar nerve scarcely ever enters into the plexus formation.

It is here convenient to summarise the constitution of the nerves derived from the lumbar and sacral plexuses, though many of them have already been examined in detail.

*N. iliohypogastricus* constitutes the ventral branch of the first lumbar nerve.

*N. ilioinguinalis* consists mainly of fibres derived from the second lumbar, but may receive a small reinforcement from the third nerve.

*N. genitofemoralis* (n. spermaticus externus) is the ventral branch of the third lumbar, to which are generally added fibres from the second and fourth nerves.

*N. cutaneus femoris lateralis* is formed by fibres from the third and fourth, and may receive an addition from the fifth lumbar nerve.



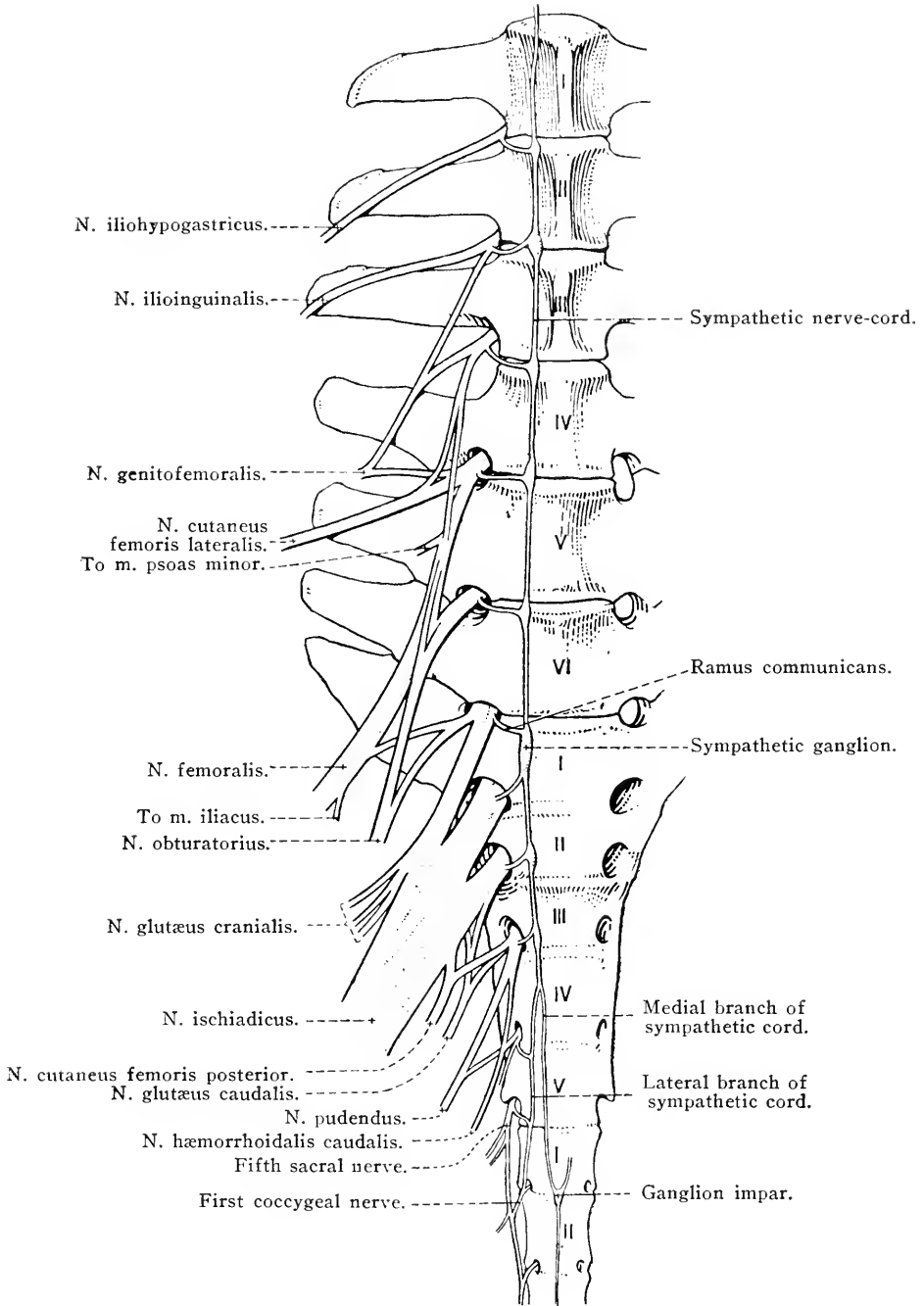


FIG. 78.—Diagram of the plexus formed by the lumbar and sacral nerves. The numbers refer to the vertebræ.

*N. femoralis*, when it possesses its most widespread origin, receives fibres from the third, fourth, fifth and sixth lumbar nerves; but the third often fails to contribute. The root from the fifth lumbar nerve is the largest.

*N. obturatorius* has three roots, derived from the fourth, fifth and sixth lumbar nerves. The largest contribution comes from the fifth, and the smallest from the fourth nerve.

*N. ischiadicus*, the largest nerve from the plexus, arises by large roots from the sixth lumbar and the first and second sacral nerves, and occasionally by a much smaller bundle of fibres from the third sacral nerve.

*N. gluteus cranialis* is composed of fibres from the sixth lumbar and first sacral nerves.

*N. gluteus caudalis*. *N. cutaneus femoris posterior*.—As a rule each of these nerves is formed by the union of two roots: one composed of fibres from the first and second, and the other from the second and third sacral nerves.

*N. pudendus* is formed by the third and fourth sacral nerves.

*N. hæmorrhoidalis caudalis* results from the union of a large root from the fourth sacral nerve and a smaller root from the third. A slender root may also be derived from the fifth sacral nerve.

Of the above nerves the undermentioned remain to be dissected.

**N. OBTURATORIUS.**—After its formation by the roots above mentioned, the obturator nerve passes in a ventral and caudal direction, in relation to the external iliac vein as far as the pelvic brim. It then follows the cranial face of the obturator vein, accompanies this vessel underneath the pubic head of the internal obturator muscle, and gains the thigh by traversing the obturator foramen. Its ultimate distribution to muscles on the medial aspect of the thigh is disclosed during the dissection of the pelvic limb.

**N. GLUTEUS CRANIALIS. N. GLUTEUS CAUDALIS. N. CUTANEUS FEMORIS POSTERIOR. N. ISCHIADICUS.**—The gluteal, posterior cutaneous and sciatic nerves quickly make their exit by the greater sciatic foramen, and are encountered in the dissection of the gluteal region of the pelvic limb.

**NX. COCCYGEAL.**—Leaving the vertebral canal between the first six vertebræ of the tail are five coccygeal nerves. Each nerve divides into dorsal and ventral branches, after the manner of spinal nerves in general. All the dorsal and all the ventral branches join to form dorsal and ventral nerves respectively on each side of the tail. The

dorsal branch of the fifth sacral assists in the formation of the dorsal nerve. The two nerves follow the dorsal and ventral caudal arteries.

**PARS PELVINA SYSTEMÆ SYMPATHICI.**—The pelvic part of the sympathetic may be said to begin after the last lumbar ganglion. From this point the nerve-trunk passes into the pelvis dorsal to the hypogastric artery and the common iliac vein. Traversing the pelvic surface of the sacrum medial to the ventral branches of the sacral nerves, the nerve-cord develops a ganglion opposite each of the first three ventral sacral foramina, and finally divides into medial and lateral branches. The medial branch joins its fellow from the opposite side of the body, and the single nerve thus formed accompanies the coccygeal artery into the tail. There is often a small unpaired ganglion (ganglion impar) at the point of union of the two branches. The lateral branch is connected with the last two sacral nerves, and joins the trunk formed by the union of the ventral branches of the coccygeal nerves.

The *sacral ganglia* (ganglia sacralia) are connected by rami communicantes with the first three sacral nerves. Efferent filaments pass from them to the rectum, bladder, uterus and penis.

The dissection of the pelvis should be completed by an examination of the connection of the hip-bone with the vertebral column.

**THE SACRO-ILIAC ARTICULATION** (Articulatio sacroiliaca).—Though the joint between the sacrum and the ilium is usually described as a diarthrosis, the amount of movement possible in it is exceedingly slight. This might be deduced from an examination of the articular surfaces; for these are flattened, roughened by eminences and depressions, and covered by a thin layer of cartilage. Not infrequently, the very narrow joint-cavity is crossed by fibrous bands passing from one bone to the other. Moreover, the ligaments disposed in the neighbourhood of the joint all tend to prevent movement. A very short joint capsule encloses the joint.

The fibres of the *ventral sacro-iliac ligament* (ligamentum sacroiliacum ventrale) are short and surround the joint-capsule so closely that they might be regarded as thickenings thereof. The ligament is especially strong dorsal to the joint, where it forms a collection of almost vertical bundles in the angle between the ilium and the transverse process of the first sacral vertebra.

The *short dorsal sacro-iliac ligament* (ligamentum sacroiliacum dorsale breve) is a rounded cord stretching from the sacral tuber of the ilium to the summits of the sacral spinous processes.

The *long dorsal sacro-iliac ligament* (ligamentum sacroiliacum dorsale longum) is membranous and triangular. It is attached to the medial border of the ilium from the sacral tuber to the level of the auricular surface. The sacral attachment is to the ends of the transverse processes (border of the sacrum).

At some distance from the sacro-iliac joint, but intimately concerned in the connection of the hip-bone to the vertebral column, is an extensive, strong, membranous sheet composed of the fused *sacro-spinous* and *sacro-tuberous ligaments* (ligamentum sacrospinosum: ligamentum sacrotuberosum). The dorsal margin of the combined ligament is attached to the ends of the transverse processes of the sacral and the first and second coccygeal vertebra. The ventral connection is to the summit of the sciatic spine (sacro-spinous ligament) and the sciatic tuber (sacro-tuberous ligament). The presence of the sacro-spinous ligament converts the greater sciatic notch of the ilium into the greater sciatic foramen, through which the sciatic and gluteal nerves and the cranial gluteal vessels emerge from the pelvis. In like manner, the sacro-tuberous ligament converts the lesser sciatic notch of the ischium into the lesser sciatic foramen by which the tendon of the internal obturator muscle reaches its insertion into the femur. The lesser sciatic foramen also gives passage to the nerve of the internal obturator muscle, and a communicating vessel between the internal pudendal and obturator veins. The caudal border of the sacro-tuberous ligament is thin and connected with the origin of the semi-membranosus muscle.

The *ilio-lumbar ligament* (ligamentum iliolumbale) also assists, in a measure, in the connection of the hip-bone with the vertebral column. It is in the form of a triangular sheet that passes from the transverse process of the last lumbar vertebra to the adjacent part of the medial surface of the ilium.

#### THE FEMALE PELVIS.

The examination of the female pelvis follows the same lines as those laid down for the pelvis of the male. The boundaries of the cavity in the two sexes are the same.

The first thing to be done is to make a general examination of the disposition of the pelvic viscera so far as is possible before any dissection has been carried out.

The pelvic inlet is occupied by the vertex of the bladder (if the organ is moderately distended), the body of the uterus and the termination of the small colon. The general form of the urinary bladder agrees

with that of the same organ in the male, but there are no deferent ducts, seminal vesicles, or prostate associated with its neck. As in the male, the peritoneum is reflected from its mid-ventral and lateral aspects to the pelvic wall in the form of three triangular membranous sheets. In the female the peritoneum is reflected from the dorsal wall of the bladder on to the vagina, close to its junction with the uterus. In other words, the uterus and a very short length of the vagina occupy the homologue of the urogenital fold (now the broad ligaments) of the male. The peritoneal pouch between the uterus and the bladder is designated the *vesico-uterine excavation* (excavatio vesicouterina).

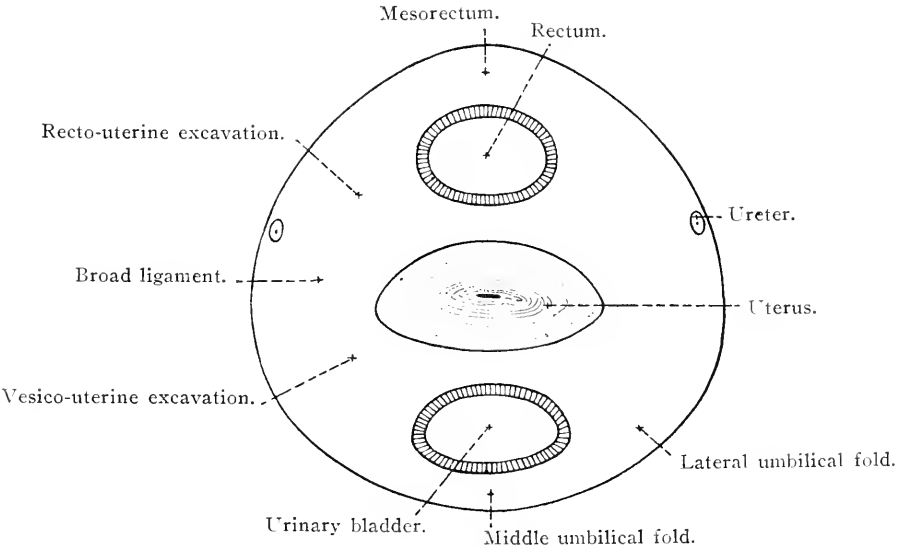


FIG. 79.—Diagram to illustrate the arrangement of the peritoneum in the female pelvis. Transverse section. The red line represents the peritoneum.

The vagina occupies a position dorsal to the bladder and urethra and ventral to the rectum.

The broad ligaments are continued for a short distance into the pelvic cavity. Converging and gradually narrowing, they cease to exist as such, and the peritoneum is reflected from the vagina, close to its junction with the uterus, on to the rectum. The broad ligaments in this manner circumscribe a peritoneal pouch, the *recto-uterine excavation* (excavatio rectouterina), which intervenes between the uterus and a small portion of the vagina on the one hand, and the rectum and termination of the small colon on the other. The terminal portion of the intestine is suspended in the excavation by a short mesentery.

*The pelvic cavity* (cavum pelvis).—Since the young is born by passing through the pelvis, the dimensions of the cavity in the female are of obstetric interest. And seeing that the inlet to the cavity is

completely surrounded by unyielding bone, its measurements are of surpassing importance. The obstetrician recognises four diameters of the inlet—a conjugate, a transverse, and right and left oblique. (1) The *conjugate diameter* is measured from the middle of the sacral promontory to the cranial end of the symphysis of the hip-bone. (2) The *transverse diameter* is the greatest width of the inlet, which, in a well-formed pelvis, is immediately dorsal to the psoas tubercles. (3) The *oblique diameters* (of minor moment) are measured from one sacro-iliac articulation to the ilio-pectineal eminence of the opposite side. The caudal aperture (outlet) of the pelvis may be measured in a similar manner.

The *axis pelvis* is a line that passes through the centre of the plane of the cranial and caudal apertures, and through the centre of a series of transverse planes between these. The term *inclination of the pelvis* (*inclinatio pelvis*) indicates the obliquity at which the plane of the inlet is set to the long axis of the body.

There are certain differences between the male and female pelvis, to the most important of which reference must be made. The whole pelvic cavity is more spacious in the mare than in the stallion, and the diameters of the inlet are appreciably greater. The inclination of the pelvis is more marked in the female than in the male, as can be best indicated by saying that a perpendicular erected from the cranial border of the pubis would strike the fourth sacral vertebra in the female and the second in the male. The outlet is larger in the female, mainly because of the greater width of the sciatic arch.

*Dissection.*—Proceed as in the dissection of the male pelvis. Constant reference must be made to page 156 *et seq.*, for it must be understood that the following paragraphs deal with the points only in which the female structures differ from those of the male. Where no difference is stated, the descriptions as given for the male are applicable to the female.

**FEMALE GENITAL ORGANS.**—The reproductive organs of the female consist of two ovaries with their associated uterine tubes, the uterus, the vagina, the vestibule of the vagina,<sup>1</sup> and the external genital parts or vulva. Of these the ovaries, uterine tubes, and the greater part of the uterus are abdominal in position, and have been examined at an earlier stage in the dissection.

The *vagina*<sup>2</sup> is a very dilatable tubular organ, about 20 cm. in length, connecting the uterus and the vestibule.<sup>3</sup> Except for a short

<sup>1</sup> Some writers include the vestibule with the vulva.

<sup>2</sup> *Vagina* [L.], a sheath.

<sup>3</sup> Externally there is no line of demarcation between the uterus and vagina or between the vagina and the vestibule. By palpation, however, it is easy to determine the position and limits of the neck of the uterus by its firm resistance.

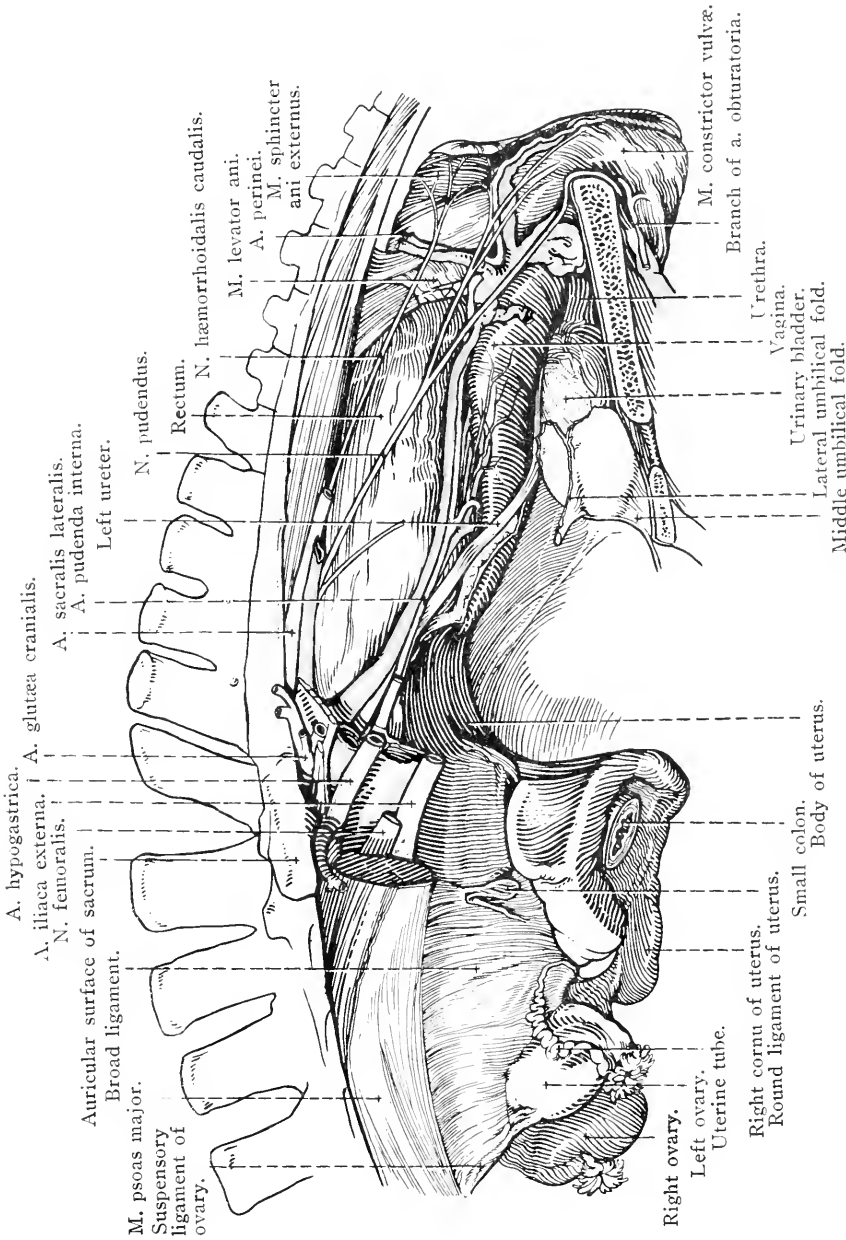


FIG. 80. — Dissection of the female reproductive organs. Left lateral aspect.

length (about 2 cm.) at its uterine extremity, where the recto-uterine excavation ends, the dorsal wall of the vagina is connected with the rectum by loose fibrous tissue. The ventral wall is in like manner associated with the vesico-uterine excavation for a short distance at its cranial end, and for the rest of its length is united by loose tissue to the bladder and urethra. The ureters run along the ventral-lateral borders of the vagina on their way to the neck of the bladder.

The loose perivaginal tissue contains plexiform veins and a variable amount of fat.

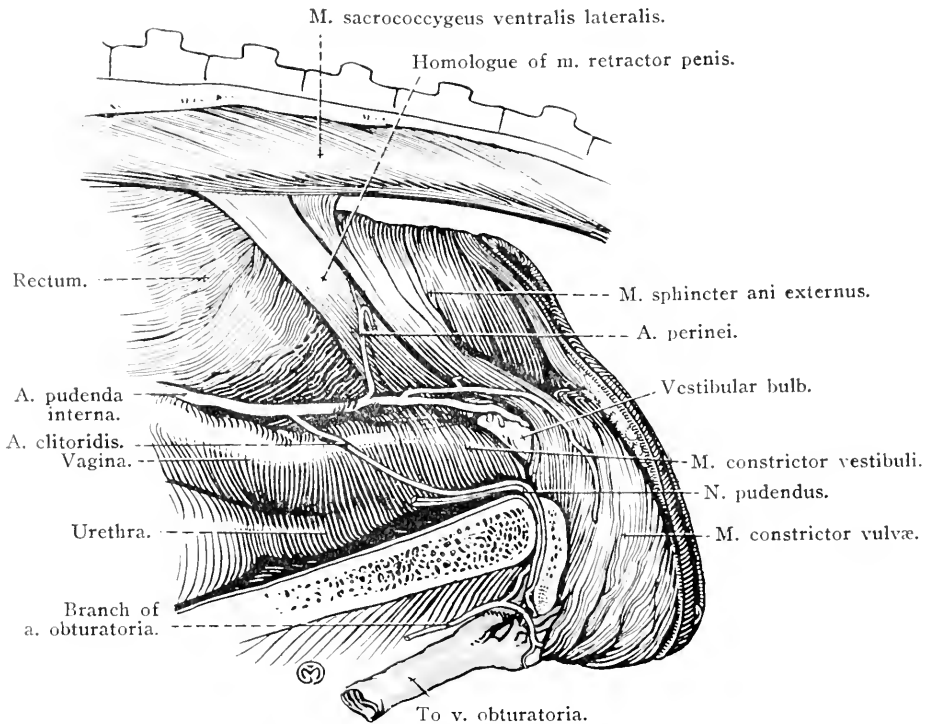


FIG. 81.—Dissection of female pelvis.

It is of surgical moment to note that the backward extension of the recto-uterine and vesico-uterine excavations varies with the degree of distension of the rectum and urinary bladder. When these organs are empty the excavations are continued further backwards than when the bowel is loaded with fæces and the bladder is full of urine. Consequently, the peritoneal relations of the vagina may be fairly extensive or scarcely present.

The *vestibule*<sup>1</sup> (*vestibulum vaginae*) continues the vagina to the external genital parts or vulva, and is in the form of a tube about 12

<sup>1</sup> *Vestibulum* [L.], an antechamber.



cm. in length. Its dorsal wall is in contact with the rectum, with which it is connected by loose fibrous tissue. Its ventral wall rests on the floor of the pelvis; while laterally the vestibule is covered by the levator ani muscle.

A constrictor muscle (m. constrictor vestibuli) covers the ventral and lateral walls of the vestibule, some of the fibres of the muscle becoming lost on the wall of the rectum.

*Vulva*.<sup>1</sup>—No sharp line of demarcation distinguishes the vestibule from the vulva, the external opening of which (*rima pudendi*) is a vertical elongated slit with dorsal and ventral *commissures* (*commissura dorsalis*: *commissura ventralis*), of which the ventral is the more rounded. The margins of the opening are formed by the prominent and rounded *labia pudendi*.

Immediately within the ventral commissure of the vulva is the *clitoris*, the homologue of the penis of the male. The rounded free end of the clitoris is the *glans* (*glans clitoridis*). The *body* (*corpus clitoridis*) is formed by two *corpora cavernosa clitoridis* which diverge to form the *crura* (*crura clitoridis*) attached to the sciatic arch. The glans of the clitoris reposes in a *fossa clitoridis*, and is provided with a small fold of membrane, the *prepuce of the clitoris* (*præputium clitoridis*).

A very small and inconspicuous ischio-cavernous muscle arises from the ischium and ends on the clitoris. A constrictor muscle of the vulva (m. constrictor vulvæ) lies between the skin and the mucous membrane and is connected with the external sphincter of the anus. This, with the constrictor of the vestibule, may be regarded as the homologue of the bulbo-cavernous muscle of the male.

*Vestibular bulbs* (*bulbi vestibuli*).—If the constrictor muscle of the vestibule be removed, an elongated mass of erectile tissue will be exposed on each side. These are the vestibular bulbs, which correspond to the bulb of the urethra of the male. Blood is carried to each bulb by a large branch of the internal pudendal artery.

A. PUDENDA INTERNA.—The internal pudendal artery has the same general course and disposition as in the male; but differences in the female pelvic organs necessitate peculiarities of distribution. The vessel ends by dividing into the *perineal artery* (*a. perinei*) and the *artery of the clitoris* (*a. clitoridis*). The middle hæmorrhoidal artery is larger than that of the male, and furnishes a *caudal uterine artery* (*a. uterina caudalis*), which supplies the vagina and the body of the uterus, and

<sup>1</sup> *Vulva* [L.], a wrapper or covering. The word *vulva* or *volva* seems to have been originally applied to the uterus. Horace is said to have used *volva* when referring to the uterus of the pig as a favourite dish.

anastomoses with the middle uterine artery, the vessel corresponding to the external spermatic of the male.

*Dissection.* Remove the pelvic organs. Separate the vagina and vestibule from the rectum, and make a longitudinal incision through the dorsal wall of the whole reproductive canal.

INTERIOR OF THE UTERUS.—The soft mucous membrane of the body and cornua of the uterus is raised into irregular and interrupted

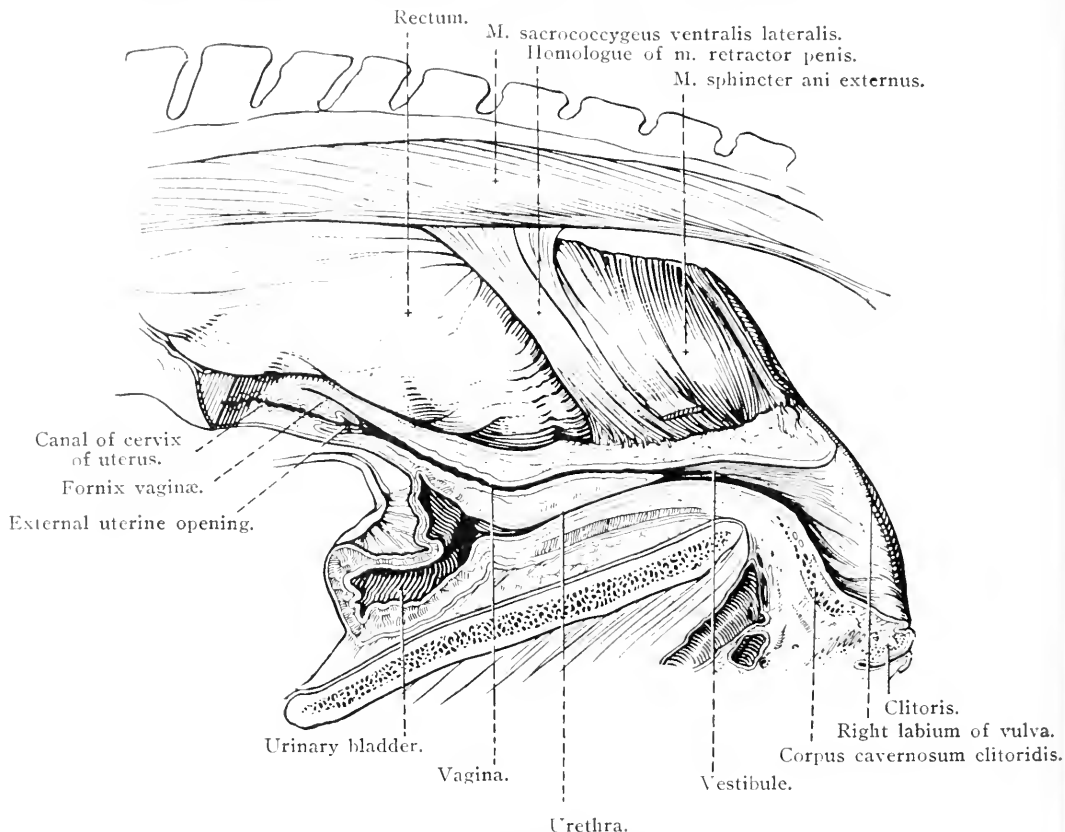


FIG. 82.—Viscera of the female pelvis, with reproductive and urinary organs in longitudinal section.

folds that become more prominent as the cervix is approached. At the extreme end of each cornu there is a small firm papilla, on the summit of which is the opening of the uterine tube (*ostium uterinum tubæ*).

The cervix of the uterus is readily distinguished by the greater thickness of its wall and the narrowness of its lumen. The *canal of the cervix* (*canalis cervicis*) is about 6 cm. in length, and communicates with the cavity of the body of the uterus by the *internal uterine opening* (*orificium uteri internum*). The vaginal end of the cervix projects into the cavity of the vagina as a rounded prominence (*portio vaginalis*

uteri), on which is the puckered *external uterine opening*<sup>1</sup> (orificium uteri externum). The interior of the canal of the cervix is occupied by numerous and prominent longitudinal folds (plicæ cervicis), which are continued beyond the external uterine opening, and give this opening its characteristic puckered appearance.

INTERIOR OF THE VAGINA.—The mucous lining of the vagina is thrown into low longitudinal folds. Because of the projection of the cervix of the uterus into the vagina, an arch-like continuity of the mucous membrane of the two organs is produced (fornix vaginae). It should be noted that the fornix is formed by that part of the vagina that is covered by peritoneum, so that an incision through the wall of the vagina in the fornix will produce an opening into the peritoneal cavity.

INTERIOR OF THE VESTIBULE.—On the ventral wall of the vestibule, close to its junction with the vagina proper, is the conspicuous *external opening of the urethra* (orificium urethræ externum).

The *female urethra* (urethra femiina) is a short (5-7 cm.) but wide and very dilatable tube, homologous with that portion of the male urethra that extends from the neck of the bladder to the seminal colliculus. It lies in the middle line ventral to the vagina, with which its caudal moiety is intimately connected. It is surrounded by a urethral muscle, which is continuous with the constrictor of the vestibule.

A fold of mucous membrane, between the urethral opening and the vagina, and extending for a variable distance on to the lateral wall of the genital passage, is all that can be said to represent a hymen.

If the wall of the vestibule be examined carefully, two rows of small papillæ should be found on each side. The papillæ of the dorsal row are the larger, and number from eight to ten. Their summits are pierced by the ducts of the *larger vestibular glands* (glandulæ vestibulares majores). The papillæ of the ventral row are smaller, and the right and left rows converge towards the ventral commissure of the vulva. The ducts of the *lesser vestibular glands* (glandulæ vestibulares minores) open on these papillæ.

Complete the dissection of the female pelvis by an examination of the connection of the hip-bone with the vertebral column (see page 179).

<sup>1</sup> Frequently referred to as the *os uteri*.

ARTERIES OF THE ABDOMEN.

	<ul style="list-style-type: none"> <li>{ Ramus cranialis.</li> <li>{ Ramus caudalis.</li> <li>{ Ramus esophageus.</li> <li>{ Rami pancreatici.</li> <li>{ Aa. pancreatice.</li> <li>{ A. gastrica dextra.</li> <li>{ A. gastroduodenalis . . . . . { A. gastropiploica dextra.</li> <li>{ Rami pancreatici . . . . . { Ramus pancreaticus.</li> <li>{ Rami lienales . . . . . { Ramus duodenalis.</li> <li>{ Aa. gastrice breves.</li> <li>{ A. gastropiploica sinistra.</li> </ul>
A. colica . . . . .	<ul style="list-style-type: none"> <li>{ A. gastrica sinistra . . . . .</li> <li>{ A. hepatica . . . . .</li> <li>{ A. lienalis . . . . .</li> </ul>
A. mesenterica cranialis . . . . .	<ul style="list-style-type: none"> <li>{ Aa. intestinales.</li> <li>{ A. colica media.</li> <li>{ A. colica dorsalis.</li> </ul>
Aa. renales . . . . .	<ul style="list-style-type: none"> <li>{ A. ileocolica . . . . .</li> </ul>
A. mesenterica caudalis . . . . .	<ul style="list-style-type: none"> <li>{ Aa. suprarenales.</li> <li>{ A. colica sinistra.</li> <li>{ A. hæmorrhoidalis cranialis.</li> </ul>
Aa. spermaticæ internæ . . . . .	<ul style="list-style-type: none"> <li>{ Ramus spinalis.</li> <li>{ Ramus dorsalis.</li> <li>{ A. circumflexa ilium profunda.</li> <li>{ A. spermatica externa.</li> </ul>
Aa. iliaçæ externæ . . . . .	<ul style="list-style-type: none"> <li>{ Truncus pudentoepigastricus.</li> <li>{ A. femoralis.</li> </ul>
Aa. hypogastricæ . . . . .	<ul style="list-style-type: none"> <li>{ A. profunda femoris . . . . . { A. circumflexa femoris medialis.</li> <li>{ A. pudenda externa . . . . . { Rami profundi penis.</li> <li>{ A. epigastrica caudalis . . . . . { A. dorsalis penis.</li> </ul>
A. sacralis lateralis . . . . .	<ul style="list-style-type: none"> <li>{ A. umbilicalis . . . . . { Aa. vesicales craniales.</li> <li>{ A. hæmorrhoidalis media . . . . . { A. deferentialis.</li> <li>{ A. perinei.</li> <li>{ A. bulbi urethrae.</li> </ul>
A. sacralis media . . . . .	<ul style="list-style-type: none"> <li>{ A. circumflexa femoris lateralis.</li> <li>{ Rami spinales.</li> <li>{ A. glutea caudalis.</li> <li>{ A. coccygea.</li> <li>{ A. caudalis lateralis ven- . . . . . { A. caudalis lateralis dorsalis</li> <li>{ tralis . . . . .</li> </ul>

NERVE AND BLOOD SUPPLY OF THE MUSCLES OF THE THORAX AND ABDOMEN.

<i>Nerve Supply.</i>		<i>Blood Supply.</i>
Thoracic . . . . .	{ M. serratus dorsalis.	Intercostal.
	{ M. iliocostalis.	Intercostal.
Thoracic and lumbar.	{ M. longissimus dorsi.	Deep cervical, transverse artery, of the neck, intercostal and lumbar.
	{ M. spinalis (et semispinalis) dorsi et cervicis.	Deep cervical, transverse artery of the neck, intercostal and lumbar.
Cervical and thoracic.	M. longissimus cervicis.	Deep cervical, transverse artery of the neck and intercostal.
Thoracic and lumbar.	M. multifidus dorsi.	Intercostal and lumbar.
Lumbar . . . . .	M. intertransversales lumborum.	Lumbar.
Intercostal . . . . .	{ Mm. levatores costarum.	Intercostal.
	{ Mm. intercostales.	Intercostal, internal thoracic and musculo-phrenic.
	{ M. transversus costarum.	External thoracic and internal thoracic.
Phrenic . . . . .	{ M. transversus thoracis.	Internal thoracic.
	Diaphragm.	Musculo-phrenic, cranial phrenic and deep circumflex iliac.
Intercostal, ilio-hypogastric and ilio-inguinal. . . . .	{ M. obliquus externus abdominis.	Intercostal, lumbar and deep circumflex iliac.
	{ M. transversus abdominis.	Intercostal, musculo-phrenic, lumbar and deep circumflex iliac.
	{ M. rectus abdominis.	Cranial and caudal epigastric.
Intercostal, ilio-hypogastric, ilio-inguinal and genito-femoral.	{ M. obliquus internus abdominis.	Intercostal, lumbar and deep circumflex iliac.
	M. cremaster externus.	External spermatic.
Lumbar . . . . .	{ M. psoas minor.	Intercostal, lumbar and deep circumflex iliac.
	{ M. quadratus lumborum.	Lumbar.

NERVE AND BLOOD SUPPLY OF THE MUSCLES OF THE  
THORAX AND ABDOMEN—*continued.*

<i>Nerve Supply.</i>		<i>Blood Supply.</i>
Lumbar and femoral.	{ M. psoas major. M. iliacus.	Intercostal, lumbar and deep circumflex iliac. Lumbar, deep circumflex iliac and lateral circumflex artery of the thigh.
Pudendal . . . . .	{ M. coccygens. M. levator ani.	Internal pudendal and (middle) coccygeal. Internal pudendal.
Hæmorrhoidal . . . . .	M. sphincter ani.	Perineal.
Coccygeal . . . . .	{ M. sacrococcygens dorsalis medialis. M. sacrococcygens dorsalis lateralis. Mm. intertransversarii. M. sacrococcygens ventralis lateralis. M. sacrococcygens ventralis medialis.	Lateral caudal.

## LYMPH GLANDS OF THE THORAX AND ABDOMEN.

<i>Afferents.</i>		<i>Efferents.</i>
Cranial, middle, and superficial cervical, axillary and cranial mediastinal glands.	Lgg. cervicales caudales.	Thoracic duct. Right lymphatic duct.
Trachea, œsophagus, heart, pericardium, pleura and thymus. Bronchial glands.	Lgg. mediastinales craniales.	Thoracic duct. Caudal cervical glands.
Lungs. Caudal mediastinal glands.	Lgg. bronchiales.	Thoracic duct. Cranial mediastinal glands.

LYMPH GLANDS OF THE THORAX AND ABDOMEN—*continued.*

<i>Afferents.</i>	<i>Lgg. mediastinales caudales.</i>	<i>Efferents.</i>
Œsophagus, diaphragm, liver, mediastinum, pleura and lungs.	<i>Lgg. mediastinales caudales.</i>	Thoracic duct. Bronchial and cranial mediastinal glands.
Thoracic vertebræ, vertebral canal, muscles of the back, intercostal muscles, diaphragm and pleura.	<i>Lgg. intercostales.</i>	Thoracic duct.
Lumbar vertebræ, vertebral canal, lumbar muscles, kidneys, adrenals, small colon and genital organs.	<i>Lgg. lumbales.</i>	Thoracic duct.
Internal iliac, external iliac, superficial inguinal and deep inguinal glands.	<i>Lgg. iliacæ internæ.</i>	Lumbar glands.
Pelvic wall, pelvic viscera, perineum and tail. External iliac, superficial inguinal, deep inguinal, sacral and ischiatic glands.	<i>Lgg. iliacæ externæ.</i>	Lumbar and internal iliac glands.
Flank, ventral wall of abdomen and lateral face of the thigh. Subiliac glands.	<i>Lgg. inguinales superficiales.</i>	Lumbar, internal iliac and deep inguinal glands.
Ventral wall of abdomen, medial face of the thigh, prepuce, penis, scrotum and mammary glands.	<i>Lgg. sacrales.</i>	Internal iliac glands.
Stomach. Splenic glands.	<i>Lgg. gastricæ.</i>	Thoracic duct. Splenic glands.
Liver and pancreas.	<i>Lgg. hepaticæ.</i>	Thoracic duct.
Spleen and pancreas. Gastric glands (of left part of the greater curvature).	<i>Lgg. lienales.</i>	Thoracic duct. Gastric glands (of sacculus cæcus).
Small intestine.	<i>Lgg. mesentericæ.</i>	Thoracic duct.
Cæcum.	<i>Lgg. cæcales.</i>	Thoracic duct.
Colon (large and small).	<i>Lgg. colicæ.</i>	Thoracic duct. Lumbar glands.
Rectum.	<i>Lgg. rectales.</i>	Internal iliac glands.
Perineum and tail.	<i>Lgg. anales.</i>	Internal iliac glands.

## THE FŒTAL CIRCULATION.

During the period when the embryo is developing *in utero*, the respiratory and digestive organs do not function. Some special and temporary provision is therefore necessary whereby oxygenation of the blood and a supply of nutritive material may be assured. A highly vascular placenta is formed partly by the extra-embryonic portion of the ovum, and partly by the mucous membrane of the uterus of the

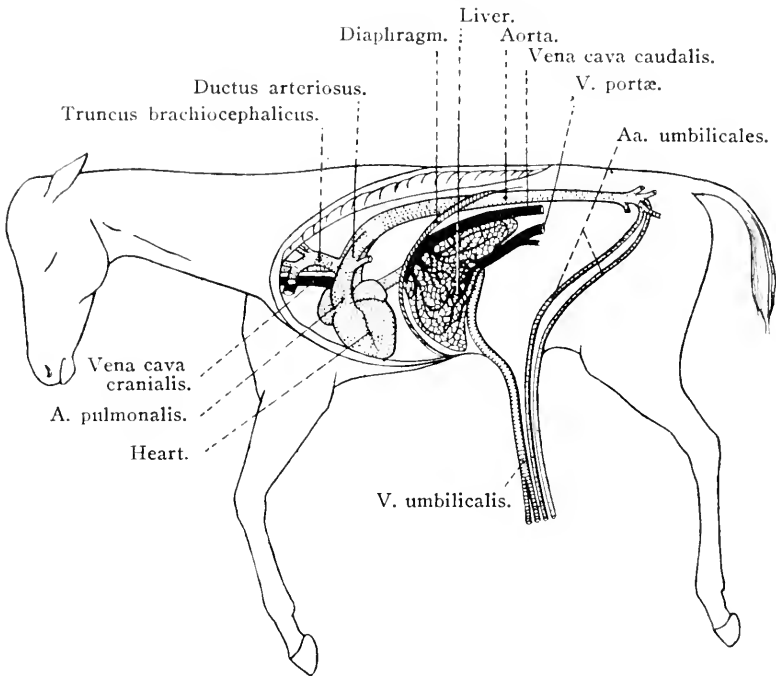


FIG. 83.—Fœtal circulation in the foal.

mother. An umbilical cord connects the placenta with the umbilicus of the embryo, and in the cord are contained the umbilical vessels through which the blood passes from the embryo to the placenta and back again.<sup>1</sup>

The blood is returned from the placenta to the embryo by two vessels that, in the horse, fuse into a single umbilical vein. This follows the free margin of the falciform ligament to the liver, where it joins the portal vein. In the majority of mammals the termination of the umbilical vein is connected with the caudal vena cava by a ductus venosus, in addition to the union effected with the portal vein. In the majority of mammals, therefore, some of the blood carried by the

<sup>1</sup> For an account of the early development of the circulation in the embryo, one of the standard works on embryology should be consulted.



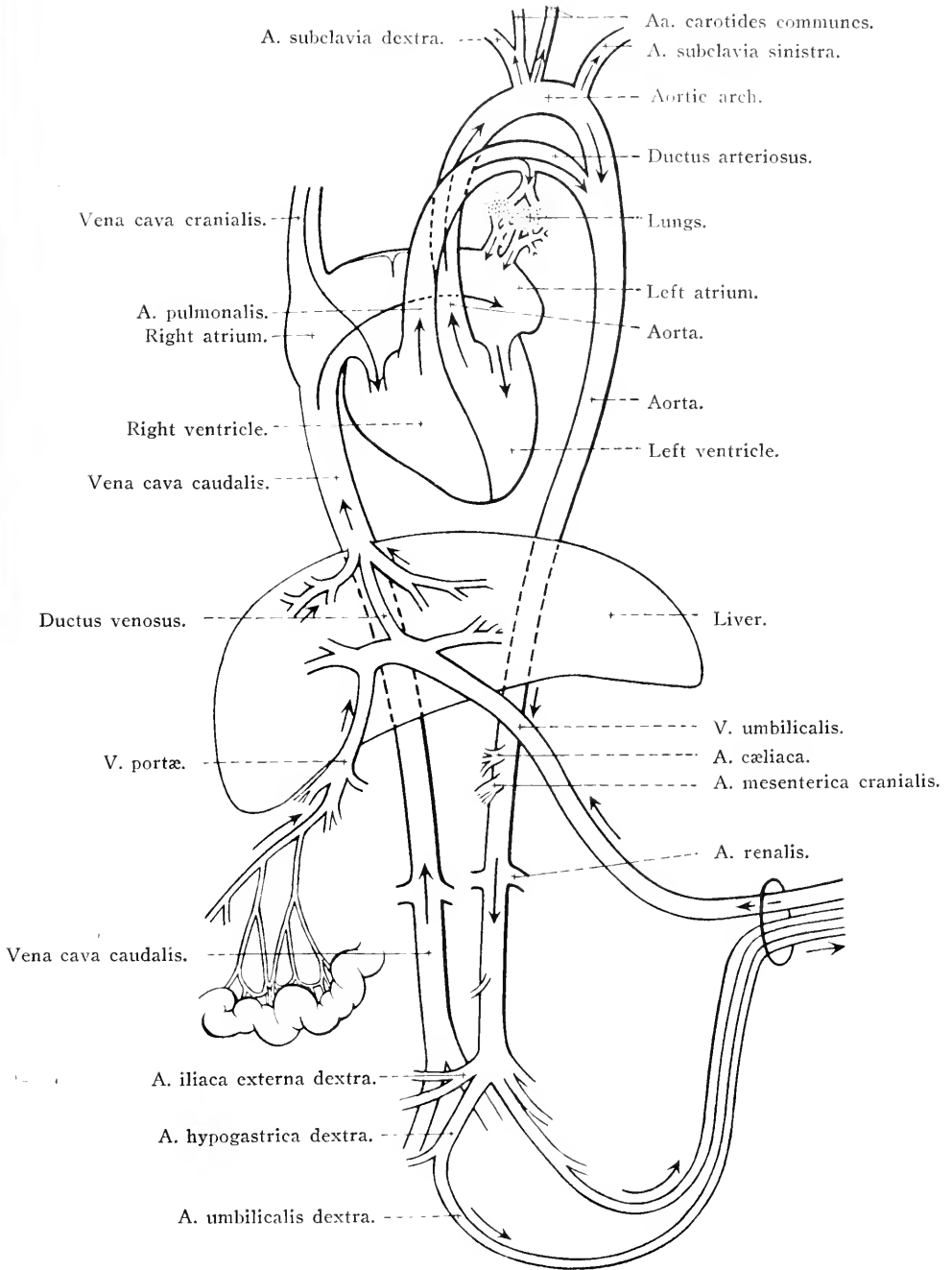


FIG. 84.—Diagram of the fetal circulation.

umbilical vein traverses the liver mixed with the blood that has been gathered from the intestines, stomach, spleen and pancreas; and some is conveyed by the ductus venosus direct to the vena cava. In the horse, the absence of a ductus venosus necessitates the passage through the liver of all the blood of the umbilical vein. The origin and course of the caudal vena cava is the same in the embryo as in the adult. Its opening into the right atrium, however, is directly facing the foramen ovale, an opening in the inter-atrial septum, and it appears probable that the blood brought to the heart by the caudal vena cava passes through the foramen into the left atrium.

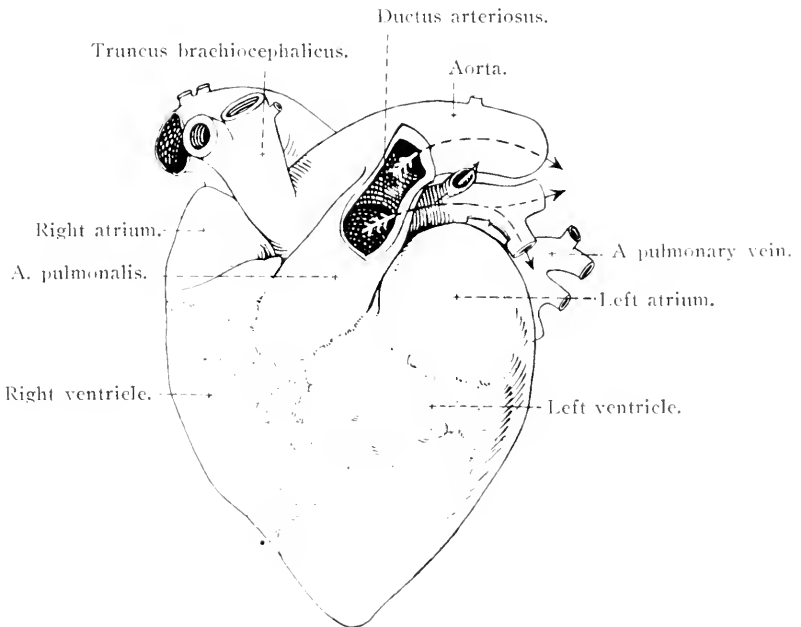


FIG. 85.—The fetal heart viewed from the left. The ductus arteriosus has been opened, and the arrows indicate the direction in which the blood flows.

Blood is collected from the head and neck, thoracic limbs and part of the wall of the thorax of the embryo in the same manner as in the adult, and consequently is carried to the right atrium by the cranial vena cava. From the right atrium it is sent into the right ventricle, and thence into the pulmonary artery. This artery furnishes a branch to each lung as in the adult; but, the lungs being unexpanded and as yet functionless, the greater part of the blood of the pulmonary artery is short-circuited into the aorta through the ductus arteriosus.

The blood of the caudal vena cava, gaining the left atrium by the foramen ovale, is there mixed with the relatively small quantity of blood brought from the lungs by the pulmonary veins. The mixed

blood is injected from the atrium into the left ventricle and thence into the aorta. By the branches of the aorta it is distributed to all parts of the body, except the lungs, as it is in the adult; but from each hypogastric artery there arises an umbilical artery that leaves the body of the embryo by the umbilicus and ends in the placenta.

It is apparent that the purest and most highly oxygenated blood in the embryo, as well as that richest in nutritive material, is that carried by the umbilical vein to the liver, where it is mixed with the portal venous blood. A further mixture with impure blood occurs when that of the caudal vena cava meets the pulmonary blood in the left atrium. A final contamination occurs in the aorta where the ductus arteriosus adds the blood that has been gathered by the cranial vena cava and transmitted through the right heart into the pulmonary artery. The aorta of the embryo, therefore, contains blood that is most heavily loaded with waste products and poorest in oxygen and nutritive material.

The changes that take place in the circulation at birth are as follows:—With the rupture of the umbilical cord blood ceases to flow through the umbilical arteries and vein. The former become the rounded cords (round ligaments) found in the free margin of the lateral umbilical folds of the urinary bladder of the adult, while the remains of the umbilical vein constitutes the round ligament of the liver. With the establishment of respiration the lungs are distended, and the branches of the pulmonary artery become sufficiently large to permit the passage through the lungs of all the blood ejected from the right ventricle. Blood ceases to flow through the ductus arteriosus, which loses its lumen and becomes the ligamentum arteriosum. At birth, also, the foramen ovale closes, and the blood carried to the heart by the caudal vena cava is then compelled to enter the right atrium. In those animals in which there is a ductus venosus in the embryo, its lumen is occluded at birth, and a ligamentum venosum is produced.

## INDEX.

- ABDOMINAL artery, subcutaneous, 76.  
 Abdominal cavity, 89.  
 Abdominal contents, 93.  
 Abdominal fascia, 82, 89.  
 Abdominal muscles, 82, 87.  
 Adrenal glands, 143.  
 Aggregated lymph nodules, 112.  
 Ampulla —  
   of ductus deferens, 165.  
   of rectum, 161.  
   of uterine tube, 139.  
 Anal canal, 161.  
 Anal lymph glands, 176.  
 Annulus portarum, 118.  
 Antrum pylori, 115.  
 Anus, 161.  
 Aortic hiatus, in diaphragm, 146.  
 Aortic opening, of heart, 35, 51.  
 Aortic plexus, 130.  
 Aortic sinuses, 36.  
 Apertures, pelvic, 156, 157.  
 Arch, aortic, 37.  
 Arch, costal, 11.  
 Arteria or arteriæ —  
   abdominalis subcutanea, 76.  
   aorta abdominalis, 146.  
   aorta thoracica, 36, 53.  
   brachiocephalica, 42.  
   bronchialis, 54.  
   bulbi urethrae, 167.  
   carotis communis, 43.  
   caudales laterales, 175.  
   cervicalis profunda, 41.  
   circumflexa femoris lateralis, 175.  
   circumflexa ilium profunda, 86, 149.  
   clitoridis, 185.  
   coccygea, 175.  
   colliaca, 124.  
   colica dorsalis, 110.  
   colica media, 110.  
   colica sinistra, 110.  
   colica ventralis, 110.  
   coronaria dextra, 29.  
   coronaria sinistra, 29.  
   costocervicalis, 41.  
   deferentialis, 167.  
   dorsalis penis, 77.  
   epigastrica caudalis, 85.  
   epigastrica cranialis, 52, 86.  
   gastricae breves, 125.  
   gastrica dextra, 126.  
   gastrica sinistra, 125.  
   gastro-piploica dextra, 128.  
   gastro-piploica sinistra, 125.  
   gastrooduodenalis, 128.  
   glutea caudalis, 174.  
   glutea cranialis, 175.  
   hæmorrhoidalis cranialis, 110, 168.  
   hæmorrhoidalis media, 167, 185.  
   hepatica, 125.  
   hepatica propria, 127.  
   hypogastrica, 173.  
   ileocecalis, 110.  
   ileocæcocolica, 110.  
   iliaca externa, 149.  
   iliolumbalis, 175.  
   intercostales, 7, 54.  
   intercostalis prima, 42.  
   intercostalis suprema, 41.  
   intestinales, 109.  
   lienalis, 125.  
   lumbales, 10, 149, 173.  
   mediastinalis cranialis, 12.  
   mesenterica caudalis, 110.  
   mesenterica cranialis, 109.  
   musculophrenica, 52.  
   nutritia ossis ilium, 175.  
   obturatoria, 80, 175.  
   oesophagea, 54.  
   ovarice, 149.  
   pancreaticoduodenalis, 128.  
   perinei, 167, 185.  
   pericardiophrenica, 52.  
   phrenicæ craniales, 54.  
   pudenda externa, 76.  
   pudenda interna, 167, 173, 185.  
   pulmonalis, 35.  
   renales, 147.  
   sacralis lateralis, 174.  
   sacralis media, 176.  
   spermatice externa, 149.  
   spermatice interna, 147.  
   subclavia dextra, 45.  
   subclavia sinistra, 41.  
   thoracica externa, 42.  
   thoracica interna, 42, 51.  
   thymicæ, 52.  
   transversa colli, 41.  
   truncus bicarotis, 38, 43.  
   truncus brachiocephalicus, 37, 39.  
   truncus costocervicalis, 42.  
   truncus bronchooesophageus, 53.  
   truncus omocervicalis, 42.  
   truncus pudendoepigastricus, 150.  
   umbilicalis, 167.

- Arteria or arteriæ—*continued*.  
 uterina caudalis, 185.  
 uterina media, 150.  
 vertebralis, 42.  
 vesicales craniales, 167.
- Arteries of the abdomen (Table), 188.
- Arteries of the thorax (Table), 67.
- Articulation or Articulations—  
 capitular, of ribs, 63.  
 costo-chondral, 52.  
 costo-transverse, 64.  
 costo-vertebral, 63.  
 interchondral, 53.  
 intersternal, 53.  
 sacro-iliac, 179.  
 sterno-costal, 52.  
 vertebral, 61.
- Atrio-ventricular bundle, 50.
- Atrio-ventricular orifices, 31, 32, 34, 51.
- Atrium of heart, left, 33.
- Atrium of heart, right, 30.
- Auricles, of heart, 26, 34.
- Axis pelvis, 182.
- Azygous vein, 24, 54, 151.
- BICAROTID trunk, 38.
- Bicuspid valve, 35.
- Bile duct, 123.
- Bladder, urinary, 163, 169.
- Blood supply of muscles (Tables), 189.
- Body or bodies—  
 cavernous, of penis, 77.  
 cavernous, of urethra, 78.  
 of epididymis, 71.  
 of seminal vesicle, 165.  
 of urinary bladder, 163.  
 of uterus, 134.
- Brachio-cephalic arterial trunk, 37, 39.
- Brachio-cephalic artery, 42.
- Broad ligaments, of uterus, 134.
- Bronchi, 21, 45.
- Bronchial artery, 54.
- Bronchial lymph glands, 22, 46.
- Broncho-oesophageal arterial trunk, 53.
- Broncho-oesophageal muscle, 46.
- Bulbo-cavernosus muscle, 79, 167.
- Bulb of urethra, 78, 171.
- Bulbo-urethral glands, 166.
- Bulb of vestibule, 185.
- Bundle, atrio-ventricular, 50.
- Bursa omentalis, 104.
- CÆCAL lymph glands, 111.
- Cæcocolic fold, 100.
- Cæcum, 94, 98.
- Canal—  
 anal, 161.  
 cervical, of uterus, 186.  
 inguinal, 84, 88.  
 milk, 68.
- Capitular articulation, of rib, 63.
- Caput epididymidis, 71.
- Caput pancreatis, 117.
- Cardia of stomach, 113.
- Cardiac nerves, 47.
- Cardiac plexus, 47, 48.
- Cardiac sphincter of stomach, 132.
- Cardiac veins, 29.
- Carotid (common) arteries, 43.
- Cauda epididymidis, 71.
- Cauda pancreatis, 117.
- Caudal arteries, 175.
- Caudal gluteal artery, 174.
- Caudal gluteal nerve, 178.
- Caudal hæmorrhoidal nerve, 169, 178.
- Caudal mesenteric artery, 110.
- Caudal uterine artery, 185.
- Caval foramen, in diaphragm, 146.
- Caval vein, caudal, 24, 150.
- Caval vein, cranial, 23.
- Cavities of the heart, 30.
- Cavity—  
 abdominal, 89.  
 pelvic, female, 181.  
 pelvic, male, 156.  
 thoracic, 10.
- Cellule of large intestine, 111.
- Centrum tendineum, of diaphragm, 145.
- Centrum verticis, of bladder, 164.
- Cervical (caudal) lymph glands, 45.
- Cervix uteri, 134.
- Chondro-xiphoid ligament, 53.
- Chorde tendineæ, 32.
- Circumflex artery of thigh, lateral, 175.
- Circumflex iliac artery, deep, 149.
- Circumflex iliac vein, deep, 150.
- Cisterna chyli, 55, 151.
- Clitoris, 185.
- Coccygeal artery, 175.
- Coccygeus muscle, 159.
- Coccygeal nerves, 178.
- Celiac artery, 124.
- Celiaco-mesenteric ganglia, 130.
- Celiac plexus, 130.
- Colic arteries, 110.
- Colic lymph glands, 111.
- Colic plexus, 130.
- Colic veins, 128, 129.
- Colliculus seminalis, 171.
- Collum glandis, 78.
- Collum vesicæ, 163.
- Colon—  
 great, 94, 100.  
 small, 96, 101.
- Commissures of vulva, 185.
- Conjugate diameter of pelvis, 182.
- Constrictor muscle, of vestibule, 185.
- Constrictor muscle, of vulva, 185.
- Contents of abdomen, 93.
- Conus arteriosus, 32.
- Cord, spermatic, 72, 140.
- Cornua uteri, 134.
- Corona glandis, 78.
- Coronary arteries, 29.
- Coronary ligament, of liver, 123.
- Corpus cavernosum penis, 77.
- Corpus cavernosum urethræ, 78.
- Corpus clitoridis, 185.
- Corpus epididymidis, 71.
- Corpus luteum, 139.
- Corpus uteri, 134.
- Corpus vesicæ, 163.

- Corpus vesiculae seminalis, 165.  
 Costal arch, 11.  
 Costal pleura, 12.  
 Costo-cervical arterial trunk, 42.  
 Costo-cervical artery, 41.  
 Costo-chondral articulations, 52.  
 Costo-mediastinal sinus, 14.  
 Costo-transverse articulation, 64.  
 Costo-vertebral articulation, 63.  
 Cranial gluteal artery, 175.  
 Cranial gluteal nerve, 178.  
 Cranial haemorrhoidal artery, 110, 168.  
 Cranial haemorrhoidal vein, 129.  
 Cranial mesenteric artery, 109.  
 Cremaster muscle, external, 71.  
 Cremaster muscle, internal, 72.  
 Crista terminalis, of heart, 30.  
 Crista urethralis, 169, 170.  
 Crura of penis, 78.  
 Crura of diaphragm, 145.  
 Crura of clitoris, 185.  
 Cryptorchism, 74.  
 Cupula pleurae, 14.  
 Curvatures of stomach, 114.  
 Cutaneous muscle, 80.  
 Cutaneous nerves—  
   dorsal, 8.  
   lateral, 9.  
   of thigh, lateral, 86, 155, 176.  
   of thigh, posterior, 178.
- DARTOS** tunic, 70.  
 Deep cervical artery, 41.  
 Deep circumflex iliac artery, 86, 149.  
 Deep circumflex iliac vein, 150.  
 Deferent duct, 72, 164.  
 Deferential artery, 167.  
 Descent of testis, 73.  
 Development of adrenals, 144.  
 Development of pancreas, 118.  
 Development of peritoneum, 105.  
 Diameters of pelvic inlet, 182.  
 Diaphragm, 145.  
 Diaphragmatic flexures of colon, 94, 100.  
 Diaphragmatic pleura, 14.  
 Diverticulum duodeni, 132.  
 Dorsal artery of penis, 77.  
 Dorsal colic artery, 110.  
 Dorsal costo-transverse ligament, 65.  
 Dorsal cutaneous nerve, 8.  
 Dorsal nerve of penis, 80, 169.  
 Dorsal oesophageal nerve trunk, 130.  
 Dorsum penis, 77.  
 Duct or Ducts—  
   deferent, 72, 164.  
   bile, 123.  
   ejaculatory, 165.  
   excretory, of bulbo-urethral glands,  
     166.  
   excretory, of seminal vesicle, 165.  
   of epididymis, 71.  
   pancreatic, 118.  
   right lymphatic, 55.  
   thoracic, 55.  
 Ductus arteriosus, 38.  
 Duodenum, 96, 117, 132.
- EJACULATORY** duct, 165.  
 Endocardium, 30, 50.  
 Endothoracic fascia, 10.  
 Epicardium, 23, 50.  
 Epididymis, 71.  
 Epigastric, caudal, artery, 85.  
 Epigastric, cranial, artery, 52, 86.  
 Epigastric veins, 86.  
 Epiploic foramen, 105.  
 Excavation—  
   recto-uterine, 135, 181.  
   vesico-uterine, 181.
- EXCRETORY** ducts, of bulbo-urethral glands,  
 166.  
 Excretory ducts, of seminal vesicles, 165.  
 External genital parts, female, 185.  
 External genital parts, male, 69.  
 External iliac artery, 149.  
 External pudendal artery, 76.  
 External spermatic artery, 149.  
 External spermatic nerve, 155, 176.
- FASCIA**—  
   abdominal, 82, 89.  
   endothoracic, 10.  
   iliac, 151.  
   lumbo-dorsal, 1.  
   pelvic, 161.  
   scrotal, 70.  
   transversalis, 161.
- Falciform ligament, 123.  
 Fallopian tube, 139.  
 Femoral nerve, 156, 178.  
 Fimbriae, of uterine tube, 139.  
 Fissure, umbilical, of liver, 122.  
**Flexure**—  
   dorsal diaphragmatic, 94, 100.  
   of duodenum, 117.  
   pelvic, 94, 100.  
   ventral diaphragmatic, 94, 100.
- FETAL** circulation, 192.  
**Fold or Folds**—  
   caeco-colic, 100.  
   gastro-pancreatic, 115.  
   ileo-caecal, 100.  
   of vena cava, 15.  
   umbilical, of bladder, 159.  
   ureteral, 169.  
   urogenital, 143, 159.
- FOLLICLES**, Graafian, 138.
- FORAMEN**—  
   caval, in diaphragm, 146.  
   epiploic, 105.  
   greater sciatic, 156.  
   lesser sciatic, 157.
- FORNIX** vaginae, 187.  
 Fossa clitoridis, 185.  
 Fossa glandis, 78.  
 Fossa ovalis, 31.  
 Fossa, ovulation, 136.  
 Fundus, of seminal vesicle, 165.  
 Fundus, of uterus, 134.
- GANGLION** or ganglia—  
   caudal cervical, 56.  
   caudal mesenteric, 130.

- Ganglion or ganglia—*continued*.  
 cœliaco-mesenteric, 130.  
 first thoracic, 57.  
 impar, 179.  
 lumbar, 156.  
 sacral, 179.  
 spinal, 59.  
 splanchnic, 144.  
 thoracic, 58.
- Gastric arteries, 125, 126.  
 Gastric lymph glands, 129.  
 Gastric plexus, 129, 130.  
 Gastric veins, 129  
 Gastro-duodenal artery, 128.  
 Gastro-duodenal vein, 129.  
 Gastro-epiploic arteries, 125, 128.  
 Gastro-epiploic veins, 129.  
 Gastro-hepatic ligament, 115.  
 Gastro-pancreatic fold, 115.  
 Gastro-phrenic ligament, 115.  
 Gastro-splenic ligament, 115.  
 Genito-femoral nerve, 155, 176.  
 Glans clitoridis, 185.  
 Glans penis, 78.  
 Gluteal arteries, 174, 175.  
 Gluteal nerves, 178.  
 Graafian follicles, 138.  
 Groove—  
   coronary, of heart, 26.  
   intermammary, 68.  
   longitudinal, of heart, 27.  
   terminal, of heart, 30.  
 Gubernaculum testis, 73.
- HÆMORRHOIDAL arteries, 110, 167, 168,  
 185.  
 Hæmorrhoidal nerves, 167, 178.  
 Hæmorrhoidal plexus, 130.  
 Hæmorrhoidal veins, 129.  
 Haustra, 98.  
 Head—  
   of epididymis, 71.  
   of pancreas, 117.  
 Heart, 24.  
 Heart, structure of, 49.  
 Hemiazygous vein, 55.  
 Hepatic arteries, 125, 127.  
 Hepatic lymph glands, 129.  
 Hepatic plexus, 130.  
 Hepatic veins, 129, 150.  
 Hepato-duodenal ligament, 117.  
 Hepato-renal ligament, 123.  
 Hiatus aorticus, 146.  
 Hiatus œsophageus, 146.  
 Hilus—  
   of lung, 18.  
   of spleen, 120.  
   renal, 142.  
 Hymen, 187.  
 Hypogastric artery, 173.  
 Hypogastric plexus, 169.  
 Hypogastric vein, 175.
- ILEO-CÆCAL artery, 110.  
 Ileo-cæcal fold, 100.
- Ileo-cæcal vein, 128.  
 Ileo-cæco-colic artery, 110.  
 Ileum, 96.  
 Iliac artery, external, 149.  
 Iliac artery, deep circumflex, 149.  
 Iliac fascia, 151.  
 Iliac lymph glands, 150.  
 Iliacus muscle, 152.  
 Iliac veins, 150, 151.  
 Ilio-costalis muscle, 3.  
 Ilio-hypogastric nerve, 86, 153, 176.  
 Ilio-inguinal nerve, 86, 155, 176.  
 Ilio-lumbar artery, 175.  
 Ilio-lumbar ligament, 180.  
 Ilio-psoas muscle, 152.  
 Inclination of pelvis, 182.  
 Infundibulum, of uterine tube, 139.  
 Inguinal canal, 84, 88.  
 Inguinal ligament, 84.  
 Inlet, pelvic, 156, 181.  
 Interarticular ligament, 64.  
 Interchondral ligaments, 53.  
 Intercostal arteries, 7, 41, 42, 54.  
 Intercostal lymph glands, 54.  
 Intercostal muscles, 6, 7.  
 Intercostal spaces, 11.  
 Intercostal nerves, 8, 86.  
 Intercostal veins, 8.  
 Interior of—  
   duodenum, 132.  
   heart, 30.  
   intestines, 111.  
   stomach, 131.  
   urethra, 170.  
   urinary bladder, 169.  
   uterus, 186.  
   vagina, 187.  
   vestibule, 187.  
 Intermammary groove, 68.  
 Intermediate lobe of lung, 18.  
 Internal pudendal artery, 167, 173, 185.  
 Internal pudendal vein, 167.  
 Internal spermatic arteries, 147.  
 Internal spermatic nerve, 130.  
 Internal spermatic veins, 150.  
 Interspinal ligament, 62.  
 Intersternal synchondroses, 53.  
 Intertransversales lumborum muscles, 5.  
 Intertransverse ligament, 63.  
 Intervenous tubercle of heart, 31.  
 Interventricular septum, 32, 34.  
 Intervertebral fibrocartilages, 61.  
 Intestinal arteries, 109.  
 Intestinal lymphatic trunks, 151.  
 Intestinal veins, 128  
 Intestines, 94, 96, 98, 111, 112.  
 Ischio-cavernosus muscle, 79, 185.  
 Ischio-urethral muscle, 167.  
 Isthmus, of prostate, 164.  
 Isthmus, of urethra, 166, 170.  
 Isthmus of uterine tube, 139.
- JEJUNUM, 96.
- KIDNEYS, 140.

- LABIA pudendi, 185.  
 Large intestine, 94, 98.  
 Lateral cutaneous nerve of thigh, 86, 155.  
 Lateral cutaneous nerve (ramus), 9.  
 Lateral iliac lymph glands, 150.  
 Lateral sacral artery, 174.  
 Left colic artery, 110.  
 Left colic vein, 129.  
 Left gastro-epiploic artery, 125.  
 Left gastro-epiploic vein, 129.  
 Levator ani muscle, 162.  
 Levatores costarum muscles, 5.  
 Ligament or Ligaments—  
   arteriosum, 37.  
   broad, of uterus, 134.  
   coronary, of liver, 123.  
   chondro-xiphoid, 53.  
   dorsal costo-transverse, 65.  
   falciform, 123.  
   flava, 62.  
   gastro-hepatic, 115.  
   gastro-phrenic, 115.  
   gastro-splenic, 115.  
   hepato-duodenal, 117.  
   hepato-renal, 123.  
   ilio-lumbar, 180.  
   inguinal (of Poupart), 84.  
   interarticular, 61.  
   interchondral, 53.  
   interspinal, 62.  
   intertransverse, 63.  
   longitudinal, of vertebral column, 61.  
   nuchal, 62.  
   of neck of rib, 65.  
   phrenico-splenic, 120.  
   proper, of ovary, 137.  
   proper sternal, 53.  
   pulmonary, 14.  
   radiate, costo-vertebral, 64.  
   radiate, sterno-costal, 53.  
   reno-duodenal, 117.  
   reno-splenic, 120.  
   round, of bladder, 159.  
   round, of liver, 123.  
   round, of uterus, 136.  
   sacro-iliac, 179.  
   sacro-spinous, 180.  
   sacro-tuberous, 180.  
   sterno-pericardiac, 22.  
   supraspinal, 62.  
   suspensory, of mammary gland, 69.  
   suspensory, of ovary, 136, 137.  
   suspensory, of penis, 77.  
   suspensory, of spleen, 120.  
   triangular, of liver, 123.  
 Limbus fosse ovalis, 31.  
 Linea alba, 87.  
 Linea terminalis, 93.  
 Liver, 120, 132.  
 Lobes of liver, 122.  
 Lobes of lung, 18.  
 Lobes of prostate, 164.  
 Longissimus cervicis muscle, 4.  
 Longissimus costarum muscle, 3.  
 Longissimus dorsi muscle, 3.  
 Longitudinal ligaments of vertebral column, 61.  
 Longus colli muscle, 58.  
 Lumbar arteries, 10, 149, 173.  
 Lumbar lymphatic trunks, 151.  
 Lumbar lymph glands, 147.  
 Lumbar nerves, 10, 153, 176.  
 Lumbar veins, 150.  
 Lungs, 16.  
 Lymphatic duct, right, 55.  
 Lymph glands—  
   anal, 176.  
   bronchial, 22, 46.  
   cecal, 111.  
   cervical, 45.  
   colic, 111.  
   gastric, 129.  
   hepatic, 129.  
   iliac, 150.  
   intercostal, 54.  
   lumbar, 147.  
   mediastinal, 45, 46.  
   mesenteric, 111.  
   pelvic, 176.  
   rectal, 176.  
   renal, 144.  
   sacral, 176.  
   splenic, 129.  
   subiliac, 87.  
   superficial inguinal, 69.  
 Lymph glands of thorax and abdomen (Table), 190.  
 Lymph nodules, aggregated, 112.  
 MAMMARY glands, 68.  
 Margo plicatus, 131.  
 Medial iliac lymph glands, 150.  
 Mediastinal arteries, 42.  
 Mediastinal lymph glands, 45, 46.  
 Mediastinal septum, 12, 15.  
 Mediastinal pleura, 12, 15.  
 Mediastinum testis, 75.  
 Mesenteric artery, caudal, 110.  
 Mesenteric artery, cranial, 109.  
 Mesenteric ganglia, 130.  
 Mesenteric lymph glands, 111.  
 Mesenteric plexus, 130.  
 Mesenteric veins, 110, 128.  
 Mesentery—  
   of small intestine, 96, 107.  
   colic, 107.  
 Mesoduodenum, 96.  
 Mesogastrium, 105.  
 Mesometrium, 136.  
 Mesorchium, 73.  
 Mesorectum, 161.  
 Mesosalpinx, 136, 139.  
 Mesovarium, 136, 137.  
 Middle colic artery, 110.  
 Middle hæmorrhoidal artery, 167, 185.  
 Middle hæmorrhoidal nerve, 169.  
 Middle sacral artery, 176.  
 Middle uterine artery, 150.  
 Milk canals, 68.  
 Milk sinus, 68.  
 Multifidus dorsi muscle, 5.



Muscles of thorax and abdomen (Table), 189.

Musculo-phrenic artery, 52.

Musculus or Musculi—

- bronchoœsophageus, 46.
- bulboœavernosus, 79, 167.
- coccygeus, 159.
- constrictor vestibuli, 185.
- constrictor vulvæ, 185.
- cremaster externus, 71.
- cremaster internus, 72.
- cutaneus, 80.
- diaphragma, 145.
- iliacus, 152.
- iliocostalis, 3.
- iliopsoas, 152.
- intercostales externi, 6.
- intercostales interni, 7.
- intertransversales lumborum, 5.
- intertransversarii, 172.
- ischioœavernosus, 79, 185.
- ischiourethralis, 167.
- levator ani, 162.
- levatores costarum, 5.
- longissimus, cervicis, 4.
- longissimus costarum, 3.
- longissimus dorsi, 3.
- longus colli, 58.
- multifidus dorsi, 5.
- obliquus externus abdominis, 82.
- obliquus internus abdominis, 84.
- obturator internus, 171.
- papillares, 32, 35.
- pectinati, 30.
- pleuroœsophageus, 46.
- prostaticus, 166.
- psoas major, 152.
- psoas minor, 152.
- quadratus lumborum, 153.
- rectococcygeus, 162.
- rectus abdominis, 85.
- retractor costæ, 84.
- retractor penis, 80, 162.
- sacrococcygei dorsales, 171.
- sacrococcygei ventrales, 172.
- serrati dorsales, 1.
- sphincter ani, 161, 162.
- sphincter cæci, 99.
- sphincter cardiæ, 132.
- sphincter ilei, 99.
- sphincter pylori, 115, 131.
- sphincter vesicæ, 170.
- spinalis (et semispinalis) dorsi et cervicis, 5.
- transversi cordis, 32.
- transversus abdominis, 87.
- transversus costarum, 6.
- transversus thoracis, 51.
- urethralis, 166.

Myocardium, 49.

NECK of uterus, 134.

Neck of urinary bladder, 163.

Nerve supply of muscles (Table), 189.

Nervus or Nervi—

- cardiaci, 47.

Nervus or Nervi—*continued.*

- coccygei, 178.
- cutaneus dorsalis, 8.
- cutaneus femoris lateralis, 86, 155, 176.
- cutaneus femoris posterior, 178.
- cutaneus lateralis, 9.
- dorsalis penis, 80, 169.
- femoralis, 156, 178.
- genitofemoralis, 155, 176.
- glutæus caudalis, 178.
- glutæus cranialis, 178.
- hæmorrhoidalis caudalis, 169, 178.
- hæmorrhoidalis medius, 169.
- iliohypogastricus, 86, 153, 176.
- ilioinguinalis, 86, 153, 176.
- intercostales, 8, 86.
- ischiadicus, 178.
- lumbales, 10, 153, 176.
- obturatorius, 178.
- perinei, 169.
- phrenicus, 22.
- pubendus, 168, 178.
- recurrens, 48.
- sacrales, 176.
- saphenus, 156.
- spermaticus externus, 155, 176.
- spermaticus internus, 130.
- spinales, 59.
- splanchnicus major, 58, 144.
- splanchnicus minor, 58, 144.
- sympathicus, 56, 156, 169.
- thoracales, 8, 86.
- truncus œsophageus dorsalis, 47, 130.
- truncus œsophageus ventralis, 47, 129.
- vagus, 46.

Node of Keith and Flack, 50.

Node of Kawara, 50.

Nutrient artery of ilium, 175.

OBLIQUE abdominal muscles, 82.

Oblique diameter of pelvis, 182.

Obturator artery, 80, 175.

Obturator muscle, internal, 171.

Obturator nerve, 178.

œsophageal artery, 54.

œsophageal hiatus, in diaphragm, 146.

œsophageal nerve trunks, 47, 129.

œsophageal plexus, 48.

œsophagus, 46.

Omental bursa, 104.

Omentum, greater, 94, 103.

Omentum, lesser, 103.

Omo-cervical arterial trunk, 42.

Openings in diaphragm, 146.

Orifice—

- abdominal, of uterine tube, 139.
- aortic, of heart, 35, 51.
- atrio-ventricular, 31, 32, 34, 51.
- external uterine, of cervical canal, 187.
- internal uterine, of cervical canal, 186.
- preputial, 75.
- pulmonary, of heart, 33.
- urethral, external, 78, 187.
- urethral, internal, 170.
- uterine, of uterine tube, 139, 186.

Ostium. *See* Orifice.

- Outlet, pelvic, 157.  
 Ovarian arteries, 149.  
 Ovarian bursa, 139.  
 Ovarian fimbriae, of uterine tube, 139.  
 Ovaries, 136.  
 Ovulation fossa, 136.
- PANCREAS, 117.  
 Pancreatic ducts, 118.  
 Pancreatico-duodenal artery, 128.  
 Pancreatico-duodenal vein, 129.  
 Pampiniform plexus, 72.  
 Paroophoron, 139.  
 Papilla, common renal, 143.  
 Papillary muscles, 32, 35.  
 Pectinate muscles, 30.  
 Pelvic apertures, 156, 157.  
 Pelvic cavity, 156.  
 Pelvic contents, female, 180.  
 Pelvic contents, male, 158.  
 Pelvic fascia, 161.  
 Pelvic flexure of colon, 94, 100.  
 Pelvic lymph glands, 176.  
 Pelvic peritoneum, 158.  
 Pelvis, renal, 143.  
 Penis, 77.  
 Pericardium, 12, 22.  
 Perineal artery, 167, 185.  
 Pericardiaco-phrenic artery, 52.  
 Pericardiac pleura, 14.  
 Peritoneum, 101, 158, 181.  
 Peyer, lymph nodules of, 112.  
 Phrenic arteries, 54.  
 Phrenic nerve, 22.  
 Phrenic veins, 150.  
 Phrenico-costal sinus, 14.  
 Phrenico-splenic ligament, 120.  
 Plexus or Plexuses—  
   aortic, 130.  
   cardiac, 47, 48.  
   coliac, 130.  
   colic, 130.  
   gastric, 129, 130.  
   haemorrhoidal, 130.  
   hepatic, 130.  
   hypogastric, 169.  
   mesenteric, 130.  
   oesophageal, 48.  
   pampiniform, 72.  
   pulmonary, 47.  
   renal, 130.  
   spermatic, 130.  
   splenic, 130.  
   tracheal, 48.  
   utero-ovarian, 130.
- Pleura, 12.  
 Pleno-oesophageal muscle, 46.  
 Plica. *See* Fold.  
 Porta hepatis, 121.  
 Portal ring, of pancreas, 118.  
 Portal vein, 128.  
 Poupart's (inguinal) ligament, 84.  
 Prepuce, of penis, 75.  
 Prepuce, of clitoris, 185.  
 Process, caudate, of liver, 122.  
 Process, omental, of liver, 122.  
 Processus dorsalis glandis, 78.  
 Proper ligament of ovary, 137.  
 Prostate, 164.  
 Prostatic muscle, 166.  
 Prostatic utricle, 165.  
 Psoas muscles, 152.  
 Pudendal arteries, 76, 167, 173, 185.  
 Pudendal nerve, 168, 178.  
 Pudendal veins, 77, 167.  
 Pudendo-epigastric arterial trunk, 150.  
 Pulmonary artery, 35.  
 Pulmonary ligament, 14.  
 Pulmonary opening, of heart, 33, 51.  
 Pulmonary pleura, 14.  
 Pulmonary veins, 20, 34.  
 Pyloric antrum, 115.  
 Pyloric sphincter, 115, 131.  
 Pylorus, 115.
- QUADRATUS lumborum muscle, 153.
- RADIATE ligament, 64.  
 Raphe seroti, 69.  
 Rectal lymph glands, 176.  
 Recto-coecygeus muscle, 162.  
 Recto-uterine excavation, 135, 181.  
 Rectum, 161.  
 Recurrent nerve, 48.  
 Renal arteries, 147.  
 Renal hilus, 142.  
 Renal lymph glands, 144.  
 Renal papilla, common, 143.  
 Renal pelvis, 143.  
 Renal plexus, 130.  
 Renal sinus, 142.  
 Renal veins, 150.  
 Reno-duodenal ligament, 117.  
 Reno-splenic ligament, 120.  
 Retractor costae muscle, 84.  
 Retractor penis muscle, 80, 162.  
 Right colic artery, 110.  
 Right colic vein, 128.  
 Right gastro-epiploic artery, 128.  
 Right gastro-epiploic vein, 129.  
 Right lymphatic duct, 55.  
 Ring—  
   portal, of pancreas, 118.  
   prepatial, 76.  
   vaginal, 71.
- Root of lungs, 20.  
 Round ligament, of bladder, 159.  
 Round ligament, of liver, 123.  
 Round ligament, of uterus, 136.
- SACRAL artery, lateral, 174.  
 Sacral artery, middle, 176.  
 Sacral ganglia, 179.  
 Sacral lymph glands, 176.  
 Sacral nerves, 176.  
 Sacro-coecygeal muscles, 171.  
 Sacro-iliac ligaments, 179.  
 Sacro-spinous ligament, 180.  
 Sacro-tuberous ligament, 180.  
 Saphenous nerve, 156.  
 Sciatic foramina, 156, 157.  
 Sciatic nerve, 178.

- Scrotum, 69.  
 Semilunar valves, 33, 35, 48.  
 Seminal colliculus, 171.  
 Seminal vesicles, 165.  
 Septum interatrial, 31.  
 Septum interventricular, 32, 34.  
 Septum mediastinal, 12, 15.  
 Septum penis, 77.  
 Septum scroti, 70.  
 Serrati dorsales muscles, 1.  
 Sheath of rectus abdominis muscle, 87.  
 Sinus or sinuses—  
   aortic, 36.  
   costo-mediastinal, 14.  
   epididymidis, 73.  
   milk, 68.  
   phrenico-costal, 14.  
   renal, 142.  
   transverse, of pericardium, 23.  
   vertebral venous, longitudinal, 61.  
 Small intestine, 96.  
 Spaces, intercostal, 11.  
 Spermatic arteries, 147, 149.  
 Spermatic cord, 72, 140.  
 Spermatic nerves, 130, 155, 176.  
 Spermatic plexus, 130.  
 Spermatic veins, 150.  
 Sphincter—  
   ani, 161, 162.  
   caeci, 99.  
   cardiac, 132.  
   ilei, 99.  
   pylori, 115, 131.  
   vesicae, 170.  
 Spinalis dorsi et cervicis muscle, 5.  
 Spinal nerves, general constitution, 59.  
 Splanchnic ganglion, 144.  
 Splanchnic nerves, 58, 144.  
 Spleen, 119, 133.  
 Splenic artery, 125.  
 Splenic corpuscles, 133.  
 Splenic lymph glands, 129.  
 Splenic plexus, 130.  
 Splenic pulp, 133.  
 Splenic vein, 129.  
 Sternal, internal proper, ligament, 53.  
 Sterno-costal articulations, 52.  
 Stomach, 112, 131.  
 Straight abdominal muscle, 85, 87.  
 Structure of—  
   bladder, 170.  
   intestines, 112.  
   liver, 132.  
   spleen, 133.  
   stomach, 131.  
 Subclavian arteries, 41, 45.  
 Subiliac lymph glands, 87.  
 Sulcus. *See* Groove.  
 Superficial inguinal lymph glands, 69.  
 Suprarenal glands, 143.  
 Suspensory ligament or ligaments—  
   of mammary glands, 69.  
   of ovary, 136, 137.  
   of penis, 77.  
   of spleen, 120.  
 Sympathetic nervous system, 56, 156, 179.
- TÆNLE, 98, 99.  
 Tail—  
   of epididymis, 71.  
   of pancreas, 117.  
 Tendinous cords, of heart, 32.  
 Terminal crest, of heart, 30.  
 Terminal line, of pelvis, 93.  
 Terminal sulcus, of heart, 30.  
 Testis, 71.  
 Thoracic arteries, 42, 51.  
 Thoracic cavity, 10.  
 Thoracic duct, 55.  
 Thoracic nerves, 8, 86.  
 Thoracic vein, external, 80.  
 Thoracic vein, internal, 52.  
 Thymic arteries, 52.  
 Thymus, 16.  
 Trabeculae carnea, 32.  
 Trachea, 45.  
 Tracheal nerve plexus, 48.  
 Transversalis fascia, 161.  
 Transverse abdominal muscle, 87.  
 Transverse artery of neck, 41.  
 Transverse diameter of pelvis, 182.  
 Transverse muscles, of heart, 32.  
 Transverse sinus of pericardium, 23.  
 Transverse thoracic muscle, 51.  
 Transversus costarum muscle, 6.  
 Triangular ligaments, of liver, 123.  
 Tricuspid valve, 32.  
 Trigone of bladder, 169.  
 Trunci lumbales, 151.  
 Trunci intestinales, 151.  
 Truncus bicarotis, 38, 43.  
 Truncus brachiocephalicus, 37, 39.  
 Truncus bronchooesophageus, 53.  
 Truncus costocervicalis, 42.  
 Truncus oesophageus dorsalis, 130.  
 Truncus oesophageus ventralis, 129.  
 Truncus omocervicalis, 42.  
 Truncus pudendoepigastricus, 150.  
 Tubercle, intervenous, of heart, 31.  
 Tube, uterine, 139.  
 Tunica albuginea, of penis, 77.  
 Tunica albuginea, of testis, 74.  
 Tunica flava abdominis, 82.  
 Tunica vaginalis, 70.  
 Tunica vasculosa testis, 75.
- UMBILICAL artery, 167.  
 Umbilical fissure, of liver, 122.  
 Umbilical folds, of bladder, 159.  
 Umbilicus, 88.  
 Ureter, 143.  
 Urethra, 78, 166, 170, 187.  
 Urethral bulb, 78, 171.  
 Urethral crest, 169, 170.  
 Urethral muscle, 166.  
 Urethral orifice, external, 78.  
 Urethral orifice, internal, 170.  
 Urethral process, 78.  
 Urinary bladder, 163, 169.  
 Urogenital fold, 143, 159.  
 Uterine arteries, 149, 150, 185.  
 Uterine tube, 139.  
 Utero-ovarian plexus, 130.


- Uterus, 134, 186.  
 Utricle, prostatic, 165.
- VAGINA, 182, 187.  
 Vaginal cavity, of scrotum, 71.  
 Vaginal portion of uterus, 134, 186.  
 Vaginal process, of peritoneum, 73.  
 Vaginal ring, 71.  
 Vaginal tunic, 70.  
 Vagus nerve, 46.  
 Valve or Valves—  
   bicuspid, 35.  
   of vena cava, 31.  
   semilunar, 33, 35, 48.  
   tricuspid, 32.
- Veins of vertebral canal, 61.
- Vena or Venæ—  
   azygos, 24, 54, 151.  
   cava caudalis, 24, 150.  
   cava cranialis, 23.  
   circumflexa ilium profunda, 150.  
   colica dextra, 128.  
   colica sinistra, 129.  
   cordis magna, 29.  
   cordis media, 29.  
   cordis minores, 29.  
   epigastricæ, 86.  
   gastricæ, 129.  
   gastroduodenalis, 129.  
   gastroepiploica dextra, 129.  
   gastroepiploica sinistra, 129.  
   hæmorrhoidalis cranialis, 129.  
   hemiazygos, 55.  
   hepaticæ, 129, 150.  
   hypogastricæ, 175.  
   ileocæcalis, 128.  
   iliaca communis, 150, 151.
- Vena or venæ—*continued*,  
   iliaca externa, 151.  
   intercostales, 8.  
   intestinales, 128.  
   lienalis, 129.  
   lumbales, 150.  
   mesentericæ, 110, 128.  
   pancreaticoduodenalis, 129.  
   phrenicæ, 150.  
   portæ, 128.  
   pudenda externa, 77.  
   pudenda interna, 167.  
   pulmonales, 20, 34.  
   renalis, 150.  
   spermatice interna, 150.  
   spinales, 61.  
   thoracica externa, 80.  
   thoracica interna, 52.
- Ventral colic artery, 110.  
 Ventral œsophageal nerve trunk, 129.  
 Ventricle, left, of heart, 34.  
 Ventricle, right, of heart, 32.  
 Vertebral artery, 42.  
 Vertebral articulations, 61.  
 Vertex vesicæ, 163.  
 Vesical arteries, 167.  
 Vesicles, seminal, 165.  
 Vesico-uterine excavation, 181.  
 Vestibular bulbs, 185.  
 Vestibule, 184, 187.  
 Vestibule of omental bursa, 105.  
 Vestibular glands, 187.  
 Villi, 112.  
 Vortex cordis, 49.  
 Vulva, 185.
- WINSLOW, foramen of, 105.





Bradley, W. O. H.  
The Thora

---



100127098