

SF 761

.S7


Copy 1




Class SF761

Book S7









# A VETERINARY DISSECTION GUIDE

282  
868

---

## PART I

# The Joints, Muscles, and Viscera of the Horse

BY

SEPTIMUS SISSON, S. B., V. S.

Professor of Comparative Anatomy in the Ohio State University.

Author of "A Text-Book of Veterinary Anatomy."

Member of the American Association of Anatomists.

---

COLUMBUS, OHIO:

1911

SF761  
LS  
.57

\$ 1.00

©CIA305097

No. 1.



## PREFACE.

---

This guide was prepared primarily for the use of students in the College of Veterinary Medicine of this University, and has been used with satisfactory results in the anatomical laboratory in the form of mimeograph sheets. It is now printed in response to the desire of several teachers, and in the hope that it may economize the time and energy of instructors and students, and conduce to orderly and thorough work in the dissecting room.

It is perhaps hardly necessary to say that this manual is in no way designed to take the place of descriptive texts and atlases,\* but attempts to state briefly and in orderly sequence the steps necessary to be taken to deal intelligently with the material under consideration. It is the belief of the writer, based on extensive experience, that the manipulations herein recommended will be found practicable and effective. It seemed desirable to interleave the guide with blank pages, on which notes and sketches might be made.

The author is indebted to his associate, Dr. F. A. Lambert, for assistance and suggestions.

SEPTIMUS SISSON.

The Ohio State University,  
September, 1911.

---

\*The nomenclature used in this guide corresponds to that of the Author's "Text Book of Veterinary Anatomy," published by Messrs. W. B. Saunders Co., 925 Walnut Street, Philadelphia; and the marginal numbers refer to figures in that text.

## INTRODUCTION.

---

Sound anatomical knowledge is very largely a product of thorough and intelligent work in the laboratory. All other methods of instruction and study are to be regarded as accessory to direct observation. The knowledge of the various structures that is essential to the professional student is mainly a matter of visual memory; the practitioner of medicine and surgery must be able to re-visualize clearly and accurately what he saw in the dissecting room. The power to do this varies greatly, depending very much on previous training. In many cases unfortunately the student finds that his ability in this respect is very limited and must be cultivated assiduously. It is evident that two conditions must be fulfilled in order to meet practical requirements. First, the parts to be observed must be clearly visible in every detail, so that a sharp definite mental picture is obtained. The work then must be clean, thorough and methodical, the various structures perfectly exposed, and the preparation in general such that the dissector need be in no way ashamed of it. The student will find that the acquisition of ordinary dissecting technique will occupy most of his time at first, so that he must proceed very slowly. Accurate and thorough dissecting is not only indispensable in anatomical study, but is also admirable training for clinical work. Dexterity in the use of those instruments which are most commonly employed in surgery should be acquired in the dissecting room. But the mechanical side of the work, important as it is, is the means, not the end. As the structures in a given region are exposed they must be carefully observed, their names learned, and their form and relations examined. The amount of time required for this will vary with the simplicity or complexity of the region and with the individual. The dissector must satisfy himself that he has seen thoroughly all that is to be seen before he proceeds further, since no clear and lasting impression will remain in the mind unless this is done. Sketches of dissections, even though of a rather primitive character, are of great value in fixing anatomical relations in the memory.

It is customary for two students to work together on a part; in dealing with large animals, such as the horse and ox, many manipulations require the co-operation of two dissectors. It is essential that each do his share of actual dissecting; the possession of greater skill or liking for the work on the part of one collaborator must never be allowed to interfere with his partner participating duly in the procedure.

Students should accustom themselves to exhaust their own resources before calling on an instructor for information or assistance. Self reliance and ability to deal with new and unforeseen situations are needed nowhere

more than in the practice of medicine and surgery. On the other hand, unusual difficulties, doubtful points, and variations from the usual arrangement should be brought to the attention of an instructor without hesitation. In this way the energies of instructors can be conserved and utilized for the best interests of the students and for the advancement of anatomical knowledge.

In beginning the dissection of a region examine all superficial features. Many bony prominences can be recognized by inspection or palpation. Study a figure of a superficial dissection, and see how much of what is shown in the illustration may be made out more or less clearly on the part before dissection. Study the region in the living animal.

#### CARE OF PART.

As soon as a part is assigned the dissectors take charge of it. Care must be taken that it is not allowed to dry, as this absolutely prevents good dissection. The face and lower parts of the limbs are to be wrapped with moist cloths at all times when they are not being worked on. Students must not interfere with parts belonging to other dissectors without the permission of the latter. Due diligence is to be observed in carrying on the work, so that material will not spoil on account of unnecessary delay and lack of attention. Do not uncover more surface than you need to work on in the time immediately available. When ceasing work endeavor to replace all parts in their natural position; this not only helps to keep the material in good condition, but may be made a means of fixing facts in the mind. Keep your part and table clean. Place all scraps of tissue in the receptacles provided for that purpose.

#### INSTRUMENTS.

Most of the dissecting sets as made up for sale are cheap and unsatisfactory. It is better to assemble what is required. (1). It is advisable to have three knives. Of these two should be high grade scalpels, of the type known as minor operating knives, with convex edges ("bellied"); the best lengths of blades for veterinary use are  $1\frac{3}{4}$  inches and 2 inches respectively. The third is a cartilage knife to be used for rough work, cutting about bone, etc., thus enabling the dissector to avoid damaging his better knives. (2). The dissecting forceps should be of large size, with properly grooved points which hold well. (3). A pair of straight scissors, medium size, with both points blunt, are very useful for working in corners, removing fat, etc. (4). One or two double hooks are necessary for fastening back flaps or structures which have been reflected from the field of operation. They are much more satisfactory than chain hooks. (5). A dissecting probe of the sort introduced by Professor Mall is very convenient for following the finer branches of vessels and nerves. (6). A blunt probe and a blowpipe are necessary for working out ducts, inflating hollow organs, etc.

Chisels, hammers, saws, bone forceps and the like are included in the laboratory equipment. These are to be returned to their proper place as soon as they are done with.

In order to do good work knives must be kept sharp, and a proper whetstone must be constantly at hand in the dissecting room. A rather quick-cutting stone which can be used with water is the most practical; probably the best is a yellow Belgian hone, but an India or a fine carborundum stone is satisfactory. When a knife can no longer be sharpened properly by this means it needs to be ground.

Instruments should be cleaned at the close of the laboratory period.

In dissecting, the scalpel is held usually like a pen, short and accurately-gauged strokes being necessary. In making long incisions, however, the knife is held "in the fist," and in cutting through firm and resistant structures this method is also used. Precision in the use of the scalpel should be diligently cultivated, and the resistance of the various tissues carefully noted.

#### CLOTHING.

A long, sleeved apron or an operating gown affords sufficient protection to the ordinary clothing in dissecting properly preserved subjects in a well-equipped and sanitary laboratory.





## DISSECTION OF THE HEAD AND NECK.

### VENTRAL REGION OF NECK AND SUBMAXILLARY SPACE.

Can you find the submaxillary lymph glands? Locate the facial vessels and parotid duct as they turn around the lower border of the ramus of the mandible. Is the ventral edge of the ramus in front of these thick or thin?

176  
462

In the middle line feel the body of the hyoid bone. The body of the thyroid cartilage of the larynx may be felt more or less distinctly a little further back. The arch of the cricoid cartilage can be located. Passing further back note where the trachea is distinctly palpable. Find the end of the cariniform cartilage.

Examine on either side the jugular furrow and vein. Gauge the thickness of the skin; is it closely adherent to the underlying parts?

Make an incision through the skin in the ventral median line from the body of the mandible to the cariniform cartilage. This will be continued backward by the dissector of the pectoral region. Reflect the skin (and only the skin) far enough to expose the lower border of the jaw and the jugular furrow.

Examine the superficial fascia and the cervical part of the panniculus carnosus. 185

Incise these along the median line and reflect them laterally. The panniculus is closely adherent to the mastoido-humeralis near the shoulder.

Clean the surface of the omo-hyoideus and sterno-cephalicus in so far as these muscles are accessible.

Cut the panniculus across near its attachment to the sternum.

Clean the jugular furrow, exposing the jugular vein.

Flex the neck so as to slacken the muscles here, and clean the deep face of the sterno-cephalicus and (as far as possible now) the omo-hyoideus.

Clean the sterno-thyro-hyoideus and the ventral surface of the trachea. Find the intermediate tendon of the former and the division of the muscles into thyroid and hyoid branches. Do not cut any of these muscles.

Note the position of the carotid artery. The vago-sympathetic nerve trunk lies on the dorsal surface of the artery, and the small recurrent nerve on its ventral face. Examine the oesophagus.

If any part of the parotid gland is uncovered, clean its surface, taking care however to save the duct and the parotido-auricularis muscle. Follow the duct and the external maxillary vessels in the submaxillary space.

Clean the mylo-hyoideus muscle, and the anterior belly of the digastricus and its tendon of insertion. Note in doing so the submaxillary lymph glands, which may be removed.

After the subject is suspended review the ventral muscles already dissected.

#### LATERAL REGION OF NECK.

Remove the skin from the lateral surface of the neck. Examine and remove the superficial fascia and the panniculus carnosus. This is a procedure which requires much care to avoid injury to the trapezius cervicalis. Note the course of the large spinal accessory nerve.

178 Clean the connective tissue and fat off the funicular part of the ligamentum nuchae.

Clean and examine the trapezius and mastoido-humeralis.

Remove the fascia from the splenius and serratus cervicis in so far as these muscles are exposed at present.

179 In conjunction with the dissectors of the withers cut the trapezius across about a handbreadth from and parallel to its origin and reflect the flaps. Clean the fascia off the muscular surface now exposed.

Dissect up the rhomboideus from the splenius. Study its origin; the insertion cannot be seen at present. Cut the muscle across about a handbreadth in front of the scapular cartilage.

Clean the deep face of the mastoido-humeralis and dissect its vertebral digitations. Cut these digitations across, leaving good-sized stumps attached to the vertebrae for review later.

Clean the lower part of the splenius and the serratus cervicis and separate these muscles:

Clean the scalenus. Note here the roots of the phrenic nerve crossing the surface of the muscle. The brachial plexus appears as a flat band between the upper and lower parts of the muscle.

After the removal of the thoracic limb examine the entire serratus magnus.

In collaboration with the dissectors of the thoracic wall, turn down the serratus magnus to its vertebral and costal attachment. Cut the muscle across a little above this attachment.

The splenius is now to be studied and the dorso-scapular ligament examined.

Cut the splenius across a short distance from its upper attachment and reflect both parts.


This uncovers the complexus, the trachelo-mastoideus, and the cervical part of the longissimus. Clean and separate these muscles, and examine them. Note the way in which the complexus passes between the two divisions of the longissimus. (The dorsal division of the longissimus = spinalis and semi-spinalis).

Clean the deep face of the complexus as far as convenient at this stage, and examine the structure and cervical attachments of the muscle; it is advisable not to dissect the poll till later. Cut the complexus across at the fifth cervical vertebrae.

Clean the lamellar part of the ligamentum nuchae in so far as it is exposed. The superior or deep cervical artery lies on the ligament.







Clean the multifidus and separate its bundles. Examine the attachments of the lamellar part of the ligamentum nuchae. 180

Clean and examine the intertransversales.

Clean the rectus capitis anterior major as far forward as the wing of the atlas; also the longus colli as far as practicable now.

Separate the head and part of the neck by cutting the soft structures as far as possible and sawing through the fifth cervical vertebra.

#### THE POLL AND AURICULAR MUSCLES.

172

The term poll is applied to the atlanto-occipital region, but is generally restricted to the dorsal structures. It is bounded in front by the occipital crest and laterally by the edges of the wings of the atlas; these can be felt. There is no natural posterior limit. 173  
562  
563  
564

In removing the skin here great care is necessary to avoid damaging the thin auricular muscles and the aponeurosis of the splenius. Incise the skin medially as far forward as a line connecting the internal canthi of the eyes, and make a transverse incision along this line. Leave a strip of skin about an inch wide around the orbit. Reflect the flaps very carefully as far outward as the zygomatic arch and the edge of the wing of the atlas, making a circular incision around the base of the ear. Strip the skin off the convex surface of the conchal cartilage.

Dissect the auricular muscles—a procedure requiring care and patience. One dissector must hold the ear in such a way as to tense the muscle which is being cleaned by the other. Superficial muscles may be cut across where necessary in order to expose those which they cover.

Pull the ear outward and backward and clean the scutiform cartilage and scutularis muscle. Note that the scutulo-auricularis superficialis superior is in reality a slip derived from the scutularis.

Draw the ear backward and a little inward and dissect the anterior auricular muscles

Expose the two superior auricular muscles by incising the cervico-scutularis and interscutularis an inch from the sagittal crest and reflecting the flaps. The scutulo-auricularis superficialis superior may be divided to expose fully the scutulo-auricularis superficialis accessorius.

Draw the ear outward and forward, and clean the cervico-auricularis superficialis. Dissect up the muscles carefully, exposing the insertion of the parieto-auricularis and the cervico-auricularis profundus major. Carefully remove the fat about the base of the ear here. The superficialis may be cut across to expose fully the profundus major, and the latter in turn divided to expose the profundus minor. Pull the ear forward and dissect up the parotid gland to see the insertion of the profundus minor.

Dissect the skin off the parotid gland sufficiently to uncover the entire parotido-auricularis.

Pull the ear outward and downward, exposing the eminentia conchae and the deep face of the scutiform cartilage. Dissect away the fat here and clean and separate the two deep auricular muscles.

To find the tragus, divide the parotido-auricularis and zygomatico-auricularis, and dissect the parotid gland carefully off the base of the ear. The annular cartilage and the lower part of the conchal cartilage can now be examined. Note the connection of the styloid process of the latter with the guttural pouch. Remove any fat which remains about the base of the ear. Examine the scutiform cartilage. Replace the muscles and review them.

Sever the origins of the posterior auricular muscles, and turn them and the ear forward. Clean the funicular part of the ligamentum nuchae.

Identify the stumps of the splenius and mastoido-humeralis. Clean the anterior part and the thin aponeurosis of these muscles. Blended with this aponeurosis is a strong tendon attached to the wing of the atlas.

Turn down the splenius from behind and above, separating it from the ligamentum nuchae. Clean its deep face and note that a digitation of the splenius is attached to the atlantal tendon just mentioned, but that the tendon may properly be regarded as belonging to the ventral part of the trachelo-mastoideus. The anterior digitation of the splenius is attached in part in common with the dorsal part of the trachelo-mastoideus.

Dissect up the mastoido-humeralis from below, separating it carefully from the omo-hyoideus. A digitation arises from the atlantal tendon of the trachelo-mastoideus.

Sever the digitations of the splenius and mastoido-humeralis from the atlantal tendon of the trachelo-mastoideus, and follow the aponeurosis of all three to the cranial attachment, dissecting up the parotid gland as much as necessary.

Cut the dorsal part of the trachelo-mastoideus across at the posterior border of the wing of the atlas, and turn the anterior stump forward together with the splenius and mastoido-humeralis.

The anterior part and the tendon of insertion of the complexus are exposed. Clean these and separate them from the ligamentum nuchae. Cut the muscle across in front of the digitation which arises from the articular process of the third cervical vertebra, and reflect the anterior stump to its insertion.

180 Clean the obliqui capitis and examine them.

The rectus capitis posterior major lies alongside of the funicular part of the ligamentum nuchae. Can you separate the muscle into superficial and deep parts, dissecting from without inward? Separate the muscle from the ligamentum nuchae, cut it across in its middle, and reflect the stumps. Cut the ligamentum nuchae across in front of the spine of the axis; note the appearance of the cross-section, and reflect the anterior stump. Do you find the supra-atloid bursa? Is there evidence of disease





here in your specimen? If so examine a normal specimen if one is available. The rectus capitis posterior minor lies in part beneath the bursa and is to be cleaned

Cut the obliqui capitis across and reflect the flaps.

Complete the dissection of the ligamentum nuchae.

The dissection of those ventral muscles of the neck which are attached to the ventral arch of the atlas and the base of the cranium cannot be completed at present, but the sterno-cephalicus, omo-hyoideus, and sterno-thyro-hyoideus are now to be worked out to their insertions if this has not been done.

#### MUSCLES AND VISCERA OF THE HEAD.

Remove the skin from the masseteric region. Note the facial nerve 172 and its branches crossing the masseter muscle. Do you observe any panniculus fibres? Clean the muscle and the parotid gland. In doing so be careful to preserve the origin of the small zygomaticus muscle. Do not dissect at present beyond the anterior border of the masseter.

Study the parotid gland and follow the duct to the point where it turns around the lower border of the ramus. Note the jugular and external maxillary veins in relation to the gland and retain them. The gland was partially dissected up previously; complete this carefully, endeavoring to avoid damaging underlying structures. The tendon of the sterno-cephalicus passes between the parotid and the submaxillary gland, and a thin aponeurosis connects this tendon with that of the mastoido-humeralis; these are useful in separating the two glands here.

Clean the submaxillary (salivary) gland in so far as it is now exposed.

Clean the stylo-mandibularis muscle.

Clean the temporalis muscle and remove the orbital fat.

The pterygoid muscles and the digastricus are to be examined later after removal of the ramus of the mandible.

Before proceeding with the dissection of the muscles of the cheek, lips and nostrils, study and examine the lips and nostrils. Explore the so-called "false nostril" and the nasal diverticulum. Palpate the alar cartilage. Find the external orifice of the naso-lacrimal duct. Locate the infra-orbital foramen, the naso-maxillary notch, and the anterior end of the nasal bones.

The remainder of the skin of the face is to be removed with great care; take no fascia with it, and leave a strip about an inch wide around the lips and nostrils.

The branches of the facial nerve may be removed with the fascia which partially conceals the muscles. Refer previously to illustrations of superficial dissections to avoid damage to the thin muscles. What is the nature of the facial panniculus?

Clean and define the zygomaticus.

Note the facial vessels and parotid duct passing upward in front of the masseter muscle. Clean these and follow the duct to its termination.

Clean the levator nasolabialis and define its two branches, between which the dilatator naris lateralis emerges. Clean the nasal expansion of the latter muscle and work backward to its origin.

Clean the buccinator and depressor labii inferioris in so far as they are now exposed, and follow the tendon of the depressor to the lower lip.

The levator labii superioris proprius is partly concealed by the levator nasolabialis. Cut the branches of the latter across and reflect the posterior part. Clean the levator proprius and dissect its tendon to the common terminal expansion.

Pass the forefinger back into the nasal diverticulum and raise the latter by bending the finger. Now dissect up the blind pouch carefully from behind forward. This exposes at the naso-maxillary notch the outer surface of the nasal mucous membrane and muscle fibres covering the bony margins of the notch. The thin muscular layer on the upper margin is the dilatator naris superior; clean it carefully, drawing the tendon of the levator labii superioris proprius aside. The dilatator naris inferior, which covers the nasal process of the premaxilla, is much thicker; clean it and determine its chief insertion.

346 Examine an illustration of the alar cartilages of the nostrils, and determine their form and arrangement by palpation. Clean the exposed surface of the dilatator naris transversus.

Determine the action of the nasal muscles. Slit the external wing of one nostril and the outer wall of the nasal diverticulum. Remove the mucous membrane from the naso-maxillary notch. Note the alar fold and its connection with the cartilaginous prolongation of the inferior turbinal bone. What muscle is attached to the cartilage?

Expose the alar cartilage of one side at least and study its form and attachment.


Remove the skin from the lips, exposing the orbicularis oris. The incisivi are best seen by everting the lips and removing their mucous lining.

Remove the skin of the eyelids, and examine the muscles thus exposed. Only the tendon of insertion of the levator palpebrae superioris is seen at present.

463 Cut the masseter across just below its origin and reflect it. Note its structure and remove it from the ramus. The posterior part of the buccinator and depressor labii inferioris are now exposed and are to be cleaned. In doing this observe the two peculiar veins which lie along the borders of the muscles and note their connection with the facial vein. The upper one is the buccinator vein. Clean the fat off its posterior part and follow it around the maxillary tuberosity to the point where it passes through the periorbita. The lower vein is the vena reflexa; it is continued on the inner surface of the ramus as the internal maxillary vein. The veins may now be removed.







The superior buccal glands lie on the upper part of the buccinator; they consist of small lobules of a pale yellow color.

The bulk of one ramus of the mandible is now to be removed. Slit the cheek lengthwise; reflect the flaps, and find the orifice of the parotid duct. Lay the head with its ventral face upward and separate the soft structures from the inner surface of the ramus. It is not advisable to do this before you have had the procedure demonstrated by an instructor. It must be done with a large knife, the blade of which is to be kept on the ramus. Sever the attachments of the internal pterygoid and stylo-mandibularis from the ramus. Then pass the knife blade along the inner surface of the horizontal part of the ramus, keeping it on the bone, and severing the soft tissues here. The separation must extend up through the floor of the mouth. Saw through the ramus (a) near its junction with the body, and (b) a little below the articulation with the temporal bone. In doing this take care not to damage the underlying structure; it is best to saw partly through the bone and finish the separation with a chisel. Remove the part of the ramus thus isolated but retain it for future reference.

The cut surface of the pterygoideus internus, which was attached to the broad part of the ramus, is exposed; behind it is the stylo-mandibularis; in front of it is the mylo-hyoideus. Along the lower part of the mylo-hyoideus is the anterior belly of the digastricus. Clean these muscles and locate their attachments to the part of the ramus which is removed. The lingual nerve crosses the pterygoideus internus and dips under the mylo-hyoideus.

The pterygoideus externus is deeply placed. It extends from the lower part of the pterygo-palatine fossa backward to the condyle and neck of the mandible. Raise up the stump of the ramus to see the insertion of the muscle, and if necessary remove part of the bone with pincers.

Dissect up the pterygoideus internus carefully to its origin and cut it off short. In doing this endeavor to avoid injuring the very thin guttural pouch by raising the muscle and pushing the pouch off its deep face with the finger or scalpel handle.

Raise the ventral end of the stylo-mandibularis and separate it carefully from the underlying structures. Note that the posterior belly of the digastricus is blended with this muscle, and must also be dealt with now. The duct of the submaxillary gland is to be found when cleaning the intermediate tendon of the digastricus.

Clean and examine the submaxillary gland.

The occipito-hyoideus muscle blends with the origin of the stylo-mandibularis; it fills the space between the upper end of the great cornu of the hyoid bone and the paramastoid (or styloid) process.

Cut the digastricus across close to its junction with the stylo-mandibularis, and cut the latter off close to its origin.

242 The stylo-hyoideus lies behind the great cornu. Clean it and note its attachments. Observe at its insertion the pulley for the intermediate tendon of the digastricus.

436 The external carotid artery passes forward under cover of the upper part of the submaxillary gland, emerges between the stylo-hyoideus and the great cornu, and crosses the latter. It is continued across the inner surface of the neck of the mandible as the internal maxillary artery. Look along it for the pharyngeal lymph glands.

Open the guttural pouch in front of the great cornu and explore it thoroughly and study its relations. Pack the sac so as to retain its shape approximately.

The large hypoglossal nerve is seen running downward and forward over the guttural pouch, the external carotid artery, pharynx and larynx. It disappears under the mylo-hyoideus, and is the motor nerve of the tongue.

Close behind or partly under the great cornu is the much smaller glosso-pharyngeal nerve.

The external maxillary artery has a somewhat similar course but passes to the submaxillary space. The large branch from it that is visible for a short distance behind the great cornu is the lingual artery; it passes under the hyo-glossus.

#### LINGUAL MUSCLES, TONGUE, ETC.

Remove the external maxillary vein and the anterior belly of the digastricus, and examine the outer surface of the mylo-hyoideus. Reflect the muscle downward to the median raphe, and clean the structures thus exposed. Find the submaxillary duct. The lingual and hypoglossal nerves are to be observed and then removed so far as they are in this layer.

436 Clean and examine the sublingual gland. Find the ducts and observe the papillae on which they open. Dissect up the gland from below and trace the submaxillary duct.

242 Dissect the mucous membrane up on the side of the tongue until it becomes firmly attached to the underlying muscle, and remove as much as you have detached. Clean the stylo-glossus and note its form, position, and attachments. Cut it across about two inches from its origin. Reflect the posterior stump, and dissect up the anterior part from below upward till it blends with the intrinsic musculature of the tongue.

Clean and examine the hyo-glossus. Raise its anterior border, cut the muscle across at right angles to its fibres and reflect the flaps. The lingual artery is exposed and may be removed.

The small kerato-hyoideus muscle occupies the space between the lower part of the great cornu and the small and thyroid cornua of the hyoid bone.

Note the triangular space between the kerato-hyoideus below, the pharyngeal muscles above and the root of the tongue in front, in which





there is no muscular layer. Pass the finger along the lateral wall of the fauces and feel here the series of rounded elevations caused by masses of lymphoid tissue, representing a diffuse tonsil.

The genio-glossus has been exposed by the reflection of the stylo-glossus and hyo-glossus. If its tendon and lower edge is raised it will be seen that the median plane has been reached; here there is a thin layer of connective tissue and some fat, which separate the right and left muscles.

The genio-hyoideus lies along the lower edge of the preceding, in contact with its fellow of the opposite side.

Replace the muscles and review them.

#### PHARYNGEAL AND PALATINE MUSCLES.

Cut the stylo-hyoideus across about an inch below its origin and reflect the lower part. Dissect the guttural pouch from below upward off the wall of the pharynx.

The pharyngeal fascia covers the muscular layer. Note the thick part which extends from the pterygoid bone to the great cornu. Remove the fascia.

Find the stylo-pharyngeus muscle arising from the deep face of the great cornu where the latter reaches the lateral wall of the pharynx. With bone forceps divide the great cornu just below the origin of the muscle, and also near the junction with the small cornu.

The pharyngeal muscles can now be completely cleaned and examined in the order given in the text. After they ~~have been~~ studied superficially the constrictors may be divided to expose the posterior part of the palato-pharyngeus and pterygo-pharyngeus. 242  
243

The anterior part of the last named muscles is crossed by the tensor palati and levator palati, which lie along the outer surface of the Eustachian tube. The tendon of the tensor can be followed to the humulus of the pterygoid bone but not further at present. The levator is internal to the tensor along the Eustachian tube, and then turns down in the pharyngeal wall. The azygos or palatine muscle is to be examined later.

#### ISTHMUS FAUCIUM, PHARYNX, LARYNX, ETC.

Depress the root of the tongue and explore the isthmus faucium; what are the boundaries? Cut the anterior pillar of the soft palate and extend the incision backward and downward through the lateral wall of the fauces just below the soft palate. Slit the lateral wall of the pharynx just above the soft palate. The isthmus faucium, the soft palate, and the cavity of the pharynx are now to be fully examined. Study in this connection the illustration of a sagittal section of this region. Note the relation of the posterior pillars of the soft palate to the entrance to the oesophagus. 254

Dissect off the oral mucous membrane of the soft palate together with the thick underlying glandular layer. The aponeurotic layer is exposed. Follow the tendon of the tensor palati to this layer. Find the azygous or palatinus muscle.

Study the position and relations of the larynx. Examine the aditus laryngis, and note its relation to the cavity of the pharynx and the isthmus faucium. Does the pharynx communicate with the mouth in the present state of the parts? If not, how is communication established?

Sever the attachments of the pharyngeal muscles from the laryngeal cartilages and examine the latter so far as they are now exposed

Place the preparation with its ventral surface upward.

Dissect up the stumps of the omo-hyoidei and sterno-hyoidei to their insertions and cut them off short. Deal likewise with the sterno-thyroideus.

Clean and examine the thyro-hyoid muscle. The ventral surface of the larynx which is exposed between them is also to be cleaned. Identify the body of the thyroid cartilage and the arch of the cricoid. Note the interval between the former and the body of the hyoid bone; clean out the fat in this space. The arch of the cricoid cartilage is largely covered by the crico-thyroid muscles.

Remove the fascia from the ventral and lateral surfaces of the trachea. In doing this look for the isthmus of the thyroid gland. Examine the thyroid; are the lateral lobes symmetrical in size and position?

Clean the oesophagus and the carotid artery. What nerves lie above and below the artery? What is the position of the oesophagus? Where and how does it change its position?

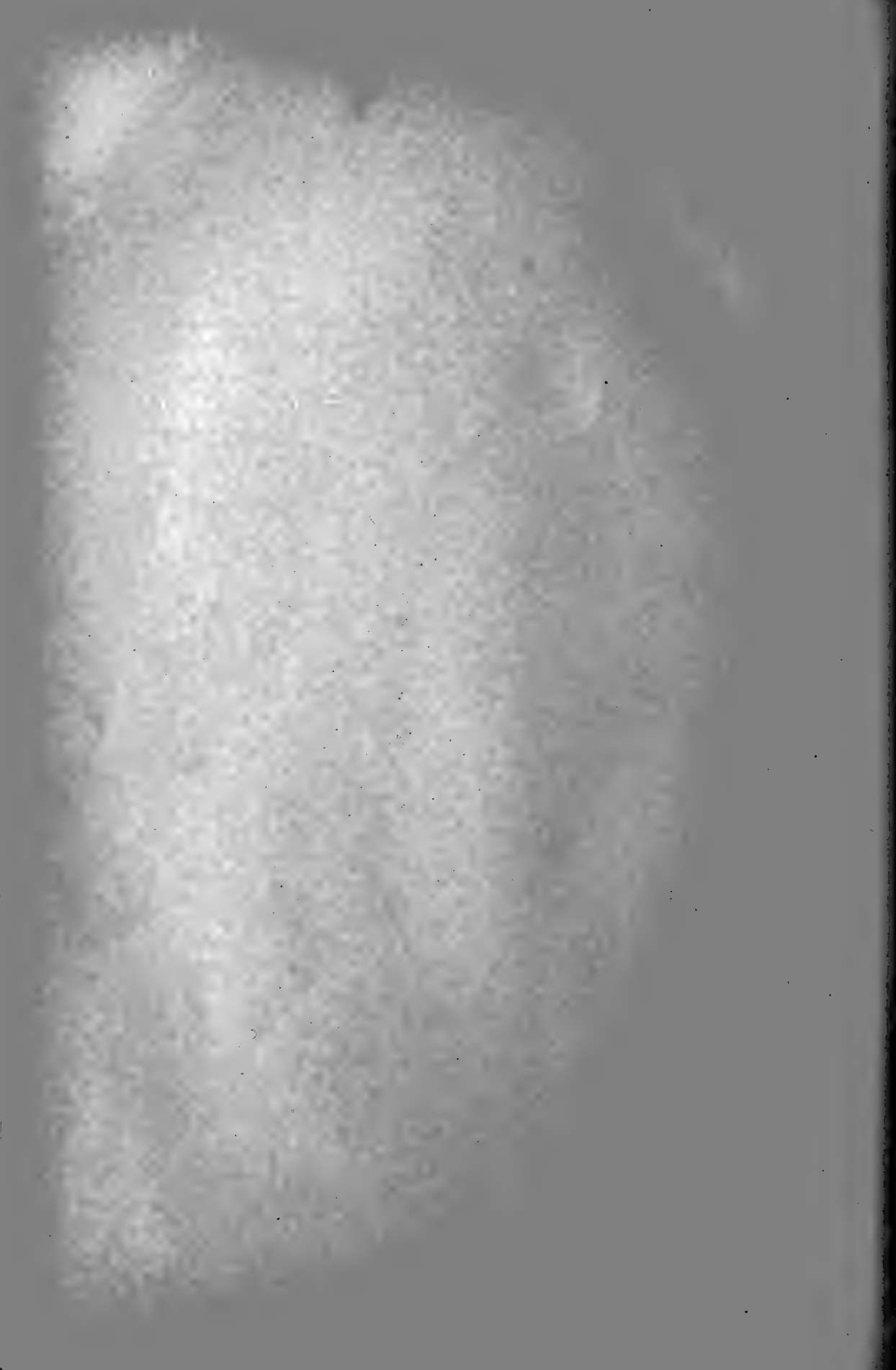The tongue, part of the hyoid bone, pharynx and soft palate, the larynx, and the trachea and oesophagus are now to be removed together for further study. Lay the preparation on its side. Cut the trachea and oesophagus across about a hand's length behind the larynx. Pull them downward and dissect them loose from the overlying structures. Complete the separation of the guttural pouches from the pharynx. Carefully separate the (previously undissected) lateral surface of the pharynx and larynx from the adjacent structures.

Divide the stylo-pharyngeus muscle. Cut the pharynx across below the Eustachian openings, and divide the soft palate in a similar direction

Depress the root of the tongue and divide the anterior pillars of the soft palate. Disarticulate the intercornual joint of the hyoid bone. Cut the attachments of the geno-hyoidei and genio-glossi to the mandible. Pull the tip of the tongue out of the mouth, cut the frenum linguae, and separate the tongue from the mylo-hyoideus, cutting the mucous membrane along the line of reflection from the tongue to the muscle.







Study the form and structure of the tongue. Wash and examine the mucous membrane. Make and study cross-sections of tip, body, and root. 240  
241

Examine the part of the pharynx and soft palate which you have removed. What is the pharyngeal isthmus? Slit the soft palate, the junction of its posterior pillars, and the first few inches of the oesophagus medially. Study the floor of the pharynx and the aditus laryngis as seen from above. 348  
355

Note the thick glosso-epiglottic fold extending from the base of the epiglottis to the root of the tongue. Incise the mucous membrane here medially, reflect the flaps, and clean the hyo-epiglottic muscle.

Examine the structure of the oesophagus. How is it connected with the pharynx and larynx?

Separate the oesophagus, pharynx, and soft palate from the larynx and hyoid bone. Dissect the external muscles of the larynx on both sides. It is necessary, before doing so, to study the cartilages, referring to illustrations of them. You can obtain a dissected specimen of the cartilages by asking an instructor for the loan of one. Do you observe any difference between the right and left muscles? If so, is the aditus laryngis unsymmetrical? 349

Cut the muscles off one side and remove the greater part of the lamina of the thyroid cartilage on the same side. Is the cartilage partly calcified? Find the lateral ventricle and pass a finger back into the laryngeal saccule; note the extent of the saccule and its relation to the muscles here. 354

Dissect the thyro-arytenoideus and crico-arytenoideus lateralis. These muscles will be atrophic (on the left side) if the animal is a "roarer."

Examine the cavity of the larynx. It may be divided in the dorsal medial line and the two sides pulled apart for this purpose. Is the cricoid partly calcified? How is it connected with the trachea?

Examine the joints and ligaments. Separate the cartilages and clean and study them. Study the structure of the trachea.

A review should now be made of the muscles of the parotid region and the inner surface of the ramus as seen from the inner side; this refers particularly to the occipito-hyoideus, stylo-mandibularis, digastricus, pterygoideus internus, and mylo-hyoideus. Clean these muscles and study them. \*

Dissect the temporo-mandibular joint. Open the joint capsule and examine the articular disc.

Remove the mandible and lay the preparation with its ventral surface upward.

Examine the dorsal part of the guttural pouches and study the Eustachian tubes. Is the term "tube" at all misleading? What muscles lie along the outer surface of the tubes? Note the median recess of the pharynx between the expanded anterior ends of the tubes.

Remove the remnants of the guttural pouches, and clean and dissect the ventral muscles; these comprise the longus colli, and the recti capitis major, minor, lateralis.

Remove the muscles from the articulations formed between the axis, atlas, and occipital bone, and dissect these joints.

Disarticulate the atlas from the skull, cutting through the spinal cord and its membranes. Remove the dorsal arch of the atlas. Examine the spinal cord and its membranes, and remove these to expose the odontoid ligament.

Examine the hard palate, gums, teeth, and posterior nares.

Examine the eyelids and conjunctiva. Separate the lids from the orbital margin. Find and examine the lacrimal gland and its ducts. Separate the gland from the supraorbital process. Saw through the root of the process and through both ends of the zygomatic arch, and remove the piece of bone thus isolated. This opens up the orbit for dissection. Remove any remaining orbital fat.


The eyeball with its muscles, vessels, and nerves is enclosed in the periorbita. Examine this sheath, then slit it lengthwise and reflect the flaps. Clean the ocular muscles and separate them from each other. In doing this one dissector should fix the eyeball with a hook in the sclera in the various positions necessary to deal with the several muscles. The retractor is visible when the recti are cut across and reflected. The optic nerve is enclosed in the retractor.

Examine the eyeball. Remove the cornea and examine the iris, pupil, and lens. Section the eyeball through its equator and examine the interior of both pieces.

The paranasal sinuses of one side are now to be opened up fully by removing their outer wall. With hammer and chisel make two openings above the facial crest, one above the anterior part of the crest, and the other just in front of the orbit. Remove with bone forceps the outer wall of the maxillary sinus, retaining the facial crest and the septum between the anterior and posterior compartments of the sinus. Explore the sinus thoroughly.

Make an opening midway between the internal canthus and the median line, and remove the outer wall of the frontal sinus. Explore the sinus fully.

Make a sagittal section of the skull about a quarter of an inch from the median plane, i. e., toward the side on which the sinuses have been opened up; be careful not to attempt to saw through the incisor tooth—finish here with a chisel. Wash the sections and study the nasal cavity. If the section is successful the septum nasi is seen on the larger piece, and the turbinal bones, lateral mass of the ethmoid, and meatuses can be examined on the other.





On the smaller portion find the naso-maxillary fissure. Open up the posterior parts of the turbinal bones. Dissect the mucous membrane off their cartilaginous prolongations. Note the course of the infraorbital canal and the naso-lacrimal canal and duct; to see these completely remove the turbinal bones. Explore the sphenopalatine sinus. 347

Make two cross-sections of the larger piece of the skull, one at the anterior end of the facial crest, and the other through the anterior part of the orbit. Be careful not to attempt to saw through the teeth; finish here with a chisel. Study the sections, noting especially the septum nasi, turbinal bones, and nasal meatuses. 37 348

Remove the brain, noting the points of exit of the cranial nerves. Examine the exterior of the brain and identify its gross divisions. Detach the dura mater and examine the inner surface of the cranial wall; note the relations of the parts of the brain to the wall.

## THE THORAX AND THORACIC LIMB.

### PECTORAL REGION.

Find by palpation the cariniform cartilage of the sternum. From this a median furrow extends backward to a depression which indicates the position of the xiphoid cartilage. Palpate the ventral border of the sternum. On the front of the breast there is a central furrow between the anterior superficial pectoral muscles, and between these muscles and the mastoido-humeralis there is a lateral furrow on either side. Can you recognize the cephalic vein in this furrow? The limb should be abducted.

Make a median incision of the skin from the cariniform cartilage to the xiphoid cartilage. This will be extended backward by the dissectors of abdomen. Make a transverse incision from the cariniform cartilage to the point of the shoulder, and another from the xiphoid cartilage outward; extend the latter about half way up the lateral wall of the thorax. Reflect the flap of skin and fasten it out of the way.

The pectoral fascia is now to be examined and removed. Is it closely adherent to the muscles?

**177** Note the position of the large cephalic vein. Is it accompanied by  
**186** an artery?


**466** Find the line between the anterior and posterior superficial pectoral muscles. The plane of division here is very oblique, since the anterior muscle overlaps the posterior one to a considerable extent. If in doubt, dissect under the anterior part of the anterior superficial pectoral and complete the separation.

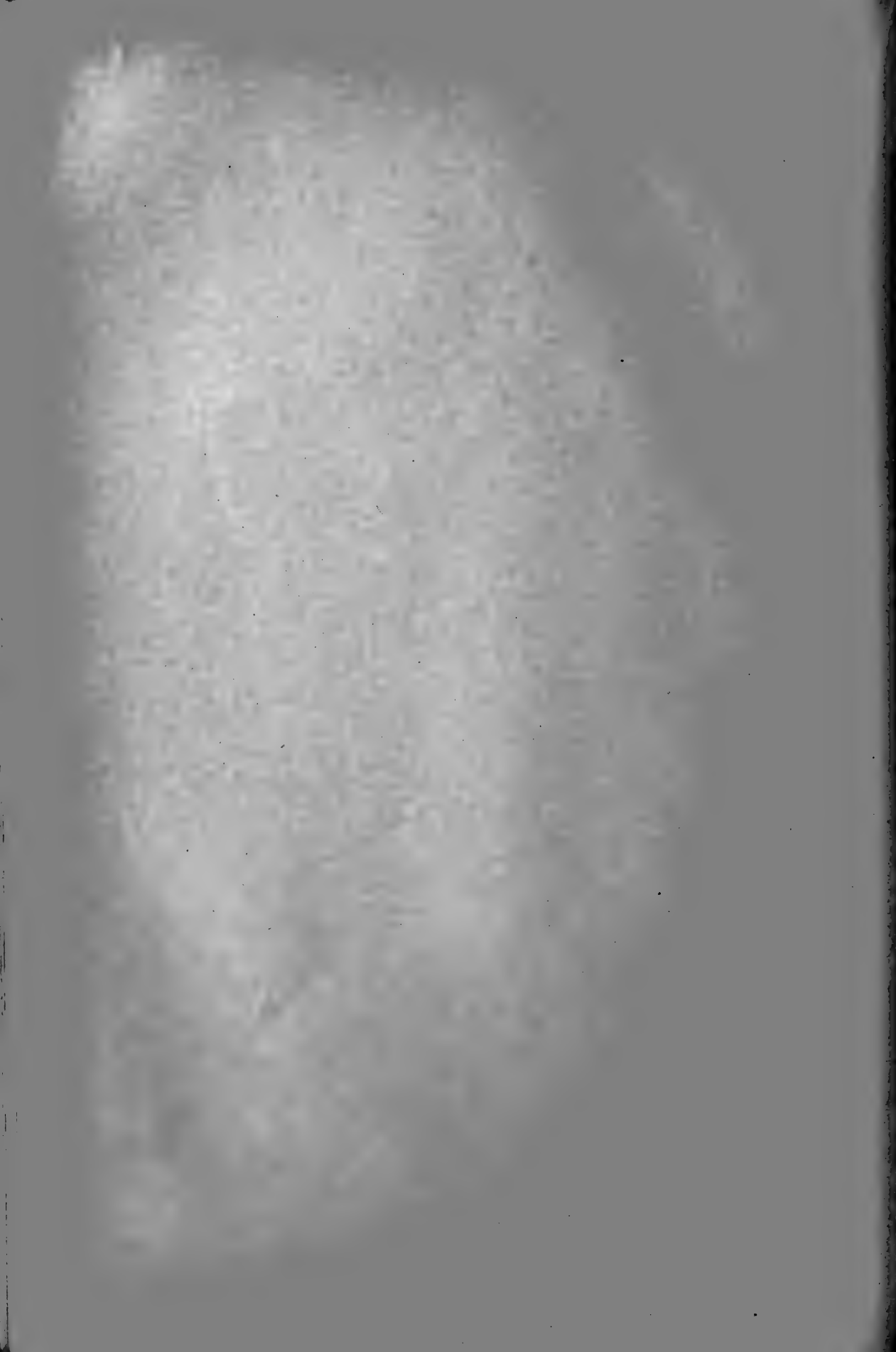Raise the anterior superficial pectoral muscle and cut it across about a handbreadth from its sternal attachment. Reflect the inner part to its sternal attachment. Reflect the outer part to the deltoid tuberosity, where it joins the mastoido-humeralis.

The posterior superficial pectoral is now exposed. Dissect under its posterior part and cut it across about a handbreadth from the sternal attachment. In doing this it must be separated *pari passu* from the deep muscle to avoid damage to the latter. Reflect both pieces to their attachments. It is convenient for the dissectors on one side to reflect the medial flap while those on the other side reflect the lateral flap.

Clean the deep face of the muscle-flaps and secure them out of the way. Clean the surface of the deep pectoral muscles as far as they are exposed. Find the line of division between the anterior and posterior muscles and separate them as far as is feasible at this stage. Note their direction and structure. Leave them intact for further examination and dissection in the natural position.







When the subject is suspended in imitation of the natural position replace the flaps of the superficial pectoral muscles and review them. Then re-examine the deep pectoral muscles. Abduct the limb and clean out the connective tissue between the shoulder and the chest wall. Here the brachial vessels and the brachial plexus of nerves are found. Clean and examine these. Separate the omo-hyoideus from the mastoido-humeralis. Note here the prescapular lymph glands which lie on the anterior border of the anterior deep pectoral muscle. 177

Cut the mastoido-humeralis and the omo-hyoideus across in front of the shoulder. Reflect the former so as to expose the anterior deep pectoral; clean the surface of this muscle and study it.

Cut the anterior deep pectoral muscle across a little below the shoulder, and separate the two parts from the posterior deep pectoral. Clean and examine the latter.

Cut the posterior deep pectoral muscle across about a handbreadth from its origin.

#### THE BACK.

The fasciae and the muscles which extend from the neck and trunk to the thoracic limb are to be dissected in collaboration with the dissectors of adjacent parts. The skin is to be removed from the back and loins. 178  
179  
523

Examine the panniculus carnosus and the superficial fascia. Then remove these, but leave for future examination the parts of the muscle which go to the inner surface of the arm and into the fold of the flank.

Study the lumbo-dorsal fascia. This is to be kept intact till a later stage.

Clean the surface of the trapezius thoracalis. Note the large dorsal branch of the spinal accessory nerve entering its deep face. Cut the trapezius across about a handbreath from its upper attachment, Reflect both flaps.

Clean the surface of the latissimus dorsi. The insertion is not visible now and must be examined later. Cut the muscle across about a handbreadth behind the shoulder. Reflect the upper part to the fusion of its aponeurosis with the lumbo-dorsal fascia. Be careful not to cut the latter nor to injure the thin aponeurosis of the serratus anticus.

Clean and examine the funicular part of the ligamentum nuchae at the withers. Remove the loose connective tissue from the scapular cartilage and the rhomboideus muscle.

Clean the serratus magnus as far as it is now exposed, including its interdigitations with the obliquus abdominis externus. Abduct the limb strongly so as to see the part of the muscle naturally concealed by the shoulder and arm. Sever the attachment of the muscle to the scapula, cutting close to the bone.

Now adduct the limb as much as possible to open up space between the scapular cartilage and the rhomboideus thoracalis. Examine this muscle and cut it across. In doing this be careful not to cut the underlying dorso-scapular ligament to which the muscle is attached. Scrape the muscle-flaps off the ligament.

Remove the limb, lay it aside and resume the dissection of the thorax.

Complete the removal of connective tissue from the surface of the serratus magnus. Note the large nerve running backward across the aponeurosis on the surface of the muscle, which it innervates. Examine the stump which was attached to the scapula; the bundles are here intersected by numerous elastic lamellae given off from the dorso-scapular ligament. Note the relation of the posterior digitations with those of the external oblique muscle.

Examine the thoracic attachments of the pectoral muscles and remove them.

Clean and examine the rectus thoracis and the anterior parts of the rectus abdominis and obliquus abdominis externus

With the dissectors of the head and neck, turn down the serratus magnus to its costal attachment and cut the muscle across a little above the latter.

Study now the dorso-scapular ligament. Remove the rhomboideus from its surface. It will be seen that the so-called ligament is a special thickening in the withers of the lumbo-dorsal fascia. What muscles are attached to it? Reflect from below upward the superficial elastic lamina given off from the ligament, exposing the serratus anticus. Clean and examine this muscle.

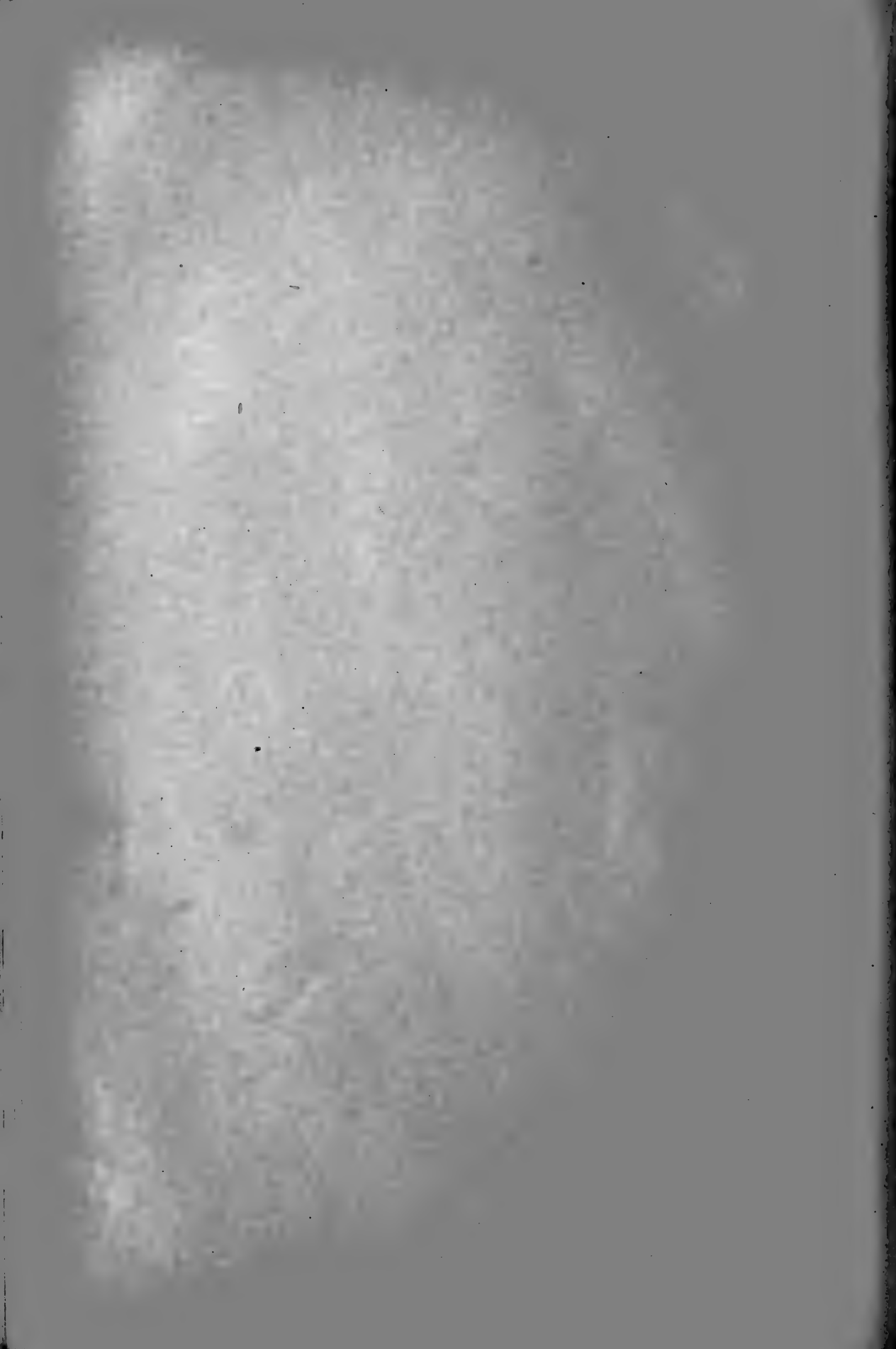Cut the serratus anticus across just above its costal attachment and reflect both flaps.

The transversalis costarum is exposed, and a thin lamina from the dorso-scapular ligament is seen coming down over the longissimus and dipping in between the two muscles to be attached to the ribs. Cut this lamina longitudinally and reflect the flaps, exposing the longissimus and spinalis.

Open up the furrow between these two muscles at the withers, and disclose a thin lamina detached from the deep face of the dorso-scapular ligament. The aponeurosis of the complexus dips in here to be attached to the transverse processes of the thoracic vertebrae. Turn down the longissimus dorsi to see this attachment.

Clean the surface of the transversalis costarum and separate its inner border from the longissimus. Note that a layer derived from the lumbo-dorsal fascia dips in between the two muscles here and is attached to the ribs. Expose the deep set of tendons of the transversalis and separate the bundles as far as any natural division exists. Remove the muscle, but leave stumps of its attachments to the ribs.





Remove the longissimus and clean and examine the multifidus and the levatores costarum. 184

Clean and examine the external intercostal muscle in one or two intercostal spaces. What is the direction of the fibres? Does it extend the entire length of the space? Remove the external intercostal muscle and expose the internal one. Note the direction of the fibres of the latter. Does it extend the entire length of the space? What is the direction of the fibres in the lower part of the spaces? Note the position of the intercostal vessels and nerves.

#### THE THORACIC CAVITY AND VISCERA.

Open the thorax by removing the greater part of its lateral walls. It is advisable to leave in situ the first, third, sixth, and last two ribs. Saw, or cut through with heavy pincers, the other ribs near their vertebral ends. As far back as the tenth rib nick the costo-chondral junctions with the cartilage knife and turn the ribs downward; in this way any rib may be replaced in its natural position for topographic purposes. From the tenth backward the ribs are to be severed at a gradually increasing height, just above the costal attachment of the diaphragm. Take care not to injure the lungs.

The lungs are now to be examined. If the subject has been preserved properly, the lungs will have approximately the size and shape which exists during life. When the thorax of an unpreserved subject is opened the atmospheric pressure causes immediate collapse of the lungs, and inflation of them gives only an imperfect idea of their true shape and size. 263  
361

Note that the costal and basal surfaces, the borders, and the apex have no attachment to the wall in normal cases. Determine how and where the lung is attached. Observe the cardiac notch on each side.

It is advisable to remove the left lung first. Take hold of the base and draw it outward a little. Cut carefully through the ligament of the lung from behind forward. It is evident now that the two lungs are adherent to each other from the ligament forward to the root. Dissect them carefully apart, endeavoring to avoid injury to the mediastinal pleura. The root of the lung is now to be dealt with. Turn the apex of the lung back, and cut the pleura as it is reflected upon the root. The bronchus can now be felt. On this are the pulmonary nerves and the relatively small bronchial artery. Divide these structures from above downward. The left branch of the pulmonary artery is now reached, and is also to be cut across. Below and behind the artery are the pulmonary veins; in dividing these take care not to damage the heart. Find the bronchial lymph glands.

Now study the mediastinal surface of the lung and observe how its various features correspond with the surface of the mediastinum with which it was in contact. Identify the structures which compose the root of the lung. Note the line of reflection of the pleura; the surface of the lung enclosed by this line has no pleural covering. 362

**428** Examine the mediastinum and the organs visible in it. Is the mediastinum median? Does it form a complete septum between the two pleural cavities? Can you trace the mediastinal pleura in the dorso-ventral direction continuously at all points? Identify and study the form and position of the chief organs in the mediastinum.

**267** The right side of the thorax is to be opened like the left one, and the  
**363** right lung dealt with in a similar manner. In removing this lung you will observe its mediastinal lobe, which lies on the other side of the posterior vena cava and the fold of pleura which extends down from that vessel; this fold must not be confused with the mediastinum. Compare the two lungs; in what important respects do they differ? Examine their structure and dissect the bronchi and larger pulmonary vessels in their ramification in the lung.

Now explore the two pleural cavities. How do they differ? Note carefully the posterior limit of each, and mark this on the outside of the chest wall. Does the line of pleural reflection correspond exactly with the costal attachment of the diaphragm? Mark the latter on the chest wall. Endeavor to restore the natural curvature of the diaphragm, and note the relation of the costal part of the muscle to the chest wall.\* How does this vary during respiration?

**358** Study cross sections of the thorax in order to understand the arrange-  
**359** ment of the pleural sacs and the general relations of the thoracic organs.  
**360** Ask for an explanation and demonstration of any features which are not clear to you.

**429** Note the position of the phrenic, vagus, cardiac, and sympathetic nerves. Identify the larger vessels, including the thoracic duct.

Examine the course and relations of the oesophagus. The tube is usually tightly contracted. Remove portions of it and study its structure. How does the terminal part differ from that further forward?

Expose the trachea and study its position and relations. Are the two bronchi alike in size and direction?

Clean the outer surface of the pericardium. Study the form and relations of the sac and the attachments of its fibrous layer. Open the pericardium by an incision on each side from base to apex and a horizontal incision carried around it at the level of the coronary groove. A variable amount of serous fluid—the liquor pericardii—escapes. When the flaps are reflected the serous layer of the pericardium is seen. Note the reflection of this layer upon the great vessels at the base of the heart and its continuation on the surface of the heart to constitute the epicardium.

With scissors cut away the pericardium along the line of reflection of its serous layer. Clean the great vessels above and below this line; and examine them.

---

\* Students should have at least once an opportunity of examining the thoracic surface of the diaphragm before the abdominal viscera are removed.







Study the form, position and external features of the heart. When convenient compare its size in your subject with others. Remove the heart, together with part of the great vessels. Clean and isolate the aorta and pulmonary artery. How are these vessels connected? What is the transverse sinus of the pericardium? Note the arrangement of the auricles as viewed dorsally. Clean the epicardium and fat off the coronary vessels. Examine the latter and remove them with the exception of a short piece of their origin.

270  
271  
419  
420  
421  
426  
427

Remove parts of the walls of the cavities by incisions parallel with the grooves of the heart; ask an instructor to demonstrate the procedure. Wash out the cavities and explore them with the aid of the description in your text book. Sectional views are also very instructive. Follow the course of the blood through the heart and lungs so as to associate the structures with their mechanical functions.

422  
423  
424

Dissect away the atria and cut the aorta and pulmonary artery off short. The form and position of the four orifices of the bases of the ventricles are now well seen. Examine the aortic and pulmonary valves. A cross section of the ventricles shows the shape of these cavities and the thickness of their walls.

425

Remove the pleura from the floor of the thorax and note the sternal attachment of the pericardium. Remove the latter except its apex.

Clean the surface of the transversus thoracis and note its form and attachments. The internal thoracic artery and vein disappear under the anterior edge of the muscle.

Clean the ventral part of the rim of the diaphragm and note carefully the attachment to the xiphoid cartilage and the adjacent costal cartilages. Examine the tendinous centre and observe the arrangements of its fibres. What foramen is found in this part? Clean the fleshy part of the crura and examine the two openings here.

Remove the transversus thoracis and examine the sternal ligament and the chondro-sternal joints.

Remove the trachea and bronchi and investigate their gross structure.

Remove the pleura and vessels from the roof of the thorax and note the attachments of the thoracic parts of the longus colli and psoas muscles. What is the lumbo-costal arch?

Clean the inferior common vertebral ligament. Dissect up the ligamentum nuchae at the withers. Is a supraspinous bursa present? What is its position and extent?

Remove three or four vertebrae with the vertebral ends of the corresponding ribs by sawing a piece out of the middle of the back. On this examine the vertebral and costo-vertebral joints. Open up the vertebral canal by sawing off the arches of the vertebrae. Examine the spinal cord and its membranes and the spinal nerves. Remove these and study the conjugal and superior common ligaments.

142  
519

## THE SHOULDER AND ARM.

Before proceeding with the muscles of the shoulder, identify the stumps of the muscles which connect the limb with the trunk. These comprise, on the external surface, the trapezius and the mastoido-humeralis. The insertion of the latter cannot well be worked out at present. The stumps of the following are found on the internal surface: 1. Both parts of the rhomboideus are attached to the inner surface of the cartilage of the scapula. 2. The serratus magnus is usually cut off close to the scapula, but its area of attachment is easily defined; does it extend upon the cartilage at all? Note here the elastic lamellae derived from the dorso-scapular ligament. 3. The latissimus dorsi is to be cleaned, and the panniculus carnosus separated from it, but its tendon of insertion can be better dealt with later. 4. The omo-hyoideus ends on the subscapular fascia above the shoulder joint. Define its tendon of insertion. 5. The anterior deep pectoral muscle lies along the front of the shoulder. Clean it and note its insertion. 6. The anterior superficial pectoral muscle accompanies the mastoido-humeralis to the front of the arm. 7. The posterior superficial pectoral muscle extends down the inner face of the arm and elbow; its insertion will be seen later. 8. The posterior deep pectoral muscle crosses the upper part of the inner surface of the arm almost horizontally. Blending with its tendinous upper edge is the tendon of the abdominal part of the panniculus carnosus. The large external thoracic or "spur" vein also runs along this edge. Clean the surface of the muscle and determine its insertion; then cut it across a handbreadth behind the attachment.

441 The connective tissue on the inner surface of the shoulder is now to be removed. In doing this note the large brachial artery and vein which cross the inner surface of the shoulder joint and turn down along the arm; also the branches of the brachial plexus of nerves. Then remove these.

187 The subscapularis muscle is exposed. Behind the subscapularis is the teres major. At the shoulder joint the two muscles are separated by an interval into which the subscapular vessels and the axillary nerve disappear. Clean out this space and extend the separation of the two muscles upward as far as any natural division can be made. The axillary lymph glands lie on the teres major at the level of the shoulder joint; examine and remove them.

Reflect the skin as far as the inner surface of the elbow. Clean the surface of the posterior superficial pectoral muscle. Dissect up this muscle as far as the elbow and reflect it.

The deep internal brachial fascia is now seen extending from the biceps brachii in front to the tensor fasciae antibrachii behind. Identify the internal tuberosity and the internal epicondyle of the humerus. Beneath the fascia are the brachial artery and vein, accompanied by large





nerves. Incise the fascia over the vessels and reflect it. On the vessels at the lower third of the arm are the cubital lymph glands. The vessels, nerves, glands, and connective tissue are to be removed. 441

Clean the surface of the tensor fasciae antibrachii from below upward. Be careful not to injure the thin aponeurosis of origin which blends with the latissimus; leave them connected. 187

Clean the common tendon of insertion of the teres major and latissimus dorsi; its attachment is concealed by the coraco-brachialis. Raise the stump of the latissimus dorsi and dissect it off the part of the aponeurosis of the tensor fasciae antibrachii which arises from the posterior border of the scapula.

Separate the tensor fasciae antibrachii from the long head of the triceps, beginning at the posterior border. The aponeuroses of the two blend at their scapular origin. Cut the tensor across a handbreadth above the elbow to facilitate the separation and reflect the flaps.

The long head of the triceps is now largely exposed. In front of it is the relatively small internal head. Clean these and separate them.

Clean the surface of the coraco-brachialis. Examine the long tendon of origin and its synovial sheath. The insertion is partly concealed by the biceps at present.

Turn the limb over and begin the dissection of the external surface of the shoulder and arm.

Reflect the skin as far as the elbow. The superficial fascia and the scapulo-humeral part of the panniculus carnosus are exposed. What is the direction of the fibres of the latter? Reflect the fascia and panniculus as far as the elbow.

Clean thoroughly the part of the mastoido-humeralis which covers the front and outer surface of the shoulder joint. Note that the upper part of the muscle is inserted into the deep fascia of the arm. 178

Remove the superficial fascia from the muscles of the shoulder and from the triceps, but do not remove the glistening aponeurosis which covers a large part of the former. 179

Reflect the stump of the mastoido-humeralis; its tendon of insertion dips in between the biceps and brachialis and will be followed later.

Clean the lower part of the deltoid, but do not disturb its covering aponeurosis. A furrow indicates the posterior border of the muscle; dissect along this furrow from below upward, separating the deltoid from the triceps as far as the division is natural. Dissect up the anterior border from below upward till the aponeurosis is reached.

Clean the lower part of the infraspinatus and supraspinatus. Between the long tendon of the infraspinatus and the deltoid there is a small triangular space in which part of the teres minor is visible.

Cut the deltoid across a handbreadth above the deltoid tuberosity. Reflect the distal stump to its insertion. Dissect up the proximal part

carefully off the long head of the triceps and the distal and posterior part of the infraspinatus as far as the fleshy part extends. It is now evident that the bulk of the muscle arises from the covering aponeurosis of the infraspinatus.

The fleshy part of the teres minor is now partly exposed, but its tendon of origin is covered by the infraspinatus. Dissect up the posterior border of the teres minor. A sheet of fibrous tissue extends over the tendon of the infraspinatus and is attached to the superficial tendon of the teres minor; remove it and define the insertion of the teres. Raise the posterior border of the infraspinatus and dissect it carefully off the teres, from the tendon of which many fibres of the infraspinatus arises.

Separate the distal third of the infraspinatus from the supraspinatus, working from below upward. Undermine the distal part of the belly of the infraspinatus and cut it across a couple of inches above the tendon. The proximal part may be easily reflected, taking the periosteum with it. Raise the distal stump and dissect its two attachments, taking care not to injure the capsule of the shoulder joint. The deep part is inserted into the upper edge of the posterior part of the external tuberosity of the humerus. Cut this attachment and reflect the long tendon. Note its structure and the bursa beneath it.

Cut the teres minor across a couple of inches above its insertion and reflect both parts; do not injure the joint-capsule. Clean thoroughly the outer surface of the triceps. A furrow shows the line of separation of the long and external heads. Dissect them carefully apart, beginning in front. Is the separation at the insertion distinct? Raise the lower border of the external head and cut the muscle across a little in front of its middle. Dissect up both parts. In the case of the proximal stump there is no difficulty, but the separation of the lower part from the underlying anconeus requires care. Begin at the lower border.

Note the thick fascia which extends from the deltoid tuberosity to the external surface of the elbow joint. It bridges over the musculo-spiral groove and the brachialis muscle. What muscle arises in part from this fascia?

The origin of the brachialis is now exposed. Find the small capsularis muscle. At the distal part of the arm you can recognize the external condyloid crest and the extensor carpi radialis arising from it.

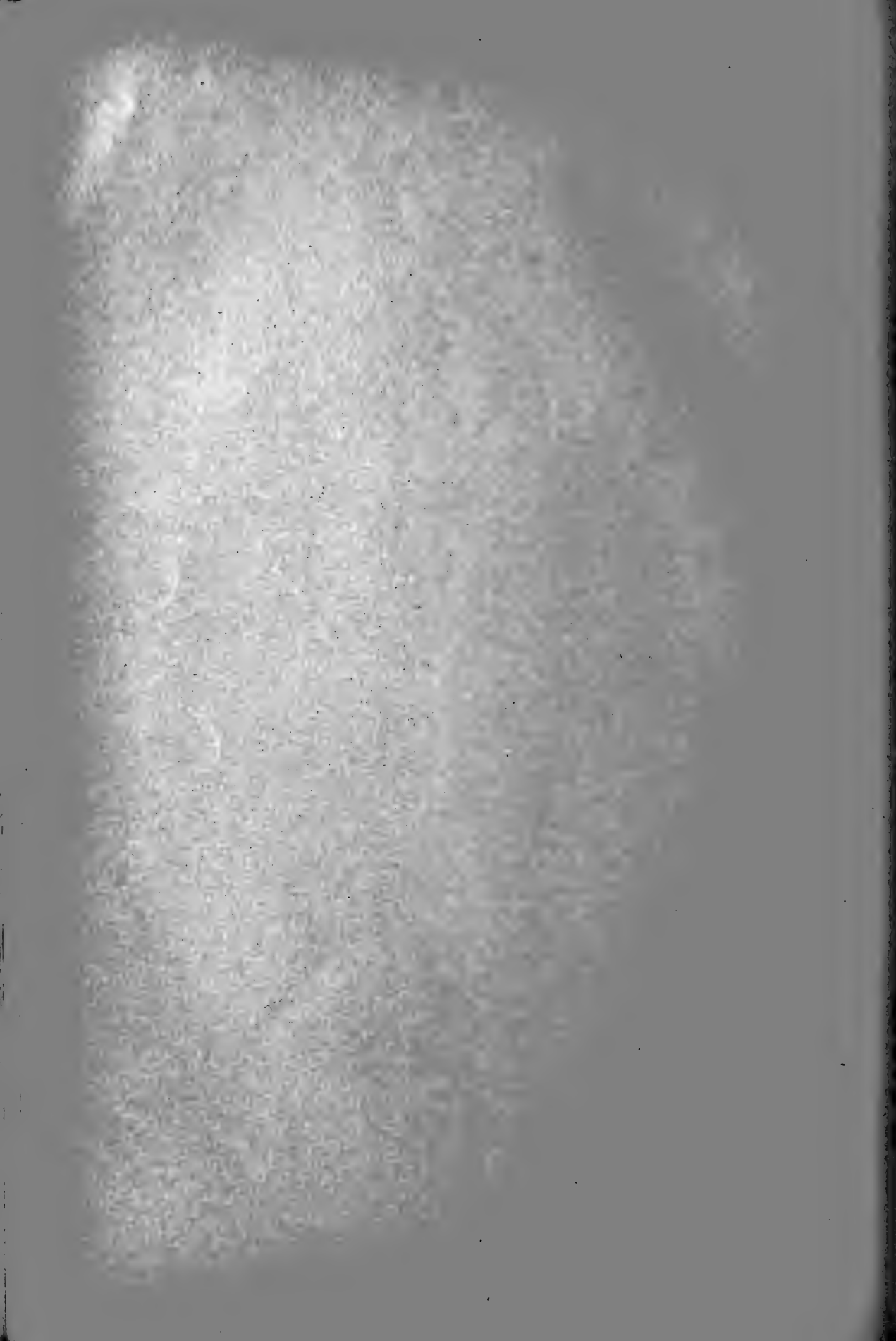Replace all parts and review the region.

Place the limb with its anterior surface facing you. Remove the anterior deep pectoral muscle with the exception of a short stump of its upper end. The supraspinatus is now exposed; clean its surface and define its borders.

Clean the terminal part of the posterior deep pectoral muscle. The insertion is threefold. Some fibres are attached to the tendon of origin of the coraco-brachialis. The bulk of the fibres end on the anterior part







of the internal tuberosity of the humerus, but a layer extends further forward and is attached to a tendinous sheet which stretches across from the inner to the outer tuberosity of the humerus. This sheet is a part of the fascial sheath of the biceps; it binds down the tendon of origin of the biceps in the bicipital groove, converting the latter into a canal.

The biceps lies on the front of the arm, enclosed in a double sheath of fascia; the latter is attached to the anterior parts of the tuberosities of the humerus and to the deltoid tuberosity, and is continuous below with the deep fascia of the forearm. Slit this sheath lengthwise over the middle of the biceps and reflect it. Be careful not to damage the long tendon which extends from the biceps to the extensor carpi radialis and is not distinct from the deep fascia; it can be felt and should be artificially defined and retained. The tendon of the biceps is seen to occupy the bicipital groove, and the large bicipital bursa lies under the tendon here. Note that the bursa extends in part around the edges of the tendon to the superficial face of the latter. The origin of the biceps is concealed at present by the supraspinatus. Slit the lower part of the supraspinatus upward to expose the bicipital tuberosity (tuber scapulae) and the origin of the biceps. Are all of the fibres of the supraspinatus inserted into the lips of the bicipital groove? Note the large suprascapular nerve which passes outward between the supraspinatus and subscapularis. Cut the supraspinatus across at this point and follow both divisions to their insertions. The origin of the coraco-brachialis is exposed.

187  
188

Cut the biceps across at the middle of the arm. Reflect the proximal part and explore the bicipital bursa (bursa intertubercularis). Note also the form and structure of the tendon of origin. Raise the distal stump and clean the insertion of the coraco-brachialis.

The tendon of insertion of the mastoido-humeralis and anterior superficial pectoral muscles is now accessible. Take hold of the muscle stumps and tense the tendon and clean its surfaces. Note the radial nerve lying along its outer side and the anterior radial vessels at its inner side. Clean the front of the humerus. Replace the various parts and review the region.

Complete the dissection of the inner surface. Cut the subscapularis across a handbreadth above the shoulder joint, and reflect both parts. The distal part is intimately attached to the capsule of the shoulder joint and is to be carefully separated from it. The capsularis muscle lies on the posterior surface of the joint capsule.

Cut the teres major and latissimas dorsi across a handbreadth from the insertion and reflect both parts, taking the tensor fasciae antibrachii with the proximal part. This uncovers the origin of the long and inner heads of the triceps and the brachialis. The insertion of the latter may be exposed by cleaning the internal lateral ligament of the elbow joint and removing the fascia in front of it. Note that the inner fibres of the tendon of the biceps are attached to the ligament.

If desired, the long head of the triceps may be cut across about an inch from its origin, so that the shoulder joint may be examined on all sides. Review the arrangement of the muscles and tendons in relation to the shoulder joint. The only uncut muscles extending from the scapula to the humerus are the coraco-brachialis and capsularis. Cut the former below the joint. If there is no opening in the capsule the head of the humerus will remain in contact with the glenoid cavity when the limb is held up by the scapula. If the capsule is perforated the head of the humerus promptly drops about an inch. Disarticulate by a circular incision of the joint capsule. Examine the latter and the joint surfaces.

Review the insertions of the muscles on the humerus. For convenience shorten the stump of the long head of the triceps. Follow the peculiar spiral course of the brachialis.

#### THE FOREARM.

Identify the bony prominences at each end of the region. Palpate the inner subcutaneous surface of the radius, which intervenes between the  
178 extensor muscles on the dorso-lateral surface and the flexors behind.  
187 Note the form and position of the mass of horn known as the "chestnut."  
190 Study figures of superficial dissections and see how much you can recognize on your specimen of what is shown there.


Incise the skin down the middle of the anterior surface of the forearm and reflect it.

442 The large cephalic vein extends from the distal end of the biceps to the inner surface of the carpus. In front of it is the smaller accessory cephalic vein.

Clean the aponeuroses of the posterior superficial pectoral and tensor fasciae antibrachii and follow them till they fuse with the deep fascia of the forearm. The first-named muscle may be removed.

Remove the superficial fascia, exposing the deep fascia, and study the latter.

190 Place the limb with its anterior surface facing you, and identify the extensor muscles. The fascial compartments in which the muscles lie are to be opened up by slitting the fascia lengthwise over the middle of each muscle, NOT along the furrows between the muscles. Incise the fascia over the extensor carpi radialis, i. e., practically down the middle of the anterior surface of the forearm. In doing so be careful not to cut the tendon of the extensor carpi obliquus, which crosses the extensor carpi radialis in the distal third of the region; also preserve the long tendon of the biceps. Reflect the fascia on each side of the incision, beginning below. At the upper part of the region fibres of the muscle arise from the fascia and must be cut off it. The inner flap is attached to the inner border of radius. The outer flap dips in between the extensor carpi and anterior





extensor as an intermuscular septum. Open up the fascia in a similar fashion over the anterior and lateral extensors of the digit and the extensor carpi obliquus. It is best not to dissect as far down as the synovial sheaths of the extensor tendons at present. But in case you have done so, insert a probe into the sheath and determine its extent upward and downward. Mark the upper limit on the tendon by nicking the latter slightly.

Clean the fleshy part of the extensor carpi obliquus.

Dissect the outer side of the extensor carpi radialis from the intermuscular septum, working from below upward.

Clean the anterior extensor. Find the small tendon of the radial head which lies along the outer border of the chief tendon. Dissect upward along this and isolate the radial head so far as a natural separation exists. Can you find the very small ulnar head in the middle of the region? It comes from the ulna at the level of the interosseous space, but its upper part is concealed by the radial head and the lateral extensor at present. 443

Place the limb with its posterior surface facing you. Slit the fascia from the accessory carpal bone to the olecranon, and also divide it transversely a little below the fleshy part of the tensor fasciae antibrachii. Reflect the inner flap to its attachment to the radius. Reflect the outer flap similarly. Are any intermuscular septa given off?

The ulnar head of the deep flexor of the digit forms the posterior contour of the forearm in its upper fourth. Below this there is a furrow between the external and middle flexors of the carpus, in which the ulnar vessels and nerve lie. Remove the vessels and nerve and open up the furrow; find here the slender tendon of the ulnar head of the deep flexor and follow it upward to the belly of the muscle. Separate the latter from the flexor carpi externus.

Lay the limb on its outer face. Clean the flexor carpi internus, which lies behind the subcutaneous surface of the radius. Note the posterior radial vessels and median nerve disappearing under the upper part of the anterior border of the muscle. Cut these off at this point and clean the internal lateral ligament of the elbow joint if this has not been done. Is there any trace here of a pronator teres muscle? If so, call the attention of an instructor to it. 442  
187

Dissect along the anterior border of the flexor carpi medius from below upward. Take care in dissecting up the posterior border not to cut the thin ulnar head in the proximal third of the forearm. The ulnar vessels and nerve lie beneath this head, and may be removed. Clean the inner surface of the ulnar head of the deep flexor.

Lay the limb on its inner surface, and clean the flexor carpi externus. The deeper dissection of the region should be deferred till the lower part of the limb (the manus) is dealt with. 191

CARPUS, METACARPUS, AND DIGIT.

190 Identify the bony prominences of the lower part of the limb. Study  
191 figures of superficial dissections and endeavor to recognize the ligaments  
447 and tendons shown in them.  
522

Incise the skin down the middle of the anterior surface of the limb and reflect it, cutting it from the upper border of the hoof as far as necessary at this stage.

Examine the superficial fascia and reflect it in a similar manner.

The deep fascia is strengthened by transverse fibres at the distal end of the forearm and at the carpus, forming the anterior annular ligament of the carpus. The extensor tendons and their synovial sheaths here must  
195 be carefully examined. Study figures illustrating these, and if you do  
196 not understand the arrangement, ask an instructor for a demonstration. Try to inflate the synovial sheaths with the blowpipe or insert a probe and determine their extent upward and downward. Slit them open and note the character of the inner surface and the glistening appearance of the tendon covered with synovial membrane. Find the mesotendon.

Note the marked increase in size of the lateral extensor tendon below the carpus. How is it accounted for?

Clean the tendons below the carpus and also the metacarpal bones and first phalanx in so far as they are free. Clean and define the anterior annular ligament of the fetlock and the branches of the suspensory ligament which join the extensor tendon on the front of the digit. Find the bursa under the anterior extensor tendon at the fetlock joint.

Remove the rest of the skin from the limb and turn the posterior face of the latter toward you. Remove the superficial fascia. In doing so  
447 note the metacarpal and digital vessels and nerves on either side of the  
522 flexor tendons. Look for the small band which descends on either side of the digit from the fibrous basis of the ergot; also the delicate tendons of the internal and external interossei above the fetlock.

The dissection of the deep fascia requires much care and patience. Note its great thickness from the distal part of the forearm to about the middle of the metacarpus. It is attached to the accessory carpal bone, the internal lateral ligament of the carpus, and the small metacarpal bones. Above the carpus it blends with the tendons of the middle and  
194 external flexors of the carpus. At the carpus it forms the posterior annular  
445 or transverse ligament of the carpus, which completes the carpal canal.  
447 This ligament is extremely thick, and is partially divisible into two or three layers, between which lie large veins, an artery, and a nerve, and at the inner side, the tendon of the flexor carpi internus.

Define and follow to their insertions the tendons of the flexors of the carpus. Clean the lateral ligaments of the carpus.







Open up the carpal canal by slitting the transverse ligament vertically. What are the attachments of the ligament? What does the canal contain? Explore the carpal synovial sheath and mark its upper and lower limits by nicking the flexor tendons.

The flexors of the digit are now to be dissected. Cut the flexor carpi internus across at the middle of the forearm, and dissect up both parts. The median nerve, the posterior radial artery, and usually two satellite veins are now seen descending on the muscular mass behind the radius. **442**  
Examine and remove them, together with the connective tissue about them. Cut the flexor carpi medius at the middle of the forearm, and dissect up both parts.

The flexors of the digit are now exposed, and are to be separated from below upward to avoid error. Begin below the carpus and dissect up the superficial flexor tendon. Take care not to cut the radial or superior check ligament when dissecting along the inner side at the lower third of the forearm. Do any of the fibres of the ligament go to the deep flexor? The belly of the superficial flexor is closely adherent to the deep flexor, and must be carefully isolated. **193**

The superficial flexor may be cut across at the middle of the forearm if found desirable in order to facilitate dissection of the deep flexor. In dealing with the latter begin at the carpus, and use the three tendons as means of isolating the three heads. It is not necessary to subdivide the humeral head.

It is advisable at this stage to remove the hoof. In well-preserved subjects the hoof usually adheres very closely and its matrix is therefore damaged more or less extensively in the process of removal.\* With a cartilage knife separate the upper part of the wall of the hoof from its matrix. Saw through the wall from top to bottom at four places at least. Grasp the portions of the wall thus separated with hoof pincers and tear them off. If two saw cuts have been made near the heels it is usually possible to remove the part behind them together with the sole, frog, and bars.

Dissect out the plantar cushion, which occupies most of the space between the lateral cartilages. Clean the cartilages and the wall and sole surfaces of the third phalanx. Note the insertion of the anterior extensor of the digit.

Clean and define the posterior annular ligament of the fetlock and the two digital annular ligaments. Examine and remove the vessels and nerves which descend on either side of the flexor tendons and clean the tendons and the suspensory ligament in so far as they are exposed. In doing so look for the small lumbricales muscles. **522**  
**189**  
**198**  
**447**

\*The interior of the hoof and the matrix should be studied on unpreserved material, from which the hoof can be removed in toto by immersing the digit in boiling water for ten or fifteen minutes or by allowing the hoof to be loosened by decomposition.

Separate the flexor tendons from above downward. Study illustrations of the digital synovial sheath (injected) and account for the pouches shown. Endeavor to inflate the sheath. Slit the posterior annular ligament of the fetlock vertically. Examine the ring formed here by the superficial flexor tendon. Explore the upper part of the digital sheath and mark its highest point on the tendons.

150 Slit the digital annular ligaments vertically and reflect the flaps. What are their attachments?

Cut through the ring of the superficial flexor tendon on one side and raise the tendon. Note the terminal bifurcation of the tendon and the insertion of the branches. Cut one branch and reflect the tendon. To expose the deep flexor more fully the superficial flexor may be removed after cutting its radial check ligament and other branch of insertion.

Raise the deep flexor tendon at the upper end of the metacarpus and pass a finger downward into the lower part of the carpal sheath in front of the tendon. The subcarpal check ligament is in front of your finger. Clean the ligament and dissect it up as far as possible from the suspensory ligament. Cut the deep flexor tendon across just below the middle of the metacarpus. Dissect up the proximal part, taking the check ligament with it, as far as the upper end of the metacarpus. Turn down the lower part of the tendon. In doing so determine the lower limit of the digital sheath and mark it on the tendon. Just below it a layer of connective tissue extends from the tendon to the capsule of the coffin joint; cut through this layer, keeping close to the tendon. The navicular bursa is opened; expose it, noting carefully its position and extent.

151 What three pulleys does the deep flexor tendon pass over? Examine the deep face of the tendon, observing its form and structure at different points. Note its insertion.


#### THE ELBOW JOINT.

Review the arrangement of the muscles about the elbow joint.

Cut the tendon of the biceps which joins the extensor carpi radialis. Pull the lower stump of the biceps inward and cut the deep principal insertion to the bicipital tuberosity of the radius. Sever the superficial insertion from the internal lateral ligament. Cut the brachialis across at the middle of the arm, and reflect the lower part to its insertion under the long internal lateral ligament; it may be cut off short here. Cut the extensor carpi radialis and anterior extensor of the digit across a hand-breadth below the elbow and dissect up the proximal stumps to their origin; cut them off, leaving short stumps. The front of the elbow joint is now exposed, and the joint capsule is to be cleaned.

Remove the anconeus carefully from the posterior part of the joint capsule. It is hardly possible to remove the flexors of the carpus and digit without opening the pouches of the synovial membrane of the joint which extend down a short distance under them.





Open up the joint capsule both in front and behind, and explore the joint cavity.

Note the attachments of the lateral ligaments and define them clearly. Cut the long part of the internal ligament across over the insertion of the brachialis to expose the latter. Disarticulate the joint and examine the joint surfaces and the attachment of the joint capsule.

Expose the interosseus space and examine the tranverse or arciform ligaments.

The lower part of the limb may be separated by sawing through the lower third of the forearm and cutting any soft tissues.

#### THE CARPAL JOINTS.

Clean the anterior part of the carpal joint capsule. It blends on either side with the lateral ligaments. The latter give attachment to the carpal fascia and hence they have a rather rough surface when the fascia is removed. The lateral extensor tendon descends in a canal in the external lateral ligament. 144  
to  
147

Note the bands which extend from the accessory carpal to the metacarpus; they transmit the pull of the external and middle flexors of the carpus.

The posterior part of the capsule (posterior ligament) is very thick and is closely adherent to the underlying bones. It forms the smooth anterior wall of the carpal canal. How is it continued downward?

Remove the anterior part of the capsule and note the three synovial sacs. Flex the joint and observe the movements of the bones. Clean the small ligaments.

Take hold of the check ligament and forcibly remove the posterior part of the joint capsule. Examine the small ligaments here and the upper attachment of the suspensory ligament.

Disarticulate the radio-carpal and intercarpal joints, but leave the distal row connected with the metacarpus

#### THE SESAMOIDEAN LIGAMENTS.

The superior sesamoidean or suspensory ligament of the fetlock has been exposed in the previous dissection. Clean and examine the ligament carefully, noting its form, position, and attachments. 150  
151  
191  
193  
198

Examine the intersesamoidean ligament and the smooth pulley formed by it and the sesamoid bones at the fetlock.

Dissect carefully the inferior sesamoidean ligaments. Observe that all of these ligaments form a continuous stay apparatus, in which the sesamoid bones are intercalated at the point of greatest pressure; note further the branches of the suspensory ligament which go forward to the extensor tendon. It is interesting to cut the suspensory ligament above the fetlock, noting the effect on the digital joints when weight is put on the limb.

#### THE FETLOCK JOINT.

Dissect up the extensor tendons, noting their attachments and bursa here. Clean the anterior part of the capsule and the lateral ligaments. Endeavor to inflate the capsule and note especially how it pouches upward behind the lower part of the large metacarpal bone. Open the front of the joint and explore the cavity here. Cut the lateral ligaments, remove  
148 the metacarpal bone, and examine the joint surfaces. Find the short  
149 sesamoidean ligaments.

#### THE PASTER N JOINT. \*

The anterior surface of the joint is covered by the wide extensor tendon, and the synovial membrane is attached to the deep face of the tendon.  
151 Clean the lateral ligaments. What structures lie on the posterior surface of the joint? Dissect the volar ligaments. Reflect the extensor tendon and examine the joint surfaces.


#### THE COFFIN JOINT.

The front of the joint is covered by the broad terminal part of the  
150 extensor tendon, to the deep face of which the synovial membrane is  
151 attached.  
152

Remove part of the lateral cartilage to expose the side of the joint. Observe how the joint capsule pouches out against the deep face of the cartilage. Clean the lateral ligaments.

Remove the deep flexor tendon. Clean the suspensory ligaments of the navicular bone. Note the pouch of the joint capsule above the level of the navicular bone. How is the joint capsule reinforced below the navicular bone? Remove the second phalanx and examine the joint surfaces.







## THE ABDOMEN, PELVIS, AND PELVIC LIMB.

### THE ABDOMINAL MUSCLES AND TUNIC.

Find the median depression which indicates the position of the xiphoid cartilage. From this follow the costal arch and locate the last rib. Note the median raphe of the skin and examine the umbilicus. If the subject is a gelding look for scars or depressions resulting from the castration incisions. Are the stumps of the spermatic cords adherent to the skin? Palpate the external inguinal ring and the prepubic tendon. Study the external part of the prepuce and its cavity. If the subject is a stallion examine the scrotum, if a mare study the mammary glands. Note the arrangement of the fold of the flank on either side. Can you trace the large external thoracic vein?

Make an incision of the skin just to one side of the ventral median line from the xiphoid cartilage to the prepubic tendon, but leave a ring of skin around the preputial orifice. From this carry an incision transversely in a plane behind the last rib. Another transverse incision is to be made from the xiphoid cartilage outward and upward to a horizontal line on a level with the point of the shoulder. Reflect the large anterior flap as far as the origin of the external oblique muscle (refer to text figure for this). Reflect the small posterior flap and secure it to the inner surface of the thigh. Take care to reflect only the skin. Is this difficult? Why?

178  
186

Examine the superficial fascia and the abdominal part of the panniculus carnosus; clean the latter and observe the external thoracic (spur) vein. Cut these across along lines corresponding to the skin incisions and reflect them.

466

Slit the prepuce along the ventral median line and expose the fascia penis and penis. Examine these and reflect the penis far enough to expose the prepubic tendon. Note the large venous plexus about the penis.

If the subject is a mare, the mammary glands are to be examined and removed.

The abdominal tunic is now exposed, and after examination is to be removed in great part. This procedure is somewhat tedious. Begin laterally over the fleshy part of the obliquus abdominis externus. Remove the tunic in strips in the same direction as the fibres of the muscle. Much care is necessary when dissecting the tunic off the external oblique to avoid injury to the latter. It is best to leave the tunic on ventrally where it is partly interwoven with the aponeurosis, but it must be carefully removed in the inguinal region, so that the external inguinal ring is properly exposed. Remove the tunic from the digitations of the serratus magnus which dovetail with those of the external oblique.

178  
186

186 The major part of the obliquus abdominis externus is now exposed. Note its line of origin. Have the fibres all the same direction? Cut the muscle across about a handbreadth from its origin, and also incise it transversely in the flank a short distance behind the last rib. This latter incision is to be carried from the upper part of the flank to the outer edge of the rectus abdominis, i. e., to the place where the aponeurosis of the two obliqui blend. Reflect the upper part of the muscle to its origin. Beginning in front of the flank incision reflect the lower part and the aponeurosis till the latter blends with that of the internal oblique. Behind the flank incision it is necessary to cut the aponeurosis of the external oblique alongside of the linea alba to permit of reflection of the posterior part. Care is necessary here as the aponeurosis is thin and easily torn.

179 The obliquus abdominis internus is now largely uncovered and is to be cleaned. Its fleshy part is to be cut across in a direction corresponding to the flank incision of the external oblique. Reflect the anterior part to its attachment to the costal cartilages and the line of fusion with the aponeurosis of the external oblique. Cut the posterior part of the aponeurosis along the linea alba, and dissect the aponeurosis and the corresponding fleshy part off the underlying rectus and transversus abdominis.

Continue the exposure of the rectus abdominis by dissecting off it the aponeurosis of the oblique muscles, together with the abdominal tunic, in so far as the latter has been retained. To do this the layer formed by the three structures mentioned must be cut alongside of the linea alba and separated carefully from the inscriptions tendineae of the rectus. Do not cut away the posterior attachment of the posterior deep pectoral muscle in the effort to expose the anterior part of the rectus; this part will be uncovered later after the dissection of the pectoral muscles.

After examination of the rectus abdominis, cut the muscle across in the same line as in the case of the obliqui. Reflect the flaps, cutting also alongside of the linea alba.

The transversus abdominis is now largely exposed. Clean the fleshy part and dissect along the inner side of the costal arch till the attachment there is visible. The deep surface is related to the transversalis fascia and the peritoneum. In horses in good condition there is a considerable layer of fat between the transversus and the peritoneum, but in the emaciated subjects generally used for dissection this is almost entirely absent.

When ready for the removal of the viscera, cut the transversus in a transverse direction as done with the other muscles, and also incise it alongside of the linea alba.

#### THE ABDOMINAL VISCERA.

The animal is to be secured squarely on its back. If the subject has been used for the dissection of the muscles the abdomen has been opened. If not, two incisions are to be made through the ventral and lateral walls





of the abdomen. A median incision is carried from the xiphoid cartilage to the prepubic tendon, and a transverse incision is made a little behind the last rib; the latter may extend to the outer edge of the longissimus. In opening the abdomen care must be taken not to cut into the large intestine, especially if the bowel is distended. Make carefully a small incision down to the peritoneum and perforate the serous membrane with the finger. From this opening the incision is to be extended in both directions. In this procedure pass the fingers between the abdominal wall and the bowel, the palm of the hand being toward the wall, and with the other hand introduce the scalpel with its back against the hand in the abdomen. The fingers of the hand in the cavity are kept a little in advance of the point of the knife and thus prevent the bowel being cut. It is much more convenient to use a probe-pointed bistoury for this purpose. Reflect the flaps and secure them out of the way.

Examine and identify the parts of the intestine now visible, but do not disturb them unnecessarily. Determine next the relationship of the intestine to the lateral walls, inclining the subject first to one side, then to the other, for this purpose. 269

Take hold of the left part of the great colon and draw it backward a little so as to see the two anterior flexures, the ventral or sternal and the dorsal or diaphragmatic.

Draw the apex and body of the caecum toward the right flank. Note here the caeco-colic fold. Find the pelvic flexure of the colon and note its form and position before it is displaced.

Raise the left parts of the great colon and lay them on the breast, straightening out the anterior flexures as nearly as practicable. Examine the right parts of the great colon.

Coils of the small intestine and small colon are now exposed and the stomach (covered by the great omentum) is partly visible. Part of the liver and of the spleen can be seen. Study the arrangement of the small intestine; spread enough of it out to examine the great mesentery. Draw the coils of small intestine over the left flank, disturbing the small colon as little as possible in doing this. Find the beginning of the mesenteric portion of the small intestine; it lies ventral to the left kidney and just behind the origin of the small colon. Note here the end of the mesoduodenum, which attaches the duodenum closely to the origin of the small colon. Apply two ligatures to the beginning of the mesenteric part, about a handbreadth apart, and divide the bowel midway between them. Find the terminal part of the small intestine (ileum) and its junction with the caecum. Is the small intestine here at the edge of the mesentery? Apply two ligatures a handbreadth apart and about a foot from the ileo-caecal junction and divide the bowel between them. Now pass one hand under the root of the mesentery, gather up the latter, and cut it across. Lay the small intestine aside for further examination.

Examine the small colon. How does it differ from the small intestine? After noting its position, draw it out of the cavity and spread it out so as to display the colic mesentery. How does the latter differ from the great mesentery? Note carefully the position of the junction of the small colon with the large, as this is constant. What is the shape of the bowel here? Are there any coils of the small colon in the pelvic cavity? Examine other subjects in regard to this. Find the junction of the small colon and rectum. Divide the bowel here, first applying ligatures if deemed necessary. Cut the colic mesentery a short distance from the sublumbar attachment, and draw the small colon—except its origin—out of the abdomen.

Incline the subject toward its left side, and carry the caecum and large colon as far as possible in the same direction. This exposes the pyloric part of the stomach and the greater part of the duodenum, as well as the right lobe of the liver.

This is the most favorable point for the study of the great omentum. Read a description of it. Spread the omentum out and make an opening into its cavity, which is evidently only a potential one in its undisturbed state. Note especially at this stage its colic attachment, as this must be severed to remove the bowel. Find the epiploic foramen (of Winslow). Examine the duodenum and mesoduodenum.

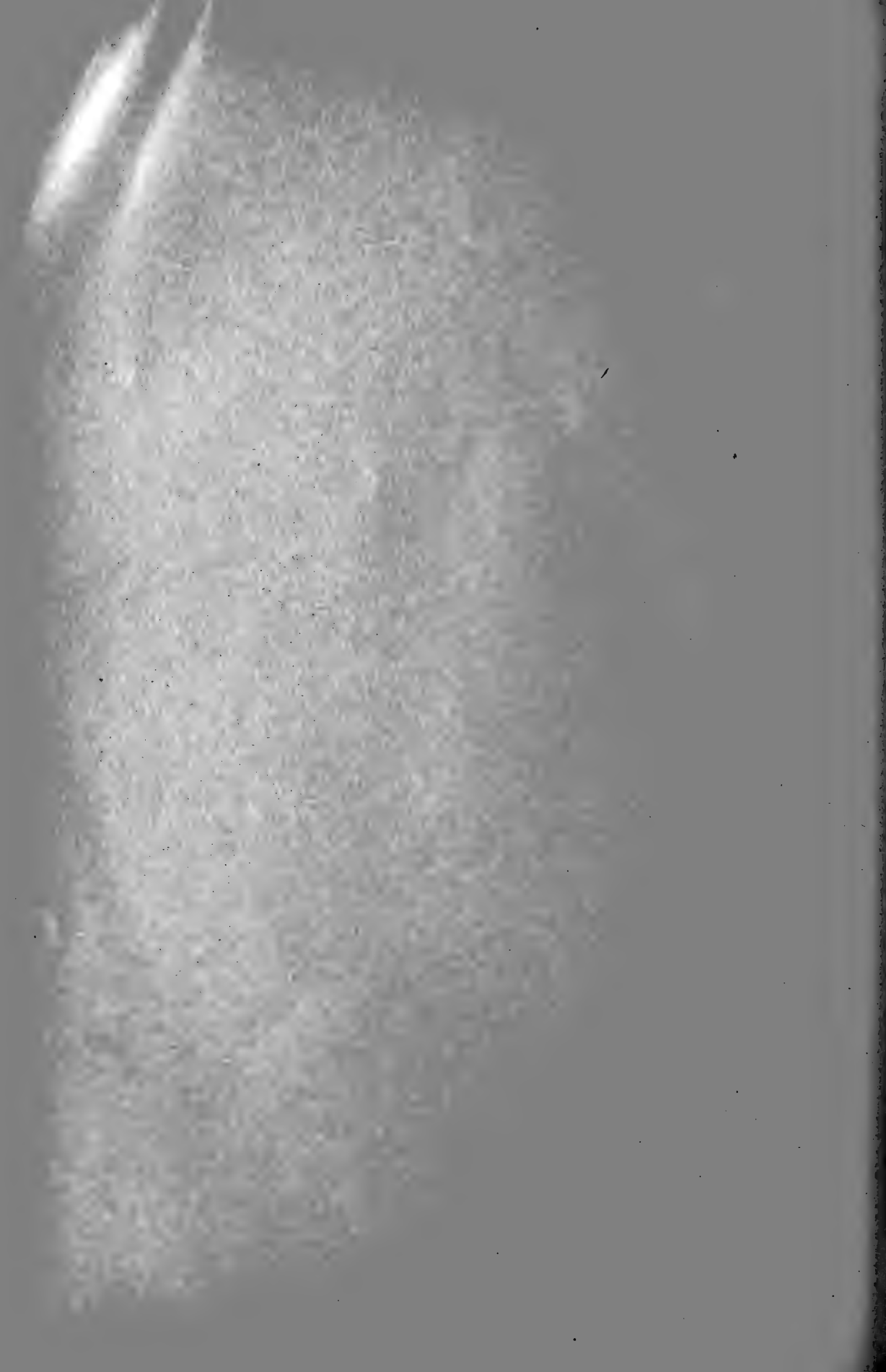The next step is the separation of the caecum and colon from the roof of the cavity. Care and skill are required in this procedure to avoid opening the bowel—an accident which is decidedly disagreeable and should not occur.\* If the intestine is much distended it is well to allow most of the gas to escape through a valvular opening made in the wall of part of the bowel which is outside of the abdomen. Cut the attachment of the great omentum and mesoduodenum to the colon and caecum. Press down with the outstretched fingers the right dorsal part of the colon, and carefully cut through the peritoneum which passes from it to the abdominal wall. Then with the fingers push back the connective tissue till the right border of the pancreas appears. The gland is to be left in situ, so the bowel must be separated from its ventral surface. Use great care now, as the wall of the colon—devoid here of the peritoneal coat—is very easily perforated. The separation may be facilitated by gentle traction on the colon. In a similar way the base of the caecum is to be detached from the sublumbar region. Cut the caecal and colic vessels and remove the bowel.

Study the structure of the small intestine. Examine the serous and muscular coats. Wash out and slit open several feet of the bowel, and examine the mucous membrane. Can you determine the presence of villi? Are Peyer's patches or solitary glands visible?

\*It is the practice of the author to have an instructor demonstrate this step before requiring students to do it.







Next examine the caecum and colon. Note especially the arrangement of the bands. How is the body of the caecum attached to the colon? Separate these and find the junction of the ileum and colon with the caecum. Separate the base of the caecum from the great colon. Examine the great colon. Compare the diameter at different points. How are the dorsal and ventral parts attached to each other? Examine the mucous membrane. Open the caecum at its base and apex, and wash out its contents. Examine the ileo-caecal and caeco-colic orifices. Note the color of the mucous membrane and the extensive folds which project into the cavity of the bowel. Can you find solitary glands?

Examine the small colon. Dissect away part of the mesentery to see the muscular band not now visible. Open up the bowel and note the marked constrictions of its lumen and the character of the mucous membrane.

Return now to the cadaver and proceed with the examination of the viscera which remain in situ. Clean the ventral surface of the pancreas and study the form and relations of the gland. Then carefully dissect it up from behind forward, taking the portal vein with it. Do not sever its attachments to the duodenum and the liver. Note now the chief relations of the dorsal surface. 273

Study the form, relations, and attachments of the stomach, duodenum, liver, and spleen. It is best to remove all of these organs together. Before this is done the position and relations of the kidneys are to be examined, and the right kidney separated from the liver.

Cut the sublumbar part of the mesoduodenum. Raise the left sac of the stomach and dissect it from the diaphragm till the hiatus oesophagus is reached. Endeavor to draw an inch or more of the oesophagus through the hiatus and sever it. Raise the base of the spleen and cut the suspensory ligament.

The separation of the liver from the diaphragm requires care and patience. Raise the right lobe and cut the right lateral ligament. Sever the posterior vena cava just behind the dorsal border of the liver. Cut the left lateral ligament. Draw the ventral border away from the diaphragm and cut the falciform and round ligaments. Sever the posterior vena cava at the foramen venae cavae, and cut the coronary ligament. Endeavor to avoid damaging either the gland or the diaphragm.

These organs are now to be removed together and laid with the parietal surface down on a table. Arrange them as nearly as possible in their natural relations to each other, and examine them systematically. If the stomach and duodenum are collapsed, inflate them moderately.

Note the lesser omentum. Find the bile-duct, and expose it. Explore the epiploic foramen (of Winslow); determine its direction and boundaries.

Expose the pancreatic duct and its chief radicles. Sever the adhesion of the pancreas to the liver. Cut the bile duct and lesser omentum. Separate the pancreas from the duodenum.

Examine the great and gastro-splenic omenta, and cut them off along the greater curvature of the stomach.

261 Open the stomach along its greater curvature and continue the incision along the duodenum. Remove the contents of these organs and wash the mucous membrane. Examine the latter. Note the condition of the cardiac and pyloric orifices. Find the duodenal diverticulum and introduce probes through the pancreatic and bile ducts into it. Can you find the opening of the accessory pancreatic duct? Dissect off the mucous membrane around the cardiac orifice to expose the remarkable sphincter *cardiae*.

274 Examine the liver, studying its lobes, surfaces, borders, and ligaments.

275 What distinct impressions are present? Dissect the structures at the portal fissure. Can you make out the lobulation? Compare the shape, etc., of your specimen with others if possible. How may some of the differences be accounted for?


277 Study the spleen. Note the peritoneal attachments along the hilus and dissect the structures here. Make a cross section of the organ and study it.

Resume the dissection of the sublumbar region. Examine the root of the great mesentery and follow the line of attachment of the colic mesentery.

The kidneys, adrenals, ureters, and vessels are now to be studied. The ventral surface of the right kidney has been exposed largely by the removal of the caecum and the pancreas. Has it any peritoneal covering? If so, remove it and clean off the connective tissue and fat from the gland, the renal vessels, ureter, and adrenal body. Now deal similarly with the left kidney and adrenal. What is the condition here with regard to the peritoneum? Note carefully the form, position, and relation of the kidneys. If the anterior mesenteric artery is enlarged (as is frequently the case) it may be cut off short. Reflect the peritoneum from the aorta, posterior vena cava, and ureters as far back as the pelvic inlet. Separate the dorsal surface of the kidneys from the abdominal wall, taking the adrenals with them. Cut the renal vessels and ureters, and remove the kidneys and adrenals to complete the study of them. Study the adrenals externally and on section. After thorough examination of the external characters of the kidneys, make two sections. Cut the left kidney horizontally, the right one transversely. Wash the surfaces of the sections and study them.

If the subject is a mare, the ovaries, broad ligaments, and cornua of the uterus should now be examined. In the stallion or gelding there is a peritoneal fold on either side which contains the spermatic vessels; follow it to the vaginal ring.





#### SUBLUMBAR MUSCLES, DIAPHRAGM, ETC.

The peritoneum and subperitoneal tissue are now to be removed completely from the sublumbar region. Care must be taken not to open the thoracic cavity where the edge of the diaphragm curves across under the psoas muscles, forming the lumbo-costal arch. In the mare the broad ligaments are to be cut away from their lumbar attachments, and the ovaries and cornua of the uterus pushed back into the pelvis. Leave the pelvic peritoneum intact. 450

Examine the aorta and the posterior vena cava, and remove them. Study the iliac fascia. Then cut it longitudinally and reflect it.

Clean the surface of the psoas muscles, the crura of the diaphragm; and the inferior common ligament, and study these.

Remove the peritoneum from the fleshy rim of the diaphragm and note carefully the costal attachment of the muscle. Examine the tendinous centre and the foramina of the diaphragm. 185

Strip the peritoneum off the lateral abdominal wall so as to expose the origin of the transversus abdominis and the insertion of the tendon of the obliquus abdominis internus to the inner face of the costal arch. Cut the connective tissue which extends from the inner face of the costal arch to the transversus abdominis, so that the actual origin of the latter is seen.

Cut the psoas major across about the middle of the sublumbar region, and reflect it to examine the quadratus lumborum. The subject is now ready to be suspended in the natural position. 524

#### THE LOIN AND FLANK.

Remove the skin from the loin and flank as far back as a transverse plane just behind the external angle of the ilium.

Clean and examine the panniculus carnosus; then remove it. 523

Clean the lumbo-dorsal fascia and examine it.

Remove the fascia from the obliquus abdominis externus in the flank if this has not already been done, and reflect the flaps.

Clean the connective tissue off the external angle of the ilium. Is there a subcutaneous or subfascial bursa here?

Collaborate with the dissectors of the back and thorax in the dissection of the latissimus dorsi and the serratus posticus. Cut the latter across a little above its costal insertion and reflect it. 178

Expose the retractor costae. Cut it across and reflect the flaps. 179  
Expose the lumbar part of the transversus abdominis.

Concur with the dissectors of the back in incising and reflecting the lumbo-dorsal fascia, clean the surface of the lumbar part of the gluteus medius, the longissimus dorsi, and the transversalis costarum.

Reflect the gluteus medius from before backward, separating its deep face carefully from the aponeurosis that covers the longissimus.

With the dissectors of the back, raise the outer edge of the longissimus to see the deep attachments of the muscles to the lumbar transverse processes and the ribs. Dissect down between the supraspinous ligament and the inner surface of the muscle, taking care to separate the longissimus from the multifidus spinae, which lies along the sides of the spinous processes of the vertebrae. Remove the longissimus as far back as a transverse plane tangent to the external angle of the ilium. Study the multifidus.

The hind quarters may now be removed by sawing the spine across at the third lumbar vertebra, and cutting through any soft structures not previously divided.

#### THE PELVIC VISCERA.

**272** Proceed to the examination of the pelvic organs and peritoneum as seen through the pelvic inlet. Do the viscera now present fill the pelvic cavity? If not, what organs formerly occupied the space now vacant?

**270** Examine the rectum and mesorectum. How far back does the peritoneum extend above, below, and on either side of the rectum? Compare  
**271** with other subjects and note any differences.

Raise the rectum and examine the form, position, and ligaments of the bladder.

In the male the urogenital fold overlies the bladder. What structures extend into this fold? Trace the fold laterally and forward.

**407** In the female the uterus and its broad ligaments are to be examined. The latter are homologous with the urogenital fold. Locate by palpation the vaginal portion of the uterus, which lies within the anterior end of the vagina. Now determine how far back the peritoneum extends above and below the uterus and vagina, forming the recto-genital and vesico-genital pouches. How much of a serous covering has the vagina?

#### INGUINAL REGION.

**272** This part of the abdominal wall, which is situated in front of the ventral  
**450** part and the sides of the pelvic inlet, is very important clinically, and is to  
**457** be dissected and studied with great care. The following indications apply to the region in the stallion or gelding.

Push any protruding organs back into the pelvic cavity, and inspect the margin of the pelvic inlet. Determine by palpation what parts of the skeleton enter directly into the formation of the margin, and compare what you find here with the skeleton.

Trace the urogenital fold forward. Where does it disappear from the abdominal cavity? Note here the descent also of the parietal peritoneum through the abdominal wall. What is the opening so formed called? Note carefully its form, size, and position. Incise the peritoneum in circular fashion around the opening and remove it as far back as the pelvic inlet.







Examine the prepubic tendon and the insertion of the recti abdominis.

The fleshy posterior part of the obliquus abdominis internus curves downward and forward on either side. Clean its surface and note the direction of its fibres. Trace the line of origin and observe how the muscle thins out medially. Determine the actual attachment; is it continuous? Locate the internal inguinal ring and note carefully its formation, position, direction, and length. Pass the finger downward through it into the inguinal canal. The inguinal canal is now to be studied and examined fully. Distinguish between the internal inguinal ring and the vaginal ring.

Cut through the anterior wall of the inguinal canal (i. e., the obliquus abdominis internus) from ring to ring and reflect the flaps. The posterior wall of the canal and the structures in the canal are now exposed. Note here the arrangement of the cremaster (externus) muscle.

Read the account of the tunica vaginalis and spermatic cord and examine these. Slit open the parietal layer of the tunica vaginalis. In the gelding the testicle and the scrotal part of the tunica are of course absent, and the spermatic cord and cremaster muscle are usually much atrophied.

Cut the obliquus abdominis internus off close to its origin and remove it. The inguinal ligament is exposed for examination. What really is this so-called ligament?

#### EXTERNAL MUSCLES OF THE HIP AND THIGH.\*

Locate the following skeletal features: The internal and external angles of the ilium, the tuber ischii, the trochanter major and trochanter tertius of the femur, and the patella. Do you find furrows which apparently indicate lines of division between muscles? Study illustrations of superficial dissections of this region and see how much you can recognize of what is shown in the figures. 178  
199

Incise the skin along the dorsal median line as far back as the root of the tail. From here carry an incision down the posterior part of the haunch to a point a little below the level of the stifle. Do not remove the skin from the anus or vulva at present. Make a third incision of the skin down the front of the thigh to the stifle. Reflect the skin. In doing so note the fold of the flank, which extends from the lower part of the flank to the front of the thigh a little above the stifle. What does the fold contain? The precrural or subiliac lymph glands are situated a little higher up. Remove the superficial fascia.

Examine the deep fascia, which comprises the gluteal fascia above and the fascia lata below. The depressions indicate the lines along which intermuscular septa are given off from the deep face of the fascia. In dissecting the fascia, incise it between these depressions, thus demonstrating the septa and also facilitating the separation of the muscles. Begin

\*If desired, the dissection of this region may be deferred until the hind quarters have been separated from each other.

behind and work forward. Slit the fascia over the middle of the surface of the semitendinosus, and also over the biceps femoris to the point where this muscle divides into three branches; from here down three incisions should be made, one over each division of the biceps. Reflect the fascial flaps, thus exposing the two muscles.

199 Begin the separation of the two muscles below, where they diverge over the gastrocnemius. Here there is no difficulty, as the biceps goes to the outer surface of the leg, while the semitendinosus goes to the inner surface. In carrying the separation upward use the intermuscular septum as a guide. In the upper part of the region fibres of both muscles arise from the septum. Carefully dissect the semitendinosus off the septum, leaving the biceps attached to the latter. In many cases an oblique muscular band connects the two muscles in the thigh; this, if present, is to be divided.

Separate the semitendinosus from the semimembranosus so far as convenient at present. Clean the surface of both muscles.

178 Clean the lower part of the superficial gluteus. The tendon of insertion is concealed by the biceps femoris. Much of the muscle arises from the gluteal fascia, which is therefore to be retained in front of the biceps femoris at present. Separate the superficial gluteus and biceps from below upward. The separation of the gluteus from the tensor fasciae latae is simple below, but becomes difficult toward the external angle of the ilium, because here both muscles are attached to a tendinous layer between them. Leave this tendinous layer on the gluteus and dissect the tensor off it.

Clean the tensor fasciae latae and the fascia lata, and study the muscles now exposed.

Cut the semitendinosus across a handbreadth below its vertebral origin. Dissect up the proximal stump to its attachment. Raise the distal stump and separate it from the underlying structures. Find the short head coming from the ventral surface of the ischium. Cut the muscle partially across at the lower border of the tuber ischii, so that the distal part is held in place by the short head.

Cut the biceps femoris across a handbreadth below its proximal end. Reflect the proximal stump. Dissect up the distal stump from the underlying parts. Look for the short tendon which attaches the deep face of the muscle to the posterior surface of the femur close to the third trochanter. Dissect the short head which is attached to the ventral border of the tuber ischii by a strong tendon; does this tendon furnish attachment also to fibres of the semitendinosus? Cut the anterior and middle divisions of the muscle across below the third trochanter, and remove the part above the incision, leaving stumps of the attachments.





Clean the tendon of insertion of the superficial gluteus and remove the aponeurotic layer which extends back over the trochanter major. Clean the latter and the insertion of the middle gluteus. Cut the posterior part of the superficial gluteus across. Reflect the upper stump and its fascial origin.

Remove the remainder of the gluteal fascia from the gluteus medius, cutting from behind forward in the direction of the muscle-fibres. This leaves the surface of the muscle somewhat rough, since many of the fibres arise from the fascia. In dissecting along the outer border of the middle gluteus note the tendinous layer which attaches the superficial gluteus to the outer border of the ilium. 179

The gluteus medius is now to be dissected up and turned backward. Begin in front and carefully separate the lumbar part from the aponeurosis of the longissimus, if this has not already been done. On reaching the ilium scrape the muscle off the bone to the gluteal line. Here a tendinous layer begins to appear; this covers the deep portion of the gluteus medius (or gluteus accessorius). An entirely natural separation of the two cannot be made, but the division may be completed artificially. In dissecting along the inner surface be careful not to cut into the sacro-iliac and sacro-sciatic ligaments. The vessels and nerves to the muscle, which emerges through the greater sciatic foramen, must be severed. Behind this, care is necessary to avoid cutting into the underlying deep gluteus; this muscle can be distinguished by the fact that its fibers are directed almost straight outward from the superior ischiatic spine. To deal more conveniently with the great bulk of the gluteus medius, cut it across a handbreadth in front of the great trochanter, and lay the anterior part aside. Dissect the stumps to their insertion. The part which ends on the posterior part (or summit) of the great trochanter is fleshy superficially, but contains a large deep tendon. The prismatic fleshy point which extends down the back of the great trochanter is attached to the outer face of the trochanteric ridge by a relatively slender tendinous edge. If the deep part (gluteus accessorius) has been left in situ, its strong tendon is seen extending over the anterior part (convexity) of the great trochanter to end on the crest just below. Cut the gluteus accessorius across and reflect the stumps. A large bursa (bursa trochanterica) occurs between the tendon of insertion and the convexity of the great trochanter. 455

Clean the surface of the deep gluteus; note its attachments and the direction of its fibres. What is its relation to the hip joint?

The ligaments of the lateral pelvic wall are now to be cleaned and examined. Note the extremely large sciatic nerve which passes back on the lower part of the sacro-sciatic ligament and turns down behind the hip joint. 154  
526

Clean away the connective tissue behind the hip joint and the upper part of the femur. The sciatic nerve may be removed.

Open up the lesser sciatic foramen. Emerging from this is the tendon of the obturator internus. Follow the tendon outward to its insertion. Immediately below the tendon is the thin gemellus muscle.

A little further down the quadratus femoris extends obliquely downward and forward from the ventral surface of the ischium to the posterior surface of the femur. Clean it and leave it intact.

#### THE PERINEUM.

Fasten the tail up out of the way. Determine the boundaries of the pelvic outlet. What structures occupy the outlet in the male and in the female? Study these parts before removing the skin.

Remove the skin carefully from the perineum and adjacent part of the root of the tail. What is its character?

The perineal fascia extends from the lateral margins of the pelvic outlet to the organs situated here.

453 Clean the fascia off the anus, noting the small anal lymph glands.  
183 The sphincter ani externus and the posterior part of the retractor ani are exposed for examination. Find the recto-coccygei, thick bands of unstriped muscle which extend up from the posterior part of the rectum to the root of the tail.

452 Remove the loose connective at the side of the posterior part of the rectum, exposing the retractor ani more. Find the bulbo-urethral (Cowper's) gland. Note the position of the internal pudic artery and pudic nerve. Expose the so-called suspensory ligament of the anus and observe its relation to the retractor penis.

In the male the root of the penis is to be dissected. Make a median incision of the skin below the anus and extend it between the thighs as far as convenient; reflect the flaps about a handbreadth on either side. Incise and reflect the fascia in a similar manner. The following structures are to be examined: (1) centrally, the retractor penis muscle; (2) also centrally, the bulbo-cavernosus (or accelerator urinae) muscle, enclosing the urethra; (3) on either side, the ischio-cavernosus (or erector penis) muscle enclosing the crus penis; (4) the body of the penis is partly visible.

The ischio-cavernosus is largely concealed by the semimembranosus. Pull the latter to one side or remove a portion of it to expose the former. Dissect the ischio-cavernosus off the crus penis and examine the latter.

453 In the mare the vulva, vestibular bulb, and clitoris are to be dissected. Clean the constrictor vulvae muscle. Find the vestibular bulb. Note the relation of the inferior commissure of the vulva to the ischial arch. The clitoris can be felt in the space between them; expose it and note its attachment to the arch by two crura.







#### THE CROUP AND TAIL.

Clean the dorsal and lateral sacro-iliac ligaments if this has not already been done.

Incise the skin of the tail in the ventral median line and remove it. Note the differences in thickness and closeness of adhesion of the skin.

The coccygeal fascia is exposed. What is it continuous with? The depressions indicate where intermuscular septa pass between the muscles. Incise the fascia longitudinally between the depressions and reflect the flaps, exposing the muscles.

Saw through the ilium internal to the sacro-iliac articulation. The strongest part of the ventral sacro-iliac ligament occupies the angle between the bones here. Examine it and cut through it. Remove the piece of the ilium and the lateral sacro-iliac ligament.

The sacral parts of the sacro-coccygei and the multifidus can now be examined. The sacro-coccygeus inferior, however, is not visible here until the sacro-sciatic ligament is removed and the rectum separated from the roof of the pelvic cavity. It is advisable to do this on one side only or to defer this part of the dissection.

#### THE INTERNAL MUSCLES OF THE THIGH.

The superficial layer of these muscles should be dissected before the two hind quarters are separated. In the male the body of the penis lies between the thighs and can be felt distinctly. Note the character of the skin here.

Incise the skin in the median line and reflect the flaps as far as the inner surface of the stifle. Note the large saphenous vein running upward and forward on the anterior part of the region; also the venous plexus about the penis. 457

Slit the fascia penis longitudinally and reflect it. How many layers are there? Remove this fascia and examine the penis. Dissect up the penis from before backward. Note its suspensory ligaments. Make cross-sections of the body and root, and a median section of the glans, and study them. Remove the venous plexus and the fascia. 451

The femoral lamina derived from the aponeurosis of the obliquus abdominis externus and the thin internal femoral fascia cover the muscles. Examine and remove these. 457

The gracilis forms the greater part of the first layer of muscles. In front of it is the sartorius. Clean these muscles. Note the triangular space between them at the upper part of the region and dissect its contents. Remove the deep inguinal lymph glands and fat, but leave the femoral vessels in place. Separate the fleshy part of the two muscles. 186  
457

Dissect up the posterior border of the gracilis, separating it from the semimembranosus. Clean the exposed part of the latter.

Raise the anterior border of the gracilis and cut the muscle across a handbreadth below its origin. Dissect both parts from the underlying muscles and reflect them. The origin of the gracilis is divided into two parts by an opening through which the large external pudic vein passes. What is the muscle attached to in front of this opening?

451 The second layer of muscles is exposed. It comprises, from before backward, the pectineus, adductor, and semimembranosus. Clean these muscles, and study and prepare the femoral canal. Leave the femoral vessels in situ at present. Dissect along the anterior border of the semimembranosus and separate that muscle from the adductor. Cut the semimembranosus across a handbreadth below its origin and reflect both parts. Dissect up the anterior border of the adductor. Note that the femoral vessels pass between the two branches of the adductor and run in the vascular groove on the posterior surface of the femur. Cut the adductor across a handbreadth below its origin. Reflect the proximal part. Raise the distal stump and cut its inner division across in line with the femoral vessels. Clean the short outer branch which is inserted into the posterior surface of the femur. The insertion of the pectineus is exposed. Prepare the long branch of the adductor which ends on the inner face of the stifle.

456 Two muscles—the quadratus femoris and obturator externus—are exposed in the upper part of the thigh. Between their origins the obturator vessels emerge. Clean and separate the two muscles. Cut the quadratus femoris in its middle and reflect the stumps.

Replace the muscles and review them.

#### PELVIC VISCERA, MUSCLES, ETC.

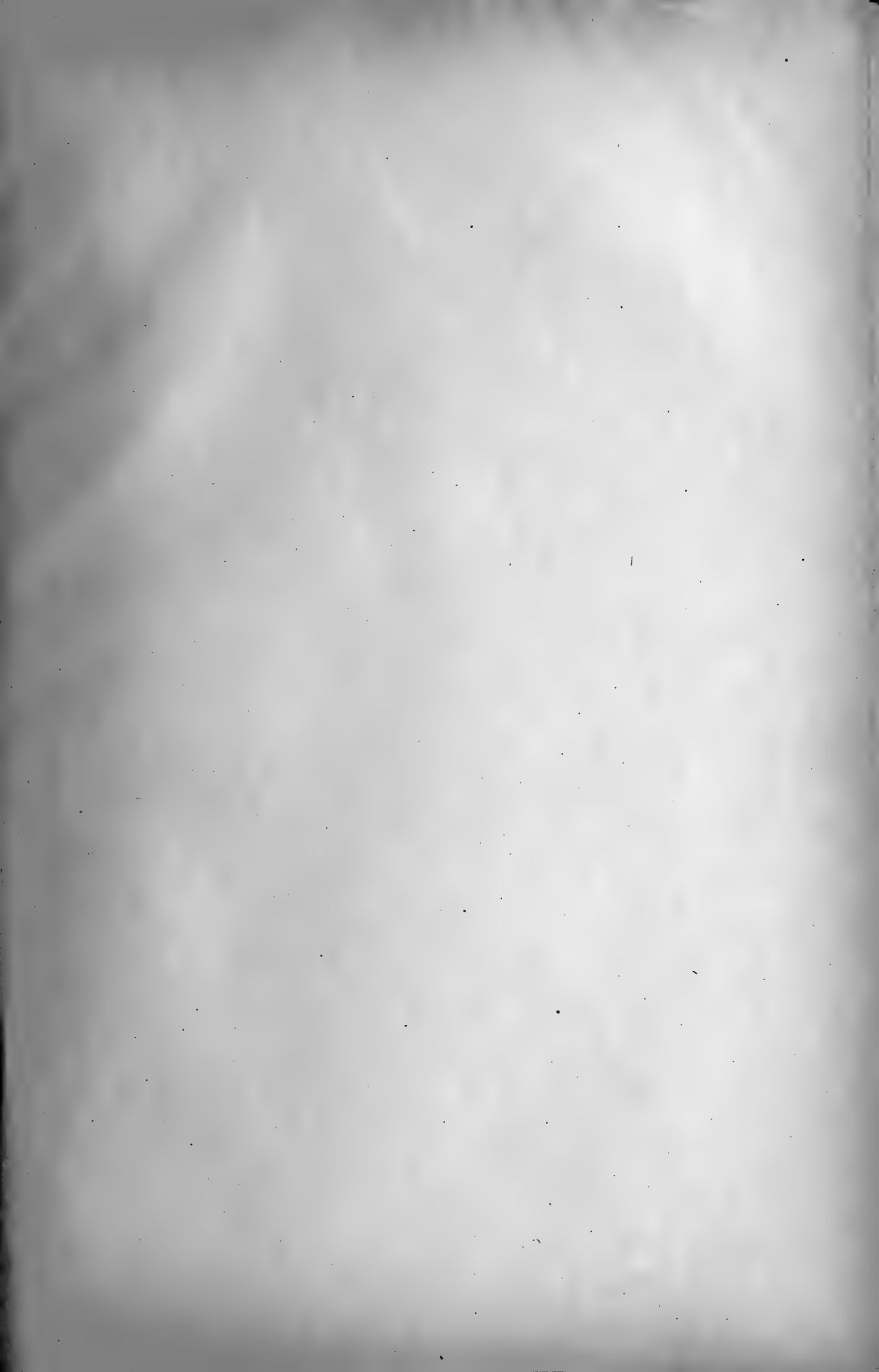
263 Remove the sacro-sciatic ligament on one side. In doing so note the  
267 origin and relations of the coccygeus and retractor ani.

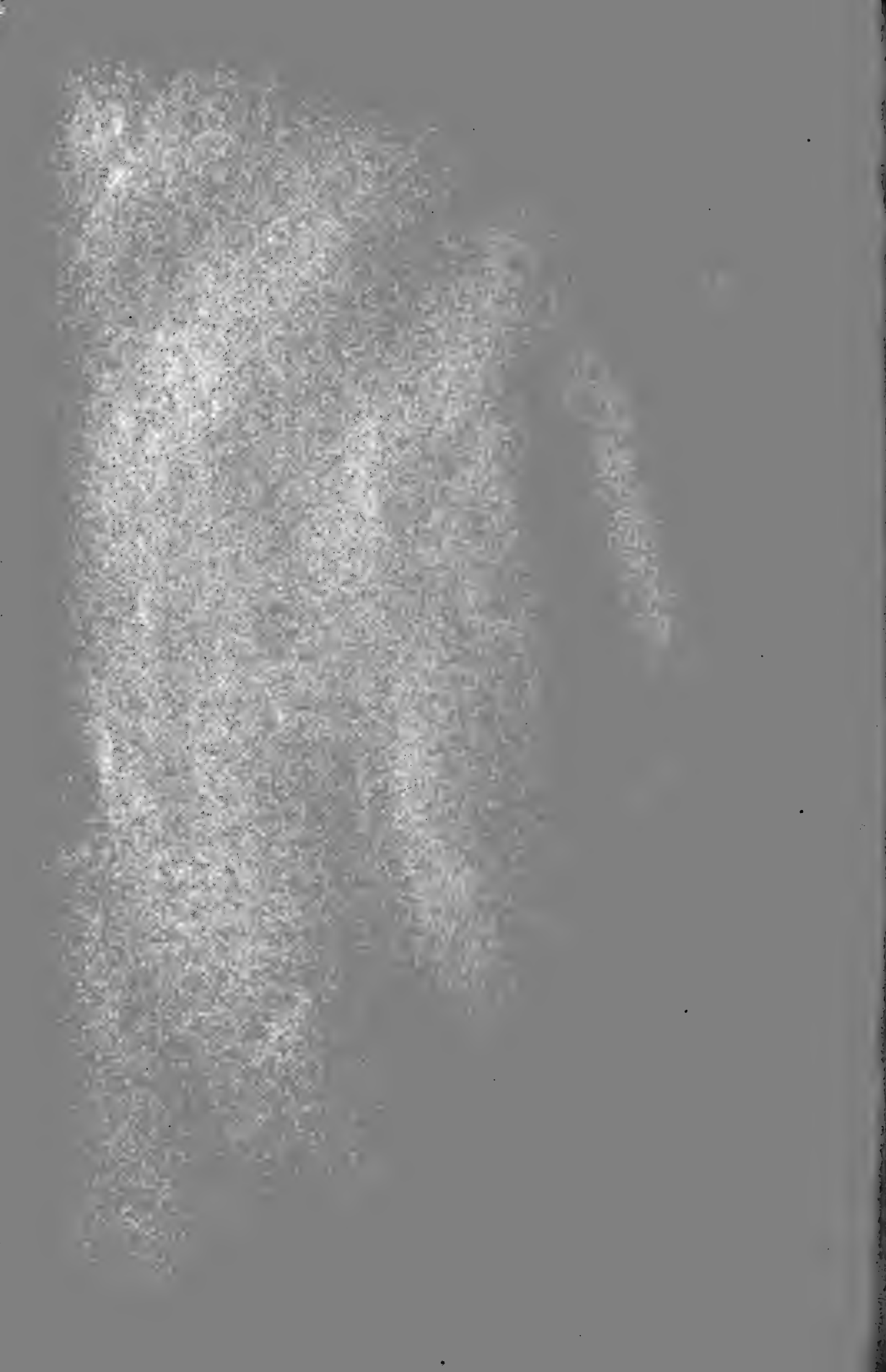
270 Examine the form and relations of the pelvic viscera. Note carefully  
407 the arrangement of the peritoneum.

256 Separate the pelvic organs from the half (or a little more) of the wall  
257 on the side from which the sacro-sciatic is removed.

The pelvis is now to be divided in the median plane, leaving the contained organs on the side on which the sacro-sciatic ligament is retained. Begin ventrally, cut through the soft tissues below the symphysis, and saw through the latter, taking care not to injure the organs on the pelvic floor. Reverse the position of the specimen. Amputate the tail a handbreadth behind the anus. Cut the recto-coccygeus and the suspensory ligament of the anus on the side from which the organs have been separated; also in the male the ischio-cavernosus and crus penis. Saw through the roof of the pelvis in the median plane, taking care not to injure the rectum.

Review the pelvic viscera in relation to the half of the pelvis to which they are still attached. Remove the connective tissue from the retro-





peritoneal part of the rectum. In the male clean the accessory genital glands and the pelvic urethra. In the female clean the vagina, vulva, and constrictor vestibuli muscle. Note the relation of the vulva to the ischial arch. Determine by palpation the position of the vaginal part of the uterus. Remove the organs for further study of their structure.

Examine the serous and muscular coats of the rectum. How are the recto-coccygei formed? Separate the rectum from the other organs; slit it open along the dorsal median line, remove the contents, wash the mucous membrane and examine it.

In the male clean and study the internal genital organs and the urethral muscle. Slit the pelvic urethra and bladder along the ventral median line and examine the mucous membrane and the various openings present here. Can you find the uterus masculinus? In the female slit the genital organs open dorsally, and examine their interior. Slit the bladder and urethra ventrally. Examine the termination of the ureters.

Clean the inner surface of the pelvic wall and examine the two heads of the obturator internus muscle.

#### THE ANTERIOR MUSCLES OF THE THIGH.

In the ordinary standing position the anterior contour of the thigh is practically a vertical line from the point of the hip to the stifle. It is formed by the tensor fasciæ latae and the fascia lata; the latter may be regarded as the tendon of the muscle.

Remove the superficial fascia from the front of the stifle if this has not been done already. Examine the fascia lata.

Cut the tensor fasciæ latae across a couple of inches below its origin, and reflect both parts. After removing the connective tissue and fat which was covered by the muscle, note the lamina iliaca derived from the aponeurosis of the obliquus abdominis externus. What muscle does it cover, and to what is it attached? Remove the lamina to expose the muscle. To what is the fascia lata attached?

Remove the external iliac and femoral vessels to the point where the latter disappear between the two heads of the gastrocnemius.

Cut the pectineus across in its middle, and clean the insertion of the ilio-psoas.

Cut the sartorius across a handbreadth below its origin. Turn down the lower part. Dissect up the proximal part, and prepare the insertion of the psoas minor.

The quadriceps femoris is now exposed. Clean the entire surface of the muscle thoroughly. In the upper part of the region the rectus femoris is clearly separated from the vastus internus and externus by intervals. Clean these spaces and continue the separation of the three muscles downward as far as it is clear. Look for the small capsularis (or rectus parvus) muscle. Note the direction of the fibres of the vastus internus and externus. The vastus intermedius is entirely concealed.

Complete the separation of the upper part of the rectus from the vasti. Lower down the fibres of the vasti must be carefully cut or scraped off the tendinous layer which covers the rectus femoris until the latter is isolated. Remove the middle third of the rectus and dissect the stumps to their attachments.

The isolation of the vastus intermedius is more or less extensively artificial. As a starting point on the inner side take the tendinous layer which covers the surface of the vastus internus in the middle of the region formerly in contact with the rectus femoris. Scrape the fibres of the intermedius off this layer. On the outer side two fissures are usually seen, but neither of these constitutes a complete division between the intermedius and externus; either may be used, and the separation completed artificially.

The vasti and semitendinosus may now be cut across and the femur sawn through at its middle.

Review the pelvic muscular attachments and dissect the hip joint.

#### THE HIP JOINT, ETC.

Review the muscles about the hip joint. These are: the ilio-psoas, 456 rectus femoris, and capsularis in front; the obturator externus internally; the obturator externus and internus and the gemellus behind; the deep gluteus above and externally.

Cut the ilio-psoas across above the acetabulum. Reflect the distal stump to its insertion. Dissect up the proximal part, scraping the muscle off the ilium; and removing it cleanly from the lumbar vertebrae with the exception of the series of digitations along the inner side.

The posterior part of the quadratus lumborum is exposed. To what is it attached?

153 Remove the vessels and nerves in this region and examine the lumbo-  
524 sacral and sacro-iliac joints.

Clean the origin of the rectus femoris. Cut the inner tendon, pull the stump of the muscle outward, and note the outer tendon and its bursa.

Examine the anterior part of the capsule of the hip joint.

456 Raise the obturator externus and cut it across, taking care not to injure the joint capsule. The obturator vessels and nerve descend through the outer part of the obturator foramen; they may be removed. The inner part of the capsule is exposed.

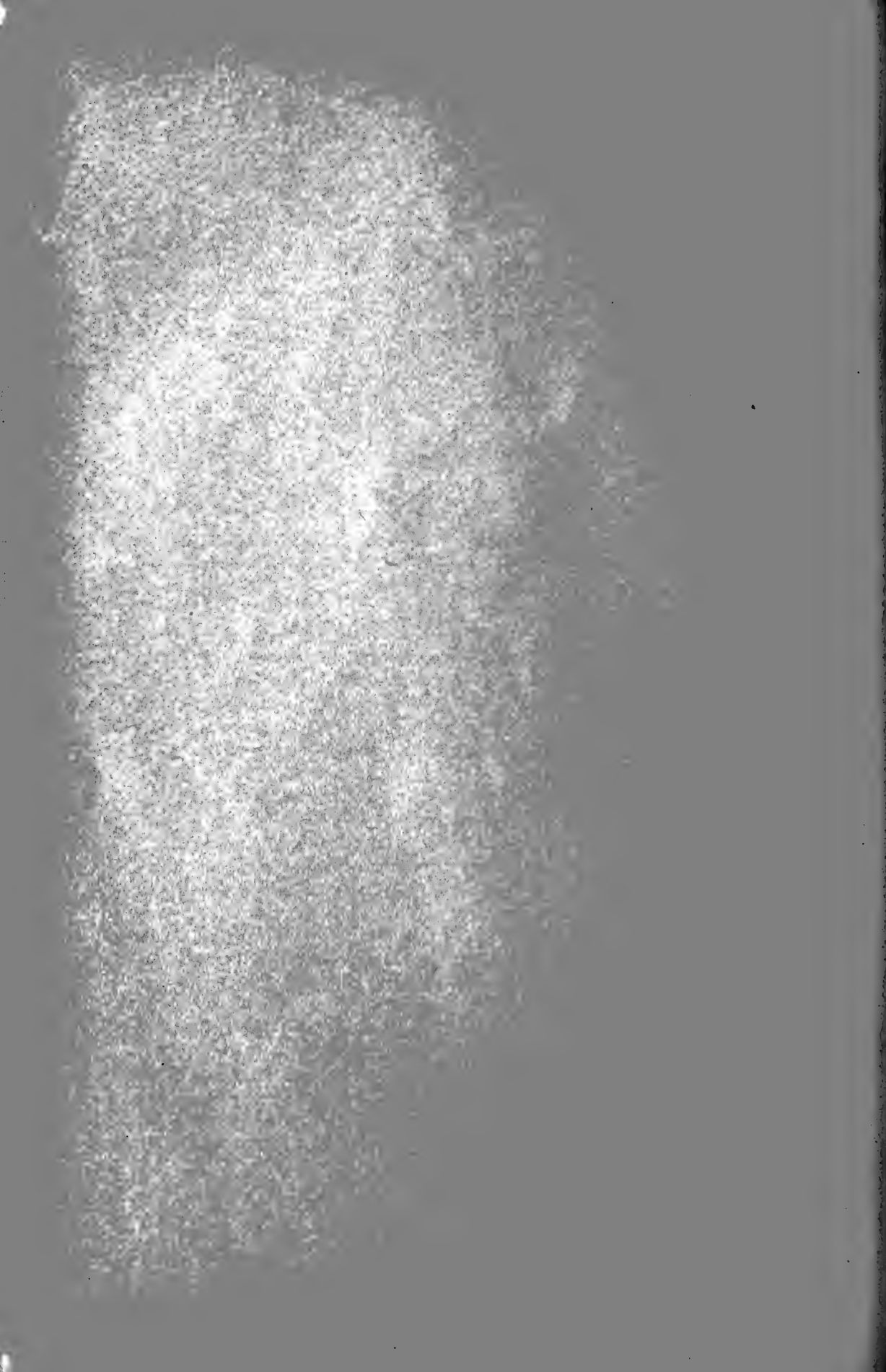
The gemellus and obturator internus cross the joint postero-externally. Cut them across.

Cut the deep gluteus across carefully and dissect up the stumps, uncovering the upper surface of the hip joint.

Find and clean the pubo-femoral or accessory ligament. What is its position and direction, and from what is it derived? Open up the joint to see the termination of this ligament and the round ligament. Slit the capsule in circular manner and examine its attachments. Examine the cotyloid and transverse ligaments and the joint surfaces.







#### THE STIFLE, LEG, AND HOCK.

The principal superficial features to be identified are as follows: The condyles, tuberosity, crest, and malleoli of the tibia are distinct. The internal surface of the tibia is largely subcutaneous; crossing it very obliquely is the saphenous vein. The patellar ligaments are palpable. The inner ridge of the trochlea of the femur can be felt; also the internal epicondyle and the internal lateral ligament of the stifle. The head of the fibula can be located. The tuber calcis and the tendo Achillis form the posterior contour of the lower half of the leg. There is no prominence corresponding to the calf of the leg of man, since the upper parts of the leg muscles are covered here by the biceps femoris and semitendinosus. The anterior and lateral extensors are easily distinguished, as they are separated by a pronounced furrow.

Identify the stumps of the muscles which are inserted in the region of the stifle.

Place the limb with the front of the stifle facing you. Locate the three patellar ligaments. Slit the fascia over each and define them. Take care in doing so to avoid injury to the joint capsule; the latter is, however, covered by a layer of fat.

Complete the dissection of the insertions of the muscles of the thigh about the stifle. Special caution is necessary in dealing with the vastus intermedius to avoid injury to the thin upper pouch of the femoro-patellar joint capsule which lies between the muscle and the distal end of the femur.

Remove the skin from the leg and hock. Note the position of the large saphenous vein, which is then to be removed in cleaning the deep fascia.

The superficial layer of the deep fascia is largely tendinous in character since it furnishes insertion to certain muscles of the hip and thigh. The action of these muscles is by this means extended to the lower part of the limb—an important factor in locomotion, and in enabling the animal to stand in spite of the flexed state of the chief joints. Examine the fascia carefully. Identify the stumps of the muscles which act on it; these comprise the biceps femoris, semitendinosus, sartorius, and gracilis, which are to be thoroughly cleaned if this has not been done. Note the strong pointed prolongation of the fascia which blends with the anterior extensor tendon below the hock.

Place the limb with its outer surface facing you. Separate the anterior and middle branches of the biceps femoris and continue the division in the same direction through the aponeurosis to the insertion at the stifle. Separate the middle and posterior branches, and extend the division into the aponeurosis in the same direction. Reflect the anterior and middle branches. This partly exposes the outer head of the gastrocnemius and the peroneal nerve passing downward and forward over it.

Place the limb with its inner surface facing you. Clean the terminal parts of the sartorius and gracilis if this has not been done, and reflect their common tendon to its insertion.

Clean and define the insertions at the stifle of the adductor and semi-membranosus.


Clean the lower end of the semitendinosus. Find and define the tendon of this muscle which is inserted into the crest of the tibia; note the bursa which underlies it.


The internal head of the gastrocnemius is partly exposed. The femoral vessels are seen disappearing between it and the external head immediately behind the femur, and a little lower down the tibial nerve passes between the two heads. Clean and retain these structures. A little lower down are the popliteal lymph glands and fat, which may be removed.

The deep fascia on the back of the leg is complicated in arrangement and difficult to prepare satisfactorily. This is partly due to the fact that the biceps femoris and semitendinosus send tendinous continuations to the tuber calcis; these bands are incorporated in the deep fascia in front of the tendons of the gastrocnemius and the superficial digital flexor. Place the limb with its posterior surface facing you. Pull on the stumps of these muscles and note the tension of the fascia. The latter is thick and strong in the middle of the leg, but becomes (superficially) thin below, since the tendinous bands mentioned above are here on the deep face of the tendo Achillis.

Slit the deep fascia along the posterior border of the leg, from the angle of divergence of the biceps femoris and semitendinosus to the tuber calcis. Using the stumps of the muscles mentioned as a guide, reflect the fascial flaps from the tendons of the gastrocnemius and the superficial flexor.

Clean the two heads of the gastrocnemius. Observe and retain for the present the strong tendinous band which descends over the external head from the external supracondyloid crest. The peroneal nerve, which crosses the external head, may be cut off at the outer edge of the muscle. The furrow into which the femoral vessels and tibial nerve disappear indicates the division between the two heads; beginning here, separate the two heads as far as a natural division exists. Working from the inner side, dissect up the internal head from the underlying parts. Cut the internal head across two or three inches distal to its origin. In doing this begin at the inner side and raise the muscle, taking care not to cut into the superficial flexor. Separate the distal stump from the external head and the superficial flexor of the digit; turn it outward and secure it out of the way. In the space now exposed the large tibial nerve, a vein, and an artery descend. Dissect these off the muscles, noting the branches which the nerve sends to the muscles here.





Clean and isolate the superficial flexor of the digit, separating it from the external head of the gastrocnemius. To facilitate this the latter may be cut across near its origin if desired. Note carefully the arrangement of the tendons of these two muscles; observe also that many fibres of the external head of the gastrocnemius arise from the tendon of the superficial flexor. The band from the external supracondyloid crest and the tendinous continuations (tarsal tendons) of the biceps femoris and semitendinosus blend with the superficial flexor just above the middle of the leg.

Lay the limb with its outer surface facing you. Find the external lateral ligament of the stifle joint and clean it. The lateral extensor extends from the lower end of the ligament straight down the outer surface of the leg. Slit the fascia over this muscle. Reflect the posterior flap of fascia carefully to avoid injury to the small soleus muscle, which arises from the furrow behind the upper end of the lateral extensor. Clean the soleus and note its origin and insertion. 201

The complex arrangement of tendons and fascial bands inserted into the tuber calcis is now to be worked out. Place the limb with its posterior surface facing you. The tendinous apparatus which lies in front of the tendo Achillis may be resolved into two parts in the lower part of the leg, although this separation is in part artificial. The superficial band joins the tendon of the gastrocnemius about a handbreadth above the tuber calcis; its chief components are the tendon of the soleus, the band from the external supracondyloid crest, and part of the tarsal tendon of the semitendinosus. The deeper band divides distally into two branches which are inserted into the sides of the tuber calcis; it furnishes insertion to the biceps femoris and semitendinosus. Determine these connections and the mechanical action of the arrangement.

The fascia and muscles on the front and outer surface of the leg are now to be dissected. The lateral extensor is clearly defined by anterior and posterior furrows, into each of which an intermuscular septum passes. The muscle is crossed obliquely at its proximal end by the peroneal nerve; the anterior division of the nerve disappears into the furrow between the lateral and anterior extensors; the posterior division, after giving off a branch which enters the lateral extensor about an inch from its origin, descends in the anterior furrow. The other muscles of the group cannot be clearly distinguished from each other until the fascia is removed. 201  
460

Slit the proper fascia lengthwise over the lateral extensor and reflect the flaps. Examine the muscle. Do any of its fibres arise from the intermuscular septa? Unless great care is used, the synovial sheath of the tendon of insertion is opened; if so, determine its proximal end, and indicate it by a nick in the tendon.

Place the limb with its anterior surface facing you. Find and define the annular ligament at the distal end of the leg, so as to avoid cutting it in the next step. Slit the fascia down the front of the leg from the tuber-

osity of the tibia to the annular ligament, and reflect the flaps. Deal with  
205 the fascia on the front of the hock in like manner. In this procedure one  
206 is almost certain to open up the synovial sacs in connection with the  
tendons here. If so, examine them carefully.

Clean the muscles now exposed and indentify them. Isolate the anterior or long extensor, working from below upward and from each side. Where do you encounter difficulty and why? In dissecting along the outer side note the deep peroneal nerve descending in front of the intermuscular septum between the anterior and lateral extensors; also the nerve branches which enter the muscles in the upper third of the leg. Define the middle and distal annular ligaments. Examine the synovial sheath of the anterior extensor tendon and mark its proximal and distal ends. Remove the fascia from the angle of convergence of the anterior and lateral extensor tendons, taking care to preserve the small extensor brevis muscle which lies in this space.

Cut the anterior extensor across about the middle of the leg. Separate the proximal part from the peroneus tertius to the point where the common tendon of origin is reached. Reflect the distal part.

The peroneus tertius and tibialis anterior are now exposed and are to be cleaned. They are fused in the middle of the leg, the peroneus tertius being the tendon on the surface of the muscular mass. Flex the hock if possible, so as to slacken the muscles, and separate the latter from the tibia. Note the anterior tibial vessels descending on the outer surface of the tibia. Find the synovial pouch which descends from the outer part of the femoro-tibial joint under the origin of the peroneus tertius and extensor longus. Beginning below this, separate the peroneus tertius from the  
458 tibialis anterior. Clean their tendons on the front and inner side of the  
460 hock. It is now seen that the peroneus divides here, and allows the tendon of the tibialis anterior to come to the surface. Isolate the divisions of the tendon of the tibialis anterior. The principal one (so-called "cunean tendon") passes obliquely across the inner surface of the hock; note carefully its position and the bursa underlying it, as this tendon is sometimes cut for the relief of spavin. The other branch is thin and passes straight downward; it blends below with the corresponding branch from the peroneus tertius. In the foregoing procedure the complex synovial membrane in connection with the tendons is necessarily opened up and should be explored in order to understand its arrangement.

Follow the end branches of the peroneus tertius at the hock. To facilitate this, the tibialis anterior may be cut across at its emergence and the distal part reflected. There are two outer branches of the peroneus tertius, between which the anterior tibial artery passes; the superficial one furnishes the middle annular ligament, which loops around the anterior extensor tendon, and gives origin to fibres of the extensor brevis; the deep one is covered by the anterior tibial artery and the deep peroneal nerve.







Two anterior branches of the peroneus tertius may also be distinguished; one of these inclines inward, while the other passes straight downward to the distal tarsal bones and the proximal end of the metatarsus. They are intimately adherent to the capsule of the hock joint.

Place the limb with its posterior surface facing you and resume the dissection of the back of the leg and hock. Remove the fascia from the back and sides of the hock if this has not already been done.

Examine thoroughly the tendons which are attached to the tuber calcis. The superficial flexor tendon is wide here, and from this expansion there is given off on either side a strong flat band which is inserted into the tuber calcis. The tarsal tendons of the biceps femoris and semi-tendinosus blend with the superficial flexor tendon on either side; when these have been made clear they may be cut off, leaving short stumps for review.

Cut the outer clamp-like attachment of the superficial flexor tendon, and turn the latter inward to examine its deep surface and its bursa; determine the extent of the latter.

Cut the tendinous band which is attached to the gastrocnemius tendon, raise the latter and note the bursa in front of its insertion.

The deep muscles on the posterior face of the tibia are now to be prepared. Reflect out of the way the stumps of muscles and tendons already dissected; the stumps may be shortened if desired. Cut the soleus across and remove remnants of fascia and fat which may remain. In doing so the large tibial nerve is found descending behind the deep muscles; it is accompanied by a vein and usually by a small artery also. At the level of the tuber calcis the posterior tibial artery emerges and forms an S-shaped curve. These may be removed.

The deep muscles are enclosed by a special fascia which extends from the intermuscular septum behind the lateral extensor to the subcutaneous surface of the tibia. Clean this fascia thoroughly, so that the muscles show through it more or less. An oblique depression indicates the division between the triangular popliteus muscle above and internally and the deep flexor below. The popliteal vessels are seen passing down between the condyles of the femur and disappearing under the popliteus.

Clean the popliteus and outline its edges. Above it is seen the capsule of the femoro-tibial joint, which conforms to the condyles of the femur. Clean the capsule and remove the popliteal vessels. The tendon of origin of the popliteus is partly invested by the synovial membrane of the outer sac of the joint capsule. Slit the capsule over the external condyle and examine the arrangement. The actual origin of the tendon is covered by the external lateral ligament and will be seen later.

Slit the fascia lengthwise from the popliteus downward over the middle of the region; reflect the flaps, working from below, since superficial fibres of the deep flexor (tibialis posterior) arises from the fascia.

Isolate the inner head of the deep flexor (flexor accessorius s. dig. longus), which extends obliquely over the back of the region. Its tendon is visible on the inner side of the distal third of the leg. Slit the thick  
205 fascial sheath over the tendon, raise the latter, and examine its synovial sheath. Dissect the muscle up; note the groove in which it lies, and the posterior tibial vessels which it covers.

The remaining muscular mass comprises a small superficial head (tibialis posterior) and a large deep head, the deep flexor proper (flexor hallucis); the two are, however, largely fused in the horse. By beginning below and internally the thin tendon and belly of the tibialis posterior may be separated partially from the flexor hallucis. Open and explore the upper part of the tarsal synovial sheath of the deep flexor tendon at the distal end of the leg. Clean the inner surface of the tarsus and proximal end of the metatarsus and identify the internal lateral ligament of the hock. Clean the posterior surface similarly to expose the plantar ligament. A thick annular ligament extends obliquely across between  
458 these two ligaments and binds down the deep flexor tendon. Slit this  
459 annular ligament, exposing the tendon and tarsal synovial sheath. With these are the plantar nerves and vessels, which may be removed. Explore the tarsal sheath.

#### THE METATARSUS AND DIGIT.

Remove the skin from the remainder of the limb. Most of the dissection from this point down is the same as in the thoracic limb, to the description of which reference is to be made. The principal differences are as follows.

458 The inner head of the deep flexor is to be followed to its junction with the chief tendon. The subtarsal check ligament is very much smaller than the corresponding band of the forelimb—it may indeed be only a weak strand of fibrous tissue or even entirely absent.

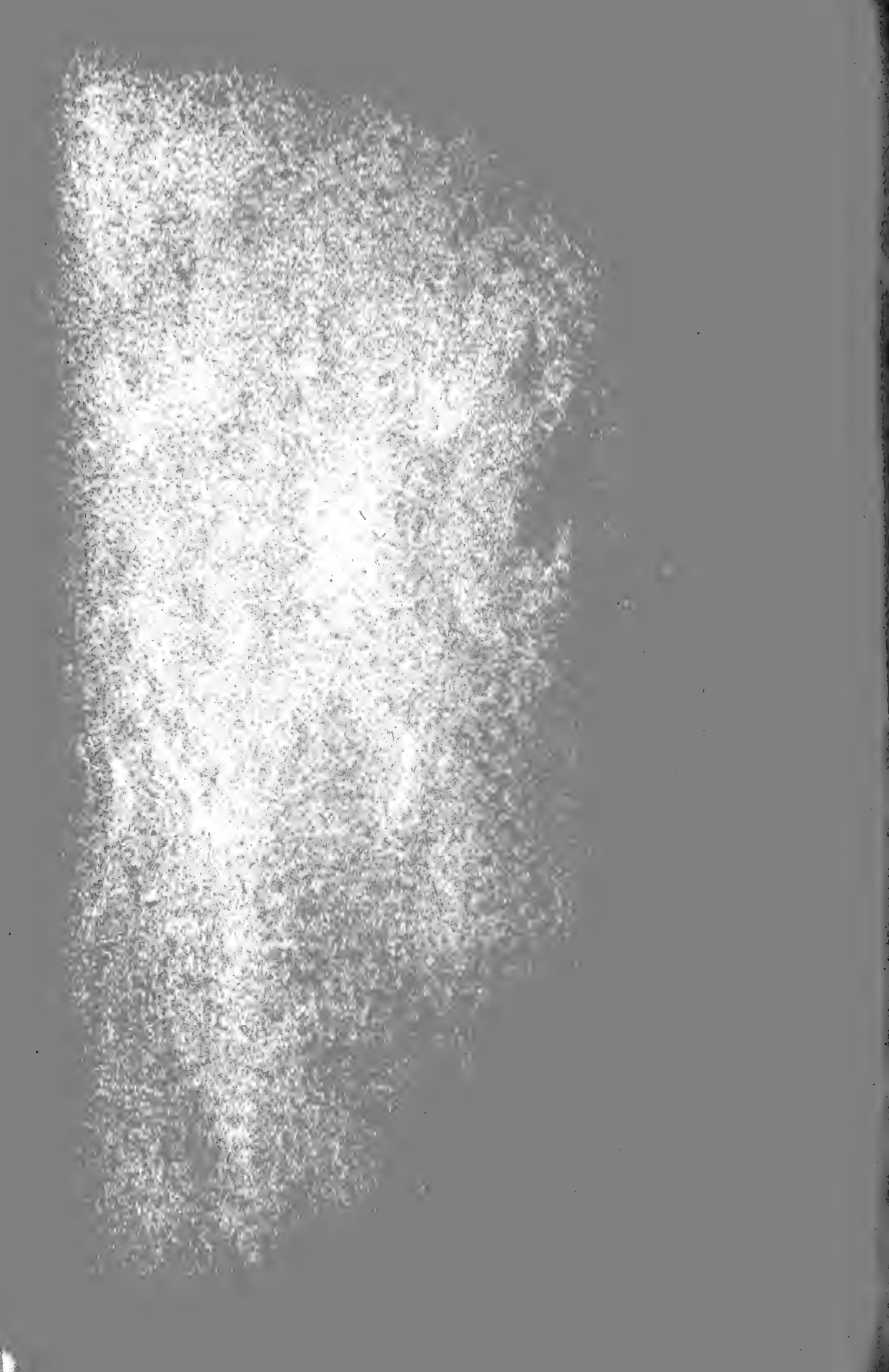
201 The tendon of the lateral extensor commonly blends with that of the  
460 anterior extensor about one-fourth of the way down the metatarsus. The position of the lateral extensor tendon below the hock should be carefully noted, as it is sometimes divided here for the relief of stringhalt. Divide the extensor brevis and note the great metatarsal artery crossing obliquely under it and the lateral extensor tendon.

#### THE STIFLE JOINT.

Part of the preparation of the joint has been done incidentally in previous dissection. It is well first to review the relations of the muscles to the joint.

156 If the capsule of the femoro-patellar joint is intact, endeavor to inflate  
161 it to determine its potential size and shape. Note its upper pouch; how high up does it extend? Does the capsule bulge on the sides? Clean it





on each side; here it is strengthened by the lateral femoro-patellar ligaments (retinacula). If the joint capsule has been damaged so that it cannot be inflated it is desirable to pack it with cotton or tow.

The anterior surface of the patella is partly covered by a tendinous layer coming from the rectus femoris; remove this. Examine and remove the patellar insertion of the biceps femoris.

Examine the patellar ligaments. Review and remove the tendons which are attached to them. Carefully clean out the fat which lies between and beneath the ligaments, exposing the lower, very thin part, of the joint capsule. 155  
157  
460

Clean thoroughly the lateral ligaments, if this has not been done. Determine the origin of the popliteus. This muscle may be cut across and the stumps reflected; it covered the popliteal vessels and their division into anterior and posterior tibial branches.

Examine the posterior part of the femoro-tibial capsule. Here there are evidently two sacs, correspondingly to the double nature of the joint surfaces. The outer sac has been opened. Remove both, exposing the condyles of the femur, the semilunar cartilages, the edges of the condyles of the tibia, and the crucial ligaments. Take care not to cut away the femoral ligament of the external semilunar cartilage. 459

The crucial ligaments lie between the two synovial sacs of the joint. Clean them as far as possible at this stage.

Flex and extend the joint, and note especially the movements of the semilunar cartilages and the effects on the crucial ligament.

Turn the joint over. Cut the femoro-patellar capsule above and on each side. Determine whether its cavity communicates with the femoro-tibial joint. If unable to find any opening, ask an instructor to demonstrate the point.

Turn the patella and its ligaments down. Flex the joint and expose the anterior part of the semilunar cartilages and the anterior crucial ligament. (The crucial ligaments may be more fully exposed if desired by sawing off the internal condyle of the femur, care being necessary, however, to avoid damaging the femoral end of the posterior ligament).

Disarticulate the femoro-tibial joint by cutting the lateral and crucial ligaments and the femoral attachment of the external semilunar cartilage. Examine the joint surfaces and the semilunar cartilages, noting the attachments of the latter. Observe the peculiar arrangement of the popliteus tendon, and the synovial pouch which descends under the tendon of origin of the peroneus tertius and anterior extensor. 158  
159.

Remove the muscles which conceal the fibula and the interosseous ligament. Note the opening in the upper end of the space, through which the anterior tibial vessels pass to the front of the tibia. Open the capsule of the tibio-fibular joint.

## THE HOCK JOINT.

If desired for convenience of handling, the lower part of the limb may be separated by cutting the soft tissues and sawing through the distal third of the tibia.

166 Review the arrangement of tendons, synovial sheaths, and bursae  
205 about the joint. It is advisable to attempt to inflate the tibio-tarsal  
206 joint capsule before cutting away the tendons or beginning the dissection of the ligaments. If unfortunately the capsule is already damaged, open it up and explore the joint cavity.

Remove the tendons from the front and back of the joint. Examine the anterior part of the capsule. Why does it bulge chiefly at its inner part when distended? Observe the nature of the posterior part of the capsule. How does it differ from the anterior part?

162 Remove these parts of the capsule and define clearly the lateral liga-  
163 ments and their divisions.

164 Clean and examine the dorsal (or oblique) and plantar (or calcaneo-  
165 metatarsal) ligaments.

Cut the lateral ligaments and examine the joint surfaces of the tibia and the tibial tarsal bone. The more important intertarsal ligaments may be recognized by undertaking the separation of the bones.




# **Veterinary Dissection Guide**


## **PART I**

**Copyrighted by S. Sisson  
Columbus, Ohio  
1911**













LIBRARY OF CONGRESS



0 002 829 001 9